

Transactions

American Laryngological Association

EIGHTY-SIXTH VOLUME

"DOCENDO DISCIMUS"

TRANSACTIONS
OF THE
EIGHTY-SIXTH ANNUAL MEETING
OF THE
American
Laryngological Association

1965

HELD AT
THE BROADMOOR
COLORADO SPRINGS, COLORADO
MAY 23 AND 24, 1965

PUBLISHED BY THE ASSOCIATION

ST. LOUIS, MO.

1965

Contents.

| | PAGE |
|--|------|
| List of Officers | 7 |
| Registration | 9 |
| President's Address: "Academic Tenure: Its Rights and Responsibilities," Albert C. Furstenberg, M.D. | 11 |
| Articular Reflex Mechanisms of the Larynx. John A. Kirchner, M.D. and Barry D. Wyke, M.B., B.S. | 16 |
| Discussion: | |
| K. Faaborg-Anderson, M.D. | 34 |
| Joseph H. Ogura, M.D. | 35 |
| Dr. Kirchner (closing) | 35 |
| The Use of Dermal Grafts in Otolaryngology. George F. Reed, M.D. | 36 |
| Discussion: | |
| Samuel Salinger, M.D. | 51 |
| Joel J. Pressman, M.D. | 51 |
| John A. Murtagh, M.D. | 52 |
| Dr. Reed (closing) | 52 |
| Histologic Changes in the Trachea Following Tracheostomy. Stanton A. Friedberg, M.D., Thomas E. Griffith, M.D. and George M. Hass, M.D. | 53 |
| Discussion: | |
| Anderson C. Hilding, M.D. | 66 |
| Dean M. Lierle, M.D. | 67 |
| Jerome A. Hilger, M.D. | 67 |
| George F. Reed, M.D. | 67 |
| John F. Daly, M.D. | 67 |
| Dr. Friedberg (closing) | 68 |
| Question: Francis L. Lederer, M.D. | 68 |
| Comment: William W. Montgomery, M.D. | 68 |
| Reply: Dr. Friedberg | 68 |

CONTENTS

| | PAGE |
|--|------|
| Histologic Changes Produced by Endotracheal Intubation. Francis A. Sooy, M.D. and Walter L. Way, M.D. | 69 |
| Comment: Dr. Sooy | 82 |
| Discussion: | |
| Daniel C. Baker, Jr., M.D. | 82 |
| Paul H. Holinger, M.D. | 82 |
| Walter P. Work, M.D. | 83 |
| Joel J. Pressman, M.D. | 83 |
| Joseph H. Ogura, M.D. | 84 |
| Paul M. Moore, M.D. | 84 |
| Dr. Way (closing) | 84 |
| Glomus Tumor of the Larynx. James D. Baxter, M.D. | 86 |
| Discussion: | |
| K. Faaborg-Andersen, M.D. | 93 |
| Dr. Baxter (closing) | 93 |
| Osteoplastic Frontal Sinus Approach: Coronal Incision. William W. Montgomery, M.D. | 94 |
| Discussion: | |
| Robert L. Goodale, M.D. | 104 |
| Sam H. Sanders, M.D. | 104 |
| Henry L. Williams, II, M.D. | 106 |
| Harry P. Schenck, M.D. | 107 |
| Jerome A. Hilger, M.D. | 107 |
| Dr. Montgomery (closing) | 108 |
| Observations on Frontal Sinus Obliteration. Robert L. Goodale, M.D. | 109 |
| Discussion: | |
| Sam H. Sanders, M.D. | 118 |
| G. Slaughter Fitz-Hugh, M.D. | 119 |
| Joel J. Pressman, M.D. | 120 |
| Dr. Goodale (closing) | 120 |

CONTENTS

| | PAGE |
|---|------|
| Rhinological Methods for Controlling Nasal Polyposis and Vasomotor Rhinitis. Francis L. Weille, M.D. | 122 |
| Discussion: | |
| Joseph L. Goldman, M.D. | 131 |
| Samuel Salinger, M.D. | 131 |
| Edley H. Jones, M.D. | 132 |
| Sam H. Sanders, M.D. | 132 |
| Dr. Weille (closing) | 132 |
| Lipoma: Epiglottis, 1947; Hypopharynx, 1961; (Same Patient). Watt W. Eagle, M.D. | 133 |
| Discussion: | |
| Francis E. LeJeune, M.D. | 144 |
| Francis W. Davison, M.D. | 145 |
| F. Johnson Putney, M.D. | 145 |
| G. Slaughter Fitz-Hugh, M.D. | 145 |
| J. Allan Fields, M.D. | 146 |
| Dr. Eagle (closing) | 146 |
| Mast Cells of the Upper Respiratory Tract. Harry P. Schenck, M.D. | 147 |
| Discussion: | |
| Herbert H. Harris, M.D. | 157 |
| David A. Dolowitz, M.D. | 157 |
| Dr. Schenck (closing) | 159 |
| Teflon Injection of Posterior Pharyngeal Wall as an Aid to Velo-Pharyngeal Closure. Robert B. Lewy, M.D. and Joseph Wepman, Ph.D. | 160 |
| Discussion: | |
| K. Faaborg-Andersen, M.D. | 165 |
| Arthur J. Cracovaner, M.D. | 166 |
| William W. Montgomery, M.D. | 166 |
| Dr. Lewy (closing) | 166 |

CONTENTS

PAGE

| | |
|---|-----|
| Nerve Grafting to Restore Function of the Trapezius Muscle After Radical Neck Dissection. Herbert H. Harris, M.D. and J. R. Dickey, M.D. | 168 |
|---|-----|

Discussion:

| | |
|-------------------------------|-----|
| Walter P. Work, M.D. | 175 |
| Delmar F. Weaver, M.D. | 176 |
| John J. Conley, M.D. | 176 |
| Emanuel M. Skolnik, M.D. | 177 |
| Dr. Harris (closing) | 178 |

Memorials:

| | |
|--------------------------------|-----|
| Howard Charles Ballenger | 180 |
| Murdock Sykes Equen | 183 |
| Colby Hall | 187 |
| Fielding Otis Lewis | 190 |
| Robert Carson Martin | 193 |

| | |
|---|-----|
| Executive Sessions and Reports of Officers and Committees | 197 |
|---|-----|

| | |
|-------------------------------------|-----|
| Presentation of Newcomb Award | 213 |
|-------------------------------------|-----|

| | |
|-----------------------------|-----|
| List of Fellows, 1965 | 215 |
|-----------------------------|-----|

| | |
|-----------------------------|-----|
| Active Fellows | 216 |
| Honorary Fellows | 223 |
| Corresponding Fellows | 223 |
| Emeritus Fellows | 224 |

| | |
|-------------------|-----|
| Benefactors | 226 |
|-------------------|-----|

| | |
|--|-----|
| Recipients of the de Roaldes Award | 227 |
|--|-----|


| | |
|---|-----|
| Recipients of the Casselberry Award | 228 |
|---|-----|

| | |
|---------------------------------------|-----|
| Recipients of the Newcomb Award | 229 |
|---------------------------------------|-----|

| | |
|---------------------|-----|
| Past Officers | 230 |
|---------------------|-----|

| | |
|--------------------|-----|
| Past Fellows | 235 |
|--------------------|-----|

| | |
|-------------|-----|
| Index | 243 |
|-------------|-----|



THOSE IN ATTENDANCE AT THE EIGHTY-SIXTH ANNUAL MEETING

Identification as seen from the front, left to right: *front row*, McHenry, Tabb, Hanckel, Miller, Montgomery, Reed, Skolnik, Bordley, Kirchner, Moore, Baker, Alfaro, Davison, Sisson; *second row*, Hoople, Brown, Clerf, Kings, Weaver, Richards, Furstenberg, LeJeune, Holinger, Hilding, Putney, Salinger, Roberts, Richter (not a member); *third row*, Tolan, Erich, Silcox, Hilger, Williams, Theobald, Hansel, Schenck, Walsh, Pressman, Fitz-Hugh, Eagle, Jones, Cracovaner, Cody, Sanders, Harris, Weille, Goodale, Meltzer, Woodman, Faaborg-Andersen, MacCormick, Conley; *fourth row*, Work, Botes, Perez, Friedberg, Goldman, Murtagh, Priest, Van Alyea, Daly, Ogura, Heatly, Lederer, Tremble, Knight, Saunders, Levy, Lindsay.

OFFICERS FOR 1964-1965

PRESIDENT

ALBERT C. FURSTENBERG, M.D.

FIRST VICE-PRESIDENT

G. SLAUGHTER FITZ-HUGH, M.D.

SECOND VICE-PRESIDENT

DANIEL C. BAKER, M.D.

SECRETARY

LYMAN G. RICHARDS, M.D.

TREASURER

ALDEN H. MILLER, M.D.

LIBRARIAN, HISTORIAN AND EDITOR

F. JOHNSON PUTNEY, M.D.

COUNCIL

The above Ex-officio and

EDWIN N. BROYLES, M.D.

DEAN M. LIERLE, M.D.

FRANCIS E. LEJEUNE, M.D.

ANDERSON C. HILDING, M.D.

TRANSACTIONS OF THE
EIGHTY-SIXTH ANNUAL MEETING

OF THE

American Laryngological Association

HELD AT

THE BROADMOOR

COLORADO SPRINGS, COLORADO

MAY 23 AND 24, 1965

The Eighty-sixth Annual Meeting of the American Laryngological Association was called to order by the President, Dr. Albert C. Furstenberg, at the Broadmoor, Colorado Springs, Colorado on May 23, 1965, at 8:30 A.M.

REGISTRATION

ALFARO, VICTOR R.

BAKER, DANIEL C.

BAXTER, JAMES D.

BOIES, LAWRENCE R.

BORDLEY, JOHN E.

BROWN, LESTER A.

BROYLES, EDWIN N.

CLERF, LOUIS H.

CODY, CLAUDE C. III

CONLEY, JOHN J.

CRACOVANER, ARTHUR J.

DALY, JOHN F.

DAVISON, FRANCIS W.

EAGLE, WATT W.

ERICH, JOHN B.

FITZ-HUGH, G. SLAUGHTER

FRIEDBERG, STANTON A.

FURSTENBERG, ALBERT C.

| | |
|----------------------------|----------------------|
| GOLDMAN, JOSEPH L. | PEREZ, ALFREDO C. |
| GOODALE, ROBERT L. | PRESSMAN, JOEL J. |
| HANCKEL, RICHARD W. | PRIEST, ROBERT E. |
| HANSEL, FRENCH K. | PUTNEY, F. JOHNSON |
| HARRIS, HERBERT | REED, GEORGE F. |
| HEATLEY, CLYDE A. | RICHARDS, LYMAN G. |
| HILDING, ANDERSON C. | ROBERTS, SAM E. |
| HOLINGER, PAUL H. | SALINGER, SAMUEL |
| HOOPLE, GORDON D. | SANDERS, SAM H. |
| JONES, EDLEY H. | SAUNDERS, WILLIAM H. |
| KING, JAMES T. | SCHENCK, HARRY P. |
| KIRCHNER, JOHN A. | SILCOX, LOUIS E. |
| KNIGHT, JOHN S. | SISSON, GEORGE A. |
| LEDERER, FRANCIS L. | SKOLNIK, EMANUEL M. |
| LEJEUNE, FRANCIS E. | SOOY, FRANCIS A. |
| LEWY, ROBERT B. | TABB, HAROLD G. |
| LIERLE, DEAN M. | THEOBALD, WALTER H. |
| LINDSAY, JOHN R. | TOLAN, JOHN F. |
| McHENRY, LAWRENCE C. | TREMBLE, G. EDWARD |
| McNALLY, WILLIAM J. | VAN ALYEA, OLIVER E. |
| MELTZER, PHILIP E. | WALSH, THEODORE E. |
| MILLER, DANIEL | WEAVER, DELMAR F. |
| MONTGOMERY, WILLIAM W. | WEILLE, FRANCIS L. |
| MOORE, PAUL M. | WILLIAMS, HENRY L. |
| MUNOZ-MACORMICK, CARLOS E. | WOODMAN, DEGRAAF P. |
| MURTAGH, JOHN A. | WORK, WALTER P. |
| OGURA, JOSEPH H. | |

SCIENTIFIC SESSION

SUNDAY MORNING, MAY 23, 1965

The first Scientific Session of the Eighty-sixth Annual Meeting of the American Laryngological Association, held at The Broadmoor, Colorado Springs, Colorado, on Sunday morning, May 23, 1965, convened in the Theater at nine-ten o'clock, Albert Carl Furstenberg, M.D., St. Joseph's Mercy Hospital, Ann Arbor, Michigan, President of the Association, presiding.

PRESIDENTIAL ADDRESS

ACADEMIC TENURE: ITS RIGHTS AND RESPONSIBILITIES

ALBERT C. FURSTENBERG, M.D.

There is nothing new in the issues that I bring to you at this Eighty-sixth Annual Meeting of the American Laryngological Association. They are time-worn issues that have been in evidence in academic life repeatedly, have never been solved and spring up periodically with renewed vigor in many of our medical schools today. I refer to academic tenure in medical education.

Since the turn of the century reforms in medical teaching and academic tenure have been proposed innumerable times in most of the medical schools of this country. Moreover, discussions of the problems pertaining to this delicate subject too often give rise to acrimonious disputes and internal dissension by those who are engaged in them. As we progress, therefore, in this modern age of medicine, we might give heed to the conflicts of the past and assume a more realistic appraisal of the thing we call right of academic tenure.

In the early years of American medical education the teachers of the basic sciences were recruited from the leading practitioners of the community. Local doctors taught the fundamental sciences and because their stipends were small they had to support themselves by devoting most of their time to the care of private patients.

The evolution of medicine, with its rapid discoveries in the basic sciences soon overwhelmed the practicing physician and left him submerged in a deluge of literature in scientific research which he had neither the time nor the ability to comprehend.

It thus became evident that teaching of the basic sciences could not be entrusted to local practitioners of medicine and that the laboratories of these sciences should be reorganized and staffed by young men of scientific rectitude and that skill and competence in teaching and research should be the important criteria for their incumbency. When this was accomplished the newly appointed members of the pre-clinical faculties rapidly developed in the scientific field and promulgated new concepts of medical education, which laid the foundation for our present curriculum. Furthermore, their activities led to the organization of various units and subdivisions and ultimately to departmentalization as we find it today in the fields of the basic sciences.

When the teaching of the fundamental sciences had been taken away from the practitioners of medicine and given to scientifically trained men not engaged in private practice, there came a cry for reform in the clinical departments of medicine. It was said that these services should be staffed by men possessed of talents and objectives similar to those of the professors in the fundamental sciences and that they should carry on research in the wards and laboratories which would lead to important contributions to medical knowledge. Like the basic science teachers, they should give all their time and effort to hospital work, teaching and clinical research; they should be well paid by the university; they should not engage in private practice; consultations should be permitted in exceptional instances, but the fees received from them should be contributed to the budget of the hospitals themselves.

Thus, since 192 a comparison of the advantages and disadvantages of full-time and part-time has been the subject of controversial discussion in most of the medical schools of this country. Academic ideals have been emphasized by the proponents of full time. Single-minded devotion to the university, they say, can be expected only from those clinical teachers who are devoid of an absorbing outside practice. In contrast the advocates of part time lean heavily upon the contention that full time limits the opportunities for mental growth, restricts clinical interest and stifles ambition. The same arguments that were posed sixty-five years ago are always in evidence when

this dispute arises and the same conclusion is usually reached, namely, a compromise which includes both full-time and part-time programs in the medical schools, which unhappily become the victims of this controversy.

In the Medical School of the University of Michigan, as in many of the medical schools of this country, both full-time and part-time men hold responsible positions in their respective departments. It is impossible to distinguish one from the other in terms of service to our School.

During the twenty-five years that I have served as Dean of the Medical School we have assumed that both plans are consistent with American ideals and the best interests of the University. We have held to the belief that the fate of the Medical School does not depend upon full time or part time, but upon the will and the spirit of the faculty.

Fortunately for me I have administered my office as Dean of the Medical School for nearly twenty-five years under the leadership of two distinguished presidents. Both of these gentlemen gave me their unfailing support on all occasions. When it became necessary to make new appointments in various departments, the Executive Committee was consulted and their approval obtained. If the president approved our recommendation he promptly sent it to the Board of Regents for their endorsement.

What I want to emphasize is this: in not a single instance did these two gentlemen ever mention full-time or part-time tenure. Their emphasis was on character, competence, loyalty and willingness to cooperate with fellow members of the faculty. It was with this spirit of competence and good will that I enjoyed my twenty-four and one-half years as an administrator in my Alma Mater.

Now, I have one more problem to bring briefly to your attention:

In 1850 the Regents of the University of Michigan dedicated the Medical School to the purpose of training young men and women to be practitioners of medicine. They had, of course, two other important purposes in mind, namely, the care of the sick and medical research. Everyone agrees that where there is no research there can be no progress in medicine. A medical school is only as strong as the chain that links together a sound educational program, unimpeachable medical practice and research worthy of its name.

What has happened to many of our medical schools today is that research dominates the picture. In 1906 Congress increased the annual expenditures for medical research to \$3 million; by 1917 it was \$186 million; subsequently it reached \$400 million; and now it is well on its way to one billion dollars. These funds are supposed to go to projects limited by law to research and traineeships and therefore are not intended to be available for undergraduate medical education. Grants from Federal sources, which are limited to research programs, now represent about 54 per cent of the total expenditures of the medical schools of this country and the ratio is greater than 70 per cent in a number of our schools. Together with gifts from industry, voluntary health agencies, foundations and private donors, the contributions add immeasurably to the domination of research at the expense of equally important obligations to our students.

Some of our medical schools today are in reality research institutes, not teaching centers. The young men on the resident staffs realize that if they want the best appointments, academic advancement and higher compensation, it is more promising to become an investigator than a teacher. Thus the trend for them is a challenging research project, generous Federal aid, adequate laboratory facilities and equipment and rapid promotion to rank.

Our educators are fully aware of the teacher shortage in the colleges and universities of this country. The field is exceedingly barren. One of our distinguished Regents, Paul G. Gobel, prepared a brochure emphasizing the need for more teachers and urging us to recognize this need and give it our unfailing support. His plea has become an axiom on our campus: "Give us the teachers." He emphasizes that it takes time to train a college or a university teacher and it takes even more time to develop men and women who can combine with teaching competence the ability to discharge the universities' second great obligation, which is to increase knowledge through research. That is an important sentence, I think, "to increase knowledge through research."

The supply of teachers is increasing as more and more young men and women go on to graduate study and as more and more elect academic careers, but it will be years, and even decades before there is any such balance between supply and demand as existed before 1940.

What we need now are competent, well qualified teachers who are motivated by academic life and dedicated to the field of education

and, what is equally important, their compensation should be enough to give them a place of dignity and security in their chosen field. Moreover, academic tenure must be granted to our teachers as soon as they qualify for professorial rank.

I am unable to reconcile to modern medical practice the time-honored tradition that the teacher enjoys starving in his attic. In spite of idealistic pronouncements to the contrary, it would seem to me that a man virile enough to be a good teacher is also sufficiently hearty to enjoy his food. Those sensitive souls who talk about one's love for teaching and believe that those engaged in it do not claim an utilitarian value for what they accomplish have never had the administrative experience of a dean.

ARTICULAR REFLEX MECHANISMS IN THE LARYNX

JOHN A. KIRCHNER, M.D.

BARRY D. WYKE, M.B., B.S.
(by invitation)

NEW HAVEN, CONN.

Do the muscles controlling the vocal cords possess a postural reflex mechanism comparable to that existing in the extremities? Buchthal¹ demonstrated increased electromyographic activity in the cricothyroid and thyro-arytenoid muscles with rising vocal pitch. He showed further that this increase in motor unit activity begins before the sound is produced. This observation implies that a singer or speaker adjusts the tension of the vocal cords to that required by a given pitch, before producing it. These and other findings imply that there exists in the laryngeal structures a monitoring receptor system which signals vocal cord position, movement and tension in the laryngeal muscles and is, therefore, independent of any additional adjusting influence signalled by the hearing mechanism after the sound is emitted.

Smoothness and precision of rapid movement are characteristic of laryngeal muscle activity, and, by analogy with other muscles, presumably depend upon several systems of controls operating unconsciously (that is, reflexly). The most important of these control mechanisms in striated muscles generally is based on the "feed-back" or "servo-mechanism" principle, in which a sensing element signals any deviation from the required condition or result. This deviation is then used to increase (positive feed-back) or decrease (negative feed-back) the power output of the mechanical controls, thereby reducing the performance error to a minimum. An example of such a feed-back system is the automatic pilot on an airliner. The device keeps the course fixed in relation to a compass setting by sensing any

From the Otolaryngology Section, Department of Surgery, Yale University School of Medicine, New Haven, Connecticut, and the Neurological Laboratory, Department of Applied Physiology, Royal College of Surgeons, London, England.

small departure from the required course, and passing a positive or negative signal back to the rudder controls.²

Similar "feed-back" mechanisms are involved in most biological activities. Thus, contraction of the pupil in the presence of increasing illumination depends upon the ability of the rods and cones to detect light, and to transform its energy into a series of afferent nerve impulses which reflexly cause contraction of the sphincter muscle of the iris. This is an example of the positive feed-back principle.

In the extremities, the position of the limbs and the related muscle tension are signalled by special pressure-sensitive end organs located in the joints, tendons and muscles themselves. In this way, for example, swaying movements during standing provoke fluctuating signals not only from the vestibular apparatus, but also from stretch receptors in the muscles of the legs, trunk and neck that adjust the tone of the muscles. In addition, a most important contribution to reflex postural regulation, as well as to position sense, is made by mechanoreceptors in the ankle, knee and vertebral joint capsules. These articular receptors initiate signals in response to joint movement which produce reflex contraction and relaxation of the appropriate extensor or flexor muscle groups so as to maintain the upright position. Under these conditions, the monitoring receptors in the muscles and joints can be said to "drive" the muscle activity.

What evidence is there, then, for a similar proprioceptive mechanism in the larynx? Two essential components must be identified in such a system; first, receptor end organs in the laryngeal muscles or joints capable of initiating afferent impulses in response to movement, or to change in muscle tension; and second, detectable effects on the tone of the laryngeal muscles of stimulating these receptors or their afferent nerves, either electrically or by movement. Such effects might be demonstrable as visible movements of the muscles, or as changes in their pattern of electrical activity.

MECHANORECEPTOR END ORGANS IN MUSCLES AND JOINTS

Vertebrates possess mechanoreceptors in all organs and tissues in which active or passive movements occur, including the digestive tract, the lungs, the heart and the blood vessels, as well as the skin, joints, and skeletal muscles. These receptors feed into the central nervous system information about movement, tension and pressure.³

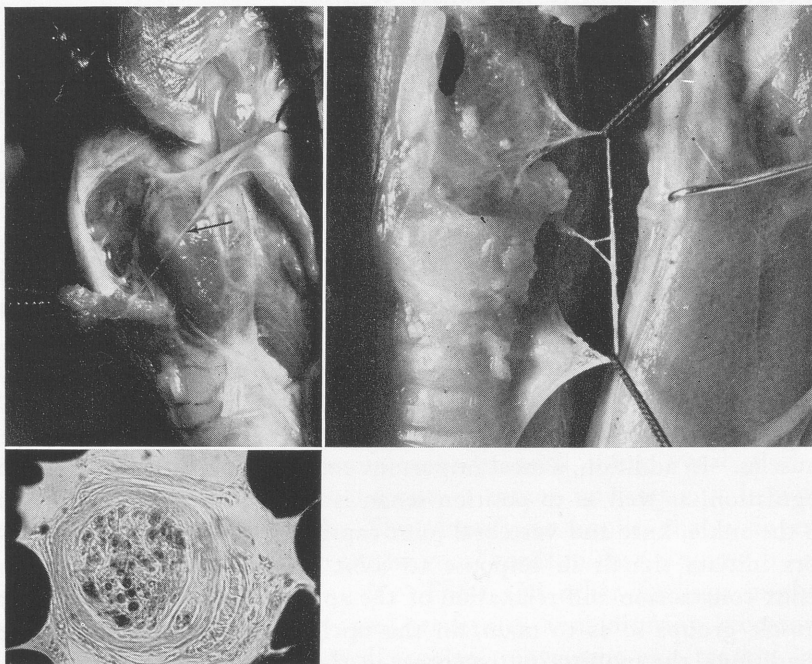


Fig. 1.—Articular nerve to cricothyroid joint capsule, arising, in this case, from the superior laryngeal nerve. The usual origin is from the recurrent.

Fig. 2.—Articular nerve to the cricoarytenoid joint capsule, arising from the ramus communicans. Cross section of such a nerve is shown in Figure 3.

Fig. 3.—Cross section of articular nerve to the cricothyroid joint capsule, arising from the recurrent laryngeal nerve.

Four types of mechanoreceptor end organ are found^{4,5} related to striated muscles, tendons and joints in most parts of the body: 1) muscle spindles in the muscles (low-threshold, very slowly adapting); 2) tendon organs of Golgi, and related Type III (v.i.) corpuscles in the joint ligaments (high-threshold, slowly adapting); 3) Ruffini corpuscles in muscle fasciae and joint capsules (low-threshold, slowly adapting); 4) modified Vater-Pacinian corpuscles in muscle fasciae and joint capsules (low-threshold, rapidly adapting).

The mechanoreceptors within the muscles (that is, the muscle spindles and tendon organs) do not contribute to the conscious perception of static position or movement of the extremities and vertebral

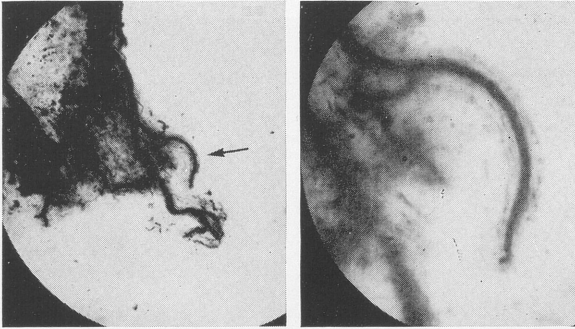


Fig. 4.—Single *Type II corpuscle* (indicated by arrow) teased out of a small cluster embedded in the superficial layers of the capsule of the cricothyroid joint. The same corpuscle is shown at higher magnification in Figure 5. Wyke gold chloride technique: teased preparation. Magnification X 300.

Fig. 5.—High-power view of the same *Type II corpuscle* seen in Figure 4, to show its internal structure. Wyke gold chloride technique: teased preparation. Magnification X 1200.

column: instead, they exert powerful feed-back influences on the unconscious (that is, reflex) regulation of tone in the related muscles.^{4,6} In contrast, the mechanoreceptors in the joint capsules (and particularly the Ruffini corpuscles) make a major contribution to the perception of posture and movement,⁶ as well as to the reflex regulation of muscle tone.^{7,8}

In the fibrous capsules of the limb joints, two distinct varieties of corpuscular endorgan have been identified histologically^{5,8-10} and physiologically.^{8,10-12} One is the Ruffini corpuscle (Type I ending)²⁶ which is a slowly adapting mechanoreceptor of varying threshold.^{10,11,13} Some of these corpuscles discharge continuously when the joint is at rest,^{8,10,11,13} while others become active when the joint is moved. The other type of articular mechanoreceptor (Type II ending)⁵ is a small, modified Vater-Pacinian corpuscle. This is a low-threshold, rapidly adapting receptor that remains inactive as long as the joint is at rest, but becomes transiently active at the moment movement occurs.

What types of receptor nerve endings have been found in the laryngeal muscles and joints?

Neurohistological studies of human laryngeal muscles^{14,15} have revealed organized nerve endings that are regarded by some workers

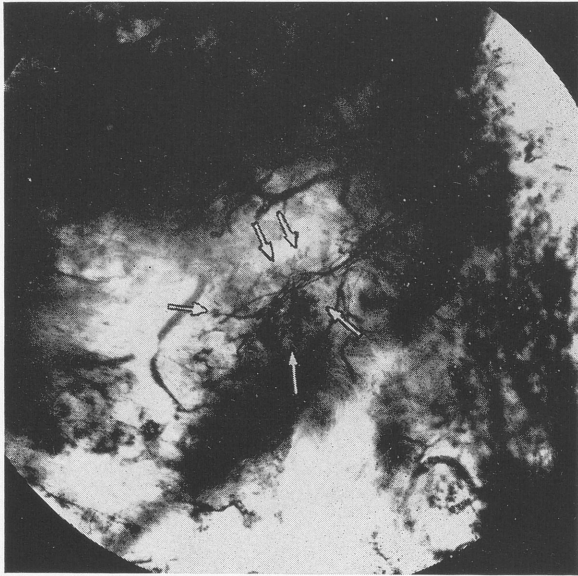


Fig. 6.—Cluster of *Type I corpuscles* (indicated by arrows) embedded in the capsule of the crico-arytenoid joint. The myelinated afferent fibers can be seen running to the edge of the capsule on the right. Fitzgerald frozen silver technique: 30 μ section. Magnification X 300.

as structurally analogous to the muscle spindles in skeletal muscles. Furthermore, the intrinsic laryngeal nerve trunks have been shown to include fibers whose diameters embrace the range of proprioceptive afferent fibers in the nerves supplying the limb muscles.^{16,17}

On the basis of these anatomical data, then, it has been assumed, contrary to the earlier views of Sherrington,¹⁸ that the intrinsic muscles of the larynx possess a proprioceptive reflex system driven by mechanoreceptors analogous to those in the skeletal musculature. Unfortunately, until lately attempts to demonstrate the operations of such a system by neurophysiological techniques have been equivocal¹⁹ or unsuccessful.²⁰ But very recently an animal experimental study²¹ has succeeded in demonstrating the unequivocal presence of myotatic (stretch) reflexes in the intrinsic muscles of the larynx (although the behavioral characteristics of these reflexes are somewhat different from the myotatic reflexes in the limb muscles).

In spite of this latter observation, however, modern students of the nerve impulse traffic provoked in afferent fibers of the laryngeal nerves by movement of laryngeal structures have felt^{19,22,23} that some of the afferent activity must come from mechanoreceptors located outside the laryngeal muscles themselves. Thus, in a recent study of the afferent activity in the internal laryngeal nerve associated with contraction of the intrinsic laryngeal muscles, Martensson²² suggested that some of the input was derived from extramuscular sources, "probably joints or tendons."

It is clear from available evidence, then, that although the intrinsic laryngeal muscles may be provided with proprioceptive mechanoreceptors, such a system cannot be the exclusive source of the reflex input that regulates and co-ordinates changes in their tension.

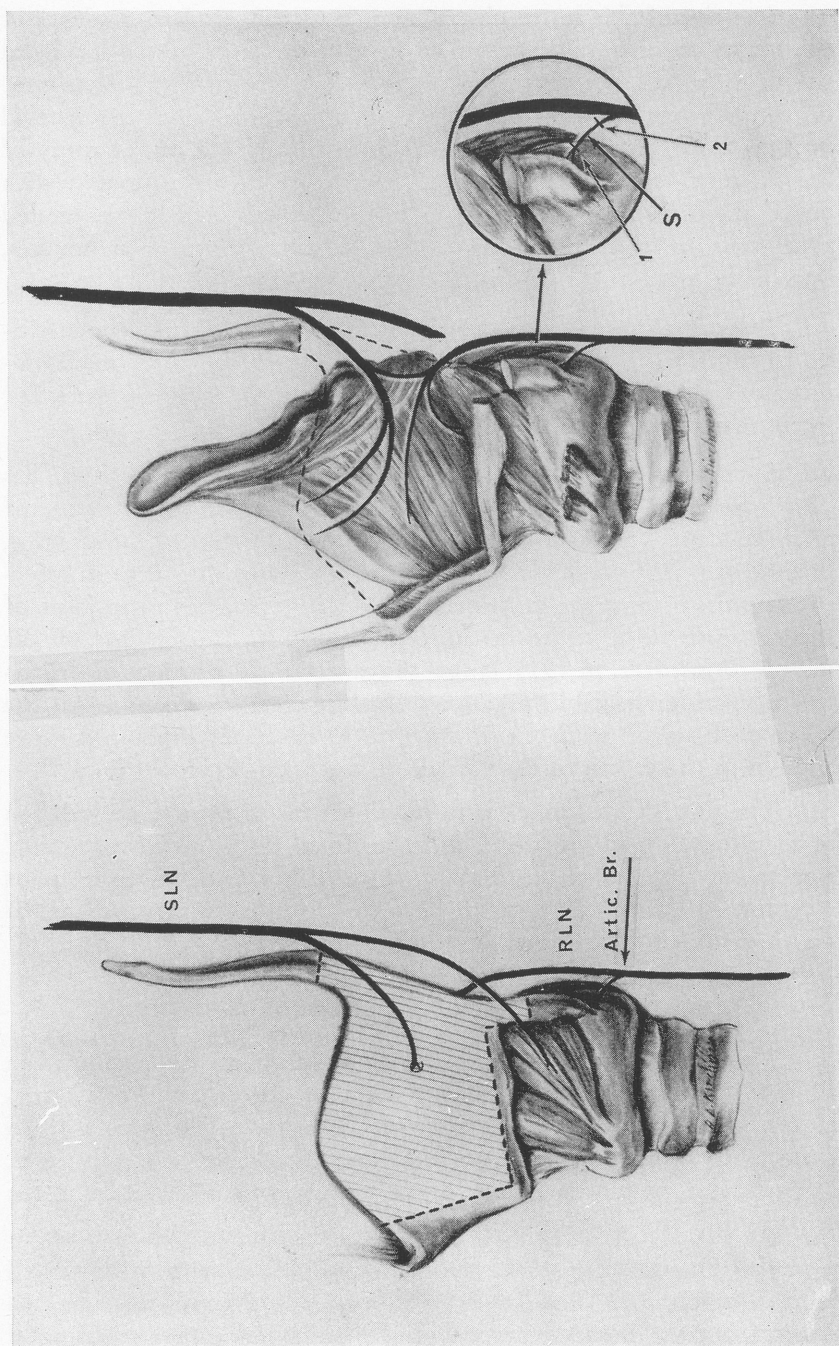
Surprisingly little attention, in view of these difficulties, has been given to the laryngeal joints as a possible additional source of afferent activity for the reflex control of the laryngeal muscles. This, in spite of Andrew's demonstration in 1954 of the discharge of afferent impulses from mechanoreceptors in the thyro-epiglottic joint of the rat, and their variations in frequency with movements of the joint.²⁴ Moreover, in 1959 Jankovskaya noted the presence of organized nerve endings in the regions of the laryngeal joint capsules of the cat and of man,²⁵ while Gracheva (1963) described organized nerve endings in the region of the capsule of the crico-arytenoid joint.²⁶

The present anatomical and physiological study was undertaken in the Neurological Laboratory of the Royal College of Surgeons of England to investigate specifically the possible role of laryngeal joint receptors in the coordination of laryngeal muscle activity, as part of a larger study of laryngeal proprioceptive mechanisms.

ANATOMICAL AND NEUROHISTOLOGICAL STUDIES

The innervation of the various laryngeal joints was examined in 31 cats.²⁷⁻²⁹ Microdissections were made of the cricothyroid, crico-arytenoid, thyrohyoid and thyro-epiglottic joints. The capsules in all these joints were found to have a direct extrinsic nerve supply; and, in particular, specific articular nerve trunks were identified for the cricothyroid and crico-arytenoid joints.

Specific articular nerve trunks supplying the crico-arytenoid joint were found in 11 of 31 preparations. These nerves were derived either from the internal branch of the ipsilateral superior laryngeal



nerve, or from the ramus communicans. Articular nerves to the cricothyroid joint were identified in 19 of 31 preparations. These nerves arose from the ipsilateral recurrent laryngeal nerve in 10 instances, from the ramus communicans in 4 instances, and from the internal branch of the ipsilateral superior laryngeal nerve in 2 instances. In two further preparations, the cricothyroid joint was supplied from both the recurrent and the internal laryngeal nerves; and in one instance from these two sources and from the ramus communicans as well (Figs. 1, 2, 3).

The capsule of each laryngeal joint was examined histologically in gold, silver and methylene blue preparations.²⁷⁻²⁹ Myelinated and unmyelinated articular nerve fibers were found ramifying in every joint capsule. This innervation is especially dense in the crico-arytenoid and cricothyroid joints. The fibers of the articular nerves, whose individual diameters extend up to about 15 microns, enter the joint capsule near its attachment to the perichondrium covering the laryngeal cartilages, and branch out amongst its fibrous layers—often in company with the articular blood vessels.

Both organized and unorganized nerve endings are present in every laryngeal joint capsule, again more densely so in the crico-arytenoid and cricothyroid joints. As these laryngeal articular nerve endings are similar in type to the articular nerve endings described by Wyke and his colleagues^{5,8,30-32} in the limb and temporomandibular joints, we have classified them according to the numerical system proposed by this group of workers.

The most numerous encapsulated end organ in all the laryngeal joints is the Type II corpuscle (similar to a miniature Vater-Pacinian corpuscle) (Figs. 4, 5). This is distributed throughout the fibrous capsule of each joint in small clusters of two or three corpuscles, each cluster being innervated by a myelinated nerve fiber averaging 10 microns in diameter. These end organs are more numerous in the crico-arytenoid and cricothyroid joints, and each is identical with the

Fig. 7.—Shaded area indicates portion of thyroid lamina removed for observation of intrinsic laryngeal muscles. The inferior cornu is left attached by its capsule.

Fig. 8.—Surgical preparation for observing laryngeal muscular response to electrical stimulation of the articular nerves. Insert: "S" is the point of stimulation. Cutting the nerve at point 1 produced no change in the response to stimulation at "S". Cutting the nerve at point 2 abolished the twitch response of the laryngeal muscles to stimulation at "S".

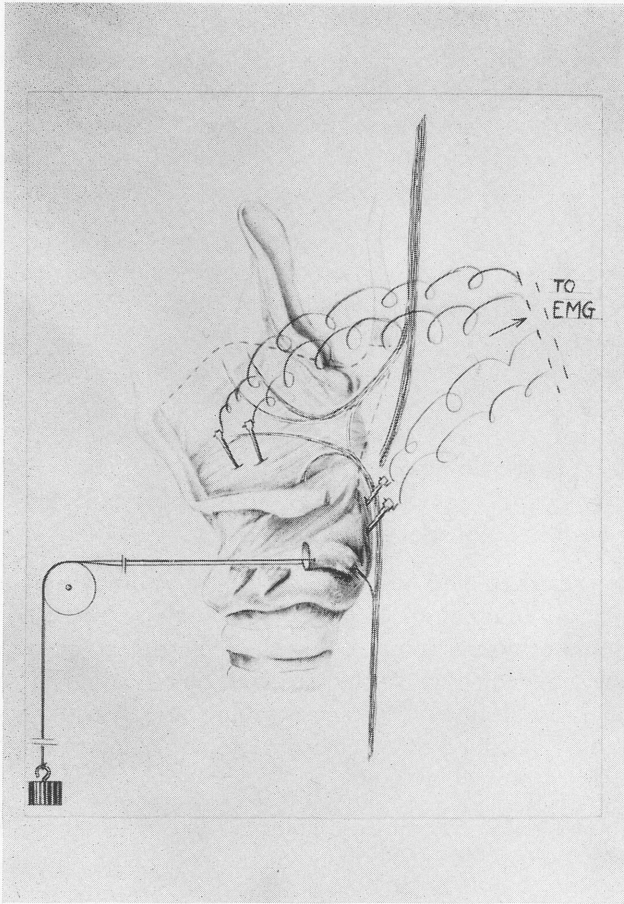


Fig. 9.—Electromyographic electrodes inserted into various laryngeal muscles during traction on the cricothyroid joint. Movement of the joint in caudal or antero-medial directions produced increased motor unit activity in the adductors, and simultaneous decreased activity in the abductors.

Type II corpuscles in the other joints of the same animal.^{5,8,31,32} On the other hand, *Type I* (Ruffini-type) corpuscles, although common in the limb joints,^{5,8,31} are extremely rare in the larynx (Fig. 6). The only laryngeal joint capsule in which we have seen them is that of the crico-arytenoid joint, where a few sparse clusters of *Type I* endings are embedded in the external layers of the fibrous capsule. Type III

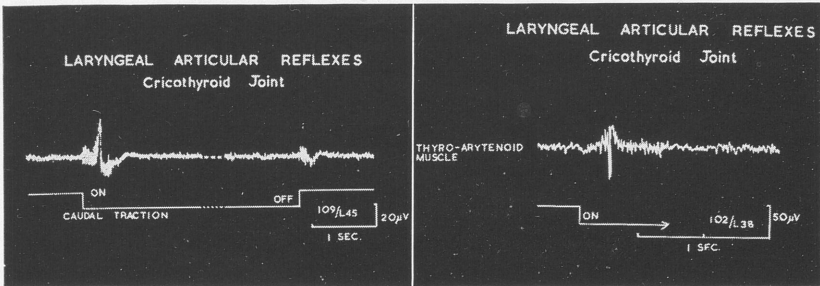


Fig. 10.—Rapidly-adapting “on” and “off” discharges in left cricothyroid muscle with traction (20 gm) on left cricothyroid joint (in caudal direction). Moderate general anesthesia with pentobarbitone. The large slow deflections are movement artifacts, on which the motor unit potentials are superimposed. Note the complete absence of any slowly-adapting response.

Fig. 11.—Rapidly-adapting “on” response in left lateral thyro-arytenoid muscle at fast recording speed (note calibration), with sustained caudal traction on left cricothyroid joint (20 gm).

end organs, which are present in the ligaments of joints elsewhere in the body, are entirely absent from all the laryngeal joints.

In addition to the corpuscular end organs (of Types I and II) the capsules of all the laryngeal joints are provided with interstitial and perivascular unmyelinated plexuses and free nerve endings that constitute the *Type IV* category of articular receptors. In this respect, the capsules of the laryngeal joints are identical with those in other parts of the body.

In summary, our neurohistological investigations allow the following proposals to be made about the innervation about the laryngeal joints.

1. The principal laryngeal articular endorgan is the Type II corpuscle, which by analogy with its behaviour elsewhere—might be expected to function as a rapidly-adapting mechanoreceptor in response to changing stresses in the joint capsule.

2. Slowly adapting mechanoreceptors of the Type I variety are rare in the laryngeal joints, and are confined to the crico-arytenoid joint.

3. The Type IV system of plexuses and free nerve endings is prominent in all the laryngeal joint capsules, and—again by analogy

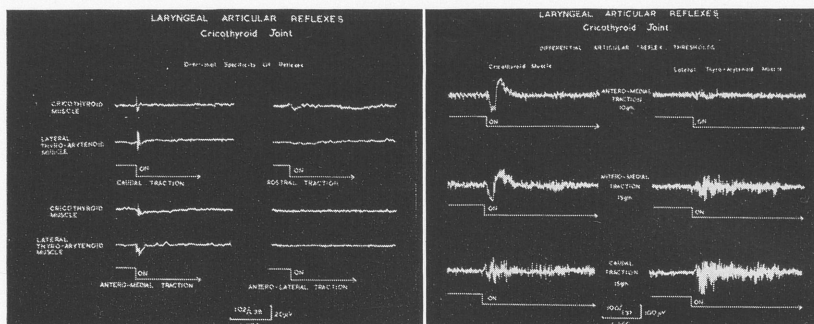


Fig. 12.—To show directional specificity of articular reflexes from left cricothyroid joint. 20 gm sustained pulls in each case. Moderate general anesthesia with pentobarbitone maintained at same stage throughout. Calibration the same for all records. The pairs of records were each made synchronously.

Note (1) that rapidly-adapting "on" responses are elicited simultaneously in the left cricothyroid and thyro-arytenoid muscles only with traction in *caudal* and *antero-medial* directions; (2) only rapidly adapting responses are elicited (hence cannot be due to muscle receptors).

Fig. 13.—To show the differential sensitivity of the articular reflex systems driving the cricothyroid muscle (left-hand column) and the thyro-arytenoid muscle (right-hand column) from the ipsilateral cricothyroid joint. Light general anesthesia with pentobarbitone maintained at same stage throughout. Calibration the same for all records. Horizontal pairs of records were made simultaneously.

Note (1). 10 gm traction in an antero-medial direction has no effect on cricothyroid muscle (movement artifact only), but produces a just-detectable brief response in the thyro-arytenoid muscle.

Note (2). 15 gm traction in the same direction produces a marked rapidly-adapting "on" response in the thyro-arytenoid muscle, and a much smaller and briefer response in the cricothyroid muscle.

Note (3). The same traction (15 gm) in a caudal direction produces greater "on" responses in both muscles—but still more marked in the thyro-arytenoid muscle.

This shows: 1. That the articular mechanoreceptors have a measurable and specific threshold. 2. That more such receptors in the cricothyroid joint are stimulated by caudal than by antero-medial traction. 3. That the articular reflex system driving the thyro-arytenoid muscle from the ipsilateral cricothyroid joint is more excitable than that driving the cricothyroid muscle on the same side.

with other joints—may be regarded as the articular pain receptor system.

4. Slowly-adapting, high-threshold Type III mechanoreceptors—which are characteristic of skeletal joint ligaments—are absent from the laryngeal joints.

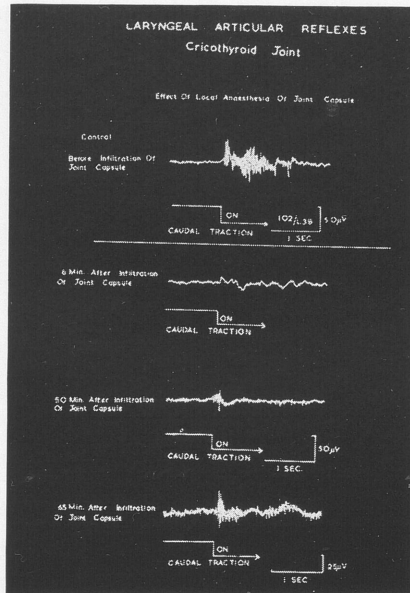


Fig. 14.—Selective reversible abolition of laryngeal articular reflexes in left lateral thyro-arytenoid muscle by local anesthesia of the joint capsule. 0.2 cc of 2% Lignocaine hydrochloride solution injected into left cricothyroid joint capsule. 20 gm pulls were applied throughout. General anesthesia with pentobarbitone maintained at the same stage throughout the experiment. The more marked rapidly-adapting “on” response in this muscle is abolished within 6 minutes of local anesthesia (movement artifact only) of the left cricothyroid joint (2nd record). After about 40-50 minutes the response begins to return (3rd and 4th records) as the effect of the drug wears off. (Note the increased amplifier gain in 4th record). The fact that the anesthetic solution has not spread to affect the muscles, or the nerves supplying them, is shown by the preservation of the resting motor unit activity in the 2nd record in each figure.

ELECTROSTIMULATION STUDIES

In 16 cats lightly anesthetized with pentobarbitone, the articular nerves supplying the cricothyroid and crico-arytenoid joints have been electrically stimulated directly with single rectangular pulses of varying amplitude and duration.^{23,33} For this purpose, the nerves were dissected out *in situ* (without dividing them) and lifted on to bipolar stimulating electrodes, under a stereoscopic operating microscope. The nerves, and the other exposed tissues, were submerged in a pool

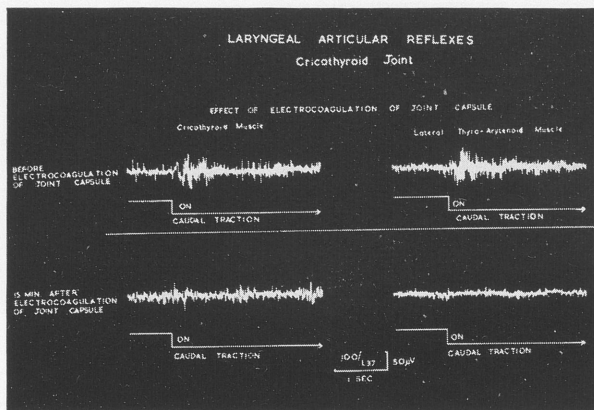


Fig. 15.—Selective abolition of articular reflexes in two laryngeal muscles by electrocoagulation of the joint capsule. The homologous pairs of records were made simultaneously. 20 gm caudal pulls were applied in each case. General anesthesia with pentobarbitone maintained constant throughout. The rapidly-adapting “on” responses produced simultaneously in the left cricothyroid and lateral thyro-arytenoid muscles by caudal displacement of the left cricothyroid joint (top records) are abolished permanently after electrocoagulation of the left cricothyroid joint capsule. The fact the electrocoagulation has not damaged the muscles, or the nerves supplying them, is indicated by the preservation of the motor unit activity in the resting record in each case.

of warm mineral oil. The animals were kept warm on a thermostatically regulated operating table.

After the thyroid lamina had been removed on one side (Fig. 7), contractions of the exposed laryngeal muscles were observed through the microscope. In some instances, movements of the vocal cords were inspected through a laryngeal speculum.³³ In other experiments²³ an oscilloscopic analysis of the flow of impulses responsible for the production of these movements was made in the articular nerves and laryngeal nerve trunks.

Low-intensity (that is, threshold) stimulation of each articular nerve consistently produced brief twitches in either abductor or adductor muscles of the larynx, or in both. The threshold for such responses was higher than that of the motor nerves to the same muscles, but much lower than that of the nerve branches supplying the laryngeal mucosa. High-intensity stimulation of the articular nerves

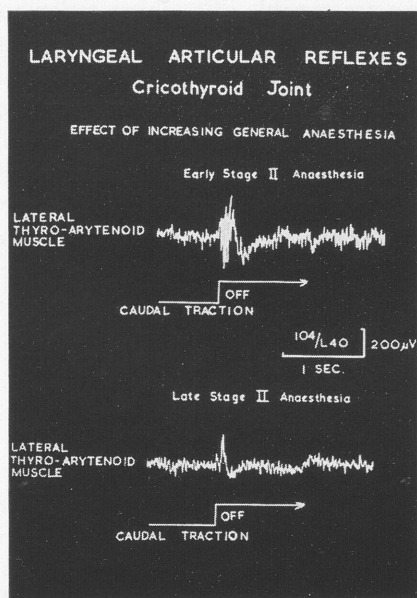


Fig. 16.—Selective abolition of articular reflexes by slight increase in general anesthesia with pentobarbitone. 20 gm caudal traction on left cricothyroid joint in each case. Between the upper and lower records, the animal was given an injection of 12 mg of pentobarbitone (equivalent to 3.5 mg/kg of body weight), the lower record being made 4 minutes after the injection.

Note. The rapidly-adapting “off” response in the upper record is abolished by the drug, leaving only the movement artifact. The fact that the increase in anesthesia is very slight is shown by the small decrease in the amplitude and frequency of the resting activity in the muscle. The EMG of the animal’s knee-jerk was unchanged throughout. This shows that the articular reflexes are polysynaptic, in view of their extreme sensitivity to barbiturate narcosis. They are abolished at a stage of anesthesia at which monosynaptic reflexes (such as the knee-jerk) are unaffected.

produced pain reflex responses (similar to those evoked by comparable stimulation of mucosal afferent nerves) involving laryngeal spasm, hyperpnea, tachycardia, dilatation of the pupils, and generalized limb and swallowing movements. The effects of laryngeal articular nerve stimulation were unaltered by section of the nerves distal to the point of stimulation, but were totally abolished by division of the nerves at any point between the stimulating electrodes and their junction with the main laryngeal nerve trunks (Fig. 8).

These findings indicate that afferent impulses set up in the laryngeal articular nerves are capable of evoking reflex contractions of the intrinsic laryngeal muscles. The relevant afferent nerve fibers have a higher threshold (and are, therefore, smaller in diameter) than the motor fibers to the laryngeal muscles. Some very high threshold (and hence very small diameter) pain afferent fibers are also present in the articular nerves. The medium-sized reflex afferent fibers in the laryngeal articular nerves are probably mechanoreceptor afferents similar to those in the articular nerves of the limbs,^{5,31} derived from the clusters of Type II receptors that are numerous in the capsules of all the laryngeal joints.^{23,29,33} The very small diameter fibers in the articular nerves are pain afferents, probably derived from the Type IV system of nerve endings in the laryngeal joint capsules.^{29,33}

ELECTROMYOGRAPHIC STUDIES

Electromyographic studies of the intrinsic and extrinsic laryngeal muscles were performed on 11 cats lightly anesthetized with pentobarbitone.³⁴ Neither tracheostomy nor intubation was performed: instead, the animals were allowed to breathe an oxygen-enriched air mixture spontaneously through an intrapharyngeal tube. The nerves, and all other exposed tissues, were kept submerged in warm mineral oil. The animals were kept warm on a thermostatically regulated, heated operating table. Operative procedures were performed with microsurgical instruments and a Zeiss operating microscope. All responses were tested at various phases of the spontaneous respiratory cycle, and at various stages of anesthesia.

The left cricothyroid joint was first isolated from the lamina of the thyroid cartilage and from the attachments of the cricothyroid and left inferior constrictor muscles. The thyroid lamina (except for its inferior cornu) was then removed on the left, the intra- and extralaryngeal branches of the superior laryngeal nerve being carefully preserved.

Non-elastic threads were tied through the residual articulated fragment of the inferior cornu of the thyroid cartilage, and graduated passive movements of the isolated cricothyroid joint were performed by attaching weights (ranging from 3 g to 20 g) to these threads, over pulley surfaces. Movements were performed in four planes mutually at right angles (that is, in cranial, caudal, anteromedial and anterolateral directions) (Fig. 9).

Electromyograms, and recordings of the animal's respiratory movements and electrocardiogram, were made simultaneously on a Grass polygraph. The effects on the responses to passive movement of infiltration of the joint capsule with 2 per cent 'Lignocaine' hydrochloride solution, of electrocoagulation of the joint capsule, of changing general anesthesia, of section of the articular nerves to the cricothyroid joint, and of ipsilateral and bilateral section of the internal, external and recurrent laryngeal nerve trunks were also examined.

Passive movements of the cricothyroid joint—but in caudal and anteromedial directions only—led to brief bursts of motor unit potentials at the onset of movement in the thyro-arytenoid, lateral cricoarytenoid and cricothyroid muscles, with coincident inhibition of spontaneous activity in the posterior crico-arytenoid muscle (Figs. 10, 11).

Varying the direction of traction and the degree of tension on the joint capsule showed that the articular mechanoreceptors located therein have a measurable and specific threshold; that more of these receptors are stimulated by caudal than by antero-medial traction; and that the articular reflex system driving the ipsilateral thyro-arytenoid muscle from the cricothyroid joint is more excitable than that driving the cricothyroid muscle on the same side (Figs. 12, 13).

The muscular responses to passive movement of the joint were reversibly abolished (for a period of 40-60 min.) by infiltration of the joint capsule with a local anesthetic (2 per cent 'Lignocaine' hydrochloride) solution (Fig. 14). They were irreversibly abolished by electrocoagulation of the joint capsule, or by section of the articular nerves (Fig. 15).

Bilateral section of the internal laryngeal nerves had no effect on the muscular responses to displacement of the cricothyroid joint. Bilateral section of the external laryngeal nerves abolished the articular reflex responses in the cricothyroid muscle only. Ipsilateral section of the recurrent laryngeal nerve below the larynx abolished the articular reflex responses in all the muscles—including the cricothyroid and strap muscles.

The responses could only be elicited at very light stages of general anesthesia, and were reversibly abolished by increasing anesthesia—as was the case with the responses to low-intensity stimulation of the articular nerves (v.s.) (Fig. 16).

The findings in these experiments confirm that the articular nerves innervating the laryngeal joints contain low and high-threshold afferent fibers, discharges in which provoke reflexly coordinated changes in the tone of the intrinsic laryngeal muscles. They further indicate that the low-threshold (larger diameter) articular afferents, at least in the case of the cricothyroid joint, are driven by rapidly-adapting (that is, Type II) mechanoreceptor endings embedded in the capsular tissues, which are selectively stimulated by movements of the joint in specific directions; whereas the high-threshold (small diameter) afferents provide a pain-conducting system from non-capsular (Type IV) nerve endings in the joint capsule. They also confirm that most of the afferents from the cricothyroid joint enter the ipsilateral recurrent laryngeal nerve, as we have indicated elsewhere,^{23,28,29,34} rather than the internal or external laryngeal nerves.

SUMMARY

Receptor nerve endings are present in the capsules of the cricothyroid, crico-arytenoid, thyrohyoid and thyro-epiglottic joints of the cat's larynx. Mechanical stimulation of these receptors, or electrostimulation of their afferent nerve fibers, produce reflexly co-ordinated contraction and relaxation of the intrinsic laryngeal muscles. Passive stretch of the joint capsule by movement in specific directions results in afferent discharges from low-threshold mechanoreceptors which produce transient alterations in motor unit activity in the intrinsic laryngeal muscles.

CONCLUSIONS

Mechanoreceptor reflexes originating in the capsules of the laryngeal joints are involved in the normal phasic co-ordination of activity in the laryngeal muscles during respiration and phonation. These *phasic* articular mechanoreceptor reflexes are distinct from, and supplementary to, the *tonic* myotatic reflexes operated from mechanoreceptors located within the laryngeal muscles.

The clinical implications of this study indicate that should abnormal situations involve the laryngeal joints as a result of trauma, inflammation or degenerative changes, then distorted reflex patterns of laryngeal muscular activity will result during phonation and respiration.

ACKNOWLEDGEMENTS—Thanks are due to Sir Victor Negus for his stimulating interest in, and helpful criticisms of these studies; to Mr. S. P. Steward and Mr. Johanna Kitau (Department of Physiology, Royal College of Surgeons of England) for their skilled technical assistance; to Mr. C. H. Redman and Mr. Keith McCarthy (Department of Photography, Royal College of Surgeons of England) for their painstaking photographic work; and to Mrs. Aline Kirchner for preparing the drawings.

REFERENCES

1. Buchthal, F.: Electromyography of Intrinsic Laryngeal Muscles. *Quart. J. Expt. Physiol.* 44:137-148, 1959.
2. Suckling, E. E.: Skeletal Muscle. Ch. 7 in *Bioelectricity*. McGraw-Hill Book Co., New York, 1961.
3. Lowenstein, W. R.: Biological Transducers. *Scientific American* 203:98-108 (Aug.) 1960.
4. Barker, D. (Ed.): *Symposium on Muscle Receptors*. Hong Kong University Press, 1962.
5. Freeman, M. A. R., and Wyke, B. D.: *J. Anat.* (in press) 1965.
6. Rose, J. E., and Mountcastle, V. B.: Touch and Kinesthesia. *Amer. Physiol. Society*, Washington, D.C., Ch. 17, *Handbook of Physiology*, Vol. 1, 1959.
7. Freeman, M. A. R., and Wyke, B. D.: *Brit. J. Surg.* (in press) 1965.
8. Freeman, M. A. R., and Wyke, B. D.: *Nature* (in press) 1965.
9. Boyd, I. A.: Nerve Impulses from Proprioceptors in the Knee-Joint of the Cat. *J. Physiol.* 123:241-50, 1954.
10. Skoglund, S.: Anatomical and Physiological Studies of Knee Joint Innervation in the Cat. *Acta Physiol., Scand.* 36, Supp. 124, 1956.
11. Boyd, I. A., and Roberts, T. D. M.: Proprioceptive Discharges from Stretch-Receptors in the Knee-Joint of the Cat. *J. Physiol.* 122:38-58, 1953.
12. Ekholm, J., Eklund, G., and Skoglund, S.: On the Reflex Effects from the Knee Joint of the Cat. *Acta Physiol., Scand.* 50:167-174, 1960.
13. Eklund, G., and Skoglund, S.: On the Specificity of the Ruffini-Like Joint Receptors. *Acta Physiol., Scand.* 49:184-191, 1960.
14. Bowden, R. E. M., Lucas Keene, M. F., Gooding, M., Mahran, T. Y., and Withington, J. L.: The Afferent Innervation of Facial and Laryngeal Muscles. *Anat. Rec.* 136:168, 1960.
15. Lucas Keene, M. F.: Muscle Spindles in the Human Laryngeal Muscles. *J. Anat.* 95:25-29, 1961.
16. Murtagh, J. A., and Campbell, C. J.: The Respiratory Function of the Larynx. III. The Relation of Fibre Size to Function in the Recurrent Laryngeal Nerve. *Laryngoscope* 61:581-590, 1951.
17. Scheuer, J. L.: Fibre Size Frequency Distribution in Normal Human Laryngeal Nerve. *J. Anat.* 98:99-104 (Jan.) 1964.

18. Sherrington, C. S.: Further Note on the Sensory Nerves of Muscles. *Proc. Roy. Soc.* 61B:247-249, 1897.
19. Bianconi, R., and Molinari, G.: Electroneurographic Evidence of Muscle Spindles and Other Sensory Endings in the Intrinsic Laryngeal Muscles of the Cat. *Acta Otolaryngol.* 55:253-9, 1962.
20. Martensson, A.: Reflex Responses and Recurrent Discharges Evoked by Stimulation of Laryngeal Nerves. *Acta Physiol. Scand.* 57:248-269, 1963.
21. Abo-El-Enein, M. A., and Wyke, B. D.: *Nature* (in press) 1965.
22. Martensson, A.: Proprioceptive Impulse Patterns During Contraction of Intrinsic Laryngeal Muscles. *Acta Physiol. Scand.* 62:176-194 (Sept.-Oct.) 1964.
23. Kirchner, J. A., and Wyke, B.: Afferent Discharges from Laryngeal Articular Mechanoreceptors. *Nature* 205:86-87 (Jan. 2) 1965.
24. Andrew, B. L.: Proprioception at the Joint of the Epiglottis of the Rat. *Jour. Physiol.* 126:507-523, 1954.
25. Jankovskaya, N. F.: Receptive Innervation of the Perichondrium of the Laryngeal Cartilages. (Russian), *Arkhir. Anat.* 70, 1959.
26. Gracheva, M. S.: Sensory Innervation of Locomotor Apparatus of the Larynx. *Fed. Proc.* 22:1120-1123, 1963.
27. Kirchner, J. A., and Wyke, B.: Innervation of Laryngeal Joints and Laryngeal Reflexes. *Nature* 201:506 (Feb. 1) 1964.
28. Kirchner, J. A., and Wyke, B. D.: The Innervation of the Laryngeal Joints in the Cat. *J. Anat.* 98:684, 1964.
29. Kirchner, J. A., and Wyke, B. D.: *J. Anat., London* (in press) 1965.
30. Wyke, B. D.: Neurophysiological Aspects of Joint Function with Particular Reference to the Temporo-Mandibular Joints. *J. Bone and Joint Surg.* 43B:396-397, 1961.
31. Freeman, M. A. R., and Wyke, B. D.: The Innervation of the Cat's Knee Joint. *J. Anat.* 98:299-300, 1964.
32. Greenfield, B. G., and Wyke, B. D.: The Innervation of the Cat's Temporo-Mandibular Joint. *J. Anat.* 98:300, 1964.
33. Kirchner, J. A., and Wyke, B.: Laryngeal Articular Reflexes. *Nature* 202: 600 (May 9) 1964.
34. Kirchner, J. A., and Wyke, B.: Electromyographic Analysis of Laryngeal Articular Reflexes. *Nature* 203:1243-1245 (Sept. 19) 1964.

DISCUSSION

DR. K. FAABORG-ANDERSEN: I always enjoy the meetings of this Association but they usually take place far from my home and therefore I cannot be with you every year.

Then I should like to thank you very much, Dr. Kirchner, for your very interesting paper. I have during the past year enjoyed the laryngeal research published by the Neurological Laboratory, Royal College of Surgeons, by you and Dr. Barry Wyke. You have added a lot of information to our knowledge about the

laryngeal articular mechano-receptors, which are no doubt involved in the coordination of activity in the laryngeal muscles.

A few years ago the possibility of muscle spindles in the intrinsic laryngeal muscles was very much discussed in laryngeal papers. Based on histological studies, a large number of authors claimed that the intrinsic laryngeal muscles were well supplied with muscle spindles. So did Goertler in 1950 and later Poulsen, Koenig, von Leden, Essleen, Schloschauer, and so on.

In your neurophysiological investigation you have been unable to record afferent impulses from muscle spindles in the motor nerve to laryngeal muscles. In this connection it is noteworthy that Andrew, 1956, and Martensson, 1964, have confirmed your results, and in this field I believe more in neurophysiological investigations than in histological studies. I believe you are right and would like to take this opportunity to congratulate you.

DR. JOSEPH H. OGURA: We have also demonstrated, not with the joints but with the muscles, that the electromyographic activity is abolished with the stages of anesthesia. I would like to ask Dr. Kirchner if he staged his activity according to the various planes of anesthesia, because I think this is very important, too.

DR. KIRCHNER (closing): Certainly, if there are three people in the world who know more about this than anyone I could think of, Dr. Faaborg-Andersen would be one of them and it is a great privilege for me to have him here to discuss this paper.

In answer to Dr. Ogura's question, we showed one slide on the planes of anesthesia and actually conducted one tracing right out to the bitter end from light anesthesia to increasing anesthesia all the way to the animal's demise. Since these are polysynaptic reflexes, there is no doubt that general anesthesia has a tremendous effect upon them.

This reflex mechanism—and this is the last thing I would like to point out and stress—does not reach the level of consciousness any more than a contraction of the pupil in response to light, so that we still don't have much to prove the position sense, in that sense of the word. It is a reflex and it may be proprioceptive but it does not constitute a position sense as we have in the extremities.

THE USE OF DERMAL GRAFTS IN OTOLARYNGOLOGY

GEORGE F. REED, M.D.

SYRACUSE, N. Y.

The use of dermis or cutis as a buried grafting material has seen wide-spread utilization since its introduction in 1913. It has been employed in many fields of surgery with excellent results in numerous applications. Its value seems to have eluded otolaryngologists, however, since the author was able to find only four references to its use in the otolaryngological literature. Only one of these was in an American otolaryngological journal and that being some thirty-three years ago.

Dermis is a tissue of great value with many potential applications in the field of otolaryngology. Accordingly, it is the purpose of this paper to bring this grafting procedure to the attention of otolaryngologists to stimulate more extensive application and evaluation of dermal grafts in the field of otolaryngology.

HISTOLOGY

An adequate understanding of the advantages and potential problems of this type of grafting material necessitates a brief review of the histological structure of the dermis or cutis. This tissue is the deeper part of the skin lying below the epidermis, being demarcated from the epidermis by the basement membrane. Although there is some question whether the basement membrane exists as a membrane per se, histologically, there is an apparent membrane which separates the epidermis from the underlying tissues, including the areas where the rete pegs of the epidermis dip down into the dermis. It should be noted that when considering skin and dermis for grafting proce-

From the Department of Otolaryngology, State University of New York, Upstate Medical Center in Syracuse.

dures, that the rete pegs are minimally developed in the abdomen, arms and legs.

The thickness of skin and epidermis varies in different parts of the body, with skin thickness varying from 0.5 mm in the eyelid to 3-6 mm in the palm or soles of the feet. The epidermal thickness varies from 0.06 mm in the eyelid to 0.5-0.8 mm in the palms or soles. In the usual donor sites of grafting, i.e., abdomen, thigh or upper arm, a graft depth of 12/1000 of an inch is safely below the level of epidermis including the depth of rete pegs in these locations.

The dermis is composed mainly of collagen and elastic fibers and is, accordingly, a very strong, pliable tissue requiring very little blood supply. Although the dermis lies below the epidermis, it does have epithelial elements extending to its depth in the form of sweat glands, sebaceous glands and hair follicles. It will be remembered that sweat glands are coiled glands lying within the dermis at various levels with individual epithelial lined ducts emptying onto the surface of the skin. Sebaceous glands lie adjacent to hair follicles emptying into epithelial lined ducts at the base of the hair follicles, thereby serving to "oil" the hair shafts before arriving on the surface of the skin.

Thus, it will be seen that a graft taken from skin deeper than 12/1000 of an inch will not contain epidermis. It will, however, contain epithelial elements in the form of sweat glands, sebaceous glands and hair follicles. It is the presence of these epithelial elements which has supplied controversy in the use of buried dermal grafts through the years, because of the fear of subsequent cyst formation from these epithelial elements.

There having been no previous comprehensive reports on this subject in the American otolaryngological literature, it would seem that a short historical review of the subject would be in order.

The first report of the clinical use of dermal grafts was in 1913 by Otto Loewe¹ of Frankfort-on-Main, who reported its use in seven patients, five for hernia repair, one for tendon repair and one for uterine suspension.

This was quickly followed in 1914 by Rehn,² who reported three successful cases of hand tendon reconstruction following dog experiments wherein dermis was used for replacement of the Achilles tendon. In his dog experiments, Rehn felt that the epithelial elements of the dermis degenerated due to tension, and the dermis assumed the func-

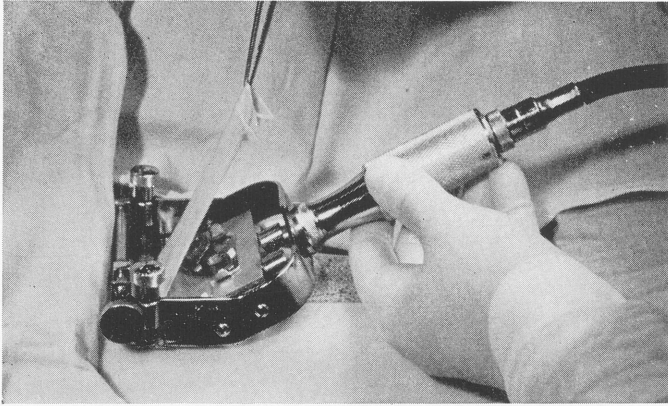


Fig. 1.—Split thickness skin section being made with electric dermatome.

tion and histologic characteristics of tendons in approximately ten weeks' time.

In 1920, Eitner³ first reported the use of buried dermal grafts for correcting defective facial contours. By 1929, Loewe's⁴ experience had increased greatly and he reported the use of buried dermal grafts in 100 cases, including hernial repairs, dural repairs, arthroplasties and recurrent shoulder dislocations. In 1932, Straatsma⁵ first reported on the use of dermis for the plastic repair of saddle nose deformities.

By 1939, Rehn's experiences in Germany had also increased and Uihlein reported on 104 cases from Rehn's clinic.⁶ These included cases involving hernia, unstable knees, recurrent dislocations of the patella and temporo-mandibular joint, and ruptured or lacerated tendons.

Although none of these authors had reported any complications due to burying the epithelial elements of dermis, there was a great deal of prejudice concerning the use of this tissue as a result of animal experimentation using full thickness skin. Kaufman,⁷ Davis,⁸ Zimches⁹ and Stewart¹⁰ had all reported on animal experiments with the development of cysts, foreign body reaction and granulations due to buried epithelial elements. It was assumed by most that the same thing would happen from the epithelial elements in buried dermis as these studies had demonstrated with buried full-thickness skin.




Fig. 2.—Split thickness skin section is left attached at one end and reflected.

In 1937, however, there appeared a very significant contribution by Peer and Paddock,¹¹ indicating the safety of buried dermal grafts relative to complications from its contained epithelial elements. These authors, working with humans, performed biopsies of buried dermal grafts at various time intervals between one week and one year. They reported a loss of sebaceous glands in one week's time and hair follicles in three weeks. They found that sweat glands were still present after one year but felt that they showed definite signs of degeneration. These findings produced renewed interest in dermal grafts and, in the period from 1950 to 1956, numerous reports of animal experimentation were recorded—all indicating good results relative to healing and tissue "take," with disappearance of cysts and epithelial elements. Included in these investigations were those of Swenson¹² and Rosenblatt¹³ working with subcutaneous implants, Armistead¹⁴ and Horton¹⁵ using intraperitoneal implants, and Horton¹⁶ and Crawford¹⁷ dealing with intrathoracic and intracranial implants respectively.

The application of findings in animal experimentation to humans, however, is always questionable and credit for the best study on the safety and outcome of dermal grafts in humans probably belongs to Thompson¹⁸ who, in 1960, very carefully and thoroughly described the histological findings, by biopsy, in 33 patients, over a period of

one to five years following dermal graft implantation. Thompson used buried dermal grafts for the correction of facial defects wherein the area was easily available for gross observation and obtaining biopsies. In ten of these patients, two implants were used to correct the defect, the implantation being done ten days apart. Over the five-year period, he noticed no cyst formation clinically in any of these patients. There were, however, minor cosmetic complications in five patients. In one, the graft became infected and had to be removed. In four, the graft became necrotic and absorbed.

Thompson's histologic findings are of great interest and deserve recapitulation. An active capillary circulation in the graft was found to be well established in one week's time. Sebaceous glands were found to survive for up to 12 weeks' time. Hair follicles were found to degenerate completely in two to ten weeks' time. It is interesting to note that sweat glands and their ducts survived throughout the five-year period with questionable activity but, at any rate, did not contribute to cyst formation. Microscopic epidermoid cyst formation was common, appearing to come mainly from hair follicles and occasionally from sebaceous glands. These cysts, however, remained microscopic and as the tension of retained epithelial products within the cyst increased, the epithelial lining was destroyed and the cysts became surrounded by foreign body giant cells and granulomatous reaction with ultimate destruction and replacement by fibrous tissue in approximately 15 months' time. In essence, the ultimate histologic outcome of the buried dermal graft was that of normal appearing dermis with sweat glands and ducts as the only residual epithelial constituent. To Thompson, then, goes credit for verifying and expanding Peer and Paddock's work in establishing the safety of subdermal implantation of dermal grafts.

Credit for stimulating the more extensive use of this type of grafting procedure in head and neck surgery belongs to Corso and Gerold¹⁹ who, in 1963, first reported its use to reinforce and protect the carotid artery and pharyngeal suture lines in radical surgery of the head and neck. These authors had been faced with the many problems of wound disruption, tissue loss, esophageal fistuli and carotid rupture commonly seen in radical head and neck surgery, especially after irradiation. They recognized the limitations of local muscle coverage of the carotid and devised the principle of using buried dermal grafts to cover the carotid artery in radical neck dissections and to cover the pharyngeal suture lines in laryngectomies and other

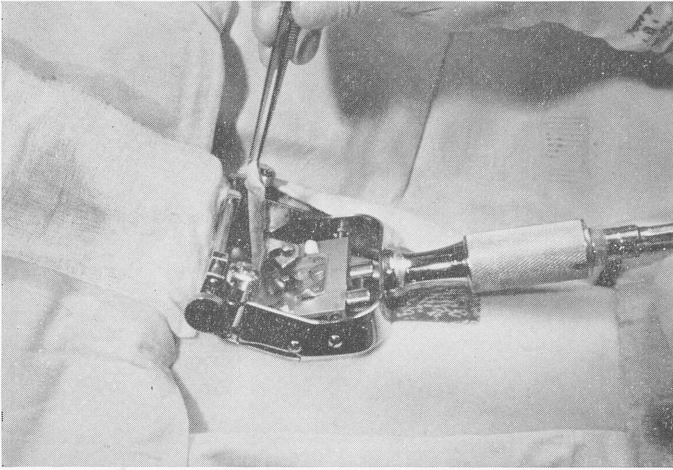


Fig. 3.—Dermal graft being sectioned with electric dermatome.

major head and neck procedures involving entrance to the pharynx. They reported on 29 patients, nine of whom were bilateral neck dissections with a total of 38 carotid arteries protected by dermal grafts. In 14 cases, there was primary healing. In 24 cases, there was tissue breakdown with exposure of viable dermal graft, which survived in all cases, despite exposure to air, gross infection and sometimes, gross infection and saliva. There were no carotid ruptures in the series. Their experience in covering the pharyngeal suture lines was limited to five patients in whom three had primary healing and two developed fistuli.

The most interesting aspect of Corso and Gerold's experience is their observations relative to the capacity of dermal grafts to survive even when exposed to saliva and infection and an unexpected finding that when the graft became exposed, the exposed portion re-epithelialized, obviating the necessity of secondary skin grafting or the use of regional flaps, the use of which is quite discouraging in the presence of saliva and infection. At the time of their publication in 1963, they had observed their patients for two years and had found no complications.

The successful results of Corso and Gerold soon led to subsequent favorable reports of dermal grafts in major head and neck surgery

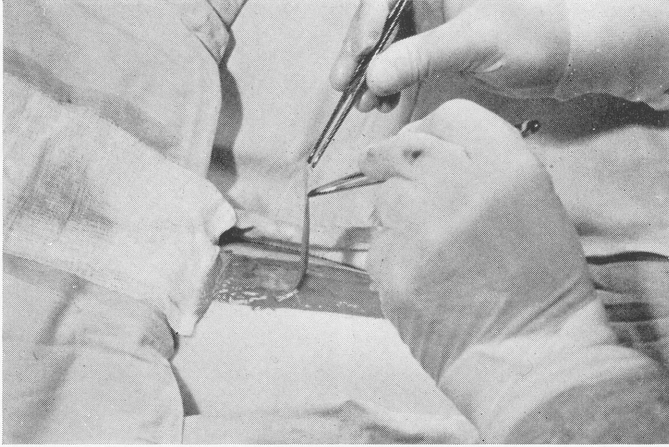


Fig. 4.—Dermal graft prior to removal.

by Dargent,^{20,21} by Tamoney²² in the repair of chest wall defects and by Bozzi²³ regarding its use in partial laryngectomy.

ADVANTAGES AND DISADVANTAGES

The use of autogenous dermis as a grafting material has many advantages in the field of otolaryngology. The grafting material is freely available in almost any quantity desired, with minimal problems concerned with the donor site. The material itself has great strength and stability, lends itself very easily to manipulation and has very limited postoperative absorption—approximately 20% according to Thompson.¹⁸ It is quickly vascularized from both sides in three to five days,¹⁹ and accordingly survives as a living transplant of viable dermis. This is of considerable importance since grafts treated by freezing or lyophilization to destroy epithelial elements do not survive as viable transplants but undergo absorption and fibrous replacements, thereby losing their suppleness, mobility and tensile strength. Lack of antigenicity or marked tissue reactivity is an attribute of non-treated, autogenous dermis not enjoyed by treated dermis or dermal homografts.

Another important attribute of autogenous dermis and its persistence as viable living transplant is the fact that its early vasculariza-

tion does not prejudice the future use of other grafting material at the same site.

Of special significance in major surgery of the head and neck is the capacity of this tissue to survive adverse conditions and heal rapidly.²⁴ The work of Corso and Gerold has demonstrated its remarkable ability to survive even when bathed in purulent and salivary secretions. Even more remarkable is the ability of the autogenous dermis to re-epithelialize when exposed to such conditions. Re-epithelialization, however, takes place only in the exposed areas of the graft with atrophy of epithelial elements of the dermis wherever it remains covered. No evidence of carcinogenicity has been reported in the 50 years since the use of autogenous dermal grafts was introduced.

The benign and harmless fate of the dermal epithelial elements has been amply described and demonstrated by Thompson¹⁸ and Peer¹⁸ as previously cited. To strengthen Thompson's findings relative to the lack of complications from subsequent cyst formation, the author was able to find only two references to the postoperative formation of cysts as a complication of dermal graft implantation. Couris and Wylie,²⁵ in 1964, described one patient who developed a sebaceous cyst 10 by 4.5 centimeters seventeen years following the use of a dermal graft for the repair of an incisional hernia. They quoted one other case by Rutter,²⁶ that being a 7 by 3 centimeter cyst 84 months following the use of a dermal graft for repair of an inguinal hernia. The technique employed in these cases was not cited and, in view of the extensive use of this material through the years with only two reported complications of cyst formation, one wonders if epidermal elements might not have been included with the dermal graft in these instances.

Aside from the potential complications of secondary infection with loss of the graft or the very low incidence of aseptic absorption (9 to 10%), it would seem that the disadvantages of using this type of tissue are almost negligible. Although the possibility of subsequent cyst formation cannot be excluded completely, it would seem that the advantages of availability, strength, stability, early vascularization, survival as a living transplant and capacity to survive under extremely adverse conditions, would certainly merit its further use and outweigh the slight potential complication of cyst formation, especially in major head and neck surgery.




Fig. 5.—Relation of dermal and epidermal sections to donor site.

TECHNIQUE

The original technique described by Loewe¹ was a very simple procedure of taking a free hand, full thickness skin graft and then scraping off the epidermis with a knife. This, of course, had drawbacks of having to place a split thickness graft over the donor site as well as the potential possibility of leaving epidermal elements with the grafted dermis.

In 1943, Swenson and Harkins²⁷ described the deratome-flap method of obtaining dermis from the donor site. The technique they described was that of cutting a split thickness graft leaving one end attached and then cutting the deeper dermal graft. After removing the dermal graft the previously elevated and attached epidermal flap was repositioned and sutured in place. At the time they introduced this technique, they thought it to be original only to find, in digging into the literature further, that this technique had been used by Rehn in his original work with dermal grafts. Although Uihlein, in reporting Rehn's work, did not mention the technique used by Rehn, Swenson and Harkins found in Maingot's textbook, "Postgraduate Surgery,"²⁸ a very concise and careful description of this technique as used by Rehn.

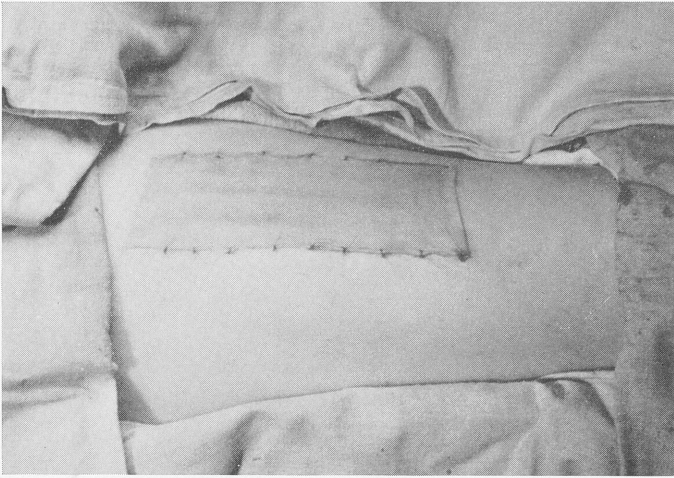


Fig. 6.—Epidermal flap repositioned after removal of dermal graft.

The present-day technique is extremely simple and employs the dermatome-flap principle further simplified by the availability of the electric dermatome. The thigh is generally used as the donor site because of its accessibility but the grafting material may be obtained from almost any portion of the body, the next most frequent sites being the upper arm or abdomen.

The approximate size of the graft having been pre-determined, the width of the electric dermatome is adjusted accordingly. After proper preparation and draping of the donor site, a split thickness skin section is performed at approximately 12/1000 to 14/1000 of an inch, leaving the resultant flap attached at one end. This flap is reflected and protected with moist sponges. The width of the dermatome is then reduced slightly to insure that no epidermis will be included in the second sectioning. The depth of the dermatome cut is then re-adjusted to a thickness of 12/1000 to 18/1000 of an inch, depending upon the thickness desired for the intended application. The dermal sectioning is then performed, being sure to start approximately a quarter of an inch above the epidermal starting point. The dermatome is withdrawn, and the dermal graft is excised and removed for application in the recipient site. The previously elevated epidermal flap is then returned to its original position and sutured in

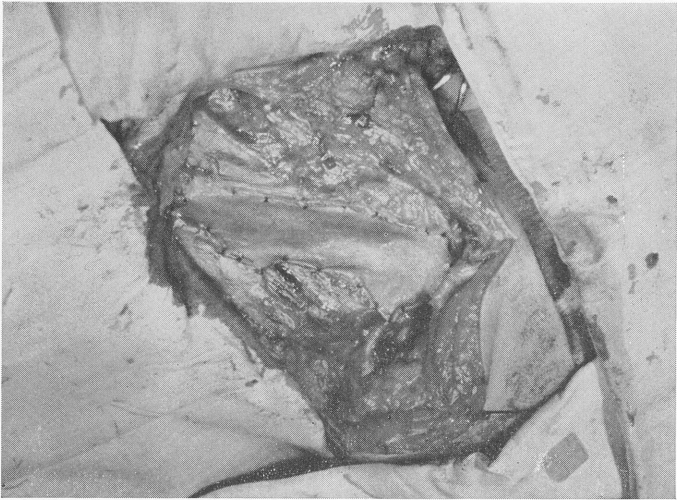


Fig. 7.—Dermal graft in place over carotid artery.

place. It is important to make numerous fenestrations in the epidermal flap to prevent its elevation by hematoma. For the same reason, it is important to inspect the donor site at fairly frequent intervals of every two to three days to be sure that any sanguinous collections beneath the flap are evacuated. Needless to say, the donor area is protected by a firm pressure dressing.

The dermal graft itself is a firm, fairly pliable tissue which tends to adhere spontaneously to the surrounding tissue in the recipient area and only a few catgut sutures are necessary to "tack" it in place in the recipient site. Figure 1 through 6 pictorially depict the various steps of obtaining the dermal graft. Figure 7 demonstrates its application to the recipient area, in this case being used to cover and protect the carotid artery.

PERSONAL EXPERIENCE

The author's personal experience with the use of dermal grafting in head and neck surgery is limited, but has been uniformly rewarding and promising. I have personally used the method in ten cases within the past year. These have included five cases of laryngectomy and neck dissection, one laryngectomy, one radical neck dissection, one

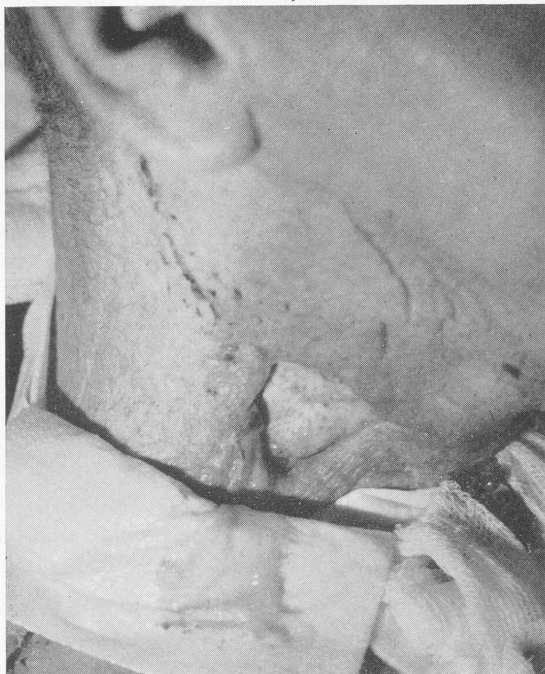

Fig. 8.—Viable dermal graft protecting carotid artery despite being bathed by purulent salivary secretions.

hemi-laryngectomy and one "commando" procedure. All of these patients had had previous radiation therapy with the exception of two of the patients receiving laryngectomy and neck dissection. In the seven patients in which the dermal graft was used to reinforce the esophageal suture line where the larynx had been entered, there was fistulization in only one case, although five of the seven patients had had previous radiation. It is interesting to note that the one patient who developed a fistula of four weeks' duration had had no previous x-ray therapy.

In the seven cases, where the dermal graft was used to protect the carotid artery, there were no carotid ruptures, despite the fact that in three cases who had had extensive radiation, there was considerable infection with fairly extensive purulent accumulations under elevated flaps postoperatively.

The ability of implanted dermis to survive under the most adverse conditions was dramatically demonstrated by one patient who had a neck dissection, hemimandibulectomy and hemiglossectomy for recurrent carcinoma of the right side of the tongue. This patient had received 7000 R of external radiation three years previously for a large lesion of the left tonsil and 7000 R to the right neck and tongue four months prior to operation. Postoperatively, he developed a fistula from the pharynx with secondary infection. All of the flaps were completely non-adherent and the dermal graft covering the carotid was bathed by saliva and gross purulent secretions for approximately one week until the infection was brought under control and the fistula closed. At this time, the flaps re-adhered but there was a loss of skin approximately 3 x 3 centimeters directly over the region of the bifurcation of the carotid. The dermal graft, thus exposed, was easily visualized and retained its viability despite these extreme adverse conditions. Figure 8 demonstrates the exposed dermal graft in place successfully protecting the carotid artery.

Two months postoperatively, the dermal graft was completely viable and being slowly epithelialized, mainly from the surrounding skin, but there did appear to be small islands of epithelialization from the graft itself.

Dermis was also used in one patient for myringoplasty. In this instance the dermis was cut thinner, approximately 12/1000 of an inch, and was placed on the exterior surface of the drum over a large perforation. The edges were tucked into pockets created by elevation of the canal wall skin anteriorly and posteriorly so that the canal wall skin covered approximately 2 mm of the dermal graft. This graft took very nicely—was quickly covered by epithelium from the canal wall skin and has survived as an essentially normal appearing drum for a period of eight months.

The author is well aware that such a small series of cases has no significance from a statistical point of view in evaluating any procedure, but the results in this small number of cases have been so impressive and rewarding that I believe the method deserves much more extensive evaluation in the field of otolaryngology.

In addition to the previously described use of dermal grafts in correcting deficient facial contours, in plastic surgery, as a covering for the carotid artery in head and neck surgery, as a reinforcement of the pharyngeal suture line in laryngopharyngeal surgery and its

use in subtotal laryngectomy, many other possible applications in the field of otolaryngology come to mind. One could consider its use in various tracheoplastic and laryngoplastic procedures for the correction of stenosis or loss of tissue as a result of surgery, trauma, etc. In this regard, dermis has been used in an ingenious fashion by Gebauer²⁹ to repair bronchial stenosis. He was successful in producing a patent bronchial opening by incising the stenotic area and closing the resultant opening with dermis which was reinforced by interlacing with stainless steel wire.

It would seem that this tissue, because of its strength, easy viability, limited absorption and capacity to survive under very adverse conditions could be of great value in the field of myringoplasty and the various tympanoplastic procedures. Dermis might be a very good tissue to use in osteoplastic obliterative surgery of the frontal sinus. It might also be of value when implanted in the nasal or sinus cavities in cases of atrophic rhinitis, either primary or secondary to extensive intranasal or sinus surgery. Another possible application of this technique might be in its use to support the orbit in "blow out" fractures of the orbit, in preference to the artificial non-viable substances now in use.

These are but a few of the possible otolaryngological applications that come to the author's mind, but surely many other applications will become apparent as, and if, this type of grafting material achieves greater use and recognition in the field of otolaryngology.

SUMMARY

Autogenous dermis, as a buried grafting material, has seen extensive successful use in various surgical applications since its introduction in 1913. Its value and potential applications in the field of otolaryngology has apparently eluded otolaryngologists, since the author was able to find only four references to its use in the otolaryngological literature.

To bring this type of grafting procedure to the attention of otolaryngologists, the subject has been reviewed, including related histology, a review of the literature, technique, advantages and disadvantages, the author's personal experience, and potential applications in the field of otolaryngology.

In the author's opinion, the attributes of this type of grafting tissue, i.e., easy availability, strength, early vascularization, limited

absorption, ability to survive as a viable transplant and capacity to survive in extremely adverse conditions, with few if any complications, merits more wide-spread use and evaluation in the various fields of otolaryngology.

750 EAST ADAMS STREET

REFERENCES

1. Loewe, O.: Ueber haut implantation an stelle der freien faszien plastik. Munchen. med. Wehnschr. 24:1320, 1913.
2. Rehn, E.: Das kutane und subkutane bindegewebe als plasticsches material. Munchen. med. Wehnschr. 13:118, 1914.
3. Eitner, E.: Uber unterpolsterung der gesichtshaut. Med. Klin. 16:93, 1920
4. Loewe, O.: Munchen. med. Wehnschr. 51:2125, 1929.
5. Straatsmas, C. R.: Use of the Dermal Graft in the Repair of Small Saddle Defects of the Nose. Arch. Otolaryng. 16:506, 1932.
6. Uihlein, A., Jr.: Use of the Cutis Graft in Plastic Operations. Arch. Surg 38:118, 1939.
7. Kaufman, E.: Ueber enkattarrhaphie von epithel. Arch. Path. Anat. 97:236, 1884.
8. Davis, J. S., and Traut, H. F.: The Production of Epithelial Lined Tubes and Sacs; Experimental Study. J.A.M.A. 86:339, 1926.
9. Zimches, J. L.: The Fate of Surface Epithelium Transplanted into Deeper Tissues, and its Relation to Epithelial Cysts. Frankfurt: Ztschr. Path. 42:203, 1931
10. Stewart, M. J.: On the Occurrence of Irritation Giant Cells in Dermoid and Epidermoid Cysts. J. Path. and Bact. 17:502, 1912.
11. Peer, L. A., and Paddock, R.: Histologic Studies on the Fate of Deeply Implanted Dermal Grafts; Observations on Sections of Implants Buried from One Week to One Year. Arch. Surg. 34:268, 1937.
12. Swenson, S. A., Jr.: Cutis Grafts: Clinical and Experimental Observations. Arch. Surg. 61:881, 1950.
13. Rosenblatt, M. S., Edelson, Z. C., and Sneed, V. D.: Clinical and Experimental Experience with Buried Skin Grafts. West. J. Surg. 61:67, 1953.
14. Armistead, W. W.: The Experimental Use of Skin Autografts Intraperitoneally. Plast. and Reconstruct. Surg. 18:9, 1956.
15. Horton, C., et al.: The Behaviour of Split Thickness and Dermal Skin Grafts in the Peritoneal Cavity. An Experimental Study. Plast. and Reconstruct. Surg. 12:269, 1953.
16. Horton, C., et al.: Behaviour of Split-thickness, Dermal, and Full-thickness Skin Grafts in the Thoracic Cavity; Experimental Study. A.M.A. Arch. Surg. 70:221, 1955.

17. Crawford, H.: Dura Replacement. An Experimental Study of Dermal Autografts and Preserved Dura Homografts. *Plast. and Reconstruct. Surg.* 19:299, 1957
References 1 to 17 quoted by Thompson.¹⁸
18. Thompson, N.: The Subcutaneous Dermis Graft. *Plast. and Reconstruct. Surg.* 26:1, 1960.
19. Corso, P. F., and Gerold, F. P.: Use of Autogenous Dermis for Protection of the Carotid Artery and Pharyngeal Suture Lines in Radical Head and Neck Surgery. *S. G. & O.* 117:37 (July) 1963.
20. Dargent, M., et al.: Value of Dermal Grafts for the Prevention of Complications of Carotid Exposure in Major Surgery of Carcinoma of the Oropharynx and Hypopharynx. *Mem. Acad. Chir. (Paris)* 89:332 (Mar.) 1963.
21. Dargent, M., et al.: L'utilisation des greffes de derme dans la chirurgie monobloc des cancers oropharynges. *J. Franc. d'O. R. L.* 12:605 (June-July) 1963.
22. Tamoney, H. J., Jr., and Stent, P. A.: Dermal Graft for Chest Wall Repair. *S. G. & O.* 118:289 (Feb.) 1964.
23. Bozzi, E.: Protection of the Operative Surface by Dermal-epidermal Grafts in Operations for Partial Laryngectomy. *Arch. Ital. Otol.* 75:1 (Jan.-Feb.) 1964.
24. Cannaday, J. E.: Some of the Uses of the Cutis Graft in Surgery. *Am. J. Surg.* 59:409, 1943.
25. Couris, G. D., and Wylie, J. H.: Epidermoid Cyst Formation Seventeen Years Following Cutis Graft Repair of Incisional Hernia. *Henry Ford Hosp. Med. Bull.* 12:141 (Mar.) 1964.
26. Rutter, A. G.: Cyst Formation Seven Years After Cutis Graft Repair of Hernia. *Brit. Med. J.* 1:951, 1955.
27. Swenson, S. A., and Harkins, H. N.: Cutis Graft—Application of Dermatomy Flap Method; Its Use in a Case of Recurrent Incisional Hernia. *Arch. Surg.* 47:564, 1943.
28. Maingot, R.: *Post Graduate Surgery.* D. Appleton-Century Company, Inc., New York, 1937.
29. Gebauer, P. W.: Plastic Reconstruction of Tuberculous Bronchostenosis with Dermal Grafts. *J. Thoracic Surg.* 19:604, 1950.

DISCUSSION

DR. SAMUEL SALINGER: In what respect do you think the dermal graft differs from the dermal fat graft which we have previously used? Do you think it has an advantage over dermal fat graft?

DR. JOEL J. PRESSMAN: Dr. Reed's contribution is a most interesting and important one. I augment what he has said by reciting experiences with similar collagen-bearing materials, to wit, arterial tree in which the use of a cadaver aorta preserved in aorta banks for other purposes has given evidence that the collagen as evidenced by the elastic fibers will remain almost without significant destruction when observed for as long as three years by histologic methods. I can guarantee that whatever element of this dermal graft is due to the elastic collagen fibers within it certainly has a very long life, and would live even if they were not a transplant of viable living tissue.

DR. JOHN A. MURTAGH: With reference to the application of grafting to other regions of the nose and throat, some of you may recall that Dr. Hoople in his discussion of his experiences in England during the last war reported grafting over a plastic tube following a radically operated frontal sinus, wrapping the tube in a skin graft. Some of you may have tried this. I have in several instances and I have found it a satisfactory way of keeping the nasofrontal duct patent. I have done it in about three or four cases, which is not very many, but it has been quite satisfactory. I mention this at this time with the hope that the procedure won't be entirely forgotten.

DR. REED (closing): I want to thank the membership, those who didn't wish to discuss as well as those who did. Those who didn't might not have been so kind.

First, in reference to Dr. Salinger's question about the advantages of dermal grafts versus dermal-fat grafts, I am not sure of what I can say here except that the dermal graft, at least from what I can read in the literature, is more apt to survive as living tissue than is the dermal-fat graft. You can, of course, by including fat with the dermis, get a much greater bulk of tissue and obliterate larger spaces. It has been assumed that fat, due to its nature, would not survive as easily as would the dermis, but I am not so sure about that. Actually, when we see what fat will do in frontals with very little nourishment, possibly, with some more animal studies, we might find that dermal-fat grafts are just as good as dermal grafts alone.

In reference to Dr. Pressman's kind statements about the cadaver aorta, I have had no experience with this. I am pleased to find that even dead collagen fibers and elastic tissue will survive for three years. We do have evidence in the literature that dermis, when it is autogenous, survives not for just three years but at least five years essentially unchanged from its original state.

In reference to Dr. Murtagh's comments about wrapping the plastic tube with a skin graft in frontal sinus surgery, this, of course, is a completely different concept. The value of dermis is that it can be buried. If you are not going to bury it or expect it to stay buried, you are better off with a regular split-thickness skin graft for the epithelial covering which you desire.

HISTOLOGIC CHANGES IN THE TRACHEA FOLLOWING TRACHEOSTOMY

STANTON A. FRIEDBERG, M.D.

THOMAS E. GRIFFITH, M.D. GEORGE M. HASS, M.D.
(by invitation) (by invitation)

CHICAGO, ILL.

This treatise represents a sequel to a recent analysis of tracheal mucosal changes following laryngectomy.¹ The present study is based upon material obtained at autopsy on 27 patients who had tracheostomies prior to death. For controls, we studied comparable autopsy tissues from 44 patients without tracheostomies. The tissues examined were specimens of trachea, carina and primary bronchi. Clinical records and autopsy protocols were scrutinized for possible relation to the histologic changes observed in the distal respiratory tract mucosa.

Various causes for alterations in the mucous membrane of the tracheobronchial tree have been listed. Recently, particular attention has been directed to the effects of tobacco and environment.²⁻⁵ The experimental work of Hilding on the tolerance of the respiratory mucous membrane to trauma is fundamental and pertinent to this clinical report.⁶ Plum and Dunning, after studying the signs of trauma to the trachea and bronchi due to aspiration catheters, proposed certain modifications in technique designed to minimize these tissue-damaging maneuvers.⁷

MATERIAL

In summarizing the observations of autopsy specimens from 27 patients with tracheostomies, we chose to select an arbitrary chronological classification as follows:

From the Department of Otolaryngology and Division of Pathology, Presbyterian-St. Luke's Hospital, Chicago.

This work has been partly supported by funds awarded by the Otho S. A. Sprague Memorial Institute

| <i>Duration of tracheostomy</i> | <i>Number of patients</i> |
|---------------------------------|---------------------------|
| 1-5 days | 14 |
| 5-10 days | 5 |
| 10-100 days | 8 |
| | <hr/> |
| Total | 27 |

Some measure of the severity of illness in these patients is indicated by the fact that the majority died within 5 days after tracheotomy was performed.

PRINCIPAL FINDINGS IN PATIENTS WITH TRACHEOSTOMY

Carinal Apical Ulceration. In 8 of the 27 patients a distinct pattern of ulceration of the tracheal carina was apparent. Interestingly, this ulcer involved the carinal apex and often extended into only one of the primary bronchi (Fig. 1). This can probably be attributed to the traumatic effect of postoperative catheter aspiration. Whether the ulcer involved the right or left side of the carina was not determined but the more direct continuation of the right bronchus from the trachea would suggest that the right side probably absorbs the main brunt of any aspiration procedure.

Ulceration, Denudation and Infection. In 10 of the 27 patients, denudation of the mucosa plus infection were observed in varying degrees. Clumps of bacteria, and, in some instances, fungi could be seen in the altered mucosal areas. Seldom was there evidence of primary bacterial infection.

Denudation, Repair and Regeneration. The pattern of mucosal repair, described so strikingly by Hilding, could be seen in 10 of the 27 patients. This was particularly apparent in those patients whose tracheostomies were of relatively short duration, although it was consistently observed in all groups regardless of the time interval (Figs. 2 and 3).

Metaplasia. Metaplastic alterations in the epithelium were observed in only 1 patient whose tracheostomy had existed for less than 5 days and this particular individual had previously undergone x-ray treatment. In the 5 to 10 day category, 4 of 5 patients exhibited epithelial metaplastic changes. In the 4 patients whose tracheostomies had been present for more than 10 days, 4 showed metaplasia and 2 of these individuals had also had x-ray therapy (Figs. 4, 5 and 6).

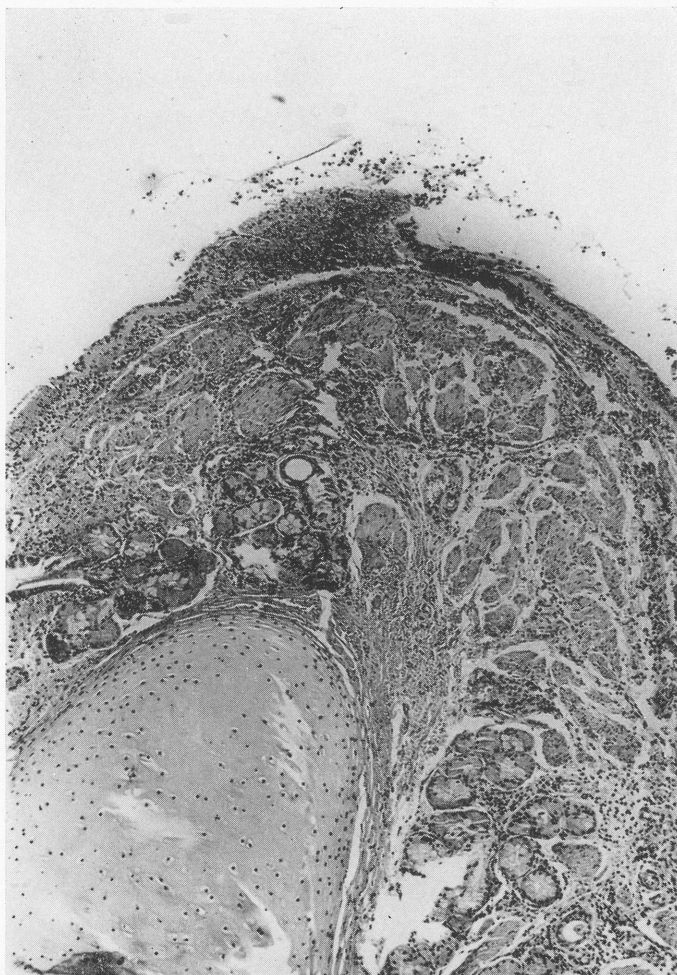


Fig. 1.—This photomicrograph illustrates an acute ulcer covered with a mound of fibro-purulent exudate on the apex of the carina. Note that the destruction of the mucosa is accompanied by denudation of all except the basal layer of epithelium of one primary bronchus with fair preservation of the epithelium of the other primary bronchus. This group of pathologic changes was found quite frequently in the tracheotomized patients. In this instance the tracheostomy was of eight days' duration. H&E stain X50.

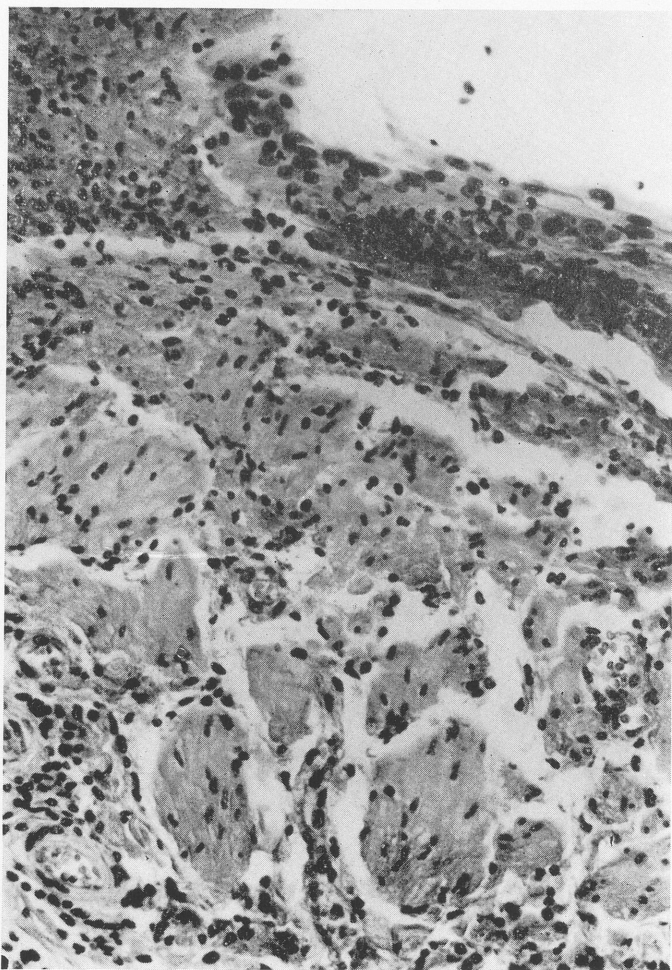


Fig. 2.—This photomicrograph illustrates one type of epithelial repair following ulceration. On the left there is a carinal ulcer covered by fibrinopurulent exudate. Extending to the margin of the exudate from the right is an irregular layer of flat squamous and low cuboidal cells which have re-epithelialized a part of the bed of the ulcer. In this instance the tracheostomy was of 5 days' duration. H&E stain X360.

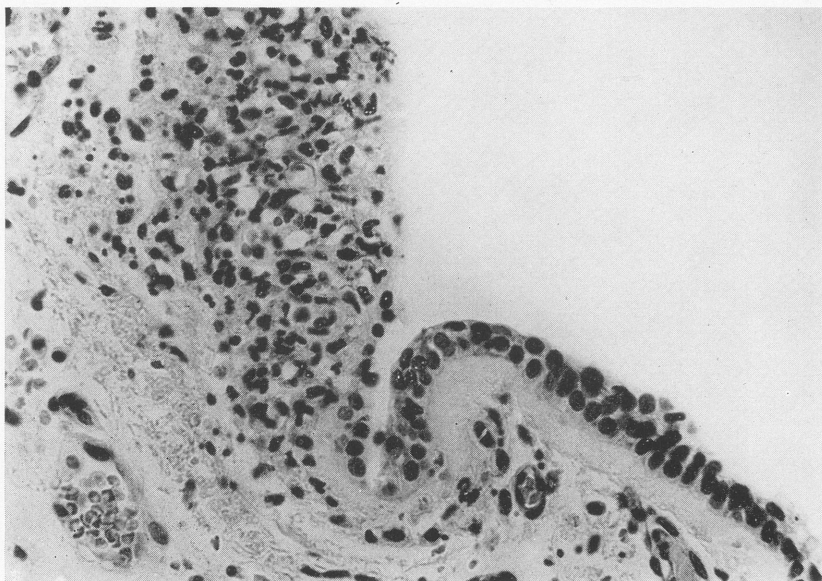


Fig. 3.—This photomicrograph illustrates a common type of epithelial repair following superficial ulceration and denudation. To the left is a lesion where the epithelium and basement membrane have been destroyed with excitation of a heavy leukocytic infiltration in the subadjacent tunica propria. To the right the ciliated columnar and goblet cells have been denuded with preservation of the basal epithelium and basement membrane. Cells arising by division of the basilar cells have acquired, at times, squamous shapes and are oriented in a direction parallel to the basement membrane. This patient died following cardiac surgery on the second day following tracheotomy. H&E stain X330.

Chronic Inflammatory Reaction. In 8 of 27 patients some degree of chronic inflammatory reaction was observed in the superficial and deep layers of the lamina propria.

Miscellaneous Findings. In only 1 of the 27 patients with tracheostomies could the epithelial layer be designated as intact and normal. There were fibrillary alterations in the basement membranes in 3 patients but the exact significance of this finding was not immediately apparent. Autolysis of the epithelium was observed in 4 specimens and was thought to be due to aspiration of gastric contents. An eosinophilic leukocyte infiltration was seen in 2 patients, neither of whose clinical histories provided any explanation for the finding.

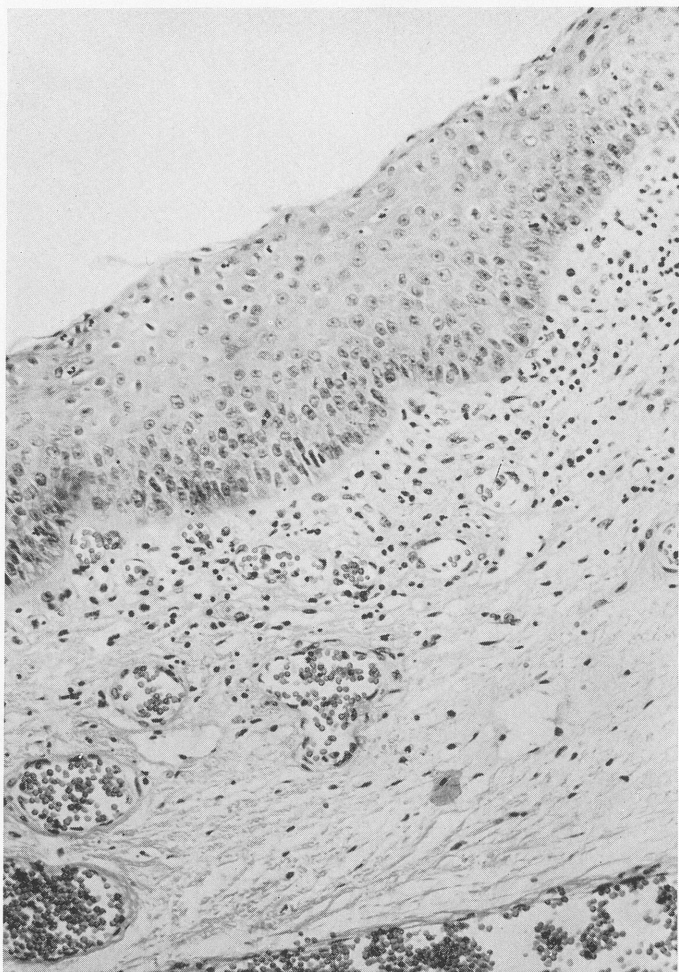


Fig. 4.—This photomicrograph shows a reparative metaplastic epithelial reaction in the trachea. This is less advanced than the pseudokeratinizing metaplasia shown in Figure 9. As is the rule there is an inflammatory cell infiltration in the tunica propria and an indistinct basement membrane. Evidence for ultimate replacement of this type of epithelium by normal pseudostratified ciliated respiratory epithelium remains largely speculative. This patient, a 61-year-old man, died, following cardiac surgery, 13 days after the tracheostomy. H&E stain X130

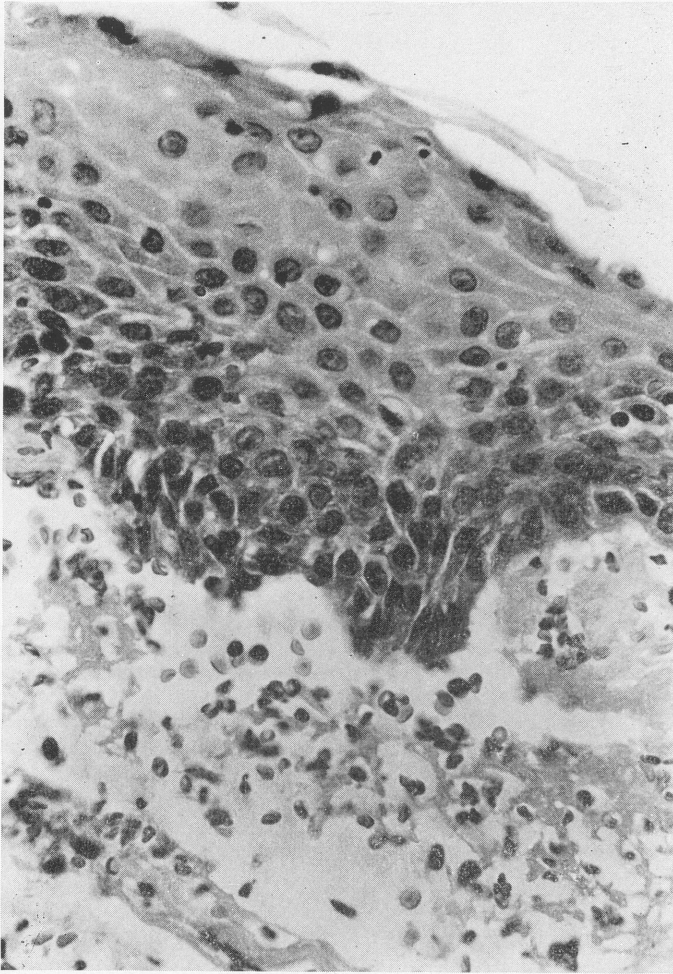


Fig. 5.—This photomicrograph shows an advanced type of epithelial metaplasia in the repair of tracheal mucosa. The basement membrane has been destroyed and the basal layer of the epithelium separated from the tunica propria by fluid containing many polys. The epithelium is several cells in thickness and the orientation resembles that which is customary for the epidermis. Whether this degree of metaplasia is reversible is unknown but reactions of this type often precede neoplastic transformations. This patient had a history of extensive irradiation for carcinoma of the esophagus. The tracheostomy was of 10 days' duration. H&E stain X330.

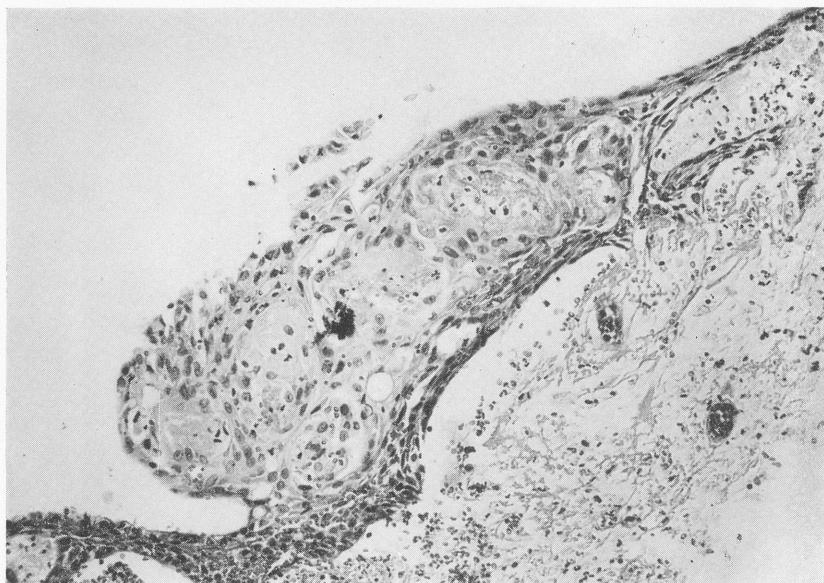


Fig. 6.—This photomicrograph shows a very atypical metaplastic epithelium. Note that, as usual, the tunica propria has severe changes referable to prior persistent inflammation. The basement membrane has been destroyed. The regenerating epithelium of the trachea has formed intra-epithelial "pearls" closely resembling arrangements encountered in the early stages of epidermoid carcinoma. It seems unlikely that the degree of metaplasia shown here is reversible to a normal respiratory ciliated epithelium. This is from the patient described in Figure 5. H&E stain X130.

CONTROL GROUP

The absence of carinal apical ulceration in any of the patients in this group is particularly noteworthy. Although there was evidence of some ulceration, denudation and infection in the epithelial and the death of the patient.

layer, this occurred in a relatively few patients (7 out of 44). There was no evidence of any regeneration of epithelium in this group, due presumably to the brief period between the development of the lesion

Intact epithelium was found in 35 of the 44 specimens (Fig. 7). Autolysis occurred in 9 (Fig. 8), metaplasia in 5 and fibrillary basement membrane changes in 3.

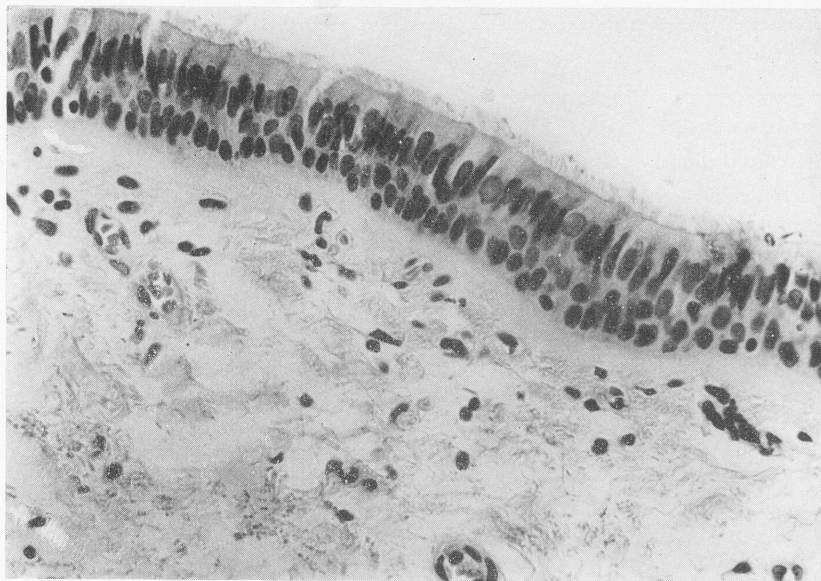


Fig. 7.—This photomicrograph shows excellent preservation of normal ciliated pseudostratified epithelium, characteristic of the mucosa of the trachea, carina and primary bronchi. Note the cuboidal and blunt columnar basal layer of cells resting on the basement membrane. As these divide and differentiate, they replace the more superficial elongated ciliated and goblet cells which normally have a limited life-span. H&E stain X300.

A chronic inflammatory reaction in the mucous membranes was apparent in 30 specimens. This was characterized as severe in 19, mild in 11. The degree of chronic inflammation seemed to bear relationship to the age of the patients, being greater in the older age group. This would tend to point to longer exposure to atmospheric pollution or other irritants as possible contributing factors.

Eosinophilic leukocyte infiltration of the mucosa was observed in 4 patients, 3 of whom were diabetic; the other patient had undergone x-ray therapy.

A comparison of the principal findings in the two groups of patients is evident in the following table:

SUMMARY OF PRINCIPAL HISTOLOGIC CHANGES

| | <i>Tracheostomy</i> (27) | <i>Control</i> (44) |
|--|-----------------------------|--------------------------------|
| TRAUMATIC | | |
| Intact Epithelium | 1 | 34 |
| Ulceration, Denudation, Infection | 10 | 7 |
| Carinal or Unilateral Bronchial Ulceration | 8 | 0 |
| Autolysis | 4 | 9 |
| REPARATIVE | | |
| Denudation, Repair, Regeneration | 10 | 0 |
| Metaplasia | 9 (3 x-ray therapy) | 5 (1 x-ray therapy) |
| MISCELLANEOUS | | |
| Fibrillary Basement Membrane | 3 | 3 |
| Chronic Inflammation | 8 | 30 (19 severe) (11 mild) |
| Eosinophilic Leukocyte Infiltration | 2 | 4 (3 diabetes) |

SEQUENCES IN REPAIR AND REGENERATION

It is apparent that denudation of epithelium with and without destruction of the basement membrane is the earliest outstanding common complication of tracheostomy with its attendant traumatic manipulations. Ulceration and infection, often localized principally on the apex of the carina, may occur following denudation (Fig. 1). This retards the process of mucosal repair. When ulceration and infection do not occur, the sequences in repair are more easily recognized.

The first evidence of repair following surface denudation depends upon the extent of denudation. If only the tall columnar superficial layer of ciliated and goblet cells is denuded, leaving the basal layer, mitotic division among the basal cells becomes conspicuous within 24 to 48 hours with a prompt differentiation of the daughter cells, restoring first the tall ciliated epithelium and somewhat less promptly the goblet cells (Fig. 3).

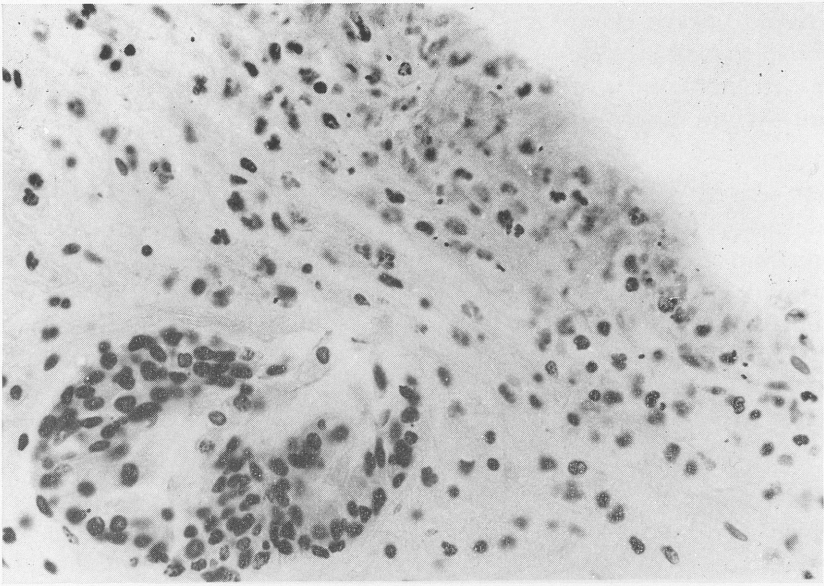


Fig. 8.—This photomicrograph illustrates the absence of the epithelium of the trachea, carina or primary bronchi. At times it was difficult to distinguish between loss of epithelium due to infection, denudation or post-mortem autolysis. Evidence of autolysis, presumably due in part to aspiration of gastric juice, is conspicuous here as indicated by the lack of sharp microscopic detail superficially and the progressive increase in the sharp staining of nuclei at increasing depth in the mucosa. H&E stain X330.

On the other hand, if the denudation involves the entire thickness of the original respiratory epithelium, the first evidence of repair is the migration of a layer of flat squamous epithelium originating from the basal epithelium at the margins of the denuded areas or from the ducts of the sero-mucus mucosal glands (Fig. 2). (This sequence was also demonstrated by Hilding in the experimental animal.)⁶ As the area is covered, continued proliferation of these cells forms a metaplastic multilayered epithelium resembling stratified squamous non-keratinizing or transitional epithelium (Fig. 4). This epithelium may persist as a multilayered structure or may undergo three modifications. One modification is characterized by the differentiation of the superficial cells into columnar ciliated cells with retention of a subjacent multilayered epithelium (Fig. 9). The second modification involves a degeneration and desquamation of the superficial cells with subsequent restoration of normal pseudo-stratified

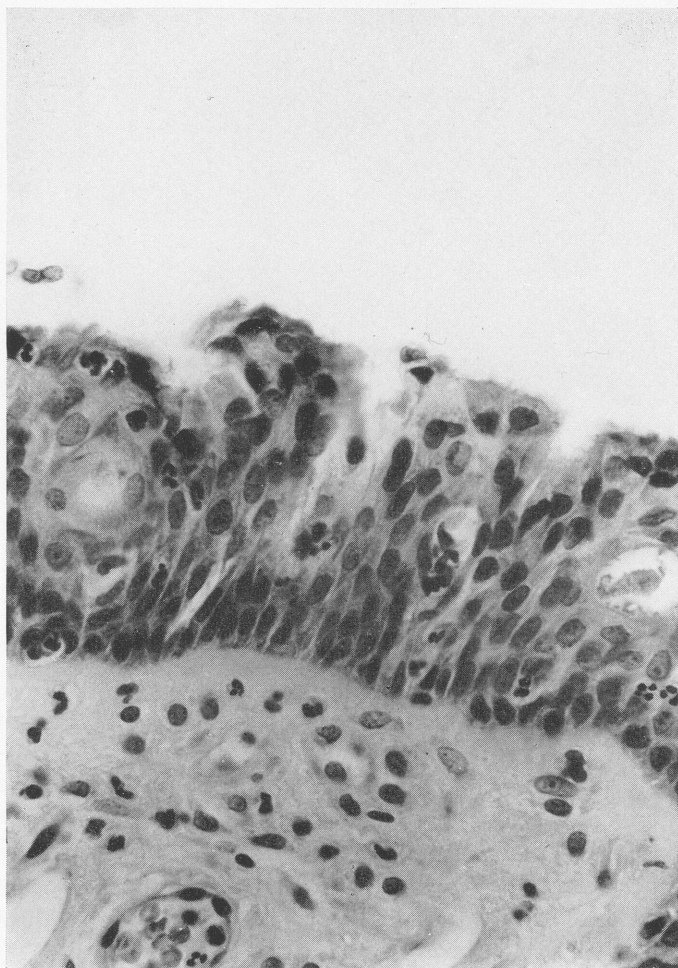


Fig. 9.—This photomicrograph illustrates an abortive attempt at reversal of a metaplastic reparative epithelial reaction to a pseudostratified type of respiratory epithelium. Note the indistinct basement membrane commonly accompanying metaplasia. This is covered by an atypical layer of epithelium, six to eight cells in thickness. The most superficial layers have undergone an irregular differentiation into blunt ciliated cells. At a later stage in repair of this type, goblet cells make an appearance. This patient died following surgery, 11 days after tracheostomy. H&E stain X330.

epithelium through a differentiation of the basal cells. The third modification involves a persistence of the transitional stratified multi-layered epithelium with an increasing tendency toward keratinization of the superficial layers (Fig. 5). The factors which regulate the direction and persistence of one or another trend in repair are unknown.

As a rule, however, there is a pronounced tendency for the epithelium to return to normal in the absence of complications such as those accompanying irradiation, persistent chronic severe inflammation or factors which render the distal respiratory tract susceptible to persistence of metaplastic changes. Among other things, this study poses the problems of factors which regulate metaplasia of respiratory tract epithelium and its persistence as a precancerous lesion or its reversibility with regeneration of normal mucosa in its place (Figs. 5 and 6).

The role of Vitamin A deficiency in the production of metaplasia of epithelium and its reversibility following restoration of Vitamin A both in the experimental animal and in vitro has been described by Wolbach and Fell.^{8,9} Hilding has also referred to the uncertainty which exists with respect to the causes of metaplasia and its role as a precursor of malignancy in the lower respiratory tract.¹⁰

SUMMARY

The histologic changes occurring in the lower respiratory tract following tracheostomy have been analyzed.

Specimens of trachea, carina and primary bronchi were obtained at the autopsy examination of 27 patients who had tracheostomies prior to death. Comparable tissues were obtained at autopsy from 44 patients without tracheostomies.

Intact epithelium was observed in only 1 of the 27 patients with tracheostomy. In the control group, 34 of the 44 patients exhibited an intact epithelial layer.

Carinal or unilateral bronchial ulceration was observed in 8 of 27 patients with tracheostomy and in none of the control group.

Various degrees of ulceration, denudation and infection in the lower respiratory tract were observed in 10 of 27 patients with tracheostomy and in 7 of the 44 controls.

In the reparative process, regeneration of epithelium was observed in 10 patients with tracheostomy and in none of the control group.

In the repair, metaplasia of the respiratory epithelium often occurred. The extent to which this might persist or be promptly reversed remains uncertain.

The regenerative process, metaplasia, chronic inflammation and other mucous membrane changes observed in this study of the lower respiratory tract have been recorded and analyzed.

1753 WEST CONGRESS PARKWAY

REFERENCES

1. Griffith, T. E., and Friedberg, S. A.: Histologic Changes in the Trachea Following Laryngectomy. *ANNALS OF OTOTOLOGY, RHINOLOGY AND LARYNGOLOGY* 73:883-893 (Dec.) 1964.
2. Knudtsen, K. D.: The Pathologic Effects of Smoking Tobacco on the Tracheal and Bronchial Mucosa. *Am. Journ. Clin. Path.* 33:310-317 (Apr.) 1960.
3. Hilding, A. C.: On Cigarette Smoking, Bronchial Carcinoma and Ciliary Activity. *ANNALS OF OTOTOLOGY, RHINOLOGY AND LARYNGOLOGY* 65:116-130 (Mar.) 1956.
4. Auerbach, O., Stout, A. P., Hammond, E. C., Garfinkle, L.: Changes in Bronchial Epithelium in Relation to Cigarette Smoke and to Lung Carcinoma. *New Eng. Jour. Med.* 265:253-267 (Aug. 10) 1961.
5. Sanderud, K.: Squamous Metaplasia of Respiratory Tract Epithelium. *Acta Path. Microbiol. Scand.* 43:47-61, 1958.
6. Hilding, A. C., and Hilding, J. A.: Tolerance of the Respiratory Mucous Membrane to Trauma: Surgical Swabs and Intratracheal Tubes. *ANNALS OF OTOTOLOGY, RHINOLOGY AND LARYNGOLOGY* 71:455-479 (June) 1962.
7. Plum, F., and Dunning, M. F.: Techniques for Minimizing Trauma to the Tracheobronchial Tree After Tracheostomy. *New Eng. Journ. Med.* 254:193-200, 1956.
8. Wolbach, S. B.: The Pathologic Changes Resulting from Vitamin Deficiency. *J.A.M.A.* 108:7-13, 1937.
9. Fell, H. B.: The Effect of Hormones and Vitamin A on Organ Cultures. *Ann. New York Acad. Science* 58:Article 7:1183-1187 (Nov. 17) 1954.
10. Hilding, A. C.: Experimental Studies on Some Little-Understood Aspects of the Physiology of the Respiratory Tract and Their Clinical Importance. *Trans. Am. Acad. Ophth. and Otolaryng.* 65:475-494, 1961.

DISCUSSION

DR. ANDERSON C. HILDING: For Dr. Friedberg to ask me to discuss this paper may have been unwise, since this subject is of special interest to me. It is like asking a Ph.D. candidate to tell you about his research project . . . you won't get away in ten minutes. Dr. Friedberg has presented enough topics for a dozen lectures. Attempting to discuss his paper reminds me of a favorite final examination question credited to one of my physiology professors—"What's of the blood?"

It is both refreshing and encouraging that damage to the respiratory epithelium from things that we do is being seriously studied. This has been a neglected field. What happens to the tracheal epithelium when the nose is by-passed, as in tracheos-

tomy, is very important. Dr. Friedberg has shown that many things happen at the time of operation and immediately postoperatively. I hope that some time he can report on a series of patients who have used a tracheostomy for five to ten years.

He mentioned autolysis. It is not always easy to identify this. The general pathologists usually do not have much to say about the respiratory epithelium, partly, I believe because of what they call postmortem autolysis. It is true that there are extensive changes commonly present, which may be due to terminal infection or postmortem changes (if the time lapse has been about two days or more before necropsy), but some of the changes are mechanical. One day, as I stood watching a necropsy, the pathologist, wearing coarse rubber gloves, split the trachea and stripped out the secretion with his thumb. I asked him to be careful of the epithelium since I wished to examine it. He replied, "Why I never touch it." "But, George, you have your thumb in it now." This step was so automatic with him that he did not realize he ever did it. Stripping out the secretion with a coarse rubber-gloved thumb does a great deal of damage.

Another source of artifact is the handling of the tissue by the technicians in the histology laboratory. I have found it desirable, in experimental work, to handle the tissue myself from the time it is removed from the animal until it is safely imbedded in paraffin. Even the areas touched by the fingers of workmen in the packing plant, incident to removal of the trachea, can be immediately demonstrated by spraying on a little methylene blue. Under the microscope, considerable damage is apparent.

All such damage can be greatly minimized by gentleness and by avoiding contact with the surface. In some of the experimental calves which I tracheotomized, there was practically no change in the epithelium just beyond the end of the tube during the days (up to 10) which the animal was permitted to live. Over longer periods, there undoubtedly are changes, as Dr. Friedberg has pointed out.

In judging metaplasia histologically, one can easily go astray. When we see epithelium made up of several layers of cells, none of which is columnar, and none of which is ciliated, we are apt to call this metaplastic. It may be that the epithelium was just in the process of repair, during which it passes through such stages. Perhaps two or three days later, the cells would be columnar in form and well ciliated.

DR. LIERLE: I would like to ask Dr. Friedberg to tell us a little bit more about the control series. I am not quite clear about it.

DR. JEROME A. HILGER: In a series such as this, inevitably a large number of the patients had as indication for tracheostomy a profound coma, such as occurs with intracranial injury or disease.

Profoundly comatose people aspirate, possibly in a matter of hours, not to mention a matter of days.

I would like to ask Dr. Friedberg how much of the damage shown is due to the aspirate and how much due to the presence of the tracheostomy?

DR. REED: I would like to ask the same question of Dr. Friedberg in reference to aspiration with suctioning.

How much of the trauma is mechanical from nurses and doctors suctioning the patient through their tracheostomy?

DR. JOHN F. DALY: I would like to ask Dr. Friedberg how many of these patients were heavy smokers?

Dr. Auerbach, a pathologist, in a study on smokers found many of these changes in smokers' tracheas.

DR. FRIEDBERG (closing): I would like to thank all of the discussers and particularly Dr. Hilding, whose pioneer efforts in this field are really quite an inspiration.

Certainly the role of the prosector performing the autopsy and the technician handling the tissues is an important one in this connection. Our uncertainty about the exact role of metaplasia is the same as Dr. Hilding's. However, when one sees a slide in which the epithelium is many, many layers thick, I think that it is evident that this represents more than just involvement of the basal layer of the epithelium.

Dr. Lierle, the control series had to do with patients who came to the autopsy room without benefit of tracheostomy. We simply took the carina, the trachea and the bronchi from those people, studied them as to whether or not there was evidence of ulceration of the mucous membrane, denudation of the mucosa, inflammatory changes in the submucosa, and so forth.

DR. LIERLE: They had no respiratory infection?

DR. FRIEDBERG: Some of them did have respiratory infections and there is ample evidence of this in the slides. I will cover that in answer to Dr. Daly's question.

Dr. Hilger, I can only say that this kind of a study gives you a bit of pause because I am sure that many of these changes are iatrogenic in origin. I think that the aspiration catheter which is placed into the trachea, through the cannula, is hitting the carina regularly and bouncing off of it down into the right main bronchus. Approximately one-third of the patients in this series presented very definite carinal ulcers and there were absolutely none in the other group, so that I think there is no question about that.

With regard to aspiration, it is true that the so-called autolysis, poor staining of the epithelium, we believe is due to the aspiration of gastric contents. Many of the patients in the control group died with those changes and I think it was the terminal episode.

Dr. Reed's question is answered in the same way. I am convinced beyond any question that the aspiration procedure is doing a good deal of the damage.

Dr. Daly, we did find that the smokers showed evidence of metaplasia and that the patients with chronic lung disease also showed evidence of metaplasia.

I think that in the printed article and in my opening remarks I have tried to indicate that we are not attempting to ascribe these changes to tracheostomy alone, that there is a combination of factors which exist, all of which have to be taken into account, but the actual traumatic ones I believe are the main by-product of this particular study.

DR. FRANCIS L. LEDERER: I purposely refrained from asking this question because it really has nothing to do with the paper, but I think for the benefit of posterity and ourselves that since tracheotomy and tracheostomy are used as almost synonymous terms, it would be beneficial to distinguish the two by definition.

DR. MONTGOMERY: Tracheotomy and tracheostomy are both names of operations, as are gastrotomy and gastrostomy. The end result of a tracheotomy is a tracheal fenestration. During this operation an opening, or a tract, is created between the skin of the anterior neck and the trachea. There is no cutaneous-mucosal connection. The end result of a tracheostomy is a tracheostoma. This operation results in a transected or opened trachea sutured to the skin of the anterior wall.

DR. FRIEDBERG: Tracheotomy is an operation that actually denotes cutting; tracheostomy is a product of that operation and refers to the communication which is established between the trachea and the exterior.

HISTOLOGIC CHANGES PRODUCED BY ENDOTRACHEAL INTUBATION

WALTER L. WAY, M.D.

(by invitation)

AND

FRANCIS A. SOOY, M.D.

SAN FRANCISCO, CALIF.

Endotracheal intubation is used as an adjunct to many surgical procedures. It is the purpose of this study to determine the adverse effects on the larynx and trachea of such intubation. The over-all objectives of the study are: 1) to consistently produce a lesion by endotracheal intubation; 2) to determine the nature of that lesion; and 3) to evaluate the effect of various therapeutic agents on the lesion.

1) To be of clinical value, the "standard" lesion should be produced in the human or in a species whose airway closely resembles that of the human. The cynomolgus monkey was chosen for this purpose. The lesion was produced by intubation with a "larger than correct size" catheter.

2) Once produced, the pathology should proceed in a definite fashion from onset of lesion to healing. Thus, the length of healing can be determined and clinical observations can be related to those made in the intubated monkey.

3) If a lesion can be produced consistently by endotracheal intubation, then therapy must be investigated and the most effective agent recommended. In this preliminary study, a steroid, dexamethasone (Decadron®), was given to part of the monkeys.

From the Department of Anesthesiology and the Division of Otorhinolaryngology, University of California Medical Center, San Francisco, California.

This study was supported in part by the University of California School of Medicine Committee on Research.

METHOD

Monkeys were anesthetized with intravenous pentobarbital sodium. Endotracheal intubation was carried out in a standardized manner by one of the authors (WLW). A #1 Miller laryngoscope was used in all monkeys. Murphy red rubber endotracheal catheters were used throughout and the "correct" size was determined by actual placement in the trachea. Any resistance was considered evidence that the tube was too large, and a tube one French size smaller was tried. Once the "correct" size was determined, that tube was removed and a tube one French size larger was inserted. These tubes were not cuffed or lubricated.

Fourteen monkeys were intubated, 11 with a catheter that was too large and three with a properly fitted tube. These last were used as controls. The endotracheal tubes were left in place for two hours. During that period of time no additional anesthesia was given, no respiratory assistance was provided, and no attempt was made to remove secretions from the airway. Pulse rate and respiratory rate were stable in all animals throughout this period.

At the end of two hours, the catheters were removed. A single dose of dexamethasone (4 mg intramuscularly) was given immediately to each of five monkeys, one of which was a control.

Sacrifice began 24 hours after termination of the intubation. A control animal and an animal intubated with an oversized tube were sacrificial at this time. The remaining animals were sacrificed at 48, 96, and 144 hours after termination of intubation. The entire larynx and trachea were removed intact. The strap muscles, fat, and external connective tissue were dissected away and the specimen placed in formalin for a four-day period of fixation. Each specimen was then cut longitudinally in the midline (Fig. 1) and 8-micra sagittal serial sections were cut to show the false cords, true cords, conus elasticus and trachea. Eight consecutive sections were chosen for staining and the next ten sections were discarded to save time and expense. This was repeated along the entire width of the specimen. About 160 slides were made from each half larynx.

Each set of eight sections was stained as follows:

- 1) with *hematoxylin and eosin* (2 sections).
- 2) with *colloidal iron-hematoxylin-picrofuchsin* for acid mucopolysaccharides¹ (2 adjacent sections. One was treated with testicular

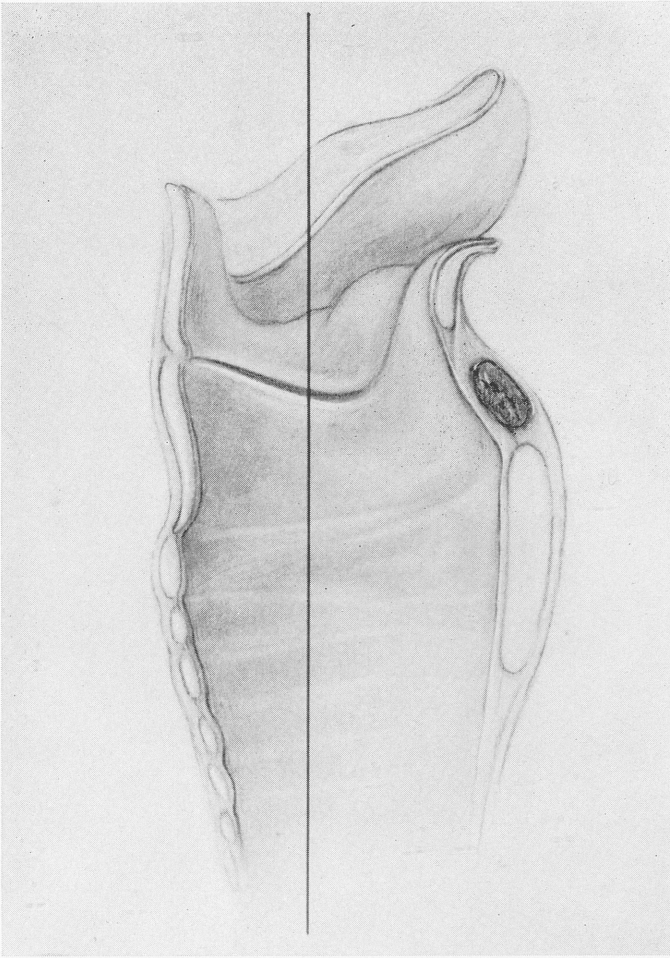


Fig. 1.—Normal monkey larynx. Vertical line indicates plane of microscopic section.

hyaluronidase to remove acid mucopolysaccharides; both sections were then stained.).

3) with *toluidine blue* for metachromasia¹ (2 adjacent sections. As before, one was treated with testicular hyaluronidase to remove acid mucopolysaccharides prior to staining.).

4) with *modified resorcin-fuchsin* for elastic tissue² (1 section).

5) with *acid orcein* for elastic tissue³ (1 section).

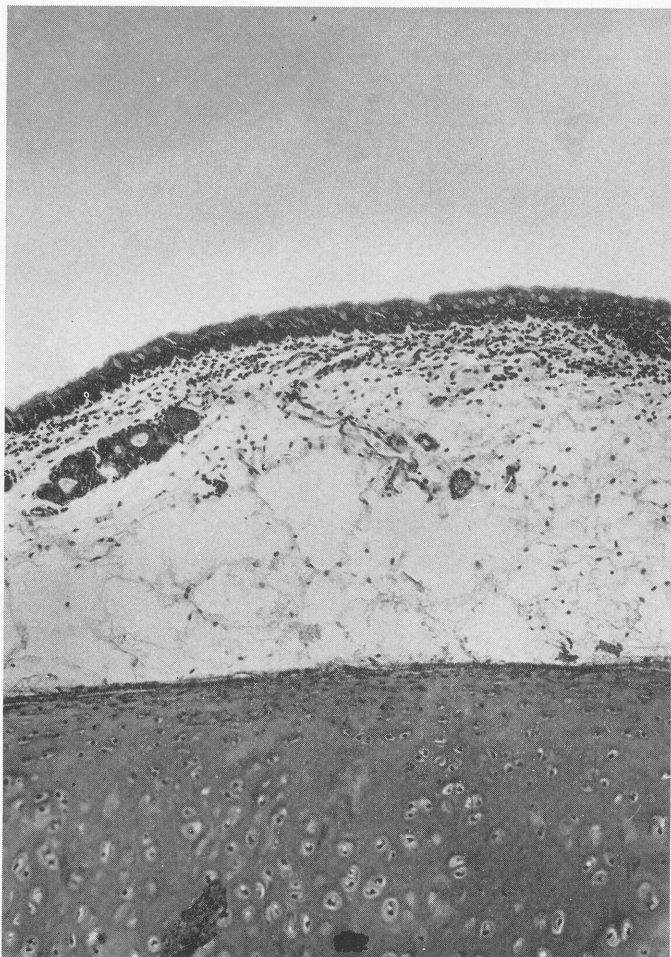


Fig. 2.—Microscopic anatomy of normal monkey larynx (X 400).

Similar sections were made of larynges of three additional monkeys in which no intubation had been done and no drugs given.

RESULTS

No pathologic lesions were seen in the larynx or trachea of the three normal (no intubation, no therapeutic agents) monkeys (Fig. 2).

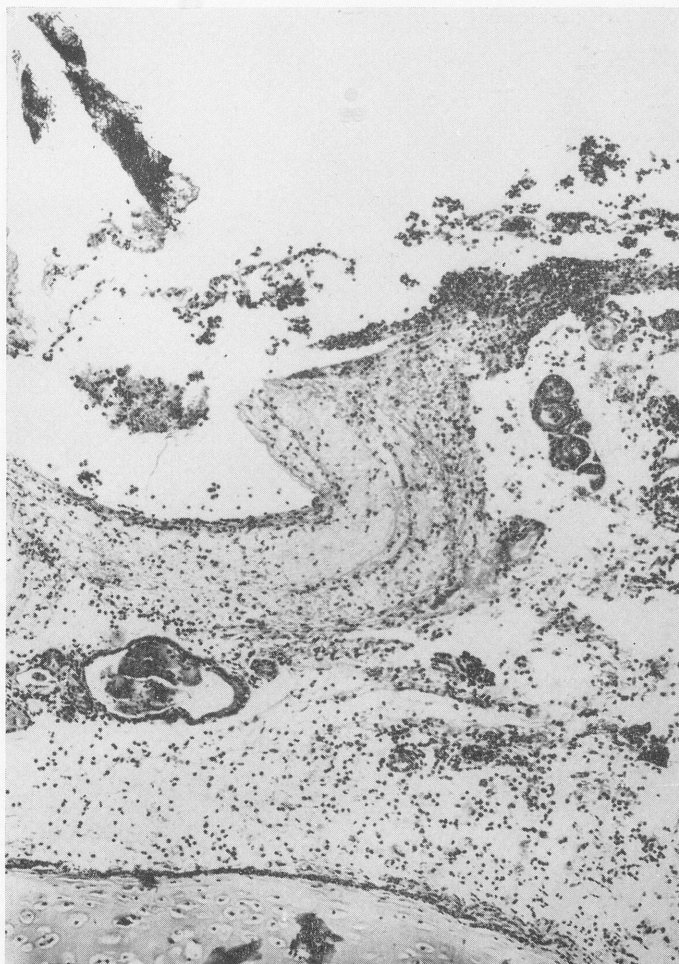


Fig. 3.—24 hrs. postintubation with large tube (X 400).

The remaining sections were examined for several specific changes: 1) the degree of polymorphonuclear infiltration, 2) the presence of ulceration, 3) the degree of epithelial regeneration if ulceration had occurred, 4) the presence of edema, 5) vascular alterations, and 6) changes in acid mucopolysaccharide content and in elastic fibers.

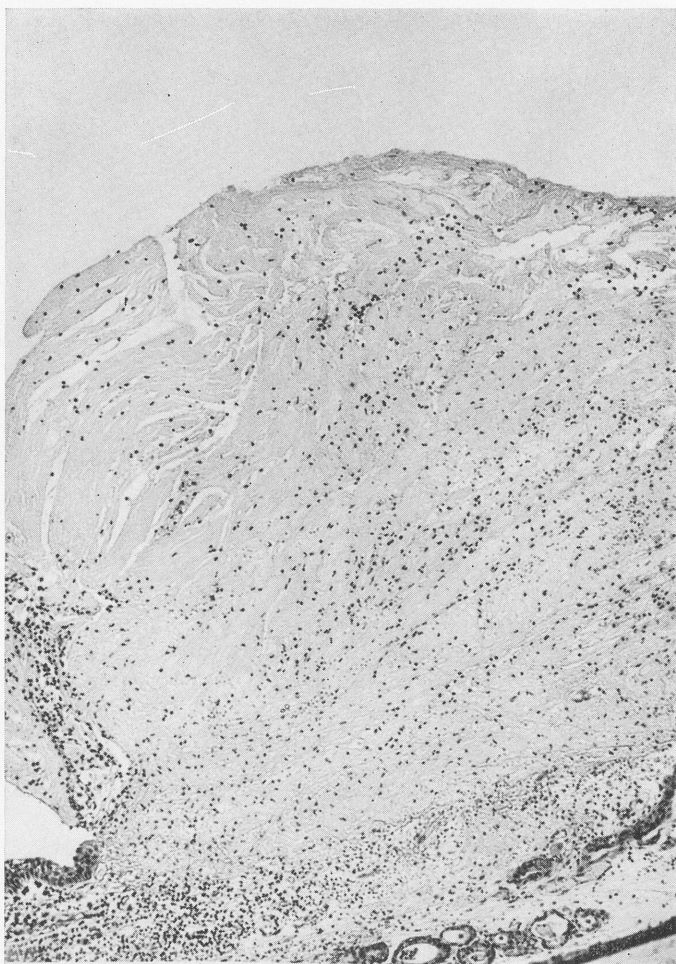


Fig. 4.—48 hrs. postintubation with large tube (X 400).

All but two of the experimental larynges showed a rather marked polymorphonuclear infiltration which was greatest in the 24- and 48-hour specimens (Figs. 3 and 4). This response had significantly diminished at 96 hours and was even less at 144 hours (Figs. 5 and 6). Infiltration of inflammatory cells was significantly less in the sections made from animals to which dexamethasone had been given. One of

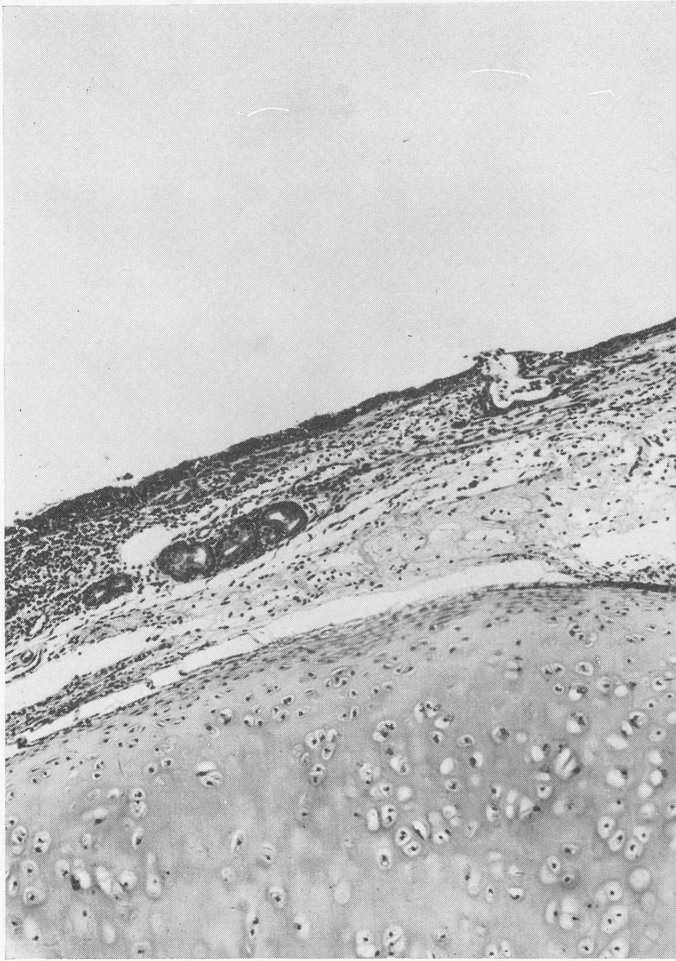


Fig. 5.—96 hrs. postintubation with large tube (X 400).

the control larynges (correct-sized tube) and one of the steroid-treated larynges showed no change in polymorphonuclear cells.

Mucosal ulceration was produced in all larynges except two control larynges (Figs. 7 and 8). It was characterized by complete epithelial denudation and production of a lesion averaging 6 mm in length at 24 hours. In all instances, the ulceration appeared over

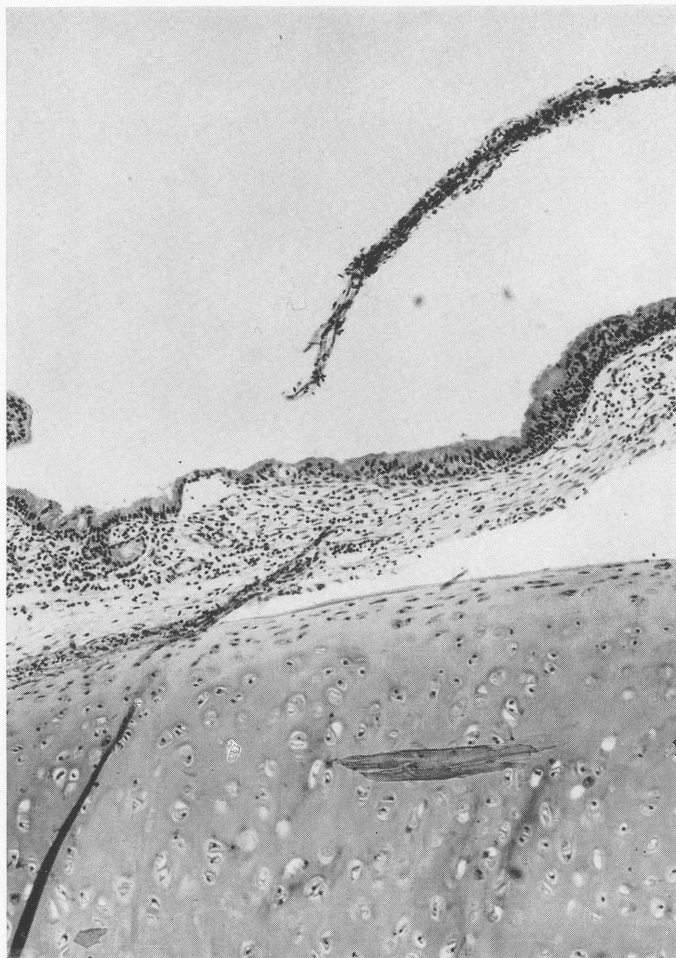


Fig. 6.—144 hrs. postintubation with large tube (X 400).

the cricoid cartilage at the point where the medial margin of the cartilage was closest to the epithelium of the respiratory tract.

Regeneration of the denuded mucosa was increased in the 48- and 96-hour specimens (the lesion averaged 2.4 mm in the 96-hour specimens); in one 144-hour specimen the ulceration had completely healed.

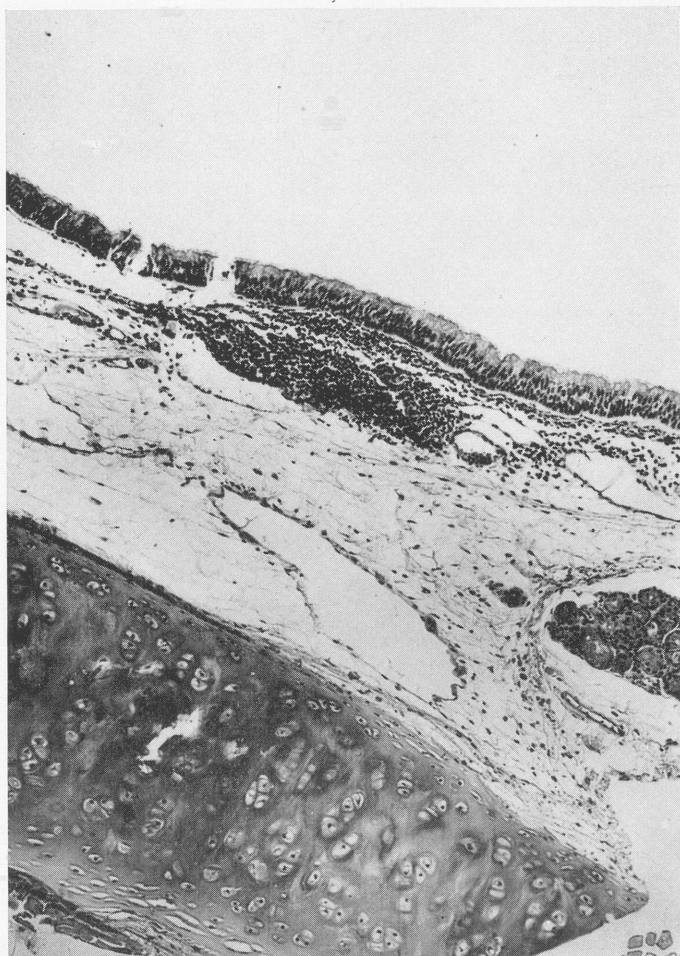


Fig. 7.—24 hrs. postintubation with control tube (X 400).

Edematous changes were evaluated by measuring the thickness of tissue between the medial margin of the cricoid cartilage and the overlying mucosal edge, and by subjectively appraising the soft tissue of that area. By these criteria, edema was present in all animals at the site of trauma. Dexamethasone appeared to have had no effect on its formation. Edema was also present in the two control larynges that had not exhibited signs of ulceration.

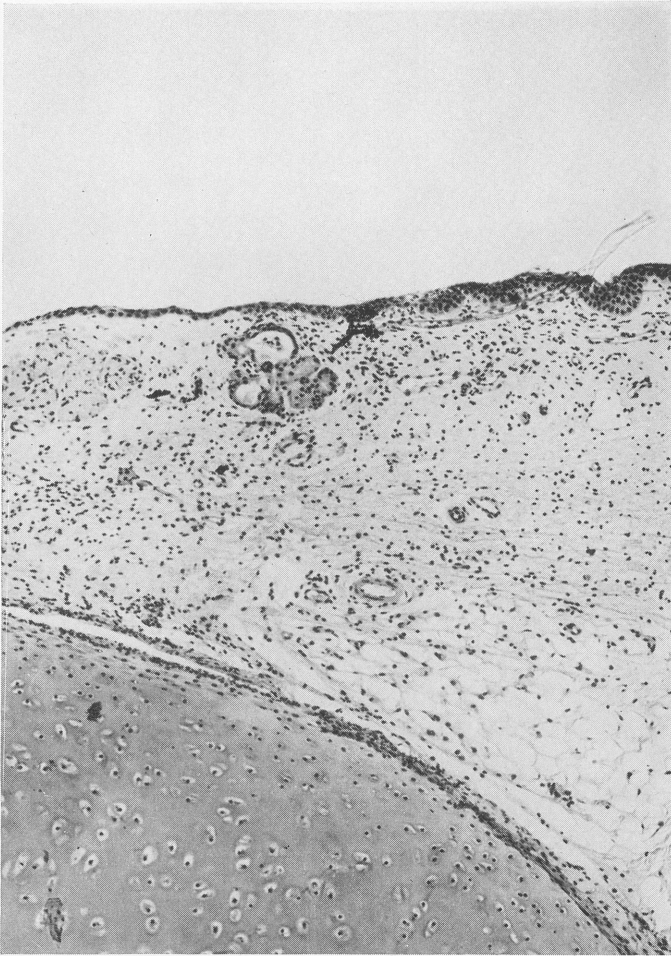

Fig. 8.—24 hrs. postintubation with control tube and 4 mgm of dexamethasone (X 400).

No significant vascular findings were noted.

In larynges intubated with an oversized tube, the submucosa showed an increase in acid mucopolysaccharides during the first 48 hours. These gradually decreased and, at 144 hours, were comparable to the normal complement. The increase was greatest in the area surrounding the conus elasticus, which might lead to speculation that

the stretching of the tissues had set up a connective tissue reaction. The smaller increase in and around the lesion probably reflected the inflammatory reactions present. Very little difference was noted between the larynges of animals that had received dexamethasone and those of untreated animals.

The conus elasticus showed no change in any of the specimens. Interestingly, the fine elastic fibrils that run through the submucosa and under the epithelium remained relatively intact at all stages even though epithelial denudation, ulceration, and marked polymorphonuclear infiltration had occurred. As healing progressed, the usual cellular population formed around these fibrils and the normal pattern was re-established.

COMMENT AND CONCLUSIONS

The lesions produced in these experiments closely resemble those noted in human beings.^{4,5} The human laryngotracheal anatomy does not significantly differ grossly or microscopically from that of the monkey except that the monkey has a slightly better developed inferior thyro-arytenoid (vocal) fold.⁶ The technique of intubation was reviewed carefully for its influence on the results. The same laryngoscope was used throughout, and the tubes were of the same type in all instances. All intubations were performed by the same individual, one experienced in the placement of endotracheal catheters. He subjectively determined the "correct" size of the tube, but the fact that he alone made these decisions should have rendered them fairly consistent.

Use of an oversized endotracheal catheter appears to be a satisfactory means of consistently producing ulceration of the tracheal mucosa. In this series, ulceration was produced only over the firm cricoid cartilage. It would appear that the cartilage prevented the mucosa and submucosa from yielding to the pressure of the outsized tube and they were firmly compressed between the two rigid structures. Whether direct necrosis of tissue resulted or whether these changes are a function of ischemia can only be conjectured at this time.

Logically, repetitive long-term movements of the trachea against an endotracheal tube would tend to increase the trauma over the cricoid cartilage. (A similar mechanism has been proposed as the cause of vocal cord polyps after endotracheal intubation.^{7,8}) When

endotracheal intubation is carried out under light anesthesia, these chances of tissue damage should be greater since the reflex responses tend to make the subject cough, close his glottis, and perform other acts that will help expel a foreign body from the airway. Obtundation of the airway reflexes is known to be poor with barbiturate anesthetics.⁹ Thus, it is not surprising that all animals coughed for 20 to 30 seconds following placement of the "chosen" catheter and again when it was removed two hours later. However, this type of anesthetic may produce a more level state of anesthesia than the inhalational agents used more frequently clinically. By doing so, it may decrease the number or degree of changes in the diameter of the airway during anesthesia. It is hoped that the effects of various types and depths of anesthesia on endotracheal-tube-induced tracheal lesions can be investigated at a later date.

In all probability, the effects of various types and dosages of steroids and antihistaminics on these lesions will be investigated and reported at a later time. Only one dosage of dexamethasone was used in the present series and it appeared to have no effect on the pathogenesis of the lesion. Clinically the tracheal lesion best treated with steroids is that of subglottic edema, especially that in the infant. Although edema was produced in all larynges studied here, it was not of the magnitude seen in patients with subglottic edema. It is possible that a lesion with a much greater degree of edema must be produced in order to adequately evaluate the efficacy of steroids in such a situation. The single dose of steroid used here did, apparently, have an anti-inflammatory effect, as is shown by the decreased number of polymorphonuclear cells. Such an effect might be of value in the treatment or prevention of the more severe subglottic edema. In the case of actual tissue disruption as produced in this experiment, steroid suppression of the healing process may be undesirable.

SUMMARY

Ulceration of the tracheal mucosa overlying the cricoid cartilage was produced consistently in anesthetized cynomolgus monkeys by insertion of an oversized endotracheal tube. The tubes remained in place for two hours. The tracheas were excised at periods ranging from 24 to 144 hours after termination of intubation, stained, sectioned and studied histologically.

All but two of the larynges showed a rather marked polymorphonuclear infiltration which was greatest in the 24- and 48-hour speci-

mens. This response had significantly diminished at 96 hours and was even less at 144 hours.

The ulcers appeared only over the cricoid cartilage. Epithelial regeneration had begun by 48 hours after intubation and was complete in some larynges by 144 hours.

Edema was present over the cricoid cartilage in all larynges.

During the first 48 hours, acid mucopolysaccharides increased in the submucosa of the larynges intubated with oversized tubes. This increase was greatest in the area around the conus elasticus, and had disappeared by 144 hours. The fine elastic fibrils that run through the submucosa and under the epithelium remained relatively intact in all specimens in all stages even in the area of polymorphonuclear infiltration and ulceration.

No significant vascular changes were noted.

Dexamethasone given as a single 4 mg intramuscular injection to some of the animals just after the period of intubation apparently decreased the number of inflammatory cells infiltrating the traumatized area. It appeared to have no effect on edema, the speed with which epithelial regeneration occurred, or acid mucopolysaccharides.

UNIVERSITY OF CALIFORNIA SAN FRANCISCO MEDICAL CENTER

ACKNOWLEDGEMENTS—The authors wish to express their appreciation to Dr. John S. Wellington of the Department of Pathology for his examination of part of the slides used in this report. The assistance of Mrs. Helen F. Burn, Mrs. Mary Carol Williams, and Miss Maud Pearson is gratefully acknowledged.

REFERENCES

1. Weisskopf, A., and Burn, Helen F.: The Ground Substance of the Nasal Turbinates. *ANNALS OF OTOTOLOGY, RHINOLOGY AND LARYNGOLOGY* 67:292-304 (June) 1958.
2. Krutsay, M.: A Versatile Resorcin-Fuchsin Formula. I. Combined with Formaldehyde, II. Used after Periodic Acid, III. Used after HCl Hydrolysis. *Stain Technology* 35:283-284 (Sept.) 1960.
3. Burn, Helen F.: Personal Communication.
4. Lu, A. T., Tamura, Y., and Koobs, D. H.: The Pathology of Laryngotracheal Complications. Lesions of the Larynx and Trachea after Intubation Anesthesia. *A.M.A. Arch. Otolaryngol.* 74:323-332 (Sept.) 1961.
5. Baron, S. H., and Kahlmoos, H. W.: Laryngeal Sequelae of Endotracheal Anesthesia. *ANNALS OF OTOTOLOGY, RHINOLOGY AND LARYNGOLOGY* 60:767-792 (Sept.) 1951.

6. Negus, V. E.: *The Comparative Anatomy and Physiology of the Larynx*. Grune and Stratton, Inc., New York, 1949.
7. Barton, R. T.: Observations on the Pathogenesis of Laryngeal Granuloma due to Endotracheal Anesthesia. *New Eng. J. Med.* 248:1097-9 (June 18) 1953.
8. Campkin, V.: Postintubation Ulcer of the Larynx. *Brit. J. Anaesth.* 31: 561-2, 1959.
9. Dundee, J. W.: *Thiopentone and Other Thiobarbiturates*. E. and S. Livingstone, Ltd., Edinburgh and London, 1956.

DISCUSSION

DR. SOOY: We were very pleased that this paper showed two things: one, that when laryngeal edema appears following intubation and appears within the first two hours, the possibility of tracheotomy is quite great and the advisability of tracheotomy, I think, is high.

And secondly that at least the clinical use of steroids probably is still open to some question.

DR. DANIEL CLIFTON BAKER, JR.: There are a few points that I would like to make about this presentation concerning the histologic changes produced by endotracheal intubation.

Several years ago in preparing a thesis for one of our societies—this goes back to 1946 or '47—I collected twelve cases of patients who developed post-intubation granulomata and for a period of years there were several granulomatas that were presented in the literature. Then there was a dropping off of this condition and the question arose of what it was ascribed to. Certainly from my standpoint the big thing has been the introduction of the relaxant anesthetics.

Trauma, of course, is not only possible by the size of the tube that might be used, but if the cough reflex isn't controlled, then presumably any tube that is in the larynx, if the patient coughs against it, can give rise to trauma, and I would like to hear some discussion about this.

DR. PAUL H. HOLINGER: Certainly this paper is extremely interesting and very timely. It leaves a great deal that must be followed further in subsequent work.

I wonder whether the authors could tell us what types of tubes were used, whether these were rubber tubes or portex tubes, and why they avoided the use of cuff tubes in carrying out the study? What cleaning agents were used on the tubes, because these, too, are of extreme importance in the development of subsequent irritation.

The trauma of introduction is likewise an important factor and we have had this problem illustrated by Dr. Baker just a moment ago. Whether the relaxants allow for total relaxation of the larynx for introduction or whether trauma with a rough laryngoscope, or rough introduction of the laryngoscope, likewise play a definite part in creating histologic changes.

Dr. Baker also mentioned the problem of coughing; did the essayists have the experience of increasing the degree of reaction by the various depths of anesthesia during which the tube was introduced?

We find that with women in labor who have endotracheal anesthesia, the percentage of irritation seems to be considerably higher because with many of them

there is a need for speed with which the anesthesia is administered and the patient may not be entirely relaxed at the time the tube is introduced.

So that the variables are, I think, the type of induction, the type of tube, the cleaning agent, trauma of introduction, to mention just a few.

The authors did not discuss the long-term changes, such as the granulomas, which are not seen until two or three months later, but certainly their paper is a tremendous help in the further elucidation of this subject.

DR. WALTER P. WORK: In any training institution you are going to get a number of people learning intubation, and I think this plays a great part in the amount of trauma that may be present postoperatively in patients.

This paper also points out interdepartmental cooperation, which I think is very good. If the anesthesiologists learn our problems and we learn theirs, we are well on the way to protecting our patients.

The thing that I would like to also ask is how much pressure—if these tubes had cuffs on them, how much pressure was used in the cuff? I think this is very important, particularly in a long-drawn-out surgical procedure.

I think that Dr. Lierle hinted at this a little while ago and I certainly heard Dr. Pressman some years ago expound on this—that infection pre-operatively or a patient in the prodrome of an infection is more susceptible to postoperative edema.

We have had two patients recently at the University Hospital, both adults, one subglottic edema that required tracheotomy twenty-four hours after intubation, and just this past week we have had an adult upon whom we did a Caldwell-Luc of less than one hour procedure, and she, too, required tracheotomy. Postoperatively she became more hoarse. We looked in her larynx indirectly and saw this leukocytic fiber membrane. As we watched that, it got more constricted until finally she had just a millimeter or so to breathe.

We have seen this very membrane in the trachea itself, and we have always placed it at the region of the cuff. I do want to congratulate the essayist and Dr. Sooy, on this interdepartmental cooperation to do the best we can for our patients.

DR. PRESSMAN: This is an excellent and thought-provoking study by the Departments of Otolaryngology and Anesthesiology at the University of California, in San Francisco.

I doubt very much that anyone would fail to recognize that pressures exerted within the larynx vary with any insert, depending upon such variables as the stage of anesthesia, not only at the time of introduction, as stressed by Dr. Holinger, but the depth of anesthesia throughout the length of time the tube is indwelling: Obviously, pressures will vary greatly when the reflex begins to return, and the larynx squeezes on the tube. In view of this, perhaps the greatest degree of trauma is not in the cricoid area but at the level of the vocal cords. The arytenoid is particularly subject to injury—since the greatest trauma comes from intermittent opening and closing as the degrees of anesthesia lessen and lighten. One should keep a rather accurate record of the depth of anesthesia throughout the experiment. In the clinical aspects of this problem it is our duty to warn the anesthesiologist of the fact that the greatest harm comes not at the time of introduction of the tube but as patients' depth of anesthesia is lightened, particularly if this is repeated on and off through the prolonged operation that Dr. Work mentioned.

We have seen it happen time and again that the anesthesiologist, in his enthusiasm to aspirate the tracheobronchial tree of any secretion at the end of the operation,

will allow the patient to become light and just before the patient actually comes out of the anesthetic to the point of consciousness returning, he will then aspirate the trachea and the bronchi, for which reason the intratracheal tube has been left in situ for so long. During this interval the larynx is closing forcibly in natural response to the presence of any foreign body within it, and I believe this particular reaction of the larynx on squeezing on this tube as the depth of anesthesia lightens is one of the most potent forces for destruction of surface epithelium and the development of granulomas.

DR. OGURA: What Dr. Pressman just brought up I would like to fortify with some experimental work which relates activity of the cord with the depth of anesthesia.

Number one, if you carry the plane of anesthesia in the animals down to the third and fourth plane, the action of the cords and the squeezing action is obliterated and lost and when you lighten it the activity is increased. Furthermore, there is a synchronous relationship with respiration, that as respiration becomes light there is increasing activity, and as respiration becomes deeper activity of the cord ceases.

DR. PAUL M. MOORE: I am so glad to learn of this work and I want to thank the essayists for their very careful investigation. To me one of the applications clinically is the tendency for many anesthesiologist to want to intubate the little children for T & A. Now, although it is a short procedure, you do have a small larynx and you have a small trachea. My experience has been that the airway is practically never threatened when not using an intubation tube but when that tube is put in, I went through the period when we had to take out a lot of foreign bodies and we did a lot of tracheotomies. I don't want to see it come back.

DR. WAY (closing): First of all, I have seen Dr. Lierle here. I don't know him personally, but I am sure if Dr. Stewart Cullen, my chief, could be here he would be very pleased to hear your remarks.

We started out, as I mentioned, attempting originally to define the subglottic edema that occurs, particularly, in children. We were not looking for granulomata, which certainly can occur and which, I think, are primarily due to adduction/abduction of the cords against the rigid structure of the tube. We think this is a function of the depth of anesthesia.

Dr. Holinger, with regard to the type of tube and laryngoscope, in this instance we used a Miller laryngoscope blade, which, as you know, is a straight blade with a small upsweep on the tip. The tubes were red rubber catheters of the Murphy type; that is, they have a side vent on them. The reason that no cuffs were used in this study is that a monkey larynx—at least in the cynomolgus monkey that we used—is small. They take anywhere from a 16 to 20 French tube normally and, as you know, it is almost impossible to buy a cuff of this type. Certainly, to put a cuff on a tube this size would compromise the already small airway. Since we were trying to check for infant intubations and the problems therefrom, we felt that the uncuffed tube (which is what is used in an infant) was the proper thing to use.

The sterilization method in our hospital is gas sterilization. The tubes were prepared as our normal tubes are prepared for the operating room, that is, packaged in polyethylene, sent to the gas sterilization room, and then utilized by us in the monkey laboratory. This should answer Dr. Work's question.

The infection is, I think, something very important. As you know, in anesthesia today the anesthetist should not just sit behind a screen, squeeze a bag, and make funny stories; he sees patients beforehand and evaluates each individually in terms of infection. In our hospital in the last month—I have just taken a small

survey—we have refused to anesthetize patients (particularly infants and children) who gave signs of upper respiratory infection. This has met with the approval of the various surgical services. Obviously, sometimes one is pushed into it because of emergency or urgent surgery, but this is an entirely different matter.

Dr. Pressman, I think you were requesting pressures in the cuff itself. As I say, we didn't use cuffs, but I am sure that that is an important factor, again producing pressure between a rigid structure with the cricoid on one side and the tube or the cuff on the other; the changing anesthesia is certainly an important factor.

Dr. Ogura mentioned the depth of anesthesia and I feel that this is also very important.

Dr. Moore mentioned T & A intubation and, as far as I am concerned, this is still an open subject. I think there are many instances in which it should be utilized. I hope your confidence in us with regard to the use of endotracheal intubation would be sufficient to allow the technique to be used whenever necessary.

GLOMUS TUMOR (CHEMODECTOMA) OF THE LARYNX

JAMES D. BAXTER, M.D.

MONTREAL, CANADA

Although glomus tumor, or chemodectoma of the larynx is extremely rare, it should be considered clinically in the differential diagnosis of any persistent, smooth, noninflammatory, intralaryngeal swelling.

The most common site of origin of chemodectoma is the carotid body. This structure was first described in the middle of the eighteenth century by Haller¹ who thought it was a sympathetic ganglion. In the intervening years it has been regarded by different authors as a ductless gland, a chromaffin body, a paraganglion, and a cavernous vascular organ. Tumors arising from the carotid body have been classified as adenomas, chromaffinomas, nonchromaffin paragangliomas, endotheliomas, as well as by the more general term of chemodectomas.² DeCastro³ first suggested that the carotid body was a chemoreceptor organ on the basis of his morphologic studies, and this has been confirmed physiologically.⁴ The organ is related to the reflex control of respiration and its prime stimulus is anoxemia. It has nothing physiologically to do with carotid sinus reflexes regulating blood pressure.

In 1941, Guild⁵ described the glomus jugulare lying in the adventitial layer of the dome of the jugular bulb, or along the tympanic branch of the IX nerve in its bony canal, or rarely, in the sulcus of the promontory. He observed small structures "usually less than half a millimeter in their longer dimensions" near or in the wall of the jugular bulb. Microscopically these structures were found to be similar to that of the carotid body. Small blood vessels, capillary, or precapillary in size, surround epithelioid cells; a capsular layer of fibrous tissue surrounds the glomus, sending fibrous septa between the small lobulations. A glomera may be predominantly cellular or vascular in type. Guild assumed that the function of the glomus jugulare and the carotid body was similar.

In 1945⁶ Rosenwasser reported the first recognized tumor arising from the glomus jugulare and called the neoplasm a carotid body tumor of the middle ear and mastoid.

Embryologically, the central nervous system is derived from the ectodermal neural tube, and its spinal ganglions are differentiated from the ganglion crest of this tube. Some of the cells of the ganglion crest migrate ventrally to form the sympathetic ganglions. Other cells, instead of becoming neurons, develop into gland cells, as in the adrenal medulla, and are called paraganglionic tissue. They stain brown with chrome salts and have been termed chromaffin. The carotid body is considered to be paraganglionic tissue although it is nonchromaffin and non-epinephrine producing.⁷ The glomus jugulare and similar tissue is presumed to be in the same category.

It is conceivable embryologically to visualize paraganglionic tissue migrating to unusual locations, and clinically this is confirmed by the occurrence of carotid body-like tumors in unusual sites. Carotid body-like tissue or glomus bodies are normally more diffusely distributed in the body than is generally recognized.

Carotid body-like tumors have been found associated with the glomus intravagale, the aortic-pulmonary bodies, along with the femoral canal, in the eye, in the mandible, in the larynx, in the retro-peritoneum, in the ileal mesentery, in the skin of the extremities, and elsewhere.

In 1955, Albert A. Andrews⁸ of Chicago reported the first case in the literature of a glomus tumor of the larynx. This occurred in a twenty-seven year old white male, and presented as a large mass in the left side of the larynx, which was dull red in colour and produced complete fixation. The right side of the larynx was essentially normal. For two years, the patient had symptoms of hoarseness, shortness of breath and dysphagia, as well as variable elevation of blood pressure for nine years. There has been an increase in the symptoms during the preceding three weeks.

Following a preliminary tracheotomy, at thyrotomy the tumor mass was observed to extend from the level of the vocal cord to the border of the aryepiglottic fold, and to occupy the entire left side of the larynx. Extremely free bleeding occurred on removal, at which a clear line of cleavage was found, and the tumor was shelled out by blunt and finger dissection.

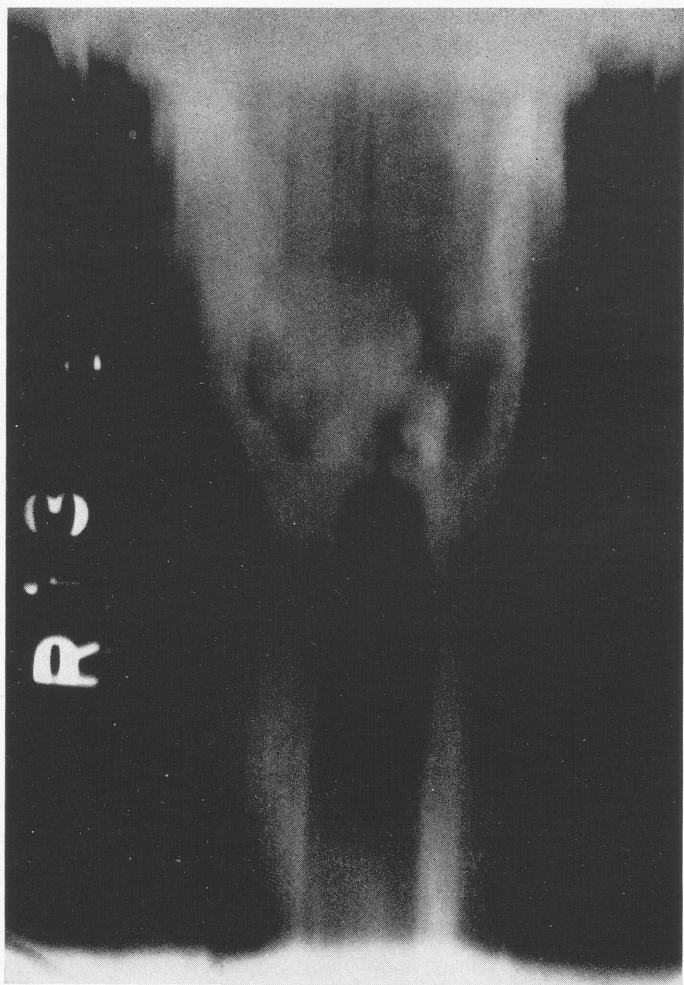


Fig. 1.—Frontal tomography (November 27, 1963) at level of the middle of the larynx showing smooth, intralaryngeal supraglottic mass on right side.

The postoperative course was uneventful, and the tracheotomy tube was removed one month later. When last examined, one and a half years following surgery, the larynx was reported to be in good condition and without evidence of recurrence. The voice was improved.

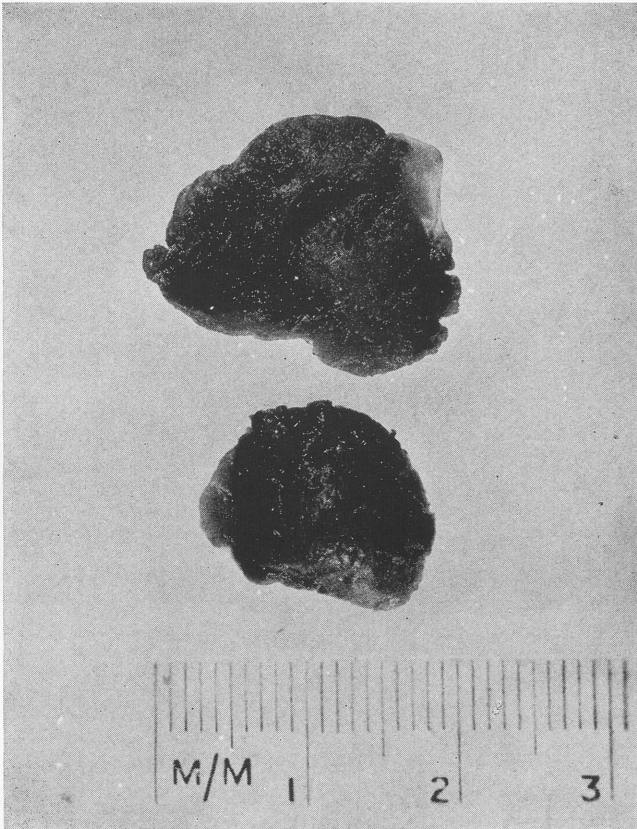


Fig. 2.—Chemodectoma of the larynx—gross specimen showing cut surface following bisection.

My interest was aroused in this subject recently by a case that I attended.

In November of 1963, Dr. W. J. McNally, who is a member of the American Laryngological Association, asked me to see a patient in consultation with him. This was a fifty-nine year old white female who was first seen by Dr. McNally in April of 1960. She consulted him at that time because of slight hoarseness and the occasional feeling of dysphagia, which she had been aware of for several months. On examination in 1960, there was a smooth cystic-like swelling involving the right aryepiglottic fold, measuring approx-

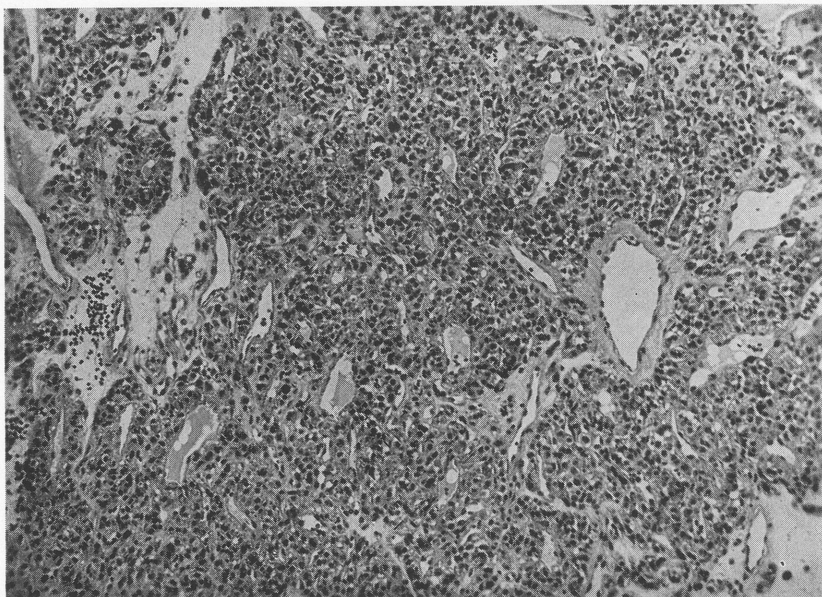


Fig. 3.—Chemodectoma of the larynx—microscopic section—low power (x 125).

imately 1.5 centimeters in diameter, and extending from the edge of the epiglottis back to and over the right arytenoid cartilage. The pyriform sinus lateral to and below the swelling appeared to be normal. The false cord was involved, but the true cord was not involved, and move freely. The left side of the larynx was normal. Clinically the lesion appeared benign, and following discussion, the patient elected to have it observed only.

She was relatively well for three years. In the fall of 1963, she began to experience increasing hoarseness and a sense of difficulty in breathing on occasions. On examination, no appreciable change in the size or location of the lesion as first observed in 1960, was noted, but in view of her increasing symptomatology, surgical removal was advised and agreed upon.

Following a preliminary tracheotomy on December 27, 1963, the lesion was removed five days later, using the extralaryngeal approach technique as described by Schall⁹ before this Association

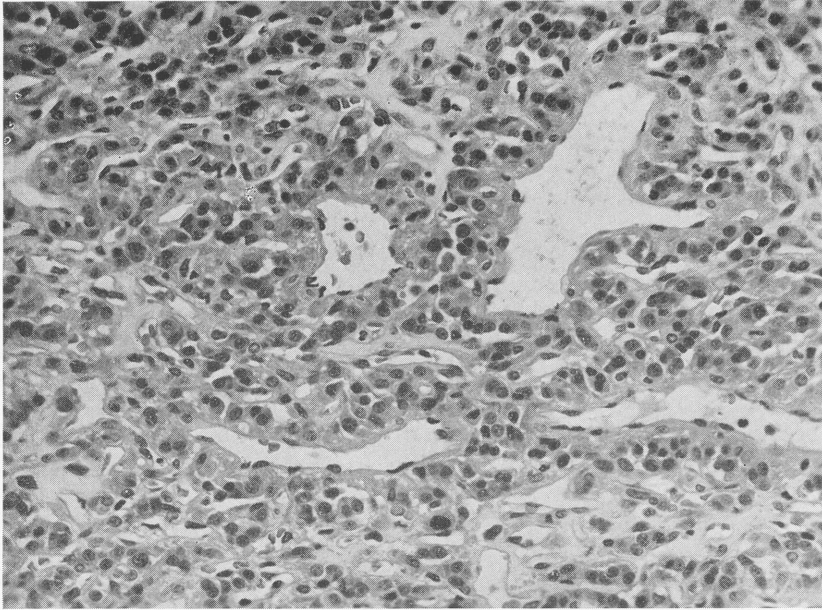


Fig. 4.—Chemodectoma of the larynx—microscopic section—high power (x 300).

in 1959. In essence this operation is an extralaryngeal approach which is direct, gives adequate exposure, does not traumatize the endolarynx, and does not have any endolaryngeal complications. The lesion was exposed lying in the right aryepiglottic fold, and was removed by blunt dissection. Very little bleeding was encountered. This specimen grossly was well circumscribed, soft on palpation, and was more or less spherical in shape, with its greatest diameter 2 centimeters. On cut surface it was composed of homogenous, yellowish, lobulated tissue. No necroses was seen. Microscopically, it was reported to be a chemodectoma.

The patient had an uneventful postoperative course. The tracheotomy tube was removed six days postoperatively, and she was discharged from hospital six days later. She has been followed since and when last examined, her larynx was normal.

This was the first case of a chemodectoma of the larynx seen by the Department of Surgical Pathology of McGill University. In

view of the rarity of such a lesion in this site, Dr. W. J. Pirozynski, Associate Professor of Pathology at McGill University, submitted microscopic sections for opinion to the Canadian Tumor Registry of the National Cancer Institute of Canada, to the Armed Forces Institute of Pathology in Washington, D.C. (AFIP accession 1126420), to Dr. Lauren V. Ackerman at Washington University Medical School, and to Dr. Arthur Purdy Stout at the College of Physicians and Surgeons of Columbia University.

From these authorities, there was a general agreement that the lesion was a chemodectoma, and their comments were most interesting.

The Canadian Tumor Registry of the National Cancer Institute of Canada had no records of such a tumor in this anatomical location. The Armed Forces Institute of Pathology in Washington, D.C., were not aware of the occurrence of such a tumor in this region either in the AFIP file material, or in the literature. Dr. Ackerman had seen such a lesion in the pharynx and in the wall of the esophagus, but had no record of one in this exact location. Dr. Stout felt that this was a most unusual place to find such a tumor.

It is interesting that in Dr. Schall's description of his extralaryngeal approach technique, he reported on four cases in which this operation had been used. One of these cases was a forty-nine year old woman who had been in and out of the Massachusetts Eye and Ear Infirmary for over twenty years, without a satisfactory biopsy of a large, smooth mass involving the left aryepiglottic fold. At operation in February of 1958, by this extralaryngeal approach, the growth proved to be a chemodectoma.

There is no question that glomus tumor, or chemodectoma of the larynx, is uncommon. I have knowledge of three that have been encountered during the past decade. Perhaps other members of the Association have seen similar cases and have not reported them.

1509 SHERBROOKE ST. WEST

REFERENCES

1. Haller, A.: *Elementa Physiologiae Corporis Humani* 4:256-257, Lausanne, 1757-1763.
2. Evans, R. W.: *Histological Appearances of Tumors; with a Consideration of Their Histogenesis and Certain Aspects of Their Clinical Features and Behaviour.* Lond, England: E. & S. Livingstone, Ltd., pp. 75-86, 1956.

3. DeCastro, F.: Sur La Structure et l'Innervation du Sinus carotidien de l'homme et des Mammiferes; Nouveaux faits sur l'Innervation et la Fonction du Glomus Caroticum. *Trav. Lab. Recherches Biol. Univ. Madrid* 25:331-380, 1927-28.
4. Heymans, C., and Bouckaert, J. J.: Les Chemorecepteurs du Sinus Carotidien. *Ergebn. Physiol.* 41:28-55, 1939.
5. Guild, S. R.: A Hitherto Unrecognized Structure, the Glomus-Jugularis in Man. *Abstracted, Anat. Rec. (Supp. 2)* 79:28, 1941.
6. Rosenwasser, H.: Carotid Body Tumor of Middle Ear and Mastoid. *Arch. Otolaryng.* 41:64, 1945.
7. Lattes, R., and Waltner, J. G.: Nonchromaffin Paraganglioma of Middle Ear (Carotid Body-like Tumor; Glomus-Jugulare Tumor). *Cancer* 2:447, 1949.
8. Andrews, Albert H., Jr.: Glomus Tumors (nonchromaffins paragangliomas) of the Larynx: Case Report. *ANNALS OF OTOTOLOGY, RHINOLOGY AND LARYNGOLOGY* 64:1034 (Dec.) 1955.
9. Schall, LeRoy A.: An Extralaryngeal Approach for Certain Benign Lesions of the Larynx. *Trans. Am. Laryn. Assoc.* 80:36-47, 1959.

DISCUSSION

DR. FAABORG-ANDERSEN: The laryngeal glomus tumor is no doubt a very rare case.

Six years ago I had a similar case, in my department, of a forty-year-old woman with breathing difficulties and a hoarse voice of several months' duration. By indirect laryngoscopy you could see a red tumor as big as a cherry starting from the left arytenoid cartilage, going forward and covering the posterior two-thirds of the glottis. The tumor was removed by direct laryngoscopy and after this, very heavy bleeding gave us some trouble before it stopped. Histological examination of the tumor gave the diagnosis: glomus or chemodectoma tumor. Three months later an indirect laryngoscopy showed a normal larynx with normal movable cords, normal voice and no tumor. Five years later there was still no tumor.

This case has been published by one of my assistants in the *Acta Oto-Laryngologica* 1959 and we were at that time unable to find a similar case in the literature. It must have been at the same time when Andrew had his case. I suppose your case is number three or four.

DR. BAXTER: I certainly appreciate Dr. Faaborg-Andersen reporting his case. I am sorry that in my review of the literature I did not come across it. I thought that I had found every case that had been reported. Actually Dr. Andrew's case was reported in 1955. These cases are very rare, but they do occur and I thought it was a very opportune time to bring it up before this Association.

OSTEOPLASTIC FRONTAL SINUS OPERATION: CORONAL INCISION

WILLIAM W. MONTGOMERY, M.D.

BOSTON, MASS.

The anterior osteoplastic frontal sinus operation has, within the past decade, become increasingly popular in this country.¹⁻⁴ The unilateral incision is fairly well hidden in the upper margin of the eyebrow. The bilateral incision, on the other hand, can be detected over the nasal process of the frontal bone. For the most part, this scarring is minimal and of no objection to the patient.

On occasion, the bilateral procedure must be performed on women who are sensitive about any degree of scarring. In such a case the surgeon may elect to use the coronal incision to approach the frontal sinuses. This incision is not practical in the male because of the ultimate recession of the hair line and exposure of the scar.

The coronal incision has been used previously as an approach to the frontal sinuses. Gibson and Walker reported this as an approach for removal of osteomas of the frontal sinus in 1954.⁵ MacBeth reported a series of cases using the coronal incision as an approach to the frontal sinuses in 1954.⁶

Preoperative Preparation. Preoperative x-rays of the sinuses are taken within a week of surgery in order to determine the current extent of disease. A pattern, or template, of the outline of the frontal sinuses is obtained from a Caldwell view of the sinus. This is made by placing a transparent exposed piece of x-ray film over the Caldwell view and tracing the outline of the sinus with a glass marking pencil. The template is cut out and placed in sterilizing solution so that it may be used during the operation. It is of particular interest to note: 1) the depth of the sinuses; 2) whether or not the anterior

From the Massachusetts Eye and Ear Infirmary and Massachusetts General Hospital, and the Harvard Medical School.

and posterior walls are intact; and 3) if the interfrontal septum has been perforated or destroyed by disease.

Cultures of the nasal cavity should be taken at least a week preoperatively; and if pathogens are found, sensitivity tests should be carried out, and a proper antibiotic instituted during the immediate preoperative period.

The evening before surgery the patient is given a thorough shampoo with hexachlorophene solution. The abdomen is shaved and prepared for surgery.

Preparation for Surgery. The patient's face and abdomen are scrubbed with hexachlorophene solution. The hair is then saturated with undiluted hexachlorophene solution, combed back, and approximately one inch of hair is shaved from the anterior hair line. Drapes are carefully sutured in place in order to maintain a sterile field during the operative procedure. The eyelids are sutured with #5-0 nylon or silk.

Endotracheal anesthesia is employed with a pharyngeal or post-nasal pack in place. The anesthetist is at the patient's side, as far toward the feet as is possible.

The line of incision is infiltrated with 1% xylocaine or procaine with added epinephrine. This, to some degree, assists the problem of hemostasis and supplements the general anesthesia.

Incision and Elevation of the Coronal Flap. The coronal incision is made as outlined in Figure 1. The incision is carried through the subcutaneous and frontalis muscle layers to the pericranium. It is important to obtain adequate hemostasis before elevating the coronal flap. Hemostasis is accomplished by the use of hemostats, coagulation cautery, and clips. The coronal flap is then easily elevated in the plane between the frontalis muscle and the frontal periosteum. It is reflected inferiorly over the face, exposing both the supraorbital rims and the nasal process of the frontal bone. The coronal incision has the disadvantage of being a long incision in which bleeding is difficult to control.

The advantages, however, outweigh this inconvenience. There is no interference with the supraorbital sensory nerve supply to the forehead. The osteoplastic flap can be more readily and accurately fashioned without retracting soft tissue for its exposure. The interior of both frontal sinuses can be easily inspected, and the entire disease

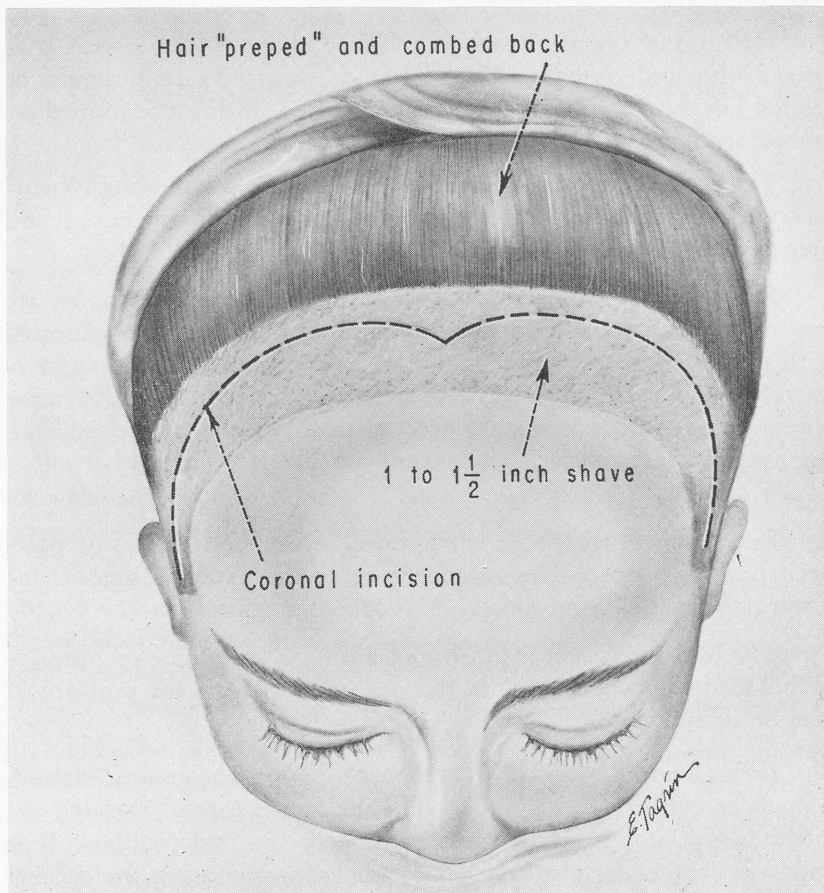


Fig. 1.—A sketch showing the outline of the coronal incision used in the osteoplastic frontal sinus operation.

removed. A normal contour of the forehead is maintained, and there is, of course, no visible scar. Unfortunately, the coronal incision can be used only in females, where there is less likelihood of a receding hairline. If the coronal incision were exposed by a receding hairline, it would be much more sightly than the conventional approach to the bilateral osteoplastic operation.

Osteoplastic Flap. The x-ray cutout (template) is taken from the sterilizing solution, rinsed with saline, and placed over the frontal

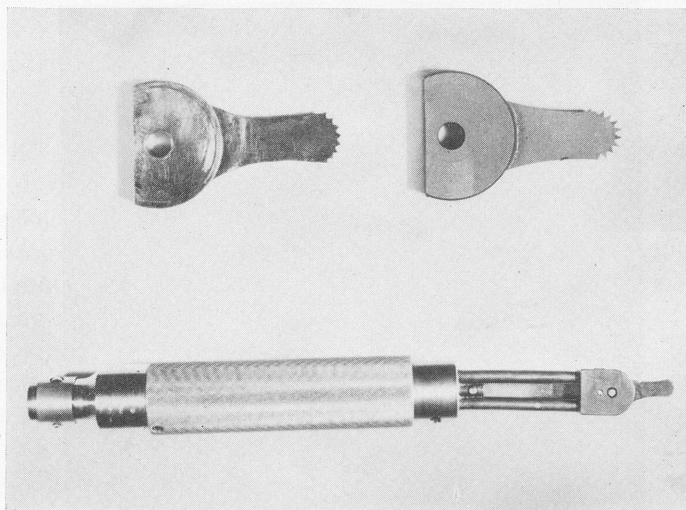
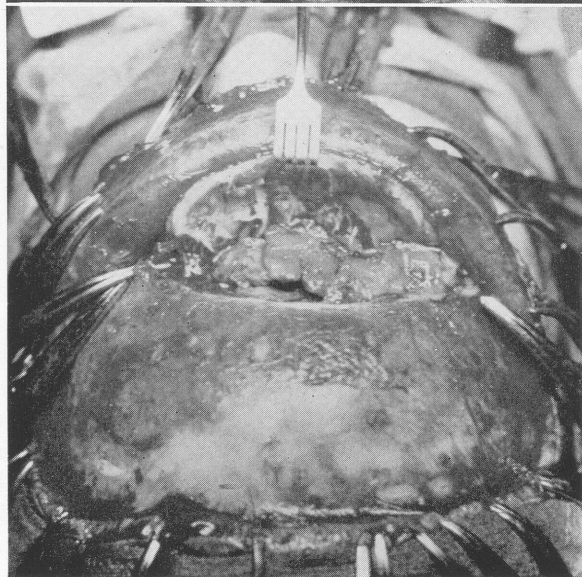
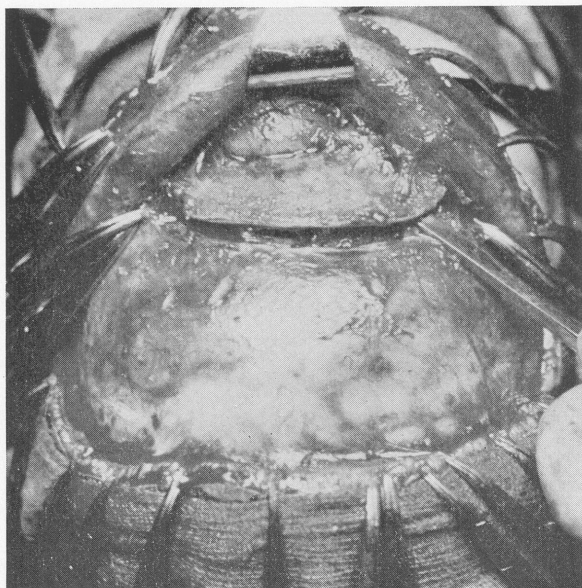


Fig. 2.—The tangential Stryker saw. The insert shows the frontal sinus blade.

periosteum. The inferior aspect of the template has been cut across horizontally at a level just above the cribriform plate. A notch has been placed in the superior aspect of the template to indicate the midline or position of the interfrontal septum. The template is positioned so that it accurately approximates the supraorbital rims on each side. It is held in place by any sharp object, such as a needle or knife, by stabbing through the template, periosteum, and against the bone. A #15 scalpel blade is used to incise the periosteum around the outline of the frontal sinus. A horizontal incision is made over the nasal process of the frontal bone. It is important to include in these incisions the periosteum over each supraorbital rim, both medially and laterally. A specially designed blade is used with the tangential Stryker saw (Fig. 2) to cut the osteoplastic flap. The bone incision, especially superiorly, is made on a bevel so as to make certain it enters the frontal sinus and also to facilitate closure and ensure an accurate re-approximation of the osteoplastic flap.

The osteoplastic flap is then elevated by prying with a chisel or elevator at the superior aspect of the bone incision (Fig. 3). As the flap reflects downward and forward, there is a fracture across the



floor of the sinuses, just behind the supraorbital rim where the bone is invariably quite thin. If the interfrontal septum is present, it will interfere with elevation of the osteoplastic flap. This must be incised by inserting a chisel from above before attempting to elevate the flap.

After the osteoplastic flap has been reflected inferiorly, the interior of the sinus is inspected (Fig. 4). A specimen is taken for bacteriological culture. The diseased tissue and mucous membrane are removed from the frontal sinus and the superior margin of the nasofrontal orifice (Fig. 5). The interfrontal septum is removed. A rotating cutting burr is then used to remove the remnants of mucous membrane and also the inner cortical lining of the sinuses. The inner cortical lining of the inner aspect of the osteoplastic flap should also be removed to ensure complete removal of the mucosal lining and also to establish an adequate blood supply to nourish the adipose implant (Fig. 6).

Subcutaneous adipose tissue is then obtained by way of either a vertical or a horizontal left rectus incision and fashioned so that it completely fills both frontal sinuses and obstructs the superior aspect of both nasofrontal ducts (Fig. 7). It is not important to attempt placing adipose tissue into the nasofrontal ducts, for they will be sealed from the sinus by the adipose implant within a few days as has been shown by animal experimentation.^{7,8}

The osteoplastic flap is returned to its original position (Fig. 8) and periosteum sutured with #4-0 chromic catgut. The coronal incision is sutured in layers using #4-0 chromic catgut and #5-0 nylon suture (Fig. 9). A pressure dressing, to remain in place for 24 to 48 hours, is placed over both orbits and the forehead. Antibiotics are continued for at least 7 days postoperatively.

Fig. 3.—The coronal flap is retracted inferiorly. The periosteum has been incised around the limits of both frontal sinuses with the aid of a template obtained from the Caldwell sinus x-ray view. The bone has been incised in accordance with the periosteal incision around the frontal sinuses and also across the nasal process of the frontal bone. The osteoplastic flap is being elevated with a chisel.

Fig. 4.—The osteoplastic flap has been elevated and is being retracted inferiorly. The frontal sinus contains purulent material and diseased mucous membrane.

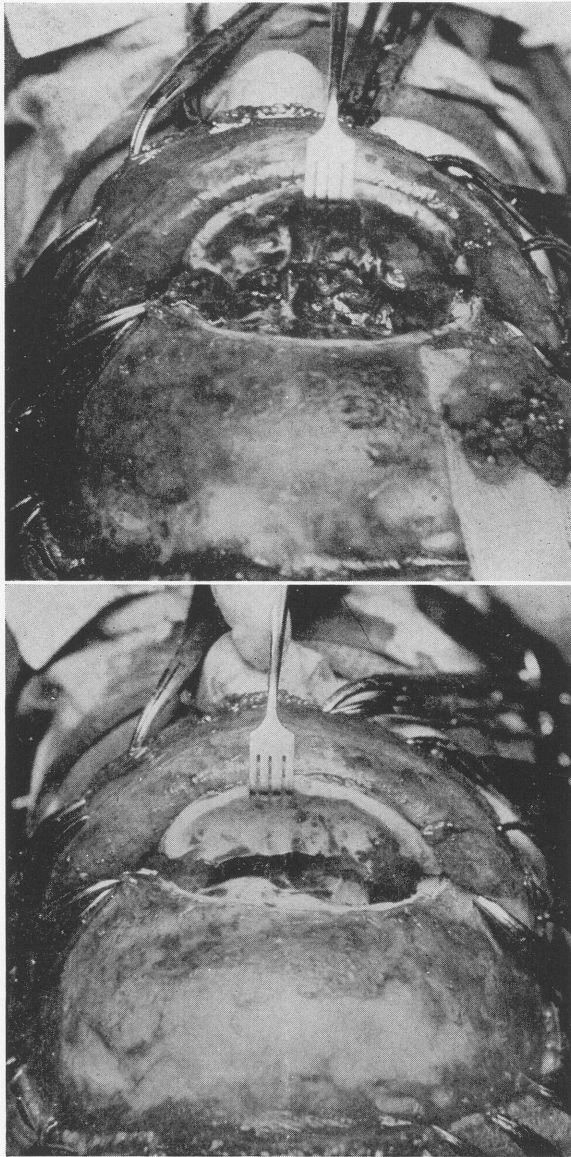


Fig. 5.—The diseased mucous membrane has been removed from both frontal sinuses. The interfrontal septum has been destroyed by disease. The diseased tissue can be seen on a gauze to the right.

Fig. 6.—The entire mucosal and inner cortical lining of both frontal sinuses has been removed with a rotating cutting burr. The superior aspect of both nasal frontal orifices can be seen.

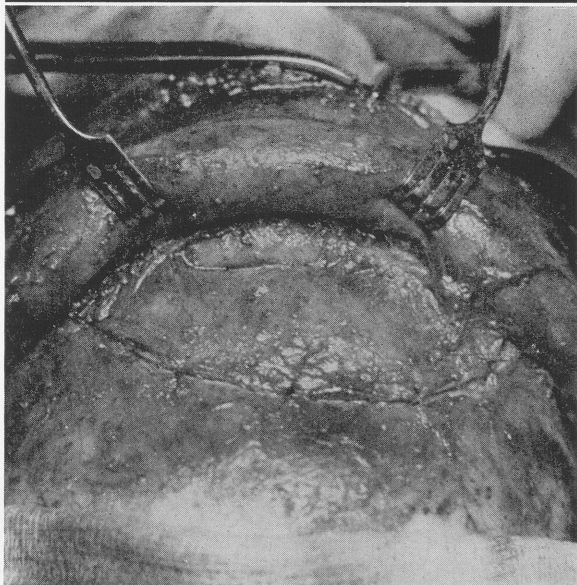
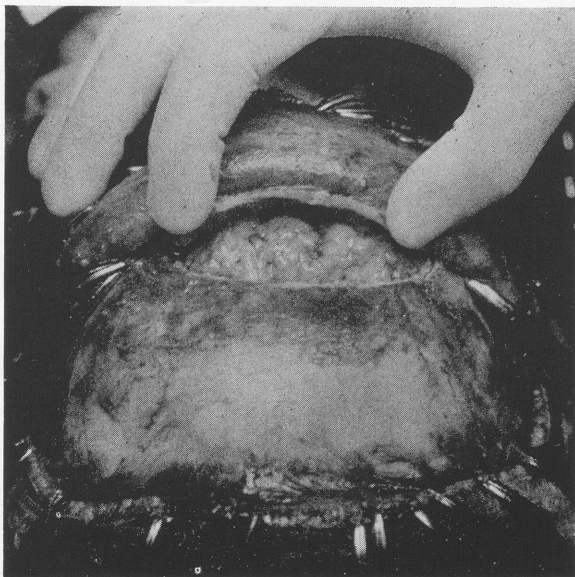


Fig. 7.—Both frontal sinuses have been filled with adipose tissue and the osteoplastic flap is being replaced.

Fig. 8.—The osteoplastic flap has been replaced, and the periosteum sutured.




Fig. 9.—(a) The coronal incision has been sutured, thus completing the operation. (b) The patient is shown one week after surgery showing the coronal incision, one inch behind the hair line. The sutures were removed at this time. (c) One week postoperative. The suture line is hidden by a temporary revision of the hair-do.

SUMMARY

The coronal incision is offered for use with the anterior osteoplastic frontal sinus operation in certain cases.

Advantages:

1. The normal contour of the forehead is maintained. There is no visible scar, using the coronal incision.
2. There is less interference with the supraorbital sensory nerve supply to the forehead.
3. The osteoplastic flap can be more readily and accurately fashioned without retracting soft tissues for exposure.

Disadvantages:

1. It is a long incision, and hemostasis is difficult.
2. It is not practical in males because of the ultimate recession of the hairline and exposure of the scar.

REFERENCES

1. Goodale, R. L., and Montgomery, W. W.: Experiences with the Osteoplastic Anterior Wall Approach to the Frontal Sinus: Case Histories and Recommendations. *Arch. Otolaryng.* 68:271-283 (Sept.) 1958.
2. Goodale, R. L., and Montgomery, W. W.: Anterior Osteoplastic Frontal Sinus Operation: Five Years' Experience. *ANNALS OF OTOLGY, RHINOLOGY AND LARYNGOLOGY* 70:860-880 (Sept.) 1961.
3. Goodale, R. L., and Montgomery, W. W.: Technical Advances in Osteoplastic Frontal Sinusectomy. *Arch. Otolaryng.* 79:522-529 (May) 1964.
4. Montgomery, W. W.: Osteoma of the Frontal Sinus. *ANNALS OF OTOLGY, RHINOLOGY AND LARYNGOLOGY* 69:245-255 (Mar.) 1960.
5. Gibson, T., and Walker, F. M.: The Osteoplastic Approach to the Frontal Sinuses. *J. of Laryng. and Otol.* 68:92, 1954.
6. MacBeth, R.: The Osteoplastic Operation for Chronic Infection of the Frontal Sinus. *J. of Laryng. and Otol.* 68:465, 1954.
7. Montgomery, W. W., and Pierce, D. L.: Anterior Osteoplastic Fat Obliteration for Frontal Sinus: Clinical Experience and Animal Studies. *Trans. Am. Acad. Ophthal. and Otolaryng.* 67:46-57 (Jan.-Feb.) 1963.
8. Montgomery, W. W.: The Fate of Adipose Implants in a Bony Cavity. *Laryngoscope* 54:6:816-827 (June) 1964.

DISCUSSION

DR. ROBERT L. GOODALE: As you know, we have been doing these operations on the frontal sinus by the anterior approach since 1956 at the Eye and Ear Infirmary. Most of ours at the beginning were the unilateral ones and we used the supra-orbital incision. This incision is made right close to the eyebrow and it doesn't leave any scar if you keep close to the upper hair line of the eyebrow.

We did run into this problem with the bilateral case which required an incision from one eyebrow, through the mid-line at the root of the nose across to the opposite side. I think this coronal incision which Doctor Montgomery has shown you is a great improvement over the other one. Although the lower incision is a very small incision across the mid-line, it does leave a little fine line for a short time. Eventually this does disappear.

I think the coronal incision might be particularly appropriate to the very large sinus. In all surgery on the frontal sinus where obliteration is desired you have to have the widest exposure of the interior of the sinus. This is hard to do through an inferior incision. You have to retract the soft tissues upward rather sharply and it is hard to reach the very high sinus. This coronal incision, of course, gives you full opportunity to make the bone cut anywhere through the frontal area.

This is a very beautiful exhibition of this technique.

DR. SAM H. SANDERS: The usual purposes for surgery on infected frontal sinuses are: *first*, to establish drainage in acute conditions for the purpose of preventing complications, one of which is irreparable damage to the lining mucosa; *second*, removal of the irreversible disease tissue, usually the lining mucosa, that has proven to be irreversible by its evidence of chronicity and resistance to the accepted method of treatment.

The osteoplastic flap procedure for chronic frontal sinusitis, presented by Dr. Montgomery, is indicated in chronic diseases of the frontal sinuses, not only infected but other conditions such as osteomas, tumors or extremely large frontals.

The advantage of this procedure is the accessibility of a portion of the diseased sinus cavity to the surgeon.

The disadvantages are the more extensive surgery required to gain access to the frontal sinus and the inaccessibility of the supraorbital and ethmoid cells through this approach.

One does have a better view of the recesses of the superior extensions of the frontal sinuses, if the sinus is unusually large or narrow anteriorly posteriorly but with the aid of mirrors and patience, the membrane from these extensions can usually be removed by approaching them through a small incision below the brow along the floor of the frontal and lateral wall of the nose. The flat bone in this area is easier to remove as it is thin and less vascular. This latter approach gives more access to the posterior portion of the supraorbital cells and floor of the frontal. There are partial septa in these cells as there are in the superior extension of the frontal.

Unfortunately, these cells cannot be ignored. Their lining mucosa usually requires the same therapy indicated for the frontal. One may see irreversible diseased ethmoidal lining mucosa with reversible diseased frontal mucosa but seldom, if ever, does one see these conditions reversed. This is the reason the frontals, ethmoids and sphenoids are sometimes referred to as a complex of sinuses.

When the floor of the frontal is not removed, there is danger of overlooking some of the lining mucosa at the outer angle of the frontal. This same danger exists in the osteoplastic flap approach when the supraorbital cells extend under the frontal. The osteoplastic flap procedure does not give the accessibility to the infra-frontal cells as can be obtained by approaching them through an incision below the brow and floor of the frontal.

It has been stated that, when necessary, the ethmoids can be exenterated intranasally. Some intranasal work is always necessary in these procedures, especially when dealing with the most anterior cells. Because of the outward curve made as the cells in the ethmoid labyrinth join the infrafrontal cells, it is impossible for the surgeon to follow this curve to remove the cellular partition and lining membrane as the intranasal structures prevent the manipulation of the available instruments within this cavity. However, one has an excellent view when the approach is made through the floor of the frontal and along the ethmo-orbital wall.

Regardless of what approach one uses to reach the lining mucosa and infra-frontal cells, all of the epithelial lining must be removed regardless of the condition. This is the purpose of the surgery.

This must be accomplished or eventually the remaining membrane will grow over the surface of the newly formed sinus lining or will be covered over by it. In either case, complications will develop as the permanent naso-frontal opening has been destroyed or should be.

If one attempts to leave the necessary tissue for a naso-frontal duct, some irreversibly diseased sinus mucosa will remain from which the newly opened membrane can become infected and the diseased tissue will grow over the new surface until it contacts more epithelial cells.

It has been proven, to the satisfaction of some surgeons that a permanent naso-frontal opening is not necessary to obtain satisfactory results for surgical treatment of chronic frontal sinusitis. Only when epithelial tissue is allowed to remain in the frontal or infrafrontal cells, is a permanent naso-frontal opening necessary. When diseased lining mucosa is allowed to remain in the sinus, the desired results will not be obtained anyway. Placing fat or anything else in a frontal sinus with diseased mucosa remaining is not going to get rid of the infection nor prevent complications. Regardless of the approach or technique used, all lining mucosa of the sinus must be removed from the frontal, infra-orbital cells and should be from the ethmoids to obtain good results.

It has been proven that where all the sinus mucosa of a sinus is removed, the cavity gradually fills in with tissue that eventually develops the radiological density of bone. The exposed surface of this tissue will be covered by epithelium similar to its ancestral cells which are influenced by the distance from which they have to migrate (Hystopathology and Bacteriology of Sinusitis with comments on Postoperative Repair: Frank B. Kistner, M.D., Portland, Oregon, Arch. Otol. 13:225-237, 1931). This has been demonstrated by the microscopical study of the tissue removed following surgery on humans.

We have success in demonstrating this healing process radiologically on all of our patients. Postoperative roentgenograms show a gradual uniformed increase in density of the sinuses if all of the membrane has been removed. If any mucous membrane is not removed, an area of less density will be visible about six months postoperative. This area gradually increases in size. Eventually this epithelial lined cavity will require removal or drainage.

Complications do not arise in the antra or ethmoid as frequently as the frontal and infra-frontal cells because the tissue allowed to remain in the cavities are less

likely to be closed in or over. Postoperatively the ethmoid roof is covered over by the growth of the nasal epithelium of the middle turbinate and the lateral wall of the nose except where ethmoid mucosa is allowed to remain. This remaining mucosa, usually in the form of islands, retains the original infection and also grows until its epithelial surface joins that of the ingrowing nasal mucosa. This tissue can be seen as a contrast to the newly formed nasal mucosa unless the free drainage and better blood supply aids it in recovery.

To prove these statements, we have over 800 cases having had external surgery on the fronto-ethmo-sphenoid complex of sinuses with less than five per cent complications collected from those having received their training in frontal sinus surgery from the University of Tennessee. The approach of the floor of the frontal and ethmo-orbital plate has been used. Some of these cases have been followed over thirty years. We realize that the percentage of good results is extremely high. Others have reported around thirty per cent failures with the procedure described in the previous article. We feel the reason for this high percentage of failures can be demonstrated in due time by postoperative radiological study.

I have enjoyed Dr. Montgomery's presentation. I think the osteoplastic flap procedure for diseased chronic frontal sinusitis is an excellent one and would be preferred in certain cases of chronic frontal sinusitis. In my hands, the approach to the frontal sinus through the floor of the frontal and the ethmo-orbital wall below the brow is preferable in the majority of cases.

DR. HENRY L. WILLIAMS II: You have probably heard some groaning and unfavorable sotto voce remarks from the floor. Ignore them, please.

I think that really it is a delightful paper that we have just heard and it is quite obvious that this is a very good procedure and should give excellent clinical results.

The coronal incision has been used for a long time. Dr. Pastore described this approach in 1935 and I believe that Dr. Furstenberg has been using it for a longer time, because I remember his presentation of this technique many years ago.

Even the fat transplantation isn't especially new. I believe it was first advocated about 1910, and it has been done off and on since then, and there can be little question that the lumen of the frontal sinus is obliterated by this technique. The only question that I have in regard to the method presented is the fact that apparently so many of these external operations have been done in so short an interval. In my experience a very widespread operation of this sort is not required in a great number of patients. I wonder what type of frontal sinusitis is being attacked in this way.

It seems to me that Dr. Montgomery has ignored some fundamental physiologic facts in regard to the etiology of chronic suppuration of the frontal sinus.

In some of the slides that were shown, the tissue removed looked polypoid and allergic. I believe it has been shown that allergy diminishes the normal physiologic resistance of the mucous membrane to bacterial invasion. Chronic pansinal infections are secondary to autonomic dysfunction (allergic reactions) caused by a great variety of environmental stimuli. Therefore to simply attack them surgically one is neglecting the very important medical approach to sinusal disease.

I think it is most unfortunate that there has been exhibited in late years a tendency for the rhinologist to declare himself simply a surgeon who does not wish to bother himself—he is so busy, you see, with his operations—with examining the medical background of his patients. This has resulted in some areas in the virtual abandonment of rhinology as a part of our specialty.

I would like to ask Dr. Montgomery why ethmoidal involvement is so seldom present in his patients. In the complicated cases of frontal sinusitis which require such extensive surgery, ethmoid involvement in my experience is the rule. I believe that an adequate operation cannot be done without clearing out the ethmoid disease.

Dr. Montgomery has previously suggested that it would be possible for him, by an operation such as Dr. Sanders described, to clean the ethmoids out at a secondary procedure. If this is done, however, it removes one of the arguments in behalf of the osteoplastic procedure; that is, that it is less time-consuming. If it be necessary to do two operations, certainly very much time has not been saved and the patient has been subjected to two anesthetics. In any event, there is little virtue in extreme speed in surgery. Before blood transfusion was routine it was quite important to do a rapid procedure because surgical shock was to be dreaded. Nowadays with adequate anesthesia and adequate preservation of the blood pressure, extreme rapidity of operation is not one of the prime desiderata of surgery. Of course, there is no reason to string it out unnecessarily, but making a talking point of terrific speed is, in my opinion, to be deprecated rather than praised.

DR. HARRY P. SCHENCK: I disagree with the idea that any single frontal sinus operation is applicable to all frontal sinus problems requiring surgery. During the past twenty years we have used a simple technique for entering the frontal sinus, attending to the abnormal conditions within, and inserting a plastic tube, 8 to 10 millimeters in diameter reaching from the sinus cavity to the nasal vestibule. The external wound is closed at once and there is minimal scarring.

At a recent conference, Dr. Hilger stated that he did not condone the use of such a tube because of the terrific pain and discomfort produced by the tube. I have never encountered this reaction nor have others in my area who have used this technique. Moreover, after the tube has remained in position for six weeks, its withdrawal is accomplished without any discomfort to the patient. By this time the tract is relined with regenerated epithelium which, six months later, can be shown to consist of ciliated columnar epithelium. The sinus cavity, however, is not relined with ciliated columnar epithelium but is slowly obliterated by fibrosis and osteogenesis.

As long as I can obtain satisfactory results with a simple technique, I see no advantage in obtaining fat from the abdomen for implantation in the frontal sinus except in special instances. My technique was developed to deal with osteomyelitis of the frontal bone and has been uniformly successful. I would like to ask Dr. Montgomery, in how many cases of osteomyelitis of the frontal bone has he used fat implants?

DR. HILGER: I would like to make two comments and one negation. It was somebody else that was talking to Dr. Schenck, I guess, not I. I have never had any particular misery from those tubes in my patients, except in my own concept of them. I felt them to be a very unsatisfactory plumbing device.

There are two things I would like to make comment on, however:

One has to do with frontal sinus surgery. It seems to me that the very large series of frontal sinus surgery in certain areas of the country as contrasted with, as Dr. Williams said, other areas in which there is relatively little of it—presumably for lack of indication—raises one point that is worthy of thought. One frontal sinus operation on a patient often begets another on that same patient. Large series as a result very often have reoperated patients counted twice or more.

The main point I would, however, raise to the group is the excellence of Dr. Montgomery's presentation. A long time ago someone said that a picture is worth

a thousand words. Dr. Montgomery exemplified that saying this morning. For a very long time it has been apparent that a great deal of verbiage at medical meetings only obscures the points being presented. I would say this is the perfect presentation.

DR. MONTGOMERY (closing): I thank Dr. Goodale for his comments and assistance.

And Dr. Sam Sanders, I still say that, at least in our hands, it is impossible to remove the entire mucous membrane from the diseased frontal sinus from below, and it is also impossible to remove an osteoma of any size from the frontal sinus without postoperative deformity with any approach other than the anterior osteoplastic operation.

You mentioned removing all the mucous membrane but not obliterating the sinus. Our animal experiments have demonstrated that, in a very short time after removal of the mucous membrane without obliteration of the sinus, mucous membrane has regrown into the sinus and in fact produced small mucocoeles.

Adipose tissue is re-vascularized in three days. This has been demonstrated by Lyndon Peer and others in soft tissue recipient sites as well as by our animal experiments in bony recipient sites.

It is indeed a distinct pleasure to be under the fire of Dr. Henry L. Williams. However, I don't want any of you to be misled by his comments.

One of our senior residents, Dr. Ricard Zonis, is now reviewing the first one hundred cases of osteoplastic frontal sinus operation. Thirteen of these one hundred are osteomas and 41 are re-operations for failures by other frontal sinus procedures.

The ethmoid can be operated from above by way of the osteoplastic approach. As a matter of fact, a fronto-ethmoidal procedure may be revised from above.

Another comment I wish to make concerning Dr. Williams' remark is that each case of chronic frontal sinus disease that we have operated upon has been a complicated, diseased frontal sinus presenting with such symptoms as diplopia, pain, sinocutaneous fistula, etc. These patients, for the most part, have had intranasal surgery as well as external ethmoidectomies, in an attempt to prevent radical frontal sinus surgery.

Our efforts to treat chronic frontal sinus disease by allergic management have been rather consistently fruitless. Dr. Zonis has recently informed me that some of the patients with chronic frontal sinus disease and co-existing nasal polyps and other intranasal and sinus allergic manifestations have been relieved by their frontal sinus obliteration. In other words, the allergic manifestations have subsided after frontal sinus surgery.

I am not too familiar with Dr. Schenck's procedure. My only comment is why bother with a tube and extensive postoperative care for one to three months when you can obliterate the sinus with one simple procedure and not be bothered with the postoperative management.

The osteoplastic frontal sinus procedure is a simple operation. It may look difficult when presented with slides, but I assure you that it is not.

Many of our cases have had chronic osteomyelitis. I would certainly never obliterate a case with acute osteomyelitis of the frontal bone. I would treat this disease intensively with high doses of intravenous antibiotics rather than any surgery, except perhaps a trephine, to relieve pressure symptoms.

OBLITERATION OF THE FRONTAL SINUS

ROBERT L. GOODALE, M.D.

BOSTON, MASS.

Since 1956 when the author first used the anterior osteoplastic approach to the frontal sinus at the Massachusetts Eye and Ear Infirmary, over one hundred such operations have been performed at this hospital. From time to time these have been reported by Montgomery and myself.²⁻⁴ This approach is ideal for various conditions such as osteoma, frontobulla cell, localized pyocele and severe irreversible chronic infection as it gives the widest surgical exposure, causes no unsightly deformity, and therefore requires no secondary plastic repair. Some of the localized conditions did not need a total removal of the mucosa and in such instances the lining was preserved after excising the abnormality. But where the infection was irreversible the entire mucous membrane of the sinus and nasofrontal duct was removed. The cavity was then filled up with an adipose tissue implant or was allowed to obliterate by osteogenetic proliferation from the bare walls of the sinus.

The use of an adipose tissue graft is based on Bergara's⁵ experiments with dogs, but while he advocated "boiled" fat from a "bank" we have used living autogenous tissue.

This paper is a follow-up study of some of my earlier cases which are now eight to nine years postoperative and therefore may be of some significance. Unfortunately for science only one of our Massachusetts Eye and Ear Infirmary cases out of 69 where fat was used has come to re-operation and I have therefore chiefly x-ray evidence or clinical observations to report. Two other such cases have come to my attention and the only reason I can account for their failure is that the fat became infected through a nasofrontal duct which did not close or through a defect in the interfrontal septum.

I would like to review some of the observations of other authors on the role of the mucous membrane in obliterative surgery and then

present four case histories which illustrate some variations in the obliterative process.

Walsh⁶ in his work on dogs pointed out that where the membrane of the sinus was eradicated, except for the region of the nasofrontal duct, the sinus rapidly acquired a new mucosa, but where the nasofrontal duct also was deprived of its lining the duct blocked off and the sinus began to fill up with fibrous or bony tissue. Bergera,⁵ Woods,⁷ and Sanders⁸ also pointed out this fact. In a personal communication Macbeth^{9,10} states that he does not use tissue implants but relies on spontaneous bone regeneration.

In my own series, Dr. A. S. Macmillan¹¹ has made an interesting x-ray observation. In the cases in which the entire mucosa had been removed and no fat was used, obliteration occurred by bone proliferation. With one exception which I will describe later, those with the fat implant showed no such bone reaction. Bergara noted this also in dogs where living tissue was used, but not where boiled fat was used.

REPORT OF CASES

CASE 1. Patient, H.C., female aged 36, was first seen in my office April 16, 1955 for a recurrent frontal sinus infection on the right side. A Lynch operation had been performed a few months before on this side. Disturbance of the superior oblique muscle, probably due to the operation, had caused some diplopia. This infection quieted down but there were similar episodes off and on until February, 1956, when she developed an acute upper respiratory infection. At this time there was inflammatory edema of the eye lids and a considerable amount of purulent discharge through the right nasofrontal duct. An incision and drainage of the right frontal sinus was done on February 27. This alleviated the situation, but infection was not completely controlled, so that in June, 1956 it was decided to do a right obliterative frontal sinusectomy using the anterior osteoplastic technique with fat implant.

The bone flap was cut with a circular electric saw and turned down. The mucous membrane of the sinus was removed completely by means of an electric burr. Abdominal fat was then implanted into the cavity and the wound was closed.

Postoperative course: This patient has had no recurrent infection. Strangely enough the diplopia has disappeared. X-rays taken

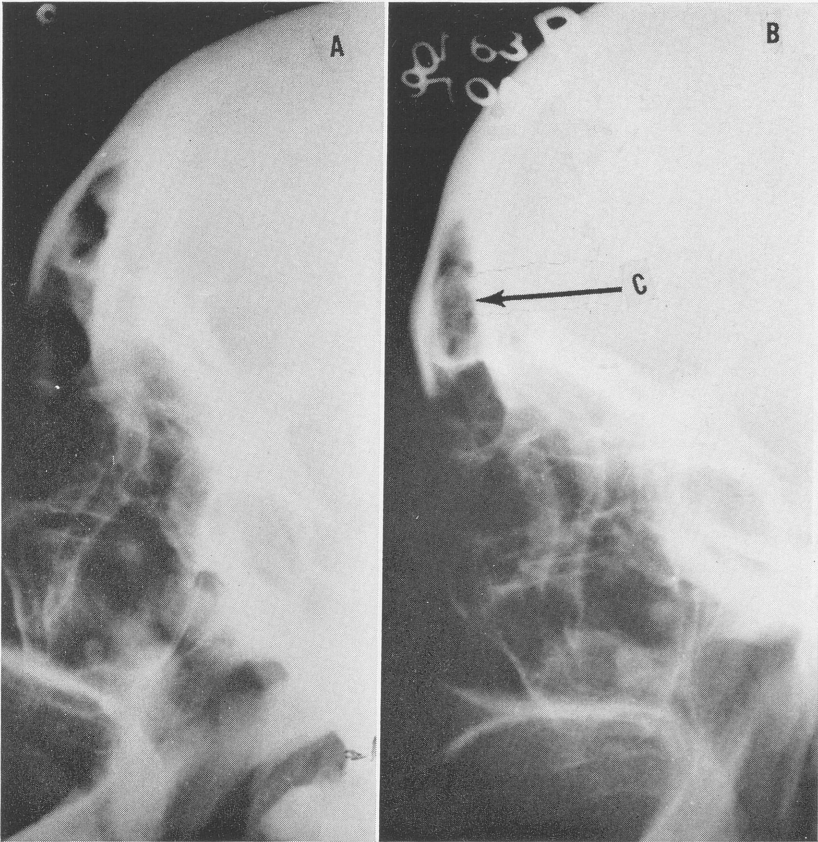


Fig. 1.—Case 1: Operated in June, 1956. Obliteration by fat implant.
A. Lateral view by x-ray 1957. B. Lateral view by x-ray 1963. C. No bone forming.

periodically have shown that the bone flap is in good position and that the fat implant seems to retain its characteristics and does not show any bone replacement. The x-rays in 1957, one year postoperatively, and in 1956 both show that the fat has remained apparently unchanged.

CASE 2. Patient, P.H., female aged 39, was first seen by me on September 27, 1957. Twelve years previously she had had a right Lynch frontal sinus operation, and following this had had incision and drainage for recurrent infection.

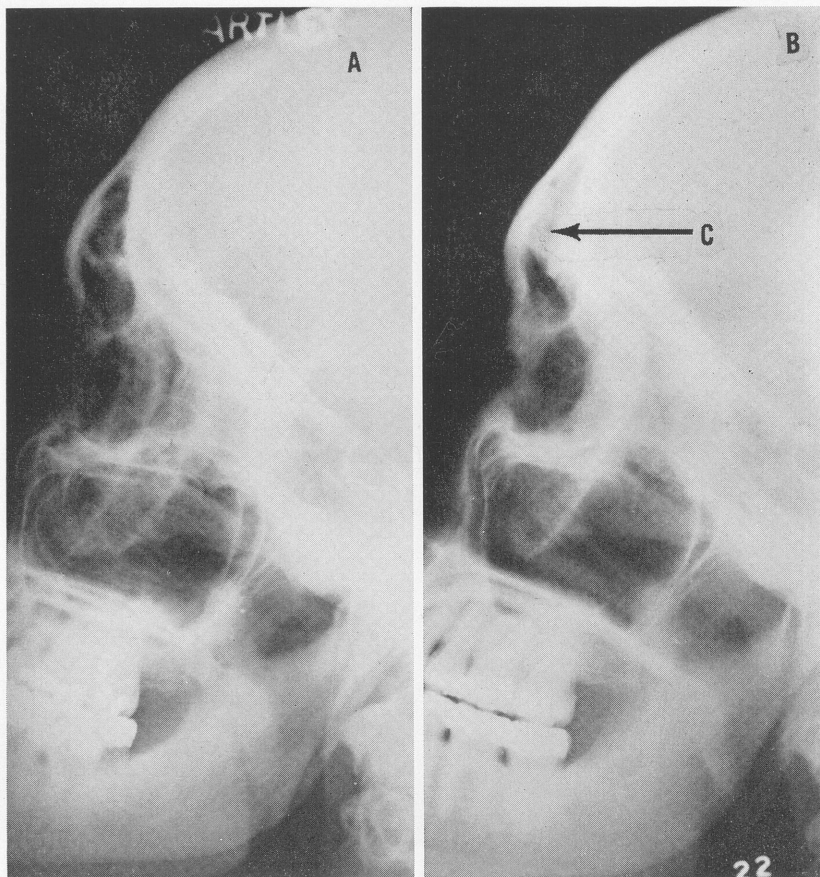


Fig. 2.—Case 2: Operated in 1956. Obliteration without fat implant. A. Lateral view by x-ray 1957. B. Lateral view by x-ray 1963. C. Bone filling the sinus.

There was a hard, tender swelling over the region of the Lynch incision. X-rays, reported by Dr. A. S. Macmillan, showed that there was a pyocoele of the right frontal sinus which had herniated through the interfrontal septum into the left frontal sinus. On October 17, 1957 an anterior osteoplastic frontal sinusotomy was performed.

The entire mucous membrane of the frontal sinus was removed and the bony surfaces were ground down by electric burr. The inter-

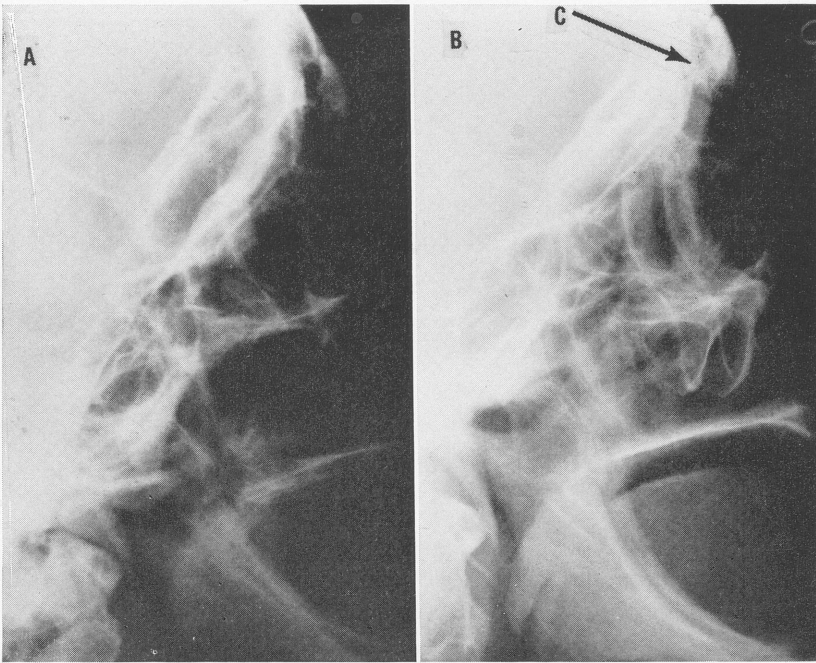


Fig. 3.—Case 3: Bone implant 1954 on right frontal sinus extending into left frontal sinus. Adipose implant 1956 in left frontal sinus. A. Lateral view by x-ray 1958. B. Lateral view by x-ray 1965. C. Bone has filled in left frontal sinus.

frontal septum was deficient and was taken down still further so that the frontal sinuses on the right and on the left then became one single cavity. The membrane on the left side was not removed, and the nasofrontal duct on the left was not interfered with. On the right the duct had been completely obliterated by previous surgery. No fat was implanted.

Postoperative course: Since operation the patient had had an uneventful history. There has been no recurrent sinus infection even when she had an occasional head cold. X-rays taken in 1958 and again in 1963 show that on the affected side the bone has begun to proliferate and obliterate the cavity.

CASE 3. Patient, M.M., female aged 57, had had repeated Lynch frontal sinus operations on the right side, which culminated in a Riedel obliterative operation in 1954. At that time, an autogenous bone

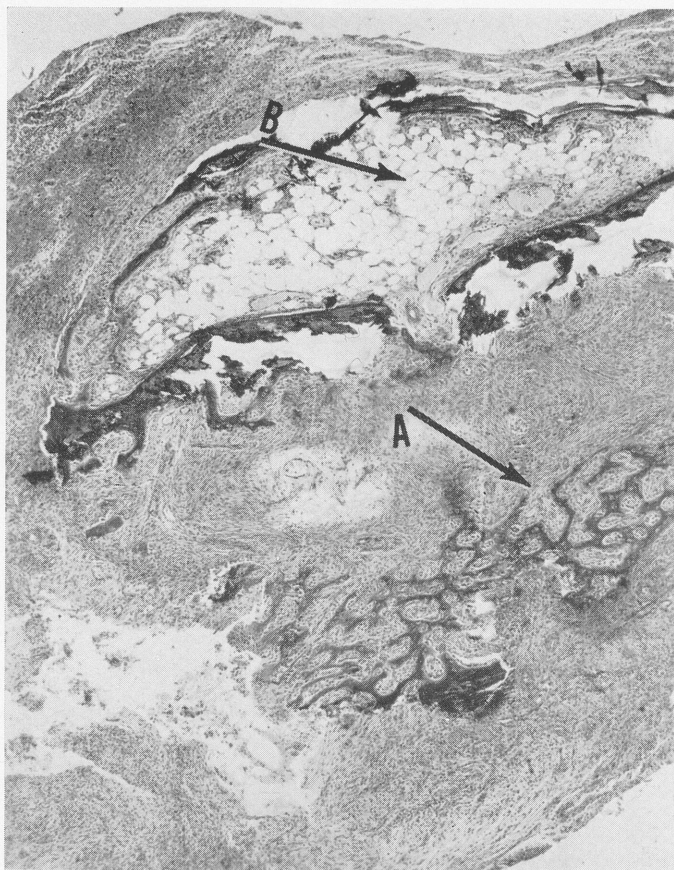


Fig. 4.—Case 3: Bone graft 3 years post op. Note new bone forming at (A) replacing graft, marrow fat at (B).

implant was made by Dr. E. M. Holmes to rebuild the forehead contours. She had had a little trouble in the opposite frontal sinus at times, but not sufficiently severe to warrant surgical interference until the fall of 1956. At that time she developed a severe infection in the left frontal sinus, and as the x-rays showed that there was much thickening of the membrane and that actually the infection amounted to a pyocele, it was decided to obliterate this side by means of an osteoplastic frontal sinusectomy and fat implant.

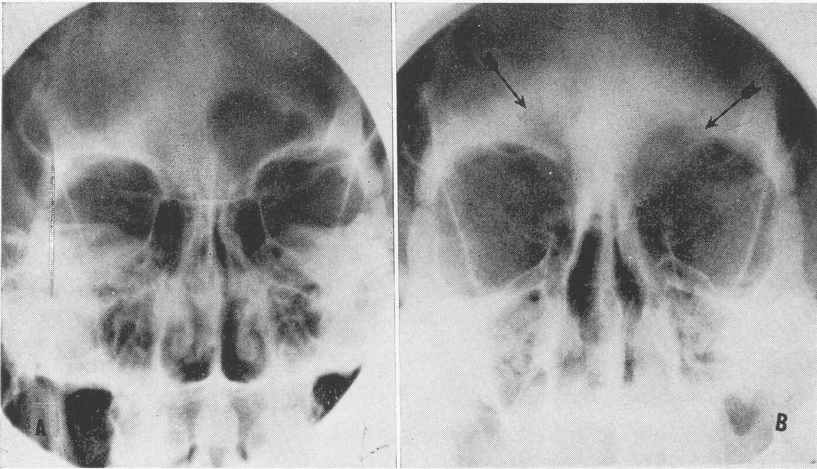


Fig. 5.—Case 4: Lynch operation 1953. Anterior osteoplastic operation 1964. A. Before Lynch operation, 1953. B. Before osteoplastic operation, 1964. New bone has filled in frontal sinuses. Arrows point to mucocoeles.

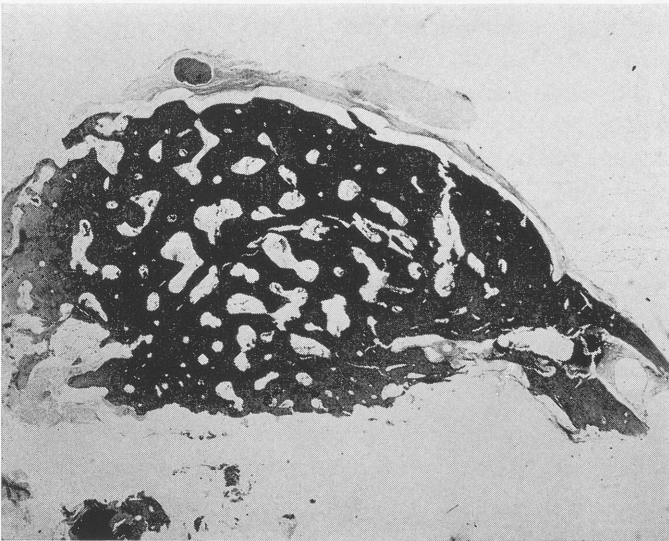

Fig. 6.—Case 4: New bone removed from posterior wall of frontal sinus at osteoplastic operation. In 11 years this has become mature lamellar bone.

The interfrontal septum was found to be deficient and through this area there was some of the previous bone graft protruding into the left side. A small bit of this was removed for microscopic examination. The fat was implanted, after removing all the mucous membrane from the left frontal sinus.

Postoperative course: Since the operation there has never been any recurrence of her sinusitis. Lateral x-ray views of her sinuses taken in 1957 and 1965 show that there has been some bone regeneration obliterating the left frontal sinus. The thought occurs that the bony implant has actually been the jumping off point for osteogenesis which replaced the fat either by building on the fat structure as Bergara has suggested or has replaced it by crowding it out. In any case there is almost complete obliteration by bone at the present time.

Banked bone might be expected to be likewise successful. One case of mine which had a deformed brow ridge following two previous Lynch operations done elsewhere showed resorption of the banked bone and spontaneous obliteration by new bone. The sinusitis was relieved, but this case required a subsequent plastic operation for the brow ridge.

CASE 4. This patient, W.C., male aged 60, was operated on by me by the Lynch technique on May 11, 1953 for a pyocele of the left frontal sinus. At that time it was found that there was no interfrontal septum. The right frontal sinus had been the seat of a very chronic infection and showed some sclerosis. As time went on he had recurrent infections. The surgical nasofrontal duct remained open until 1959 but at this time I lost track of him. He returned again in November of 1964 complaining of headaches and purulent discharge from the nose. The x-ray showed that there was extension of the sclerosis to the left side also but on both sides there were areas suggestive of pyocele.

On November 30, 1964 a bilateral frontal osteoplastic sinus-ectomy was performed. It was discovered at this time that the sclerosis had proceeded very extensively and there were pyoceles in the areas noted in the x-ray. These were removed by the electric burr.

The postoperative course has been uneventful. This patient is a very interesting example of osteogenesis in a previously operated left frontal sinus as well as in the unoperated right frontal sinus. This case suggests that there may even be spontaneous obliteration probably as a response to chronic inflammation.

CONCLUSIONS

1. Successful obliteration depends on the total removal of mucous membrane from the nasofrontal duct as well as from the cavity of the sinus.
2. Spontaneous obliteration by osteogenesis can occur where the bone is denuded and living adipose tissue is not used.
3. Implantation of autogenous bone will assist new bone replacement.
4. If the interfrontal septum is deficient it is advisable to remove it entirely. There is no danger of infecting the opposite healthy sinus, but if the opposite sinus is infected it would be advisable to remove the sinus and duct lining on this side. This can be done by a bilateral one flap technique or by operating through the interfrontal area if the sinuses are not too large.
5. Adipose tissue should be used only where it is certain that the nasofrontal duct is occluded and the interfrontal septum is intact. Implantation of the living adipose tissue seems to prevent osteogenesis.

330 DARTMOUTH ST.

REFERENCES

1. Goodale, R. L.: Trends in Radical Frontal Sinus Surgery. *ANNALS OF OTOTOLOGY, RHINOLOGY AND LARYNGOLOGY* 66:369 (June) 1957.
2. Goodale, R. L., and Montgomery, W. W.: Experiences with the Osteoplastic Anterior Wall Approach to the Frontal Sinus. *A.M.A. Arch. of Otolaryng.* 68:271-283, 1958.
3. Goodale, R. L., and Montgomery, W. W.: Anterior Osteoplastic Frontal Sinus Operation—Five Years' Experience. *ANNALS OF OTOTOLOGY, RHINOLOGY AND LARYNGOLOGY* 70:860 (Sept.) 1961
4. Goodale, R. L., and Montgomery, W. W.: Technical Advances in Osteoplastic Frontal Sinusotomy. *A.M.A. Arch. of Otolaryng.* 79:522-529 (May) 1964.
5. Bergara, A. R., and Itoiz, O. A.: Experimental Study of the Behavior of Adipose Tissue within the Frontal Sinus of Dog. *Argent. Rev. Oto-Rhino-Laryng.* 184-192 (July-Sept.) 1951.
6. Walsh, Theodore E.: The Role of the Ostium and Nasofrontal Duct in Postoperative Healing. *Laryngoscope* (Feb.) 1943.
7. Woods, R. R.: Proceedings of the Fourth International Congress of Otolaryngology, London, 1:109, 1949.

8. Sanders, S. H.: Is a Permanent Naso-Frontal Opening in Surgery for Chronic Suppurative Disease of the Fronto-Ethmo-Sphenoid Complex of Sinuses Really Necessary? Presented at the Amer. Acad. of Ophthalm. and Otolaryng., Oct. 1964.

9. Macbeth, R.: The Osteoplastic Operation for Chronic Infection of the Frontal Sinus. *Jour. of Laryngol. and Otol.* 68:7 (July) 1954.

10. *Ibid.*: Personal Communication, 1965.

11. MacMillan, A. S.: Personal Communication. (Roentgenologist at Massachusetts Eye and Ear Infirmary, Boston, Massachusetts.)

DISCUSSION

DR. SANDERS: The point that Dr. Goodale brings out, and that I would like to stress, is regardless of what one does at the time of sinus surgery or regardless of the surgical approach, if every vestige of the diseased mucous membrane is not removed, one is going to have trouble whether the cavity is left empty or fat put in it.

Everyone is familiar with the work that Dr. Hilding has done on this subject. Drs. Kistner, Semenov, Knowlton, McGregor, Coats, Gorhan, Bacher, Proetz and Walsh are among the men that published articles on/or related to this subject in the nineteen-thirty era.

I would like to show a few slides to substantiate the fact that Dr. Goodale has brought out.

Here is the reproduction of an x-ray of a patient with an Ingals tube inserted into the frontal sinus to establish a permanent drainage for the relief of a chronic frontal sinusitis. It has been in place fifteen years. No lining mucosa of the frontal sinus was removed. There has been no filling in of the cavity. The diseased membrane is still present. There are less symptoms because of the drainage. This and the next three slides were given to me by Dr. Harbert Anthony of Memphis.

Here is another reproduction of the roentgenogram of the frontal sinuses. This roentgenogram was made in 1940. One sees the frontal sinus cavity is partially filled with, what the radiologist is likely to say is, bone. It has the density of bone and may have some bone in it but it is more cicatricial tissue than bone. This tissue has replaced the membrane that was removed from this part of the frontal. Where the lining mucosa was not removed, there has been no obliteration of that part of the frontal sinus cavity. This shows the results of the partial removal of the lining membrane of the frontal sinus. As long as this cavity contains any mucous membrane covered with epithelium, a permanent nasofrontal opening is essential. Should one desire to complete the removal of the entire lining mucosa of this frontal sinus, an osteoplastic flap approach should be used. This cicatricial tissue is so firmly attached to the bone that it cannot be removed completely by the approach through the floor of the frontal. This is an example of where an osteoplastic flap procedure would take precedent over the approach through the floor of the frontal.

Two years later, as shown by this roentgenogram, the findings are essentially the same.

Thirteen years later (1953) as shown in this slide, the filling defect is the same as in 1940. In other words, only that part of the frontal sinus from which the lining mucosa was removed shows any filling defect regardless of the elapse of time.

Here we have a pre-operative roentgenogram of a patient with chronic frontal sinusitis and a five year postoperative roentgenogram. One can see the sinus has

been completely obliterated following the complete removal of the lining mucosa. This approach was made through the floor of the frontal below the brow as was done on all of the cases presented.

And here one again sees the obliteration of the frontal sinus cavity following the complete removal of the lining mucosa. We can predict good results on these patients.

Here are the roentgenograms on a patient that has had three external frontal operations. One can see that this membrane was not removed from this frontal sinus.

This is a photograph of the epithelial lining removed from this frontal.

And here, one again sees in the roentgenogram the obliteration of the frontal sinus cavity following the complete removal of the lining mucosa.

When any epithelial lined mucosa is allowed to remain in the frontal sinus, at the time of surgery, one is going to have trouble. This trouble can be predicted when the postoperated roentgenogram shows an area of less density or a filling defect as can be seen in this next roentgenogram.

Each one of these areas of lesser density represents an epithelial lined cavity resulting from the incomplete removal of the frontal sinus mucosa.

To further substantiate the contention that, if all the lining mucosa of the frontal sinus is removed, the cavity will fill in with inactive connective tissue, I would like to show you the roentgenograms and the pathological specimen from another case. This patient had an acute frontal sinusitis with an osteomyelitis and cerebral complications. The frontal was drained and later on the mucous membrane was partially removed. An area of less density at the outer angle of the right frontal, as shown on the roentgenogram, indicates a filling defect resulting from the incomplete removal of the lining mucosa about 20 years ago. This roentgenogram was made about ten years following the first operation. The patient had an acute exacerbation of an infected mucocoele when this roentgenogram was made in 1960. External drainage was performed. After the acute symptoms subsided, the frontal was reopened at which time the remaining mucosa was removed. A section was taken from the tissue that had filled in that portion of the frontal sinus cavity that has the radiological density of bone.

One can see from the reproduction of the pathological specimen that this is scar tissue with no epithelial covering. Our microscopic examination of the tissue that fills in the frontal sinus cavity following the removal of the mucous membrane is the same as reported by others.

In contrast to the previous roentgenogram, this is a pre-operative roentgenogram showing an increased density in the right frontal. The roentgenogram below this was made five years later showing a uniform postoperative density. The third roentgenogram shows a small aerated cavity in the frontal which is caused by the retraction of the scar tissue resulting in the nasal mucosa being pulled into the frontal sinus. This picture was made ten years following the surgical procedure.

This photograph of the patient shows practically a total lack of deformity.

DR. G. SLAUGHTER FITZ-HUGH: I would like to describe briefly our experience with this case that Dr. Goodale mentioned in his paper. Incidentally, it was our first one, and I don't really think you could call it a failure as far as Goodale's and Montgomery's procedures are concerned, but possibly a failure in our personal technique.

This patient had been operated upon elsewhere and was referred to us because of recurrent pain and a slight amount of swelling in the frontal region, particularly in the scar of the previous operation.

We performed an osteoplastic flap procedure on this patient, removed the mucous membrane with the burr technique but not under magnification—and here in retrospect I don't think that I cleaned out the naso-frontal duct mucous membrane as thoroughly as I should have. Approximately a month after the operation the patient returned complaining of pain in the frontal region and had swelling in the region of the scar. This was drained and a very small amount of exudate was obtained. He was placed on an antibacterial drug—I was absent at the time at one of the medical meetings—so he was discharged, returned home on the antibacterial drug, and came in a few weeks afterward. He was asymptomatic at the time except for a complaint of fullness and some discomfort in the right frontal region.

I was a little timid. This was our first case. I was also a little skeptical as far as the procedure was concerned, so I decided to re-explore this frontal tissue. I did so and my comments to my assistants and residents at the time were that this cavity looked pretty good and I rather regretted investigating it again. This mass of fat that had been placed in was somewhat more solid than it was at the time it was inserted initially. I obtained the idea that fibrosis was occurring. There was no free exudate present but there was a small amount of serum, yellow serum, in droplet form, probably fatty substance, that could be pressed from the graft. Now, the graft had filled the cavity completely; it was well formed and actually there was certainly no gross infection and the whole situation looked pretty good, but because this was the third operation in this particular case, I removed the fatty implant, and again cleaned out the cavity and placed a polyethylene tube leading from the cavity into the nose. This remained in for a period of several months and then was taken out and the patient has had no real evidences of recurrent infection but still complains from time to time—he is a very apprehensive individual—of fullness in the area.

In retrospect, I think we would probably have been just as well off, or better off, if we had not reoperated upon this patient. I also think it cannot be classified as a real failure according to the technique of Goodale and Montgomery but could be classified as a failure according to my technique.

I would like to say that we have had since then approximately six or seven cases in which we have performed this procedure and have been well pleased with it. I do think though that the real indication for it is in cases in which they have been operated upon on one or two occasions previously.

We have had some success in operating upon these cases by going in through the floor, removing the membrane and then using a tube in the naso-frontal duct for a period of several months, but I am convinced that we cannot remove the entire mucous membrane of a well developed frontal sinus by any other technique than that of the osteoplastic one.

DR. PRESSMAN: May I ask Dr. Goodale if he would be so kind as to repeat his method of closing the nasofrontal duct and how the site is determined?

DR. GOODALE (closing): Dr. Sanders and I are in complete agreement on the necessity for complete removal of the mucosa. Where he differs with me, of course, is in regard to technique, which is a matter of opinion. What suits me, suits me perfectly, and he is just as satisfied with his. If you can do it with one technique, that is the way to do it. Get all the membrane out.

I am very grateful to Dr. Fitz-Hugh for sending me that slide. We have not had a chance to re-operate more than one case and I was unable to find the slide on that one. Dr. Fitz-Hugh's case also became reinfected in much the same manner. I feel the same way that he does, that perhaps with a little patience the case might have recovered without re-operation. When you are on the spot and you see the patient with infection, you do feel somewhat uneasy about it.

We have so few cases that have come to re-operation that any material that we can get is welcome.

In regard to the obliteration of the nasofrontal duct; it is easy to get the membrane off the posterior, inferior and anterior wall, but when you approach the nasofrontal duct you are coming down into a funnel. You saw that picture of Dr. Montgomery's yesterday. It was a beautiful shot, showing both nasofrontal ducts as seen from above in the typical Killian view, from the head of the table, which Mosher said was so important in evaluating the status of the sinus. You can look right down into that little funnel and see the nasofrontal "ostium"—it really looks like an ostium there—down in the depths. What I do first of all is to take a curette and carefully remove the membrane from the duct, going right down into the nose. Then I take the electric burr—the polishing one in this case, not the grinding, because the grinding sometimes cuts a little bit sharp and a little deep—and go down in there and gently burr and polish away the bony walls of the nasofrontal duct.

In the last case I did I took a little thin strip of gauze and fed it down from above and then reached up through the nose and fished it out through the nose. In that way I caught some of the mucosa, and inverted it downward into the nose. Then it appeared that the bone was completely denuded.

Incidentally, that case was interesting. It was a secondary operation for a pyocele on the left side. Also, there was a fronto-ethmoid cell that had come up under the sinus, had pneumatized laterally around the frontal sinus almost to the upper limit of the sinus, so that it really looked as though this patient had two frontal sinuses on the left side. I know there was another one on the right, so I was sure that this was an ethmoid extension. When I had the membrane out it appeared that both of them had what looked like normal nasofrontal ducts leading down into the nose. In this case I obliterated both sinuses as there was a history of severe infection. As I wanted to try obliteration by osseogenetic repair, I did not put fat in. I merely removed the membrane right down into the nose. The result has been very good.

It is too early to report here on a case like that but it does show a method of obliterating the nasofrontal duct: curette, dissect the mucosa away, burr it, and then, if necessary, take a very thin, very small strip of gauze and pull it down through the nose and take the membrane along with it.

RHINOLOGICAL METHODS FOR CONTROLLING NASAL POLYPOSIS AND VASOMOTOR RHINITIS

FRANCIS L. WEILLE, M.D.

BOSTON, MASS.

In dealing with nasal obstruction in patients who have nasal polyps, or polypoid degeneration of the nasal mucosa, or vasomotor rhinitis separately or together, there are two problems which must be met. The first is the pathogenesis of polyps and polypoid degeneration because simple excision of such tissue is so frequently followed by recurrence. The second is how to alleviate permanently the gross turgescence or labile instability (with rhinorrhea and paroxysmal sneezing) of the nasal mucosa in vasomotor rhinitis.

The great majority of otolaryngologists turn to the allergist for the solution of these two key problems, even though the control of underlying allergy often results in failure. For example Kern and Schenck¹ pointed out that in 232 cases of nasal polyposis in 874 allergic patients, only four were said by them to have been cured of such polyposis by elimination and hyposensitization methods. In vasomotor rhinitis there is also frequent failure to control the extremely turgescient mucosa by similar techniques. It is paradoxical that if the allergist fails to produce a favorable result, he will himself ask the rhinologist for help. This paper concerns itself with what can be done locally, and why, by surgical methods.

NASAL POLYPOSIS

There is no doubt that nasal polyps are commonly present in allergy patients. In a study of the nose and throat in 500 asthma patients, I found 211 or 42% to have nasal polyps. The edema fluid expressed from such tissue may contain reagins like all other body fluids in those who have atopy. Eosinophiles and eosinophilic plasma cells may be present, etc. However, it is also well known that many

individuals will wheeze in the presence of a supposedly virus head cold; and that polyps not previously present may appear in the nose at such times, and disappear along with the wheezing when the viral infection clears up. Moreover, "bacterial allergy" as a term refers not only to ordinary bacteria, but also to viral agents, which may be regarded as degenerated obligatory intracellular parasites, dependent upon cell metabolism for reproduction.

VIRUS HYPOTHESIS OF NASAL POLYP ETIOLOGY

In 1956 Weille and Gohd² cited experimental observations that a viral agent may be concerned in nasal polyp etiology.

The more important findings were 1) the recovery of a virus routinely from inoculation of the chorioallantoic membrane of nine to ten day old chick embryos with 0.1 cc of a 10% polyp suspension; and 2) the transmissibility of the viral agent routinely for 5 generations or more. The Koch postulates required for etiological significance³ of an organism are:

1. The organism should be found in all cases of the disease in question, and its distribution in the body should be in accordance with the lesions observed.
2. The organism should be cultivated outside of the body of the host in pure culture for several generations.
3. The organism so isolated should reproduce the disease in other susceptible animals.

The experimental work indicated that the first two postulates were met. This was done by following the technique reported by Kilbourne and Horsfall⁴ for the nonspecific chemical detection of viral alterations of the chick embryo allantoic membrane. This permits the recognition of viral infection by measuring the increased protein concentration of the adjacent allantoic fluid. This is done by precipitation of proteins in the fluid with 10% trichloroacetic acid and assessing the resulting degree of turbidity in the spectrophotometer 48 hours after the inoculation. The optical density found is in direct proportion to the protein concentration up to 500 turbidity units. We found that there was about three times as much protein in the polyp inoculated eggs as in the saline inoculated controls. Host reaction to virus infection is believed to explain the increased protein.

The second Koch postulate requires that the agent found be transmissible; i.e., grown for several generations outside the body. It was possible to harvest the infected allantoic fluid from several eggs, pool it, and inoculate a small amount of the pooled fluid into a second group of eggs, and assay the result. If after several passages a small amount of material from a previous passage still induced the same effect, then this demonstrated transmissibility which is a property of viruses. In our experiments by this method the viral agent could be grown at least to the fifth generation.

The third Koch postulate requires that the viral agent reproduce polypoid disease in susceptible animals, namely, human beings. This we could not try for lack of volunteers. However, it is well known that viruses have the same immunological properties as other bacteria. The presence of a specific antibody concentration in the serum of polypoid cases and its absence in controls might be considered legitimate and important evidence.

This statement requires clarification. This is most easily done by pointing out a somewhat analogous scientific situation familiar to doctors: in syphilis the *treponema pallidum* has never been grown on artificial media. To quote Eagle,⁵ "Despite numerous reports of the cultivation of the *treponema pallidum* on artificial media, there is good reason to believe that this organism has never been cultivated." However, the disease can be regularly produced by inoculation of rabbits, and found in the chancre and other lesions of lues, thus meeting two of the three Koch postulates. In man serological evidence in the form of the Wasserman complement fixation test, or the Kahn (or other) flocculation test is universally accepted in medicine as having a high degree of validity if positive.

Complement fixing antibodies are probably formed in all virus infections.⁶ Complement fixation technique is well suited⁷ for tests where the antigen is in a far from pure state, as in virus containing tissue extracts. Moreover, this test is considered by immunologists to be more reliable in viral than in ordinary bacterial disease. Perhaps one reason is that the viral particle is said to lose its protein sheath ("overcoat") into extracellular fluid when its nucleic acid ("heart") gains entrance into the susceptible cell. Here the viral nucleic acid is able to influence cell metabolism so that its protein sheath is reproduced.⁸ Thus the protein component of the virus particle may act as an antigen both on entry to and exit from a cell.

A complement fixation system using a polyp tissue extract as the antigen, and the serum of the polyp patient for possible specific antibody has been under study in the Bacteriology and Virology Laboratory of the Massachusetts General Hospital for the past year. Because of innumerable complexities in setting up the test, no final results are as yet available. It is interesting that about 10^7 to 10^8 doses of antigen are required for a positive test under ordinary circumstances. That is, if complement is fixed, the nature of the system is such that excess antigen must be present to unite with enough hypothetical specific antibody to use up all added complement. This means that none of the latter is left over for the hemolytic system, thereby avoiding a false negative.

I excised nasal and sinus polyps from four patients and promptly placed this tissue in Ringer's solution. The polyps were then frozen and kept for study. Venous blood was withdrawn from each patient's forearm and properly stored for future use. Less than a month before this paper was to be presented before the American Laryngological Association 1965 annual meeting, a report was obtained from the laboratory that with a 1:1 or 1:2 dilution of polyp tissue antigen, the complement fixation test result was a four-plus positive in the first case studied. With a dilution of 1:16 the test was completely negative. Moreover, if all components of the test were added to each other without the polyp tissue antigen, the test was completely negative, as would be expected. The system is now being checked for possible anti-complementary action of polyp tissue and other sources of error. It should be stressed that the facts regarding the other three cases are not yet available. Nevertheless, the evidence lends further support to a possible viral etiology of nasal polyposis, and may prove to be comparable to a four-plus Wasserman test in lues.

Electron microscopy of polyp tissue at a magnification of 65,500 is equivocal. At this magnification normal visible nucleic acid granules said to be DNA in the nucleus and RNA in the ribosomes of the endoplasmic reticulum of the cytoplasm cannot be distinguished from viral nucleic acid particles.

HOW TO PREVENT RECURRENCE OF POLYPOSIS

If the viral hypothesis just described has merit, is this important in controlling polyposis, especially recurrence? The answer is yes. The pathology of viral disease is characterized in general by prolifera-

tion or degeneration of cells, or a combination of the two. If the action of a virus is not extremely rapid and explosive, and if the susceptible cells are capable of multiplication, the viral parasite in the cell stimulates hyperplasia.⁹ Polyposis is a form of hyperplasia of nasal and sinus mucosa.

When a virus is safely reposing in a susceptible cell, it is believed today that recovery depends on the presence of a protein called interferon (discovered in 1957), while prevention depends on antibodies in extracellular fluid, including plasma. Humphry and White¹⁰ define interferon as "a soluble protein, whose nature is not yet known, which is produced by many animal cells within a few hours after uptake of living or suitable killed virus. Interferon suppresses the growth of the same or many different viruses in other cells by interfering with the synthesis of new virus nucleic acid." Interferon protein can be produced by many types of cell, and specifically by those of the respiratory tract as in influenza.¹¹ It is a normal product of the cell, not of the virus which stimulates it. Curiously, dead virus or that inactivated by mild heat or certain other methods, will produce it. Interferon protects against many different viruses, regardless of which one produces it.

If after excision of polypoid tissue either diathermy coagulation cauterization or desiccation is used to treat residual or recurrent polyposis, over a period of time permanent cure will often result. It is conceivable that the explanation is not only cell destruction but also the release of inactivated virus from the periphery of the area treated, resulting in the production of interferon, the action of which is found experimentally to last about five to six days.

What is the virus present in nasal polyps? We mentioned in our original publication some of the viruses found in the nose and throat which are unlikely candidates. Since then many new viral agents have been recognized. Rhodes and Van Roogen¹² in 1964 mention 400 antigenically distinct types known now, of which about 200 divided into 15 groups infect man. Gohd¹³ thinks that the respiratory syncytial virus may be a likely prospect in polyp etiology. He feels also that others such as the parainfluenza myxoviruses and certain enteroviruses should be explored. It is well known that myxoviruses, when inactivated by heat, act as powerful interfering agents by liberating interferon. Interferon inhibits in tissue cultures the growth of several groups of viruses which have aerobic metabolic requirements.

VASOMOTOR RHINITIS

It was stated at the beginning of this paper that the allergist not infrequently has difficulty in relieving the nasal obstruction, rhinorrhea, sneezing attacks and other symptoms of vasomotor rhinitis in patients both with and without demonstrable allergy. In the antigen-antibody reaction there is an acute release of noxious agents such as histamine, a heparin-like substance, serotonin, slow-reacting substance, and bradykinin. Most of the histamine and heparin are believed to come from the granules of mast cells; serotonin from platelets, bradykinin from plasma alpha globulin; and slow-reacting substance is known to appear gradually over more than 15 minutes as a lipid attached to protein, although its exact chemical constitution is uncertain at present.

Granted that "allergic rhinitis" is an entity, and can be controlled by allergy therapy, this is not necessarily the only mechanism producing the symptom complex of rhinorrhea, sneezing and nasal obstruction. For example, Golding-Wood¹⁴ believes that autonomic imbalance with parasympathetic over-activity may be responsible, and cites much evidence to support this hypothesis. Walsh¹⁵ regards vasomotor rhinitis "not a disease of the nose but as a manifestation of systemic disease, the result of which is a sympathetic parasympathetic imbalance." He believes that allergy is not a common cause and cites endocrine disorders (thyroid, ovarian, testicular) and emotional disturbances as important in many cases. The vasomotor rhinitis of pregnancy, the nasal pressure headache accompanying pale, very turgescient nasal mucosa in myxo-edema patients with dramatic relief of both headache and intranasal swelling by thyroid therapy, etc., strongly support Walsh's view.

The problem of stabilizing highly-turgescient nasal mucosa can be accomplished most easily in my experience by subepithelial diathermy coagulation cauterization of the inferior turbinates. The details of this technique are described elsewhere.¹⁶ It is very necessary that the slender non-breakable needle used as the active electrode be introduced through the non-ciliated anterior end of the inferior turbinate and reach to but not through the posterior tip, about half-way between the conchal bone and the surface of the mucosa, well away from the tear duct area. The Bovie diathermy machine has its coagulation unit set at "30" (about 4000 milliamperes) or less, and the coagulation with each streak lasts 10 seconds or less. One to three

such streaks are used, depending on the degree of turgescence of the mucosa. The streaks radiate fan-wise from the anterior tip, always avoiding the region of the tear duct. If there is extreme hypertrophy of the posterior tip of the inferior turbinate, it is excised. Organization and connective tissue shrinkage of the resulting eschar will have a very favorable effect upon the mucosa of this turbinate in the great majority of cases.

This procedure can be combined with the usual intranasal surgical techniques for the relief of nasal obstruction, such as submucous resection of the septum, resection of an extremely hypertrophied middle turbinate when the septum is returned to the midline, intranasal ethmoidectomy if indicated, polypectomy, etc.

VIDIAN NERVE SURGERY IN VASOMOTOR RHINITIS

In severe vasomotor rhinitis it is possible to control sneezing and rhinorrhea by sectioning the vidian nerve. Golding-Wood¹⁷ has described a practical technique for this surgery with successful results in 67 of 72 cases.¹⁸ While the objective is primarily to control rhinorrhea and sneezing, he states that "airways improve from mucosal shrinkage."

The operation as done at the Massachusetts Eye and Ear Infirmary involves removal of the medial posterior superior portion of the infratemporal surface of the superior maxilla through a Caldwell-Luc radical antrum approach. In other words, the bony anterior wall of the pterygopalatine fossa is excised, and the periosteum is opened with care to preserve all structures in this space. The internal maxillary artery is identified and avoided. The maxillary division of the trigeminal nerve is visualized and used as a guide to locate the foramen rotundum. The sphenopalatine ganglion is easily seen as this part of the dissection proceeds. The orifice of the pterygoid canal lies a few mm medial and slightly inferior to the foramen rotundum, an oblique bony ridge separating the two. The vidian nerve is cut and coagulating diathermy is applied to the area of its emergence from the canal. The artery of the pterygoid canal is automatically destroyed thereby. There is risk to the sphenopalatine artery as it crosses on its way to the sphenopalatine foramen, and to the pharyngeal branch of the internal maxillary artery also. The chief structure to avoid injuring, however, is the sixth cranial nerve lying low in the superior orbital fissure, even though it is protected by the lower origin

of the lateral rectus, as well as the origin of the inferior rectus muscle. Since the foramen rotundum lies in the medial portion of the great wing of the sphenoid which makes the lower margin of the superior orbital fissure, the greatest gentleness must be used in the dissection of the superior aspect of the foramen rotundum. The dissecting microscope makes this possible; it should be used in the entire pterygo-palatine fossa part of the operation.

Ten cases have been operated on in this manner, on one or both sides, at the Massachusetts Eye and Ear Infirmary up to the present time.¹⁹ Several surgeons (Chasin, Werner; Klotz, Robert; Montgomery, William; and Lofgren, R. H.) have pooled their experience, and agree that their results are favorable, and that no serious complications have occurred. Rhinorrhea and sneezing are controlled, and usually there is less nasal blockage. Chasin emphasizes both that this operation is in a trial period and that the objective is not the relief of nasal obstruction. He has not seen polyposis regress. Others differ with this view regarding nasal obstruction.

It is, of course, possible that some of the favorable results are related to the resulting sclerosis around the contents of the pterygo-palatine fossa.

In using subepithelial diathermy cauterization of the inferior turbinates, in combination with other intranasal surgery, the result to be expected is most favorable for relief of nasal obstruction, and less so but still good for rhinorrhea and sneezing. It has many advantages over vidian nerve surgery. For example, usually only one operation is required; it is short and is accomplished in about one minute per side after proper anesthesia precautions relating to inflammability; there is no swelling of the cheeks; no operating microscope or special retractor for exposure is necessary; etc. The difference in magnitude of the two techniques permits great flexibility when diathermy cauterization subepithelially is used. Thus, in both vasomotor rhinitis and nasal polyposis whatever surgery is necessary can be combined with it.

Vidian nerve section resulting in the immediate cessation of rhinorrhea and sneezing offers much food for thought. It may explain the rationale of treatment techniques of past years, such as injection of the sphenopalatine ganglion with procaine-adrenalin or ethyl alcohol; attempts to diminish hyperesthesia of the "sensitive points" of the nose, etc.

CONCLUSIONS

1. An attempt has been made to find a reasonable explanation for the tendency of polyps to recur after excision.
2. Evidence has been cited that a viral etiology is possible.
3. Long-term diathermy cauterization or desiccation of such tissue as it recurs may be beneficial not only by tissue destruction but also by the release of interferon if the viral hypothesis is correct.
4. Hyperesthetic vasomotor mucosa not controlled by other methods can be stabilized by either subepithelial diathermy cauterization of the inferior turbinates or by vidian nerve section. The relative merits of these techniques have been discussed.

247 COMMONWEALTH AVENUE

REFERENCES

1. Kern, R. A., and Schenck, H. P.: Importance of Allergy in Etiology and Treatment of Nasal Mucous Polyps. *J.A.M.A.* 103:1293, 1934.
2. Weille, Francis L., and Gohd, Robert S.: The Virus Theory of Nasal Polyp Etiology and Its Practical Applications. *ANNALS OF OTOTOLOGY, RHINOLOGY AND LARYNGOLOGY* 65:433 (June) 1956.
3. Wilson, G. S., and Miles, A. A.: Principles of Bacteriology and Immunity. Williams and Wilkins Co. (Baltimore) 2:1002, 1946.
4. Kilbourne, Edwin D., and Horsfall, Frank L., Jr.: A Chemical Method for the Detection of Virus Infection of the Chick Embryo. *Proc. Soc. for Exper. Biol. and Med.* 71:708, 1949.
5. Eagle, Harry: Bacterial and Mycotic Infections in Man (edited by R. J. Dubos). J. B. Lippincott Co., Philadelphia, p. 529, 1948.
6. Gell, P. G. H., and Coombs, R. R. A.: Clinical Aspects of Immunology. F. A. Davis Co., Philadelphia, p. 65, 1964.
7. *Ibid.*, p. 35.
8. Stanley, W. M.: On the Nature of Viruses. *Modern Medicine* 26:75 (July 1) 1958.
9. Rivers, Thomas M.: Viral and Rickettsial Infections in Man. J. B. Lippincott Co., Philadelphia, p. 6, 1949.
10. Humphrey, J. H., and White, R. B.: Immunology for Students of Medicine. F. A. Davis Co., Philadelphia, p. 453, 1964.
11. *Ibid.*, p. 224.
12. Rhodes, A. J., and Van Roogen, C. E.: Virology. Williams and Wilkins Co., Baltimore, p. 3, 1962.
13. Gohd, Robert S.: Personal Communication (January) 1965.
14. Golding-Wood, P. H.: Observations on Petrosal and Vidian Neurectomy in Chronic Vasomotor Rhinitis. *J. Laryng. and Otol.* 75:232, 1961.

15. Walsh, Theodore E.: Vasomotor Rhinitis. *Laryngoscope* 60:360, 1950.
16. Weille, Francis L.: The Treatment of Chronic Vasomotor Rhinitis. *Medical Clinics of North America* 39:1439, 1955.
17. Golding-Wood, P. H.: Pathology and Surgery of Chronic Vasomotor Rhinitis. *J. Laryng. and Otol.* 76:969, 1962.
18. Golding-Wood, P. H.: Sympathetic Neurosurgery in Otolaryngology. Unpublished data.
19. Chasin, Werner: Personal Communication (March) 1965.

DISCUSSION

DR. JOSEPH L. GOLDMAN: Dr. Goodale and Dr. Montgomery have presented us with a new operation, or rather they have shown us their development of this procedure, and I think that it should be accepted as progress in sinus surgery. Also, this operation should be viewed in the total picture of sinus surgery. This type of surgery, to be performed properly, requires adequate treatment of the ethmoidal sinuses. The osteoplastic operation on the frontal sinus and intranasal surgery of the ethmoidal sinuses can be done simultaneously.

I would like to direct my remarks particularly to Dr. Weille's paper.

Actually, there has been very little progress in the concepts of polyposis and polypoid disease of the paranasal sinuses in the last twenty or thirty years. Dr. Weille indicated to us how to control nasal obstruction by various methods and he has shown the value of intranasal procedure. There has been very little progress in ideas and knowledge relating to the control of the disease itself.

Through the work of Dr. Williams and Dr. Hilger on the autonomic instability of the vasomotor nervous system of the nose, we know that the reaction of nasal stricture is due to hyperstimulation of the cholinergic fibers of the parasympathetic system. Understanding of this hyperactivity should determine therapy.

In my experience, certain of these cases are allergic to allergens—we are talking about polyps, polypoid disease—but these cases are in the great minority. Even if these patients are treated with hyposensitization, the formation of polyps or polypoid disease is not controlled. Polypoid disease of the sinuses seems to be primarily a constitutional disease. We know that this disease is related to hormones, emotions and other such factors which stimulate the parasympathetic nervous system, but the complete mechanism of specific etiologic factors have not been clarified as yet. Until this happens, we shall have to rely, as Dr. Weille has indicated, on the judicious application of intranasal procedures to relieve the obstruction caused by polyposis and vasomotor rhinitis.

DR. SALINGER: Dr. Weille has been pursuing this virus for quite a few years and I admire his tenacity and hope that he will soon be able to achieve the establishment of the third postulate of Koch with regard to those viruses that he has been investigating.

I want to say a few words about purely vasomotor rhinitis. Now, I don't like to give drugs without an indication and we have usually based our indications for giving thyroid extract on the metabolism and the PBI tests. In my hands they and even the sedated metabolism test fail to reveal cases in which there is thyroid deficiency. To give it empirically is a very hazardous business.

I want to recite one instance in which, despite negative allergy findings, despite normal PBIs, normal sedated basal metabolism, the woman failed to react to cauterization, or respond to T3, Cytomel, etc. I finally gave her pure thyroid extract. Now, how much should one give? I base the dose on the patient's reaction, whether

they show any symptoms of hyperthyroidism when they are taking it. I got this woman up to six grains a day and lo and behold, her vasomotor rhinitis disappeared. Now, I kept her on that for several weeks, a couple of months—no signs of any thyroid overactivity—so I thought, "Well, maybe this is just a coincidence. I will reduce it." So I said, "Cut the dose down to three grains a day." The symptoms recurred! She went back to six grains a day and her symptoms disappeared, and that has been the status up to now.

I would like to know why we don't have a dependable method whereby we can determine how much of this medication to give without resorting to a hit or miss regime.

DR. EDLEY H. JONES: This is a very fascinating subject and I just have one comment to make, which is implied by the essayist:

All nasal allergy is a form of vasomotor rhinitis. Please keep in mind that not all vasomotor rhinitis is allergic.

DR. SANDERS: What I would like to call to your attention is the progress that has been made in food allergy. There is now a provocative food test that has worked out very well. After evaluating the reaction of the skin, resulting from the intradermal food test and injecting a certain amount of the specific food being tested, one can produce symptoms. These symptoms can be relieved by finding the end-point of that food and this is determined by administering 0.10 of the next weaker dilution (Rinkel 1 to 5) of the specific food being tested. We are finding improvement in many cases of nasal polyps. Some polyps in the nose can be reduced in size by controlling food allergy.

DR. WEILLE (closing): In reply to Dr. Goldman, I feel that intranasal ethmoidectomy is a most valuable surgical procedure, merely because you can convert the triangle of the frontal plane of the nasal cavity to a quadrangle to gain more air space, 5 millimeters anteriorly and 15 millimeters posteriorly, and it can be done without altering the physiology or the mechanics of the nose.

What causes polyposis? Well, that is what I talked about and I could keep on talking the rest of the day. A good case can be made for a viral etiology.

In regard to vasomotor rhinitis, it is well known that pregnancy, for example, can produce a temporary vasomotor rhinitis throughout the pregnancy. Myxedema may be accompanied by vasomotor rhinitis. Dr. Ted Walsh reported years ago a cure of vasomotor rhinitis by treatment with thyroid, and others have reported this also.

I think that there may be food for thought in that there is a specific antibody in the blood serum in the particular polyp case I mentioned and this is obviously not a reagen.

A virus is an obligatory intracellular parasite that is equivalent to a bacterium, so that the viral hypothesis of nasal polyp etiology may be considered as equivalent to bacterial allergy.

With Dr. Salinger I agree that many vasomotor cases are controlled by using thyroid extract and I routinely check the basal metabolism, the PBI, the PB uptake and the blood cholesterol. For treatment I only go as high as two grains, that is, 125 milligrams, of thyroid a day; beyond that, I let the endocrinologist take over.

I think that Dr. Jones' remark epitomizes the situation pretty well.

And as to what Dr. Sanders said, if you are lucky enough to have an extrinsic allergen, such as a food allergy, by all means have the allergist treat the patient. Then the otolaryngologist is not needed.

LIPOMA OF THE EPIGLOTTIS AND LIPOMA OF THE HYPOPHARYNX IN THE SAME PATIENT

WATT W. EAGLE, M.D.

DURHAM, N.C.

Lipomata may occur frequently beneath the skin over the entire body, and in such locations they may be multiple and small, but they also may become very large—however, this type is usually a solitary lipoma. Lipomata do occur, but much more rarely, beneath the mucosa of the respiratory tract and the upper esophagus. Verification of the paucity of lipomata of the upper respiratory tract was brought to our attention some years ago when New and Erich¹ in their studies found only one case of lipoma in 722 cases of benign laryngeal neoplasms (0.1%), and quoted Chevalier Jackson as stating that in 40 years of his practice he had seen only seven cases of lipomata of the upper respiratory tract.

The usual so-called lipoma is actually in most instances a fibrolipoma because the lipoma is encapsulated by stratified epithelium and is "baled-in" by a mesh-work and strands of fibrous tissue, causing it to be somewhat lobulated in gross appearance after excision. They are usually egg-yolk color before and after excision. Eggston and Wolf² state that a pure lipoma is extremely rare and, when it does occur, it is usually attached at the base of the tongue, although they do not cite any clinical cases of a pure lipoma. For brevity, we shall use the term "lipoma" throughout this presentation rather than the full name of "fibro-lipoma."

Otolaryngological reports of hypopharyngeal lipomata have been recorded in the literature since 1854 (Holdt). Authors have usually divided the lipomata into groups relative to their point of origin.

From the Division of Otolaryngology, Department of Surgery, Duke University Medical Center, Durham, N.C.

Thus, one group is composed of those tumors originating in the pharynx and the hypopharynx. The second group is composed of those lipomata which originate submucosally in the retropharyngeal regions. The third group is composed of those with origin in the postcricoid area. Lipomata composing the fourth group are those originating in the bronchial tree.

The greater portion of all cases of lipomata in the upper respiratory tract originate in the hypopharynx, with the lower pole of the tonsil, the hypopharyngeal wall, and the aryteno-epiglottic fold being the main areas of attachment. Individual reports, and sometimes a summation of previous case reports, of lipomata arising from these areas are to be found in the literature by Kramer³ in 1934, Davison⁴ in 1942, Som and Wolff⁵ in 1952, Harper⁶ in 1959, Laskiewicz⁷ in 1962, and others.

Retropharyngeal lipomata have been described by Figi and Hunt in 1927 and Putney and Fry⁸ in 1940, who summarized all retropharyngeal lipomata that had been reported up to 1940, there being a total of 15 cases. The retropharyngeal lipomata are located between the cervical spine and the pharyngeal mucosa, causing a visible growth intra-orally and frequently externally.

Lipomata attached to the postcricoid region have been observed by Garretson and Hardin in 1928, Kramer³ in 1934, Penfold in 1952, and Harper⁶ in 1959. These lipomata usually drop into the esophagus from their attachment posteriorly from the cricoid region.

A lipoma of the bronchial tree, with surgical removal, was first reported by Kernan⁹ in 1927. Further reports of bronchial lipomata have been made by Som and Feuerstein¹⁰ in 1951 and Beaton and Heatly¹¹ in 1952. All reported lipomata of the bronchial tree have occurred in the main stem bronchi.

Some lipomata are intermingled with other types of neoplasms. For instance, Onidi and Hoag in 1945 reported a case of lipomyxofibroma, and Unfer reported a case of lipoma with sarcomatous changes in 1946. Cancuillo¹² in 1956 had a most interesting case of a 22 year-old female who had a growth attached to the cartilage of the anterior surface of the epiglottis. This growth was diagnosed pathologically as a myxo-chondro-fibro-lipoma. This is the only case involving a lipomatous growth attached to the anterior surface of the epiglottis that could be found in the literature, but it is to be recalled that this specimen included cartilaginous, fibrous, and myxomatous,

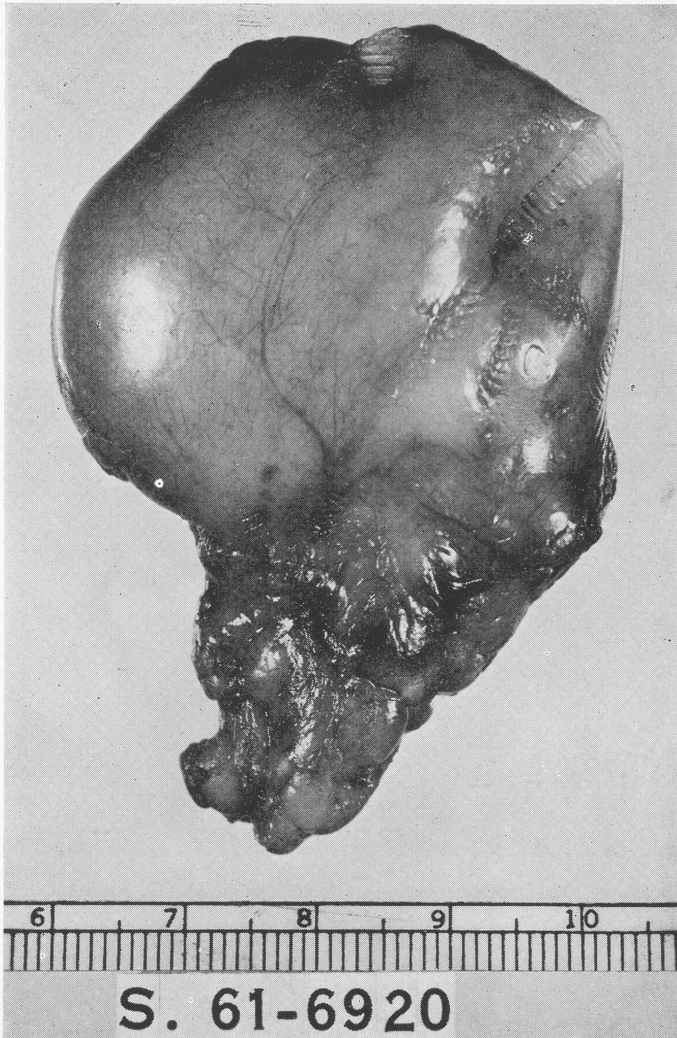


Fig. 1.—Gross specimen of lipoma attached to anterior surface of epiglottis removed September 1947.

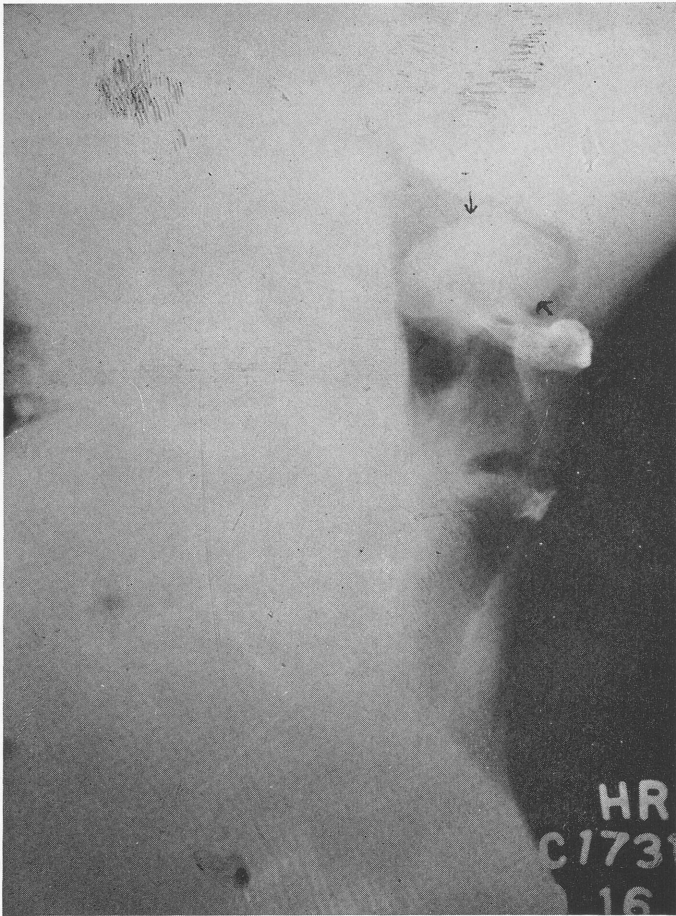


Fig. 2.—Lateral roentgenogram of lipoma of epiglottis removed in September 1947.

as well as lipomatous tissues. Cancuillo's case and the case herein reported are the only instances of a lipomatous growth being attached to the anterior surface of the epiglottis. The patient cited in this presentation had his first lipoma in 1947 attached to the anterior surface of the epiglottis, but his second lipoma in 1961 was attached to the right tonsil inferiorly and the hypopharynx.

There has been considerable conjecture as to the cause of a lipomatous growth. Gladstein¹³ suspected that embryonic invagina-

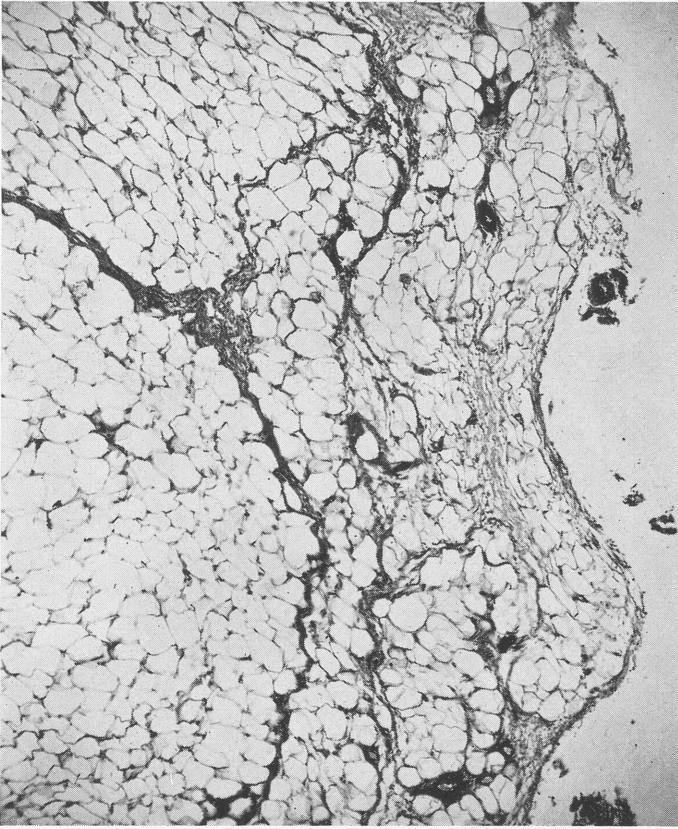


Fig. 3.—Section of lipoma removed September 1947 from anterior surface of epiglottis. Squamous epithelium, which was relatively thin, has sloughed mainly.

tion of mesenchymal cells may cause a lipoma, but he also thought that a lipoma may be due to hyperplastic changes in adipose tissue—or else, to a disturbance of the chemistry in normal cells, due to the retention of fatty acids in the cells rather than the fatty acids being excreted. In the case of the complex multi-type neoplasm that Cancuillo reported he postulated that an embryonic bud of mesenchymal tissue did not develop properly in the region of the hyoid arch, since it was found to include all the various types of tissues mentioned previously, causing a neoplasm somewhat resembling a

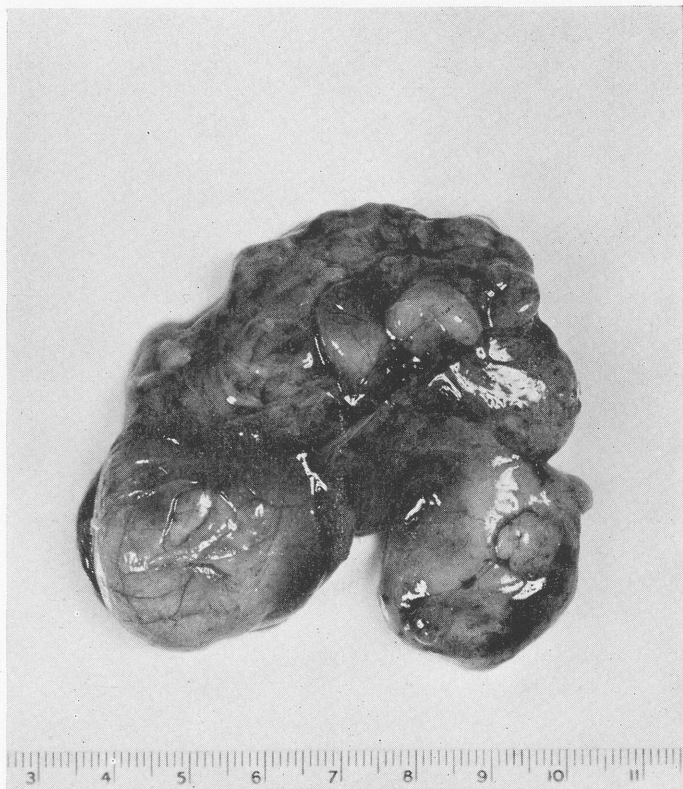

Fig. 4.—Gross specimen of lipoma originating from right tonsil and hypopharynx removed September 1961.

teratoma. He pointed out the likelihood of a recurrence locally following surgery, and such did occur in his patient.

There are very few symptoms relative to a hypopharyngeal lipoma and they usually occur only after the lipoma has attained considerable size. Then the growth may interfere with the normal function of swallowing and breathing, with possibly an alteration of the voice. Several authors described lipomata, when attached to the posterior cricoid and hypopharyngeal regions, as eventually being swallowed because they hang down into the esophagus. Those that do project into the esophagus can be regurgitated into the hypopharynx, where they may be visible with or without the necessity of

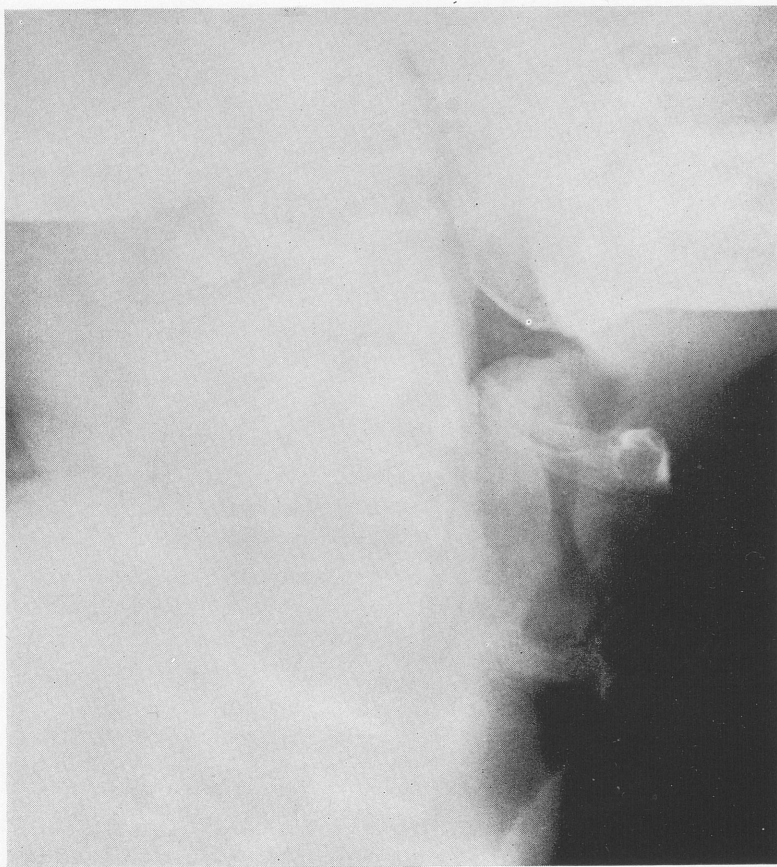


Fig. 5.—Lateral roentgenogram of lipoma removed from right tonsil and hypopharynx in September 1961.

depressing the tongue during examination. Davison's⁶ case, for instance, was that of a lipoma which had its origin in the hypopharynx, projecting down into the esophagus, and on excision was found to be eight inches long and one inch wide. The majority of patients who swallow a lipoma have very little trouble in swallowing food. One case of asphyxia is to be found in the literature, and this was because the growth on regurgitation fell into the trachea.

Usually small lipomata of the hypopharynx can be removed under general anesthesia by the exposure provided by a Crowe-Davis

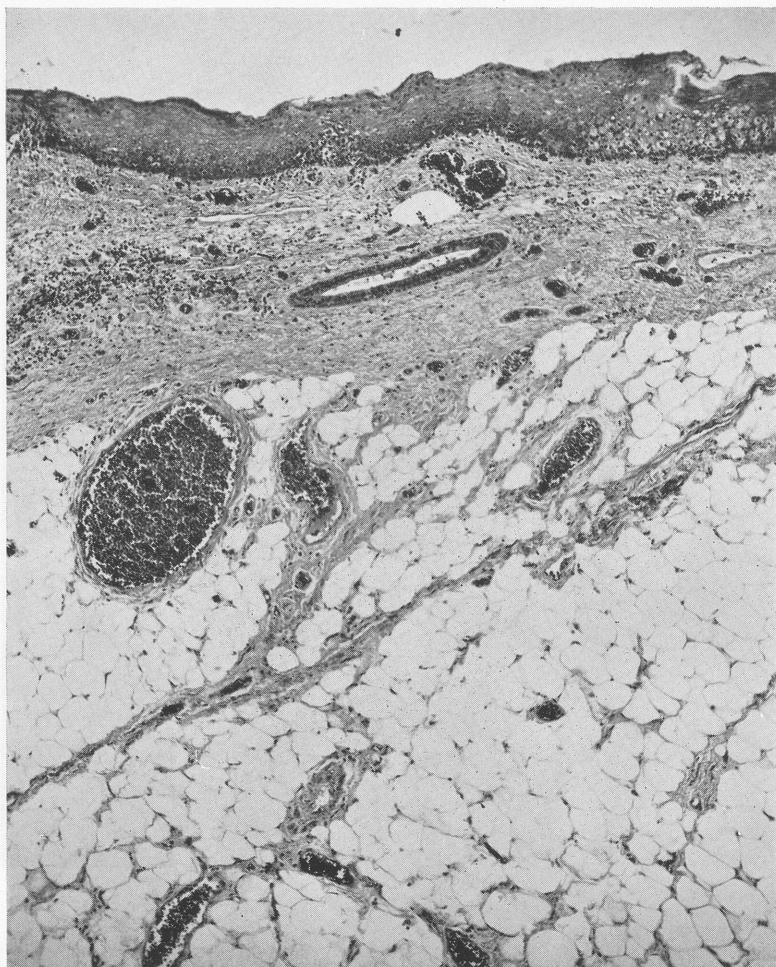


Fig. 6.—Section of lipoma from right tonsil and hypopharynx removed in September 1961. Note thickness of squamous epithelium, thick fibrous layer, fibrous mesh-work, and marked vascularity.

mouth gag. The anesthesia is inhaled as it exits from the small tube attached to the tongue blade in front of the glottis. This is an ideal armentarium for the removal of a small lipoma. However, when a large lipoma exists, intubation anesthesia is necessary, and in some instances the intratracheal tube cannot be inserted until after the lipomatous growth has been grasped with forceps and lifted for direct

vision for the passage of the endotracheal tube. All of the hypopharyngeal growth can easily be dissected from its attachments. Bleeding is minimal and easily controlled, although there are some fairly good-sized blood vessels in the lipomatous growth. No severe bleeding has been reported by any author. Laryngoscopy, either by suspension or not, is necessary for the removal of postcricoid lipomata. When a lipoma is retropharyngeal and large, it probably will be necessary to make an external incision anterior to the sternomastoid muscle for adequate operative vision and working space. Healing is rapid after all of the redundant mucosa is resected from the posterior pharyngeal wall after the retropharyngeal lipoma has been removed. There is no recurrence locally of lipomata if all the original growth has been removed, regardless of the point of origin.

REPORT OF A CASE

S.J., white, male, aged 42, was referred by Dr. R.M. of Rock Hill, S.C. and was first seen on September 15, 1947. The patient stated that he had noted symptoms of only a mild "fullness" in the throat for three to four months and that he had noticed trouble in swallowing and interference with respiration for only two weeks. There had been some disturbance of sleep, but by changing his position he could breathe freely again. His relatives stated that he had a voice change of three weeks' duration. The entire physical examination was negative except a growth which was located between the base of the tongue and the epiglottis, which had the appearance of the yolk of an egg. All laboratory studies were normal. Roentgenograms verified the growth to be anterior to the epiglottis. On the day after admission, under endotracheal anesthesia, and with the use of a Crowe-Davis mouth gag for exposure, there appeared to be a cyst of the epiglottis,¹⁴ which pushed the epiglottis backward, similar to a previous case of mine in 1942, but this patient's growth was found to be more firm than a cyst on palpation and probing. The growth was then grasped with forceps and was easily dissected from its insertion in the middle of the anterior wall of the epiglottis. Bleeding was minimal. The excess mucosa at the base was pulled over the raw surface on the epiglottis, and healing was very prompt. He was allowed to leave the hospital on the following day. All symptoms referable to the difficulty with swallowing and respiration were alleviated, and his voice returned to normal. The microscopic examination of the growth revealed a fibro-lipoma. The weight of the lipoma was 32 grams; measurements were 6 x 4.5 x 2.5 cm.

On September 26, 1961 (fourteen years after the previous removal of an epiglottic lipoma in this patient) Dr. R.M. called again and stated that the patient was again having trouble with breathing, especially at night, and that the patient's wife thought he was going to expire—each breath being his last one. He was admitted as an emergency because of his stertorous breathing, but he did not require surgery until the following day. He and his family stated that he had had no symptoms during the intervening 14 years since 1947 until two weeks prior to this admission. There had been no particular swallowing difficulty during this time, having had only impaired respirations. Again the general examination was negative except for a tumor in the hypopharynx. This growth was observed to be bi-lobed and could be seen only when he gagged, at which time it would appear above the tongue and would completely obstruct respiration. It was impossible to determine exactly where the growth was attached, but it would fall mainly back into the right side of the hypopharynx. Actually the growth appeared to be more fibrous than the growth that was removed fourteen years previously. Roentgenograms showed the bi-lobed growth in the hypopharynx. On the day after admission, under general intubation anesthesia, following sodium pentothal induction, the growth was grasped with forceps and lifted for the passage of the endotracheal tube. The growth was observed to be attached to the inferior pole of the right tonsil and the adjacent hypopharyngeal wall. Excision was performed without any difficulty whatever insofar as bleeding or technical difficulty was concerned. The growth measured 6 x 4 x 1.5 cm. The weight was not recorded but it was larger than the previous lipoma removed and probably weighed 45 grams. It was about the size of a black walnut, including the outer hull. The pathological section showed a thicker stratified squamous epithelial capsule, and there was much more fibrous tissue in this specimen than in the 1947 lipoma. Again all of his symptoms were relieved following the surgery and the patient was able to leave the hospital in the next day.

No further information was obtained on this patient until January 1965 when I wrote to him to inquire as to his pharyngeal condition for the preparation of this presentation. His wife wrote me that he had had no recurrence whatever of any pharyngeal or laryngeal symptoms and that he had died of an intracranial vascular accident on January 16, 1962, three days following surgery for a ruptured peptic ulcer.

SUMMARY

An occurrence of a lipoma (fibrolipoma), having its origin on the anterior surface of the epiglottis, with surgical removal in 1947, and then another lipoma (fibrolipoma) in the same patient in 1961, with its origin at the inferior pole of the right tonsil and the adjacent hypopharyngeal area, with surgical removal, is herein reported. Roentgenograms, photographs, and pathological sections of each excised lipoma have been shown.

This report is unique, not only because two lipomata—fourteen years apart—occurred in the upper respiratory tract in the same individual, but because the first lipoma had occurred on the anterior surface of the epiglottis, the only case of such point of origin ever reported.

DUKE UNIVERSITY MEDICAL CENTER

REFERENCES

1. New, G. B., and Erich, J. B.: Benign Tumors of the Larynx: Study of 722 Cases. *Arch. Otolaryng.* 28:841, 1938.
2. Eggston, A. A., and Wolf, D.: *Histopathology of Ear, Nose and Throat.* Baltimore: Williams and Wilkins Co., 1947.
3. Kramer, R.: Multiple Fibro-lipomata of the Hypopharynx and Esophagus. *ANNALS OF OTOLGY, RHINOLOGY AND LARYNGOLOGY* 43:880-883 (Sept.) 1934.
4. Davison, F. W.: Fibro-lipoma of the Laryngopharynx. *ANNALS OF OTOLGY, RHINOLOGY AND LARYNGOLOGY* 51:853-854 (Sept.) 1942.
5. Som, M., and Wolff, L.: Lipoma of the Hypopharynx Producing Menacing Symptoms. *Arch. Otolaryng.* 56:524-534 (Nov.) 1952.
6. Harper, A. R.: Lipomata of the Upper Air and Food Passages. *J. Laryng. and Otol.* 73:419-422 (July) 1959.
7. Laskiewicz, A.: Pedunculated Fibro-lipomas of the Pharynx. *Eye, Ear, Nose and Throat Monthly* 41:369-373 (May) 1962.
8. Putney, F. J., and Fry, K. E.: Retro-pharyngeal Lipoma. *ANNALS OF OTOLGY, RHINOLOGY AND LARYNGOLOGY* 49:967-972 (Dec.) 1940.
9. Kernan, J. D.: Three Unusual Endoscopic Cases. *Laryngoscope* 31:62-64 (Jan.) 1927.
10. Som, M. L., and Feuerstein: Endoscopic Removal of Lipoma of Bronchus—Report of Two Cases. *Arch. Otolaryng.* 54:341-346, 1951.
11. Beaton, A. H., and Heatly, C. A.: On the Tracheobronchial Fibro-lipomas. *ANNALS OF OTOLGY, RHINOLOGY AND LARYNGOLOGY* 61:1206, 1952.

12. Cancuillo, D.: Myxo-chondro-fibro-lipoma of the Epiglottic Cartilages. *L'Oto-rino-laringologia Italiana* 24:185, 1956.

13. Gladstein, M. A.: The Pedunculated Pharyngeal Fibro-lipomas. *Laryngoscope* 29:641, 1909.

14. Eagle, W. W.: Bacterial Allergy: Otolaryngological Aspects. *Sou. Med. J.* 35:908-912 (Oct.) 1942.

DISCUSSION

DR. FRANCIS E. LEJEUNE: Dr. Eagle has presented not only an interesting case but a rather unique one in that the patient concerned had two unrelated lipomas.

Lipomas of the epiglottis and of the hypopharynx are uncommon and to find both of these conditions occurring in the same individual, even though fourteen years apart, is indeed unique.

Fortunately these growths are benign in character and only produce mild symptoms of fullness in the throat, interference with deglutition and occasionally respiration, depending, of course, upon the position and the size of the growth.

The British Journal of Laryngology and Otology of June, 1951, contains a survey of the literature on lipomas of the larynx by A. C. Maconie, in which he briefly describes the pertinent findings in twenty-three cases of lipoma of the larynx.

He states that G. Laurens, in 1904, reported finding a very large lipoma arising from the whole anterior surface of the epiglottis. Because of its size it was thought best to remove it by transhyoid pharyngotomy.

Maconie also reports that Posthumus Meyjes removed a lipoma from the inner surface of the epiglottis of an eight-year-old girl.

As stated by Dr. Eagle, the area of predilection for the development of lipomas is the aryepiglottic folds. Once removed, these tumors do not recur in the same locality.

Might I report a tumor attached to the postcricoid area with a pedicle, which allowed downward extension to just below the cricopharyngeus? Because of a receding mandible it was impossible to visualize the tumor with the suspension laryngoscope and it was also impossible to remove the tumor with the aid of an esophagoscope or a plain laryngoscope. We therefore discontinued the operative procedure and planned to do an external approach, but four hours after recovery from sodium pentothal anesthesia and following a drink of water the patient had a severe coughing spell and in spite of emergency help, he suffocated. Autopsy showed the tumor wedged in the glottis. I should like to show you four slides of this latter tumor.

This first slide shows a thickening on the left side of the epiglottis, as you can see right there (indicating). This tumor was attached to the side of the larynx, to the postcricoid area and to the lateral area. The epiglottis has been removed for better visualization of the entire area.

This slide shows the tumor protruding from the area and it can well be seen there.

Here we have the entire tumor. This (indicating) is the hypopharynx and, of course, this (indicating) is the larynx and you can see that the tumor is attached to the lateral wall and part of the posterior wall at the larynx.

This is the pedicle, which extended to the cricopharyngeal region.

And this is the way we found this tumor located when we did the autopsy. It fell down into the glottis, was aspirated, and, in spite of trying resuscitation and such things as that, this man expired.

I enjoyed Dr. Eagle's paper and I certainly think that he presented a very unusual and interesting case to us.

DR. FRANCIS W. DAVISON: Since he mentioned a case I reported in the 1942 Transactions of the A.B.E.A., I would like to show briefly two slides.

This was very interesting because this chap, aged 70 years, had no symptoms except two or three times a year when he had an attack of nausea and vomiting and brought this mass up. Thereafter he swallowed it and had no trouble until three or six months later. I didn't believe his story when he came in, but after depressing the tongue with the tongue blade, this is what happened.

Using local anesthesia, the hypopharynx was exposed with a direct laryngoscope. The tumor mass was found to be attached by a pedicle one-half inch in diameter to the left lateral wall of the hypopharynx. The pedicle was transfixed with a needle-carried ligature and ligated. The pedicle was then severed by an electrode attached to the cutting current. A much smaller, but similar tumor mass arising just mesial to the large one was then removed with the cutting current after its pedicle had been crushed. The large tumor mass after removal was eight inches in length and one inch in diameter at its thickest point.

Here is the growth after removal. The pedicle was quite narrow and was attached to the posterior wall of the hypopharynx. Histologic report—Fibrolipoma.

DR. F. JOHNSON PUTNEY: As often happens in rare lesions after reporting two cases of retropharyngeal lipoma 25 years ago, I have not observed another case in this locality and have seen only one fibrolipoma in the larynx and one in the bronchus.

There seems to be a tendency for certain individuals to develop lipomas which may be multiple in various parts of the body. When situated in the pharyngeal or retropharyngeal area symptoms usually develop only after the tumor has become large enough to interfere with swallowing or breathing. It is difficult to know how a pre-operative diagnosis of lipoma can be made since large lesions present as a smooth mass and the lobulations which are nearly always present cannot be palpated due to the tenseness of the presenting submucosal mass. There seems no valid reason for biopsy, and the initial surgery can be aimed at complete removal once its nature has been established at the operating table. In large lesions with a broad base I would prefer the external route of removal even though the lesion may be limited to the vallecula. The cases presented here were excellently handled by the intraoral method without complication, but in my hands I feel safer and better able to control the surgical procedure by an external approach.

DR. FITZ-HUGH: I would like to add one more case and demonstrate the external approach.

This particular patient had, twelve years prior to the operation that will be shown here, a lipoma removed from the esophagus. The present one extended upward from the left pyriform sinus area into the hypopharynx.

This demonstrates the external approach (pharyngotomy) here for the removal of the lipoma. I am inclined to agree with Dr. Putney that the external approach in the over-all picture is probably the more desirable one.

DR. J. ALLAN FIELDS: About fifteen years ago a marine recruit was admitted to the Naval Hospital serving Parris Island, South Carolina with a complaint that he kept his tent mates awake with his choking type stertor. By mirror laryngoscopy a smooth tumor was found lying in the laryngeal vestibule. It appeared to arise from the left aryepiglottic fold. He was given endotracheal anesthesia. An attempt made at removing the tumor by snare failed. An external approach was planned for the next day but several hours after he was returned to the ward, his respiration suddenly became worse and before the physician on duty arrived the patient expired.

At autopsy, the findings were almost identical to those found in Dr. LeJeune's patient except that the tumor was smaller. The pathologist reported a fibrolipoma. His opinion was that death was caused by a combination of suffocation and tuberculous adhesive pericarditis.

DR. EAGLE (closing): I wish to thank all the discussants very much. I apologize for not having found the article that Dr. LeJeune found relative to the anterior attachment of a lipoma on the epiglottis in the British medical journal.

MAST CELLS IN THE UPPER RESPIRATORY TRACT

HARRY P. SCHENCK, M.D.

PHILADELPHIA, PA.

Mast cells are a normal component of the tunica propria and sub-mucous tissue of the mucous membranes of the turbinates,⁴⁵ paranasal sinuses,²⁸ bronchi,⁴⁰ pharynx, and the faucial and pharyngeal tonsils.²¹ They contain large granules which are the source of substances that play an important role in inflammation and allergic reactions.

In 1877, Paul Ehrlich¹¹ discovered tissue basophilic granulocytes to which he gave the name "mast cells." He described them as connective tissue cells distinguished by the presence of basophilic granules that stain metachromatically with certain aniline dyes and noted their abundance in chronic inflammation of connective tissue. Ehrlich postulated that the numerous mast cells in chronic inflammation of connective tissue indicated that the granules in these cells represent nutrient for the connective tissue.^{11,14} He also gave some consideration to the reciprocal relationship of mast cells and eosinophiles¹² and, later, reported the presence in the blood of a cell with basophilic granules (blood basophil).^{13,15}

The absence of interest in the physiological and pathological significance of the biologically active mast cells during the next 80 years is inexplicable since Holmgren and Wilander²² in 1937 reported connective tissue mast cells were very rich in a sulfonated acid mucopolysaccharide possessing a demonstrable anticoagulant activity, and Cazal¹⁰ in 1942 noted a relationship between histamine and mast cells.

Following the recognition of the so-called collagen diseases, the mast cells were found to play an important role in fibrillogenesis and in the elaboration of connective tissue matrix or ground substance due to their production, in addition to other substances, of hyaluronic acid which has a regulating influence on the ground substance. Rawlins³⁴ pointed out that the cellular elements of connective tissue consist, in the main, of fibroblasts and mast cells, and that, while mast

cells contribute to the production of the ground substance, they also store histamine, heparin and many other substances which are liberated in the inflammatory chain reaction whereas fibroblasts are concerned with the production of collagen fibers. He suggested that the term "connective tissue disease" be substituted for collagen disease and stated that the pathology in hay fever, perennial nasal allergy, vasomotor rhinitis, hypometabolic stuffy noses and accidental or surgical trauma was primarily in the ground substance of the connective tissue and consisted of edema accompanying an increase and liquefaction of the amorphous substance.

Ehrlich¹² as early as 1879 observed numerous mast cells in certain tumors and it is now generally recognized that some neoplastic growths are accompanied by an increase in the number of mast cells in the growing tumor and especially along the border between normal tissue and the expanding neoplasm. The rare occurrence of a mast cell tumor in man has been reported.²⁰ Bloom,⁷ employing electron microscopy in the examination of neoplastic mast cells, found a large number of tumor cells which showed peculiar morphological alterations of a definite pathological character, and fine cytoplasmic particles with a striking similarity to the virus particles observed in some other tumors.

Mast cells are a source of numerous substances of which the most important appear to be heparin, histamine and 5-hydroxytryptamine. Conclusive evidence for the presence of heparin in the granules of mast cells and for the presence of heparin in the blood basophil has been obtained by a wide variety of methods and techniques. In 1953, Riley and West³⁶ firmly established that mast cells are very rich in histamine and found a strong correlation between the histamine content of normal and pathological tissues and their mast cell population. There has been repeated verification of the localization of histamine within the tissue mast cell but although the tissue mast cell may be the main source of histamine, histamine has been found to be present in goblet cells during their increased activity and proliferation.^{28,29} An increase in the volume of mast cells follows the application of histamine and there is increasing evidence that eosinophiles destroy histamine.

Riley^{35,37} found that the tissue mast cell not only contains histamine but also undergoes degranulation under the influence of histamine liberators. He considered the cytologic evidence of histamine discharge to be swelling, vacuolation, degranulation and, finally, dis-

ruption of the cell, and regarded the morphology of the mast cell to be a reliable indication of its functional activity.

The releasing mechanism for the appearance of the extracellular granules remains obscure but major changes in the mast cells are readily induced by many substances of exogenous and endogenous origin including cortisone, estrogens, thyroxine and hypophysin.²¹ The granules released from mast cells under various conditions have the same constituents as the granules within mast cells and the free granules are phagocytized to some extent by macrophages. Histamine liberating compounds produce degranulation and dissolution of both tissue mast cells and blood basophils with the liberation of histamine locally in intercellular fluid or into the blood plasma.²⁷

A hypothesis to explain the joint occurrence in, and release of heparin and histamine from, the tissue mast cells has been proposed by Riley.³⁰ When the mast cell is injured, histamine is released first, causing vasodilation of the regional vessels and a flooding of the injured zone with protein-rich lymph, and also acts directly on the nearby connective tissue cells to increase their phagocytic activity and capacity. These cells now ingest and rapidly digest the heparin-containing mast granules that follow. The connective tissue cells are thus stimulated to produce specific mucopolysaccharide ground substance of their own. He concludes that the mast cells participate in the earliest phase of the local reaction of the connective tissue to injury.

The effects of an antigen-antibody reaction on mast cells explain, at least in part, some of the mysterious tissue changes in the upper respiratory tract. Mota³¹ attributes the mast cell damage in anaphylaxis to the reaction of antigen antibodies fixed on the mast cells which induce damage to the cells by a mechanism as yet unknown but resulting in the liberation of histamine.

Theoretically, the antigen-antibody reaction underlying allergic phenomena depends upon the exposure of plasma cells to an antigen. The general significance of antibody formation by the plasma cell in the physiology of Waldeyer's ring has been recognized for a decade⁴¹ but the plasma cell now appears to have a greatly expanded role in the upper respiratory tract and elsewhere. The exposure of plasma cells to an antigen induces the production of specific antibodies, which whether released locally or into the blood, attach to tissue mast cells. When the specific antigen reaches the altered mast cells, a reaction occurs between the antigen and the antibodies attached to the mast

cells resulting in disruption of the mast cells and the distribution of granules of histamine or a histamine-like substance in the intercellular spaces.

Bryan and Bryan,⁹ in an extensive investigation of wiped smears of nasal secretions, found that the significant cells in the allergic response are goblet cells, eosinophiles and mast cells. A marked increase of goblet cells was a constant and reliable feature in the smears obtained from allergic patients even though mast cells could not be demonstrated. Goblet cells were observed rarely in secretions other than those obtained by their method of wiping the nasal mucosa because these cells are not exfoliated normally. They regarded the presence of goblet cells in nasal smears as a fairly definite sign of allergy and especially if a few eosinophiles and mast cells were present. While they found mast cells very infrequently in smears from acute and chronic nasal infections, there was a marked increase in severe allergic reactions.

Hlavacek and Lojda²¹ and Palva and Palva^{28,29} have carried out extensive studies of the mast cells in the upper respiratory tract. Their observations have been confirmed in the main by other investigators. Palva²⁹ determined the normal distribution of mast cells in three different levels of the mucosa: 1) directly bordering the epithelium, 2) the middle submucosal layer, and 3) the deep submucosal layer. They were thus able to compare the distribution of mast cells and eosinophiles and reported that mast cells were present mainly in the deep submucosal layer while eosinophiles appeared in the two superficial layers and very rarely in the deep submucosal layer. The number of mast cells present in various abnormalities of the upper respiratory tract and their variations from the normal have been determined by light microscopy²¹ but electron microscopy^{19,42,43,47} is of increasing importance in the investigation of the morphology of the mast cell and in detecting the changes induced within them by experimental procedures.

In the upper respiratory tract, as elsewhere, mast cells are present in greater number in chronic than in acute inflammation. It is probable that in acute inflammation the mast cells are disrupted because they are greatly diminished or completely absent and the few residual cells show vacuolation and a paucity of granules.²¹ A definite increase in mast cells occurs in chronic, prolonged infections which have produced thickened mucosa but here the tinctorial character of the granules is that of the normal.

During active nasal allergy, there is degranulation with the release of histamine and the mast cell population is decreased drastically so that the cells may disappear completely even in the deep sub-mucosal layer. As the mast cells diminish, the eosinophiles increase in number, presumably attracted by the released histamine which they then proceed to either alter or destroy. Where edema is most marked, few or no mast cells are found but eosinophiles are numerous. As the antigen-antibody reaction subsides, mast cells reappear and eosinophiles become less numerous. The reappearing mast cells are at first small round cells which become normal in size and structure as the edema subsides.

Mast cells are sparse or absent in mucous nasal polyps. A small number may remain in the deeper tissue near the attachment of the polyp or in areas free of edema. Here no eosinophiles appear, their greatest concentration being where histamine is present and the intercellular fluid is increased. Berdal and Olhagen⁶ have shown that high gamma globulin values occur in polyp fluid and that plasma cells appear in large numbers where there is an increase of gamma globulins in the polyp fluid. However, they were unable to find a correlation between the number of eosinophiles present and the increase of gamma globulins in the polyp fluid. Wherever an appreciable quantity of histamine can be demonstrated, no undamaged mast cells are found because the mast cells in that area have become degranulated with the liberation of histamine.

Juhlin and Shelley²⁴ were the first to report the degranulation of mast cells in the cold urticaria reaction and, using a new *in vitro* technique, demonstrated the specific degranulation of basophils in cold urticaria patients when chilled. In this auto-immune state, the individual reacts to his own tissue upon cooling and although the urticaria is usually confined to the areas exposed to cold, in severe sensitivity there may be generalized urticaria and other signs of massive histamine release. They recognize three main classes of diverse, temperature-dependent, auto-immune reactions. The first group has hive formation in the cold as its primary manifestation with urticaria reflecting histamine release; the second group of cold hypersensitivity reactions results from the presence of cold agglutinins and hemolysins; and the third group of reactions follows abnormal amounts of a globulin (cryoglobulin) in the blood stream. In this report they refer exclusively to the problem of the first group of cold reactors, those with cold urticaria and its associated systemic signs (cold anaphylaxis),

and define cold urticaria as a syndrome of urticaria and other histamine release phenomena regularly occurring as a result of local or general cold exposure, and emphasize the absence in the serum of cold hemolysins, cold agglutinins and cryoglobulins. Two types of essential or idiopathic cold urticaria are described. The rarer form is congenital or familial, is inherited as a dominant trait and the sensitivity cannot be passively transferred. The usual type is the acquired type and may appear suddenly at any time of life. This is the commonest of the hypersensitivity reactions due to cold and there is no absolute temperature at which it develops, relative temperature change being more important.²⁶ The clinical manifestations are precipitated by histamine but the histamine liberator has not been identified. It is probable that exposure to cold affects a circulating substance in the blood which is so altered that it stimulates histamine release. This humoral substance can be passively transferred to a normal individual who will have cold urticaria at the prepared site.^{24,26} When cold urticaria is produced in an extremity, systemic symptoms do not develop when the venous return from the exposed site is obstructed with a tourniquet indicating that histamine is liberated locally and carried by the blood to other areas.

The occasional appearance of inordinate nasal occlusion with sneezing and rhinorrhea after general cooling of the body, or the mere inhalation of air at very low temperature, suggested that these symptoms might be manifestations of the cold hypersensitive state. Two patients with such symptoms volunteered as subjects for a study which entailed the removal of three biopsy specimens from an inferior turbinate prior to exposure to low temperatures and three biopsy specimens following exposure. Neither topical application nor injection of anesthetic agents were used. Punch specimens of tissue were obtained with surprisingly little discomfort to the patients when taken with rapidity and precision.

REPORT OF CASES

CASE 1. A white male, 31 years of age, was employed as a butcher. His occupation required frequent changes from a room temperature of 68 to 74 degrees F. to temperatures of 34 to 38 degrees F. in a refrigerating chamber. Exposure to the low temperatures varied from a few minutes to as long as one half hour. Nasal obstruction, rhinorrhea and occasional sneezing appeared within 15 to 20 minutes after the first prolonged exposure of the day and continued during working hours. Three to four hours after leaving his place

of employment, the nasal symptoms had largely disappeared. No symptoms were experienced during holidays but promptly reappeared on the first working day. There was no personal history of bronchial asthma, eczema or urticaria and the family history was negative for allergy and cold hypersensitivity. A complete physical examination disclosed no abnormalities other than moderate pallor of the nasal mucosa and roentgenologic evidence of slight mucous membrane thickening in the frontal, maxillary and ethmoidal sinuses. Three differential blood counts fixed the eosinophile content at 1 per cent. Other blood studies gave normal values and cold hemolysins, cold agglutinins and cryoglobulin were absent.

At the end of two weeks of vacation his symptoms had vanished and at this time three biopsy specimens were removed from one inferior turbinate. The tissue sections prepared from these provided information concerning the number, distribution and character of the mast cells in the quiescent turbinate. After entering and remaining in a cold chamber with a temperature of 34 degrees F., for 35 minutes there was profuse rhinorrhea and complete nasal obstruction. Upon his return to room temperature (73 degrees F.), biopsy specimens were obtained from the same turbinate after 30 minutes, 8 hours and 24 hours.

CASE 2. A white male, 21 years of age, had lived in Florida until entering a college in New England. Here, at the onset of cold weather and especially when the outdoor temperature fell to 45 degrees F. or lower, he experienced continuous nasal obstruction, rhinorrhea and intermittent sneezing. The symptoms diminished only slightly when he remained indoors at temperatures of 70 degrees F. or above. There was no history of bronchial asthma, hives or eczema, and the family history was negative for allergy and familial cold hypersensitivity. A general physical examination found no significant abnormalities and the paranasal sinuses appeared normal by roentgen examination. Blood studies were essentially normal and the differential blood count was reported to contain 2 per cent of eosinophiles. His serum contained no cold agglutinins, cold hemolysins or cryoglobulin.

Skin tests for foods, inhalants and a few pollens were negative. When the nasal secretions were exceptionally profuse, stained smears revealed a few eosinophiles but no mast cells and only a rare micro-organism. Cultures of the secretions contained neither pathogens nor molds.

Three biopsy specimens were obtained from an inferior turbinate during a summer vacation when the patient was entirely free of symptoms and the outdoor temperature ranged from 68 to 82 degrees F. After exposure in a cold chamber at a temperature of 34 degrees F. for 35 minutes, he was returned to a room temperature of 74 degrees F. Biopsy specimens were taken from the same turbinate 30 minutes, 8 hours and 24 hours later.

In each patient, the tissue obtained prior to cold exposure contained mast cells which were normal in morphology and staining reaction but situated at some distance from the epithelium.

Tissue obtained from the first patient 30 minutes after exposure to cold was terminated showed marked degranulation of mast cells and a profusion of extracellular granules but no increase in eosinophiles; tissue obtained after 8 hours contained only shadow cells, largely devoid of granules, and an increase in the number of eosinophiles particularly near the epithelium; the tissue obtained after 24 hours contained extremely few eosinophiles even in the superficial layers but small round cells which stained metachromatically were present in the deep submucosal layer.

In the second patient, the tissue examined 30 minutes after cessation of exposure to 34 degrees F. for 35 minutes, contained no intact mast cells but many shadowy forms with the faint residual metachromatic staining described by Uhlin and Shelley. There was a profusion of extracellular granules and a moderate increase of eosinophiles which were disposed near the epithelium. The tissue obtained 8 hours after exposure to cold failed to show the presence of mast cells and there were more eosinophiles in the middle submucosal layer. Twenty-four hours after exposure to cold had been terminated, the tissue contained very few eosinophiles but small atypical cells which stained metachromatically could be detected in the deep submucosal layer.

It was expected that a positive passive transfer test would be obtained with the serum of each patient. Using the technique of Uhlin and Shelley, three presumably normal individuals received an intradermal injection of 0.1 cc of serum from the first patient and three other normal individuals received a similar intradermal injection of serum from the second patient. In each instance, the contact of an ice cube with the injection site on the forearm for ten minutes failed to produce an urticarial wheal.

CONCLUSION

Evidence that mast cell degranulation and tissue alterations associated with histamine release occur in turbinal tissue as a result of exposure to cold was obtained in a study of two cold hypersensitive patients. It is anticipated that similar circumstances may produce corresponding tissue changes in other portions of the upper respiratory tract but as yet the supporting evidence for this assumption is lacking.

326 S. 19TH ST.

REFERENCES

1. Ackerman, G. A.: Cytochemical Properties of the Blood Basophilic Granulocyte. *J. Histochem. Cytochem.* 9:534-541, 1961.
2. Amann, R., and Martin, H.: Blutmastzellen und Heparin. *Acta Haematol.* 25:209-215, 1961.
3. Becker, R. M.: Paroxysmal Cold Hemoglobinurias. *Arch. Intern. Med.* 81: 630-648 (May) 1948.
4. Behrens, M., and Taubert, H.: Der Nachweis von Heparin in den Basophilen Leukocyten. *Klin. Wochschr.* 30:76-81, 1952.
5. Benditt, E. P.: Morphology, Chemistry and Function of Mast Cells. *Ann. N. Y. Acad. Sci.* 72:204-219, 1958.
6. Berdal, P., and Olhagen, B.: Proc. 5th International Congress of Otorhinolaryngology, Amsterdam, 1953, pp. 181-187.
7. Bloom, G. D.: Electron Microscopy of Neoplastic Mast Cells: A Study of the Mouse Mastocytoma Mast Cell. *Ann. N. Y. Acad. Sci.* 103:53-83, 1963.
8. Braunsteiner, K.: Mast Cells and Basophil Leukocytes. In the Physiology and Pathology of Leukocytes, pp. 46-62, . Braunsteiner and D. Zucker-Franklin, Ed. Grune & Stratton, New York, N. Y., 1962.
9. Bryan, W. T. K., and Bryan, M. P.: Cytologic Diagnosis in Otolaryngology. *Trans. Am. Acad. Ophthal. and Otolaryng.* 63:597-612 (Sept.-Oct.) 1959.
10. Cazal, P.: Mastocytes, Mastocytoses, Histamine et Héparin. *Bull. Soc. Sci. Med. Biol., Montpellier, France,* 21:152-161, 1942.
11. Ehrlich, P.: Beiträge zur Kenntniss der Anilinfärbungen und ihrer Verwendung in der mikroskopischen Technik. *Arch. Mikroskop. Anat.* 13:263-270, 1877.
12. Ehrlich, P.: Beiträge zur Kenntnis der granulierten Bindegewebszellen und der eosinophilen Leukocyten. *Arch. Anatom. Physiol., Leipzig,* 3:166-169, 1879.
13. Ehrlich, P.: Über die spezifischen Granulationen des Blutes. *Arch. f. Anat. u. Physiol., Phys. Abt.,* p. 571, 1879.
13. Ehrlich, P.: Methodologische Beiträge zur Physiologie und Pathologie der verschiedenen Formen der Leukocyten. *Ztschr. f. klin. Med.* 1:553-559, 1880.
15. Ehrlich, P.: Farbenanalytische Untersuchungen zur Histologie und Klinik des Blutes. Hirschwald, Berlin, Germany, 1891.

16. Ehrlich, P.: Contributions to Theory and Practice of Histological Staining (Inaugural Dissertation, University of Leipzig, 1878) in Collected Papers of Paul Ehrlich, edited by F. Himmelweit and M. Marquardt, Pergamon Press, London, 1:65-98, 1956.
17. Farmer, R. G., Cooper, T., and Pascuzzi, C. A.: Cryoglobulinemia. *Arch. Intern. Med.* 106:483-495 (Oct.) 1960.
18. Fisher, E. R.: Tissue Mast Cells. *J.A.M.A.* 173:171-173 (May 14) 1960.
19. Hibbs, R. G., Phillips, J. H., and Burch, G. E.: Electron Microscopy of Human Tissue Mast Cells. *J.A.M.A.* 174:508-510 (Oct. 1) 1960.
20. Hissard, R. L., Moncourier, M., and Jacquet, J.: Une nouvelle affection hematodermique, la mastocytose. *Compt. Rend. Acad. Sci.* 23:253-255, 1950.
21. Hlaváček, V., and Lojda, Z.: Mast Cells in the Mucous Membrane of the Upper Respiratory Tract during Normal and Pathological States. *Acta Oto-Laryngologica* 56:182-188 (Mar.-Apr.) 1963.
22. Holmgren, H., and Wilander, O.: Beitrag zur Kenntnis der Chemie und Funktion der Ehrlichschen Mastzellen. *Z. Kellforsch. Mikroskop. Anat.* 42:242-278, 1937.
23. Horton, B. T., Brown, G. E., and Roth, G. M.: Hypersensitiveness to Cold, with Local and Systemic Manifestations of Histamine-Like Character; Its Amenability to Treatment. *J.A.M.A.* 107:1263-1269 (Oct. 17) 1936.
24. Juhlin, L., and Shelley, W. B.: Role of Mast Cell and Basophil in Cold Urticaria with Associated Systemic Reactions. *J.A.M.A.* 177:371-377 (Aug. 12) 1961.
26. Kingery, F. A. J.: Cold Urticaria. *J.A.M.A.* 192:107-108 (Apr. 12) 1965.
27. Lagunoff, D., Phillips, M., and Benditt, E. P.: The Histochemical Demonstration of Histamine in Mast Cells. *J. Histochem. Cytochem.* 9:534-539, 1961.
28. Palva, T., and Palva, A.: Allergic Changes in the Mucosa of the Upper Respiratory Tract. *Pract. Otorhinolaryng., Basel*, 24:1-20, 1962.
29. Palva, T.: Discussion of Hlavacek and Lojda.²¹
30. Martin, H., and Roka, L.: Zur Frage des Heparin-Gehaltes der Blutmastzellen des Menschen. *Acta Haematol.* 10:26-31, 1953.
31. Mota, I.: Mast Cells and Anaphylaxis. *Ann. N. Y. Acad. Sci.* 103:264-277, 1963.
32. Padawer, J.: Studies on Mammalian Mast Cells. *Trans. N. Y. Acad. Sci.* 19:690-713, 1957.
33. Palva, T., and Palva, A.: Allergic Changes in the Mucosa of the Upper Respiratory Tract. *Pract. Otorhinolaryng., Basel*, 24:1-9, 1962.
34. Rawlins, A. G.: Observations on Collagen Disorders of the Upper Respiratory Tract. *ANNALS OF OTOTOLOGY, RHINOLOGY AND LARYNGOLOGY* 66:706-709 (Sept.) 1957.
35. Riley, J. F.: Histamine in Tissue Mast Cells. *Science* 118:332, 1953.
36. Riley, J. F., and West, G. B.: The Presence of Histamine in Tissue Mast Cells. *J. Physiol.* 120:528-537, 1953.

37. Riley, J. F.: The Location of Histamine in the Body. In *Ciba Symposium on Histamine*, pp. 398-403. G. E. W. Wolstenholme and C. M. O'Connor, Eds. Little, Brown and Co., Boston, 1956.
38. Riley, J. F.: Mast Cells. Williams and Wilkens Company, Baltimore, 1959.
39. Riley, J. F.: Histamine and Heparin in Mast Cells. *Lancet* 2:40-46 (July 7) 1962.
40. Salvato, G.: Studio istomorphologico e istochemico della mucosa bronchiale nell'asma. *Minerva Med.* 49:2868-2877, 1958.
41. Schenck, H. P.: The Plasma Cell Theory of Antibody Formation: Its Importance in the Interpretation of the Physiology of the Lymphoid Structures of Waldeyer's Ring. *ANNALS OF OTOTOLOGY, RHINOLOGY AND LARYNGOLOGY* 64:109-118 (Mar.) 1955.
42. Smith, D. E., and Lewis, Y. S.: Electron Microscopy of the Tissue Mast Cell. *J. Biophys. and Biochem. Cytol.* 3:9-14 (Jan. 25) 1957.
43. Smith, D. E.: Electron Microscopy of Normal Mast Cells under Various Experimental Conditions. *Ann. N. Y. Acad. Sci.* 103:40-52, 1963.
44. Stats, D., and Wasserman, L. R.: Cold Hemagglutination—Interpretive Review. *Medicine (Baltimore)* 22:363-424 (Dec.) 1943.
45. Weisskopf, A., and Burn, H. F.: The Ground Substance of the Nasal Turbinates. *ANNALS OF OTOTOLOGY, RHINOLOGY AND LARYNGOLOGY* 67:292-304 (June) 1958.
46. West, G. B.: Histamine and Mast Cells. In *Ciba Symposium on Histamine*, pp. 14-19. G. E. W. Wolstenholme and C. M. O'Connor, Eds. Little, Brown and Company, Boston, 1956.
47. Winqvist, G.: Electron Microscopy of the Basophilic Granulocyte. *Ann. N. Y. Acad. Sci.* 103:352-374, 1963.

DISCUSSION

DR. HERBERT H. HARRIS: Several years ago I embarked on a little study of mast cells and I just wanted to substantiate some of his findings. I never published this because I felt that I had not worked it out thoroughly enough from a research basis, but we did take tissue from a normal middle turbinate and examine this for mast cells and we found, using Lillie's stain to bring out the granules, that there were approximately two mast cells per low power field.

Seventeen allergic patients, with allergic polypi, were examined and it was rare to find a mast cell in any of the tissues. My conclusions were that, number one, there was a great deal of edematous tissue in the polyps and often not many inflammatory cells. Were mast cells supposed to be present? Had these mast cells exploded, liberating the granules which I felt might in some way be a protective mechanism to prevent allergy? Number two, were these cells lacking in the individual who was allergic or were they being exploded so fast that they could not be manufactured in enough numbers to maintain the physiological state of the ground substance?

DR. DAVID A. DOLOWITZ: It was a great privilege to hear Doctor Schenck's paper on the mast cell. I had not intended to speak but I think there is one thing that has been missing from our discussion today and that is the importance of the mast cell in the concept of nasal physiology.

Since medical school I have remembered Lewis's work that when histamine was released it produced calor, dolor, rugor, and turgor. This made a tremendous impression on me and I have been trying to find a chemotaxic approach because it seemed that anatomically and physiologically we are at a stage where such an approach could be used to explain the details of inflammation and allergy.

The mast cell is not an interesting cell only because it picks up granules. Incidentally it was named "mast cell" by Ehrlich because he said it was like a well stuffed pig that went out into the connective tissue forest and picked up the equivalent of mast, or acorns. The mast cells pick up debris and form granules. The material that is picked up is a mixture of histamine and heparin. There are various forms of inflammation: one from the histamine group, which includes serotonin; one from the catechol amines, which we are just beginning to study and which will probably have an entirely different mechanism.

The mast cell is originally a fibroblast that picks up a mixture of the histamine and the heparin. Histamine is an alkaline substance, and heparin is an acidic substance; together they form a salt, the metachromatic granule. You can actually trace fibroblasts turning into mast cells if you watch them under a phase microscope for long periods.

One of the other things about the mast cell which is so intensely interesting is that if we will take a given amount of tissue in any one child we will find that in a given tissue there is, to use representative figures, 600 milligrams of heparin per gram of tissue and a hundred grams of histamine. When this same child reaches twenty, there will be a drop in the heparin, and an increase in the histamine. When he reaches his fifties and sixties the amounts are almost reversed. There will be a small amount of heparin and a tremendous amount of histamine. Perhaps we are aging because we can no longer neutralize inflammation as easily.

The question of the effect of cold was raised by Doctor Schenck: we have been able to show that stimuli from cold, heat, bacteria, plasma from other animals from the same litter, or from other animals all cause anaphylaxis. If we use a litter mate we find we get a very gentle reaction; if we use other animals, we get a very severe anaphylaxis; but when any stimulus is employed an immediate degranulation occurs the severity depending on what we are using as our exciting agent.

Histamine is a very small molecule and moves rapidly through the connective tissue and gets into the blood stream and causes reactions over the entire body. Heparin is a very large molecule and remains only in the neighborhood of the cells that have degranulated and neutralizes the histamine there. As it neutralizes the histamine the fibroblasts pick it up and it turns into new mast cells.

Doctor Schenck mentioned the fact that eosinophils come into the field after histamine release. When histamine damage has ruptured cells, our theory, given to us by Dr. Eyring, a physical chemist, and Doctor Dougherty in Anatomy, is that the histamine chelates sodium and potassium from connective tissue into the cell, causing the cell to swell because of the entrance of water, until it finally breaks. Once the cell membrane is broken its histamine is again literally setting up a chain-reaction by attacking another cell. One of the mechanisms of protecting the cells against this chain reaction is the local neutralization of histamine by heparin. Doctor Tom Dougherty showed that another method of protection occurs as corticosteroids toughen the cell membrane so that histamine and water are not able to penetrate the cell membrane.

The eosinophil comes to the area when the cell membranes are broken. Scavenger cells, the macrophages, are not able to pick up all the debris. The remnants are chiefly nuclei. A nucleus does not come apart until the eosinophils form a contact with it. While the contact lasts one can see the lysozymes going about in a circle almost as a bucket brigade. The eosinophil then wanders off. While it would seem nothing has happened, yet when a macrophage now comes in contact with the nuclear membrane it falls apart and the macrophages can engulf the nucleus.

I feel we are going into details now. The thing that I would like to stress is that there is a chemotactic control of the activity of connective tissue cells. Understanding of such control will be very valuable in giving us a concept of how the cells are working, how the nose is working and perhaps enable us to explain and later control inflammation and allergies.

DR. SCHENCK (closing): I appreciate Dr. Harris's remarks, because he was one of the early otolaryngologists who showed an interest in the mast cell.

I especially appreciated Dr. Dolowitz's remarks because he has had tremendous experience. He has some admirable motion pictures showing the activity of cells and he elaborated on some of the material which, of course, we cut out in a short discussion.

I would like to echo his opinion that the mast cell is important in many areas. For instance, in blood lipemia, where a patient has been fed large amounts of butter, degranulation of mast cells appears to occur probably because heparin is physiologically important in the clearing of the blood serum, and hence of importance in the clearing reaction.

(Slide) This is some of Shelley's work on blood lipemia. The cell on the left is, of course, a normal cell and the other two are cells that have undergone changes due to degranulation.

I also want to pay tribute to Dr. Rawlins, because soon after collagen diseases were recognized Dr. Rawlins did a good bit of investigation on mast cells because mast cells were found to play an important role in collagen diseases and I think it is well worth rereading his work.

I don't believe that the two cases that are reported here are especially significant until this work is repeated a number of times, but under the conditions of the experiment it was very difficult, as you may imagine, to obtain volunteers for this harrowing experience.

TEFLON INJECTION IN THE CORRECTION OF VELOPHARYNGEAL INSUFFICIENCY

ROBERT LEWY, M.D.

RICHARD COLE, PH.D. JOSEPH WEPMAN, PH.D.
(by invitation) (by invitation)

CHICAGO, ILL.

A considerable amount of experimental and clinical data has appeared in the literature dealing with the implantation of various materials in the nasopharynx and other areas of the body. The history of such procedures is long. Substances such as ivory, bone, fat tissue, acrylic and many others have been used in the field of otolaryngology for many years. The use of many or most of these substances was discontinued for a number of reasons. Complications such as foreign body reaction, both early and late, leaching, migration, dispersion, and rejection occurred all too frequently.

Of special historical interest is the use of paraffin which, though now obsolete, started the series of successful experiments which led to its use in human tissue. Brunings,¹ in spite of the clear objection of Killian,¹ used paraffin and established a technique of vocal cord injection. Both the use of the material and the injection technique disappeared largely from view until Arnold,² using tantalum, revived the injection technique. Not long after, both Arnold and Lewy³ began using Teflon[®] for the same purpose. The results of this recent work are well known to otolaryngologists and speech therapists. During this period, Goff,⁵ Ruedi, Waltner,⁶ Meurman and others have been pursuing the injection technique using bone dust, cartilage, acrylic and other substances.

Ward and Wepman,⁷ learning of the Teflon injection technique, employed both Teflon and tantalum as implantation substances in the posterior nasopharynx of experimental animals. The substances appeared to be well tolerated. Because of the large measure of success

with the Teflon injection of human vocal cords and the Teflon injection of the nasopharynx in experimental animals, it was decided to apply the technique to the posterior pharyngeal wall in humans.

The idea of building up the posterior wall of the nasopharynx is not new. Various substances and various methodologies have been used to do this in the past with some varying degree of success and failure. The patient with velopharyngeal insufficiency may benefit from any one of several techniques. Pharyngeal flap surgery has become increasingly popular in such cases and prosthetic speech appliances have been used with such cases for years. Blocksma's⁹ work with the implantation of silicones appeared to have been quite successful. Blocksma himself, however, introduced a note of caution about his own work since some of the implants migrated and some created enough tissue reaction to bring about the rejection of the implant.

The present work evolves, therefore, from the relatively successful application of implantation technique in the posterior pharyngeal wall of humans and from the Teflon injection techniques in the vocal cords of humans and the posterior pharyngeal wall of experimental animals. The essence of the technique is the delivery, through a needle, of a particulate suspension of a reasonably nonreactive substance into the tissue of the posterior pharyngeal wall. It has been argued that the amount of animal research has been insufficient to warrant the application of this technique to humans. It is the feeling of the authors, however, that the work of Arnold² and of Ward and Wepman⁷ on animals has established an adequate background for this technique in humans. In addition, one must consider the total of thousands of implants in the vascular system, the middle ear, and the vocal cord. It must be stated that there can never be an absolute extrapolation from the results of animal research to humans.

The invention of Teflon came as a product of the Manhattan Project of the Atomic Energy Commission. It was found to be an extremely nonreactive substance and was used, therefore, as a gasket material in machinery handling radioactive materials. Teflon has realized great commercial success because of its use as a lining for frying pans. Such utensils need no grease or butter for cooking since the Teflon will not react with the food being cooked even at high temperature.

Teflon is a large polymer molecule of $(C_2F_4)_n$. It is prepared in a sterile state and is suspended in glycerine. The individual gran-

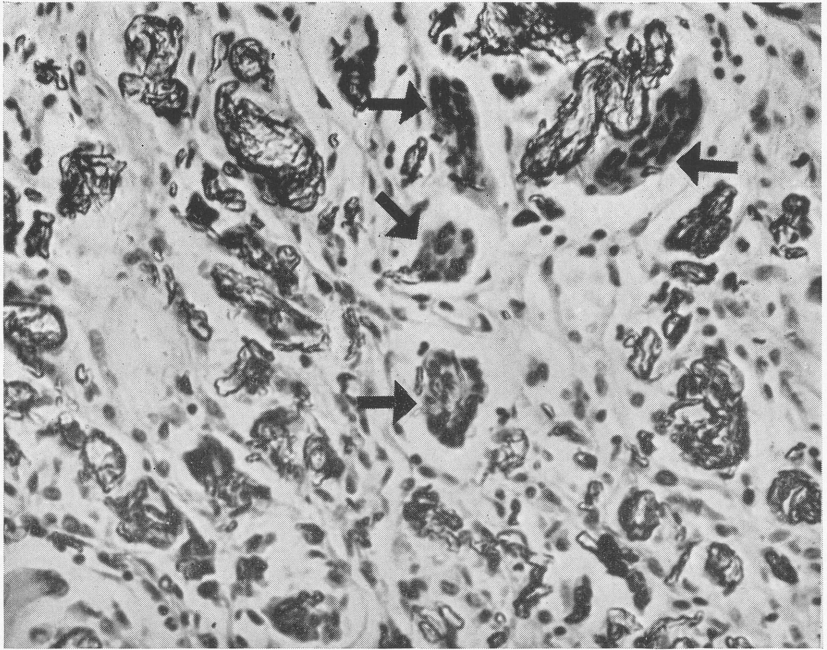


Fig. 1.—Teflon granules in tissue. Giant cells indicated. Refractile substance is Teflon granules. (High power)

ules of Teflon are fabricated at between 50 and 100 micra in diameter. The particle size is deliberately larger than the lymphatic channels and unless placed in the area of a fascial plane or a moving part, this size factor prevents drift of the material. Clinical experience of several years' duration indicates no drift, especially in the vocal cord situation. This is remarkable in view of the vibration of the vocal cords.

The reactivity of Teflon to body tissues has been studied in animal and in man. In the vocal cords, a mild inflammatory reaction results but subsides promptly and the cords appear normal within a matter of days. Histopathological studies of these cords show a localized mild foreign body response with a few giant cells and some lymphocytic infiltration. This infiltration remains close to the granules. Leaching and extrusion appear not to have occurred. With respect to reaction, Teflon has been used thousands of times in the

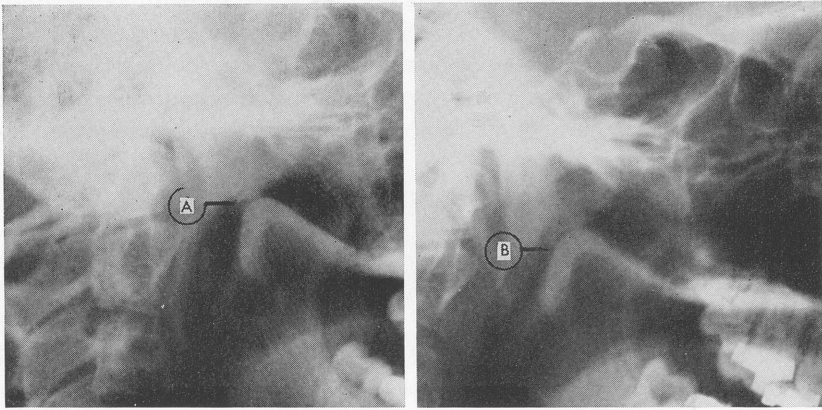


Fig. 2.—A. Velopalatine gap. B. Teflon in position. Velopalatine gap closed.

middle ear as an artificial vascular graft and to date, neoplastic responses to the implants have not occurred. The experimental work of Hilger et al.⁸ indicates that the particulate from a substance is not cancerogenic.

Glycerine, as the vehicle for the Teflon particles, has long been used in this capacity. It has been used for years as a vehicle for allergens with no history of extensive or long-term reactions. Glycerine is a normal body metabolite. The independent injection of glycerine⁸ in humans indicates that it is absorbed in approximately five days and causes a very limited local reaction.

This technique of injecting Teflon into the posterior pharyngeal wall in cases with velopharyngeal insufficiency is particularly desirable because of its simplicity. However, there are decided limitations, and these should be discussed. Velopharyngeal insufficiency may result from any one or a combination of factors and generally results in one or a combination of symptoms. The most common causes of the problem are congenitally short velum, unoperated cleft velum, post-operative cleft but short velum and partial or complete paralysis of the palatal and pharyngeal muscles or both.

It has long been recognized that even minimal incompetence of the velopharyngeal valve may result in a considerable degree of hypernasality and nasal air escape. It seems likely that the present

technique will be of limited value in cases where the velopharyngeal aperture is wide or where there is a near total paralysis of the velum. On the other hand, this technique may provide a valuable secondary procedure in cases where previous surgical attempts have failed to provide a competent velopharyngeal valving mechanism or where the velum is capable of considerable movement even though inadequate in length.

REPORT OF A CASE

The patient (L.B.), the first to our knowledge, injected by this technique, was a fifteen year old white female who entered the hospital with the history of an inability to phonate properly since the age of one year. At that time, she is said to have suffered a high fever and a condition that was diagnosed as acute poliomyelitis. Since that time, attempts to phonate resulted in hypernasal speech and nasal air escape.

Physical examination at the time of admission revealed a well developed and well nourished white female in apparent good health. The only abnormal physical finding was a limitation of motion of the soft palate. X-ray studies of the palate during phonation demonstrated incomplete closure of the velopharyngeal space. A tape recording and spectrographic analysis of her speech confirmed the general impression of hypernasality.

Under general anesthesia the soft palate was retracted forward and 3 to 5 cc of a Teflon and glycerine mixture injected along the area of Passavant's line. X-ray studies (Fig. 2) following the injection indicated the presence of the Teflon along this area and the closure of the velopharyngeal valve. Tape recordings and spectrographic records were again taken and confirmed the subjective impression of marked improvement in voice quality.

Subsequent history shows a dramatic improvement in the quality of the voice 24 hours after surgery. Speech therapy pre-operatively had met with limited success. Postoperative speech therapy has resulted in a steady improvement in voice quality and in articulatory patterns.

COMMENTS

A case is reported in which the velopharyngeal space is reduced by the injection of a Teflon glycerine mixture along Passavant's line. This treatment effectively eliminated nasal emission of air and hyper-

nasality in a situation in which there was limitation of soft palate movement due to paralysis. The postoperative course has shown steady improvement. Since Teflon is used in the particulate form and is larger than the lymphatics, it is presumed that it will remain in situ. Thus far it has. This fact, plus its ease of application, makes it highly desirable for this purpose.

It is recognized that this is only a starting point and that large spaces cannot be effectively reduced in this manner. However, the ease of application, the non-leaching, non-slipping, and the limited reactivity all suggest that this substance, in this form, is most probably the best substance to date for the purpose. It is hoped that this experience plus the repeated and considerable experience with particulate Teflon in the vocal cords will represent a springboard for further endeavor along similar lines.

25 EAST WASHINGTON ST.

REFERENCES

1. Brunings, W.: *Über eine neue Behandlungsmethode der Rekurrenslähmung* Verhandl. Ver. Deutsch. Laryn. 18:93:525, 1911.
2. Arnold, G.: Vocal Rehabilitation of Paralytic Dysphonia. *Arch. Otol.* 76:4:358 (Oct.) 1962.
3. Lewy, R. B.: Glottic Reformation with Voice Rehabilitation in Vocal Cord Paralysis. *Laryngoscope* 73:5:547-555 (May) 1963.
4. Lewy, R. B.: Glottic Rehabilitation with Teflon Injection—the Return of Voice, Cough and Laughter. *Acta Oto-Laryngologica* 58:214-220, 1964.
5. Goff, W.: Laryngeal Abductor Paralysis Treated by Vocal Cord Injection of Bone Paste. *Trans. Pacific Coast, Oto-Ophthal. Soc.*, 1960.
6. Waltner, J. G.: Surgical Rehabilitation of Voice Following Laryngofissure. *Arch. Otolaryngol.* 67:99, 1958.
7. Ward, P. H., Wepman, J. M.: Pharyngeal Implants for Reduction of Air Space in Velopharyngeal Insufficiency. *ANNALS OF OTOTOLOGY, RHINOLOGY AND LARYNGOLOGY* 73:2:443 (June) 1964.
8. Hohman, A., Hilger, J. A., Carley, R.: Fate of Implants in Rats. *ANNALS OF OTOTOLOGY, RHINOLOGY AND LARYNGOLOGY* 73:3:791 (Sept.) 1964.
9. Blocksma, R.: Correction of Velopharyngeal Insufficiency by Silastic Pharyngeal Implant. *Plast. and Reconstruct. Surg.* 31:268-274.

DISCUSSION

DR. FAABORG-ANDERSEN: As consultant at the Royal Danish Institute of Speech Disorders in Copenhagen, I have seen a lot of patients with a bad velopharyngeal closure. These patients can be divided into two main groups: patients unsuccessfully operated upon for cleft palate and patients with a paralyzed velum.

Their main complaints are highly nasal phonation and fluid coming through the nose when they are drinking.

One way of solving the problem is to give the patient an obturator, an artificial velum, but in many cases the improvement does not fully make up for the disadvantages of the prosthesis.

For many years we have used the pharyngeal flap procedure, a plastic operation which I suppose you all know. A flap from the posterior pharyngeal wall is connected with a flap from the soft palate, making a good velo-pharyngeal closure.

This operation gives considerable improvement in speech in most cases, but it is my experience that this operation does not help if there are drinking difficulties.

In this case I should like very much to try Teflon injection of the posterior pharyngeal wall. I have not tried it yet because it is impossible to get usable Teflon in Denmark, but perhaps you can tell me where I can buy this?

May I finally ask a question? I have seen patients with a very incomplete velo-pharyngeal closure but with normal phonation, not nasal. On the other hand, I have seen patients with highly nasal phonation but a fairly good velo-pharyngeal closure. Can you explain this for me, or can anybody here explain this?

DR. ARTHUR J. CRACOVANER: I would like to ask Dr. Lewy just how he determines the site of the injection.

DR. MONTGOMERY: Drs. Herbert Silverstein, Peter Van Orman and I have used liquid silastic, which immediately prior to injection, has been treated with a catalyst for vulcanization within ten minutes. Silastic has been used rather than teflon for improving velo-pharyngeal insufficiency because of the lack of tissue reaction around this substance. As a laboratory test we injected both liquid silastic and teflon paste subcutaneously into the cat's abdomen. After a period of two months there was no reaction in the tissues surrounding the silastic. There was, however, considerable reaction in the tissue surrounding the teflon paste; this included round cell infiltration, fibroblastic activity, and an exudate collection in one area.

Dr. Ralph Blocksma of Grand Rapids, Michigan has reported good results in a substantial series of velo-pharyngeal insufficiency using injectible silastic. Our series is limited to 6 cases. Three of these cases resulted in good improvement. The other three had only slight improvement in speech. These latter three cases may be offered further improvement by speech therapy.

The most dramatic result was a 14 year old girl who sounded exactly as Dr. Lewy's patient. She had never been able to inflate a balloon. Six cc of liquid silastic was injected into the posterior epipharyngeal wall at the level of Passavant's ridge, under local anesthesia. Before leaving the office she was able to inflate a balloon. Her speech was normal and has been since.

Our cases have been studied pre-operatively and postoperatively with cineradiography using barium as a contrast medium. Our only real contribution to this effort has been offered by Dr. M. S. Potsaid (radiologist at Massachusetts General Hospital) who has discovered that the insufficiency can be much more readily demonstrated and studied if the cineradiography is carried out with the patient in the supine position.

DR. LEWY (closing): I want to thank my discussers very much. This discussion, of course, highlights the paper, bringing out both the good and the bad, and the limitations of the method.

In a series of over sixty cases of injection into human tissue of Teflon all cases, even those who had an immediate reaction and including two cases which actually had to have a tracheotomy because of the local edema which occurred when we were doing this for vocal cord work, all reaction subsided and the Teflon stayed in place, in residence, where we put it; we felt that the degree of reaction, therefore, of the Teflon in the amounts in which we used it was quite tolerable. I have never used an amount up to 6 cc and it may be that we can tolerate up to 6 cc, I don't know.

Dr. Montgomery points to three successes and three failures. He refers to Blocksma's work. Blocksma pointed out his successes and also the limitations of his work.

To Dr. Cracovaner's question, how is the site determined? It is an anatomical area known as Passavant's line. We take a Jackson or a Love retractor, or we sometimes take a Hasslinger retractor—in an adult you can do it under local and in a child probably best under general—pull the soft palate forward and try to see where we get the closest approximation of the soft palate to the posterior pharyngeal wall—this is where Passavant's line is located—and then we infiltrate along that line.

I cannot answer, of course, Dr. Faaborg-Andersen's question and I am sure that this answer to his question comes to him as no surprise. How to get Teflon? Actually, Teflon is probably somewhat more easily available abroad through the Ethicon Corporation than it is in the United States of America because under the existing law, Teflon is not yet released except to accredited investigators. It is still under the control of the Federal drug authority. I made an appearance before them last year. There is some hope that within the next year that the large accumulation of human experimentation will subsequently lead them to believe that we don't have to experiment on dogs for twenty years and then extrapolate from dogs to humans. There is very real hope that Teflon will be available to all qualified laryngologists and plastic surgeons within a year's time; a letter to the Ethicon people in Somerville, New Jersey, will probably solve the problem for anybody who is on a university faculty and has done research and who is therefore somebody that can be trusted with the material not to misinterpret its use.

NERVE GRAFTING TO RESTORE FUNCTION OF THE TRAPEZIUS MUSCLE AFTER RADICAL NECK DISSECTION

(A PRELIMINARY REPORT)

HERBERT H. HARRIS, M.D.

J. R. DICKEY, M.D.
(by invitation)

HOUSTON, TEX.

Following many surgical procedures there is some alteration of normal physiology. In most instances, however, normal physiology is re-established and the patient usually recovers with few if any residual symptoms. A radical neck dissection does not produce marked disturbance in physiology unless it is combined with a more formidable procedure such as a laryngectomy, a partial mandibulectomy and glossectomy, or a maxillectomy.

In our experience the most significant alteration of function following radical neck dissection has been the loss of shoulder function due to section of the accessory nerve and denervation of the trapezius muscle. This altered function of the shoulder is certainly minimal considering the disease for which the radical neck dissection is usually done. However, this should not preclude improvement of technique to minimize postoperative shoulder symptoms. Two solutions to the problem of preservation of trapezius function seem obvious. One would be preservation of the spinal accessory nerve during the procedure. Preservation of this nerve carries with it some risk, as it traverses a portion of the en bloc dissection and involved nodes may lie close to the nerve in this area. This modality was abandoned by us several years ago as a compromising procedure even in individuals

From the Department of Otolaryngology, Baylor University College of Medicine, Houston, Texas.

where no positive nodes were felt and the surgery was done for possible subclinical metastases.

The solution that we have adopted is an attempt to restore function of this muscle by primary nerve grafting at the time of surgery, utilizing a section of the greater auricular nerve. To our knowledge there has been no mention in the literature using a sensory nerve to restore continuity of the accessory nerve.

By way of review, the trapezius muscle receives its motor nerve supply from the spinal portion of the accessory nerve. There are fibers from cervical 3 and 4 which communicate with the muscle across the posterior triangle but these have been thought to be afferent fibers. The sternomastoid muscle also receives its motor supply from the spinal accessory. Since this muscle must be removed in the en bloc dissection it will not be considered further.

The trapezius muscle is principally an elevator of the shoulder although the levator scapulae and rhomboid muscles play a great part in maintaining the shoulder in proper position for action of the trapezius. Much greater disability to the shoulder girdle is apparent if the nerve to the levator scapulae is injured. This nerve arises from cervical 3 and 4 and crosses over the posterior scalene to enter the levator scapulae. The nerve to the rhomboid muscles arises from cervical 5 and pierces the medial scalene muscle and proceeds downward under cover of the levator scapulae to break up in its muscle. Interruption of this nerve causes winging of the scapula. These two nerves may be injured during an ordinary neck dissection if special care is not taken to preserve them as they lie beneath the investing fascia which covers the muscles in the posterior triangle of the neck. Restoration of function of the trapezius muscle was thought to be possible using a section of the greater auricular nerve to splice between the cut ends of the accessory nerve. This modality was begun approximately three years ago on selected cases. Selected cases, meaning those in whom the upper and lower ends of the spinal accessory nerve could be preserved for suturing and a suitable length of the greater auricular nerve could be salvaged.

The following technique was used in all of our cases. The greater auricular nerve was identified just beneath the superficial fascia in the superior part of the neck as it crosses the upper limb of the incision (Fig. 1). The nerve was sectioned as it emerged from the cervical plexus at the posterior border of the sternocleidomastoid



Fig. 1.—Upper arrow shows suture line of graft to stump of accessory nerve above. Lower arrow shows suture line to lower stump.

and again lateral to the mastoid as it began its arborization. In most instances this nerve appeared to be approximately the size of the accessory nerve. The length of the nerve before it branched varied considerably. In some instances its length was as much as eight centimeters but in others only four or five centimeters could be salvaged. The nerve was preserved in Tis-U-Sol for use at the end of the operation.

Later in the radical neck dissection the accessory nerve was separated from the external surface of the internal jugular vein and was cut sharply with a knife approximately two centimeters below the jugular foramen. At the lower end the nerve was exposed in the posterior triangle as it passed deep to the trapezius muscle. As great a length as possible was preserved here in order to reduce the length of the graft. The length saved depended upon the stature of the

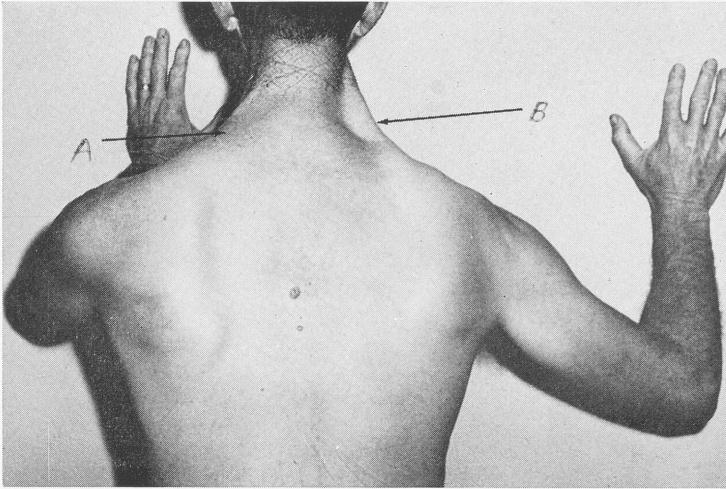


Fig. 2.—Bilateral neck dissection. Arrow *A* shows good recovery of trapezius muscle on side grafted. Arrow *B* shows appearance of neck with no graft but hypertrophy of levator scapulae.

individual, whether long or short necked and also on whether there were positive jugular chain nodes present or enlarged nodes in the posterior triangle.

At the completion of the radical neck dissection and other procedures combined with the radical neck dissection, the splicing of the greater auricular between the cut stumps of the accessory was done. Immediately before inserting the nerve between the upper and lower stumps a sharp knife was used to trim the ends of the nerve and the nerve graft squarely, cutting down on a wooden tongue depressor. The nerve was then laid into position. No. 6-0 black silk suture was passed through the perineurium of the graft and the stump and tied. An attempt was made to place two sutures at 180 degrees from one another. The upper and lower stumps were sutured similarly to the graft. No attempt was made to sheath the nerve with polyethylene tubing or as recommended by Campbell and Luzio,¹ with sialastic sheets.

Twenty-three cases were treated according to the above techniques over approximately three years. The earliest recovery was at five and a half months and was estimated to be approximately sixty

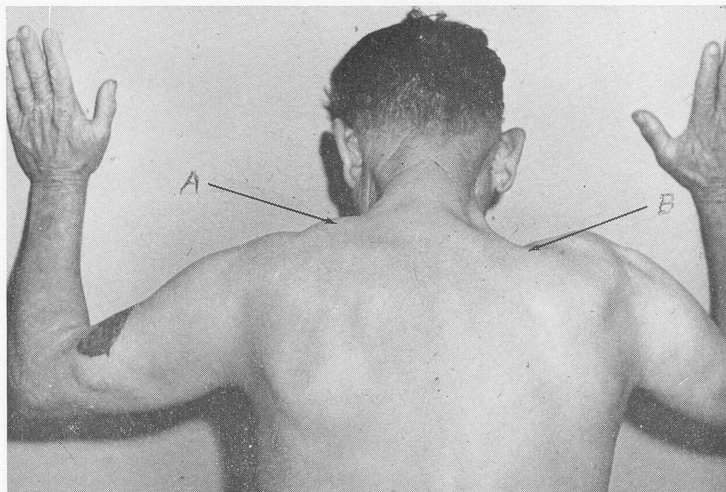


Fig. 3.—Bilateral neck dissection. Arrow A shows excellent return of mass of trapezius muscle due to grafting. Arrow B shows atrophy of trapezius muscle and no graft of accessory nerve.

percent. The remaining cases were not followed at regular intervals, therefore, the estimated return of function is that which was present at one year or more.

The evaluation of the return of function of the trapezius muscle was based wholly on clinical evaluation, by palpation of the muscle while the patient raised or shrugged the shoulders and with the patient leaning forward with the arms outstretched and hands flat, braced against a wall. These patients were classified according to the examiner's estimate of the return of function and not on the patient's symptomatology.

| | |
|--|---|
| Number of cases showing above 75% recovery | 8 |
| Number of cases showing 50-75% recovery | 4 |
| Number of cases showing 25-50% recovery | 2 |
| Number of cases showing no recovery | 5 |
| Number of cases not followed | 4 |

Five cases who had bilateral neck dissection done at different times, one side grafted and the other not grafted, showed rather striking results. The recovery of the trapezius muscle on the first side oper-

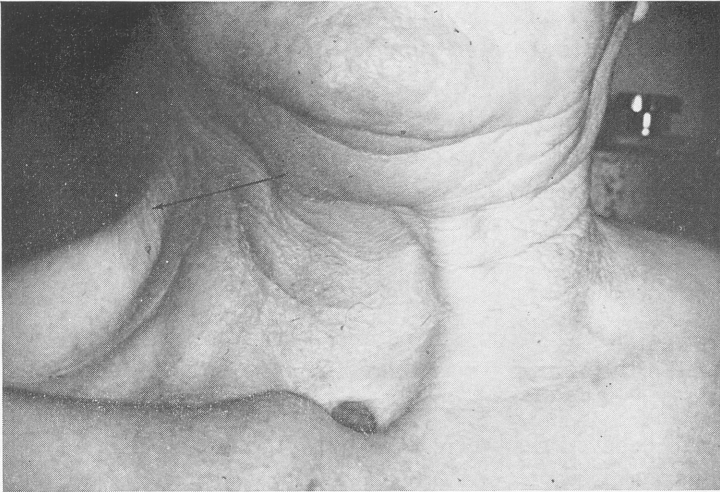

Fig. 4.—Arrow shows excellent return of mass of trapezius muscle due to grafting of accessory nerve.

ated and grafted was compared with the second side both before surgery and six months after surgery. There was little difference in the appearance of the shoulders before surgery but marked difference in the objective function of the shoulder and in the subjective evaluation by the patient.

Shoulder function always improved to some extent without grafting due to hypertrophy of the levator scapulae. This improvement, however, never equalled that seen in the patients who had as much as fifty percent recovery of the trapezius muscle who were able to shrug their shoulders and move the arms above the head without difficulty. This was especially noticeable in the five cases who had bilateral neck dissections and were grafted on one side and not on the other (Figs. 3, 4, 5).

Several factors influencing the above results should be noted. One of the most obvious causes of failure was poor approximation of the nerve to the graft. The neurorrhaphy coming near the end of a long surgical procedure tended to be hurriedly done or delegated to a less experienced assistant. It is our feeling that careful approximation under at least 2X magnification and without undue tension would be well worth the extra few minutes of operating time required, and would easily make the difference between success and failure.

Another difficulty encountered in this study was the problem of follow-up. The nerve could not be expected to have regenerated in much less than six to nine months and often by this time follow-up visits are spaced too widely for exact timing of muscular recovery.

This should be considered a preliminary report since our technique of neurorrhaphy is still evolving. Although the successful cases are encouraging, it is felt that better results will be forthcoming with a more exact neurorrhaphy.

CONCLUSIONS

Grafting the preserved section of the accessory nerve with the greater auricular nerve was found to be definitely advantageous to those who had good return of function of the trapezius muscle.

It is believed that there would have been a higher rate of return of function if more exacting methods of neurorrhaphy had been done.

SUMMARY

1. Twenty-three cases, using the greater auricular nerve as a graft between the stumps of the accessory nerve were studied clinically for return of trapezius function.

2. Eight of these cases showed approximately 75 per cent recovery of the function of the trapezius muscle.

3. Four cases showed between 50 and 75 per cent recovery of the trapezius function.

4. Two cases showed 25 to 50 per cent recovery.

5. Five cases showed no recovery after one year.

6. Those cases who had 50 per cent or better recovery of the function of the trapezius muscle definitely had greatly improved movement of the shoulder and could place the arm over the head without any difficulty.

7. It is a valuable technique and is to be recommended in all cases having radical neck surgery.

1200 MOORSUND AVE.

REFERENCES

1. Campbell, James B., and Luzio, Jose: Facial Nerve Repair: New Surgical Techniques. *Trans. Amer. Acad. of Ophthal. and Otolaryn.* 68:1068-1075 (Nov.-Dec.) 1964.

DISCUSSION

DR. WORK: Some three years ago I was talking to Dr. Harris and I knew that he had initiated this work and I didn't know of anyone else who had done this. A year or so ago I saw Dr. Harris again and he reported that he was getting return of function in this rather large muscle mass. It aroused my interest again, so we did five cases.

We have found and verified everything that he said today and probably this is a useful procedure. We don't know for sure yet. We have not done this routinely. We simply did these five cases to see what would happen to them. Of the five cases we have done one died of cancer before the graft could grow, three had return of function, and one did not.

The three that did recover I will show in a moment. Here we are as surgeons, we are doing destructive surgery, we are trying to cure cancer, and what can we do to rehabilitate the patient? We teach them to talk. Is it worth-while in their occupation—after all, we are trying to get them back to their full occupation—is it worth-while from the functional standpoint, and so on, to do this extra procedure?

To do this work it takes a little extra time, you must preserve the great auricular nerve, and it doesn't make any difference whether you use the nerve or not, but if you think it is worth-while you can get a nerve from some other portion of the body. I don't know and I can't give you the full answers today whether the patients are going to have less pain, whether they are going to be able to lift more, and so on.

This is a case that we did a year ago and, as you notice, the muscle mass on this—this was a bilateral simultaneous neck dissection and, as you see, the muscle mass on this side is much larger than the atrophied side. This side (indicating) was grafted.

Here it is and you see the return of the trapezius on this side as compared to the ungrafted side.

Now, with the lack of function in the trapezius the shoulders will drop. This case was grafted and the trapezius returned on this side in approximately nine months.

We went one step further in these cases and did electromyography studies. In the cases that returned there was no question of electrical responses. The electromyography studies showed that this large muscle mass had re-energated. We tried to find out from the physiotherapist if he could estimate the amount of muscle that had returned and he said that his test was qualitative, just like Dr. Harris's test for clinical function.

Here is the same patient later on. You see the muscle, the trapezius, has regenerated.

Another case, successful. Notice the large trapezius has re-energated in this case.

This emphasizes—it was one of the failures—the electromyography studies showed no return from the trapezius. This was in addition to the clinical function. When the needles were placed in the muscle mass, the physiotherapist, who is a physician, incidentally, noted that he could feel the fibrous mass of this muscle as the needle entered.

This case illustrated the point that the hypertrophy of the levator scapulae muscle tries to compensate for the loss of function of the trapezius.

So I would say in conclusion that Dr. Harris has probably made a very valuable contribution. Those who do this sort of work in their attempts at total rehabilitation might expend the extra few moments to re-anastomose this nerve. It will re-grow and will re-function.

I don't know whether every case should be grafted, but one might think about it in this manner: if a block dissection is indicated, grafting might be indicated. This is a pretty broad statement.

DR. DELMAR F. WEAVER: I want to take one moment to add my praise and thanks to Dr. Harris for this very excellent presentation of an original subject.

I also enjoyed Dr. Work's discussion.

Dr. Work mentioned the question of pain and said that he wasn't certain whether it was better or not and I should like to hear Dr. Harris's comments on what he has been able to determine in a larger series of cases, whether this improves the ache and discomfort that these people have.

DR. JOHN J. CONLEY: This is a commendable piece of work indeed and I think here perhaps the fundamental concept for all of us is the application of the ideal of maximum immediate rehabilitation in all of these extirpative operations as the key point. I don't think there is any question about the fact that this grafting technique works. The incidence of success will eventually be much higher than 60 or 70 per cent. I would imagine it would go up around 80 or 90 per cent, because here the technique is simply implanting a single nerve filament of fairly good diameter, a diameter of perhaps two or three or four millimeters, and sewing this together with four fine silk sutures.

It conjures, however, other questions:

Number one, does this work so well because it is a cranial nerve and not a peripheral nerve, because when this work is done on limbs, arms and legs, it doesn't work nearly this well. In a series of seventy-two facial nerve grafts, where the problem is more complex because you are sewing together not only a main trunk but five very small distal filaments, the incidence of return is about 70 per cent.

I would like to state that we had a little experience with two other methods of rehabilitating the shoulder. One was the use of the millipore tube that Dr. Pete Campbell had researched. Dr. Campbell is a neurosurgeon and he has done original work with the millipore tube. These tubes have a very small filament ingress and egress, the filament in the millipore substance being small enough to keep out certain antigenic molecules, letting in serum but keeping out the heavier molecules. We used some of these in the spinal accessory chain and we found that the nerve would grow along the millipore tube but the tubes were brittle and they would crack and fracture and this was abandoned. Dr. Campbell discovered that even when he put the millipore tube around the spinal cord, that had been transected in cats, he could get them to grow back together again in a fairly high percentage of instances, but there was no functional return.

The other method that we used was the use of the homologous nerve graft taken from cadavers and we found that this was a complete failure in that this homologous graft turned to fibrous tissue and did not supply a conduit or a pathway for the regeneration of this nerve along a homologous pathway. Therefore I think the experiment you did is absolutely correct in that you used autogenous material, which is the ideal material.

I would like to add two words of caution. I think Dr. Harris brought this out but I would only emphasize it.

Number one, he picks the autogenous nerve graft from the specimen that presumably contains the cancer and the nerve he picks is the great auricular nerve, which is in a relatively superficial position and is the farthest away from the cancer, so that if you had to pick one from the specimen that you were removing, this would probably be the best one to pick. There are many other nerves in the cervical plexus, C3 and C4 particularly, but I would be cautious about picking a nerve from a specimen that presumably contains cancer. Now, the more cancer the specimen contains the more dangerous it is to try to pick the raisins out of this cake without contamination.

I think the other word of caution is that in all of these exercises the emotions of the operator tend to try to conserve tissue and here I think we might have a tendency to want to save as much of the roots of the spinal accessory nerve as possible in order to make the nerve graft shorter to facilitate the grafting. Here I think we have to be careful that we don't get trapped by either of these emotional positions.

I would like to congratulate Dr. Harris and say that we should follow on with this, because I think that this will eventually, in selected cases, become a routine part of the procedure.

DR. EMANUEL M. SKOLNIK: Dr. Harris alluded to a statement "abandonment of the preservation of the spinal accessory nerve" in radical neck dissection. In 1946 I performed a neck dissection with preservation of the XI cranial nerve on a patient with malignancy of the thyroid gland. The satisfactory functional result without nullification of the surgery and survival of the patient prompted a study of the justification of such a procedure. Most of the subsequent procedures performed were on patients with thyroid disease. There was no problem of rehabilitation in most of these patients, although in some the scarring that did occur inhibited to a degree the mobility of the shoulder, and on occasions the patients complained of some "burning sensation."

The favorable results suggested that a patient with cancer in the head and neck region, without evidence of palpable nodes in the neck, and in whom an elective neck dissection is planned would, in selected instances, be a candidate for preservation of the spinal accessory nerve.

In radical neck dissection it has been routine to sacrifice the XI nerve while preserving the X and XII nerves. The anatomic proximity of the great vessels of the neck to the nerves indicated that in elective neck dissection, the XI nerve could be spared as well as the X and XII. This procedure has not compromised the surgical cure rate in any way and coupled with restoration of function to the shoulder and the relative absence of pain, justifies this approach.

To reinforce this attitude, I recently had an opportunity to do a one-stage bilateral neck dissection in a patient with carcinoma of the thyroid gland, who had palpable nodes in both sides of the neck. The spinal accessory nerve was preserved on the right side but sacrificed on the left. The patient commented that she noticed a marked difference on the two sides several days postoperatively, and she mentioned that the right shoulder gave her no discomfort whatsoever, and the movement was quite good, whereas the left side of her neck was painful and limited in its activity.

Since the word "routine" should not apply to any surgical procedure, and since the X and XII nerves are preserved in neck dissection, I would like to make a plea for preservation in the branch of the XI nerve which innervates the trapezius muscle in selected elective neck dissections.

DR. HARRIS (closing): I want to thank Dr. Work for his discussion. I did not have an opportunity to discuss this with him before and I am happy to know that he has found approximately the same conditions after grafting.

Dr. Weaver, I am not sure that these patients have had less pain. I think in elderly people that bursitis may account for a lot of the pain and I am not sure how much of the discomfort these people have in shoulders is due to fatigue of muscles or whether it is due to bursitis.

Dr. Conley, I thank you for your discussion and I believe that using the great auricular in most cases does not compromise the patient. This is a very superficial nerve. It lies just beneath, in part, beneath the platysma, which most of us leave attached to the skin except in certain instances where we have superficial carcinoma, the lip, and so on.

Now, Dr. Skolnik, I have since abandoned very definitely the preservation of the spinal accessory nerve in any type of en bloc dissection. I think first of all that it just isn't good cancer surgery. If you are going to do an en bloc dissection, do an en bloc dissection, and I believe with grafting this nerve that we have shown that there is sufficient recovery and in those that don't recover the disability is not great, but we do add a little comfort and a little effort at rehabilitating all of our patients by using this procedure.

I might say that in some of our cases that we have not left much stump above or below and the graft is often a little too short and it has been too taut when we sutured it in place. This may have accounted for some of our failures.

Memorials

HOWARD CHARLES BALLENGER, M.D.

1886 - 1965

Dr. Howard Ballenger was born in Economy, Indiana August 17, 1886 and died in Winnetka, Illinois March 9, 1965. He lived through an eventful period in medicine and in his specialty of Otolaryngology. He saw marked changes in practice and greatly helped mold its evolution in the direction of conservatism and sound methods by example and precept.

He had the drive of intellectual curiosity and the practicality to apply new knowledge and made notable contributions. He helped prove the relative frequency of bacteremia in upper respiratory infections and after tonsillectomy. His organized group study of harmful effects of cigarette smoking was a pioneer effort in this field, although the emphasis was on hygroscopic agents.

In pursuit of his editorial work, Dr. Ballenger kept abreast of the medical literature and read, in whole or in abstract, nearly all articles published in his field in English or foreign languages. He became part of a medical family tradition when, in 1925, he joined his Uncle William Ballenger as co-author of the influential *Diseases of the Ear, Nose and Throat*. In 1937 he became sole editor and in 1957 was joined by his son, Dr. John Ballenger, who carries on this valuable text, now in its 10th edition.

Dr. Ballenger started as a business college student but, inspired by his famous uncle, studied at Earlham College and the University of Michigan, and received his M.D. from the University of Indiana. After an internship at the Methodist Hospital, Indianapolis he served a preceptorship with his uncle. He was a diligent student.

Dr. Ballenger served many faithful years on staffs of schools and hospitals. He was an instructor at the University of Illinois and Attending Otolaryngologist at Illinois Eye and Ear Infirmary and at Evanston Hospital. He became acting Head of the Department of Otolaryngology at Northwestern University Medical School in 1944, and was Chairman from 1948 to 1951. He was a painstaking teacher



HOWARD CHARLES BALLENGER

of his fine techniques and always strove to imbue students, interns and young colleagues with enthusiasm for the specialty to which he was dedicated.

He was a Fellow of the American Otological Society and the American Laryngological Association, of the Triological Society and of the Academy. He was a Past President of the Chicago Laryngological and Otological Society.

Although failing health in the last few years had limited his professional activity and personal contacts, Howard Ballenger is vividly remembered by his contemporaries for his fine character, his intellectual integrity and his loyalty to his ideals and his friends.

Surviving Dr. Ballenger are his sons, Howard O. and Dr. John J., a daughter, Mrs. Barbara Williams, and seven grandchildren.

He leaves a record of fine service to the Medical School, to the community and to his profession.

T.C.G.

MURDOCK SYKES EQUEN, M.D.

1892 - 1964

Jonte Equen, a New Orleans (Louisiana) planter of French lineage, married English-descended Willie Sykes. From this union, there were five children. The fourth was born April 9, 1892, and was given the name of Murdock Sykes Equen. Jonte died while Murdock was still preschool age.

The early life of this boy was spent in Columbus, Mississippi, and he received his preliminary education at Franklin Academy of that city. Later, he attended Vanderbilt University.

Presbyterian minister, Reverend Dunbar Ogden, a favorite relative of this family, lived in Atlanta, Georgia, and it was his influence which brought Murdock Equen to Atlanta to attend the Emory University School of Medicine, from which he graduated in 1916. He spent the next year studying otolaryngology at the Brooklyn Eye and Ear Infirmary.

During World War I, he served in the United States Army with Base Hospital 43, the Emory University Unit, as a First Lieutenant. Following this, resumed medical training, this time at the New York Eye and Ear Infirmary, taking certain postgraduate courses. He concentrated on laryngology and broncho-esophagology, which from the beginning seemed to be his major concern. He then returned to Atlanta where he went into practice with one of that city's outstanding otolaryngologic pioneers, Dr. Dunbar Roy, with whom he was associated from 1922 to 1934.

In 1922, Dr. Equen married Ann Hart of Union Point, Georgia. There were two daughters, Ann Hart (Mrs. W. Perry Ballard) and Carol Sykes (Mrs. Sebastian Miller).

Dr. Equen was affiliated with the Cathedral of St. Philip Episcopal Church. He adhered to the Democratic political party and held memberships in the Kiwanis Club, the Piedmont Driving Club, the Capitol City Club, the Kappa Sigma literary fraternity and the Phi Rho Sigma Medical Fraternity.



MURDOCK SYKES EQUEN

From the beginning of his practice, he was intensely interested in the progress of otolaryngology in Atlanta and he maintained his special affection for broncho-esophagology. He was far enough ahead of his time that he was unable to arouse the administrators of certain hospitals to the pressing necessity of this specialty. So, he was unable to get enough hospital service to care for the many foreign body cases which by this time were already coming to him. Years later, he stated that the driving force toward having his own hospital was being unable to accommodate these people in public facilities.

In 1936, against the advice of many friends and colleagues, he opened his own small hospital under the name of Ponce de Leon Eye and Ear Infirmary. From the beginning, things went well, and before the due date, he had the pleasure of inviting some of his closest friends to a social occasion to "burn the notes."

His good fortune was not altogether sheer luck. He was a tireless worker who was able to devote practically all his time to his work because his wife very capably took charge of the family affairs. Night after night, Dr. Equen could be found at the Infirmary, maybe by himself, maybe with close friends, maybe in the operating room, maybe on the front steps of his clinic, but always having worked late and still ready to help whenever the need might arise. It was almost unheard of for any doctor to ask for Dr. Equen's help and not receive that help the same day. He often mentioned that "availability was a much more important asset than ability." This, he said, was the reason that he was always on the job, or at least at the other end of the telephone, so it is no surprise that he was one of the first doctors in the state of Georgia to put a telephone in his automobile.

He had two other favorite expressions: "A doctor doesn't have to worry about retiring, his patients will take care of that." and "The older a doctor gets, so do his patients. The first thing he knows, he is not hearing anything from pediatricians."

His medical affiliations were numerous and include the American College of Surgeons (1925), the American Triological Society, Inc. (1928), the American Academy of Ophthalmology and Otolaryngology (1931), the American Broncho-esophagological Association (1938), the American Laryngological Association (1954), the Southern Medical Association and several local otolaryngologic societies. His name was listed in *Who's Who In America* (1954). At one time he served as president of the state board of medical examiners (Georgia).

In 1944, he was awarded the Thomas A. Edison Foundation Gold Award for Achievement and Contribution to the Arts and Sciences. This honor came to him because of his work on the use of a magnet for removing magnetic foreign bodies from the tracheobronchial tree and upper gastro-intestinal tract. It was probably the monumental medical accomplishment of his life. Of the more than 21 articles on the subject of rhinology and laryngology that he published in national medical magazines, the majority concerned this magnet. After many operative and technical improvements he published a book on this subject (*Magnetic Removal of Foreign Bodies*).

Dr. Equen had few hobbies. His life was devoted to otolaryngology. He did, however, confess his love for football and baseball, neither of which he ever played. His acme of diversion was to watch the games, especially football, and more especially the Georgia Tech variety. He almost never missed a home game and he frequently went on the road trips. It is said that after a game, he would go into the dressing room and rejoice or moan with the coaches, as the occasion demanded. Indeed he was an avid fan. He considered himself the personal physician to the Georgia Institute of Technology, and specifically to the members of the football team, its coaches and all immediately involved. Long is the list of the players and coaches whom he has surgically treated.

To the nonmedical people, Dr. Equen was a wizard at removing foreign bodies from the food and air passages. He was the man who could treat any kind of ear, nose and throat disease and did so at any hour of the day or night in his hospital on Ponce de Leon Avenue. To many, he was a genius.

To his medical colleagues, Dr. Equen was a continuous worker who knew not how to be unkind, who could not refuse a plea for professional help, who had great skill in removing foreign bodies from food and air passages and expanded the use of the little magnet for removing foreign bodies, who always seemed deaf to criticisms of other doctors by patients, and above all, the doctor who was never known to say anything derogatory about a fellow physician.

L.A.B.

COLBY HALL, M.D.

1904 - 1964

Colby Hall was born September 13, 1904, in Springfield, Illinois. He died September 6, 1964, from his third attack of coronary occlusion, while vacationing in Ventura, California.

After attending schools in Springfield, where the Halls were a pioneer family, Colby entered the University of Illinois, and subsequently he attended and was graduated from the School of Medicine of Washington University, in St. Louis, Missouri. He also served his internship and residency in St. Louis, at Barnes Hospital.

Upon the completion of his formal training, Colby left the Midwest, having decided to practice in Los Angeles. He became an associate of Doctor Chester Bowers, and soon was appointed to the staff of the Children's Hospital, the Hospital of the Good Samaritan, and the County General Hospital of Los Angeles.

One of his keenest interests was the preparation of future otolaryngologists, for Colby was a fine teacher. A member of the clinical faculty of the School of Medicine of the University of Southern California, he devoted many hours to instruction, and he is gratefully remembered as a dynamic teacher by his students. His didactic methods were direct and he was unswerving in the pursuit of truth. Understanding of an honest mistake, he was, nevertheless, fiercely intolerant of carelessness or deliberate concealment of error.

His characteristic honesty is exemplified in his brief, almost terse, contributions to the literature of his field. Unwilling to write unless convinced of the intrinsic merit of the matter to be presented, his articles display true intellectual selectivity. Witty, but not caustic, he is perhaps best remembered as a shrewd diagnostician, and an excellent and kind practitioner.

An active member of the Wilshire Presbyterian Church of Los Angeles, Colby was one of those rare men who read and also enjoyed numerous sports. An interlude in his service to the Los Angeles community was his four year wartime duty as medical officer in the CBI theater, following which he became area consultant in Otolaryngology



COLBY HALL

for the Veterans Administration. Upon his return from military service, Colby married his wife, Hannah, in 1946, and re-established his practice.

Elected to membership of the Laryngological Association in 1950, Colby, following his first coronary attack in 1962, became an Emeritus Fellow. He was also a member of the Triological Society, the Los Angeles County Medical Society, and the California and American Medical Associations. His fraternal affiliations were Nu Sigma Nu and Alpha Omega Alpha. In addition to his widow, who is living in Los Angeles, Colby is survived by his mother, Mrs. Honoretta Colby Hall.

P.V.

FIELDING OTIS LEWIS, M.D.

1878 - 1965

Doctor Fielding Otis Lewis, an Honorary Fellow of the American Laryngological Association, was elected to Active Fellowship in 1918 and to Honorary Fellowship in 1943. He was born in Hebbardsville, Henderson County, Kentucky on August 20, 1878, and died in the Jefferson Medical College Hospital, Philadelphia on May 9, 1965.

Doctor Lewis attended the Philadelphia College of Pharmacy with the view of studying medicine and graduated from this institution in 1901. He then entered the Jefferson Medical College from which he received the degree of Doctor of Medicine in 1906. He served his internship at the Jefferson Medical College Hospital where he became interested in Otolaryngology through the influence of Doctor Braden Kyle who was then Professor of Laryngology at Jefferson, and as a result when he completed his internship he became an associate of Doctor Kyle and began a long and brilliant career in private practice, and the teaching of Laryngology at Jefferson, which led to his appointment as Professor in 1924. His career was interrupted in 1918 when he joined the Army Medical Corps as a captain to serve in World War I. At the end of World War I, after his discharge from the army, he resumed his private practice and teaching. Doctor Lewis became particularly interested in the surgical treatment of cancer of the larynx, and it was in this field that he attained wide recognition for his contribution to the development of the operation of total laryngectomy. Through his efforts, and those of a few other men, notably Doctor Joe Beck of St. Louis and Doctor MacKenty of New York City, total laryngectomy was established in this country as a cure for many cases of cancer of the larynx, which up until then were considered inoperable and hopeless. Total removal of the larynx to eradicate cancer had been tried before and discarded, because of the high mortality rate and prolonged suffering it entailed which made it a more fearsome ordeal than the disease.

His pioneering efforts and accomplishments in the treatment of cancer of the larynx received wide acclaim, and at the time of his enforced retirement in 1934 because of illness, he was recognized as an authority on the subject.



FIELDING OTIS LEWIS

Although best known for his attainments in the surgical treatment of cancer of the larynx, Doctor Lewis was considered by his colleagues to be outstanding in all branches of Otolaryngology. Sinus surgery, rhinoplasty, mastoid surgery, tonsillectomy and laryngeal surgery were done by him with the skill and thoroughness of a master craftsman. Furthermore, behind his surgical skill there was the keen observation, diagnostic ability and medical judgement of a great clinician. To him Otolaryngology was much more than just a surgical specialty. It was, in a sense, a picture window which looked out upon the whole broad field of medical and surgical practice, and to his undergraduate students he constantly stressed the importance of looking for and being aware of the local manifestations of systemic disease in their examination of the special areas of the nose, throat and ears. Not infrequently his own patients were indebted to him for an early diagnosis of some unsuspected systemic condition because of his alertness to the possibility that their local complaint indicated more than local disease.

Doctor Lewis took an active part in both local and national medical societies and frequently contributed important papers based upon his clinical work. In addition to the American Laryngological Association he was a member of the American Laryngological, Rhinological and Otological Society, American Broncho-Esophagological Association, American Academy of Ophthalmology and Otolaryngology and the American College of Surgeons.

He never missed a meeting of these national societies if possible, because he was convinced that it was the best way for the busy clinician to keep up with the progress of medicine in his specialty.

In October 1934 without premonition or warning Doctor Lewis suffered a stroke, which compelled him to retire at the height of his career. It was a tragic disappointment to him, his colleagues, patients and friends. He accepted this cruel blow without bitterness or complaint, but with the equanimity, courage, and insight of a great physician. To those who knew him well it illustrated, more than any other incident of his brilliant career, the fine character of the man. He spent the remaining span of his long life in the quiet, beautiful surroundings of his country home, Kenmore Wood, near Media, Pennsylvania.

A.T.S.

ROBERT CARSON MARTIN, M.D.

1894 - 1964

Doctor Robert C. Martin suffered a sudden and totally unexpected coronary occlusion while dining with his family on May 9, 1964.

"Ki" was born in Redding, California on February 26, 1894 to Robert Martin and Alice Eaton. He graduated from the University of California, Berkeley, in 1916 and from the University of California School of Medicine in San Francisco in 1920. Following this he served as the first resident in otolaryngology at the University of California Hospital, his training consisting of a joint appointment between Neurosurgery under Doctor Howard C. Naffziger and Otolaryngology under Doctor Albert J. Houston. In 1922-23, he took an additional year of otolaryngology training in Vienna at the Allgemeines Krankenhaus, following which he entered practice in San Francisco. In 1927 he completed the postgraduate course under the direction of Doctor Harris P. Mosher of the Harvard Medical School in Boston.

He was a member of all of the senior societies in otolaryngology including the American Laryngological Association, the Triological Society, and the American Otological Society. In 1950 he was President of the Triological Society; ten years later, in 1960, he was elected President of the Otological Society.

He was twice offered the chairmanship of the Division of Otolaryngology at the University of California San Francisco Medical Center: once in 1944 following the retirement of Doctor Wallace B. Smith and again in 1956 following the untimely death of Doctor Lewis Francis Morrison.

He was best known for his pioneer work in facial nerve surgery for which he received international recognition. He has, by personal example, left a heritage of high ideals, courage and devotion which will long endure.

A man's only real possession is his memory. We shall long keep the memory of "Ki". His going leaves us lonelier but richer and



ROBERT CARSON MARTIN

better for his having passed our way. In all truth, he was a fine human being, one of God's gentlemen.

Our sincere sympathy goes to his beloved wife, Ruth, and only son, Bob.

F.A.S.

Executive Sessions

EXECUTIVE SESSION

SUNDAY MORNING, MAY 23, 1965

The Opening Session of the Eighty-sixth Annual Meeting of the American Laryngological Association, held at The Broadmoor, Colorado Springs, Colorado, convened in the Theater on Sunday morning, May 23, 1965, at eight fifty-five o'clock, Albert Carl Furstenberg, M.D., St. Joseph's Mercy Hospital, Ann Arbor, Michigan, President of the Association, presiding.

PRESIDENT FURSTENBERG: Our first order of business is the election of Emeritus Fellows and the Secretary will read the names.

Lyman G. Richards, M.D. (Wellesley Hills, Massachusetts, Secretary of the Association) presented the ballot.

The following men were elevated to Emeritus Fellowship:

Dr. Norton C. Canfield

Dr. W. Likely Simpson

Dr. Oliver A. Van Alyea

The following men were elected to Active Fellowship:

Dr. James T. King

Dr. John S. Knight

Dr. Richard W. Hanckel

Dr. Daniel Miller

PRESIDENT FURSTENBERG: Somebody can move that the Secretary cast one ballot for the election of both the Emeritus and the Active Fellows.

(Such motion was duly made, seconded from the floor and carried.)

The next item on the agenda is the election of the Nominating Committee by the Association.

(The following were then elected after nomination from the floor:)

Paul M. Moore, M.D.

George F. Reed, M.D.

William James McNally, M.D.

John R. Lindsay, M.D.

Stanton A. Friedberg, M.D.

The next order of business is the introduction of the newly elected Active Fellows and will the sponsors please bring them forward.

(The newly elected Active Fellows were escorted to the platform by their sponsors.)

I should like to congratulate all of our new members. I know they are going to do everything they possibly can to contribute to the success of this American Laryngological Association, and they are very, very well trained gentlemen who have practiced otolaryngology for many years and we look forward with a good deal of anticipation to their help in the conduct of these meetings.

ANNUAL BUSINESS MEETING

MONDAY MORNING, MAY 24, 1965

The meeting reconvened for the Annual Business Meeting of the Association on Monday morning, May 24, 1965, at eight-twenty o'clock, in the Theater, President Furstenberg presiding.

REPORT OF THE SECRETARY

The Eighty-fifth Annual Meeting of the American Laryngological Association was held on April 10th and 11th, 1964, at the St. Francis Hotel, San Francisco, California.

The President, Dr. Anderson C. Hilding, presided.

A Scientific Program of thirteen papers was presented.

Seventy-three Fellows and two hundred and four guests attended.

The Librarian, Historian and Editor, Dr. Francis W. Davison, reported the deaths of the following:

Emeritus Fellows:

DR. EDWARD H. CAMPBELL

DR. WESLEY C. BOWERS

Active Fellows:

DR. JAMES M. ROBB

The Newcomb Award was presented to Dr. Fred W. Dixon.

The following were elected to Fellowship:

Active Fellowship:

Claude C. Cody, III, Houston, Texas

Blair Fearon, Toronto, Canada

William F. Keim, Montclair, New Jersey

William W. Montgomery, Boston, Massachusetts

William H. Saunders, Columbus, Ohio

Emanuel M. Skolnik, Chicago, Illinois

Emeritus Fellowship:

Julius W. McCall, Cleveland, Ohio

Henry L. Williams, Minneapolis, Minnesota

Fred W. Dixon, Shaker Heights, Ohio

Harry P. Schenck, Philadelphia, Pennsylvania

The following officers were elected for the coming year:

President: Dr. Albert C. Furstenberg

First Vice-President: Dr. G. Slaughter Fitz-Hugh

Second Vice-President: Dr Daniel C. Baker

Secretary: Dr. Lyman G. Richards

Treasurer: Dr. Alden H. Miller

Editor, Historian, Librarian: Dr. F. Johnson Putney

First Councilor: Dr. Edwin N. Broyles

Second Councilor: Dr. Dean M. Lierle

Third Councilor: Dr. Francis E. LeJeune

Fourth Councilor: Dr. Anderson C. Hilding

The next Annual Meeting of the Association will be held at the Americana Hotel, San Juan, Puerto Rico, on April 23rd and 24th, 1966.

The other Society meetings to be held in Puerto Rico are:

The Triological Society, April 20 to 22

The American Otological Society, April 18 and 19

The American Broncho-Esophagological Society, April
20 and 21 in the afternoon

The American Society for Head and Neck Surgery,
April 22 in the afternoon.

Since the last Annual Meeting, the Association has lost through death the following:

Dr. Olof Larsell, a Corresponding Fellow since 1950,
who died on April 14, 1964

Dr. Robert C. Martin, an Emeritus Fellow since 1963,
who died on May 7, 1964

Dr. Colby H. Hall, an Emeritus Fellow since 1962,
who died on September 6, 1964

Dr. Murdock Equen, an Active Fellow since 1954,
who died on November 11, 1964

Dr. Fielding O. Lewis, an Honorary Fellow since 1943,
who died on May 9, 1965

And I have since learned that Dr. Ballenger, in Chicago, died.

That leaves us as of to date an Active Membership of 97—but this does not include the newly elected members. This is last year's Meeting report. Honorary, 3; Corresponding, 15; and Emeritus, 25; making a total of 140. With four additional Active Members from yesterday's election, that makes 144.

Respectfully submitted,

Lyman Richards, M.D., Secretary

(The Secretary's Report was accepted as read.)

REPORT OF THE TREASURER

*Exhibit A*AMERICAN LARYNGOLOGICAL ASSOCIATION
GENERAL FUND OPERATING STATEMENT

For the Year Beginning April 1, 1964 and Ending March 31, 1965

Income

Dues:

| | | |
|---|------------|-------------|
| Ninety (90) members at \$75.00 | \$6,750.00 | |
| Six (6) new members at \$115.00 | 690.00 | \$ 7,440.00 |
| | <hr/> | |
| Sales of <i>Transactions</i> | | 785.00 |
| Interest received—Savings account | | 790.30 |
| Registration fees—Annual meeting | | 560.00 |
| | | <hr/> |
| | | \$ 9,575.30 |

Expenses

Annual meeting—1964:

| | | |
|-----------------------------|------------|-------------|
| Banquet and cocktails | \$2,010.20 | |
| Projectionist | 179.50 | |
| Reporting service | 442.47 | |
| Entertainment | 240.00 | \$ 2,872.17 |
| | <hr/> | |

| | |
|---|----------|
| Council expenses (travel, room rental and luncheon) | 1,113.37 |
|---|----------|

Cost of *Transactions*:

| | | |
|------------|------------|----------|
| 1963 | \$3,442.81 | |
| 1964 | 2,864.43 | 6,307.24 |
| | <hr/> | |

General expenses:

| | | |
|--|-----------|-----------|
| Stationery, printing and postage | \$ 798.88 | |
| Clerical hire | 500.00 | |
| Auditing | 87.50 | |
| Treasurer's bond | 62.50 | |
| Donation | 100.00 | |
| Loss on Canadian Exchange | 21.48 | |
| Miscellaneous | 77.93 | 1,648.29 |
| | <hr/> | <hr/> |
| | | 11,941.07 |

| | | |
|--|--|---------------|
| Net profit (loss) for the year | | \$ (2,365.77) |
| General Fund balance April 1, 1964 | | 12,909.40 |
| | | <hr/> |
| General Fund balance, March 31, 1965 | | \$10,543.63 |

Exhibit B

AMERICAN LARYNGOLOGICAL ASSOCIATION
TRUST FUND OPERATING STATEMENT

For the Year Beginning April 1, 1964 and Ending March 31, 1965

Income

| | |
|----------------------------------|-------------|
| Interest—Government bonds | \$ 1,391.91 |
| Dividends—Common stocks | 61.95 |
| Bequest—Dr. G. F. Harkness | 1,000.00 |

| | |
|---|------------------|
| Trust Fund balance, April 1, 1964 (Exhibit C) | \$ 2,453.86 |
| | <u>52,594.12</u> |

| | |
|--|-------------|
| Trust Fund balance, March 31, 1965 (Exhibit C) | \$55,047.98 |
|--|-------------|

Trust Fund balance represented by:

| | |
|---|-------------|
| Government bonds (at cost, par and maturity values) | \$43,500.00 |
|---|-------------|

Common stocks:

| | |
|--|------------------------|
| Purchased (at cost) | \$ 5,189.27 |
| Donated (market value at date of donation) | 2,362.00 7,551.27 |

| | |
|--|-------------|
| Total bonds and stocks (Exhibit D) | \$51,051.27 |
|--|-------------|

| | |
|------------|----------|
| Cash | 3,996.71 |
|------------|----------|

\$55,047.98

Cash recapitulation

| | |
|----------------------------|-------------|
| Cash in Trust Fund | \$ 3,996.71 |
| Cash in General Fund | 10,543.63 |

\$14,540.34

| | |
|----------------------------------|-------------|
| Cash in commercial account | \$ 1,988.18 |
|----------------------------------|-------------|

| | |
|-------------------------------|----------|
| Cash in savings account | 7,552.16 |
|-------------------------------|----------|

| | |
|---------------------------------------|----------|
| Cash in savings deposit receipt | 5,000.00 |
|---------------------------------------|----------|

\$14,540.34

Exhibit C

AMERICAN LARYNGOLOGICAL ASSOCIATION
REPORT OF TRUST FUNDS

March 31, 1965

| <i>Fund</i> | <i>Principal & Unused Income 4-1-64</i> | <i>Income* 4-1-64 to 3-31-65</i> | <i>Principal & Unused Income 3-31-65</i> |
|---------------|---|--------------------------------------|--|
| Casselberry | \$ 7,683.86 | \$ 358.50 | \$ 8,042.36 |
| Johnston | 6,941.40 | 323.86 | 7,265.26 |
| de Roaldes | 4,777.42 | 222.90 | 5,000.32 |
| Newcomb Trust | 2,725.23 | 127.15 | 2,852.38 |
| Newcomb Prize | 636.09 | 29.68 | 665.77 |
| Research | 24,452.89 | 1,140.89 | 25,593.78 |
| Memorial | 5,377.23 | 250.88 | 5,628.11 |
| | <u>\$52,594.12</u> | <u>\$2,453.86</u> | <u>\$55,047.98</u> |

* Income has been allocated to each fund by the ratio that each fund bears to the total fund as of 3-31-65.

Exhibit D

AMERICAN LARYNGOLOGICAL ASSOCIATION
TRUST FUND INVESTMENTS

March 31, 1965

U. S. GOVERNMENT BONDS (at cost, par and maturity values):

| | <i>Quantities</i> | <i>Denomination</i> | | |
|----------------------|-------------------|---------------------|-------------|-------------|
| Negotiable | 10 | \$1,000 | \$10,000.00 | |
| | 1 | 5,000 | 5,000.00 | \$15,000.00 |
| | | | | |
| Non-negotiable | 5 | 1,000 | \$ 5,000.00 | |
| | 1 | 5,000 | 5,000.00 | 10,000.00 |
| | | | | |
| Series H bonds | 10 | 1,000 | \$10,000.00 | |
| | 1 | 500 | 500.00 | 10,500.00 |
| | | | | |
| Series K bonds | 3 | 1,000 | \$ 3,000.00 | |
| | 1 | 5,000 | 5,000.00 | 8,000.00 |
| | | | | |
| | | | | \$43,500.00 |

COMMON STOCKS:

| | <i>No. of Shares</i> | <i>Cost</i> | <i>Market Value at Date of Donation</i> | |
|---|----------------------|-------------|---|----------|
| McDonnell Aircraft Corp. ¹ .. | 54 | | \$1,170.00 | |
| International Business Machines | 1 | | 517.00 | |
| Internat'nal Business Machines ² | 1 | \$ 344.25 | | |
| McIntyre-Porcupine Mines | 15 | | 675.00 | |
| Amer. Telephone & Telegraph .. | 70 | 4,845.02 | | |
| | | | | |
| | | \$5,189.27 | \$2,362.00 | 7,551.27 |

TOTAL TRUST FUND

INVESTMENTS \$51,051.27

¹ Includes 28 shares received as stock dividends.

² Includes 25% stock dividend.

ACCOUNTANTS' REPORT

To the Members of the American Laryngological Association
Dear Sirs:

We have examined the accounts and financial records of the American Laryngological Association for the year beginning April 1, 1964 and ending March 31, 1965.

Cash receipts and disbursements were verified and all United States Government Bonds and common stocks were physically counted and examined.

In our opinion, the accompanying statements present fairly the cash position of the American Laryngological Association as of March 31, 1965 and the results of its operations for the year beginning April 1, 1964 and ending March 31, 1965.

Respectfully submitted,

SERENE, KOSTER & BARBOUR

Certified Public Accountants

It will be noted that the General Fund had a net loss of \$2,365.77 for the year. This was occasioned by the fact that the printing bill for our *Transactions* for 1963 was received too late to be paid in 1963 and had to be paid in 1964. Exhibit A of the report shows that the cost of both the 1963 and the 1964 *Transactions* was paid during this past year. If the \$3,442.81 cost for 1963 is not charged to 1964, then our net profit for the General Fund for this past year is \$1,077.04, which is about what our average net profit has been in the last few years.

Alden H. Miller, Treasurer

Respectfully submitted,

(The Treasurer's report was accepted as presented.)

PRESIDENT FURSTENBERG: May we now have the report of the Nominating Committee.

DR. PAUL M. MOORE (Chairman of the Nominating Committee): The Nominating Committee recommends the following for membership on the Council:

Paul Holinger, M.D.

Carlos Munoz-MacCormick, M.D.

Arthur Cracovaner, M.D.

Lyman Richards, M.D.

Alden Miller, M.D.

F. Johnson Putney, M.D.

Dean M. Lierle, M.D.

Francis LeJeune, M.D.

Anderson Hilding, M.D.

Albert C. Furstenberg, M.D.

(The report of the Nominating Committee was unanimously accepted.)

PRESIDENT FURSTENBERG: The next item on the agenda is the report of the Librarian-Historian-Editor.

REPORT OF THE LIBRARIAN, HISTORIAN AND EDITOR

The Eighty-fourth Annual Meeting of the American Laryngological Association held on April 10 and 11, 1964 at the St. Francis Hotel, San Francisco, California, was reported by the Martin C. Johnson reporting service whose representative, Mrs. Annabella Square, gave efficient and dependable service.

The manuscripts were submitted promptly and all appeared in the June issue of the *Annals of Otolaryngology and Rhinology*. The discussions were received three weeks following the meeting and promptly mailed to each discussant for correction. If an additional copy of the paper could be prepared for the recorder it would help to facilitate the interpretation in the discussions and also familiarize her with many of the scientific terms used in the discussion.

The galley proofs were received from the publisher in final form and returned on September 1, 1964, but the completed *Transactions* did not reach the membership until the latter part of December. An addition this year was the inclusion of a yearly index. This would seem to be a good idea for only a few extra pages are needed, and it will aid succeeding editors in preparation of a ten year index. According to council directive 250 copies of the 1964 *Transactions* were ordered.

In September, 1964, letters were sent to all corresponding and emeritus Fellows inquiring whether or not they wished to receive the 1964 *Transactions* at the Council established price of \$5.00. No *Transactions* were sent unless they were specifically ordered. Letters

were sent to all previous subscribers asking if they wished to purchase the 1964 Volume.

The distribution of the 1964 volume was as follows:

105 copies were sent direct from the publisher to the active and honorary members together with the families of the two deceased members.

There are 52 standing orders for the *Transactions* and 20 additional orders, 6 of which signed at the annual meeting.

A set of 20 back issues were supplied to two newly elected fellows at a cost of \$24.00 per set according to council directive.

Complimentary volumes were sent to the honorary members, the Library of Congress, the National Library of Medicine for the Index Medicus and Dr. Samuel Salinger, abstract editor. Dr. Lyman Richards received 2 volumes for his use in preparation of data for next year's *Transactions*.

Cancellations to date were 3 effective in 1964.

Advance orders to date were 3 beginning in 1964.

Two orders for the back issues of 1962 and 1963 were received.

Respectfully submitted,

F. Johnson Putney, M.D., Editor

(The Editor's report was accepted as read.)

REPORT OF THE AMERICAN BOARD OF OTOLARYNGOLOGY

The American Board of Otolaryngology held two examinations in 1964, one in New Orleans, March 30 to April 2, at which time eighty-six candidates were examined. Of this group, sixty-two passed, twenty conditioned and four failed. The second examination was held in Chicago, October 12 to 15, 1964. At this examination eighty-eight candidates were examined and of this group fifty-seven passed, nineteen conditioned and twelve failed. This is a 32 per cent condition or failure rate for the totals of both examinations. The next examination will be held in Chicago during the week of November 7, 1965.

During the year the Board published and distributed a "Booklet of Information" concerning the following subjects: Source of Author-

ity, General and Special Requirements, Application and Reapplication Routines, Examination Procedures and Fees.

A Committee of the Board (consisting of Dr. Gordon Hoople, chairman, Francis Lederer, Dean Lierle, Daniel Baker, Lawrence Boies, George Reed and Walter Work) prepared a survey on "The Future Trends in Otolaryngology." Correlated with this was a survey on the present status of otolaryngological training in the United States, encompassing eighty-two medical schools and thirty-five non-university programs.

The Board also prepared a brochure containing a description of the area of the examination of the American Board of Otolaryngology. This is primarily for heads of accredited Departments or Sections of Otolaryngology.

These informative brochures on medical education both within and outside the specialty are available through the office of the Executive Secretary-Treasurer, Dr. Dean Lierle.

Respectfully submitted,

Francis L. Lederer, M.D.

Paul H. Holinger, M.D.

(Dr. Holinger's report was accepted as read.)

REPORT OF THE LARYNGOLOGICAL RESEARCH FUND COMMITTEE

The principal and annual income of the Research Fund was \$24,452.89, as reported at the 1964 meeting of the Association. An income of \$1,140.89 accrued in the intervening year, bringing the Fund to a total of \$25,593.78.

One request for a research grant from the Fund was received during the year. The Committee studied this and submitted a report to the Council, favoring granting this request by a four to two vote. The Council reversed this decision and the request was denied.

Respectfully submitted,

John E. Bordley

Jerome A. Hilger

Joel J. Pressman

F. Johnson Putney

Walter P. Work

Paul H. Holinger, Chairman

(The report of the Research Fund Committee was accepted as read.)

REPORT FROM THE AMERICAN COLLEGE OF SURGEONS

This is the report of the Representatives of the American Laryngological Association to the Board of Governors, American College of Surgeons.

The increasing participation of Otolaryngologists in the programs of the American College of Surgeons is heartening. Both in the scientific and the organizational aspects of the College a greater recognition of the results of this participation is becoming more apparent. Through excellent regional and national programs the extent of our interest in the ancillary fields of otolaryngology is continuously before the College Fellowship.

Percentage of College members in a specialty society has recently been established as the guide to representation on the Board of Governors. As stated in this report in 1962, representation of the American Laryngological Association to the Board would be reduced gradually to one member. Dr. Walter Work, whose term expires in 1966, will represent the American Laryngological Association. Paul H. Holinger, American Laryngological Association representative, whose term was to have expired in 1965, was elected to the Board of Regents, replacing Dr. Dean Lierle, who served so effectively as Regent for three successive three-year terms.

Of interest to American Laryngological Association membership are several significant actions of the Board of Governors:

There is continued effort to prepare and implement programs of training of surgical technicians to augment the dwindling supply of operating room nurses.

The Board, through its Graduate Training Committee, is continuing to study the problems of residency training and available surgical training material in third party insurance plans. This serious problem affects all of our residency programs.

In another vein, the College representatives to the Hospital Accreditation Committee have helped to rescind Bulletin No. 36 and substitute recommendations of criterion of dental participation in hospitals more in keeping with suggestions submitted by otolaryngo-

logic members. This problem is not solved as yet, however. While control is placed on the realm of dentistry in large centers, the smaller hospitals still may have inadequate otolaryngological coverage in some phases of our specialty in which dentists have an interest.

Mention must be made that we are plagued again by an unfortunate conflict in our Otolaryngology meetings with those of the College of Surgeons. Just when we had the Academy and the College meetings separated, the International Congress chose to hold its meeting in Atlantic City. This has seriously curtailed the efforts of the Program Committee, which has continued to make our College programs multi-discipline types of discussions.

Respectfully submitted,

Walter P. Work

Paul H. Holinger

(Dr. Holinger's report was accepted as read.)

EXECUTIVE SESSION

MONDAY AFTERNOON, MAY 24, 1965

The meeting reconvened in Executive Session in the Theater at twelve twenty-nine o'clock, following the end of the Scientific Session, President Furstenberg presiding.

SECRETARY RICHARDS: I would like to announce that this Committee has met and elected the officers as follows for the coming year of this Association:

For President: Dr. Paul Holinger

First Vice-President: Dr. Munoz-MacCormick

Second Vice-President: Dr. Arthur Cracovaner

Secretary: Dr. Lyman Richards

Treasurer: Dr. Alden Miller

Editor: Dr. F. Johnson Putney

For Councilors: Dr. Dean Lierle

Dr. Francis LeJeune

Dr. Anderson Hilding

Dr. Albert C. Furstenberg

(President-elect Holinger came to the platform as requested.)

PRESIDENT FURSTENBERG: It is my very great pleasure to ask you to take my position as President of this august Society. I am perfectly certain that you will carry on the duties of this Society in a very, very comprehensive manner and in a very discreet manner.

I know that you have created epics in the progress of rhinology, laryngology, otolaryngology—all of our specialties—and epics which will not fail of lasting recognition in the end, and I am very, very happy at this moment to turn over my gavel to you.

PRESIDENT HOLINGEG: I can assure you that this is a tremendous honor. I appreciate it very, very much.

Words kind of fail a person at a time like this and yet this is a pleasure that I look forward to this coming year.

I know that this past year has been a very difficult one for you who have carried on the work and I realize the importance of it. I hope that we can continue in the same vein and in the same spirit as you have brought this Association to at this point.

There are so many illustrious names ahead of us and I can feel great pride in accepting this offer.

My first duty as President is to congratulate you on the year that has passed and to present to you, in behalf of the Society, this recognition of your service to the Society for this past year . . . (presenting gift to Immediate Past President Furstenberg).

It is a pleasure, of course, to have Dr. Richards as our Secretary and the Council, which is a distinguished series of names.

I know that the First Vice-President, Dr. Munoz-MacCormick, has extended to us an invitation for the meeting next year in Puerto Rico, and we look forward to seeing all of you, and many more, present at that meeting. It should be an outstanding meeting of the Association because of the leadership in Puerto Rico of Dr. Munoz-

MacCormick in the specialty, and the Fellowship of the Association will find great pleasure in meeting him and seeing him in his own home, as we have in the past.

(The meeting was adjourned at twelve thirty-four o'clock.)

THE JAMES E. NEWCOMB AWARD

DR. LAWRENCE R. BOIES: I have the honor to speak for a Committee consisting of Dr. Perce Ireland, Dr. Kinsey Simonton and myself to present to you the recipient of the James A. Newcomb Award for 1965.

This Award was established in 1939 through a bequest from the Estate of James A. Newcomb, who was Secretary of the American Laryngological Association for 11 years and its President in 1911. The Award is given annually to a Fellow of the American Laryngological Association who has made the most outstanding contribution to the literature of Laryngology during the previous calendar year, or as a mark of esteem and appreciation for services to the Association.

Our Committee and the Council were unanimous in the decision that this Award is merited by an outstanding contributor to Laryngology. He has served the American Laryngological Association as Editor and Historian, and more recently as its President. He has also served the American Broncho-Esophagological Association as its Secretary and its President and has been its Guest of Honor and has received the Chevalier Jackson Award of that Association. He has served his country in military service as a Captain in the Medical Corps of the U. S. Navy and has been honored with its Commendation Ribbon. He is a Consultant in Otolaryngology to the Bureau of Medicine and Surgery of the U. S. Navy. His contributions to the literature of modern Laryngology and his ingenuity in devising instruments that have contributed to the advance of Laryngology are well known to contemporary students of this specialty.

One of the great honors that he has received is to have the Edwin Nash Broyles Bronchoscopy Clinic at the Johns Hopkins Hospital bear his name.

Mr. President, it is a privilege for me to present to you the Newcomb Award recipient for 1965, Edwin Nash Broyles of Baltimore, Maryland.

List of Fellows

LIST OF FELLOWS

Date Indicates Year Admitted to Active Fellowship

Attendance at meetings is shown by figures following each name.

Asterisk (*) indicates year paper was read.

Active Fellows

1962. ALEXANDER, FRED W., 10515 Carnegie Ave., Cleveland 6, Ohio, 1962, '63*, '64.
1958. ALFARO, VICTOR R., 917 - 20th St. N. W., Washington 6, D. C., 1958, '59, '60, '61, '62, '63, '64, '65.
1962. ARNOLD, GODFREY E. T., 2500 N. State St., Jackson 6, Mississippi, 1962, '63*, '64*.
1958. ATKINS, JOSEPH P., 3400 Spruce St., Philadelphia 4, Pa., 1958, '59*, '60, '61, '62, '63, '64.
1956. BAKER, DANIEL CLIFTON, JR., 903 Park Avenue, New York 21, N. Y., 1956, '57, '58, '59*, '60, '61, '62*, '63, '64, '65.
1963. BAXTER, JAMES D., 1509 Sherbrooke St. West, Montreal, P.Q., Canada, 1963, '65*.
1944. BOIES, LAWRENCE R., University Hospital, Minneapolis 14, Minnesota, 1944, '46, '47, '48*, '49, '50*, '51*, '53, '54, '55, '56, '57, '58, '59, '60, '61, '62, '63, '64, '65.
1955. BORDLEY, JOHN E., Johns Hopkins Hospital, Baltimore 5, Maryland, 1955, '56, '57, '59, '60, '62, '63, '64, '65.
1959. BREWER, DAVID W., 1100 E. Genesee St., Syracuse 10, N. Y., 1959, '60*, '61, '62*, '63*.
1955. BROWN, LESTER ALEXANDER, 490 Peachtree Street, N.E., Atlanta 8, Georgia, 1955, '56, '57, '58, '59, '61, '63, '65.
1940. BROYLES, EDWIN N., 11 East Chase St., Baltimore 2, Maryland, 1940, '41*, '42, '46, '48*, '49, '50, '51*, '52, '53, '54, '55, '56, '58, '59*, '60, '61*, '63, '64, '65.
1963. BRYCE, DOUGLAS P., 170 St. George St., Room 320, Toronto, Canada, 1963*, 64.

1945. CAMPBELL, COLONEL PAUL A., 321 Park Hill Drive, San Antonio, Texas, 1946, '47, '49, '51, '57*, '61.
1959. CARDWELL, EDGAR P., 109 So. Munn Ave., East Orange, N. J., 1959, '60, '61, '62, '63.
1964. CODY, CLAUDE C., III, 1600 Memorial Professional Building, Houston, Texas, 1964, '65.
1957. CONLEY, JOHN J., 139 East 36th Street, New York 16, N.Y. 1958*, '60*, '61, '62*, '63*, '64, '65.
1957. CONVERSE, JOHN MARQUIS, 722 Park Avenue, New York 21, N.Y., '60, '62*.
1959. CRACOVANER, ARTHUR J., 103 E. 78th St., New York 21, N. Y., 1959, '60, '61*, '62, '63, '65.
1960. DALY, JOHN F., Faculty Practice Offices, 566 First Ave., New York 16, N. Y., 1960, '61*, '62, '63, '64, '65.
1951. DAVISON, FRANCIS W., Geisinger Medical Center, Danville, Pa., 1951, '52, '53*, '54, '55, '56, '57, '58, '59, '60, '61, '62, '63*, '64, '65.
1947. EAGLE, WATT WEEMS, Duke Hospital, Durham, N. C., 1948*, '49, '51, '53, '54, '56, '57, '59, '62, '64, '65*.
1954. EQUEN, MURDOCK S., Ponce de Leon Infirmary, Atlanta 8, Ga., 1954, '55, '57, '58, '60, '63.
1952. ERICH, JOHN B., Mayo Clinic, 102 Second Avenue, Rochester, Minn., 1953, '56*, '57, '65.
1964. FEARON, BLAIR, Medical Arts Building, Toronto 5, Ontario, Canada, 1964.
1963. FERGUSON, CHARLES F., 300 Longwood Ave., Boston 15, Mass., 1963, '64*.
1955. FITZ-HUGH, GLASSELL SLAUGHTER, 2003 Spottswood Road, Charlottesville, Virginia, 1955, '57, '59, '60, '61, '62*, '64, '65.
1956. FRIEDBERG, STANTON A., 122 So. Michigan Ave., Chicago 3, Illinois, 1956, '57*, '58, '59, '60, '61, '62, '63, '64, '65*.
1932. FURSTENBERG, ALBERT CARL, St. Joseph's Mercy Hospital, Ann Arbor, Michigan, 1933*, '36*, '38*, '46, '48*, '50, '51, '53, '54, '55*, '56, '57, '58*, '59, '60, '61, '62, '63*, '64, '65*.

1959. GOLDMAN, JOSEPH L., 1050 Park Ave., New York, N. Y., 1959, '60*, '61, '62, '63, '64, '65.
1940. GOODALE, ROBERT L., 330 Dartmouth St., Boston 16, Massachusetts, 1940, '41, '42*, '44*, '46, '47, '49, '50*, '53, '54, '55*, '56, '57*, '60, '61*, '62, '63, '64, '65*.
1965. HANCKEL, RICHARD W., 55 Doughty St., Charleston, S. C., 1965.
1957. HARRILL, JAMES A., Bowman Gray School of Medicine, Winston-Salem, N. C., 1957, '58, '59, '61, '62, '63, '64.
1960. HARRIS, HERBERT, 907 Hermann Professional Building, Houston 25, Texas, 1960, '61*, '62, '63, '64, '65*.
1959. HART, VERLING K., 106 W. 7th St., Charlotte, N. C., 1959, '60, '62.
1942. HEATLY, CLYDE A., 11 North Goodman Street, Rochester 7, N.Y., 1942, '46*, '49, '50, '52, '53*, '54, '55, '57, '58, '60, '61, '65.
1959. HENRY, G. ARNOLD, 170 St. George St., Toronto, Canada, 1959, '61, '63.
1943. HILDING, ANDERSON C., Research Laboratory, St. Luke's Hospital, Duluth 11, Minnesota, 1944*, '46, '47, '48*, '49, '50, '51, '53, '55, '56*, '57, '60, '61, '62*, '63, '64*, '65.
1955. HILGER, JEROME A., 350 St. Peter Street, St. Paul 2, Minnesota, 1955, '56*, '57, '58, '59, '60, '62, '63, '64, '65.
1945. HOLINGER, PAUL H., 700 North Michigan Ave., Chicago 11, Illinois, 1946, '47, '49, '50*, '51*, '52, '53, '54*, '55, '56, '57, '58*, '59, '60, '61*, '62*, '63, '64, '65.
1957. HOLMES, EDGAR M., 330 Dartmouth Street, Boston 16, Mass., 1957, '59, '61, '63.
1944. HOOPLE, GORDON D., 1100 East Genesee St., Syracuse 10, New York, 1946, '47, '48, '49, '50, '51, '52, '53, '54*, '55, '56, '58, '59, '60, '61, '62, '63, '64, '65.
1952. IRELAND, P. E., Room 82, Banting Institute, University of Toronto, Toronto, Ontario, 1952, '53, '54, '55, '56*, '57, '59, '61, '62, '63, '64.
1961. JONES, EDLEY H., First National Bank Building, Vicksburg, Mississippi, 1961, '62, '63*, '65.

1964. KEIM, WILLIAM F., 67 South Munn Ave., East Orange, N. J., 1964.
1965. KING, JAMES T., Baptist Professional Building, Atlanta, Ga., 1965.
1963. KIRCHNER, JOHN A., 333 Cedar St., New Haven 4, Conn., 1963, '65*.
1965. KNIGHT, JOHN S., 305 West 43rd St., Kansas City, Mo., 1965.
1963. LATHROP, FRANK D., 605 Commonwealth Ave., Boston 15, Mass., 1963, '64*.
1953. LEDERER, FRANCIS LOEFFLER, 1853 W. Polk Street, Chicago 12, Illinois, 1953, '54, '55, '56, '57*, '58, '60, '61, '62, '63*, '64, '65.
1936. LEJEUNE, FRANCIS ERNEST, Ochsner Clinic Building, Prytania and Aline Streets, New Orleans 15, Louisiana, 1937, '46*, '47, '50, '51, '52, '53, '54*, '55, '56, '57, '58, '59, '60, '61, '62, '63*, '64, '65.
1961. LEWY, ROBERT B., 25 East Washington St., Chicago 2, Ill., 1961, '62*, '63, '65*.
1933. LIERLE, DEAN M., University Hospital, Iowa City, Iowa, 1933, '34, '35*, '37, '38, '39, '40*, '42*, '44*, '46, '47*, '48, '49, '50*, '51, '52, '53, '54, '55*, '56, '57, '58, '59, '60, '62*, '63, '65.
1949. LINDSAY, JOHN R., 950 E. 59th Street, Chicago 37, Illinois, 1949, '50, '51*, '53, '55*, '56, '57, '58, '59, '60, '61, '62, '65.
1952. MCCALL, JULIUS W., 610 Rose Building, Cleveland 15, Ohio, 1952, '53*, '54, '55, '56, '57, '58, '59, '60*, '61, '62*, '63, '64.
1963. MCGOVERN, FRANCIS H., 139 South Main St., Danville, Virginia, 1963, '64.
1951. MCHENRY, LAWRENCE C., 301 N. W. 12th St., Oklahoma City 2, Okla., 1953*, '62, '63, '64, '65.
1933. MCMAHON, BERNARD J., 150 No. Meramec Ave., Clayton 5, Missouri, 1934*, '35, '36, '38*, '41, '44, '46*, '47, '48, '49, '50*, '51, '52, '53, '54, '55*, '56*, '57, '58, '59, '60, '61, '62, '64.

1931. McNALLY, WILLIAM JAMES, 1509 Sherbrooke Street West, Montreal, Canada, 1931, '33, '34*, '39, '44, '47, '49, '49, '52, '53, '54*, '55, '56, '57, '58, '59, '60, '61, '65.
1954. MELTZER, PHILIP E., 285 Commonwealth Ave., Boston 15, Mass., 1954*, '56, '57, '58, '59, '60, '61, '62, '63, '65.
1952. MILLER, ALDEN H., 1407 N. Vermont Ave., Los Angeles 27, Calif., 1952, '53*, '55, '57, '58*, '61, '62, '63, '64.
1965. MILLER, DANIEL, Deaconess Medical Building, 110 Francis St., Boston, Mass., 1965.
1964. MONTGOMERY, WILLIAM W., 243 Charles St., Boston 14, Mass., 1964, '65*.
1958. MONTREUIL, FERNAND, Centre Professionnel, 801 Sherbrooke, E., Montreal, Canada, 1958, '60, '64.
1954. MOORE, PAUL M., 10515 Carnegie Ave., Cleveland 6, Ohio, 1954, '55*, '56, '57, '59, '60, '61, '62, '63, '64, '65.
1957. MUNOZ-MACCORMICK, CARLOS EDUARDO, 71 Park Terrace, Santurce, Puerto Rico, 1957, '58, '59, '60, '61, '62, '63, '64, '65.
1953. MURTAGH, JOHN A., 2 Maynard Street, Hanover, New Hampshire, 1953, '54, '55, '56*, '57, '58, '59, '61, '62, '63, '65.
1937. NASH, C. STEWART, Medical Arts Building, Rochester 7, New York, 1937, '38*, '40, '42, '44, '46, '49, '50, '51, '52, '53, '54, '55, '56*, '58, '59, '60, '61, '62, '64.
1956. NORRIS, CHARLES MORGAN, 3401 North Broad Street, Philadelphia 40, Pennsylvania, 1956, '57, '58*, '59, '60, '61*, '62, '63, '64.
1961. OGURA, JOSEPH H., 640 So. Kingshighway, St. Louis 10, Mo., 1961*, '62*, '63, '64*, '65.
1958. O'KEEFE, JOHN J., 255 S. 17th St., Philadelphia 3, Pa., 1958, '59*, '60, '62, '64.
1961. O'NEIL, JAMES J., 612 Medical Arts Building, Omaha, Nebraska, 1961, '62*, '64.
1961. PANG, LUP Q., 1374 Nuuanu Ave., Honolulu 17, Hawaii, 1961, '62*, '64.

1961. PASTORE, PETER N., Box 25, 1200 East Broad St., Richmond, Virginia, 1961, '62*, '64.
1954. PRESSMAN, JOEL J., Department of Surgery, UCLA Medical Center, Los Angeles 24, Calif., 1954, '56*, '59*, '60, '61, '62, '64, '65.
1951. PRIEST, ROBERT E., 79, S. Ninth St., Minneapolis 2, Minn., 1951, '53*, '54*, '56, '59, '60*, '61, '65.
1951. PUTNEY, F. JOHNSON, 1712 Locust St., Philadelphia 3, Pa., 1951, '52, '53*, '54, '55, '56, '58*, '59, '60, '61, '62, '63*, '64*, '65.
1951. RAWLINS, AUBREY G., 384 Post Street, San Francisco 8, Calif., 1951, '53*, '56, '58, '64.
1963. REED, GEORGE F., Zero Emerson Place, Charles River Park, Boston 14, Mass., 1963, '65*.
1934. RICHARDS, LYMAN GILDER, 12 Clovelly Road, Wellesley Hills 81, Mass., 1934, '35, '36*, '37, '38, '39, '47, '49, '51*, '54, '56, '57*, '59, '60, '61, '62, '63, '64, '65.
1956. RICHARDSON, JOHN ROBERT, 403 Commonwealth Avenue, Boston 15, Massachusetts, 1957, '58, '59, '60, '63, '64.
1953. ROBERTS, SAM E., 1100 Professional Bldg., Kansas City, Missouri, 1953, '54*, '55, '56, '57, '58, '59, '60, '63, '65.
1959. SANDERS, SAM H., 1089 Madison Ave., Memphis 3, Tenn., 1959, '60, '61, '62, '63, '65.
1964. SAUNDERS, WILLIAM H., N-820 University Hospital, Columbus, Ohio, 1964, '65.
1959. SILCOX, LOUIS E., 102 Lankenau Med. Bldg., Philadelphia 31, Pa., 1959, '60, '61, '62, '63, '64, '65.
1958. SIMONTON, KINSEY M., Mayo Clinic, Rochester, Minn., 1958, '59*, '62, '64.
1962. SISSON, GEORGE A., 1200 E. Genesee St., Syracuse 10, N. Y., 1962, '63*, '65.
1964. SKOLNIK, EMANUEL M., 1853 West Polk Street, Chicago, Ill., 1964*, '65.
1950. SMITH, AUSTIN T., Pennsylvania Hospital, 330 So. 9th St., Philadelphia 7, Pa., 1950, '51, '52, '53, '55, '56, '57, '58*, '59, '60, '61, '62*.

1954. SOOY, FRANCIS A., 490 Post Street, San Francisco 2, Calif., 1954, '56*, '58, '60, '62, '63, '64, '65*.
1961. SUEHS, OLIVER W., 14 Medical Arts Square, Austin, Texas, 1961, '62*, '63, '64.
1963. TABB, HAROLD G., 1430 Tulane Ave., New Orleans 12, La. 1963, '65.
1947. THEOBALD, WALTER H., 307 N. Michigan Ave., Chicago 11, Illinois, 1947, '48*, '49, '50, '51, '52, '53, '54, '55, '56, '57, '58, '60, '61, '62, '64, '65.
1954. THORNELL, WILLIAM C., 2508 Auburn Avenue, Cincinnati 19, Ohio, 1955*, '57, '59, '60, '63.
1963. TOLAN, JOHN F., 1118 Ninth Ave., Seattle 1, Washington, 1963, '64, '65.
1950. TREMBLE, G. EDWARD, 1390 Sherbrooke St. W., Montreal, Quebec, Canada, 1950, '51, '52, '53, '54, '55*, '56, '57, '58, '60, '61, '62, '63, '65.
1954. WALSH, THEODORE E., 640 S. Kingshighway Blvd., St. Louis 10, Missouri, 1954, '55*, '56, '57, '58, '59, '60, '61, '62, '63, '64, '65.
1962. WEAVER, DELMAR F., 571 Fisher Building, Detroit 2, Michigan, 1962, '63, '64*, '65.
1940. WEILLE, FRANCIS L., 247 Commonwealth Avenue, Boston 16, Massachusetts, 1940, '41, '42, '44, '46*, '47, '48, '49, '50, '51, '52, '53, '54, '55, '56*, '57, '58, '59, '60, '61, '62, '63, '64, '65*.
1948. WILLIAMS, HENRY L., 2nd, 54th St. & 48th Ave., Minneapolis 17, Minnesota, 1948, '49, '50*, '51, '52*, '53, '54, '55, '56, '57, '58*, '59, '60, '62, '63, '64, '65.
1951. WOODMAN, DEGRAAF, Talbottown Lane, P. O. Box 560, Easton, Md., 1951, '53, '54, '55*, '56, '58, '59, '60, '61, '62, '63, '64, '65.
1953. WORK, WALTER P., University Hospitals, Ann Arbor, Michigan, 1953, '54, '56, '58, '59*, '62, '63*, '65.

Honorary Fellows

1957. (1925) CLERF, LOUIS H., 5575 Eighth Avenue, North, St. Petersburg 2, Florida, 1957, '58, '59, '60, '61, '63, '64, '65.
1960. (1928) HILL, FREDERICK THAYER, Thayer Memorial Hospital, Waterville, Maine, 1960, '61, '63, '64.
1957. (1930) NEGUS, SIR VICTOR E., Hill Farm Lodge, Haslemere, Surrey, England, 1957*.
1957. (1924) PROETZ, ARTHUR W., 12 Westmoreland Place, St. Louis 8, Missouri, 1957, '58, '59, '60, '62.

Corresponding Fellows

1946. ALONSO, REGULES JUSTO E., Mercedes 1233, Montevideo, Uruguay.
1959. BARRETTO, PLINIO DE MATTOS, Ru Cons Torres, Homer 371, Sao Paulo, Brazil, 1960.
1959. BATEMAN, GEOFFREY H., 55 Harley Street, London W.1., England.
1942. BATSON, OSCAR V., 203 South DeKalb St., Philadelphia 4, Pennsylvania, 1942*, '54*.
1964. CLEVES, CARLOS, Carrera 14 No. 44-54, Apto. 202, Bogota, Colombia, S.A.
1943. EGGSTON, ANDREW A., 653 Park Avenue, New York, N. Y., 1944, '49, '55, '60, '61*.
1961. FAABORG-ANDERSEN, K., Central Hospital, Nykøbing, Falster, Denmark, 1961, '65.
1957. HUIZINGA, EELCO, Noorderhaven 7, Groningen, The Netherlands, 1957.
1957. ONO, JO, 75 Zaimoku-cho, Azabu, Minato-ku, Tokyo, Japan, 1957.
1964. PEREZ, ALFREDO C., Instituto Celis Perez, Avenida Montes de Oca, Apartado 163, Valencia, Venezuela, S.A., 1965.

1937. PORTMANN, GEORGES, 25 bis Cours de Verdun, Bordeaux, France, 1947.
1957. RUEDI, LUZIUS, Ramistrasse 100, Zurich, Switzerland, 1957.
1924. SCHAEFER, J. PARSONS, 4634 Spruce Street, Philadelphia 39, Pennsylvania, 1934.
1952. TAPIA ACUNA, RICARDO, Av. Insurgentes Sur 300, Mexico 7 D.F., 1953, '57, '60*.
1936. VIALLE, JACQUES, 27 Rue de France, Nice (Alpes Maritimes), France.

Emeritus Fellows

1941. (1923) BARLOW, ROY A., Musquodoboit Harbor, Nova Scotia, Canada.
1951. (1944) BEATTY, HUGH G., 390 Oak St., Apt. No. 35, Columbus 15, Ohio, 1951, '52, '53.
1965. (1942) CANFIELD, NORTON, Harwood Hospital, Christiansted, St. Croix, Virgin Is.
1964. (1941) DIXON, FRED W., 19101 Van Aken Blvd., Shaker Heights 22, Ohio, 1964.
1958. (1930) FIGI, FREDERICK A., Mayo Clinic, Rochester, Minnesota.
1961. (1936) GALLOWAY, THOMAS CYRUS, 636 Church St., Evanston, Illinois, 1961, '62, '64.
1951. (1928) GITTINS, THOMAS R., 408 Davidson Bldg., Sioux City, Iowa.
1963. (1928) GOODYEAR, HENRY M., 556 Doctors' Building, Cincinnati 2, Ohio.
1960. (1940) HANSEL, FRENCH, 634 N. Grand Blvd., St. Louis 3, Missouri, 1962, '65.
1957. (1944) HAVENS, FRED Z., 102 Second Avenue S.W., Rochester, Minnesota.
1955. (1930) HOUSER, KARL M., 2035 Delancey Street, Philadelphia 3, Pennsylvania.

1951. (1928) JARVIS, DEFOREST C., Quarry Bank Bldg., Barre, Vt., 1952.
1960. (1942) KELLY, JOSEPH D., 140 East Fifty-fourth Street, New York 22, N. Y.
1961. (1950) KLINE, ORAM R., 514 Cooper Street, Camden, N. J., 1961, '63.
1954. (1927) LUKENS, ROBERT M., 141 West Heather Road, Wildwood Crest, N. J.
1964. (1952) MCCALL, JULIUS W., 610 Rose Building, Cleveland 15, Ohio, 1964.
1959. (1927) MYERSON, MERVIN C., 435 No. Bedford Drive, Beverly Hills, Calif.
1957. (1948) PHELPS, KENNETH A., 1850 Willow Road, Palo Alto, Calif. 1958.
1958. (1938) SALINGER, SAMUEL, 1260 East Alejo Road, Palm Springs, Calif., 1958, '59, '61, '62, '63, '64, '65.
1962. (1932) SCHALL, LEROY A., Scudder Lane, Barnstable, Mass., 1964.
1964. (1934) SCHENCK, HARRY P., 326 South 19th Street, Philadelphia 3, Pa., 1964, '65*.
1965. (1939) SIMPSON, W. LIKELY, 351 South Highland St., Memphis, Tenn.
1965. (1943) VAN ALYEA, OLIVER E., 135 South LaSalle St., Chicago 3, Ill., 1965.
1961. (1941) VIOLÉ, PIERRE P., 241 South Windsor, Los Angeles, Calif., 1964.
1963. (1948) WHALEN, EDWARD J., 750 Main Street, Hartford, Connecticut.
1964. (1948) WILLIAMS, HENRY L., II, U. S. Veterans' Hospital, Minneapolis 17, Minn., 1964, '65.
1951. (1935) WOODWARD, FLETCHER D., 1326 Rugby Road, Charlottesville, Va., 1959, '60, '61.

BENEFACTORS

DR. JOHN F. BARNHILL

DR. GORDON BERRY

DR. EDWIN N. BROYLES

DR. WILLIAM E. CASSELBERRY

DR. LOUIS H. CLERF

DR. CORNELIUS COAKLEY

DR. & MRS. FRANCIS W. DAVISON

DR. & MRS. LEE WALLACE DEAN

DR. ARTHUR W. DEROALDES

DR. FRED W. DIXON

DR. WILLIAM E. GROVE

DR. GORDON F. HARKNESS

DR. FREDERICK T. HILL

DR. & MRS. GEORGE E. HOURN

DR. SAMUEL JOHNSTON

DR. JAMES E. NEWCOMB

DR. HENRY B. ORTON

DR. SAMUEL SALINGER

DR. SAM H. SANDERS

DR. HARRY P. SCHENCK

DR. BURT R. SHURLY

MR. LESTER T. SUNDERLAND

DR. H. MARSHALL TAYLOR

DR. WALTER H. THEOBALD



Obverse of the deRoaldes medal

RECIPIENTS OF THE DEROALDES AWARD

- 1928. DR. CHEVALIER JACKSON
- 1931. DR. D. BRYSON DELAVAN
- 1934. DR. HARRIS P. MOSHER
- 1937. DR. LEE WALLACE DEAN
- 1943. DR. RALPH A. FENTON
- 1949. DR. GEORGE M. COATES
- 1951. DR. ARTHUR W. PROETZ
- 1954. DR. LOUIS H. CLERF
- 1959. DR. ALBERT C. FURSTENBERG
- 1960. DR. DEAN M. LIERLE
- 1961. DR. FREDERICK T. HILL

RECIPIENTS OF THE CASSELBERRY AWARD

1923. DR. GEORGE FETTEROLF AND DR. HERBERT FOX
1928. DR. RALPH A. FENTON AND DR. O. LARSELL
1929. DR. RICHARD A. KERN AND DR. HARRY P. SCHENCK
1929. DR. EDWARD H. CAMPBELL
1931. DR. ARTHUR W. PROETZ
1934. DR. ANDERSON C. HILDING
1936. DR. FRANCIS E. LEJEUNE: DR. JOEL J. PRESSMAN
1939. DR. H. MARSHALL TAYLOR: DR. BRIEN T. KING
1940. DR. FRENCH K. HANSEL
1941. DR. NOAH D. FABRICANT
1946. DR. PAUL H. HOLINGER
1949. DR. HENRY B. ORTON
1962. DR. HANS VON LEDEN

RECIPIENTS OF THE NEWCOMB AWARD

- 1941. DR. BURT R. SHURLY
- 1942. DR. FRANCIS R. PACKARD
- 1943. DR. GEORGE M. COATES
- 1944. DR. CHARLES J. IMPERATORI
- 1947. DR. HARRIS P. MOSHER
- 1948. DR. GORDON BERRY
- 1949. DR. GORDON B. NEW
- 1950. DR. H. MARSHALL TAYLOR
- 1951. DR. JOHN D. KERNAN
- 1952. DR. WILLIAM J. McNALLY
- 1953. DR. FREDERICK T. HILL
- 1954. DR. HENRY B. ORTON
- 1955. DR. THOMAS C. GALLOWAY
- 1956. DR. DEAN M. LIERLE
- 1957. DR. GORDON F. HARKNESS
- 1958. DR. ALBERT C. FURSTENBERG
- 1959. DR. HARRY P. SCHENCK
- 1960. DR. JOEL J. PRESSMAN
- 1961. DR. CHEVALIER L. JACKSON
- 1962. DR. PAUL H. HOLINGER
- 1963. DR. FRANCIS E. LEJEUNE
- 1964. DR. FRED W. DIXON
- 1965. DR. EDWIN N. BROYLES

PAST OFFICERS

Presidents

(Year of Election)

| | | | |
|-------|--------------------|-------|------------------------|
| 1879. | Louis Elsberg | 1909. | J. E. Logan |
| 1880. | J. Solis-Cohen | 1910. | D. Braden Kyle |
| 1881. | F. I. Knight | 1911. | James E. Newcomb |
| 1882. | G. M. Lefferts | 1912. | George A. Leland |
| 1883. | F. H. Bosworth | 1913. | Thomas Hubbard |
| 1884. | E. L. Shurly | 1914. | Alexander W. MacCoy |
| 1885. | Harrison Allen | 1915. | G. Hudson Makuen |
| 1886. | E. Fletcher Ingals | 1916. | Joseph L. Goodale |
| 1887. | R. P. Lincoln | 1917. | Thomas H. Halstead |
| 1888. | E. C. Morgan | 1918. | Cornelius G. Coakley |
| 1889. | J. N. Mackenzie | 1919. | Norval H. Pierce |
| 1890. | W. C. Glasgow | 1920. | Harris P. Mosher |
| 1891. | S. W. Langmaid | 1921. | Harmon Smith |
| 1892. | M. J. Asch | 1922. | Emil Mayer |
| 1893. | D. Bryson Delavan | 1923. | J. Payson Clark |
| 1894. | J. O. Roe | 1924. | Lee Wallace Dean |
| 1895. | W. H. Daly | 1925. | Greenfield Sluder |
| 1896. | C. H. Knight | 1926. | Chevalier Jackson |
| 1897. | T. R. French | 1927. | D. Bryson Delavan |
| 1898. | W. E. Casselberry | 1928. | Charles W. Richardson |
| 1899. | Samuel Johnston | 1929. | Lewis A. Coffin |
| 1900. | H. L. Swain | 1930. | Francis R. Packard |
| 1901. | J. W. Farlow | 1931. | George E. Shambaugh |
| 1902. | J. H. Bryan | 1932. | George Fetterolf |
| 1903. | J. H. Hartman | 1933. | George M. Coates |
| 1904. | C. C. Rice | 1934. | Dunbar Roy |
| 1905. | J. W. Gleitsman | 1935. | Burt R. Shurly |
| 1906. | A. W. deRoaldes | 1936. | William B. Chamberlain |
| 1907. | H. S. Birkett | 1937. | John F. Barnhill |
| 1908. | A. Coolidge, Jr. | 1938. | George B. Wood |

| | |
|-------------------------------|-----------------------------|
| 1939. James A. Babbitt | 1953. Gordon F. Harkness |
| 1940. Gordon Berry | 1954. Henry B. Orton |
| 1941. Thomas E. Carmody | 1955. Bernard J. McMahon |
| 1942-3. Charles J. Imperatori | 1956. LeRoy A. Schall |
| 1944-5. Harold I. Lillie | 1957. Harry P. Schenck |
| 1946. Frank R. Spencer | 1958. Fred W. Dixon |
| 1947. Arthur W. Proetz | 1959. William J. McNally |
| 1948. Frederick T. Hill | 1960. Edwin N. Broyles |
| 1949. Ralph A. Fenton | 1961. Dean M. Lierle |
| 1950. Gordon B. New | 1962. Francis E. LeJeune |
| 1951. H. Marshall Taylor | 1963. Anderson C. Hilding |
| 1952. Louis H. Clerf | 1964. Albert C. Furstenberg |

Vice-Presidents

| | |
|-----------------------|-------------------|
| 1879. F. H. Davis | J. O. Roe |
| 1880. W. C. Glasgow | W. Porter |
| 1881. E. L. Shurly | E. F. Ingals |
| 1882. C. Seiler | S. Johnston |
| 1883. S. W. Langmaid | W. H. Daly |
| 1884. J. H. Hartman | G. W. Major |
| 1885. H. A. Johnson | J. N. Mackenzie |
| 1886. E. C. Morgan | S. W. Langmaid |
| 1887. J. N. Mackenzie | C. E. DeM. Sajous |
| 1888. W. C. Glasgow | C. E. Bean |
| 1889. E. Holden | J. H. Hartman |
| 1890. J. O. Roe | S. Johnston |
| 1891. M. J. Asch | J. C. Mulhall |
| 1892. S. Johnston | W. E. Casselberry |
| 1893. J. C. Mulhall | S. H. Chapman |
| 1894. C. C. Rice | A. W. deRoaldes |
| 1895. J. Wright | D. N. Rankin |
| 1896. T. M. Murray | H. S. Birkett |
| 1897. A. W. MacCoy | F. W. Hinkel |
| 1898. J. W. Farlow | M. R. Brown |
| 1899. T. A. DeBlois | A. A. Bliss |
| 1900. H. L. Wagner | |

| | |
|-----------------------------|---------------------|
| 1901. J. W. Gleitsmann | D. Braden Kyle |
| 1902. G. A. Leland | T. Melville Hardie |
| 1903. J. H. Lowman | W. Peyre Porcher |
| 1904. Thomas Hubbard | W. J. Freeman |
| 1905. J. L. Goodale | C. W. Richardson |
| 1906. G. H. Makuen | A. B. Thrasher |
| 1907. J. P. Clark | J. E. Rhodes |
| 1908. E. Mayer | F. R. Packard |
| 1909. C. G. Coakley | H. P. Mosher |
| 1910. Robert C. Myles | J. M. Ingersoll |
| 1911. F. C. Cobb | B. R. Shurly |
| 1912. A. W. Watson | W. Scott Renner |
| 1913. F. E. Hopkins | Geo. F. Shambaugh |
| 1914. Clement T. Theisen | Lewis A. Coffin |
| 1915. J. Gordon Wilson | Christian R. Holmes |
| 1916. Thomas H. Halsted | Greenfield Sluder |
| 1917. John Edwin Rhodes | D. Crosby Greene |
| 1918. G. E. Shambaugh | John R. Winslow |
| 1919. Francis R. Packard | Harmon Smith |
| 1920. Harmon Smith | W. B. Chamberlin |
| 1921. Dunbar Roy | Robert C. Lynch |
| 1922. George Fetterolf | Lorenzo B. Lockard |
| 1923. Hubert Arrowsmith | Joseph B. Greene |
| 1924. Ross H. Skillern | Gordon Berry |
| 1925. John E. Mackenty | Robert Levy |
| 1926. Lewis A. Coffin | William V. Mullin |
| 1927. Charles W. Richardson | Hill Hastings |
| 1928. Robert Clyde Lynch | Francis P. Emerson |
| 1929. William B. Chamberlin | Ralph Albert Fenton |
| 1930. Harris P. Mosher | James A. Babbitt |
| 1931. Joseph B. Greene | E. Ross Faulkner |
| 1932. Gordon Berry | Frank A. Spencer |
| 1933. E. Ross Faulkner | Thomas S. Carmody |
| 1934. Gordon B. New | Samuel McCullagh |
| 1935. Edward C. Sewall | H. Marshall Taylor |

| | |
|------------------------------|----------------------|
| 1936. William P. Wherry | Harold I. Lillie |
| 1937. Frank R. Spencer | Bernard J. McMahon |
| 1938. Ralph A. Fenton | Frederick T. Hill |
| 1939. John H. Foster | Thomas R. Gittins |
| 1940. Charles H. Porter | Gordon F. Harkness |
| 1941. Arthur W. Proetz | Henry B. Orton |
| 1942-3. Harold I. Lillie | Dean M. Lierle |
| 1944-5. John J. Shea | Thomas C. Galloway |
| 1946. H. Marshall Taylor | C. Stewart Nash |
| 1947. John J. Shea | Frederick A. Figi |
| 1948. Henry B. Orton | Anderson C. Hilding |
| 1949. LeRoy A. Schall | Fletcher D. Woodward |
| 1950. W. Likely Simpson | Lyman G. Richards |
| 1951. Wm. J. McNally | Thomas C. Galloway |
| 1952. J. Mackenzie Brown | Edwin N. Broyles |
| 1953. Claude C. Cody | Daniel S. Cuning |
| 1954. James H. Maxwell | Clyde A. Heatly |
| 1955. Robert L. Goodale | Paul H. Holinger |
| 1956. Henry M. Goodyear | Robert E. Priest |
| 1957. Francis E. LeJeune | Pierre P. Viole |
| 1958. Charles Blassingame | Chevalier L. Jackson |
| 1959. James Maxwell | Oliver Van Alyea |
| 1960. Walter Theobald | Anderson Hilding |
| 1961. Julius W. McCall | P. E. Ireland |
| 1962. Paul M. Moore | Jerome A. Hilger |
| 1963. Paul M. Holinger | Lester A. Brown |
| 1964. G. Slaughter Fitz-Hugh | Daniel C. Baker |

Secretaries and Treasurers

| | |
|-------------------------|---------------------|
| 1879. G. M. Lefferts | 1895. H. L. Swain |
| 1882. D. Bryson Delavan | 1900. P. E. Newcomb |
| 1889. C. H. Knight | 1911. Harmon Smith |

Secretaries

| | |
|-------------------------|------------------------|
| 1912. Harmon Smith | 1919. J. M. Ingersoll |
| 1918. D. Bryson Delavan | 1920. George M. Coates |

| | |
|-----------------------------|-------------------------|
| 1933. William V. Mullin | 1947. Louis H. Clerf |
| 1935. James A. Babbitt | 1952. Harry P. Schenck |
| 1939. Charles J. Imperatori | 1957. James H. Maxwell |
| 1942. Arthur W. Proetz | 1959. Lyman G. Richards |

Treasurers

| | |
|-----------------------------|--------------------------|
| 1912. J. Payson Clark | 1939. Frederick T. Hill |
| 1923. George Fetterolf | 1948. Gordon F. Harkness |
| 1932. William V. Mullin | 1953. Fred W. Dixon |
| 1933. James A. Babbitt | 1958. Francis E. LeJeune |
| 1935. Charles J. Imperatori | 1962. Alden H. Miller |

Librarians

| | |
|----------------------|------------------------|
| 1879. F. H. Bosworth | 1930. John F. Barnhill |
| 1883. T. R. French | 1934. Burt R. Shurly |
| 1903. J. H. Bryan | 1935. George M. Coates |

Librarian and Historian

| | |
|------------------------|----------------------|
| 1936. George M. Coates | 1944. Louis H. Clerf |
|------------------------|----------------------|

Librarian, Historian and Editor

| | |
|--------------------------|--------------------------|
| 1947. Harry P. Schenck | 1955. Edwin N. Broyles |
| 1952. Bernard J. McMahon | 1960. Francis W. Davison |
| 1964. F. Johnson Putney | |

PAST FELLOWS

Dates indicate original election to the Association

**Deceased*

Honorary Fellows

- *1908. Barnhill, John F., Miami Beach, Florida.
- *1893. Birkett, Herbert S., Montreal, Canada.
- *1878. Bosworth, Francke H., New York City.
- *1917. Coates, George M., Philadelphia, Pa.
- *1918. Dean, Lee Wallace, St. Louis, Mo.
- *1881. Delavan, D. Bryson, New York City.
- *1893. deRoaldes, Arthur W., New Orleans, La.
- *1890. De La Sota Y. Lastra, Ramon, Seville, Spain.
- *1923. Fenton, Ralph A., Portland, Oregon
- *1879. French, Thomas R., Brooklyn, N. Y.
- *1880. Garcia, Senior Manuel, London, England.
- *1903. Harris, Thos. J., New York City.
- *1907. Jackson, Chevalier, Schwenksville, Pa.
- *1878. Johnston, Samuel, Baltimore, Md.
- *1878. Lefferts, George Morewood, Katonah, N. Y.
- *1914. Levy, Robert, Denver, Colo.
- *1918. Lewis, Fielding O., Media, Pa.
- *1883. Mackenzie, John N., Baltimore, Md.
- *1881. Mackenzie, Sir Morel, London, England.
- *1910. Masser, Ferdinand, Naples, Italy.
- *1904. Mosher, Harris P., Marblehead, Mass.
- *1910. Moure, J. J. E., Bordeaux, France.
- *1937. Nager, F. R., Zurich, Switzerland.
- *1918. Oliver, H. K., Boston, Mass.
- *1906. Pierce, Norval Harvey, San Diego, Calif.
- *1909. Semon, Sir Felix, Great Missenden, England.
- *1878. Solis-Cohen, J., Philadelphia, Pa.
- *1889. Swain, Henry L., New Haven, Conn.
- *1914. Thomson, Sir St. Clair, London, Eng.
- *1903. Tilley, Herbert, London, England.
- *1914. Wagner, Clinton, New York City.
- *1890. Wright, Jonathan, Pleasantville, N. Y.

Corresponding Fellows

- *1892. Browne, Lennox, London, England.
- *1938. Blair, Vilray P., St. Louis, Missouri.
- *1940. Colledge, Lionel, London, England.
- *1901. Collier, Mayo, Kearsney Abbey, Kent, England.
- *1893. Desvernine, Carlos M., Havana, Cuba.
- *1930. Emerson, Francis P., Franklin, Mass.
- *1936. Fraser, John S., Edinburgh, Scotland.
- *1901. Grant, Sir James Dundas, London, England.
- *1887. Cougenheim, A., Paris, France.
- *1894. Holden, Edgar, Newark, N. J.
- *1919. Kelly, Adam Brown, Helensburgh, Scotland.
- *1881. Labus, Carlo, Milan, Italy.
- *1950. Larsell, Olof, Portland, Oregon.
- *1931. LasSagna, Francesco, Parma, Italy.
- *1926. Law, Frederick M., New York, N. Y.
- *1921. LeMaitre, Ferdinand, Paris, France.
- *1902. Lermoyez, Marcel, Paris, France.
- *1897. Luc, H., Paris, France.
- *1896. MacDonald, Greville, Haslemere, Surrey, England.
- *1894. MacIntyre, John, Glasgow, Scotland.
- *1903. McBride, P., York, England.
- *1920. McKenzie, Dan, London, England.
- *1919. McKernon, James F., New Canaan, Conn.
- *1880. Meyer, Wilhelm, Copenhagen, Denmark.
- *1910. Moure, J. J. E., Bordeaux, France.
- *1896. Mygind, Holger, Copenhagen, Denmark.
- *1950. Neil, James Hardie, Auckland, New Zealand.
- *1919. Paterson, Donald Rose, Cardiff, Wales.
- *1941. Patterson, Norman, Herts, England.
- *1919. Rogers, John, Jr., New York City.
- *1894. Sajous, C. E. DeM., Philadelphia, Pa.
- *1896. Schmiegelow, Ernst, Copenhagen, Denmark.
- *1946. Segura, Eliseo, Buenos Aires, Argentina.
- *1940. Soto, E. Fernandez, Havana, Cuba.
- *1881. Thornton, Pugin, London, England.
- *1913. Turner, A. Logan, Edinburgh, Scotland.
- *1880. Whistler, W. McNeil, London, England.
- *1901. Wingrave, Wyatt, Lyme Regis, Dorset, England.
- *1894. Wolfenden, R. Norris, Kent, England.

Emeritus Fellows

- *1936. Ballenger, Howard C., Winnetka, Ill.
- *1915. Barnes, Harry Aldrich, Kingston, Mass.
- *1928. Beck, Joseph C., Chicago, Illinois.
- *1921. Berry, Gordon, Worcester, Mass.
- *1941. Bowers, Wesley C., New York, N. Y.
- *1901. Brown, J. Price, Toronton, Canada.
- *1891. Bryan, Joseph H., Washington, D. C.
- *1913. Butler, Ralph, Philadelphia, Pa.
- *1930. Campbell, Edward H., Philadelphia, Pa.
- *1897. Clark, J. Payson, Boston, Mass.
- *1899. Cobb, Frederick C., Bradenton, Florida.
- *1939. Cody, Claude C., Jr., Houston, Texas.
- *1905. Coffin, Lewis A., New York City.
- *1893. Coolidge, Algernon, Boston, Mass.
- *1937. Crowe, Samuel J., Baltimore, Maryland.
- *1941. Cuning, Daniel S., New York City.
- *1913. Dabney, Virginius, Washington, D. C.
- *1882. De Blois, Thomas Amory, Boston, Mass.
- *1892. Farlow, John W., Boston, Mass.
- *1922. Forbes, Henry H., New York City.
- *1933. Foster, John H., Houston, Texas.
- *1905. Freer, Otto T., Chicago, Ill.
- *1940. Gatewood, E. Tribble, Richmond, Va.
- *1880. Gleitsmann, Joseph W., New York City.
- *1922. Goldsmith, Perry G., Toronto, Canada.
- *1898. Goodale, Joseph L., Ipswich, Mass.
- *1932. Graham, Harrington B., San Francisco, California.
- *1906. Greene, D. Crosby, Jr., Boston, Mass.
- *1917. Greene, Joseph B., Asheville, N. C.
- *1950. Hall, Colby, Encino, Calif.
- *1905. Halsted, Thomas H., Los Angeles, Calif.
- *1896. Hardie, Thomas Melville, Chicago, Ill.
- *1915. Hastings, Hill, Los Angeles, Calif.
- *1888. Hinkel, Frank Whitehill, Buffalo, New York.
- *1895. Hopkins, Frederick E., Springfield, Mass.
- *1927. Hubbard, Thomas, Toledo, Ohio.
- *1919. Hurd, Lee Maidment, Rowayton, Conn.
- *1920. Imperatori, Charles J., Essex, N. Y.
- *1904. Ingersoll, John Marvin, Miami, Fla.
- *1939. Johnston, William H., Santa Barbara, Calif.

- *1918. Kenyon, Elmer L., Chicago, Ill.
- *1921. Kernan, John D., New York
- *1929. Kistner, Frank B., Portland, Oregon.
- *1885. Knight, Charles H., New York City.
- *1939. Large, Secord H., Cleveland, Ohio.
- *1894. Leland, George A., Boston, Mass.
- *1922. Lillie, Harold I., Rochester, Minn.
- *1943. Lincoln, William R., Cleveland, Ohio.
- *1928. Lyman, Harry Webster, St. Louis, Mo.
- *1886. MacCoy, Alexander W., Philadelphia, Pa.
- *1941. Martin, Robert C., San Francisco, Cal.
- *1896. Mayer, Emil, New York City.
- *1951. McCart, Howard W. D., Toronto, Canada.
- *1939. McCaskey, Carl H., Indianapolis, Indiana.
- *1943. McCullagh, Samuel, New York, N. Y.
- *1923. McKinney, Richmond, Memphis, Tenn.
- *1939. Myers, John L., Kansas City, Mo.
- *1922. New, Gordon B., Rochester, Minn.
- *1878. Porter, William, Ocean Springs, Miss.
- *1901. Myles, Robert C., New York City.
- *1923. Newhart, Horace, Minneapolis, Minn.
- *1903. Packard, Francis R., Philadelphia, Pa.
- *1942. Potts, John B., Omaha, Nebr.
- *1903. Renner, W. Scott, Buffalo, N. Y.
- *1897. Rhodes, John Edwin, Chicago, Ill.
- *1884. Rice, Clarence C., New York City.
- *1905. Richards, George L., South Yarmouth, Mass.
- *1878. Robinson, Beverly, New York City.
- *1921. Sauer, William E., St. Louis, Mo.
- *1923. Sewall, Edward C., Palo Alto, Cal.
- *1930. Seydell, Ernest M., Wichita, Kansas
- *1907. Shambaugh, George E., Chicago, Ill.
- *1908. Smith, Harmon, New York City.
- *1923. Spencer, Frank R., Boulder, Colo.
- *1927. Tobey, Harold G., Boston, Mass.
- *1925. Tucker, Gabriel, Haverford, Pa.
- *1892. Wagner, Henry L., San Francisco, Calif.
- *1892. Watson, Arthur W., Philadelphia, Pa.
- *1922. White, Francis W., New York, N. Y.

Active Fellows

- *1939. Wilson, J. Gordon, Old Bennington, Vt.
- *1905. Wood, George B., Wynnewood, Pa.
- *1880. Allen, Harrison, Philadelphia, Pa.
- *1917. Arrowsmith, Hubert, Brooklyn, N. Y.
- *1879. Asch, Morris J., New York City.
- *1942. Ashley, Rae E., San Francisco, Cal.
- *1923. Babbitt, James A., Philadelphia, Pa.
- *1906. Ballenger, William L., Chicago, Ill.
- *1880. Bean, C. E., St. Paul, Minn.
- *1949. Beck, August L., New Rochelle, N. Y.
- *1904. Berens, T. Passmore, New York City.
- *1924. Bigelow, Nolton, Providence, R. I.
- *1938. Blassingame, Charles D., Memphis, Tenn.
- *1893. Bliss, Arthur Ames, Philadelphia, Pa.
- *1951. Boyden, Guy L., Portland, Oregon
- *1895. Boylan, J. E., Cincinnati, Ohio.
- *1932. Brown, John Mackenzie, Los Angeles, Calif.
- *1892. Brown, Moreau R., Chicago, Ill.
- *1933. Buckley, Robert E., New York City.
- *1915. Canfield, R. Bishop, Ann Arbor, Mich.
- *1934. Carmack, John Walter, Indianapolis, Ind.
- *1924. Carmody, Thomas E., Denver, Colo.
- *1889. Casselberry, William E., Chicago, Ill.
- *1883. Chamberlain, C. W., Hartford, Conn.
- *1917. Chamberlin, William B., Cleveland, Ohio.
- *1896. Chappell, W. F., New York City.
- *1882. Chapman, S. Hartwell, New Haven, Conn.
- *1902. Coakley, Cornelius G., New York City.
- *1913. Coffin, Rockwell C., Boston, Mass.
- 1918. Cox, Gerald H., New York City.
- *1880. Cushing, E. W., Boston, Mass.
- *1878. Cutter, Ephraim, West Falmouth, Mass.
- *1880. Daly, W. H., Pittsburgh, Pa.
- *1878. Davis, F. H., Chicago, Ill.
- *1941. Davis, Warren B., Philadelphia, Pa.
- 1926. Dennis, Frank Lownes, Colorado Springs, Col.
- *1901. Dickerman, E. T., Chicago, Ill.
- *1878. Donaldson, Frank, Baltimore, Md.
- *1947. Engler, Clarence W., Cleveland, Ohio.
- *1954. Equen, Murdock S., Atlanta, Ga.

- *1935. Eves, Curtis C., Philadelphia, Pa.
- *1919. Faulkner, E. Ross, New York City.
- *1914. Fetterolf, George, Philadelphia, Pa.
- *1901. Freeman, Walter J., Philadelphia, Pa.
- *1917. Friedberg, Stanton A., Chicago, Ill.
- 1940. Fuchs, Valentine H., New Orleans, La.
- *1897. Frothingham, Richard, New York City.
- 1909. Getchell, Albert C., Worcester, Mass.
- *1907. Gibb, Joseph S., Philadelphia, Pa.
- *1940. Gill, William D., San Antonio, Texas.
- *1878. Glasgow, William Carr, St. Louis, Mo.
- *1913. Goldstein, Max A., St. Louis, Mo.
- *1905. Grayson, Charles P., Philadelphia, Pa.
- *1934. Grove, William E., Milwaukee, Wisconsin.
- *1933. Harkness, Gordon F., Davenport, Iowa.
- *1878. Hartman, J. H., Baltimore, Md.
- *1945. Hickey, Harold L., Denver, Colo.
- *1879. Holden, Edgar, Newark, N. J.
- *1907. Holmes, Christian R., Cincinnati, Ohio.
- *1882. Hooper, Franklin H., Boston, Mass.
- *1893. Hope, George B., New York City.
- *1938. Hourn, George E., St. Louis, Mo.
- *1939. Hunt, Westley Marshall, New York, N. Y.
- *1901. Hyatt, Frank, Washington, D. C.
- *1925. Iglaue, Samuel, Cincinnati, Ohio.
- *1878. Ingals, E. Fletcher, Chicago, Ill.
- *1882. Ives, Frank L., New York City.
- *1938. Jackson, Chevalier L., Philadelphia, Pa.
- *1880. Jarvis, William C., New York City.
- *1878. Johnson, Hosmer A., Chicago, Ill.
- *1879. Johnson, Woolsey, New York City.
- *1960. Johnston, Kenneth C., Chicago, Ill.
- *1944. Jones, Marvin F., New York City.
- *1879. Kealhofer, R. H., St. Louis, Mo.
- *1942. King, Edward D., North Hollywood, Calif.
- *1901. King, Gordon, New Orleans, La.
- *1885. Knight, Charles H., New York City.
- *1878. Knight, Frederick Irving, Boston, Mass.
- *1898. Kyle, D. Braden, Philadelphia, Pa.
- *1880. Langmaid, Samuel W., Boston, Mass.
- *1878. Lincoln, Rufus P., New York City.

- *1911. Lockard, Lorenzo B., Denver, Colo.
- *1913. Loeb, Hanau W., St. Louis, Mo.
- *1897. Logan, James E., Kansas City, Mo.
- *1935. Looper, Edward A., Baltimore, Maryland.
- *1888. Lowman, John H., Cleveland, Ohio.
- *1919. Lynah, Henry L., New York City.
- *1952. Lynch, Mercer G., New Orleans, La.
- *1915. Lynch, Robert Clyde, New Orleans, La.
- *1879. McBurney, Charles, New York City.
- *1927. McGinnis, Edwin, Chicago, Ill.
- 1936. McGregor, Gregor, Toronto, Canada.
- *1913. McKimmie, O. A., Washington, D. C.
- *1945. McLaurin, John G., Dallas, Texas.
- *1885. McSherry, H. Clinton, Baltimore, Md.
- *1914. Mackenty, John E., New York City.
- *1898. Makuen, G. Hudson, Philadelphia, Pa.
- *1881. Major, G. W., Montreal, Canada.
- *1948. Maxwell, James H., Ann Arbor, Mich.
- *1881. Morgan, E. C., Washington, D. C.
- *1950. Morrison, Lewis F., San Francisco, Calif.
- *1940. Morrison, William W., New York City.
- *1886. Mulhall, J. C., St. Louis, Mo.
- *1925. Mullin, William V., Cleveland, Ohio.
- *1914. Munger, Carl E., Waterbury, Conn.
- *1892. Murray, T. Morris, Washington, D. C.
- *1881. Mynter, H., Buffalo, N. Y.
- *1893. Newcomb, James E., New York City.
- *1895. Nichols, J. E. H., New York City.
- *1927. Orton, Henry B., Newark, N. J.
- *1894. Park, William H., New York City.
- *1892. Porcher, W. Peyre, Charleston, S. C.
- *1927. Porter, Charles T., Boston, Mass.
- *1908. Randall, B. Alexander, Philadelphia, Pa.
- *1882. Rankin, D. N., Allegheny, Pa.
- *1902. Richardson, Charles W., Washington, D. C.
- *1930. Ridpath, Robert E., Philadelphia, Pa.
- *1879. Roe, John O., Rochester, N. Y.
- *1945. Robb, James M., Detroit, Michigan.
- *1881. Robertson, J. M., Detroit, Mich.
- *1913. Roy, Dunbar, Atlanta, Ga.
- *1878. Rumbold, T. F., St. Louis, Mo.

- *1879. Seiler, Carl, Philadelphia, Pa.
- *1928. Shea, John Joseph, Memphis, Tennessee.
- *1893. Shields, Charles M., Richmond, Pa.
- *1909. Shurly, Burt R., Detroit 1, Mich.
- *1878. Shurly, E. L., Detroit, Mich.
- *1892. Simpson, William Kelly, New York City.
- *1919. Skillern, Ross H., Philadelphia, Pa.
- *1909. Sluder, Greenfield, St. Louis, Mo.
- *1879. Smith, Andrew H., Geneva, N. Y.
- *1932. Smyth, Duncan Campbell, Boston, Mass.
- *1928. Sonnenschein, Robert, Chicago, Ill.
- 1924. Stein, Otto J., Chicago, Ill.
- 1934. Stevenson, Walter, Quincy, Ill.
- *1911. Staut, George C., Philadelphia, Pa.
- *1879. Tauber, Bernhard, Cincinnati, Ohio.
- *1924. Taylor, Hermon Marshall, Jacksonville, Fla.
- *1903. Theisen, Clement F., Albany, N. Y.
- *1899. Thorner, Max, Cincinnati, Ohio.
- *1892. Thrasher, Allen B., Cincinnati, Ohio.
- *1937. Tobey, George L., Jr., Boston, Mass.
- *1888. Van der Poel, S. O., New York City.
- *1938. Vail, Harris H., Cincinnati, Ohio.
- *1936. Voislowsky, Antonie P., New York City.
- *1933. Wanamaker, Allison T., Seattle, Wash.
- 1896. Ward, Marshall R., Pittsburgh, Pa.
- *1879. Ward, Whitfield, New York City.
- *1886. Westbrook, Benjamin F., Brooklyn, N. Y.
- *1924. Wherry, William P., Omaha, Neb.
- *1924. White, Leon E., Boston, Mass.
- *1939. Williams, Horace J., Philadelphia, Pa.
- *1942. Wishart, D. E. Staunton, Toronto, Canada.
- *1922. Wishart, David J. G., Toronto, Ontario.
- *1940. Wood, V. Visscher, St. Louis, Mo.
- *1896. Wollen, Green V., Indianapolis, Ind.
- *1953. Wilkerson, William W., Nashville, Tenn.

INDEX

to the

TRANSACTIONS

of the

AMERICAN
LARYNGOLOGICAL ASSOCIATION

1965

INDEX

A

| | |
|--|----|
| Address | |
| President: Furstenberg, A. C. | 11 |
| Articular Reflex Mechanisms of the Larynx (Kirchner and Wyke) | 16 |

B

| | |
|---------------------------------------|-----|
| Baxter, James D. | |
| Glomus tumor of the larynx | 86 |
| Brown, Lester A. | |
| obituary of Murdock Sykes Equen | 183 |

C

| | |
|--|-----|
| Cells | |
| Mast, of upper respiratory tract (Schenck) | 147 |

D

| | |
|---------------------------|-----|
| Dickey, J. R. | |
| (see Harris, H. H.) | 168 |

E

| | |
|---|-----|
| Eagle, Watt W. | |
| Lipoma: epiglottis, 1947, hypopharynx, 1961 (same patient) .. | 133 |
| Endotracheal Intubation | |
| Histologic Changes Produced by (Sooy and Way) | 69 |
| Epiglottis | |
| lipoma of (Eagle) | 133 |

F

| | |
|---|----|
| Friedberg, Stanton A. | |
| Histologic Changes in the Trachea following Tracheostomy (with Thomas E. Griffith and George M. Hass) | 53 |

| | |
|--|-----|
| Frontal Sinus | |
| Osteoplastic approach: coronal incision (Montgomery) | 94 |
| Observations on Obliteration (Goodale) | 104 |
| Furstenberg, Albert C. | |
| President's Address | 11 |

G

| | |
|--|-----|
| Galloway, Thomas C. | |
| obituary of Howard Charles Ballenger | 180 |
| Glomus Tumor of Larynx (Baxter) .. | 86 |
| Goodale, Robert L. | |
| Observations on Frontal Sinus Obliteration | 109 |

| | |
|--|----|
| Grafts | |
| Use of Dermal in Otolaryngology (Reed) | 36 |
| Griffith, Thomas E. | |
| (see Friedberg, Stanton A.) | 53 |

H

| | |
|--|-----|
| Harris, Herbert H. | |
| Nerve grafting to restore function of the trapezius muscle after radical neck dissection (with J. R. Dickey) | 168 |
| Hass, George | |
| (see Friedberg, Stanton A.) | 53 |
| Histologic Changes in the Trachea Following Tracheostomy (Friedberg, Griffith and Hass) | 53 |
| Histologic Changes produced by Endotracheal Intubation (Sooy and Way) | 69 |
| Hypopharynx | |
| lipoma of (Eagle) | 133 |

I

Incision

- Coronal, for osteoplastic approach
to frontal sinus (Montgomery) 94

K

Kirchner, John A.

- Articular Reflex Mechanisms of
Larynx (with Barry D. Wyke) 16

L

Larynx

- Articular Reflex Mechanisms
(Kirchner and Wyke) 16

- Glossoma tumor of (Baxter) 86

- Lipoma of epiglottis (Eagle) 133

Lewy, Robert B.

- Teflon injection of posterior pharyngeal wall as an aid to velopharyngeal closure (with Joseph Wepman) 160

- Lipoma: epiglottis, 1947, hypopharynx, 1961 (same patient) (Eagle) 133

M

- Mast cells of the upper respiratory tract (Schenck) 147

Montgomery, William W.

- Osteoplastic frontal sinus approach: coronal incision 94

Muscle

- Trapezius, nerve grafting to restore function after radical neck dissection (Harris and Dickey) 168

N

Nerve Grafting

- To restore function of the trapezius muscle after radical neck dissection (Harris and Dickey) 168

Neck Dissection

- Nerve grafting to restore function of the trapezius muscle (Harris and Dickey) 168

Nose

- Methods for controlling polyposis and vasomotor rhinitis (Weille) 122

O

Obituaries:

- Ballenger, Howard Charles 180

- Eggen, Murdock Sykes 183

- Hall, Colby 187

- Lewis, Fielding Otis 190

- Martin, Robert Carson 193

Obliteration

- Frontal sinus (Goodale) 104

- Observations on frontal sinus obliteration (Goodale) 104

- Osteoplastic Frontal Sinus Approach: coronal incision (Montgomery) 94

P

Pharynx

- Teflon injection of posterior wall as aid to velopharyngeal closure (Lewy and Wepman) 160

Polyposis, nasal

- Rhinological methods for control (Weille) 122

R

Reed, George F.

- Use of Dermal Grafts in Otolaryngology 36

Respiratory Tract

- Mast cells of upper (Schenck) 147

- Rhinological Methods for Controlling Nasal Polyposis and Vasomotor Rhinitis (Weille) 122

S

- Schenck, Harry P.
 Mast cells of the upper respiratory tract 147
- Smith, Austin T.
 obituary of Fielding Otis Lewis ... 190
- Sooy, Francis A.
 Histologica Changes Produced by Endotracheal Intubation (with Walter L. Way) 69
- Sooy, Francis A.
 obituary of Robert Carson Martin 193

T

- Teflon Injection of Posterior Pharyngeal Wall as an Aid to Velo-Pharyngeal Closure (Lewy and Wepman) 160
- Trachea
 Histologic Changes following Tracheostomy (Friedberg, Griffith and Hass) 53
- Tracheostomy
 Histologic Changes in Trachea (Friedberg, Griffith and Hass) .. 53
- Tumor
 Glomus, of larynx (Baxter) 86

U

- Use of Dermal Grafts in Otolaryngology (Reed) 36

V

- Vasomotor rhinitis
 Rhinological methods for control (Weille) 122
- Velo-pharyngeal closure
 Teflon injection of posterior pharyngeal wall (Lewy and Wepman) 160
- Violé, Pierre P.
 obituary of Colby Hall 187

W

- Way, Walter L.
 (see Sooy, Francis A.) 69
- Weille, Francis L.
 Rhinological methods for controlling nasal polyposis and vasomotor rhinitis 122
- Wepman, Joseph
 (see Lewy, R. B.) 160
- Wyke, Barry D.
 (see Kirchner, J. A.) 16

