

Transactions

American Laryngological Association

EIGHTY-SEVENTH VOLUME

“DOCENDO DISCIMUS”

TRANSACTIONS
OF THE
EIGHTY-SEVENTH ANNUAL MEETING
OF THE
American
Laryngological Association

1966

HELD AT
THE AMERICANA HOTEL
SAN JUAN, PUERTO RICO
APRIL 23 AND 24, 1966

PUBLISHED BY THE ASSOCIATION

ST. LOUIS, MO.

1966

Contents.

	PAGE
List of Officers	7
Registration	9
Opening Remarks: Paul H. Holinger, M.D., President	11
Address of Guest of Honor: "The Best Milieu for Advancement of Otolaryngology," Francis L. Lederer, M.D.	15
Introduction of Guest Speaker	20
Histological Classification of Early Malignant Lesions of the Oral Cavity, Pharynx, and Larynx. George L. Wied, M.D.	21
Ultrastructure of Tracheal Cilia and Cells During Regeneration. David Hilding, M.D. and Anderson C. Hilding, M.D.	22
Discussion:	
John F. Daly, M.D.	35
Francis L. Weille, M.D.	35
Catherine Smith, Ph.D.	36
Dr. David Hilding (closing)	36
Replantation and Homotransplantation of the Canine Larynx. Joseph H. Ogura, M.D.	37
Discussion:	
Louis H. Clerf, M.D.	54
Histopathology of Larynges and Radical Neck Specimens in a Combined Radiation and Surgery Program for Advanced Carcinoma of the Larynx and Laryngopharynx. Joseph L. Goldman, M.D.	55

CONTENTS

	PAGE
Pre-operative Radiation in Head and Neck Surgery. Emanuel M. Skolnik, M.D.	78
Discussion:	
George A. Sisson, M.D.	97
Gabriel F. Tucker, Jr., M.D.	99
Douglas P. Bryce, M.D.	99
Dr. Goldman (closing)	100
Dr. Skolnik (closing)	101
Metastatic Carcinoma of the Esophagus. Joseph P. Atkins, M.D.	102
Discussion:	
J. Allan Fields, M.D.	113
Dr. Atkins (closing)	113
Exploration of the Mediastinum Under Local Anaesthesia. Paul H. Ward, M.D.	114
Discussion:	
Joseph L. Goldman, M.D.	125
Joseph P. Atkins, M.D.	125
John E. Bordley, M.D.	125
John L. Pool, M.D.	125
Dr. Ward (closing)	126
Surgical Correction of Choanal Atresia. Jerry Cherry, M.D.	127
Discussion:	
Charles F. Ferguson, M.D.	135
Dr. Cherry (closing)	135
Cricothyroid Arthrodesis. William M. Montgomery, M.D.	136
Discussion:	
Francis L. Lederer, M.D.	147
Douglas P. Bryce, M.D., F.R.C.S.(C)	147
David W. Brewer, M.D.	147
Dr. Montgomery (closing)	147

CONTENTS

	PAGE
Further Efforts for Correction of Severe Acute or Chronic Laryngeal Stenosis; Double Posted Teflon Tube Utilization. John S. Knight, M.D.	148
Discussion:	
William M. Montgomery, M.D.	154
Dr. Knight (closing)	154
An Approach to the Internal Laryngocele and Other Submucosal Lesions of the Larynx. C. T. Yarrington, Jr., M.D.	155
Discussion:	
W. Franklin Keim, M.D.	159
President Holinger	159
Dr. Yarrington (closing)	159
Prolapse of the Laryngeal Ventricle. Douglas P. Bryce, M.D., F.R.C.S.(C)	161
Discussion:	
John E. Bordley, M.D.	170
Jerome A. Hilger, M.D.	170
Francis L. Lederer, M.D.	170
Joseph P. Atkins, M.D.	170
W. Franklin Keim, M.D.	170
Dr. Bryce (closing)	170
Memorials:	
Roy Alexander Barlow	174
Fred Willis Dixon	175
Fred Z. Havens	178
Duncan MacPherson	181
Arthur Walter Proetz	184
Edward Joseph Whalen	189

CONTENTS

	PAGE
Executive Sessions and Reports of Officers and Committees	193
Presentation of de Roaldes Award	210
Presentation of Newcomb Award	211
Presentation of Casselberry Award	212
List of Fellows, 1966	213
Active Fellows	214
Honorary Fellows	220
Corresponding Fellows	221
Emeritus Fellows	222
Benefactors	224
Recipients of the de Roaldes Award	225
Recipients of the Casselberry Award	226
Recipients of the Newcomb Award	227
Past Officers	228
Past Fellows	233
Index	241



THOSE IN ATTENDANCE AT THE EIGHTY-SEVENTH ANNUAL MEETING

First row seated, left to right, Moore, Goldman, Miller, Schall, Cracovaner, Munoz-MacCormick, Holinger, Lederer, LeJeune, Hilding, Lierle, Theobald, Hill. *Second and third rows*, Boies, McCall, McCabe, Lewis, Saunders, Atkins, Smith, McGovern, Ireland, Woodman, Baker, McHenry, Williams, Ferguson, Jones, Daly, Eagle, Keim, Henry, Hoople, Lindsay, Meltzer, Tremble, Hanckel, Salinger, Simonton, Arnold. *Standing*, Skolnik, Galloway, Clerf, Hart, Norris, Suehs, Dohlman, Davison, Pressman, Harris, Baxter, Bryce, Dan Miller, Montgomery, Alexander, Ogura, Tabb, Sisson, Putney Pang.

OFFICERS FOR 1965-1966

PRESIDENT

PAUL H. HOLINGER, M.D.

FIRST VICE-PRESIDENT

CARLOS E. MUNOZ-MacCORMICK, M.D.

SECOND VICE-PRESIDENT

ARTHUR J. CRACOVANER, M.D.

SECRETARY

LYMAN G. RICHARDS, M.D.

TREASURER

ALDEN H. MILLER, M.D.

LIBRARIAN, HISTORIAN AND EDITOR

F. JOHNSON PUTNEY, M.D.

COUNCIL

The above Ex-officio and

DEAN M. LIERLE, M.D.

FRANCIS E. LEJEUNE, M.D.

ANDERSON C. HILDING, M.D.

ALBERT C. FURSTENBERG, M.D.

TRANSACTIONS OF THE
EIGHTY-SEVENTH ANNUAL MEETING

OF THE

American Laryngological Association

HELD AT

THE AMERICANA HOTEL

SAN JUAN, PUERTO RICO

APRIL 23 AND 24, 1966

The Eighty-seventh Annual Meeting of the American Laryngological Association was called to order by the President, Dr. Paul H. Holinger, at the Americana Hotel, San Juan, Puerto Rico on April 23, 1966, at 8:30 A.M.

REGISTRATION

ALEXANDER, FRED W.

ALFARO, VICTOR R.

ARNOLD, GODFREY E.

ATKINS, JOSEPH P.

BAKER, DANIEL C.

BAXTER, JAMES D.

BOIES, LAWRENCE R.

BORDLEY, JOHN E.

BREWER, DAVID W.

BRYCE, DOUGLAS P.

CLERF, LOUIS H.

CRACOVANER, ARTHUR J.

DALY, JOHN F.

DAVISON, FRANCIS W.

DEVINE, KENNETH

EAGLE, WATT W.

FEARON, BLAIR

FERGUSON, CHARLES F.

- | | |
|-------------------------|-----------------------------|
| FITZ-HUGH, G. SLAUGHTER | MONTGOMERY, WILLIAM W. |
| GALLOWAY, THOMAS C. | MOORE, PAUL M. |
| GOLDMAN, JOSEPH L. | MUNOZ-MACCORMICK, CARLOS E. |
| HANCKEL, RICHARD W. | MURTAGH, JOHN A. |
| HARRILL, JAMES A. | NORRIS, CHARLES M. |
| HARRIS, HERBERT | OGURA, JOSEPH H. |
| HART, VERLING K. | PANG, LUP Q. |
| HENRY, G. ARNOLD | PASTORE, PETER N. |
| HILDING, ANDERSON C. | PRESSMAN, JOEL J. |
| HILGER, JEROME A. | PUTNEY, F. JOHNSON |
| HILL, FREDERICK T. | REED, GEORGE F. |
| HOLINGER, PAUL H. | SALINGER, SAMUEL |
| HOOPLE, GORDON D. | SAUNDERS, WILLIAM H. |
| IRELAND, P. E. | SCHALL, LEROY A. |
| JONES, EDLEY H. | SCHENCK, HARRY P. |
| KEIM, W. FRANKLIN | SILCOX, LOUIS E. |
| KING, JAMES T. | SIMONTON, KINSEY M. |
| KNIGHT, JOHN S. | SISSON, GEORGE A. |
| LEDERER, FRANCIS L. | SKOLNIK, EMANUEL M. |
| LEJEUNE, FRANCIS E. | SMITH, AUSTIN T. |
| LEWIS, JOHN | SUEHS, OLIVER W. |
| LIERLE, DEAN H. | TABB, HAROLD G. |
| LINDSAY, JOHN R. | THEOBALD, WALTER H. |
| MCCABE, BRIAN | TREMBLE, G. EDWARD |
| MCCALL, JULIUS W. | VAN ALYEA, OLIVER E. |
| MCGOVERN, FRANCIS H. | WALSH, THEODORE E. |
| MCHENRY, LAWRENCE C. | WEILLE, FRANCIS L. |
| MELTZER, PHILIP E. | WILLIAMS, HENRY L. |
| MILLER, ALDEN H. | WOODMAN, DEGRAAF |
| MILLER, DANIEL | |

SCIENTIFIC SESSION

SATURDAY MORNING, APRIL 23, 1966

The first Scientific Session of the Eighty-seventh Annual Meeting of the American Laryngological Association, held at the Americana Hotel, San Juan, Puerto Rico, on Saturday morning, April 23, 1966, convened in the Arecibo Room at eight-forty o'clock, Paul H. Holinger, M.D., Chicago, Illinois, President of the Association, presiding.



REMARKS OF THE PRESIDENT

I deeply appreciate the honor of serving as President of the American Laryngological Association for 1966 and of presiding at this 87th Annual Meeting of the Association. This highest honor in our foremost specialty society carries the traditions of laryngologists handed down for almost a century. One cannot help but feel humble in reading the names on the gavel; I can assure you I do. There are, of course, obligations with the privilege of this office which I have endeavored to recognize and to some degree to fulfill. The Association has the responsibility of leadership in the specialty because we seem closer to general medicine and surgery than our sister specialty society. It is my hope that we will make every effort to avoid isolation through greater correlation of our activities with general medicine and surgery. To accomplish this we might best follow the lead suggested by Dr. Walter Heck, former Secretary of the Section of Laryngology of the AMA, whose guidance we deeply miss, and who brought the specialty societies into the Section program. The meetings last year, carried on so successfully by Drs. Victor Alfaro, George Sisson, Daniel Baker and Walter Maloney, with Dr. George Shambaugh as President of both the Triological and the Section of the AMA, were of tremendous importance to the specialty. Our senior groups, the American Laryngological Association and the American Otological Society, did not participate in this combined effort to support the AMA Section. I sincerely hope that they will do so in the

not too distant future. Only by such participation in our over-all parent medical group can our needs be made known and our efforts effective in directing our wishes into action for what is best in Otolaryngology and in medicine. Unless we state our views to this audience that is extremely anxious to have them, we cannot object if others step in and represent us in our stead. As leaders, we are looked toward for an expression of laryngological thought, and it is our obligation to express it where it will do the most good.

The year has been most interesting and rewarding. Dr. Lyman Richards has conducted the affairs of the Association with his usual thoroughness, interest, and finesse, and I have just received the following cable from him: "Best wishes for a successful, Secretaryless meeting. Warmest regards to the Fellows." We are all extremely sorry that at the last minute illness prevented Doctor Richards from being here, but I am pleased to state that we have word that he is progressing well and should be out and among us in the very near future. In the interim, my deepest appreciation to Dr. Francis LeJeune, former Treasurer of the Association, and then its President, and now on the Council, who kindly consented, at no more than a moment's notice, to take on the duties he had discharged so well some years back.

I shall take this opportunity to express my deep appreciation to the First Vice President, Dr. Carlos Munoz-MacCormick, for the excellence of his arrangements and the overwhelming hospitality here in San Juan. We all have enjoyed this week immeasurably, and find this meeting of the ALA a magnificent climax. To the Officers of the Council, I wish to extend my personal appreciation for carrying on the affairs of the Association so exceedingly well this past year.

I should like to direct these Presidential remarks toward a problem which concerns us all in Laryngology, namely, carcinoma-in-situ of the larynx. In the April issue of the Archives of Otolaryngology, 1966, Doctor Shambaugh published an editorial on this subject which points out the dilemma which we face in this problem. On the one hand we stress "conservation of function" in the management of cancer of the larynx, stressing the use of limited surgical procedures which just skirt the lesion, and on the other hand we talk of radical surgery for *potential* extension of malignancies that carry a relatively low rate of metastasis. Then there is a "grey zone" of which the diagnostic significance and definition needs clarification. We speak synonymously of "non-invasive carcinoma," "intra-epithelial carcinoma," "carcinoma?," "dysplasia," "acanthosis," "dyskeratosis," and

even in some instances obtain the clinical interpretation of the pathologist before he establishes the differentiation between a hyperkeratosis, a carcinoma-in-situ, or an actual borderline carcinoma of the larynx.

What are our definitions of these terms? What are our criteria for differentiating one from another? A variation of interpretation surely affects our patients, and a variation of interpretation most certainly affects statistics in our end result reports. Some centers report an unusually low or almost non-existent incidence of patients with hyperkeratosis of the larynx who ultimately are shown to have developed a carcinoma of the larynx, while other centers with equal statistical evidence of broad experience report an unusually high incidence of hyperkeratosis becoming malignant. With these "Presidential Remarks" I should like to pose a question. Can we as Fellows of the American Laryngological Association develop inflexible rules to define carcinoma of the larynx?

Fortunately, or unfortunately, we are not alone in our dilemma. We can compare our problems with those of gynecologists dealing with carcinoma of the cervix, where there is a much greater clinical experience on record and where pathologists and gynecologists are far ahead of us in studying this problem. They have enlisted an "International Committee for Histological Definitions" and have established criteria on which Dr. George Wied, our Guest Speaker, will elaborate later this morning. This Committee concerned itself with establishing definitions of invasive carcinoma, carcinoma-in-situ, and dysplasia, which are inflexible for carcinoma of the cervix. These are not intended to influence the choice of therapy, which still is the responsibility of the individual clinician. But for scientific uniformity of classification, these pathologic entities have been established to their own satisfaction in their own field. It will be my pleasure to introduce Doctor Wied later before his discussion.

At this time I have the privilege of introducing a man who has been selected by the American Laryngological Association as its Guest of Honor for 1966. He is a man who has done much for Otolaryngology in all ramifications of the specialty and in diverse areas of endeavor. I speak for the many men he has guided; for his direct impact on the teaching programs of the specialty; for his insight and help in organizational problems within the specialty; for the way he shares his rich clinical experience with students and colleagues both directly and occasionally with humor and a quick turn of a phrase; for his insistence that Otolaryngology maintain its position

in the forefront as a specialty, without apology; and, if I may add, for my debt to him personally in guidance and encouragement.

Dr. Francis Lederer has headed the Department of Otolaryngology at the University of Illinois since 1928 and, as a matter of fact, was my father's Chief in the Department there. He has always prided himself on the number of second-generation otolaryngologists in the Department, numbering 13 at one time. His biography includes citations, editorships, authorships, active and honorary society memberships too numerous to list here. He was a Private in the Marine Corps in World War I and a Commander in the Navy in the Second World War, receiving the Navy Commendation Ribbon for organization and administration of the Rehabilitation Program of the Blind and Hard-of-Hearing. His Navy experience took him through a crash landing in the African jungle and over the Hump in China before establishing this program in Philadelphia. Of his many awards he is probably proudest of the teaching awards presented him by his own students at the University of Illinois; they have given him the "Golden Apple"—well polished, I am sure—many times. He has had a profound influence on the course of Otolaryngology in the University, on the Board, in the government programs, and on the art and science of Otolaryngology.

ADDRESS OF GUEST OF HONOR

THE BEST MILIEU FOR ADVANCEMENT
OF OTOLARYNGOLOGY

FRANCIS L. LEDERER, M.D.

Medicine in general, and otolaryngology in particular, has been concerned with their image in the eyes of the public as well as in the hierarchy of the specialties. In medicine as in other walks of life, it is evident that where people regard one another with mutual trust and respect, the environment is more suited to progress than where a person has to defend himself from devastating criticism. It is comparatively easy to pit people against people, class against class, or group against group. Only the thinkers in a society can get people working together to build an atmosphere of mutual respect and good fellowship in which the learning process can flourish. Out of honest differences of opinion comes progress. Someone once expressed the thought that "no great ability is required to disorganize a group, but to hold people together for a constructive purpose is a challenge to the intellect."

On the facade of the National Archives Building in Washington, D.C., there are two significant statements, viz., STUDY THE PAST and WHAT IS PAST IS PROLOGUE. This leads me to comment upon 87 glorious years of The American Laryngological Association whose spirit reminds me of the words of Goethe, "It is delightful to transport oneself into the spirit of the past, to see how wise men have thought before us, and at what glorious heights we have at last reached."

Among other things history teaches us: we are not superior to our fathers and we are shamefully and monstrously inferior to them if we do not advance beyond them. Those unwilling to be guided or learn from history are condemned to lose by it. Thus, they are relics of otolaryngology of the past and become sign posts to the future. Such expressions are by no means novel and we are reminded that "Originality is undetected plagiarism." (Dean W. R. Inge)

There is a great difference between struggling for the purpose of advancing knowledge, and suppressing all schools of thought except one's own. It is indeed fortunate that we have so many schools of

thought. We in otolaryngology can devote all energy to the advancement of knowledge and positive drive instead of wasting our substance on matters personal. This does not mean either that we are to agree just for the sake of being agreeable or do we advocate a "follow-the-leader" philosophy, currently regarded as the "peck order." Today's challenge is heralded by a remark of John Henry Cardinal Newman (1801-90), "A man would do nothing if he waited until he could do it so well that no one would find fault with what he had done."

Examination of the otolaryngological milieu discloses that there are a number of problems. In order to find a solution is: admitting its existence, defining it, and then proceeding to understand the problem. Many of these problems were made startlingly clear while we were engaged in a fact-finding survey. They were:

1. A concern for the image of the specialty.
2. That other groups of specialty and general surgeons have sought to arbitrarily define the otolaryngologist's surgical areas without regard for individual background of training, skill, etc.
3. That departments of otolaryngology in some medical schools were either non-existent or were functioning without evidence of an understanding of the responsibility on the part of the university administration for the specialty and/or its place in the curriculum.
4. That we have not recognized or capitalized on the "acres of diamonds" before us, namely, the medical student, whose attention we should attract early by demonstrating the commonplace in our field so that it would relate to his preclinical and clinical background.
5. That needs of the nation for specialists in otolaryngology were so great that we must double the number of qualified men and women in the field.
6. That requisite to the selection of faculty and house staff, professional competence be defined.
7. That the role of the teacher be recognized and at the same time understanding the importance of research in conveying the scientific method in preparation for a clinical field characterized by changing patterns and concepts.

Ladies and gentlemen, it is not change just for the sake of change that must be sought. Napoleon once declared that one must alter tactics every decade in order to maintain superiority. In this regard, we are faced with the challenge of accepting or rejecting current approaches to the educational process. Today, the object of teaching is to enable the student to get along without the teacher. The main task of the teacher is neither to educate his students nor to stuff them with facts or theories, nor to display his own erudition. It is to make his students care about learning.

In every discussion concerned with residency training, the question arises as to what becomes of the "worthy" young man who is deemed unworthy or of the so-called slow learner. It begins with the responsibility every department of otolaryngology assumes to educate and train young men and women to meet the ever increasing need for competent physicians and surgeons, those capable of carrying out the practices and skills they learned in the many fine schools throughout the country.

Today, educators in otolaryngology have a greater responsibility than just training competent young surgeons to meet the growing needs of the public. If we are to maintain our place in this fast moving scientific age we must identify leadership potential at every educational level. We must discover young men who have the potential for being more than just good surgeons. We must find those who not only have the intellectual capacity to achieve academically but who also possess the vision, imagination, curiosity, aggressiveness and creativity, to set the pace and to be the leaders. It is generally accepted that a school is known *not* by the number of good students it turns out but by the number of leaders it produces.

We might as well admit that the future of our specialty depends upon *our* ability as administrators to seek out, train and develop leadership. We cannot just build the finest plant and provide it with the most sophisticated equipment and staff it with the best instructors. It is simply not enough to make otolaryngological education available and then sit back and wait for potential leaders to seek us out. Leadership is too rare a gem to entrust to chance—we must seek it out not only in the medical school but also at undergraduate levels.

It seems that we should begin with a re-evaluation and reorientation of our screening and selection methods. We might be less preoccupied with "screening out" and more concerned with "screen-

ing in" those qualities, traits and basic personality characteristics common to men who do not only achieve academically but go on to become leaders in their field. Those tests which are concerned primarily with the measurement of intellectual endowment, scholastic aptitude and boast of a "cut off" point at which the applicant for residency is accepted or "screened out" must be placed in a proper perspective. Our interviewing techniques and resulting decisions which can influence the career and life goals of the applicant; decisions which oftentimes are based on surface observation that "he seems to be a nice boy and appears to have done well in medical school" *must* be reappraised.

If we as administrators and educators are to make better judgments about the anticipated performance of physicians and surgeons; if we are to conscientiously estimate other factors which can influence the goals they seek, we must explore and utilize the modern tools of appraisal to enhance our own insights about the non-intellectual factors which influence academic and career performance. If the present means of accomplishing this are inadequate we must be pioneers in this area. This has, in fact, been the goal of Arthur Loewy, Professor of Otolaryngology at the University of Illinois who has collaborated with John Parsons, an industrial psychologist. They are determined to improve our screening techniques, our ability to make better judgments about men and are motivated by the need to seek out leadership potential. Let it be clearly understood that "tests" must not be the only criteria. Leadership is identified with as many skills, levels of education and intellectual needs as there are occupational titles. Uniqueness of individual personality is clearly present in each man who earns the privilege of leadership, but despite these unique aspects, each shares in common identifiable personality patterns, attitudes and values.

In conclusion, we must view the scene of sociologic and economic unrest without foreboding. If the selection and education of our young men and women is maintained at the highest level we need have no concern. We have finally emerged from our cocoon of educational complacency which placed technique as its primary goal, identifying otolaryngology with only a few isolated procedures as if each were a talisman. This is the service-oriented or "trade-school" approach now to be replaced by motivated teachers in a milieu of learning who strive for an end-product of otolaryngological competence defined by:

1. Knowledge as a fundamental qualification.
2. Basic dexterity and space perceptual eye-hand coordination.
3. Ability to use one's knowledge with discriminating, objective judgement.
4. Capacity to correlate between problems at hand, efficient methods of problem solving, initiative, self-direction and emotional independence.
5. Honesty of thought and attitude and the ability to detect and disarm fraud.
6. Efficiency and effectiveness in verbal and written communication.
7. A positive self-respecting attitude and the ability to consider consequences of one's action.
8. Insight into the relationship between competence and success, and between competence and status with full realization of the ethical responsibility involved.



PRESIDENT HOLINGER: Dr. Lederer, as usual you have given us much food for thought. We at Illinois realize with added pride the significance of this honor to you, recognizing the manner in which you have led us, not only in the University but in our specialty nationally and internationally. My congratulations to you again for receiving this honor awarded you by the Fellowship of the Association. You have illustrated by your discussion the reason why this has been given you and we are deeply appreciative of all your work.

INTRODUCTION OF GUEST SPEAKER

PRESIDENT HOLINGER: In my opening remarks I indicated a serious problem we face in laryngology and also indicated that our Guest Speaker was one who is particularly fitted to help us. Dr. George L. Wied was born in Carlsbad, Czechoslovakia, and last night as he and our Guest of Honor, Doctor Lederer, met each other and started speaking Czech, it was all any of us could do to break into this fascinating conversation, which was worse than Greek to the rest of us.

Doctor Wied received his medical education in Prague and his specialty training in gynecology in Germany. He was Chairman of the Department of Obstetrics and Gynecology in the Free University of West Berlin where he met and married his charming wife who is also with us today. They came to the United States in 1955, and 10 years later Doctor Wied was Professor in the Department of Obstetrics and Gynecology at the University of Chicago School of Medicine. He is here to help us in the problem of clarification of carcinoma-in-situ of the larynx, and his many honors and awards received for his outstanding work in carcinoma-in-situ in the cervix explain the reasons for inviting him to our meeting. Doctor Wied was Chairman of the Committee on Cytologic Terminology of the International Academy of Cytology and is Editor-in-Chief of "Acta Cytologica," The Journal of Exfoliative Cytology. His laboratory is one of the most sophisticated conglomerations of IBM machinery, microscopes of all descriptions, unbelievable apparatus for chemical analyses, and all the superb assistants that one could wish. I have known Doctor Wied through his participation on the Medical and Scientific Committee of the Illinois Division of the American Cancer Society, where we have served together several years. Because of his editorial in "Acta Cytologica," in which he stated the problem of definition of carcinoma-in-situ of the cervix, which is similar to our own problem, it seemed appropriate to the Council of the Association that we ask him to tell us how we can reach a similar clarification of early malignant lesions of the oral cavity, pharynx and larynx. It is hoped that we can reach a histologic classification that we can all agree upon in these areas as well.

HISTOLOGICAL CLASSIFICATION OF
EARLY MALIGNANT LESIONS OF THE ORAL CAVITY,
PHARYNX, AND LARYNX

GEO. L. WIED, M.D.

CHICAGO, ILL.



At the time of publication of the *Transactions* this presentation had not been cleared by the various committees involved in these studies. Therefore, at the request of Dr. Weid the paper was not included in this issue of the *Transactions*.—
EDITOR.

ULTRASTRUCTURE OF TRACHEAL CILIA AND CELLS DURING REGENERATION

DAVID A. HILDING, M.D.
(by invitation)

NEW HAVEN, CONN.

A. C. HILDING, M.D.

DULUTH, MINN.

A two-day symposium on cilia at Duke University in 1965 brought forth an amazing array of information, much of it new. However, toward the end of the symposium, one of the speakers commented, "No one has seen a baby cilium." This remark stimulated our present study.

Just what the speaker meant by "baby cilium" was not explained. As a matter of fact, many workers have studied the development of cilia with the light microscope. Generally, Henneguy and Lenhossek are credited with the theory that centrioles divide to produce numerous basal bodies which then migrate to the surface where cilia arise from them.^{1,2} Our observations with the electron microscope, as well as those of previous investigators, have confirmed the accuracy of this view originally published in 1898. In 1923 Jordan³ clearly illustrated these steps in the developing testes and Saguchi⁴ compared ciliogenesis in a number of different tissues in his 1917 paper. Burian and Stockinger⁵⁻⁹ have caused varying degrees of injury using a number of different chemical reagents and studied regeneration of cilia with electron microscopy. They found that a large number of basal bodies formed within regenerating cells prior to the development of mature cilia. They also observed cilia which lacked normal fibrils and appeared nearly homogeneous. They were found among normal, injured and developing cilia and these workers interpreted them as

From the Research Laboratory, St. Luke's Hospital, Duluth, and the Otologic Research Laboratory, Yale University School of Medicine, New Haven, Connecticut.

Supported through grants from the United States Public Health Service Research Grant No. GM 09603-03, National Institute of Neurological Disease and Blindness, Grants NB 03447-03 and NB 3995-03 and the Deafness Research Foundation.

pathological. We have found similar homogeneous cilia and wonder if they might represent a normal precursor stage during ciliogenesis. That a single cilium might exhibit pathological lesions was strikingly brought out by Duncan's¹⁰ work on porcine atrophic rhinitis. His study demonstrated relatively huge enlargement of some cilia with abnormalities in the number and length of the ciliary fibrils.

Previously reported experiments¹¹ on living calves demonstrated the steps in regeneration of tracheal epithelium following minimal mechanical surface damage that removed the cilia. These deciliated mature cells remained in situ for a brief period but after an hour had largely exfoliated leaving the underlying immature replacement cells to rebuild the epithelium which they did in five to seven days. These replacement cells not only matured to cilia-bearing columnar cells but they reproduced to replace themselves with other immature cells. The epithelium attained normal depth and near normal appearance in four days but as of that time there were practically no cilia.

Since our aim was to observe the development of cilia after mechanical damage these experiments looked promising and it was decided to pursue them further with this in mind, excepting that rabbits were used instead of calves. The questions to be resolved were: 1. How do cilia regenerate after mechanical injury? 2. What happens within the cells during ciliogenesis? 3. Will a cell survive removal of its cilia?

MATERIAL AND METHODS

Fifteen young albino rabbits were used in these experiments. Light microscopic observations were made in every animal and electron microscopy was used to study tissue from seven animals.

Under combined general and local anesthesia, the trachea was exposed, rotated, and opened with diathermy along the dorsal midline. The wall along this line is membranous. The lesion (surface injury) was produced by means of a weighted cotton swab, which delivered a pressure of 5 grams (not 10 grams as in experiments on the calves). This swab was passed once, in an axial direction, over the epithelial surface, at or near the ventral midline. Methylene blue, 1 per cent in saline, was used to stain the track. When the epithelium has been disturbed, it stains heavily with methylene blue in contrast to the undisturbed, living epithelium which scarcely stains. Thus the path of the track made by the swab may be sharply visualized

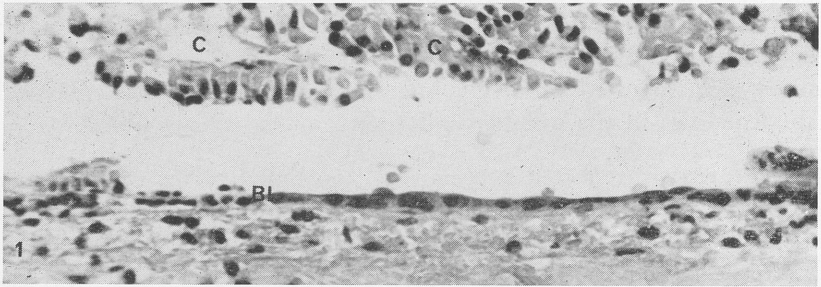


Fig. 1.—Tracheal epithelium two hours after passage of weighted cotton swab delivering 5 grams of pressure. The ciliated cells (C) have been torn off and the residual basal cells have formed a smooth layer (BL).

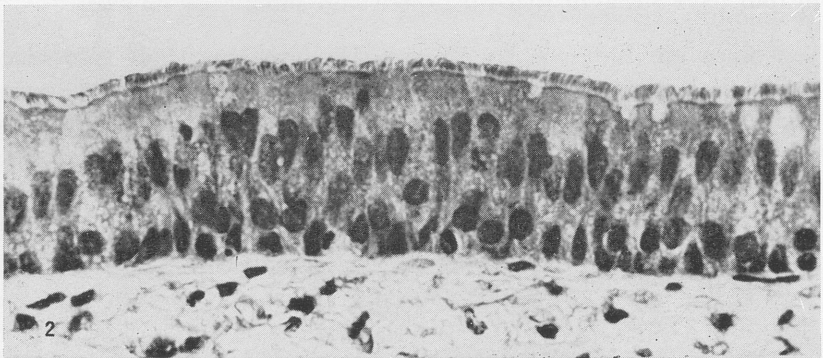


Fig. 2.—Five days following injury the epithelium appeared normal by light microscopy.

and located. The course of the track was marked on the outside of the trachea by means of 6-0 silk sutures placed in the outer wall. The animals were permitted to live for varying periods of time up to seven days, after which they were sacrificed by a lethal dose of intravenous anesthetic and the tracheal specimens excised and fixed in formalin or glutaraldehyde, respectively, preparatory to examination by light or electron microscope.

Glutaraldehyde-fixed tissue was mailed from Duluth to New Haven for processing for electron microscopy. These specimens were post-fixed for two hours in buffered osmium tetroxide, dehydrated

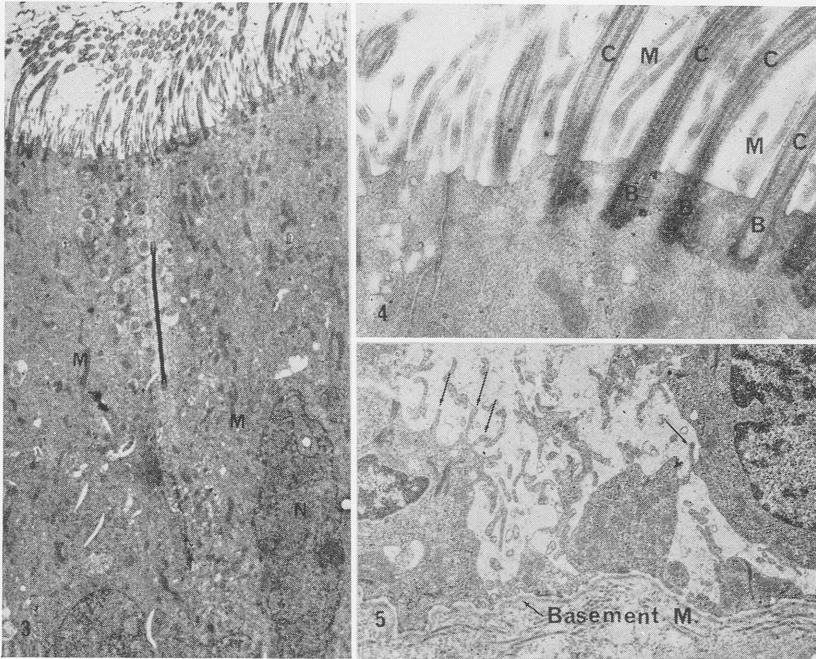


Fig. 3.—Normal tracheal ciliated cells in low power electron micrograph. Numerous mitochondria (M) are visible in the cytoplasm between the nucleus (N) and cell surface.

Fig. 4.—Apical end of normal ciliated cell showing that each cilium (C) has a basal body (B). Microvilli (M) are common between cilia.

Fig. 5.—The cells resting on the basement membrane have numerous cell processes (arrows) which straighten to appear as microvilli after cells above were removed.

and imbedded in Epon.[®] After the plastic had hardened, free-hand sections were cut with a razor blade and mounted in liquid Epon under a cover glass on a microscope slide. Selection of areas for electron microscopy was made by modifying a technique taught by Jan Wersall (personal communication) which is similar to methods recently described by Grimley¹² and Stell.¹³

These razor blade sections were scanned under the phase contrast microscope, appropriate areas located and separated from the rest of the section. Such chosen small bits of embedded tissue were remounted on plastic blocks with epoxy resin and sectioned for elec-

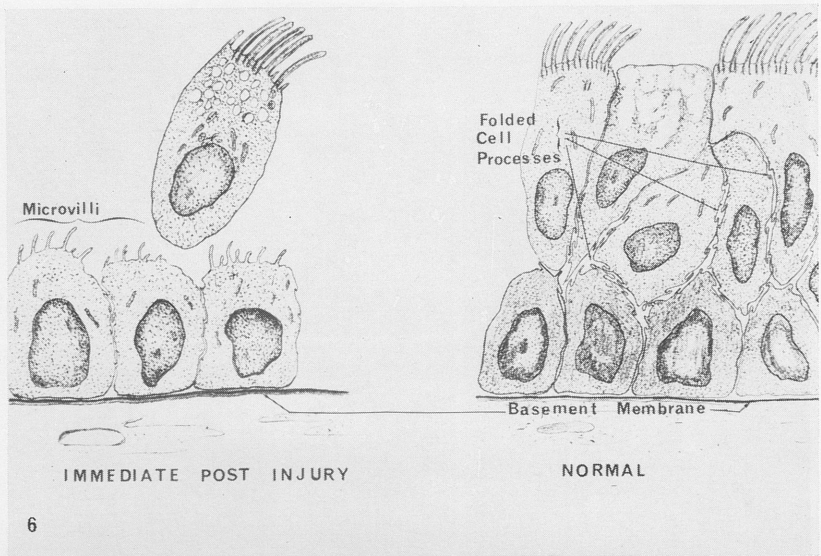


Fig. 6.—Diagram to illustrate how the folded cell processes between cells normally (right) unfold to become microvilli when cells above are removed (left).

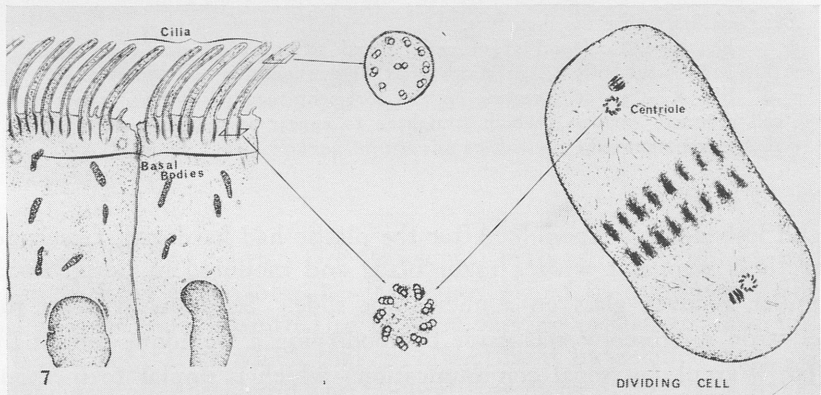


Fig. 7.—Each normal cilium has a 9 and 2 pattern of microtubules and its basal body a similar arrangement of triplets. This diagram illustrates that centrioles have identical ultrastructure. Centrioles are evident as the centers of cell division (right).

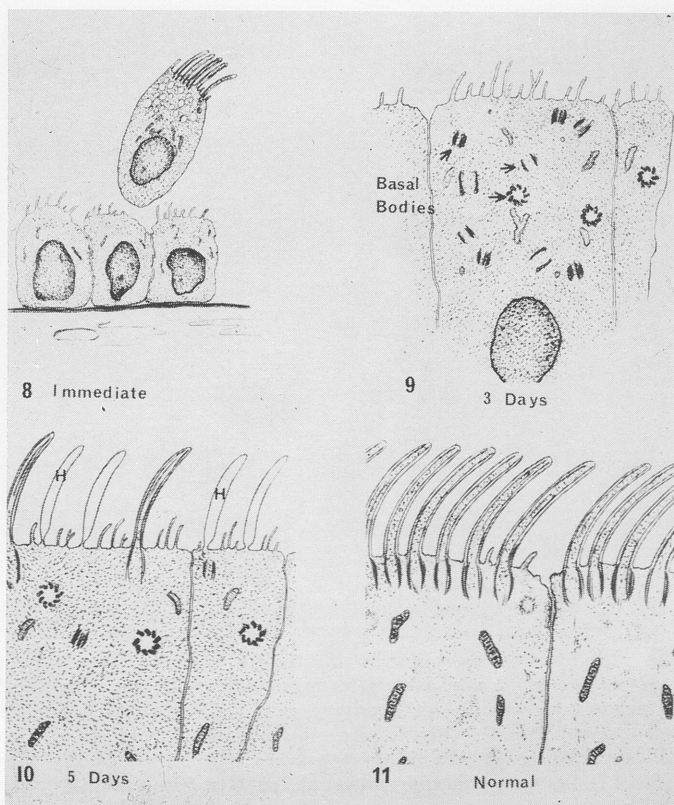


Fig. 8.—Immediately after cells above were removed microvilli were observed on remaining basal layer cells.

Fig. 9.—Three days after injury the cells were found to contain a large number of basal bodies between the nucleus and cell surface which was still covered by microvilli.

Fig. 10.—Homogeneous cilia (H) were numerous in five day specimens. The same cell had fully developed cilia as well as basal bodies deep within.

Fig. 11.—In normal tracheal cells each cilium has a basal body and it is rare to find free basal bodies in the cytoplasm.

tron microscopy (Fig. 19). Thus it was possible to examine the same cells by both light and electron microscopy.

RESULTS

As the cotton swab passed over the ciliated epithelium it tore away all but the basal layers of cells in most areas. There was consid-

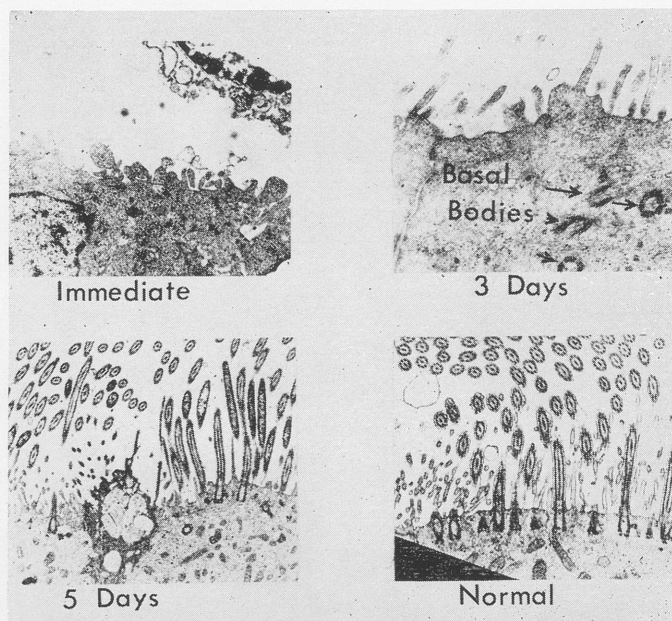


Fig. 12.—Electron micrographs illustrating each of the steps diagrammed previously. Immediately after injury microvilli appear on the free surface exposed by removal of overlying cells. After three days profuse numbers of basal bodies appeared, before mature cilia formed on the upper surface. Five-day specimens had homogeneous cilia between fully formed ones. Basal bodies were still approaching the surface. In a normal specimen every cilium has a 9 and 2 arrangement of microtubules and a basal body.

erable variation in the amount of damage produced because the cotton became lubricated by mucus as it progressed, and tended to skip over some areas with less destruction. In some spots all layers of the epithelium were removed, including some basement membrane.

The destruction and repair of the epithelium was similar to that in the calves except that in the rabbit a 5-gram swab immediately removed all cells down to the basal layer—and in some areas even these. This was in contrast to the lesion produced by a 10-gram swab in the calves, where only the cilia and surface of the columnar cells were obviously damaged. Healing, on the other hand, seemed to progress somewhat more rapidly in the rabbits, since the epithelium had attained full thickness by three days—a stage that was attained only after four to five days in the calves. After four days, the

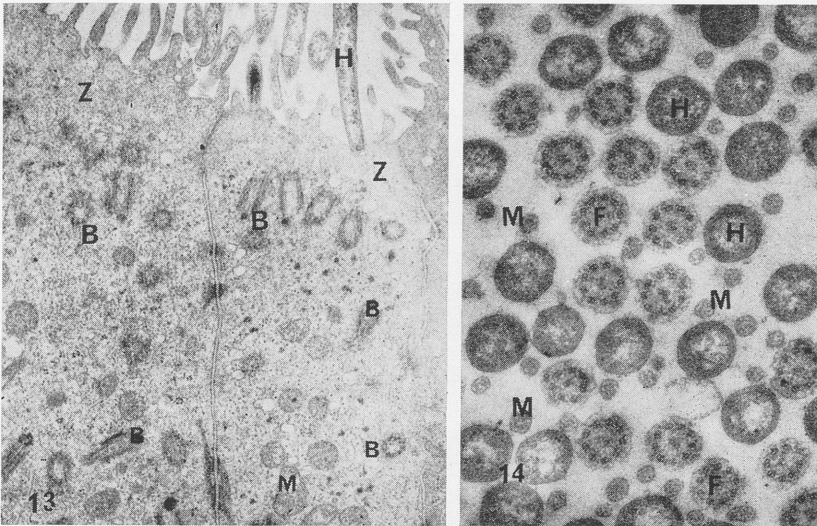


Fig. 13.—Among the microvilli that are seen at the top of tracheal cells four days after injury, a number of homogeneous cilia are found (H). This low power electron micrograph shows a number of basal bodies (B) rising through the upper portion of the cell between mitochondria (M). Often a zone (Z) free of basal bodies was observed immediately below the apical surface.

Fig. 14.—In a section cut parallel to the upper cell surface of a five-day specimen, homogeneous cilia (H) are shown between microvilli (M) and mature cilia with fibrils (F).

rabbits' epithelium had been so completely restored that usually the swab lesion could not be identified with certainty. At the end of two hours, it appeared as in Figure 1. At the end of three days, the epithelium was of normal depth but cilia were absent or very short, as seen by the light microscope. After five days the epithelium often looked normal (Fig. 2).

To determine evidence of functioning cilia, ciliary streaming was visualized with India ink three days after passage of the swab. There was slowing in the line of the track, which formed a sagging crescent, but the adjacent cilia dragged the mucous blanket along surprisingly well—apparently by traction. The presence of functioning cilia along the line of the track could neither be proved nor disproved by these findings.

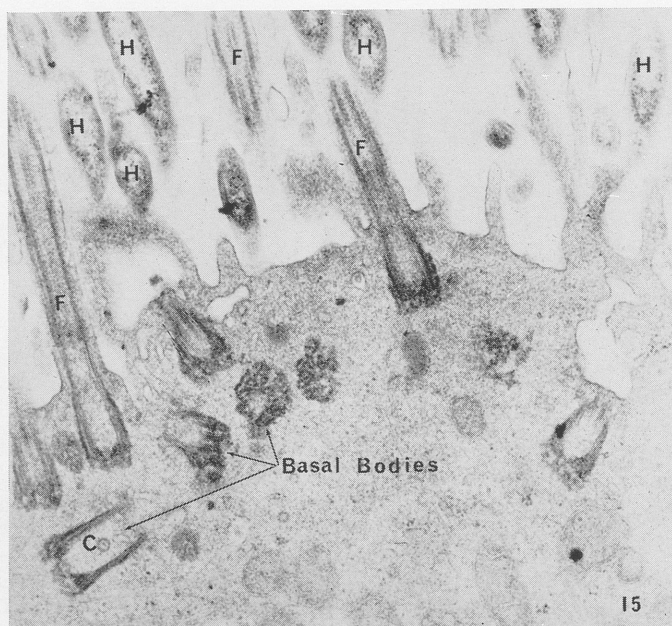


Fig. 15.—Another electron micrograph of a five-day specimen showing the mixture of mature cilia, microvilli and homogeneous cilia at the upper surface of the cell. New basal bodies are seen approaching the surface. One of them contains a circular structure (C) which is the only suggestion we found of what may happen during basal body replication.

Polymorphonuclear leucocytes appeared in the epithelium amidst ciliated cells showing varying degrees of abnormality. In some of the animals surviving five and seven days these changes appeared mainly in the swab track. Consequently, there is an element of uncertainty about which light and electron microscopic findings are due to mechanical trauma and the trachea's response to it and which resulted from superimposed infection.

Electron microscopic findings helped in understanding the way new cilia are formed at the top of the regenerating cells, but also raised many new questions about this process. We used the electron microscope to study the epithelium's appearance immediately after the injury and during the process of regeneration.

Within a few minutes after injury, the remaining cells were surmounted by small finger-like processes, as illustrated in Figure 8.

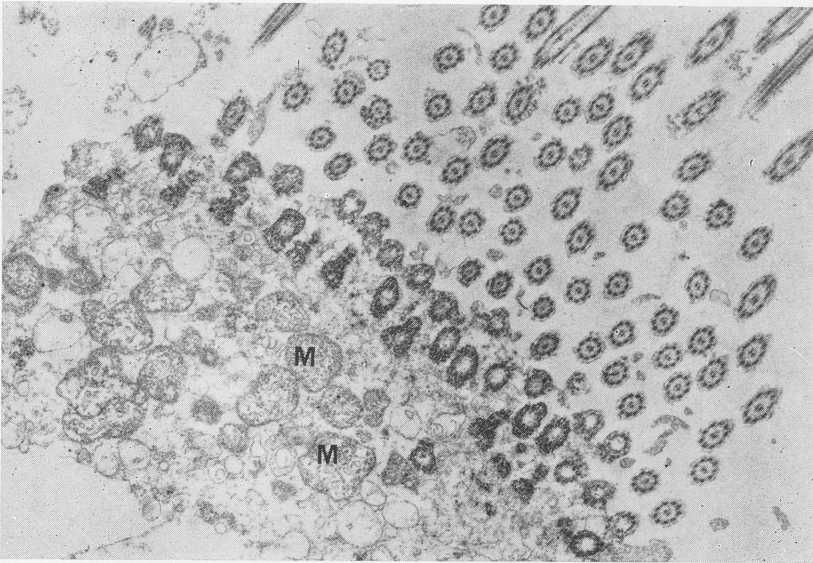


Fig. 16.—The apical portion of this cell was torn off along with the cilia. Removal of cilia without extensive damage to the cell was not observed.

Apparently, these microvilli are always present in most tracheal cells on those cell surfaces facing other cells. As illustrated diagrammatically in Figure 6, these pre-existing cell processes are normally folded but straighten out when the overlying cells are removed.

Torn-off cells were observed in several specimens. These cells showed marked vesicular degeneration soon after the injury. Yet the cilia remained firmly attached to the upper portion of the cell suggesting that it would be difficult to remove the cilia from one of these cells without severely injuring it (Fig. 16).

By the fourth day after injury, many of the cells contained numerous basal bodies in the cytoplasm between the nucleus and the upper end of the cell which was covered by microvilli. Despite diligent search, we never recognized basal bodies during the process of formation. Presumably, through some process they are all derived from the cell's original pair of centrioles.^{14,15}

At the time basal bodies concentrate near the upper end of the cell, a different type of cell process or cilium appears. In general these

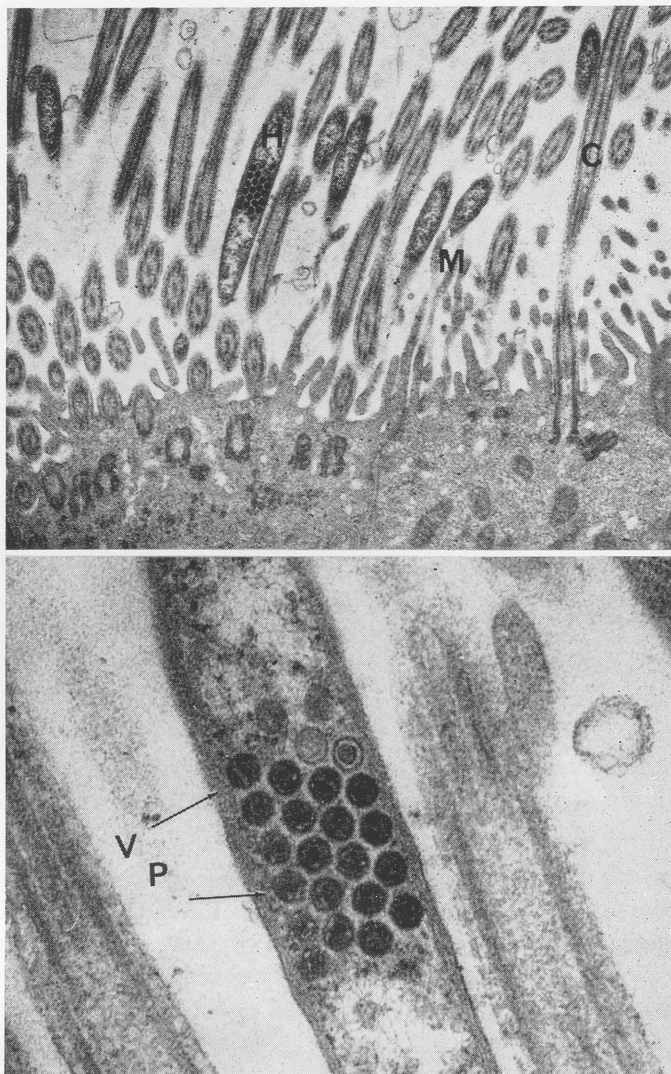


Fig. 17.—Virus particles about 500 \AA in diameter were seen in this specimen within its homogeneous cilia (H). Microvilli (M) are shown between cilia. Mature cilium (C).

Fig. 18.—High magnification electron micrograph showing geometric pattern of virus particles (VP) in homogeneous cilium.

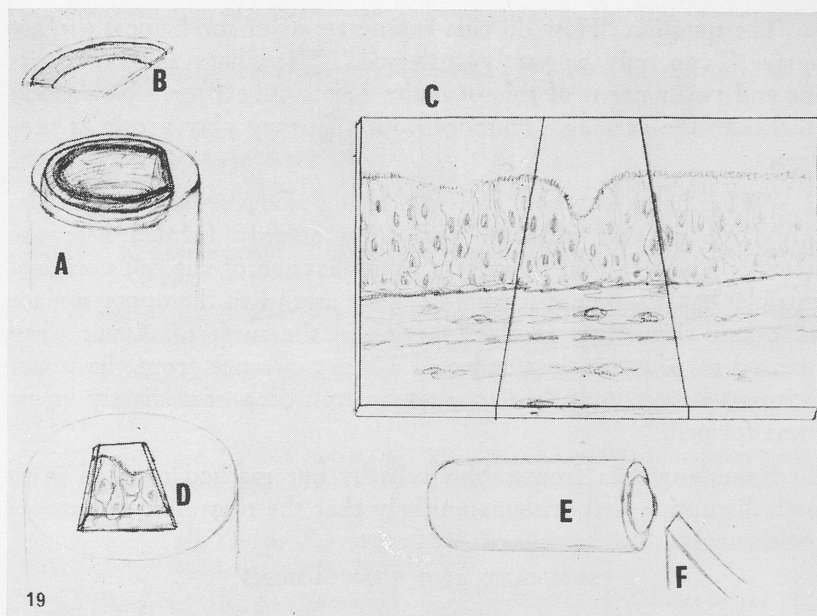


Fig. 19.—Illustrating how identical cells could be studied by light, then electron microscope. A segment of trachea imbedded in Epon (A). Razor-blade sections were cut free-hand (B) suitable for phase contrast microscopy. Areas were selected, then separated (C) to be remounted on new blocks (D). Remounted specimens (E) were then cut with glass or diamond knives (F) for electron microscopy.

are the size and shape of mature cilia but they contain no fibrils . . . they are homogeneous. Neither do they have basal bodies. They are sausage-shaped with a narrow portion at the attachment to the cell. They may be an invariable accompaniment of the development of mature cilia or they could represent some sort of inflammatory reaction.

Spherules 500 Å in diameter were found in the homogeneous cilia of one animal. They were arranged in a geometric pattern and had a definite substructure, suggesting that they were virus particles, but their identity cannot be determined by their electron microscopic appearance alone. They were not evident in nuclei or cytoplasm of tracheal cells, but were located only in homogeneous cilia (Figs. 17, 18).

COMMENT

The question "How do cilia regenerate after mechanical surface damage?" can only be partly answered. The ciliary shaft with its nine and two pattern of microtubules forms only after a basal body attaches to the surface. Homogeneous cilia may play a role as precursors.

"What happens within the cells during ciliogenesis?" A surprisingly large number of basal bodies are quickly formed near the nucleus. The way that they form by replication of the cell's original centrioles has not been discovered. They ascend to the upper surface and orient themselves at right angles to the surface. Often they appeared to pause as they collected a short distance from the upper surface so a basal-body free zone one micron deep immediately below it was formed.

Removing cilia from rabbit cells by our method resulted in so much disruption that it seems unlikely that the remaining fragments would survive.

SUMMARY AND CONCLUSIONS

Electron microscopy was employed to study the events that follow mechanical injury to tracheal epithelium in the rabbit. Classical histologists had decided that the cells of the trachea formed their cilia after the centrioles subdivided to form basal bodies which ascended to the upper cell surface where cilia then grew. Our electron microscopic observations confirm these findings.

Immediately after overlying cells were removed, the folded cell processes of remaining cells straightened to become microvilli.

During succeeding days hundreds of basal bodies appeared deep in the cytoplasm near the nucleus. They each had a close ultrastructural resemblance to centrioles. By a process we did not recognize, the original centrioles multiplied to produce these numerous basal bodies.

Homogeneous cilia formed at the upper surface of the tracheal cells as the basal bodies ascended and oriented themselves at right angles to the surface. These afibrillar cilia may represent a step in ciliogenesis.

Virus particles were recognized in one specimen. They were found only in homogeneous cilia.

ST. LUKE'S HOSPITAL

REFERENCES

1. Heidenhain, M.: Plasma und Zelle. Vol. 1, pp. 284-295. Gustav Fischer, Jena, 1907.
2. Erhard, H.: Die Henneguy-Lenhosseksch Theorie. *Ergeb. Anat. U. Entwickl.* 19:893-929, 1909.
3. Jordan, H. E., and Helvestine, F., Jr.: Ciliogenesis in the Epididymus of the Rat. *Anat. Record* 25:7-15, 1928.
4. Saguchi, S.: Studies on Ciliated Cells. *Jour. Morph.* 29:217-272, 1917.
5. Burian, K., and Stockinger, L.: Elektronehmikroskopische Untersuchungen An Der Nasenschleimhaut 1. Das Flimmerepithel Nach Lokalen Schädigungen. *Acta Oto-Laryng.* 56:376-389 (Mar.-Apr.) 1963.
6. Burian, K.: Regeneration in Respiratory Epithelium. *Proc. of 8th Internat. Cong. of Oto-Rhino-Laryngol.* (Mar.) 1966 (in press).
7. Burian, K.: Die Histologischen Veränderungen der Nasenschleimhaut Nach Formalinadaptation und Gekreuzter Resistenzsteigerung. *Acta Otolaryngology* 52: 429-437, 1961.
8. Stockinger, L., and Burian, K.: Die Regeneration Des Flimmerepithels der Nase Nach Verätzung Mit Zinksulfat. *A. Mikroskopisch anat. Forsch.* 63:193-211, 1957.
9. Stockinger, L.: Die Ultrastruktur Des Flimmerepithels Des Nasenseptums der Ratte. *Z. Zellforsch.* 59:443-66, 1963.
10. Duncan, J. R., and Ramsey, F. K.: Fine Structural Changes in the Porcine Nasal Ciliated Epithelial Cell Produced by Bordetella Bronchiseptica Rhinitis. *Am. J. Path.* 47:601-612 (Oct.) 1965.
11. Hilding, A. C.: Regeneration of Respiratory Epithelium After Minimal Surface Trauma. *ANNALS OF OTOTOLOGY, RHINOLOGY AND LARYNGOLOGY* 74:903-914 (Dec.) 1965.
12. Grimley, P. M.: Preparation of Large Epoxy Sections for Light Microscopy as an Adjunct to Fine-Structure Studies. *Stain. Techn.* 40:357-366, 1965.
13. Stell, W. K.: Correlation of Retinal Cytoarchitecture and Ultrastructure in Golgi Preparations. *Anatomical Record* 153:389-397, 1965.
14. Fawcett, D.: *The Cell.* Saunders, Phil., 1966.
15. Sorokin, S.: Centrioles and the Formation of Rudimentary Cilia by Fibroblasts and Smooth Muscle Cells. *J. Cell. Biol.* 15:363-377, 1962.

DISCUSSION

DR. JOHN F. DALY: I would like to ask whether all of the cells that regenerated develop into the ciliated epithelium or whether some cells remain free of the cilia and merely have microvilli. Rhodine has suggested that microvilli cells may have a hemostatic effect on the mucus. Is there any evidence of that in your study?

DR. FRANCIS L. WEILLE: I was delighted to hear this kind of a paper and particularly to see the accidental finding of virus particles in the cilia. For years I have looked for and have tried to identify a viral agent in polyp tissue, and have studied as the most probable locus the ribosomes of the cytoplasm of the cells. It is impossible in such an area to distinguish between viral granules and normal granules. This beautiful presentation of probable virus particles in the cilia is an amazing accomplishment.

DR. CATHERINE SMITH: I wonder if Dr. Hilding could elaborate a bit on the formation or differentiation of the kino-cilia. Do the basal bodies initiate the formation of the fibrils within the cilia? I wasn't clear as to whether the "homogeneous cilia" are invaded by the fibrils and the kino-cilia are actually formed and developed from the "homogeneous cilia," or if the "homogeneous cilia" are an entirely different structure.

DR. DAVID HILDING (closing): The microscopists in 1898 wondered where the beat comes from and they looked to the basal bodies. Hans Engstrom went further when he described the electron microscopic appearance of tracheal cilia to wonder if their fibrillar appearance didn't have something to do with the way the cilia beat. I think this actually is one important question that led us to our investigation. We want to know how the cilia function and hope that in understanding their morphology and their genesis will provide some clue.

To try to answer the questions briefly:

Dr. Smith, we observed homogeneous cilia in most of our specimens that were more than three days after injury—to be specific, four out of five animals. You well know the sampling problems of electron microscopy, that we can look at only a minute percentage of the tissue involved, but we feel that they represent a constant feature at this stage in regeneration.

We were never able to visualize the invasion of the homogeneous cilia or the microvilli by the ciliary shaft and, of course, we looked very hard for just this sort of thing. One thing is clear and that is that the ciliary shaft does not form until the basal body reaches the upper cell surface. You never see the ciliary shaft forming within the cell such as the type of thing you see in spermatogenesis and the formation of flagella and tissue culture, as Dr. Sorokin observed.

I would like to thank Dr. Weille for his remarks about the virus. I wish we had some way of culturing it and doing further work to identify its type, but, of course, all the tissue from this animal was fixed and until we run across it again as an accidental finding we really can't say anything more than that it looked like a virus particle.

Dr. Daly, concerning microvilli—one thing that we couldn't stress enough in our presentation was the wide variation in the cells that remain, let us say, five days after injury. Some cells showed complete maturity, some cells showed nothing but microvilli on top. There was an increased number of goblet cells topped with microvilli. There was a mixture of all kinds of cells and a lot of them were goblet cells. We tried to trace the genesis of cilia in the cells that were going on to produce mature cilia and have not paid much attention to goblet cells.

REPLANTATION AND TRANSPLANTATION OF THE CANINE LARYNX

JOSEPH H. OGURA, M.D.

MASASHI KAWASAKI, M.D. SATORU TAKENOUCHI, M.D.

(by invitation)

(by invitation)

MASAKATSU YAGI, M.D.

(by invitation)

ST. LOUIS, MO.

Replantation of the larynx is logically the first step to overcome before the step towards homotransplantation and its immunologic problems can be undertaken and solved. Organ replacement such as the kidney,¹⁻³ liver,⁴ heart,^{5,6} lung⁷⁻¹² and the immunological problems^{13,14} are in their experimental phase with the ultimate objective of having such structures function with reasonable satisfaction.

Transplantation of the larynx with its denervated state is a more difficult problem because it is placed in an unsterile area. Any success in replacing this structure which functions for airway, deglutition and voice would be somewhat compromised in its physiological activity from the normal. With a successful "take" the unanswered question is whether the animal can adapt to this physiological disability.

This study presents a successful canine larynx replant and homotransplant from the general aspects with some mention of the various other modalities which have failed. Subsequent publications will deal with: 1) the hemodynamics and the neurophysiological aspects of the replanted larynx in dogs,¹⁵ 2) the technical problems of the replanted canine larynx,¹⁶ 3) surgical pathology of the replanted canine larynx,¹⁷ and 4) the current status of the homotransplanted canine larynx.¹⁸

From the Department of Otolaryngology, Washington University School of Medicine, Saint Louis, Missouri 63110.

This research project is supported by the N.I.H. Grants NB-03408-05 and NB-06200-01.

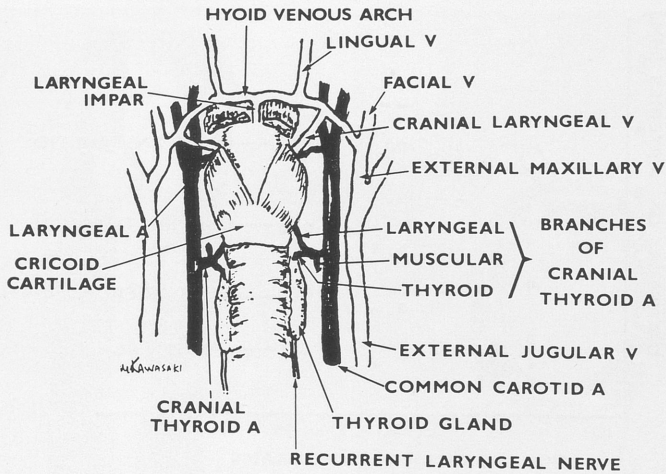
In the early era of total laryngectomy there was no pattern of laryngeal reconstruction following necessary removal for cancer. To a great extent this is still true today. Gussenbauer¹⁹ then reconstructed an "artificial larynx" into this area in an effort to re-establish the airway continuity between the tracheostoma and the pharynx. Voice was rather monotonous and deglutition difficulties were present for some patients. More recently, McCall and Whitaker²⁰ were unsuccessful in substituting a larynx in the human.

In 1962, in an effort to find a simplified larynx, the senior author²¹ used the host's own tissue (cricopharyngeus) to reconstruct the pseudocords in dogs. Although such a "larynx" functioned with limited success, the minimum requirements for adequate adaptation of the larynx could not be met. Swallowing was fair, airway better, and voice excellent. Failure for deglutition inevitably led to death in all of these animals.

In 1956,²² and 1964,^{23,24} investigations were directed towards developing a better understanding of the physiological concepts and principles involved with deglutition and phonation of normal animals and in certain experimental surgical procedures of the larynx simulating clinical situations.²⁵ Through these studies and the clinical successes of the reconstructed simplified larynx in humans which demonstrated that a sphincter need not be present for reasonable function,^{26,27} investigation towards a larynx replantation was initiated. In the only reports to date on larynx replantation in dogs, Work and Boles²⁸ and Boles²⁹ pointed out the difficulty of small vessel anastomoses. They reported no successes with replantation. However, they showed a larynx survival with one intact vascular pedicle. The factor of small vessel thromboses has been the principal cause for their failures to replant the larynx.

EXPERIMENTAL DESIGN

Three basic experimental situations were studied. First, it was necessary to determine the minimum vascular requirements of the larynx. Thirteen dogs were used to study the dynamics of blood flow.¹⁵ The "isolated" larynx was made anoxic by clamping the various arteries in combination, and then flow volume measurements made from the two cranial laryngeal veins. The intrinsic muscles of the larynx were monitored by electromyographic means.^{15,16} Our isolated larynx is one where the larynx was completely dissected off



CANINE LARYNX ANTERIOR VIEW
SHOWING A-ARTERIES V-VEINS & NERVE

Fig. 1.—Anterior view of canine larynx, showing arteries, veins, and nerves concerned in the replantation of the larynx.

from its adjacent structures except that the recurrent and superior laryngeal nerves, laryngeal and cranial thyroid arteries, cranial laryngeal veins and laryngeal impar were left attached to the larynx (Fig. 1).

For the second series of experiments, replantation of the excised larynx was performed with an evaluation of anastomotic sites of small vessels. This consisted of isolating the larynx, transecting the vessels and nerves, perfusing the isolated larynx, re-anastomosing the vessels and nerves and re-attaching the larynx. In these experiments we investigated only small vessel (diameter $2 \text{ mm} \pm 0.5 \text{ mm}$) anastomoses using various techniques.

In the third set of experiments, six dogs were used to compare the effect of suture anastomoses of the larger vessels compared to the smaller diameter vessels. The cranial thyroid arteries and the common carotid arteries were considered as a unit (Fig. 1). The laryngeal arteries were ignored because their diameters were often less than 1 mm, and were difficult to anastomose.

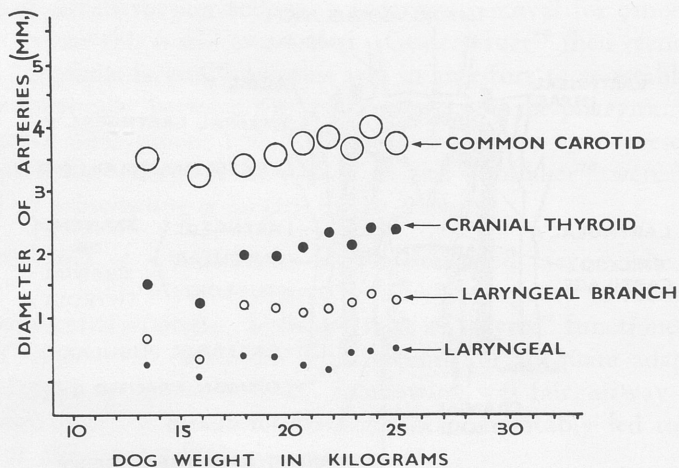


Fig. 2.—Compares the diameter of the arteries concerned with the replantation of the canine larynx, according to the weight.

In these three basic experiments, replantation was the sole aim. With success in replantation, homotransplantations were performed. These dogs, in addition, were given an immunosuppressive drug (Imuran®) along with a splenectomy.

METHOD

Surgical Anatomy. The canine larynx is supplied by four arteries (Fig. 1). Each cranial thyroid artery with its laryngeal branch is a branch of the common carotid artery, and each laryngeal artery is a branch of the external carotid artery. The venous return is mostly through the cranial laryngeal veins and the laryngeal impar. The minute veins laterally draining into the small internal jugular veins are ligated. The relative sizes of these vessels are tabulated in Figure 2.

Technique. Ten days prior to laryngeal surgery, a preliminary gastrostomy is performed. Using Diabital® and Surital® anesthesia, a midline incision is made and the larynx isolated (see above). When the separation of the larynx is accomplished, vascular clamps are attached to the arteries and veins (Fig. 2). Then the vessels along with the nerves are cut. The common carotid artery (having the cranial thyroid artery and the isolated larynx) is divided, and a bypass

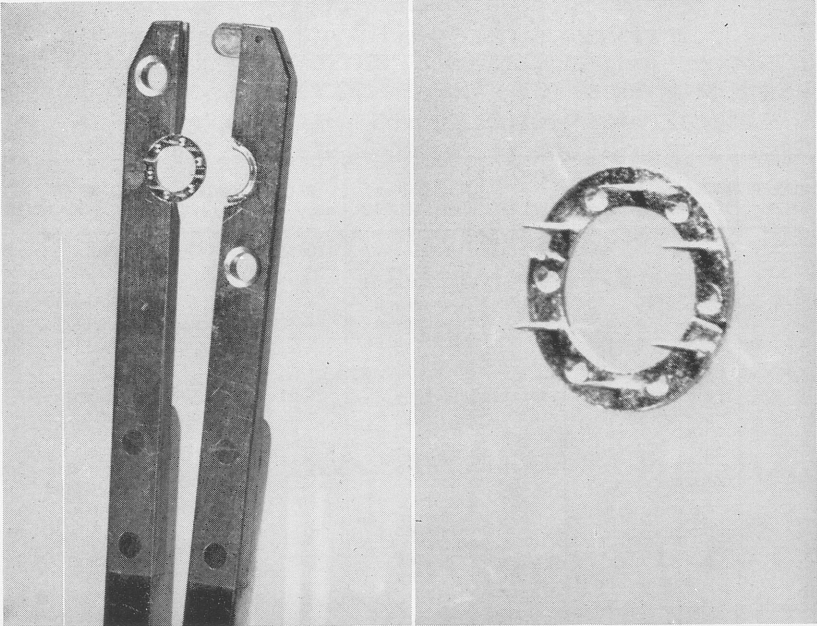


Fig. 3.—Depicts an eyelet-rivet, along with the eyelet-rivet positioned in the Nakayama vascular clamp.

tube inserted to allow for cerebral blood flow. This common carotid artery is perfused with a plasma expander (Dextran,[®] Rheomacrodex[®]) until clear fluid egresses from the veins.

At the present time our successful replant and homotransplant of the larynx uses the eyelet-rivet technique (Fig. 3). This eyelet-rivet technique anastomoses the common carotid artery (with cranial thyroid) in its normal location and the lingual with the external maxillary veins. The remainder of the larynx (either replanted or homotransplanted) is re-approximated.

DATA

This data does not include the first 23 laryngeal experimental dogs because meaningful interpretation could not be made. Then, the next seven dogs had their esophagus removed along with the larynx. Our studies showed that the inclusion of a section of esopha-

TABLE I
 TWENTY-EIGHT CONSECUTIVE CASES OF THE
 REPLANTED CANINE LARYNX

REPLANTED CANINE LARYNX							
NUMBER of dogs	MODEL 1 2 3	sites of ANASTOMOSES	PARTIAL or ISOLATED	METHOD of ANASTOMOSES	DAYS survived	CONDITION OF LARYNX	ALIVE or CAUSE of DEATH
3	1	t	partial	suture	420-540	good	alive
8	1	tt	isolated	suture & adhesive pl. eyelet	4-42	necrosed	pneumonia asphyxiation sacrificed
2	2	tt	isolated	suture	1-11	necrosed good one	pneumonia sacrificed
3	3	tt	isolated	suture	1-3	bad	anesthetic thrombosed vessels.
2	2	cc	isolated	eyelet- rivet	1-2	good	cerebral edema
10	2 3	ct & c	isolated	eyelet- rivet	2-63	good	sacrificed asphyxiation
28							

This depicts the three model designs, the partial and the completely isolated larynx, as well as the method of anastomoses, days survived, and the condition of the larynx in the postoperative period. Notice that the C-design using the eyelet-rivet and the mechanical clamp presented the best survival results.

gus adjacent to the larynx did not alter the viability of the replanted larynx appreciably. This paper presents 28 consecutive cases of the canine larynx replant (Table I).

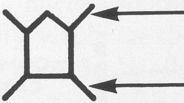





Hemodynamics. Table II illustrates the results of venous outflow from the cranial laryngeal veins when the arterial supply to the canine larynx was interrupted by clamping off any combination of the cranial thyroid and the laryngeal arteries. It was found that one cranial thyroid artery can supply 50 per cent of the normal venous outflow of the larynx.

From the larynx hemodynamics experiments (Table II) it was found that a single cranial thyroid artery with venous return through the two cranial laryngeal veins is enough to maintain larynx viabil-

TABLE II

THE RESULTS OF VENOUS FLOW FROM THE CRANIAL LARYNGEAL
VEINS OF THE CANINE LARYNX WHEN THE ARTERIAL SUPPLY
TO THE LARYNX WAS INTERRUPTED BY CLAMPING OFF
THE COMBINATION OF ARTERIES AS SHOWN

VENOUS FLOW OF LARYNX
RELATED TO ARTERIAL SUPPLY

FLOW VOLUME (%)	SCHEMA	PATENT ARTERIES
100		2 LARYNGEAL 2 LARYNGEAL BRANCH CRANIAL THYROID
65 - 80		
40 - 55		
70 - 85		
50 - 60		
30 - 40		

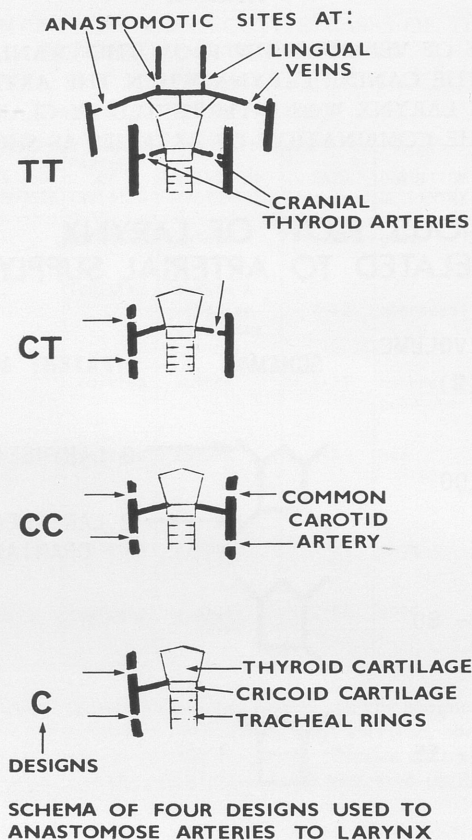


Fig. 4.—Schematic drawing showing the Model Designs of the anastomotic sites for the canine larynx. For the current replant and homotransplant of the canine larynx, the C design was used because its results are the best.

ity.^{15,16} Based on this, the replant and homotransplant of the canine larynx was performed using this technique (C design, Fig. 4).

Sites of Anastomoses (Fig. 4). All cases where the cranial thyroid arteries were used as the sites of anastomoses (TT design) failed. The re-anastomoses using the C-T design where one common carotid artery with its attached cranial thyroid branch and the opposite cranial thyroid are re-anastomosed showed improved survival rates compared to the TT design. Autopsy examinations of the C-T design

TABLE IV
THE RESULTS OF THE THREE TYPES OF LARYNX
RE-APPROXIMATION FOR THE REPLANTED AND
HOMOTRANSPLANTED OPERATIONS
MODELS OF LARYNX RECONSTRUCTION

<i>Model</i>	<i>Cases</i>	<i>Results</i>
1	8	All died as result of pneumonia
2	11	5 sacrificed had moderate pneumonic consolidation 6 sacrificed had minimal pneumonia
3	5	All Model 3 eventually fistulized to become Model 2

pneumonia were the least. Success of the replanted larynx was considered as that being totally viable on the eighth day since if failure is to occur it would have done so by the third day.

Successful Replantation of the Larynx. Reports on successful cases done are listed (Tables I and V). We have 6 dogs with a replanted larynx with successes ranging from 9 to 62 days (Table I). These replanted larynges function well for deglutition. Figure 6 shows an endoscopic view of a homotransplanted larynx (18 days postop.). Postoperatively these dogs have been maintained on Penicillin,[®] Streptomycin,[®] fluids, followed by high protein gastrostomy feedings.

Homotransplant. The homotransplant data are given in Table V. The third set of experimental dogs used were litter mates. These dogs were placed on immunosuppressive drug (BW 57-322 Imuran[®]) five days before surgery. From the day of surgery and thereon, maintenance dose was given, the latter being controlled by the outcome of the leucocyte, erythrocyte and the differential leucocyte count. We have done three sets of larynx homotransplants with one dog (receiving Imuran daily) surviving 48 days. This homotransplanted larynx functions well for deglutition.

COMMENT

The success of replanting the canine larynx is contingent upon the success of small vessel anastomoses. The success is directly related to the size of the artery, so that chances for survival increase with the

TABLE V
THREE SETS OF DOGS WHERE THE LARYNGES WERE
INTERCHANGED

HOMO TRANSPLANTED CANINE LARYNX

NUMBER of dogs	MODEL 1 2 3	sites of ANASTOMOSES	PARTIAL or ISOLATED	METHOD of ANASTOMOSES	DAYS survived	CONDITION OF LARYNX	ALIVE or CAUSE of DEATH
2*	1	tt	isolated	suture	1-5	necrosed	pneumonia
2*	2	c	isolated	eyelet- rivet	2-11	good bad(day 8) necrosed (day 10)	rupture carotid sacrificed
2**	2	c	isolated	eyelet- rivet	3-48	excellent	rupture carotid still alive

*these dogs did not get immuno-suppressive drugs in the pre and post-operative period; nor where they related.

**these dogs received immuno-suppressive pre-operatively, and are getting it postoperatively.

Immuno-suppressive drug used: B.W. 57-322, courtesy Burroughs-Wellcome Co.

usage of the common carotid artery rather than the cranial thyroid artery (Figs. 1, 2).

From the larynx hemodynamic experiments, one cranial thyroid artery governs 50 to 60 per cent of the normal blood flow when it is the sole arterial supply to the isolated larynx. It increases the blood flow almost 100 per cent when it is the sole supply.^{15,16} In our series of five cases (Table I), it has been shown that one cranial thyroid artery (and its laryngeal branch) maintains viability as long as the outflow from the two cranial laryngeal veins are functioning. By electromyographic monitoring^{15,16} one sees that 40 to 50 per cent of the normal flow is sufficient to keep the canine larynx viable.

It was important to determine the maximum duration of time that the isolated larynx can have its blood supply completely interrupted and still remain viable while the vascular supply was re-anastomosed. This factor was particularly important when four vascular channels (two arteries and four veins) needed to be anastomosed by the suture method. Our investigations showed that the canine larynx

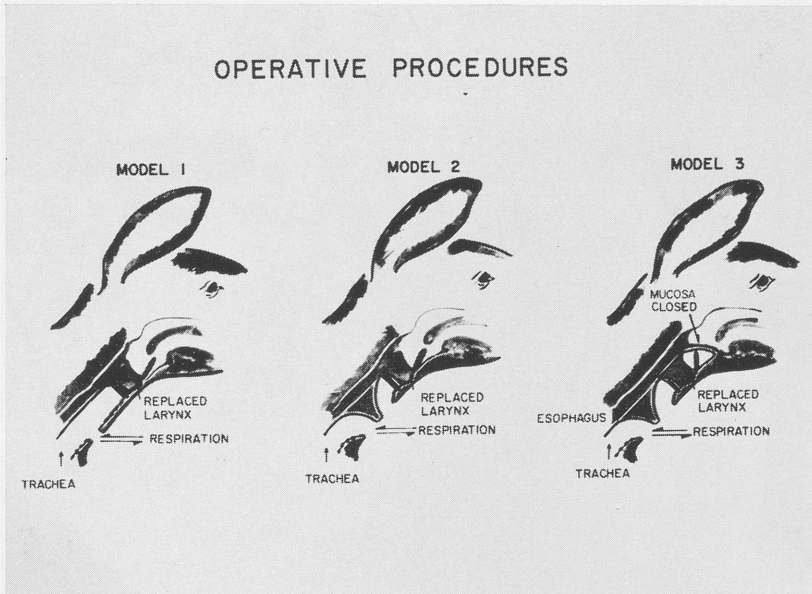


Fig. 5.—Gives three different models of reapproximating the canine larynx following its isolation and perfusion. Currently, Model 2 is used.

can survive for a maximum of 45 minutes with its vascular supply completely interrupted (Fig. 7). Even for anastomosing one artery and two veins it takes about 30 minutes. Though this is below the critical time for irreversible shock, one can see some damage to the muscles^{15,16} (Fig. 7).

The use of the adhesive (Methyl 2 cyanoacrylate®) has shown only limited value. It was difficult to keep the apposing cut surfaces of the vascular channels together in spite of apposing vascular clamp (our own design). Continued efforts using another type of adhesive (Isobutyl cyanoacrylate®) and the apposing vascular clamp has shown improved results, and it may have an eventual place. Methods to keep the artery open with plastic eyelets were found to be of limited use. Too much time was taken for the anastomoses, and the forceps handling caused irreversible damage to the vessel ends.

Rapid eyelet-rivet anastomoses has been found to be the ideal method to reattach the vascular channels to the larynx. Several types

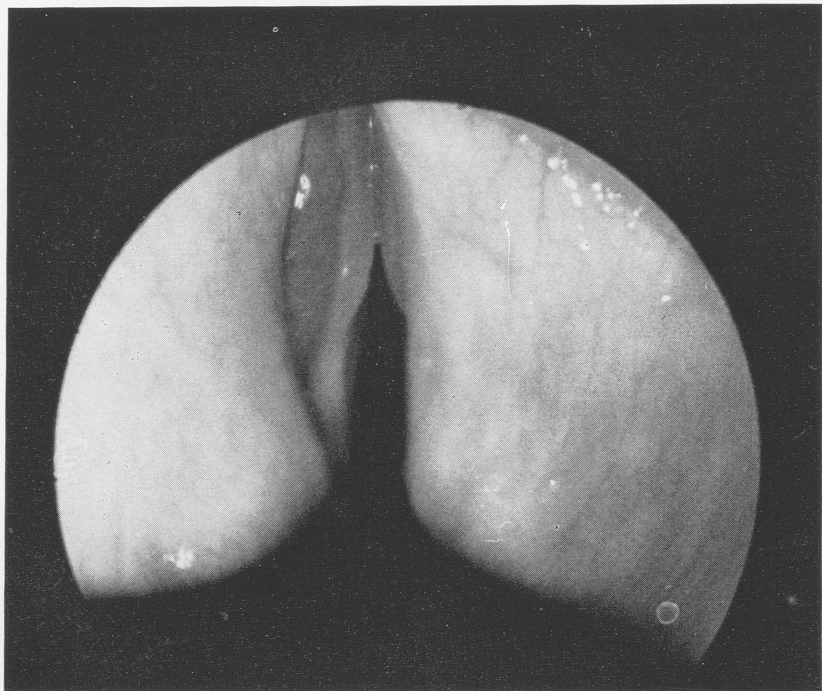


Fig. 6.—Endoscopic view of a homotransplanted canine larynx on the 18th postoperative day. Notice the slight edema of the anterior one third of the true cord. This is a common persistent finding in all of our replanted and homotransplanted larynges.

of these are in existence. For the larynx area, the limited space has required a compact instrument. The Nakayama clamp with the eyelet-rivet served the purpose adequately.

The success of the eyelet-rivet system is due to the fact that 1) the arteries are kept open following the anastomoses and 2) very little trauma is sustained by the vessel ends because forcep handling is kept to a minimum. Occasionally the vessel wall may slip from the rivets of the eyelets, with hemorrhage. In two of our cases, hemorrhage occurred within the immediate postoperative period. In one further case, the postmortem examination on a dog (Table I, dog #274^{15,16}), the distal common carotid artery anastomotic site showed a dislodgement of the eyelet-rivet, and the whole area was surrounded

TABLE III
COMPARISON OF SUTURE, ADHESIVE, EYELET AND
EYELET-RIVET ANASTOMOSES OF SMALL VESSELS

<i>Type of anastomoses</i>	<i>Dogs operated</i>	<i>Alive</i>	<i>Dead</i>	<i>Cause</i>
Control*	3	3	0	—
Suture	16	3	13	thromboses
Adhesive	5	1	4	rupture
Eyelet (plastic)	5	1	4	thromboses
Eyelet-rivet (metal)	10	7	3	rupture

* Control: Larynx was isolated, and "C" design was used for all cases.

showed that the T side was invariably thrombosed, so that for all practical purposes C-T design all became a C design. As a matter of fact, the survival rate using the C-T design was comparable to that where the C design was used.

Types of Anastomoses. Table III shows the results of various anastomotic methods. These include:

1. Suture
2. Adhesive (Eastman monomer glue®)
3. Plastic eyelets of our design
4. Metal eyelet-rivets and clamp (Nakayama)

The data available clearly demonstrate that function following the mechanical anastomoses and suture anastomoses for vessels larger than 2 mm are comparable. Suturing took about 10 to 15 minutes per vessel, adhesives 2 to 5 minutes and the mechanical clamp 1 to 2 minutes. Therefore, for purposes of facilitation, we now use the mechanical clamp. In addition to increasing the chances for larynx viability, we use the common carotid artery as the stem in our anastomoses (Fig. 4).

Model Designs of Larynx Reconstruction. Reconstructive techniques following vessel and nerve anastomoses consist of three models (Fig. 5). The outcome of these three models is tabulated (Table IV). Model design 2 gave the best postoperative results in that deaths from

RELATIONSHIP OF ARTERIAL SUPPLY AND EVOKED E.M.G.

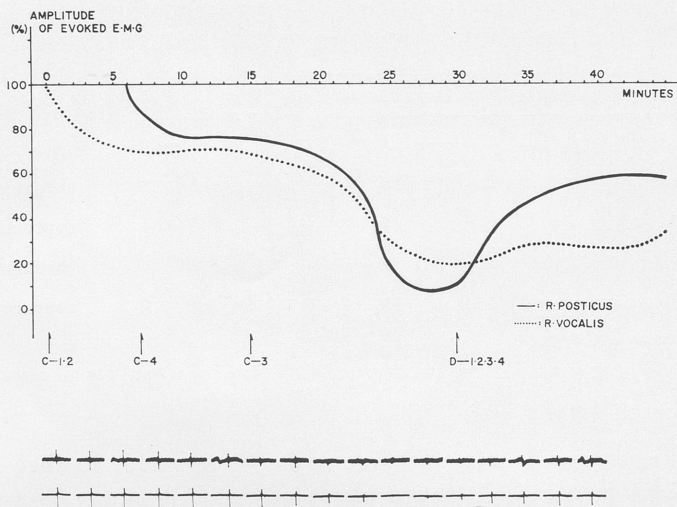


Fig. 7.—Shows the amplitude of the electromyographic responses both graphically above, and in actuality below as related to the arterial supply. C-1.2 refers to compression of right and left laryngeal arteries. C-3 and C-4 refers to compression of the right and left cranial thyroid arteries respectively. D-1.2.3.4. refers to decompression of the right and left laryngeal and cranial thyroid arteries respectively. Of the electromyographic responses, the upper figure refers to the posticus, whereas the lower one refers to the vocalis.

by fibrous tissue forming a channel for the passage of blood distal to it (thus becoming a C model design—see above). Our cases of post-operative mortality due to the rupture of a vessel, fell within the range of a normal operative mortality.

Necrosis and infarction of the larynx due to thromboses of the vessels at the sites of anastomoses constituted the principal cause of failure. Most thromboses occurred between the immediate postoperative period to three days.

The inability of the dog to handle its respiratory discharge following surgery, and the subsequent autopsy evidence of pneumonic consolidation in dogs dying within the immediate postoperative period, and even thirty days later, necessitated a better method to handle these secretions. The survival of the larynx replanted dog

increased markedly with the application of the principle of marsupialization of the subglottic and tracheal areas. In all of our dogs the closure of the supraglottic area from the hypopharynx (Model 3, Fig. 5) and larynx pathway re-opened in a few days (Table IV) with continuity established between the pharynx and the subglottic area.

Following a period of healing ranging from 8 to 18 days, oral feedings are instituted. The dogs have little difficulty in swallowing even though the infraglottic area is wide open and the cords are immobile. These series of experiments affirm the view previously held^{23,24} that the glottis can be patent and still perform the protective functions during deglutition as long as it is attached so that the replanted larynx can be abutted against the base of the tongue^{23,24} which is intact and functioning. The phonatory components are essentially unimportant in the rehabilitative process. Reconstitution of the infraglottic airway is done at a later date.

It has been recommended by the developers of Imuran (BW 57-322)¹⁴ that this immunosuppressive drug be started on the day of surgery. Our plan to begin therapy at about five days prior to surgery and a maintenance dose to begin on the day of surgery may have a place in the homotransplant of any body organ. Under this regimen, the dog with a homotransplanted larynx (Table V) is now in the 48th day (Fig. 6). This animal can swallow liquids and solids well even though the glottis is patent and the cords are immobile.

On the basis of our limited success with replantation and homotransplantation of the canine larynx, the future possibilities of such application to humans appear bright. Further immunologic studies for recipient acceptance of the organ similar to that currently under study for the kidney need to be undertaken in order to insure a higher success rate.

CONCLUSIONS

1. It appears that the arterial supply to the canine larynx is adequately supplied from each of the four arteries carrying from 60 to 80 per cent of its capacity. The cranial thyroid artery is significantly larger than the laryngeal artery.
2. Minimum requirements for the survival of an isolated canine larynx can be met if 40 per cent of the total blood flow, or greater, can be maintained. One cranial thyroid artery, which has a laryngeal

branch, and two cranial laryngeal veins can meet this minimum requirement.

3. Since the laryngeal branch of the cranial thyroid artery is about 50 per cent in its diameter as compared to the cranial thyroid artery the two laryngeal arteries could adequately supply the canine larynx. Its attachment so close to the external carotid root in the dog makes the anastomoses difficult.

4. Successful replantation of the canine larynx is contingent upon the method used for small blood vessel anastomoses. It is successful when the common carotid artery is used for re-anastomoses instead of the cranial thyroid artery. The diameter of the blood vessel is important. The chances for a success with a 4 ± 0.5 mm vessel (common carotid artery) is good; whereas, a 2 ± 0.5 mm vessel (cranial thyroid artery) and a 1 ± 0.5 mm vessel (laryngeal artery) is poor.

5. Pneumonia is a common complication following surgery. Marsupialization of the infraglottic area provides good egression of the respiratory secretions. This prevents the mucus from pooling into the lower respiratory tract during the rehabilitative period.

6. Immunosuppressive drug (Imuran) appears to control the antigen-antibody phenomena in the homotransplanted canine larynx. This regimen may be started five days prior to surgery, so that only maintenance doses need to be given from the day of surgery.

7. Good function can be maintained in the replanted and transplanted larynx for the dog.

517 SOUTH EUCLID AVE. 63110

The authors wish to acknowledge the assistance of the research technicians: Donald A. Davis, John R. Layton, Glenn E. Lorberg and James F. Williams.

REFERENCES

1. Hume, D. M., Magee, J. H., Kauffman, M., Rittenbury, M. S., and Prout, G. R.: Renal Homotransplantation in Man in Modified Recipients. *Ann. Surg.* 158: 608, 1963.
2. Reemtsma, K., McCracken, B. H., Schlegel, J. U., Pearl, M. A., Pearce, C. W., Smith, P. E., Hewitt, R. L., Flinner, R. L., and Creech, O.: Renal Heterotransplantation in Man. *Ann. Surg.* 160:384 (Sept.) 1964.
3. Starzl, T. E.: Experience in Renal Transplantation. W. B. Saunders, Philadelphia, 1964.

4. Otto, J. J., Pender, J. C., Cleary, J. H., Sensenig, D. M., and Welch, C. S.: Use of a Blood Donor in Experimental Animals with Elevated Blood Ammonia. *Surgery* 43:301, 1958.
5. Webb, W. R., and Howard, H. S.: Cardio-pulmonary Transplantation. *Surg. Forum* 8:313, 1958.
6. Willman, V. L., Jelinek, M., Cooper, T., Tsunekawa, T., Kaiser, B. C., and Hanlin, C. K.: Metabolism of the Transplanted Heart. Effect of Excision and Reimplantation of Myocardial Glycogen, Hexokinase and Acetylcholine Esterase. *Surgery* 56:266 (July) 1964.
7. Faber, L. P., Kenwell, J. M., and Beattie, E. J., Jr.: Homologous Lung Transplantation. *A.M.A. Arch. Surg.* 83:491 (Oct.) 1961.
8. Christiansen, K. H., Mawr, B., Smith, D. E., and Pinch, L. W.: Homologous Transplantation of Canine Lungs. *A.M.A. Arch. Surg.* 86:495 (Mar.) 1963.
9. Hardy, J. D., Eraslan, S., Dalton, M. L., Jr., Alican, F., and Turner, M. D.: Reimplantation and Homotransplantation of the Lung. *Ann. Surg.* 157:707 (May) 1963.
10. Nigro, S. L., Reimann, A. F., Mock, L. F., Fry, W. A., Benfield, J. R., and Adams, W. E.: Dogs Surviving with a Reimplanted Lung. *J.A.M.A.* 183:854 (Mar.) 1963.
11. Blumenstock, D. A., Collins, J. A., Hechtman, H. B., Hosbein, D. J., Thomas, E. D., and Ferrebee, J. W.: Late Results of Homotransplantation of the Lungs in Dogs. *Dis. Chest* 45:484 (May) 1964.
12. Nettleblad, S. J., Soroff, H. S., Sachs, B. F., Sharma, A. N., Bellas, A. E., Sherman, J., Harrison, H. N., and Deterling, R. A.: Experimental Studies of the Response to Homotransplantation of Pulmonary Tissues. *Ann. N. Y. Acad. Sc.* 120:689 (Nov.) 1964.
13. Calne, R. Y., and Murray, J. E.: Inhibition of the Rejection of Renal Homografts in Dogs by Burroughs-Wellcome 57-322. *Surg. Forum* 12:118, 1961.
14. Searle, D. S.: Notes for Investigators, Imuran, Azathioprine. Burroughs-Wellcome and Co. Inc., Tuckahoe, New York (Aug.) 1965.
15. Yagi, M., Ogura, J., Kawasaki, M., and Takenouchi, S.: Hemodynamics and Physiological Aspects of the Replanted Canine Larynx (to be published).
16. Takenouchi, S., Ogura, J., Kawasaki, M., and Yagi, M.: Technical Problems of the Replanted and Homotransplanted Canine Larynx (to be published).
17. Kawasaki, M., Ogura, J., and Takenouchi, S.: Surgical Pathology of the Replanted Canine Larynx (to be published).
18. Kawasaki, M., Ogura, J., and Takenouchi, S.: Current Status of the Homotransplanted Canine Larynx (to be published).
19. Gussenbauer, C.: Zur Casuistik der Kehlkopf-Exstirpation. *Prager Medicinische Wochenschrift* 8:31 (Aug.) 1883.
20. McCall, J. W., and Whitaker, C. W.: The Use of Prosthesis in the Larynx and Trachea. A Preliminary Report. *ANNALS OF OTOTOLOGY, RHINOLOGY AND LARYNGOLOGY* 71:397, 1962.
21. Ogura, J. H., Shumrick, D. A., and Lapidot, A.: Some Observations on Experimental Laryngeal Substitution in Laryngectomized Dogs. *ANNALS OF OTOTOLOGY, RHINOLOGY AND LARYNGOLOGY* 71:532, 1962.

22. Doty, R., and Bosma, J. F.: An Electromyographic Analysis of Reflex Deglutition. *Jour. Neurophysiol.* 19:44, 1956.
23. Kawasaki, M., Ogura, J. H., and Takenouchi, S.: Neurophysiologic Observations on Normal Deglutition. I. Its Relationship with the Respiratory Cycle. *Laryngoscope* 74:1766, 1964.
24. Kawasaki, M., Ogura, J. H., and Takenouchi, S.: Neurophysiologic Observations on Normal Deglutition. II. Its Relationship to Allied Phenomena. *Laryngoscope* 74:1767, 1964.
25. Ogura, J. H., Kawasaki, M., and Takenouchi, S.: Neurophysiologic Observations on the Adaptive Mechanism of Deglutition. *ANNALS OF OTOTOLOGY, RHINOLOGY AND LARYNGOLOGY* 73:1062, 1964.
26. Ogura, J. H., and Roper, C. L.: Surgical Correction of Traumatic Stenosis of the Larynx and Pharynx. *Laryngoscope* 72:468, 1962.
27. Ogura, J. H., and Powers, W. E.: Functional Restitution of Traumatic Stenosis of the Larynx and Pharynx. *Laryngoscope* 74:1081, 1964.
28. Work, W. W., and Boles, R.: Larynx Replantation in the Dog. *A.M.A. Arch. Otolaryngol.* 82:401, 1965.
29. Boles, R.: Larynx Replantation in the Dog. Presented at the Middle Section of the Amer. Triol. Soc. (Jan. 23) 1966, Indianapolis, Ind.

DISCUSSION

DR. LOUIS H. CLERF: When I was elected a Fellow of this Association in 1925 laryngectomy was considered a mutilating operation and there were many Fellows of the Association who felt it was unjustifiable even in the presence of carcinoma with a view of saving the patient's life. I am very happy to have lived long enough to see that there are now provided replacements, even if it is your own larynx, and to me this is one of the most remarkable advances that I believe has ever been reported before this Association, in spite of the fact that we have been in the forefront in advancing whatever is good and desirable in the field of laryngology. I do want to compliment Dr. Ogura and his associates for their ingenuity, imagination, resourcefulness—and, happily, also the fact that they have a lot of resources to work with in this field.

I am convinced—and I sincerely hope that I will still be around when he or his associates, or other Fellows—and I emphasize "Fellows"—of this Association will be presenting to us the first successful case of a human being who has been presented with somebody else's larynx from the deep freeze.

HISTOPATHOLOGY OF LARYNGES AND RADICAL NECK SPECIMENS

IN A COMBINED RADIATION AND SURGERY PROGRAM
FOR ADVANCED CARCINOMA OF THE
LARYNX AND LARYNGOPHARYNX

JOSEPH L. GOLDMAN, M.D.

ROBERT V. CHEREN, M.D. FREDERICK G. ZAK, M.D.
(by invitation) (by invitation)

AND

MELVIN J. GUNSBERG, M.D.
(by invitation)

NEW YORK, N. Y.

The program of combined radiation and surgical therapy for advanced carcinoma of the larynx and laryngopharynx was started in the Department of Otolaryngology at The Mount Sinai Hospital in 1958.^{1,2} Included in this program were patients who could be classified as stage III as determined by the VIIth International Congress of Cancer.³ Reclassifying the 37 patients involved according to the criteria of the American Joint Committee on Cancer Staging and End Results Reporting,⁴ it was found that 19 belonged in stage IV, nine in stage III and nine in stage II.

The treatment program is a unified and uncompromising plan and involves, first, 5500 rads tumor dose of cobalt 60 to the primary tumor and neck nodes via parallel opposed ports in five to six weeks. The second phase comprises an interval waiting period of three to six

From the Department of Otolaryngology, The Mount Sinai Hospital and School of Medicine, New York, N. Y.

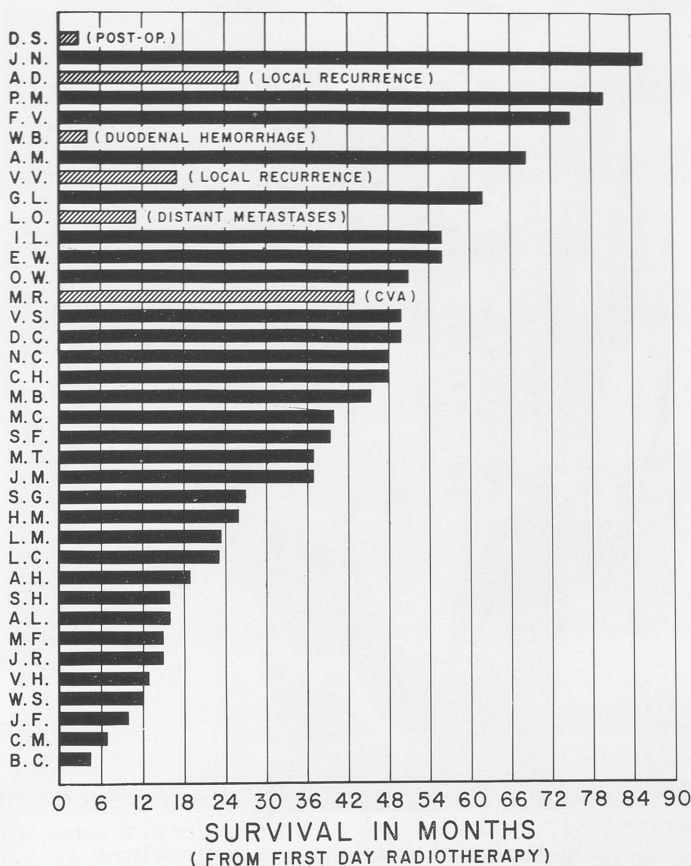
weeks after the end of therapy to allow the radiation reaction to subside. The third phase is the surgical procedure, generally consisting of wide-field laryngectomy, ipsilateral hemithyroidectomy and radical neck dissection. The extent of the surgery is determined by the preradiation examination of the lesion and is not modified by the apparent response of the tumor to radiotherapy. Thus far, 37 patients have been treated and 19 of 25 are living and free from disease for periods ranging from two to seven years (Table I). The survival rate for two years is 76%, for three years 74%. The available literature indicates that the difference between the two and five year survival rates of these cancers treated with radiation is only 10%.⁵ Since the expected survival rates of these cancers treated with either radiation or surgery alone is about 10 to 40%,^{6-18,24} it would seem that the combined therapy approach will at least double the survival figure for advanced cancer in the locations described.

As a result of the preliminary clinical effectiveness of this program, a histopathological study of resected laryngeal and neck specimens was undertaken in 1961 in order to determine precisely the effect of radiotherapy. We studied in detail, by the serial section technique (Fig. 1), the manner in which the cancer cells regressed and were destroyed and the location of residual tumor nests.

A preradiation description of the appearance of the larynx on mirror laryngoscopy and the results of palpation of the neck were recorded on the patient's hospital chart. A diagrammatic map was made of the larynx (Fig. 2) and neck (Fig. 3) representing the site and size of the primary tumor and the size and location of the palpably involved cervical nodes. These maps were brought to the operating room at the time of surgery and served as a guide to indicate the extent of the resection. Further delineation of the lesion was obtained by tomograms and laryngograms.

The surgical specimens, consisting of larynx or laryngopharynx, neck specimen and ipsilateral half of the thyroid gland, were taken from the operating room immediately after extirpation, examined grossly and then photographed. The larynx with its extrinsic muscles then was dissected free from the neck specimen and placed in 20% formalin. The sternocleidomastoid muscle was dissected from the remainder of the neck specimen and sent to the pathology laboratory for routine study. The neck tissue was affixed to cork board with thumb tacks in such a way that its configuration resembled that in the body as closely as possible. This tissue then was immersed in 10%

TABLE I



formalin and retained beneath the surface of the formalin by means of lead weights.

The larynx was not split in order to preserve normal anatomic relationships. Sectioning was done in the coronal plane since this was perpendicular to most of the laryngeal mucosa. The entire planar surface of the specimen was retained on one slide so that the relationships of the tumor to the various anatomic structures within the larynx were not disturbed. The sections obtained were large and had to be mounted on lantern slides which were $3\frac{1}{4} \times 4$ inches in size. Furthermore, the processing of so large a volume of tissue dictated that imbedding be done in celloidin rather than in paraffin.

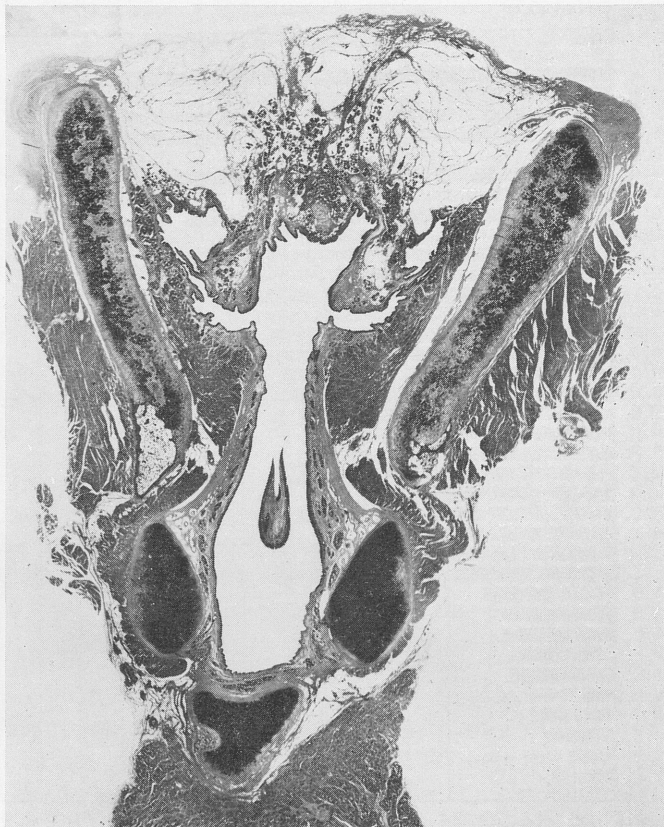


Fig. 1.—Typical coronal section of irradiated larynx.

PREPARATION OF THE LARYNGEAL SECTIONS

The technique of preparation of the larynges is derived from that described by Broyles and by Tucker.¹⁹ We have had to modify this technique because of tissue changes induced by the pre-operative radiotherapy.

Preservation. The technique of preservation is the same as that described by Tucker. The specimen is placed in 20% formalin for 48 hours. The volume of formalin is at least ten times the volume of the tissue being prepared. After the 48 hours, the larynx is placed in 10% formalin for an additional three days with a daily change of the formalin.

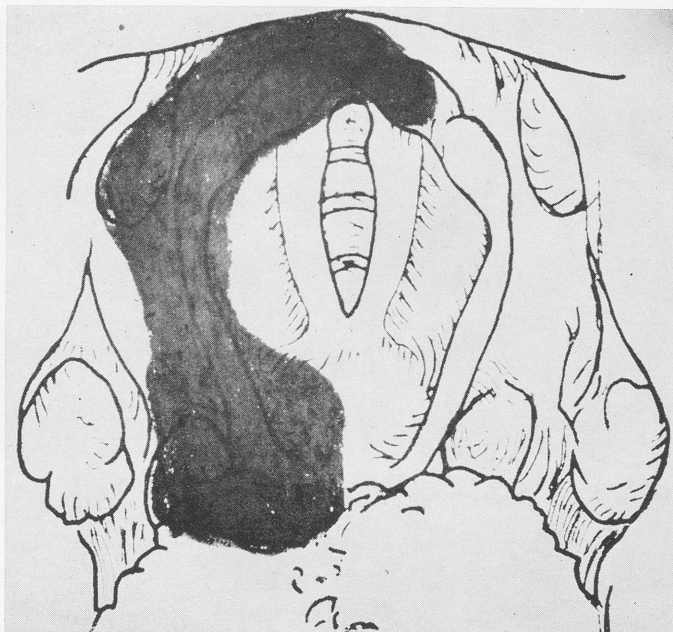


Fig. 2.—Diagrammatic map of larynx with site and size of tumor represented.

Decalcification. The tissue is decalcified with 1% nitric acid in 10% formalin. The decalcifying solution is changed daily until the calcium precipitation test is negative. The first test is performed after the tissue is in solution for 10 days and the test becomes negative in 10 to 30 days. After a negative calcium precipitation test has been obtained, the tissue is retained in the decalcifying solution for a period equal to that which was necessary for decalcification, again with daily changes of solution, and the tissue then is washed in running tap water for one day.

Dehydration. The specimen is dehydrated by being placed in progressively increasing concentrations of alcohol as follows: 35, 50, 80, 90, 95% for three days in each, again with daily changes of solution. Dehydration is completed in absolute alcohol for two days followed by equal parts of absolute alcohol and ether for one day.

Imbedding. Because the bulk of tissue is so great, imbedding is accomplished in progressively increasing concentrations of celloidin (parlodion): one and one-half per cent celloidin for one week, fol-

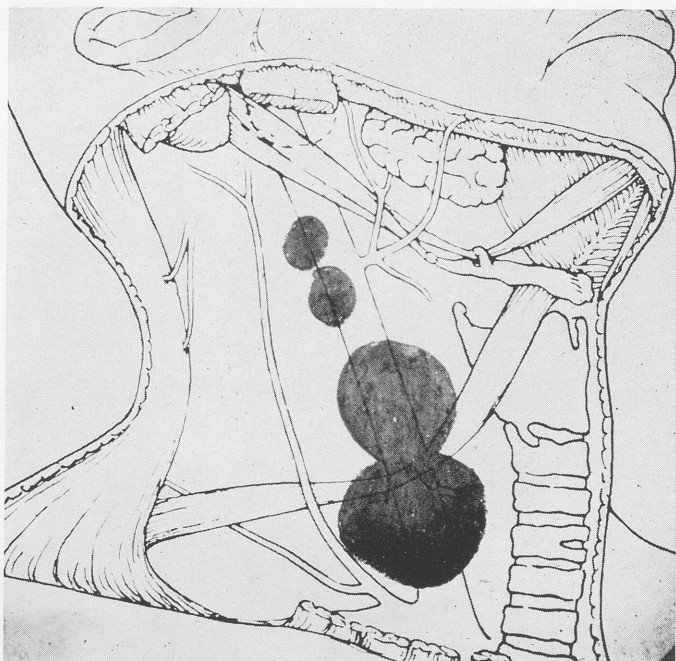


Fig. 3.—Diagrammatic map of neck with size and location of palpably involved cervical nodes indicated.

lowed by 4%, 8%, and 12% celloidin for five weeks in each strength, and then 15% celloidin for one week. At this point the cover of the specimen jar is loosened to permit slow evaporation of the solvent which results in the hardening of the celloidin block. This requires four to five months. Final hardening is then achieved with equal mixtures of chloroform and 80% alcohol for 5 to 15 days followed by chloroform alone for an additional seven days. Finally, the celloidin block is placed in 80% alcohol for storage.

Sectioning and Staining. The tissue block is trimmed and mounted on specially designed large block holders. It is important that the trimming of the celloidin be done in such a way as to allow the posterior surface of the larynx to be parallel to the block holder. This permits sectioning in the true coronal plane. Serial sections 24 to 28 microns thick then are cut and stored in 80% alcohol between numbered onionskin paper sheets. Every tenth slide is stained with hematoxylin and eosin and mounted on $3\frac{1}{4} \times 4$ inches slides; alter-

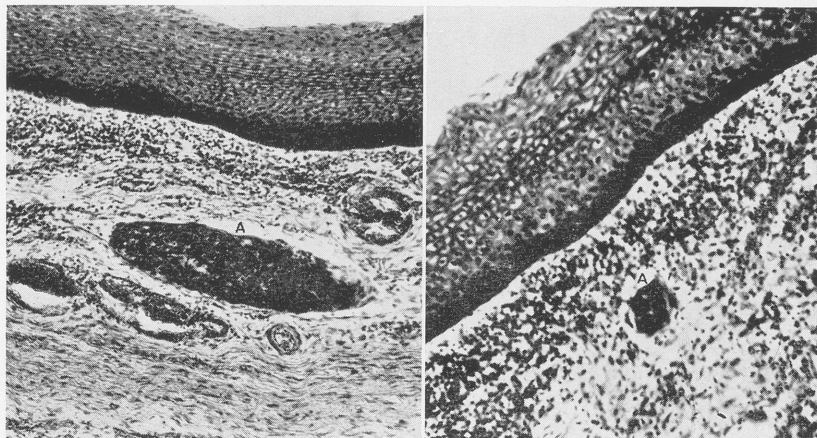


Fig. 4.—Cancer focus (A) in subcutaneous tissue beneath intact mucous membrane.

Fig. 5.—Cancer cells in lymphatic (A) underlying intact mucous membrane.

nate fortieth slides are stained with an elastic or a Masson trichrome stain and similarly mounted. The remaining sections are stored unstained and unmounted between numbered onionskins in large glass jars for any additional studies that may become indicated in the future.

In order to accommodate these large sections, we had to institute several modifications on the standard Spencer No. 860 microtome. First, the vertical distance between the knife edge and the block holder had to be increased because of the thickness of our specimens. This was accomplished by means of steel plates bolted in place between the knife arm and body of the microtome. An especially large block holder was machine-tooled for our tissue blocks and a large clamp was obtained to hold the block holder firmly in place. Because of the restricted distance between the clamp and the body of the microtome, the metal flange by which the block holder was held in the clamp was placed towards the edge of the block holder near the microtome.

PREPARATION OF RADICAL NECK DISSECTION SPECIMENS

In the routine pathology laboratory a radical neck specimen generally yields 20 to 30 lymph nodes. In accordance with our pur-

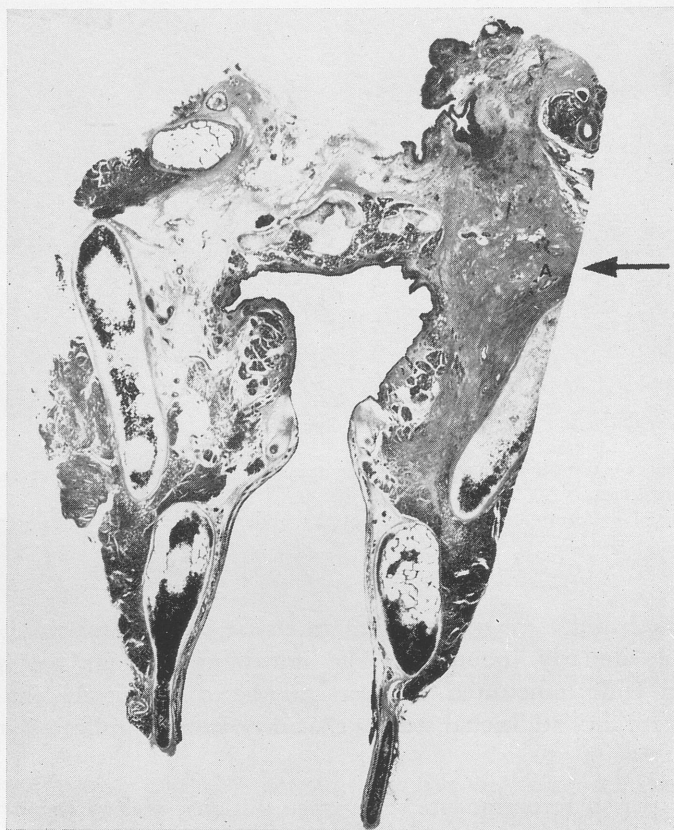


Fig. 6.—Nest of cancer cells (A) 1.5 cm distant from mucosal surface.

pose of doing a minute histologic study, we adopted a technique of "clearing" of the neck tissue. This method involved the use of cedar-wood oil which changes the refractive index of light transmitted through the specimen and yielded 85 to 100 or more lymph nodes per neck specimen. However, this technique has been abandoned since 1) it does not include the study of soft tissues outside the lymph nodes, and 2) the opportunity to demonstrate the precise pathways of lymphatic involvement by tumor is lost after removing the nodes from the specimen. Therefore, it was decided to study the entire neck specimen, exclusive of the sternocleidomastoid muscle, by the serial section technique.

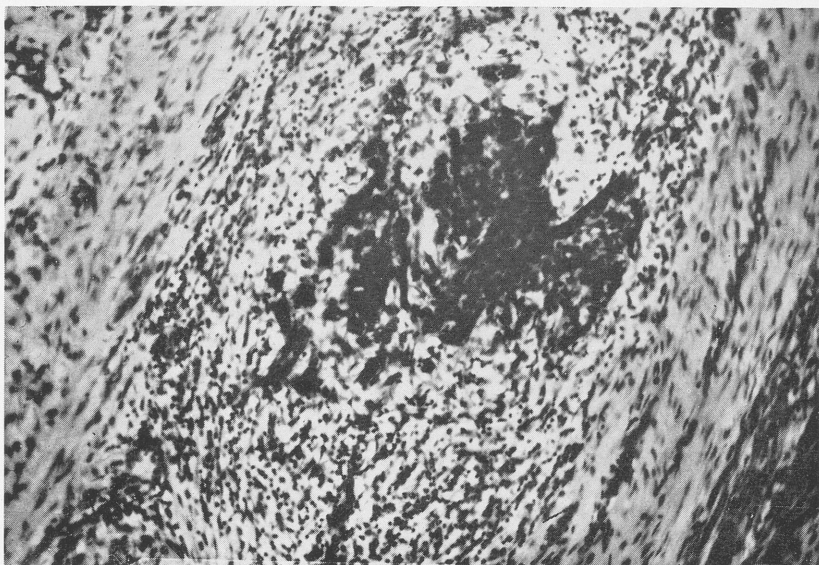


Fig. 7.—High power view of cancer nest shown in previous illustration.

The technique of preparation of the neck specimens is actually adapted from a method of preparing brain tissue but involves most of the same steps as for the larynges.

Preservation. The tissue is allowed to remain in 10% formalin for 48 hours with daily changes of solution. Again, the volume of formalin is at least 10 times that of the tissue.

Decalcification. This is accomplished with a mixture of 5% nitric acid and 10% formalin for 10 days or more with daily changes of solution. When the calcium precipitation test becomes negative, neutralization is accomplished with 5% sodium sulfate for two days, and the tissue then is washed with running tap water for one day.

Dehydration. The specimen is dehydrated in progressively increasing concentrations of alcohol: 80%, 95% and absolute alcohol for two days each, with daily changes of solution followed by one day in equal mixtures of absolute alcohol and ether.

Imbedding. Impregnation with celloidin is carried out in progressively increasing concentrations starting with the specimen in

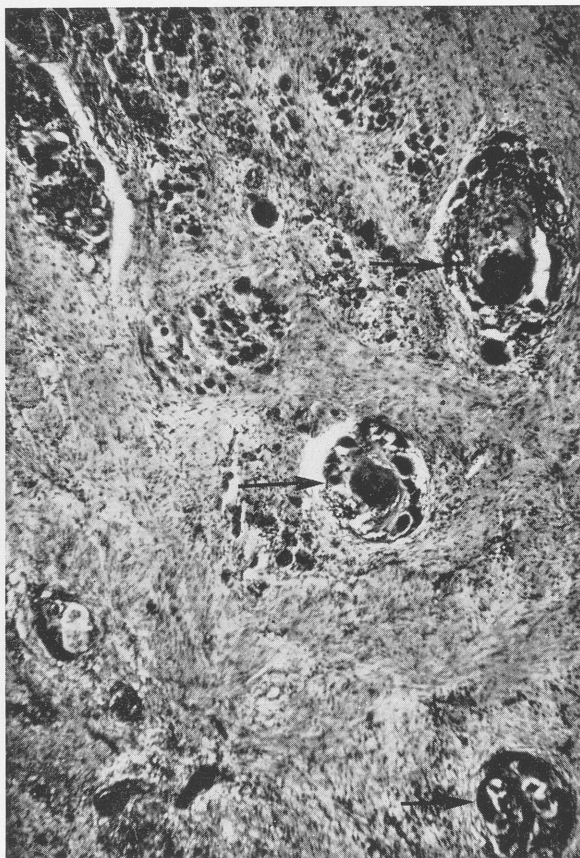


Fig. 8.—Region, formerly involved by cancer, now occupied by multiple foreign body giant cells containing fully keratinized pearls.

1½% celloidin for five days, then in 3% celloidin for two weeks, 6% celloidin for two and one-half weeks, 12% celloidin for three weeks, and finally 15% celloidin for five days.

Following this, slow evaporation of the solvent is permitted to take place in order to harden the celloidin block. This requires about three weeks. Final hardening is brought about by adding chloroform for two days, and then transferring the tissue block to 80% alcohol for at least two days.

At this point one might conceivably proceed with sectioning and staining. The entire planar surface of the neck would be obtained on each slide and the problem of tracing the pathways of metastatic nodal involvement would be facilitated. However, the cost of the required slides and cover slips is prohibitive. Therefore, we divide the tissue block into three segments and then proceed with sectioning.

Sectioning and Staining. The celloidin block is trimmed so that the specimen will lie as nearly parallel to the block holder as possible. The deep aspect of the specimen is placed facing the block holder. The sections are cut 18 microns thick and placed between numbered onionskins in 80% alcohol. Every tenth section is stained with hematoxylin and eosin. When the sections are mounted on the $3\frac{1}{4} \times 4$ inches glass slides, the slides are labelled stating from which one of the three neck segments the section originated and its depth within the tissue block. In this way we are able to reconstitute the entire neck specimen.

RESULTS OF STUDIES OF LARYNGEAL SPECIMENS

Of the 37 patients treated by combined therapy, the larynges of the first 10 were studied in the routine pathology laboratory. There was excellent correlation between the clinical impression and the results of routine histopathologic study. Four were thought to be clinically negative for residual tumor on mirror laryngoscopy following irradiation, and all of them were histologically negative. Five were both clinically and microscopically positive, and only one was clinically negative and microscopically positive. These figures are disconcerting, however, in that they would seem to indicate that four of the 10 operative procedures removed cured larynges. This is in marked contrast to the clinically observed fact that the expected cure rate of lesions of this size by radiation^{5,13-17} is only 10 to 15%.

The larynges of the other 27 patients were submitted for processing for serial section examination. Eleven of these have been studied completely and form the basis of this report. On mirror laryngoscopy after irradiation, seven of these 11 patients showed no evidence of residual tumor but actually did contain cancer remnants on serial section study. It was believed from physical examination that the four other larynges harbored residual cancer, but only two of the four showed cancer on histological examination. Thus, there was a

lack of clinical and histologic correlation in nine of the 11 specimens. Two larynges were found to be free from cancer on serial section study of every tenth slide.

In order to be more certain that both the laryngeal and neck specimens indeed have been "cured" of cancer, we have inaugurated a policy of staining and examining every fifth slide of every specimen found negative on the usual serial section study. We believe that this program once completed will make the chance of missing any cancer nests insignificant.

The size of the residual tumor nests that frequently were found in the larynges is of major importance. In five cases there were several tumor nests 0.5 millimeters or less in diameter. Two cases contained solitary tumor nodules between 0.8 and 1 millimeter in diameter; another revealed the presence of a nest 1.8 millimeters in diameter. In the remaining larynx studied there was a single focus 1 x 1.5 centimeters in size. It becomes apparent, then, that in most cases the response to 5500 rads of teletherapy is such that the tumor regresses into tiny nests. In the hands of many clinicians, teletherapy in the dose range of 5500 to 6500 rads is given as the primary treatment modality, and the patient is subjected to operation only if the lesion fails to respond to radiotherapy or if there is evidence of recurrence of neoplasm on mirror laryngoscopy some time after the end of the radiation treatment. It is our contention that the small size of the tumor remnants usually found after this dosage range makes clinical evaluation of residual tumor very difficult or perhaps impossible for even the most experienced clinician. We also feel that the practice of doing random biopsies on an irradiated larynx carries with it only a small chance of finding these minute nests.

The location of the cancer remnants is even more significant than their size. We have seen cancer subjacent to intact mucous membrane both lying free in the subcutaneous tissues (Fig. 4) and in lymphatics (Fig. 5). The most diligent follow-up examinations of these patients would fail to reveal the presence of these foci, and surgery performed only after clinical observation of recurrent cancer would have to deal with a new generation of cancer cells with the attendant poor results of surgery for recurrent cancer. We believe that our findings seriously question the practice of treating advanced cancer of the larynx with therapeutic levels of radiation and operating only after the clinical appearance of residual carcinoma.

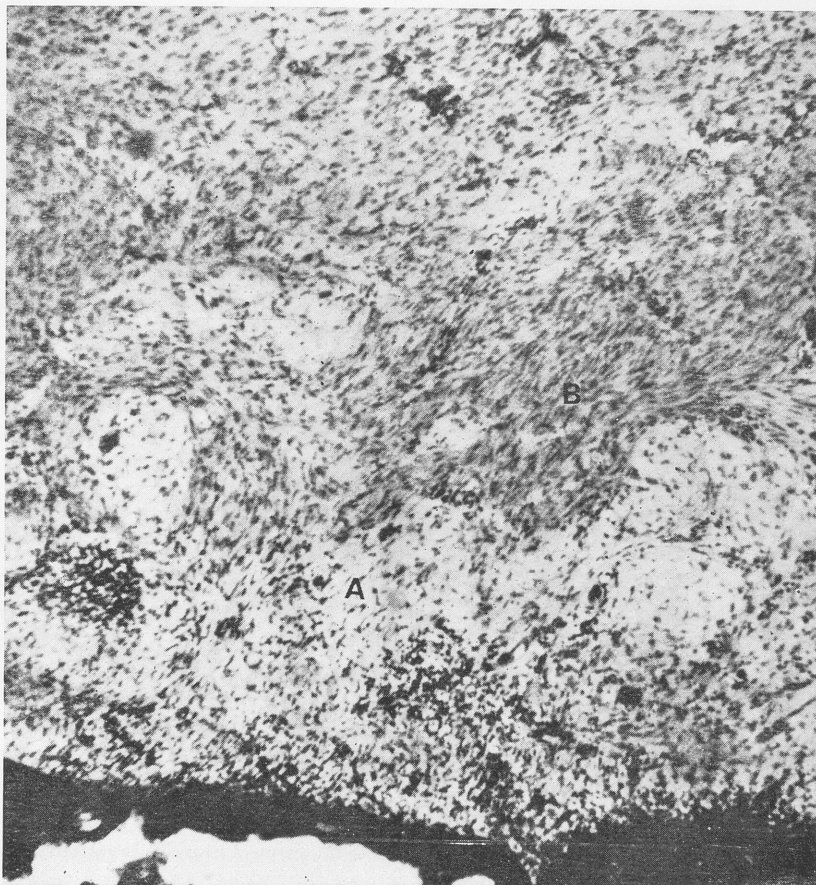


Fig. 9.—Area, formerly filled with cancer, now occupied by young fibroblasts (A) and more mature connective tissue (B).

Another principle which has become clear as a result of our studies is that it is essential to remove the same volume of tissue which would have been excised if surgery had been done as the sole modality of treatment. If carcinoma were to undergo a centripetal regression as its response to therapeutic levels of irradiation, it would be possible to do a less extensive resection after radiotherapy. On the contrary, we have seen nests of tumor cells distant from the mucosal surface presumed to be the origin of the neoplasm (Figs. 6, 7). The locations

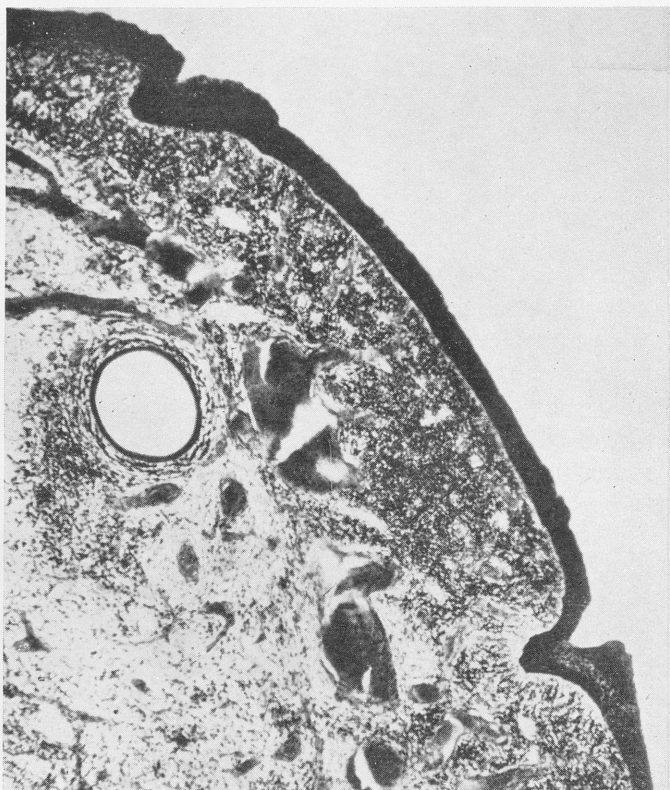


Fig. 10.—Young connective tissue containing randomly scattered blood vessels surrounded by inflammatory cells in tissue formerly involved by cancer.

of the residual cancer follow no discernible pattern and can lie anywhere in the area previously occupied by tumor.

RESPONSE OF TUMOR AND HOST TISSUES TO IRRADIATION

The histopathological response of the radiation reaction of both tumor and host tissue has been observed. Some of the tumor cells retain a normal cytoarchitecture. The fact that these cells seem to be morphologically normal is not necessarily proof that they have retained the biologic capacity for reproducing themselves and becoming ultimately the sources of recurrent cancer. The problem of deter-

mining cell viability is an important one and will be discussed in a subsequent section of this presentation.

Often tumor cells are seen with pyknotic nuclei and vacuolization of cytoplasm. Despite the fact that these cells retain the ability to take a stain, they are dead and will go on to dissolution. Another stage in the radiation reaction of tumors is represented by "lakes" that appear in regions formerly filled with cancer. These "lakes" appear to be keratin on low power; however, on higher magnification they are found to be cellular debris.

As cancer cells are destroyed, they usually evoke a foreign body giant cell reaction. These giant cells remove the destroyed cancer cells. We have seen giant cells containing dying tumor cells, parakeratotic cancer cells, fully keratinized pearls (Fig. 8), and foreign body granulomas surrounding an empty canoe-shaped space filled formerly with cholesterol esters from degenerated cells dissolved by the ether alcohol in the processing.

In a later stage of the radiation reaction, the giant cells themselves disappear and are replaced by young fibroblasts (Fig. 9). In the region of this newly formed connective tissue many small blood vessels sometimes are found arranged in a haphazard manner with considerable surrounding inflammation (Fig. 10). Still later, dense connective tissue which is relatively avascular appears.

In both ventricles of each larynx examined to date we have noted an abnormal squamous metaplasia of the normal respiratory epithelium (Fig. 11). There is a loss of cell polarity and the presence of large cells with huge polyploid nuclei. In some areas the normal respiratory epithelium overlies the metaplastic epithelium (Fig. 12), and in others the normal epithelium joins the metaplastic epithelium at an acute angle. In most cases the transition is abrupt. These changes if present in the epithelium of the uterine cervix would be interpreted as carcinoma-in-situ. However, that diagnosis implies that these changes, if untreated, would progress to an invasive carcinoma. Since we do not know that this is true in the larynx, we cannot call this carcinoma-in-situ; instead we have chosen the term "atypical hyperplasia." Recently, we have seen this same picture in the true cord, false cord and pyriform sinus in addition to the ventricle. Gabriel Tucker, Jr. has afforded us the opportunity to study the serial sections of four unirradiated laryngeal carcinomas and the same findings again were noted. We have made similar observations in our own unirradiated specimens. There is no apparent relationship

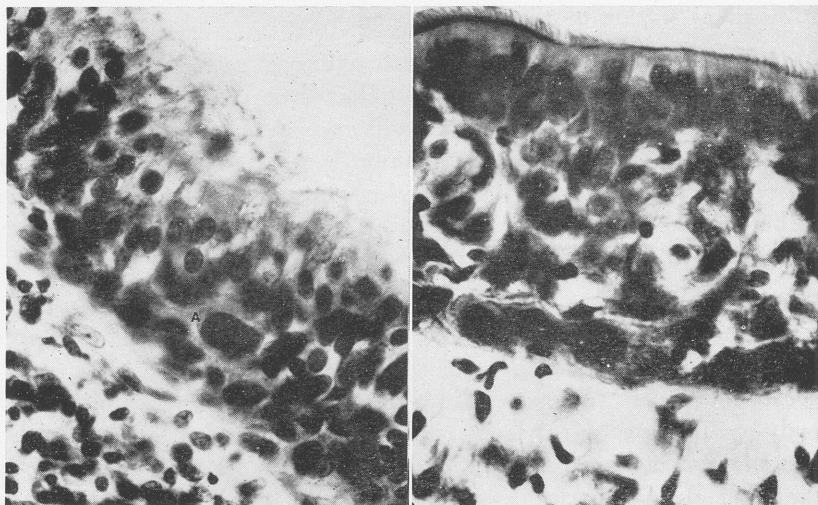


Fig. 11.—Mucosa of laryngeal ventricle showing atypical hyperplasia. Note large polyploid nucleus (A).

Fig. 12.—Normal ciliated columnar epithelium overlying area of atypical hyperplasia.

between the sites involved by carcinoma and the locations of the atypical hyperplasia. The changes have been seen in both ventricles even in association with strictly unilateral lesions. In its extra ventricular locations, this change has been noted in the mucous membrane of the pyriform sinus overlying an infiltrating carcinoma and in the laryngeal mucosa far removed from the sites involved by cancer. In an attempt to gain further insight into the significance of this finding, we have inaugurated a program of collecting the larynges of patients who have died of bronchogenic carcinoma to determine if atypical hyperplasia exists in these specimens. We are wondering whether these changes are related to smoking.

The atypical hyperplasia discussed does not appear to be part of the radiation reaction in the larynx. The response of laryngeal epithelium to therapeutic levels of irradiation is usually a squamous metaplasia of the epithelial surfaces normally lined with columnar epithelium.²⁰ The squamous epithelium thus formed has none of the abnormal features described as atypical hyperplasia. Other changes in the epithelium as a result of radiation include squamous metaplasia of the ducts of mucous glands without evidence of obstruction and a pemph-

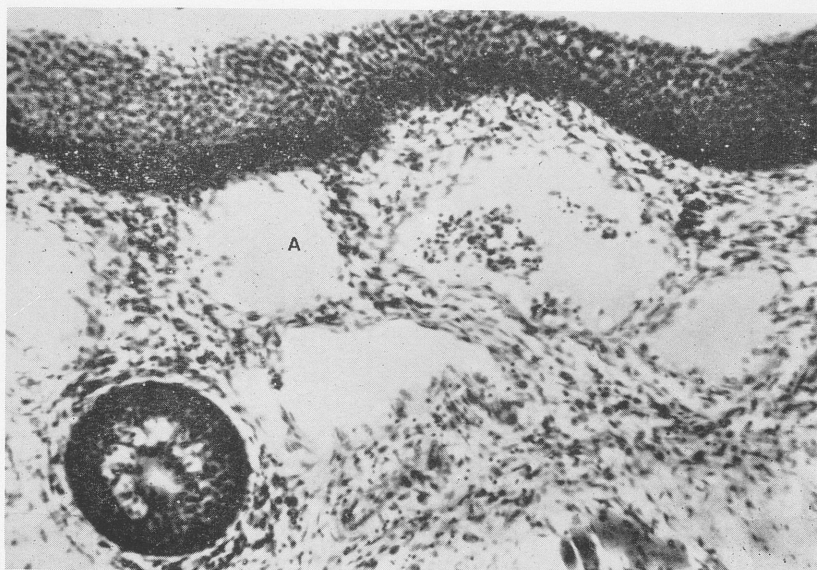


Fig. 13.—Submucosal lymphangiectasia (A).

igus-like mucous vesiculation of the squamous lining of the surface epithelium. This latter finding of mucosal retention cysts indicates that the ducts of the mucous glands are blocked and is probably responsible for the absence of the mucus blanket and consequent dryness of the throat so distressing to these patients.

Muscle changes induced by radiation include atrophy of muscle fibers with multiple sarcolemmal nuclei, Zenker's degeneration with deposition of hyaline, and replacement of muscle fibers with fat cells and scar tissue.

Peripheral nerves, normally resistant to radiation, also have been found to undergo degenerative changes in some instances. Changes in nerves include marked swelling of the myelin sheaths and the presence of myelin figures. These changes appear to be focal in nature; we have seen a full-blown radiation reaction in one nerve, and no histologic change in another just several millimeters away. It may well be that host tissue factors play a role in this regard.

Changes in irradiated blood vessels also have been noted. Submucosal lymphangiectasia is a common finding (Fig. 13). This is

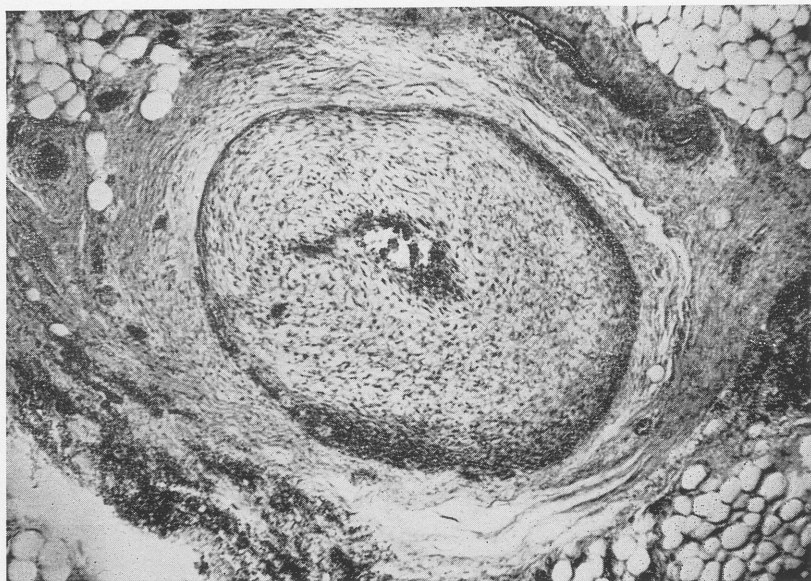


Fig. 14.—Paratracheal artery showing marked endothelial proliferation.

thought to be due to obliteration of lymph channels by intimal proliferation with resulting lymph stasis locally. Similarly, endothelial proliferation of small blood vessels is observed frequently (Fig. 14). There is also fragmentation of the elastic fibers in the tunica media as well as hyalinization of the smooth muscle fibers. In addition fibrosis of the adventitia is seen often. As a result of all these changes there is encroachment on the lumen leading to thrombosis and obliteration of the smaller vessels and reduced caliber of the lumen of larger vessels. These radiation effects also may account for the increase in the incidence of blood vessel rupture in the presence of wound infection and fistulization. The long-term effects of radionecrosis are probably due, in part at least, to chronic anoxia of the irradiated tissues.

Changes in the cartilage include perichondritis, chondritis and cartilage necrosis of a minor degree. Whether the cartilage necrosis is a direct effect of radiation or secondary to the effects of radiation on nutrient vessels and perichondrium has not been answered as yet by this study.

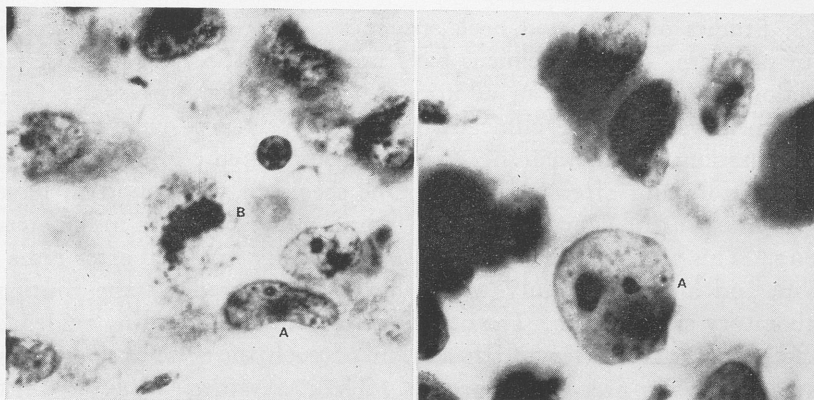


Fig. 15.—Irradiated larynx with cell (A) showing normal nuclear morphology. Note cell (B) in mitosis. These cells are considered viable.

Fig. 16.—Irradiated cell (A) showing clumping of nuclear chromatin, absence of bands of chromatin. No mitotic figures seen. These cells are considered non-viable.

Radiation effects in elastic tissue are seen most readily in the larger blood vessels and in the conus elasticus. The characteristic response to radiation appears to be a fragmentation of the elastic fiber with clumping and disarray of the fragmented fibers. In unilateral lesions we have at times observed a greater effect on the conus elasticus on the same side as the tumor and a relatively normal conus on the other side of the larynx. This has been true even in the presence of lesions which are entirely supraglottic. Again, there arises the question of the influence of local tissue factors on the radiation reaction.

INTERESTING ANATOMIC FINDINGS

In addition to the radiation induced changes, we have noted certain interesting anatomic findings. We have observed a true joint lined with synovial membrane between the body and lesser cornua on either side of the hyoid bone. It is our impression that such a finding has not been described previously. We also have seen paraganglia lying outside the larynx just external to the cricoid cartilage. Paraganglia in this region have been described rarely and there have been no reports of carotid body tumors arising from this region. Taste buds are a common finding in the supraglottic larynx.

STUDIES OF RADICAL NECK DISSECTION SPECIMENS

Studies of irradiated neck specimens were inaugurated later in our program. Four specimens have been studied so far by the serial section technique, and an additional 13 are being processed. One specimen was negative clinically pre-operatively and on microscopic examination. The remaining three were considered clinically positive both before and after radiation. One specimen was found to have a single focus of cancer cells in a lymph node just four millimeters long. This was not the node felt to be clinically involved after radiation, and almost certainly would have been missed by the routine laboratory examination. The other two specimens showed no evidence of cancer, and so every fifth section of each of these specimens is currently being prepared for study. The program of studying neck dissection specimens by the serial section method was instituted in part because of the observed fact that there had been poor correlation between the results of routine pathological study and the clinical impression of the status of metastatic nodes following radiotherapy.⁴

CANCER CELL VIABILITY FOLLOWING IRRADIATION

We have alluded earlier to the problem of cell viability. Up to now viability has been established by the presence of the physical criteria within the cells as observed under the highest magnification of the light microscope (1600 x). If the nuclear morphology, such as nucleoli, chromocenters and chromatin bands, after radiation resembled that in the cell of the preradiation biopsy specimen, that cell was considered viable.²¹ It is probably not valid, however, to assume that an irradiated cancer cell which has retained its morphology also has retained its biologic capacity to reproduce itself as a cancer cell. Supportive evidence for viability is the finding of mitotic figures within nests of residual tumor cells after radiation (Figs. 15 and 16).*

In order to test these criteria and provide additional information concerning cancer cell biology, a separate but related study has been discussed. This would involve testing the ability of cancer cells to elaborate desoxyribonucleic acid (DNA) following exposure to 5500 rads of irradiation by labeling the irradiated tissue with tritiated thymidine and then examining the labeled cells with microautoradiographic techniques.^{22,23}

* This phase of our study has been carried out under the guidance of Dr. Herbert E. Nieburgs, Director of the Cytology Laboratory in the Department of Pathology.

SUMMARY AND CONCLUSIONS

Combined therapy of advanced carcinoma of the larynx and laryngopharynx is a three phase program consisting of 5500 rads tumor dose of cobalt 60, followed by an interval waiting period of three to six weeks, and then the radical surgical procedure. The extent of the surgical resection is planned on the basis of the preradiation examination of the lesion, and is not altered by the response of the tumor to radiotherapy. To date, 37 patients, classified stage III by the international system, have been treated with a three year survival rate of 74%.

The primary purpose of this paper is to present the findings of histopathological examinations of the resected tissues. The laryngeal and neck specimens removed at operation were subjected to processing with celloidin for serial section study. The technique of processing is complicated and time-consuming. Sections were cut about 26 microns thick and every tenth section was mounted and examined. The locations and sizes of residual cancer nests were noted. Negative specimens were subjected to even more detailed scrutiny to rule out the presence of very minute cancer foci.

This study so far strongly suggests that the clinical appearance of a larynx after exposure to therapeutic levels of irradiation is a poor indicator of whether or not that larynx harbors residual cancer. In most cases the residual cancer nests were too small to be seen by the naked eye. Furthermore, cancer remnants were found underlying intact mucous membrane. This fact alone would seem to question a policy of observation after radiation. It is true that in a very small percentage of cases an irradiated larynx appearing clinically normal may indeed be cured of cancer. In the large majority of instances, however, a period of observation will only serve to allow a new generation of cancer cells to develop and thereby might negate the therapeutic effectiveness of radiation.

It has been our observation that squamous cell carcinoma in the larynx undergoes regression into small cancer islands distributed at random in the tumor bed. Radiation does not cause regression of cancer towards a central core. Thus, pre-operative radiotherapy does not favor a less extensive curative surgical resection. Any treatment program which depends upon biopsy of radiated tissue to determine the limits of resection inevitably will have a high percentage of recurrences. It is not uncommon to observe both areas of cancer-free

tissue in the tumor bed and cancer islands close to the preradiation tumor margins.

Destroyed cancer cells elicited a foreign body giant cell reaction with subsequent replacement of giant cells by connective tissue.

An atypical hyperplasia of the mucosa of larynges in areas not involved with cancer, particularly in the ventricles, was described. This was an intriguing finding and its significance is being explored.

The radiation reaction in mucous membranes, mucosal glands, muscles, nerves, blood vessels, cartilage and elastic tissue was noted.

Interesting anatomic findings were described such as the presence of a true joint between the body and lesser cornua of the hyoid bone, and the existence of paraganglia just outside the larynx.

Of three neck specimens which were considered positive before and after radiation, two were found to be free from cancer on serial section study of every tenth slide. This aspect of the study promises to yield valuable information. One conclusion which seems warranted is that a node which remains palpable after radiotherapy may be free from cancer.

The problem of determining cell viability of irradiated tissue was discussed briefly. The present criteria relied on details of nuclear morphology. A histochemical approach to this problem has been discussed.

11 EAST 100 ST.

We wish to express our appreciation to Mrs. Trudy Pollak for technical assistance.

REFERENCES

1. Goldman, J. L., and Silverstone, S. M.: Combined Radiation and Surgical Therapy for Cancer of the Larynx and Laryngopharynx. *Trans. Am. Acad. Ophthalmol. and Otolaryngol.* 65:496-507 (July-Aug.) 1961.
2. Goldman, J. L., Silverstone, S. M., Rosin, H. D., Cheren, R. V., and Zak, F. G.: Combined Radiation and Surgical Therapy for Cancer of the Larynx and Laryngopharynx II. *Laryngoscope* 74:1111-1134 (Aug.) 1964.
3. Nabre, M. O. R.: Clinical Stage Classification of Malignant Tumors of the Larynx. *Acta Un. Int. Cancer* 16:1865-1873, 1960.
4. Smith, R. R., Caulk, R. M., Russell, W. O., and Jackson, C. L.: End Results in 600 Laryngeal Cancers Using the American Joint Committee's Proposed Method of Stage Classification and End Results Reporting. *Surg., Gynec. and Obstet.* 113: 435-444 (Oct.) 1961.
5. Harris, W., Silverstone, S. M., and Kramer, R.: Roentgen Therapy for Cancer of the Larynx and Laryngopharynx. *Am. Jour. Roentgenol.* 71:813-825 (May) 1954.

6. Pietrantoni, L., and Firo, R.: Clinical and Surgical Problems of Cancer of the Larynx and Hypopharynx. *Acta Otolaryngol.* (Stockholm) Supplement 142:1-61, 1958.
7. Orton, H. B.: Symposium: Carcinoma of the Larynx. *Trans. Am. Acad. Ophthalmol. and Otolaryngol.* 58:30-34 (Jan.-Feb.) 1954.
8. Martin, H., quoted by Morfit, H. N.: Surgical Treatment of Cancer of the Extrinsic Larynx and Hypopharyngeal Walls. *Surgery* 37:229-241 (Jan.-June) 1955.
9. Clerf, L. H.: Evaluation of Dissection of the Neck in Carcinoma of the Larynx. *ANNALS OF OTOTOLOGY, RHINOLOGY AND LARYNGOLOGY* 64:451-456 (June) 1955.
10. Norris, C. M.: Causes of Failure in Surgical Treatment of Malignant Tumors of the Larynx. *ANNALS OF OTOTOLOGY, RHINOLOGY AND LARYNGOLOGY* 68:487-508 (June) 1959.
11. Hendrick, J. W.: Surgical Treatment of Larynx and Hypopharynx Cancer. *Arch. Otolaryngol.* 79:269-287 (Mar.) 1964.
12. MacComb, W. S., and Fletcher, G. H.: Planned Combination of Surgery and Radiation in Treatment of Advanced Head and Neck Cancers. *Am. Jour. Roentgenol.* 77:397-414 (Mar.) 1957.
13. LeRoux-Robert, J.: Etude Statistique de 644 Cas de Cancers du Larynx et de l'Hypopharynx Traites par Chirurgie au Associations Radio-Chirurgicales. *Annales d'Otolaryngologie* 76:533-566, 1959.
14. LeRoux-Robert, J.: Indications for Radical Surgery, Partial Surgery, Radiotherapy and Combined Surgery, and Radiotherapy for Cancer of the Larynx and Hypopharynx. *ANNALS OF OTOTOLOGY, RHINOLOGY AND LARYNGOLOGY* 65:137-153 (Mar.) 1956.
15. O'Keefe, J. J.: The Surgery of Cancer of the Larynx. *ANNALS OF OTOTOLOGY, RHINOLOGY AND LARYNGOLOGY* 65:131-136 (Mar.) 1956.
16. Orton, H. B.: Surgery of Carcinoma of the Larynx. *Arch. Otolaryngol.* 64:205-206, 1956.
17. Pietrantoni, L.: Personal Communication.
18. Lederman, M.: Place of Radiotherapy in Treatment of Cancer of the Larynx. *Brit. Med. Jour.* 5240:1639-1646 (Apr.) 1961.
19. Tucker, G. F., Jr.: A Histological Method for the Study of the Spread of Carcinoma Within the Larynx. *ANNALS OF OTOTOLOGY, RHINOLOGY AND LARYNGOLOGY* 70:910-921 (Sept.) 1961.
20. Windolz, F.: Late Changes in Mucous Membrane of the Irradiated Larynx. *Radiology* 48:274-281 (Mar.) 1947.
21. Nieburgs, H. E.: Personal Communication.
22. Jofte, D. L.: Liquid Emulsion Autoradiography with Tritium. *Lab. Invest.* 8:131-136 (Jan.-Feb.) 1959.
23. Johnson, H. A., Haymaker, W. E., Rubin, J. R., Fleidner, T. M., Bond, V. P., Cronkite, E. P., and Hughes, W. L.: A Radioautographic Study of a Human Brain and Glioblastoma Multiforme After the In Vivo Uptake of Tritiated Thymidine. *Cancer* 13:636-642 (May-June) 1960.
24. Johnson, N. E., and Sisson, G. A.: Carcinoma of the Larynx. Review of 100 Cases. *Laryngoscope* 74:710-722 (May) 1964.

PRE-OPERATIVE RADIATION IN HEAD AND NECK CANCER

PRELIMINARY REPORT

E. M. SKOLNIK, M.D.

L. T. TENTA, M.D. J. N. COMITO, M.D.
(by invitation) (by invitation)

D. L. JEROME, M.D.
(by invitation)

CHICAGO, ILL.

There has been a surge of interest in re-evaluation of combined therapy in mouth, tongue, pharynx, hypopharynx and larynx, employing supervoltage irradiation plus a full surgical resection.^{1,2} An initial evaluation of this proposition would logically assume that this is a resurgence of past history, where irradiation failures underwent definitive surgery, now complicated to some extent by irradiation effects on the surrounding normal tissues and by a delay in initiating the surgical management. The same, of course, may be said for surgical failures exposed to delayed and hampered irradiation therapy. However, the significant differences in several studies have been that supervoltage is the source of irradiation, that both a tumorcidal and a tumorostatic dosage level is attempted for ultimate comparison of tissue effects, and a fully definitive surgical extirpation is part of the over-all plan of therapy.

Since October of 1963 a program of combined pre-operative radiation and surgery has been employed in the treatment of advanced malignant lesions of the head and neck. These lesions had in common surgical resectability and a prognosis for two years of less than

From the Department of Otolaryngology, College of Medicine of the University of Illinois at the Medical Center, Chicago, and the Research and Educational Hospitals and the Illinois Eye and Ear Infirmary.

TABLE I
ANTICIPATED 5 YEAR SURVIVAL RATES
ARE DEPICTED

From Smith et al.⁵

	<i>Surg.</i>	<i>Rad.</i>
Stage I	92%	92%
Stage II	75%	58%
Stage III	48%	25%
Stage IV	34%	0%

50 per cent (Table I). It must be emphasized that an operable situation was not being sought by administering radiation to an inoperable case. It was with the thought of enhancing the survival that such a program was devised.

PRE-OPERATIVE RADIATION PROTOCOL FOR ADVANCED HEAD AND NECK CANCER

Population Under Study. All patients with primary, previously untreated, squamous cell carcinoma of the oral cavity, hypopharynx, laryngopharynx, and larynx are to be included in the population under study. This group includes all patients deemed suitable by the investigating group for randomization into the forms of treatment under test. For inclusion into this group, the following criteria must be met:

a) A practical surgical procedure must exist for surgical extirpation of the primary tumor and regional lymph nodes.¹

b) The local lesion must be advanced or the prognosis otherwise will be poor from a tumor standpoint. For oral cavity lesions, including the tonsil, this would mean patients with a primary lesion of any size and palpable clinically involved regional neck nodes or an advanced (T_4) oral cavity lesion with or without clinically positive neck nodes. All lesions of the base of the tongue, hypopharynx and laryngopharynx are to be included. Extensive intrinsic laryngeal lesion with palpable clinical positive neck nodes and T_4 intrinsic laryngeal lesions without neck nodes are also to be included in the experimental group.

This experimental group would basically exclude only T_1 , T_2 , and T_3 intrinsic laryngeal lesions. Also excluded would be any lesion

for which a practical surgical approach does not exist. These excluded patients would be treated by the best methods available in the judgment of their attending physician.

c) No evidence of distant metastasis.

d) General medical status sufficient to undergo the outlined treatment.

All patients included in the experimental group are examined prior to the institution of treatment with a view to designing the subsequent surgical procedure. This is necessary in order that an adequate surgical procedure be accomplished when radiation therapy has been completed and the gross tumor extent may be markedly reduced. In patients for whom a satisfactory surgical procedure to encompass the extent of the primary lesion and regional nodes exists, assignment is made to pre-operative radiation group A. Within this group, a random assignment to radiation therapy technique 1 and radiation therapy technique 2 is made according to the birth-date of the patient. Patients born on an even day of the month are assigned to pre-operative radiation technique 1, and patients born on the odd day of the month are assigned to pre-operative radiation technique 2. After completion of the appropriate pre-operative therapy, the initially planned surgical procedure will be accomplished at the suitable interval.

Patients considered not suitable for a surgical procedure when first seen are assigned to pre-operative radiation group 2 and one month after completion of their therapy, reconsideration given for possible surgery. If at that time such surgery is considered not technically possible, additional radiation therapy to tolerance limits is administered.

RADIATION THERAPY TECHNIQUES

A. *Equipment.* The Allis-Chalmers 23-mev betatron is used for the super-voltage radiation. The x-ray beam is used only because of its skin sparing qualities (no electron beam).

Most patients are treated at an 80 cm distance. The half value layer (HVL) of the beam is 14 mm Pb.

In the pre-operative radiation of the laryngopharyngeal region, the portal size varies from 6 x 8 to 8 x 10 cm, depending upon the extent and size of the primary.

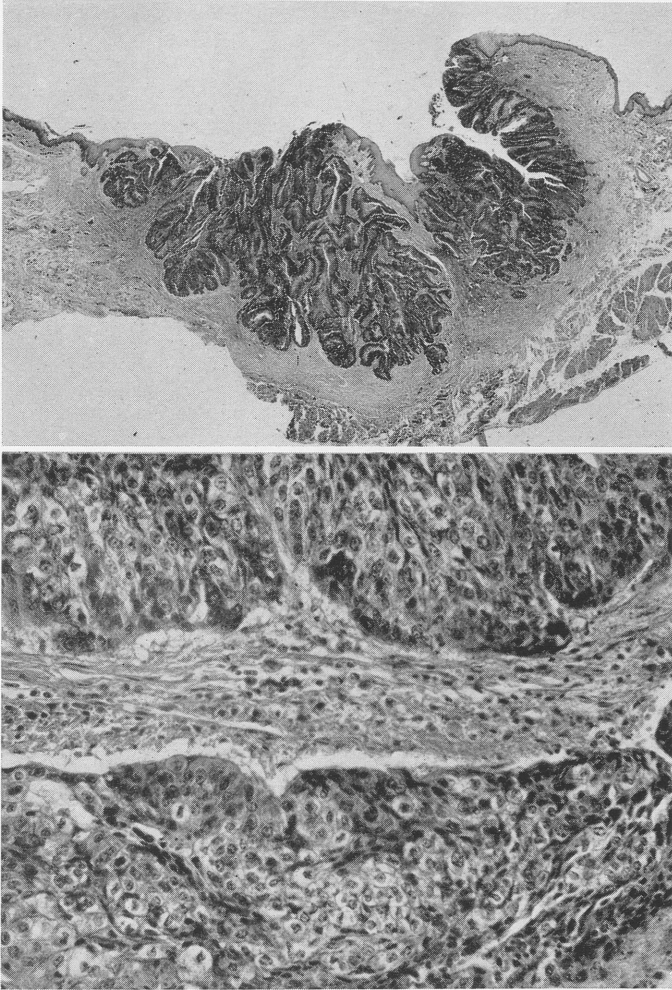


Fig. 1.—Primary. Virtually no tumor regression detectable in this primary lesion.

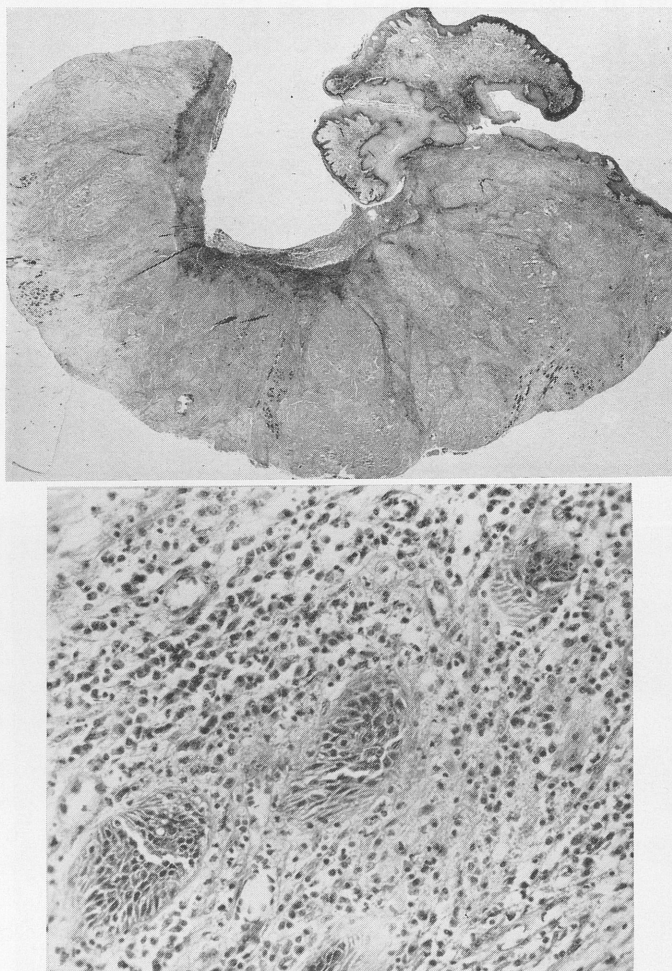


Fig. 2.—An apparently gratifying tumor response in the primary site, yet nests of neoplastic cells are scattered in the stroma.

Those patients receiving 2,000 rads receive a crossfire lateral portal technique. Originally, this amount was administered in ten days, but due to the delay in having the patient re-admitted for surgery, we now recommend that the 2,000 rads be given in five to six days. The patient remains in the hospital and is operated upon as soon as the course of treatment is completed.

Those patients receiving 5,000 rads are treated over a period of four weeks, but no longer than five weeks if necessary. If the lesion involves the midline we employ crossfire lateral technique usually to 3,500 rads and then give the additional 1,500 rads to the site of maximum involvement. This is usually given in anterior and posterior fields nearly 90 degrees to the former so as to spare the skin of the opposite uninvolved side and to reduce the dose to the spinal cord. This has also the advantage of increasing the dose to any neck nodes of the involved side which may be present.

The 5,000 rad group should be operated upon four to six week after the completion of radiation.

B. *Area of Treatment.* Treatment should be designed to include the primary site and regional lymph nodes. For lesions with unilateral neck involvement, a posterior oblique field on the ipsilateral side should be selected. For midline lesion or lesions with bilateral lymph node involvement, with the medial edge of their tumor more than 2 cm lateral to the midline, two fields from the ipsilateral side (one anterior field and one posterior oblique field) is generally satisfactory. If the primary tumor is closer to the midline, one field on each side of the head is recommended.

C. *Field Size.* Field sizes should range from a minimum of 6 x 8 cm to a maximum of 8 x 15 cm. They should be designed to include the primary and nodes in the minimum practical volume.

D. *Number of Fields.* Ordinarily, techniques should be designed as simply as possible and a two-field technique is generally recommended.

E. *Tumor Dosage.* Patients randomized into pre-operative treatment group 1 (those born on the even day of the month) are to receive a tumor dose of 2,000 rads in a period of five elapsed days. This would ordinarily be five treatments of 400 rads each. Surgery in this group will follow as soon after completion of radiation therapy as possible. Patients randomized into pre-operative treatment group 2 (those born on the odd day of the month) are to receive 5,000 rads in a minimum period of four weeks, surgery to follow three to six weeks after completion of the radiation therapy in order to permit the acute radiation reaction to subside.

SURGERY

Because of the changes in the tumor and the anatomy produced by the pre-operative radiation therapy, the surgical procedure to be

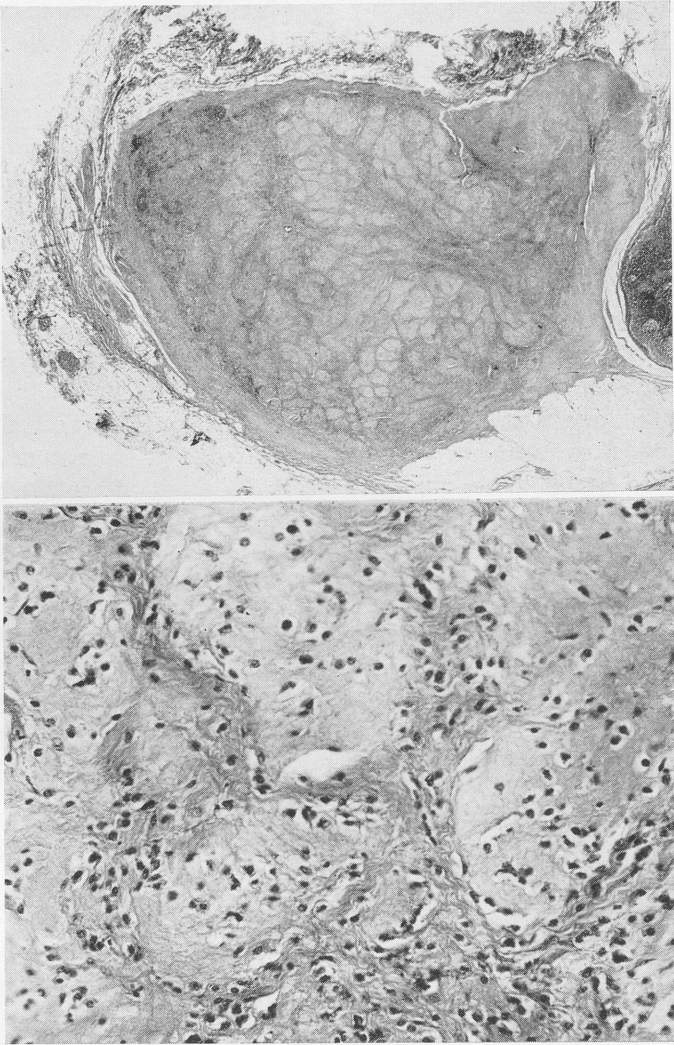


Fig. 3.—Lymph node demonstrating complete eradication of neoplastic cells and replacement of normal architecture with scattered round cell infiltrate in fibrous tissue.

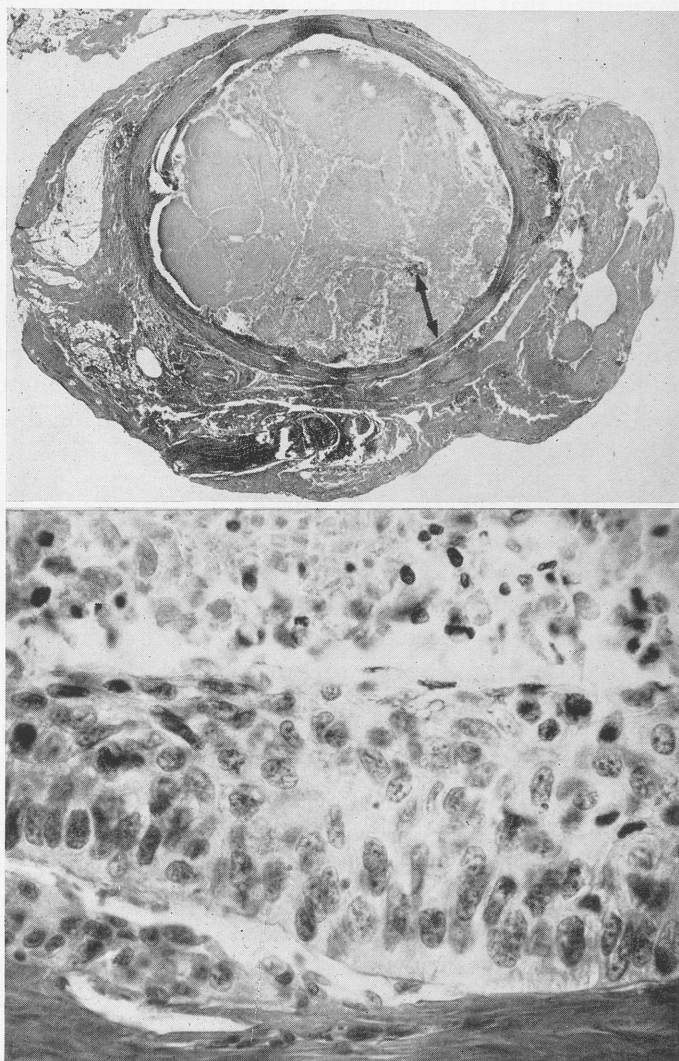


Fig. 4.—Necrotic lymph node with dense population of neoplastic cells in subcapsular area.

performed is planned prior to institution of radiation therapy. Regardless of the apparent clinical response to radiation therapy, it is to be emphasized that the planned surgical procedure is to be carried out.

Since the effect of radiation is the reduction of cellular population and mitosis, it was postulated that the administration of localized radiation to the affected area might be beneficial in augmenting the surgical attack on such lesions by circumscribing the periphery of the radiosensitive tumor cells.³ During the course of the program random samplings of the surgical specimens were studied serially by histological means. The en bloc tumor specimen was serially sectioned and every fifteenth slide examined for the presence of tumor cells and post-irradiation tissue changes. It was noted that in several patients in whom 5,000 rads were delivered to lymph nodes containing cancer cells, serial sections demonstrated complete eradication of disease in some nodes.

Paradoxically, it was also noted that in tumors of similar cytology equivalent radiation produced no discernible regressive changes. A spectrum of histopathological responses was apparent⁴ (Figs. 1, 2, 3, 4). One must re-emphasize that this is a select series of cases in which the lesion, though resectable, is quite extensive, and in which the anticipated prognosis in any patient was less than 50 per cent for a two year period. Significantly, the irradiation effect was highly variable from one patient to the next, indicating perhaps a selective biological response to the therapy. In some patients the clinical response to irradiation appeared gratifying. However, biopsies through an intact mucosa revealed the presence of active disease. Similarly, in random samplings of en bloc dissections serially studied, there was no single case in which either the primary lesion or the metastatic lymph nodes did not demonstrate the presence of tumor cells. The tumor regression that occurred in certain patients did permit, in select instances, a conservation approach to be employed during the surgery.

ANALYSIS OF CASES

A total of 79 patients received x-ray therapy (Table II). Sixty-three patients subsequently underwent surgical resection. Of the 16 patients who did not have surgery, one was deemed inoperable following x-ray therapy, two died during therapy and six adamantly refused to have any subsequent surgical procedure performed. The remain-

TABLE II

SURVIVAL RATE OF 32%

All series patients receiving 2000 and 5000 rads pre-operatively.

All of these patients had extensive malignant disease
with anticipated poor survival.

Total Survival

Mos. P.O.	A \bar{c} D	A \bar{s} D	E \bar{c} D	E \bar{s} D	No Surg.
6	2	7	3		1 ² , 1 ³
12	2	6	4		1 ¹ , 1 ³
18	2	8	6	1	2 ⁴ , 1 ²
24	2	7	9		3 ² , 3 ³
30			2	2	1 ² , 2 ³

32%

Percentages indicate
two year survival without disease

A \bar{c} D - Alive with Disease

A \bar{s} D - Alive without Disease

E \bar{c} D - Expired with Disease

E \bar{s} D - Expired without Disease

1 - inoperable

2 - patient refused surgery

3 - gratifying x-ray response -
surgery deferred

4 - expired during therapy

ing 7 are accounted for by "a gratifying clinical response to irradiation therapy (Table III). Of these 7 there is only one survivor who is alive without evidence of disease 6 months since the conclusion of his irradiation therapy. Of the 6, 2 subsequently had surgery and all 6 have died with evidence of persistent disease.

With respect to the 63 patients operated upon, comment will be restricted to those whose elapsed time since surgery is more than two years. Tables are included (Tables IV to IX) tabulating all patients

TABLE III

Total series patients irradiated (79).
Total series patients operated upon (63).

ALL LESIONS

	2000R	5000R
Total cases	35	44
Cases oper.	30	29 (2)
Refused	3	3 (2)
Good response to x-ray	1 (1)	7
Inoperable	1 (2)	2

from 6 months to two and one-half years following their ultimate therapy. For graphic purposes these extensive lesions were classified anatomically as laryngopharyngeal and oropharyngeal. Each of these classes is divided according to the amount of the administered radiation, either 2,000 rads or 5,000 rads (Tables IV and V). There are 22 cases two years postoperative, 9 of which are alive, 7 without disease and 2 with persistent disease (Tables IV and V). Both patients with persistent disease occurred in the 5,000 rads group. One might draw attention to the fact that all patients in the 5,000 rads group had surgery deferred for a period of 4 to 6 weeks following conclusion of irradiation therapy. Of these same two patients, one presented a primary lesion in the laryngopharynx, the other in the oropharynx.

Among the 22 patients, 9 had received 2,000 rads pre-operatively. A total of 4 patients survived (44%), all with laryngopharyngeal lesions. There were no survivors with the oropharyngeal lesion. Superficially, there appears to be no difference in survival of the patients with oral pharyngeal lesions irrespective of the amount of radiotherapy. One must note, however, that there were but 2 patients in this latter category. A total of 3 surviving patients is found among the 13 (38) in the 5,000 rads group. All 3 patients had laryngopharyngeal lesions. There were no survivors in the oral pharyngeal group. In the 15 laryngopharyngeal lesions, the best results apparently occurred in those 7 patients who fell into the 2,000 rads group. There is a 19% disparity between the 57% survival rate of laryngopharyngeal lesions having 2,000 rads and 38% survival in the 5,000 rads group. Considering the entire project from the point

TABLE IV

These charts show all series patients with pre-operative radiation depicting the survival results according to radiation received.

All Head and Neck
Series Patients

2000R

Mos. P.O.	A \bar{c} D	A \bar{s} D	E \bar{c} D	E \bar{s} D	No Surg.
6	2	2	2		1 ²
12	2	3	2		
18		4	4		1 ⁴
24		4	4		1 ³ , 2 ²
30			1		

44%

All Head and Neck
Series Patients

5000R

Mos. P.O.	A \bar{c} D	A \bar{s} D	E \bar{c} D	E \bar{s} D	No Surg.
6		5	1		1 ³
12		3	2		1 ¹ , 1 ³
18	2	4	2	1	1 ⁴ , 1 ²
24	2	3	5		1 ² , 2 ³
30			1	2	2 ³ , 1 ²

23%

TABLE V

These charts depict survival results of laryngeal lesions receiving 2000 and 5000 rads.

Larynx**2000R**

Mos. P.O.	A \bar{c} D	A \bar{s} D	E \bar{c} D	E \bar{s} D	No Surg.
6	2	1	1		
12	1	3			
18		2	2		
24		2	1		2 ²
30					

66%

Larynx**5000R**

Mos. P.O.	A \bar{c} D	A \bar{s} D	E \bar{c} D	E \bar{s} D	No Surg.
6		4			
12		2			
18	1	2	1	1	1 ²
24		2	3		1 ³
30					

40%

of view of anatomical sites of the primaries, that is laryngopharynx or oral pharynx, one finds the sole survivals to occur in the laryngopharyngeal group.

COMPLICATIONS

The claim that postoperative morbidity is not substantially increased cannot be entirely supported by surgical experience. A course

TABLE VI

The survival results in pharyngeal and lateral pharyngeal wall lesions receiving 2000 and 5000 rads are revealed.

Pharynx and Lateral
Pharyngeal Wall

2000R

Mos. P. O.	A \bar{c} D	A \bar{s} D	E \bar{c} D	E \bar{s} D	No Surg.
6					
12					
18			2		
24		1	1		
30					

50%

Pharynx and Lateral
Pharyngeal Wall

5000R

Mos. P. O.	A \bar{c} D	A \bar{s} D	E \bar{c} D	E \bar{s} D	No Surg.
6					
12					
18		1			1 ⁴
24	1				
30					1 ²

0%

of irradiation, involving a dose averaging 5,000 to 6,000 rads delivered to a vascular area such as the neck, carries the possibility of some degree of anemia from the destruction of blood corpuscles. Therefore, during the postirradiation phase and for a varying time, the general healing powers of the tissues must inevitably be impaired.

TABLE VII

These charts show survival results in base of tongue and epiglottic lesions receiving 2000 and 5000 rads.

Base of Tongue and Epiglottis

2000R

Mos. P. O.	A \bar{c} D	A \bar{s} D	E \bar{c} D	E \bar{s} D	No Surg.
6		1			1 ²
12	1				
18					
24		1	1		1 ³
30					

50%

Base of Tongue and Epiglottis

5000R

Mos. P. O.	A \bar{c} D	A \bar{s} D	E \bar{c} D	E \bar{s} D	No Surg.
6					
12		1	1		1 ³
18	1	1			
24		1			1 ³ , 1 ³
30				1	1 ³

50%

At every level, the normal vascular bed and its innervation are, therefore, impaired to a greater or lesser extent by the developing fibrosis and as the blood flow from one level to another is reduced. There may also be other less identifiable and perhaps more profound changes in the irradiated tissues whereby the cells are enfeebled and their growth and reparative powers affected, even when the blood

TABLE VIII

These charts indicate survival results of the combined laryngopharyngeal lesions. Laryngopharynx includes larynx, base of tongue and epiglottis, as well as pharynx and lateral pharyngeal wall.

Laryngo-Pharynx

2000R

Mos. P. O.	A \bar{c} D	A \bar{s} D	E \bar{c} D	E \bar{s} D	No Surg.
6	2	2	1		1 ²
12	2	3			
18		2	4		
24		4	3		1 ³ , 2 ²
30					

57%

Laryngo-Pharynx

5000R

Mos. P. O.	A \bar{c} D	A \bar{s} D	E \bar{c} D	E \bar{s} D	No Surg.
6		4			
12		3	1		1 ³
18	2	4	1	1	1 ⁴ , 1 ²
24	1	3	3		2 ³
30				1	1 ²

38%

supply appears adequate. This is sometimes demonstrated by the failure of apparently good skin to accept a transferred well-vascularized tube pedicle graft.

The disabling complications of pharyngocutaneous fistulae and massive carotid artery hemorrhage were studied in all cases irrespec-

TABLE IX

These charts depict survival rates in oral pharyngeal lesions which include anterior 2/3 of tongue, floor of mouth, gingiva, tonsillar and soft palate.

Oral-Pharyngeal

2000R

Mos. P.O.	A \bar{C} D	A \bar{S} D	E \bar{C} D	E \bar{S} D	No Surg.
6			1		
12			2		
18		2			1 ²
24			1		
30			1		

0%

Oral-Pharyngeal

5000R

Mos. P.O.	A \bar{C} D	A \bar{S} D	E \bar{C} D	E \bar{S} D	No Surg.
6		1	1		1 ³
12			1		1 ¹
18			1		
24	1		2		1 ²
30			1	1	2 ³

0%

tive of the elapsed postsurgical time (Table X). A pharyngocutaneous fistula evident beyond the fourteenth postoperative day occurred in 33 of the 63 cases (52 per cent). Twelve of these cases were in the 2,000 rads series and of these, 9 closed spontaneously. In the 5,000 rads series, 9 of the fistulae closed spontaneously. Of the 3 cases of persistent pharyngocutaneous fistula in the 2,000 rad cases,

TABLE X

Thirty-three patients developed fistulae of which 15 required reconstructive closure. Carotid artery hemorrhage invariably occurred in the presence of persistent fistula and disease.

COMPLICATIONS		
	2000R	5000R
Primary healing	18	12
Fistula	12	21
Fistula healed	9	9
Persistent fistula	3	12
Carotid a. blowout	1	2

2 evidenced persistent disease, only 1 of whom is alive. The third is alive, 6 months postoperative, without evidence of persistent or recurrent disease. Of the 12 cases of persistent pharyngocutaneous fistula in the 5,000 rads program, 5 displayed disease from one month through 2 years postoperatively, two of whom are surviving. Of the remaining 8 patients free of tumor activity, one died 18 months postoperatively without evidence of disease. The elapsed time from surgery of the survivors spans 3 to 24 months.

In summary, the persistence of a pharyngocutaneous fistula in the 2,000 rad series usually indicated presence of active disease. In contrast, active disease was present in less than half of the cases of persistent fistula in the 5,000 rad series, leading one to surmise that the poor healing response might in some way be related to the effect of the radiation.

The alarming hemorrhage from carotid artery blowout occurred in 3 of the 63 patients operated upon (5%). All 3 patients manifested a pharyngocutaneous fistula. All survived the acute hemorrhagic diathesis. The sole patient from the 2,000 rads group died one month following ligation, with active disease. The remaining 2 from the 5,000 rads series are alive but with disease present in the primary site. These patients had, as common denominators, persistent pharyngocutaneous fistulae and presence of persistent disease at the primary site.

TABLE XI

Anatomic comparison of lesions in 2000 and 5000 rad series, indicating augmentation of 2 year survival in laryngopharyngeal group and disappointing results in oropharyngeal group.

	2000R	5000R
Laryngopharynx	57%	38%
Oral-pharynx	0%	0%
Total	44%	23%
Combined	32%	

	2000R	5000R
Tong. and epig.	50%	50%
Larynx	66%	40%
Pyrif. sinus	50%	0%
Total	57%	38%

SUMMARY

A program of combined pre-operative irradiation therapy has been presented. Cases included in this study were those which, based upon previous experience, were operable but judged to have a prognosis of less than 50 per cent two year survival. The methodology and protocol of irradiation therapy has been presented. A tabulation of all patients in the entire study is included and discussion of survival is centered about those patients in whom surgery was performed at least two years prior to this publication.

The histological changes that occur with irradiation therapy are noted. Attention is drawn to the fact that random histological samplings of the en bloc dissections serially sectioned demonstrated that in no case was there complete eradication of the tumor either in the primary site or in the metastatic lymph node following irradiation therapy. It is also noted, however, that in certain select instances in which a tumor regressive response occurred, a conservation type of procedure was performed. Postoperative complications, namely, those of pharyngocutaneous fistulae and carotid artery hemorrhage, are mentioned.

CONCLUSIONS

The morbidity of the patient operated upon was accentuated by the incidence of persistent pharyngocutaneous fistulae. These fistulae were more common in the 5,000 rads group. Those that occurred in the 2,000 rads group were coincidental with a poor prognosis and usually indicated persistence of the neoplastic process.

Considering the laryngopharyngeal lesions as a unit, the combined modality of radiation therapy and surgery did augment the two year survival. In the oral-pharyngeal group, the results were disappointing (Table XI).

One must recognize that this is an early, though not premature, appraisal of a continuing program. Although trends appear, a definite statistical analysis of the data and population must await further long term case studies.

1853 WEST POLK ST.

We acknowledge with thanks the assistance of the Division of Radiotherapy, Edwin J. Liebner, M.D., Director.

REFERENCES

1. Goldman, J. L., et al.: Combined Radiation and Surgical Therapy for Cancer of the Larynx and Laryngopharynx. *Laryngoscope* 73:1111-1134 (Aug.) 1964.
2. Powers, W. E., and Ogura, J. H.: Pre-operative Irradiation in Head and Neck Cancer Surgery. *Arch. Otolaryng.* 81:153-158 (Feb.) 1965.
3. Skolnik, E. M.: Therapy of Laryngeal Cancer. *Arch. of Otolaryng.* 83:98-100 (Feb.) 1966.
4. Skolnik, E. M., Tenta, L. T., and Comito, J. N.: Surgical Planning Modified by Irradiation. VIIIth Internat. Cong. Otorhinolaryng., Tokyo, Japan (Oct.) 1965.
5. Smith, R. R., et al.: American Joint Committee Proposed Method of Stage Classification and End Result Reporting Applied to 1320 Pharynx Cancers. *Cancer* 16:1505-1520 (Dec.) 1963.

DISCUSSION

DR. GEORGE A. SISSON: The use of pre-operative irradiation for the control and cure of cancer is certainly not new. This procedure, I presume, is up for discussion today to determine whether or not it should be considered as a standard part of our therapeutic armamentarium. This method of treatment is the subject of debate in other specialties. The skin sparing qualities of CO-60 and other super-voltage radiation have contributed considerably to this increase in interest.

Today we are attempting to evaluate in our Society two papers that have presented current statistical and histological evidence that there is merit in planned

and programmed combined radiotherapy, particularly in reference to the head and neck.

Theoretically there are three reasons why such a program might be advocated.

The first is that the radiotherapy possibly could render a locally inoperable lesion resectable. When one subscribes to this concept, then it follows that he must have accepted the theory that inoperable primary cancer is actually radiosensitive. This has been substantiated in the laboratory by such investigators as Powers, Tohmach, Ogura and others. However, most radiotherapists, and Dr. Moss particularly comes to mind in this regard, state on record that they reject this theory in the absence of clear cut clinical confirmation.

The second reason for advocating pre-operative therapy is the current thought that possibly one could render highly malignant cells non-viable, thereby lessening local and distant seeding of malignant cells during surgery. Hoyer and Smith in 1961 substantiated this theory in laboratory work on mice.

A third reason frequently presented, and particularly true in head and neck cancers, is that it is often difficult to accurately estimate the extent of spread. Many times this pre-operative judgment is necessary in order to select the most effective method of treatment.

Two essays have just been presented on this subject. Dr. Goldman and his group actually were modern pioneers, having started their pilot study in 1958. Their scholarly approach and particularly their careful laboratory work has quickened the interest of many pathologists, radiotherapists and, of course, otolaryngologists. What we truly want to learn is whether or not we can accept these conclusions—are we ready to accept them and are we ready to use them? Because of the tedious technical problems ever present in the laboratory as well as the inordinate number of man hours necessary to study final specimens, this report today involves only thirty-seven cases although it does cover an eight year period. The specimens are from eleven larynxes and four necks, but even with this small series a trend is detected. However, I feel we must critically analyze the 76%, two-year rate that he has reported. This was perhaps highlighted a bit more in the original manuscript than it was today. In the paper it is compared to the 10% to 30% cure rate and so implies that results with pre-operative therapy show a 40% to 60% improvement in cure rate. This conclusion is based on the report that since 1958 nineteen out of twenty-five survived for at least two years. If we are to accept this, then I think we have to ask Dr. Goldman one question, and I am certain he has the answer. Why are stage II and stage III cases included? Perhaps it is a retro-classification.

While I personally might favor using pre-operative radiotherapy for certain stage II and III laryngeal cancers, I still would hesitate to include them in an advanced laryngeal protocol for fear they would weight the statistics, since by standard methods their cure rates are high.

Our reported five-year cure rate statistics reported in Syracuse showed an 83% cure rate for forty-eight cases in stage II, an 86% cure rate for nine cases in stage III and only a 30% cure rate for twelve cases in stage IV. In a larger series, mentioned in both papers, Smith reported a 75% cure rate for stage II and a 48% rate for stage III. Consequently, I would like to ask Dr. Goldman if any of his nineteen cases still alive are stage II or stage III? Or, conversely, of the six cases that died, how many were stage IV? It would be of interest if Dr. Goldman could include stage IV cases *only* or possibly classify somewhat more precisely in his stage II and III cases.

Dr. Skolnik and his co-workers have taken on a most ambitious project and, as he mentioned, it is a preliminary report. In a sense it seems that he is analyzing two distinctly differently planned programs.

One is the effect of irradiation when used to prevent neck node recurrences, somewhat similar to Dr. Frazell's series at Memorial; the other is a program on irradiating advanced head and neck lesions with 5000 rads, somewhat similar to Dr. Goldman's series.

Possibly it should be noted that this series is partially randomized. However, neither the New York nor the Chicago series has randomized controls. Of course, the need for controls is recognized, but we are all sympathetic to how difficult, how impractical and often how inhumane rigid controls can become when applied in a randomized series involving human beings. When a favorable trend is reflected, we all want to use it.

Dr. Skolnik's series, as used for both his programs, includes seventy-nine cases; and, as he has stated, only twenty-two are ready for a two-year evaluation. The graphs that I have received and actually that part of the paper that Dr. Skolnik didn't have time to present pointed out how few cases were used to make his conclusion, and so I think, and Dr. Skolnik would probably agree, that it is too early in this series to even consider a trend.

Both reports demonstrate the difficulty encountered when trying to persuade a patient to undergo surgery. Both convincingly pointed out that the absence of disease cannot be proven by clinical examination or standard histopathological methods, particularly with the beautiful sections of the still viable submucosal tissue.

In spite of what our colleagues, the radiotherapists, would like us to believe, fistulae and complications are a problem. Both authors brought out this point and I personally will continue to use pre-operative radiation in selected lesions of the head and neck. I do not believe we have to date enough laboratory evidence to extend this modality to other than certain highly selected cases. At this time we only have a clinical impression and a small amount of laboratory evidence that is really of value.

I would hope that more investigators and more laboratories will take on these programs.

DR. GABRIEL F. TUCKER, JR.: In listening, I am reminded of a question which comes from the laboratory work we have done. Since starting on our modification of Dr. Broyles' original method we have studied over a hundred larynges. It is true that few of these are combined therapy patients, but there are some radiation failure cases which bring out a point which I think might be further investigated.

In some of these failures there was found—in the area around the residual tumor—relatively unirradiated tissue. Now to us this would suggest that in these cases, radiation as a method, failed although it was probably due to the fact that the radiation beam did not hit all the ramifications of the tumor. In Dr. Goldman's material there were cricothyroid nodes in the very anterior part of the specimen; there was also posterior arytenoid disease in the posterior part of the specimen. I wonder if, as his work progresses, correlation was made for irradiation effect immediately to the tumor and if correlation was made with the radiotherapist's ports and his ability to stick to the port he planned.

DR. DOUGLAS P. BRYCE: I have listened to both these papers with great interest because we have also engaged in this field for more than five years now and we feel very enthusiastic about the use of pre-operative radiotherapy.

I merely want to make one point, which will not help the situation, but—

Dr. Goldman, you are aware of the difficulty in maintaining a rigid program in this field. In other words, the patient who has had his radiotherapy is feeling

much better and you wait five weeks and you have difficulty in convincing him, and his referring physician, that a radical surgical procedure should be followed.

I suggest that on the basis of some recent research that possibly the future in this field of pre-operative radiotherapy will be along the lines that we have followed recently in which we have given the patient a largish dose of radiotherapy, 1000 r, in selected cases an hour prior to the surgical procedure and then have carried out our radical surgical procedure. This applies chiefly in the field of pharyngolaryngectomy and has great advantage in that you are eliminating the problems of post-operative complications.

Just a suggestion which will throw a little more confusion into the picture!

DR. GOLDMAN (closing): It is not possible at this hour to answer all the questions that can arise in relation to this complex problem. I shall try to answer a few of them.

It is obvious that if a program of this kind is to be successful, the original plan must be observed very accurately. As I indicated in the last few slides, the lesions that are mapped before radiotherapy are the tissues that must be excised, which include the entire original tumor. Any deviation from this will lead to recurrences.

You are aware of the difficulties that have existed in the past with regard to classification. There is no one classification which is perfect. When we started this work in 1958, the classification that was accepted at that time was the international classification of the VIIIth International Congress of Cancer and we have included in this program one group of cases, those which could be classified as Stage III according to this classification, which are advanced lesions.

In 1961 there was the report in this country of the American Joint Committee on Cancer Staging and End Results Reporting. We reclassified our cases to indicate for your information how they related to the criteria of this Committee. This may create some confusion, but we must adhere to our original program of including cases that can be classified Stage III according to the international classification of 1958 if our reports are to be properly analyzed and evaluated.

I indicated that there were six deaths in our series and three of these were due to local disease. In analyzing these latter cases, we were able to come to the conclusion that radiation and surgical errors may have played a part in these failures. We have corrected these errors.

As far as controls are concerned, we have had since 1930 many reports on results from x-ray therapy and from surgery. These are the controls. What can be accomplished by x-ray therapy alone and by surgery alone has been established. We have to accept these results as the survival rates (which have been poor) and we should regard combined therapy, whether it is combined radiotherapy and surgery or combined radiotherapy and chemotherapy and surgery, as an evolutionary process in the treatment of cancer of the larynx.

It is difficult to evaluate the question of complications. In our series every patient healed ultimately. We have had our share of complications. Radiotherapy does make some of the healing problems more difficult, but our objective is to improve and obtain the best survival rate. However, I wish to call to your attention that patients belonging to Stage III and Stage IV in the past have developed complications even without radiotherapy.

It seems possible to improve the survival rate of these patients from 20 to 25 per cent to over 60 per cent; an increase in complications should not be a deterring factor.

In closing, may I repeat that this program to be significant has to be rigid and for this reason we follow an uncompromising plan. I am grateful to Dr. Daly for including in a panel discussion on this subject at last year's meeting in New York a mystery guest who turned out to be a statistician. At the end of the discussion, he stated that our statistics were valid.

DR. SKOLNIK (closing): I would like to thank Dr. Sisson. He did an admirable job of evaluating these two papers and presenting other studies of a similar category.

I congratulate Dr. Goldman for his persistent attitude in this type of program. Although this has already been alluded to as an "old type" of program, I think only in the last eight or nine years has there been an attempt to create and bring forth a very systematized type of program such as Dr. Goldman has presented.

As far as the pitfalls of percentages, I agree that this must be carefully evaluated. Dr. Sisson mentioned statistics. When one talks about percentages, they become meaningful only when there are sufficient numbers of cases in similar categories.

Our statistical department suggests very definite trends and that we must pursue this course of randomization.

Of particular emphasis, as I mentioned earlier, is that we were not attempting to convert an unresectable lesion into a resectable state. One should be very cautious of this and, as Dr. Goldman mentioned, one cannot deviate from the original definition of the program and must carry out the definitive surgery as planned prior to radiation.

Regarding the complications, many of the patients that we operated had extensive disease involving the pharynx. When the pyriform sinus is involved and there is extensive involvement of the base of the tongue, it was not uncommon to have complication, even though they have not had radiation. However, complications were more numerous when radiation was employed. Furthermore, it must be recognized that we are not trying to bring out the radiation failures.

I encourage the use of the program of combined therapy and in 3 to 5 years, the final results will be significant, and will decide the merits, if any.

METASTATIC CARCINOMA TO THE ESOPHAGUS

ENDOSCOPIC CONSIDERATIONS WITH SPECIAL REFERENCE TO CARCINOMA OF THE BREAST

JOSEPH P. ATKINS, M.D.

PHILADELPHIA, PA.

The purpose of this paper is to point out certain differences in the behavior of the esophagus which we have encountered in metastatic carcinoma arising in a distant organ and to call attention to the differences which the endoscopic picture presents. In particular, we would like to call attention to certain hazards which have not heretofore been appreciated.

Metastatic cancer of the esophagus is unusual. It has been reported in a study by Fischer¹ who found 55 cases of metastatic carcinoma of the esophagus in a collected group of 10,044 autopsies performed on patients with carcinoma. Toreson² discovered 19 in 599 autopsies on carcinoma patients, an incidence of 3.2%. Gross and Freedman³ in 1942 reported a patient presenting symptoms of esophageal obstruction produced by a carcinoma of the prostate which metastasized to the esophagus and felt that it was a very rare example of a metastatic tumor to the esophagus. The patients reported by Toreson consisted of the 19 cases mentioned above, plus 7 other cases which he found in his autopsy records, making a total of 26 cases. Of these 26, twelve presented the symptom of esophageal obstruction. In nine of these patients the tumors were primary in adjacent organs so that the involvement of the esophagus was by simple extension of the tumor into a contiguous organ. Of the 26 cases which he reported only three presented with dysphagia produced by metastases from a distant primary. Two of these were patients with carcinoma of the breast and a third with a carcinoma of the testis. Carcinoma has been reported in the esophagus arising from the following organs:

From the Broncho-esophagologic Clinics of the University of Pennsylvania.

stomach, breast, larynx, hypopharynx, pancreas, testis, eye, tongue, bronchus, mediastinal lymph nodes, prostate, tibia, and undetermined sites.

INVOLVEMENT OF THE ESOPHAGUS BY TUMORS ARISING IN CONTIGUOUS ORGANS

It is common for carcinoma of the cardiac end of the stomach to manifest itself initially by esophageal symptoms. Most commonly this is a direct extension of the tumor into the esophagus producing dysphagia and presenting no particular problem to the endoscopist because the fungating tumor in the lumen of the esophagus makes diagnosis easy. Occasionally these carcinomas will extend into the esophagus submucosally producing a stenosis of the esophagus without ulcerating into the lumen. This increases the diagnostic problem because of the difficulty of obtaining a biopsy. I am aware of only one instance of invasion of the esophagus from a carcinoma at the pyloric end of the stomach and this is reported in the series of Toreson. Carcinomas arising in the trachea and larger bronchi frequently extend into the esophagus. At times it is difficult to be certain which side of the party wall was the primary site. The symptoms may be related to the respiratory tract or esophagus. Llambes and Moreno⁴ reported three patients whose bronchogenic carcinomas first manifested themselves by the development of esophageal stenosis.

Tumors of the larynx, trachea, bronchi, stomach, hypopharynx and perhaps the thyroid are in reality only extensions of the primary tumor. They constitute only a variation in the behavior of the primary tumor. The diagnostic problem here is essentially the diagnosis of the primary lesion which includes an estimate of its extent in order to evaluate properly its therapeutic possibilities. It is to be noted that mediastinal lymph nodes involved with carcinoma rarely extend into the esophagus.

INVOLVEMENT OF THE ESOPHAGUS BY METASTASIS FROM DISTANT TUMORS

It is sometimes difficult to determine just what constitutes primary and what constitutes secondary carcinoma of the esophagus. In 1961, we saw a 55-year-old man (Case 1) with well-differentiated carcinoma involving the right cord and the subglottic larynx (Fig. 1) immediately beneath it. It appeared to be completely removed by total laryngectomy. There was no evidence of blood vessel invasion

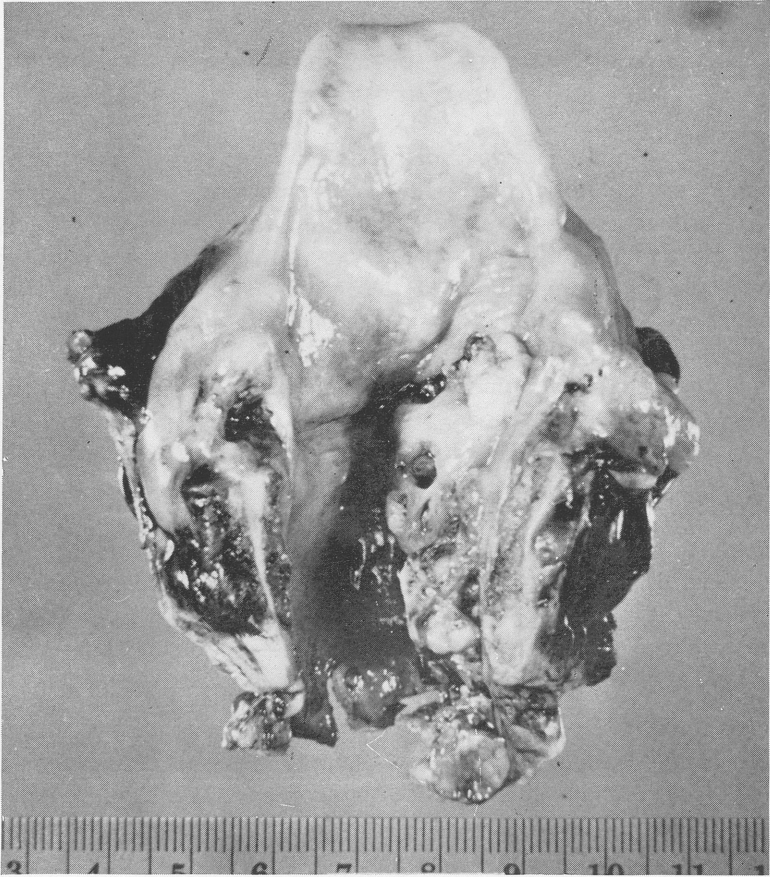


Fig. 1.—Larynx removed in Case 1 five years before onset of esophageal symptoms.

and the lines of resection were free of tumor. On March 10, 1964, a slight prominence was noted in the right superior mediastinum which was thought to be vascular. When he returned for follow-up in February, 1966, he complained of abdominal discomfort, diarrhea, and weight loss and was admitted to the hospital for evaluation. X-ray examination (Fig. 2) at this time showed a very typical carcinoma in the midesophageal area which, on esophagoscopy examination, had the characteristic appearance of a primary esophageal carcinoma. Biopsy of the esophagus and the bifurcation of the

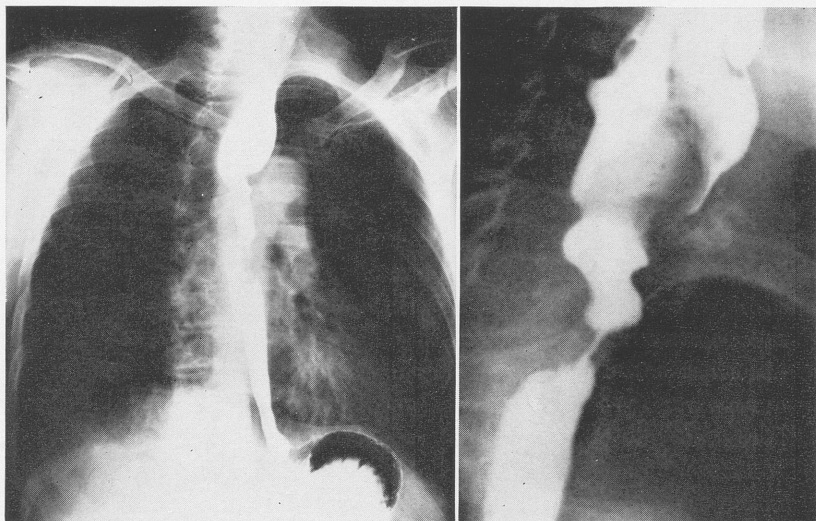


Fig. 2.—Roentgenogram showing esophageal deformity in Case 1 after onset of esophageal symptoms. Previous radiologic study of the esophagus was negative.

Fig. 3.—High esophageal constriction from carcinoma of pharyngeal origin (Case 2) six years after original diagnosis of cancer. Note smoothness of mucosal outline.

trachea both demonstrated a squamous cell carcinoma which had the identical cellular appearance as the tumor that had been removed from the larynx. There was no sign of recurrence in the tissues of the neck or trachea and it was our feeling that this was probably a new tumor of the esophagus which had extended into the carina. To relieve his dysphagia a plastic prosthesis was introduced and he was given 3000 rads of supervoltage x-ray therapy. This caused his tumor to melt so much that the prosthesis was dislodged from the esophagus and, unfortunately, he developed a tracheo-esophageal fistula. While we cannot prove that this is not a metastatic carcinoma of the esophagus, we feel that it probably is a second primary.

In contrast to this patient we saw a 69-year-old Negro male (Case 2) in October of 1965 complaining of sore throat and increasing dysphagia of 2 to 3 months' duration. He gave a history of having had a carcinoma removed from his uvula in 1960 and at the time of admission a tiny lesion was removed from the left tonsillar pillar. This proved to be carcinoma. Esophagoscopy was attempted

but could not be accomplished because of the narrowness of the lumen at the level of the cricopharyngeus. X-ray examination (Fig. 3) demonstrated a marked constriction at the level of the upper esophagus and a small amount of x-ray therapy was given to the area of esophageal constriction. We were then asked to see the patient and on September 7, 1965, a small esophagoscope was introduced through this area of narrowing. We found the wall to be firmly constricted, but passed a 5 mm esophagoscope through the area of narrowing into an apparently normal esophagus below. At no point was there any break in the mucous membrane of the esophagus and the appearance was that of a cicatricial contraction of the esophageal lumen. Because of continued difficulty in swallowing and because of the lack of a tissue diagnosis, Dr. Kjell Christiansen explored the neck and found the esophagus to be surrounded by a poorly differentiated carcinoma. He was given further x-ray therapy and at the present time is swallowing satisfactorily with no significant difficulties; however, he continues to show narrowing in the cervical esophagus. This is probably an example of a true metastatic carcinoma arising in the pharynx and involving the esophagus circumferentially. This lesion differs from the other metastatic lesions of the esophagus that we have encountered in that it tolerated rather vigorous bougienage which was carried out while we were under the impression that this was a cicatricial stenosis before a tissue diagnosis had been established.

The principal concern of this paper is with the five cases of carcinoma of the breast which involved the esophagus and which presented findings which are all strikingly similar.

The first patient (Case 3) was a woman in late middle age who was seen many years ago and whose records have since been destroyed. She had a history of having had a radical mastectomy a number of years before, but after getting along satisfactorily for several years, began to have symptoms of chest involvement including pleural effusion. She was chiefly troubled by difficulty in swallowing due to a smooth constriction in the midesophagus which was demonstrated by x-ray examination. In order to relieve her symptoms of inanition, esophagoscopy was performed and the stricture encountered. It appeared to be a smooth, cicatricial stricture and when an effort was made to dilate this stricture, it opened up with the greatest of ease very much like one encounters when dilating web-like strictures of the esophagus. We were quite concerned when she then developed

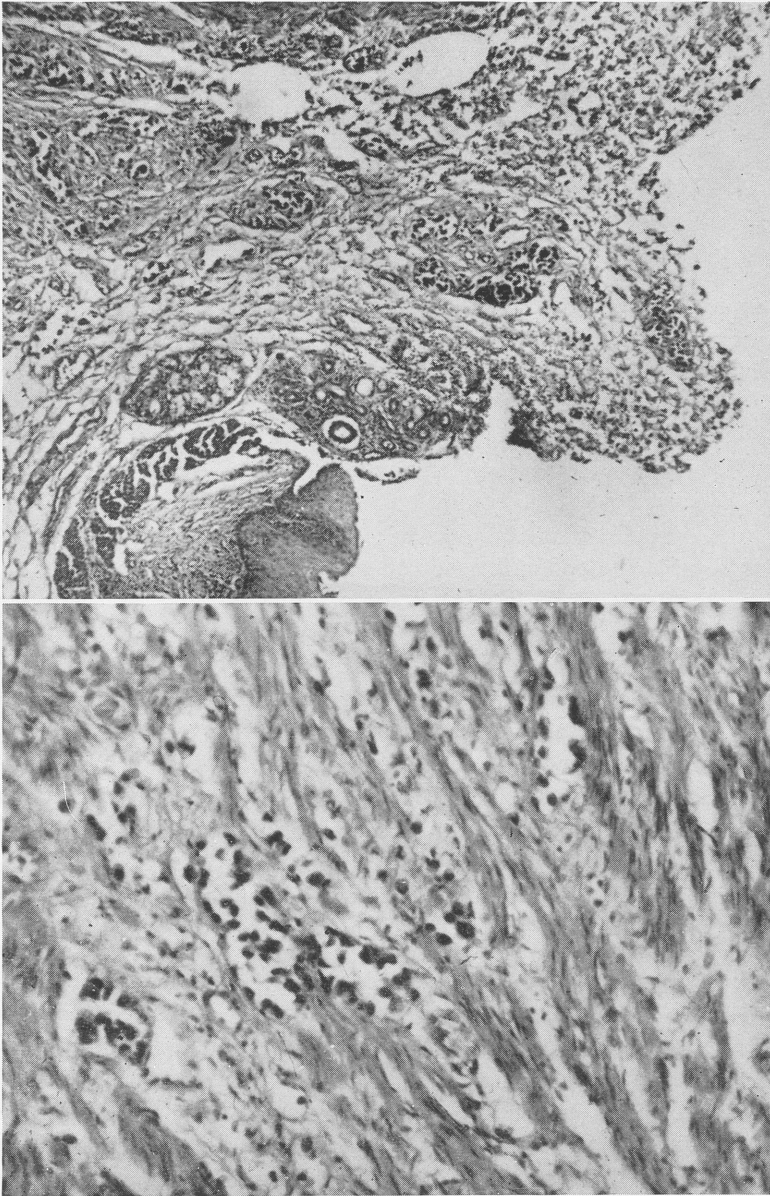


Fig. 4.—Photomicrograph of esophagus showing A) the wall infiltrated by tumor cells believed to be of mammary origin; B) high power view of same area showing detail of invasive cells. These tumors tend to remain within the wall of the esophagus and often are not grossly evident on the outside of the esophagus. The mucosa in the lumen is usually intact. Impaired nutrition with interference with the vasculature of the esophagus probably accounts for friability of the wall which may occur.

symptoms of esophageal perforation. Because of the evidence of tumor in her chest it was felt that she was not a proper subject for radical surgical intervention and was treated conservatively. She did not survive this accident and was found at post-mortem to have a carcinoma involving the wall of the esophagus. We did not realize at this point that esophageal friability is characteristic of these lesions.

The second patient (Case 4) was a 69-year-old woman who had a radical mastectomy eleven years prior to admission. She had progressive dysphagia for six months and x-ray evidence of scattered densities in both lungs with a smooth stricture in the midesophageal region. Esophagoscopy was carried out and again a smooth constriction suggestive of a cicatricial stricture was encountered. It dilated with the greatest of ease and this was immediately followed by symptoms of esophageal perforation. She developed a right-sided empyema and diffuse mediastinitis and died in ten days despite treatment. The rupture of the esophagus occurred opposite to a site of adherence to the right stem bronchus at a point of thickening in the esophageal wall. Histologic examination of the esophagus (Fig. 4) revealed an undifferentiated carcinoma infiltrating the wall of the esophagus. At this point and on the basis of these two cases, we began to realize that this kind of carcinoma of the esophagus is very different from the primary carcinoma of the esophagus which will tolerate a rather remarkable amount of manipulation and which is easy to recognize because it ulcerates into the lumen of the organ. It seems that the weakness of the wall may be due to the impaired nutrition caused by interference with blood flow in the area of invasion.

When our third patient (Case 5) was seen in 1961, we were thoroughly appreciative of the friability of the esophagus whose walls have been invaded by carcinoma of the breast. This 77-year-old patient had developed her carcinoma seven years prior to her first visit and had been having dysphagia for about two years as well as local recurrences in the wound site. She had had numerous local excisions of tumor as well as x-ray therapy to the esophagus and axilla. X-ray examination (Fig. 5) disclosed narrowing in the mid-esophagus. Esophagoscopy confirmed the roentgen diagnosis of a constriction in the midesophagus where there was moderate narrowing of the lumen with no ulceration of the mucous membrane. Biopsy of the mucosa failed to reveal evidence of malignancy. We attempted to treat her by bougienage and very cautiously and gently carried out this procedure with Maloney bougies which gave her moderate

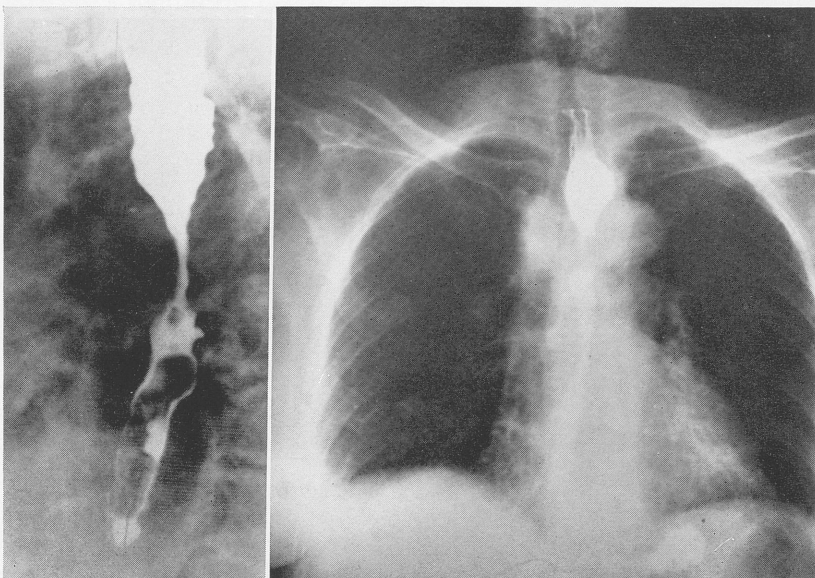


Fig. 5.—Midesophageal stricture of breast tumor (Case 5) metastatic to esophagus. Attempted very cautious bougienage of this lesion was partially successful but there was probably a perforation of this esophagus produced by bougienage although this could not be proven by clinical study.

Fig. 6.—Esophageal constriction at junction of upper and middle third of esophagus by metastatic carcinoma from breast. This case is notable in that esophagoscopy biopsy through the intact mucosa revealed tumor cells thought to be of mammary origin in tissue spaces of muscularis and sub-mucosa.

relief of her symptoms. Two months later she was re-admitted for esophagoscopy and bronchoscopy. The esophageal picture was essentially the same, but a biopsy of the bronchus revealed a poorly differentiated carcinoma which did not appear to arise from the respiratory epithelium. She was then treated with Testosterone® and Estrogen® with some temporary improvement. By October of 1962, she was entirely unable to eat. Esophagoscopy was again attempted and we found an extremely tight stricture. We made rather tentative efforts to dilate this, but because of the resistance encountered did not pursue it. Following this procedure she had symptoms suggestive of an esophageal perforation, but we could never demonstrate that a perforation existed and her symptoms subsided spontaneously. A gastrostomy was done and she was discharged. It was planned that she

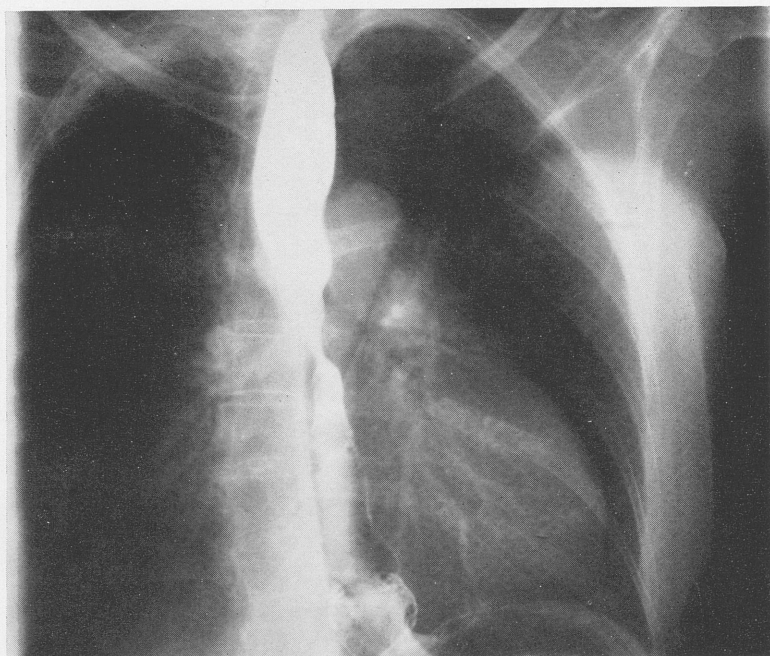


Fig. 7.—(Case 7). Esophageal stricture due to metastatic tumor three years after right radical mastectomy with axillary metastases. This lesion responded well to supervoltage roentgen therapy.

should continue on gastrostomy feedings and symptomatic treatment thereafter.

The next patient (Case 6) was seen in August of 1965 with a history of a previous mastectomy followed by sudden development of inability to swallow food. X-ray examination (Fig. 6) revealed a constriction of the junction of the upper and middle thirds of the esophagus. This was examined esophagoscopically and found to be smooth and rather unyielding. A biopsy was done and one section revealed nests of malignant cells some of which form irregular acini. They are seen in the tissue spaces and lymphatics of the muscularis and submucosa. It was diagnosed as a poorly differentiated adenocarcinoma of the esophagus following adenocarcinoma of a site unknown. Careful bougienage of this patient did not give her any significant relief. She was given irradiation, receiving 3500 rads in

eighteen elapsed days with a 6 million volt linear accelerator which gave her a significant degree of palliation. I last saw her in December at which time she was having no pain, but was losing weight and had a moderate amount of dysphagia. In March of this year I received a note from her daughter that because of weakness she is unable to travel five months after the completion of her palliative x-ray therapy. She will probably need gastrostomy.

Our last patient (Case 7), a 64-year-old woman, had a right radical mastectomy in April of 1962 with five of nine nodes in her axilla involved. Following this she was given x-ray therapy and in December of 1964 developed a small amount of right pleural effusion. In August of 1965 in addition to the pleural effusion she showed evidence of a midesophageal stricture (Fig. 7) and was admitted to the hospital because of her progressive dysphagia. By thoracentesis, 400 cc of straw-colored fluid was removed from her right chest. It contained definitely malignant cells. Esophagoscopy revealed a non-ulcerated, concentric constriction. Two biopsies of this constriction failed to give any evidence of neoplasm. Very careful bougienage permitted the passage of #24 and #28 Maloney bougies, but did not relieve her dysphagia. Between September 8 and September 29, she received 3500 rads to the esophageal lesion and required nasogastric tube feeding from September 29 to October 29. By November 24, she was swallowing very satisfactorily and in March of this year she is having no symptoms of dysphagia. There is minor residual narrowing of the mid-thoracic esophagus noted by cinefluorography and it is our intention that if further dysphagia develops consideration should be given to the use of more x-ray therapy.

COMMENT

Except for the patient with carcinoma of the larynx and subsequent esophageal manifestations, we believe that these cases are true instances of metastatic involvement of the esophagus from a distant primary. None showed intraluminal fungations. Positive endoscopic biopsies are difficult to obtain. The endoscopic appearance suggests cicatricial stricture rather than the ulceration and fungation the endoscopist ordinarily associates with esophageal malignancy.

Caution is demanded in endo-esophageal manipulation of these patients because of the friability which these tissues may exhibit.

SUMMARY AND CONCLUSIONS

Metastatic cancer to the esophagus is not common. It may be involved by extension of a primary tumor from a contiguous organ such as the larynx, trachea, bronchi, stomach, thyroid, or hypopharynx. These tumors may produce esophageal symptoms, notably dysphagia, but the diagnosis and management of these lesions is essentially that of the primary tumor. True metastasis from distant primaries has been recorded in tumors which arose in the breast, pharynx, pancreas, testis, eye, tongue, prostate, and tibia, with one case reported arising from an undiscovered primary.

In this paper seven cases are presented. One is probably an example of a second primary arising in the esophagus following cancer of the larynx. The possibility of this being a metastatic tumor cannot be excluded. A second case is a primary tumor of the pharynx with metastasis to the cervical esophagus. Five cases of carcinoma of the breast with metastatic involvement of the esophagus are presented.

Asymptomatic metastatic carcinoma to the esophagus has been reported in slightly more than half of a series of autopsy cases. All of the cases here presented had symptoms of esophageal disease. Of the six cases believed to be examples of true metastatic tumor none showed intraluminal fungations. The esophagosopic appearance is strongly suggestive of cicatricial stricture rather than neoplasm. Positive endoscopic biopsies are difficult to obtain. It would appear that in tumors of the breast metastasizing to the esophagus, tumor invasion or interference with the nutrition of the esophageal wall creates an unusually friable esophagus which is much less tolerant of manipulation, particularly dilatation, than primary carcinomas of the esophagus exhibit.

3400 SPRUCE STREET

Appreciation is expressed to Drs. R. Chamberlin, R. Harvey, M. Strumia for the courtesy of x-ray films and photomicrographs.

REFERENCES

1. Fischer, W.: Speiserohre in F. Hencke and O. Lubarsch Handbuch der Speziellen Pathologischen Anatomie und Histologie. Verdauungsschlauch, Erster Teil, Berlin, Springer, pp. 75-165, 1926.
2. Toreson, W. E.: Secondary Carcinoma of Esophagus as a Cause of Dysphagia. Arch. Path. 38:82-84, 1944.
3. Gross, P., and Freedman, L. J.: Obstructing Secondary Carcinoma of the Esophagus. Arch. Path. 33:361-364, 1942.
4. Llambes, J., and Moreno, R.: La Forma Esophagica del Cancer Broncopulmonar. Prensa Med. Argent. 35:130, 1948.

DISCUSSION

DR. J. ALLAN FIELDS: I had such a problem approximately two months ago, except that mine was from a lower bronchial lesion. It migrated up through the mediastinal lymph nodes. After two esophagoscopies and many x-ray studies, we finally decided to open up the chest in order to nail down the diagnosis. His only complaint was a very slight nebulous sensation that his swallowing was not entirely automatic.

DR. ATKINS (closing): I would like to thank Dr. Fields for his addition of another case to this group.

I think perhaps carcinoma metastases to the esophagus might come from a great many sources, but it is particularly in the group of breast tumors that I think we may have to show our greatest caution with the endoscopic manipulation.

UNDER LOCAL ANESTHESIA

PAUL H. WARD, M.D.

(by invitation)

SAM E. STEPHENSON, JR., M.D. PERRY F. HARRIS, M.D.

(by invitation)

(by invitation)

NASHVILLE, TENN.

Mediastinoscopy as a diagnostic endoscopic procedure for the exploration and biopsy of lesions of the superior mediastinum has achieved rapid acceptance throughout Europe since its introduction by Carlens in 1959.³ The slow acceptance of the procedure in this country may be due in part to the name "mediastinoscopy" which according to Pearson¹⁶ suggests to some surgeons, "rather formidable and frightening possibilities and may conjure up visions of blind instrumental probing in among the great vessels and vital structures of the mediastinum." An even more important detracting factor has been the belief that a general anesthetic was necessary.^{3,13} In his recently published monograph, Palva¹³ stated, "The operation is always made in general anesthesia; local anesthesia would not be feasible when working as low down as at the bifurcation and main bronchi." Our recent experiences have demonstrated this latter statement to be incorrect. Having on several occasions withheld mediastinoscopy from moribund patients because of the hazards of general anesthesia, we decided to attempt to perform the procedure under local anesthesia. So superior were the results of performing mediastinoscopy under local anesthesia that we have used general anesthesia in only five of the last 30 cases.

Mediastinoscopy has proven to be a valuable method of exploration and biopsy of lesions of the superior mediastinum. Originally

From the Division of Otolaryngology and Department of Surgery, Vanderbilt University School of Medicine.

This work was supported in part by U. S. Public Health Service Training Grant 1 T8 NB 10,030-02.

it was used to determine the operability of bronchogenic carcinoma without resort to thoracotomy. Subsequent reports from several European centers have confirmed the usefulness of mediastinoscopy in the diagnosis of other systemic and thoracic diseases that involve the mediastinum.^{1,4,11,12,14,15}

Earlier efforts to acquire histopathological proof of the metastasis of lung tumors to lymph nodes were made by Daniels⁸ in 1949. He described the technique of removing the scalene fat pad and its contained lymph nodes which in advanced cases sometimes contained metastatic tumor. Harken and co-workers⁹ in an effort to acquire nodes in the primary drainage area elaborated on the scalene node technique and approached the superior mediastinum by blunt dissection through the cervical fascia, passing either anterior or posterior to the subclavian vein. A laryngoscope was inserted and biopsy of the homolateral paratracheal nodes was obtained with a laryngeal forceps. Radner¹⁷ in 1955 pointed out the unnecessary hazards of the lateral approach and described five cases of paratracheal lymph node biopsy carried out by a midline approach through a suprasternal incision. In 1959 Carlens³ introduced the technique of endoscopic midline approach to the mediastinum. He presented 100 cases of mediastinoscopy performed without complication. The midline approach under direct vision decreased the hazards of damage to the major vessels and pleura and, in addition, allowed bilateral exploration, palpation, visualization and biopsy of the paratracheal nodes. This approach also facilitated exploration of the region of the carina with biopsy of any nodes or other mediastinal masses encountered. A distinct advantage of this latter procedure is the increased probability of finding metastasis in the primary drainage nodes rather than in the more distant secondary nodes of the scalene fat pad.

The degree of mediastinal involvement in cases with bronchogenic carcinoma has always been difficult to evaluate. Laminography, esophagography, tracheobronchography, angiography, phlebography, lymphadenography and gas mediastinography have proven helpful in attempts to assess this area. Often, however, additional information would have been beneficial.

A review of the recent literature on the surgical results in bronchogenic carcinoma leaves no doubt of the need for additional preoperative information concerning the extent of spread of the tumor. Harken and his co-workers⁹ expressed the opinion that "a technique that spares needless suffering for the hopelessly involved patient is

as important as the extension of excisional therapy in an attempt to cure more people." We have entered an era of almost unlimited technical ability and are able to perform extensive lung and mediastinal resections. A number of thoracic surgeons can cite an example of an occasional survivor who has undergone pneumonectomy with mediastinal dissection for bronchogenic carcinoma. These same surgeons usually fail, however, to recall the high mortality and morbidity that accompanied the extended resections. Even with the advances in surgical technique, the five year survival rate of all patients with bronchogenic carcinoma remains at 9 to 10 per cent.² About half of these cases were non-resectable when they first consulted the surgeon. Among the resected cases, the five year survival rate has been reported to be from 19 to 28 per cent.^{5-7,10,19} Of the cases explored, an average of about 40 per cent were found to be non-resectable and the exploration provided no more than a tissue diagnosis. If the diagnosis and non-resectability could have been determined by other means, these unfortunate victims could have been spared unnecessary thoracotomy with its accompanying morbidity and mortality. For this large group of patients with such limited life expectancy, the mortality, which averages 10 per cent or higher for thoracotomy and resection and 3.5 to 9 per cent for simple exploration and biopsy, could have been avoided.^{2,5}

Mediastinoscopy offers promise as a method of determining the operability of patients with lung cancer. Reynder¹⁸ initiated the use of mediastinoscopy in all patients with suspected bronchogenic carcinoma seen in their clinic. He found that the use of the information obtained from mediastinoscopy resulted in a drop in the incidence of unnecessary exploratory thoracotomies from 40 per cent to less than 10 per cent, decreased the number of surgical complications and deaths and decreased the number of curative pneumonectomies, while increasing the number of curative lobectomies.

Not to be neglected in discussing the merits of mediastinoscopy is its value in the diagnosis of other diseases of the mediastinum. Diseases diagnosed in this manner have included sarcoidosis, tuberculosis, thymoma, liposarcoma, mediastinal cyst, Hodgkin's disease and other lymphomata, silicosis, vascular anomalies and metastatic tumor from other areas of the body than the lung.^{1,4,11-13} Mediastinoscopy appears to be particularly effective in obtaining a histological diagnosis of sarcoid. Bergh and his colleagues¹ utilized mediastinoscopy to establish the diagnosis of sarcoid in 87 per cent of suspected cases.

Because of the numerous advantages of local anesthesia as compared to general anesthesia, we now reserve the latter for those patients who refuse local anesthesia, extremely nervous patients and children. In addition to the elimination of the hazards of a general anesthesia, we have found many other advantages to the performance of mediastinoscopy under local anesthesia. The almost bloodless field allows better visualization and definition of the mediastinal structures with resulting increased safety. The operating room time is shortened. The discomfort to the patient during and after the procedure is minimal. Throughout the procedure the patient can describe any discomfort or shortness of breath. This assists in the early detection and correction of pneumothorax, bilateral recurrent nerve paralysis and other complications.

The morbidity and serious complications reported to date are no greater than for scalene node biopsy. Among the hundreds of cases performed in Europe, Palva¹³ was able to find only two reported deaths up to 1964. One was a 67 year old man in severe respiratory distress with extensive mediastinal metastasis who never awakened from the anesthesia and died one hour after the procedure. The other was a 40 year old woman with lymphosarcoma who died of cardiac arrest immediately postoperatively. Bergh and his colleagues subsequently reported two deaths in their series of 300 mediastinoscopies. One patient was a 67 year old man with advanced carcinoma metastatic to the mediastinum who progressively deteriorated and died on the sixth day following mediastinoscopy. The other was a 75 year old male who had oat cell carcinoma and did well until the tenth day when he developed a pneumothorax. In spite of correction of this problem he continued to deteriorate mentally and physically and died on the thirteenth day following the mediastinoscopy. The authors felt it improbable that mediastinoscopy was directly responsible for either death.

Among the non-fatal complications reported were pneumothorax, recurrent nerve paralysis and bleeding from the superior vena cava, azygos vein and brachial artery. In cases where there was excessive bleeding, it was easily controlled by temporary tamponade except one case in which perforation of the ascending aorta necessitated a sternal splitting mediastinotomy. The laceration was repaired and recovery was uneventful. There were no reported cases of mediastinitis.

Mediastinoscopy is a safe and relatively easy procedure to perform, which can yield valuable information about the diseases of the chest and mediastinum. Because of the increased safety that accompanies the use of local anesthetic, we are presenting this technique and our experiences in 25 cases performed in this manner, in the hope that others will develop an interest in the use of this procedure.

METHOD

It is essential that mediastinoscopy be performed in a general operating room with meticulous sterile technique. Mediastinoscopy is a sterile procedure and should not be considered comparable to other endoscopic procedures which are not sterile, but rather surgically clean procedures. While complications in the hands of the careful operator are rare, the possibilities of damage to the great vessels and pneumothorax do exist and are much better managed in the general operating room.

The patient is placed supine on the operating table with the shoulders elevated by a shoulder roll or sand bag. This extends the neck while leaving the head in the midline free to be turned to either the right or left. The neck, chin and upper thorax are prepared and draped in the fashion similar to the required for a tracheotomy or thyroidectomy. When the procedure is performed under local anesthesia, the skin and suprasternal notch area are infiltrated with 1% xylocaine with adrenalin. In patients with hypertension or heart disease, the sympathomimetic drug is omitted. A transverse 3-4 cm skin crease incision is made about 2 cm above the manubrium (Fig. 1). Midline dissection is carried down to the ventral surface of the trachea. Particularly important is the division of the pretracheal fascia since the plane of dissection is against the trachea posterior to this fascia. If this is not done the dissection may be in an improper plane with the possibility of damage to the great vessels.

About 2 cc of 1% xylocaine is then injected into the lumen of the trachea to diminish the cough reflex. The index finger is then used to perform a major portion of the dissection. The finger gently dissects down the anterior surface of the trachea. It is usually possible to palpate the tracheobronchial angles and carina. Should the patient experience discomfort, several cubic centimeters of 1% xylocaine are placed in the wound and massaged into the mediastinal tissues. A remarkable evaluation of the upper mediastinum can be performed

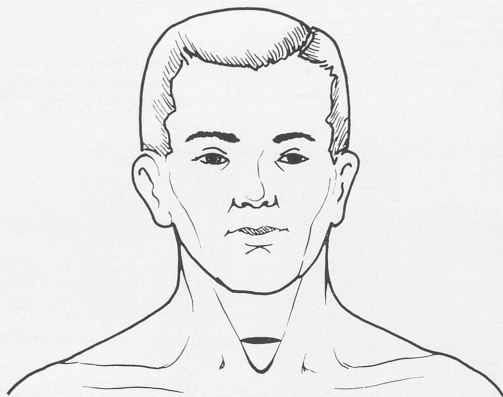


Fig. 1.—Diagram of small suprasternal incision area used to approach the trachea and through which the mediastinoscope is introduced.

with the palpating finger. The aortic arch, innominate artery and left common carotid artery are easily identified. Any enlarged paratracheal lymph nodes or tumor infiltrates in the mediastinum or against the mediastinal pleural walls can be felt and their adherence and mobility ascertained. Bleeding, particularly when the procedure is performed under local anesthetic, is negligible up to this point.

The mediastinoscope (which is like a modified child's esophagoscope) is introduced into the pretracheal space that has been prepared by finger dissection (Fig. 2). As it is passed down the tract, care is taken to always keep the anterior tracheal wall in the field of vision. Further paratracheal and carinal dissection can be performed using a specially designed spreader or by a forceps modified to hold a small dissecting sponge. Delicate, blunt tipped laryngeal scissors are used to divide small fibrous bands. Prior to dissection or division, possible blood-filled structures can be identified by means of a long hypodermic needle and aspiration. Sometimes exposed and to be protected are the superior vena cava and azygos veins on the right and on the left the pulmonary artery as it crosses the left main bronchus anteriorly and the descending aorta as it passes behind the left main bronchus and to the left of the esophagus. Care must also be taken not to injure the left recurrent nerve which is much more ventrally located in the lower tracheal area near the bifurcation. Large pigment (carbon particles) containing lymph nodes literally bulge before

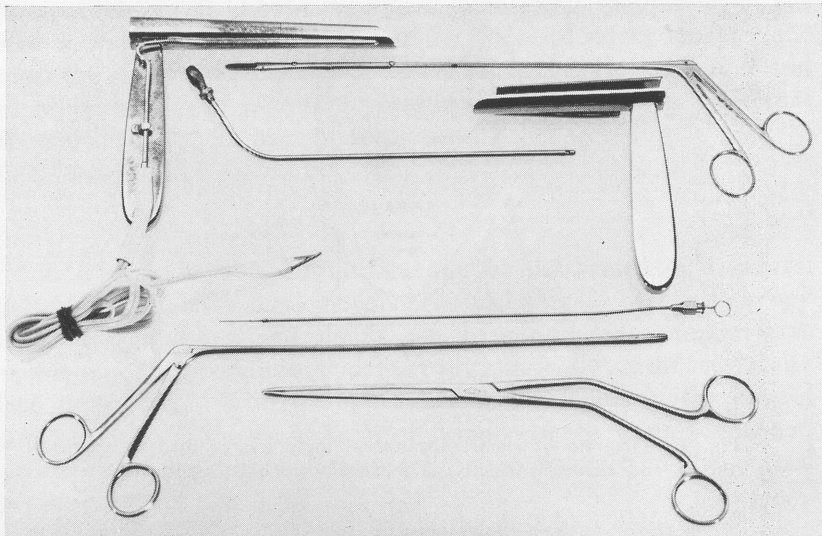


Fig. 2.—Photograph of the special instruments used in the performance of mediastinoscopy. These include: mediastinoscopes, light carriers, suction tubes, long aspirating needle, cup biopsy forceps, laryngeal scissors and dissecting instrument (spreader).

the orifice of the mediastinoscope as the dissection progresses. Often masses of matted nodes can be freed and removed in toto. The anterior, superior and inferior surfaces of the bronchial walls can be explored out to the pleural reflections. Biopsies are routinely taken of any tumor masses, the paratracheal hilar nodes on both sides and the subcarinal nodes (Fig. 3). Cup or basket-type laryngeal forceps are used to obtain these biopsies. In the event of more profuse bleeding, gelfoam and packing may be used. The packing can be removed and the gelfoam left in place upon closing. Upon completion of the exploration, the mediastinoscope is removed allowing the mediastinal tissues to fall back against the trachea providing additional hemostasis. The wound is then closed in layers without drainage and a gentle pressure dressing is applied over the neck incision. The operating time required for performance of mediastinoscopy under local anesthesia is usually around 30 to 45 minutes.

Postoperatively discomfort is minimal and is far less than that encountered after tracheostomy. The patients are ambulated the same day and may go home one or two days after mediastinoscopy.

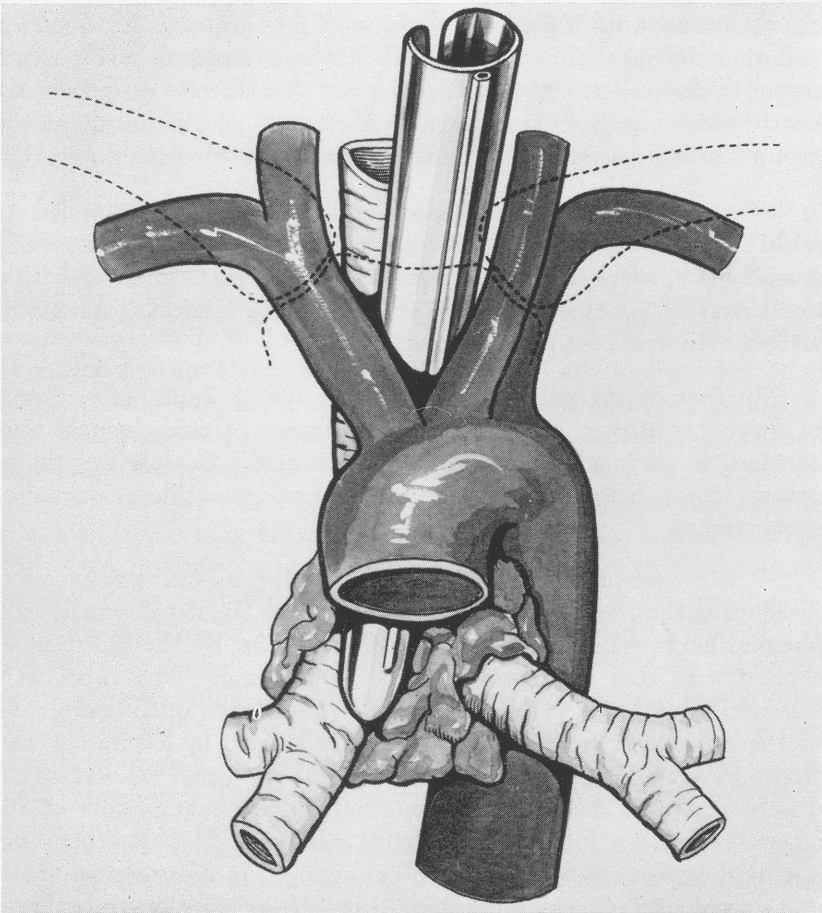


Fig. 3.—Diagram showing mediastinoscope in position to explore and obtain biopsies of paratracheal and carinal lymph nodes.

RESULTS

During the past 14 months, we have performed mediastinoscopy using local anesthesia in 25 patients.

In 22 of the cases the procedure was performed in an effort to obtain a primary diagnosis, other conventional examinations such as bronchoscopy and cytology having been negative. In three cases

a tissue diagnosis was available prior to mediastinoscopy and the objective was to determine the degree of mediastinal involvement. Two of the three cases with a previously positive tissue diagnosis had received radiation therapy. One of these patients was found to have residual tumor in the mediastinal lymph nodes and was thereby spared unnecessary thoracotomy. The other two cases of the tissue diagnosed group had a negative mediastinoscopy and were considered operable.

The mediastinal lymph node biopsies in this series revealed 11 with hyperplastic anthracotic lymph nodes, three with non-specific granulomata, seven with squamous cell carcinoma and three with a non-caseating granuloma which confirmed the clinical diagnosis of sarcoid. In one case no biopsy was taken.

In four of the patients in whom the lymph node biopsies were negative for tumor, large fixed masses were palpable which were adherent to the mediastinal pleura and rib cage. Exploratory thoracotomy confirmed the impression of the non-resectable character of these tumors.

There were no serious complications and in no case was excessive bleeding encountered. In two cases there was the development of a pneumothorax which was corrected in each case by the insertion of a chest tube that was connected to a water seal. The tubes were removed in 48 hours without sequelae. In one case, upon completion of the procedure, the patient was observed to be in respiratory distress. He stated in a hoarse voice that he had no pain. He was immediately placed in the sitting position and mirror examination of the larynx revealed a bilateral vocal cord paralysis. Because there was potential easy access to the trachea through the mediastinoscopy incision, it was elected to maintain him in the sitting position and observe his course. Within one and a half hours, the effects of the local anesthetic had passed and both vocal cords had regained their normal movements.

In another case, attempts to dissect with the spreading forceps in a plane at right angles to the slit in the mediastinoscope broke the light bulb from its carrier. Fortunately the intact bulb stuck in the mediastinoscope and was discovered while preparations were being made for irrigation of the mediastinum. Accidents similar to this can be avoided by always dissecting the spreading forceps in the same plane as the mediastinoscope slit. If another plane of dissection is required, the mediastinoscope is rotated.

COMMENT

Our experience and those reported by others substantiate the value of mediastinoscopy in the diagnosis of diseases of the mediastinum. The success and increased safety that we have experienced through performing mediastinoscopy under local anesthesia should contribute to its acceptance as a standard diagnostic procedure.

The exact place mediastinoscopy will achieve as a means of determining the operability of lung tumors remains to be seen. Much will depend upon the attitude and philosophy of the thoracic surgeons. For those surgeons who consider extended resection to be worthwhile, mediastinoscopy may yield information on the extent of mediastinal involvement to be encountered at surgery. For other surgeons who consider unilateral, contralateral, bilateral, carinal or any combination of positive mediastinal lymph node biopsies as indications of nonresectability, this procedure has much to offer in the selection of their cases. For those obviously nonresectable cases in which all efforts have failed to yield a tissue diagnosis, mediastinoscopy will often provide a tissue diagnosis without resort to thoracotomy. In two of our cases with only hilar adenopathy on x-ray, mediastinal lymph node biopsies were obtained which contained carcinoma. In one of these cases laminography of what was previously considered to be a normal lung field revealed the primary lesion. In the other case the primary still has not become manifest. Mediastinoscopy may thus help make a diagnosis in some cases before the primary is clinically apparent. The prognosis with current methods of therapy is poor in these cases.

The most valuable information to be obtained may be a negative mediastinoscopy for this means absence of metastasis in a large percentage of cases.

The simplicity of the technique, the low morbidity encountered and the valuable information obtainable suggests that mediastinoscopy may replace diagnostic thoracotomy in many instances.

SUMMARY

Mediastinoscopy as a diagnostic procedure has achieved rapid acceptance throughout Europe. It has previously been considered necessary to perform mediastinoscopy under general anesthesia. We have found this concept to be wrong.

The technique of performing mediastinoscopy under local anesthesia and our experiences in 25 cases performed in this manner are presented. Because of the valuable information obtainable with minimal accompanying morbidity, it is anticipated that mediastinoscopy will achieve wider acceptance in this country and will in many cases replace diagnostic thoracotomy.

VANDERBILT UNIVERSITY SCHOOL OF MEDICINE

REFERENCES

1. Bergh, N. P., Rydberg, B., and Scherstén, T.: Mediastinal Exploration by the Technique of Carlens. *Dis. Chest* 46:399, 1964.
2. Burford, T. H., Center, S., Ferguson, T. B., and Spjut, H. J.: Results in the Treatment of Bronchogenic Carcinoma. *J. Thorac. Surg.* 36:316, 1958.
3. Carlens, E.: Mediastinoscopy: A Method for Inspection and Tissue Biopsy in the Superior Mediastinum. *Dis. Chest* 36:343, 1959.
4. Carlens, E., and Herlitz, L.: Mediastinoscopy as an Aid in the Diagnosis of Intrathoracic Tuberculosis. *Acta Tuberc. Scand.* 35:35, 1964.
5. Chamberlain, J. M., McNeil, T. M., Parnassa, P., and Edsall, M. B.: Bronchogenic Carcinoma. An Aggressive Surgical Attitude. *J. Thorac. and Cardiovas. Surg.* 38:727, 1959.
6. Churchill, E. D., Sweet, R., Scannell, G., and Wilkins, E. W.: Further Studies in the Surgical Management of Carcinoma of the Lung. *J. Thorac. Surg.* 36:301, 1958.
7. Churchill, E. D., Sweet, R., Soutter, L., and Scannell, J. G.: Surgical Management of Carcinoma of the Lung. *J. Thorac. Surg.* 20:349, 1950.
8. Daniels, A. C.: A Method of Biopsy Useful in Diagnosing Certain Intrathoracic Diseases. *Dis. Chest* 16:360, 1949.
9. Harken, D. E., Black, H., Clauss, R., and Farrand, R. E.: A Simple Cervico-mediastinal Exploration for Tissue Diagnosis of Intrathoracic Disease. *N. Engl. J. Med.* 251:1041, 1954.
10. Johnson, J., Kirby, C. K., and Blakemore, W. S.: Should We Insist on "Radical Pneumectomy" as a Routine Procedure in the Treatment of Carcinoma of the Lung? *J. Thorac. Surg.* 36:309, 1958.
11. Palva, T.: Clinical Evaluation of Mediastinoscopy. *Arch. Otolaryng.* 77:19, 1963.
12. Palva, T.: Mediastinal Sarcoidosis. *Acta Otolaryng. Supp.* 188:258, 1964.
13. Palva, T.: Mediastinoscopy. Verlag S. Karger A. G., Basel/New York, 1964.
14. Palva, T.: Mediastinoscopy—A New Field for Bronchologist. *Acta Otolaryng.* 53:578, 1961.
15. Palva, T., and Viikari, S.: Mediastinoscopy. *J. Thorac. and Cardiovas. Surg.* 42:206, 1961.

16. Pearson, F. G.: Value of Mediastinoscopy. *Canad. J. Surg.* 6:423, 1963.
17. Radner, S.: Suprasternal Node Biopsy in Lymph Spreading Intrathoracic Disease. *Acta Med. Scand.* 152:413, 1955.
18. Reynders, H.: Mediastinoscopy in Bronchogenic Cancer. *Dis. Chest* 47:606, 1964.
19. Shimkin, M. B., Connelly, R. R., Marcus, S. C., and Cutler, S. J.: Pneumnectomy and Lobectomy in Bronchogenic Carcinoma. A Comparison of End Results of the Overholt and Ochsner Clinics. *J. Thorac. and Cardiovas. Surg.* 44:503, 1962.

DISCUSSION

DR. JOSEPH L. GOLDMAN: I would like to ask Dr. Ward a question:

Has he ever attempted to dissect out the nodes rather than take a biopsy? The procedures that I have seen done through mediastinoscopy have involved dissection and removal of lymph nodes. I wonder if he may run into complications by taking biopsies. When I saw these procedures done, much to my surprise, it seemed easy to dissect out the lymph nodes.

DR. JOSEPH P. ATKINS: We have been interested in mediastinoscopy and Dr. John Tucker, on our staff, has developed a new mediastinoscope which is being worked on by the Pilling Company, and which we think has some advantages over the current system.

I would like to ask Dr. Ward about the patient who may start coughing vigorously during mediastinoscopy. For that reason doing this under general anesthesia might be a safer procedure to avoid mediastinal emphysema. We have been a little concerned about that and wonder if you have had any experience with patients coughing during mediastinoscopy under local anesthesia.

Regarding the problem of bleeding, we have had very little ourselves, but we have heard that some of our general surgical friends have apparently gotten a little enthusiastic about the extent of the examination they wanted to carry out and got into difficulties which justified their fear that they might have to do a thoracotomy on the patient.

DR. JOHN E. BORDLEY: We have had a fatality at the Hopkins doing this. One of the great vessels was ruptured during the biopsy attempt. We have done a good number of these procedures without any other complication. This was done under general anesthesia.

DR. JOHN L. POOL: I am a thoracic surgeon in this group and I would like to make two comments and ask the essayist two questions.

I heard his figures from Vanderbilt on the postoperative deaths from exploratory thoracotomy and from pulmonary resection and it sounded to me as though they were a little higher than ones published from elsewhere in the country. Actually exploratory thoracotomy in many series runs about 2 per cent and postoperative deaths, that is, within thirty days, runs about 9 per cent, and in some hands less. Maybe this isn't the major point, but I hate to hear someone suggest that the frontiers of cancer resection should be pushed back, particularly in a disease where the total salvage rate is certainly less than 9 or 10 per cent at the five-year mark and where the salvage rate after resection today is about 25 per cent at five years.

We have heard some wonderful papers in the last two or three days concerning extended surgery in other areas and I think extended surgery has a place in lung

cancer. I think there are patients who have—in fact I know there are patients in whom mediastinal nodes contained metastatic cancer who have been salvaged by extended resection of the lung and mediastinal nodes.

Now, I don't say this to decry mediastinoscopy or the careful report this morning, but simply to place this fact on the record, where I think it belongs.

I think that mediastinoscopy has a real place in diagnosing such patients as the essayist presented, where there is a question of—where you have a non-resectable situation from the patient's general health or from the obvious extent of the disease, or where you have a breast cancer metastatic to the mediastinum, or lymphoma or sarcoïd, where a node is not readily available in the neck.

I would also disagree with him in his statement, however, that if you have a negative biopsy in the mediastinum it means that there is no cancer in the mediastinum.

I would like to ask two questions:

I thought those biopsies were so beautiful. How does he keep his biopsy forceps sharp enough to get such good specimens?

And the other question has to do with the patient under local anesthesia. You have that sterile drape over the patient's face. It is often my experience in neck work that the patient has trouble getting enough air. And how does he keep the patient psychologically content?

DR. WARD (closing): Dr Atkins asked the question about the resection of the lymph nodes versus biopsy. We do dissect these nodes, free them up and frequently remove them as intact nodes. Dissection is very simple and I think bleeding is less common than when one attempts to biopsy the nodes. It is very easy and frequently the index finger can do a great deal of the dissection by bluntly freeing these nodes. Then if there is fibrosis, the spreading forceps can be utilized to complete the dissection.

Certainly there is need for improvement of the instruments. We have a company interested in making some new instruments, including some new dissection forceps, a forceps similar to Carlens' spreading forceps, which will hold a peanut sponge that will assist in blunt dissection.

Bleeding is much less of a problem with local anesthesia and if one ever performs a mediastinoscopy under local anesthesia, he will rarely do one under general anesthesia again.

Coughing has been no problem for us in the twenty-five cases we have performed under local anesthesia. Perhaps injecting some anesthetic into the trachea is one of the secrets. It is amazing how little sensation there is in the mediastinum.

Dr. Pool, these figures that I gave are not Vanderbilt's or mine. They are Dr. Ochsner's and also Dr. Overholt's series and since I trust both of these men, I therefore only pass on to you their figures. I think they are honest and I don't know of many people who report dishonest figures that show the mortality to be relatively high. If these figures seem incorrect, I wish you would approach Dr. Ochsner and Dr. Overholt.

As far as the drapes are concerned, we put a Mayo stand up over the patient's head to support the drapes and if the patient seems apprehensive at all, an oxygen tube is placed beneath the drapes. We also have the nurse talk to the patient throughout the procedure. The drapes do present a problem for a patient that has some claustrophobia, since he feels fenced in, as perhaps all of us would.

SURGICAL CORRECTION OF CHOANAL ATRESIA

JERRIE CHERRY, M.D.

(by invitation)

AND

JOHN E. BORDLEY, M.D.

BALTIMORE, MD.

Congenital choanal atresia while uncommon is not rare. The interest in this problem has recently increased, and the diagnosis is being made more frequently in infancy and childhood. As a result of this increased interest, pediatric services are now including the passage of soft rubber catheters through the nares of each newborn as part of the physical examination. It is then understandable that we are confronted today with an increasing number of infants suffering from the severe effects of airway occlusion and feeding problems. Compounding this problem one sees an increase in associated anomalies. This study showed anomalies associated with choanal atresia in 50 per cent of the cases. The increased incidence of such children coming to surgery is not only the result of early and better examination, but is, to a large extent, the result of the improvement in the care of the newborn by pediatricians. Many of the children suffering multiple anomalies are surviving and grow up to adulthood to live a normal or near normal life. How are we as otolaryngologists affected by this improved survival rate? We are confronted with the task of doing surgery on many more poor risk infants. We should, therefore, design surgical procedures which can be done on small acutely ill children which will provide a permanent correction without the need for subsequent multiple procedures. Such thinking throws some doubt on the use of many of our present methods for correction of choanal atresia. Once the information has been collected and the evaluation of the infant completed, a plan of therapy can be set up and carried out. Repair of choanal atresia has to be part of that plan, but the exact time of repair depends on the nature and severity of the other anomalies. Frequently the multiple handi-

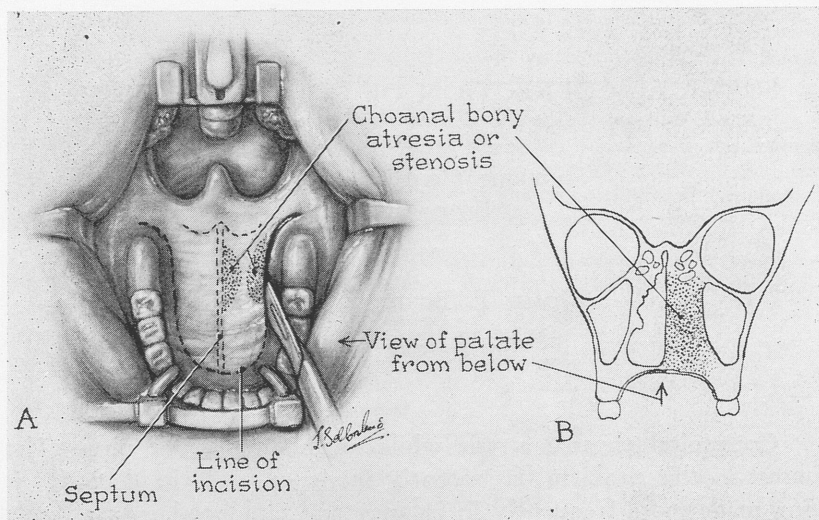


Fig. 1.

capped child must be provided with the means to compensate for choanal atresia for a period long enough to permit correction of more urgent anomalies. This can be accomplished by the temporary use of oral airways rather than tracheostomy. Of course, the use of an oral airway to allow other operations to take place enhances the problem of gavage feeding and increases the likelihood of aspiration pneumonia. A surgical procedure designed for temporary correction of choanal atresia should be avoided if possible as it complicates the subsequent permanent surgical correction. Total bilateral permanent correction of choanal atresia can be done in infancy with little risk to the patients and good results are obtained. No stenosis following the transpalatal approach was seen in this study. The surgeon today can employ improved light and magnification in the total correction of choanal atresia. The surgical approaches and techniques are not new, having been described by many surgeons in the past 50 years.

The transpalatal approach is best carried out in the Trendelenberg position with the head low. Endotracheal anesthesia allows for complete relaxation and careful positioning of the patient. A mouth gag is invaluable in lifting the tongue anteriorly and allowing an unobstructed view of the palate. Headlights and magnification have been

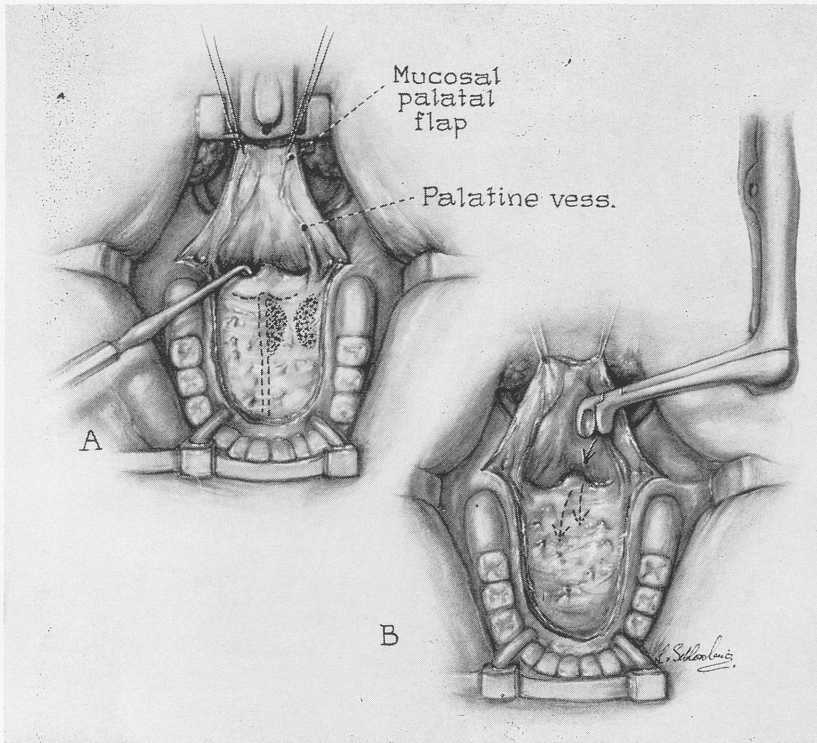


Fig. 2.

found useful in this procedure. The incision begins at the second molar on one side and extends in a gentle curve to the second molar on the opposite side, 4 mm inside the gingival margin extending through the mucosa and submucosa to bone (Fig. 1). Care must be taken to contain the palatine arteries in this flap as it is raised. The flap is easily elevated and should be raised beyond the margin of the hard palate posteriorly, care being taken not to injure the superior mucosal surface of the soft palate (Fig. 2). The posterior ridge of the hard palate is removed with the sphenoid punch. The nasal mucosa must be reflected from the hard palate ahead of the sphenoid punch so as to prevent injury to this mucous membrane. The hard palate is removed beyond the atretic area on the involved side and nearly as far on the opposite side if the lesion is unilateral. At this

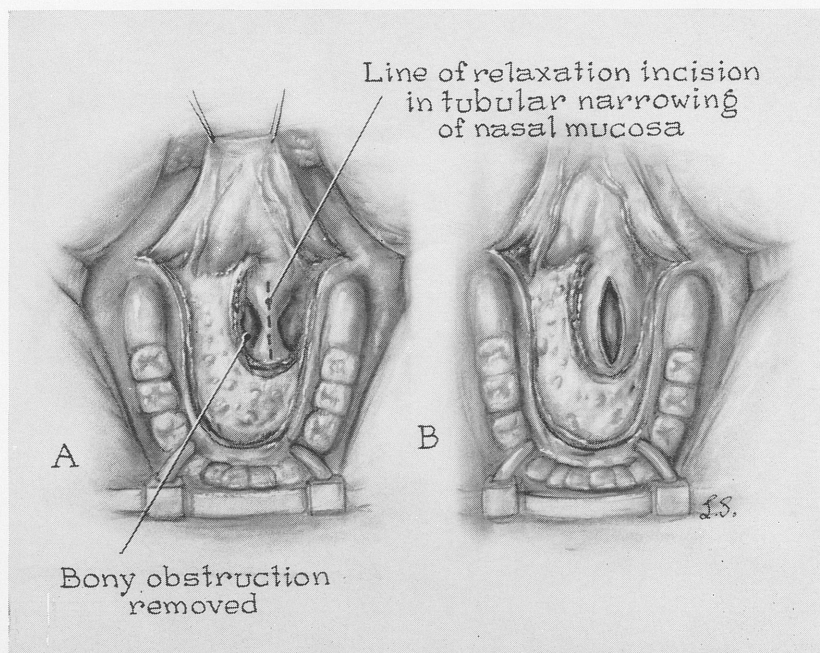


Fig. 3.

point the anatomy of the deformity should become clear (Fig. 3). One can see the anatomy of the bony and membranous atresia as related to the vomer to the lateral nasal wall and to the nasopharynx. Removal of the thinnest part of this obstruction which closes the lumen is not sufficient to insure permanent patency because the real problem lies in the thickened vomer and lateral nasal wall shown in this illustration. To accomplish the proper removal, one must have these deformities under direct vision. The transpalatal approach accomplishes this. Eighty-four per cent of our cases had some bony involvement which necessitated complete removal of this bony abnormality or permanent correction would not have been obtained. A soft tissue obstruction is next dealt with by an excision of the membranous stenotic zone (Fig. 3). Often a longitudinal incision in the mucosa of the nasal floor anterior to the deformity will allow a clearer evaluation of membranous obstruction. This is an important consideration for it allows one to evaluate more accurately the com-

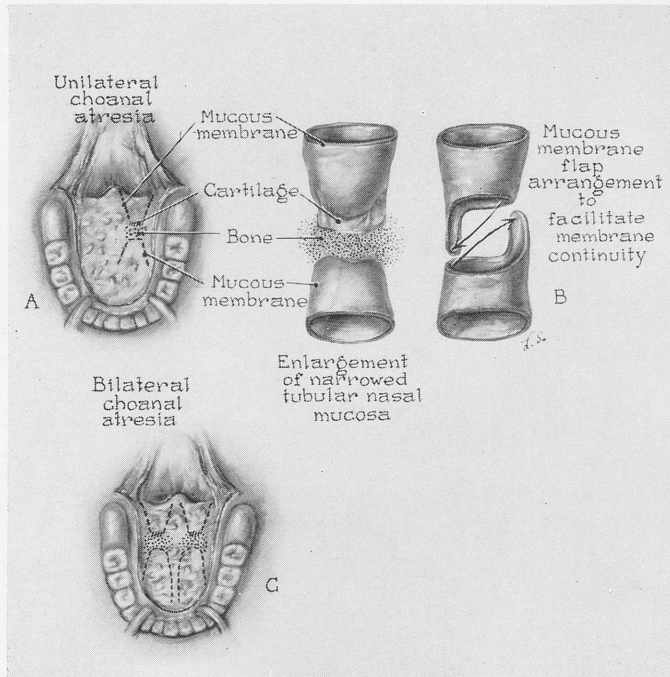


Fig. 4.

plicated relationship between the bony and membranous occlusion. The excision of this membranous septum reduces the possibility of scar formation and stenosis on a membranous basis. The narrowed mucosal tubule is seen more clearly and this hour glass narrowing which occasionally occurs can be corrected by the relaxation incision which is made in the floor of the nasal mucosa, and is held open by a molded or preformed polyethylene tube placed in the deformed nostril, thus allowing re-epithelialization of the floor from side to side. The construction of mucosal flaps at the point nearest the previously removed atretic bone should be attempted (Fig. 4). Nasal mucosal flaps created from nasal tubular mucosa have proven useful. Flaps created from the nasal septum can be fashioned if the tubular flaps are impossible to construct or if they leave large areas still uncovered. The molded polyethylene stent is placed in the nostril in such a fashion that the previously reconstructed mucosal flaps will be held

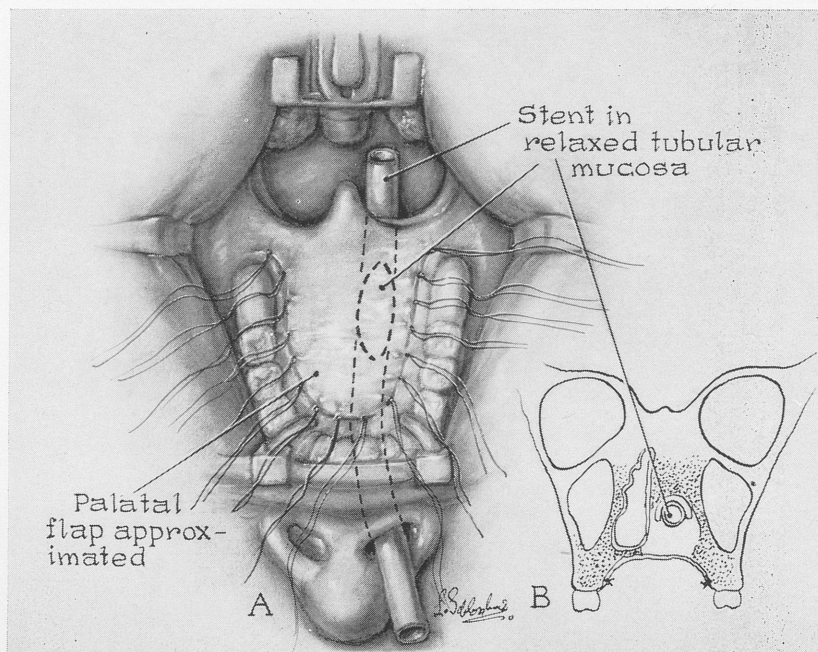


Fig. 5.

in place by the stent (Fig. 5). The mucoperiosteal flap from the hard palate is then laid back against the hard palate. The margins of the wound are sutured in place leaving the sutures long so they can be tied over a gauze stent molded to fit the palate (Fig. 6). It should be noted that the voice has been unchanged by total correction of choanal atresia via the transpalatal approach in this series.

An analysis of the 18 most recent cases of choanal atresia operated upon at the Johns Hopkins Hospital on the otolaryngological service showed there were 8 bilateral and 10 unilateral choanal atresias (Table I). The incidence of occurrence was 5 to 1 in the Caucasian race over the Negro race while within the hospital population at large there were more Negroes than Caucasians. No patients showed evidence of familial disease. There was, however, a strong association of other anomalies with congenital atresia being 50 per cent in this series. There were no cases with pre-existing sinusitis and only one case with pre-existing otitis media on the side opposite the atresia.

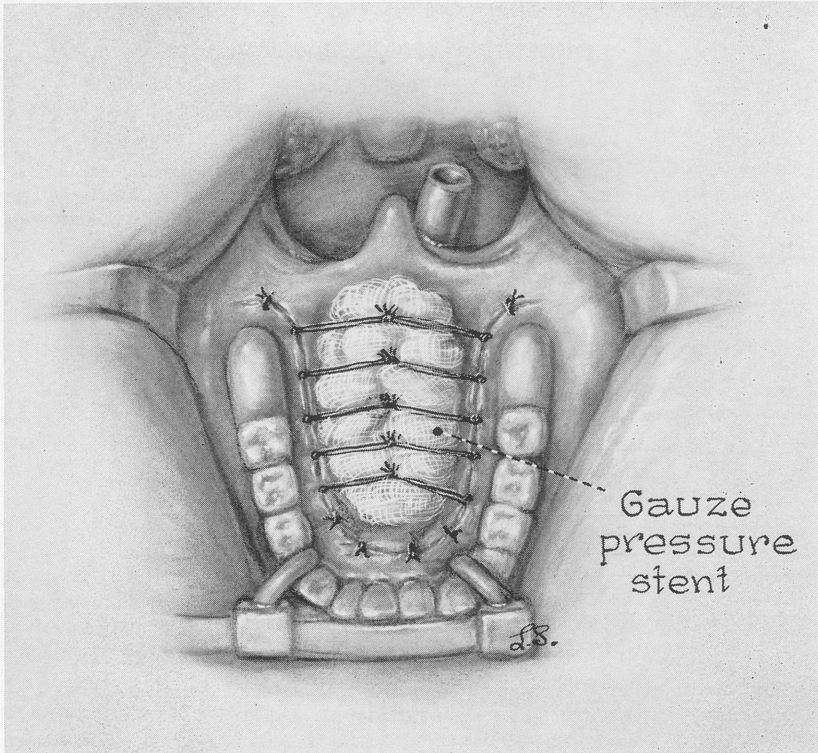


Fig. 6.

Two cases had repeated adenoidectomies before the diagnosis of choanal atresia was established. Unilateral lesions were all diagnosed after the first year of life (Table II). Symptoms of nasal obstruction, nasal discharge and excoriation of the nasal vestibule were often seen for years before the diagnosis was established in unilateral choanal atresia. Symptoms of bilateral choanal atresia seemed more severe and led to the diagnosis early in the course of the disease. In this series the pathology was seen as osseous or osseous and membranous in 84 per cent of the cases (Table III). Since the bony and membranous distortion occurs so frequently in choanal atresia, the best surgical approach has proven to be through the hard palate. The five cases in which this transpalatal procedure has been employed have developed no complications nor shown any evidence of recurrence of obstruction.

TABLE I
CONGENITAL CHOANAL ATRESIA
18 Most Recent Cases

	<i>Bilateral</i>	<i>Unilateral</i>
Boys	5	3
Girls	3	7
	—	—
TOTAL	8	10

TABLE II
TIME THE DIAGNOSIS WAS ESTABLISHED

<i>Diagnosis Established</i>	<i>Bilateral</i>	<i>Unilateral</i>	<i>Total</i>
1st Week	5	0	5
1st Year	0	1	1
Later	3	9	12
	—	—	—
TOTAL	8	10	18

TABLE III
TYPES OF OCCLUSION

Osseous	10	84%
Osseous and Membranous	5	
Membranous	3	16%

SUMMARY

Some features of the surgical anatomy of choanal atresia are presented and discussed. The transpalatal approach for its correction have been review with special attention directed to the narrowed nostril by bony overgrowth.

The recent results of the surgical correction of choanal atresia at the Johns Hopkins Hospital on the otorhinolaryngology service

have been reported. These results indicate the method of choice for correction of choanal atresia is via the transpalatal exposure.

THE JOHNS HOPKINS HOSPITAL

REFERENCES

1. Flake, Carlyle G., M.D., and Ferguson, Charles F., M.D.: Congenital Choanal Atresia in Infants and Children. *ANNALS OF OTOTOLOGY, RHINOLOGY AND LARYNGOLOGY* 73:458-573, 1964.
2. McKibben, Col. Byron G., MC: Congenital Atresia of the Nasal Choanae. *Laryngoscope* 67:731-755, 1957.
3. Owens, Harold, M.D.: Observations in Treating Twenty-Five Cases of Choanal Atresia by the Transpalatine Approach. *Laryngoscope* 75:84-104, 1965.
4. Peebles, Edward McC., Pr.D., Dent, John H., M.D., and Rutledge, Lewis J., M.D.: Choanal Atresia in the Newborn Infant: Report of Two Cases with Detailed Anatomic Studies. *Laryngoscope* 75:783-792, 1965.

DISCUSSION

DR. CHARLES F. FERGUSON: I enjoyed very thoroughly this paper which Dr. Cherry and Dr. Bordley have so nicely presented. I think it is a very good idea to bring this subject up from time to time. Even now, with as much instruction which has been given to many residents, pediatricians and obstetricians, still the diagnosis is not made as early as it should be.

I would certainly agree that the transpalatal approach is the proper one for definitive surgery. We still see many patients on whom an operation has been done intranasally, and find that it has to be repeated transpalatally. This makes the second procedure more difficult.

We have felt, as I reported in the cases presented two years ago at the San Francisco meeting, that the transpalatal approach can be done very easily in the newborn. The youngest we have operated upon transpalatally was fifteen days. However, with the "nipple technique," which McGovern offered a few years ago, we now manage to get these patients in better shape for the transpalatal operation. We can postpone this operation until the baby is around a month or two of age, ideally, but it is perfectly safe and perfectly feasible to do this procedure earlier in the newborn period. This "nipple technique" obviates the necessity for tracheotomy, which I would agree was not indicated in most patients. They can be carried along much better *without* tracheotomy.

I would like to ask one question. What was the nature of the splint that Dr. Cherry and Dr. Bordley used? We have found that in most of the transpalatal operations, even in infants, tubing or stents are not necessary if you do take out some of the posterior portion of the septum. Then you do not get closure of this area and the choanae stay open very well.

DR. JERRY CHERRY (closing): The splint consists of a polyethylene tube fitted to the opening. Various sizes are available and the proper sized tube is selected for each individual case.

CRICOARYTENOID ARTHRODESIS

WILLIAM W. MONTGOMERY, M.D.

BOSTON, MASS.

As a junior resident in otolaryngology I admitted to the hospital a 62-year-old man who complained of symptoms referable to his larynx of ten years' duration. His voice was reduced to an almost inaudible whisper. He frequently aspirated liquids, and his cough was ineffective. Indirect laryngoscopy demonstrated a paralyzed left larynx which remained in the position of extreme abduction. The right larynx functioned normally. The absent laryngeal sphincteric function was the obvious cause of his symptoms.

The patient was discharged from the hospital shortly after his admission, and I was instructed with a certain degree of indignation that there was no therapy for this condition. This was the initial stimulus for research on the repositioning and fixation of the arytenoid to the cricoid and the resultant operative procedure with which this paper is concerned, cricoarytenoid arthrodesis.

There are two types of vocal cord paralysis for which our current therapy is inadequate: unilateral or bilateral paralysis in the position of abduction; and bilateral midline paralysis.

No operative procedure has been introduced which will relieve the symptoms due to paralysis of one or both sides of the larynx in the position of abduction. In this situation the laryngeal airway remains patent. The three sphincter functions of the larynx, however, are inadequate: 1) the voice is weak or absent; 2) aspiration is most frequent during the deglutition of liquids; and 3) the cough reflex is inadequate.

There have been numerous operative procedures devised for the relief of the inadequate airway associated with bilateral vocal cord

paralysis in the position of adduction. Surgical treatment ranges all the way from one of the various techniques for arytenoidectomy to a procedure for the lateral displacement of the arytenoid. These procedures are not consistently successful in providing the patient with an adequate airway. Since the sphincteric, vocal and ptussic functions of the larynx are not altered in this situation, some laryngologists prefer a permanent tracheotomy with or without a one-way valve (Tucker or Kistner).

Such a permanent tracheotomy, however, requires considerable care and definitely limits the patient's activities. An operative procedure which would allow the surgeon to fix the arytenoid and vocal cord in a position so as not to appreciably interfere with the vocal function and which would provide the patient with an adequate airway without interfering with the other functions of the larynx would be ideal. The repositioning and fixation of the arytenoid to the cricoid in the cricoarytenoid arthrodesis operation may be the answer to this problem.

Numerous experiments were conducted over a two year period to arrive at a suitable technique for repositioning and fixing the arytenoid to the cricoid. Large canines were used for these experiments to simulate the size of the human larynx. In this way the instruments designed for the experimental work would not have to be significantly altered for operating on humans.

The first stage experiment consisted of producing a unilateral laryngeal paralysis by sectioning the left recurrent laryngeal nerve. The lower thyroid cartilage, cricoid and upper trachea were exposed using a vertical skin incision. A nerve stimulator is used to positively identify the recurrent laryngeal nerve and its branches. There is considerable variation in the course of the recurrent nerve and its branches even in canines of the same breed. For the most part it ascends fairly close to the trachea. On occasion, however, it is found crossing obliquely towards the cricoid cartilage from the carotid sheath. The nerve branches just before entering the larynx under the cricoid cartilage. In most animals there were two branches. The response evoked by stimulating these branches was variable. The usual response induced by stimulating either branch was a massive unilateral adduction of the larynx. However, in some canines we noted with considerable interest that by stimulating the lower branch the left larynx adducted, while stimulation of the upper branch produced abduction of the left larynx. For the experiments concerned

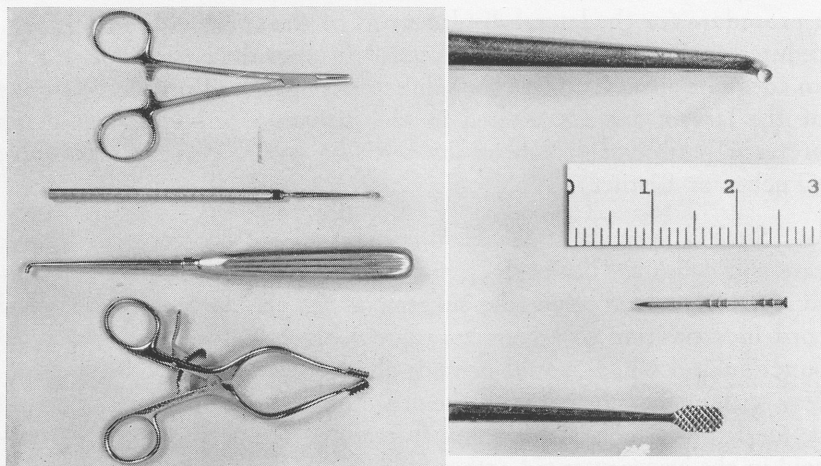


Fig. 1.—*a*. Instruments used for the cricoarytenoid arthrodesis. From top to bottom: pin holder, cricoarytenoid pin, joint rasp, pin pusher, and thyrotomy retractor. *b*. A close-up photograph of the pin pusher, cricoarytenoid pin (17.5 mm) and joint rasp.

with this presentation the entire left recurrent laryngeal nerve was sectioned producing a paralysis either in the midline or paramedian position. Direct laryngoscopy was performed during recovery from anesthesia in the first stage experiment and also during anesthesia induction prior to the second stage experiment.

The second stage experiment consisted of a cricoarytenoid arthrodesis. A thyrotomy was accomplished by way of a vertical midline incision. Exposure of the entire endolarynx was accomplished using a self-retaining retractor of special design (Fig. 1*a*).

The cricoarytenoid joint in the dog varies considerably from that of the human but is sufficiently similar so that information gained from experimentation can be readily applied to the human larynx. A number of canine larynges were dissected under magnification in order to accurately outline the cricoarytenoid joint. The posterior aspect of the cricoarytenoid joint is 1 cm anterior to the posterior cricoarytenoid muscle of the same side. The center of the joint is located directly beneath the base of the corniculate process. The site for the entry of the cricoarytenoid pin is thus at this point. An interesting finding in the canine larynx is an interarytenoideus carti-

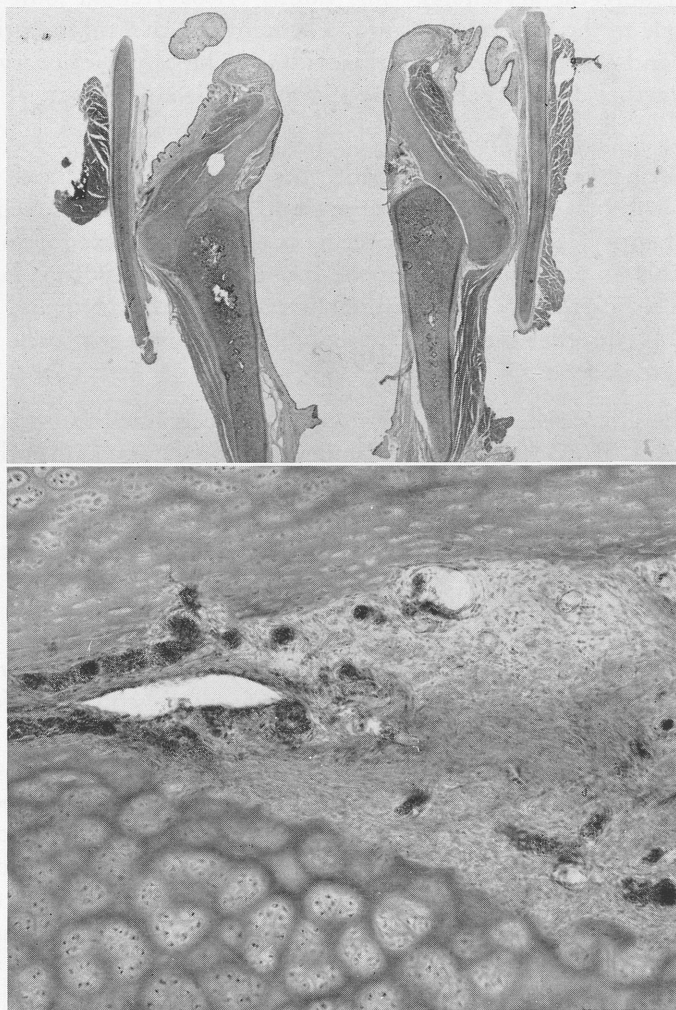


Fig. 2.—*a*. A section of canine cricoarytenoid joints two months after a left cricoarytenoid arthrodesis. The specimen was sectioned in a horizontal plane from posterior to anterior. The normal cricoarytenoid joint is seen on the right side. *b*. A higher magnification of the fibrous ankylosis accomplishing the cricoarytenoid arthrodesis.

laginous bridge which replaces the interarytenoideus muscle. This thin cartilaginous interarytenoid bridge must be severed prior to repositioning the arytenoid. The canine cricoarytenoid joint is at a 35° angle to the horizontal plane. The joint is 7 to 8 ml in horizontal length and 4 ml in anteroposterior width. The canine cricoarytenoid joint is arthroidial in type, having a joint capsule and a synovial lining, as it is in the human.

During our early experiments the arytenoid was fixed to the cricoid without entering the cricoarytenoid joint. This proved to be unsatisfactory, for without entering the cricoarytenoid joint it is impossible to accurately direct the pin into the medullary layer of the cricoid cartilage. Also, without fixation of the arytenoid to the cricoid (arthrodesis) there is the possibility of disengagement of the cricoarytenoid pin.

The cricoarytenoid pin (Fig. 1*b*) is constructed from stainless steel. A 17.5 ml length is satisfactory for the canine and both sexes of the human larynges. The head of the pin resembles that of a common pin. At levels on the shaft which are to be in contact with the arytenoid and cricoid cartilages are constructed two separate rows of circumferential barbs to prevent retrograde displacement of the pin.

There are three essentials for a successful arthrodesis: compression, continuity, and contact. They are accomplished by the following technique. A horizontal incision is made in the mucous membrane over the cricoarytenoid joint. The size and position of the joint are palpated using a small curved periosteal elevator. A specially designed joint rasp (Figs. 1*a* and 1*b*) is inserted into the joint and both the arytenoid and cricoid surfaces are disrupted. A 1 ml incision is made in the mucous membrane at the anterolateral aspect of the base of the corniculate process of the arytenoid. This corresponds to the base of the muscular process of the arytenoid. The cricoarytenoid pin is grasped in the mid-shaft region, and it is inserted vertically through the body of the arytenoid until it can be visualized or palpated in the cricoarytenoid joint. The arytenoid is then moved and rotated to the desired position of abduction or adduction, and the pin is inserted into the medullary layer of the cricoid. The final advancement of the pin is accomplished with an instrument which is called a pin-pusher (Figs. 1*a* and 1*b*). A direct laryngoscopy checks the position of the left vocal cord after the laryngofissure has been closed.

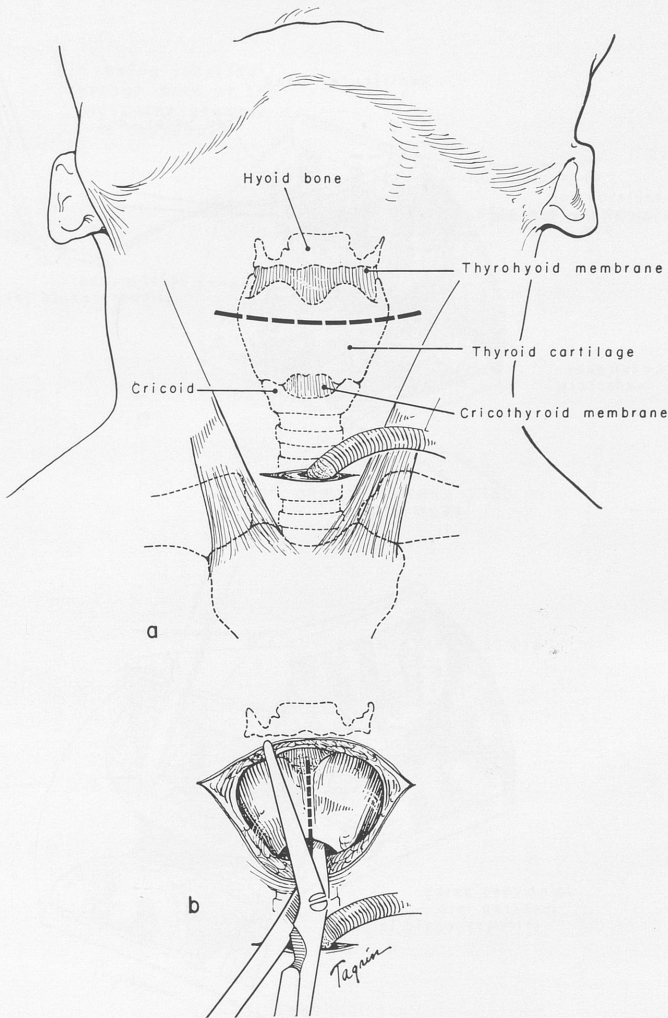


Fig. 3.—*a*. A separate horizontal incision for both the laryngofissure and tracheotomy are preferable to a single vertical incision for the reason of cosmesis. The level of the incisions are shown in relation to the hyoid bone, thyroid and cricoid cartilages, and trachea. An endotracheal tube is inserted into the trachea by way of the tracheotomy. The horizontal and thyroid incision is carried through the platysma exposing the sternohyoid muscles. Dissection is continued until the thyrohyoid membrane, anterior aspect of the thyroid cartilage and cricothyroid membrane are exposed. *b*. A vertical incision is made in the cricothyroid membrane. The lower blade of the laryngeal scissors is then inserted into the larynx by way of this incision. This blade is carefully placed into the anterior commissure by palpation before the anterior aspect of the thyroid cartilage is transected. A small portion of the thyrohyoid membrane and base of the epiglottis is incised with a button knife for additional exposure of the larynx before the self-retaining retractor (Fig. 1*a*) is inserted.

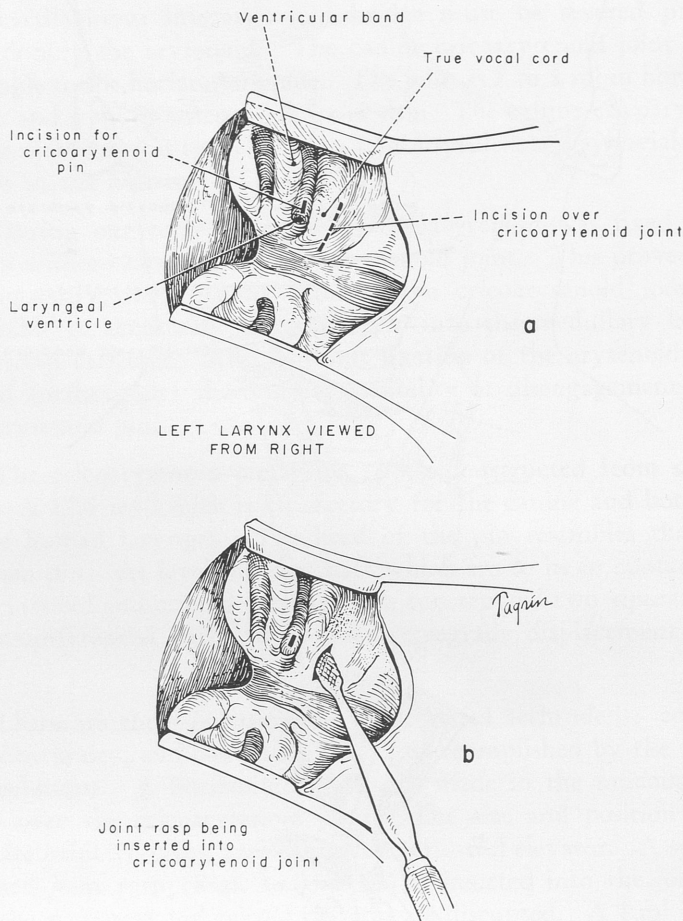


Fig. 4.—*a*. The self-retaining thyrotomy retractor has been inserted into the larynx. The left larynx is viewed from the right side. It is necessary to obtain full view of the ventricular band, laryngeal ventricle and true vocal cord as well as the immediate subglottic area. The cricoarytenoid joint is palpated with a spatula just below the level of the vocal cord. The vocal process of the arytenoid can be used as a guide. An incision is made in the mucous membrane over the joint. A separate incision using a number 11 blade is made just above the vocal cord in the region of the base of the muscular process of the arytenoid. *b*, After the cricoarytenoid joint has been carefully palpated with a laryngeal spatula, a joint rasp (Fig. 1) is inserted to disrupt the continuity of both the arytenoid and cricoid surfaces of the cricoarytenoid joint.

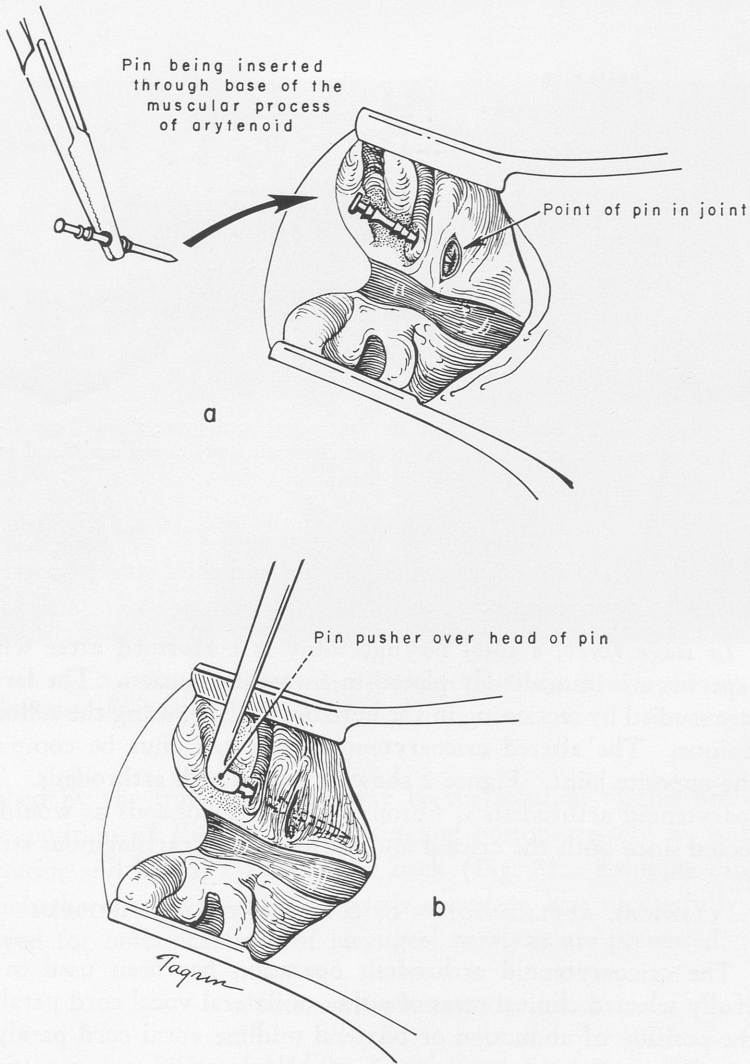


Fig 5.—*a*. The cricoarytenoid pin is grasped in the center of the shaft and inserted by way of the base of the muscular process of the arytenoid into the cricoarytenoid joint. It is essential to either visualize or palpate the point of the pin in the joint in order to direct it into the medullary layer of the posterior cricoid lamina. The arytenoid is then placed in the desired position and the pin is inserted into the posterior cricoid lamina. *b*. A pin pusher is necessary to complete the insertion of the pin so that the head lies beneath the mucous membrane and in contact with the base of the muscular process of the arytenoid. It is not necessary to suture the intralaryngeal or cartilaginous incisions. The sternohyoid muscles are sutured in the midline over the thyroid cartilage. Subcutaneous and dermal sutures are used to close the thyrotomy incision. At the completion of the operation, a direct laryngoscopy determines the position of the arytenoid and vocal cord on the operated side.

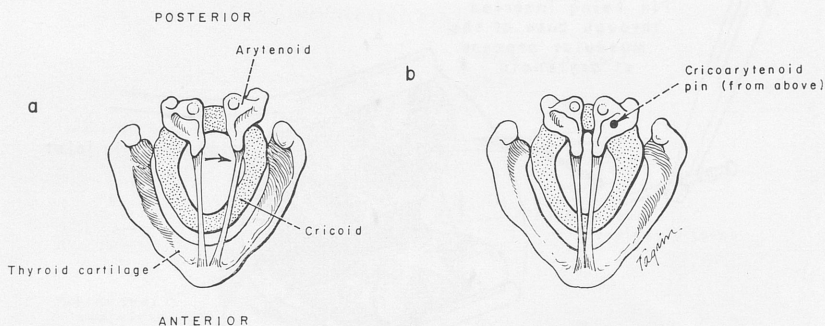


Fig. 6.—*a*. A sketch showing the left vocal cord paralysis in the position of abduction. *b*. The left arytenoid has been repositioned and fixed in the midline.

The length of time between the second and third stages has varied from one to four months.

In stage three, a total laryngectomy is performed after which the specimen is immediately placed in formalin solution. The larynxes are studied by sectioning in the horizontal plane, using the celloidin technique. The altered cricoarytenoid joint can thus be compared to the opposite joint. Figure 2 shows a two-month arthrodesis. The cricoarytenoid arthrodesis is fibrous rather than osseous as would be expected since both the cricoid and arytenoid are cartilaginous structures.

CLINICAL APPLICATION - CRICOARYTENOID ARTHRODESIS

The cricoarytenoid arthrodesis operation has been used in 14 carefully selected clinical cases of either unilateral vocal cord paralysis in the position of abduction or bilateral midline vocal cord paralysis. The technique for this operation in the human does not vary from the experimental procedure. For unilateral paralysis in the position of abduction, the arytenoid on the paralyzed side is repositioned and fixed in the midline position. The arytenoid is repositioned and fixed in the paramedian for bilateral midline vocal cord paralysis in order to improve the airway. It is much easier to reposition the arytenoid to the midline position. This is probably because of the lateral retraction of the anterior aspect of the thyroid cartilage which is necessary for exposure during the laryngofissure approach. Further refinement of the procedure or a cricoarytenoid arthrodesis accom-

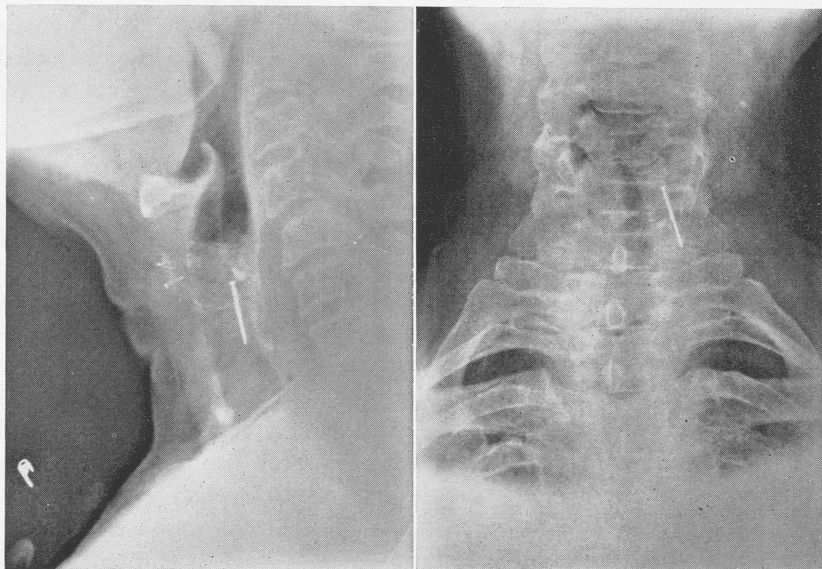


Fig. 7.—Lateral and anteroposterior cervical x-rays showing the cricoarytenoid pin in place (Case 1).

plished by the transoral route may be the solution to this problem. The position of the pin can be checked postoperatively by anteroposterior and lateral x-rays of the neck (Fig. 7). Example cases in which the cricoarytenoid arthrodesis operation was successfully employed for both situations of laryngeal paralysis are presented.

REPORT OF CASES

CASE 1. *Bilateral Midline Vocal Cord Paralysis.* Mrs. E. K., aged 61, was admitted August 19, 1965 with a history of bilateral vocal cord paralysis in the midline position of ten years' duration. This resulted from thyroid surgery. One year prior to this admission, she had had a left arytenoidectomy performed. This was unsuccessful. Her voice was only slightly hoarse. She had no inspiratory airway. A tracheotomy was in place. On August 20, 1965 a right cricoarytenoid arthrodesis was accomplished, with fixation of the arytenoid in the position of abduction. During the procedure it was noted that there was almost no tone to either the true or false cords, on both

sides, because of long-standing paralysis. Two weeks following the operation the patient began to show signs of an increasing inspiratory airway. There was little or no change in her voice. Two months postoperatively, her airway was sufficient so that she no longer needed a tracheotomy tube. She has remained well since. Cervical x-rays show the cricoarytenoid pin in place (Fig. 7).

CASE 2. Unilateral Paralysis in the Position of Abduction. Mrs. L. D., aged 52, was admitted to the Massachusetts Eye and Ear Infirmary on August 27, 1964. One year before this time she had had a sudden onset of severe hoarseness to the point of near aphonia. She also had difficulty due to aspiration of liquids and had loss of an effective cough. Her past history was not significant except for symptomatology following streptomycin treatment of pneumonia eight years before this admission. Since this illness she has had persistent rotational vertigo when recumbent on her right side. A complete general and neurological examination was within normal limits except for a hyperactive caloric response on the left side. On indirect laryngoscopy a left laryngeal paralysis in the position of abduction was visualized. Her vocal cords did not approximate during attempted phonation. On August 28 a left cricoarytenoid arthrodesis by way of a laryngofissure was carried out following tracheotomy. The left arytenoid was repositioned and fixed in the midline position.

Recovery following this procedure was uneventful. Three weeks after surgery the patient enjoyed a normal voice, had no aspiration of liquids and an effective cough. She has been carefully observed for one year, and there has been no regression of laryngeal function.

SUMMARY

This paper presents an operative procedure, cricoarytenoid arthrodesis, which was developed from canine animal experimentation. It was designed to relieve the distressing symptoms (dysphonia or aphonia, aspiration and ineffective cough) of unilateral laryngeal paralysis in the position of abduction.

The cricoarytenoid arthrodesis operation accomplishes a repositioning and fixation of the arytenoid to the cricoid by first entering and disrupting the normal continuity of the cricoarytenoid joint and then fixing the arytenoid to the cricoid with a stainless steel pin of special design. The operation has thus far been employed in 14 carefully selected clinical patients. Case reports are included in which

the cricoarytenoid arthrodesis operation was used either to correct the disability associated with unilateral laryngeal paralysis in the position of abduction or bilateral midline vocal cord paralysis.

243 CHARLES STREET

DISCUSSION

DR. FRANCIS L. LEDERER: I think it is to Dr. Montgomery's credit to have alerted us to this possibility and his observation and his solution of the problem point the way.

We have come a long way in the treatment of rheumatoid states since the days of Frank Billings and Rosenau in otorhinolaryngology, where the sacrificial lamb was the tonsil, occasionally with some sinuses thrown in for good measure, in the focal infection era.

We have now come of age and are recognized among our colleagues for our ability to help them in the salicylate problems, where the treatment of rheumatoid arthritis has produced ototoxicity.

I am certain, too, that with the use of steroids we are going to see more complications of one type and another.

Dr. Montgomery, I am sure, in assembling fourteen cases, or something in that amount, has carefully selected the patients for this procedure. He has indicated it under conditions where the patient is in difficulty. I am sure that they have all been subjected to many types of procedures. I wondered how their physicians arrived at the diagnosis, how they knew when to send this type of patient to a laryngologist.

Certainly we need to speak of these things before rheumatologists and others in the field so we can let them know what the laryngologist and the otorhinologist has to offer.

DR. DOUGLAS P. BRYCE: I wish to ask two questions:

One is, in the intralaryngeal manipulation attempted sometimes for lateralization of the arytenoid the problem has been, in my hands, of granulation when the mucous membrane has been opened and I wonder if Dr. Montgomery is bothered with granulations after the insertion of this particular pin.

And secondly, I wasn't quite clear whether this method he was suggesting for adduction only or whether he feels that this could be used, or might better be used, for abduction in other than fixed joints.

DR. DAVID W. BREWER: Dr. Montgomery's procedure is an excellent one. As I listened to his presentation, about fifteen or sixteen years ago Earl Blaisdell, who was to become a member of this Association and unfortunately died just before the meeting, had such a case with a bilateral abductor fixation. His procedure, which he typically described as a "Queen operation," or a "reverse-King," was to remove the arytenoid and take a portion of the sternohyoid muscle and tuck it in to push the cord medially.

I think Dr. Montgomery's procedure is a very much neater affair and he can position the arytenoid in a much more accurate fashion.

DR. MONTGOMERY (closing): We have noticed no granulation tissue forming in the animal experiments or the human. These are very small incisions. Maybe I implied by the drawings that they were large. The one in the ventricle is less than a millimeter in length and the one over the joint is 3 or 4 millimeters in length.

FURTHER EFFORTS FOR CORRECTION OF SEVERE, ACUTE OR CHRONIC LARYNGEAL STENOSIS

DOUBLE POST TEFLON TUBE UTILIZATION

JOHN S. KNIGHT, M.D.

KANSAS CITY, Mo.

The original cases, where the plastic sheeting was used for the development of an anterior commissure with satisfactory voice as well as airway, are still maintaining their improvement.

The first patient, M.P., had a laryngofissure and left cordectomy in April of 1948 for squamous cell carcinoma. A second laryngofissure and tracheostomy was required in April of 1956 to correct the progressive web formation and poor voice aggravated by keloid formation. Fixation of an acrylic tube was performed and the tube was allowed to remain in the larynx for five weeks. She had the usual skin sores associated with wire or suture fixation in the neck tissues. Decannulation was possible, but a poor voice persisted. Eleven years after her first surgery, a third laryngofissure and right cordectomy was required in September 1961 for a new primary squamous cell carcinoma. The implantation of plastic sheeting, 2 cm x 1½ cm, over the right vocal cordectomy area was maintained by transfixion with two nylon mattress sutures. One month later, the sutures were cut externally and the plastic sheeting was removed by direct laryngoscopy. A recording of her voice five and a half years later is now produced (Fig. 1).

The second case with voice recording is presented to show the development of a satisfactory voice in a young man following an automobile accident where there was marked hoarseness from webbing of the anterior third of the larynx. A laryngofissure and plastic sheeting implantation gave a sufficient improvement so that he has been accepted for military service.

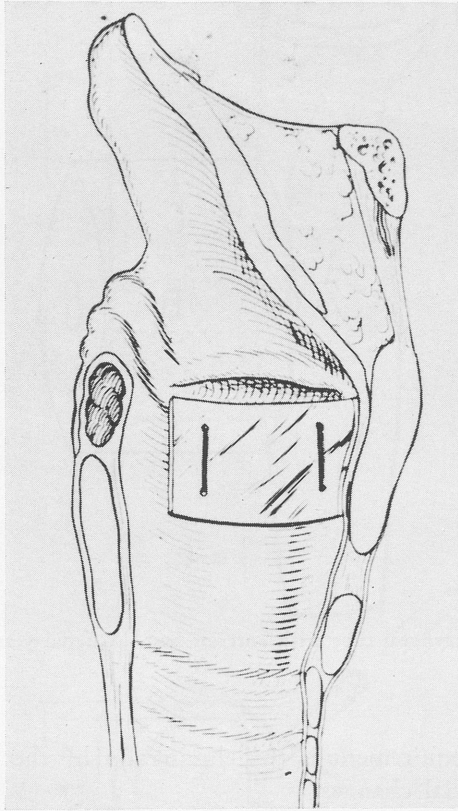


Fig. 1.—Median sagittal section showing placement of deep mattress sutures.

The third recording is of interest because the patient has a good airway and a satisfactory voice three years after the implantation of a polyethylene tube, associated with an extensive hemilaryngectomy.

When the subject of rehabilitation of patients with laryngeal stenosis with the use of plastic sheeting¹ was presented at the Middle Section of the Triological Society in Rochester, Minnesota, on January 18, 1964, a question was raised as to the proper handling of the more severely traumatized voice boxes or those cases that had had extensive surgery for carcinoma removal.

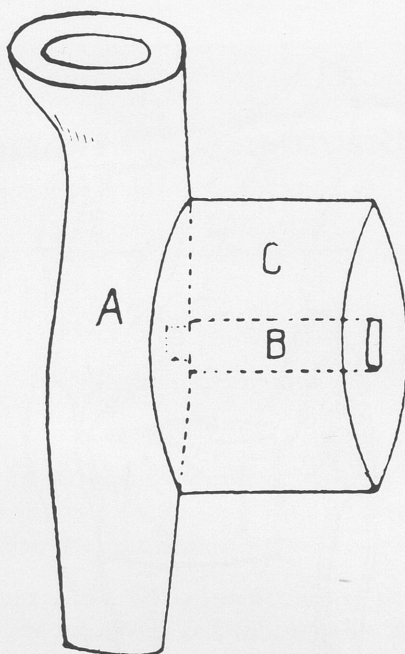


Fig. 2.—Laryngeal tube with anterior post. Offered years ago—author unknown.

The first requirement is the elimination of the offending neoplasm or cicatricial changes.

Of second importance is the creation of a satisfactory laryngeal airway. The corking of the tracheal cannula should be accomplished in the postoperative period. The patient can assume many duties thereby. A core mold would preclude such a situation, but the use of an indwelling tube in the laryngeal space would be of value for breathing purposes and phonation.

A reconstruction of the new larynx for phonation should be attempted. This phase is the basis for this presentation.

John Conley's tracheal prosthesis,² a "collar button" attached to a stent or tube, for stenosis of the larynx is an excellent advancement. Others have had this idea in the past.

A Teflon® or nylon tube with two posts can be very firmly anchored in the damaged larynx at the time of the laryngofissure.

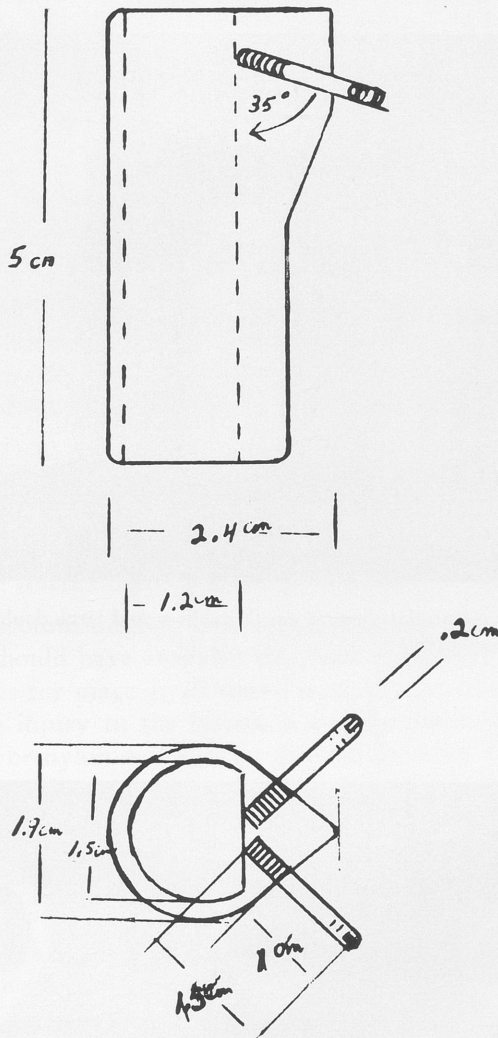


Fig. 3.—Double posted laryngeal tube.

Small openings in the thyroid cartilages and soft tissues should be made with a knife or burr. The posts were well tolerated by the neck tissues except in one case where the individual was allergic to plastic materials, even a plastic feeding tube and a plastic artificial eye. A short tag of merceline suture is placed in the small holes in the ends of the posts and the suture ends can be left dangling external to the




Fig. 4.—Anterior view of small, medium and large double posted tubes. Note: posts unscrew.

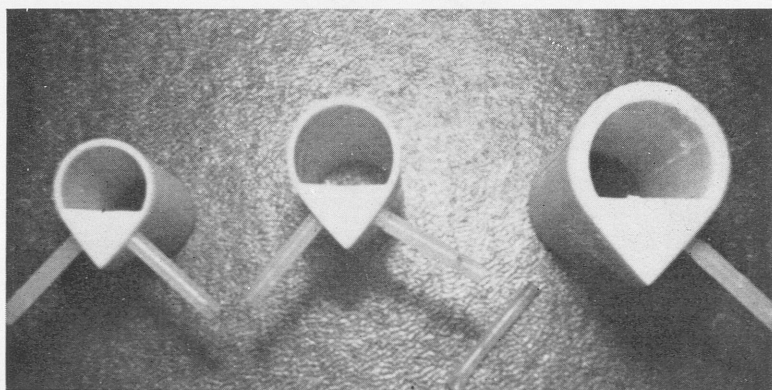


Fig. 5.—Superior view of three sizes of double posted tubes. Note: anterior angulation in superior portion.

neck skin. The posts should be short enough that there will be complete coverage by the skin and subcutaneous tissues. It is our opinion that the two posts should anchor the laryngeal tube better than one post, wire or nylon sutures (Fig. 2).

The acute angulation on the anterosuperior portion of the tube has been developed in the hope of obtaining an anterior commissure formation with the resultant potential of improved phonation. The use of a round tube has not produced a similar result.

Avoidance of an operation when the tube is to be removed can be accomplished by the unscrewing and removal of each post through small skin incisions and then the withdrawal of the tube from the larynx or upper trachea under direct laryngoscopy. This second procedure can be a very simple one and will not require hospitalization.

There is complete fixation in the larynx or upper trachea, where one wishes to correct the stenosis or prevent one following hemilaryngectomy. It is the author's opinion that this tube can be left in the larynx or upper trachea indefinitely, if so desired.

It is my recommendation that surgical clinics or groups of otolaryngologists should have available the three sizes of laryngeal tubes of variable types for usage at all times, especially in view of the fact that a crushing injury to the larynx is a daily potential. The fact that the Teflon or nylon tube can be re-used also is of value.

SUMMARY

1. Two patients have been rehabilitated by implantation of plastic sheeting.
2. A patient's voice is doing well three years after placement of a plastic tube in his larynx.
3. The use of a Teflon tube, double posted for fixation in the laryngeal area and fashioned with an acute angulation for anterior commissure formation, is advocated.

305 WEST 43RD ST.

REFERENCES

1. Knight, J. S.: Laryngeal Stenosis: Method of Surgical Correction. *Laryngoscope* 74:4:564-574 (Apr.) 1964.
2. Conley, J. J.: Tracheal Prosthesis for Stenosis. *Arch. Otolaryng.*, Vol. 82 (Oct.) 1965.

DISCUSSION

DR. WILLIAM M. MONTGOMERY: Since this is a hollow tube, I would like to ask if there is aspiration while it is in place.

And number two, I would like to ask if there is any voice during the time a tube is in place and is it necessary to leave these patients cannulated during the implantation?

DR. KNIGHT (closing): In answer to the spill-over problem of food, and particularly liquids, while the patient is wearing this tube, we have found that these patients have had no difficulty, except for this one allergic individual, and he gave me great distress. In the routine case, after the fourth or fifth day the feeding tube can be removed and the tracheal cannula, if it was needed, has been removed or corked after the second day.

We are using the word tube instead of stent. The *Dorland Medical Dictionary, Twenty-Second Edition*, describes a stent: 1) an impression taken in Stent's composition; 2) a mold to hold a graft in place.

No excessive granulations have been associated with the use of the teflon tube. There was marked mucosal lymphedema in the case of the previously mentioned allergic individual. He failed to respond to large intramuscular injections of enzymes but the lymphedema regressed quickly in twenty-four hours after the removal of the plastic tube and tracheal cannula. At the present time he is doing very well.

The hospital residence should be lessened by this procedure. The implantation of the double posted teflon tube at the same time of the emergency tracheostomy following a crushed voice box is feasible.

AN APPROACH TO THE INTERNAL LARYNGOCELE
AND OTHER SUBMUCOSAL LESIONS
OF THE LARYNX

C. T. YARINGTON, JR., M.D.

(by invitation)

JOHN P. FRAZER, M.D.

(by invitation)

FORT CARSON, COLO.

Our purpose here is to present a surgical approach which we have found successful in dealing with the problem of the internal laryngocele. The pathophysiology and natural history have been recently reviewed by Krekorian,¹ Cody,² as well as by ourselves,³ and will not be repeated here. Instead, we would like to direct our attention to a description of the surgical treatment of this lesion.

The diagnosis of these lesions has been discussed previously,^{1-3,10} and will not be discussed in detail. Usually the lesion can be diagnosed by direct laryngoscopy, and the differential diagnostic problems solved by soft tissue films of the neck. In contrast to the findings of others, we have found properly exposed anterior and lateral soft tissue films of the neck more useful than tomograms in diagnosing these lesions. Moreover, the use of Valsalva maneuvers is considered dangerous by some³ due to the occasional problem of acute inflation and obstruction.

Although Lore⁴ and others have felt that these lesions are adequately controlled by endoscopic excision, we believe that an external approach offers better results. The procedure which we have used is not new. It is an adaptation of procedures described by Walls,⁵ Keim,⁵ Livingston,⁵ O'Keefe,⁵ Johnston,⁷ Hill,⁸ Price,⁹ Lane,¹⁰ and others.¹¹

From the United States Army Hospital, Fort Carson, Colorado, and the Department of Surgery, Division of Otolaryngology, University of Rochester, School of Medicine and Dentistry.

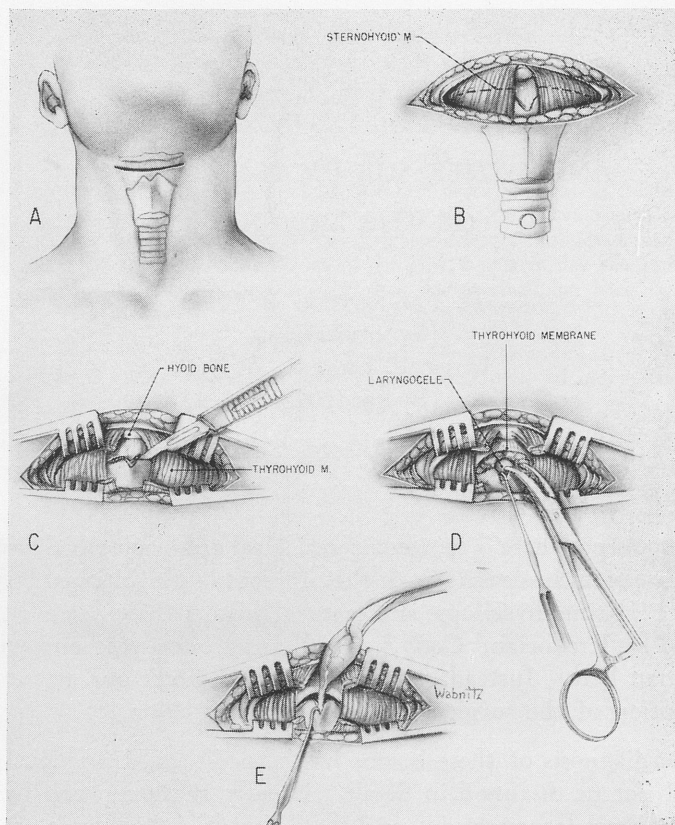


Fig. 1.

All of these men have utilized various lateral and anterior external approaches to the internal laryngocele. Therefore, the procedure to be described is the summation of what we feel are the best points of each approach. It is a graphic description of the work of many, rather than an original contribution.

As illustrated in Figure 1, an incision is made in the skin crease over the lower portion of the thyrohyoid membrane. The medial two-thirds of each sternohyoid muscle are transected and the thyrohyoid muscle retracted laterally. Limiting the lateral extension of the surgical field in this way protects the neurovascular bundles piercing the lateral thyrohyoid membranes. The thyrohyoid mem-

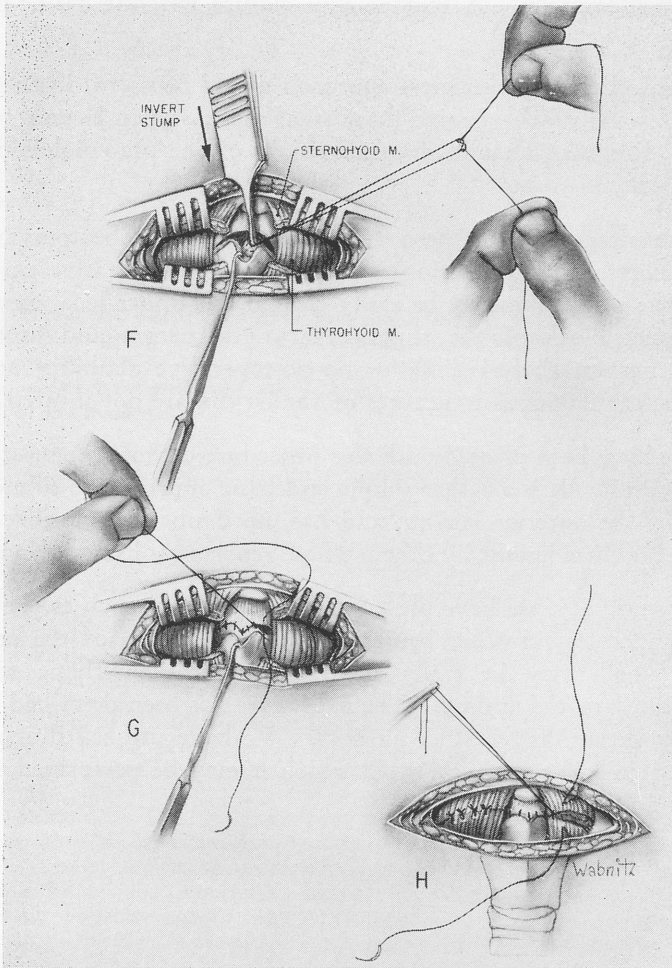


Fig. 2.

brane is incised along the upper border of the thyroid, following the contour of the notch. Dissection is carried into the fatty tissue of the pre-epiglottic space where the internal laryngocele is encountered and dissected free with sharp excision under traction.

In Figure 2, emphasis is placed on the principle of the use of the inverting purse-string suture, much like that used in hernia repairs. The incision in the thyrohyoid membrane is closed with absorbable,

interrupted or continuous sutures, as are the medial portions of the sternohyoid muscles. A routine skin closure without drains is then effected.

We feel that this surgical approach would be useful in the treatment of some of the benign tumors of the anterior larynx such as lipomas, fibromas, chondromas and lesions of the pre-epiglottic space and vallecula.

Advantages of this procedure are: that a tracheotomy should not be necessary if dissection is careful and postoperative care adequate; the procedure may be easily carried out under local anesthesia or regional block of the superior laryngeal nerves and superficial cervical nerves; there is little or no postoperative disability or scarring; the cartilaginous structures of the larynx are not injured.

We have been pleased with this procedure during our brief experience with it. It is a rather simple and basic approach to submucosal lesions of the anterior larynx, and has, no doubt, been utilized previously for these lesions by others whose reports we have not noted.

In summary, we have presented a surgical approach to the internal laryngocele and other benign submucosal lesions of the anterior larynx which may be easily done under local anesthesia without tracheotomy or thyrotomy. The procedure has been described before in many variations by other authors. We have utilized illustrations to call attention to the ease with which it may be performed by the otolaryngologist.

U. S. ARMY HOSPITAL

REFERENCES

1. Krekorian, E. A.: Laryngocele and Laryngopyoceles. *Laryngoscope* 72:1297, 1962.
2. Cody, C. C.: Laryngocele: Diagnosis and Management with Case Report. *E.E.N.T. Monthly* 44:68, 1965.
3. Yarrington, C. T., Jr., and Frazer, J. P.: The Surgical Treatment of Laryngocele. *Surg. Gyn. Obstet.* 122:308-312, 1966.
4. Lore, J. M.: An Atlas of Head and Neck Surgery. W. B. Saunders Co., pp. 392-393, 1962.
5. As quoted by Krekorian.
6. O'Keefe, J. J.: The Surgical Treatment of Laryngocele with Report of a Case. *ANNALS OF OTOLARYNGOLOGY, RHINOLOGY AND LARYNGOLOGY* 56:1071, 1952.

7. Johnston, J. H., Jr.: External Laryngocele. *Surgery* 34:307, 1953.
8. Hill, M. R., and Kipen, C. S.: Laryngocele. *Surgery* 35:273, 1954.
9. Price, T. B., Seltsam, J., and Pressman, J. J.: Laryngocele. *Amer. Jour. Surg.* 94:902, 1957.
10. Lane, S. L., Cohen, B., and Ippolito, C.: Co-existing Internal and External Laryngoceles. *Am. Jour. Surg.* 96:810, 1958.
11. Moghtader, A., and Arena, S.: Laryngocele: Report of Two Cases. *ANNALS OF OTOTOLOGY, RHINOLOGY AND LARYNGOLOGY* 74:1079, 1966.

DISCUSSION

DR. FRANKLIN KEIM: We have been impressed by the increasing frequency of the discovery of this lesion. I have made it almost a routine in doing laryngectomy to turn the larynx upside down under a stream of water and I have been surprised to notice how often one can pick up a small laryngocele, sometimes even bilateral, in this manner.

Of course, this means that probably many people have this lesion without even being aware of it and even the qualified laryngologist isn't aware of the existence of it.

I would like to ask Dr. Yarrington what he feels are the indications for resection of a laryngocele. The few that we have done have had more or less impairment of their airway and this has been in our mind the indication for resection of such a lesion.

I can see the advantage of an incision in the midline, transversely, which would be cosmetically a very acceptable one.

I would also like to ask him if he has found it necessary to wedge or resect any of the superior border of the thyroid cartilage in order to get at the lowest point of the laryngocele in the anterior portion of the ventricle.

DR. HOLINGER: Our own experience has been one of diagnosis and in two instances recently we have found the problem of an obvious laryngocele as noted on direct laryngoscopy and on mirror laryngoscopy only to enter the area that you were mentioning through the thyrohyoid membrane and to find a tumor in the back of this, a round, perfectly smooth tumor. Your indication is that of better exposure by carrying the incision to the opposite side and in this way more adequate removal is possible through this type of incision for laryngocele.

DR. YARRINGTON (closing): I feel in a very awkward situation having Dr. Keim ask me anything about indications for head and neck surgery. I have to refer to my reviews of the literature because I don't have very much experience in this field of determining whether laryngoceles are operable or whether an operation is indicated on them. I would have to say that from my brief experience and from my reading that individuals who are troubled and have symptoms of any kind from the internal laryngocele which may bring them to the physician with that as the chief complaint probably have an indication for surgery for the condition which is directly proportional to the disability or to the degree of discomfort of their symptoms.

Now, there has been a very interesting and unusual type of laryngocele recently reported by Krekorian in his second paper on this subject of a pilot who flew jet planes and whenever he flew over 27,000 feet in an unpressurized cabin without a

flight suit on, his laryngocele became so extensive that it gave him some airway difficulty and of course this would be an indication for the operation.

The gentleman whose slide we showed here just a few minutes ago came into the hospital requiring a tracheotomy for airway obstruction which had been progressive and of course he required excision of his laryngocele.

There has also been another recent report, in Canada, I believe, of a number of asymptomatic laryngoceles, which were found in a survey and which did not require surgery, so that I think the symptoms probably should dictate the choice of treatment.

Now, your second question about whether or not the thyroid cartilage would have to be wedged, actually when we first did this procedure we had every intention of doing a thyrotomy and it was only just to try and see what would happen by entering the thyrohyoid membrane and dissecting down just to see if we could perhaps pick the laryngocele up and, as a matter of fact, it almost fell out and we were able to put traction on it and get down to the origin of the ventricular appendix without any difficulty at all and we had very nice exposure and could look around down there without any difficulty, no bleeding, and it was such a pleasant experience that I don't think that I would consider wedging the thyroid cartilage.

PROLAPSE OF THE LARYNGEAL VENTRICLE

DOUGLAS P. BRYCE, M.D., F.R.C.S. (C)

J. R. CRANSTON, M.D., F.R.C.S. (C)

TORONTO, CANADA

In recent years there has been very little interest shown in the condition of prolapse of the laryngeal ventricle because it is a rare clinical entity and there has been confusion as to the nature of the disease. Erwin Moore,¹ who made the major contribution to the literature on this subject in 1921, was himself in some doubt as to whether or not such a condition did really exist. Since that time, almost nothing new has been added to our knowledge of the subject. Four recent cases in which a diagnosis of ventricular prolapse was made are therefore of current interest and it is hoped that their presentation may serve to clarify the nature and pathogenesis of this benign laryngeal tumor.

Moore's articles¹ on this subject are nostalgic in their frequent reference of famous laryngologists of his time. The term "prolapse" is attributed to Lefferts, of New York, in 1876,² and "eversion of the ventricle" to Moxton,³ of Guy's Hospital, London, 1868. Morel MacKenzie, in 1840,⁴ also wrote on this subject. Many other authors are quoted but their contributions result in confusion chiefly because of the absence of accurate anatomical definition.

Confusion will be avoided if the saccule of the laryngeal ventricle is separated in the discussion from the laryngeal ventricle itself. The saccule may or may not be involved in ventricular displacements but it is frequently the site of laryngoceles and mucocoeles. Saccular lesions are much more common than those involving the ventricle and there is a considerable body of literature with regard to these conditions.

From the Department of Otolaryngology, University of Toronto, Toronto, Canada.

The terms prolapse and eversion referring to the laryngeal ventricle have been used synonymously by some authors and this has led to a great deal of confusion. The term prolapse properly refers to a displacement out or forward whereas eversion is literally a turning inside out. Prolapse of the laryngeal ventricle is a condition of protrusion of the ventricle between the false and true cords so that it becomes visible to laryngoscopy, and is the result of non-specific mechanical or inflammatory causes with hyperplasia of normal structures. It is an isolated lesion and is not directly related to other laryngeal disease.

Eversion of the laryngeal ventricle is a more common condition and it describes a turning inside out or displacement of the mucous membrane of the ventricle by the traction or pulsion of tumors or cysts or deposits in the laryngeal region. It is therefore more of a descriptive term than a clinical entity.

These definitions are somewhat arbitrary but follow Moore's classification. If adhered to they will reduce the confusion which in the past has appeared in the literature.

INCIDENCE

Erwin Moore recorded 85 cases, collected from 1868 to 1921. Holinger,⁶ in a review of 1,190 cases of benign laryngeal tumors, lists ten cases of prolapsed ventricle. New and Erich⁷ reported six cases in a series of 722 benign laryngeal tumors. Almost all the cases reported have been in males and usually in the adult.

ETIOLOGY

Almost all cases of ventricular prolapse are associated with chronic bronchitis, chronic laryngitis or sinusitis. The commonly associated symptoms are cough and hoarseness. It has been suggested that laryngeal trauma is related to this condition. Tuberculosis and syphilis have long been blamed as a cause of laryngeal prolapse but there appears to be little evidence to support this theory, particularly in recent years. In all likelihood chronic laryngitis and bronchitis lead to mucosal edema and hypertrophy and submucosal edema with subsequent fibrosis and some invasion by inflammatory cells. Such a tumor does not differ greatly from nasal polyps but in the gross it is much more firm and neoplastic in appearance.

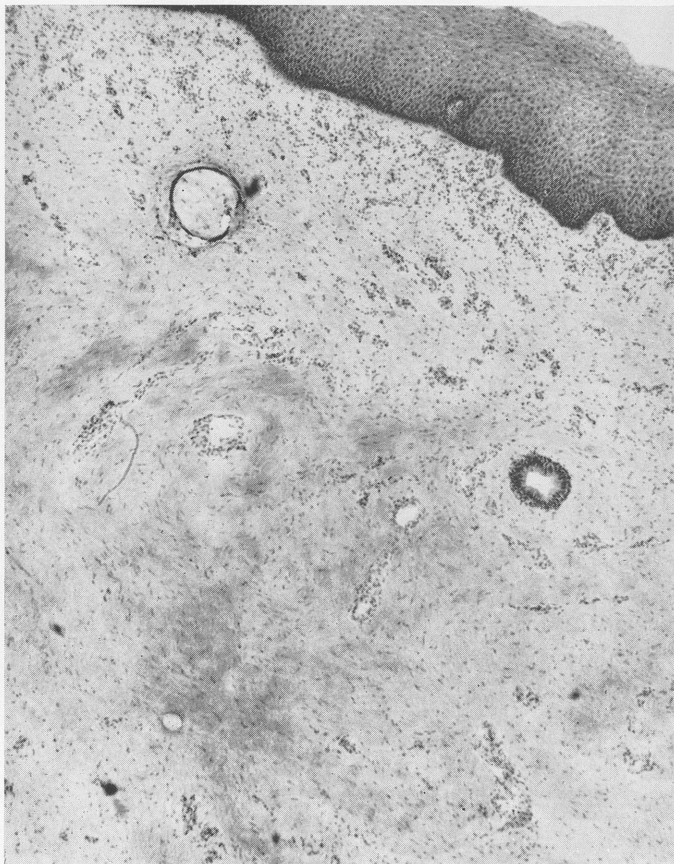


Fig. 1.—Medium power of ventricular mass showing overlying epithelium and the dense hyalinized fibrous stroma.

CLINICAL PICTURE

A history of chronic cough and hoarseness of gradual onset is common. If the prolapse is sufficiently large to interfere with the airway, respiratory stridor may occur. Dysphagia and local or referred pain are uncommon. Laryngoscopy usually provides the diagnosis. The lesion is almost universally unilateral and appears as a pear-shaped, smooth or edematous-looking tumor, sometimes red or greyish pink in color. It protrudes from the ventricle and usually partly or

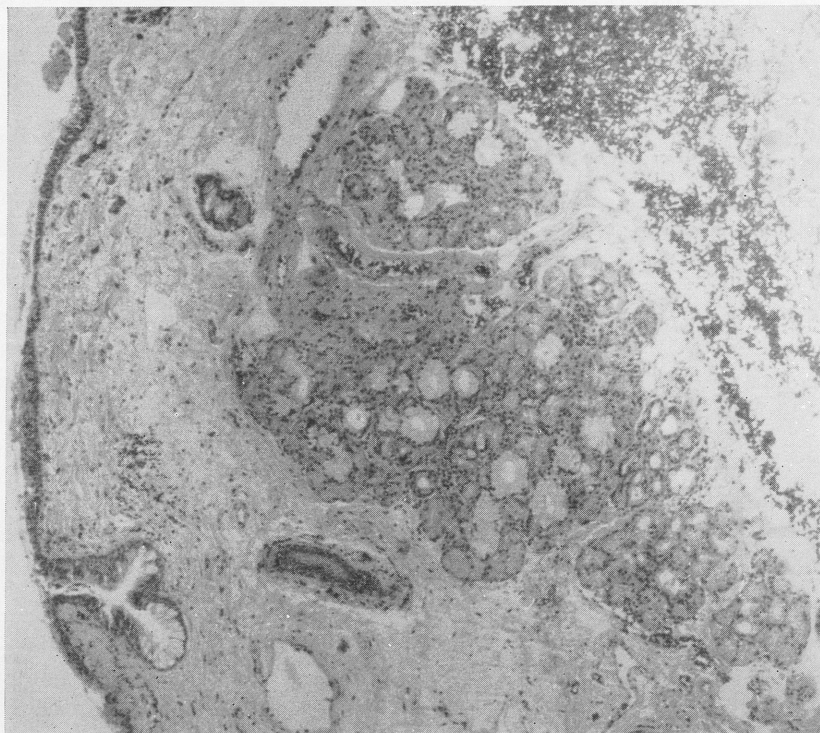


Fig. 2.—The lymphatics are distended and the stroma edematous. The minor salivary glands and ducts are prominent.

entirely covers the true cords. In some cases the ventricular band is grossly enlarged and there is a lack of demarcation between the ventricle and the ventricular band. It may or may not be possible to reduce the prolapse into the ventricle and if so it usually re-appears on coughing or phonations. Ventricular hypertrophy is usually present.

Differentiation from benign tumors of the ventricle may be difficult by laryngoscopic appearance alone. Fibroma, lipoma, fibromyxoma and ventricular cysts may produce a similar picture. Laryngocele is also often confused with prolapse of the laryngeal ventricle, but is usually less firm, and may be deflated with local pressure. X-ray studies will be of assistance in the differential diagnosis of these two conditions. Generally speaking, however, diagnosis requires biopsy

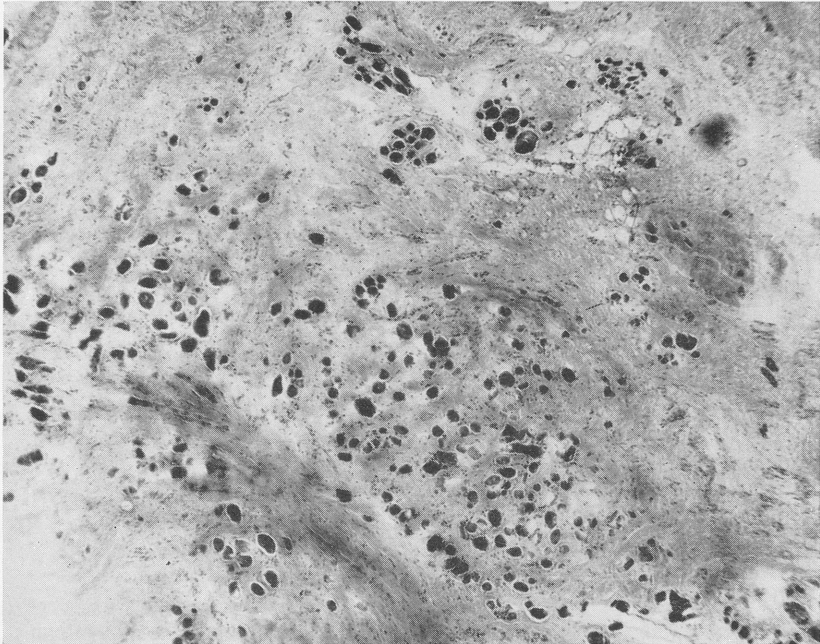


Fig. 3.—Isolated and atrophic muscle fibers within the dense fibrous tissue which forms the bulk of the mass.

and, even so, complete removal of the tumor may be necessary to rule out neoplastic disease.

TREATMENT

A diagnostic procedure only may be necessary unless symptoms are sufficiently severe to require further treatment. Local endoscopic removal with biting forceps, which may be combined with cautery, is probably the treatment of choice. Moore's method of painting with astringent seems less suitable in this present age. Persistent or recurring tumors, however, can be removed completely only by laryngofissure or possibly suspension laryngoscopy.

REPORT OF CASES

CASE 1. Mr. J.L., aged 61, presented with progressive hoarseness of four years' duration and a persistent cough which was non-

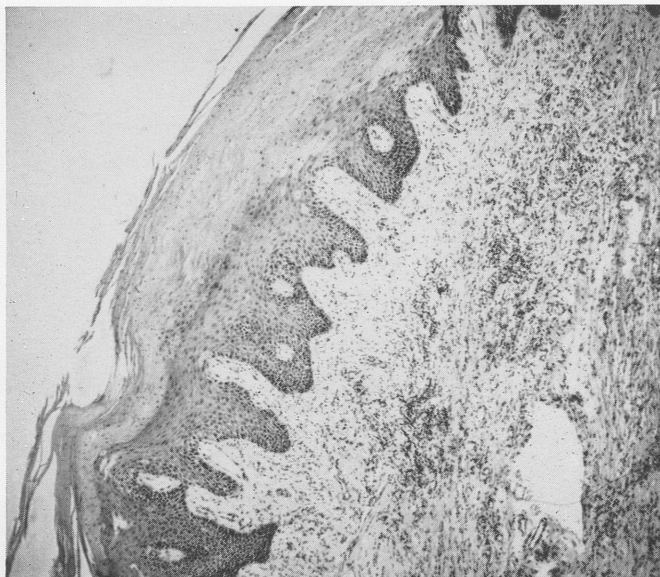

Fig. 4.—Specimen made up of coarse fibrous tissue containing a moderate number of inflammatory cells and covered with squamous epithelium showing a thick layer of parakeratotic cornification.

productive. Laryngoscopic examination revealed a considerable fullness and thickening of the entire left false cord with obliteration of the ventricle by tumor appearing particularly anteriorly. It was possible by direct laryngoscopy to reduce the mass laterally by pressure but this readily recurred. Adequate biopsies were taken of the tumor and the result was non-specific, so that a laryngofissure was performed and part of the left false cord and the tumor were removed totally. The pathologist reported extensive fibrosis in which a few normal looking seromucinous glands were imbedded. No other neoplastic tissue was seen (Fig. 1).

CASE 2. Mr. J.G., aged 28, presented with a chief complaint of extreme huskiness which was sufficient to interfere with his employment. His huskiness began following a hockey stick injury to his larynx three years prior to admission. Chronic sinus infection preceded his injury and for this a radical antrostomy was done. Numerous biopsies of the larynx failed to establish a diagnosis so that a laryngofissure was done with the partial removal of a benign ven-

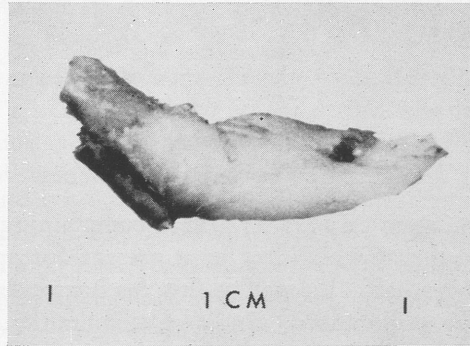


Fig. 5.—Gross specimen removed from the laryngeal ventricle of Case 4.

tricular tumor. Following this procedure the huskiness was not improved and in fact became steadily worse over the next year leading to his present admission.

Laryngeal examination revealed a smooth bulging mass protruding from the right ventricle and extending along the entire length of the false cord. A laryngogram was reported as revealing asymmetry in the right false cord without evidence of laryngocele. Biopsy was nonspecific and therefore a laryngofissure was again performed and a very large, irregular, firm tumor was found to occupy the ventricle and part of the false cord. This was removed along with the major portion of the false cord. The pathologists reported the specimen to consist of firm, dense scar tissue, cystic dilatation of submucosal glands and some chronic inflammatory cells (Figs. 2 and 3).

CASE 3. Mr. M.N., aged 54, had a previous hospital admission for investigation of hemoptysis. No diagnosis was made at that time except that of chronic bronchitis. He remained well except for a two months' episode of hoarseness which interfered with his employment.

Laryngoscopic examination revealed a firm tumor, occupying the right ventricle, particularly anteriorly, and protruding across the laryngeal aperture, preventing approximation of the vocal cords. A laryngofissure was performed and the tumor was removed along with a portion of the false cords. Once more the pathological specimen consisted of minor salivary glands and edematous connective tissue.

A transitional type of epithelium partially covered this lesion but gave way to stratified squamous epithelium, in areas showing papillomatous redundancy (Fig. 4).

CASE 4. Mr. S.S., a 45 year old man, was seen in an out-patient clinic in 1953, at which time it was felt that he had a prolapse of his right laryngeal ventricle. No further investigation was deemed necessary at that time as the symptoms of hoarseness were minimal.

He was seen again on May 31, 1965, complaining of a sensation of a lump in his throat which had been present for approximately a year to a year and a half. As well as this, his hoarseness had persisted and become more pronounced. Indirect examination of the larynx revealed a protrusion from the right laryngeal ventricle suggestive of a laryngeal polyp or ventricular prolapse. The physical examination revealed mild hypertension, chronic bronchitis and mild emphysema with a poor chest expansion and basal rales.

In June of 1965, a laryngoscopy was done revealing hypertrophy of the ventricular folds with a tumor in the right ventricle preventing good apposition of the vocal cords. A biopsy of this tumor was reported as negative for neoplasia. Because of this a laryngofissure was done two weeks later and a tumor was removed from the posterior two thirds of the laryngeal ventricle (Fig. 5).

The tissue was made up of fairly coarse fibrous tissue containing moderate numbers of inflammatory cells and was covered with squamous epithelium showing a thick layer of parakeratotic cornification. The postoperative course was uneventful and the patient's hoarseness has slowly improved.

We have reviewed the clinical course of four patients, each of whom presented with a severe degree of persistent hoarseness due to a unilateral tumor presenting from the laryngeal ventricle. Each of the patients had, in addition, upper respiratory disease with cough. In one case there was a possible contributing history of laryngeal trauma and sinusitis.

In all four, despite adequate biopsy, no tissue diagnosis could be made and laryngofissure was necessary for complete removal of the tumor. In Case 2, previous inadequate removal of the prolapse resulted in recurrence of the tumor which increased considerably in size in the interval. Its complete removal later necessitated almost a hemilaryngectomy and further surgery will be necessary to restore a good voice. All cases have now been over a year postoperative and

there has been no recurrence in any. In all but one, the restoration of good voice, however, has not been satisfactorily accomplished.

COMMENT

It has been our purpose to show that the clinical entity of ventricular prolapse does exist and may be more commonly seen than diagnosed. It is a nonspecific, irritative phenomenon, associated with hypertrophy and edema of the ventricular constituents in a manner similar to the production of nasal polyps but with a production of a much more dense tumor. It is associated with generalized inflammation of respiratory epithelium as evidenced by its frequent association with chronic bronchitis, and sinusitis.

The diagnosis of prolapse is based on the clinical history and physical findings but will probably also require the evidence supplied by tissue biopsy. Radiographic studies will help to rule out laryngoceles and more extensive soft tissue tumors. The chronic granulomas of tuberculosis and syphilis and the infiltrates seen in leukemia may be distinguished on occasion by other clinical studies.

The treatment of prolapse of the laryngeal ventricle should be conservative if a firm diagnosis of this condition can be established. It is important, however, that all the tumor be removed as in our meager experience recurrence will otherwise result, and laryngeal function may eventually be seriously interfered with.

CONCLUSIONS

Four cases of laryngeal ventricular prolapse have been presented. The clinical aspects of this condition were described and the methods of treatment discussed. It appears that a definite clinical entity of prolapse of the laryngeal ventricle exists and may require more frequent recognition.

UNIVERSITY OF TORONTO

ACKNOWLEDGEMENTS—The authors wish to express their appreciation for the assistance of Dr. W. Anderson, Dr. T. C. Brown and Dr. H. J. Barrie in the preparation of the pathological specimens and illustrations.

REFERENCES

1. Moore, I.: *Jour. of Laryngol.* 26:11:49, 1921, and 37:265, 1922.
2. A.M.A. *Arch. of Otolaryng.* 28:841, 1938: Lefferts, George M. (New York): A Unique Cure of Prolapse of Both Ventricles of the Larynx. Their Removal by Thyrotomy: Cure. *New York Med. Rec.* 10:1:359, 1876.

3. Moxon, Walter (Guy's Hospital): Care of Eversion of Sacculus Laryngis. *Trans. Path. Soc.*, London, 19:65, 1868.
4. Mackenzie, Morell: Growths in the Larynx. *Land* 34:35, 1871. *Dis. of Throat and Nose* 1:310-404, 1880.
5. Holinger, P. H.: Treatment of Benign Tumors of the Larynx. In: Pack, G. T., and Ariel, J. M. (Editors): *Treatment of Cancer and Allied Diseases*. 2nd Ed., Vol. 3, p. 484, 1959.
6. New, G. B., and Erich, J. B.: Benign Tumors of the Larynx. A Study of 722 Cases. *A.M.A. Arch. Otolaryngol.* 28:841, 1938.

DISCUSSION

DR. JOHN E. BORDLEY: I wanted to ask him if he could tell us a little bit more about the actual technique that he employed in the removal of these tumors.

DR. JEROME A. HILGER: A few points of clarification, please, Dr. Bryce:

Is this a tumor? Can it be removed completely? What is the origin of the pathology in your mind? Is it reasonable in many instances to leave the lesion alone and do nothing but observe it?

DR. FRANCIS L. LEDERER: Perhaps what I have got to say represents antiquity but certainly all of you have had to do with tuberculosis and while respiratory disease was mentioned, this specific area was not.

I know that one of the definite pictures that is presented in tuberculosis of the larynx is a prolapse. The nature of the prolapse is infiltration. It can present itself almost as a tumor. I do not wish to get into the semantics that clouded the issue in 1921 or thereabouts, but certainly this can occur and under current management these would not result in surgical resections, these would be amenable to modern therapy.

Perhaps we carried on improperly in calling this a prolapse of the laryngeal ventricle, but it was, and I hope now that Dr. Bryce has gone into this subject—and certainly he should make no apologies for doing so, because you can dig up things of ancient vintage and be quite modern with it if you dress it up with modern audio-visual accessories.

DR. JOSEPH P. ATKINS: I would like to ask Dr. Bryce if this condition occurs in patients who are heavy cigarette smokers and whether or not there is any relationship between this condition and that condition of the vocal cords which we sometimes call polypoid degeneration of the cords. I have the feeling that sometimes something like this originates from the upper surface of the vocal cord rather than from its usual position on the phonating surface of the vocal cord.

DR. W. FRANKLIN KEIM: I would like to ask you whether you feel—and perhaps this should be addressed both to you and to Dr. Holinger—that the Holinger resectoscope might have any part in the treatment of this condition once you are sure of the diagnosis.

DR. BRYCE (closing): Dr. Bordley, the technique that we used to remove these tumors was a simple laryngofissure or pharyngotomy and when the larynx was opened the tumor was found to lie in the ventricle so that the differentiation between the false cord and the ventricle could not be seen. You could palpate it, it was firm, it could not be retracted out of position, as is often described in the case

of laryngeal prolapse, and all four cases—and I have neglected some of the details for this discussion—all four cases were almost identical.

There is one point, however, I might mention, which comes with regard to Dr. Atkins also, that in every case, or almost every case, there was hypertrophy of the false vocal cords along with this tumor though not forming part of the tumor.

The technique of removal was merely to grossly remove the tumor, which was not encapsulated.

The question, is it a tumor? Yes, it is a definite tumor, in my opinion, but it is not neoplastic.

Of course, if the diagnosis can be made, these tumors need not be removed unless they are causing symptoms of sufficient seriousness to warrant such a procedure.

As far as tuberculosis is concerned, the literature is full of references to this tumor being the result of tuberculosis or specific disease and again you must split hairs here. If we are going to talk about a tuberculous or syphilitic tumor, then it is no longer what I call a prolapse. This becomes an eversion secondary to a specific disease in the larynx.

As far as the heavy cigarette smokers, I am afraid that four cases is not sufficient, in my experience, to make any comment. They all were cigarette smokers. The recent literature, as I recall it, and the past literature, does not bring this point out. I don't know.

I asked Dr. Holinger if I might read a letter from Dr. John Kirchner, who kindly wrote me to say that he couldn't be at this meeting but sent two slides. I will read you the letter. I think that this is a nice time to do this, seeing that Dr. Kirchner received a Society Award just the other day. He says:

"I am unable to come. I am enclosing two slides which you may use as you wish."

And he goes on to say:

"Laryngeal ventricular prolapse occurs regularly in brachycephalic dogs."

Fortunately he explains this as the English bulldog, pugs, et cetera.

"It results from inspiratory resistance in the nostrils and palatal arch and can be corrected by excising part of the soft palate and widening the nostril. A local veterinarian is quite well known nationally for having devised a cure for this condition in dogs. It is often fatal, as is shown by the enclosed slides."

(Slide) This is his picture of the larynx of one of the dogs to which he refers and the forceps is on the tumor described.

(Slide) This is a picture of the trachea from the dog, which also tends apparently to collapse and may be something to do with the fatal nature of the disease.

I am sure that conservative surgical removal is the method of choice if a diagnosis can be made. Adequate removal is essential, however, as in one of our cases the tumor recurred and ultimately required a much more radical procedure for its removal.

Memorials

ROY ALEXANDER BARLOW, M.D.

1886 - 1965

Dr. Roy A. Barlow, an Emeritus Fellow of the American Laryngological Association, was elected to Active Fellowship in 1923 and Emeritus Fellowship in 1941. He was born in Rochester, New York and died in Musquodoboit Harbor, Nova Scotia, on September 29, 1965 at the age of 79.

Dr. Barlow spent his boyhood in Rochester, New York and graduated from the University of Rochester in 1911. His medical degree was earned at the University of Michigan, Ann Arbor, Michigan, and in 1916 he left Ann Arbor to join the staff of the Mayo Clinic in Rochester, Minnesota. From there, he went to the Jackson Clinic in Madison, Wisconsin, where he received an appointment on the teaching staff of the University of Wisconsin.

Upon returning to Rochester in 1928, he married Dr. Doris Murray, a pediatrician, and the couple went to Berryville, West Virginia in 1940 to practice. They moved to Nova Scotia in 1950 to continue practice there.

Dr. Barlow was a 33rd Degree Mason, and although he practiced in several different locations and moved frequently he was considered a competent and unusual otolaryngologist by the men who knew him. He did not attend many medical meetings.

He leaves his wife, two sons, Dr. Craig Barlow, an obstetrician in Ann Arbor, Michigan, and Captain Charles Barlow of the Merchant Marine in Honolulu, Hawaii, and seven grandchildren.

F.J.P.

FRED WILLIS DIXON, M.D.

1888 - 1966

Dr. Fred Dixon was born in Mahoningtown, Pennsylvania, on November 18, 1888. He studied medicine at the University of Pennsylvania. After graduating from Medical school he did General Practice in Leetonia, Ohio for a short time. He then entered the New York Eye and Ear Infirmary for his resident training in Otolaryngology. He did postgraduate study in Vienna. He came to Cleveland in 1922 and began the practice of Otolaryngology. He was appointed to the Otolaryngological staff of Western Reserve University's School of Medicine.

Fred Dixon received many honors in medicine. He was past president of the Ohio Medical Association, the American Broncho-Esophagological Association and Treasurer of the Sixth International Congress of Otolaryngology. He served on the Board of Governors of the American College of Surgeons for twelve years. He was a member and past vice-president of the Academy of Ophthalmology and Otolaryngology. He was treasurer and president of the American Laryngological Association and was given the Newcomb Award in 1964. Of all the medical societies the American Laryngological Association was closest to his heart.

Dr. Dixon suffered a slight stroke which necessitated his retiring from active practice. However, he continued his interest in medicine.

He attended a meeting of the Cleveland Otolaryngological Club two days before his fatal heart attack.

Fred had several outside interests. He was a collector of fine antique silver. Some of these pieces would be a welcome addition to any museum. Fred Dixon was an extensive traveler and there were few places on the globe he had not visited. He was an able after-dinner speaker. His dry humor and ready wit were infectious.



FRED WILLIS DIXON

Fred was never too busy to help a younger medical man prepare a thesis or write a paper.

He is survived by his devoted wife, Marie; a brother, Dr. George Dixon, a dentist; and a sister, Mrs. John D. Kyle of New Castle, Pennsylvania.

Fred Dixon will long be remembered by his many friends and patients.

J.W.M.

FRED Z. HAVENS

1890 - 1965

Dr. Fred Z. Havens, consultant in plastic surgery and laryngology at the Mayo Clinic and associate professor of laryngology in the Mayo Graduate School of Medicine of the University of Minnesota at Rochester, Minnesota, died in Rochester on Thursday, July 29, 1965, after a three-day illness.

Born in Hallville, Illinois, on January 22, 1890, Dr. Havens received the degree of bachelor of science in 1912 from Drake University and that of doctor of medicine in 1915 from the Rush Medical College of the University of Chicago. After an internship in St. Luke's Hospital, Chicago, in 1915, he began a general practice of medicine in Michigan and later in Wisconsin. - In 1926 he entered the Mayo Graduate School of Medicine as a fellow in otolaryngology and three years later was appointed to the permanent staff of the Mayo Clinic.

He became a member of numerous professional organizations, including the American Laryngological Association, the American Academy of Ophthalmology and Otolaryngology, the American Laryngological, Rhinological and Otological Society, the American Association of Plastic Surgeons, the American Society of Plastic and Reconstructive Surgeons and the Society of Sigma Xi.

Dr. Havens was an exceedingly skillful surgeon, especially resourceful in laryngology. He was one of the first to show that the larynx can be removed more easily and with fewer postoperative sequelae in a single operation than in a two-stage procedure. He developed or modified several plastic surgical techniques, particularly as they applied to such defects as cleft palate and hypospadias. In 1965 he was one of 18 Minnesota physicians honored by the Minnesota State Medical Association for their attainment of 50 years of practice.

A mild-mannered person with an amiable personality, Dr. Havens was particularly responsive to the afflictions of others, and he was genuinely interested in the welfare of struggling young physicians. He was an able teacher who could convey his knowledge to



FRED Z. HAVENS

others with more than ordinary clarity. Many former residents of the Mayo Graduate School of Medicine will long remember him for his friendliness and guidance during their three-year periods of graduate training.

In Dr. Havens' passing surgeons in otolaryngology and plastic surgery alike have lost a sincere and friendly colleague who did much to advance the status of these specialties.

J.B.E.

DUNCAN MACPHERSON, M.D.

1872 - 1964

Dr. Duncan MacPherson died at the Dresden Nursing Home, New York City, after a lingering illness. He had fallen and broken his hip almost a year previously.

Dr. MacPherson had been in relatively good health up to the occasion of his fall, although for the past seven years due to sensitivity in respect to his poor hearing, and a facial paralysis secondary to a "glomus jugulare" tumor, he had not attended the medical meetings which he enjoyed so much.


Born in River Beaudette, Quebec, he received his preliminary education under private tutors and his medical degree from McGill in 1896. Following graduation he came to New York City, first receiving an appointment as clinical assistant at Manhattan Eye & Ear Hospital. In 1912 he was promoted to Junior Surgeon at Manhattan Eye & Ear and Associate Professor in Otology at New York Post Graduate Medical School.

From 1915 to 1932 he was Professor and Director of Laryngology at Post Graduate, and from 1932 to his resignation in 1935 he was Professor and Director of both Otology and Laryngology at the same institution.

Dr. MacPherson was consultant to a number of hospitals, among them: Manhattan Eye & Ear, Bronx Eye & Ear, Mid Town Hospital, West Side Hospital, Englewood Hospital, and Elizabeth Hunter Hospital, Middletown, N.Y.

He was a Fellow of N. Y. Academy of Medicine, American College of Surgeons, International College of Surgeons (Regent of U.S. Section in Otolaryngology 1941-43), American Laryngological Society, American Laryngological, Rhinological and Otolological Society, American Academy of Ophthalmology and Otolaryngology, N. Y. Laryngological (president 1929), and N. Y. Otological (president 1933-35).

In 1951 he was chosen by its President, Dr. Clerf, to be Guest of Honor at the Triological Society Meeting.



DUNCAN MacPHERSON

During World War I, he served as captain in the Canadian Army Medical Corps in France.

As Director of Otolaryngology at N. Y. Post Graduate Hospital and Medical School, he was concerned and active in post graduate study in otolaryngology. Never one to take part in formal presentations, he was active in the quorums where free discussions took place and policies were formulated.

His clubs were the Englewood Golf Club and the Union League.

He was a member of the Canadian Society (serving in the capacity of secretary and later as vice-president and chairman of the Board of Trustees), Valentine Mott Society, St. Andrew Society of N. Y. (vice-president), Canadian Legion of New York, Burns Society, and British Schools and Universities.

One cannot express the respect in which his knowledge, judgment and integrity were held both by his associates in the medical profession and by his patients.

W.A.N.

ARTHUR WALTER PROETZ, M.D.

1888 - 1966

Dr. Arthur Walter Proetz died in the Barnes Hospital, St. Louis, Missouri on January 31, 1966. He had been in failing health for some time. A memorial service for him was held at the Washington University Auditorium on February 19th.

Dr. Proetz was born October 12, 1888 in St. Louis, the son of William H. and Laura Kriekhaus Proetz, members of an old St. Louis family of German origin. After attending public schools in St. Louis, he graduated from Washington University in 1910 with the degree of A.B. He then enrolled in the Washington University School of Medicine, graduating with the degree of M.D. in 1912. After serving an internship at the St. Louis City Hospital he began the study of Oto-laryngology under Drs. Greenfield Sluder and John B. Shapleigh at Washington University.

His graduate education was interrupted by World War I when he served with Base Hospital 21 in France as 1st Lieut., Medical Corps, U.S. Army in 1917, Captain, 1918. After the cessation of hostilities he acted as Consultant in Oto-laryngology to the Veterans Administration. He took further postgraduate work with Dr. Chevalier Jackson at the University of Pennsylvania in 1922.

On his return to St. Louis he began his career of clinical practice, teaching and research in his chosen specialty, which brought him national and international recognition and contributed greatly to his native city's reputation as a leading medical center. He was on the Oto-laryngological Staffs of the Barnes, the McMillan, the St. Louis Children's, the Beaumont, the Jewish, St. Luke's and the St. Louis City Hospitals as either attending surgeon or consultant, until his retirement.

His teaching appointments were at his own medical school of Washington University where he served in the Department of Oto-laryngology, first as Assistant in 1919, culminating in his becoming Professor of Clinical Oto-laryngology from 1936 to 1954, when he became Professor Emeritus.

From 1951 to 1953 he served as consultant to the United States Air Force, and in 1956 and 1957 he was consultant to the Surgeon General, travelling extensively to various bases overseas. In 1950 Colby College honored him with the degree of Doctor of Science.

He was a member of the American Medical Association and Chairman of the Section on Otolaryngology in 1939; a Fellow of the American Laryngological Association in 1924; Secretary, 1943 to 1948, and President, 1948 to 1949. He was a member of the American Otological Society; the American Laryngological, Rhinological and Otological Society; Chairman of the Mid-western Section in 1934; the American Broncho-esophagological Association; the American Academy of Ophthalmology and Otolaryngology; of which he was 1st Vice-President in 1940; the American College of Surgeons; the St. Louis Nose and Throat Club; and the Collegium Oto-rhinolaryngologicum Amicitiae Sacrum.

He was awarded the Casselberry Prize of the American Laryngological Association in 1931 and the DeRoaldes Medal, the Association's highest award, in 1951. In 1952 he was the recipient of the Sir Felix Semon Medal, on the occasion of his Felix Semon Lecture at the University of London, in 1952, the second time this honor had come to an American.

He became one of the first associates of the American Board of Otolaryngology and served as its President from 1949 to 1950. He was Editor of the *Annals of Otology, Rhinology, and Laryngology* from 1928 to his death this year.

He was an Honorary Fellow of the Pacific Coast Oto-Ophthalmological Society, the Dallas, Kansas City, Cleveland, and Buenos Aires Otolaryngological Associations, as well as the similar associations of Argentine, Chile, and Peru. He was a Corresponding Fellow of the Oto-rhino-laryngological Society of Greece.

His keen inquiring mind early led him into Research, largely in the field of Nasal Physiology, about which too little was known, at that time. He was able to disprove many misconceptions previously accepted and point to more rational methods and procedures. His studies on cytology and pathology of nasal tissues have gained universal acceptance. This shortly led into the field of air-conditioning and the effect of cigarette smoking on nasal mucous membranes.



ARTHUR WALTER PROETZ

Dr. Proetz belonged to the following fraternities: Sigma Chi, Nu Sigma Nu, Alpha Omega Alpha, Sigma Xi, as well as the University Club of St. Louis.

On the evening of January 23, 1957, to commemorate his retirement, his confreres in St. Louis tendered him a testimonial dinner. This was a wonderful affair which the writer of these lines will never forget, especially as he was privileged to be present on that occasion. This event, honoring Arthur Proetz and his accomplishments, could not help but be one of the highlights of his career.

But although he figuratively retired in 1957, actually that meant only retirement from active practice. He still continued his editorship of the *Annals*, his attendance at the meetings of our National societies, and his own research in his laboratory at his home at 12 Westmoreland Place.

In 1957 the Sixth International Congress of Oto-laryngology was held in this Country in Washington, D. C. In the planning for this event and its organization, Dr. Proetz was the unanimous choice for President. All details were carefully studied and assigned to the proper individuals and the Congress went on without a hitch. To many, the high point was his Presidential Address. Not only was it scholarly and beautifully delivered, but, what to our foreign visitors unaccustomed to even bilingual abilities in us Americans, our President, after speaking in English, without the slightest hesitation continued in German, then in French, and finally in Spanish. This was an accomplishment rare among our own confreres.

He was a most prolific writer, always contributing articles of value indicative of his keen thinking and practical approach to any problem. He was in great demand as a lecturer and teacher, appearing on programs of our leading special societies, as well as participating in post-graduate programs throughout the world.

While Medicine, particularly Oto-laryngology, was the main interest throughout his life, Dr. Proetz was a man of many talents. He was an ardent photographer and one or more cameras always accompanied him on his travels. In this field he was especially expert. He was Director and Associate Editor of the Biological Photographic Association and he published numerous papers on photography. His other hobbies were Music, Art, and Drama. He played both the piano and the organ. Often on returning home from the theater he would sit at the piano and play certain of the musical numbers from memory,

music he had never heard before. In his younger days he composed the scores for four musical productions for the Quadrangle Club at Washington University of which he was one of the founders.

One of his last writings was a nostalgic story of his early boyhood life in St. Louis. This started as a series of stories in the St. Louis Post-Dispatch but later was published under the title, "I Remember You, St. Louis." This is beautifully done, adequately illustrated by photographs of persons and places of those early days, a tribute to his city which he loved.

In politics he was a Republican. Of religious affiliations he professed none, yet in truth no man had higher ideals or lived up to them more than he. No man was a more devoted seeker after truth.

He married Erma Bird Perham November 29, 1918, a boyhood sweetheart, who died August 7, 1944. He married Esther Schroepfer on December 31, 1946. This proved to be a most happy event for both people. She had been associated with Dr. Proetz as Secretary and Assistant for 18 years and was keenly interested in all his work, his writing, his research, and his editorship of the Annals, and contributed more than we will ever know towards making his life a happy one to his last days.

He was a very sincere person with high ideals which he would never compromise. He had no respect for those who did not measure up in practice to what they professed, either in scientific literature or in research. He could not countenance dishonesty or hypocrisy. He was always loyal to his teachers and predecessors. He always gave credit where credit was due and often was the first to recognize the hidden talents in younger men. He was a firm friend, a delightful companion with always a keen sense of humor.

His passing will be mourned by many people throughout the world. The loss to Medicine and especially to Otolaryngology, and this Association, cannot be measured.

F.W.H.

EDWARD JOSEPH WHALEN, M.D.

1886 - 1965

Doctor Edward J. Whalen died at St. Francis Hospital, Hartford, Connecticut, on August 30, 1965.

Born in Northampton, Massachusetts, Doctor Whalen was a graduate of Yale University School of Medicine, Class of 1908. He interned at St. Francis Hospital from 1908 to 1909 and after several years of general practice, took residency training in Otolaryngology at the Brooklyn Eye and Ear Hospital from 1915 to 1916. In the first World War, Doctor Whalen's tour of duty included service for one year as Chief Otolaryngologist of Base Hospital No. 49 in France from 1918 to 1919. On returning from the Armed Forces, he again set up practice in Otolaryngology in Hartford.

Doctor Whalen was a member of the American Medical Association, the American College of Surgeons, and a Diplomate of the American Board of Otolaryngology. His specialty societies included the American Academy of Ophthalmology and Otolaryngology, the American Laryngological Society, and the American Broncho-esophagological Society. He served as President of the Hartford Medical Society in 1938, the Hartford County Medical Association in 1943, and the Connecticut State Medical Society in 1952. He was Vice-President of the American Laryngological, Rhinological and Otolaryngological Society in 1942 and President of the New England Otolaryngological Society in 1944. He was Consultant in Otolaryngology to St. Francis Hospital, McCook Memorial Hospital, Hartford Hospital, Institute of Living, Cedarcrest Hospital, Charlotte Hungerford Hospital, Manchester Memorial Hospital and Veterans' Home and Hospital.

The list of the many professional societies to which Doctor Whalen belonged is an indication of his strong interest and dedication to medicine. The positions of honor to which he was elected are a reflection of the esteem in which he was held by his colleagues. However, none of these professional associations or election honors can truly mirror the homage which he received from the medical fraternity and his patients. The respect that was accorded him came not



EDWARD JOSEPH WHALEN

only from his medical knowledge, but his appreciation of the patient as an individual. He had the rare attribute of being a good listener, but also the ability to give a proper judgment when his opinion was sought.

Because of his pioneer efforts Dr. Whalen was acknowledged as the Father of Broncho-esophagology in Connecticut. His intense interest, especially in foreign bodies of the esophagus and bronchus stimulated him to devise and modify many instruments used in this specialized field. Until ill health restricted his activities Dr. Whalen could always be counted on as a companion to attend the sectional and national meetings of our otolaryngological societies. Although he was basically a shy, retiring individual he never hesitated to express his opinions when his counsel was sought. He had a sympathetic ear, especially for the younger men, who had a problem to solve or wished to project a new idea in the treatment of some ear, nose and throat pathology.

Despite his diminishing activity in the past few years he maintained a keen interest in the development of his specialty. Although he insisted that one should never forget the accomplishments of the past he acknowledged the newer innovations long before they were accepted by many of his colleagues. Dr. Whalen received many accolades during his long lifetime, but his greatest rewards came from his association with the many friends in his profession to which he was truly dedicated.

T.L.C.

Executive Sessions

EXECUTIVE SESSION

SATURDAY MORNING, APRIL 23, 1966

The Opening Session of the Eighty-seventh Annual Meeting of the American Laryngological Association, held at the Americana Hotel, San Juan, Puerto Rico, convened in the Arecibo Room on Saturday morning, April 23, 1966, at eight-twenty o'clock, Paul H. Holinger, M.D., Chicago, Illinois, President of the Association, presiding. The meeting opened in Executive Session.

PRESIDENT HOLINGER: The first order of business is the election of the candidates. The following men were elected:

Active Fellowship:

Dr. Kenneth Devine

Dr. John Lewis

Dr. Brian McCabe

Emeritus Fellowship:

Dr. Paul Campbell

Dr. Bernard McMahon

Dr. Walter Theobald

Honorary Fellowship:

Dr. Jo Ono, of Tokyo, who at the present time is a
corresponding member

Corresponding Fellowship:

Dr. Gosta Dohlman, of Sweden, South America, North
America, and Canada.

The next order of business is the election of the Nominating Committee and we will entertain nominations for the Nominating Committee.

The following were then elected after nomination from the floor:

Walter Theobald, M.D.

Paul Moore, M.D.

Daniel Baker, M.D.

Verling Hart, M.D.

George Sisson, M.D.

The next order of business is the introduction of the newly elected Active Fellows.

(The newly elected Active Fellows were escorted to the platform by their sponsors.)

You gentlemen are initiated and introduced into what I consider and many consider our foremost society in otolaryngology in this country. You have a charge, you have a responsibility, you have privileges, which go with Fellowship and I feel that you are obligated to carry these out. These are obligations which I hope you will enjoy—and I am sure you will. It should be active participation in the Association, in its scientific work, scientific presentations, the responsibilities of helping in the administrative attitudes and aspects of the Association and I know that all of you will be very willing and able to assist in these responsibilities as well as the privileges that go with Fellowship.

I am sorry Dr. Devine is not here, but the remarks do go to the three of you as well as to Professor Dohlman and Dr. Jo Ono, who has been elected to Honorary Fellowship, but as far as the Active candidates, and now initiates, are concerned, there are three out of ten of you—ten who were proposed for Fellowship this year. This leaves us with a very difficult problem. All ten were excellent men. There is a tremendous limitation on our Fellowship. The Fellowship is limited to one hundred, as you know. We have the possibility that we might increase this total in view of the exploding population situation, of course, and furthermore the exploding interest and tremendous enthusiasm with otolaryngology. Are we still justified in keeping this membership list to one hundred Fellows?

Three were elevated to Emeritus Fellowship this year, as you can see by the ballot: Dr. Theobald, Dr. McMahon and Dr. Campbell, and there is a rule in the Association that a Fellow may request elec-

tion to Emeritus status if he has been a member of the Association for twenty years and if he is sixty years or older. Some of them can and have retired from their academic positions as well as from their active practice and contributions to the Association, so that the Council is suggesting—and this will have to follow through the routine and the usual part of notifying the membership and getting your opinions on it—that this rule be changed to provide that anyone seventy years or older will automatically receive Emeritus Fellowship, in order to make possible the introduction of more Active people, who should carry on the flag in this specialty in this Association. For this reason we are proposing, or suggesting, that this rule be changed and we hope that your enthusiastic support in this change will make it possible for us to introduce new members in place of those who have served so well for a long time but are still maintained on the Active list simply because of the fact that they have not been Fellows of the Association for twenty years or more.

ANNUAL BUSINESS MEETING

SUNDAY MORNING, APRIL 24, 1966

The meeting reconvened in the Arecibo Room for the Annual Business Meeting of the Association on Sunday morning, April 24, 1966, at eight-twenty o'clock, President Holinger presiding.

REPORT OF THE SECRETARY

The Eighty-sixth Annual Meeting of the American Laryngological Association was held on May 23 and 24, 1965, at Hotel Broadmoor, Colorado Springs, Colorado. The President, Dr. Albert C. Furstenberg, presided. A Scientific program of twelve papers was presented. Seventy-one Fellows and seventy-six guests attended.

The Newcomb Award was presented to Dr. Edwin N. Broyles.

The following were elected to Fellowship:

Active Fellowship:

James T. King, M.D., Atlanta, Georgia

John S. Knight, M.D., Kansas City, Mo.

Richard W. Hanckel, M.D., Charleston, South Carolina

Daniel Miller, M.D., Boston, Massachusetts

Emeritus Fellowship:

Norton C. Canfield, M.D., St. Croix, Virgin Islands

W. Likely Simpson, M.D., Memphis, Tenn.

Oliver O. Van Alyea, M.D., Boston, Massachusetts

The following officers were elected for the coming year:

President: Dr. Paul H. Holinger

First Vice-President: Dr. Carlos E. Munoz-MacCormick

Second Vice-President: Dr. Arthur Cracovaner

Secretary: Dr. Lyman G. Richards

Treasurer: Dr. Alden H. Miller

Editor, Historian, Librarian: Dr. F. Johnson Putney

First Councilor: Dr. Dean M. Lierle

Second Councilor: Dr. Francis E. LeJeune

Third Councilor: Dr. Anderson C. Hilding

Fourth Councilor: Dr. Albert C. Furstenberg

The next Annual Meeting of the Association will be held at the Seignory Club, Monte Bello, Canada, on May 15 and 16, 1967. This will be followed on May 17 and 18 by the meeting of the American Otological Society. The meetings of the Triological Society, the American Broncho-Esophagological Association and the Society of Head and Neck Surgery will be held at the Queen Elizabeth Hotel in Montreal, Canada, May 21-24, 1967.

Since the last Annual Meeting of the Association the following have been lost through death:

Dr. Fred Z. Havens, an Emeritus Fellow since 1957,
who died on July 29, 1965

Dr. Roy A. Barlow, an Emeritus Fellow since 1941,
who died September 29, 1965

Dr. Edward J. Whalen, an Emeritus Fellow since 1963,
who died August 30, 1965

Dr. K. Faarborg-Anderson, a Corresponding Fellow since
1957, who died October 21, 1965

Dr. Arthur W. Proetz, an Honorary Fellow since 1957,
who died January 31, 1966

Dr. Fred Dixon, an Emeritus Fellow since 1964,
who died April 11, 1966

Dr. Duncan McPherson died in August, 1965.

The Fellowship of the Association as of April 1, 1966 is as follows: Active, 98; Emeritus, 26; Corresponding, 15; Honorary, 4. Total: 143.

Respectfully submitted,

Lyman G. Richards, M.D., Secretary

(The Secretary's report was accepted as read.)

REPORT OF THE TREASURER

*Exhibit A*AMERICAN LARYNGOLOGICAL ASSOCIATION
GENERAL FUND OPERATING STATEMENT

For the Year Ended March 31, 1966

Income

Dues:

Ninety-six (96) members at \$75.00	\$7,200.00	
Four (4) new members at \$115.00	460.00	\$7,660.00
Sales of <i>Transactions</i>	557.00	
Interest received—Savings account	562.50	
Registration fees—Annual meeting	430.00	\$ 9,209.60

Expenses

Annual meeting—1965:

Banquet and cocktails	\$1,318.52	
Speaker	300.00	
Projectionist	172.50	
Reporting service	514.38	\$2,305.40

Council expenses (travel, room rental and

luncheon)	1,336.27	
Loss on redemption of government bonds	1,376.69	
Cost of 1965 <i>Transactions</i>	2,846.92	

General expenses

Stationery, printing and postage	\$1,376.69	
Clerical hire	400.00	
Auditing	150.00	
Treasurer's bond	62.00	
Dues	200.00	
Loss on Canadian Exchange	25.51	
Miscellaneous	39.33	2,253.53
		10,526.62

Net profit (loss) for the year	\$ (1,317.02)
General Fund balance, April 1, 1965	10,543.63
General Fund balance, March 31, 1966	\$ 9,226.61

The accompanying accountants' letter is an integral part of this statement.

*Exhibit B*AMERICAN LARYNGOLOGICAL ASSOCIATION
TRUST FUND OPERATING STATEMENT

For the Year Ended March 31, 1966

Interest—Government bonds	\$ 1,282.56	
Dividends—Common stocks	256.38	
	<u>\$ 1,538.94</u>	
Trust Fund balance, April 1, 1965 (Exhibit C)	55,047.98	
Trust Fund balance, March 31, 1966 (Exhibit C)	\$56,586.92	
Trust Fund balance represented by:		
Government bonds (at cost, par and maturity values)	\$30,500.00	
Common stocks:		
Income		
Purchased (at cost)	\$ 5,189.27	
Donated (market value at date of donation)	2,362.00	7,551.27
Total bonds and stocks (Exhibit D)		<u>\$38,051.27</u>
Cash		18,392.15
Accounts receivable		143.50
		<u>\$56,586.92</u>
Cash recapitulation		
Cash in Trust Fund	\$18,392.15	
Cash in General Fund	9,226.61	
	<u>\$27,618.76</u>	
Cash in commercial account	\$ 1,893.06	
Cash in savings account	20,725.70	
Cash in savings deposit receipt	5,000.00	
	<u>\$27,618.76</u>	

*The accompanying accountants' letter is an integral part of this statement.**Exhibit C*AMERICAN LARYNGOLOGICAL ASSOCIATION
REPORT OF TRUST FUNDS

March 31, 1966

Fund	Principal & Unused Income 4-1-65	Income* 4-1-65 to 3-31-66	Principal & Unused Income 3-31-66
Casselberry	\$ 8,042.36	\$ 224.83	\$ 8,267.19
Johnston	7,265.26	203.11	7,468.37
de Roaldes	5,000.32	139.79	5,140.11
Newcomb Trust	2,852.38	79.74	2,932.12
Newcomb Prize	665.77	18.61	684.38
Research	25,593.78	715.51	26,309.29
Memorial	5,628.11	157.35	5,785.46
	<u>\$55,047.98</u>	<u>\$1,538.94</u>	<u>\$56,586.92</u>

* Income has been allocated to each fund by the ratio that each fund bears to the total fund as of 3-31-65.

The accompanying accountants' letter is an integral part of this statement.

Exhibit D

AMERICAN LARYNGOLOGICAL ASSOCIATION
TRUST FUND INVESTMENTS

March 31, 1966

U. S. GOVERNMENT BONDS (at cost, par and maturity values):

	<i>Quantities</i>	<i>Denomination</i>		
Negotiable	5	\$1,000	\$ 5,000.00	
	1	5,000	5,000.00	\$10,000.00
Non-negotiable	2	1,000		2,000.00
Series H bonds ¹	10	1,000	\$10,000.00	
	1	500	500.00	10,500.00
Series K bonds ¹	3	1,000	\$ 3,000.00	
	1	5,000	5,000.00	8,000.00
				<u>\$30,500.00</u>

COMMON STOCKS:

	<i>No. of Shares</i>	<i>Cost</i>	<i>Market Value at Date of Donation</i>	
McDonnell Aircraft Corp. ²	56		\$1,170.00	
Internat'nal Business Machines ..	1		517.00	
Internat'nal Business Machines ³	1	\$ 344.25		
McIntyre-Porcupine Mines	15		675.00	
Amer. Telephone & Telegraph ..	70	4,845.02		
		<u>\$5,189.27</u>	<u>\$2,362.00</u>	<u>7,551.27</u>
				<u>\$38,051.27</u>

¹ These bonds were in process of redemption at March 31, 1966.

² Includes 30 shares received as stock dividends.

³ Includes 25% stock dividend.

The accompanying accountants' letter is an integral part of this statement.

ACCOUNTANTS' REPORT

To the Members of the American Laryngological Association—
Dear Sirs:

We have examined the accounts and financial records of the American Laryngological Association for the year ending March 31, 1966.

Cash receipts and disbursements were verified and all United States Government Bonds and common stocks were examined or properly accounted for.

In our opinion, the accompanying statements present fairly the cash position of the American Laryngological Association as of March 31, 1966 and the results of its cash operations for the year then ended.

Respectfully submitted,
SERENE, KOSTER & BARBOUR
Certified Public Accountants

(The Treasurer's report was accepted as read.)

DR. THEOBALD: The Nominating Committee is pleased to report the following names for election to the Board of Directors:

Dr. Joel J. Pressman
Dr. Lawrence R. Boies
Dr. G. Edward Tremble
Dr. Lyman G. Richards
Dr. Alden H. Miller
Dr. F. Johnson Putney
Dr. Francis E. LeJeune
Dr. Anderson C. Hilding
Dr. Albert C. Furstenberg
Dr. Paul H. Holinger

(The report of the Nominating Committee was unanimously accepted.)

REPORT OF THE LIBRARIAN, HISTORIAN AND EDITOR

The eighty-sixth annual meeting of the American Laryngological Association was held on April 23 and 24, 1965 at the Broadmoor, Colorado Springs, Colorado. The meeting was reported by the Martin C. Johnson Reporting Service whose representative, Mrs. Annabella Square, gave efficient and dependable service. All of the material for

th 1965 *Transactions* together with the corrected discussions were in the hands of the printer the first week of September, 1965.

The manuscripts from the annual meeting appeared in the September issue of the *Annals of Otology, Rhinology and Laryngology*, which was not circulated until the middle of December, 1965. This delayed the publication of the *Transactions* which were mailed the first of March, 1966. The delay in publication is regrettable, but can be explained in large part by the final illness of Dr. Arthur Proetz. It is anticipated that publication will be facilitated in the future, and Dr. Ben Senturia, the present editor of the *Annals*, has promised to give us complete cooperation in this regard. It is imperative that all papers be turned in at the annual meeting in their final form ready for publication. In the past, delay has resulted from last minute changes and corrections by the authors so that the final manuscript was not available at the time of the annual meeting.

According to Council Directive, 250 copies of the 1965 *Transactions* were ordered and distributed.

Letters have been sent to all emeritus and corresponding Fellows who subscribed last year asking them whether or not they wished to receive the 1965 *Transactions* at the Council established price of \$5.00. No *Transactions* were sent unless they were specifically ordered. Letters were sent to all previous subscribers asking if they wished to purchase a 1965 volume.

The distribution of the 1965 volume was as follows: 111 copies were sent from the publisher to the active and honorary members.

There were 53 standing orders for the *Transactions* and 13 additional orders.

A set of the available volumes of the *Transactions* for the past twenty years was sent to Dr. Jerome Hilger for the medical library at St. Joseph's Hospital in St. Paul, Minnesota. This was not a complete set since these have been exhausted. Complimentary volumes were sent to the honorary members, the library of Congress, the National Library of Medicine for the Index Medicus, and the families of the five deceased members. Dr. Lyman Richards received 3 volumes for his use in preparation of data for this year's *Transactions*.

Sometimes it is difficult to secure recent photographs of the members, and if a photograph other than the one submitted with the original application is available I should like one for the files. I should

also like to remind the members to send me a print of any photograph which may be taken subsequently.

Three orders for the back issue of 1964 were received.

Effective this year Dr. Samuel Salinger's abstracts which were so ably done have been discontinued, largely due to lack of demand and publication space in journals.

Respectfully submitted,
F. Johnson Putney, M.D., Editor

(The Editor's report was accepted as read.)

REPORT OF THE AMERICAN BOARD OF OTOLARYNGOLOGY

During the last year 114 candidates were examined. Of these, 81 were certified, 25 were conditioned and eight failed. The failing rate was 29.4%. At the present time there is a backlog of 225 applicants for examinations so that two examinations will be necessary this year. One will be given in New Orleans from June 5 to 10, 1966, and another in Chicago from October 10 to 14, 1966.

It is very gratifying to note that the caliber of the applicants taking the Board examination is much improved and most of them are superior students. It is also interesting to note that many of the applicants have had more than one year of surgery, and some of them have been previously certified in surgery. Practically all of the residency positions will be filled this year and there is a decided increase in the number of applicants.

Two years ago the Board of Otolaryngology submitted a report of a survey made of the present status of otolaryngology. A number of deficiencies were found including the fact that the weakest departments of otolaryngology were sections or divisions of departments of surgery, and the strongest ones were autonomous in their administrative planning. The quality of teaching, generally speaking, was found to be improving, but it is evident that more full-time teachers are needed.

The American Board of Otolaryngology, as the result of this survey, voted to establish an office which would concern itself with otolaryngological education in order to fulfill one of its basic objectives, the improvement of teaching in otolaryngology. Dr. Dean Lierle was appointed director and coordinator of the program. He has made visits to about 50 institutions within the last 18 months,

usually in the company of other Board members. These visits have been very fruitful and it is the Board's impression that a great deal of value to otolaryngology and medicine in general will result, subject to modification by the Society of University Otolaryngologists at its February meeting. Several years ago the Society of University Otolaryngologists was organized. Their meetings are held once a year in conjunction with the American Academy of Ophthalmology and Otolaryngology and at other times they deem advisable. Their chief objective is to improve the quality of teaching in otolaryngology. A liaison committee from the Society of University Otolaryngologists and the Board was formed and met at Ann Arbor in February 1966.

One of the current problems of otolaryngology is the scarcity of competent teachers, since the number of men going into academic otolaryngology has been comparatively small. Progress is being made at this time in fulfilling this need and it is our considered opinion that the situation will be greatly improved within the period of five years. The general surgeon can, and we hope will, help by strengthening those sections under his direction by obtaining a core of full-time teachers in otolaryngology, procure for them sufficient space, beds, and teaching hours and demonstrate a willingness to share surgery in the areas of overlapping interests. Generally speaking, the one-year residency program in general surgery, under re-evaluation, has been a great aid in the development of well-trained otolaryngologists, and the general surgeons, in the majority of instances, have been most cooperative in this respect. The Board has organized a bureau to help qualified individuals seeking academic positions in the universities to find such positions; and in addition to assist medical schools in finding individuals who are academically inclined and oriented who might be interviewed for top administrative positions. It is requested that individuals interested in teaching and/or research notify the secretary of the Board.

Revision of Bulletin 36 regarding Dental Oral Surgery was an improvement, but the Board does not feel that the Accreditation Committee went far enough. The field of dental surgery can be controlled fairly well in large teaching hospitals but this may not be true in the smaller hospitals. Certainly otolaryngologists should have more to say in regard to the activities of para-medical individuals in our hospitals, such as dentists, whose fields are related to ours.

The Tri-Part Residency Review Committee consisting of representatives from the American College of Surgeons, American Medical

Association and the Board has performed an outstanding service. It has been most effective and productive. It has contributed more to elevate standards in otolaryngology in the various institutions than any other factor.

Credit must also be given to various grants provided by the National Institutes of Health. They, too, have been responsible for raising the standards, stimulating research in otolaryngology and in making it possible to train academicians.

Mention should be made of the fact that the Board of Otolaryngology has revised its Articles of Incorporation and By-Laws in 1965. As a result of this revision there has been a change in tenure to a six year term. A Board member may be re-elected for one succeeding term. An age limit of 70 years of age has been stipulated. The Board also has prepared a Guide in regard to the requirements for preparation of the Board examination.

Respectfully submitted,
Francis L. Lederer, M.D.
Paul H. Holinger, M.D.

(Dr. Lederer's report was accepted as read.)

REPORT OF THE LARYNGOLOGICAL RESEARCH FUND COMMITTEE

The Fund consists of approximately \$25,000.00, principal and unused income.

Annual income is approximately \$1,200.00.

The Council in January 1966 recommended that one half of the annual income of 1965 (\$600.00) be earmarked for a film being prepared by the ABEA on prevention of foreign body accidents. The Committee has not come to a decision in regard to the second half. Seven requests for funds have been received to this date.

Respectfully submitted,
Joel Pressman, '67
Jerome Hilger, '67
Francis LeJeune, '70
Daniel Baker, '70
Alden Miller, '70
Paul Holinger, 67, Chairman

(Dr. Holinger's report was accepted as read.)

PRESIDENT HOLINGER: The next item of business is concerned with a constitutional change, which has been circularized. It was circularized in detail in the post-Council letter:

In order to clarify the non-profit status of each Fellow of the American Laryngological Association, the Council recommends the adoption of the following proposed Amendment to the By-Laws and its submission to the Fellowship, to be voted on at the Annual Meeting, as prescribed in the Constitution. I will read this for your interest:

Association Assets

Section I. The interest in the funds, property and other assets of the Association of any member whose membership shall terminate for any reason except the dissolution of the Association shall, ipso facto, immediately cease, and such member and the representatives of such member shall have no claim against the Association or against the other members or their representatives or any of them.

Section II. In the case of dissolution of the Association, the funds, property, and other assets shall be used for the purpose of furthering the expressed purposes for which this Association was formed and no other member shall be entitled to receive any of the assets on liquidation.

(On a motion by Dr. Miller, duly seconded by Dr. Ireland, the constitutional change was unanimously approved.)

REPORT FROM THE AMERICAN COLLEGE OF SURGEONS

The importance of adequate representation of laryngologists in the American College of Surgeons should again be stressed. Membership representation on the Board of Governors of the College is in part dependent upon the percentage of Fellowship in the College in a specialty society such as ours. Otolaryngology is gaining stature in problems of surgery of the head and neck and must maintain it. This can be done through active program participation, exhibits and committee activities, all of which are essential in order to be effective in College activities. It is hoped that those who are Fellows of the American Laryngological Association and on the Council of the Academy should insist on separating the Academy and American Board of

Otolaryngology meetings from those of the College. The American Laryngological Association has a stake in this problem and should influence the Academy administration to realize the effects of the direct conflict between the meetings of the American Board of Otolaryngology being held in Chicago and that of the American College of Surgeons being held in San Francisco this October. With the Academy meeting in Chicago the following week, attendance, program and committee participation obviously will suffer. It is tragic that we cannot reach a solution to this problem which has been under discussion for years.

Respectfully submitted,

Paul H. Holinger for Walter Work

EXECUTIVE SESSION

SUNDAY MORNING, APRIL 24, 1966

The meeting reconvened in Executive Session in the Arecibo Room on Sunday morning, April 24, 1966, at eleven fifty-five o'clock, following the Scientific Session and a brief meeting of the Board of Directors, President Holinger presiding.

ACTING SECRETARY LEJEUNE: It is my privilege and honor to tell you that the Board of Directors have elected the following officers for the coming year:

President: Dr. Joel J. Pressman

First Vice-President: Dr. Lawrence Boies

Second Vice-President: Dr. Edward Tremble

Secretary: Dr. Lyman Richards

Treasurer: Dr. Alden Miller

Librarian, Historian and Editor: Dr. F. Johnson Putney

Councilors: Dr. Francis LeJeune

Dr. Anderson Hilding

Dr. Albert Furstenberg

Dr. Paul Holinger

PRESIDENT HOLINGER: Before asking our honored guest to conduct the President to the rostrum I should like to take this opportunity to thank you again for the honor you have given me to be your President this past year and to say how much I have enjoyed it and to assure you that it has been a most fruitful year in every way.

We are only sorry that Lyman Richards is not here to conduct this program as he has arranged it.

And now, Dr. Lederer, if I may ask you to conduct Dr. Pressman to the rostrum.

I offer Dr. Pressman the congratulations of the Association on its newly elected officers and on his election to the office of President of the Association.

PRESIDENT PRESSMAN: No one has ever stood before you as president-elect without being grateful, stimulated and humble. I am certainly no exception.

Since 1936 the American Laryngological Association has been very good to me in many ways but this is my first opportunity to serve it in return. I shall do so with all the vigor and enthusiasm of which I am capable, ever mindful of the responsibility one accepts in becoming your president. If these efforts fall short of that to which you have been accustomed, you will understand the difficulties inherent in following in Paul Holinger's footsteps.

I express my deepest appreciation from the very bottom of my heart first to the Nominating Committee for having put my name before you and then to each of you for having bestowed this highest of all honors upon me.

I look forward to this coming year's service with much enthusiasm.

My first duty is a very pleasant one. Paul Holinger has served this Association in many ways. He has given it stature not only by his professional achievements but by the respect, admiration and love

showered upon him by his colleagues in all fields and by the laity as well.

To those of you who have not had a chance to hear it, this Association last night recognized his achievements by naming him the recipient of the De Roaldes Award, the highest in our armamentarium of three, he having won the Casselberry and Newcomb Awards previously, to add to those which have recognized his achievements and have been given to him from many sources throughout the world, and yet yesterday in his presidential address Paul spoke of his presidency as the honor he valued most highly.

As a memento of this, the American Laryngological Association takes great pleasure and satisfaction in presenting this token to him, which I know he will cherish as long as he lives.

Paul, in the name of the Association I express our sincere gratitude for your having served us so well and present you with this token of our affection and our esteem.

(The meeting was adjourned at 12 o'clock noon.)

THE ARTHUR W. DE ROALDES AWARD

The 1966 recipient of the de Roaldes Award obtained his B.S. and M.S. degrees from the University of Chicago and his M.D. degree from Northwestern University in 1933. He received his residency training in Otolaryngology at the Research and Educational Hospital, University of Illinois, and held an assistantship with Chevalier Jackson and Chevalier L. Jackson at Temple University. Later, he became professor of Bronchoesophagology at the University of Illinois College of Medicine. In addition, he has been attending Bronchoesophagologist at the Illinois Eye and Ear Infirmary, Presbyterian-St. Luke's Hospital and the Children's Memorial Hospital in Chicago.

Our awardee has had an unceasing desire and put forth successful effort to maintain the highest standards of medical practice, not only at the local, but at the State, National and International level as well. He is a member of all of the medical societies pertaining to his specialty and has held high offices in practically all of them and is an honorary member of many foreign societies. At the present time, he is on the Editorial Board of five publications.

He has made contributions not only to Clinical Medicine, but has been active in research and has greatly aided education at all levels as Professor of Bronchoesophagology in the Department of Otolaryngology at the University of Illinois. His literary contributions in his field number 250. One of his greatest contributions to audio-visual education has been his production of colored films of the respiratory and digestive tracts.

At the present time, he is President of the American Laryngological Association, a member of the Board of Regents of the American College of Surgeons and a Director of the American Board of Otolaryngology.

He is the recipient of the Casselberry Award, the James Newcomb Award and now the committee recommends that the de Roaldes Award, the highest honor bestowed by the American Laryngological Association be given to this man, who is most deserving because of his faithful duties in the American Laryngological Association over the years and for his great contribution to clinical medicine, research and education.

Ladies and gentlemen, let me present our President, Dr. Paul Holinger, who now, for the first time in our history, has the distinction of receiving all three awards in addition to being President of the American Laryngological Association.

Respectfully submitted,

Dean M. Lierle, M.D.

THE NEWCOMB AWARD

The Newcomb Award was established in 1939 through a bequest of the estate of James A. Newcomb who was Secretary of the American Laryngological Association for 11 years and its President in 1911. It is given annually to a Fellow of the American Laryngological Association as a mark of esteem and appreciation for services to the Association or one who has made the most outstanding contribution to the literature of Laryngology during the previous calendar year.

Our Committee which includes Dr. Kinsey Simonton and Dr. Francis Sooy, and the Council decided that this Award is merited by one who has had such a productive hand in guiding the destiny

of our Association in recent years. His training for this important role began developing more than 20 years ago when he edited the Transactions of the Triological Society, of which he was President in 1948. He also was Secretary of the American Broncho-Esophagological Association from 1935 to 1939 and its President in 1939. His writings have always been models of clarity and exposition.

Many of us remember with enjoyment some of his lighter literary efforts such as the scripts for amateur talent entertainment at some of our annual meetings such as "The Fred Allen Show" in Atlantic City in 1948. What modern banquet of the A.L.A. could be complete without his performance on the violin?

Mr. President, it is a privilege for me to present the Newcomb Award for 1965 to our esteemed Secretary—Lyman G. Richards.

Lawrence R. Boies, M.D.

THE CASSELBERRY AWARD

The Casselberry Award was established in 1906 to be granted to a scientific worker in the field of Rhinology and Laryngology. It is stipulated that it shall be based on a thesis submitted, unidentified, to a committee made up of Fellows of the Association who would evaluate it on originality of material, its scientific and clinical value, and the method of presentation. This year a thesis was submitted that had the unanimous approval of the Casselberry Award Committee as one which merited this honor. The Committee's action was also unanimously approved by the Council, another of the stipulations required before granting the Award.

It is my pleasure and privilege to announce that the Award in 1966 has been granted to Dr. John A. Kirchner, Professor of Otolaryngology, Yale School of Medicine, New Haven, Connecticut, and Dr. Barry D. Wyke, Neurological Laboratory, Dept. of Applied Physiology, Royal College of Surgeons, London, England, for their thesis, "The Role of Cricothyroid Joint Reflexes in Laryngeal Function."

Unfortunately, Doctors Kirchner and Wyke were not aware of the honor to be bestowed upon them in time to be present at the meeting here in Puerto Rico. They will be notified by letter and the appropriately inscribed Award certificate will be sent to them.

Paul H. Holinger, M.D.

List of Fellows

LIST OF FELLOWS

Date Indicates Year Admitted to Active Fellowship

Attendance at meetings is shown by figures following each name.

Asterisk (*) indicates year paper was read.

Active Fellows

1962. ALEXANDER, FRED W., 10515 Carnegie Ave., Cleveland 6, Ohio, 1962, '63*, '64, '66.
1958. ALFARO, VICTOR R., 917 - 20th St. N. W., Washington 6, D. C., 1958, '59, '60, '61, '62, '63, '64, '65, '66.
1962. ARNOLD, GODFREY E. T., 2500 N. State St., Jackson 6, Mississippi, 1962, '63*, '64*, '66.
1958. ATKINS, JOSEPH P., 3400 Spruce St., Philadelphia 4, Pa., 1958, '59*, '60, '61, '62, '63, '64, '66.
1956. BAKER, DANIEL CLIFTON, JR., 903 Park Avenue, New York 21, N. Y., 1956, '57, '58, '59*, '60, '61, '62*, '63, '64, '65, '66.
1963. BAXTER, JAMES D., 1509 Sherbrooke St. West, Montreal, P.Q., Canada, 1963, '65*, '66.
1944. BOIES, LAWRENCE R., University Hospital, Minneapolis 14, Minnesota, 1944, '46, '47, '48*, '49, '50*, '51*, '53, '54, '55, '56, '57, '58, '59, '60, '61, '62, '63, '64, '65, '66.
1955. BORDLEY, JOHN E., Johns Hopkins Hospital, Baltimore 5, Maryland, 1955, '56, '57, '59, '60, '62, '63, '64, '65, '66.
1959. BREWER, DAVID W., 1100 E. Genesee St., Syracuse 10, N. Y., 1959, '60*, '61, '62*, '63*, '66.
1955. BROWN, LESTER ALEXANDER, 490 Peachtree Street, N.E., Atlanta 8, Georgia, 1955, '56, '57, '58, '59, '61, '63, '65.
1940. BROYLES, EDWIN N., 11 East Chase St., Baltimore 2, Maryland, 1940, '41*, '42, '46, '48*, '49, '50, '51*, '52, '53, '54, '55, '56, '58, '59*, '60, '61*, '63, '64, '65.

1963. BRYCE, DOUGLAS P., 170 St. George St., Room 320, Toronto, Canada, 1963*, '64, '66*.
1959. CARDWELL, EDGAR P., 109 So. Munn Ave., East Orange, N. J., 1959, '60, '61, '62, '63.
1964. CODY, CLAUDE C., III, 1600 Memorial Professional Building, Houston, Texas, 1964, '65.
1957. CONLEY, JOHN J., 139 East 36th Street, New York 16, N.Y. 1958*, '60*, '61, '62*, '63*, '64, '65.
1957. CONVERSE, JOHN MARQUIS, 722 Park Avenue, New York 21, N.Y., '60, '62*.
1959. CRACOVANER, ARTHUR J., 103 E. 78th St., New York 21, N. Y., 1959, '60, '61*, '62, '63, '65, '66.
1960. DALY, JOHN F., Faculty Practice Offices, 566 First Ave., New York 16, N. Y., 1960, '61*, '62, '63, '64, '65, '66.
1951. DAVISON, FRANCIS W., Geisinger Medical Center, Danville, Pa., 1951, '52, '53*, '54, '55, '56, '57, '58, '59, '60, '61, '62, '63*, '64, '65, '66.
1966. DEVINE, KENNETH D., Mayo Clinic, Rochester, Minn., 1966. 1948*, '49, '51, '53, '54, '56, '57, '59, '62, '64, '65*, '66.
1947. EAGLE, WATT WEEMS, Duke Hospital, Durham, N. C., 1948*, '49, '51, '53, '54, '56, '57, '59, '62, '64, '65*.
1952. ERICH, JOHN B., Mayo Clinic, 102 Second Avenue, Rochester, Minn., 1953, '56*, '57, '65.
1964. FEARON, BLAIR, Medical Arts Building, Toronto 5, Ontario, Canada, 1964, '66.
1963. FERGUSON, CHARLES F., 300 Longwood Ave., Boston 15, Mass., 1963, '64*, '66.
1955. FITZ-HUGH, GLASSELL SLAUGHTER, 2003 Spottswood Road, Charlottesville, Virginia, 1955, '57, '59, '60, '61, '62*, '64, '65, '66.
1956. FRIEDBERG, STANTON A., 122 So. Michigan Ave., Chicago 3, Illinois, 1956, '57*, '58, '59, '60, '61, '62, '63, '64, '65*.
1932. FURSTENBERG, ALBERT CARL, St. Joseph's Mercy Hospital, Ann Arbor, Michigan, 1933*, '36*, '38*, '46, '48*, '50, '51, '53, '54, '55*, '56, '57, '58*, '59, '60, '61, '62, '63*, '64, '65*.

1959. GOLDMAN, JOSEPH L., 1050 Park Ave., New York, N. Y., 1959, '60*, '61, '62, '63, '64, '65, '66.
1940. GOODALE, ROBERT L., 330 Dartmouth St., Boston 16, Massachusetts, 1940, '41, '42*, '44*, '46, '47, '49, '50*, '53, '54, '55*, '56, '57*, '60, '61*, '62, '63, '64, '65*.
1965. HANCKEL, RICHARD W., 55 Doughty St., Charleston, S. C., 1965, '66.
1957. HARRILL, JAMES A., Bowman Gray School of Medicine, Winston-Salem, N. C., 1957, '58, '59, '61, '62, '63, '64, '66.
1960. HARRIS, HERBERT, 907 Hermann Professional Building, Houston 25, Texas, 1960, '61*, '62, '63, '64, '65*, '66.
1959. HART, VERLING K., 106 W. 7th St., Charlotte, N. C., 1959, '60, '62, '66.
1942. HEATLY, CLYDE A., 11 North Goodman Street, Rochester 7, N.Y., 1942, '46*, '49, '50, '52, '53*, '54, '55, '57, '58, '60, '61, '65.
1959. HENRY, G. ARNOLD, 170 St. George St., Toronto, Canada, 1959, '61, '63, '66.
1943. HILDING, ANDERSON C., Research Laboratory, St. Luke's Hospital, Duluth 11, Minnesota, 1944*, '46, '47, '48*, '49, '50, '51, '53, '55, '56*, '57, '60, '61, '62*, '63, '64*, '65, '66*.
1955. HILGER, JEROME A., 350 St. Peter Street, St. Paul 2, Minnesota, 1955, '56*, '57, '58, '59, '60, '62, '63, '64, '65, '66.
1945. HOLINGER, PAUL H., 700 North Michigan Ave., Chicago 11, Illinois, 1946, '47, '49, '50*, '51*, '52, '53, '54*, '55, '56, '57, '58*, '59, '60, '61*, '62*, '63, '64, '65, '66*.
1957. HOLMES, EDGAR M., 264 Beacon St., Boston 16, Mass., 1957, '59, '61, '63.
1944. HOOPLE, GORDON D., 1100 East Genesee St., Syracuse 10, New York, 1946, '47, '48, '49, '50, '51, '52, '53, '54*, '55, '56, '58, '59, '60, '61, '62, '63, '64, '65, '66.
1952. IRELAND, P. E., Room 82, Banting Institute, University of Toronto, Toronto, Ontario, 1952, '53, '54, '55, '56*, '57, '59, '61, '62, '63, '64, '66.
1961. JONES, EDLEY H., 1301 Washington St., Vicksburg, Miss., 1961, '62, '63*, '65, '66.

1964. KEIM, W. FRANKLIN, 75 Union St., Montclair, N. J., 1964, '66.
1965. KING, JAMES T., Baptist Professional Building, Atlanta, Ga., 1965, '66.
1963. KIRCHNER, JOHN A., 333 Cedar St., New Haven 4, Conn., 1963, '65*.
1965. KNIGHT, JOHN S., 305 West 43rd St., Kansas City, Mo., 1965, '66*.
1963. LATHROP, FRANK D., 605 Commonwealth Ave., Boston 15, Mass., 1963, '64*.
1953. LEDERER, FRANCIS LOEFFLER, 1853 W. Polk Street, Chicago 12, Illinois, 1953, '54, '55, '56, '57*, '58, '60, '61, '62, '63*, '64, '65, '66.
1936. LEJEUNE, FRANCIS ERNEST, Ochsner Clinic Building, Prytania and Aline Streets, New Orleans 15, Louisiana, 1937, '46*, '47, '50, '51, '52, '53, '54*, '55, '56, '57, '58, '59, '60, '61, '62, '63*, '64, '65, '66.
1966. LEWIS, JOHN S., 3 East 71st Street, New York 21, N. Y., 1966.
1961. LEWY, ROBERT B., 25 East Washington St., Chicago 2, Ill., 1961, '62*, '63, '65*.
1933. LIERLE, DEAN M., University Hospital, Iowa City, Iowa, 1933, '34, '35*, '37, '38, '39, '40*, '42*, '44*, '46, '47*, '48, '49, '50*, '51, '52, '53, '54, '55*, '56, '57, '58, '59, '60, '62*, '63, '65, '66.
1949. LINDSAY, JOHN R., 950 E. 59th Street, Chicago 37, Illinois, 1949, '50, '51*, '53, '55*, '56, '57, '58, '59, '60, '61, '62, '65, '66.
1966. McCABE, BRIAN F., Dept. of Otolaryngology, University Hospital, Iowa City, Iowa, 1966.
1963. MCGOVERN, FRANCIS H., 139 South Main St., Danville, Virginia, 1963, '64, '66.
1951. MCHENRY, LAWRENCE C., 301 N. W. 12th St., Oklahoma City 2, Okla., 1953*, '62, '63, '64, '65, '66.

1931. McNALLY, WILLIAM JAMES, 1509 Sherbrooke Street West, Montreal, Canada, 1931, '33, '34*, '39, '44, '47, '49, '49, '52, '53, '54*, '55, '56, '57, '58, '59, '60, '61, '65.
1954. MELTZER, PHILIP E., 285 Commonwealth Ave., Boston 15, Mass., 1954*, '56, '57, '58, '59, '60, '61, '62, '63, '65, '66.
1952. MILLER, ALDEN H., 1407 N. Vermont Ave., Los Angeles 27, Calif., 1952, '53*, '55, '57, '58*, '61, '62, '63, '64, '66.
1965. MILLER, DANIEL, Deaconess Medical Building, 110 Francis St., Boston, Mass., 1965, '66.
1964. MONTGOMERY, WILLIAM W., 243 Charles St., Boston 14, Mass., 1964, '65*, '66*.
1958. MONTREUIL, FERNAND, Centre Professionnel, 801 Sherbrooke, E., Montreal, Canada, 1958, '60, '64.
1954. MOORE, PAUL M., 10515 Carnegie Ave., Cleveland 6, Ohio, 1954, '55*, '56, '57, '59, '60, '61, '62, '63, '64, '65, '66.
1957. MUNOZ-MACCORMICK, CARLOS EDUARDO, 71 Park Terrace, Santurce, Puerto Rico, 1957, '58, '59, '60, '61, '62, '63, '64, '65, '66.
1953. MURTAGH, JOHN A., 2 Maynard Street, Hanover, New Hampshire, 1953, '54, '55, '56*, '57, '58, '59, '61, '62, '63, '65, '66.
1937. NASH, C. STEWART, Medical Arts Building, Rochester 7, New York, 1937, '38*, '40, '42, '44, '46, '49, '50, '51, '52, '53, '54, '55, '56*, '58, '59, '60, '61, '62, '64.
1956. NORRIS, CHARLES MORGAN, 3401 North Broad Street, Philadelphia 40, Pennsylvania, 1956, '57, '58*, '59, '60, '61*, '62, '63, '64, '66.
1961. OGURA, JOSEPH H., 640 So. Kingshighway, St. Louis 10, Mo., 1961*, '62*, '63, '64*, '65, '66*.
1958. O'KEEFE, JOHN J., 255 S. 17th St., Philadelphia 3, Pa., 1958, '59*, '60, '62, '64.
1961. O'NEIL, JAMES J., 612 Medical Arts Building, Omaha, Nebraska, 1961, '62*, '64.
1961. PANG, LUP Q., 1374 Nuuanu Ave., Honolulu 17, Hawaii. 1961, '62*, '64, '66.

1961. PASTORE, PETER N., Box 25, 1200 East Broad St., Richmond, Virginia, 1961, '62*, '64, '66.
1954. PRESSMAN, JOEL J., Department of Surgery, UCLA Medical Center, Los Angeles 24, Calif., 1954, '56*, '59*, '60, '61, '62, '64, '65, '66.
1951. PRIEST, ROBERT E., 79, S. Ninth St., Minneapolis 2, Minn., 1951, '53*, '54*, '56, '59, '60*, '61, '65.
1951. PUTNEY, F. JOHNSON, 1712 Locust St., Philadelphai 3, Pa., 1951, '52, '53*, '54, '55, '56, '58*, '59, '60, '61, '62, '63*, '64*, '65, '66.
1951. RAWLINS, AUBREY G., 384 Post Street, San Francisco 8, Calif., 1951, '53*, '56, '58, '64.
1963. REED, GEORGE F., 766 Irving Ave., Syracuse, N. Y., 1963, '65*, '66.
1934. RICHARDS, LYMAN GILDER, 12 Clovelly Road, Wellesley Hills 81, Mass., 1934, '35, '36*, '37, '38, '39, '47, '49, '51*, '54, '56, '57*, '59, '60, '61, '62, '63, '64, '65.
1956. RICHARDSON, JOHN ROBERT, 403 Commonwealth Avenue, Boston 15, Massachusetts, 1957, '58, '59, '60, '63, '64.
1953. ROBERTS, SAM E., 1100 Professional Bldg., Kansas City, Missouri, 1953, '54*, '55, '56, '57, '58, '59, '60, '63, '65.
1959. SANDERS, SAM H., 1089 Madison Ave., Memphis 3, Tenn., 1959, '60, '61, '62, '63, '65.
1964. SAUNDERS, WILLIAM H., N-820 University Hospital, Columbus, Ohio, 1964, '65, '66.
1959. SILCOX, LOUIS E., 102 Lankenau Med. Bldg., Philadelphia 31, Pa., 1959, '60, '61, '62, '63, '64, '65, '66.
1958. SIMONTON, KINSEY M., Mayo Clinic, Rochester, Minn., 1958, '59*, '62, '64, '66.
1962. SISSON, GEORGE A., 1200 E. Genesee St., Syracuse 10, N. Y., 1962, '63*, '65, '66.
1964. SKOLNIK, EMANUEL M., 1853 West Polk Street, Chicago, Ill., 1964*, '65, '66*.
1950. SMITH, AUSTIN T., Pennsylvania Hospital, 330 So. 9th St., Philadelphia 7, Pa., 1950, '51, '52, '53, '55, '56, '57, '58*, '59, '60, '61, '62*, '66.

1954. SOOY, FRANCIS A., 490 Post Street, San Francisco 2, Calif., 1954, '56*, '58, '60, '62, '63, '64, '65*.
1961. SUEHS, OLIVER W., 14 Medical Arts Square, Austin, Texas, 1961, '62*, '63, '64, '66.
1963. TABB, HAROLD G., 1430 Tulane Ave., New Orleans 12, La. 1963, '65, '66.
1954. THORNELL, WILLIAM C., 2508 Auburn Avenue, Cincinnati 19, Ohio, 1955*, '57, '59, '60, '63.
1963. TOLAN, JOHN F., 1118 Ninth Ave., Seattle 1, Washington, 1963, '64, '65.
1950. TREMBLE, G. EDWARD, 1390 Sherbrooke St. W., Montreal, Quebec, Canada, 1950, '51, '52, '53, '54, '55*, '56, '57, '58, '60, '61, '62, '63, '65, '66.
1954. WALSH, THEODORE E., 640 S. Kingshighway Blvd., St. Louis 10, Missouri, 1954, '55*, '56, '57, '58, '59, '60, '61, '62, '63, '64, '65, '66.
1962. WEAVER, DELMAR F., 571 Fisher Building, Detroit 2, Michigan, 1962, '63, '64*, '65.
1940. WEILLE, FRANCIS L., 247 Commonwealth Avenue, Boston 16, Massachusetts, 1940, '41, '42, '44, '46*, '47, '48, '49, '50, '51, '52, '53, '54, '55, '56*, '57, '58, '59, '60, '61, '62, '63, '64, '65*, '66.
1948. WILLIAMS, HENRY L., 2nd, 54th St. & 48th Ave., Minneapolis 17, Minnesota, 1948, '49, '50*, '51, '52*, '53, '54, '55, '56, '57, '58*, '59, '60, '62, '63, '64, '65.
1951. WOODMAN, DEGRAAF, Talbottown Lane, P. O. Box 560, Easton, Md., 1951, '53, '54, '55*, '56, '58, '59, '60, '61, '62, '63, '64, '65, '66.
1953. WORK, WALTER P., University Hospitals, Ann Arbor, Michigan, 1953, '54, '56, '58, '59*, '62, '63*, '65.

Honorary Fellows

1957. (1925) CLERF, LOUIS H., 5575 Eighth Avenue, North, St. Petersburg 2, Florida, 1957, '58, '59, '60, '61, '63, '64, '65, '66.
1960. (1928) HILL, FREDERICK THAYER, Thayer Memorial Hospital, Waterville, Maine, 1960, '61, '63, '64, '66.

1957. (1930) NEGUS, SIR VICTOR E., Hill Farm Lodge, Haslemere, Surrey, England, 1957*.
1966. (1957) ONO, JO, 75 Zaimoku-cho, Azabu, Minato-ku, Tokyo, Japan.

Corresponding Fellows

1946. ALONSO, REGULES JUSTO E., Mercedes 1233, Montevideo, Uruguay.
1959. BARRETTO, PLINIO DE MATTOS, Ru Cons Torres, Homer 371, Sao Paulo, Brazil, 1960.
1959. BATEMAN, GEOFFREY H., 55 Harley Street, London W.1., England.
1942. BATSON, OSCAR V., 203 South DeKalb St., Philadelphia 4, Pennsylvania, 1942*, '54*.
1964. CLEVES, CARLOS, Carrera 14 No. 44-54, Apto. 202, Bogota, Colombia, S.A.
1966. DOHLMAN, GUSTA, Dept. of Otolaryngology, University of Toronto, Toronto, Canada, 1966.
1943. EGGSTON, ANDREW A., 653 Park Avenue, New York, N. Y., 1944, '49, '55, '60, '61*.
1957. HUIZINGA, EELCO, Noorderhaven 7, Groningen, The Netherlands, 1957.
1964. PEREZ, ALFREDO C., Instituto Celis Perez, Avenida Montes de Oca, Apartado 163, Valencia, Venezuela, S.A., 1965.
1937. PORTMANN, GEORGES, 25 bis Cours de Verdun, Bordeaux, France, 1947.
1957. RUEDI, LUZIUS, Ramistrasse 100, Zurich, Switzerland, 1957.
1924. SCHAEFER, J. PARSONS, 4634 Spruce Street, Philadelphia 39, Pennsylvania, 1934.
1952. TAPIA ACUNA, RICARDO, Av. Insurgentes Sur 300, Mexico 7 D.F., 1953, '57, '60*.
1936. VIALLE, JACQUES, 27 Rue de France, Nice (Alpes Maritimes), France.

Emeritus Fellows

1951. (1944) BEATTY, HUGH G., 390 Oak St., Apt. No. 35, Columbus 15, Ohio, 1951, '52, '53.
1966. (1945) CAMPBELL, PAUL A., 321 Park Hill Drive, San Antonio, Texas.
1965. (1942) CANFIELD, NORTON, Harwood Hospital, Christiansted, St. Croix, Virgin Is.
1958. (1930) FIGI, FREDERICK A., Mayo Clinic, Rochester, Minnesota.
1961. (1936) GALLOWAY, THOMAS CYRUS, 636 Church St., Evanston, Illinois, 1961, '62, '64, '66.
1951. (1928) GITTINS, THOMAS R., 408 Davidson Bldg., Sioux City, Iowa.
1963. (1928) GOODYEAR, HENRY M., 2012 Edgecliff Point, Cincinnati, Ohio 45206.
1960. (1940) HANSEL, FRENCH, 634 N. Grand Blvd., St. Louis 3, Missouri, 1962, '65.
1955. (1930) HOUSER, KARL M., 2035 Delancey Street, Philadelphia 3, Pennsylvania.
1951. (1928) JARVIS, DEFOREST C., Quarry Bank Bldg., Barre, Vt., 1952.
1960. (1942) KELLY, JOSEPH D., 140 East Fifty-fourth Street, New York 22, N. Y.
1961. (1950) KLINE, ORAM R., 514 Cooper Street, Camden, N. J., 1961, '63.
1954. (1927) LUKENS, ROBERT M., 141 West Heather Road, Wildwood Crest, N. J.
1964. (1952) MCCALL, JULIUS W., 610 Rose Building, Cleveland 15, Ohio, 1964, '66.
1966. (1933) MCMAHON, BERNARD J., 150 North Meramec Ave., Clayton, Mo.
1959. (1927) MYERSON, MERVIN C., 435 No. Bedford Drive, Beverly Hills, Calif.

1957. (1948) PHELPS, KENNETH A., 7200 34th St., South, St. Petersburg, Fla.
1958. (1938) SALINGER, SAMUEL, 1260 East Alejo Road, Palm Springs, Calif., 1958, '59, '61, '62, '63, '64, '65, '66.
1962. (1932) SCHALL, LEROY A., Scudder Lane, Barnstable, Mass., 1964, '66.
1964. (1934) SCHENCK, HARRY P., 326 South 19th Street, Philadelphia 3, Pa., 1964, '65*, '66.
1965. (1939) SIMPSON, W. LIKELY, 351 South Highland St., Memphis, Tenn.
1966. (1947) THEOBALD, WALTER H., 307 N. Michigan Ave., Chicago 11, Ill., 1966.
1965. (1943) VAN ALYEA, OLIVER E., 135 South LaSalle St., Chicago 3, Ill., 1965, '66.
1961. (1941) VIOLÉ, PIERRE P., 241 South Windsor, Los Angeles, Calif., 1964.
1964. (1948) WILLIAMS, HENRY L., II, U. S. Veterans' Hospital, Minneapolis 17, Minn., 1964, '65, 66.
1951. (1935) WOODWARD, FLETCHER D., 1326 Rugby Road, Charlottesville, Va., 1959, '60, '61.

BENEFACTORS

DR. JOHN F. BARNHILL	DR. FREDERICK T. HILL
DR. GORDON BERRY	DR. & MRS. GEORGE E. HOURN
DR. EDWIN N. BROYLES	DR. SAMUEL JOHNSTON
DR. WILLIAM E. CASSELBERRY	DR. JAMES E. NEWCOMB
DR. LOUIS H. CLERF	DR. HENRY B. ORTON
DR. CORNELIUS COAKLEY	DR. SAMUEL SALINGER
DR. & MRS. FRANCIS W. DAVISON	DR. SAM H. SANDERS
DR. & MRS. LEE WALLACE DEAN	DR. HARRY P. SCHENCK
DR. ARTHUR W. DEROALDES	DR. BURT R. SHURLY
DR. FRED W. DIXON	MR. LESTER T. SUNDERLAND
DR. WILLIAM E. GROVE	DR. H. MARSHALL TAYLOR
DR. GORDON F. HARKNESS	DR. WALTER H. THEOBALD



Obverse of the deRoaldes medal

RECIPIENTS OF THE DEROALDES AWARD

- 1928. DR. CHEVALIER JACKSON
- 1931. DR. D. BRYSON DELAVAN
- 1934. DR. HARRIS P. MOSHER
- 1937. DR. LEE WALLACE DEAN
- 1943. DR. RALPH A. FENTON
- 1949. DR. GEORGE M. COATES
- 1951. DR. ARTHUR W. PROETZ
- 1954. DR. LOUIS H. CLERF
- 1959. DR. ALBERT C. FURSTENBERG
- 1960. DR. DEAN M. LIERLE
- 1961. DR. FREDERICK T. HILL
- 1966. DR. PAUL H. HOLINGER

RECIPIENTS OF THE CASSELBERRY AWARD

1923. DR. GEORGE FETTEROLF AND DR. HERBERT FOX
1928. DR. RALPH A. FENTON AND DR. O. LARSELL
1929. DR. RICHARD A. KERN AND DR. HARRY P. SCHENCK
1929. DR. EDWARD H. CAMPBELL
1931. DR. ARTHUR W. PROETZ
1934. DR. ANDERSON C. HILDING
1936. DR. FRANCIS E. LEJEUNE: DR. JOEL J. PRESSMAN
1939. DR. H. MARSHALL TAYLOR: DR. BRIEN T. KING
1940. DR. FRENCH K. HANSEL
1941. DR. NOAH D. FABRICANT
1946. DR. PAUL H. HOLINGER
1949. DR. HENRY B. ORTON
1962. DR. HANS VON LEDEN
1966. DR. JOHN A. KIRCHNER AND DR. BARRY D. WYKE

RECIPIENTS OF THE NEWCOMB AWARD

- 1941. DR. BURT R. SHURLY
- 1942. DR. FRANCIS R. PACKARD
- 1943. DR. GEORGE M. COATES
- 1944. DR. CHARLES J. IMPERATORI
- 1947. DR. HARRIS P. MOSHER
- 1948. DR. GORDON BERRY
- 1949. DR. GORDON B. NEW
- 1950. DR. H. MARSHALL TAYLOR
- 1951. DR. JOHN D. KERNAN
- 1952. DR. WILLIAM J. McNALLY
- 1953. DR. FREDERICK T. HILL
- 1954. DR. HENRY B. ORTON
- 1955. DR. THOMAS C. GALLOWAY
- 1956. DR. DEAN M. LIERLE
- 1957. DR. GORDON F. HARKNESS
- 1958. DR. ALBERT C. FURSTENBERG
- 1959. DR. HARRY P. SCHENCK
- 1960. DR. JOEL J. PRESSMAN
- 1961. DR. CHEVALIER L. JACKSON
- 1962. DR. PAUL H. HOLINGER
- 1963. DR. FRANCIS E. LEJEUNE
- 1964. DR. FRED W. DIXON
- 1965. DR. EDWIN N. BROYLES
- 1966. DR. LYMAN G. RICHARDS

PAST OFFICERS

Presidents

(Year of Election)

1879.	Louis Elsberg	1909.	J. E. Logan
1880.	J. Solis-Cohen	1910.	D. Braden Kyle
1881.	F. I. Knight	1911.	James E. Newcomb
1882.	G. M. Lefferts	1912.	George A. Leland
1883.	F. H. Bosworth	1913.	Thomas Hubbard
1884.	E. L. Shurly	1914.	Alexander W. MacCoy
1885.	Harrison Allen	1915.	G. Hudson Makuen
1886.	E. Fletcher Ingals	1916.	Joseph L. Goodale
1887.	R. P. Lincoln	1917.	Thomas H. Halstead
1888.	E. C. Morgan	1918.	Cornelius G. Coakley
1889.	J. N. Mackenzie	1919.	Norval H. Pierce
1890.	W. C. Glasgow	1920.	Harris P. Mosher
1891.	S. W. Langmaid	1921.	Harmon Smith
1892.	M. J. Asch	1922.	Emil Mayer
1893.	D. Bryson Delavan	1923.	J. Payson Clark
1894.	J. O. Roe	1924.	Lee Wallace Dean
1895.	W. H. Daly	1925.	Greenfield Sluder
1896.	C. H. Knight	1926.	Chevalier Jackson
1897.	T. R. French	1927.	D. Bryson Delavan
1898.	W. E. Casselberry	1928.	Charles W. Richardson
1899.	Samuel Johnston	1929.	Lewis A. Coffin
1900.	H. L. Swain	1930.	Francis R. Packard
1901.	J. W. Farlow	1931.	George E. Shambaugh
1902.	J. H. Bryan	1932.	George Fetterolf
1903.	J. H. Hartman	1933.	George M. Coates
1904.	C. C. Rice	1934.	Dunbar Roy
1905.	J. W. Gleitsman	1935.	Burt R. Shurly
1906.	A. W. deRoaldes	1936.	William B. Chamberlain
1907.	H. S. Birkett	1937.	John F. Barnhill
1908.	A. Coolidge, Jr.	1938.	George B. Wood

1939. James A. Babbitt	1954. Henry B. Orton
1940. Gordon Berry	1955. Bernard J. McMahon
1941. Thomas E. Carmody	1956. LeRoy A. Schall
1942-3. Charles J. Imperatori	1957. Harry P. Schenck
1944-5. Harold I. Lillie	1958. Fred W. Dixon
1946. Frank R. Spencer	1959. William J. McNally
1947. Arthur W. Proetz	1960. Edwin N. Broyles
1948. Frederick T. Hill	1961. Dean M. Lierle
1949. Ralph A. Fenton	1962. Francis E. LeJeune
1950. Gordon B. New	1963. Anderson C. Hilding
1951. H. Marshall Taylor	1964. Albert C. Furstenberg
1952. Louis H. Clerf	1965. Paul H. Holinger
1953. Gordon F. Harkness	

Vice-Presidents

1879. F. H. Davis	J. O. Roe
1880. W. C. Glasgow	W. Porter
1881. E. L. Shurly	E. F. Ingals
1882. C. Seiler	S. Johnston
1883. S. W. Langmaid	W. H. Daly
1884. J. H. Hartman	G. W. Major
1885. H. A. Johnson	J. N. Mackenzie
1886. E. C. Morgan	S. W. Langmaid
1887. J. N. Mackenzie	C. E. DeM. Sajous
1888. W. C. Glasgow	C. E. Bean
1889. E. Holden	J. H. Hartman
1890. J. O. Roe	S. Johnston
1891. M. J. Asch	J. C. Mulhall
1892. S. Johnston	W. E. Casselberry
1893. J. C. Mulhall	S. H. Chapman
1894. C. C. Rice	A. W. deRoaldes
1895. J. Wright	D. N. Rankin
1896. T. M. Murray	H. S. Birkett
1897. A. W. MacCoy	F. W. Hinkel
1898. J. W. Farlow	M. R. Brown
1899. T. A. DeBlois	A. A. Bliss
1900. H. L. Wagner	

1901. J. W. Gleitsmann	D. Braden Kyle
1902. G. A. Leland	T. Melville Hardie
1903. J. H. Lowman	W. Peyre Porcher
1904. Thomas Hubbard	W. J. Freeman
1905. J. L. Goodale	C. W. Richardson
1906. G. H. Makuen	A. B. Thrasher
1907. J. P. Clark	J. E. Rhodes
1908. E. Mayer	F. R. Packard
1909. C. G. Coakley	H. P. Mosher
1910. Robert C. Myles	J. M. Ingersoll
1911. F. C. Cobb	B. R. Shurly
1912. A. W. Watson	W. Scott Renner
1913. F. E. Hopkins	Geo. F. Shambaugh
1914. Clement T. Theisen	Lewis A. Coffin
1915. J. Gordon Wilson	Christian R. Holmes
1916. Thomas H. Halsted	Greenfield Sluder
1917. John Edwin Rhodes	D. Crosby Greene
1918. G. E. Shambaugh	John R. Winslow
1919. Francis R. Packard	Harmon Smith
1920. Harmon Smith	W. B. Chamberlin
1921. Dunbar Roy	Robert C. Lynch
1922. George Fetterolf	Lorenzo B. Lockard
1923. Hubert Arrowsmith	Joseph B. Greene
1924. Ross H. Skillern	Gordon Berry
1925. John E. Mackenty	Robert Levy
1926. Lewis A. Coffin	William V. Mullin
1927. Charles W. Richardson	Hill Hastings
1928. Robert Clyde Lynch	Francis P. Emerson
1929. William B. Chamberlin	Ralph Albert Fenton
1930. Harris P. Mosher	James A. Babbitt
1931. Joseph B. Greene	E. Ross Faulkner
1932. Gordon Berry	Frank A. Spencer
1933. E. Ross Faulkner	Thomas S. Carmody
1934. Gordon B. New	Samuel McCullagh
1935. Edward C. Sewall	H. Marshall Taylor

1936. William P. Wherry	Harold I. Lillie
1937. Frank R. Spencer	Bernard J. McMahon
1938. Ralph A. Fenton	Frederick T. Hill
1939. John H. Foster	Thomas R. Gittins
1940. Charles H. Porter	Gordon F. Harkness
1941. Arthur W. Proetz	Henry B. Orton
1942-3. Harold I. Lillie	Dean M. Lierle
1944-5. John J. Shea	Thomas C. Galloway
1946. H. Marshall Taylor	C. Stewart Nash
1947. John J. Shea	Frederick A. Figi
1948. Henry B. Orton	Anderson C. Hilding
1949. LeRoy A. Schall	Fletcher D. Woodward
1950. W. Likely Simpson	Lyman G. Richards
1951. Wm. J. McNally	Thomas C. Galloway
1952. J. Mackenzie Brown	Edwin N. Broyles
1953. Claude C. Cody	Daniel S. Cunning
1954. James H. Maxwell	Clyde A. Heatly
1955. Robert L. Goodale	Paul H. Holinger
1956. Henry M. Goodyear	Robert E. Priest
1957. Francis E. LeJeune	Pierre P. Viole
1958. Charles Blassingame	Chevalier L. Jackson
1959. James Maxwell	Oliver Van Alyea
1960. Walter Theobald	Anderson Hilding
1961. Julius W. McCall	P. E. Ireland
1962. Paul M. Moore	Jerome A. Hilger
1963. Paul M. Holinger	Lester A. Brown
1964. G. Slaughter Fitz-Hugh	Daniel C. Baker
1965. C. E. Munoz-MacCormick	Arthur J. Cracovaner

Secretaries and Treasurers

1879. G. M. Lefferts	1895. H. L. Swain
1882. D. Bryson Delavan	1900. P. E. Newcomb
1889. C. H. Knight	1911. Harmon Smith

Secretaries

1912. Harmon Smith	1939. Charles J. Imperatori
1918. D. Bryson Delavan	1942. Arthur W. Proetz
1919. J. M. Ingersoll	1947. Louis H. Clerf
1920. George M. Coates	1952. Harry P. Schenck
1933. William V. Mullin	1957. James H. Maxwell
1935. James A. Babbitt	1959. Lyman G. Richards

Treasurers

1912. J. Payson Clark	1939. Frederick T. Hill
1923. George Fetterolf	1948. Gordon F. Harkness
1932. William V. Mullin	1953. Fred W. Dixon
1933. James A. Babbitt	1958. Francis E. LeJeune
1935. Charles J. Imperatori	1962. Alden H. Miller

Librarians

1879. F. H. Bosworth	1930. John F. Barnhill
1883. T. R. French	1934. Burt R. Shurly
1903. J. H. Bryan	1935. George M. Coates

Librarian and Historian

1936. George M. Coates	1944. Louis H. Clerf
------------------------	----------------------

Librarian, Historian and Editor

1947. Harry P. Schenck	1955. Edwin N. Broyles
1952. Bernard J. McMahon	1960. Francis W. Davison
1964. F. Johnson Putney	

PAST FELLOWS

Dates indicate original election to the Association

**Deceased*

Honorary Fellows

- *1908. Barnhill, John F., Miami Beach, Florida.
- *1893. Birkett, Herbert S., Montreal, Canada.
- *1878. Bosworth, Francke H., New York City.
- *1917. Coates, George M., Philadelphia, Pa.
- *1918. Dean, Lee Wallace, St. Louis, Mo.
- *1881. Delavan, D. Bryson, New York City.
- *1893. deRoaldes, Arthur W., New Orleans, La.
- *1890. De La Sota Y. Lastra, Ramon, Seville, Spain.
- *1923. Fenton, Ralph A., Portland, Oregon
- *1879. French, Thomas R., Brooklyn, N. Y.
- *1880. Garcia, Senior Manuel, London, England.
- *1903. Harris, Thos. J., New York City.
- *1907. Jackson, Chevalier, Schwenksville, Pa.
- *1878. Johnston, Samuel, Baltimore, Md.
- *1878. Lefferts, George Morewood, Katonah, N. Y.
- *1914. Levy, Robert, Denver, Colo.
- *1918. Lewis, Fielding O., Media, Pa.
- *1883. Mackenzie, John N., Baltimore, Md.
- *1881. Mackenzie, Sir Morel, London, England.
- *1910. Masser, Ferdinand, Naples, Italy.
- *1904. Mosher, Harris P., Marblehead, Mass.
- *1910. Moure, J. J. E., Bordeaux, France.
- *1937. Nager, F. R., Zurich, Switzerland.
- *1918. Oliver, H. K., Boston, Mass.
- *1906. Pierce, Norval Harvey, San Diego, Calif.
- *1924. Proetz, Arthur C., St. Louis, Mo.
- *1909. Semon, Sir Felix, Great Missenden, England.
- *1878. Solis-Cohen, J., Philadelphia, Pa.
- *1889. Swain, Henry L., New Haven, Conn.
- *1914. Thomson, Sir St. Clair, London, Eng.
- *1903. Tilley, Herbert, London, England.
- *1914. Wagner, Clinton, New York City.
- *1890. Wright, Jonathan, Pleasantville, N. Y.

Corresponding Fellows

- *1892. Browne, Lennox, London, England.
- *1938. Blair, Vilray P., St. Louis, Missouri.
- *1940. Colledge, Lionel, London, England.
- *1901. Collier, Mayo, Kearsney Abbey, Kent, England.
- *1893. Desvernine, Carlos M., Havana, Cuba.
- *1930. Emerson, Francis P., Franklin, Mass.
- *1961. Faaborg-Andersen, Knud, Nykobing, Denmark.
- *1936. Fraser, John S., Edinburgh, Scotland.
- *1901. Grant, Sir James Dundas, London, England.
- *1887. Cougenheim, A., Paris, France.
- *1894. Holden, Edgar, Newark, N. J.
- *1919. Kelly, Adam Brown, Helensburgh, Scotland.
- *1881. Labus, Carlo, Milan, Italy.
- *1950. Larsell, Olof, Portland, Oregon.
- *1931. LasSagna, Francesco, Parma, Italy.
- *1926. Law, Frederick M., New York, N. Y.
- *1921. LeMaitre, Ferdinand, Paris, France.
- *1902. Lermoyez, Marcel, Paris, France.
- *1897. Luc, H., Paris, France.
- *1896. MacDonald, Greville, Haslemere, Surrey, England.
- *1894. MacIntyre, John, Glasgow, Scotland.
- *1903. McBride, P., York, England.
- *1920. McKenzie, Dan, London, England.
- *1919. McKernon, James F., New Canaan, Conn.
- *1880. Meyer, Wilhelm, Copenhagen, Denmark.
- *1910. Moure, J. J. E., Bordeaux, France.
- *1896. Mygind, Holger, Copenhagen, Denmark.
- *1950. Neil, James Hardie, Auckland, New Zealand.
- *1919. Paterson, Donald Rose, Cardiff, Wales.
- *1941. Patterson, Norman, Herts, England.
- *1919. Rogers, John, Jr., New York City.
- *1894. Sajous, C. E. DeM., Philadelphia, Pa.
- *1896. Schmiegelow, Ernst, Copenhagen, Denmark.
- *1946. Segura, Eliseo, Buenos Aires, Argentina.
- *1940. Soto, E. Fernandez, Havana, Cuba.
- *1881. Thornton, Pugin, London, England.
- *1913. Turner, A. Logan, Edinburgh, Scotland.
- *1880. Whistler, W. McNeil, London, England.
- *1901. Wingrave, Wyatt, Lyme Regis, Dorset, England.
- *1894. Wolfenden, R. Norris, Kent, England.

Emeritus Fellows

- *1936. Ballenger, Howard C., Winnetka, Ill.
- *1923. Barlow, Roy A., Nova Scotia, Canada.
- *1915. Barnes, Harry Aldrich, Kingston, Mass.
- *1928. Beck, Joseph C., Chicago, Illinois.
- *1921. Berry, Gordon, Worcester, Mass.
- *1941. Bowers, Wesley C., New York, N. Y.
- *1901. Brown, J. Price, Toronton, Canada.
- *1891. Bryan, Joseph H., Washington, D. C.
- *1913. Butler, Ralph, Philadelphia, Pa.
- *1930. Campbell, Edward H., Philadelphia, Pa.
- *1897. Clark, J. Payson, Boston, Mass.
- *1899. Cobb, Frederick C., Bradenton, Florida.
- *1939. Cody, Claude C., Jr., Houston, Texas.
- *1905. Coffin, Lewis A., New York City.
- *1893. Coolidge, Algernon, Boston, Mass.
- *1937. Crowe, Samuel J., Baltimore, Maryland.
- *1941. Cunning, Daniel S., New York City.
- *1913. Dabney, Virginius, Washington, D. C.
- *1882. De Blois, Thomas Amory, Boston, Mass.
- *1892. Farlow, John W., Boston, Mass.
- *1922. Forbes, Henry H., New York City.
- *1933. Foster, John H., Houston, Texas.
- *1905. Freer, Otto T., Chicago, Ill.
- *1940. Gatewood, E. Tribble, Richmond, Va.
- *1880. Gleitsmann, Joseph W., New York City.
- *1922. Goldsmith, Perry G., Toronto, Canada.
- *1898. Goodale, Joseph L., Ipswich, Mass.
- *1932. Graham, Harrington B., San Francisco, California.
- *1906. Greene, D. Crosby, Jr., Boston, Mass.
- *1917. Greene, Joseph B., Asheville, N. C.
- *1950. Hall, Colby, Encino, Calif.
- *1905. Halsted, Thomas H., Los Angeles, Calif.
- *1896. Hardie, Thomas Melville, Chicago, Ill.
- *1915. Hastings, Hill, Los Angeles, Calif.
- *1944. Havens, Fred Z., Rochester, Minn.
- *1888. Hinkel, Frank Whitehill, Buffalo, New York.
- *1895. Hopkins, Frederick E., Springfield, Mass.
- *1927. Hubbard, Thomas, Toledo, Ohio.
- *1919. Hurd, Lee Maidment, Rowayton, Conn.
- *1920. Imperatori, Charles J., Essex, N. Y.

- *1904. Ingersoll, John Marvin, Miami, Fla.
- *1939. Johnston, William H., Santa Barbara, Calif.
- *1918. Kenyon, Elmer L., Chicago, Ill.
- *1921. Kernan, John D., New York
- *1929. Kistner, Frank B., Portland, Oregon.
- *1885. Knight, Charles H., New York City.
- *1939. Large, Secord H., Cleveland, Ohio.
- *1894. Leland, George A., Boston, Mass.
- *1922. Lillie, Harold I., Rochester, Minn.
- *1943. Lincoln, William R., Cleveland, Ohio.
- *1928. Lyman, Harry Webster, St. Louis, Mo.
- *1886. MacCoy, Alexander W., Philadelphia, Pa.
- *1941. Martin, Robert C., San Francisco, Cal.
- *1896. Mayer, Emil, New York City.
- *1951. McCart, Howard W. D., Toronto, Canada.
- *1939. McCaskey, Carl H., Indianapolis, Indiana.
- *1943. McCullagh, Samuel, New York, N. Y.
- *1923. McKinney, Richmond, Memphis, Tenn.
- *1928. MacPherson, Duncan, New York, N. Y.
- *1939. Myers, John L., Kansas City, Mo.
- *1922. New, Gordon B., Rochester, Minn.
- *1878. Porter, William, Ocean Springs, Miss.
- *1901. Myles, Robert C., New York City.
- *1923. Newhart, Horace, Minneapolis, Minn.
- *1903. Packard, Francis R., Philadelphia, Pa.
- *1942. Potts, John B., Omaha, Nebr.
- *1903. Renner, W. Scott, Buffalo, N. Y.
- *1897. Rhodes, John Edwin, Chicago, Ill.
- *1884. Rice, Clarence C., New York City.
- *1905. Richards, George L., South Yarmouth, Mass.
- *1878. Robinson, Beverly, New York City.
- *1921. Sauer, William E., St. Louis, Mo.
- *1923. Sewall, Edward C., Palo Alto, Cal.
- *1930. Seydell, Ernest M., Wichita, Kansas
- *1907. Shambaugh, George E., Chicago, Ill.
- *1908. Smith, Harmon, New York City.
- *1923. Spencer, Frank R., Boulder, Colo.
- *1927. Tobey, Harold G., Boston, Mass.
- *1925. Tucker, Gabriel, Haverford, Pa.

- *1892. Wagner, Henry L., San Francisco, Calif.
- *1892. Watson, Arthur W., Philadelphia, Pa.
- *1948. Whalen, Edward J., Hartford, Conn.
- *1922. White, Francis W., New York, N. Y.
- *1939. Wilson, J. Gordon, Old Bennington, Vt.
- *1905. Wood, George B., Wynnewood, Pa.

Active Fellows

- *1880. Allen, Harrison, Philadelphia, Pa.
- *1917. Arrowsmith, Hubert, Brooklyn, N. Y.
- *1879. Asch, Morris J., New York City.
- *1942. Ashley, Rae E., San Francisco, Cal.
- *1923. Babbitt, James A., Philadelphia, Pa.
- *1906. Ballenger, William L., Chicago, Ill.
- *1880. Bean, C. E., St. Paul, Minn.
- *1949. Beck, August L., New Rochelle, N. Y.
- *1904. Berens, T. Passmore, New York City.
- *1924. Bigelow, Nolton, Providence, R. I.
- *1938. Blassingame, Charles D., Memphis, Tenn.
- *1893. Bliss, Arthur Ames, Philadelphia, Pa.
- *1951. Boyden, Guy L., Portland, Oregon
- *1895. Boylan, J. E., Cincinnati, Ohio.
- *1932. Brown, John Mackenzie, Los Angeles, Calif.
- *1892. Brown, Moreau R., Chicago, Ill.
- *1933. Buckley, Robert E., New York City.
- *1915. Canfield, R. Bishop, Ann Arbor, Mich.
- *1934. Carmack, John Walter, Indianapolis, Ind.
- *1924. Carmody, Thomas E., Denver, Colo.
- *1889. Casselberry, William E., Chicago, Ill.
- *1883. Chamberlain, C. W., Hartford, Conn.
- *1917. Chamberlin, William B., Cleveland, Ohio.
- *1896. Chappell, W. F., New York City.
- *1882. Chapman, S. Hartwell, New Haven, Conn.
- *1902. Coakley, Cornelius G., New York City.
- *1913. Coffin, Rockwell C., Boston, Mass.
- 1918. Cox, Gerald H., New York City.
- *1880. Cushing, E. W., Boston, Mass.
- *1878. Cutter, Ephraim, West Falmouth, Mass.
- *1880. Daly, W. H., Pittsburgh, Pa.
- *1878. Davis, F. H., Chicago, Ill.
- *1941. Davis, Warren B., Philadelphia, Pa.

1926. Dennis, Frank Lownes, Colorado Springs, Col.
*1901. Dickerman, E. T., Chicago, Ill.
*1878. Donaldson, Frank, Baltimore, Md.
*1947. Engler, Clarence W., Cleveland, Ohio.
*1954. Equen, Murdock S., Atlanta, Ga.
*1935. Eves, Curtis C., Philadelphia, Pa.
*1919. Faulkner, E. Ross, New York City.
*1914. Fetterolf, George, Philadelphia, Pa.
*1901. Freeman, Walter J., Philadelphia, Pa.
*1917. Friedberg, Stanton A., Chicago, Ill.
1940. Fuchs, Valentine H., New Orleans, La.
*1897. Frothingham, Richard, New York City.
1909. Getchell, Albert C., Worcester, Mass.
*1907. Gibb, Joseph S., Philadelphia, Pa.
*1940. Gill, William D., San Antonio, Texas.
*1878. Glasgow, William Carr, St. Louis, Mo.
*1913. Goldstein, Max A., St. Louis, Mo.
*1905. Grayson, Charles P., Philadelphia, Pa.
*1934. Grove, William E., Milwaukee, Wisconsin.
*1933. Harkness, Gordon F., Davenport, Iowa.
*1878. Hartman, J. H., Baltimore, Md.
*1945. Hickey, Harold L., Denver, Colo.
*1879. Holden, Edgar, Newark, N. J.
*1907. Holmes, Christian R., Cincinnati, Ohio.
*1882. Hooper, Franklin H., Boston, Mass.
*1893. Hope, George B., New York City.
*1938. Hourn, George E., St. Louis, Mo.
*1939. Hunt, Westley Marshall, New York, N. Y.
*1901. Hyatt, Frank, Washington, D. C.
*1925. Iglauer, Samuel, Cincinnati, Ohio.
*1878. Ingals, E. Fletcher, Chicago, Ill.
*1882. Ives, Frank L., New York City.
*1938. Jackson, Chevalier L., Philadelphia, Pa.
*1880. Jarvis, William C., New York City.
*1878. Johnson, Hosmer A., Chicago, Ill.
*1879. Johnson, Woolsey, New York City.
*1960. Johnston, Kenneth C., Chicago, Ill.
*1944. Jones, Marvin F., New York City.
*1879. Kealhofer, R. H., St. Louis, Mo.
*1942. King, Edward D., North Hollywood, Calif.
*1901. King, Gordon, New Orleans, La.

- *1885. Knight, Charles H., New York City.
- *1878. Knight, Frederick Irving, Boston, Mass.
- *1898. Kyle, D. Braden, Philadelphia, Pa.
- *1880. Langmaid, Samuel W., Boston, Mass.
- *1878. Lincoln, Rufus P., New York City.
- *1911. Lockard, Lorenzo B., Denver, Colo.
- *1913. Loeb, Hanau W., St. Louis, Mo.
- *1897. Logan, James E., Kansas City, Mo.
- *1935. Looper, Edward A., Baltimore, Maryland.
- *1888. Lowman, John H., Cleveland, Ohio.
- *1919. Lynah, Henry L., New York City.
- *1952. Lynch, Mercer G., New Orleans, La.
- *1915. Lynch, Robert Clyde, New Orleans, La.
- *1879. McBurney, Charles, New York City.
- *1927. McGinnis, Edwin, Chicago, Ill.
- 1936. McGregor, Gregor, Toronto, Canada.
- *1913. McKimmie, O. A., Washington, D. C.
- *1945. McLaurin, John G., Dallas, Texas.
- *1885. McSherry, H. Clinton, Baltimore, Md.
- *1914. Mackenty, John E., New York City.
- *1898. Makuen, G. Hudson, Philadelphia, Pa.
- *1881. Major, G. W., Montreal, Canada.
- *1948. Maxwell, James H., Ann Arbor, Mich.
- *1881. Morgan, E. C., Washington, D. C.
- *1950. Morrison, Lewis F., San Francisco, Calif.
- *1940. Morrison, William W., New York City.
- *1886. Mulhall, J. C., St. Louis, Mo.
- *1925. Mullin, William V., Cleveland, Ohio.
- *1914. Munger, Carl E., Waterbury, Conn.
- *1892. Murray, T. Morris, Washington, D. C.
- *1881. Mynter, H., Buffalo, N. Y.
- *1893. Newcomb, James E., New York City.
- *1895. Nichols, J. E. H., New York City.
- *1927. Orton, Henry B., Newark, N. J.
- *1894. Park, William H., New York City.
- *1892. Porcher, W. Peyre, Charleston, S. C.
- *1927. Porter, Charles T., Boston, Mass.
- *1908. Randall, B. Alexander, Philadelphia, Pa.
- *1882. Rankin, D. N., Allegheny, Pa.
- *1902. Richardson, Charles W., Washington, D. C.
- *1930. Ridpath, Robert E., Philadelphia, Pa.

- *1879. Roe, John O., Rochester, N. Y.
- *1945. Robb, James M., Detroit, Michigan.
- *1881. Robertson, J. M., Detroit, Mich.
- *1913. Roy, Dunbar, Atlanta, Ga.
- *1878. Rumbold, T. F., St. Louis, Mo.
- *1879. Seiler, Carl, Philadelphia, Pa.
- *1928. Shea, John Joseph, Memphis, Tennessee.
- *1893. Shields, Charles M., Richmond, Pa.
- *1909. Shurly, Burt R., Detroit 1, Mich.
- *1878. Shurly, E. L., Detroit, Mich.
- *1892. Simpson, William Kelly, New York City.
- *1919. Skillern, Ross H., Philadelphia, Pa.
- *1909. Sluder, Greenfield, St. Louis, Mo.
- *1879. Smith, Andrew H., Geneva, N. Y.
- *1932. Smyth, Duncan Campbell, Boston, Mass.
- *1928. Sonnenschein, Robert, Chicago, Ill.
- 1924. Stein, Otto J., Chicago, Ill.
- 1934. Stevenson, Walter, Quincy, Ill.
- *1911. Staut, George C., Philadelphia, Pa.
- *1879. Tauber, Bernhard, Cincinnati, Ohio.
- *1924. Taylor, Hermon Marshall, Jacksonville, Fla.
- *1903. Theisen, Clement F., Albany, N. Y.
- *1899. Thorner, Max, Cincinnati, Ohio.
- *1892. Thrasher, Allen B., Cincinnati, Ohio.
- *1937. Tobey, George L., Jr., Boston, Mass.
- *1888. Van der Poel, S. O., New York City.
- *1938. Vail, Harris H., Cincinnati, Ohio.
- *1936. Voislowsky, Antonie P., New York City.
- *1933. Wanamaker, Allison T., Seattle, Wash.
- 1896. Ward, Marshall R., Pittsburgh, Pa.
- *1879. Ward, Whitfield, New York City.
- *1886. Westbrook, Benjamin F., Brooklyn, N. Y.
- *1924. Wherry, William P., Omaha, Neb.
- *1924. White, Leon E., Boston, Mass.
- *1939. Williams, Horace J., Philadelphia, Pa.
- *1942. Wishart, D. E. Staunton, Toronto, Canada.
- *1922. Wishart, David J. G., Toronto, Ontario.
- *1940. Wood, V. Visscher, St. Louis, Mo.
- *1896. Wollen, Green V., Indianapolis, Ind.
- *1953. Wilkerson, William W., Nashville, Tenn.

INDEX

to the

TRANSACTIONS

of the

AMERICAN
LARYNGOLOGICAL ASSOCIATION

1966

INDEX

A

Address	
Guest of Honor:	
Lederer, Francis L.	15
Anesthesia	
Exploration of mediastinum with local (Ward, Stephenson, Jr. and Harris)	114
Arthrodesis	
Cricothyroid (Montgomery)	136
Atkins, Joseph P.	
Metastatic Carcinoma of the Esophagus	102
Atresia	
Surgical correction of choanal (Cherry and Bordley)	127
Approach to the Internal Laryngo- cele and other Submucosal Lesions of the Larynx (Yarrington and Frazer)	155

B

Bordley, John E.	
(see Cherry, Jerry)	127
Bryce, Douglas P.	
Prolapse of the Laryngeal Ventricle	161

C

Cancer	
Pre-operative radiation in head and neck (Skolnik, Tenta and Comito)	78
Carcinoma	
Histopathology of Larynges and Radical Neck Specimens in a combined radiation and surgery program (Goldman)	55

Metastatic of the Esophagus (Atkins)	102
---	-----

Cells	
Ultrastructure during regenera- tion (Hilding and Hilding)	22

Cherry, Jerry	
Surgical Correction of Choanal Atresia (with John E. Bordley) ..	127

Choana	
Surgical Correction of Atresia (Cherry and Bordley)	127

Cilia	
Ultrastructure during Regenera- tion (Hilding and Hilding)	22

Classification	
Early malignant lesions of the Oral Cavity, Pharynx and Larynx (Wied)	21

Comito, John N.	
(see Skolnik, Emanuel M.)	78

Cricothyroid Arthrodesis (Montgomery)	136
--	-----

Curran, Timothy	
Obituary of Edward Joseph Whalen	189

E

Erich, John B.	
Obituary of Fred Z. Havens	178

Esophagus	
Metastatic Carcinoma (Atkins) ..	102

Exploration of Mediastinum under Local Anesthesia (Ward, Stephenson, Jr. and Harris)	114
--	-----

F

- Frazer, John P.
(see Yarrington, C. T., Jr.) 155

- Further Efforts for Correction of
Severe Acute or Chronic Laryn-
geal Stenosis; Double Posted
Teflon Tube Utilization (Knight) 148

G

- Goldman, Joseph L.
Histopathology of Larynges and
Radical Neck Specimens in a
Combined Radiation and
Surgery program for advanced
Carcinoma of the Larynx and
Laryngopharynx 55

H

- Harris, Perry F.
(see Ward, Paul H.) 114

- Head
Pre-operative Radiation in Cancer
(Skolnik, Tenta and Comito) .. 78

- Hilding, A.
(see Hilding, D.) 22

- Hilding, D.
Ultrastructure of Tracheal Cilia
during regeneration (with
Anderson C. Hilding) 22

- Hill, Frederick T.
Obituary of Arthur Walter
Proetz 184

- Histologic Classification of Early
Malignant Lesions of the Oral
Cavity, Pharynx and Larynx
(Wied) 21

- Histopathology of Larynges and
Radical Neck Specimens in a
combined Radiation and Surgery
Program for advanced Carcinoma
of the Larynx and Laryngo-
pharynx (Goldman) 55

- Homotransplantation of dog larynx
(Ogura, Kawasaki, Takenouchi
and Yagi) 37

K

- Kawasaki, Masashi
(see Ogura, Joseph H.) 37

- Knight, John S.
Further efforts for Correction of
Severe Acute or Chronic
Laryngeal Stenosis; Double
Posted Teflon Tube Utilization 148

L

- Laryngeal
Correction of Severe Acute or
Chronic Stenosis; Double
Posted Teflon Tube Utilization
(Knight) 148
Prolapse of Ventricle (Bryce) 161

- Laryngopharynx
Histopathology in a Combined
Radiation and Surgery Program
for Advanced Carcinoma
(Goldman) 55

- Larynx
Approach to Internal Laryngocele
and other Submucosal Lesions
(Yarrington and Frazer) 155

- Histological Classification of
Early Malignant Lesions
(Wied) 21

- Histopathology in a Combined
Radiation and Surgery Program
for Advanced Carcinoma
(Goldman) 55

- Replantation and Homotransplan-
tation of Dog Larynx (Ogura,
Kawasaki, Takenouchi and
Yagi) 37

- Laryngocele
Approach to Internal and other
Submucosal Lesions (Yarrington
and Frazer) 155

- Lederer, Francis L.
Address of Guest of Honor 15

M

- Malignant Lesions
Histological Classification of Oral
Cavity, Pharynx and Larynx
(Wied) 21
- McCall, Julius W.
Obituary of Fred Willis Dixon 175

- Mediastinum
Exploration under Local
Anesthesia (Ward, Stephenson,
Jr. and Harris) 114
- Metastatic Carcinoma of the
Esophagus (Atkins) 102
- Montgomery, William M.
Cricoidoarytenoid Arthrodesis 136

N

- Neck
Pre-operative Radiation in Cancer
(Skolnik, Tenta and Comito) .. 78
- Neck Dissection
Histopathology in a Combined
Radiation and Surgery Program
for Advanced Carcinoma
(Goldman) 55
- Newlands, W. A.
Obituary of Duncan MacPherson 181

O

- Obituaries
Barlow, Roy Alexander 174
Dixon, Fred Willis 175
Havens, Fred Z. 178
MacPherson, Duncan 181
Proetz, Arthur Walter 184
Whalen, Edward Joseph 189

- Ogura, Joseph H.
Replantation and Hemotransplan-
tation of Dog Larynx (with
Masashi Kawasaki, Satoru Tak-
enouchi and Masokatsu Yagi) .. 37

- Oral Cavity
Histological Classification of
Early Malignant Lesions
(Wied) 21

P

- Pharynx
Histological Classification of
Early Malignant Lesions
(Wied) 21
- Pre-operative Radiation in Head and
Neck Cancer (Skolnik, Tenta
and Comito) 78
- Prolapse of the Laryngeal Ventricle
(Bryce) 161

R

- Radiation
Histopathology of Larynges and
Radical Neck Specimens in a
Combined Surgery Program
for Advanced Carcinoma
(Goldman) 55
- Pre-operative in Head and Neck
Cancer (Skolnik, Tenta and
Comito) 78
- Replantation and Homotransplanta-
tion of the Dog Larynx (Ogura,
Kawasaki, Takenouchi and Yagi) 37

S

- Skolnik, Emanuel M.
Pre-operative Radiation in Head
and Neck Cancer (with Louis
T. Tenta and John N. Comito) 78
- Stenosis
Laryngeal, correction of; double
posted teflon tube utilization
(Knight) 148

- Stephenson Jr., Sam E.
 (see Ward, Paul H.) 114

Surgery

- Histopathology of Larynges and
 Radical Neck Specimens in a
 Combined Radiation Program
 for Advanced Carcinoma
 (Goldman) 55

- Surgical Correction of Choanal
 Atresia (Cherry and Bordley) 127

T

- Takenouchi, Satoru
 (see Ogura, Joseph H.) 37

- Tenta, Louis T.
 (see Skolnik, Emanuel M.) 78

Trachea

- Ultrastructure of Cilia and Cells
 during Regeneration (Hilding
 and Hilding) 22

Teflon tube

- Correction of severe acute or
 chronic stenosis (Knight) 148

U

- Ultrastructure of Tracheal Cilia
 and Cells during Regeneration
 (Hilding and Hilding) 22

V

Ventricle

- Laryngeal prolapse (Bryce) 161

Ward, Paul H.

- Exploration of Mediastinum under
 local anesthesia (with Sam E.
 Stephenson, Jr. and Perry F.
 Harris) 114

W

Wied, George L.

- Histological Classification of
 early malignant lesions of the
 Oral Cavity, Pharynx and
 Larynx 21

Y

Yagi, Masokatsu

- (see Ogura, Joseph H.) 37

Yarrington, C. T. Jr.

- An approach to the internal
 laryngocele and other submu-
 cosal Lesions of the Larynx
 (with John P. Frazer) 155

