

Transactions

American Laryngological Association

EIGHTY-EIGHTH VOLUME

“DOCENDO DISCIMUS”

TRANSACTIONS
OF THE
EIGHTY-EIGHTH ANNUAL MEETING
OF THE
American
Laryngological Association

1967

HELD AT
THE SEIGNIORY CLUB
MONTEBELLO, CANADA
MAY 15 AND 16, 1967

PUBLISHED BY THE ASSOCIATION

ST. LOUIS, MO.

1967

Contents.

	PAGE
List of Officers	7
Registration	9
Presidential Address: Joel J. Pressman, M.D.	11
Introduction of Guest of Honor, Joel J. Pressman, M.D.	18
Address of Guest of Honor: W. J. McNally, M.D.	20
SYMPOSIUM ON THE INFANT LARYNX	
Physiology of the Fetal Larynx and Lung . Forrest Adams, M.D.	24
Discussion:	
Theodore E. Walsh, M.D.	33
Francis A. Sooy, M.D.	33
John A. Kirchner, M.D.	33
Forrest Adams, M.D. (closing)	33
Congenital Anomalies of the Larynx. Paul A. Holinger, M.D.	35
Inflammatory Diseases of the Larynx of Infants and Small Children. Francis W. Davison, M.D.	45
Treatment of Airway Problems in the Newborn. Charles F. Ferguson, M.D.	55

CONTENTS

	PAGE
Laryngomalacia: Its Radiologic Demonstration. J. Scott Dunbar, M.D.	68
Discussion:	
Robert B. Lewy, M.D.	69
W. Franklin Keim, M.D.	70
Charles F. Ferguson, M.D.	70
Francis W. Davison, M.D. (closing)	70
Laryngeal Reflex Pathways Related to Rate and Rhythm of the Heart. Masafumi Suzuki, M.D., John A. Kirchner, M.D.	71
SYMPOSIUM ON LARYNGEAL TRAUMA	
Biomechanics of Injury to the Larynx and Adjacent Structures. Alan Nahum, M.D.	78
Laryngotracheal Injuries. Robert E. Priest, M.D.	83
The 'Trough' Method of Laryngotracheal Reconstruction. Douglas P. Bryce, M.D.	91
Discussion:	
Charles Morgan Norris, M.D.	102
Herbert Harris, M.D.	103
John S. Knight, M.D.	104
Joseph H. Ogura, M.D.	105
Application of Voiceprint Techniques to Vocal Tract Analysis. L. G. Kersta	106
Discussion:	
Lyman Richards, M.D.	113
Joel J. Pressman, M.D.	113
SYMPOSIUM ON NEWER SURGICAL TECHNIQUES	
Elective Cervical Esophagostomy. G. Slaughter Fitz-Hugh, M.D.	114
Use of the Tubed Pedicle Flap in Head and Neck Surgery. Delmar F. Weaver, M.D.	120

CONTENTS

	PAGE
First Experiences with the Asai Technique for Vocal Rehabilitation After Total Laryngectomy. Alden H. Miller, M.D.	141
Discussion:	
Joseph H. Ogura, M.D.	146
W. Franklin Keim, M.D.	146
Joel J. Pressman, M.D.	147
Lyman G. Richards, M.D.	147
Dr. Miller (closing)	147
Recent Electron Studies, with Special Reference to Respiratory Cilia. G. Edward Tremble, M.D.	148
Discussion:	
Catherine Smith, Ph.D.	157
Carcinoma of the Trachea. Mario J. Acquarelli, M.D.	158
Discussion:	
Joseph P. Atkins, M.D.	166
Douglas P. Bryce, M.D.	167
Lawrence R. Boies, M.D.	167
Joel J. Pressman, M.D.	167
Dr. Acquarelli (closing)	167
Memorials:	
Karl Musser Houser	170
DeForest Clinton Jarvis	172
Philip Edward Meltzer	174
Sam E. Roberts	178
Executive Sessions and Reports of Officers and Committees	181
Presentation of Newcomb Award	197

CONTENTS

	PAGE
List of Fellows, 1967	199
Active Fellows	200
Honorary Fellows	206
Corresponding Fellows	207
Emeritus Fellows	208
Benefactors	210
Recipients of the de Roaldes Award	211
Recipients of the Casselberry Award	212
Recipients of the Newcomb Award	213
Past Officers	214
Past Fellows	219
Index	228



THOSE IN ATTENDANCE AT THE EIGHTY-EIGHTH ANNUAL MEETING

Front row, reading left to right: Fitz Hugh, Bryce, Woodman, Smith, Hildings, Miller, Richards, McNally, Pressman, Boies, LeJeune, Tremble, Hill. *Second row:* Jones, Goldman, Lewis, Miller, Cocke, Keim, Cracovaner, Skolnik, Lathrop, Weaver, Pastore, King, Lewy, Pratt, Richardson, O'Neil. *Third Row:* Broyles, Purney, Kirchner, Atkins, Baxter, Montreuil, Weille, Munoz-Mac-Cormick, Converse, Fearon, Henry, Bordley, Priest, Ferguson, Ogura, Cody, O'Keefe, Tapia-Acuna. *Back row:* Simonton, Sooy, Pang, Alfaro, Davison, Hoople, Tribble, Tabb, Work, Knight, Williams, Norris, Tolan, Lierle, Friedberg, Cardwell, Hanckel, Salinger, Harrill.

OFFICERS FOR 1966-1967

PRESIDENT

JOEL J. PRESSMAN, M.D.

FIRST VICE-PRESIDENT

LAWRENCE R. BOIES, M.D.

SECOND VICE-PRESIDENT

G. EDWARD TREMBLE, M.D.

SECRETARY

LYMAN G. RICHARDS, M.D.

TREASURER

ALDEN H. MILLER, M.D.

LIBRARIAN, HISTORIAN AND EDITOR

F. JOHNSON PUTNEY, M.D.

COUNCIL

The above Ex-officio and

FRANCIS E. LeJEUNE, M.D.

ANDERSON C. HILDING, M.D.

ALBERT C. FURSTENBERG, M.D.

PAUL H. HOLINGER, M.D.

TRANSACTIONS OF THE
EIGHTY-EIGHTH ANNUAL MEETING

OF THE

American Laryngological Association

HELD AT

THE SEIGNIORY CLUB

MONTABELLO, CANADA

MAY 15 AND 16, 1967

The Eighty-eighth Annual Meeting of the American Laryngological Association was called to order by the President, Dr. Joel J. Pressman, at the Seignior Club, Montebello, Canada on May 15, 1967, at 8:15 A.M.

REGISTRATION

ALFARO, VICTOR R.

ATKINS, JOSEPH P.

BAXTER, JAMES D.

BOIES, LAWRENCE R.

BORDLEY, JOHN E.

BROYLES, EDWIN N.

BRYCE, DOUGLAS P.

CARDWELL, EDGAR P.

COCKE, EDWIN W.

CODY, CLAUDE C., III

CONVERSE, JOHN M.

CRACOVANER, ARTHUR J.

DALY, JOHN F.

DAVISON, FRANCIS W.

DEVINE, KENNETH D.

FEARON, BLAIR

FERGUSON, CHARLES F.

FITZ-HUGH, GLASSSELL SLAUGHTER

FRIEDBERG, STANTON A.

GOLDMAN, JOSEPH L.

HANCKEL, RICHARD W.	O'NEIL, JAMES J.
HARRILL, JAMES A.	PANG, LUP Q.
HARRIS, HERBERT	PASTORE, PETER N.
HENRY, G. ARNOLD	PRATT, LORING W.
HILDING, ANDERSON C.	PRESSMAN, JOEL J.
HILL, FREDERICK T.	PRIEST, ROBERT E.
HOOPLE, GORDON D.	PUTNEY, F. JOHNSON
JONES, EDLEY H.	RICHARDS, LYMAN G.
KEIM, W. FRANKLIN	RICHARDSON, JOHN R.
KING, JAMES T.	SALINGER, SAMUEL
KIRCHNER, JOHN A.	SILCOX, LOUIS E.
KNIGHT, JOHN S.	SIMONTON, KINSEY M.
LATHROP, FRANK D.	SKOLNIK, EMANUEL
LEJEUNE, FRANCIS E.	SMITH, AUSTIN T.
LEWIS, JOHN S.	SOOY, FRANCIS A.
LEWY, ROBERT B.	TABB, HAROLD G.
LIERLE, DEAN M.	TAPIA ACUNA, RICARDO
LINDSAY, JOHN R.	TOLAN, JOHN F.
M McNALLY, WILLIAM J.	TREMBLE, G. EDWARD
MILLER, ALDEN H.	TRIBLE, WILLIAM MACL.
MILLER, DANIEL	WALSH, THEODORE E.
MONTREUIL, FERNAND	WEAVER, DELMAR F.
MUNOZ-MACCORMICK, CARLOS E.	WEILLE, FRANCIS L.
MURTAGH, JOHN A.	WILLIAMS, HENRY L.
NORRIS, CHARLES M.	WOODMAN, DEGRAAF
OGURA, JOSEPH H.	WORK, WALTER P.
O'KEEFE, JOHN J.	

OPENING SESSION

SCIENTIFIC SESSION

MONDAY MORNING, MAY 15, 1967

The first Scientific Session of the Eighty-eighth Annual Meeting of the American Laryngological Association, Inc., held at the Seignior Club, Montebello, Canada, convened on May 15, 1967, at eight thirty-nine o'clock, Joel J. Pressman, M.D., Los Angeles, California, President of the Association, presiding.



PRESIDENTIAL ADDRESS

It is my very great pleasure to welcome you to this 88th meeting of the American Laryngological Association, and my privilege to deliver the Presidential Address which event has been a tradition since its very first meeting.

We are an association rich in tradition and in studying its *Transactions* from the very first to the most recent, I find that the bonds which tie us to the past have been our strength through these many decades; for the traditions established by the Founders have borne up well in the test of time.

Luckily for you, I do not have the oratorical urge of the first President, for his address covers more than 170 pages of the first *Transactions* of which 58 were text and 113 bibliography, with references covering a span of 70 years beginning in 1809, and with further references in the text to writings as far back as 1638. To those of you interested in the history of laryngology I can heartily recommend this address of your first President as a most interesting, authoritative classic, which in itself established a tradition of scholarly effort and achievement that has been the Keynote of this Association ever since.

In 1894, President D. Bryson Delavan, citing the question in his mind of the desirability of having any Presidential address at all, pointed to it as a highly desirable event, since it offered an opportunity to call attention to ideas and suggestions of timely interest, and to record and study events of historic value in the career of the Association.

We belong to a very wonderful Association indeed and, of course, a very old one. As a matter of fact, it is one of the oldest national surgical specialty

societies in the United States. Our Association was founded in 1878 in Buffalo, New York by a group of twelve who had convened there for the purpose. The first official meeting was held in New York City a year later on June 10, 11, and 12, 1879, with Dr. Louis Elsberg of New York as its first President. After the morning session of the first day, a special meeting of the Fellows was called to allow the election to Fellowship of certain well known laryngologists whose names were to be considered, along with the original twelve, as having been omitted inadvertently at the meeting in Buffalo. After "much discussion" and unmistakable evidence of some ill feeling, eleven names were added to the list to be considered as original Fellows, so that, as far as I can determine, they numbered 23.

It is clear that the intent of the founding fathers was to severely limit the number of members, for it was voted at this first meeting that the number of Active Fellows not exceed 50, plus 30 corresponding Fellows and twenty Honorary Fellows of which 15 were to be Foreign. This was increased over the years until now we have 100 places for Active Fellows of which 99 were filled as of the 1966 meeting.

At the first meeting of the Association, Dr. Thomas F. Rumbold, Editor of the St. Louis Medical and Surgical Journal, offered to publish the Transactions of the Association in his journal, provided it were to be made the official publication of the Association. However, when Dr. Rumbold found that the Presidential Address covered almost 200 pages, he refused to publish the Transactions at all, and the Proceedings of the first meeting did not appear for three years, and then as a separate book, representing the format in which they appear today. The tradition of publishing the *Transactions* as a separate volume has, therefore, been maintained throughout these 88 years.

The first meeting in 1879 produced an interesting resolution as follows: "that the membership of the American Laryngological Association are desirous at this, their inaugural meeting, of expressing their sense of indebtedness to Manuel Garcia of London for demonstrating the feasibility of inspecting the interior of the larynx in the living subject, and orders that the Council be instructed to present the name of Manuel Garcia as the first Honorary Fellow of this Association."

Manuel Garcia, therefore, 21 years after his invention of the laryngeal mirror, then called a laryngoscope, became our first Honorary Member, to be succeeded in later years by some of the most distinguished laryngologists the world has ever known.

It was further ruled that the cover of any pamphlet published by the Association be stamped with a double circular dye, the one on the left to enclose the word "Garcia" surrounded by the legend "Tenebra" or "Darkness," and the

other, the word "Czermak" surrounded by the legend "Lux" or "Light." The significance, of course, is that Garcia and Czermak between them, one inventing the mirror and the other making its use clinically practical by coordinating it with the head mirror and artificial light, had taken us from darkness to light as indeed they had.

The Nominating Committee of this first meeting then presented the incumbent officers elected at the organizational meeting in Buffalo, recommending that they succeed themselves but with the distinct understanding that their action was not to be construed as a precedent for the future Nominating Committees, and except on two occasions during War years no President has ever succeeded himself.

The highlight of the first meeting was President Elsberg's Address, to which I have already alluded, and I refer to it again with special emphasis, for it outlined in great detail the scope of our specialty, and established a priority in the distribution of surgical cases such as we have always held to be valid, but have often been denied. Admittedly much of this loss has been by default; but we are now in what I might refer to as the "Renaissance of Laryngology" and are beginning to reclaim this birthright and to establish a sphere of surgical influence which lends breadth and scope to our specialty, and to which we are entitled as pioneers in the development of the surgery of the region of the head and neck.

If this Renaissance is to bloom and flower to its fullest, we need a framework within which we can develop, and broad boundaries within which we can grow. This framework was established for us by President Elsberg in his Presidential Address 88 years ago. He staked our claim and I quote as follows for all to hear who would deny us. President Elsberg said: "The domain of our specialty, at first uncertain in its boundaries, has become clearly defined in the appreciation of the medical profession and lay public alike, as well as in the practice of the leading specialists. It embraces par excellence, the larynx around which are grouped many other parts. . . ." He then referred in broad terms to "older writers who referred to diseases in which deglutition and respiration, separately or united, were affected, and stipulated that these belonged in our specialty, provided that such affections were above the stomach and the lungs."

"The throat specialist," he said, "is, therefore, called upon to treat affections of the larynx and trachea; of the root of the tongue; the valleculae and the hyoid bone; of the tonsils, palate and uvula; the pharynx, pyriform sinuses and esophagus; the pharyngo-nasal space; the nasal passages and accessory sinuses;" . . . and now note this, he then added "the thyroid body, the parotid and sublingual glands and the areolar tissue and other structures that make up the substance of the neck."

Then by pointing out the continuity of the mucous membrane with other structures such as the Eustachian tube, President Elsberg included the ear and

mastoid and the lachrimal apparatus. Fields of interest such as cosmetic surgery and reconstructive surgery of the head and neck were not dwelt upon specifically, but since so much of this was pioneered, developed, and reported upon by our own people from many platforms and in many journals, it must be taken for granted that these surgical fields of interest likewise fall within our domain. In fact, it would be impossible to separate them from the anatomical structures which are traditionally ours, and with which they are concerned. Here then, clearly stated by the first President of our Association nearly a century ago, and based upon clearly defined lines of surgical spheres of interest as recognized by the medical profession and laity alike, and traditionally practiced by the leading specialists in the formative years of modern surgery, is the framework within which we as a specialty were expected to function, and still expect to function. It is now long overdue, therefore, that we should once again forcefully reaffirm our position, and reclaim that which is ours, as outlined by Dr. Elsberg, not only by reason of tradition and priority; but by reason of logical argument; and by virtue of surgical skills, and because of our own professional needs.

It must be admitted that there was an era over several decades during which admission to the ranks of our specialty was virtually uncontrolled, and as a group we were ill prepared to accept such broad responsibility; but these days have long since passed, and by long ago founding the first of the national specialty "Boards" we re-established high standards of training and skills essential to the practice of so broad a field.

In an entirely different vein, I would very much like to refer to a Dr. Thomas French, President of our Association in 1897, whose work as a pioneer in laryngology needs to be recalled to mind.

In 1886, Thomas French presented a paper before this Association entitled "The Laryngeal Image as Seen in Photographs Taken During the Production of Tones in the Singing Voice."

He illustrated his paper with 37 photographs of the larynx which established the basis for virtually all that is known today concerning the physiology of the vocal function. But Dr. French's reports have been lost sight of, and we seldom now see reference to them or acknowledge the priorities to which he is entitled. He was really the first to describe vocal cord patterns as part of the physiology of the larynx. French studied, described in our *Transactions* and illustrated photographically, the effects upon tone production of the force of a blast of air and the variations in the vocal cords as they are seen in different subjects producing the same pitch and variations in the same subject as tones of varying pitch are produced. He illustrated the physiological effects of vocal training and all this with such accuracy and in such exquisite detail as to be momentous contributions even if they were made today.

It is all the more remarkable that French's pictures were taken with sunlight as their own source of illumination.

While scientists were still debating the validity of the germ theory and the need for antisepsis, and before the discovery of the Tubercle Bacillus, Thomas French so vividly and so accurately demonstrated vital phases of laryngeal physiology that we have in almost a century scarcely added anything to it and he thereby without doubt placed himself upon a pedestal as one of the all-time "greats" of our specialty.

I have for a long time now been anxious to resurrect his memory, and this Presidential Address has given me a good opportunity to do so, especially since it is in keeping with Dr. Bryan Delavan's premise, spoken before this body in 1894, to the effect that one of the prime purposes of the Presidential Address is to recall noteworthy incidents in the history of our specialty in general, and of our society in particular. I know of none more noteworthy.

To this I would add that in speaking of a Dr. John McIntire, who was experimenting with cinematography in conjunction with x-rays and had been successful in demonstrating movements of the frog's bones and legs, Dr. French stated that it was possible to get x-ray shadows of the larynx.

As far as I know, this was the first reference to the study of the larynx by x-ray.

To sum up then, by reason of a sabbatical leave, I have been able to study the *Transactions* of this Association beginning with the first one of 1879 and continuing through the current edition. They are a beautiful compendium of the progress of the laryngology of modern times. This opportunity has given me a broad insight into the purposes and accomplishments of this Association, which is now, and has without doubt always been, one of the most stimulating and productive forces in the history of modern medicine and certainly this would be true within our own specialty.

I have pointed out that we are one of the oldest national surgical specialty societies in the United States (but we are not as old as the New York Laryngological Society which in a sense was our Godfather), that our origin antedates the discovery of the germ theory of disease, the principles of antisepsis and the discovery of x-rays. We were born with the advent of modern medicine and since that time have stood for the highest ideals in practice, have stressed the importance of fundamental research, and have included in our numbers virtually all the leaders in laryngology for the past 90 years.

Our *Transactions* accurately and completely reflect the progress of laryngology, most of the important steps in the progress having been taken by our membership.

From the very beginning we have outlined the framework within which our specialty is expected to function and is able to function, and this delineation as our sphere of influence is rapidly being reclaimed.

We recognize that the progress of laryngology needs to be based upon the firm foundation of fundamental truths as established by basic research and by clinical observation and that progress depends upon the combined efforts of the academician, the research worker, and the clinician working in cooperation with one another.

While we encourage the basic research worker in every possible way, we go along with Pasteur who said "We have science and the application of science, which are as united as the tree and its fruit," which concept Dr. French paraphrased at a meeting of this society. He said "while practical ends are the mere outcome of antecedent forces which broaden the horizon, in laryngology as in all of medicine the need is clearly for three classes of workers: the original investigators who seek the truth for truth's own sake; the teacher who diffuses the knowledge acquired by original investigation; and the applier of such knowledge to practical ends. . . . thus, as in the tree that is the whole, the trunk, the branches, the leaves and the fruit share equally."

We as a group recognize the contributions of each of these as essential and reflect this in our membership and in our scientific programs as well.

We have taken upon ourselves the responsibility of providing a forum especially for laryngologists per se, although this was not true in the beginning when, we as a national group, were the only representatives of the specialty. As a matter of fact, of the 197 papers presented during our first ten years, 95 did not relate to the larynx at all. With the advent of numerous other national societies this need became far less, and we are now almost altogether a forum for pure laryngology.

This is as it should be.

We hold that the specialist in laryngology is not one who shall have acquired skills in it, at the cost of lack of knowledge of general medicine and surgery, but that his training and skill in laryngology shall augment rather than substitute for skills in the broader field of medicine and surgery

As I see it, the preservation and advancement of these principles and policies represent our role as heirs to the rich heritage we have received from those who founded and nurtured this Association through these many years. Each generation of our membership has added its share to the general storehouse of knowledge and to the advancement of laryngology. We need to see that this continues with ever increasing fervor.

There are expressed fears in high places to the effect that this may not come to pass due to a supposed current lack of interest in laryngology. This is attributed to rebirth of otologic surgery beginning with Julius Lempert.

You will, however, note that our program this year is limited entirely to the larynx, and I can tell you now that the program was virtually complete last July almost ten months ago.

This is evidence of constantly growing interest in laryngology and negates the fallacy that our specialty is now made up of otologists.

Admittedly there are a few of them around, and they are going to be with us for quite a while; but the laryngologist is not going out of business either. The otologist is simply catching up, and it is high time that he should do so!

I need now only to thank the membership for the high privilege of serving as your President, and to express my gratitude to the officers and members of the Council who have guided me through this year of great responsibility for which I was poorly endowed.

My particular thanks are hereby showered upon Dr. Lyman Richards with whom we have been blessed as our Secretary for many years.

Those of you who have not worked intimately with him cannot appreciate the extent of the value of his services or properly evaluate the degree of his dedication to duty or his affection for this Association and for all of the men in it, or realize what an important role we play in his life, and he in ours.

INTRODUCTION OF DR. WILLIAM J. McNALLY, THE GUEST OF HONOR

PRESIDENT JOEL J. PRESSMAN

I come now to the privileged task of presenting our Guest of Honor whom you all know, of course, but you do not know all about him. I would like to begin by citing three of his distinguished honors about which I did not know until recently. Dr. McNally is the recipient of the highest honor with which the Catholic Church can endow a layman — the "Equestrian Knighthood of St. Gregory the Great."

He received the Dalby Memorial Prize of the Royal Society of Medicine of London given every fifth year for the best work in Otology, and is a Governor of St. Francis Xavier University from which he received the Honorary Doctorate of Laws, *Honoris Causa*.

His presence here as Guest of Honor is not a new experience for Dr. McNally, and if it is trite it is certainly true that in accepting many such invitations he has honored those who seek to honor him. These include the American Academy of Ophthalmology and Otolaryngology, the American Otologic Society and the Pan-American Congress.

Besides being a member of virtually every national society in Canada, Britain and the United States, Dr. McNally is an Honorary Member of the Scottish Otological and Laryngological Society of Glasgow, and of the Royal Society of Medicine of London.

Various societies have recognized the value of his contributions as evidenced by the awards he has received including not only the Dalby Prize, but the Honors Award of the American Academy, our own Newcomb Award, and the Award of Merit of the American Otological Society.

Dr. McNally was the first Director of the Institute of Otolaryngology of McGill University and the Royal Victoria Hospital. He is Professor and Chairman of the Department of Otolaryngology also at McGill and Otolaryngologist in Chief at Royal Victoria as well. His record of public service is a model for all who believe with him that there is much more to life than one's own self. I have already alluded all too briefly to his service to his Church. He has been equally unselfish in his dedication to public duty within his profession, and has for example given freely of himself in such posts as Examiner and Member of the Executive Committee of the American Board of Otolaryngology and as President of

the Certification Board in Otolaryngology of the College of Physicians and Surgeons of the Province of Quebec. Dr. McNally has been Chairman of the Subcommittee on Research of the Committee on Conservation of Hearing of the American Academy, and of the Panel on Auditory and Vestibular Problems of the Defense Research Board of Canada.

He has been President of the Canadian Otolaryngological Society, the Montreal Medico-Surgical Society, the American Otological Society and of our own American Laryngological Association in 1960.

Dr. McNally is one of the most exquisitely trained men I have ever known. He holds the Bachelor of Arts, the Doctorate of Medicine and a Master's degree in Surgery from Dalhousie University. He likewise holds the Masterate and Doctorate of Science from McGill.

After becoming Board-qualified, our Guest of Honor became successively the Cooper Research Fellow in Experimental Physiology at McGill, the Travers Allan Travelling Fellow at Rijks University in Utrecht, Holland, and for seven years worked at McGill as a Research Fellow of the American Academy.

Dr. McNally is, therefore, an outstanding and shining example of a leader who has combined his research talents to which he has given free expression with a distinguished career in teaching and clinical medicine.

But these are not the primary reasons for our seeking him as our Guest of Honor, which he happily accepted.

It was because without doubt, Bill McNally is one of the gentlest, sweetest, kindest, most thoughtful and most lovable gentlemen ever to be born.

I count it as the highlight of my Presidency that I am privileged to present as our Guest of Honor this distinguished Otolaryngologist who has given so freely of his many talents to his religion, his nation, his profession, his family and to us.

I ask that Dr. William McNally be conducted to the rostrum as Guest of Honor upon the occasion of this 88th Annual Meeting of our Association.

THE ADDRESS OF THE GUEST OF HONOR

W. J. McNALLY, M.D.

To be invited to be the guest of honour of the American Laryngological Association is a unique personal experience. First of all, there is nothing to lead you to believe that it is going to happen to you. It comes as a complete surprise. You cannot believe the President's invitation—is it for you? You wonder why! And finally you are overcome with delight and pride. Eventually, you come down to earth, and realize that from the guest of honour are expected a few words of wisdom. If you have been chosen before you are too hopelessly senile, you will remember that the audience is hoping that the emphasis will be on the fewness of the words and that it is not expecting too much wisdom.

I have taken this opportunity to bring to the attention of the membership how much our recent Councils have done to foster and support the reporting of scientific research, as an integral part of the program at the annual meetings. They have done this in such a way that, rather than taking away from the clinical, it has elevated the level of the clinical presentations.

Such a topic is especially apt this morning because our President illustrates so well, in his own career, the points which I wish briefly to bring to your attention.

Dr. Joel S. Pressman is presently Professor and Chairman of the Department of Head and Neck Surgery at the University of California in Los Angeles, has also been Assistant Dean of Medicine and has devoted his medical career to its four important aspects: Research, Teaching, Administration and Practice.

In his formative years of medicine at Harvard he devoted his skills to the development and mastery of research techniques which later won for him a Science Doctorate from the University of Pennsylvania. He was one of the first to modify and apply the modern techniques of cinematography to the visualization and study of the larynx. His methods and films received world-wide adoption as basic teaching material of laryngeal motility and its alteration during pathological involvement.

His research has covered a wide range, included in which was the exposition of the finer details of lymphatic drainage of the larynx. He traced the paths of spread of laryngeal malignancy and he developed methods of tracheal reconstruction following malignancy and trauma.

In his teaching he has tirelessly advocated that our standards of training should be raised, so that they may compare favorably with those in other special-

ties. He has demonstrated, by his own example, that the major surgery in our areas can best be retained by having in the specialty men thoroughly competent to carry out such surgery. It is noteworthy that his Department is titled the Department of Head and Neck Surgery, rather than that of Otolaryngology.

His honours have been many, but I will only remind you that he won the Casselberry Award of this Society in 1936, its Newcomb Award in 1960, and today he is its President.

Many years ago he was invited by Sir Sinclair Thomson to present his research on cinematography of the larynx before the Royal Society of Medicine in London

President Pressman is to be congratulated on the careful blending of the scientific and the clinical aspects in this program which he has arranged for our benefit.

In 1959, Dr. Arthur Proetz was anxious to find some way to utilize the Research Fund of this Society for the fostering of research in the training of otolaryngologists, because then as now the income from the Fund was too small to offer as a research grant. In 1962, it was determined that the income from the Research Fund might be used to have a member of the Society report on foreign research at an annual meeting.

Drs. Proetz and Hill were later empowered to seek legal opinion to determine whether or not the income from the Research Fund might be used, at the discretion of Council, to cover the travel expenses of non-member research workers in the sciences related to Rhinology, whom the President might choose to invite to present their work at an annual meeting.

In 1964, Dr. Hill, in Dr. Proetz's absence, was able to report that the income from the Research Fund could be so used at the discretion of Council, and with the approval of the Research Committee. The annual income from the Research Fund in 1965 was over \$1,000.00. This means that, without any embarrassment to the President, to the Council or to the Society Members, the very latest scientific work can be presented before this Association. It is crucial that each and every member of the Society should be aware of this and if one knows of research going on anywhere in the world, which even remotely relates to our specialty, it should be brought to the attention of the President or other members of Council, so that it can be considered for possible presentation at an annual meeting.

It is my personal hope that some day soon our Society will see fit to make the first vice-president also president-elect, so that the President will have an additional year to prepare the program and to seek out basic scientific material for presentation at the annual meeting over which he will preside.

In his presidential address in 1949, Dr. Frederick Hill noted that "tradition of the right kind is a good thing to tie to when we see so many of our philosophies are threatened by radicalisms; untested, unproven, and often dangerous in their implications." He went on to point out, however, that new discoveries gradually eliminate old procedures and new knowledge modifies older methods, so that we must be prepared to adapt to a changing specialty, while we strive to become ever better physicians, and not merely surgical technicians.

Dr. Arthur Proetz stated in 1948 "that the scientific record of the American Laryngological Association for seventy years stands proudly on a shelf, now five feet long." He added, "these are our laurels, we must not rest on them, however comfortably we may sometimes lean." Proetz himself never rested nor even leaned on these laurels but, on the contrary, made many brilliant contributions to our basic knowledge in Rhinology and did much to stimulate and promote research.

In 1949, he and Dr. H. I. Lillie analyzed the contributions of some of the leading laryngologists of the time. It was noted that their major achievements were begun before any of these men was thirty years of age. Proetz emphasized the importance of encouraging research in the early stages of training. He was most emphatic, however, about distinguishing between a true search for new knowledge and the mere promotion of a surgical technique. He illustrated this very forcefully by saying that "the rush to new surgical procedures reminded him of the tooters who climb on the bandwagon when the circus comes to town." He added, "one cannot help observing that there are very few soloists, and fewer composers, on a bandwagon."

The following have been listed as the qualities essential for the researcher:

To have basic knowledge.

To have imagination.

To be able to cope with the unexpected, the unpredictable, and the non-existent through originality, ingenuity and persistence.

To be prepared for hard work, long hours and disappointments.

To meditate with pleasure.

To be one's own "devil's advocate" checking one's hypothesis from every angle.

To suspend judgment with patience.

To abhor imposture.

To say "it is finished" with caution, and

To eagerly accept the challenge of the many questions still unanswered, after having successfully completed an experiment.

(Taken largely from the Royal Bank of Canada Monthly Letter. Vol. 46, No. 12, Head Office: Montreal, December 1965)

The clinician trained in the self-critical discipline of research becomes a keener observer, because not only does he appreciate what he is looking at, but he is, all the while, searching for the underlying principle or cause—he becomes a conceptual thinker

Because we have such a great heritage we must not be smug and it can't be allowed to stifle us. If anyone of us makes a worthwhile contribution to the heritage of this Society, the whole Society can well rejoice at his leaving—some-what akin to the Negro philosophy which states, "Rejoice when one leaves the world, cry only when one comes into it."

If each one of us makes the best use of his potential, it could even be a better world to come into.

It is essential that we be good technicians, availing ourselves of every new scientific advance, whether it be mechanical, electrical, biochemical, mathematical, in order to attain perfection in the practice of what must be a changing specialty. Pride in our traditions must not blind us to the constant need for an "aggiornamento" (a renewal and updating) such as Pope John XXIII instituted in his Church.

All the while we must be becoming greater physicians as Dr. Hill has stressed. We are specialists in Rhinolaryngology, but we are physicians to the whole patient.

In our haste to progress, we must be ever-mindful of our responsibility to each individual patient. He is always our patient and never an experiment. A new procedure should not be attempted on him that has not had the fullest possible preliminary animal experimentation. That patient has something of our God in him, and being conscious of that, our treatment of him must be such that it manifests to him that we also are made in the image and likeness of God.

Let us ask the Good Lord to enkindle in each of us both the fire of our love for Him and the flame of Eternal Charity towards each other.

PHYSIOLOGY OF THE FETAL LARYNX AND LUNG

FORREST ADAMS, M.D. DONALD T. DESILETS, M.D.

(by invitation)

(by invitation)

LOS ANGELES, CALIF.

AND

BERNARD TOWERS, M.B., CH.B.

(by invitation)

CAMBRIDGE, ENGLAND

Evidence has been presented both for and against the hypothesis that the fetus normally breathes in utero. The authors have concluded, however, that the fetus does not normally make respiratory-like movements in utero, but does so only if severely distressed.¹ Our conclusion is based on the following: 1) the fate of materials injected into the amniotic cavity; 2) the chemical composition of lung fluid and amniotic fluid; and 3) the presence of surfactant in lung fluid and not in amniotic fluid.

In utero, the fetal lung normally produces a fluid much as the kidney produces urine and this fluid has a chemical composition which is rather characteristic. Furthermore, obstruction of the upper respiratory tract in utero causes dilatation of the alveoli and the alveolar ducts due to accumulation of this fluid.² The origin of the fluid in the fetal lung has not yet been determined, but since it contains surfactant, at least some of the fluid must come from the alveoli.

The amniotic fluid is composed primarily of lung fluid and urine. Studies show that the human fetus normally swallows as much as 500 ml of amniotic fluid per 24 hours.

The authors believe that the baby does not breathe in utero. This is based partly on amniographic studies, extensive ones having been performed recently in humans, and some by us in sheep near term. We injected Thorotrast® into the amniotic sac and then took serial daily x-rays of the mother, focusing on the fetus. After a period of 24 hours, the Thorotrast appears in the small bowel of the fetus, but none of it appears in the lung. The ewe was allowed to deliver and a subsequent x-ray again showed the presence of Thorotrast in the bowel but not in the lung. Davis and Potter³ showed that radiopaque dye injected into the amniotic cavity appeared in the lung; however, the babies were stressed in the process of cesarean section. Other studies show that if the babies are not

TABLE I
COMPARISON OF (MEAN) MATERNAL AND FETAL FLUIDS

<i>Constituents - mEq./L</i>	<i>Maternal Arterial Blood</i>	<i>Fetal Umbilical Blood</i>	<i>Fetal Lung Fluid</i>	<i>Amniotic Fluid</i>
Sodium	143	140	142	110
Potassium	4.7	4.4	6.6	10.7
Calcium	4.37	4.66	1.28	-
Magnesium	1.65	1.75	0.69	1.8
Chloride	108	105	144	94
Total Carbon Dioxide	22.6	21.1	4.4	18.4
Inorganic Phosphorus	1.49	3.2	0	-
Lactic Acid	2.3	3.5	0.6	2.1
Protein	18	16	0	1
Osmolality	302	300	300	275
pH	7.44	7.33	6.43	7.07
Protein in mg %	6500	4400	20	700

stressed and they are allowed to deliver vaginally, none of the amniotic fluid appears in the lungs.⁴⁻¹³

To gain a better understanding of hyaline membrane disease, we have been using sheep near term, partly because the lamb at term is very close to the size of a human infant, ranging in weight from six to eight pounds. By sewing the uterus to the anterior abdominal wall under either spinal anesthesia or general anesthesia, we can marsupialize the uterus, deliver the fetus by cesarean section onto a warm table and easily maintain adequate umbilical circulation. This preparation can be sustained for periods up to 24 hours, during which the fetus will make no attempt to breathe, making possible a number of studies.

A tracheotomy tube is placed in the trachea and immediately the lung fluid flows out and one can collect rather large volumes of this fluid (60 to 100 ml) in a period of ten to fifteen minutes. We have done chemical analyses on this lung fluid and have compared it with the fetus' blood, the amniotic fluid and the mother's blood.

To offset comments and criticisms of this technique, we have exteriorized the fetal head for a short enough period to insert a tracheotomy tube and reposition the fetal head in the uterus with the collecting system exteriorized so that the lung fluid could be collected in utero under relatively normal conditions of pressure and temperature. By this method, we can collect 10 to 30 ml of lung fluid every hour in a term lamb fetus.

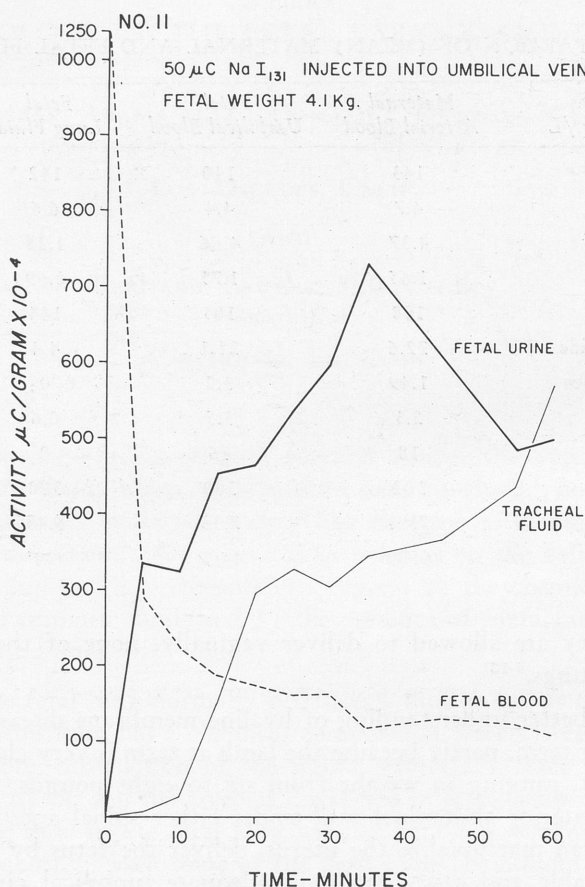
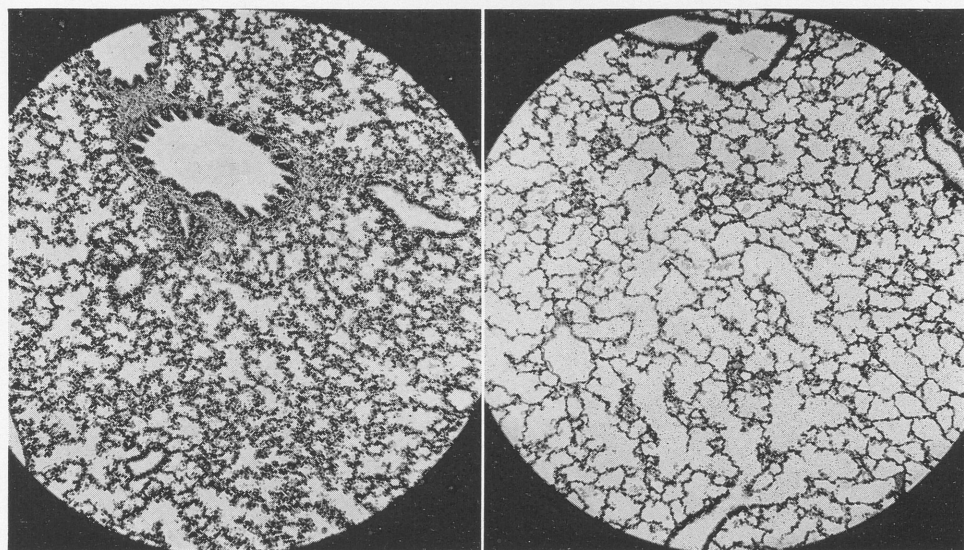


Fig. 1.—Graph showing fate of 50 μ C of Na I^{131} injected into the umbilical vein of a 4.1 kg lamb fetus with intact placental circulation. There was a gradual and similar rise in radioactivity in fluid removed from the fetal trachea and urinary bladder. Adams, Fujiwara and Rowshan¹⁴ (The Journal of Pediatrics 63:881, 1963, The C. V. Mosby Co., St. Louis, Mo.)

Table I shows the composition of the mother's blood, the fetus' blood, the fetal lung fluid and amniotic fluid. If one looks at the chemistry of the lung fluid, one is forced to come up with a conclusion that it is certainly different than amniotic fluid; the osmolality is different: 300 mosm in lung fluid, 275 mosm in amniotic fluid. The pH is quite different; the lung fluid is acid compared with the fetus' blood or amniotic fluid and there is a very striking difference in the protein composition. There is almost no protein in the lung fluid. It is very



CONTROL

EXPERIMENTAL

Fig. 2.—Histological sections of fetal lung tissue showing control lung (left) and experimental (right) from the same litter. In the experimental lung, there is marked dilatation of the alveoli and terminal bronchioles as well as thinning of their walls. (American Journal of Diseases of Children 109:452, 1965²)

much like spinal fluid, about 10 to 30 mg per cent protein in the lung fluid whereas in the amniotic fluid it is 700 to 1,000 mg per cent. It actually appears as though there are some pumps within the lung: a hydrogen pump, a chloride pump, very much as there are pumps in the kidney.

Another piece of evidence that the fetus does not breathe in utero was an experiment of nature. We were fortunate in having one lamb fetus delivered in our laboratory that had no eyes, nose or mouth; probably a variant of a cyclops. In all other respects the lamb seemed to be normal. On dissection of this lamb, it turned out that there was a normal lung and respiratory tract, trachea and larynx, and there was an esophageal caecum that did not communicate with the amniotic cavity. There was no opportunity for this animal to breathe amniotic fluid into the lung. The trachea and larynx communicated with the esophageal caecum and the entire respiratory tract was filled with lung fluid.

In the microscopic section of the lung of this fetus, alveoli and alveolar ducts were distended and looked as though the animal had been breathing. This is the

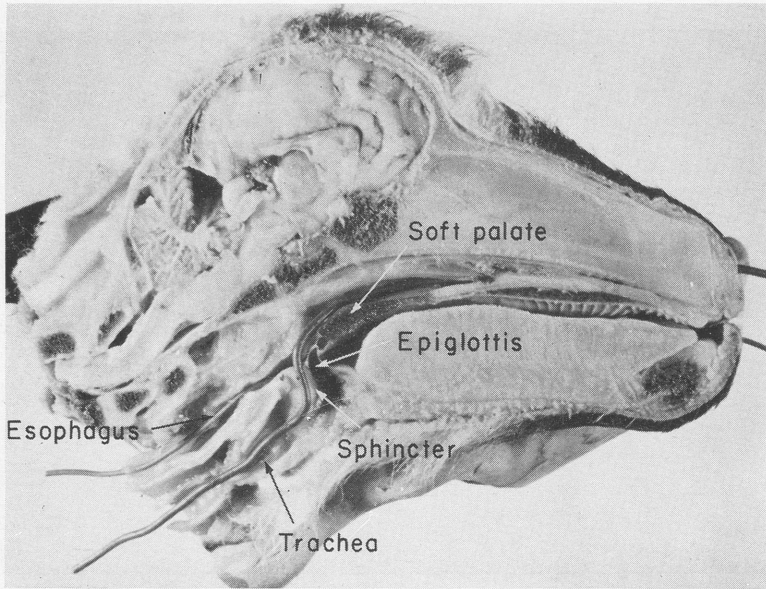


Fig. 3.—Sagittal section of head of lamb near term showing relationship of trachea, outlet area, epiglottis, soft palate and esophagus. (*Respiration Physiology* 2:302, 1967)

way the normal fetal lung appears in humans and in animals prior to the first breath. The lungs were fully expanded and contained fluid which was formed in the alveolar region that came up the respiratory tract and helped to contribute to the formation of amniotic fluid. Since the lung was forming so much fluid, we wondered whether the fetal lung might not be a kidney and performed a number of studies in which we studied the clearance rate. In one (Fig. 1), we injected labeled sodium iodide into the umbilical vein in a fetus that weighed 4.1 kilos, and measured the radioactivity in counts against the time in the fetal urine, in the lung fluid, and its disappearance from the fetal blood stream. There was a rise in the activity of the lung fluid almost equal to that of the urine. The time lag of the isotope in the lung fluid was due to the length of the collection system which was estimated to be about seven minutes. The urine collection system, on the other hand, was much shorter.

If one ties off the trachea in the fetus, the fetal lung will become distended with more fluid than usual.² There are experiments of nature in which there is complete obstruction of the respiratory tract in newborn infants and a similar finding is seen here.

In a series of rabbit experiments, we took alternate fetuses in utero, tied off the trachea and then kept them in utero for another two or three days, using

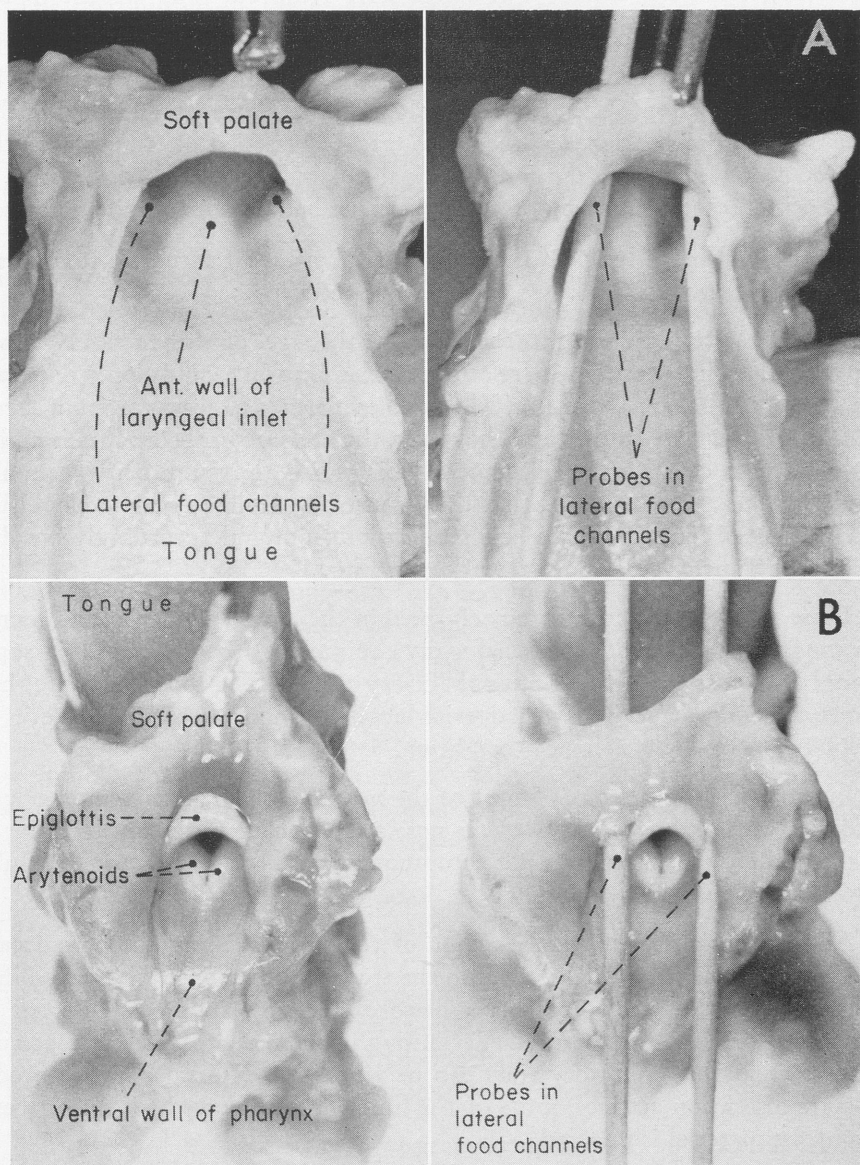


Fig. 4.—Soft tissue dissection showing relation of epiglottis to soft palate in the fetal lamb. Note lateral food channels on either side of the laryngeal outlet. A - anterior view; B - posterior view. (Respiratory Physiology 2:302, 1967)

steroids, and sacrificed them. The lungs were removed, lung weight to body weight ratio was determined and microscopic examinations were made.

In Figure 2, the left section is the lung from a rabbit fetus at term whose trachea was not tied off; the alveolar ducts and alveoli are distended with fluid, but in the experimental group where the trachea was tied off for two or three days, you will see hyperdistention of the alveolar duct and of the alveoli. It appears as if this fetus had been breathing and yet had no opportunity to do so.

The weight of the lungs of the experimental group of fetuses is considerably elevated over the control fetuses of the same gestation.

When the pressure in the trachea right at the level of the trachea was measured, it was always positive in relation to the ambient condition. Normally when we, as adults, are breathing, we breathe in negative pressure from zero to minus 4 cm of water. In the fetus, however, the pressure in the trachea is positive at 10 to 15 mm of water and because of this positive pressure being present in the fetal trachea, we postulated that there must be a sphincter some place above the trachea in order to produce this positive pressure and accordingly we did a series of experiments which are recorded on film.

These next experiments were performed in the heart catheterization room in order to take advantage of the special x-ray equipment. The uterus is marsupialized and the fetus is delivered onto the x-ray table. The blood pressure, heart rate and gas concentration of the arterial blood are monitored and the fetus can be kept in optimal physiological condition.

In order to reduce sensory input to the nose and throat area, a rubber glove containing warm saline is put over the nose and the extremities are restrained so that the umbilical circulation is not compromised. The fetus is active but makes no attempts to breathe.

An incision is made over the region of the trachea, using the percutaneous catheter technique. A needle is put into the trachea; a fine wire is threaded down through the needle, and over this a piece of Teflon® tubing is inserted and advanced to the level of the carina. Through this tubing, contrast material is injected so that the respiratory tract can be visualized. In order not to produce a pressure distention artifact, some of the lung fluid is allowed to run off before the contrast material is injected.

Figure 3 is a sagittal section of a lamb's head, with the various parts labelled. The epiglottis approximates above the soft palate and combined with the arytenoids, forms the sphincter. The esophagus and the trachea are also visualized during the procedure. Contrast material is injected through the trachea down past the level of the carina and comes up the trachea and stops at the sphincter. Contrast material is also injected into the nose and throat.

The relationship of the epiglottis and the soft palate in the fetal lamb is shown in Figure 4A. The tongue and the anterior side of the soft palate is indicated, showing the relationship of the anterior wall of the tracheal inlet and the lateral food channels which are on either side.

Figure 4B is the dissection from the back with the arytenoids and epiglottis indicated. When they are relaxed, they open the sphincter.

As the catheter is filled with contrast material, the material comes up and stops at the sphincter and the sphincter opens up periodically, discharging contrast material. Some of it goes down the esophagus; some others parts of the contrast material go up through the nose and out into the amniotic cavity. The action and movement of the sphincter has been timed. It seems to open up about every 15 or 20 seconds and allows a small amount of contrast material to be discharged. The question of whether this is a cough needs to be established by further experiments.

When contrast material is injected onto the surface of the tongue or into the nose, as long as the fetus is in good condition, it never goes down the trachea; it always goes down the esophagus, so the sphincter is intact and it helps to protect the lungs from aspiration of nasal pharyngeal mucus or amniotic fluid.

If the umbilical cord is obstructed and the blood supply is therefore impaired to the fetus, the fetus will attempt to breathe and contrast material goes down into the trachea. The contrast material does this after the fetal heart rate drops below about 60 to 80 beats per minute. When the clamp is removed and the circulation is allowed to re-establish itself to the fetus, the contrast material is evacuated and the lung is cleared of it.

When contrast material is injected into the main bronchi, the material is also evacuated, leading us to believe that there is a sphincteric action in the respiratory tract lower down as well as the upper. In a P.A. view, it is possible to inject contrast material into the mouth so that the lateral food channels can be visualized. In this way, the fetus swallows amniotic fluid without getting it into the lungs, and it is probably the mechanism by which the newborn baby can both breathe and swallow milk simultaneously in breast feeding.

When one of the recurrent laryngeal nerves is cut, the material leaks out, and when both laryngeal nerves are severed, the impression is like that of an incontinent bladder.

In conclusion, the fetal lung secretes a fluid and the fluid flows up the respiratory tract; a sphincter exists at the laryngeal outlet and the epiglottis rests above the soft palate and lung fluid is periodically discharged into the nasopharynx.

In summary, I would like to say that when the newborn baby takes its first breath, if you believe the studies I have just shown you, then, obviously, he has to change from a state where the laryngeal sphincter is closed all the time to a state where the laryngeal sphincter is open all the time. The only time it closes is when the baby coughs or swallows, so, in a sense, there has to be a 180 degree reversal in the sphincter's condition and we postulate that there will be physiological situations where this switch-over will be incomplete.

The vocal cords will remain either in partial or total apposition and this in itself will give rise to respiratory distress. We are asking this very important question as to whether this might not be the main method by which hyaline membrane disease is started; namely, that there is respiratory tract obstruction, poor gas exchange, accumulation of CO_2 in the blood, a drop in the oxygen content of the blood and along with it, a drop in the blood pH, which we know affects pulmonary blood flow very significantly in the newborn baby. Then, as the pulmonary blood flow is further reduced, the synthesis of lung surfactant is interfered with and we get the vicious cycle of hyaline membrane disease.

DEPARTMENT OF PEDIATRICS, UCLA SCHOOL OF MEDICINE
LOS ANGELES, CALIF. 90024

REFERENCES

1. Adams, F. H.: Functional Development of the Fetal Lung. *Jour. Pediat.* 68:794, 1966.
2. Carmel, J. A., Friedman, F., and Adams, F. H.: Fetal Tracheal Ligation and Lung Development. *Amer. Jour. Dis. Child.* 109:452, 1965.
3. Davis, M. E., and Potter, E. L.: Intrauterine Respiration of the Human Fetus. *J.A.M.A.* 131:1194, 1946.
4. Steele, A. G., and Windle, W. F.: Some Correlations Between Respiratory Movements and Blood Gases in Cat Fetuses. *Jour. Physiol.* 94:531, 1939.
5. Windle, W. F., Becker, R. F., Barth, E. E., and Schultz, M. D.: Aspiration of Amniotic Fluid by the Fetus. An Experimental Roentgenological Study in the Guinea Pig. *Surg. Gyn. Obs.* 69:705, 1939.
6. De Snoo, K.: Das trinkende Kind im Uterus. *Monatschr. Geburtsch. Gynäk.* 105:88, 1937.
7. Becker, R. F., Windle, W. F., Barth, E. E., and Schultz, M. D.: Fetal Swallowing, Gastrointestinal Activity and Defecation in Amnio: An Experimental Roentgenological Study in the Guinea Pig. *Surg. Gyn. Obs.* 70:603, 1940.
8. Speert, H.: Swallowing and Gastrointestinal Activity in the Fetal Monkey. *Jour. Obs. Gyn.* 45:69, 1943.
9. DeBlasio, A., Ambrosio, A., and D'Amora, G.: Sui movimenti respiratori endouterin del feto umano a termine. *Pediatria* 68:1124, 1960.
10. Liley, A. W.: Amniotic Fluid. *Modern Trends in Human Reproduction. Physiology* 1: 227, 1963.

11. McLain, C. R., Jr.: Amniography: A Versatile Diagnostic Procedure in Obstetrics. *Jour. Obst. Gyn.* 23:45, 1964.
12. Carter, W. A., Becker, R. F., King, J. E., and Barry, W. F., Jr.: Intrauterine Respiration in the Rat Fetus. II. Analysis of Roentgenological Techniques. *Amer. Jour. Obs. Gyn.* 90:247, 1964.
13. Adams, F. H.: Unpublished observations.
14. Adams, F. H., Fujiwara, T., and Rowshan, G.: The Nature and Origin of the Fluid in the Fetal Lamb Lung. *Jour. Pediat.* 63:881, 1963.

DISCUSSION

DR. THEODORE E. WALSH: Dr. Adams, I think you said there is quite a difference in the volume of lung fluid produced in the fetus outside the body as compared with when it was returned to the uterus and I wondered how much the tubes within the trachea might be stimulating both fluid and movement.

Have you ever tried transecting the trachea, for instance, with diathermy and putting something on the outside of the trachea to cause the fluid so there would be nothing inside to stimulate them? Would that make a difference in the volume?

DR. FRANCIS A. SOOY: Would Dr. Adams care at this point to conjecture as to what defect in this mechanism that he describes so clearly may lead to, or be responsible for, hyaline membrane disease?

DR. JOHN A. KIRCHNER: There was one incidental item that he alluded to that I wanted to ask him about: the slowing of the heart rate that results. I wonder if some of this could be due to stimulation of the respiratory tract by instillation of the dye into the nose, or is it entirely due to occlusion of the placental circulation?

We know that in the experimental animal, the rabbit, for example, the heart rate can be slowed or stopped very often by stimulating the posterior part of the nose and swimmers, even the human swimmer, will have a bradycardia to about two-thirds his resting level simply by immersion of the face in water, whereas holding the breath in air will not do this and I wonder whether—this is apart from your subject, I know—but the bradycardia that you reported, whether some of this might be due to instillation of the material into the nose.

DR. ADAMS (closing): First to clear up a point: all of our initial studies were done with the exteriorized fetus and when we submitted the paper for publication they criticized the fact that the fetus was exteriorized and wondered whether or not the difference in pressure relationships might not account for this, so that another series of experiments with the fetus inside the mother was performed and exactly the same flow rate, which is about 10 to 40 mls. per hour in a term fetus was obtained.

We recognized that perhaps putting something in the trachea might be irritating to the trachea, and we have not been able to solve the problem as to how to set up a study to do it differently.

The fluid that comes from tracheotomized patients is quite different. It is tenacious, very stringy and mucoid. The fluid from the fetus is very much like spinal fluid. It has almost no protein in it; it has a low pH. Other than that, it has the same osmolarity as blood. If you inject an isotope into the blood stream, it immediately appears in this fluid, which makes us think that there is an active transport across the lung. The fact that surfactant was present in this lung fluid makes us feel that it is coming all the way down from the alveolus where the surfactant is formed. We are fairly convinced that this is not an artefact, and the fact that there is a positive pressure within makes us feel that it is being formed there.

One of the things I didn't stress is that this positive pressure within the trachea perhaps is essential to the development of the lung during fetal life and that it helps to force the lung alveoli and alveolar ducts out into the mesenchymal tissue. This needs to be tested, however.

One thing that needs to be remembered is that hyaline membrane disease is almost entirely limited to the prematurely born infant. It rarely is seen in full-term infants, but even in the babies of diabetic mothers, where this also occurs, one can make a case that, although they may weigh the same as a term infant, that in fact they are born prematurely because of macrophomia.

What we are thinking at the present time—and it is purely speculation—is that the primary problem resides in the respiratory center in the brain stem and that something has gone wrong there. The premature baby has a poorly developed nervous system anyway, and perhaps there is hemorrhage or edema in the respiratory center. Certainly it is known that at least 50 to 60 per cent of babies dying of hyaline membrane disease have central nervous system lesions grossly. We are postulating that something has gone wrong in the respiratory center which interferes with vagal function in one way or another and that therefore the activity of the vocal cord area is impaired and that there will be obstructed breathing. This remains to be determined.

I might mention one other thing that perhaps will be of practical significance to otolaryngologists and that is that the baby born by Caesarean section does not get rid of this fluid as readily as the baby who is born by vaginal delivery. There is something about the delivery process that tends to squeeze out or wring out the baby's lungs and if one follows lung weight/body weight ratios, following Caesarean section, the lungs remain more moist and have more water in them for as long as six to seven hours. Compliant studies done on human infants delivered by section show that their lungs are stiffer, so that there is something unusual and abnormal about Caesarean section that does not permit adequate removal of the lung fluid. I think this helps to explain why the incidence of hyaline membrane disease may be higher in babies born by section, and it may eventually happen that one of the procedures that are performed routinely in Caesarean section will be cleaning out of the airway, at least that is our thought at the moment.

In reply to Dr. Kirchner's question: As long as nothing is done to the placental circulation the material instilled in the nose will, in a repeated fashion, go down the esophagus and not down the trachea.

The lamb's fetal heart rate is about 180 to 200 beats per minute and it stays rather constant, even when material is injected into the nose or throat. If the umbilical cord is clamped, it takes about three or four minutes before the heart rate will get below 100, so it is really fetal anoxia. This actually hasn't been documented, but it is planned to get it set up whereby the pH, CO₂ and P_{CO₂} can be continuously monitored on line and then determine at just which point the fetus makes an attempt to breathe. This also has implications in terms of what is the driving force that causes the baby to take its first breath. It may be CO₂.

I would like to make one other practical comment that now we believe that the vocal cords are in apposition and only open up after the first breath. I think this may have some important bearing on why, when one does a tracheotomy on a newborn infant, it tends to revert to the fetal pattern. The feed-back mechanism into the brain stem is such that it quickly falls back into the fetal pattern and that perhaps is why it is difficult to wean the newborn baby from a tracheotomy tube.

It is essential, in order to maintain normal respiration, for air flow to go past the posterior pharynx. If you once stop that air flowing past the driving center in the back end of the nose respiration ceases, and there is the problem of starting it up again.

CONGENITAL WEBS, CYSTS, LARYNGOCELES AND OTHER ANOMALIES OF THE LARYNX

PAUL H. HOLINGER, M.D.

CHICAGO, ILL.

WILLIAM T. BROWN, M.D.

CORAL GABLES, FLA.

Interest in all congenital anomalies, including those of the larynx, is increasing. This is probably due to several factors, among which are more widespread and prompt means of recognition, improvements in management, salvage of infants with other anomalies formerly considered incompatible with life who also have complicating laryngeal anomalies and the intense interest recently directed toward iatrogenic factors of congenital anomalies. The present study broadens and updates a previous review of this subject.

SYMPTOMS

The symptomatology of congenital laryngeal anomalies does not vary greatly. A weak or absent cry in an infant at birth suggests a laryngeal anomaly, whether or not respiration is impaired. However, in the infant who has dyspnea, stridor, or cyanosis, the character of the cry becomes of great diagnostic importance. The muffled, pharyngeal quality of cry of the infant with a thyroglossal duct cyst, lingual thyroid or other pharyngeal obstruction is quite characteristic. An infant with a laryngeal (glottic) web generally has some dyspnea with indrawing of the suprasternal notch and epigastrium in addition to the weak cry, but this combination is by no means indicative of the diagnosis since identical symptoms are noted in infants with subglottic stenosis. Similarly, the loud, stuttering, crowing inspiration which characterizes congenital laryngeal stridor could by no means be considered diagnostic in itself because infants with bilateral recurrent laryngeal nerve paralysis and those with tracheomalacia, alone or in association with a vascular anomaly compressing the trachea, have an identical stridor.

In addition to an abnormal cry and stridor, a third group of symptoms suggesting a congenital laryngeal anomaly are those due to neurogenic dysfunctions of swallowing. These are symptoms caused by an overflow of saliva and

From the Department of Otolaryngology, Illinois College of Medicine and the Illinois Eye and Ear Infirmary, Chicago, Illinois.

pharyngeal secretions into the larynx in infants with gustatory pareses or paralysis related to central nervous system anomalies. They are identical to the symptoms of congenital esophageal atresia, or a tracheoesophageal fistula without atresia, which are characterized by the constant presence of fluid in the pharynx and trachea, complicated by aspiration pneumonia.

DIAGNOSIS

The presumptive diagnosis of a laryngeal anomaly may be considered from an evaluation of the history and symptoms; but the final diagnosis is made only by means of direct visual examination of the larynx through the direct laryngoscope, with or without anesthesia. Lateral x-rays of the neck to identify soft tissue structures in the region of the larynx are of great aid in identifying the size of some lesions such as congenital cysts. Cinefluoroscopy is almost indispensable in differentiating a neurogenic overflow from a small, high tracheoesophageal fistula and assists in identifying the rare laryngo-esophageal cleft. Cinefluoroscopy of the esophagus and trachea is indicated as well in order to rule out possible compressing esophageal vascular anomalies or anomalies of the tracheobronchial tree.

Direct laryngoscopy of the infant larynx may be carried out with a small laryngoscope without an anesthetic. However, if severe dyspnea is present, the instrumentation may precipitate complete respiratory obstruction; therefore, in an acute emergency, direct laryngoscopy should be attempted only if the diagnosis cannot be established otherwise or if surgical relief of the obstruction through direct examination and aspiration, intubation, or tracheostomy is being considered. Instrumentarium for this eventuality should be ready if a direct examination of the obstructed larynx is contemplated. The difficulties of direct laryngoscopy in infants are the small size of the larynx and the curled, short, slippery, omega-shaped epiglottis. The larynx is easily displaced, and there is a tendency toward spasm of the larynx as the laryngoscope is introduced. This often makes visualization of the true cords and of the glottic airway difficult. The procedure must be done rapidly to avoid instrumental trauma. Visualization of the motility of the true cords may be determined best by first inserting the blade of the laryngoscope into the vallecula prior to dipping it under the epiglottis tip to visualize the glottis and the anterior commissure.

CLASSIFICATION

The following clinical classification of congenital anomalies of the larynx is practical; the incidence of each indicates its relative frequency observed by one of us during a period of 30 years in a pediatric hospital and a university endoscopic clinic.

1. Cartilaginous Anomalies 657
 - Laryngomalacia 650
 - Absence or deformities
 - Epiglottis 2
 - Thyroid cartilage 0
 - Cricoid cartilage
 - Fusion of ring 3
 - Failure of dorsal fusion (laryngo-esophageal cleft) 2
2. Cysts and Laryngoceles 20
 - Internal thyroglossal duct cysts 5
 - Glottic cysts 3
 - Ventricular laryngoceles 5
 - Artenoid and aryepiglottic fold laryngoceles 7
3. Webs, Stenoses and Atresia 86
 - Supraglottic webs 4
 - Glottic webs 24
 - Glottic atresia 1
 - Subglottic webs 4
 - Subglottic stenosis 53
4. Duplication of Cords 0
5. Neurogenic Lesions 84
 - Bilateral recurrent laryngeal nerve paralysis 56
 - Unilateral recurrent laryngeal nerve paralysis 28
6. Vascular Anomalies 19
 - Hemangiomas 13
 - Lymphangiomas 6

1. *Cartilaginous Anomalies.* Laryngomalacia, or congenital laryngeal stridor, is a common, transient form of stridor in infants which is associated with a softness or abnormal flaccidity of the laryngeal cartilages. Stridor is a symptom which is generally indicative of respiratory obstruction rather than a specific disease entity, and consequently the former term is preferred. In every infant with stridorous, noisy respirations, a differentiation must be made as to whether the symptoms are produced by the soft, flaccid structures of the larynx, by a neurogenic or other obstruction due to congenital anomalies, or a lesion acquired in infancy. Typically, the stridor of laryngomalacia is present from birth and is at first audible only on inspiration. It may be either constant or intermittent and may vary with the position of the infant, being louder when the infant is on its back, and sometimes scarcely noticeable or absent when the infant is

on its abdomen. The fluttering nature of the stridor may lead one to suspect that the infant's hypopharynx is filled with mucus but aspiration does not relieve the condition. Synchronous with the stridor may be fluttering intercostal, suprasternal or epigastric retractions. A number of infants with congenital laryngeal stridor are noted to have funnel breast (*pectus excavatum*). The association with micrognathia has been suggested but is not apparent in our group of patients. Laryngoscopy is necessary to confirm the diagnosis and to rule out other causes of stridor. In many cases, the epiglottis is the structure from which the fluttering sound originates, although the arytenoids may participate with the epiglottis which is curled or tubular in extreme instances. Generally, symptoms subside gradually after one to one and a half years, and rarely is surgical intervention necessary. Tracheostomy has been necessary only in two extreme cases when feedings were either accompanied by severe cyanosis, or had to be interrupted so frequently to allow the infant to breathe that the infant failed to gain weight. The two infants that required tracheostomy because of these complications were ultimately extubated when they reached one and a half years of age.

Congenital absence of the epiglottis is a rare anomaly encountered only twice in this series, and in both instances it was associated with severe glottic stenosis. Absence of the thyroid cartilage has not been encountered. Deformities of the cricoid cartilage are more numerous. Three have been observed with a shelf-like plate of cartilage filling the convex inner surface of the arch, extending posteriorly as a solid, rigid sheet leaving only a small posterior opening and necessitating tracheostomy.

Laryngotracheal-esophageal cleft in infants has been encountered twice and consists of a failure of dorsal fusion of the cricoid lamina. The clinical picture is very similar to that of a tracheo-esophageal fistula which is accompanied by an absent or very weak cry. Anatomical findings consist of a dehiscence between the arytenoids which extends inferiorly through the cricoid lamina, descending to involve the "party wall" between the trachea and esophagus for varying distances. Surgical correction is recommended through a lateral pharyngotomy. It is a severe anomaly often associated with extensive anomalies of other organ systems.

2. *Cysts and Laryngoceles.* Most congenital cysts described in the literature are confined to the immediate neighborhood of the ventricular appendix. It is probable that cysts are the result of simple disturbances in fetal development and not genuine embryonic malformations. Congenital cysts and laryngoceles have a similar development, but cysts do not communicate with the interior of the larynx. Laryngoceles admittedly become clinically perceptible only when swollen by air forced into them, or when filled with a collection of fluid; thus it is obvious that congenital laryngoceles and cysts are often indistinguishable from each

other. Glottic cysts have their origin in the true and false cords. Laryngoceles, however, originate from the ventricle, either bulging out from between the true and false cords or dissecting posteriorly into the arytenoid and aryepiglottic fold. Three infants have been seen who have had simple congenital glottic cysts. Twelve cases of congenital laryngoceles have been observed in infants, whereas 51 laryngoceles have been seen in adults. Of the 12 infants, nine were females and three males. The sacs were ventricular in five cases and involved the aryepiglottic fold in seven. Three were seen at less than a week of age, four from one week to one month of age, two between one and six months, and three over six months of age.

Internal thyroglossal duct cysts are found at the base of the tongue, and while generally they are cystic enlargements of the portion of the thyroglossal duct proximal to the hyoid bone, they occasionally originate from the laryngeal ventricle. They produce laryngeal symptoms of dysphagia and dyspnea by pushing the epiglottis posteriorly, trap-door fashion, over the larynx. Their presenting symptoms are dyspnea and a weak or absent cry. Therapy consists of aspiration with a heavy bore needle through the direct laryngoscope. Few require surgical removal through an external pharyngotomy. A total of five infants with this anomaly have been seen, all treated by laryngoscopic needle aspiration of the cyst when respiratory obstruction occurred. None required more extensive marsupialization as has been suggested, nor was it necessary to remove them externally, as is done in the usual thyroglossal duct cyst appearing in the anterior surface of the neck.

3. *Webs, Stenoses and Atresias.* Supraglottic webs consist of a fusion of the false cords of varying degrees from the anterior commissure posteriorly to a point just above the vocal processes of the arytenoids. Respiration is maintained through a small posterior chink. The condition is much less common than the glottic web. Only four infants with supraglottic webs have been seen.

Glottic webs are seen in three forms: a thin, transparent, membranous sheet covering the superior surfaces of the cords and the anterior part of the glottis between them; a web of varying thickness between portions of the membranous cords; fusion of the anterior half of the phonating edges. Twenty-four patients with congenital glottic webs have been observed. There were 11 males and 13 females. In 16 cases the web consisted of a membrane across the anterior portion of the glottis at the level of the superior surfaces of the cords, through which the outlines of the phonating edges of the cords could be distinguished. The degree to which the glottis was covered varied from small anterior commissure webbing to almost complete closure of the glottis. In the majority of cases the anterior two-thirds of the glottis was involved, the tough membrane originating along the entire membranous cord with the exception of the vocal process of the arytenoid; it arched anteriorly to leave a posterior chink for respiration.

In four infants the web consisted of an extremely thin, transparent membrane across the anterior one-half of the larynx at the level of the superior surface of the true cords. These newborn infants made no sound on crying, and a direct laryngoscopy was performed for diagnostic purposes. The membrane was visualized and split with laryngeal alligator forceps. The edges immediately retracted into the laryngeal mucosa. In four infants, the congenital glottic web appeared to be a fusion of the anterior half of the phonating edges of the cords which were in apposition with each other, separating posteriorly in an inverted "V". Passage of dilators through the larynx demonstrated the fused portion of the glottis to be fibrous, the fusion extending subglottically. The degree of fibrosis necessitated the use of a tantalum keel for effective surgical correction.

Congenital atresia of the larynx is obviously incompatible with life unless the condition is recognized immediately at birth and steps are taken at once to establish an airway. One such case is reported by Jackson and Jackson, in which direct laryngoscopic examination of a "blue baby" that had ceased to make respiratory movements immediately after delivery revealed a complete membranous occlusion of the glottis. The airway was established by a 3 mm bronchoscope which was forced through the web into the trachea. A similar dramatic instance has been reported previously, in which an emergency tracheostomy a few minutes after birth established an airway. A subsequent direct laryngoscopy revealed the presence of an atresia.

Congenital subglottic webs. Four infants with subglottic membranous webs have been observed. These must be differentiated from subglottic stenosis and cartilaginous deformities of the cricoid, both of which they simulate.

Congenital subglottic stenosis. This clinical picture consists of a thickening of subglottic structures and sometimes of the true cords themselves which cause respiratory obstruction of a severe degree in newborn infants. The least laryngeal inflammation precipitates the need of a tracheostomy since the limiting cricoid cartilage does not permit swelling of tissues in any direction other than inwardly, at the expense of the airway. The point of greatest obstruction is generally 2 to 3 mm below the level of the superior surface of the true cords. Biopsy of one such area showed no inflammatory reaction. This condition must be differentiated from the severe obstructing deformities of the cricoid cartilage described above. Fifty-three cases of congenital subglottic stenosis of the larynx have been seen. There were 31 males and 22 females. The earliest symptom of this condition beginning at birth was stridor with or without episodes of cyanosis depending upon the severity of the stenosis. In mild cases, recurrent episodes of "croup" were the only suggestion of this condition, with repeated superimposed respiratory infections simulating laryngotracheobronchitis, although characterized by severe obstruction with minimal evidence of infection. Progressive

respiratory distress necessitates a tracheostomy which was required in 39 of the 53 infants with congenital subglottic stenosis.

Mild stenosis usually disappears with growth of the larynx. In more severe cases, periodic dilatations of the larynx are performed to attempt to increase the lumen to a more adequate caliber. This can be done without fear of resulting edema leading to complete obstruction of the larynx in patients who have been tracheotomized, but such therapy carries some risk if done without a tracheotomy. With an inflammatory component, adequate antibiotics, hydration and a humidified atmosphere are of utmost importance.

4. *Duplication of Cords.* This extremely rare anomaly has been reported as consisting of an accessory vocal fold demonstrated on both gross and microscopic finding to exist immediately below the normal glottis. It has been considered responsible for hoarseness in patients in whom the condition has been described but has not been encountered in this series.

5. *Neurogenic Lesions.* The paralysis of one or both vocal cords in newborn infants is usually a serious laryngeal manifestation of a gross anomaly of another organ system. Bilateral paralysis or paresis is rarely seen in an otherwise normal infant, but is generally found in association with cerebral agenesis, severe retardation, a meningomyelocele, or as a result of birth trauma. Unilateral paralysis found at birth is more common on the left than on the right because of the involvement of the left recurrent laryngeal nerve in anomalies of the great vessels, the heart, the esophagus or the tracheobronchial tree. In surgical procedures for congenital lesions such as a patent ductus, double aortic arch, esophageal atresia or a bronchogenic cyst, the left recurrent laryngeal nerve is particularly vulnerable.

The indications for the laryngeal examinations in the newborn which revealed the laryngeal paralyse herein recorded were dyspnea, an absent or weak cry, abnormalities of deglutition, or known cardiac, central nervous system or esophageal anomalies. The use of an anesthetic for the laryngoscopy is unnecessary; it adds to the hazard of the procedure and makes difficult an evaluation of cord movement. Vocal cord action and a comparison of the motility of one cord with the other is best determined when the laryngoscope blade is introduced into the vallecula and the tongue lifted forward. Only after laryngeal movement has been studied during this phase of the examination should the laryngoscope blade be inserted under the epiglottis and the configuration of the cords, the anterior commissure and the subglottic surface studied. It is often apparent at this time that the blade of the laryngoscope fixes the right vocal cord through pressure on the right aryepiglottic fold to simulate the appearance of right vocal cord paralysis. This may lead to a false diagnosis if not re-evaluated with the blade in the vallecula to permit freedom of cord movement.

Inspection must include a sufficient observation time to insure visualization on inspiration as well as during phonation or cry. Often this is difficult because of cyanosis, apnea, or the cardiac status of the infant, the examination having been requested because of a known severe congenital cardiac anomaly. Oxygen should be administered throughout the direct laryngeal examination, and the duration of the procedure itself limited or discontinued if cyanosis develops. Preparations for a tracheotomy should be made before beginning the laryngoscopy if dyspnea is severe; not because of the laryngoscopic examination itself, but because of the pathology disclosed by the examination; a bilateral paralysis may require a tracheotomy if life is to be maintained.

It seems apparent that laryngeal nerve paralysis in infants is more common than previously recorded. In a review of 84 infants with laryngeal paralysis, partial or complete bilateral paralysis was observed in 56. In 34 of these the laryngeal paralysis was only one phase of a major neurologic disorder. In bilateral paralysis, the cry is clear, although weak, but the dyspnea was severe enough to have required a tracheotomy in 36 of the 56 cases. Dysphagia with aspiration of food was a common phenomenon because of the frequency of an associated pharyngeal paralysis. Unilateral vocal cord paralysis was observed in 28 of the 84 infants; the right cord in 10, and the left cord in 18. In only three of the 28 infants with unilateral paralysis was a tracheotomy necessary. The prominent clinical feature of the 28 was the weak or absent cry. In four of the 10 infants with right cord paralysis, this paralysis was an isolated finding in otherwise apparently normal infants. However, in 14 of the 18 infants with left cord paralysis a congenital cardiovascular lesion was considered to be the etiologic factor of the paralysis. Thus in infants with bilateral vocal cord paralysis the lesion is most frequently a part of a generalized central nervous system disorder and, as such, the prognosis is relatively poor. Infants with the right cord paralysis may have no other neurologic lesion or the condition may be associated with other peripheral anomalies; the prognosis for ultimate voice function is relatively good. In the majority of infants with left vocal cord paralysis an associated cardiovascular anomaly is the etiologic factor. While the prognosis regarding voice is fair, the ultimate prognosis is dependent on the cardiac status and the presence of the cord paralysis may influence any contemplated surgical corrective procedure.

6. *Vascular Anomalies.* Congenital vascular lesions of the larynx fall into two categories, capillary and cavernous hemangiomas and lymphangiomas. The great majority of hemangiomas occur about the head and neck and it is apparent that infants with hemangiomas of the skin often have laryngeal, particularly subglottic, hemangiomas. They are found in a predominance of females to males in a ratio of more than five to one, and are generally recognized soon after birth when infants with obvious skin lesions become increasingly hoarse and

dyspneic. Direct laryngoscopy discloses pharyngeal and laryngeal mucosal discoloration, and swelling. Changes in the larynx are progressive, similar to progressive changes noted in the skin lesions.

Thirteen infants, 11 females and two males ranging in age from three days to 10 months, have been observed with laryngeal hemangiomas, all associated with similar skin lesions. Tracheotomy was required in 12 of the 13 cases at some time during this observation, all before six months of age. Spontaneous involution occurs, and therefore active surgical or irradiation therapy is avoided or postponed. Surgical failure to control the lesion is often complicated by distortion and destruction of the phonating mechanism; irradiation is complicated by loss of the growth potential of the larynx causing a chronic laryngeal stenosis as the infant grows to adulthood. Nevertheless, six of the 13 infants required irradiation, usually 400 r given only once because of progressive enlargement of the external and laryngeal lesions.

Five cases of cavernous hemangiomas have been seen, two males and three females, all adults. In three, the lesions were localized on the arytenoids, one on the left false cord and two on the left aryepiglottic fold with extension upward onto the lateral pharyngeal wall and palate. Only one has required partial pharyngeal and neck resection because of a progressive increase in size not controlled by sodium morrhuate injections.

Lymphangiomas are generally laryngeal extensions of cystic hygromas of the neck usually requiring tracheostomy because of extensive laryngeal swelling in conjunction with the neck mass. Improvement follows only after control of the neck mass.

SUMMARY

Commonest of all congenital anomalies of the larynx is laryngomalacia. This anomaly is characterized by a gradually increasing stridor during the first year of life which spontaneously decreases in intensity and disappears six months to a year later. It is important because stridor is the principal symptom of all obstructions of the airway, congenital and acquired, and therefore must be accurately identified to differentiate it from other conditions characterized by stridor such as laryngeal cysts, subglottic stenoses and vascular rings. Other cartilaginous anomalies are absence of the epiglottis and deformities of the cricoid such as a stenotic cricoid ring and a laryngo-esophageal cleft.

Cysts and laryngoceles are encountered originating in the neighborhood of the ventricle of the larynx. Internal laryngoceles protruding from between the true and false cords and those bulging within the aryepiglottic fold generally have some connection with the interior of the larynx. Glottic cysts and internal thyroglossal duct cysts do not have actual or potential communication with the interior of the larynx.

Webs may be a supraglottic fusion of the false cords, glottic membranes between the true cords, or fusion of the anterior portion of the true cords, or subglottic webs which are membranous, distinct from cartilaginous cricoid obstruction. Congenital glottic atresia is rarely seen in the living because only if immediately recognized at birth and relieved at once by intubation or tracheostomy can the infant survive.

Subglottic stenosis, a thickening of the subglottic structures, is common and accounts for many cases of recurring "croup" or prolonged extubation in infants tracheostomized because of the respiratory obstruction early in life.

Bilateral laryngeal paralysis is associated with cerebral retardation, a meningomyelocele or extensive birth trauma. Unilateral left cord paralysis may often be traced to anomalies of the heart or great vessels, the esophagus or the tracheobronchial tree. Unilateral right cord paralysis may be seen in an otherwise normal infant. It should be noted that the voice (cry) of an infant with bilateral recurrent laryngeal nerve paralysis is more normal than one with a unilateral paralysis; but inspiration is stridorous and a large per cent require a tracheostomy.

Vascular anomalies consist of hemangiomas and lymphangiomas, the former as capillary and cavernous, usually associated with other hemangiomas about the head and neck, the latter as laryngeal extensions of a cystic hygroma.

700 N. MICHIGAN AVE., CHICAGO, ILL. 60611

INFLAMMATORY DISEASES OF THE LARYNX OF INFANTS AND SMALL CHILDREN

F. W. DAVISON, M.D.

DANVILLE, PA.

Croup is the diagnosis most frequently made when a physician sees a child with acute laryngeal obstruction. This diagnosis is inadequate because there are at least five different causes of the obstruction. Dorland's Illustrated Medical Dictionary, 24th Edition, 1965, defines croup as follows: "A condition resulting from acute obstruction of the larynx caused by allergy, foreign body, infection or a new growth occurring chiefly in infants and children and characterized by resonant barking cough, hoarseness and persistent stridor."

It seems evident that croup does not apply to a specific pathological entity and therefore should not be used as a diagnostic label because the term is too indefinite. In order to clarify the diagnosis and thus pinpoint the urgency and type of treatment indicated, I suggest the following classification of acute obstructive laryngitis in children.

1. Acute epiglottitis
2. Supraglottic allergic edema
3. Laryngeal diphtheria
4. Subglottic allergic edema (spasmodic croup, false croup)
5. Acute laryngotracheobronchitis (subglottic laryngitis and non-diphtheritic croup, virus croup)

Each of these forms of acute laryngeal obstruction causes the classic symptoms of stridor, retraction of the soft tissues above the clavicles and in the epigastrium during inspiration and elevated pulse and respiratory rates, but the urgency and treatment needed depend on the type of disease present.

ACUTE EPIGLOTTITIS

This term is applied to inflammation involving chiefly the epiglottis and aryepiglottic folds. It is a clinical entity and should be distinguished from all

From the Department of Otolaryngology and Broncho-Esophagology, The Geisinger Medical Center, Danville, Pa.

other types of laryngeal obstruction, because it develops with great rapidity. Only four or five hours may elapse from the first symptom until the time that tracheostomy is urgently needed. Failure to recognize this fact may lead to a fatality, as is evident from the following case report.

CASE 1. This child, a male aged two and a half years, was in good health until eight hours before admission when he had an emesis and was noted to have a temperature of 103° . Two and a half hours prior to his admission on the pediatric service his respirations become noisy and rapid. While a lumbar puncture was being attempted, the child ceased breathing. An emergency tracheostomy was performed in the ward but respirations were not re-established. One hour had elapsed from the time of admission until the time of death. Much work had been done as evidenced by the large number of laboratory reports in the chart, but the child died because the attending physician did not know that a child with epiglottitis can breathe reasonably well sitting up and yet breathing can become totally obstructed by the swollen supraglottic structures when the child is placed in the horizontal position. For those who place great faith in the importance and veracity of cultures, I cite the following facts. This child's nasal culture showed a *diplococcus pneumoniae*, the throat culture a *Beta hemolytic streptococcus* and the blood culture showed *Hemophilus influenzae*.

The clinical picture is usually recognizable without direct laryngoscopy. Direct laryngoscopy should be done only by someone who has at hand a 3.5 mm bronchoscope and knows how to introduce it rapidly and safely. The fiery red and tremendously swollen epiglottis can be seen if the child is examined while being supported and restrained in the sitting position if the examiner uses a head light and a small, child-sized metal tongue blade. If the examination is done skillfully and quickly there will be only momentary increase in dyspnea. These children should not be restrained in the supine position.

With this type of obstruction there is stridor on inspiration and a coarse fluttering sound during expiration due to vibration of the swollen aryepiglottic folds. A croupy cough is never present because a croupy cough is due only to subglottic swelling. I have never seen epiglottitis and subglottic inflammation in the same patient. Respirations are apt to be relatively slow in relation to the pulse rate because the patient has learned that rapid or forceful inspiration sucks the edematous aryepiglottic folds into the larynx and thus increases the obstruction. Pale cyanosis is often present. The shock-like picture described by some authors is in my opinion due to hypoxia. I say this because it clears up immediately after introduction of a bronchoscope and performance of a tracheostomy. As Miller¹³ says, these children insist on sitting up and extending the head forward in order to increase the greatly narrowed supraglottic airway. Older children will complain of pain in the throat. Swallowing is very difficult, so saliva drools from the mouth.

This type of infection is usually but not always due to *H. influenzae* type B.

Acute epiglottitis may occur in children of any age from five months up to adulthood. If the child is three years of age or younger it is safest to perform a tracheostomy as soon as the diagnosis is made, but prior to tracheostomy a 3.5 mm bronchoscope should be inserted without anesthesia.

Introduction of a flexible endotracheal tube has been advocated by some, but in my opinion the airway through the tremendously swollen supraglottic structures can be found much more readily if one uses the 3.5 mm bronchoscope. After the bronchoscope has been introduced, general anesthesia can be administered by the side arm of the bronchoscope during performance of a tracheostomy.

In the past I have used streptomycin plus penicillin by intramuscular injection as the antibacterial therapy. Intramuscular ampicillin probably offers the same antibacterial spectrum.

I have never known a child to have two attacks of acute epiglottitis, but frequently children do have recurring attacks of acute subglottic laryngitis.

Epiglottitis remains a localized infection. It does not extend downward to produce bronchitis.

One of the best early articles on acute epiglottitis was written by Miller in 1948. Prior to that time many authors had failed to distinguish between the supraglottic and subglottic types of laryngeal inflammation. Miller pointed out that increasing hoarseness is a constant complaint in laryngotracheobronchitis, but it is rarely noted in patients who have *H. influenzae* epiglottitis. He said the children who have epiglottitis have a muffled, thick guttural voice and much higher fever than do the children with subglottic laryngitis and show more evidence of toxemia, prostration and exhaustion.

SUPRAGLOTTIC ALLERGIC EDEMA

Allergic edema involving the supraglottic structures can develop with great rapidity and present exactly the same clinical picture as that caused by acute supraglottic laryngitis, but direct laryngoscopy shows a pale watery edema of the epiglottis and aryepiglottic folds in contrast to the fiery red edema seen when the obstruction is due to *H. influenzae* infection. Allergic edema will usually respond quickly to parenteral administration of epinephrine plus hydrocortisone phosphate, but in one of my cases it was necessary to insert a bronchoscope and leave it in position for a period of fifteen minutes until the edema had subsided sufficiently to permit unembarrassed respiration. In this patient, a six year old boy, the acute supraglottic allergic edema was the result of antitetanic serum given ten days previously.

LARYNGEAL DIPHTHERIA

Laryngeal diphtheria sometimes occurs when there is no membrane visible on the pharynx or tonsils, so that an accurate diagnosis must depend on direct laryngoscopy, smears and cultures. However, certain points in the history and physical examination should lead the examiner to suspect its presence. Usually diphtheritic laryngitis is slow in development with a lapse of two or three days from the onset of hoarseness until dyspnea is sufficiently marked to require tracheostomy. The cry is hoarse because normal vibration of the cords is hampered by the presence of membrane.

A specimen for smears and cultures can be obtained by using an aspirating collector through the direct laryngoscope. If there is a membranous type of exudate, or if the direct smears are positive for the presence of diphtheria organisms, it is advisable to give antitoxin and penicillin without waiting for the culture report. Further details of the management of diphtheritic cases may be found in any of the standard pediatric textbooks.

SUBGLOTTIC ALLERGIC EDEMA
(SPASMODIC CROUP, FALSE CROUP)

Characteristically, children with subglottic allergic edema waken at night with dyspnea, croupy cough and inspiratory stridor. They usually have been quite well the preceding day, may possibly have had a little rhinitis but no fever. By morning the symptoms clear up only to recur the next night and possibly for several succeeding nights. For generations this clinical picture has been referred to as spasmodic croup, the inference being that the obstruction is due to adductor spasm of the vocal cords. This concept is erroneous for the following reason. The sound of the croupy cough is identical with that produced by the subglottic swelling seen by direct laryngoscopy in cases of acute laryngotracheitis. In cases of nocturnal croup direct laryngoscopy shows a pale watery edema of the subglottic tissues. The obstructive symptoms clear up within fifteen minutes after subcutaneous administration of 0.2 cc of aqueous solution of 1:1000 epinephrine. The rapid onset of stridor and later improvement in one to four hours in these patients having allergic edema is quite comparable to the transitory nature of hives in the skin.

I⁵ have suggested the term subglottic allergic edema for this malady because it is descriptive of both the anatomical location and the etiology. It is distinguished from the other forms of obstructive laryngitis by its sudden onset and by the complete or almost complete remission of symptoms during the daytime. All physicians to whom I have suggested the use of epinephrine for treatment of nocturnal spasmodic croup have reported that it was effective and have said in addition that use of diphenhydramine hydrochloride (Benadryl[®]) saved them many night calls for children who were subject to croup.

ACUTE LARYNGOTRACHEOBRONCHITIS

(SUBGLOTTIC LARYNGITIS, NON-DIPHTHERITIC CROUP OR VIRUS CROUP)

Acute laryngotracheitis starts as a primary subglottic laryngitis.⁴ The obstruction is due to two factors. 1) Inflammatory swelling of the submucous tissues in the conus elasticus and 2) crusting of transudate on the surface of the conus elasticus where loss of epithelium has occurred. These crusts can be softened by humid air and can be dislodged by the forceful cough induced by prodding the tongue downward at the height of inspiration. These children have a dry croupy cough and inspiratory stridor produced by subglottic swelling. In almost all cases the sound of the cry is clear, indicating that the edges of the vocal cords are normal and free of membrane. The temperature varies from 100° to 105°. The dyspnea becomes progressively worse for a period of one to seven days before it is severe enough to require admission of the child to a hospital. If untreated the infection spreads downward to produce bronchitis and pneumonitis as reported by Richards¹⁹ in 1933.

Many of the patients have had previous acute rhinitis. This causes mouth breathing so that the extremely dry indoor air in winter impinges directly on the larynx without having been moistened by passage through the nose.

The pathological changes observed by means of direct laryngoscopy and bronchoscopy are redness and swelling of the lateral walls of the trachea just below the vocal cords so that the subglottic space is reduced to an antero-posterior slit 1 to 2 mm wide as described by Holinger⁹ and by Brenneman and associates.¹ Often the subglottic tissues are coated with a layer of dry, rough, adherent exudate which extends downward about 1 cm below the cords and increases the obstruction. Usually this exudate does not have the appearance of diphtheritic membrane. The swelling of the subglottic tissues is firm and indurated as demonstrated by the fact that it requires considerable pressure to introduce even a 3.5 mm bronchoscope. This subglottic swelling is not due to simple watery edema, but to infiltration of the submucous tissues of the conus elasticus with inflammatory cells as postmortem examinations have shown. Holinger and Johnston¹⁰ have called our attention to the fact that the subglottic tissues are surrounded by the firm cartilaginous ring of the cricoid so that the inflammatory swelling can take place only at the expense of the airway.

Rabe,¹⁸ Cramblett² and others think that subglottic laryngitis is due primarily to a virus infection, but our cultures and those of Neffson¹⁵ indicate that any of the pathogenic gram positive cocci can be the bacterial agent responsible for this disease. Moreover, smears made from the intratracheal exudate aspirated through the bronchoscope introduced just prior to tracheostomy often show gram positive cocci mixed with neutrophils, so it seems unnecessary to postulate a virus infection as the cause of the disease. In addition, most patients have

shown such prompt response to treatment with penicillin that it seems evident that the infection is due to penicillin-sensitive organisms. It is of course possible that a virus does initiate the infection.

Please note that the reduction in mortality from the 70 per cent reported by the Jacksons¹¹ to near zero in recent years has not been brought about by antiviral agents. The viral theory of origin has done nothing to prevent or cure the disease.

TREATMENT

The most urgent part of the treatment is relief of the airway obstruction. These patients are placed immediately in the humidified oxygen tent or croupette. The relative humidity should be at least 90 per cent with the temperature maintained between 70° and 75° F.³ The high humidity helps to maintain the fluidity of the tracheal bronchial secretion and tends to soften the crusts adherent to the subglottic mucosa, so that they can be coughed out. We frequently see rapid improvement in the airway within two hours after a child has been placed in a humidified tent

The nurse is instructed to count and record the pulse and respiratory rates every fifteen minutes. I regard a pulse rate of over 140 or a respiratory rate of over 40 per minute as danger signs. If the pulse and respiratory rate continue to increase during the next three hours it is probable that tracheostomy will be required. If there is obvious urgent dyspnea with marked retraction and the pale gray type of cyanosis at the time of admission, a small bronchoscope is introduced and the tracheostomy performed immediately before the child is placed in the tent. This situation is illustrated by Case 2.

CASE 2. An eight year old boy was admitted in an almost moribund state. He was pale and irrational and had rapid shallow noisy respiration. There was marked indrawing of the soft tissues in the suprasternal notch and in the epigastrium with each inspiratory effort. Immediate direct laryngoscopy showed marked redness and swelling of the lateral walls just below the vocal cords. Hard, dry, adherent crusts almost filled the remaining airway. A 5 mm bronchoscope was introduced and the crust were removed with aspirator and forceps. An orderly tracheostomy was then performed. After five minutes, the boy sat up and drank a cup of water. Cultures from the endotracheal exudate showed a beta hemolytic streptococcus. The temperature which was 103° F (39° C) on admission of the patient returned to normal in less than two days. Additional treatments used were a humidified tent, fortified procaine penicillin G, 1 million units, by intramuscular injection every four hours and streptomycin, 0.25 gm, by intramuscular injection every eight hours. The tracheal cannula was removed on the sixth day and the patient went home on the eighth day.

The value of postural drainage and postural irrigation in the tracheotomized cases have been described by Galloway.^{7,8}

In the past I have relied chiefly on adequate doses of penicillin and safe doses of streptomycin by intramuscular injection. Recently we have been using ampicillin by intramuscular injection.

By using these principles of treatment, I was able to report, in 1959, 140 cases including 28 for whom tracheostomy was required with only one fatality. Fearon⁶ in 1962 reported a series of 4,148 patients with only four deaths. This is the largest series with the best results recorded anywhere in the world.

Since 1958 we have been using corticosteroids with increasing frequency, giving intramuscular injections of 100 mgm of hydrocortisone succinate or hydrocortisone phosphate as soon as the child is admitted. Occasionally the dose is repeated in eight hours. The value of this therapy is indicated by the fact that in the past two years 114 children have been admitted to our hospital with a diagnosis of laryngotracheitis and not one has required a tracheotomy. Eighty per cent of these children received hydrocortisone.

Mills¹⁴ points out that after intramuscular injection of hydrocortisone maximum plasma cortisol levels are reached in 30 minutes to 2 hours.

In 1960 Novik¹⁶ reported a controlled series of 208 cases in which every other patient was treated with prednisone. His conclusion was that administration of Prednisone[®] did reduce the incidence of tracheostomy.

Pennington¹⁷ wrote in 1964, "In six years of practice in a large municipal hospital where approximately 200 cases of croup are admitted each year, no tracheostomy has been necessary for an inflammatory laryngeal condition since the introduction of steroids in the treatment of edema of the subglottic compartment."

In 1967 Lederer and associates¹² reported, "In allergic patients corticosteroids are particularly helpful since laryngotracheobronchitis in these patients tends to be more progressive and severe. Often one cannot immediately determine which of these patients are allergic. During an emergency, therefore, steroids might well be given in all cases of laryngotracheobronchitis having respiratory obstruction."

If tracheostomy is required, I prefer the technique described by Waldapfel.²²

I think a horizontal or collar type of incision through the skin is wrong for a tracheostomy in children because it will not permit the lower one-fourth of the tracheal cannula to be aligned with the long axis of the trachea. It should be remembered that during coughing or deep respiration, the trachea may move up and down at least an inch. If the cannula is not free to move with the trachea or if its lower end is not perfectly aligned with the tracheal lumen the lower

edge of the cannula will dig into the tracheal mucosa causing erosion, crusting and obstruction. Adequate humidification will not prevent crusting due to this factor if it is present.

The danger of placing the tracheostomy fistula too low has been well demonstrated by Silen and Spieker²⁰ who reported four proved and two suspected cases of massive hemorrhage from the innominate artery as a complication of tracheostomy. In these cases postmortem examination showed that the tracheal stomas were between the fifth and eighth tracheal rings.

Two other complications of tracheostomy that can be avoided are excessive crusting, all too often due to deep catheter aspiration and pneumothorax which seldom occurs if a bronchoscope is introduced prior to performance of tracheostomy. However, spontaneous pneumothorax can occur as indicated by the following case report.

CASE 3. A three year old boy was admitted on the pediatric service with a chief complaint of croup. Symptoms had been present for only 24 hours prior to admission. Six hours prior to admission the difficulty in breathing became severe. On admission the temperature was 99.6° F (37.5° C); the respiratory rate was 40 and the pulse rate 120 per minute. Thirty minutes after admission the child became cyanotic. An emergency tracheostomy was performed without previous insertion of a bronchoscope. A No. 2 tracheal cannula was inserted without difficulty, but the child still had a pale ashen gray type of cyanosis and labored breathing. Breath sounds were absent over the left side of the chest. Thoracentesis was immediately performed and 200 cc of air was aspirated. The breathing and color promptly improved. It is probable that the pneumothorax was present before tracheostomy and was the cause of the sudden attack of cyanosis which prompted the tracheostomy. His convalescence was uneventful.

In an effort to avoid tracheostomy, Striker and associates²¹ used nasotracheal intubation for fourteen patients who had acute laryngotracheobronchitis. During intubation cardiac arrest occurred in five patients and there were two fatalities. The other complication was subglottic stenosis in four patients which developed between two and six weeks after extubation. It seems evident that properly performed tracheostomy is the best method of relieving inflammatory obstruction of the larynx in children if medical treatments have failed to relieve the obstruction.

In summary, the treatment factors that have progressively lowered the mortality from 70 per cent in 1936 to almost zero in 1966 may be listed as follows:

1. Close observation by an experienced physician.
2. Cool moist air provided by a humidified oxygentent.

3. Adequate doses of penicillin and *safe doses* of streptomycin.
4. Early tracheostomy after insertion of a bronchoscope.
5. Postural drainage and postural irrigation.
6. Avoidance of instrumental trauma to the mucosa of the trachea and bronchi.
7. Administration of corticosteroids.

GEISINGER MEDICAL CENTER, DANVILLE, PA. 17821

REFERENCES

1. Brennemann, J., Clifton, W. M., Frank, A., and Holinger, P. H.: Acute Laryngotracheobronchitis. *Am. Jour. Diseases of Children* 55:667-693 (Apr.) 1938.
2. Cramblett, H. G.: Croup (Epiglottitis, Laryngitis, Laryngotracheobronchitis), p. 261, in *Disorders of the Respiratory Tract in Children*, edited by Kendig, E. L., Jr. W. B. Saunders Co., Philadelphia, 1967.
3. Davison, F. W.: Some Observations on the Control of Temperature and Humidity in Oxygen Tents. *ANNALS OF OTOTOLOGY, RHINOLOGY AND LARYNGOLOGY* 49:1083 (Dec.) 1940.
4. Davison, F. W.: Acute Laryngotracheobronchitis - Further Studies on Treatment. *Arch. Otolaryngol.* 47:455, 1948.
5. Davison, F. W.: Acute Laryngeal Obstruction in Children. *J.A.M.A.* 171:1301-1305 (Nov. 7) 1959.
6. Fearon, B.: Acute Laryngotracheobronchitis in Infancy and Childhood. *Pediatric Clinics of N. America* 9:1095-1112 (Nov.) 1962, published by W. B. Saunders Co., Philadelphia.
7. Galloway, T. C.: Postural Treatment of Acute Laryngotracheobronchitis. *J.A.M.A.* 112: 1566-1569 (Apr. 22) 1939.
8. Galloway, T. C.: Treatment of Respiratory Emergencies Including Bulbar Poliomyelitis. Charles C. Thomas, Pub., Springfield, Ill., 1953.
9. Holinger, P. H.: Acute Laryngotracheobronchitis. *Jour. Mich. State Med. Soc.* (Dec.) 1937.
10. Holinger, P. H., and Johnston, K. C.: Factors Responsible for Laryngeal Obstruction in Infants. *J.A.M.A.* 143:1229-1232 (Aug. 5) 1950.
11. Jackson, C., and Jackson, C. L.: Acute Laryngotracheobronchitis. *J.A.M.A.* 107:929-932 (Sept. 19) 1936.
12. Lederer, F. L., Samter, M., Gendler, J. C.: The Patient, the Prescription, the Problem: Corticosteroid Therapy in Otorhinolaryngology. *Trans. Am. Acad. of O. and O.* 71:262-271 (Mar.-Apr.) 1967.
13. Miller, A. H.: Acute Epiglottitis. *Trans. A.A.O.O.*, pp. 519-524 (May-June) 1949.
14. Mills, I. H.: *Clinical Aspects of Adrenal Function*. F. A. Davis Co., Philadelphia, 1964.
15. Neffson, A. H.: Acute Laryngotracheobronchitis. Grune and Stratton, Inc., New York, 1949.
16. Novik, A.: Corticosteroid Treatment of Non-Diphtheritic Croup. *Acta Otolaryngol. Suppl.* 158:20 (June) 1960.

17. Pennington, C. L., Jr.: Glottic and Supraglottic Injury and Stenosis from External Trauma. *Laryngoscope* 74:317, 1964.
18. Rabe, E. F.: Infectious Croup, II Virus Croup. *Pediatrics* 2:415-427 (Oct.) 1948.
19. Richards, L. G.: Fulminating Laryngotracheobronchitis. *ANNALS OF OTOTOLOGY, RHINOLOGY* 42:1014-1040 (Dec.) 1933.
20. Silen, W., and Spieker, B.: Fatal Hemorrhage from the Innominate Artery After Tracheostomy. *Trans. Pac. Coast Oto-Ophthal. Soc.*, pp. 361-374, 1965.
21. Striker, T. W., Stool, S., and Downes, A. J.: Prolonged Naso-Tracheal Intubation in Infants and Children. *Arch. Otolaryngol.* 85:210 (Feb.) 1967.
22. Waldapfel, R.: Classic and Other Types of Tracheotomy. *Arch. Otolaryngol.* 45:446, 1947.

TREATMENT OF AIRWAY PROBLEMS IN THE NEWBORN

CHARLES F. FERGUSON, M.D.
BOSTON, MASS.

The two classic moments of greatest import in the life of any living organism are those of birth and death. As a result of enormous strides in medicine during the past few decades (always euphemistically characterized as "medical progress"), the latter milestone is no longer one definite moment, but often a prolonged period of time, with an indeterminate end-point. In fact, now the process of death may actually cover a matter of weeks or months, often creating serious legal complications. By employing sundry physicochemical or biochemical apparatus, on occasions it may not even be possible to determine whether a body is truly alive or existing merely as a heart-lung preparation! However, birth still occurs at one specific time, and this shocking experience is the most precarious moment in the life of the individual.

Sudden emergence from a completely protective and homeostatic environment into a hostile and constantly changing outside world, where all vital systems must be on an immediate "go" basis, creates for this emerging organism a new and completely independent existence. Lungs, which until now have remained solid, with their associated airways completely filled with fluid and debris, must suddenly be cleared and quickly inflated with air. However, adequate air exchange demands a patent and normally developed pathway from the nose practically to the diaphragm. As the placenta (the fetal lung) is suddenly eliminated as the source of constant oxygenation and the new lung is on its own, profound circulatory adjustments must also immediately be made. Lung expansion, which results from altered blood gases and other biochemical changes, a drop in environmental temperature and new tactile and pain stimuli, produces increased pulmonary blood flow. This in turn causes a reduction in pulmonary vascular resistance and arterial pressure. Removal of the large placental vascular bed produces a rise in systemic vascular resistance and arterial pressure. The net result forces the blood flow through the ductus arteriosus to reverse itself, and the flow now is from left to right. The ductus, already very sensitive to oxygen tension, closes almost completely within the first twenty-four hours. This increases pulmonary venous return to the left atrium, which closes the valve of the foramen ovale located on the left side of the arterial septal wall. However,

if pulmonary pathology is present (e.g., atelectasis, pneumothorax, hyaline membrane obstruction, or intrauterine pneumonia) or the main airway is obstructed, there is additional hypoxia and pulmonary arterial hypertension. This tends to keep the ductus open, and causes a return to the fetal right to left shunt. Further hypoxia now on a circulatory basis ensues, thereby creating a vicious cycle. Obviously, a properly functioning airway and adequate oxygenation are most important and vital factors for the survival of the newborn infant, and for the proper change-over to a normal postfetal circulation and respiration.

Unfortunately, there may be little time for adequate clinical investigation of an urgent airway problem at birth, although cardiac, neurological, or even esophageal abnormalities may simulate airway obstruction. Slow, shallow respirations in a cyanotic infant, who is making poor attempts to breathe and shows no chest retractions, may indicate cardiac disease, cerebral damage or other central nervous system difficulty, toxicity, or over-sedation of the mother. A rapid respiratory rate with the forced use of all accessory muscles, associated with retractions of the chest, usually indicates true respiratory distress and not simple respiratory depression. This is an important distinction to make from the beginning, since respiratory distress usually indicates airway obstruction.

The importance of an immediate evaluation of the newborn infant was emphasized in 1953, when Dr. Virginia Apgar¹ promulgated her now classic scoring technique (Table I). This technique assigns values of 0, 1 or 2 points

TABLE I
APGAR SCORING TECHNIQUE FOR NEWBORNS

<i>Sign</i>	<i>Heart rate</i>	<i>Resp. rate</i>	<i>Muscle tone</i>	<i>Reflex irritability</i>	<i>Color</i>
0	absent	absent	limp	no response	blue, pale
1	below 100	slow irregular	some flexion	grimaces	pink trunk, blue extrem.
2	over 100	good crying	active motion	cough, sneeze	all pink

to five very important but simple, observational factors, and an immediate Apgar score of 0 to 10 can be obtained as early as one minute after delivery, and may be checked again for comparison at 5, 10 or 30 minute intervals. Categories considered are 1) color, 2) respiratory efforts such as crying, 3) heart rate, 4) muscle tone, and 5) cough or sneeze response to nasal catheter stimulation. Scores of under 3 demand urgent resuscitation, and carry a very poor prognosis.

Scores of 4 to 6 indicate moderate depression in an infant who needs immediate attention, but whose condition is momentarily otherwise satisfactory. Scores above 7 are associated with a good prognosis, although idiopathic respiratory distress syndrome may not be manifested for several hours. One further advantage in making this simple early evaluation is that the catheter used to produce the nasal stimulation for cough and sneeze can be passed through each nostril on down into the stomach, thereby ruling out both a choanal as well as an esophageal atresia. These two conditions are important causes of airway obstruction in the newborn. It also has the added advantage of immediately clearing the airway of secretions.

Further procedures to be considered in an infant suspected of airway difficulties are x-ray studies of the chest, with lipiodol swallow, angiography, laryngoscopy, or bronchoscopy as indicated. Blood gas and pH determinations may be necessary for proper treatment of respiratory or metabolic acidosis. The history of the mother may give valuable information in determining the cause of respiratory difficulty in the infant. If the mother is a diabetic, or the baby is prematurely delivered, especially by cesarean section, idiopathic respiratory distress syndrome (hyaline membrane disease) is to be suspected. If the mother has had a preceding respiratory infection, or if the membranes have been ruptured over 12 hours, or if the delivery has been contaminated, pneumonia must be considered. If the mother has been on Reserpine® or similar drugs, nasal edema in the infant may be very marked, even simulating the picture of choanal atresia. In instances of prolonged gestation with a postmature baby, or in cases of maternal bleeding, breech delivery, prolapsed cord or placental insufficiency, massive pulmonary aspiration of amniotic fluid and meconium must first be considered.

If oxygen is to be administered, the infant's airway must immediately be completely aspirated of mucus, debris or meconium. Since the use of 100% oxygen over a prolonged period of time predisposes to retrolental fibroplasia, the concentration should be just high enough to maintain a pink color. Unless the airway is patent, forced oxygen administration may produce serious injuries to the respiratory or gastrointestinal tract. If intermittent positive pressure is used, such pressure should not exceed 20 to 25 cm of water. When resuscitation is indicated because of apnea, laryngoscopy using a Holinger aspirator, followed by the gentle insertion of a proper-sized, soft endotracheal tube is recommended. Positive pressure then can be applied directly to the tube which prevents over-inflation of the stomach. If mouth-to-mouth or mouth-to-tube resuscitation is necessary because of lack of proper equipment, care should be taken not to blow too forcefully, but to exhale air gently from a previously well-filled lung. External cardiac massage is a procedure which must be used with the utmost gentleness in the newborn. Intravenous sodium bicarbonate or THAM (or

TRIS-trishydroxy-methyl-aminomethane) will correct acidosis, but frequent blood pH and blood gas determinations must be made. Infants have a poorly developed cough reflex and make very little effort on their own to clear the airway. Respiration in infants must move proportionately greater amounts of air than in adults, since there is proportionately greater surface area. This is accomplished by increasing the rate of respiration, but not the depth, leaving a very small tidal volume. Therefore, slight reduction in this tidal volume (already low as in diaphragmatic hernia, or a very small pneumothorax, or slight pleural effusion, possibly insignificant in an older child) may produce a very serious problem in an infant. Death may be sudden and totally unexpected. Death in respiratory distress is usually due to 1) hypoxia, 2) respiratory acidosis, or 3) circulatory failure, so treatment includes 1) oxygen, 2) intravenous sodium bicarbonate and glucose (with frequent pH determinations), and 3) possibly digitalization.

SPECIFIC PROBLEMS

Before a specific airway problem can be treated, it is essential to know the location of the obstruction, since difficulties may occur anywhere from the external nares to the diaphragm. It would be impossible in anything short of a monograph to cover all airway problems of the newborn, but Table II will illustrate important locations and causes of airway obstruction. A few of these problems will be discussed briefly.

NASAL AND NASOPHARYNGEAL OBSTRUCTIONS

One of the commonest causes of stillbirth may be bilateral choanal atresia, although unfortunately this anomaly is not always suspected or properly diagnosed even at autopsy, so meaningful statistics are woefully deficient. It should be a simple diagnosis to make at birth. An otherwise normal newborn infant will die unless there is a patent nasal airway. The harder the infant tries to breathe, the tighter the mouth is shut, and death from asphyxia rapidly ensues. Mouth-breathing is purely and simply an acquired accomplishment. In bilateral choanal atresia, all of the classical signs of airway obstruction are present, such as dyspnea, cyanosis, gasping, intercostal and sternal retractions, and asphyxia. In only 5 to 10% of such patients is there a simple membranous obstruction. In these cases, perforation of the membrane and the use of an indwelling vinyl tube for a few days result in a satisfactory cure. In the 90% who show bony obstruction, such treatment frequently is inadequate and later definitive surgery is indicated for the removal of the bony obstruction. Better than a mouthgag, airway, or tongue suture, is the use of the McGovern nipple technique, where an old-fashioned rubber nipple with the tip cut off is left strapped in the infant's mouth for a two to three week period. Although such a patient requires relatively constant nursing care, this care is no greater than that demanded by an

TABLE II
AIR WAY PROBLEMS IN THE NEWBORN

-
1. *Nose and Nasopharynx*
 - Atresia or agenesis
 - Cysts (nasal encephaloceles)
 - Congenital choanal atresia
 - Tumors (dermoids, teratomas)
 2. *Oral Cavity*
 - Macroglossia
 - Lymphangioma
 - Muscular hypertrophy
 - Micrognathia (hypoplasia of mandible)
 - Treacher-Collins syndrome
 - Pierre-Robin syndrome
 - Cysts or tumors
 - Thyroglossal duct cyst
 - Aberrant thyroid
 - Lymphangioma (cystic hygroma)
 3. *Neck*
 - Congenital goiter
 - Cystic hygroma
 - Tumors
 4. *Larynx*
 - Atresia
 - Subglottic stenosis
 - Webs
 - Laryngomalacia
 - Tumors
 - Hemangioma
 - Papilloma
 - Cysts
 - Paralysis
 - Subluxation of arytenoids
 5. *Trachea*
 - Tracheomalacia
 - Webs
 - Stenosis
 - Tracheo-esophageal fistula with esophageal atresia
 - Compressions
 - Vascular anomalies
 - Tumors of mediastinum
 - Cysts (esophageal duplications)
 6. *Lung or chest cavity*
 - Pneumonitis (aspiration or intrauterine)
 - Atelectasis (primary or secondary)
 - Pneumothorax
 - Pneumomediastinum
 - Congenital lobar emphysema
 - Congenital cystic disease (solitary or multiple)
 - Congenital chylothorax (or other effusions)
 - Diaphragmatic hernia (or paralysis)
 - Hyaline membrane disease (IRDS)
 - Pulmonary hemorrhage
 - Tumors
 - Agenesis or hypoplasia

infant with a tracheotomy. In general, tracheotomy for this condition is usually unnecessary as well as undesirable. Through the use of the McGovern nipple, the infant can be properly fed, and also has an adequate airway at all times. Within 10 to 14 days mouth-breathing is usually satisfactorily established, although the infant may be a problem in feeding for a longer period. The transpalatal operation can be satisfactorily performed after one month of age, at which time all of the atretic bone and the posterior third of the septum are removed, and the palate heals by primary intention. In 1964 Dr. Flake and I² reported on 40 cases of choanal atresia, with nearly 50% of them (19 cases) satisfactorily operated upon under six months of age.

Other causes of upper airway obstruction to be considered in the newborn are cysts, tumors, or even nasal atresia or agenesis. A cystic mass in the nose of an infant most probably will prove to be a nasal encephalocele. Six of 546 meningoceles and encephaloceles reported by Ingraham and Matson³ were nasal, and obviously in these cases aspiration or local surgery on the mass would be disastrous. The accompanying defect in the cribriform plate is best closed through a neurosurgical approach from above. Solid nasopharyngeal masses in the newborn may be teratomas or dermoids, and surgical removal is indicated.

MOUTH AND NECK OBSTRUCTIONS

In cases of oral or pharyngeal obstruction, respirations are usually stertorous and raspy, with no inspiratory stridor or crowing. Malformations of the first branchial arch result in hypoplasia of the mandible, and frequently other associated defects, as seen in the Treacher-Collins syndrome (mandibulofacial dysostosis). If the palate is partially cleft and the tongue unusually large, it is referred to as the Pierre-Robin syndrome, and this is a common cause of airway obstruction in the newborn. In such instances, the relatively large tongue falls back into the incomplete cleft of the palate, and when the infant is supine, the harder he tries to breathe, the tighter he sucks the tongue into the defect. Even without a cleft palate, an associated macroglossia produces glossoptosis when associated with hypoplasia of the mandible. True macroglossia is commonly due to a lymphangioma in the substance of the tongue or the floor of the mouth. In rare cases there exists a genuine hypertrophy with excessively large individual muscle fibers, not merely an increase in the number of the fibers. Koop⁴ has reported eight cases of macroglossia involving lymphangiomas of the tongue, which he resected. Three were in the newborn period, and tracheotomy was necessary in each of these instances.

Patients with the Treacher-Collins syndrome, the Pierre-Robin syndrome, or true macroglossia, can usually be treated satisfactorily by being kept in a prone position, strapped to a Bradford frame, to allow the tongue to fall forward and maintain a proper airway. A plastic feeding tube, a cleft palate feeder, or even

the McGovern nipple technique, may be used for ten days or two weeks, and by that time proper feeding is learned. Traction sutures on the tongue usually result in erosion, further edema, or tearing out of the suture. They generally are unsatisfactory. In troublesome cases, the so-called Douglas procedure of temporarily suturing the tongue to the lower lip or floor of the mouth has been used. However, this method is usually unnecessary. Tracheotomy is rarely indicated in such patients, and proper breathing and feeding will usually result in ten days to two weeks.

Cysts or tumors at the base of the tongue should suggest the possibility of a thyroglossal duct cyst or aberrant thyroid. If the cyst is causing obstruction, it can be simply and immediately aspirated with prompt relief of symptoms. However, such a cyst will continue to fill up until it is properly removed by dissection and the secreting epithelium completely destroyed. Lymphangiomas of the tongue are not infrequently associated with cystic hygromas of the neck, so that swelling is visible externally as well as internally. Congenital goiter may be large enough to cause a respiratory problem in the newborn, and may require surgical removal of the isthmus and central portion of the gland even in the first few days of life. Thyroid extract causes marked regression in a few days. Congenital goiter is usually seen in infants whose mothers have taken iodides or antithyroid drugs during pregnancy.

LARYNGEAL OBSTRUCTIONS

Involvement of this vital area of the airway is frequent in the newborn, since it is anatomically the narrowest portion of the respiratory tract. Nearly 30 cases of atresia of the larynx have been reported, most of them, however, autopsy reports. The condition must be immediately recognized, and instant tracheotomy or puncture of a simple membranous obstruction must be performed at the delivery table. Otherwise, a stillbirth results. Violent inspiratory efforts on the part of the infant, with no air entering or leaving the lung, should give immediate warning of impending disaster.

The commonest cause of laryngeal obstruction, producing an inspiratory type of stridor, a high-pitched crow, dyspnea, retractions, and even cyanosis, is the exaggerated infantile larynx (laryngomalacia). This in itself rarely causes severe obstruction, and in most cases the stridor is not apparent until the second or third week of life. Direct laryngoscopy reveals the abnormality, and rules out a more serious cause of airway obstruction. Laryngomalacia is due to lack of proper mechanical support of the laryngeal structures during inspiration. The epiglottis is characteristically narrow and tubular in appearance, and the aryepiglottic folds closely approximated toward the midline. This causes them to be drawn into the glottis during inspiration. The cry is usually clear and strong differentiating it from a web. As the aryepiglottic folds and epiglottis are

retracted by the tip of the laryngoscope, the stridor subsides. No treatment is necessary for this condition, except in very rare instances where the symptoms are very marked and tracheotomy may be necessary. Most cases, however, resolve spontaneously within 6 to 12 months by further growth and development of the larynx.

With laryngeal web, the cry is usually hoarse or even aphonic, since 75% of these webs involve the glottis itself. Some webs may be broken by the insertion of a bronchoscope, but the thicker ones may need incision through the laryngoscope, followed by occasional dilatations. Tracheotomy must always be considered if the obstruction is severe.

Laryngeal paralysis occurs in the newborn, and when bilateral it should suggest birth trauma to the brain stem. Tracheotomy may be indicated here. However, unless there is significant brain damage, rapid improvement may ensue as edema subsides, and intracranial hemorrhage is brought under control. Unilateral paralysis of the larynx is usually peripheral and most commonly seen on the left side, since the course of the left recurrent laryngeal nerve is a long one, and the nerve is subject to trauma in the neck or compression within the thorax. Chest x-rays, barium swallow or angiography may be indicated to demonstrate pressure on the recurrent laryngeal nerve in its thoracic portion.

In subglottic stenosis, hemangioma must always be considered, although symptoms due to this condition are not usually manifested for several weeks after birth. However, stridor and recurrent episodes of croup may occur during the first few weeks of life in the specific newborn period. If a subglottic hemangioma is demonstrated, roentgen therapy in the order of 300 to 450 r usually produces prompt resolution, and in most cases tracheotomy is not necessary.⁵

TRACHEAL PROBLEMS

Atresia of the esophagus is thought to occur approximately once in twenty-five hundred deliveries, and 90% of these infants have an associated tracheo-esophageal fistula which connects with the lower esophageal segment. This malformation produces a respiratory problem immediately following birth, since vomiting and aspiration of foreign material occur at the very first attempt to feed. Even though the infant may appear normal at birth, within a few minutes he begins to choke on his secretions, and may develop cyanotic attacks due to the overflow of mucus into the airway. The necessity for repeated suctioning should always suggest the possibility of esophageal atresia with tracheo-esophageal fistula. Abdominal distension on crying adds to the respiratory distress. If a practice is made to pass a catheter through each nostril into the stomach shortly after birth, the diagnosis should be obvious in every case of atresia of the esophagus before symptoms develop. If confirmation is indicated, roentgen studies with lipiodol

swallow will confirm the diagnosis. Emergency repair of the atresia, with closure of the fistula, must be done even if pneumonitis has developed, since pneumonitis will become progressive as a result of constant aspiration.

Vascular compressions of the trachea may produce respiratory problems early in life, although in most instances severe symptoms may not be apparent in the newborn period, but frequently develop during the following two to four months. Dyspnea from birth, with intermittent cyanotic attacks especially during feedings or change of position, associated with a biphasic type of stridor (usually predominantly expiratory), and wheezing and hyperextension of the head are commonly seen in this condition. If the esophagus is involved, regurgitation and aspiration pneumonitis may ensue. Commonest anomalies are the double aortic arch, producing a complete vascular ring around both trachea and esophagus, the right aortic arch with a patent ductus, or a tight ligamentum arteriosum, and anterior compressions of the trachea from innominate or left common carotid arteries. Esophagogram and bronchoscopy with contrast medium injections of the trachea confirm the diagnosis. Early surgical correction of the tracheal compression is necessary to allow proper development of the cartilaginous rings, and in cases of double aortic arch severe difficulty is usually encountered by six months of age.

Respiratory distress in the newborn may be due to primary tracheomalacia where the cartilaginous supporting rings are either absent or deficient. The lumen becomes considerably narrowed during expiration, associated with a rather stertorous type of stridor and characteristic wheeze. Bronchoscopic examination confirms the collapsibility of the trachea, and is important in ruling out a congenital web or secondary tracheomalacia due to extrinsic compression from a vascular ring or mediastinal tumor, such as a neuroblastoma, teratoma or lymphoma. Tracheotomy is usually not indicated in these cases of tracheomalacia, but conservative management with humidification and prevention of respiratory infections by antibiotic therapy are in order. The condition is usually satisfactorily outgrown.

PULMONARY PROBLEMS

Pneumothorax. Treatment of airway problems in the newborn necessarily must include some reference to the many serious pulmonary conditions, although time and space in a symposium such as this prevent anything but a very superficial coverage of this broad and important field. Because of the frequent necessity for artificial resuscitation at birth, and the use of various mechanical resuscitators and positive pressure insufflation techniques, complications are bound to occur. Among the more important are pneumothorax and pneumomediastinum. If positive pressure is not carefully monitored, or if the airway is partially obstructed and a closed system used with an airtight face mask, rupture of alveoli may occur. It does not take much pressure or a very sustained period of

resuscitation to produce this accident. Alveolar rupture is followed by interstitial emphysema, with dissection of air along the sheaths of the great vessels and bronchi to the mediastinum, with accumulation of large bubbles of air in the mediastinum. Rupture of subpleural blebs may produce pneumothorax. Pneumothorax may also occur spontaneously in infants with idiopathic respiratory distress (hyaline membrane disease) especially in those who are premature or who have pneumonitis, particularly *Staphylococcus aureus* in origin. Rupture of the esophagus or stomach has also occurred during the process of resuscitation. If the pneumothorax is small, it should be left alone and will resolve satisfactorily as the air completely absorbs. If the pneumothorax is large and the patient's pulmonary function significantly embarrassed, or if the pneumothorax is of the tension type, air should be withdrawn by a large syringe and needle. This relieves over half of the cases of pneumothorax. If air tends to recur and tension is produced, closed intercostal drainage laterally in the fifth or sixth interspace is carried out with attachment to water suction or Wangenstein bottles. Open thoracotomy is indicated only if there has been a rupture of a major bronchus or the esophagus. Bronchoscopy is not indicated unless such rupture is suspected. Pneumomediastinum is best treated by watchful waiting and avoidance of chest tap, since the air is usually encapsulated in multiple blebs, and tapping may produce further complications. If the pneumomediastinum is very severe, it is possible to drain the area anteriorly by a suprasternal notch incision, and finger dissection breaks up the isolated air blebs.

Congenital Lobar Emphysema. Occasionally confused with pneumothorax is congenital lobar emphysema of the newborn. This condition, however, usually involves the right upper or right middle lobes, but may be seen in the left chest as well. Although bronchial obstruction may not always be demonstrable, it is considered to result from bronchial obstruction at some earlier stage, possibly due to deficiency or absence of the cartilages (chondromalacia), stenosis or web formation. Extraluminal pressure may be an etiological factor, but frequently the cause cannot be determined. The entrapped air is unable to escape, and the rest of the lung may be severely compressed, with shift of the mediastinum, resulting in severe respiratory distress with cyanosis. Emergency bronchoscopy may be of value in locating the obstruction, but if symptoms are severe, lobectomy in the newborn period is indicated. Aspiration is unwise, since pneumothorax results, with recurrence of the original condition. Occasionally regression without surgery may occur, but the patient must be watched carefully for the development of respiratory embarrassment.

Congenital Cystic Disease. True bronchogenic cysts in small infants are rare, except those multiple pneumatocoeles resulting from staphylococcus pneumonia very early in life. These are associated with a history of preceding infection, sometimes dating from delivery. They tend to regress with time and proper

antibiotic treatment. However, the congenital solitary lung cyst is not uncommon, and may be due to malformation of a tiny or twisted bronchiole allowing air to enter the segment, with rupture of alveolar spaces, and formation of a true cyst. A single cyst may become very large within a few days, and may fill the entire hemithorax with mediastinal displacement as in lobar emphysema. On examination there are absent breath sounds and an almost tympanic note on percussion, and the picture may become confused with pneumothorax. X-rays, however, show the cyst with its curved outline, and fine pulmonary trabeculations surrounding it, with no hilar shadows. Frequently, the cysts contain fluid which becomes infected, and there are cartilage or muscle elements in the walls. Early operative removal by lobectomy is essential, and sometimes even pneumonectomy is necessary. Aspiration is a risky procedure, and in cases of true cysts it is ineffective. This condition should always be suspected in any infant who shows significant respiratory distress, and the true pulmonary cyst of the newborn demands early surgical intervention.

Other intrathoracic cysts may result from malformations of the gastrointestinal tract. Esophageal duplications may be responsible for airway compression in the newborn, resulting in dyspnea, tachypnea and cyanosis from birth. These are found in the posterior mediastinum and cause pressure on the esophagus as well as the airway. Severe hemorrhage may result from peptic digestion of the cyst wall, with erosion of closely related blood vessels. Solid masses in the anterior mediastinum are usually teratomas, whereas posterior mediastinal masses are usually neuroblastomas or occasionally lymphomas. In any case, surgery is indicated.

Congenital Chylothorax. Congenital chylothorax is rare, but can produce signs of respiratory distress in the first week or two of life. Symptoms are produced by a sudden accumulation of chyle in the chest cavity, due to birth trauma, or a congenital anomaly of the thoracic duct or mediastinal and pulmonary lymphatics. There may be a massive effusion of chyle into the thorax, with considerable respiratory distress. Dullness and diminished breath sounds are found, and roentgenograms show the mediastinum displaced to the opposite side. Recommended treatment is aspiration of the chyle from the chest, and in 50 per cent of the cases one or two aspirations are sufficient to control the condition, although thoracotomy to repair a large leak and to ligate the thoracic duct has occasionally been necessary.

Agenesis of the lung, and other associated congenital anomalies, should be mentioned, but in these instances there is usually no specific airway problem.

Idiopathic Respiratory Distress Syndrome (Hyaline Membrane Disease). The commonest single cause of respiratory distress in the newborn, which accounts for 30 per cent of all neonatal deaths, and 50 to 70 per cent of all

premature deaths, is idiopathic respiratory distress or hyaline membrane disease. In the United States alone, it is estimated that 2,500 infants die each year from this condition, in spite of the best treatment available. The incidence is highest in premature infants (under 2,500 gms), and in those babies delivered of diabetic mothers, especially if cesarean section has been employed, since these infants are generally more immature. At birth such infants may have a satisfactory Apgar score, but after a symptomless interval of a few hours rapidly deteriorate with signs of increasing respiratory distress. The respiratory rate rapidly increases to 80 to 100 per minute, with shallow irregular breathing, an expiratory grunt, poor air exchange, rapid pulse, bulging abdomen, and signs of respiratory or metabolic acidosis. Even on oxygen inhalation, the arterial oxygen tension may be less than 40 to 50 mm of mercury.

Because of a deficiency of surfactant lining the alveolar spaces necessary for maintaining lung stability, the terminal alveoli collapse on expiration, even though the bronchioles may become distended. This gives a granular appearance to the x-ray. Unless the biochemical cause for this deficiency of surfactant is discovered, treatment can be only symptomatic, and therefore unsatisfactory. If the infant can survive for three or four days, the prognosis rapidly improves, since most of the deaths occur within the first three days of life.

Treatment consists of oxygen and humidity of at least 65%, assisted ventilation (never over 25 to 30 cm of water), and the correction of acidosis by the administration of sodium bicarbonate (100 milliequivalents per litre in 10% dextrose at the rate of 65 ml per kg per day). The blood pH should be titrated frequently and ideally kept around 7.4. Unfortunately, with adequate oxygen, even under pressure and even in high concentrations over a sustained period, it is not always possible to maintain satisfactory oxygenation of the blood, or keep the alveoli from collapse. THAM (or TRIS) may be used as an acceptor of hydrogen ions, and this may be some improvement over sodium bicarbonate, since it does not increase the sodium ion or reduce carbonic acid ($p\text{CO}_2$). It will reduce the metabolic acidosis (lactic acid accumulation), but does not affect the respiratory acidosis (with CO_2 retention). Although this is the commonest cause of death of newborns, treatment in general is still unsatisfactory. These patients, however, rarely come under the care of the otolaryngologist unless tracheotomy is requested, and in most instances this procedure has also proved disappointing.

Congenital Diaphragmatic Hernia. A severe airway problem of the newborn infant is not infrequently created by a diaphragmatic hernia. This is usually a serious situation and demands immediate surgery. In contrast to the adult where a hiatal hernia is the rule, most instances of diaphragmatic hernia in the newborn and early infancy are due to a defect in the posterior crus of the diaphragm, with a persistent pleuroperitoneal sinus. This is the so-called hernia of the foramen

of Bochdalek. It is usually a large defect and allows most of the viscera to be extruded up into the chest, causing severe respiratory distress with cyanosis, dyspnea and tachypnea. Attacks may be intermittent. Death usually occurs in a few hours if operation is unduly postponed, because the opposite lung also remains atelactatic. These hernias are predominantly on the left side, since this is the side to close last in embryonic life. Occasionally, there is an anterior hernia into the retrosternal space of Morgagni, and here strangulation is frequent because of the very small opening. In this case, there is usually a serosal sac, but none is seen in the hernia of Bochdalek. In a series of 91 cases of diaphragmatic hernia, Gross⁶ reported that 82 (69 on the left and 13 on the right) were through the foramen of Bochdalek, only 4 through the retrosternal space of Morgagni, and only 5 of the esophageal hiatal type. The latter cases do not demand immediate surgical treatment, as is so imperative in the former two situations.

The treatment for a diaphragmatic hernia, once it is suspected from x-ray studies, is the immediate insertion of a nasogastric tube to deflate the stomach and prevent further intestinal distension which compresses the good lung. Also necessary are intermittent suction and oxygen administration through an endotracheal tube to prevent further stomach distension while transporting the baby to a center where immediate surgery can be carried out. Surgical repair must be performed as soon as the baby has been properly prepared and cross-matched with blood for transfusion.

300 LONGWOOD AVE. 02115

REFERENCES

1. Apgar, Virginia: Proposal for New Method of Evaluation of Newborn Infant. *Anesthesia and Analgesia* 32:260, 1953.
2. Flake, C. G., and Ferguson, C. F.: Congenital Choanal Atresia in Infants and Children. *ANNALS OF OTOLARYNGOLOGY AND LARYNGOLOGY* 73:458, 1964.
3. Ingraham, F. D., and Matson, D. D.: Spina Bifida and Cranium Bifidum: Unusual Nasopharyngeal Encephalocele. *New Eng. Jour. Med.* 228:815, 1943.
4. Koop, C. E., and Moschakis, E. A.: Capillary Lymphangioma of the Tongue Complicated by Glossitis. *Pediatrics* 27:800, 1961.
5. Ferguson, C. F., and Flake, C. G.: Subglottic Hemangioma as a Cause of Respiratory Obstruction in Infants. *ANNALS OF OTOLARYNGOLOGY AND LARYNGOLOGY* 70:1095, 1961.
6. Gross, R. E.: *The Surgery of Infancy and Childhood*. W. B. Saunders, Philadelphia, 1953.

LARYNGOMALACIA: ITS RADIOLOGIC DEMONSTRATION

J. SCOTT DUNBAR, M.D.

MONTREAL, CANADA

A few years ago in trying to assess an infant in the first few months of life, who had inspiratory stridor, radiologic reliance was placed on the absence of findings that were attributed to any other cause. In the absence of such other abnormalities and the presence of a typical clinical picture, it was ascribed to laryngomalacia, with or without laryngoscopy. In the difficult cases, laryngoscopy was done.

It would be of value to have a positive approach to this, for the severity of laryngomalacia varies from one child to another. Young infants make some kind of quiet or soft noise on inspiration in certain stages of relaxation and it is reasonable to attribute this to normal flaccidity of the laryngeal structures and normal relaxation of the muscles. There are patients who make enough noise that the mother consults the physician and the physician reassures her.

Radiologically, this problem can be approached by the two main methods at our disposal, namely, x-rays of the laryngeal area and x-ray movies. The lateral projection is the only one that is of any value. In all the problems of respiratory obstruction where the site of the obstruction is not definite, x-rays of the neck and of the chest are performed separately in AP and lateral projections. In laryngomalacia the AP projection has no value at all because the structures are obscured by the cervical vertebral column.

It is important to look at the infant who may have laryngomalacia while a noise is being transmitted. Laryngomalacia is intermittent and when the infant cries or is excited, the symptoms of laryngomalacia tend to disappear presumably because the laryngeal structures tighten up under excitement or increased effort to a point where the flaccidity is no longer present and the stridor disappears. This is very characteristic. When the infant tends to be relaxed or to sleep, the stridor appears or becomes more severe so that it is important to take an x-ray when the infant is actually making the noise; thus the x-rays are made usually by spot films to expose the film when the noise is actually occurring. Otherwise, nothing abnormal will be seen and the same applies to cineradiography.

A lateral film of the neck shows the base of the tongue and the hyoid bone, the epiglottis, the aryepiglottic folds, the larynx, the trachea below this and the

retropharyngeal structures, which are mobile and bulge forward in expiration. Inspiration and expiration films of this area are taken when an upper tract problem is being investigated and the chest is included when the etiology of the airway obstruction is not yet known.

When the inspiratory stridor is occurring the findings vary from an epiglottis which is slightly tilted backward and aryepiglottic folds which are slightly buckled forward to the point where the buckling is quite striking and very obvious. A normal infant in quiet respiration has a pharynx which only changes volume very slightly in relaxed breathing, while the baby with an obstruction of any kind, croup, laryngomalacia, or hemangioma of the subglottic area inflates the pharynx during inspiration as he breathes against an obstruction. The buckling of the aryepiglottic folds anteriorly as they suck downward into the glottic chink may be quite striking.

On the plain film the features of obstruction are a dilated pharynx with the aryepiglottic folds bending forward and there is no other condition that can produce these x-ray findings. Contrast media have been of no particular value in diagnosis.

In the normal infant, the baby in the relaxed condition shows only slight dilatation of the pharynx on inspiration, slight movements of the tongue and very slight movements of the aryepiglottic area. They elongate, but they do not show any significant buckling or collapse anteriorly. In an abnormal infant there is tremendous anterior displacement of the aryepiglottic folds with sometimes a small aryepiglottic flutter. The epiglottis remains remarkably stable. The aryepiglottic laxity is absolutely characteristic of laryngomalacia in the infant. The pharynx and the epiglottis remain stationary, while the aryepiglottic folds collapse or flop into the glottic chink.

The condition is usually a mild and benign situation, but occasionally becomes sufficiently severe to cause concern on the part of the attending physician. There have been a few cases in whom laryngomalacia could not be demonstrated roentgenologically when it was obvious endoscopically. In the last five years the number of cases that have been endoscoped for laryngomalacia has dropped almost to the vanishing point, because in those cases where there is doubt it is almost always possible to show the condition radiologically without endoscopic intervention.

DISCUSSION

DR. ROBERT B. LEWY: All of us have faced the tragedies and terrible challenges which are involved in this condition and as a consequence I think that we are interested in every minute thing that might be of therapeutic value.

Dr. Williams asked me to pass on the question as to the risk involved in the use of 100 per cent oxygen; also I am wondering whether the use of helium as a vehicle for the oxygen might be of value.

I wonder also whether the proteolytic enzyme streptodornase, streptokinase or corresponding enzymes might possibly have some value in the treatment of these cases, in dissolving crusts.

Would the use of a wetting agent such as sodium lauryl sulfate, which has been reported in the literature, have value?

I also wonder whether the use of a high humidity room rather than a tent would seem so confining? Is this a practical thing to do? Does it have value?

DR. WILLIAM FRANKLIN KEIM: Having had a couple of shattering experiences in the past with an attempt to establish the airway through the larynx, especially in cases of acute epiglottitis, I have abandoned the introduction of any form of endotracheal airway in these patients. It has seemed to me that where there is supraglottic pathology and even in the subglottic inflammatory changes, it is adding insult to injury to try to insert a tube through this area and even though our incidence of tracheostomies is lower now with the corticosteroids, occasionally we do have to do a tracheostomy and it has been more effective and less traumatic to me, and to the patient, to do it without the tube introduced from above.

I was really shocked a few days ago to read a paper from the Philadelphia Children's Hospital, advocating the use of indwelling nasotracheal tubes in many of these respiratory problems and it seems to me that a refutation of this rests on the incidence of three cases of laryngeal stenosis in their series, so that I think we should take up the cudgels against this kind of practice.

DR. CHARLES F. FERGUSON: I just want to say one thing, that I would thoroughly endorse Dr. Davison's use of corticosteroids in the treatment of acute laryngeal infections. I think it has been the one advance which has cut down the incidence of tracheotomy more than anything else, more than humidification, and more even than the use of antibiotics. We have cut down our incidence of tracheotomy tremendously.

I should also like to go on record in thoroughly condemning the use of the nasotracheal tube in infections of the larynx and advising resort to tracheotomy when it is indicated. We are seeing more and more complications from the use of indwelling endotracheal tubes and at the Council meeting of the Broncho-Esophagological Association in January we even discussed the possibility of having a Registry formed, such as the Bone Registry or the Tumor Registry, for the reporting of these complications so we will have something specific with which to confront the anesthesiologists who have been pushing this technique so much. There is no doubt that we are now seeing many, many cases of severe laryngeal damage due to the indwelling endotracheal catheter used to tide over the patient in order to prevent him, as they say, in quotation marks, "prevent him" from having to "undergo a tracheotomy."

DR. DAVISON (closing): I have never used 100 per cent oxygen.

I like the tents rather than the room. It is easier to handle and our oxygen concentration in tents is hard to keep up above 50 per cent.

I have not been satisfied with the use of enzymes or proteolytic agents of any kind. I have relied entirely upon water vapor.

I have not used helium. My feeling is that when a youngster gets to the point that he needs helium, he needs a tracheotomy.

LARYNGEAL REFLEX PATHWAYS RELATED TO RATE AND RHYTHM OF THE HEART

MASAFUMI SUZUKI, M.D.
(by invitation)

JOHN A. KIRCHNER, M.D.
NEW HAVEN, CONN.

Arrhythmia, bradycardia and cardiac arrest may result from mechanical stimulation of the upper or lower respiratory tract. In patients under general anesthesia, these disturbances are enhanced by hypoxia or hypercapnia, by light anesthesia and by certain types of anesthetic agents.¹⁻⁵ Topical anesthesia of the larynx and trachea before intubation may not only fail to prevent these complications but may, of itself, produce significant increases in blood pressure and pulse rate.⁶ Similar disturbances have been reported in patients who were intubated while awake.⁶

Most observers agree that ventricular arrhythmias and other cardiac disturbances during endotracheal manipulation are due to increased arterial CO₂ or decreased O₂ and are usually transient.^{7,8} They are significant, however, as a warning that conditions are not satisfactory and that more serious trouble may be in store for the patient. Electrocardiographic evidence of extra systoles, shifting pacemaker and changes in A-V conduction are regarded by Harken and Norman as "pre-fibrillation states," a warning of impending ventricular fibrillation or cardiac arrest.⁹

Reflex bradycardia from stimulation of the superior laryngeal nerve (SLN) is said to have been described first by Francois Franck in 1876.¹⁰ Reflex cardiac inhibition by the action of chloroform on the larynx was reported in 1900 by Brodie and Russell.¹¹ These authors concluded that of the vagal afferent fibers whose stimulation produced reflex bradycardia, the pulmonary fibers gave the most marked reaction. Sloane, however, failed to produce cardiac arrest on stimulating the vagus nerve at the dog's hilum, unless a marked degree of hypoxia was present.¹²

Hering reported slowing of the rabbit's heart when pressure was made on its larynx.¹³ However, he later localized the origin of this reflex to the carotid.¹⁴

From the Section of Otolaryngology, Department of Surgery, Yale University School of Medicine.

Supported by USPHS 5 R01-NB-05465-03.

In our present study, we are seeking the sources within the upper respiratory tract, of cardiovascular reflexes, and studying the influences of various chemical and physical agents. The present report describes 1) a reflex response in a pulse-monitored single fiber of the vagus to SLN stimulation; and 2) an aortic baroreceptor-chemoreceptor pathway to the central nervous system by way of the recurrent laryngeal nerve (RLN).

The anatomical basis for laryngeal cardiac reflexes has interested many investigators and has been studied by nerve degeneration experiments^{15,16} and by electrophysiological recordings from the relevant nerves.¹⁷⁻²¹ Details of the system are still not entirely clear.

In this connection the following points require clarification: 1) the role of deep, as contrasted with superficial, sensory receptors within the larynx²²; 2) the pathways of baroreceptor fibers from the aorta and carotid sinus and their relations to the superior and recurrent laryngeal nerves^{23,24}; 3) the question of cardio-inhibitory fibers within the vagus.²⁰

METHODS

Twenty adult cats and six adult rats were anesthetized with intraperitoneal Nembutal® 30 mg/kg body weight. Some animals were paralyzed by gradual intravenous injection of gallamine triethiodide (Flaxedil®) under artificial respiration. With the animal supine the trachea was opened and cannulated. The nerves being studied were exposed by dissecting them free of surrounding tissues under an operating microscope. Further dissection of the nerves was performed under warm mineral oil enclosed by supported skin flaps.

To record from vagal efferent fibers the vagus trunk was cut low in the neck, the sheath removed for 3 cm and the nerve divided into multiple groups of fibers repeatedly until strands which showed single unit or small multifiber group activity were obtained.

Recording electrodes were platinum. Electrode potentials were displayed on a Tektronix® model 564 oscilloscope and photographed by a Grass camera. Up to four separate channels could be recorded: EKG, respiration, nerve action potential or any combination. An audio amplifier and speaker monitored the action potential channel.

Intratracheal air pressure variations were recorded by a Statham pressure transducer and signaled lung excursions during artificial respiration. Electrocardiogram was recorded from needle electrodes inserted into the forelimbs.

Electrical stimulation of afferent fibers from the larynx was delivered by a Grass S-4 stimulator which furnished rectangular wave pulses of graduated amplitude and duration through a stimulus isolation unit to bipolar platinum

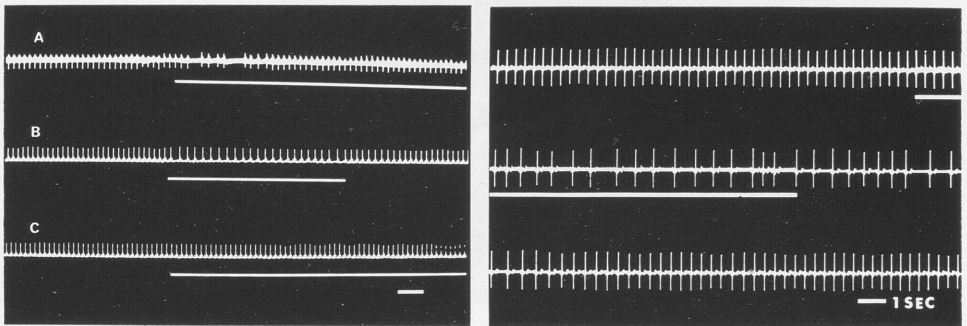


Fig. 1.—Effect of stimulating superior laryngeal nerve on the rate and rhythm of the rat's heart. (A) A glass rod was passed through the glottic chink, as indicated by the solid line below EKG. Arrhythmia is shown during the first 3 seconds after passage of the rod. (B) Superior laryngeal nerve stimulated at 3.0 volts, 0.1 msec, 20 cps. Bradycardia present throughout period of stimulus. (C) Same stimulus as in (B), but 20 minutes after intraperitoneal injection of 0.3 cc atropine. Cardiac rhythm and rate remain unchanged. An incidental observation in this experiment is that the respiratory cycle, as indicated by the rhythmic crests along the EKG discharges, is arrested during SLN stimulation in (B). In (C), after atropine, respiratory cycle is arrested for 4 seconds, then resumes its rhythm. Time marker 1.0 second.

Fig. 2.—Electrical stimulation of cat's superior laryngeal nerve. Top, middle and lower lines are continuous recording. Top trace is EKG. Lower solid line represents stimulus at 3.0 volts, 0.1 msec, 20 cps. Arrhythmia and bradycardia during period of stimulation and for 8 seconds afterwards. Normal rate and rhythm then returned.

electrodes. The stimulus was applied to the central segment of the internal branch of the superior laryngeal nerve which had been cut near its entrance to the larynx. Stimulus intensities were usually between 1.0 and 3.0 volts, 0.1 msec duration, with various frequencies. Intensities were kept at the lowest levels which produced consistent responses in any individual animal. Mechanical stimulation of the laryngeal mucosa consisted of touching it with a small glass probe.

RESULTS

1. Superior laryngeal nerve stimulation producing bradycardia.

The central segment of the internal branch of the SLN was stimulated at 3.0 volts, 0.1 msec at 20 cps. In the rat, this produced bradycardia throughout the period of stimulation (Fig. 1). In the cat, both bradycardia and arrhythmia resulted (Fig. 2). Cats showed considerable individual variation in cardiac response to SLN stimulation. In these experiments, reflex cardiac inhibition was produced by superior laryngeal nerve stimulation in 4 of 20 cats, and in all of the 6 rats.

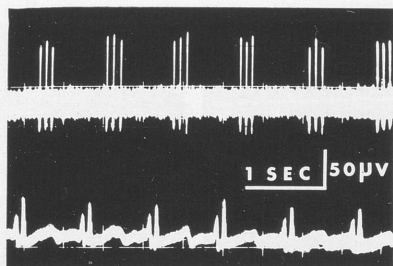


Fig. 3.—Single efferent fiber in cat's vagus spontaneously discharging with heart beat (lower tracing).

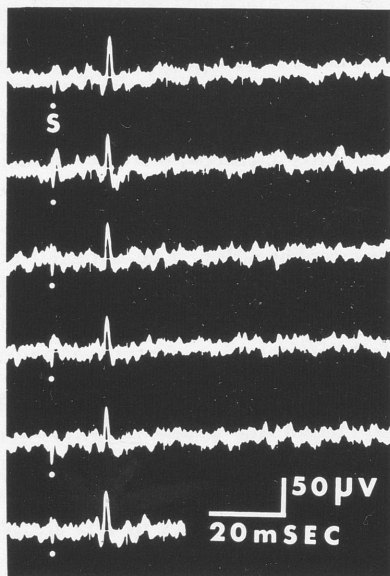


Fig. 4.—Same fiber as in Figure 3 but with high speed time sweep. Evoked responses to repeated single shock stimulations applied to central segment of ipsilateral superior laryngeal nerve. Response occurred 15 msec after stimulus (S). Each trace is triggered by the stimulus and follows the preceding by 1.0 second.

2. Superior laryngeal nerve stimulation producing a reflex response in a pulse modulated vagal efferent fiber.

A fiber showing single unit activity related to the pulse was placed on recording electrodes (Fig. 3). A low intensity stimulus was then delivered to the central segment of the internal branch of the SLN. An evoked potential was recorded in the vagal fiber, as shown in Figure 4.

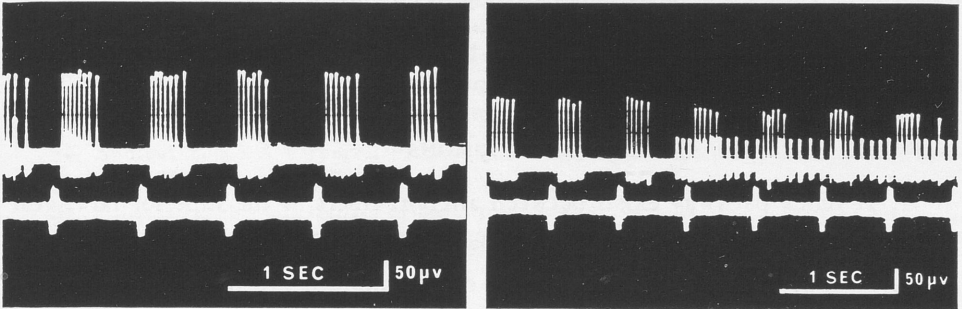


Fig. 5.—Baroreceptor discharges recorded from filament in cat's recurrent laryngeal nerve (upper trace). Nerve trunk cut between electrodes and larynx, vagus nerve cut low in neck. Tracing begins 1 second after cessation of artificial respiration. Discharges are synchronous with pulse (lower tracing).

Fig. 6.—Chemoreceptor discharges appearing in the filament used in Figure 5, but after 10-12 seconds of apnea. These discharges are superimposed on the baroreceptor activity already present. Lower trace is EKG.

The nature of this single unit is probably cardio-inhibitory, the Type I described by Jewett, although it was not studied for reaction to various physical and chemical agents. It could also be the Type VI of Jewett, although these are rare.²⁰ In any case, it could be expected to influence heart rate and showed a definite reflex response to stimulation of the superior laryngeal nerve. The latency time of the reflex indicates that it is polysynaptic.

3. Aortic baroreceptor and chemoreceptor fibers in recurrent laryngeal nerve.

The left recurrent laryngeal nerve was first freed of branches from the trachea and esophagus as far caudally as the clavicle. It was then cut near the larynx and divided into filaments. The ipsilateral vagus trunk was then cut across completely, to eliminate efferent discharges in the RLN.

Various filaments were placed individually on the recording electrodes until one was found which exhibited spontaneous rhythmic activity, synchronous with the pulse (Fig. 5). This fiber resembles that described by Andrew in the rat.¹⁷

The animal in this experiment had been paralyzed by Flaxedil so that the respiration had to be supported by means of a mechanical respirator. At several points the respirator was stopped. After a brief period of apnea, a second spontaneously discharging unit appeared on the tracing superimposed on the baroreceptor discharge (Fig. 6). This discharge can only represent chemoreceptor activity, since it became active during increasing apnea and disappeared when artificial respiration was re-instituted.

The authors believe that it is this baroreceptor nerve which is usually responsible for the vasomotor reflex effects that result from stimulating the larynx.

4. Stimulation of afferent fibers in the recurrent laryngeal nerve (that is, after cutting its trunk near the larynx) produced no reflex cardiac effects.

CONCLUSIONS

1. A reflex pathway exists between afferent fibers in the superior laryngeal nerve and cardio-inhibitory fibers in the vagus.

2. It appears likely that the source of the afferent arc lies in baroreceptor end organs in the aorta.

333 CEDAR ST., NEW HAVEN, CONN. 06504

REFERENCES

1. Burstein, C. L., Woloshin, G., and Newmann, W.: Electrocardiographic Studies During Endotracheal Intubation. II. Effects During General Anesthesia and Intravenous Procaine. *Anesthesiol.* 11:299-312, 1950.
2. Converse, J. G., Landmesser, C. M., and Harmel, M. H.: Electrocardiographic Changes During Extubation. *Anesthesiol.* 13:163-168 (Mar.) 1952.
3. Scherf, D.: Cardiac Reflexes Originating in Respiratory Tract. *N. Y. St. Jour. Med.* 45: 1647-1650 (Aug.) 1945.
4. Reid, L. C., and Brace, D. E.: Irritation of Respiratory Tract and Its Reflex Effect Upon Heart. *S. G. O.* 70:157-162 (Feb.) 1940.
5. Reid, L. C.: Practical Considerations in the Surgical Management of Children With Regard to the Autonomic Nervous System. *N. Y. St. Jour. Med.* 50:2937-9, 1950.
6. King, B. D., Elder, J. D., Proctor, D. F., and Dripps, R. O.: Reflex Circulatory Responses to Tracheal Intubation Performed Under Topical Anesthesia. *Anesthesiol.* 15:231-238, 1954.
7. Denison, J. S., and Joseph, S. I.: Cardiac Rhythm and Endotracheal Intubation - a Clarification. *Anesthesiol.* 15:650-657, 1954.
8. Heller, M. L., and Watson, T. R.: Electrocardiographic Studies of the Tracheocardiac Reflex During Light Analgesia With Nitrous Oxide and Relaxants. *Anesthesiol.* 19:103 (abstr.) 1958.
9. Harken, D. E., and Norman, L. R.: The Control of Cardiac Arrhythmia During Surgery. *Anesthesiol.* 11:321-327, 1950.
10. Franck, François: *Trav. Du Labor De Marey* 2:221, 1876 (cited by Brodie and Russell¹¹).
11. Brodie, T. G., and Russell, A. E.: On Reflex Cardiac Inhibition. *Jour. Physiol.* 26:92-106, 1900.
12. Sloan, H. E.: Vagus Nerve in Cardiac Arrest. *S.G.O.* 91:257-264 (Sept.) 1950.
13. Hering, H. E.: Über den Vagusdruckversuch und Demonstration eines Larynxdruckversuches. *Münch. Med. Wschr.* 67:28, 1920.

14. Hering, H. E.: Der karotisdruckversuch. Münch. Med. Wschr. 70:1287-1290, 1923.
15. Agostini, E., Chinnock, J. E., Daly, M., and Murray, J. G.: Functional and Histological Studies of the Vagus Nerve and Its Branches to the Heart, Lungs and Abdominal Viscera in the Cat. Jour. Physiol. 135:182-205, 1957.
16. Murray, J. G.: Innervation of the Intrinsic Muscles of the Cat's Larynx by the Recurrent Laryngeal Nerve: A Unimodal Nerve. Jour. Physiol. 135:206-212, 1957.
17. Andrew, B. L.: A Laryngeal Pathway for Aortic Baroreceptor Impulses. Jour. Physiol. 125:352-60, 1954.
18. Calaresu, F. R., and Pearce, J. W.: Electrical Activity of Efferent Vagal Fibres and Dorsal Nucleus of the Vagus During Reflex Bradycardia in the Cat. Jour. Physiol. 176:228-240, 1965.
19. Green, J. H.: Cardiac Vagal Efferent Activity in the Cat. Jour. Physiol. 149:47-49, 1959.
20. Jewett, D. L.: Activity of Single Efferent Fibres in the Cervical Vagus Nerve of the Dog. With Special Reference to Possible Cardio-inhibitory Fibres. Jour. Physiol. 175:321-357, 1964.
21. Widdicombe, J. G.: Action Potentials in Parasympathetic and Sympathetic Efferent Fibres to the Trachea and Lungs of Dogs and Cats. Jour. Physiol. 186:56-88, 1966.
22. Sampson, S., and Eyzaguirre, C.: Some Functional Characteristics of Mechanoreceptors in the Larynx of the Cat. Jour. Neurophysiol. 27:464-80 (May) 1964.
23. Holmes, R.: Carotid Sinus Baroreceptor Afferent Fibers in the Aortic Nerve of the Cat. Jour. Physiol. 126:40-41 P.
24. Jewett, D. L.: Direct Nervous Pathways Between the Cervical Vagus and the Aortic or Superior Laryngeal Nerves Traversed by Baroreceptor, 'Pulmonary Stretch' and Other Fibres in the Cat. Jour. Physiol. 175:358-371, 1964.

BIODYNAMICS OF INJURY TO THE LARYNX IN AUTOMOBILE COLLISIONS

ALAN M. NAHUM, M.D.
(by invitation)

ARNOLD W. SIEGEL, M.S.
(by invitation)

LOS ANGELES, CALIF.

In view of the magnitude of traffic accident injuries, it is both surprising and fortunate that injuries to the upper respiratory tract are relatively infrequent. However, since the consequences of such injuries in terms of morbidity and mortality are so great, early recognition and effective treatment are vital to consider. It is appropriate to preface such considerations with a discussion of the mechanics of injury causation and methods of prevention.

The mechanisms of injury causation are also of importance to persons who may be required to render first aid to these victims. Most persons officially rendering first aid to traffic accident victims do not have adequate training in establishing and maintaining an airway and instituting effective ventilation. Since injury to the upper respiratory tract frequently results in partial or complete airway obstruction, recognition and early management are necessary information for all persons entrusted with emergency medical care, including all physicians. This may be particularly true for situations in which there is likely to be a significant delay before the patient reaches a hospital emergency room. Children with such injuries are particularly susceptible to airway obstruction.

Most traffic accident injury data does not reflect the incidence of injuries to the upper respiratory tract. Those studies which do tabulate neck injuries also include hyperextension (whiplash) injuries which are the most common of all neck injuries. Nahum et al.¹ in a preliminary analysis of 150 injury-producing accidents analyzed the 496 injuries which were sustained by the 239 injured motorists. Of the total injuries tabulated, three occurred to the anterior neck and upper respiratory tract. Other papers devoted exclusively to laryngeal injuries³⁻⁶ confirm that the majority occurred in traffic accidents.

BIODYNAMICS OF INJURY PRODUCTION

All accidents are different. But the factors which result in anterior neck trauma are surprisingly constant. The most frequent accident configuration is

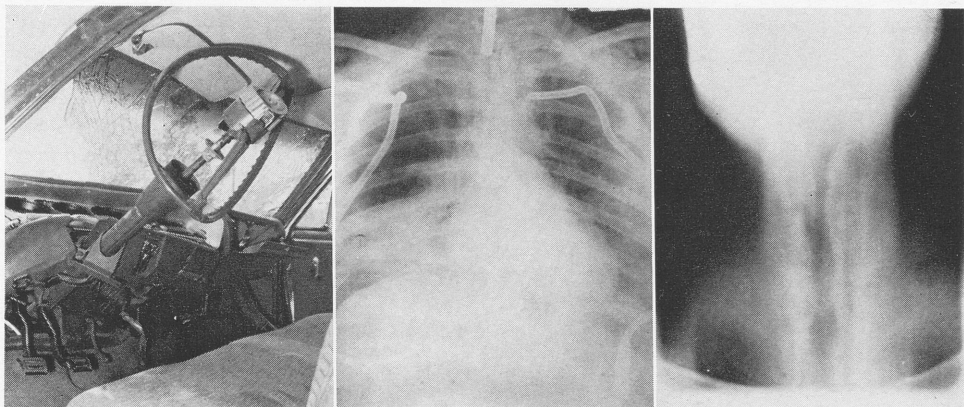


Fig. 1.—Steering wheel and column, Case 1.

Fig. 2.—Chest x-ray, Case 1.

Fig. 3.—Laryngeal laminograph, Case 1.

a frontal impact where one vehicle strikes an object in the environment (pole, tree, abutment) or another vehicle. The driver is the most frequent victim and the steering wheel most commonly is the object which the neck strikes. The right front seat passenger can also sustain a similar injury against the instrument panel. The average victim is a male of average height and is not wearing a seat belt or any other type of restraint.

The kinematics of the unrestrained motorist are best analyzed from films of anthropometric dummies in experimental collisions.² During a typical head-on collision of one vehicle with another at 25 miles per hour, both car and occupants are moving at the same speed prior to collision. As the cars contact and begin to decelerate, there is a delay of approximately 25 milliseconds before the driver moves forward. Continuing forward in a seated, upright posture, the driver 40 milliseconds after impact contacts the lower rim of the steering wheel with his upper abdomen and lower chest. In the majority of collisions, this deflects the upper rim toward the driver's face, often resulting in soft tissue damage and facial fractures. Frequently this contact forces the mandible downward, providing even more protection for the neck. In rare instances, the driver may either hit the windshield first causing hyperextension and allowing the exposed neck to glance downward onto the wheel or the hub may be exposed and forced upwards toward the neck.

Many other factors may affect the occurrence and nature of neck injuries. These include: 1) configuration of the steering wheel and column (e.g. armature strength, rim diameter, number of spokes, type of plastic or metal horn accessor-

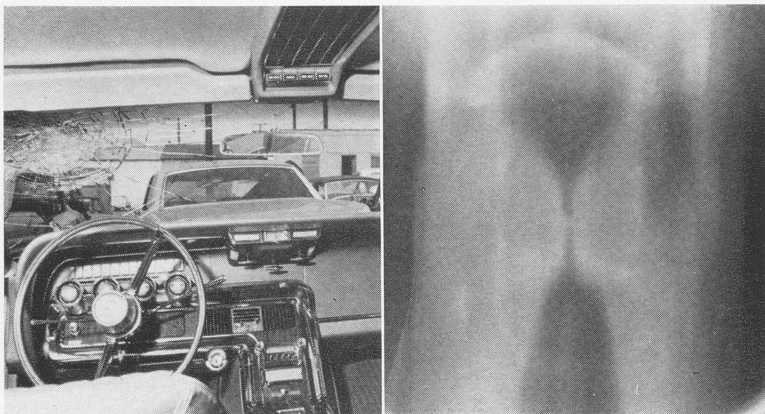


Fig. 4.—Steering wheel and windshield, Case 2.

Fig. 5.—Laryngeal laminograph, Case 2.

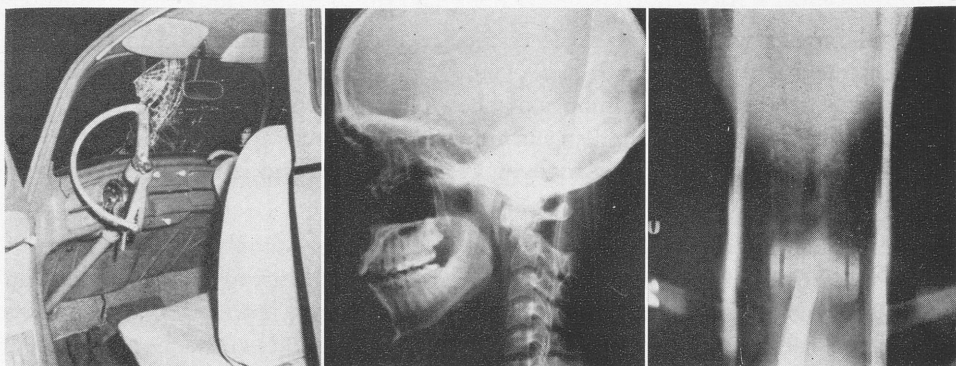


Fig. 6.—Relation of victim to steering wheel immediately after accident, Case 3.

Fig. 7.—Fracture of cervical spine, Case 3.

Fig. 8.—Laryngeal laminograph, Case 3.

ies, angle of wheel-column system to the driver), 2) amount of energy absorption and collapsibility of the wheel-column, 3) amount of relative rearward excursion of the wheel-column.

REPORT OF CASES

CASE 1. The patient, a 21-year-old male, was driving a 1964 station wagon weighing about 3000 pounds. He lost control of the vehicle which left the freeway, went down an embankment and hit a signpost and then came to rest,

The impact speed with the post was about 35 miles per hour. The driver was not wearing a seat belt or other restraint. As the driver moved forward in a seated posture, the steering column and wheel were thrust relatively forward and upward. His upper torso bent the wheel rim downward exposing the hub which contacted his larynx and trachea (Fig. 1). He sustained a blunt injury to his larynx, a transection of the trachea and a bilateral hemopneumothorax (Fig. 2). Subsequent examinations of the larynx showed diffuse edema with a bilateral vocal cord paralysis. Laminographs of the larynx showed diffuse swelling and narrowing of the airway (Fig. 3).

This patient survived due to the rapid and skillful emergency medical care which he received.

CASE 2. The patient, a 56-year-old male, was driving a 1966 two-door sedan weighing about 4400 pounds when he struck the rear of another (parked) car at a speed of about 15 miles per hour. He was not wearing a seat belt or other restraint. He moved forward and upward in a seated posture striking his head against the windshield and then coming down against the rim of the steering wheel with his neck (Fig. 4). Note the bulge in the new type windshield which contains a thicker plastic inner-liner and thereby prevents penetration of the head and face and reduces the incidence of facial lacerations. Following the accident, the patient noted marked hoarseness. Examination showed diffuse edema and limited motion of the vocal cords. There was no evidence of fracture. X-rays (Fig. 5) of the larynx showed diffuse edema. Over the course of a few months, he made a complete recovery with conservative management.

CASE 3. The patient, 21-year-old male, fell asleep while driving a small imported car weighing 1600 pounds. The car struck a utility pole at about 30 miles per hour. He was not wearing a seat belt or other restraint. The driver moved forward against the steering wheel striking his neck on the rim and his head against the windshield causing hyperextension of his head (Fig. 6). In the emergency room he required a tracheostomy to relieve progressive dyspnea. X-rays revealed an injury to the cervical spine consisting of a fracture of the odontoid and 50 per cent forward subluxation of the odontoid on the body of the second vertebra (Fig. 7). Later examination of the larynx showed massive edema with a bilateral vocal cord paralysis which was also reflected in laminographs (Fig. 8) of the larynx.

PREVENTION

The majority of the injuries described can be prevented by the use of restraints such as one of the many seat belt-upper torso combinations. The upper torso restraint prevents the motorist from contacting the steering wheel since it is not practical to make the steering wheel so soft that it would yield completely on contact. As steering wheels become reduced in diameter and the

angle of the wheel column to the driver is altered in future car designs, the pattern of injuries for the unrestrained driver may be expected to change.

DEPT. OF SURGERY, UCLA SCHOOL OF MEDICINE 90024

REFERENCES

1. Nahum, et al.: Causes of Significant Injuries in Nonfatal Traffic Accidents. Proc. 10th Stapp Car Crash Conf., 1966.
2. Severy, D. M., et al.: Automobile Head-on Collisions, Series II. UCLA Report 58-41 (May) 1958.
3. Brandenburg, J. H.: Problem of Closed Laryngeal Injury. Arch. Otolg. 81:91, 1965.
4. Holinger, P. H., and Johnston, K. C.: Laryngeal Trauma and Its Complications. Am. Jour. Surg. 97:513, 1959.
5. Holinger, P. H., and Curtin, J. W.: Automobile Accidents and Laryngeal and Upper Tracheal Trauma. Presbyt. St. Luke's Hosp. Med. Bull. 3:46, 1964.
6. Ogura, J. H., and Powers, W. E.: Functional Restitution of Traumatic Stenosis of the Larynx and Pharynx. Laryngoscope 74:1081, 1964.

LARYNGOTRACHEAL INJURIES

ROBERT E. PRIEST, M.D.

JOHN S. HUFF, M.D. JOHN D. BANOVEZ, M.D.
(by invitation) (by invitation)

MINNEAPOLIS, MINN.

This paper is written to summarize current thinking about laryngotracheal injuries. We are presenting principles of diagnosis and treatment and emphasizing details only enough to illustrate the principles.

The watchword of laryngeal injury is that treatment is best done early. When initiated quickly, open surgical exploration and reconstruction is likely to produce the best end result. Treatment is directed toward the best possible utilization of the damaged tissues; the surgeon's purpose is to reconstruct the optimum speaking and breathing apparatus from the remnants that survive. Early operation will probably permit repositioning and fixation of fractured parts and may spare the patient painful and expensive treatment necessary for correcting cicatricial laryngeal stenosis. Sometimes the patient's general condition will preclude carrying out early surgical repair, and late treatment of a scarred larynx will be inevitable. By early treatment we mean treatment as soon as the patient's general condition permits, preferably well within four to five days after the injury. As Henry⁸ and Fitz-Hugh⁶ have pointed out, it is important to remember that some laryngeal injuries do not require active treatment, but that severe crushing or perforating injuries require immediate treatment.

Negus¹ discussion of laryngeal injury possesses remarkable clarity. It has been used as a framework for part of this paper. Negus believes that the hyoid bone can occasionally be fractured by muscular action alone but usually is injured by direct violence. Hyoid fracture can be diagnosed erroneously because of the late ossification of the hyoid bone. The greater cornua and the body unite in middle life, and the lesser cornua rarely ankylose with the body, but may unite with the greater cornua.¹¹ These open suture lines can be mistaken for fractures when bruising and tenderness suggest the possibility. When a fracture actually exists, the hyoid body separates from the greater cornu and is displaced forward and upward. This vertical separation between the body and greater cornu is necessary to be certain of fracture. As compared with the laryngeal cartilages,

From the Division of Otolaryngology of the University of Minnesota Medical School, Minneapolis, Minnesota.

the hyoid bone is rarely fractured due to its protection by the lower jaw and because it is suspended by elastic muscles.

Laryngeal fracture is not apt to occur from concussion unless the vertebral column is fixed with the chin hyperextended. An individual with a long, lean neck is more likely to sustain a laryngeal injury, especially a supraglottic one, than a person with a short thick neck. Almost all modern authors emphasize the automobile accident as the most important cause for today's laryngeal injuries. At high speed an unseat-belted passenger is thrown forward with head erect, neck extended, and the larynx held firmly in position in front of the rigid vertebral column which serves as the anvil against which the larynx is hammered. Not only may the larynx be crushed and fragmented, but the cricoid may be torn off the cervical trachea or the larynx may be avulsed from the pharynx.

Fractures of the thyroid cartilage are most common. The cricoid gives way more rarely. Thyroid cartilage fractures may be central, vertical, or irregular, and may involve only the cornua. The paper by Ogura and Powers² contains excellent illustrations of these fractures. Acute airway narrowing may result from overlapping of cartilage fragments, hematoma, or displacement of the arytenoid cartilage into the airway. The recurrent nerves may be stretched, lacerated, or divided. This produces airway narrowing by paralyzing the vocal cords in the position of adduction. The external perichondrium may rupture, and the mucous membrane may be torn or bruised or detached. Adhesions may form between adjacent raw surfaces with subsequent stenosis. Injuries are classified as supraglottic, glottic, or infraglottic. All can compromise the airway or cause emphysema.

Symptoms and examination findings of laryngeal fracture include pain, tenderness, and swelling. There may be interference with phonation, deglutition, and respiration. Some severe injuries may not produce poor voice quality. Thus the presence of good voice quality does not rule out severe injury. Emphysema results from laryngeal, tracheal, and bronchial rupture. Pericardial emphysema can result from a supraglottic injury in the absence of any chest injury; the extent of the emphysema is not indicative of the severity of the injury. Hemoptysis may occur, with or without hematoma. The presence of chest or facial injury tends to make the physician dealing with the acutely injured patient less concerned about laryngeal injury once the airway has been established by tracheotomy.

External examination may yield surprisingly little evidence of the damage lying within. In severe laryngeal injuries the skin is often intact. Palpation may reveal displacement or mobility of fragments. Crepitus may be present. One must distinguish the roughness felt when the normal larynx is moved from side to side from the roughness due to abnormal crepitus.

When laryngeal injury is suspected, the physician should have in mind a routine of examination which will delineate the problem and will prevent him from encountering unexpected trouble later because some particular diagnostic procedure was not remembered in the heat of the moment when he was confronted by the acutely injured patient.

A minimum battery of diagnostic studies to evaluate a laryngeal injury should include chest x-ray, laryngeal mirror examination, lateral x-ray of the larynx, planigrams of the larynx, and roentgen study of the esophagus. Endoscopy is often necessary. Chest x-ray may reveal pneumothorax or pleural effusion. The use of contrast material is necessary to rule out tracheoesophageal fistula. This complication is so likely to lead to mediastinal infection that the use of contrast medium to exclude it is usually justified even if open operation needs to be delayed. Barium is not a desirable contrast agent; iodized poppyseed oil (Lipiodol®) or gastrograffin are much more acceptable because they produce less reaction and are less viscous. Barium produces foreign body reaction in the lung. The less viscous the medium, the more likely the chance of detecting a small tracheoesophageal fistula.

Laryngoscopic examination may reveal edema, ecchymosis, airway narrowing, and, at times, vocal cord immobility. A slight blow as from a baby's elbow to its mother's neck may cause cord paralysis. Compression of the recurrent laryngeal nerve as it passes medial to the inferior cornu of the thyroid cartilage, as described by Ogura,³ may be the mechanism.

Roentgenographic study of the larynx by means of plain films, laminographs, or laryngograms using contrast medium may help to delineate a fracture. Planigrams in the frontal plane may be of value. Cine fluorography may show immobility of a vocal cord. Ogura² has pointed out that if contrast material is to be used in the larynx and open operation is contemplated, it should be done soon after the laryngogram because infection may be carried into the soft tissues by the contrast medium. Roentgen studies should be done with the patient phonating and performing the Valsalva maneuver, as well as during normal respiration.

Prognosis in laryngeal injuries is grave, but the use of a prompt tracheotomy, antibiotics, antitetanus treatment, and early open surgery have improved it greatly. Clear indications for tracheotomy are: cervical emphysema, palpable evidence of fracture, and airway obstruction. If there is any doubt regarding the need for tracheotomy, it should be done. Whenever possible, tracheotomy should be carried out through normal cervical trachea and not through the fracture site. If the tracheotomy cannula is inserted through the fracture site, infection and resorption of the cartilage are apt to follow.

Early treatment of laryngeal injury implies intelligent evaluation of the entire patient and establishment of proper priority of treatment of various

injured body regions. Surgical exploration should be done in any case of laryngeal injury requiring a tracheotomy, any with cervical emphysema, or with extensive cervical skin lacerations, or with bone or cartilage protruding into the lumen. Some laryngeal contusions and hematomas may be treated conservatively. These will be the cases exhibiting pain and dysphonia but not more serious symptoms.

Fractures of the hyoid, unless producing airway narrowing, usually can be handled expectantly. In unusual cases hematoma will produce conditions requiring tracheotomy in the absence of laryngeal fracture, or with undisplaced fracture. Stab wounds can sometimes be treated conservatively. Conservative treatment includes measures such as by-pass feeding, antibiotics, and may even include tracheotomy.

In early surgery of an injured larynx the mucosal lacerations are repaired if possible. If mucosa is missing, skin grafts may be used to cover the raw areas. Grafts prevent persistent low-grade infection and excessive scarring with its complicating contracture. Cartilage can be fixed by direct through-and-through sutures including both the cartilage and its perichondrium. Short segments of the airway can be excised, e.g., excision of the cricoid or one or two tracheal rings, followed by end to end anastomosis as described by Conley,¹² Shaw,¹³ and Rush.¹⁹ Tracheal elongation can make up such a distance.^{17,18} Splints may be needed in the acutely injured larynx for two to three weeks. Since laryngeal wounds can be contaminated from the pharynx, they should be drained. By-pass feeding by gastric tube or by vein should be used initially.

Curtin, Holinger, and Greeley⁴ say, "Fractures of the larynx, just as fractures elsewhere in the body, require adherence to the basic principles of all trauma surgery, namely, restore the parts to as nearly normal positions as possible, and splint them in positions of function." They report experience with 82 laryngeal fracture patients, 80 of whom already had laryngeal cicatricial stenosis when first seen. In only two cases did they have the opportunity to treat the patients in the immediate post-accident period, and in both cases good functional restoration was secured.

Contrast this report to that of Fitz-Hugh, Wallenborn, and McGovern,⁶ who reported on 28 cases, 25 of which came under their care immediately, or shortly after injury. These patients had 16 good airways and 14 good voices out of 24 completed cases.

It is of interest to speculate upon why 80 out of 82 cases handled by Curtin, Holinger, and Greeley had already developed laryngeal stenosis, and presumably had been denied the benefit of early surgical treatment. This denial surely must have been dictated by the poor general medical condition of some of the patients. However, one must admit the probability that many were not treated early

because the attending medical personnel were unaware of the importance of early definitive care of laryngeal injuries; and did not think in terms of systematic and diagnostic routines which would have clarified the problem at hand.

It appears that geographical differences alone could not dictate the lack of adequate immediate treatment in these cases. Holinger et al. very probably received these patients from a wide geographic area. Yet there are few geographic areas today, at least in the United States of America and in Canada, where qualified laryngeal surgical assistance could not be obtained if requested by the attending physician.

The nub of the problem must be lack of awareness by many physicians and surgeons of the importance of early evaluation and treatment of laryngeal injuries before scarring and stenosis can occur. It is important that this information be circulated widely among medical people dealing with trauma.

Curtin, Holinger, and Greeley pointed out that "Generally, the patient has so many other injuries that once a tracheostomy has established an airway, the laryngeal injury itself and its management are overlooked. Failure of, or inadequate early management of such injuries results in chronic laryngeal stenosis and the need for a permanent tracheostomy. Late reconstructive procedures, for the most part successful, need not be necessary if proper early reduction and fixation of the laryngeal fractures are carried out." They went on to say that the purpose of their presentation was to urge physicians to be more alert for the injuries of the larynx in accident cases and to treat them primarily and more aggressively.

The surgical procedures used in treating laryngeal stenosis have been discussed by numerous authors. No attempt will be made here to discuss them in detail. A few general observations appear to be in order. The treatment of late injuries of the larynx and cervical trachea is designed to: 1) restore an adequate lumen to the airway, 2) prevent spillage into the airway during swallowing, and 3) if possible, to restore a normal voice. To achieve these goals, scar tissue must be excised, a new epithelial lining grafted, and a stent inserted as a framework. Laryngeal mucosa, if it can be saved, is preferable to a graft from a donor site outside the larynx. Hairless split-thickness skin is excellent. Vein graft works well for small areas. Because of investigations concerning the rapid regeneration of tracheal mucosa, Longmire¹⁷ raises the question of whether the "good results from open operation and skin grafting are derived chiefly from the careful and complete dissection of the scar tissue and the prolonged use of an obturator, rather than from the presence of the skin graft." Iglaue¹⁴ pointed out that epithelialization of the anterior commissure is necessary to regain good voice quality. A sharp-angled anterior commissure permits a clear voice. The McNaught keel^{15,16} is a tried and true appliance. The Knight¹⁰ splint offers promise.

Studies in the esophagus, after corrosive esophagitis, have shown that collagen fibers mature in eight weeks. Therefore it appears that a stent must be left in place at least eight weeks, probably longer. This is not always necessary, and sometimes is impossible due to discomfort. We have several cases in which stents were removed after three weeks, and skin grafts had taken nicely inside laryngeal cartilage. Probably the less rigid esophagus requires longer stenting than the more rigid larynx to maintain a patent lumen. Surely a larynx converted into a flaccid tube by a crushing injury must require longer stenting than one retaining part of its normal rigidity. In selection of a stent one must try to achieve fixation with minimum mechanical irritation and tissue reaction. The stent should extend well beyond both ends of the injured area. Myotomy of the cricopharyngeus muscle can improve swallowing.^{20,21} False vocal cords can be used in talking. Motivation of the patient to try to speak by whatever means possible can be enhanced by encouragement by all people dealing with the patient. In addition to their possible use in speech, the false vocal cords are important as a sphincter of the larynx; their adduction, together with elevation of the larynx against the tongue, close off the airway during swallowing. Preservation or reconstruction of the false cords by pedicled mucosal flaps must be borne in mind as the repair of the larynx is in progress.

Although exposure, decompression, and reanastomosis of laryngeal nerves would be desirable, in practice the nerves are difficult to find in scar tissue and the results are poor.

SUMMARY

The watchword of laryngeal injury is that treatment is best done in the first four or five days after injury to prevent the ultimate development of cicatricial stenosis. The general condition of the patient may make late treatment inevitable. Some laryngeal injuries can be treated expectantly, but many require active, aggressive surgical management including open operation, repositioning of fragments, use of grafts, introduction of stents, and maintenance of airway by tracheostomy.

It is apparent that many patients are denied the benefits of early treatment because physicians generally are not sufficiently aware of the methods useful in diagnosis of laryngeal injury and do not realize the importance of "early restoration of the parts of the injured larynx to as nearly normal positions as possible" and the need "to splint them in positions of function."⁴

REFERENCES

1. Negus, Sir Victor: Diseases of the Nose and Throat. Thomson and Negus, Cassell and Co., Ltd., London, 1955.
2. Ogura, J. H., and Powers, W. E.: Functional Restitution of Traumatic Stenosis of the Larynx and Pharynx. Trans. Amer. Laryngol., Rhinol. and Otol. Soc., Inc., pp. 755-84, 1964; also published in Laryngoscope 74:1081-1110 (Aug.) 1964.
3. Ogura, J. H.: Surgical Decompression of the Recurrent Laryngeal Nerve in Idiopathic Unilateral Vocal Cord Paresis. Trans. Amer. Laryngol. Assn. 82:85-99, 1961; also published in ANNALS OF OTOTOLOGY, RHINOLOGY AND LARYNGOLOGY 70:451-62 (June) 1961.
4. Curtin, J. W., Holinger, P. H., and Greeley, P. W.: Blunt Trauma to the Larynx and Upper Trachea: Immediate Treatment, Complications, and Late Reconstructive Procedures. Jour. Trauma 6:493-502 (July) 1966.
5. Ogura, J. H., Powers, W. H., Holtz, S., McGavran, M. H., Ellis, B., and Voorhees, R.: Laryngograms: Their Value in the Diagnosis and Treatment of Laryngeal Lesions. A Study Based on Clinical, Radiographic, and Pathologic Findings in 99 Patients with Cancer of the Larynx. Trans. Amer. Laryngol., Rhinol. and Otol. Soc., Inc., pp. 745-75, 1960; also published in Laryngoscope 70:780-809 (June) 1960.
6. Fitz-Hugh, G. S., Wallenborn, W. M., and McGovern, F.: Injuries of the Larynx, and Cervical Trauma. Trans. Amer. Laryngol. Assn. 83:43-68, 1962; also published in ANNALS OF OTOTOLOGY, RHINOLOGY AND LARYNGOLOGY 71:419-42 (June) 1962.
7. Erich, J. B.: Mechanical Appliance for Cicatricial Stenosis of Larynx and Upper Part of Trachea. Trans. Amer. Laryngol. Assn. 77:206-17, 1956; also published in ANNALS OF OTOTOLOGY, RHINOLOGY AND LARYNGOLOGY 65:799-810 (Sept.) 1956.
8. Henry, G. A.: Laryngeal Trauma. Can. Med. Assn. Jour. 88:833-36 (Apr. 20) 1963.
9. Knight, J. S.: Further Efforts for Correction of Severe, Acute, or Chronic Laryngeal Stenosis. ANNALS OF OTOTOLOGY, RHINOLOGY AND LARYNGOLOGY 75:392-97 (June) 1966.
10. Knight, J. S.: Laryngeal Stenosis: Method of Surgical Correction. Laryngoscope 74:564-74 (April) 1964.
11. Morris' Human Anatomy, edited by C. M. Jackson, Eighth Edition. P. Blakiston's Son and Co., Philadelphia, p. 168, 1925.
12. Conley, J. J.: Reconstruction of the Subglottic Air Passage. ANNALS OF OTOTOLOGY, RHINOLOGY AND LARYNGOLOGY 62:477-95 (June) 1953.
13. Shaw, R. R., Paulson, D. L., and Kee, J. L., Jr.: Traumatic Tracheal Rupture. Jour. Thorac. and Cardiovasc. Surg. 42:281-97 (Sept.) 1961.
14. Iglauer, S.: A New Procedure for the Treatment of Web in the Larynx. Arch. Otolaryngol. 22:597, 1935.
15. McNaught, R. C.: Surgical Correction of Anterior Web of the Larynx. Laryngoscope 60:264-72 (Mar.) 1950.
16. Banovetz, J. D., and Priest, R. E.: Surgical Therapy of Laryngeal Webs. Minn. Med. 46:774-76 (Aug.) 1963.
17. Longmire, W. P., Jr.: The Repair of Large Defects of the Trachea. ANNALS OF OTOTOLOGY, RHINOLOGY AND LARYNGOLOGY 57:875-83 (Sept.) 1948.
18. Pressman, J. J., and Simon, M. B.: Observations Upon the Experimental Repair of the Trachea Using Autogenous Aorta and Polyethylene Tubes. Surg. Gynec. Obstet. 106:56-62 (Jan.) 1958.

19. Rush, B. F., Jr.: Repair of the Injured Larynx Following Destruction of the Cricoid Cartilage. *Surg. Gynec. and Obstet.* 112:507-10 (Apr.) 1961.
20. Bofenkamp, B.: Aphagia from Poliomyelitis: Treatment by Denervation of Cricopharyngeus Muscle. *Trans. A.A.O.O.* 61:584-7 (Sept.-Oct.) 1957.
21. Bofenkamp, B.: The Surgical Correction of Aphagia Following Bulbar Poliomyelitis. *J.A.M.A. Arch. Otolaryngol.* 68:165-72 (Aug.) 1952.

THE "TROUGH" METHOD OF LARYNGOTRACHEAL RECONSTRUCTION

DOUGLAS P. BRYCE, M.D., F.R.C.S. (C), F.A.C.S.

VICTOR G. LAWSON, M.D.
(by invitation)

TORONTO, CANADA

Injury to the larynx and trachea results from two main causes. Most commonly, trauma to the neck, either from automobile accidents or other forms of violence, results in fractures of the thyroid alae or tracheal rings with dislocation of the cartilage and subsequent stenosis. Early adequate treatment of such injuries very often can prevent the formation of stenosis which becomes such a difficult problem when allowed to develop. A more recent cause of laryngotracheal injury results from the use of indwelling nasotracheal, orotracheal, or tracheotomy tubes with inflatable cuffs. Laryngotracheal damage from such tubes is being seen with increasing frequency in respiratory units where prolonged ventilation has been necessary.^{1,2} Regardless of the method of injury, the principles of treatment remain the same. Early reduction of fractured cartilage with adequate support to protect the lumen will prevent later complications. Where patients have been intubated for long periods of time, frequent direct examination of the trachea and larynx must be made over a six month period. This will discover the signs of injury in time to prevent serious stricture formation. If stenosis develops, excision of the stenosed area of the airway with end-to-end anastomosis is the treatment of choice. This applies particularly to the trachea. If the larynx and trachea area are extensively involved and excision and anastomosis is impossible, then some other method of restoration of lumen and function is necessary. It is the purpose of this paper to present one such method which has been successfully employed in two patients and is being used currently in one other.

HISTORICAL REVIEW

The management of chronic laryngeal stenosis has taxed the skill and ingenuity of laryngological surgeons for almost one hundred years. In 1870, Schroetter³ first reported treatment of this problem with repeated bougienage using hard India rubber dilators. Since then there have been many worthwhile

contributions to the literature. In 1885, O'Dwyer described a method of laryngeal intubation with rubber tubes. However, peroral dilatation methods were limited to patients with incomplete stenosis. It was not until 1929 that a method suitable for management of atresia of the larynx was introduced by Schmiegelow.⁴ His method initiated the era of open laryngeal surgery. Schmiegelow reported 18 cases treated between 1910 and 1925 by laryngofissure. With the larynx open, the pathology could be carefully examined. A lumen was re-established by excision of scar, cartilage, or bone and the airway was then maintained with a hard India rubber tube fixed with a translaryngeal silver wire. The internal rubber splint was placed low enough in the airway system so that it did not interfere with pharyngeal function. The splint had a central lumen so that the patient could breathe through the larynx immediately postoperatively. The splint was maintained for a period of one week to nine months, with an average of six weeks. This was a one-stage procedure as the tracheotomy was closed at the time of laryngeal surgery.

In 1927 Arbuckle^{5,6} reported two cases of post-diphtheritic and one case of post-streptococcal laryngeal stenosis treated successfully with an open operation, excision of scar, and placement of a Thiersch (split thickness) skin graft in the lumen. The graft was supported with a small rubber balloon in two of the cases and a sea sponge covered with rubber in the third case.

In 1935 LeJeune and Owens⁷ reported management of two cases of chronic laryngeal stenosis with an open stent method not unlike the "trough" method to be described. One patient was twelve years of age, the other twenty-six years of age. Both were treated identically with laryngofissure, Thiersch graft over a stent and approximation of the laryngofissure with two retention sutures. The stent was removed for cleansing at regular intervals and then reinserted through the fissure. After two months, the airway lumen appeared stable in size and after four months the stent was removed. The patient was then followed for two months with the edges of the fissure apposed with tape. When it was apparent that the airway lumen was well maintained, the fissure was closed surgically. In 1936 interest in laryngeal bougienage was renewed, particularly in children, by Chevalier Jackson.⁸ He stressed that the growing larynx of a child could be developed internally with soft elastic rubber core molds. He indicated that 95 per cent of children so treated could be cured.

In 1938 Looper⁹ first described a tissue implantation method to assist in establishing a laryngeal airway. He mobilized the left half of the hyoid bone with a portion of its blood supply intact and placed it between the incised edges of the thyroid cartilage. In 1950 MacNaught¹⁰ described the use of a tantalum keel to correct an anterior glottic web.

In 1961 Rush¹¹ reported a case of end-to-end reconstruction of the airway system in a 26 year old man who suffered from subglottic laryngeal stenosis due

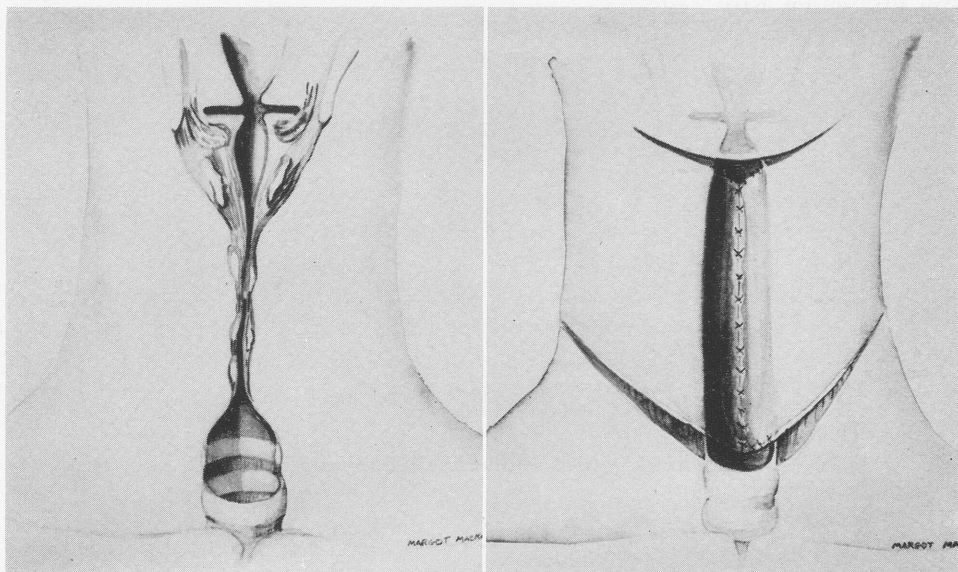


Fig. 1.—Artist's illustration of the injury sustained in Case 1 seen at laryngofissure.

Fig. 2.—Demonstrates the method of skin rotation used to line the laryngotracheal trough.

to a separation of the major portion of the cricoid from the thyroid cartilage. A small amount of the posterosuperior aspect of the cricoid cartilage with the arytenoid cartilages remained attached to the bulk of the larynx. The avulsed portion of the cricoid and the stenotic first and second tracheal rings were resected. The trachea was mobilized down into the mediastinum and then the airway gap was closed by end-to-end apposition using stainless steel sutures. A polyethylene stent was placed across the suture line for a period of two and a half months and then removed endoscopically.

In 1962 Knight¹² described the use of polyethylene sheeting anchored with nylon sutures to prevent laryngeal web formation following surgical treatment of carcinoma of the vocal cord and multiple laryngeal papillomatosis. In 1962 Conley¹³ described the use of skin flaps to rehabilitate the airway system of the hypopharynx, glottis, and trachea. His method could be managed as a single stage procedure by doing an epithelial shave with apposition of the "raw" epithelial edges at the time of the rotation flaps, or as a multi-stage procedure. "Thin" flaps could be used for covering a vocal cord following excision of a papilloma or "thick" flaps, including platysma, could be employed when bulk was required following extensive excision of cicatrix and traumatized cartilage, bone or both.

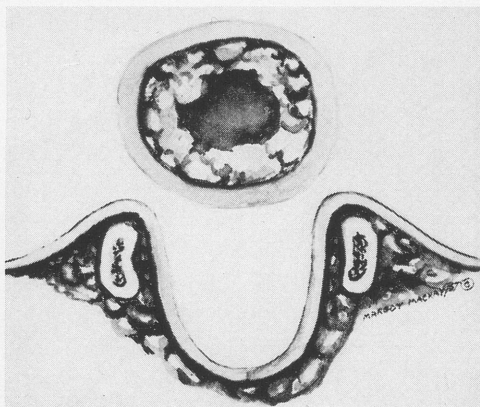


Fig. 3.—A diagrammatic section to illustrate the tubed skin graft in place relative to the "trough."

He suggested that with severe tissue loss, particularly when the trachea was involved, exteriorization of the airway was advantageous. In 1962 McCall and Whitaker¹⁴ used a tantalum prosthesis to restore airway continuity after resection of the cricoid and the first four tracheal rings. The patient was able to phonate adequately but he continued to require airway assistance from a tracheotomy. The authors attributed the relative airway failure to a small prosthesis, but felt that the operation was successful in all other respects. The most encouraging prosthetic material available for tracheal reconstruction today is heavy Marlex[®] mesh. This material is a high density polyethylene of exceptional tensile strength. It is rigid enough to withstand the positive intraluminal pressure of a forceful cough and the negative intraluminal pressure of inspiration, yet it is flexible enough to permit a wide range of neck movement. It is well tolerated by the host and it is resistant to decomposition. It is porous, permitting granulation tissue to grow through the interstices with subsequent epithelialization of the lumen. In 1962 Ellis et al.¹⁵ reported the successful use of a tubular Marlex prosthesis, 2.5 cm in diameter and 6 cm in length, in a 49 year old man with recurrent carcinoma of the tracheostome following laryngectomy. The distal end of the prosthesis was placed inside the tracheal stump and fixed with Marlex sutures. In 1966 Pearson¹⁶ reported experimental and clinical studies on tracheal reconstruction using porous Marlex. Experimentally, circumferential defects of seven to nine tracheal rings in mongrel dogs were bridged with tubular Marlex mesh. The prosthesis was anastomosed to the outside of the trachea in one group and to the inside of the trachea in another. The group with the prosthesis anastomosed to the inside of the cut end of the trachea developed troublesome endo-

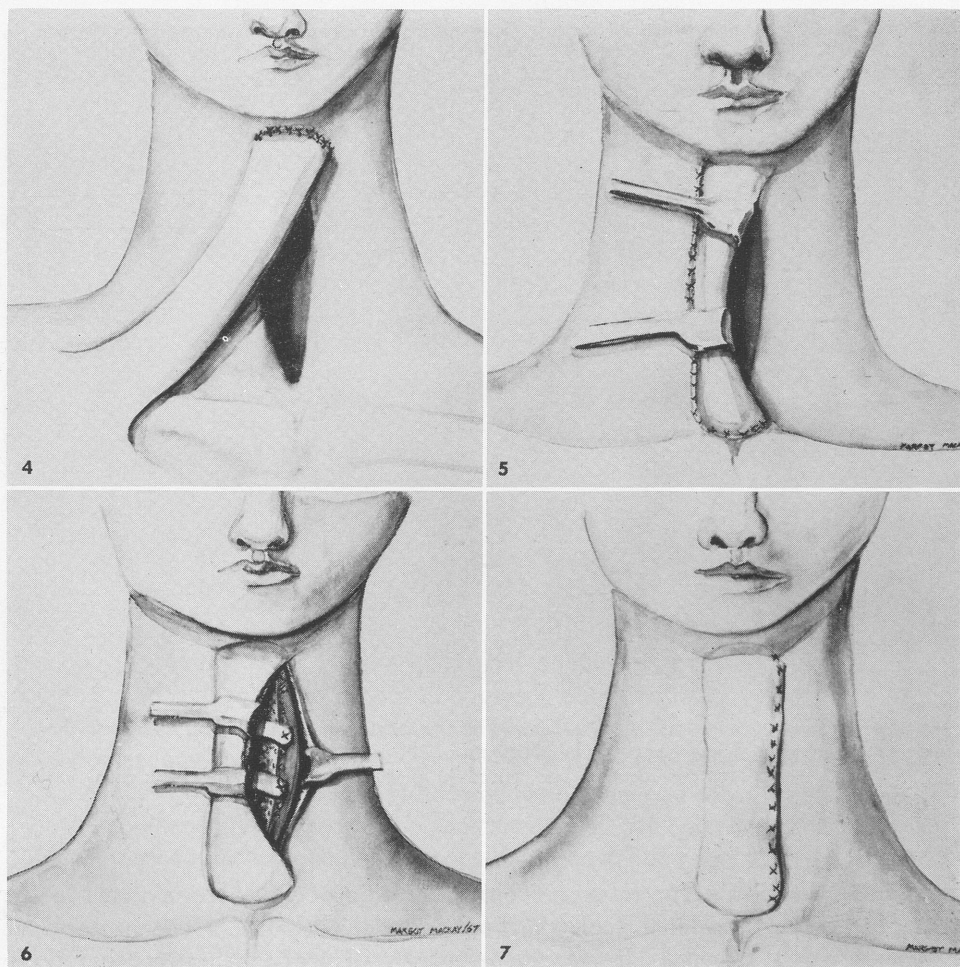


Fig. 4.—A tubal graft rotated and set in place proximal to the laryngeal opening of the trough.

Fig. 5.—The tubal graft set in place except for a left lateral opening to allow visualization of the trachea.

Fig. 6.—Cartilage graft in place in the substance of the "tube" to provide stability to the anterior wall of the trachea.

Fig. 7.—The tube sutured in place to form a stabilized anterior wall.

tracheal granulations and stenosis. The group with the prosthesis fixed to the outside of the trachea were relatively free of granulations. Epithelialization of the endoluminal surface of the prosthesis occurred from the cut ends of the trachea. There was, however, a tendency to stenosis in the midportion of the

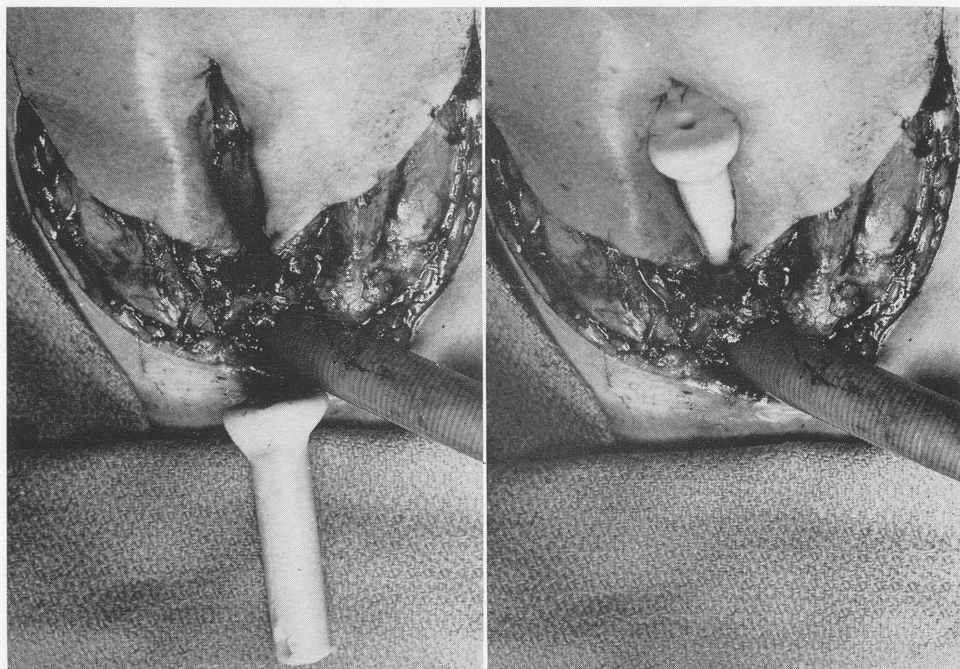


Fig. 8.—Rotation cervical skin flap to line the laryngotracheal groove. The prosthesis used is seen in the lower part of the photograph.

Fig. 9.—A prosthesis inserted and wired in place to maintain the laryngotracheal groove.

prosthesis presumably due to excessive proliferation of granulation tissue in the part of the prosthesis that took the longest to epithelialize. The problem of stenosis could be alleviated by placing a narrow strip of tracheal mucosa along the inside of the prosthesis. Two successful clinical cases were reported: one in a 15 year old girl with adenoid cystic carcinoma of the trachea, requiring a tracheal replacement of 6.5 cm in length, and the other in a 48 year old man with adenoid cystic carcinoma of the trachea that required replacement from the cricothyroid membrane to the lower half of the intrathoracic trachea. In 1965 Grillo¹⁷ described a method of mobilization of the tracheobronchial tree to permit reconstruction of the cervical and mediastinal trachea by end-to-end suture. He states that full mobilization of the right hilum with division of the inferior pulmonary ligament obtains 3.0 cm of length. Detachment of the left main bronchus with reimplantation into the bronchus intermedius provides another 2.7 cm, and finally dissection of the pulmonary vessels from the pericardium obtains 0.9 cm. This provides a total length of 6.6 cm, or more than one-half

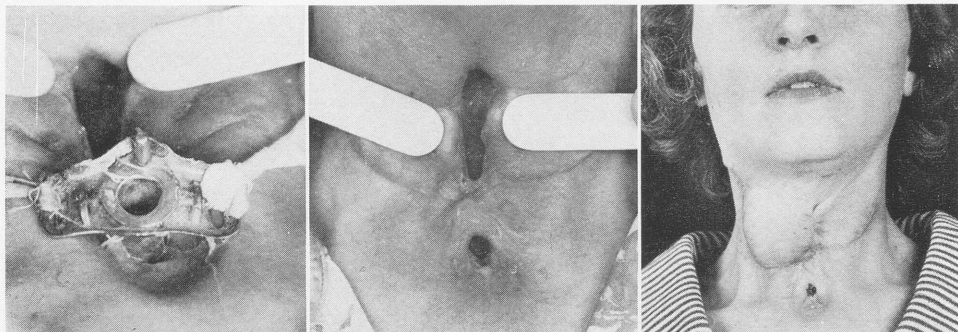


Fig. 10.—The deepened laryngeal trough as a result of laterally placed cartilage grafts.

Fig. 11.—A further view of the laryngotracheal trough after cartilage grafts.

Fig. 12.—All incisions healed and the trough functioning well.

the average length of an adult trachea, and allows for resection of as many as 13 tracheal rings with end-to-end closure.

REPORT OF CASES

CASE 1. Mr. E.W.W., a 19 year old white male, received severe injury to the front of his neck while travelling in a truck in July, 1957. This necessitated an emergency tracheotomy. Three months later, laryngoscopy revealed bilateral vocal cord paralysis and complete subglottic laryngeal stenosis. Because of this, a laryngofissure was carried out and the cricoid, first, second and third tracheal rings were found to be missing, and the lumen (Fig. 1) at that point obliterated by thick scar. This was treated by excision of the scar and insertion of a polyethylene mold and a tantalum keel because of anterior vocal cord webbing. The anterior wall of the trachea was supported by tantalum mesh and lined by fascia. Four months subsequent to this procedure, subglottic stenosis was evident, so the obturator was removed and a new one inserted which extended from above the vocal cords proximally to the level of the tracheotomy distally. At the time of the second operation, the tantalum mesh was found to be fragmented and this was removed. Several attempts were made to remove the indwelling prosthesis over the next eleven months without success. Because of this, he was again operated upon and a new prosthesis inserted with a skin graft. He was discharged from hospital with the obturator in place and one year later was re-admitted for removal of the obturator. After this was done, the lumen remained adequate for six months and the tracheotomy was closed. Unfortunately the stenosis recurred. It was decided at this point that a new method of management must be developed and so the patient was again admitted to hospital.

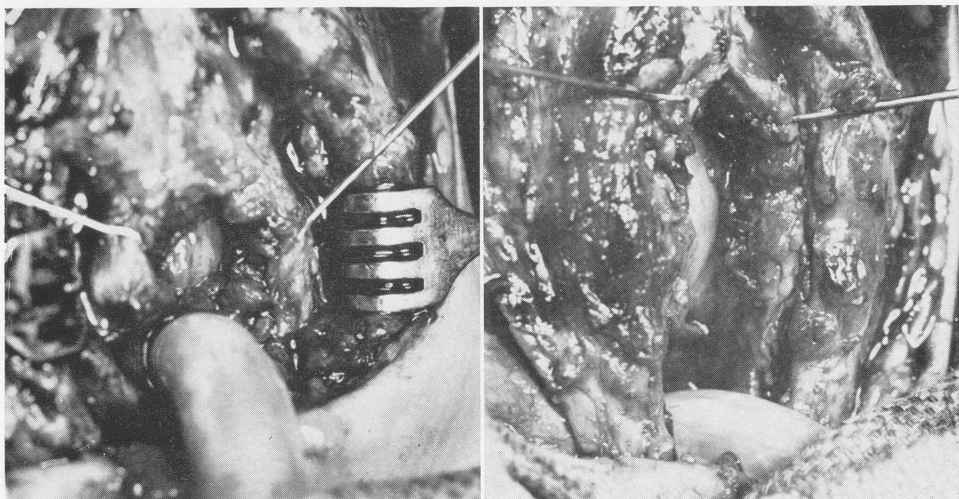


Fig. 13.—A view of the necrotic damage to the anterior wall of the trachea seen at operation in Case 3.

Fig. 14.—The total extent of tracheal damage seen after debridement.

The area was exposed and once more the scar tissue excised. Rotation skin flaps from the neck were used to line the trough of the trachea so formed (Fig. 2). The lumen was left open from the lower border of the thyroid cartilage proximally to the level of the tracheotomy distally. Three months later, this trough was free of granulations and well healed. Bone grafts were then inserted on each side of the laryngeal trough (Fig. 3) to increase the AP diameter and a tube skin pedicle was raised on the chest and transferred to the neck to close the anterior aspect of the trough (Figs. 4 and 5). This pedicle was incised to provide skin lining for the tracheal lumen as well as the anterior aspects of the neck. It was felt necessary to support the tube flap so that the negative pressure on respiration in the trachea would not obliterate the lumen, and so cartilaginous semicurved grafts were cut from the costal cartilages and inserted into the anterior skin flap (Figs. 6 and 7). One month subsequent to this procedure, the patient was examined directly and the lumen was seen to be adequate. He is now five years postoperative with no evidence of recurrence. His airway is adequate for all ordinary purposes and he is carrying on normally his vocation.

CASE 2. Mrs. M.H., a 40 year old white female, was involved in an automobile accident in May, 1965, with resulting dashboard injury to the anterior neck. The tracheotomy was done the same day and the patient was seen three months later when extubation was impossible. At that time, there was obvious

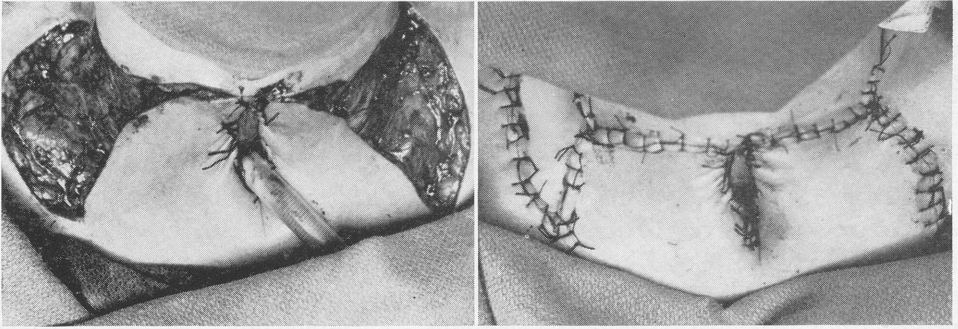


Fig. 15.—Rotation skin flaps to line the tracheal trough.

Fig. 16.—Completed cervical rotation flaps to line the trough and cover donor areas.

complete stenosis of the larynx so that she was unable to breathe or speak without use of a tracheotomy tube. Laryngoscopy demonstrated complete loss of all landmarks except for the tip of the epiglottis, and no laryngeal airway. A laryngofissure was done and the larynx examined. The left thyroid cartilage was found to be fragmented and displaced posteriorly. Both arytenoids were displaced from their normal position and the right thyroid ala was fractured but remained roughly in its normal position. No lumen existed in an area extending from the glottis to the first tracheal ring. Cicatrix was excised and the arytenoid cartilages removed. The thyroid alae were dissected free and replaced in a relatively normal position. Mucous membrane from the postcricoid area was freed and pulled forward and downwards to provide a mucosal lining for the posterior aspect of the trough. The lateral walls of this trough were covered by rotation skin flaps from the neck (Fig. 8). A prosthesis was inserted extending from the supraglottic area above to the tracheotomy below, so as to splint the replaced cartilage, mucous membrane and skin graft (Fig. 9). The prosthesis was wired to the soft tissues of the neck. The anterior aspect of this trough was left open so that the prosthesis was visible. Approximately six weeks later, the prosthesis was removed and rib cartilage grafts were inserted on each side of the trough at the level of the glottis in order to raise the margins and so deepen the trough (Figs. 10 and 11). Five weeks subsequent to this operation, a third operation closed the glottis and the anterior tracheal wall by rotation of skin flaps from the trough margins and the neck. An attempt was made at that time to approximate the area of the glottis so that some sphincter action might result in a voice. Healing was uneventful, the tracheostomy was closed, and the patient was discharged from hospital four months after her admission (Fig. 12). At that time her voice was a hoarse whisper and her swallowing of solids was quite good.

Fluids and saliva tended to spill into the trachea to some extent but not enough to cause serious trouble. When examined two and four months after discharge, the patient reported that swallowing had become much more effective and that the spill-over of saliva and fluids was much less. Her voice was also improved so that she now had a hoarse but adequate voice. On examination, the laryngeal area has maintained its postoperative lumen and seems to be taking on the appearance of a normal glottic chink.

CASE 3. Mrs. Y., a 28 year old mother of two children, required nine days of respiratory ventilation through a nasotracheal tube in October, 1966, following barbiturate and bromide over-dosage. When she was extubated, she rapidly developed laryngeal stridor, respiratory embarrassment, and pneumonia necessitating reintubation and tracheotomy. Laryngoscopy, two weeks later, revealed a severe subglottic stenosis that was 3 cm in length on tomographic studies. A laryngeal stent was inserted but five months later the subglottic lumen was still severely inadequate and filled with granulations. Through a curved incision at the midthyroid level, the trachea was examined. The anterior wall was found to be completely destroyed for a distance of 6 cm distal to the cricoid cartilage (Figs. 13 and 14). Posterior wall mucous membrane had survived but only small posterior cartilage remnants remained in this area. Rotation skin flaps from the adjacent neck area were fashioned and sutured to the posterior mucous membrane remnant to form an open "trough" connecting the larynx at the level of the cricoid above the trachea distal to the tracheotomy tube, which temporarily was left in place (Figs. 15 and 16). No prosthesis was used. This "trough" has now epithelialized well and no granulations remain. The second stage closure is planned shortly.

COMMENT

It is not the purpose of this presentation to suggest that the trough method of tracheal repair should be widely adopted. Most cases of laryngotracheal injury are mild in degree and the results are not apparent to the patient or the doctor unless direct examination is carried out. There are a large number of other minor degrees of tracheal and laryngeal damage which can be controlled by endoscopic dilatation or by the use of an indwelling prosthesis to allow for the return of stability of the structure.

This presentation is in reference to much more serious and extensive laryngotracheal damage. There is considerable difference in prognosis and technique depending upon whether the larynx is damaged as well as the trachea and whether or not the recurrent laryngeal nerves are involved. If the trachea itself is severely damaged, then the acute therapy for this injury is surgical exploration and excision of the damaged area. The immediate treatment for serious laryngeal injuries may be merely the replacement of the structures in the appropriate position by

endoscopic or direct methods and the maintenance of this position by an indwelling prosthesis.

The third case reported is of interest because of the nature of the tracheal injury. The use of nasotracheal tubes to support or maintain respiration in respiratory units has become in our experience a major cause of tracheal and laryngeal injury. It is not clear yet to what extent the inflated cuff of the tube contributes to the damage. Further work on this problem is necessary and, in the meanwhile, it is well to be alert to the threat to the airway inherent in their use.

It is the correction of the stenotic damage to the trachea and larynx following extensive injury that presents the greatest problem. It may not be possible in these cases to restore the lumen by any simple method, because of the movement in the cervical area in which these structures lie, and because of a tendency for granulation and stricture formation. Furthermore, the airway in this area requires considerable support to prevent collapse on respiration. It is our opinion that prosthetic materials for repair are not suitable. We believe that the combination of infection and movement requires the use of autogenous grafts of skin, cartilage or bone. In some cases, it may be possible by various means to restore the function of the larynx and trachea without resorting to the radical method described in this paper. However, when other methods have failed and when no other means of repair seems apparent, this method has been shown to be effective. In particular, it has its value in that the trachea and larynx can be exposed and visualized daily and that granulations and stricture formation can be controlled and stabilized before an attempt is made to permanently close the airway using some sort of supported material to form an anterior wall. The disability due to permanent laryngotracheal stenosis or injury with loss of airway is very great indeed, and there should never be hesitation in embarking upon the type of surgical procedure described in this paper for its repair.

SUMMARY

Injury to the laryngotracheal airway is becoming very much more common and minor degrees of respiratory obstruction must be frequent. Treatment is only necessary when there is sufficient loss of cartilage so that stricture formation in the trachea or larynx becomes apparent. In most cases, resection of the narrowed area or some form of dilatation and indwelling prosthesis can manage the problem satisfactorily. There are a few cases, however, in which damage is so extensive and severe that more radical surgical methods are necessary to restore the airway adequately. One such method, requiring extensive rehabilitation with skin and cartilage grafts, is described. This method has proven to be satisfactory when necessary.

REFERENCES

1. Fearon, B., MacDonald, R. E., Smith, C., Mitchell, D. P.: Airway Problems in Children Following Prolonged Endotracheal Intubation. *ANNALS OF OTOTOLOGY, RHINOLOGY AND LARYNGOLOGY* 75:975 (Dec.) 1966.
2. Byrn, Davies, Harrison: Tracheal Stenosis Following Tracheotomy. *Brit. Jour. of Anaesth.* 39:171, 1967.
3. Schroetter: *Allz. Wien - Fed. Ztg.* Vol. 12, 1867.
4. Schmiegelow, E.: Stenosis of the Larynx. *Arch. of Otolaryngol.* 9:473, 1929.
5. Arbuckle, M. F.: Cicatricial Laryngotracheal Stenosis Treated Successfully by Open Operation and Skin Graft. *Trans. Am. Laryngol., Rhinol. and Otol. Soc.* 33:450, 1927.
6. Arbuckle, M. F.: The Treatment of Cicatricial Stenosis of the Larynx. *ANNALS OF OTOTOLOGY, RHINOLOGY AND LARYNGOLOGY* 39:134 (Mar.) 1930.
7. LeJeune, F., Owens, N.: Chronic Laryngeal Stenosis. *ANNALS OF OTOTOLOGY, RHINOLOGY AND LARYNGOLOGY* 44:354 (June) 1935.
8. Jackson, C.: Stenosis of the Larynx. *Trans. Am. Laryngol., Rhinol. and Otol. Soc.* 42:12, 1936.
9. Looper, E. A.: Use of the Hyoid Bone as a Graft in Laryngeal Stenosis. *Arch. Otolaryngol.* 28:106 (July) 1938.
10. McKnaught: Surgical Correction of Anterior Webs. *Laryngoscope* 60:264 (Mar.) 1950.
11. Rush, B. F.: Repair of Injured Larynx Following Destruction of the Cricoid Cartilage. *S.G.O.* 112:507 (Apr.) 1961.
12. Knight, J. S.: Laryngeal Stenosis - Method of Surgical Correction. *Trans. Am. Laryngol., Rhinol. and Otol. Soc.*, p. 222, 1964.
13. Conley, J. J.: Rehabilitation of the Airway of Bi-neck Flaps. *ANNALS OF OTOTOLOGY, RHINOLOGY AND LARYNGOLOGY* 71:404 (June) 1962.
14. McCall, J. W.: The Use of Prosthesis in the Larynx and Trachea. *ANNALS OF OTOTOLOGY, RHINOLOGY AND LARYNGOLOGY* 71:397 (June) 1962.
15. Ellis, Harrington, Beale, DeBakey: The Use of Heavy Marlex Mesh for Tracheal Reconstruction Following Resection for Malignancy. *Jour. Thoracic and Cardiovas. Surg.* 44:520 (Oct.) 1962.
16. Pearson, F. G.: Personal communication.
17. Grillo, H. C.: Circumferential Resection and Reconstruction of the Mediastinal and Cervical Trachea. *Ann. Surg.* 162:374 (Sept.) 1965.

DISCUSSION

DR. CHARLES MORGAN NORRIS: I wanted to make just a few comments regarding the so-called "open" method in the treatment of subglottic stenosis or atresia (open in the sense that an elongated tracheal fistula is deliberately created to facilitate manipulation, inspection and the use of apparatus)

A lady had sustained a crushing injury of the larynx two months before we first saw her. A mold had been inserted shortly after the accident but apparently was not properly placed, or had become dislodged, because we found, on direct laryngoscopy and roentgen examination, a complete atresia of the subglottic region and the upper segment of the trachea.

At the time of the surgery it was very difficult, of course, to re-establish a supportive framework for the airway. Since the cricoid as well as the thyroid had been crushed, an elongated tracheal fistula was created and a teflon mold introduced.

A strip is elevated and in the aperture thus created a quadrangular block of silastic is inserted. This, of course, is elastic and can be compressed so that when it is inserted in the aperture below the elevated strip it stays in place and thus maintains the fistula.

Once epithelialization has occurred an acrylic mold is put in.

The acrylic mold makes use of a thin stainless steel plate which fits tightly in a little slot in the projecting part of the mold; this serves to maintain the elongated fistula but allows the two sides of the fistula to approximate more closely.

The advantages of these types of apparatus are threefold:

In the first place, they are easily removed and re-inserted and thus one can check as often as necessary as to the condition of the mucosal surface, the presence of granulation, and so forth.

They are much cleaner, because using this type of apparatus, the tracheal cannula can be changed daily.

It is not necessary to use sutures or anchoring devices attached to the tracheal cannula or to the tracheal fistula to keep them in place.

The acrylic mold fits in the elongated fistula, which extends up to the lower margin of the stenotic segment.

The projecting portion of the mold is shaped so that it fits nicely on the dorsum of the tracheal cannula and thus allows daily changing of the tube.

The mold itself is easily removed by the patient at home for cleaning and re-insertion.

The third advantage is that when the time comes for the "test period" this mold is easily removed, left out for increasing intervals and again re-inserted by the patient.

This symposium, which Dr. Nahum, Dr. Priest and Dr. Bryce presented yesterday, was certainly a very instructive one. I think we all use what mechanical ability we have in adapting apparatus to individual patients. The ones shown have been used in four cases, three of whom have been decannulated. The case presented is now in the "test period" and the mold is being left out one or two days at a time.

DR. HERBERT HARRIS: These were certainly wonderful papers but I don't agree with all aspects of their management.

(Slide) This is an unusual case of a laceration of the trachea with resulting atresia apparently due to separation of the upper and lower segments. This patient had three operations previously on her trachea in an attempt to gain a lumen. The larynx was entirely normal and the vocal cords functioned normally.

Now you see one tracheotomy tube here leading to the upper segment and the lower tube to the lower segment for breathing purposes, and the ingenious device used here was a curved tube which fitted from the lower tracheotomy tube to the upper tube, thus bypassing the atresia of the trachea so that she could talk.

(Slide) This lady, during exploration, showed absolutely no trachea for a distance of about one inch, so it was absolutely impossible to do an end-to-end anastomosis because of the fibrous tissue about the trachea and our inability to mobilize it. Dr. Arthur C. Beall has been using a Marlex trachea and this is one of our most recent cases using the Marlex material for replacement.

This is a different type of Marlex from that which is ordinarily used for the repair of hernias. It has to be cut and the actual cautery is used to burn the ends to prevent them from becoming frayed. The Marlex suture material is used to suture the synthetic trachea in place.

(Slide) This slide shows the Marlex trachea having been placed in the upper segment and the lower segments of the trachea. It must be placed within the trachea and the trachea sutured over it. If this is not done a stricture has always developed in experimental animals. We did not injure the recurrent laryngeal nerve during the placing of this segment of Marlex and she now has a perfect voice and perfect function; slightly more than a year has elapsed since she was operated upon.

At one time during the postoperative period she did develop some granulations which required a bronchoscopy and the removal of these because of obstruction. It is a little difficult to know whether she has entire regeneration of the mucous membrane lining this segment but certainly there is some.

(Slide) Six weeks before seeing me this young man had been hit with a cable across his trachea. There was no break in the skin but this is the upper segment of his trachea and this is the tracheotomy tube and there was no continuity here.

Fortunately we were able to mobilize the trachea down as far as the carina and do an end-to-end anastomosis.

We now have made another tracheotomy opening—this was the original tracheotomy opening about 2 cm above the new opening.

(Slide) This slide shows the upper segment, which has one ring of the trachea, the cricoid being above. This is the lower segment and the new tracheotomy opening. Polyethylene monofilament suture was used here to close the end-to-end anastomosis.

This young man has bilateral severance of his recurrent laryngeal nerves. The cords are now in the mid-position. He gets along quite well and has a complete recovery as far as his airway is concerned but has, of course, a very poor voice. He has learned to phonate reasonably well with his false cords.

DR. JOHN S. KNIGHT: One year ago, I gave a paper at the San Juan Meeting on the use of the double-posted teflon tube. We have had more cases. One was an atresia case of four months' duration: a twelve-year-old boy who had a farm truck accident associated with a broken jaw and an emergency tracheostomy. After competent care by an otolaryngologist for tracheostomy care and an oral surgeon for his jaw, he was sent to us completely obstructed and aphonic. The jaw was in fine shape. After usage of the double-posted teflon tube for the first phase of his voice box formation, the plastic sheeting operation for development of an anterior commissure was used. He has been decannulated, has a normal laryngeal airway and a satisfactory voice.

The use of the teflon tubes has proven satisfactory, not too difficult to handle in the hands of ourselves and others who have used them.

The sizes have been made smaller than the ones originally made by George P. Pilling and Son Co., on my recommendation. We have the four new sizes which are available; namely, male adult, female adult, adolescent and child.

The teflon tube was to be left in situ for thirty to sixty days. To date we have had only one patient who has manifested an allergy or intolerant reaction to all forms of plastic materials, including the teflon tube.

In his case, the polyethylene feeding tube and the double-posted teflon tube had to be removed on the twelfth postoperative day following his laryngofissure and extensive cordectomy. It was most gratifying to see the mucosal development over the previous operative site in such a short time. He has maintained a good laryngeal airway, a satisfactory voice, and no evidence of cancer recurrence since his original surgery fifteen months ago.

Very severe trauma cases and stenosis following surgical procedures should respond to the use of the teflon tube.

Again I reiterate there should be a set of variable sizes of this type, or other types that have been developed, available in every surgical group or hospital or emergency room for use at the time of trauma.

DR. JOSEPH H. OGURA: Dr. Priest emphasized open reduction. I agree with everything he has said.

I would like to present some different aspects.

This is a case which Dr. Priest and I know very well. He is the son of an anesthesiologist in St. Louis, who was struck in the neck by a soccer player while he was up at Minnesota.

One of the things that happens is that the thyroid cartilage gets displaced and I think this is one of the things that has not been mentioned. The thyroid cartilage has been displaced upwards and here is the other portion.

Operation was done about the fifth day, and the cords with the two thyroid lamina were brought back together and sutured. Naturally, if this were left alone, he would have a stricture.

This is a summary of our cases over the last five years. I have not included those before that time. You can see that with the acute cases you can get excellent results in all of them. I might say that you can perform reductions up until the eighth day.

Our problem cases are here with the chronic end-to-end anastomosis. You can accomplish good results by thyrotracheal anastomosis in about fourteen out of sixteen subglottic stenosis and with supraglottics requiring resection you can get an excellent result in every instance.

With the glottic lesions you can have a midline split at the thyroid cartilage; stent it and close it with the split of the thyroid cartilage repositioned, or perform a hemilaryngectomy.

For a supraglottic evulsion which is beyond the eighth day, we prefer to do a resection immediately, even in the acute form because of the infection that has taken place, healing will be delayed and a re-anastomosis will be complicated by stricture.

With arytenoid dislocation very often a thyrotomy is necessary. For a vocal cord paralysis we approach it from the side, take out the thyroid lamina that has compressed the recurrent laryngeal nerve.

For a chronic subglottic form we perform the thyrotracheal anastomosis by direct resection but one must be very careful not to resect the cricothyroid articulation because the rostral end of the cricoid will then ride up into the lumen. In other words, do not disturb the cricothyroid articulation. You can resect two tracheal rings and do an end-to-end anastomosis and you can accomplish a good result by this. It requires also a Woodman's procedure.

For the supraglottic stenosis, a resection with or without a Woodman, and for the combined type I use a mucosal graft from the epiglottis to repair the reduction of the anterior/posterior diameter of the lumen of the glottis. As a result you can produce a gun-barrel pseudo-larynx which functions.

APPLICATION OF VOICEPRINT TECHNIQUES TO VOCAL TRACT ANALYSIS

L. G. KERSTA
SOMERVILLE, N. J.

The greater part of my career was spent at the Bell Telephone Laboratories, in the Research Department, where my basic studies were in speech, its production, its intelligibility factors, its naturalness factors. I studied methods by which speech could be best transmitted, whether by analog signals or, in most recent years, by digital signals, so that speech could be processed by mathematical computers.

During my researches at the Bell Telephone Laboratories, we were asked, during a rash of bombing threats to airlines in New York City in 1961, whether it would be possible to identify people by their voices.

The inquiry was much in my line of interest and I requested permission to attempt to design such an identification system. Within two years I was able to report to the American Physical Society at the Acoustical Society branch that I had in fact developed such a system

It is a system using a common tool in speech and acoustic research called a spectrograph. You are familiar with the high frequency type spectrograph, which is used generally for analyzing chemical constituents. The acoustic spectrograph is a similar instrument, the difference lies in the fact that it analyzes frequencies lower in the spectrum than the chemical analysis spectrograph does. It is a very valuable research tool and it played an important part in the design of a voiceprint identification system.

In application, the voiceprint identification system works very much like the fingerprint identification system. It employs an analytical technique, in which the spectral patterns of unique acoustical sources are compared. The acoustical sources signal can be anything which is liable to write its signature by its acoustical output. Naturally, the human voice falls in this category.

Since I developed the voiceprint identification system, I have cooperated with various police departments in performing voiceprint identifications on people who had used, generally, the telephone communication system for some nefarious or criminal purpose. In the past three years I have cooperated with over twenty police organizations and been involved in about 100 different cases.

In our knowledge, and by confirmation in most cases, we have been correct in every instance. We have testified as a expert witness in several trials, at each of which voiceprint evidence was ruled as admissible evidence.

In each possible medical application case I have had as my colleague and collaborator a doctor operating in that field. We have tried to apply the spectral pattern recognition technique as an additional analytical tool for medical research.

We have, because of interest in the medical field, touched on many areas. Our published papers so far have been wholly in the field of heart sound analysis and in the determination of the emotional stress levels in schizophrenics.

The spectrograph is an electronic instrument which analyzes acoustic sounds as they have been recorded on magnetic tape by the rather standard type magnetic taps recorders which most of us have these days. The spectrograph has the capability of translating recorded acoustic signals on magnetic tape and then automatically converting them to electronic signals, processing them through analyzing filters and automatically drawing a visual portrayal of the acoustic sound being analyzed. There are two important modes in which it operates.

A conventional spectrogram of the type used in voiceprint identification for law enforcement purposes is called a voiceprint, analogous to the fingerprint.

A bar voiceprint exhibits horizontal bars. The horizontal bars are caused by speech cavity resonances, and in our field these are called speech formants.

The spectrogram has physical dimensions from which we can take numerical parameters. Along the horizontal, or the abscissa, is a measurement of time. The time illustrated is about three-tenths of a second. It takes about three-tenths of a second to say "you." Along the vertical, or ordinate scale, there is a dimension of pitch, or frequency, with low pitch at the base. The relative darkness of the marking measures the intensity.

For the application to speech studies and to laryngeal studies, it is important to know that pitch frequency can be seen by the vertical striations in the pattern and, since we can count the number of vertical striations as a function of time, we can determine pitch frequency, its regularity, and study factors which may change the pitch frequency of the voice.

A form of spectrogram that is, for purposes of law enforcement, used in the classification of voiceprints much as the classification of fingerprints is called a contour voiceprint. This type is most used in medical applications. They provide a much better quantitation of intensity. The time dimension is identical in both cases, but now there is a measure of intensity as a function of contour lines which exist exactly as do the contour lines on a topographical map. Instead of having contours of altitude, contours of intensity are identified, and progressing

from one contour line to the other, from the outer to the inner, the intensity is increased six decibels each time for a total range of 48 decibels. These levels of intensity change can be resolved very accurately, whether they be body sounds or any other acoustic signal. The spectrograph is an instrument which gives very fine resolution and portrays a range of intensity far beyond the capabilities of the human ear and of most other types of analytical equipment available today.

Pattern differences are caused by the uniqueness of each speaker's voice. The pattern illustrates the reason, by making these pattern matches, a person's voice can be identified. The voice illustrates invariant uniquenesses which are created by the person's vocal tract and the method by which he uses his muscles to speak.

In one individual the high frequency resonance is a nasal resonance and does not appear in other speakers' voices. This person's high frequency resonance takes the form of a lobster claw. The fact is that a voiceprint of this person's utterance would always show a lobster-claw-like formation at the high frequency part of his speech pattern and it is used to help identify him.

In "e" formation one person had a sort of an angular type. Over the "e" there was a strong cap. The cap over the "e" was not present on any of the other prints. By placing the prints side by side and making an area-by-area match many points of coincidence between two utterances and very few points of coincidence with anyone else's voice can be found. Much like fingerprint identification, this is the way voiceprint identification is performed.

To make a positive identification of a person's voice a large series of words is used to get a sufficient number of spectral pattern similarities to identify the voice.

To describe the speech factors which cause the uniquenesses in the voice and the patterns in speech may be of value in your field.

The vocal cords do not produce intelligible speech. The vocal cords are the sound generator which produce for our ears just a buzz sound and this buzz sound must be reinforced and modified by the application of resonances at certain vocal cavities and the operation of our articulators to make intelligible speech.

In the bar spectrograms of speech the horizontal bars were caused by the reinforcement of the laryngeal energy in four major vocal cavities. These are in turn, from the low frequency to the high frequency, as follows: pharyngeal cavity, the largest cavity which resonates the lowest frequency; and the next two bars are caused by the oral cavities, the front and back cavity, and these vary in size depending upon the position of the tongue when an intelligible word is formed.

When you go "ee-ah, ee-ah," the tongue goes back and forth changing the size of the front and back cavities in your mouth, which changes the position of the speech formants and changes the location of the two middle bars.

The upper frequency resonances are produced in the nasal cavities and they produce the high frequency bars. Their existence depends on the position of the soft palate, whether the soft palate is hanging limply at the back of the throat or pressed firmly against the back of the throat to close off the nasal cavities.

The first uniqueness factors used in determining the identification of a person are caused by the improbability of finding two people with exactly the same sized vocal cavities and coupled in exactly the same way.

In tandem with the uniquenesses imparted by the vocal cavities are the uniquenesses which are imparted by the pattern which was learned and became conditioned to for the use of the articulators. For voiceprint identification the important articulators are the lips, the teeth, the tongue, the soft palate, and the jaw muscles.

Why is the method by which we have learned a pattern of use for our articulators unique? It is best to recall to your mind how an infant learns to speak. An infant does not learn how to speak spontaneously but learns speech by imitating those around him. Long before he can make intelligible speech he begins to understand the communication of those around him and he has a great desire to communicate. No one tells him, for instance, when he makes his first intelligible sound, which for example may be "ma-mama," that when he says "m-m-m" he must close his lips tightly together, allow his soft palate to dangle loosely at the back of his throat, and allow the energy to come through the nasal cavities. Then to make an "ah" he has to almost reverse the process, open his mouth wide, push his soft palate firmly up against the back of his throat and allow the "ah" sound to come through his mouth.

There isn't a person who can consciously push the soft palate up against the back of the throat, but while speaking in the normal speaking voice the soft palate is flipping back and forth opening and closing the nasal cavities.

How does the baby learn? It is an intelligent animal and by a random learning process in which it employs thousands and thousands of trials and errors in manipulating its cavities and articulators, he finally achieves the miraculous combination which is proper to make an intelligible sound. From then on, he develops a pattern for the use of his articulators, which he becomes conditioned to, and indeed, it is very difficult to consciously change. The factors which are difficult to consciously change we use for voiceprint identification.

The speech invariants appear to prevail through attempts at disguises, mimicry and ventriloquists' attempts to create new and different voices.

Trained high school girls were never defeated by any attempt at disguise, mimicry or ventriloquism.

The spectrogram language is a written phonetic language and can be learned in about the same period of time that it takes to learn any foreign language, and thus language can be transcribed phonetically.

It is quite easy to recognize the difference between male and female voices. It becomes a little more difficult to differentiate between a child's and a woman's voice, but principally the male voice is lower pitched, and the pitch frequency striations are farther apart. They can be counted in a unit of time, and the pitch frequency can be determined accurately.

In the female voice the striations are much closer together illustrating a much higher pitch frequency.

The oral resonances are somewhat lower in the spectrum for males than for females. There is generally a greater ratio difference between the formants of a female speaker and a male speaker and the voiceprints can determine emotional stress levels of people. Emotional state levels are determined by measuring three basic parameters. One measure is pitch frequency, which rises with increasing emotional levels. Secondly, syllabic rate, the rate at which syllables are connected to make speech is measured. This rises as a function of emotional state. Thirdly, speech formants are measured, the time/rate change of speech formants rises as a function of emotional state. These three numeral parameters are combined in a linear function, which is called emotional index.

The spectrogram shows the effects in speech improvement over a period of time of a cleft palate victim who has had surgical repair. The speech at the point of surgical repair indicates that the patient has not learned to use the soft palate for closing the nasal cavities. There is very little energy in the speech pattern areas which are caused by resonances of the oral cavities. Strong energy in the nasal cavities pattern area is noted, and this is the reason for high nasality in the speech of cleft palate victims.

After some speech therapy, there appeared great strengthening of energy in the middle speech formants. The nasal energy was still very strong and the speech sounded somewhat nasal.

There was a dramatic change in the succeeding period, a very short period of time, only fourteen days. The speech pattern indicated a reduction in the high frequency energy and a further strengthening of the low frequency energy. There was weakness of the second formant coming down to meet the base line and the roughness of the pitch frequency in this area but very regular pitch and a very smooth progression of the second formant. There were dramatic changes in the speech quality as you heard it. It can be displayed well in the pictorial

form and it provides a good method for plotting the improvement of speech during therapy and has been used in aiding in the design of prosthetic devices to improve speech during design.

The asthmatic wheeze can be seen by a strong energy concentration in the upper part of the spectrum during inspiration. The inspiration cycle is a pronounced whistle, which is easily determined and quantitated.

The expiration cycle comes in two attempts at exhausting the lungs and again shows a strong whistle-type wheeze and, interestingly, it is at a much higher frequency during expiration than it is during inspiration and can be accurately quantitated.

Two hours later after administration of a decongestant drug the high frequency energy is entirely gone and the inspiration and expiration cycles have been considerably shortened. The wheeze is entirely gone, the two-step expiration is eliminated and the total time of expiration is markedly reduced.

Air at a controlled velocity can be blown through the outer ear and the sound of the air passing through the eustachian tube can be recorded with a microphone placed in or near the front of the mouth

In eustachian tube trumpet tests the eustachian tube makes unique sounds, dependent upon strictures in the eustachian tube and their position as they relate to the point at which the air is introduced and where the acoustic sound is recorded in the mouth.

There are two different trumpet sounds. In one the high intensity area was located in the frequency spectrum approximately between 600 and 700 cycles. There was another high frequency energy area at something like 1200 cycles, and some minor ones up in frequency to about 4000 cycles.

The second had three very high intensity areas in the trumpet sound, one at about 1000 cycles, one at about 1400 cycles, and one at a very high frequency of about 3500 cycles.

In performing acoustic analysis and in the calculation of sizes of equivalent resonances, the points at which there are strictures or closures in the eustachian tube can be specified, aiding in possible surgical procedures, if indicated.

The spectrogram of a normal heart has two cycles: first, there is the first heart sound (systoli) and second heart sound (diastoli), and then the next complex. The normal heart sound pattern is a nice, clean, regular, rhythmic pattern, with even intensity lines that can be measured over a 48 decibel range. Further, there are significant heart sounds that exist higher than 2000 cycles. From the work we have done to date, particularly in the murmur cause area, we think that there are significant clues in frequencies produced in heart murmur cases which now are not presently being used.

In isolated valvular aortic stenosis, the first heart sound, the systoli, is mostly full of the murmur sound, and the second heart sound has two complexes. In isolated valvular pulmonic stenosis, the first heart sound, second heart sound, and a very severe murmur during systoli can be detected.

During two years of research, we have compiled recordings for twenty-five victims of isolated valvular aortic stenosis and twenty-five cases of isolated valvular pulmonic stenosis. These spectrograms were presented in a randomized array to high school girls, who had never seen a heart spectrogram before but had had training in identifying people's voices. They were shown a pattern which specified the uniqueness in the pattern display of aortic stenosis and one for pulmonic stenosis. At their first comparison attempt they compiled an 84% correct identification of valvular aortic stenosis and valvular pulmonic stenosis.

Quite often there is confusion in present methods of diagnosis of aortic or pulmonic stenosis and the diagnosis must be confirmed by catheterization. It is hoped that this tool may in some cases obviate the need for catheterization and confirm whether the murmur source is aortic or pulmonic in origin.

The contour type of spectrogram, which is a quantitized amplitude spectrogram, lends itself to computer programming which will be more importantly used in medicine and in diagnosis in the next few years, mainly as a tool to reduce the period of time that it requires to make a diagnosis.

Many times the popular press gives the impression that eventually doctors will be replaced by machines. Doctors are not going to be replaced by machines any more than anybody else in the scientific areas. The computer should be viewed as a valuable aiding tool. It will perform, with a certain amount of input information, a best-guess type answer, and that is all a computer can do. The best guess it provides is dependent on what has been programmed into it. What has been programmed into it is only that information which some programmer has supplied. In medical use a committee of doctors would provide the program information. The computer will aid in the rapid identification or diagnosis of malfunctions and it will use a small, quickly accessible file where case histories can be consulted. To sum up, computer techniques should be viewed as a means of aiding, speeding up, and guiding the processing information for the identification of particular types of malfunctions. In operation, the computer is programmed to count the contours in each of the illustrated indexed areas and recorded in its memory. When it gets an unknown heart sound, it can rapidly check its memory and screen the pattern display with those in storage and give a best guess diagnosis. The spectrograph in combination with the computer replaces nothing. Hopefully, it is an added tool to make the job of analysis and diagnosis more simple and quicker, allowing histories to be explored a little faster.

The spectrograph is a research tool which allows analysis of magnetically recorded taped material; recorded any place and processed any place. The spectrograph can be connected with a computer through telephone lines and an answer is possible to be achieved in a very short time. The signal on the tape is automatically analyzed by an analyzing drum and the spectrogram is automatically drawn, a number of different modes of display can be obtained by switching switches. An analysis can be produced in 80 seconds and the analysis of the visual patterns results in more sensitive and accurate results than those achieved by ear. The ear must use memory links, it is confined to rough estimates of time, frequency and intensity. Research continues to substantiate the usefulness of the spectrograph as an additional diagnostic tool.

DISCUSSION

DR. LYMAN G. RICHARDS: When Dr. Pressman first suggested that Mr. Kersta might be invited to come and address this audience, he sent me with his letter a brochure coming from the Voiceprint Laboratory in Somerville. I read that over and my first impression was, "This is hopeless. Nobody will understand a word this man says. There doesn't seem to be any application to laryngology." I couldn't have been more wrong.

It seems to me that Mr. Kersta has brought us a view of the future. This is an electronic age, computers are in the news all the time. I would venture to guess that this procedure is more and more going to be appropriate to laryngologists who are interested in people's voices, their changes, their improvements after surgery, and what may come of this nobody knows.

As a non-medical man, as a physicist and ideologist, Mr. Kersta has given an excellent presentation of a very technical subject which has, I think, and will have more and more, a future applicability to our work, and I am delighted to find how wrong I was in thinking that this subject would be so technical that most of us—at least myself—wouldn't understand it. I think that he has acceded to my request that he make it applicable to our work in a most commendable fashion.

DR. JOEL J. PRESSMAN: I sat and listened with fascination to every word that Dr. Kersta said.

The importance of this subject, as evidenced by the mass of material being published upon it in the professional and lay press, made it not simply desirable, but essential that the membership of this Association should be informed upon it, at least in a general way, and so far as we can understand it.

I would like to ask Dr. Kersta if he would answer one question that puzzles me. You have stated that courts of law have accepted your conclusions based upon this technique as proof positive of identity, and I know that this is so.

What do you present as data before a court of law to convince the judge and/or the jury that these analyses should be accepted as valid for the positive identification of an individual? Before you answer, may I express my very great personal appreciation for your having been kind enough to come here and give this fine description of your important work to us.

ELECTIVE CERVICAL ESOPHAGOSTOMY

G. SLAUGHTER FITZ-HUGH, M.D.

DONALD E. SLY, M.D.
(by invitation)

CHARLOTTESVILLE, VA.

Tubal alimentation is necessary to maintain adequate nutrition in many patients following head and neck surgery. This problem is also present in patients with mechanical obstruction secondary to unresectable or recurrent tumors of the upper air and food passages. Patients with neurological problems in which dysphagia is a prominent portion of their symptomatology, must also have their nutrition maintained by accessory methods, because of an inability to maintain an adequate oral intake. Prior to Klopp's¹ description of cervical esophagostomy in 1951, gastrostomy or an indwelling nasogastric tube comprised the only routine methods of long term tubal alimentation. In 1962, Ketcham² reported the use of cervical esophagostomy in 168 patients on the surgical service of the National Cancer Institute. This was the first report of the routine use of this type of tubal alimentation in a large series of patients. In 1962, Lockhart³ recorded the use of a cervical esophagostomy feeding tube and its application to more rapid vocal rehabilitation. A series of nine patients, in whom cervical esophagostomy was successfully used, was reported in 1964 by Woodburn et al.⁴ More recently, Weaver and Palmer⁵ reported the use of this type of tube in a small series of patients and reiterated its application to vocal rehabilitation as described by Lockhart. Ware⁶ and associates have recently presented an addition to the technique which could possibly be helpful in certain incidences. Skolnik⁷ has described a useful procedure similar to the one presented but with a somewhat different technique and indications.

Since July, 1964, cervical esophagostomy has been used as the preferred method of tubal alimentation, in those patients requiring this method of nutrition for more than one week on the otolaryngology service at the University of Virginia Hospital. This has also become a satisfactory method of maintaining nutrition for those patients on the neurology and medical services in whom dysphagia secondary to neurological dysfunction precludes adequate oral intake.

From the Department of Otolaryngology, University of Virginia Hospital, Charlottesville, Virginia.

REPORT OF CASES

TABLE I

CERVICAL ESOPHAGOSTOMY

<i>Number</i>	<i>Average Age yrs.</i>	<i>Sex ratio M to F</i>	DIAGNOSIS		<i>Complications</i>	
			<i>Carcinoma</i>	<i>Neurological Deficits</i>		
85	58	5 to 1	75	10	Laryngeal nerve paralysis (transient)	3
					Unintentional tube removal	2

The procedure of cervical esophagostomy has been performed on over 85 cases by the members of the Department of Otolaryngology (Table I). The information with regard to the 85 consecutive cases is included in this report. As one would anticipate in 75 patients of this group, the disability creating the necessity for this type of alimentation was due to carcinoma of the oral cavity and upper respiratory and digestive tracts. In the majority of cases, the procedure was carried out at the time of major head and neck surgery. It was also found to be useful in a few inoperable cases who were treated with chemotherapy and irradiation alone.

In the remaining 10 patients of the 85, a neurological deficit was responsible for need of this form of alimentation. This number though small now will, we predict, increase with time for obvious reasons; one being the increased familiarity of the internist and neurologist as to the advantages of cervical esophagostomy feeding. Of the ten patients with neuromuscular disorders, seven were cerebrovascular stroke victims, two suffered with amyotrophic lateral sclerosis and one had Huntington's chorea.

ADVANTAGES OF CERVICAL ESOPHAGOSTOMY

The advantages of cervical esophagostomy are manifold. The tube is not painful or unsightly and may be easily concealed beneath the patient's shirt. There is minimal drainage about the stoma and only the smallest dressing, if any, is necessary. Regurgitation of food materials or mucus around the tube with subsequent excoriation of the surrounding skin has not been a problem. The tube is easily changed after a period of five to six days. The patient or a member of his family may be instructed to perform this task. Additionally, the patient does not have to remove any clothing or assume the recumbent position in order to introduce feedings through the tube. If physically able, there is no need for assistance in self-feeding.

This procedure has the advantage of immediately feeding after insertion of the tube. A shorter operative period is required, when performed as a primary

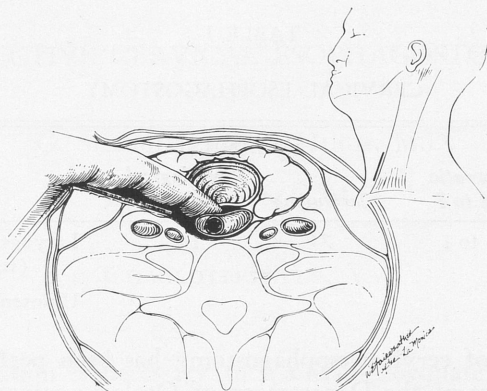


Fig. 1.—Locating endo-esophageal nasogastric tube.

procedure, and the peritoneum and intra-abdominal cavity do not have to be disturbed, as in gastrostomy. When performed in conjunction with radical head and neck surgery, the placement of the tube is within the operative area without additional exposure required. After removal of the tube, the fistulous tract closes over in a matter of hours with insignificant subsequent scarring.

The unsightliness and uncomfortable nature of an indwelling nasogastric tube is eliminated as well as obviating the physical presence of a tube approximating the mucosal suture line following laryngectomy. Problems associated with nasogastric tubes, such as posterior cricoiditis, aspiration and local irritation in the nose and nasopharynx are also eliminated. To our knowledge, there have been no serious complications with this procedure, and no patient's hospitalization has been prolonged because of morbidity attributable to this type of tubal alimentation.

TECHNIQUE

This procedure may be performed under general or local anesthesia. When done as a primary operation for feeding purposes because of neurological dysfunction or mechanical obstruction, tracheotomy is sometimes necessary at the same time.

Placement of the tube in the cervical esophagus is not difficult to perform, whether a part of a neck dissection or as a primary procedure. It is advantageous to have a nasogastric tube within the esophageal lumen prior to placement of the cervical esophagostomy as palpation of this affords immediate identification of the esophagus. This is obviously not necessary when associated laryngectomy is performed.

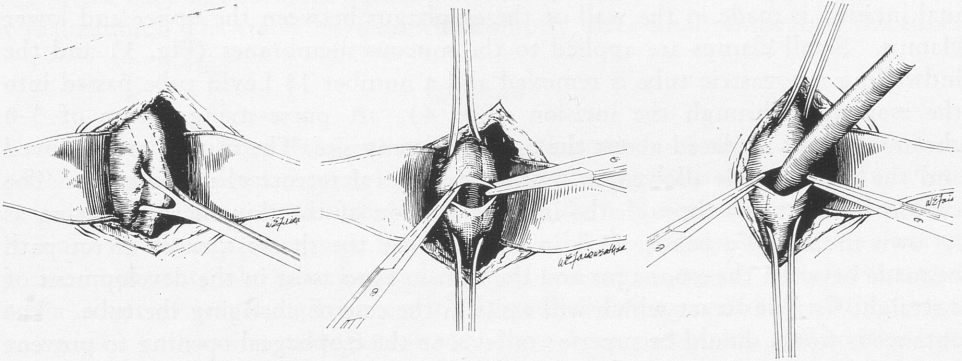


Fig. 2.—Babcock clamp on tube.

Fig. 3.—Incision into esophagus.

Fig. 4.—Insertion of cervical tube into esophagus.

When done primarily (without neck dissection) an incision is made parallel to the anterior border of the sternomastoid muscle beginning approximately a finger-breadth above the clavicle (Fig. 1). The tube is preferably placed in the left neck as the esophagus tends to lie more to the left of the midline in its cervical portion. We have placed the tube from the right side of the neck (31 times), but with some increased difficulty. At the time of neck dissection, the unoperated side of the neck is preferred for the site of the tube. Sharp dissection is used to identify the anterior border of the sternomastoid muscle which is retracted laterally. A small portion of the clavicular head of the muscle may be divided for exposure purposes, if necessary. Utilizing blunt dissection, the carotid sheath, its contents and adjacent structures are identified and retracted laterally. Dissection is carried through the areolar tissues, posteriorly, until the transverse process of the sixth or seventh vertebra is palpable. The trachea, thyroid and associated vessels lie anterior and medial to this area. The esophagus is palpable retrotracheally. With the finger, the indwelling nasogastric tube is easily located within the esophagus (Fig. 1). The recurrent laryngeal nerve, situated between the trachea and esophagus or more anteriorly, is sometimes identified, but more frequently is not seen. With blunt dissection, the nerve is displaced anteriorly with the trachea and soft tissue adjacent to the esophagus and is usually not harmed. Minimal freeing of the esophagus is performed. The lateral portion of the esophagus is bluntly freed from the trachea, anteriorly, and gently retracted laterally by means of palpation over the indwelling nasogastric tube. A Babcock clamp is placed about the endo-esophageal tube and it, with the esophagus, is retracted laterally (Fig. 2); thus affording excellent visualization of the lateral esophageal wall. Additional clamps are placed superiorly and inferiorly as diagrammed (Fig. 3) to aid in exposure of the area of the esophagus to be

incised, thus minimizing the likelihood of laryngeal nerve trauma. A longitudinal incision is made in the wall of the esophagus between the upper and lower clamps. Small clamps are applied to the mucous membranes (Fig. 3) and the indwelling nasogastric tube is removed and a number 18 Levin tube passed into the esophagus through the incision (Fig. 4). A purse-string suture of 3-0 chromic catgut is placed about the esophagostomy site. The clamps are removed and the esophagus is allowed to resume its natural retrotracheal position. The tube is brought out through the inferior portion of the skin incision, acting as its own drain. We believe it is important that the shortest, most direct path be made between the esophagus and the skin so as to assist in the development of a straight fistulous tract which will assist in the ease of changing the tube. The cutaneous stoma should be superior in level to the esophageal opening to prevent gravitational leakage of esophageal contents through the tract. The superior portion of the incision is closed in the usual manner leaving the lower portion open for drainage purposes.

When placing a cervical esophagostomy tube at the time of radical neck dissection, the unoperative side is preferred. This allows the utilization of surrounding musculature and soft tissue to envelope the tube and thus seal it off from the operative area and establish a more substantial tract. One should take care to avoid direct contact of the jugular vein and carotid artery with the tube. When used in conjunction with radical neck dissection the esophagostomy tube is brought out through a stab wound in the skin where it is sutured securely. It is important to adequately anchor the tube to the skin until the tract is well established; thus guarding against inadvertent removal of it by the patient or personnel not familiar with its use.

It is of prime importance that the nursing personnel and others associated with the patient's care be informed of the necessity of the immediate replacement of the esophagostomy tube should it be removed. The fistulous tract will close over in a matter of hours. Immediate replacement of the tube, regardless of the time of day, is mandatory.

COMPLICATIONS

Complications of this procedure have been surprisingly few. Three patients had transient vocal cord paralysis on the side of the operation. We suspect that more may have occurred, for in the earlier cases following oral surgery such an examination would have been inadvisable. There were no incidences of permanent paralysis. There were two cases in which the tube was accidentally removed within five days of the surgery and could not be reinserted. These two incidences were considered complications.

Tubes have been left in place for a matter of weeks and months without any evident difficulty. There have been no unusual skin or deeper infections. Kink-

ing of the tube has occurred occasionally. This was corrected under fluoroscope visualization. The tracts have healed promptly after final removal of the tube.

SUMMARY

Cervical esophagostomy is a most desirable method of tubal alimentation in patients with inadequate oral intake due to chronic neurological dysfunction or unresectable tumor within the region of and above the cricopharyngeus muscle. It is also of distinct advantage for routine use in the postoperative convalescent period in patients who have had radical head and neck surgery. The advantages as the result of actual experience with 85 consecutive cases of this method over nasogastric intubation and gastrostomy have been presented. Its routine use for tubal alimentation in the cases mentioned is recommended.

1400 JEFFERSON PARK AVE., CHARLOTTESVILLE, VA. 22903

Dr. Sly is at present on duty with the Armed Forces in Southeast Asia.

REFERENCES

1. Klopp, C. T.: Cervical Esophagostomy. *Jour. Thoracic Surgery* 21:490-491 (May) 1951.
2. Ketcham, A. S., and Smith, R.: Elective Esophagostomy. *Am. Jour. Surg.* 104:682-685 (Nov.) 1962.
3. Lockhart, H. B.: Surgical Rehabilitation of the Laryngectomized Patient. *Laryngoscope* 72:1585 (Nov.) 1962.
4. Woodburn, B. T., Hartwell, S. W., Jr., and Anderson, R.: Cervical Esophagostomy. *Cleveland Clinic Quarterly* 31:231-234 (Oct.) 1964.
5. Weaver, N. E., and Palmer, B. W.: Elective Cervical Esophagostomy. *Laryngoscope* 76: 91-98 (Jan.) 1966.
6. Ware, L., Garrett, W. S., Jr., and Pickrell, K.: Cervical Esophagostomy. *Ann. of Surg.* 165:142 (Jan.) 1967.
7. Skolnik, I. N., Tenta, L. T., and Massar, F. S.: Pharyngo-esophagostomy. *Arch. Otolaryngol.* 84:88 (Nov.) 1966.

USE OF THE TUBED PEDICLE FLAP IN HEAD AND NECK SURGERY

DELMAR F. WEAVER, M.D.

DETROIT, MICH.

The tubed pedicle flap is referred to in the literature also as the tubular, round, circular, Filatov, Gillies, Gillies-Filatov and Anglo-Russian flap.

Its chief value is that the raw surface of open flaps which tends to drain, granulate and develop scar contracture is eliminated by tubing. This allows for the easier transfer of one end of the tube to a defect. It also makes possible the transfer of skin and subcutaneous tissue from a distance.

In 1914 Vladimir Petrovich Filatov¹ began contemplating the development of such a tube and after testing the operation experimentally on rabbits, on September 9, 1916, performed the first tubed pedicled flap operation. Twenty days later one end of the tubed pedicle flap was lined with mucous membrane from the lip and finally it was used to reconstruct the lower eyelid. Six months later, in March, 1917, Ganzer¹ independently recommended the use of the tubed pedicle flap to the Laryngological Society of Berlin and in November of that year he reported its use to close a palatal defect. At this time Sir Harold Gillies¹ had already performed his first tubed pedicle operation, on October 3, 1917. In 1935 Gillies,² in speaking of the tubed pedicle flap, wrote "It was first described by Filatov in 1917 but the idea occurred to me quite independently in the same year." Its immense usefulness was immediately recognized and its popularity grew extensively.

Two to three weeks after the tube is formed, if there have been no complications, one end is ready for transfer. If it is planned so it will reach the defect, this can be covered. If the distance is too great for this it is attached at an intermediate point. Often one such step is sufficient but, on occasion, it may be moved a number of times, as in the procedure reported by Havens³ in which he moved a small tube from the submental region to a nasal columella defect with about six steps in a zig-zag line. The circulation in it is, of course, reversed each time this is done.

After the flap has remained attached to the defect for three to four weeks the tube can be divided at the margin of the defect and discarded or otherwise used according to the circumstances.

Shaping up procedures may be necessary later. If excess fat remains after six or more months it can be removed through one of the healed edges. Injury to the subdermal plexus of blood vessels should be avoided.

These tubes, with or without an untubed flap, have been used to repair defects in practically every area of the body.

FORMATION OF THE TUBE

Thorough evaluation of the defect is necessary so that the reconstruction can be planned in all its stages. Adhesive tape, thin lead sheeting and similar materials are useful as patterns. For repair of nasal losses and other moderate sized losses of the face, the clavicular flaps, as recommended by New and Erich,⁴ are best (Fig. 1). If the cervical tube is used the transfer can usually be made without the intermediate stage but scarring in that area is conspicuous. If more tissue is needed or if the supraclavicular regions are scarred, a thoracic tubed pedicle can be used. The acromiopectoral tube is useful for repairs in the neck also (Fig. 2). The thoraco-epigastric tube described by Webster⁵ is another choice. The tube formed on the back is least satisfactory of all and it has been suggested by Conway⁶ that for this tube the 3:1 ratio between the length and the width, which is standard for most tubes, is not safe and a 2:1 ratio is recommended. Maltz⁷ introduced the tubed graft with the raw surface outside and the epithelium enclosed. This was to prevent curling and also to prevent the necessity for making incisions in order to flatten it out later.

The donor area is marked with skin pencil or methylene blue and parallel incisions are made through the skin and subcutaneous tissue to the deep or muscle fascia. The flap is elevated, leaving both ends attached, and after the bleeding is thoroughly controlled it is tubed by suturing both edges together so that the subcutaneous tissue is enclosed in an epithelial covered tube. The sutures close the tube toward both ends until tension becomes great enough to discontinue. This leaves a triangular shaped flap at each end. The donor area is then undermined and closed using several retention sutures of heavy silk and medium silk for the edges. Gentle handling with skin hooks is essential throughout.

Davis and Kitlowski⁸ recommended staggered incisions to facilitate closure of both the tube and the donor area and Gabarro⁹ recommended curved incisions for somewhat the same purpose (Fig. 3). Macomber and Patton¹⁰ recommended covering the donor area with a free graft and Sanders and Lynn¹¹ suggested that the sutures of the free graft be left long and tied over mechanics waste. In those cases requiring a graft to close the donor area, New and Erich⁴ preferred to raise the flap, apply a free split skin graft to the donor area and resuture the flap in its bed over the graft. Ten to fourteen days later the flap is tubed. In the applica-

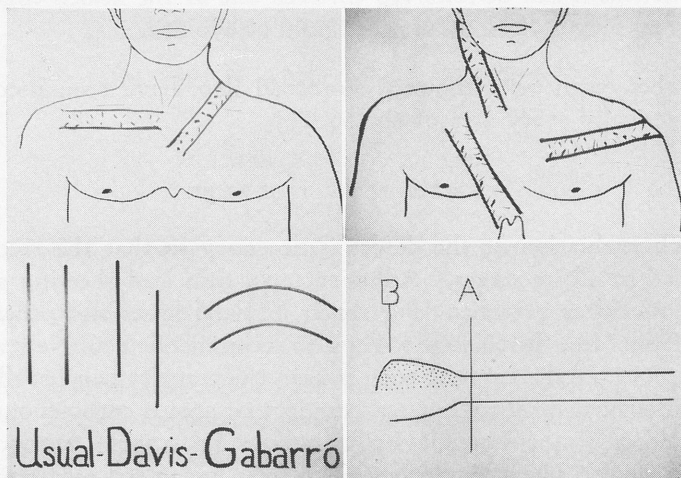


Fig. 1.—Clavicular tubed flaps.

Fig. 2.—Cervical, thoracic and acromio-pectoral tubed flaps.

Fig. 3.—Incisions for elevating and tubing flaps.

Fig. 4.—May separate at "A" in one stage at times. "B" shows partial excision and elevation of stippled area.

tion of dressings it is, of course, essential that none be allowed to cause pressure on the tube.

The causes of failure at this stage are development of a hematoma in the tube, exceeding the 3:1 ratio of length to width, rough handling predisposing to infection, accidental pressure on the tube and unrecognized previous irradiation of the donor area.

In 1933 German, Finesilver and Davis,¹² using double tubed flaps on the abdomens of dogs, found that immediately after tubing a flap blood vessels cross it at right angles but none run parallel to the long axis. At the end of one day a few vessels run almost the entire length of the tube. These were more numerous on the fourth day and by the seventh day there was a well developed blood supply. There was an increase in both the size of the vessels and the number of functioning vessels with re-orientation corresponding to the long axis of the tube. There was little change from the eleventh to the fourteenth day. Although, in the absence of complications, one end of the tube can usually be transferred in two to three weeks, the blood supply becomes more stable if left several weeks longer. If for such reasons as occupation or school attendance it is more

convenient to postpone the next step, the tube can be left intact indefinitely with no disadvantage. Some have been left as long as a year.

If one wishes to have a tube longer than the 3:1 ratio this can be done by the "jump" method described by de River¹³ which consists of leaving a bridge of untubed skin to be tubed later. A healed tube can also be lengthened by extending the parallel incisions the desired distance, undermining between them, resuturing in the original bed and tubing later.

TRANSFER

The technique of transfer of one end of the tubed flap depends on the requirements of the defect to be covered and whether or not an intermediate attachment is necessary because the tube will not reach the defect. In the latter case I usually cut through the proper end in two stages. However, if the blood supply is well stabilized and the incision is through the actual tube, which has a longitudinal blood supply, it may be safe to separate it completely at once. If the untubed triangular flap extending from the tube is to be used, the separation should definitely be carried out in stages.

This is done by first incising approximately one half of it, resuturing this, and a week or ten days later completely excising and transferring it (Fig. 4). The location of the intermediate attachment is determined by testing with the excised end of the flap. A semicircular incision is made in the determined location and the skin and subcutaneous tissue dissected free and turned, so a circular recipient area is formed which will fit the free end of the tubed flap. The subcutaneous tissue and fat are brought together with interrupted catgut sutures and the skin edges with fine silk. A small dressing simply covers the fresh wound. Millard¹⁴ prefers the "pocket" method of attachment at this stage. He shaves the epithelium off the proper end of the tubed flap and buries it through a transverse incision. He says the blood supply, fixation and mobility are better and there is minimal scarring.

When the proper end of the tube, after separation in stages, will reach the defect without intermediate attachment, the scar may be dissected from the defect, the skin edges freshened properly and the end of the tube or flap attached. As a rule, the tube may be excised at the margin of the defect in three weeks and discarded unless it is to be opened or otherwise used. I usually do this in two stages.

If the defect involves a cavity requiring an epithelial lining the problem is somewhat more involved. If it is small enough the lining may be formed simply by turning in the margins. At times the epithelial covered flaps used for this may be delayed for safety. The term delay, of course, meaning to assure the blood supply by incising, undermining and resuturing in the original location.

The lining may be formed by turning in the skin adjacent to the donor end of the tubed flap a week or so before final transfer. It may be formed by attaching one end of the tube to a margin of the defect, in several weeks folding the tube and attaching the second end near the first. The defect will be closed later by uniting the adjacent surfaces of the folded tube and still later the edges of the defect to the adjacent surface of the folded tube.

In some defects the lining can be formed at the time the tube is excised at the margin of the defect by leaving sufficient tissue to turn in as a lining.

The method I have used most often is lining the donor end of the flap with a split thickness skin graft ten to twelve days before transfer (Fig. 6). When this is done I will usually cut completely through the donor end in two stages before transferring it. Macomber and Berkeley¹⁵ recommended further delay if the flap is to be larger than 4 x 7 cm.

The chances of complications developing at the stage of final transfer to the defect are as great or greater than at any other stage.

Although the tubed pedicle flap is quite flexible and freely movable, any undue twisting, kinking or stretching will interfere with the arterial supply and may cause necrosis. If the blood supply in the recipient area is poor from irradiation or other reasons, healthy attachment may be somewhat jeopardized. If the graft is attached to a relatively small surface compared to the weight of the tube, the attachment may become ischemic. This should be observed closely and, if necessary, some means used to correct the problem. If the tube or flap remains ischemic and is not replaced in its former position, vesication may develop about the third day and necrosis will follow.

In certain situations, gravity alone may be responsible for venous congestion in the flap, in which case it becomes blue. While some tendency to bluish tint is common, if it is marked or sustained, it may result in necrosis.

Hynes¹⁶ says in mild cases simply raising and lowering the end of the flap every ten or fifteen minutes will suffice. For more severe cases he has developed an instrument with a rubber bag similar to a sphygmomanometer cuff for alternately raising and lowering pressure in the graft. He says it will help even if necrosis has already started.

Since the nerve supply in newly formed pedicle flaps is usually interfered with, care must be taken to protect the flap from injury. This is especially true of flaps applied to weight-bearing areas. Davis and Kitlowski¹⁷ found the nerve regeneration rate in tubed flaps of average size to be about one cm per month.

Since the early 1940's efforts have been made by several investigators to determine, by measurable tests, the adequacy of the blood supply of a tubed

pedicle flap. It has been felt that much time can be saved if this is definitely known, since often transfers are unnecessarily delayed. While a detailed discussion of these tests is beyond the realm of this paper, a brief bibliographical summary of what has been done may be of interest. Douglas and Bucholz¹⁸ found the temperature return test useful in 1943. Douglas and Millikan¹⁹ described the oximeter test for this purpose in 1947 and stated that predictions of successful transfers are highly reliable. Hynes²⁰ described the atropine absorption test in 1948. He and MacGregor²¹ later discussed the relative value of that test and the fluorescein test and expressed preference for the atropine absorption test because of its simplicity. Conway and associates²²⁻²⁴ have written several articles on the subject and in 1952, after reviewing the subject thoroughly, concluded that the histamine wheal test was the most practical of the available tests. They considered it a reliable guide to the efficiency of the circulation in pedicles of soft tissue. Furthermore, it can be executed in a few moments without elaborate equipment.

In 1961 Winsten, Manalo and Barsky²⁵ reported the use of skin temperature as index of circulation and concluded that it is a useful investigative tool, but too imprecise to be used as a substitute for the surgeon's judgment or time proven empiric formulas in the moving of flaps.

In 1964 Sturman²⁶ found that intravenous heparin and locally applied hypothermia tended to prevent loss of tissue in tubed pedicles in rabbits.

This type of experimental work is certainly interesting, progressive and commendable. The results are helpful to surgeons in this field and especially those most familiar with the details of the tests.

However, for the most part, the average surgeon must still rely on other factors in successfully transferring tubed flaps. It is important to know the usual behavior of the circulation in these flaps. Familiarity with the usual time limits for transfer is essential. One should recognize complications which require postponement, such as incomplete healing, cyanosis of the suture line of the tube, hematoma or infection. Observation of the presence or absence of free bleeding from the freshly incised flap and a healthy or unhealthy color during the handling and positioning of the flap is helpful.

It seems to me that except in situations when major arteries are exposed, there is usually no hurry in these transfers. These operations are relatively uncommon except in war time and are usually done for a major problem. A delay of a week or two here and there seems of relatively little importance in the long run.

SCALP

In 1938 Cahill and Caulfield²⁷ discussed the use of tubed pedicle flaps of skin in the repair of avulsion of the scalp and reported a case using two tubed

flaps from the back. They thought that free split skin grafts were not satisfactory for this repair because of the need to protect the cranium and pericranium with thicker grafts. Straith and McEvitt²⁸ later reported use of free split thickness grafts with success.

EAR

Cahill and Caulfield²⁷ also reconstructed the right ear on the same patient with the tubed flap and a number of others have reported the use of tubed flaps of skin in the construction of an entire ear or the helix. Straith,²⁹ New and Devine,³⁰ Lewin,³¹ Steffanoff³² and Smith³³ are prominent among these.

NOSE

There is a difference of opinion regarding the use of the tubed pedicle flap in the repair of defects of the nose. At the Dallas meeting of the American Laryngological Association in 1962, during a brief discussion of a paper by Converse and Smith³⁴ on carcinoma of the nose, the statement was made that there are times when the excisional scar on the forehead justifies the use of a tubed pedicle flap. It was suggested that it should be considered in these cases. Converse³⁴ replied that "despite the objection of the secondary deformity, in the hands of those of us who are experienced, the forehead flap remains the method of choice." This opinion was based on tragedies he had seen from all over the world, connected with failures of this procedure. He mentioned particularly flaps from the abdomen and arm.

Escoffier³⁵ listed the advantages of the forehead flap and offered answers for the objections. He said the scar is often inconspicuous and usually well accepted if repair is satisfactory. Farina³⁶ expressed similar opinions regarding it.

Blocksma and Innis³⁷ discussed 30 cases of amputated noses reconstructed in Pakistan with forehead flaps or tubed pedicles from the arm and other areas as the infraclavicular. In their opinion the forehead flap provided the simplest, most rapid method of repair with the best cosmetic result. They said in these dark skinned people the increase in pigmentation with the tubed flaps is a major problem. Farrior³⁸ suggested that the tubed pedicle graft is usually unnecessary in the mid-face.

On the other hand, in 1958 and again in 1963, Erich,^{39,40} who has had extensive experience in all methods of repair, expressed his preference for the tubed pedicle flap from the clavicular region or thorax because the scar in the donor area can be covered with clothing. He uses the forehead flap in only those patients who are not concerned about scarring of the forehead, who want the reconstruction done as quickly as possible and who have a scarred or hairy chest.

During the twenties, thirties and forties reports of satisfactory results, following repair of nasal losses with the tubed pedicle flap, were published by

Straatsma,⁴¹ Straith,⁴²⁻⁴⁴ Havens,³ Ivy,⁴⁵ Young,⁴⁶ Steiss⁴⁷ and others. Among similar reports during the past 15 years are those of Crawford,⁴⁸ Pierce, Klablunde and Shadish,⁴⁹ Erich⁴⁰ and Weaver.⁵⁰

As is well known, use of the forehead flap for repair of nasal defects has been practiced for hundreds of years. In the hands of modern surgeons the nasal results are excellent. However, some scarring of the forehead is inevitable and even though it may be slight in some cases, it is conspicuous in others. While the smaller defects can be closed without a skin graft, when a graft is necessary, it is conspicuous as a rule. Gillies⁵¹ once said that if a free graft is needed to cover any part of the forehead the appearance is usually better if the entire forehead is covered with it.

While forehead scarring may be of little concern to some older men and to women who can cover it with hair, it may be unacceptable to young men and to women whose hair is not suitable for this. In spite of this scarring though, the forehead flap is often the method of choice.

It does seem, however, that the place of the tubed pedicle flap in nasal repair is sufficiently well established so that it should be considered among the other methods when planning such repairs. If this is done with open-minded discrimination, often soliciting the patient's help in the decision, it is likely that it will frequently be chosen. When the forehead is already scarred or when precancerous or cancerous lesions are present on it, use of the tubed pedicle flap may prove to be the only suitable method available if reconstruction of the nose is to be carried out at all.

SINUSES

There are relatively few reports in the literature of reconstruction, by any method, of defects resulting from the treatment of cancer of the sinuses. This can be explained to some extent by the relatively infrequent occurrence of such cancers, the high mortality rate and the fact that following resection of the maxilla there is no such defect except in the orbital region. This is often left open for better observation. The following, however, are examples of such reports:

In 1931 Ohngren⁵² reported the use of tubed pedicle flaps from the neck and chest for the repair of large postoperative defects of this nature.

In 1934 New, Figi and Havens⁵³ used a tubed pedicle flap from the back to cover a defect of the forehead extending into the frontal sinuses from previous removal of fibrosarcoma.

In the same year Beck and Guttman⁵⁴ reported closure of a large defect of the cheek following electrocoagulation for cancer of the antrum with a tubed

pedicle flap from the neck and chest. They folded in a flap of skin adjacent to the chest end for the lining.

In 1938 Figi⁵⁵ reported the repair of two similar defects with thoracic tubed flaps.

An unusual use for the tubed flap in this region is that reported by Neumann⁵⁶ who prepared a large tubed flap on the chest and abdomen and attached it to the wrist immediately. At a later stage he removed the epithelium from the tube and after elevating the skin over the face, transplanted the tubed flap under it to correct a case of progressive facial hemiatrophy.

PALATE

In 1933 Smyrnoff⁵⁷ reported the use of tubed flaps from the arm and shoulder in the repair of palatal defects.

Masson and Bowen⁵⁸ closed a large palatal cleft by preparing an acromipectoral tubed flap and first migrating it to the upper end of the neck. The pectoral end was then brought beneath the mandible near the angle and through the floor of the mouth. This end had been lined with a split thickness graft. Speech was decidedly improved.

Evans and Walker⁵⁹ used a small cervical tube for the repair of the nasal columella and a larger arm tubed flap for repair of a palatal defect in the same patient.

LIPS AND CHEEKS

The tubed pedicle flap has been used many times for the repair of defects involving the lip and adjacent cheek. New and Havens⁶⁰ and Straith⁶¹ were among those reporting this type of case.

In 1945 I replaced much of the lower lip with a lined tubed flap from the chest. The defect was a result of treatment for advanced cancer of the lip which involved the mandible.

CHIN

Erich⁶² used a tubed clavicular flap to repair the lower jaw following destruction for adamantinoma. An intra-oral prosthesis was used in conjunction. Dingman and Natvig⁶³ reported reconstruction of a somewhat similar loss of the chin, floor of mouth and submandibular area following a gunshot injury. They used a tubed pedicle flap based on the neck.

NECK

Extensive losses of the skin of the neck, especially if much subcutaneous tissue is involved, may best be repaired by use of the tubed pedicle flap.

In 1932 Moorehead⁶⁴ repaired such a defect in the submaxillary region with a previously prepared tubed pedicle graft from the right chest and soon afterwards Mixter⁶⁵ used a tube from the chest for the repair of the neck of a child after removing contracted burn scars.

Wilmoth⁶⁶ used an acromiopectoral flap to repair an x-ray burn of the submaxillary region and in 1943 Figi, New and Dix⁶⁷ discussed the treatment of radiodermatitis and reported use of the tubed pedicle flap in certain cases.

Use of the tubed pedicle flap for repair of pharyngo-esophageal defects, when other methods are not suitable, is one reason for presenting this paper.

A brief review of other methods follows:

Hardin⁶⁸ recommended a lined and delayed arm flap for this purpose. Tallent⁶⁹ used a bipediced, hair-bearing scalp flap to repair a stoma following laryngopharyngectomy.

Bakamjian⁷⁰ reported the use of large flat flaps from the neck for this purpose. Some of the defects were repaired at the time of primary surgery and some later.

Ogura et al.⁷¹ reported the use of large bilateral non-delayed regional flaps on three cases with success. The indications are anticipated loss from surgery upon large carcinomatous fistulae when skin and mucosa are not otherwise available and when there is postoperative development of a similar defect.

Bakamjian⁷² reported use of a two stage method of reconstruction consisting of rotating an oblong rectangular flap from the pectoral region into the neck at the time of primary surgery. It was sutured to the oropharynx. Three to five weeks later the operation was completed. Incisions in the neck for the primary operation were transverse.

LeQuessne and Ranger⁷³ reported use of the operation of anastomosing the fundus of the stomach to the pharynx above the level of the hyoid bone at the time of pharyngolaryngectomy. Nine of thirteen such patients swallowed well within two weeks with no fistulae. Those dying of recurrence swallowed until death.

When one or the other of the above or similar methods are not suitable for any reason, the only choice is use of the tubed pedicle flap.

The tube may be used alone or in conjunction with either another tube or another method.

Since 1933 a number of excellent reports describing these procedures have been published. Among them are those by Gillies and McIndoe,⁷⁴ Catlin,⁷⁵ Phillips,⁷⁶ Erdelyi,⁷⁷ Cowan and McDougall,⁷⁸ Devine and Kragh,⁷⁹ Glaninger,⁸⁰

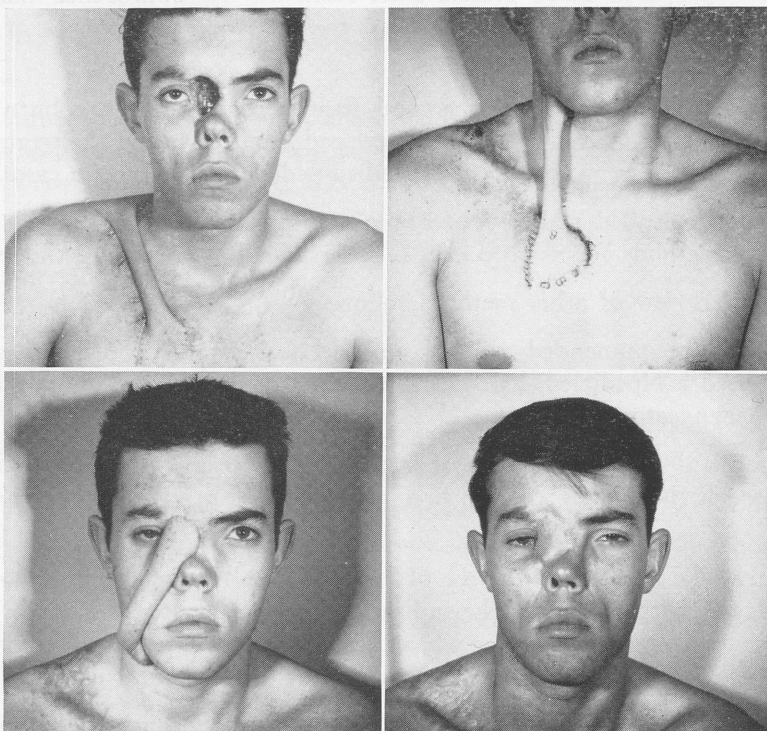


Fig. 5.—Defect from chondrosarcoma. Tubed pedicle graft.

Fig. 6.—Lower end of tubed flap lined with free skin graft.

Fig. 7.—Lined graft transferred to defect.

Fig. 8.—Seven years after diagnosis of chondrosarcoma.

Farina,⁸¹ Gaisford and Hanna⁸² and Khitrov.⁸³ The tubes were formed in the clavicular, thoracic or shoulder regions as a rule. There were three general methods of repair reported. The surrounding skin was turned in as a lining and the tubed flap used to cover the resulting defect. Two tubed flaps were formed and later attached to the defect side by side, or a single tube was attached and, if necessary, it was folded on itself to give the same effect. The adjacent surfaces of the tubes were closed later and at some time the edge of the defect was attached to the surface of the tube adjacent to it.⁷⁹

Khitrov⁸³ used a "T"-shaped pedicle flap for this purpose and Farina⁸¹ used a prefabricated neopharynx combining a Maltz tube with other tubes. This reached directly to the oropharynx.

Bricker, Burford and Eisman⁸⁴ repaired an upper esophageal defect using a thoracic flap tubed with the epithelium inside. They approached the defect through the thorax.

Gaisford and Hanna⁸² also repaired an esophageal defect resulting from tracheo-esophageal fistula with a tubed pedicle. The patient was a child.

Although well beyond the realm of this paper, the following publications are thought worthy of mention:

Bergman, Howard and Barnes⁸⁵ published an excellent article on reconstruction of the penis with the tubed pedicle graft. They stated that although the primary need is for prevention of soiling during urination, sexual functions may be restored.

Moran⁸⁶ and others formed a tubed graft of skin and subcutaneous tissue on the chests of dogs. They later attached one end to the myocardium and demonstrated free anastomosis between the coronary arteries and the blood vessels of the graft. This helped maintain cardiac function after ligation of the descending branch of the left coronary artery.

An attempt is made to emphasize some of the above principles in the following case discussions.

REPORT OF CASES

CASE 1. A 14-year-old boy was seen first in October 1959 with a chondrosarcoma extensively involving the right nasal cavity, the right maxillary sinus and both ethmoid and frontal sinuses. There was partial destruction of the right nasal bone and nasal process of the superior maxilla. The posterior plate of the frontal sinus and the bone in the cribriform plate region were destroyed. The frontal lobe of the brain was displaced posteriorly by the tumor.

Widespread electrocoagulation destroyed all of the tumor except that displacing the frontal lobe. 2,760 mg-hr of radium were given over this.

Six months later another 2,700 mg-hr of radium were given in the same location since x-ray examinations indicated the tumor was progressing.

A neurosurgical consultant advised that the defect, following removal of the residual tumor, would be too great to allow it.

However, arrest of the tumor followed and a large defect in the right cheek and nasal region resulted (Fig. 5). In spite of the extent of the tumor the eye and orbital contents were saved.

In June of 1963, almost four years after the diagnosis was made, reconstruction of the defect was begun.

A flap of skin measuring 6.5 x 19.5 cm extending over the clavicle from the supraclavicular region to the upper thorax was tubed (Fig. 5).

For a variety of reasons, the next step was not carried out for several months. At this time, the upper end of the tubed flap was transferred to the upper neck in the submaxillary region. This had been delayed by cutting it partially across and resuturing ten days previously. About four weeks later the lower end of the tubed flap was lined with a free split thickness skin graft from the lower chest. The graft was held in place with silk sutures. The lateral edges were included in the sutures which closed the skin incisions and the other edges were held with silk sutures tied externally over small cotton rolls (Fig. 6).

Ten days later the lined flap was cut half across and in another ten days it was cut completely across. In another week it was brought up and the defect covered after properly preparing its edges (Fig. 7).

Four weeks later, following one delay, the unused part of the tube was excised and discarded and the defects closed.

Six months later a previously prepared silicone implant was inserted into the dorsum of the nose.

At present, over seven years after the diagnosis of chondrosarcoma was made, the patient is a junior in college, majoring in oceanography, and participates actively in touch football, basketball and volleyball. He is apparently well adjusted in every way (Fig. 8).

CASE 2. A 35-year-old man was referred to me on April 21, 1964 by an otolaryngologist who had recently operated on his right maxillary antrum through a Caldwell-Luc approach. When I removed the pack from the right antrum a tumor about 2 cm in diameter could be seen in the ethmoid region. Pathological diagnosis was transitional cell carcinoma.

Over a period of six weeks cobalt treatment was carried out at the rate of five treatments per week delivering a total of approximately 6,000 r in depth to the right maxillary, ethmoid and frontal sinuses. The eye was shielded.

At the conclusion of the treatment, on June 11, 1964, a right external fronto-ethmosphenoidectomy was carried out. Much of the medial wall of the maxillary antrum was removed. Electrocoagulation was rather thoroughly carried out in those areas where it was thought advisable.

Although primary healing of the fronto-ethmoid incision followed, it broke down later and a major fistula into the nasal cavity developed.

On July 6, 1965, 13 months after the original operation, a skin flap measuring 6 x 18 cm was elevated and tubed. It extended over the right clavicle from the supraclavicular region to the chest.

About five weeks later, on August 16, 1965, the upper end of the tubed graft was cut half across and resutured. Ten days after this delay this end was transferred to the right submaxillary region.

Due to circumstances having nothing to do with the case, the next step was not begun until October 15, 1965, at which time the lower end of the tubed flap was lined with a free split thickness skin graft. The graft was fixed with silk sutures, some of which were tied over small cotton rolls as in Case 1, Figure 6.

Ten days later the lined pedicled flap was cut partially across and resutured and a week later the unexcised part was cut completely across and resutured.

At the end of another week the lined pedicled flap was transferred to the properly prepared defect. It was necessary to trim the excess tissue from each side of the pedicled flap. Healing was uneventful. In about a month the unused part of the tube was excised and discarded after one delay. The defects were closed.

At the present time, three years after diagnosis and one and a half years after reconstruction of the defect, the patient is in excellent condition.

CASE 3. A 52-year-old colored man had a right hemimaxillectomy with exenteration of the orbit by Dr. Jan Beekhuis in September 1962. The resulting defect gave him enough concern so that two years later, in 1964, it was closed with a tubed pedicle flap from the right clavicular region.

A lined flap similar to that used in Cases 1 and 2 was used to cover the defect. Although poor healing after transfer caused some delay, the defect was completely closed and the result was quite satisfactory.

In October 1966 he was admitted to the Detroit General Hospital in a comatose condition. He died following an arteriogram. Post-mortem examination showed no evidence of carcinoma to the base of the skull or brain.

CASE 4. A 42-year-old woman was first seen in July of 1960. She had had much treatment for multiple basal cell epitheliomata of the face and hand. She had had x-ray treatment for cancer of the nose as early as the 1940's and had had cancer removed from the right alar region with plastic reconstruction by means of a pedicled flap from the right cheek.

On examination, there was found to be extensive involvement of the reconstructed right alar region and side of the nose and more superficial involvement of the left side of the nose by cancer. There was a tumor on the right forearm that proved to be a low grade squamous cell epithelioma.

Many years before, she had been employed as a dental technician and had apparently over-exposed her face, right arm, hands and, as will be seen, probably the right supraclavicular region.

On August 4, 1960 the involved skin over the left side of the nose was removed and since the underlying tissues were free of tumor, the defect was



Fig. 9.—Defect following removal of carcinoma of nose.
Fig. 10.—Following repair with tubed pedicle graft.

covered with a free skin graft from the postauricular region combined with an adjacent cheek flap.

The cancer was removed from the right side of the nose with the electric cautery, leaving a large defect (Fig. 9). The lesion on the arm was excised and the wound sutured.

Fifteen months later, since there was no evidence of recurrence of tumor, nasal reconstruction was begun by elevating and tubing a clavicular flap. The flap was 6.5 x 18 cm, well within the 3:1 ratio of length and width, but it became ischemic in the center later, vesiculation appeared on about the fourth day and central necrosis developed. I now believe that the supraclavicular region had been sufficiently irradiated to reduce the blood supply dangerously.

The longest section of the tube was lengthened and the reconstruction completed by advancing it toward the nose with a series of steps in a zig-zag line. Most of these procedures were carried out in my office (Fig. 10).

In May of 1966 she developed a new squamous cell carcinoma on the left half of the lower lip which was excised.

Otherwise, she is in excellent condition seven years after she was first seen.

CASE 5. A 50-year-old white woman was first seen on January 14, 1964. She had noticed a swelling in the left side of the neck two months previously. On examination, one of the lymph nodes of the left superior deep cervical group was found to be firm and about three to four cm in diameter. On further examination, an ulcerated carcinoma was seen to extensively infiltrate the left tonsil and posterior pharyngeal wall. It extended almost to the midline.

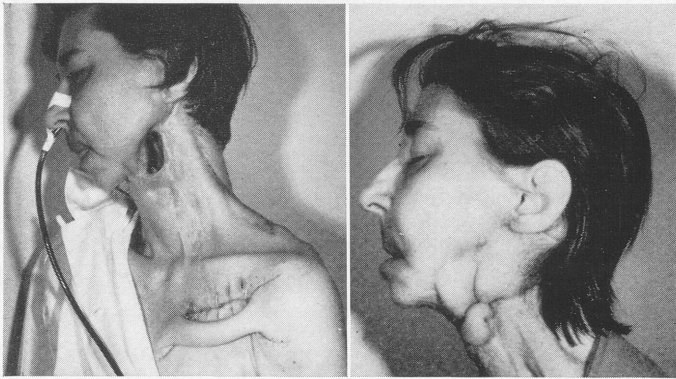


Fig. 11.—Large pharyngeal fistula. The base of tongue and epiglottis shown.
 Fig. 12.—Pharyngeal fistula closed.

Cobalt teletherapy was given over a period of six weeks. The dose was approximately 6,000 r.

On March 16, 1964, about two weeks after completion of the irradiation, a left radical neck dissection was carried out. No evidence of malignancy was found in any of the lymph nodes.

The wound healed well enough so that there was no leak of food or saliva after several weeks. Six months later, however, necrosis of tissue resulted in a large pharyngeal opening (Fig. 11). Its borders were the mandible above, the pyriform sinus below, the larynx and base of tongue anteriorly and the common and internal carotid arteries posteriorly. The vessels were barely covered by skin.

The left greater cornu of the hyoid bone was removed in the office as a sequestrum. The necrotic hypoglossal nerve was also removed.

Attempts at closure with surrounding tissue, as well as an occipital flap, were futile, especially since it was thought best to close it without exposing the carotid arteries.

On April 26, 1965 a skin flap 6 x 18 cm was elevated transversely just below the left clavicle. This extended to the shoulder (Fig. 11). The medial end of this flap was later lined with a free skin graft and after the necessary delays and transfers it was combined with a flat flap based in the occipital region and they were transferred to the defect. The lining for the occipital flap was obtained by turning the skin from behind the carotid arteries forward without uncovering the arteries. A small tubed flap from the anterior neck was also

brought up later before getting a complete closure (Fig. 12). Although the result was quite satisfactory, a large number of minor procedures were required. Most of these, however, were carried out in my office.

Most of the reports in the literature deal with fistulae following laryngopharyngectomy.

It is felt that closure of large pharyngeal defects may be more difficult when the larynx is intact than following laryngopharyngectomy.

In the latter situation the mobility of the soft tissue facilitates reconstruction while, when the larynx is intact, the full force of the act of swallowing is a deterrent.

571 FISHER BLDG., DETROIT, MICH. 48202

REFERENCES

1. Barsky, A. J.: Filatov and the Tubed Pedicle. *Plast. Reconstr. Surg.* 24:456-462 (Nov.) 1959.
2. Gillies, Sir Harold: Experiences With the Tubed Pedicle Flaps. *Surg., Gynec. and Obst.* 60:291-303 No. 2A (Feb.) 1935.
3. Havens, Fred Z.: Reconstruction of the Columella Nasi. *Surg. Clin. N. A.* 877-879 (Aug.) 1945.
4. New, G. B., and Erich, J. B.: Pedicle Flaps in Plastic Surgery of the Head and Neck. Chas. Thomas, Pub., 1950.
5. Webster, Jerome: Thoraco-Epigastric Tubed Pedicles. *Surg. Clin. N. A.* 17:145-184 (Feb.) 1937.
6. Conway, H., Stark, R. B., and Nieto-Cano: Arterial Vascularization of Pedicles. *Plast. Reconstr. Surg.* 12:348-363 (Nov.) 1953.
7. Maltz, Maxwell: New Method of Tubed Pedicle Skin Grafting. *Amer. Jour. Surg.* 43: 216-222 (Jan.-Mar.) 1939.
8. Davis, J. S., and Kitlowski, E. A.: Method of Tubed Flap Formation. *South. Med. Jour.* 29:1169-1174 (Dec.) 1936.
9. Gabarro, P.: New Design for Raising Tubed Pedicle Flap. *Surg.* 18:732-741 (Dec.) 1945.
10. Macomber, W. B., and Patton, H. S.: Split Thickness Graft - Useful Adjunct in Tube Pedicle Preparation. *Surg., Gynec. and Obst.* 84:97-100 (Jan.) 1947.
11. Sanders, G. B., and Lynn, R. B.: Graft Fixation Beneath Tubed Pedicle Flaps. *Amer. Jour. Surg.* 73:700-702 (June) 1947.
12. German, W., Finesilver, E. M., and Davis, J. S.: Establishment of Circulation in Tubed Skin Flaps (and an Experimental Study). *Arch. Surg.* 26:27-40 (Jan.) 1933.
13. de River, J. P.: Jump Method or Interrupted Tube Flaps. *J.A.M.A.* 87:662-663 (Aug. 28) 1926.
14. Millard, D. R., Jr.: Pocket Attachment for Pedicles. *Plast. Reconstr. Surg.* 16:465-471 (Dec.) 1955.

15. Macomber, W. B., and Berkeley, W. T.: Use of Neck Tubed Pedicles in Reconstruction of Defects. *Plast. Reconstr. Surg.* 2:585-596 (Nov.) 1947.
16. Hynes, W.: "Blue Flap" Method of Treatment. *Brit. Jour. Plast. Surg.* 4:166-172 (Oct.) 1951.
17. Davis, J. S., and Kitlowski, E. A.: General Sensations in Pedunculated Flaps of Skin. *Arch. Surg.* 29:982-1000 (Dec.) 1934.
18. Douglas, B., and Bucholz, R. R.: Blood Circulation in Pedicle Flaps; Accurate Test (Temperature-Return Test) for Determining Its Efficiency. *Ann. Surg.* 117:692-709 (May) 1943.
19. Douglas, B., and Millikan, G. A.: Blood Circulation in Pedicle Flaps. *Plast. Reconstr. Surg.* 2:348-357 (July) 1947.
20. Hynes, W.: Simple Method of Estimating Blood Flow With Special Reference to Circulation in Pedicled Skin Flaps and Tubes. *Brit. Jour. Plast. Surg.* 1:159-171 (Oct.) 1948.
21. Hynes, W., and Macgregor, A. G.: Use of Fluorescein in Estimating Blood Flow in Pedicled Flaps and Tubes. *Brit. Jour. Plast. Surg.* 2:4-12 (Apr.) 1949.
22. Conway, H., Stark, R. B., and Docktor, J. P.: Vascularization of Tubed Pedicles. *Plast. Reconstr. Surg.* 4:133-143 (Mar.) 1949.
23. Conway, H., Stark, R. B., and Joslin, D.: Cutaneous Histamine Reaction as Test of Circulatory Efficiency of Tubed Pedicles and Flaps. *Surg., Gynec. and Obst.* 93:185-189 (Aug.)
24. Conway, H.: Clinical Tests for Evaluation of Circulation in Tubed Pedicles and Flaps. *Ann. Surg.* 135:52-59 (Jan.) 1952.
25. Winsten, J., Manalo, P. D., and Barsky, A. J.: Studies on the Circulation of Tubed Flaps. *Plast. Reconstr. Surg.* 28:619-633 (Dec.) 1961.
26. Sturman, M. J., et al.: The Prevention of Necrosis in Congested Tube Pedicles. *Plast. Reconstr. Surg.* 34:555-563 (Nov.) 1964.
27. Cahill, J. A., Jr., and Caulfield, P. A.: Complete Avulsion of Scalp and Loss of Right Ear. *Surg., Gynec. and Obst.* 66:459-465 No. 2A (Feb.) 1938.
28. Straith, Claire, and McEvitt, W. G.: Total Avulsion of the Scalp. *Occupat. Med.* 1:451-462 (May) 1946.
29. Straith, Claire: Possibilities of Plastic Surgery. *Clin. Med.* 51:309-313 No. 11 (Nov.) 1944.
30. New, G. B., and Devine, K. D.: Skin Grafting Methods and Their Indications. *Surg. Clin. N. A.* 26:890-905 (Aug.) 1946.
31. Lewin, M. L.: Reconstruction of Helix. *Arch. Oto.* 47:802-808 (June) 1948.
32. Steffanoff, D. N.: Auriculo-Mastoid Tube Pedicle for Otoplasty. *Plast. Reconstr. Surg.* 3:352-360 (May) 1948.
33. Smith, F.: Flaps Utilized in Facial and Cervical Reconstruction. *Plast. Reconstr. Surg.* 7:415-455 (May) 1951.
34. Converse, J. M., and Smith, D. W.: The Surgical Treatment of Carcinoma of the Nose. *Trans. Amer. Laryng. Assn.* 83:190-197, 1962.
35. Escoffier, J. B.: The Forehead in Nasal Repairs. *Plast. Reconstr. Surg.* 21(2) (Feb.) 1958.
36. Farina, R.: Total Rhinoplasty for Deformities Following Leprosy. *Plast. Reconstr. Surg.* 20(1)78-82 (July) 1957.

37. Blocksma, R., and Innis, C. O.: Reconstruction of Amputated Nose, 30 Cases. *Plast. Reconstr. Surg.* 15:390-403 (May) 1955.
38. Farrior, R. T.: Reconstructive Surgery for the Middle One-Third of the Face. *E.E.N.T. Monthly* (Oct. Nov. Dec) 1965 and (Jan.) 1966.
39. Erich, John B.: Discussion in *Trans. Amer. Acad. Ophth. and Oto.*, p. 90 (Jan.-Feb.) 1958.
40. Erich, John B.: A Survey of Skin Grafts and Pedicle Flaps for Repair of Nasal Defects. *ANNALS OF OTOTOLOGY, RHINOLOGY AND LARYNGOLOGY* 72:808-830 (Sept.) 1963.
41. Straatsmas, C. R.: Plastic Repair of Partial Losses of Tip. *Ann. Surg.* 911:792-794 (May) 1930.
42. Straith, Claire: Management of Facial Injuries Caused by Motor Accidents. *J.A.M.A.* 108: 101-105 (Jan. 9) 1937.
43. Straith, Claire: Automobile Injuries. *J.A.M.A.* 109:940-943 (Sept. 18) 1937.
44. Straith, Claire: Reconstruction About the Nasal Tip. *Amer. Jour. Surg.* 43 (Jan.-Mar.) 1939.
45. Ivy, R. H.: Repair of Defects by Low-Neck Pedicle Flaps. *Plast. Reconstr. Surg.* 1:119-123 (Sept.) 1946.
46. Young, Forrest: Repair of Nasal Losses. *Surg.* 20:5:670-683 (Nov.) 1946.
47. Steiss, C. F.: Utilization of Tube Pedicle in Reconstruction of Defects (of Face). *Surg.* 4:545-558 (Nov.) 1949.
48. Crawford, B. S.: Repair of Defects of Nose by Clavicular Tubed Pedicles. *Brit. Jour. Plast. Surg.* 8:318-319 (Jan.) 1956.
49. Pierce, G. W., Klabunde, E. H., and Shadish, W.: Use of Double Tubed Pedicle Graft in Reconstruction of Large Facial Defects. *Amer. Jour. Surg.* 95(2)194-196 (Feb.) 1958.
50. Weaver, Delmar F.: Free Skin Grafts and Pedicle Flaps in the Repair of Nasal Defects. *Trans. Amer. Acad. Ophth. and Oto.* (Jan.-Feb.) 1958.
51. Gillies, Sir Harold: Oral Communication.
52. Ohngren, G.: Plastic Surgery Following Electrocoagulation Treatment of Malignant Tumors of Nose and Accessory Sinuses. *Acta Oto-laryng.* 16:292-305, 1931.
53. New, G., Figi, F. A., and Havens, F. Z.: Replacement of Tissues of Forehead and Scalp. *Surg. Clin. N. A.* 14:607-613 (June) 1934.
54. Beck, J. C., and Guttman, M. R.: Plastic Repair of Defect Following Operative Treatment of Cancer of Antrum and Upper Jaw. *Surg. Clin. N. A.* 14:775-782 (Aug.) 1934.
55. Figi, F. A.: Plastic Repair After Removal of Extensive Malignant Tumors of the Antrum. *Arch. Otol.* 28:29-41 (July) 1938.
56. Neumann, C. G.: Use of Large Buried Pedicle Flaps of Dermis and Fat in Treating Progressive Facial Hemiatrophy. *Plast. Reconstr. Surg.* 11:315-332 (Apr.) 1953.
57. Smyrnoff, S. A.: Plastic Closure of Palatal Defects by Means of the Tube Pedicle Flap. *Amer. Med.* 39:115 (Mar.) 1933.
58. Masson, J. K., and Bowen, R., Jr.: Closure of a Wide Cleft Palate in an Adult by Means of a Tube Flap. *Proc. Mayo Clin.* 35:11-14 (Jan.) 1960.
59. Evans, A. J., and Walker, F. A.: Nasal Epithelial Inlay and Tube Pedicle Repair of Palate: Case History. *Brit. Jour. Plast. Surg.* 19:117-123, 1966.

60. New, Gordon, and Havens, F. Z.: Epithelioma of Face. Treatment and Subsequent Reconstruction. *J.A.M.A.* 97:687-690 (Sept. 5) 1931.
61. Straith, Claire: Plastic Surgery in Facial Cancer. *Harper Hosp. Bull.* 6:2:59-64, 1948.
62. Erich, John B.: Loss of Mandible: Repair With Clavicular Tube Flap and Intraoral Prosthesis. *Plast. Reconstr. Surg.* 18:191-198 (Sept.) 1956.
63. Dingman, Reed, and Natvig, Paul: Surgery of Facial Fractures. W. B. Saunders Co., Phil. and London, p. 362, 1964.
64. Moorehead, F. B.: Lesions of Jaw, Nose and Cheek; Cleft Lip and Cleft Palate; Cartilage Transplant and Tube Graft. *Surg. Clin. N. A.* 12:57-66 (Feb.) 1932.
65. Mixer, C. G.: Contractions of Neck Following Burns (Treatment by Use of Tubular Skin Grafts). *New Eng. Jour. Med.* 208:190-196 (Jan. 26) 1933.
66. Wilmoth, C. L.: Tubed Pedicle Graft in Facial Reconstruction: Superiority When Subcutaneous Loss Is Present. *Amer. Jour. Surg.* 53:300-305 (Aug.) 1941.
67. Figi, F. A., New, Gordon, and Dix, C. R.: Radiodermatitis of the Head and Neck With a Discussion of Its Surgical Treatment. *Surg., Gynec. and Obst.* 77:284-294 (Sept.) 1943.
68. Hardin, C. A.: Reconstruction of Cervical Esophagus by Means of Arm Flap. *Ann. Surg.* 142:121-123 (July) 1955.
69. Tallent, A.: Closure of a Pharyngostoma With a Bipedicled Flap of Scalp in the Leon-Dufourmentel Chin-Strap. *Ann. Chir. Plast.* 8:123-127 France (June) 1963.
70. Bakamjian, C., and Littlewood, M.: Cervical Skin Flaps for Intraoral and Pharyngeal Repair Following Cancer Surgery. *Brit. Jour. Plast. Surg.* 17:191-210 (Apr.) 1964.
71. Ogura, J. H., and Dedo, H. H.: Repair of Large Pharyngostoma Utilizing Bilateral Non-delayed Regional Pedicle Flaps. *Laryngoscope* 75:588-600 (Apr.) 1965.
72. Bakamjian, V.: A Two-Stage Method for Pharyngo-esophageal Reconstruction With Primary Pectoral Skin. *Plast. Reconstr. Surg.* 36:173-184 (Aug.) 1965.
73. Le Quesne, L. P., and Ranger, D.: Pharyngolaryngectomy With Immediate Pharyngogastric Anastomosis. *Brit. Jour. Surg.* 53:105-109, 1966.
74. Gillies, H. D., and McIndoe, A. H.: Plastic Surgery in Chronic Radiodermatitis and Radionecrosis. *Brit. Jour. Radiol.* 6:132-147 (Mar.) 1933.
75. Catlin, D.: Use of Tubed Pedicle Transplant in Reconstruction of Surgical Defects in Head and Neck. *Plast. Reconstr. Surg.* 6:207-216 (Sept.) 1950.
76. Phillips, A.: Laryngeal Fistula Following Radiotherapy and Plastic Repair. *Jour. Laryng. and Otol.* 69:277-282 (Apr.) 1955.
77. Erdelyi, R.: Tubular Flap Procedure for Closure of Large Pharyngeal Fistula. *Brit. Jour. Plast. Surg.* 9:72-76 (Apr.) 1956.
78. Cowan, R. J., and McDougall, J. G.: Reconstruction of the Pharynx Following Laryngopharyngo-esophagectomy. *Plast. Reconstr. Surg.* 21:362 (May) 1958.
79. Devine, K. D., and Kragh, L. V.: Reconstruction of the Pharynx and Upper Esophagus. *Surg.* 46:319-332 (Aug.) 1959.
80. Glaninger, J.: A Round Pedicle Flap for the Closure of Large Pharyngeal Defects After Laryngectomy. *Mscr. Ohrenheilk* 94:91-108 (Germany) (Apr.) 1960.
81. Farina, R.: Pharyngoneoplasty. *Brit. Jour. Plast. Surg.* 14:82-90, 1961.

82. Gaisford, J. C., and Hanna, D. C.: Reconstruction of the Cervical Esophagus. *Plast. Reconstr. Surg.* 29:561-572 (May) 1962.

83. Khitrov, F. M.: The Method of Using a T-shaped Filatov Flap in the Repair of Combined Defects in the Face. *Acta Chir. Plast. Praha* 4:46-58, 1962.

84. Bricker, E. M., Burford, T. H., and Eiseman, B.: Pedicle Grafts in Carcinoma of Upper Esophagus. *Jour. Thorac. Surg.* 18:304-315 (June) 1949.

85. Bergman, R. T., Howard, A. H., and Barnes, R. W.: Plastic Reconstruction (Using Skin Tube Graft and Rib Cartilage) of Penis. *Jour. Urol.* 59:1174-1182 (June) 1948.

86. Moran, R. E., et al.: Revascularization of Heart by Tubed Pedicle Graft of Skin and Subcutaneous Tissue. *Plast. Reconstr. Surg.* 10:295-302 (Nov.) 1952.

FIRST EXPERIENCES WITH THE ASAI TECHNIQUE FOR VOCAL REHABILITATION AFTER TOTAL LARYNGECTOMY

ALDEN H. MILLER, M.D.
LOS ANGELES, CALIF.

Late in 1965, it was my privilege and pleasure to see and hear a sound movie by Dr. Ryoza Asai, in which he demonstrated a method of providing laryngectomized patients with an almost normal voice. The basis of his technique was the construction of a dermal tube from the upper end of the trachea into the hypopharynx. When the lower tracheal fistula, which had been placed for breathing, was closed with the patient's finger, air could then be expired up the dermal tube and into the pharyngeal cavity with sound produced there and transformed into speech. The voices of these patients had an excellent quality and a wide range of pitch. They could sing; whistle with ease; and speak sentences of average length with normal pauses for inspiration.

In January of 1966, I used Dr. Asai's technique for the first time, performing the first stage at the conclusion of a wide field laryngectomy. I have now completed the final stage in four such patients and have completed the first or second stage in another three patients. The four have excellent voices, far superior, in my opinion, to the average esophageal voice after laryngectomy. There are two slight inconveniences for these patients. First, one has to use a hand to close the tracheal opening when he talks and second, he has to manually press the skin over the upper end of the dermal tube sometimes when swallowing saliva or liquid foods.

TECHNIQUE

The technique consists of three stages or operations. The first stage is employed at the end of an ordinary wide-field laryngectomy. After removal of the larynx, the open end of the trachea is sutured to the skin opening of the mid-line of the neck in the usual fashion. I continue to use a posterior triangular tongue of tracheal mucosa in making this stoma. When using the usual mid-line vertical skin incision for the laryngectomy, I place the open end of the trachea a centimeter or two higher than that usually done. This necessitates some closure of the lower end of the incision below the tracheal stoma thus being formed. A permanent tracheal stoma is then made through the fourth or fifth tracheal ring with 2 cm of skin between it and the upper opening. This will be the

patient's permanent opening for breathing the remainder of his life. The stoma made above it will become the lower opening of the final dermal tube into the pharynx. This completes the first stage of the technique.

The second stage consists in making, a month or so later, a fistula into the pharynx, suturing mucosal edges to skin edges. This fistula should enter the pharynx just under the overhang of the bulge posteriorly of the base of the tongue. The patient now has three stomae in a vertical line.

The third and final stage, another month or so later, forms a tube of skin with its lower opening being the upper tracheal stoma and its upper opening being the fistula into the pharynx. This tube is formed by making a vertical skin incision one centimeter on each side of the mid-line of the neck and curving these incisions around and above the pharyngeal stoma by one centimeter, and below and around the upper tracheal stoma by the same centimeter. The cut edges of this island of skin are then approximated and sutured vertically in the mid-line. Thus is formed a tube of skin connecting the uppermost end of the trachea and the pharynx. The remaining cut skin edges are now closed vertically in the mid-line over the dermal tube, burying it.

The first six patients have taught me certain rules and measurements to follow during the surgery of each stage and in postoperative management. In the first stage, I prefer to insure that the lowermost opening, the permanent tracheal stoma, be a little smaller than usual. A diameter of about 12 mm is probably the best. This may mean the use of a number seven or eight laryngectomy tube instead of a number nine. I would like the middle stoma, the uppermost end of the trachea, to end up being about six millimeters in diameter. This may necessitate the wearing of a small plastic tube or plug in this opening during the month intervening between the first and second stage and even that month between the second and third stages of the technique.

In the second stage I attempt to place the pharyngeal stoma in such a way that it runs downhill from its skin opening to its pharyngeal opening. I place the pharyngeal opening just under the ledge formed by the remaining floor of the valleculae left at the conclusion of the laryngectomy. This, of course, necessitates leaving some of this anterior floor when the larynx is severed from the base of the tongue. I use a direct laryngoscope during this second stage to direct the insertion to this spot of a large needle through the skin of the mid-line of the neck at just about where the skin of the neck angulates with that of the underside of the floor of the mouth. This is about the level of the removed hyoid bone. When the needle is angulated properly, an incision then follows it into the pharynx. The skin opening is kept high when mucosal edges are sutured to skin edges. This pharyngeal stoma is made vertically with a vertical diameter of one centimeter. The pharyngeal stoma will narrow in the postoperative course of this second stage. Ideally, it should end up remaining with a diameter

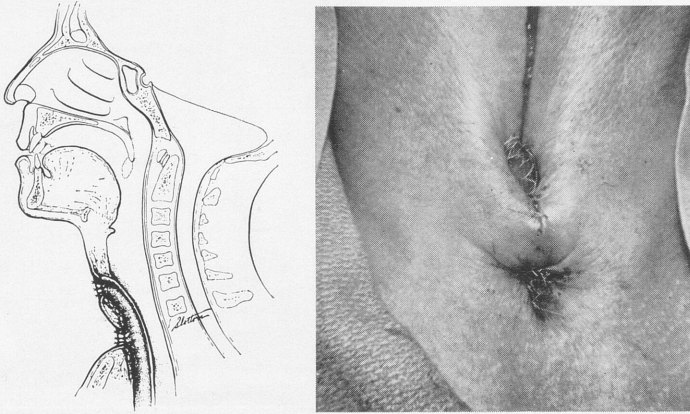


Fig. 1.—End of first stage.

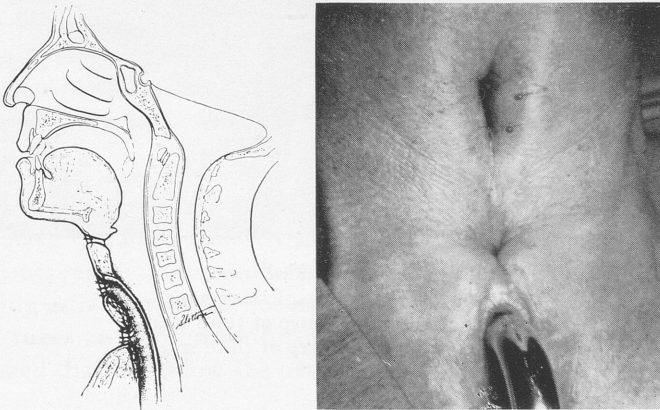


Fig. 2.—End of second stage.

of about four millimeters. This may necessitate the wearing of a plastic tube or plug in this stoma or in daily dilations for a few weeks.

During the third operation, I form the dermal tube over a section of plastic tubing having an outside diameter of six millimeters. This tubing is left in place for two or three weeks from just where it can be seen through the permanent tracheal stoma, up the dermal tube, into the pharynx and standing with its upper end at the level of the top surface of the tongue. Suture is tied into both ends of it to form an endless circle in order to replace it if it moves upwards

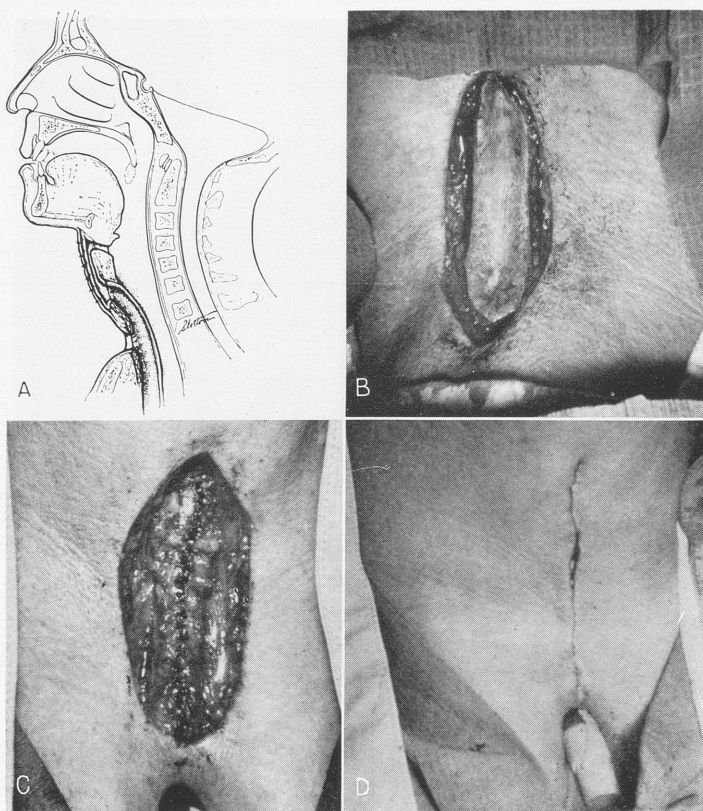


Fig. 3A.—End of third stage.

Fig. 3B.—First step of third stage.

Fig. 3C.—Second step of third stage.

Fig. 3D.—Third step of third stage.

or downwards. At the conclusion of the third stage, the patient will immediately be able to talk in a hoarse whisper even with the plastic tube in place.

RESULTS

The first two patients, the two who have had their final operation completed the longest, have excellent voices. They can talk with inflection and a wide range of pitch and tonal quality and can even sing. The oldest patient has been completed nine months and his voice continues to improve. The second patient has had her procedures completed four months and she, too, has continued to have a voice that steadily improves in loudness, range and singing ability and she has retained her Southern accent. The third and fourth patients' voices are still

rather soft after just the month following their final surgery but are steadily improving.

The first patient has no difficulty with swallowing solids, but sometimes must use digital pressure over the skin over the upper end of the dermal tube with drinking some liquids. The second patient must use the digital pressure with the swallowing of all liquids. The third patient, in whom for the first time the pharyngeal stoma was deliberately slanted downwards from the skin, has absolutely no leak of either liquids swallowed or of his saliva. None of the patients report any cough resulting from the trickling down of saliva and none have had any infections of their respiratory tract. All report that talking seems to keep the dermal tube clear of saliva.

The first two patients report that talking is much easier when they leave their laryngectomy tubes in place and occlude its opening rather than occluding the tracheal stoma when the tube is not in place. The first patient obtains his loudest and clearest voice when he uses a second finger for digital pressure over the lowermost end of the dermal tube in order to narrow its lumen. Interestingly, the greatest vibration of the dermal tube is felt where it is narrowed.

Only the first patient has had hair grow up through the pharyngeal stoma from the dermal tube. This has given him no symptoms and the hairs are being evulsed at direct or indirect laryngoscopy.

Hinged trap-door tracheotomy tubes or tubes with diaphragms have been used so as to allow the patient to close off the tube on expiration and thus talk without having to use one hand to close the opening of the tracheotomy tube. Their voices have remained almost the same as with digital closure of the stoma but both patients report an uncomfortable, suffocating-like feeling after a minute or so of talking as if they could not expire enough air. They have insisted that these hinged tubes are too uncomfortable. It seems sure that soon a trap-door can be fashioned that will allow the patient to flip it open to relieve this sensation.

CONVERSION

Can this technique be used to convert the patient who has had the usual laryngectomy with just the formation of one rather low-lying stoma? A few weeks ago, I assisted Dr. Fred Turnbull of Los Angeles in completing the technique on such a patient. Dr. Turnbull had placed a pharyngeal fistula as a second stage. At the time of the third and final stage, the stoma was freed in its anterior 180° of circumference and the trachea was elevated 2 to 2½ cm. A new lower permanent tracheal fistula was formed and the upper two openings connected in forming a dermal tube in the usual manner. This patient had an uncomplicated postoperative course and has a good voice. The actual steps of this technique will be reported later.

SUMMARY

My first experience with the usage of the Asai technique for vocal rehabilitation of the laryngectomized patient have been recounted. I am convinced that these patients will continue to have excellent voices far superior to those with esophageal voices. However, they must put up with some discomforts in order to have these voices. Instead of one, there will be three operations and convalescent periods. They must use one hand to close the tracheal stoma when talking and some patients will experience slight annoyance in having to close the dermal tube with digital pressure when swallowing liquids. These drawbacks must be pointed out to the patient contemplating such surgery. The patients who have an excellent esophageal voice will probably not choose to be converted to the Asai technique, nor would I encourage them to have the conversion, although I think we will be able to convert almost any laryngectomized patient.

1407 NORTH VERMONT AVE. 90027

DISCUSSION

DR. JOSEPH H. OGURA: This past February, when Dr. Som and I were invited out to Los Angeles, we could almost feel an air of excitement with Dr. Alden because he was now taking us to Hollywood Presbyterian Hospital to see these three cases.

I believe these represent a milestone in rehabilitation. We were very impressed, we saw these cases and I can attest to the fact that this works.

I believe, though, that, as he has stated, I think the future in this operation will be eventually directed at two areas:

One is that of the upper stoma; and

The second will be trying to eliminate the tracheotomy tube, and reducing the three-stage operation to two.

I think that if we could change that lower stoma, that it could be a permanent one, this would be a significant advantage.

We had tried the pseudo-larynx, which is the reconstruction of flaps and valves. These patients—I have never published this because good functional results were not attained, namely, that they could not swallow completely, although they had an excellent voice. This indicates that one does not have much of a problem in voice if you can provide an air passage and I think that eventually the Asai operation will become standard.

It is unfortunate that Dr. Asai never did publish his results. As I understand it, he has done some 65 cases in Japan and those of us that saw this movie were very impressed by it.

DR. W. FRANKLIN KEIM: I would like to address my remarks to the paper by Dr. Fitz-Hugh on Esophagostomy, to bring to your attention the fact that this is not a procedure entirely without complications.

I agree with Dr. Fitz-Hugh that it is an extremely valuable procedure and we, too, have used it more and more as time has gone on.

One of our complications has been hemorrhage. I think, in all probability, it was due to the use of a red rubber catheter as a feeding tube. We have since, of course, gone over to the use of

polyethylene and have had no further difficulty. However, the hemorrhage that we had was apparently esophageal. We never did locate the exact origin of it, in spite of x-ray studies, esophagoscopy, and so on, but this man required 26 pints of blood, esophageal and gastric freezing in order to save his life. He is still alive and in the process of reconstruction following total mandibulectomy.

The other complication I think was due to a technical error in that the purse string, which I habitually put around the opening in the esophagus, gave way and the feedings which were given by the tube regurgitated and puddled in the neck. This man had a neck dissection at the time and the lower supraclavicular area did become contaminated by the regurgitated feedings.

However, with these two exceptions, we have found the procedure most effective and I think it will continue to be so.

DR. JOEL J. PRESSMAN: You will notice—or I noticed—that in each of your cases the patients were still wearing a tracheotomy tube.

Would you be willing to discuss the possibility of decannulation of these patients as compared with ordinary total laryngectomy?

I can't permit this Symposium on Newer Surgical Techniques to go by without a word.

When I visited "The University" I saw Dr. FitzHugh's use of these tubes and have used them frequently since that time with the greatest of satisfaction. It has been a practical, most gratifying procedure, in each patient upon whom it has been done.

We had no complications from it. I think it was most important that Dr. Fitz-Hugh bring this to our attention and I would like to comment on Dr. Keim's problem.

We haven't actually had any bleeding, but we have seen in the surgical field important thyroid vessels, particularly those from the thyroid axis, and I am led to believe that the bleeding he had might have come from the evulsion or erosion of one of the vessels of this important arterial branch.

Dr. Weaver's contribution is, of course, of great importance in the implication of its use for the reconstruction of pharyngeal stomata following total laryngectomy and I think it represents the logical method of repair of this very unfortunate sequela.

Dr. Miller's paper, I would presume we will all agree, represents one of the most important advances in the surgery of carcinoma of the larynx requiring total laryngectomy, which automatically makes it perhaps one of the most important papers ever presented before this Association.

This was presented magnificently, and I think we have to rewrite the book. My only regret about the whole thing is that it comes from the other side of the tracks at USC instead of our side at UCLA.

DR. LYMAN G. RICHARDS: Why can't these patients exhale with a valve tube?

DR. MILLER (closing): Yes. There are so many things that I couldn't, in my time, touch upon. There are all kinds of problems to try to solve and I had hoped that I would intrigue you into thinking about these. Dr. Asai's movie on forty patients showed the tracheotomy tube was not worn, and my patients do not have to wear the tracheotomy tube. It is just that so far these first four seemed to prefer it. It means to me that the tracheal stoma is too big. Now we are making all of our permanent breathing stomas smaller than they usually end up being after a standard laryngectomy.

I showed you the picture of one of the two kinds that I use. But all of the tubes that are hinged are hinged in such a way that only a small amount of air is lost on talking and thus the patients don't breathe enough air out. I have devised a little hinged door that can be propped open for expiring air. If the patient is going to have both hands free, he must wear a tracheotomy tube with a hinge on it.

RECENT ELECTRON STUDIES
WITH SPECIAL REFERENCE TO
RESPIRATORY CILIA

G. EDWARD TREMBLE, M.D.

MONTREAL, CANADA

Our knowledge of respiratory cilia has been very limited until recent years. The standard type light microscope in use at the present time, and known to every medical student, is a development of the first compound microscope made in Delft, Holland, about three hundred years ago. We are indebted to a poor janitor, with little or no education, Antony Van Leeuwenhoek¹ by name, who observed that objects were tremendously magnified under a convex lens. He became so engrossed with the appearance of small objects under his lens, such as blades of grass, flowers, butterfly wings, etc., that he ground larger and more powerful lens and neglected his other duties. He later developed the first compound microscope.

Another Dutchman, Anton de Heide,² noted and described cilia for the first time in 1683, and then twelve years later in 1695, Leeuwenhoek observed and drew attention to ciliary movement. After he died several hundred lens were found in his house.

A few years earlier, in 1660, Schneider³ observed that the nasal mucosa was the source of mucus. To quote from his reference, "mucus may be squeezed out of the membrane in these regions, even in the dead subject." Previous to this it was only natural for Hippocrates, Galen and their followers for over a thousand years to think that nasal secretion was formed in the brain and filtered through the sieve-like cribriform plate to bathe the lining of the nose.

Unfortunately the microscope had not been developed at that time, so Schneider was unaware that the serous and goblet cells and racemose glands were responsible for the nasal secretion. Nearly sixty-five years passed (1724) before Santorini⁴ discovered the glands in the nasal mucosa, under the microscope, which by this time was used in some European countries.

The present day standard type light microscope has three or four objectives with various degrees of magnifying power depending on the lens used. The high-power objective with oil-immersion lens gives a magnification of about

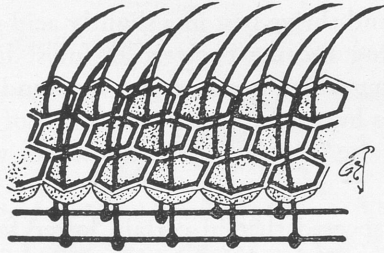


Fig. 1.—A small portion of the surface of a paramecium, showing the co-ordinating fibers connecting the bases of the cilia. (Diagram after Lund.)

twelve hundred times. When magnified to this extent, normal respiratory mucosa shows cilia that appear as homogeneous, hair-like projections from the high columnar cells interspersed with goblet cells which open to the surface. The nucleus and nucleolus are well shown in the granular cytoplasm as well as the basement membrane with the connective tissue below containing the blood vessels.

In an article published in 1950,⁵ the author described ciliary movement in one of the lowest forms of animal life—the paramecium. This single cell aquatic animal is studied by every student of biology. These observations were made with the ordinary type microscope mentioned above and showed a few similarities between the movement of cilia on the surface of paramecia and those on human nasal mucous membrane.

"The paramecium, a small unicellular animal found in fresh water pools, is covered with about twenty-five hundred short hairlike projections, or cilia. These cilia are really protoplasmic extensions which protrude through minute holes in the stiff surface covering. Beating in rhythm, ciliary waves are formed, beginning at the anterior end and progressing backward. By this means the animal is propelled through the water in search of food. It should also be mentioned that in the presence of danger, the animal can reverse the beat of the cilia, back up and go off in another direction. The high degree of co-operation displayed by the cilia in swimming and in taking food suggests some co-ordinating mechanism resembling nerve control found in higher animals. It is interesting to note that within the last few years a system of fine protoplasmic fibers has been discovered which runs longitudinally just beneath the surface and connects the bases of the cilia. There appears to be little doubt that this system of fibers forms the mechanism which regulates the activity of the cilia, for when this mechanism is injured as has been done experimentally, the cilia no longer beat in rhythm and certain of the swimming movements are impaired⁶ (Fig. 1). One

point of similarity to nasal mucosa should be stressed. *Paramecia* avoid strong acids and also back up when passing from dilute acid to tap water. In other words, they congregate and thrive best in a slightly acid medium. This behaviour aids the animal in feeding because bacteria are most likely to be present near decaying organic matter, which renders the surrounding water slightly acid. Under normal conditions human cilia beat at the rate of about two hundred and fifty cycles per minute, also in a slightly acid medium with the nasal pH at 5.5 to 6.5."

For years it was suspected that in certain lower forms of animal life each cilium on the surface contained a dense axial core with a thin peripheral sheath.

In 1889 Butschli⁷ suggested axial fibers in certain flagellata. Under polarized light and dark field illumination, the central core was thought to consist of many individual fibrils running the length of the cilium. With greater magnification, Brown⁸ in 1945 described flagellated protozoa in which the flagella contained an axial fibrillar core and a peripheral sheath, and the next year (1946) Jakus and Hall⁹ studied the cilia of *paramecia* under the electron microscope and found longitudinal fibrils, usually eleven in each cilium.

Since that time the importance of the electron microscope has become more recognized. Although the first instrument was made in Germany by Knoll and Ruska in 1931 and improved two years later, it had little or no value from the point of view of histology for a number of years. Although the resolving power was much greater than that obtained with the light microscope, it was only when sections were made thin enough to be penetrated by the electron beam that the instrument came into general use.

During the last twenty years methods have been devised whereby sections could be cut about a millionth of an inch in thickness. It was only then that the tremendous magnification seen under the electron microscope became practical.

When we remember that the highest magnification seen with the ordinary light microscope with oil-immersion lens is twelve to thirteen hundred times the normal, it is difficult to appreciate the detail when objects are magnified one hundred or one hundred and fifty thousand times the normal size.

It should be pointed out that the unit of measurement in common use for the electron microscope is the millimicron which is 1/1000th of a micron, or the Angstrom unit which is one tenth of a millimicron. A micron or μ is 1/1000th of a millimeter. When we consider that a cilium in the human trachea is six to seven microns in length or about the size of a red blood corpuscle, we begin to realize these almost infinitesimal units of measurement under this instrument. With the ordinary light microscope very little information is obtained. At this magnification (x1200) stained slides or movie films show human cilia as hairlike

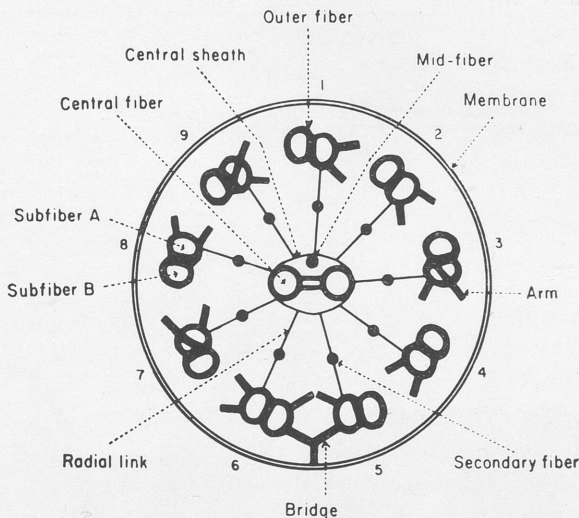


Fig. 2.—Diagrammatic transverse section of a cilium. The effective stroke is downward toward the bridge.

projections which appear homogeneous and protrude from the surface of the columnar epithelium. They seem to be anchored to the basal bodies (dark staining) just below the surface in the cytoplasm.

In seeking an explanation of the to and fro motion, it was thought by some that a cilium was a curved tubular extension of the cell and that hyaloplasm was forced into each cilium making it straighten out.¹⁰ When the fluid returned to the cell the cilium again resumed the curved position. As there are multiple cilia on each columnar cell, if this theory was correct, the ciliated cells would shrink as hyaloplasm was forced into the cilia and expand as the fluid returned to the cell. Careful measurements have not shown any alteration in size of these cells, even when ciliary movement was accelerated as with an acute sinusitis.

Others such as Heidenhain¹¹ suggested that a contractile core on one side of the cilium made it bend over during the effective stroke and straighten up when the core relaxed. These theories were quickly discarded when the architectural pattern was noted under much higher magnification.

Before the advent of the electron microscope, it was thought that each columnar cell in the respiratory tract contained relatively few cilia on the surface. Within the last twenty years, it has been found that each ciliated cell in the human trachea has well over two hundred cilia. As suspected, each cilium is made up of two parts, the shaft which protrudes from the free surface of the cell

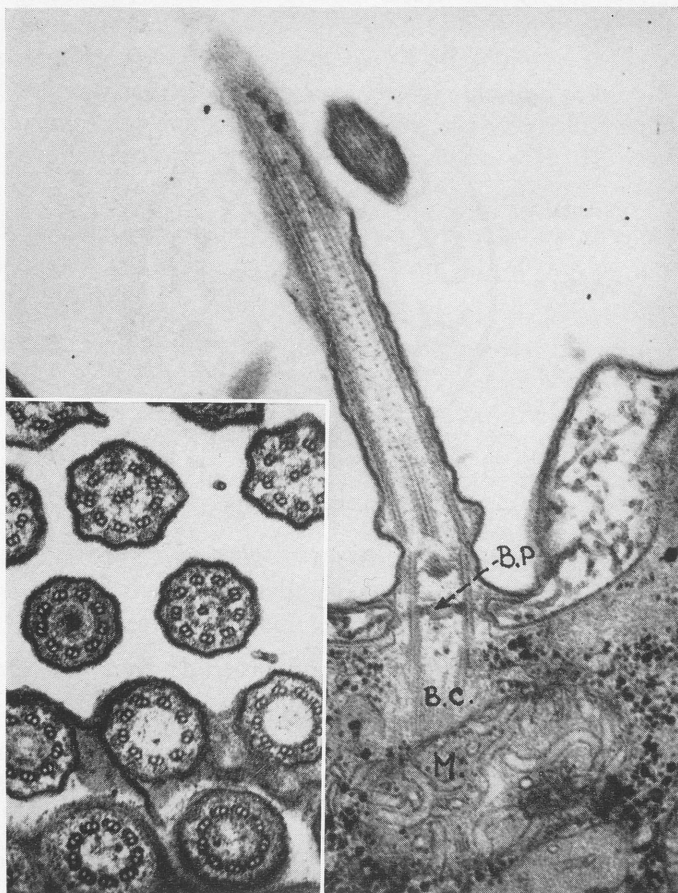

Fig. 3.—A longitudinal section (right) of cilium of a paramecium ($\times 100,000$) showing the free portion covered with cell membrane. The central filaments terminate before reaching the basal plate (B.P.). The basal corpuscle (B.C.) resembles a centriole. The cross sections above on the left show the exposed portion of cilia while those below are sections beneath the surface. The central filaments which are present above disappear and the double filaments become triple filaments. Below the basal corpuscle (B.C.) is a mitochondrion (M) which has to do with respiration and energy. (Prepared by Dr. K. R. Porter.)

and the portion that extends just below the surface into the cytoplasm. The outward extension is covered with the cell membrane, while the portion that is anchored below the surface is devoid of membrane. A cross section of the shaft shows a constant picture (Fig. 2). There are two central tubular filaments and nine paired fibers evenly spaced between the central filaments and the periph-

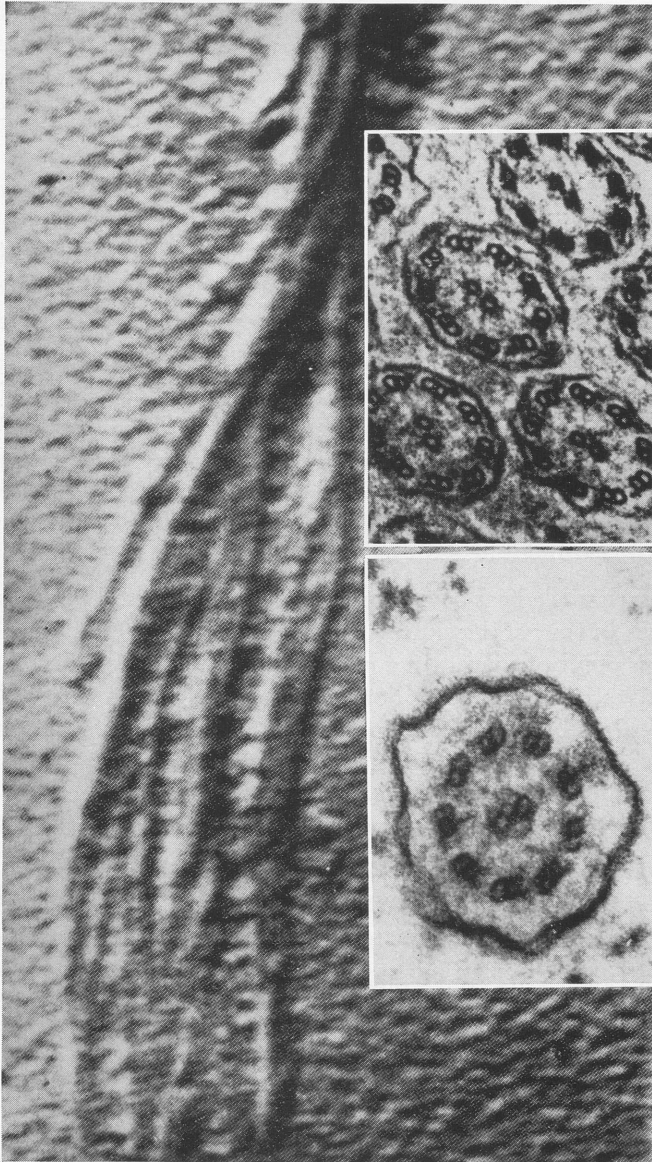


Fig. 4.—Micrograph of fringed tip of rat spermatozoan, $\times 40,000$. (Prepared by Dr. C. P. Leblond.) Upper insert shows a cross section of human sperm tails which are identical with those in the rat and a cilium in the human respiratory tract, lower insert on right, $\times 100,000+$. (Prepared by Dr. T. S. Leeson.)

ery. Each of the nine paired filaments resembles a figure 8 with two bars or legs at the base. Radial links extend from the central fibers or filaments like the spokes of a wheel and each link or spoke contains a secondary fiber half way between the central and paired outer fibers. Each cilium ends just below the surface in a basal corpuscle or body which is held in place by intracellular rootlet fibrils.

In the lower forms of animal life there is a web-like structure just below the attachment of the cilium called the basal plate. The central filaments stop just short of this membrane but the nine paired filaments toward the periphery extend below the basal plate into the basal corpuscle. Here the nine double filaments gain another and become triple filaments (Fig. 3). It should be mentioned that the basal corpuscle ends below the surface in a clump-like group of fine filaments called the basal foot. This basal foot terminates in a curved tapering end which resembles the blade of a hockey stick in the direction of the beat. These filaments appear to support the cilia and connect with inter-communicating fibrils from the basal corpuscles of neighboring cells. It is thought by some authorities that impulses are transmitted through the fibrils to the adjacent basal corpuscles giving a uniform stroke.

Assuming that the beat occurs in this way, it seems to be very similar to the connecting rods in the paramecium as mentioned earlier. However, not everyone agrees with this point of view. In a personal communication, Dr. K. R. Porter,¹² an eminent investigator, said, "I doubt very much if the intracellular rootlets of cilia are responsible for much more than anchoring the cilium in a gelled cortex. They do not extend into neighbouring cells as far as I know and are so inconstant in occurrence that I doubt if they have much to do with the co-ordinated movement."

Several years ago Fawcett and Porter¹³ described the similarity in the structure of cilia on cross section in plant and animal life. It is surprising that the cilia of mollusks, amphibia and mammals, including man, are almost identical.

Although this is true concerning the exposed portion of each cilium, there are minor differences below the attached surface in the region of the basal corpuscle.

According to Negus,¹⁴ "in sub-mammalian species a basal plate separates the cilium and its fibrils from the basal corpuscle; in the Mouse and Man there is no basal plate, the peripheral filaments seeming to extend with modifications down into the basal corpuscle."

Five years ago (1962) the author¹⁵ noted some findings with the electron microscope on spermatozoa of rats, carried out by Professor C. P. Leblond and his associates at McGill University. One article of particular interest showed the progressive stages in the development of spermatozoa in the rat, mouse,

hamster and guinea pig. It is surprising that in all these rodents, "it was found that spermiogenesis could be readily sub-divided into the same four phases in all the species examined."¹⁶ This was a constant finding. To those of you who are interested, this is a most stimulating article.

In a later paper they¹⁷ described their original findings in the head of rat spermatozoa. Micrographs magnified 10,000 times showed the head in some detail, which is roughly triangular in cross section. In the lateral view the oval-shaped nucleus is situated in the head just behind the curved tip which resembles a beak. It is relatively large and occupies most of the head. The tail, it was also noted, was about ten times the length of the head and ended in a fringed tip or flagellum.

In a paper on laryngology, some might wonder why reference has been made to the head and tail of rat spermatozoa. The point of interest lies in the fact that the extreme tip of the tail of rat spermatozoa and human spermatozoa as well, is made up of about a dozen cilia exactly the same on cross section as cilia from the nose and trachea of humans (Fig. 4).

Although these facts have been known for some time, new refinements in technique and greater magnification have brought out further details in recent years. One observation not generally known might be worth mentioning. Cilia in the human respiratory tract appear to be the same length in infants and children as in adults. They are similar in this respect to the bony labyrinth in humans.

In an article some years ago, the author¹⁸ made a comparative study of the bony labyrinth of the newborn infant and the adult. Careful measurements were made on corrosion casts and showed in conclusion that, "the bony labyrinth of the newborn infant is practically the same size as that of the adult." This applied to the cochlea, vestibule and semicircular canals.

In seeking an explanation of the rhythmic movement and how groups of cilia vibrate while others rest, Gray^{19,20} suggested that the filaments contract causing the effective stroke and relax on the recovery stroke. As the central paired filaments are in the same plane, they appear to control the direction of the beat so that the cilia bend to and fro without interfering with one another. Others, such as the above mentioned Dr. K. R. Porter, agree that the central filaments likely give the direction to the beat but "doubt if they perform an important function in ciliary beat."²¹ In other words, he does not think that the central paired filaments are responsible for the ciliary movement by contracting and relaxing. In spite of our increased knowledge we are still at a loss to explain the exciting cause of ciliary activity and where it begins. Perhaps this is not surprising "when we remember that really nothing is known of the machinery whereby a muscle develops a tension when it is stimulated."²²

In view of this it might be some time before we understand the origin and nature of the ciliary beat.

SUMMARY

In this article an attempt has been made to trace a few of the highlights in the developing field of microscopy. The study of histology began just three hundred years ago when it was observed that small objects were tremendously magnified under a convex lens. This led to the discovery, a short time later, of the first compound microscope. During the last couple of hundred years, this instrument has been improved until the ones in common use today magnify minute particles about twelve hundred times. At this magnification some details of ciliated mucosa can be seen but the real advance occurred with the development of the electron microscope in recent years. With its tremendous power of magnification, fine details have come into view that were undreamed of even twenty years ago. However, in spite of this increased knowledge, we still do not know the mechanism which causes the to and fro movement of respiratory cilia.

1374 SHERBROOKE ST. WEST, MONTREAL, CANADA

REFERENCES

1. Van Leeuwenhoek, A.: *Arcana Naturae, Delphis Batavorum*, H. a Krooneveld, p. 48 et seq., 1695.
2. De Heide, Anton: *Anatome Militi*, 1683.
3. Wright, J.: *The Nose and Throat in Medical History*, p. 130.
4. Santorini, J. D.: *Observations Anatomical*. Chapter 5, Venice, 1724.
5. Tremble, G. Edward: *Mechanics of the Nose With Special Reference to Nasopharyngeal Discharge*. *Arch. Otolaryngol.* 51:205-214 (Feb.) 1950.
6. Buchsbaum, R.: *Animals Without Backbones: An Introduction to the Invertebrates*, p. 25 University of Chicago Press, Chicago, 1938.
7. Butschli, O.: *Braun's Klassen und Ordnungen, Protozoa*, 3, Leipzig, 1889.
8. Brown, H. P.: *On the Structure and Mechanics of the Protozoa Flagellum*. *Ohio Jour. Sci.* 45:247-301, 1945.
9. Jakus, M. A., and Hall, C. E.: *Electron Microscope Observations of Trichocysts and Cilia of Paramecium*. *Biol. Bull.* 91, N:02, 141-144 (Oct.) 1946.
10. Schäfer, E. A.: *On the Structure of Ameboid Protoplasm and a Suggestion Regarding the Mechanism of Ciliary Activity*. *Proc. Roy. Soc.* 49:193, London, 1891.
11. Heidenhain, M.: *Plasma und Zelle*. Jena, VEB Gustav Fischer Verlag, Vols. 1 and 2, 1911.
12. Porter, K. R.: Personal communication to the author.
13. Fawcett, D. W., and Porter, K. R.: *A Comparative Study of Ciliated Epithelium With the Electron Microscope*. *Anat. Rec.* 115:2425, 1953.
14. Negus, V. E.: *The Comparative Anatomy and Physiology of the Nose and Paranasal Sinuses*, p. 227. E. & S. Livingston Ltd., Edinburgh and London, 1958.

15. Tremble, G. Edward: Milestones in Research of Upper Respiratory Cilia. *Arch. Otolaryngol.* 76:346-351 (Oct.) 1962.
16. Leblond, C. P., and Clermont, Y.: Spermiogenesis of Rat, Mouse, Hamster and Guinea Pig as Revealed by "Periodic Acid-Fuchsin Sulfurous Acid" Technique. *Amer. Jour. of Anatomy* 90:168 (Mar.) 1952.
17. Clermont, Y., Einberg, E., Leblond, C. P., and Wagner, S.: The Perforatorium: An Extension of the Nuclear Membrane of the Rat Spermatozoon. *Anat. Rec.* 121:1-11, 1955.
18. Tremble, G. Edward: The Bony Labyrinth of the New-Born Infant and of the Adult. *Arch. Otolaryngol.* 9:175-180 (Feb.) 1929.
19. Gray, J.: The Effects of Ions upon Ciliary Movement. *Quart. Jour. Micro Sci.* 64:345, 1919-20.
20. Gray, J.: The Mechanism of Ciliary Movement. *Proc. Roy. Soc. B.* 93, 104 and 122, 1922.
21. Porter, K. R.: Personal communication to the author.
22. Gray, J.: Ciliary Movement, p. 7. Cambridge University Press, Fetter Lane, London, 1928.

DISCUSSION

DR. CATHERINE SMITH: I thoroughly agree with Dr. Tremble that, as we have been able to see things with higher magnification, sometimes they have only become more complicated instead of becoming simpler, and we have a great deal more to explain and a great deal more to understand.

CARCINOMA OF THE TRACHEA

MARIO J. ACQUARELLI, M.D.
(by invitation)

NEIL O. WARD, M.D. GEORGE W. HANGOS, M.D.
(by invitation) (by invitation)

LOS ANGELES, CALIF.

Primary carcinoma of the trachea is rare in the general practice of medicine, but to those of us specializing in diseases of the head and neck, though being an uncommon tumor, tracheal cancer must be considered in the evaluation of our patients. The trachea, being approximately 11 cm in length, lies hidden from the mirror beneath the vocal cords, and much of it above the level of the average chest x-ray. Thus if early malignancy of this organ is to be discovered, it is necessary for the laryngologist to be acutely aware of this disease, its manifest symptomatology, and the prompt evaluation and the extent of the tumor.

ETIOLOGY

As with most cancer, the final etiology of tracheal carcinoma still remains if not unknown at least unproven. There is little doubt that smoking plays a prominent factor in the etiology of this cancer. Some of us who have seen and treated laryngeal and tracheal carcinoma for many years can honestly say that we have never seen carcinoma of the trachea in a person who did not at one time smoke quite heavily. In addition to the carcinogenic effect of tobacco smoke, there have been mentioned other factors as to the relative low incidence of tracheal cancer as compared to cancer of the larynx. Ranke feels that tracheal cancer is rare because carcinogenic material does not have the opportunity for sustained contact with tracheal epithelium that it does with laryngeal and bronchial epithelia. As previously mentioned, primary carcinomas of the trachea are also not as evident clinically as those of the larynx and may become sizable and formidable before discovery. In fact, these tumors may be difficult to differentiate from secondary malignant tumors that have extended from the esophagus, thyroid gland, and less commonly from the larynx.

Because of the size of the lumen, and there being no valvular mechanism in the trachea, carcinogens have little opportunity for pooling with the initiation of chronic irritation and inflammation so often a precursor of malignancy of

From the Head and Neck Section, Wadsworth General Hospital, Los Angeles, California, and the Department of Surgery, UCLA School of Medicine, Los Angeles, California.

other portions of the respiratory tract. An active and forceful cough reflex helps keep the trachea clear of noxious agents, and even as we sleep the trachea is continuously being swept clean by the incessant beating of the cilia in the direction of the glottis.

These factors have been greatly reinforced by the work of Beattie, who performed reversed autogenous grafts of the cervical trachea in dogs. The reversed trachea still retained its ciliary beat, but now the cilia moved the mucus toward the carina. At its distal anastomosis a mucous block was formed where the down beating cilia met the normal upheating cilia. After the introduction of a known carcinogen (benzanthracene) carcinoma was produced at the site of this mucous block. At the proximal anastomoses, the up-beating cilia, opposed by the downward movement of mucus on the graft segment caused drying of the mucosa, followed by squamous metaplasia and incipient carcinoma.

There is some disagreement as to the actual incidence of primary carcinoma of the trachea. In 1938, Culp reported 147 cases of primary carcinoma of the trachea; McCafferty, in 1964, reported on 381 cases of tracheal carcinoma. In 97,355 autopsies, Ranke found 7 cases of primary tracheal malignancy or an incidence of 1 case per 13,900 necropsies. This figure is comparable to Culp's, and Keeney's finding of 1 primary tracheal cancer in every 15,000 necropsies. Our incidence at the Veterans Administration Center at Los Angeles, however, varies sharply with these findings. In the years 1947 to 1967, in 16,016 consecutive necropsies we found 8 histologically proven primary tracheal carcinomas. This is 1 tracheal carcinoma per every 2,002 necropsies, a figure considerably lower than any other previously reported. No doubt our predominantly elderly male population has much to do with our statistics. Then again, the fact that this is predominantly a disease of the man in his 50's and 60's has made us keenly aware of this malignancy in the differential diagnosis of disease of the upper respiratory tract.

As our social customs are changing, so too is the incidence of diseases affecting males and females. Culp's 147 cases in 1938 showed a male to female ratio of about 5 : 1. This figure has been reported by others. However, McCafferty, in 1964, had 235 male tracheal malignancies to 141 female. It will be interesting to see if this less than 2 : 1 ratio is repeated by others, showing in truth that the ladies are "smoking more and enjoying it less."

An unexplained phenomenon of carcinoma of the trachea is a tendency for the cases to come in groups or clusters with relatively long pauses between cases. This has been true also of our 9 cases over a 20 year period. We had one case in 1947, then none until 1953 to 1956 when we had a case a year. No tracheal carcinoma presented then until 1959 and 1960 when we diagnosed three more cases. It was then 1965 and 1967 when we saw our last two cases (Table I).

TABLE I

Age	Chief complaint	Time of onset SX to DX	Diagnosis made by	Location
42	Cough	12 mos.	Bronchoscopy	Sup $\frac{1}{3}$
63	Cough, dyspnea	6 mos.	Bronchoscopy #2	Inf $\frac{1}{3}$
70	Cough	12 mos.	Autopsy	Sup $\frac{1}{3}$
66	Cough, dyspnea	2 mos.	Bronchoscopy	Sup & Mid $\frac{1}{3}$
47	Substernal pain, dyspnea	23 mos.	Bronchoscopy #2	Inf $\frac{1}{3}$
67	Cough, dyspnea	8 mos.	Autopsy	Inf $\frac{1}{3}$
60	Cough, dyspnea	3 mos.	Laryngoscopy	Sup $\frac{1}{3}$
70	Hemoptysis	4 mos.	Bronchoscopy	Inf $\frac{1}{3}$
27	Dyspnea, wheezing	12 mos.	Surgery	Sup $\frac{1}{3}$

Average age: 57

NOTE: All patients smoked at least one pack of cigarettes per day.

PATHOLOGY

In a child, a tumor of the trachea has only a 7% chance of being malignant, but in the adult a tumor of the trachea has better than a 50% possibility of malignancy. However, when dealing with a lesion which has the potential of suddenly preventing the flow of life-giving oxygen, we must consider all lesions of the trachea as being of a malignant potential.

There are two major types of primary tracheal malignancies. These being epidermoid carcinoma and adenoid-cystic-carcinoma or cylindroma. Some unselected series list oat cell carcinoma, basal cell carcinoma, carcinosarcomas, and thyroid carcinomas as arising in the trachea. It is our feeling that most of these tumors are various stages or forms of squamous carcinoma or cylindroma, or perhaps because of late diagnosis represent primaries arising in areas other than the trachea and being secondarily invasive. Our series comprises eight cases of primary squamous carcinoma in males from the fourth to the seventh decade, and one adenocystic carcinoma in a young man of 27.

The site of origin of these tumors is either high in the trachea in the area of the first tracheal ring, or distally in the region of the carina. Our series reflects the majority of findings with predilection of the posterior lateral wall, 35% occurring near the carina, 55% in the subglottic region, and 10% arising in the mid-portion of the trachea.

DIAGNOSIS AND SYMPTOMS

Many years ago Chevalier Jackson cautioned that "all that wheezes is not asthma." In no other disease is this observation more pertinent than in tracheal carcinoma. In McCafferty's large series of 381 tumors, dyspnea was the predominant symptom in 71% of the patients. This assumes even added significance when one considers that the tracheal lumen must be occluded almost 75% before the symptom of shortness of breath is felt. Two other common symptoms of tracheal cancer worthy of consideration are the presence for many months of a hacking, non-productive cough with the sensation of tickling in the throat. More than a third of the patients present with an initial complaint of intermittent hemoptysis. For months, and sometimes even years, these patients may be treated for asthma, bronchiectasis, and repeated pneumonia before a definitive diagnosis is made.

The routine chest x-ray frequently fails to demonstrate the lesion, and although cytological washings show a close correlation with the presence of carcinoma, the follow-up examination may still miss the lesion. It is important that an experienced laryngologist examine these patients, for we had one patient come to us with a large lesion of the upper portion of the trachea which had been missed by bronchoscopy. This patient had positive bronchial cytologies but a "negative" bronchoscopy and was irradiated for bronchogenic carcinoma at another hospital. Six months later the patient was admitted here for terminal care, and autopsy showed the site of the positive cytology to be a tracheal carcinoma. Another patient underwent a right pneumonectomy for bronchogenic carcinoma, but when no malignancy was found in the specimen, bronchoscopy was repeated disclosing a tracheal carcinoma.

TREATMENT

We wish we had a revolutionary means of treating tracheal carcinoma with a large percentage of cures. Unfortunately our series is no better than most other series of tracheal cancers. Despite vigorous irradiation and surgical treatment, all eight of our tracheal squamous cell cancer patients died of their disease or its complications. The young man with adenocystic carcinoma has been controlled for several months with x-ray therapy following surgical excision of the gross tumor as it encroached on the tracheal lumen.

REPORT OF CASES

CASE 1. Mr. W.H.J., a 42 year old Caucasian male, was admitted December 16, 1946 with a history of fatigue, malaise and weight loss for almost one year. The patient's chief complaint was a nonproductive cough for which he had seen his private doctor. A chest x-ray had demonstrated pneumonia but there was no clinical or radiological improvement over a period of six weeks

treatment. Mr. J. was noted to be a smoker. Physical examination on admission revealed an emaciated man who coughed frequently. There was an inspiratory wheeze and diminished breath sounds at the base of the right lung.

The pneumonia resolved on penicillin and sputums were negative for acid fast bacillus. Because of the persistent cough and wheeze, bronchoscopy was performed exposing a broad-based mass protruding into the tracheal lumen from the posterior wall subglottically; esophagoscopy was unremarkable. The biopsy was read as squamous cell carcinoma and the Tumor Board recommended radiation therapy. The patient received 6750 r between February 6 and March 14, 1947. His hospital course was characterized by increasing dysphagia and wasting. He expired on April 6, 1947 having received much of his nourishment intravenously since completion of radiation therapy.

Necropsy revealed primary squamous cell carcinoma of the upper one-third of the trachea with direct invasion of the esophagus. Death was attributed to bronchopneumonia.

CASE 2. Mr. J.J.B. was admitted in July, 1952 for evaluation of cough and exertional dyspnea. The 63 year old patient reported smoking one and a half packages of cigarettes per day. Bronchoscopy revealed a lesion thought to be in the right main stem bronchus; the biopsy revealed squamous cell carcinoma. A right pneumonectomy was performed, but no tumor was found in the surgical specimen. Repeat bronchoscopy disclosed the tumor to be in the lower trachea. The Tumor Board recommended a course of radiation therapy which was repeated when follow-up bronchoscopy revealed viable cancer cells. The cough persisted and dyspnea progressed necessitating re-admission for nursing care in April, 1954; on June 3, 1954, the patient expired.

At autopsy the squamous cell carcinoma of the trachea was found to extend from the carina to the fourth tracheal ring and metastases were present in the left lung, paratracheal and hilar nodes.

CASE 3. Mr. H.L.M., a 70 year old white male, was admitted for terminal care on June 16, 1953. The patient had been seen initially at another hospital in September 1952 with superior vena caval syndrome, paroxysmal cough, and a mass in the right hilum on the chest film. Bronchoscopy failed to reveal a lesion but the right vocal cord was paralyzed and bronchial washings were positive for malignancy. The patient received a course of radiation therapy for bronchogenic carcinoma.

On admission here, the patient was comatose with a chest x-ray demonstrating destruction of part of the right clavicle and opacification of the right upper lobe. Parenteral feedings were started but the patient expired on June 22, 1953.

Postmortem examination revealed squamous cell carcinoma of the upper one-third of the trachea with regional lymph nodes extension and metastasis to the pancreas, liver, thoracic vertebrae, right clavicle, and lung.

CASE 4. Mr. C.L.M. was 66 years old when admitted on May 30, 1956, with a two month history of cough and severe dyspnea. The patient also reported dysphagia associated with a 30 pound weight loss and the sensation of heaviness high in the anterior chest. A history of heavy cigarette consumption was noted. Physical examination disclosed a chronically ill-appearing Caucasian male with loud stridorous respirations and suprasternal and intercostal retractions. No cervical masses were detected but movement of the thyroid cartilage was limited. The admission chest film demonstrated a superior mediastinal mass and a barium swallow demonstrated posterior displacement of the esophagus and concentric narrowing of the trachea. Direct laryngoscopy revealed a paralyzed right vocal cord and at bronchoscopy 2 cm below the cords an annular, necrotic lesion was discovered. Biopsy established the diagnosis of squamous cell carcinoma. Because of increasing dyspnea, a tracheotomy was performed through tumor and the Tumor Board's recommendation of radiation therapy was implemented. The patient's hospital course was marked by increasing dyspnea and subcutaneous emphysema of the face, neck and trunk. Bronchopneumonia accounted for the patient's demise on June 15, 1956 and necropsy revealed tumor extending along the right lateral wall from the cricoid 5 cm distally. Carcinoma had invaded the adjacent esophagus.

CASE 5. R.H.H., a 47 year old heavy smoker, was admitted on April 19, with an 18 months' history of left upper quadrant pain and a three days' history of substernal pain associated with dyspnea which was somewhat relieved by leaning forward. The patient had signs of pericardial effusion and confirmatory findings on roentgenologic examination. A pericardial tap was performed but development of cardiac tamponade prompted emergency surgery to make a pericardial window. The specimen of pericardium and the fluid were reported negative for malignancy. Multiple thoracenteses failed to reveal evidence of malignancy and work-up of gastrointestinal symptoms was unrevealing. The patient improved postoperatively on penicillin and antituberculosis medications. Bronchoscopy was reported within normal limits and the patient was discharged on July 1, 1959.

The patient was re-admitted in October of the same year with chest pain and fever. Chest films demonstrated massive enlargement of both hila and at bronchoscopy a lesion was detected just above the carina laterally which proved to be squamous cell carcinoma microscopically. The patient was judged to be inoperable as he rapidly developed signs and symptoms of superior vena caval obstruction. Radiation therapy was started but the patient expired on November 22, 1959.

At autopsy a squamous cell carcinoma was found one centimeter above the carina with metastases to the hilar nodes, epicardium, superior vena cava, small intestine, pelvic peritoneum and right retroperitoneal space surrounding the right adrenal, kidney, and ureter and causing right hydronephrosis.

CASE 6. Mr. C.F.N. was admitted on September 29, 1959 for evaluation of dyspnea and nonproductive cough present for six months. The patient was 67 years old and acknowledged smoking at least one pack of cigarettes each day for 30 years. A temperature of 102.6 was recorded on admission and the patient noted to be emphysematous. A tracheotomy was performed on the second hospital day because of tenacious secretions and after two weeks' treatment with antibiotics, the patient became afebrile. On November 5, 1959, the patient experienced severe dyspnea with cyanosis which responded to tracheal suctioning, aminophylline and steroids. These symptoms were recurrent over the next 24 hours and the patient expired on November 6, 1959 during one such episode.

A "large walnut-shaped mass" 2 cm above the carina was found obstructing the trachea on postmortem examination. There was no evidence of distant metastasis or carcinoma of the lungs, but the pathologist did note extensive metaplasia of the trachea with sites of carcinoma-in-situ in addition to the polypoid squamous cell carcinoma which obstructed the trachea.

CASE 7. Mr. H.L.N., a 60 year old male, was admitted on September 2, 1960, with a cough and difficult breathing for 8 to 10 weeks. The patient had a history of Laennec's cirrhosis and of smoking one and one-half packs of cigarettes daily for 30 years. Inspiratory stridor and a 1 cm left cervical node were noted on physical examination. The chest film suggested a tracheal mass and planigrams demonstrated a 2x5 cm lesion 1.5 cm below the larynx. Direct laryngoscopy and biopsy established the diagnosis of squamous cell carcinoma of the trachea. Resection of the neoplasm was planned but at surgery there was extensive paratracheal and mediastinal involvement and it was the surgeon's opinion that the lesion could not be cleared. A tracheotomy was performed and the patient referred to the radiotherapist. Progressive weakness and hepatomegaly were noted and the patient expired on October 30, 1960. Necropsy confirmed the diagnosis of primary tracheal carcinoma with metastasis to the liver, spleen and marrow.

CASE 8. Mr. E.C.S., a 70 year old man, was admitted on November 5, 1964 and underwent bronchoscopy to evaluate hemoptysis of 3 to 4 months' duration. The patient was a one to one and a half pack per day smoker. Bronchial washings revealed malignant cells and biopsy of a lesion at the carina established the diagnosis of squamous cell carcinoma. The Tumor Board recommended radiation therapy and the patient received 4641 r. A repeat bronchoscopy and biopsy revealed viable cancer cells and at the patient's request, transfer

to his home state VA hospital was arranged for recommended surgery. On February 18, 1965 a carinal resection with Marlex[®] grafting was performed utilizing the cardio-pulmonary by-pass. The patient became oliguric and expired on his fourth postoperative day. No residual carcinoma was detected on postmortem examination.

CASE 9. Mr. F.G.R., the youngest patient in our series, a 27 year old Negro male, was admitted on January 9, 1967 with increasing shortness of breath of one year's duration. The patient denied cough or hemoptysis but did report some dysphagia. He had smoked one to one and one-half packs of cigarettes daily for eight years. X-rays with barium in the cervical esophagus demonstrated a mass between the trachea and esophagus which compressed both structures. A bronchoscope could not be passed beyond the mass and because of dramatically increased dyspnea the patient was taken to surgery on January 20, 1967 to relieve tracheal compression. A 5x8 cm retrotracheal mass was found compressing the trachea between the first and sixth rings and was noted to be attached to the right lobe of the thyroid. The diagnosis on frozen section was "embryonal thyroid adenoma" and the mass was subsequently dissected with difficulty from the posterior tracheal wall; the specimen included the right lobe of the thyroid. Permanent sections of the tumor were reported as adenoid-cystic carcinoma with invasion of the right lobe of the thyroid. The patient's postoperative course was uneventful with markedly improved breathing. Radiation therapy was initiated on the recommendation of the Tumor Board.

SUMMARY

In summary we have found primary tracheal cancer a rare disease in the general medical population, but not an uncommon disease for the laryngologist. The use of tobacco must play a significant part in the etiology of this disease and the cleansing action of the cilia aids to considerably lessen its incidence.

Tracheal carcinoma should be suspected in the patient with a normal chest x-ray who presents with a history of dyspnea, cough, and hemoptysis which is reinforced by positive sputum cytology.

VETERANS ADMIN. CENTER, WILSHIRE AND SAWTELLE BLVDS.
LOS ANGELES, CALIF. 90073

Grateful appreciation is extended to Dr. Uwanie Tomiyasu for her indispensable assistance in preparing the pathological material, and to Dr. Thomas J. McDevitt for assistance in preparation of the manuscript.

REFERENCES

1. Ash, J. E., and Raum, M.: An Atlas of Otolaryngic Pathology. U.S. Armed Forces Inst. of Pathol., Washington, D.C., 1956.
2. Beattie, E. J., Staub, E. W., Correll, N., and Hass, G.: Bronchogenic Carcinoma Produced Experimentally in the Dog. Jour. Thoracic and Cardiovasc. Surg. 42:615, 1961.

3. Culp, O. S.: Primary Carcinoma of the Trachea. *Jour. Thorac. Surg.* 7:471, 1938.
4. Dalby, J. E., and Jones, R. F. M.: Primary Malignant Growths of the Trachea. *Acta Otolaryngol.* 53:12, 1961.
5. Fleming, R. J., Medina, J., and Seaman, W. B.: Roentgenographic Aspects of Tracheal Tumors. *Radiology* 79:628, 1962.
6. Frable, W. J., and Wheelock, M. C.: Carcinoma of the Trachea. *Arch. Otolaryngol.* 76:174, 1962.
7. Gilbert, J. G., Mazzarella, L. A., and Feit, L. J.: Primary Tracheal Tumors in Infants and Adults. *Arch. Otolaryngol. (Chig.)* 58:1, 1953.
8. Grillo, H. C.: Circumferential Resection and Reconstruction of the Media Stinum and Cervical Trachea. *Ann. Surg.* 162:374, 1965.
9. Grillo, H. C.: Management of Cervical and Mediastinal Lesions of the Trachea. *J.A.M.A.* 197:1085, 1966.
10. Holinger, P. H., Novak, F. J., and Johnston, K. C.: Tumors of the Trachea. *Laryngoscope* 60:1086, 1950.
11. Mathey, J., Binet, J. P., Galey, J. J., Evrard, C., Lemoine, G., and Denis, B.: Tracheal and Tracheobronchial Resection. *Jour. Thoracic and Cardiovasc. Surg.* 51:1, 1966.
12. McCafferty, G. J., Parker, L. S., and Suggit, S. C.: Primary Malignant Disease of the Trachea. *Jour. Laryngol. and Otol.* 78:441, 1964.
13. Miglets, A. W.: Primary Tracheal Carcinoma. *Laryngoscope* 75:1853, 1965.
14. Parrish, C. M., and Jones, R. E.: Primary Tracheal Tumors. *Amer. Surg.* 26:95, 1960.
15. Ranke, E. J., Presley, S. S., and Holinger, P. H.: Tracheogenic Carcinoma. *J.A.M.A.* 182:519, 1962.
16. Salm, R.: Primary Carcinoma of the Trachea: A Review. *Brit. Jour. Dis. Chest* 58:61, 1964.
17. Waddell, W. R.: Extensive Resection of the Trachea for Cancer. *Trans. Am. Acad. Ophth. Otolaryngol.* 63:761, 1959.

DISCUSSION

DR. JOSEPH P. ATKINS: Dr. Acquarelli's presentation has been extremely interesting and the incidence which he has reported to us of "Carcinoma of the Trachea" is rather astonishing. It is unusual to see a group of cases so large as this.

We have had at least four instances of tracheal malignancies. One of these was a squamous cell carcinoma at the lower end of the trachea involving the right posterior wall. The patient's complaint was hemoptysis. He was treated by super-voltage irradiation about five years ago. I saw him a month ago. He was completely asymptomatic and had a perfectly normal chest x-ray. After following this patient for about three years, I had our pathologists review these biopsies which they did. They have insisted that their diagnosis is correct on reviewing the original biopsies.

A second patient was a woman with a pedunculated cylindroma of the upper trachea which almost occluded the organ. This was removed endoscopically and the base cauterized. She lived twelve years thereafter and died of a heart lesion with no evidence of tracheal disease. Unfortunately, she lived upstate and we did not have the opportunity to get an autopsy. We, therefore, do not know for certain that her disease was completely eradicated.

We have a third patient who presented the symptoms of asthma and a negative chest x-ray, as did a number of the cases reported this morning. The internist who was caring for him said, "We will do a bronchoscopy on this patient just because this isn't behaving quite like asthma,

although everything else indicates that it is asthma." This patient had a sessile cylindroma which was treated by irradiation. This palliated him for about three years during which time we occasionally had to go back and core tumor out of the airway. In spite of the fact that we did not cure this patient, he did receive real palliation.

Our most recent case is still in the hospital. She is a woman in her late forties who had an obstructive lesion in the trachea at the level of the suprasternal notch. The mass obstructed the trachea for a distance of about three centimeters. The diagnosis was made bronchoscopically. The lesion was removed by an external approach, seven rings of the trachea were excised and a primary anastomosis of the trachea carried out. Her postoperative course was uneventful. Just before I came to this meeting, we examined her bronchoscopically and found that her tracheal lumen is excellent. One thing that helped us in getting satisfactory approximation after removal of seven rings of the trachea is that the hyoid bone was cut in this instance so that the attachment of the larynx to the styloid process at the base of the skull was partially overcome by allowing the larynx to descend in the neck. We got additional room to close the trachea. A number of years ago, Dr. Oscar Batson reminded us that the trachea is suspended from the base of the skull through the styloid process and the stylohyoid ligaments. This connection must be relaxed before the larynx can freely drop down into the lower neck. It is remarkable that this technique has not been utilized in repairing tracheal defects before but, so far as I know, this is the first application of this anatomic effect to this problem. We have no idea whether this patient is cured, but at least we have a successful resection and anastomosis.

DR. DOUGLAS P. BRYCE: I really wanted to report an interesting case of Dr. Ireland's, whom we saw last fall: a woman who had what for all the world looked like a foreign body in her trachea. It looked like a button. On examination by bronchoscope this turned out to be a circular, pedunculated mucoepidermoid tumor of the trachea. This was removed by bronchoscopy and eventually that section of the trachea was removed and no tumor was found in the base, so this, we hope, will represent a cure.

One further thing I would like to mention: in the past year and a half we have had three adenocystic carcinomas of the trachea and these have been resected and as a palliative procedure we have replaced that section of the trachea, which is quite a long one, with a Marlex tube. This has turned out to be a good palliative procedure, although by using Marlex we have not been able to prevent granulation formation.

DR. LAWRENCE BOIES: I would like to ask Dr. Acquarelli if he employs tomography in these cases?

DR. ACQUARELLI: Some of these cases came to us from the outside areas and the diagnoses were easily made. We did use the tomograms on several of the cases. There are also bronchoesophagrams, etc., but the diagnoses on some of these were pretty well established at this stage of the game.

PRESIDENT PRESSMAN: Do these lesions show on x-ray at all? Are they diagnosable by x-ray?

DR. ACQUARELLI: None of these were diagnosed by x-ray.

Memorials

KARL MUSSER HOUSER, M.D.

1893 - 1967

Dr. Karl M. Houser, Emeritus Professor of Otolaryngology at the University of Pennsylvania School of Medicine and the Graduate School of Medicine of the University of Pennsylvania, died in Philadelphia, Pennsylvania on January 5, 1967.

Born in Pennsylvania Furnace, Huntington County, Pennsylvania, on September 30, 1893, the son of a physician, Dr. Houser spent his early life in this vicinity and attended both Franklin and Marshall Academy and Franklin and Marshall College, graduating from the latter in 1915. His medical training was obtained at the University of Pennsylvania, where he graduated in 1921, and received a Master of Science from the same institution in 1926. After serving a rotating internship and chief residency at the University of Pennsylvania Hospital, he began the study of laryngology under Dr. George Fetterolf in the Graduate Hospital of the University of Pennsylvania.

He became a member of numerous professional organizations including the American Laryngological Association, the American Academy of Ophthalmology and Otolaryngology, the American Laryngological, Rhinological, and Otolological Society, the American Otological Society, and the American College of Surgeons. He held honorary memberships in the Society of Sigma Xi and Alpha Omega Alpha Fraternities.

His medical life was spent in Philadelphia on the staff of the University of Pennsylvania Hospital, the Graduate School of Medicine, and Delaware County Hospital. He maintained a flourishing otolaryngological practice and reputedly counted the elite of Philadelphia society as his patients. As Professor of Otolaryngology at his alma mater, his chief interest was in nasal and sinus disease although he practiced all phases of the specialty.

A serious automobile accident some years prior to his death forced a marked curtailment in his medical practice as well as other activities since he had considerable difficulty moving around. His retirement was hastened by this unfortunate occurrence.

Golfing and fishing were his diversions while stamp collecting was a hobby.

He is survived by his wife, the former Grace Ellen Shipley, whom he married in September, 1925, and two boys, Karl Musser Houser, Jr., and Luther Murray Houser II.

F.J.P.



KARL MUSSER HOUSER

DEFOREST CLINTON JARVIS, M.D.

1880 - 1966

The author of *Folk Medicine* and *Arthritis and Folk Medicine*—both of which books were on the best-seller list of the New York Times for more than seventy-five weeks—(along with an earlier article in *Fortune* magazine) gave to the public a philosophy and conviction concerning the practice of medicine that sold more than a million copies in this country, England, Canada and Ireland and encouraged their translations into French, Portuguese and Spanish.


So far as known no one ever disliked Dr. Jarvis nor questioned his honesty or sincerity but few of his colleagues subscribed to his theories or methods of experimentation.

But his life was broader and more effervescent than “honey and vinegar” and “alkaline or acid ash” diets.

A Vermonter!—Yes. A country doctor!—Yes, but most emphatically was he a citizen par excellence. For years he was instrumental in organizing and conducting the Barre Symphony orchestra for young people. He was a physician and coach to local football teams, an adviser to cattle and horse men and a churchman, too.

“Controversial”—“polemic”—and “disputatious” are words aptly attached to Dr. Jarvis who—right or wrong—gave of himself to what he considered the welfare of mankind.

C.S.N.



DEFOREST CLINTON JARVIS

PHILIP EDWARD MELTZER, M.D.

1895 - 1967

Few physicians devoting their major professional life to the practice of Otolaryngology have brought to it more enthusiasm, more technical proficiency or more interest in teaching and the day-to-day care of patients than did Philip E. Meltzer. Endowed with an abundance of physical energy, with what the great John Hunter called "the great curiosity" and with a ceaseless aim toward perfection in all his work, he achieved in his most productive years a national and international reputation rarely attained in this highly competitive age. His literary contributions were numerous and diverse, his operative skill was the envy of his colleagues and the gratitude of countless patients marked him not only as a fine physician but a great humanitarian. His death on March 7, 1967 deprived the specialty of one of its most distinguished members and the community of a beloved public servant.

Philip Meltzer was born in Boston March 17, 1895 and maintained a lifelong residence in that city. Following his graduation from high school he entered Tufts University Dental School from which he graduated in 1915. Deviating from his initial intention to practice dentistry, he entered Tufts Medical School from which he graduated in 1918. This unconventional and seemingly superfluous training in dentistry was destined in later years to prove of inestimable value in Dr. Meltzer's later work in aural surgery, accustoming him, as it did, to work in relatively inaccessible areas, with instruments of almost microscopic size and under indirect illumination and magnification.

The medical school years were followed by an internship at the Massachusetts Eye and Ear Infirmary and this in turn by the opening of an office for private patients, by work in out-patient clinics and in hospital wards. During the early 1920s what time could be spared from a growing family and the ever-increasing demands of the office was devoted to anatomical study in the dissecting room and laboratories, work which laid the foundation for a knowledge of the intricate structures of the temporal bone. More and more consulting attachments to local and suburban hospitals made added demands on a seemingly inexhaustible supply of energy and professional interest and enthusiasm. In 1931 Dr. Meltzer supplied the major impetus to the Harvard Medical School Graduate Course in Otology with the sacrifice of hours, both day and night, which by many a less dedicated worker might have been devoted to leisure and recreation. Scattered throughout the country today are otolaryngologists who have good reason to feel grateful for the hours they spent under his stimulating instruction and encouragement.



PHILIP EDWARD MELTZER

While always interested in the broad aspects of Otolaryngology, Dr. Meltzer, with the passing years, leaned more and more toward a special interest in Otology and problems relating to the treatment of deafness. The concept of some practical surgical approach to the restoration of hearing in patients afflicted with otosclerosis had intrigued many an otologist since the early 1890s when Dr. Frederick Jack conceived the idea of an operative attack on fixation of the stapes. Efforts toward this were ultimately abandoned, as yielding too disappointing results. It was not until many years later that the work of Dr. Julius Lempert in fenestration of the labyrinth reawakened an interest in this problem. With far-sighted perspective as to the possibilities of this operation Dr. Meltzer became one of Dr. Lempert's most devoted and hard-working disciples, making in 1945 repeated semi-weekly trips from Boston to New York, becoming in Boston one of the pioneers of this newer concept. Stimulated by the early encouraging results in fenestration, he became the prime factor in the development at the Massachusetts Eye and Ear Infirmary of what became known as the Winthrop Foundation. Through the generosity and support of Mr. Frederick Winthrop and under the enthusiastic stimulation of Dr. D. Harold Walker, Professor of Otology at the Harvard Medical School, the Foundation was soon providing a much needed service to patients suffering from otosclerosis. It will never be known how much time and effort Dr. Meltzer devoted to the progressive development of this work and the personal attention and sacrifice of other personal interests which he gave to it.

Unlike many of today's otologists, Dr. Meltzer came to the practice of Otolaryngology long before the advent of chemotherapy and was therefore quite familiar with the many problems and frustrations characterizing otitic suppuration in its manifold forms. He had therefore a broad perspective which ranged over the wide areas between simple serous otitis and surgery for the deaf. Indeed the breadth of his otolaryngological interest was manifested in several of his latest writings, directed to a consideration of an improved technique for the removal of the humble adenoid.

The transition from the early fenestration operation to the less complicated procedure of stapes mobilization was, for many of the enthusiasts of the former, not an easy one. It was a mark of Dr. Meltzer's breadth of vision that he was able to accept the merits of the latter and with each succeeding year to perfect his operative technique and to attain continuously better results. He became an enthusiastic member of the Otosclerosis Study Group, a project developed under the aegis of the American Academy of Ophthalmology and Otolaryngology. It was no surprise when he was made an active member of the American Board of Otolaryngology.

For two decades Dr. Meltzer was Professor of Otolaryngology at Tufts University Medical School, and during the interim between the termination of

Dr. LeRoy Schall's tenure as Chief of Otolaryngology at the Infirmary and the arrival of Dr. Harold Schuknecht, he assumed this burden and heavy responsibility in addition to all his other duties. Dr. Meltzer's teaching capacity, his concise and lucid lectures and above all his enthusiasm for imparting his knowledge to students were only one more evidence of his stature as a teacher, clinician and surgeon. His generous contributions to the literature and his lengthy bibliography clearly indicate the breadth of his interest in and sound knowledge of the specialty. His many society memberships included the American Laryngological Association, the Triological Society of which he was a Vice-President and Eastern Section Chairman, and the American Otological Society. In 1949 he was elected a Vice-President of the latter and in 1950 became its President, as high an honor as any to which an otologist can aspire, and clear evidence of the esteem in which Dr. Meltzer was held by his colleagues. His Presidential address, summarizing the progressive developments in Otology, is in itself a picture of his own many-sided interest in all phases of his work and his appreciation of the many contributions by others who have done so much to advance a once rather simple science to the complex entity as we know it today. This address is likewise a masterpiece of exposition, of competence in the use of the English language and the ability to express with clarity and conciseness the author's knowledge of a highly technical and many-sided subject.

Dr. Meltzer was a frequent participant in postgraduate courses and seminars, always bringing to them something of practical value and stimulation to those privileged to attend. All these activities were superimposed on an ever-increasing private practice with a daily patient load that would seem staggering to many a less energetic and dedicated physician. One might well wonder whether under the burden of such a professional load Dr. Meltzer ever found time for relaxation and recreation. Somehow, he managed intermittent fishing and hunting trips to Canada, an area where he could, for a time at least, be beyond the reach of the telephone. To the former of these hobbies he undoubtedly brought the same meticulous attention to equipment and technique as to his beloved mobilizations.

Dr. Meltzer died suddenly on March 7, 1967 at the age of 72, having been in the best of health the previous day in the office. Perhaps characteristic of his incredible store of energy was the fact that his death followed soon after an unwise and wholly unnecessary engagement with a snow shovel. He is survived by three daughters, Mrs. Phyllis Baye and Mrs. Joan Schwartz of Newton Center, Mass. and Mrs. Marilyn DeNoon of Coral Gables, Florida. Mrs. Meltzer died in 1955. Her loss had for its only compensation a furthering of the intensity with which Dr. Meltzer applied himself to the many aspects of his work.

Otolaryngology has lost one of its pioneers in the advancement of its horizons, a superb teacher, a dedicated, sympathetic and skillful clinician and a master surgical technician.

L.G.R.

SAM E. ROBERTS

1887 - 1966

Sam E. Roberts, M.D., a physician in Kansas City for more than 50 years, Professor of Otolaryngology at the University of Kansas School of Medicine, and a member of the American Laryngological Association, died unexpectedly at his home on July 18, 1966, of a heart attack.

After keeping a busy office schedule the same day, he spent a quiet evening at home and suddenly expired 30 minutes after retiring. Ironically, Dr. Roberts had just completed, two weeks previously, the manuscript of a medical text entitled, "Exhaustion, Its Causes and Treatment."

Dr. Roberts was born on October 28, 1887, in Concordia, Kansas. He graduated from the University of Kansas School of Medicine in 1911 and had postgraduate work at the University of Vienna, Austria, and the University of London, England. In his years of developing his practice, he became known among his colleagues as a voluminous contributor. One of his books gave him international stature. "Dysfunction of the Ear, Nose and Throat," published in 1957 and translated into seven languages, was the publication. Dr. Roberts was a member of and received a citation from the American Academy of Medical Writers and Authors.

In recognition of his work, particularly in this field, the University of Kansas Medical Center dedicated the Sam E. and Mary Roberts Biochemistry Library in November, 1961. He developed the Sam E. Roberts Laryngoscope in 1948, which eliminated shadows and reflections and combined the good qualities of three different instruments. Dr. Roberts also developed several other surgical instruments.

Dr. Roberts' hospital and teaching appointments include the following: Executive Staff and Head of the ENT Department, Research Hospital, Kansas City, Missouri; Professor and Head of the Department of Otorhinolaryngology, University of Kansas Medical Center for 35 years. At the time of his death, he was an active Professor Emeritus. He taught 35 years at the American Academy of Ophthalmology and Otolaryngology.

His society affiliations (social) included Delta Upsilon and Phi Beta Pi. Alpha Omega Alpha was his honorary medical. Professional and scientific societies were the following: The American Laryngological Association, the American Broncho-Esophagological Association of which society he was Guest of Honor in



SAM E. ROBERTS

1964 at Hollywood Beach, Florida, the Triological Society, and the American College of Surgeons (he was a Fellow). Dr. Roberts was certified by the American Board of Otolaryngology in 1925. He was a Diplomate of the American Academy of Ophthalmology and Otolaryngology, and on the Council for three terms.

Dr. Roberts served in World War I as a Captain in the Medical Corps of the United States Army.

Dr. Roberts is survived by his wife, three daughters and 11 grandchildren.

The Roberts' home and garden have been graciously shared with his family, friends, patients, and medical confreres and students.

It is a sad, but pleasant honor, to be asked to write "Dr. Sam's" (as he was affectionately called) obituary. He was my Preceptor in 1929-1932, and appointed me to the University of Kansas School of Medicine faculty. The Weekly ENT Clinical Conferences were a "must" in his program, and we all gained much from his experiences and knowledge. His example of the good doctor doing much for his fellow man will endure. He has been a remarkable person.

J.S.K.

Executive Sessions

OPENING SESSION

EXECUTIVE SESSION

MONDAY MORNING, MAY 15, 1967

The Opening Session of the Eighty-eighth Annual Meeting of the American Laryngological Association, Inc., held at the Seignior Club, Montebello, Canada, convened in the Ballroom on Monday morning, May 15, 1967, at eight-thirty o'clock, Joel J. Pressman, M.D., President of the Association, presiding.

The following candidates were elected to Fellowship:

Active Fellowship

Dr. Loring Pratt, of Waterville, Maine

Dr. Edwin Cocke, of Memphis, Tennessee

Dr. William Tribble, of Washington, D.C.

Emeritus Fellowship

Dr. John R. Lindsay

Honorary Fellowship

Dr. Dean M. Lierle

PRESIDENT PRESSMAN: In the name of the Association we welcome into Fellowship: Dr. Pratt, Dr. Cocke and Dr. Tribble. We feel this expression of confidence on the part of the Association is one which each of you deserves very much indeed. We hope the opportunities the Association will offer to you will justify your having been willing to become Fellows and that the Association itself will give you many opportunities to be of service to the specialty that otherwise would not have been available to you.

Gentlemen, you are more than welcome into this Association. We are proud and pleased to have you.

We now have to elect a Nominating Committee. May we have nominations from the floor, please?

The following were then elected following nomination from the floor:

Frank D. Lathrop, M.D., Boston, Mass.

Kinsey M. Simonton, M.D., Rochester, Minn.

Francis A. Sooy, M.D., San Francisco, Calif.

James A. Harrill, M.D., Winston-Salem, N. C.

Robert E. Priest, Minneapolis, Minn.



ANNUAL BUSINESS MEETING

TUESDAY MORNING, MAY 16, 1967

The Annual Business Meeting of the Association convened in the Ballroom on Tuesday morning, May 16, 1967, at eight-fifteen o'clock, President Pressman presiding.

Secretary Richards then presented the report of the Secretary.

REPORT OF THE SECRETARY

The Eighty-seventh Annual Meeting of the American Laryngological Association was held on April 23 and 24, 1966 at the Americana Hotel, San Juan, Puerto Rico. The President, Dr. Paul Holinger, presided. Thirteen scientific papers were presented. Seventy-four Fellows and 80 Guests were in attendance. The Librarian, Historian and Editor, Dr. F. Johnson Putney, reported the deaths of:

Honorary Fellow: Arthur W. Proetz

Emeritus Fellows: Roy A. Barlow, Fred Z. Havens, Fred W. Dixon,

Edward J. Whalen

The deRoaldes Award and Gold Medal were presented to Dr. Paul H. Holinger.

The Newcomb Award was presented to Dr. Lyman G. Richards.

The Casselberry Award was presented to Dr. John A. Kirchner and Mr. Barry Wycke.

The following were elected to Fellowship:

Active

Dr. Kenneth D. Devine, Rochester, Minn.

Dr. John S. Lewis, New York, N. Y.

Dr. Brian F. McCabe, Iowa City, Ia.

Emeritus

Dr. Paul A. Campbell, San Antonio, Tex.

Dr. Bernard J. McMahon, Clayton, Mo.

Dr. Walter H. Theobald, Chicago, Ill.

Corresponding

Dr. Gosta Dohlman, Toronto, Canada

Honorary

Dr. Jo Ono, Japan

The following officers were elected for the coming year:

President: Dr. Joel J. Pressman

First Vice-President: Dr. Lawrence R. Boies

Second Vice-President: Dr. G. Edward Tremble

Secretary: Dr. Lyman G. Richards

Treasurer: Dr. Alden H. Miller

Librarian, Historian, Editor: Dr. F. Johnson Putney

First Councilor: Dr. Francis E. LeJeune

Second Councilor: Dr. Anderson C. Hilding

Third Councilor: Dr. Albert C. Furstenberg

Fourth Councilor: Dr. Paul H. Holinger

The next Annual Meeting will be held at the Hollywood Beach Hotel, Hollywood, Florida on April 25 and 26, 1968. The Triological Society, the American Broncho-Esophagological Association and the Society for Head and Neck Surgery will meet from April 21 to 26. The American Otological Society will celebrate its 100th Anniversary meeting April 18 to 20.

Since the last Annual Meeting the Association has lost through death the following:

Dr. Sam E. Roberts, an Active Fellow since 1953, who died on
July 18, 1966

Dr. DeForest C. Jarvis, an Emeritus Fellow since 1951, who died on
August 18, 1966

Dr. Karl M. Houser, an Emeritus Fellow since 1955, who died on
January 5, 1967

Dr. Philip E. Meltzer, an Active Fellow since 1954, who died on
March 7, 1967.

The present Fellowship of the Association is:

Active 96 Honorary 4 Corresponding 14 Emeritus 24 Total 138.

Respectfully submitted,
Lyman G. Richards, M.D., Secretary

(Treasurer Miller then presented the report of the Treasurer.)

REPORT OF THE TREASURER

Exhibit A

AMERICAN LARYNGOLOGICAL ASSOCIATION
GENERAL FUND OPERATING STATEMENT AND
STATEMENT OF GENERAL FUND BALANCE

For the Year Ended March 31, 1967

Income

Dues:

Ninety (90) members at \$75.00	\$6,750.00	
Three (3) new members at \$115.00	345.00	\$ 7,095.00

Sales of <i>Transactions</i>		916.00
Registration fees—Annual meeting		580.00
Interest received on savings accounts		863.06
		<u>\$ 9,454.06</u>

Expenses

Annual meeting—1966:

Banquet and cocktail party	\$1,598.95	
Speaker	500.00	
Projectionist	248.00	
Reporting service	385.47	\$2,732.42
		<u>1,520.67</u>
Council expenses (travel, room rental and luncheon)		1,520.67
Cost of <i>Transactions</i>		2,944.49

General expenses:

Stationery, printing and postage	\$1,414.69	
Clerical hire	300.00	
Auditing	150.00	
Treasurer's bond	63.00	
Donation	100.00	
Loss on Canadian exchange	26.61	
President's key	13.25	2,067.55
		<u>9,265.13</u>

Net profit for the year		\$ 188.93
General Fund balance, April 1, 1966	\$9,226.61	
Adjustment to correct prior year's distribution of loss on redemption of bonds	1,784.50	11,011.11
		<u>\$11,200.04</u>
General Fund balance, March 31, 1967		\$11,200.04

The accompanying accountants' letter is an integral part of this statement.

Exhibit B

AMERICAN LARYNGOLOGICAL ASSOCIATION
TRUST FUND OPERATING STATEMENT AND
STATEMENT OF TRUST FUND BALANCE

For the Year Ended March 31, 1967

Income

Interest on government bonds		\$	720.41
Dividends on common stock			173.35
Dividends from investment fund:			
Received in cash	\$	214.29	
Reinvested in fund		1,091.64	1,305.93
			<hr/>
			\$ 2,199.69
Expense—Loss on bond redemption			4.00
			<hr/>
Net income for the year			\$ 2,195.69
Trust Fund balance, April 1, 1966 (Exhibit C)	\$56,586.92		
<i>Deduct:</i>			
Grants and prizes disbursed during the year	\$3,200.00		
Adjustments to correct prior year's distribution of loss on redemption of bonds	1,784.50	4,984.50	51,602.42
			<hr/>
Trust Fund balance, March 31, 1967			\$53,798.11

COMPOSITION OF TRUST FUND

Cash		\$	6,387.88
Accounts receivable			259.00
Investments: (Exhibit D)			
Government bonds (at cost, par and maturity values)	\$13,500.00		
Common stocks:			
Purchased (at cost)	\$5,189.27		
Donated (market value at date of donation)	2,362.00	7,551.27	
			<hr/>
Investment fund stock (at cost)	26,099.96	47,151.23	
			<hr/>
			\$53,798.11

CASH RECAPITULATION

Cash in commercial account		\$	1,970.18
Cash in savings account			5,617.74
Cash in time certificates of deposit			10,000.00
			<hr/>
			\$17,587.92
<i>Distribution:</i>			
General Fund	\$11,200.04		
Trust Fund	6,387.88		
			<hr/>
			\$17,587.92

The accompanying accountants' letter is an integral part of this statement.

Exhibit C

AMERICAN LARYNGOLOGICAL ASSOCIATION
REPORT OF TRUST FUNDS
March 31, 1967

Fund	Principal and Unused Income 4-1-66	Income (Note 1)	Disbursed	Adjustments (Note 2)	Principal and Unused Income 3-31-67
Casselberry	\$ 8,267.19	\$ 320.78	\$ (200.00)	\$ (260.71)	\$ 8,127.26
Johnston	7,468.37	289.79		(235.52)	7,522.64
De Roaldes	5,140.11	199.45		(162.10)	5,177.46
Newcomb Trust	2,932.12	113.77		(92.47)	2,953.42
Newcomb Prize	684.38	26.55		(21.58)	689.35
Research	26,309.29	1,020.86	(3,000.00)	(829.68)	23,500.47
Memorial	5,785.46	224.49		(182.44)	5,827.51
	<u>\$56,586.92</u>	<u>\$2,195.69</u>	<u>\$ (3,200.00)</u>	<u>\$ (1,784.50)</u>	<u>\$53,798.11</u>

Note 1—Income is allocated according to the ratio each fund bears to the total fund at the beginning of the year.

Note 2—Adjustment required to correct a prior year's distribution of loss on redemption of bonds which had been charged to the General Fund.

The accompanying accountants' letter is an integral part of this statement.

Exhibit D

AMERICAN LARYNGOLOGICAL ASSOCIATION
TRUST FUND INVESTMENTS
March 31, 1967

U. S. GOVERNMENT BONDS (at cost, par and maturity values):

	Quantities	Denomination		
Negotiable: 3 7/8% Treasury bonds	7	\$1,000		\$ 7,000.00
Non-negotiable: Series H bonds	6	1,000	\$6,000.00	
	1	500	500.00	6,500.00
				<u>\$13,500.00</u>

COMMON STOCKS:¹

	Number of Shares	Cost	Market Value at Date of Donation	
American Telephone & Telegraph	70	\$4,845.02		
International Business Machines	1		\$ 517.00	
International Business Machines ²	2	344.25		
McDonnell Aircraft Corp. ³	112		1,170.00	
McIntyre-Porcupine Mines, Ltd.	15		675.00	
		<u>\$5,189.27</u>	<u>\$2,362.00</u>	<u>7,551.27</u>

Investment fund (at cost):¹

Boston Fund, Inc.	2,636.967 shares	26,099.96
		<u>\$47,151.23</u>

¹ At March 31, 1967 common stocks had a market value of approximately \$11,200.00 and investment fund stock a market value of approximately \$24,400.00.

² Includes 1 1/4 shares received as a stock dividend.

³ Includes 86 shares received as a stock dividend.

The accompanying accountants' letter is an integral part of this statement.

ACCOUNTANTS' REPORT

To the Members of the American Laryngological Association—
Gentlemen:

We have examined the accounts and financial records of the American Laryngological Association for the year ending March 31, 1967.

Cash receipts and disbursements were verified and all stocks and bonds were examined or properly accounted for.

In our opinion, the accompanying statements present fairly the cash position of the American Laryngological Association as of March 31, 1967 and the results of its cash operations for the year then ended.

Respectfully submitted,
SERENE, KOSTER & BARBOUR
Certified Public Accountants

DR. LATHROP: The Nominating Committee has selected the following members as nominees for members of the Council:

Dr. Boies
Dr. Daly
Dr. Friedberg
Dr. Richards
Dr. Alden Miller
Dr. Putney
Dr. Hilding
Dr. Furstenberg
Dr. Holinger
Dr. Pressman

(The report of the Nominating Committee was unanimously accepted.)

(F. Johnson Putney, M.D. then presented the Report of the Librarian, Historian and Editor.)

REPORT OF THE LIBRARIAN, HISTORIAN AND EDITOR

The eighty-seventh annual meeting of the American Laryngological Association was held on April 23 and 24, 1966 at the Americana Hotel, San Juan, Puerto Rico. There were 77 members in attendance. The meeting was ably reported by the Martin C. Johnson reporting service, whose representative, Mrs. Annabella Square, gave efficient and dependable service as usual. The completed papers were sent to the Annals Publishing Company within two weeks and were

published in the June issue of the *Annals*. All of the material for the 1966 *Transactions* together with the corrected discussions were in the hands of the printer by September, 1966 and the *Transactions* were mailed to the membership on December 1, 1966.

The present editor of the *Annals* has given us complete cooperation in the matter of speeding up publication of the *Transactions*. Priority will be given to our Association every other year alternating with the American Otological Association. The delay in the past has not been in the printing of the manuscripts, for the typesetting for this has been available after publication of the *Annals*, but considerable time has been lost in the binding of the *Transactions*. It is anticipated that some of the delay will be eliminated since an additional firm for binding has been obtained. It is imperative that all papers be turned in at the annual meeting in their final form ready for publication. Invariably delays result from last minute changes and corrections by the authors so that the final manuscript is not available at the time of the annual meeting. Forwarding of the completed manuscript with illustrations prior to the annual meeting to the *Annals* Publishing Company is an additional help in securing prompt publication.

According to Council Directive, 250 copies of the 1966 *Transactions* were ordered and 103 books were sent from the publisher to the active and honorary members.

There were 53 standing orders for the *Transactions* and 28 additional single orders. An order for 16 back issues was filled. One cancellation for the 1967 volume was received.

Complimentary volumes were sent to the honorary members, the Library of Congress, the National Library of Medicine for the Index Medicus, and the families of the deceased members.

Since the price of the *Transactions* has been raised to \$10.00 per volume an increase in income is expected over previous years.

Respectfully submitted,
F. Johnson Putney, M.D., Editor

REPORT OF THE AMERICAN BOARD OF OTOLARYNGOLOGY

The American Board of Otolaryngology held an examination in New Orleans, Louisiana, June 5-9, 1966, at which time 98 candidates were examined. Of this group 68 passed.

The Board also held an examination in Chicago, October 9-13, 1966, and 109 candidates were examined. Of this group 81 passed.

The Board will hold a meeting in Toronto, Canada, May 9-11, 1967 and expect to examine approximately 92 candidates. The Board will also hold a meeting in Chicago, Illinois, October 29 to November 1, 1967.

We have about 100 new applications at the present time and at the rate they are submitted there will probably be about 135 for the Credentials Committee to review at the meeting in May.

Respectfully submitted,

Paul H. Holinger, M.D.

REPORT OF LARYNGOLOGICAL RESEARCH FUND COMMITTEE

Your Committee wishes to report that checks for three grants were awarded last year to:

Dr. Patrick J. Doyle, University of Oregon

Dr. Roger Boles, University of Michigan

Dr. George Kelemen, University of Southern California

No requests for grants have been received this year.

Respectfully submitted,

Francis E. LeJeune, M.D.

REPORT FROM BOARD OF GOVERNORS, AMERICAN COLLEGE OF SURGEONS

The Eastern Section of the American College of Surgeons met in New York February 27 to March 2, 1967 at the New York Hilton and Americana Hotels.

At the breakfast for the Board of Governors on Monday, February 27, Dr. George Finney presided in a two-hour meeting which considered the following topics:

1. *Nursing Education.* The ANA has been very resistant to the interest of the College in this sphere, but the Association of Operating Room Nurses is backing a bona fide program for training O.R. technicians.

2. *Local Chapters—How to Improve Programs.* Establishment of prizes for residents who present or publish outstanding material. Consolidation of meetings with other local surgical and specialty societies.

3. *Medicare—Effect on Surgical Education.* In the Federal Register of February 8, 1967 is published the final word on payment of the operating surgeon

by the Social Security Administration. A group in New England has formed a collecting agency called "Surgery 500" from which funds are distributed twice yearly to the surgeons concerned.

4. *College Publicity to Interns, Residents and Fellows.* A new department of information and communication has been established within the College with a lay chief, Mr. Howard Cartwright, responsible for getting out a newsletter, supplementing the Bulletin, published six times yearly.

The Section on Otolaryngology held one of its best attended and most successful meetings at the Americana. Dr. John Daly, its guiding spirit, organized a dinner at the Century Club, supported by the other members in the metropolitan area. An unrehearsed, critical, constructive and at times brisk discussion developed after dinner, laying bare some of the sensitive issues in our changing specialty.

Respectfully submitted,

W. Franklin Keim, M.D.

NEW BUSINESS

DR. RICHARDS: The major new business is a somewhat thorny one because two amendments to the Constitution were sent out, as is required, for consideration at this meeting. They are not mutually exclusive, but they supplement each other.

1. "All Fellows on reaching the age of seventy shall automatically be elevated to Emeritus Fellowship." Council members shall be exempt to finish out their term of service.

"In view of the fact that the passage of this Amendment will involve a change of Fellowship status from Active to Emeritus for approximately fifteen Fellows, the Council at its Mid-Winter Meeting proposed consideration of an alternative amendment:

"2. Any Fellow reaching seventy, regardless of duration of Fellowship, may apply for elevation to Emeritus Fellowship."

SAMUEL SALINGER, M.D.: I think it should be optional.

ALDEN H. MILLER, M.D.: Anybody who is already seventy will become Emeritus only if he chooses. But after this amendment is passed, anybody who at this minute is not seventy, when he becomes seventy—it may be five years from now—must become Emeritus.

PRESIDENT PRESSMAN: Dr. Richards pointed out that we had 96 Active members. Last year we had 99 out of 100, and the proposal was made in order

that there shall be vacancies created for new, younger, active men to come into the Association in a capacity more likely to be productive than the older members.

ANDERSON C. HILDING, M.D.: Would it be legal, according to the Constitution, to change the wording and to clarify it?

RICHARD B. LEWY, M.D.: I would like to rise in support of Dr. Salinger's statement relative to making it optional. I think that if we accept the first statement and not the second statement we might be dealing ourselves an unnecessary blow and depriving ourselves of the activity of a rather large number of very vigorous members. If we put it on an optional basis, those who are still active in writing and attending meetings will continue on and we certainly want to have their talents with us.

JOHN A. KIRCHNER, M.D.: With all due respect to our senior members, a scientific organization can always stand the infusion of new blood and I think that this proposal is a very good one, that we must get younger people into this group and I would support the amendment.

VICTOR R. ALFARO, M.D.: I think it would be perfectly legal and proper to consider any amendments proposed here to what you sent out in the letter. As long as there is notice of the recommended change in the Constitution, that changes in wording, or alternatives to the wording, can be approved here without having to wait another year.

DR. ALDEN H. MILLER: Really today you are considering two changes. One is that in the past you could not even ask for Emeritus, no matter if you reached seventy, unless you had been in the Society twenty years. So the first thing that is different is that now, upon reaching seventy, if you have been in only nineteen years, or sixteen, or ten, you still are eligible for Emeritus. That is point number one.

Point number two is that after this amendment anybody who was not seventy and who now reaches seventy must become Emeritus.

THEODORE E. WALSH, M.D.: Was it your intention in the second part to indicate 'on reaching the age of seventy'? If this wording had been written when the Society was first formed, anybody getting to seventy, whether he was seventy now or would be, would become Emeritus, or be eligible for Emeritus status. So it doesn't matter whether he is seventy now or whether he is seventy-five or sixty-five. When he becomes seventy—anybody who is seventy then becomes Emeritus. Isn't that what you meant?

DR. ALDEN H. MILLER: Let's leave the twenty years out of it. You understand that. The other one was that the men who are already seventy are not to

be forced into Emeritus status, because some of them are still very active and want to be and may want to stay to eighty, and so they are protected. In order to establish a cut-off, after the amendment is accepted, anybody who isn't already seventy but who becomes seventy tomorrow, or a year from now, then falls under the new axe.

AUSTIN T. SMITH, M.D.: It seems to me that if you had read the second amendment first, that would clarify it.

PRESIDENT PRESSMAN: Mr. Secretary, would you be good enough to read the second amendment first and let's vote on that.

CHAIRMAN RICHARDS: "Any Active Fellow reaching the age of seventy, regardless of duration of Fellowship, may apply for elevation to Emeritus Fellowship."

PRESIDENT PRESSMAN: You have heard the amendment, submitted by Dr. Lyman Richards and recommended by the Council. All those in favor of approving this amendment say "aye"; all those opposed? The amendment is carried.

SECRETARY RICHARDS: Now we are going to take up the first one: "All Fellows reaching the age of seventy shall automatically be elevated to Emeritus Fellowship"—except the people who have positions on the Council, who shall complete their terms of office.

PRESIDENT PRESSMAN: Is there any further discussion on this proposed amendment?

JOSEPH P. ATKINS, M.D.: The remarks of the Secretary earlier today about the number of applicants for this Society makes me question whether this amendment is necessary at all. I should think it might be worth considering that until such time as there is a clamor for places in this Society that this amendment is unnecessary.

PRESIDENT PRESSMAN: I would like to point out that this amendment actually doesn't become activated for many years because every man who is now a member of this Association and who is under seventy would continue and the number of those reaching seventy is few actually over the next two or three years.

DR. PUTNEY: There are fifteen members who are now seventy or over. The ones that reach seventy in the next two years are only four or five.

PRESIDENT PRESSMAN: You have heard this important amendment. There isn't a law that says an Emeritus Fellow can't be as active as he pleases, except in holding office. I don't think anybody reaching seventy has any rule placed upon him that he can't contribute to this Association, except as a mechanism for

making places available for people in the younger age brackets so that we don't fall into the mistake of only elders.

SECRETARY RICHARDS: He can write a paper for every meeting that we have from now on. The only thing he can't do is vote, that's the only difference.

DR. ALDEN H. MILLER: There are 21 who are now sixty-nine or over and of those there are four who are sixty-nine, so this is the four that a year from now will have to become Emeritus. There are 17 who are already seventy or over, and they would not have to become Emeritus.

DR. SALINGER: I would like to accentuate this last point, namely, you are making it mandatory on these four and you are making it optional on these seventeen, which is not fair.

PRESIDENT PRESSMAN: You have heard Dr. Salinger's sage remark. It may well be that this is a case in point.

Please read the amendment as it now stands, Dr. Richards.

SECRETARY RICHARDS: "All Fellows on reaching the age of seventy shall automatically be elevated to Emeritus Fellowship, except for those who are on the Council, who shall fill out their terms of office."

PRESIDENT PRESSMAN: That is the amendment. May we have a show of hands.

All those in favor of this amendment, please raise your hand.

Twenty-five of those present are in favor. All those opposed?

Well, I think it is obvious that we don't have a three-quarters vote.

So the amendment is defeated.

We have long been faced with the problem of presentation of papers at these meetings and their publication in specific journals. This represents a serious handicap to us in the matter of invited guests who are authorities upon certain subjects and who have undoubtedly published these papers previously.

The Council felt that this was an unnecessary burden upon those who were trying to put the programs together and that it represented an unnecessary limitation upon the speakers. For example, just to pick a name out of a hat, someone like Dr. Harry Salk couldn't come here and talk to us about poliomyelitis and its relationship to our field because he has published it before. He certainly wouldn't want to publish as an exclusive contribution a document for the medical profession as a whole in our *Journal* with its limited publication of a hundred or two, or in one of our specialty journals. So we felt these limitations should be removed and the council approved this sentiment, so that, unless there are serious objections raised by the membership, persons reading papers before this

organization will not be required to fulfill the necessity of having had it unpublished at a prior time.

SECRETARY RICHARDS: The Constitution states: "No paper shall be read before the Association which shall have been printed or have been read before another body."

PRESIDENT PRESSMAN: What we will have to do with this is to submit it in the regular form by circularizing it before the next meeting.

WALTER P. WORK, M.D.: Does that include those papers that have been presented here that are not supposed to be published by other organizations?

PRESIDENT PRESSMAN: That's right. We thought it would be best in the light of the complications that have arisen.

DR. WORK: But you still run into the problem, particularly with the universities, where promotions often depend on publication. For this reason and for the dissemination of this knowledge I think we ought to look to the future, after the paper has been presented here.

PRESIDENT PRESSMAN: This isn't my interpretation. It isn't the requirement that we do not publish it in the future or that it can't be published in another journal.

That is a matter for next year's deliberations because this requires a constitutional amendment, and we will need to consider it at the regular formal Business Meeting and circularize it properly.

SECRETARY RICHARDS: Since the last meeting, through death we have lost:

Dr. Meltzer Dr. Jarvis Dr. Roberts Dr. Houser

PRESIDENT PRESSMAN: Gentlemen, in loving memory of these distinguished colleagues, each of whom has contributed so much of his life to the welfare of this Association and to his profession, I ask that we stand.



EXECUTIVE SESSION

TUESDAY MORNING, MAY 16, 1967

The meeting reconvened in Executive Session on Tuesday morning, May 16, 1967, at one o'clock, immediately following the close of the Scientific Session, Secretary Richards presiding.

CHAIRMAN RICHARDS: In these days of space travel and electronics, it has been possible for your Council to meet and to elect their officers for the coming year, which are as follows:

President: Dr. Lawrence Boies

First Vice-President: Dr. John Daly

Second Vice-President: Dr. Stanton Friedberg

Secretary: Dr. Lyman Richards

Treasurer: Dr. Alden Miller

Librarian, Historian, Editor: Dr. F. Johnson Putney

First Councillor: Dr. Anderson Hilding

Second Councillor: Dr. Albert Furstenberg

Third Councillor: Dr. Paul Holinger

Fourth Councillor: Dr. Joel Pressman

PRESIDENT PRESSMAN: Dr. Boies, I couldn't be more delighted to be succeeded by one so illustrious and one for whom I have such deep affection.

It gives me the greatest possible pleasure to pass this gavel to you as a symbol of your assuming office (presenting gavel to President-elect Boies) and as far as Dr. Richards' remarks about the advice from me as to how to conduct this presidency, you know very much more about it than I through your various presidencies of many of these associations. I would give you as a word of advice, based on my own experience: the best thing to do in conducting this office is to run for your life!

PRESIDENT BOIES: I deeply appreciate this high honor.

One of the first duties that I have, or privileges that I have, is to present Dr. Pressman with an official key of the Society in token of our appreciation of your services to the Society (presenting key to Immediate Past President Pressman).



THE NEWCOMB AWARD

"The Newcomb Award is given annually to a Fellow of the American Laryngological Association presenting the most outstanding contribution to the literature of laryngology during the previous year or as a mark of esteem and appreciation for services to the Association."

The Committee recommends and the Council approves Dr. Joseph H. Ogura as the 1967 recipient of the Newcomb Award.

Doctor Ogura is a California by birth and education, a Missourian by choice, and a laryngologist by exclusion.

Following graduation from the University of California, Doctor Ogura spent four years in the study of pathology and internal medicine before eliminating these disciplines in his choice of a career. He then embarked on a training program in otolaryngology, completing his residency at the hospitals affiliated with Washington University in 1948.

At the termination of his residency he was appointed instructor in otolaryngology at Washington University School of Medicine. Academic promotions came regularly, and he was appointed professor of otolaryngology in 1960 and chairman of the department in 1966.

One does not merely glance at the bibliography of so prolific a writer as Doctor Ogura. Careful perusal of this document reveals a total lack of interest in the ear and a profound fascination with the problems of the upper aerodigestive tract. His investigations cover the areas of neuro-anatomy, physiology, pathology, and experimental surgery. Clinical writings reveal a productive interest in the treatment of malignancies and in the reconstruction of the air and digestive passages, with particular emphasis on conservation of function. His educational interests envelop all of these fields.

For continued contributions to the progress of laryngology, we are proud to honor our colleague, Dr. Joseph H. Ogura.



List of Fellows

LIST OF FELLOWS

Date Indicates Year Admitted to Active Fellowship

Attendance at meetings is shown by figures following each name.

Asterisk (*) indicates year paper was read.

Active Fellows

1962. ALEXANDER, FRED W., 10515 Carnegie Ave., Cleveland 6, Ohio, 1962, '63*, '64, '66.
1958. ALFARO, VICTOR R., 917 - 20th St. N. W., Washington 6, D. C., 1958, '59, '60, '61, '62, '63, '64, '65, '66, '67.
1962. ARNOLD, GODFREY E. T., 2500 N. State St., Jackson 6, Mississippi, 1962, '63*, '64*, '66.
1958. ATKINS, JOSEPH P., 3400 Spruce St., Philadelphia 4, Pa., 1958, '59*, '60, '61, '62, '63, '64, '65, '67.
1956. BAKER, DANIEL CLIFTON, JR., 180 Fort Washington Ave., New York 21, N. Y., 1956, '57, '58, '59*, '60, '61, '62*, '63, '64, '65, '66.
1963. BAXTER, JAMES D., 1509 Sherbrooke St. West, Montreal, P.Q., Canada, 1963, '65*, '66, '67.
1944. BOIES, LAWRENCE R., University Hospital, Minneapolis 14, Minnesota, 1944, '46, '47, '48*, '49, '50*, '51*, '53, '54, '55, '56, '57, '58, '59, '60, '61, '62, '63, '64, '65, '66, '67.
1955. BORDLEY, JOHN E., Johns Hopkins Hospital, Baltimore 5, Maryland, 1955, '56, '57, '59, '60, '62, '63, '64, '65, '66, '67.
1959. BREWER, DAVID W., 1100 E. Genesee St., Syracuse 10, N. Y., 1959, '60*, '61, '62*, '63*, '66.
1955. BROWN, LESTER ALEXANDER, 490 Peachtree Street, N.E., Atlanta 8, Georgia, 1955, '56, '57, '58, '59, '61, '63, '65.
1940. BROYLES, EDWIN N., 11 East Chase St., Baltimore 2, Maryland, 1940, '41*, '42, '46, '48*, '49, '50, '51*, '52, '53, '54, '55, '56, '58, '59*, '60, '61*, '63, '64, '65, '67.

1963. BRYCE, DOUGLAS P., 170 St. George St., Room 320, Toronto, Canada, 1963*, '64, '66*, '67*.
1959. CARDWELL, EDGAR P., 109 So. Munn Ave., East Orange, N. J., 1959, '60, '61, '62, '63, '67.
1967. COCKE, EDWIN W., 899 Madison, Memphis, Tenn., 1967.
1964. CODY, CLAUDE C., III, 1600 Memorial Professional Building, Houston, Texas, 1964, '65, '67.
1957. CONLEY, JOHN J., 139 East 36th Street, New York 16, N.Y. 1958*, '60*, '61, '62*, '63*, '64, '65.
1957. CONVERSE, JOHN MARQUIS, 722 Park Avenue, New York 21, N.Y., '60, '62*, '67.
1959. CRACOVANER, ARTHUR J., 103 E. 78th St., New York 21, N. Y., 1959, '60, '61*, '62, '63, '65, '66, '67.
1960. DALY, JOHN F., Faculty Practice Offices, 566 First Ave., New York 16, N. Y., 1960, '61*, '62, '63, '64, '65, '66, '67.
1951. DAVISON, FRANCIS W., Geisinger Medical Center, Danville, Pa., 1951, '52, '53*, '54, '55, '56, '57, '58, '59, '60, '61, '62, '63*, '64, '65, '66, '67*.
1966. DEVINE, KENNETH D., Mayo Clinic, Rochester, Minn., 1966. 1948*, '49, '51, '53, '54, '56, '57, '59, '62, '64, '65*, '66, '67.
1947. EAGLE, WATT WEEMS, 703 Professional Drive, New Bern, N. C. 28506, 1948*, '49, '51, '53, '54, '56, '57, '59, '62, '64, '65*.
1952. ERICH, JOHN B., Mayo Clinic, 102 Second Avenue, Rochester, Minn., 1953, '56*, '57, '65.
1964. FEARON, BLAIR, Medical Arts Building, Toronto 5, Ontario, Canada, 1964, '66, '67.
1963. FERGUSON, CHARLES F., 300 Longwood Ave., Boston 15, Mass., 1963, '64*, '66, '67*.
1955. FITZ-HUGH, GLASSELL SLAUGHTER, 2003 Spottswood Road, Charlottesville, Virginia, 1955, '57, '59, '60, '61, '62*, '64, '65, '66, '67*.
1956. FRIEDBERG, STANTON A., 1725 West Harrison St., Chicago, Ill., 1956, '57*, '58, '59, '60, '61, '62, '63, '64, '65*, '67.

1932. FURSTENBERG, ALBERT CARL, St. Joseph's Mercy Hospital, Ann Arbor, Michigan, 1933*, '36*, '38*, '46, '48*, '50, '51, '53, '54, '55*, '56, '57, '58*, '59, '60, '61, '62, '63*, '64, '65*.
1959. GOLDMAN, JOSEPH L., 1050 Park Ave., New York, N. Y., 1959, '60*, '61, '62, '63, '64, '65, '66, '67.
1940. GOODALE, ROBERT L., 330 Dartmouth St., Boston 16, Massachusetts, 1940, '41, '42*, '44*, '46, '47, '49, '50*, '53, '54, '55*, '56, '57*, '60, '61*, '62, '63, '64, '65*.
1965. HANCKEL, RICHARD W., 55 Doughty St., Charleston, S. C., 1965, '66, '67.
1957. HARRILL, JAMES A., Bowman Gray School of Medicine, Winston-Salem, N. C., 1957, '58, '59, '61, '62, '63, '64, '66, '67.
1960. HARRIS, HERBERT, 907 Hermann Professional Building, Houston 25, Texas, 1960, '61*, '62, '63, '64, '65*, '66, '67.
1959. HART, VERLING K., 1600 East Third St., Charlotte, N. C. 28204, 1959, '60, '62, '66.
1942. HEATLY, CLYDE A., 11 North Goodman Street, Rochester 7, N.Y., 1942, '46*, '49, '50, '52, '53*, '54, '55, '57, '58, '60, '61, '65.
1959. HENRY, G. ARNOLD, 170 St. George St., Toronto, Canada, 1959, '61, '63, '66, '67.
1943. HILDING, ANDERSON C., Research Laboratory, St. Luke's Hospital, Duluth 11, Minnesota, 1944*, '46, '47, '48*, '49, '50, '51, '53, '55, '56*, '57, '60, '61, '62*, '63, '64*, '65, '66*, '67.
1955. HILGER, JEROME A., 350 St. Peter Street, St. Paul 2, Minnesota, 1955, '56*, '57, '58, '59, '60, '62, '63, '64, '65, '66.
1945. HOLINGER, PAUL H., 700 North Michigan Ave., Chicago 11, Illinois, 1946, '47, '49, '50*, '51*, '52, '53, '54*, '55, '56, '57, '58*, '59, '60, '61*, '62*, '63, '64, '65, '66*.
1957. HOLMES, EDGAR M., 264 Beacon St., Boston 16, Mass., 1957, '59, '61, '63.
1944. HOOPLE, GORDON D., 1100 East Genesee St., Syracuse 10, New York, 1946, '47, '48, '49, '50, '51, '52, '53, '54*, '55, '56, '58, '59, '60, '61, '62, '63, '64, '65, '66, '67.

1952. IRELAND, P. E., Room 82, Banting Institute, University of Toronto, Toronto, Ontario, 1952, '53, '54, '55, '56*, '57, '59, '61, '62, '63, '64, '66.
1961. JONES, EDLEY H., 1301 Washington St., Vicksburg, Miss. 39108, 1961, '62, '63*, '65, '66, '67.
1964. KEIM, W. FRANKLIN, 75 Union St., Montclair, N. J., 1964, '66, '67.
1965. KING, JAMES T., Baptist Professional Building, Atlanta, Ga., 1965, '66, '67.
1963. KIRCHNER, JOHN A., 333 Cedar St., New Haven 4, Conn., 1963, '65*, '67*.
1965. KNIGHT, JOHN S., 305 West 43rd St., Kansas City, Mo., 1965, '66*, '67.
1963. LATHROP, FRANK D., 605 Commonwealth Ave., Boston 15, Mass., 1963, '64*, '67.
1953. LEDERER, FRANCIS LOEFFLER, 1853 W. Polk Street, Chicago 12, Illinois, 1953, '54, '55, '56, '57*, '58, '60, '61, '62, '63*, '64, '65, '66.
1936. LEJEUNE, FRANCIS ERNEST, Ochsner Clinic Building, Prytania and Aline Streets, New Orleans 15, Louisiana, 1937, '46*, '47, '50, '51, '52, '53, '54*, '55, '56, '57, '58, '59, '60, '61, '62, '63*, '64, '65, '66, '67.
1966. LEWIS, JOHN S., 3 East 71st Street, New York 21, N. Y., 1966, '67.
1961. LEWY, ROBERT B., 25 East Washington St., Chicago 2, Ill., 1961, '62*, '63, '65*, '67.
1966. McCABE, BRIAN F., Dept. of Otolaryngology, University Hospital, Iowa City, Iowa, 1966.
1963. MCGOVERN, FRANCIS H., 139 South Main St., Danville, Virginia, 1963, '64, '66.
1951. MCHENRY, LAWRENCE C., 301 N. W. 12th St., Oklahoma City 2, Okla., 1953*, '62, '63, '64, '65, '66.

1931. McNALLY, WILLIAM JAMES, 1509 Sherbrooke Street West, Montreal, Canada, 1931, '33, '34*, '39, '44, '47, '49, '49, '52, '53, '54*, '55, '56, '57, '58, '59, '60, '61, '65, '67*.
1952. MILLER, ALDEN H., 1407 N. Vermont Ave., Los Angeles 27, Calif., 1952, '53*, '55, '57, '58*, '61, '62, '64, '66, '67*.
1965. MILLER, DANIEL, Deaconess Medical Building, 110 Francis St., Boston, Mass., 1965, '66, '67.
1964. MONTGOMERY, WILLIAM W., 243 Charles St., Boston 14, Mass., 1964, '65*, '66*.
1958. MONTREUIL, FERNAND, Centre Professionnel, 801 Sherbrooke, E., Montreal, Canada, 1958, '60, '64, '67.
1954. MOORE, PAUL M., 10515 Carnegie Ave., Cleveland 6, Ohio, 1954, '55*, '56, '57, '59, '60, '61, '62, '63, '64, '65, '66.
1957. MUNOZ-MACCORMICK, CARLOS EDUARDO, 71 Park Terrace, Santurce, Puerto Rico, 1957, '58, '59, '60, '61, '62, '63, '64, '65, '66, '67.
1953. MURTAGH, JOHN A., 2 Maynard Street, Hanover, New Hampshire, 1953, '54, '55, '56*, '57, '58, '59, '61, '62, '63, '65, '66, '67.
1937. NASH, C. STEWART, Medical Arts Building, Rochester 7, New York, 1937, '38*, '40, '42, '44, '46, '49, '50, '51, '52, '53, '54, '55, '56*, '58, '59, '60, '61, '62, '64.
1956. NORRIS, CHARLES MORGAN, 3401 North Broad Street, Philadelphia 40, Pennsylvania, 1956, '57, '58*, '59, '60, '61*, '62, '63, '64, '66, '67.
1961. OGURA, JOSEPH H., 640 So. Kingshighway, St. Louis 10, Mo., 1961*, '62*, '63, '64*, '65, '66*, '67.
1958. O'KEEFE, JOHN J., 255 S. 17th St., Philadelphia 3, Pa., 1958, '59*, '60, '62, '64, '67.
1961. O'NEIL, JAMES J., 612 Medical Arts Building, Omaha, Nebraska, 1961, '62*, '64, '67.
1961. PANG, LUP Q., 1374 Nuuanu Ave., Honolulu 17, Hawaii, 1961, '62*, '64, '66, '67.
1961. PASTORE, PETER N., Box 25, 1200 East Broad St., Richmond, Virginia, 1961, '62*, '64, '66, '67.

1967. PRATT, LORING W., 177 Main St., Waterville, Maine, 1967.
1954. PRESSMAN, JOEL J., Department of Surgery, UCLA Medical Center, Los Angeles 24, Calif., 1954, '56*, '59*, '60, '61, '62, '64, '65, '66, '67*.
1951. PRIEST, ROBERT E., 79, S. Ninth St., Minneapolis 2, Minn., 1951, '53*, '54*, '56, '59, '60*, '61, '65, '67*.
1951. PUTNEY, F. JOHNSON, 55 Doughty St., Charleston, S. C., 1951, '52, '53*, '54, '55, '56, '58*, '59, '60, '61, '62, '63*, '64*, '65, '66, '67.
1951. RAWLINS, AUBREY G., 384 Post Street, San Francisco 8, Calif., 1951, '53*, '56, '58, '64.
1963. REED, GEORGE F., 766 Irving Ave., Syracuse, N. Y., 1963, '65*, '66.
1934. RICHARDS, LYMAN GILDER, 12 Clovelly Road, Wellesley Hills 81, Mass., 1934, '35, '36*, '37, '38, '39, '47, '49, '51*, '54, '56, '57*, '59, '60, '61, '62, '63, '64, '65, '67.
1956. RICHARDSON, JOHN ROBERT, 403 Commonwealth Avenue, Boston 15, Mass., 1957, '58, '59, '60, '63, '64, '67.
1959. SANDERS, SAM H., 1268 Peabody Ave., Memphis 3, Tenn., 1959, '60, '61, '62, '63, '65.
1964. SAUNDERS, WILLIAM H., N-820 University Hospital, Columbus, Ohio, 1964, '65, '66.
1959. SILCOX, LOUIS E., 102 Lankenau Med. Bldg., Philadelphia 31, Pa., 1959, '60, '61, '62, '63, '64, '65, '66, '67.
1958. SIMONTON, KINSEY M., Mayo Clinic, Rochester, Minn., 1958, '59*, '62, '64, '66, '67.
1962. SISSON, GEORGE A., 1200 E. Genesee St., Syracuse 10, N. Y., 1962, '63*, '65, '66.
1964. SKOLNIK, EMANUEL M., 1853 West Polk Street, Chicago, Ill., 1964*, '65, '66*, '67.
1950. SMITH, AUSTIN T., Pennsylvania Hospital, 330 So. 9th St., Philadelphia 7, Pa., 1950, '51, '52, '53, '55, '56, '57, '58*, '59, '60, '61, '62*, '66, '67.
1954. SOOY, FRANCIS A., 490 Post Street, San Francisco 2, Calif., 1954, '56*, '58, '60, '62, '63, '64, '65*, '67.

1961. SUEHS, OLIVER W., 14 Medical Arts Square, Austin, Texas, 1961, '62*, '63, '64, '66.
1963. TABB, HAROLD G., 1430 Tulane Ave., New Orleans 12, La. 1963, '65, '66, '67.
1954. THORNELL, WILLIAM C., 2508 Auburn Avenue, Cincinnati 19, Ohio, 1955*, '57, '59, '60, '63.
1963. TOLAN, JOHN F., 1118 Ninth Ave., Seattle 1, Washington, 1963, '64, '65, '66, '67.
1950. TREMBLE, G. EDWARD, 1390 Sherbrooke St. W., Montreal, Quebec, Canada, 1950, '51, '52, '53, '54, '55*, '56, '57, '58, '60, '61, '62, '63, '65, '66, '67*.
1967. TRIBLE, WILLIAM MACL., 1234 19th St., N.W., Washington, D. C., 1967.
1954. WALSH, THEODORE E., 640 S. Kingshighway Blvd., St. Louis 10, Missouri, 1954, '55*, '56, '57, '58, '59, '60, '61, '62, '63, '64, '65, '66, '67.
1962. WEAVER, DELMAR F., 571 Fisher Building, Detroit 2, Michigan, 1962, '63, '64*, '65, '67*.
1940. WEILLE, FRANCIS L., 247 Commonwealth Avenue, Boston 16, Massachusetts, 1940, '41, '42, '44, '46*, '47, '48, '49, '50, '51, '52, '53, '54, '55, '56*, '57, '58, '59, '60, '61, '62, '63, '64, '65*, '66, '67.
1951. WOODMAN, DEGRAAF, Talbottown Lane, P. O. Box 560, Easton, Md., 1951, '53, '54, '55*, '56, '58, '59, '60, '61, '62, '63, '64, '65, '66, '67.
1953. WORK, WALTER P., University Hospitals, Ann Arbor, Michigan, 1953, '54, '56, '58, '59*, '62, '63*, '65, '67.

Honorary Fellows

1957. (1925) CLERF, LOUIS H., 5575 Eighth Avenue, North, St. Petersburg 2, Florida, 1957, '58, '59, '60, '61, '63, '64, '65, '66.
1960. (1928) HILL, FREDERICK THAYER, Thayer Memorial Hospital, Waterville, Maine, 1960, '61, '63, '64, '66, '67.
1967. (1933) LIERLE, DEAN M., University Hospitals, Iowa City, Iowa, 1967.

1957. (1930) NEGUS, SIR VICTOR E., Hill Farm Lodge, Haslemere, Surrey, England, 1957*.
1966. (1957) ONO, JO, 75 Zaimoku-cho, Azabu, Minato-ku, Tokyo, Japan.

Corresponding Fellows

1946. ALONSO, REGULES JUSTO E., Mercedes 1233, Montevideo, Uruguay.
1959. BARRETTO, PLINIO DE MATTOS, Ru Cons Torres, Homer 371, Sao Paulo, Brazil, 1960.
1959. BATEMAN, GEOFFREY H., 55 Harley Street, London W.1., England.
1942. BATSON, OSCAR V., 203 South DeKalb St., Philadelphia 4, Pennsylvania, 1942*, '54*.
1964. CLEVES, CARLOS, Carrera 14 No. 44-54, Apto. 202, Bogota, Colombia, S.A.
1966. DOHLMAN, GOSTA, Dept. of Otolaryngology, University of Toronto, Toronto, Canada, 1966.
1943. EGGSTON, ANDREW A., 653 Park Avenue, New York, N. Y., 1944, '49, '55, '60, '61*.
1957. HUIZINGA, EELCO, Noorderhaven 7, Groningen, The Netherlands, 1957.
1964. PEREZ, ALFREDO C., Instituto Celis Perez, Avenida Montes de Oca, Apartado 163, Valencia, Venezuela, S.A., 1965.
1937. PORTMANN, GEORGES, 25 bis Cours de Verdun, Bordeaux, France, 1947.
1957. RUEDI, LUZIUS, Ramistrasse 100, Zurich, Switzerland, 1957.
1924. SCHAEFER, J. PARSONS, 4634 Spruce Street, Philadelphia 39, Pennsylvania, 1934.
1952. TAPIA ACUNA, RICARDO, Av. Insurgentes Sur 300, Mexico 7 D.F., 1953, '57, '60*, '67.
1936. VIALLE, JACQUES, 27 Rue de France, Nice (Alpes Maritimes), France.

Emeritus Fellows

1951. (1944) BEATTY, HUGH G., 390 Oak St., Apt. No. 35, Columbus 15, Ohio, 1951, '52, '53.
1966. (1945) CAMPBELL, PAUL A., 321 Park Hill Drive, San Antonio, Texas.
1965. (1942) CANFIELD, NORTON, Harwood Hospital, Christiansted, St. Croix, Virgin Is.
1958. (1930) FIGI, FREDERICK A., Mayo Clinic, Rochester, Minnesota.
1961. (1936) GALLOWAY, THOMAS CYRUS, 636 Church St., Evanston, Illinois, 1961, '62, '64, '66.
1951. (1928) GITTINS, THOMAS R., 408 Davidson Bldg., Sioux City, Iowa.
1963. (1928) GOODYEAR, HENRY M., 2012 Edgecliff Point, Cincinnati, Ohio 45206.
1960. (1940) HANSEL, FRENCH, 634 N. Grand Blvd., St. Louis 3, Missouri, 1962, '65.
1960. (1942) KELLY, JOSEPH D., 140 East Fifty-fourth Street, New York 22, N. Y.
1961. (1950) KLINE, ORAM R., 514 Cooper Street, Camden, N. J., 1961, '63.
1967. (1949) LINDSAY, JOHN R., 950 E. 59th St., Chicago 37, Ill., 1967.
1954. (1927) LUKENS, ROBERT M., 141 West Heather Road, Wildwood Crest, N. J.
1964. (1952) MCCALL, JULIUS W., 610 Rose Building, Cleveland 15, Ohio, 1964, '66.
1966. (1933) MCMAHON, BERNARD J., 150 North Meramec Ave., Clayton, Mo.
1959. (1927) MYERSON, MERVIN C., 436 Roxbury Drive, Beverly Hills, Calif.
1957. (1948) PHELPS, KENNETH A., 7200 34th St., South, St. Petersburg, Fla.

1958. (1938) SALINGER, SAMUEL, 1260 East Alejo Road, Palm Springs, Calif., 1958, '59, '61, '62, '63, '64, '65, '66, '67.
1962. (1932) SCHALL, LEROY A., Scudder Lane, Barnstable, Mass., 1964, '66.
1964. (1934) SCHENCK, HARRY P., 326 South 19th Street, Philadelphia 3, Pa., 1964, '65*, '66.
1965. (1939) SIMPSON, W. LIKELY, 351 South Highland St., Memphis, Tenn.
1966. (1947) THEOBALD, WALTER H., 307 N. Michigan Ave., Chicago 11, Ill., 1966.
1965. (1943) VAN ALYEA, OLIVER E., 135 South LaSalle St., Chicago 3, Ill., 1965, '66.
1961. (1941) VIOLÉ, PIERRE P., 241 South Windsor, Los Angeles, Calif., 1964.
1964. (1948) WILLIAMS, HENRY L., II, U. S. Veterans' Hospital, Minneapolis 17, Minn., 1964, '65, '66, '67.
1951. (1935) WOODWARD, FLETCHER D., 1326 Rugby Road, Charlottesville, Va., 1959, '60, '61.

BENEFACTORS

DR. JOHN F. BARNHILL	DR. FREDERICK T. HILL
DR. GORDON BERRY	DR. & MRS. GEORGE E. HOURN
DR. EDWIN N. BROYLES	DR. SAMUEL JOHNSTON
DR. WILLIAM E. CASSELBERRY	DR. JAMES E. NEWCOMB
DR. LOUIS H. CLERF	DR. HENRY B. ORTON
DR. CORNELIUS COAKLEY	DR. SAMUEL SALINGER
DR. & MRS. FRANCIS W. DAVISON	DR. SAM H. SANDERS
DR. & MRS. LEE WALLACE DEAN	DR. HARRY P. SCHENCK
DR. ARTHUR W. DEROALDES	DR. BURT R. SHURLY
DR. FRED W. DIXON	MR. LESTER T. SUNDERLAND
DR. WILLIAM E. GROVE	DR. H. MARSHALL TAYLOR
DR. GORDON F. HARKNESS	DR. WALTER H. THEOBALD



Obverse of the deRoaldes medal

RECIPIENTS OF THE DE ROALDES AWARD

- 1928. DR. CHEVALIER JACKSON
- 1931. DR. D. BRYSON DELAVAN
- 1934. DR. HARRIS P. MOSHER
- 1937. DR. LEE WALLACE DEAN
- 1943. DR. RALPH A. FENTON
- 1949. DR. GEORGE M. COATES
- 1951. DR. ARTHUR W. PROETZ
- 1954. DR. LOUIS H. CLERF
- 1959. DR. ALBERT C. FURSTENBERG
- 1960. DR. DEAN M. LIERLE
- 1961. DR. FREDERICK T. HILL
- 1966. DR. PAUL H. HOLINGER

RECIPIENTS OF THE CASSELBERRY AWARD

1923. DR. GEORGE FETTEROLF AND DR. HERBERT FOX
1928. DR. RALPH A. FENTON AND DR. O. LARSELL
1929. DR. RICHARD A. KERN AND DR. HARRY P. SCHENCK
1929. DR. EDWARD H. CAMPBELL
1931. DR. ARTHUR W. PROETZ
1934. DR. ANDERSON C. HILDING
1936. DR. FRANCIS E. LEJEUNE; DR. JOEL J. PRESSMAN
1939. DR. H. MARSHALL TAYLOR; DR. BRIEN T. KING
1940. DR. FRENCH K. HANSEL
1941. DR. NOAH D. FABRICANT
1946. DR. PAUL H. HOLINGER
1949. DR. HENRY B. ORTON
1962. DR. HANS VON LEDEN
1966. DR. JOHN A. KIRCHNER AND MR. BARRY D. WYKE

RECIPIENTS OF THE NEWCOMB AWARD

- 1941. DR. BURT R. SHURLY
- 1942. DR. FRANCIS R. PACKARD
- 1943. DR. GEORGE M. COATES
- 1944. DR. CHARLES J. IMPERATORI
- 1947. DR. HARRIS P. MOSHER
- 1948. DR. GORDON BERRY
- 1949. DR. GORDON B. NEW
- 1950. DR. H. MARSHALL TAYLOR
- 1951. DR. JOHN D. KERNAN
- 1952. DR. WILLIAM J. McNALLY
- 1953. DR. FREDERICK T. HILL
- 1954. DR. HENRY B. ORTON
- 1955. DR. THOMAS C. GALLOWAY
- 1956. DR. DEAN M. LIERLE
- 1957. DR. GORDON F. HARKNESS
- 1958. DR. ALBERT C. FURSTENBERG
- 1959. DR. HARRY P. SCHENCK
- 1960. DR. JOEL J. PRESSMAN
- 1961. DR. CHEVALIER L. JACKSON
- 1962. DR. PAUL H. HOLINGER
- 1963. DR. FRANCIS E. LEJEUNE
- 1964. DR. FRED W. DIXON
- 1965. DR. EDWIN N. BROYLES
- 1966. DR. LYMAN G. RICHARDS
- 1967. DR. JOSEPH H. OGURA

PAST OFFICERS

Presidents

(Year of Election)

1879. Louis Elsberg	1909. J. E. Logan
1880. J. Solis-Cohen	1910. D. Braden Kyle
1881. F. I. Knight	1911. James E. Newcomb
1882. G. M. Lefferts	1912. George A. Leland
1883. F. H. Bosworth	1913. Thomas Hubbard
1884. E. L. Shurly	1914. Alexander W. MacCoy
1885. Harrison Allen	1915. G. Hudson Makuen
1886. E. Fletcher Ingals	1916. Joseph L. Goodale
1887. R. P. Lincoln	1917. Thomas H. Halstead
1888. E. C. Morgan	1918. Cornelius G. Coakley
1889. J. N. Mackenzie	1919. Norval H. Pierce
1890. W. C. Glasgow	1920. Harris P. Mosher
1891. S. W. Langmaid	1921. Harmon Smith
1892. M. J. Asch	1922. Emil Mayer
1893. D. Bryson Delavan	1923. J. Payson Clark
1894. J. O. Roe	1924. Lee Wallace Dean
1895. W. H. Daly	1925. Greenfield Sluder
1896. C. H. Knight	1926. Chevalier Jackson
1897. T. R. French	1927. D. Bryson Delavan
1898. W. E. Casselberry	1928. Charles W. Richardson
1899. Samuel Johnston	1929. Lewis A. Coffin
1900. H. L. Swain	1930. Francis R. Packard
1901. J. W. Farlow	1931. George E. Shambaugh
1902. J. H. Bryan	1932. George Fetterolf
1903. J. H. Hartman	1933. George M. Coates
1904. C. C. Rice	1934. Dunbar Roy
1905. J. W. Gleitsman	1935. Burt R. Shurly
1906. A. W. deRoaldes	1936. William B. Chamberlain
1907. H. S. Birkett	1937. John F. Barnhill
1908. A. Coolidge, Jr.	1938. George B. Wood

1939. James A. Babbitt	1954. Henry B. Orton
1940. Gordon Berry	1955. Bernard J. McMahon
1941. Thomas E. Carmody	1956. LeRoy A. Schall
1942-3. Charles J. Imperatori	1957. Harry P. Schenck
1944-5. Harold I. Lillie	1958. Fred W. Dixon
1946. Frank R. Spencer	1959. William J. McNally
1947. Arthur W. Proetz	1960. Edwin N. Broyles
1948. Frederick T. Hill	1961. Dean M. Lierle
1949. Ralph A. Fenton	1962. Francis E. LeJeune
1950. Gordon B. New	1963. Anderson C. Hilding
1951. H. Marshall Taylor	1964. Albert C. Furstenberg
1952. Louis H. Clerf	1965. Paul H. Holinger
1953. Gordon F. Harkness	1966. Joel J. Pressman

Vice-Presidents

1879. F. H. Davis	J. O. Roe
1880. W. C. Glasgow	W. Porter
1881. E. L. Shurly	E. F. Ingals
1882. C. Seiler	S. Johnston
1883. S. W. Langmaid	W. H. Daly
1884. J. H. Hartman	G. W. Major
1885. H. A. Johnson	J. N. Mackenzie
1886. E. C. Morgan	S. W. Langmaid
1887. J. N. Mackenzie	C. E. DeM. Sajous
1888. W. C. Glasgow	C. E. Bean
1889. E. Holden	J. H. Hartman
1890. J. O. Roe	S. Johnston
1891. M. J. Asch	J. C. Mulhall
1892. S. Johnston	W. E. Casselberry
1893. J. C. Mulhall	S. H. Chapman
1894. C. C. Rice	A. W. deRoaldes
1895. J. Wright	D. N. Rankin
1896. T. M. Murray	H. S. Birkett
1897. A. W. MacCoy	F. W. Hinkel
1898. J. W. Farlow	M. R. Brown
1899. T. A. DeBlois	A. A. Bliss
1900. H. L. Wagner	

1901. J. W. Gleitsmann	D. Braden Kyle
1902. G. A. Leland	T. Melville Hardie
1903. J. H. Lowman	W. Peyre Porcher
1904. Thomas Hubbard	W. J. Freeman
1905. J. L. Goodale	C. W. Richardson
1906. G. H. Makuen	A. B. Thrasher
1907. J. P. Clark	J. E. Rhodes
1908. E. Mayer	F. R. Packard
1909. C. G. Coakley	H. P. Mosher
1910. Robert C. Myles	J. M. Ingersoll
1911. F. C. Cobb	B. R. Shurly
1912. A. W. Watson	W. Scott Renner
1913. F. E. Hopkins	Geo. F. Shambaugh
1914. Clement T. Theisen	Lewis A. Coffin
1915. J. Gordon Wilson	Christian R. Holmes
1916. Thomas H. Halsted	Greenfield Sluder
1917. John Edwin Rhodes	D. Crosby Greene
1918. G. E. Shambaugh	John R. Winslow
1919. Francis R. Packard	Harmon Smith
1920. Harmon Smith	W. B. Chamberlin
1921. Dunbar Roy	Robert C. Lynch
1922. George Fetterolf	Lorenzo B. Lockard
1923. Hubert Arrowsmith	Joseph B. Greene
1924. Ross H. Skillern	Gordon Berry
1925. John E. Mackenty	Robert Levy
1926. Lewis A. Coffin	William V. Mullin
1927. Charles W. Richardson	Hill Hastings
1928. Robert Clyde Lynch	Francis P. Emerson
1929. William B. Chamberlin	Ralph Albert Fenton
1930. Harris P. Mosher	James A. Babbitt
1931. Joseph B. Greene	E. Ross Faulkner
1932. Gordon Berry	Frank A. Spencer
1933. E. Ross Faulkner	Thomas S. Carmody
1934. Gordon B. New	Samuel McCullagh
1935. Edward C. Sewall	H. Marshall Taylor

1936. William P. Wherry	Harold I. Lillie
1937. Frank R. Spencer	Bernard J. McMahon
1938. Ralph A. Fenton	Frederick T. Hill
1939. John H. Foster	Thomas R. Gittins
1940. Charles H. Porter	Gordon F. Harkness
1941. Arthur W. Proetz	Henry B. Orton
1942-3. Harold I. Lillie	Dean M. Lierle
1944-5. John J. Shea	Thomas C. Galloway
1946. H. Marshall Taylor	C. Stewart Nash
1947. John J. Shea	Frederick A. Figi
1948. Henry B. Orton	Anderson C. Hilding
1949. LeRoy A. Schall	Fletcher D. Woodward
1950. W. Likely Simpson	Lyman G. Richards
1951. Wm. J. McNally	Thomas C. Galloway
1952. J. Mackenzie Brown	Edwin N. Broyles
1953. Claude C. Cody	Daniel S. Cuning
1954. James H. Maxwell	Clyde A. Heatly
1955. Robert L. Goodale	Paul H. Holinger
1956. Henry M. Goodyear	Robert E. Priest
1957. Francis E. LeJeune	Pierre P. Viole
1958. Charles Blassingame	Chevalier L. Jackson
1959. James Maxwell	Oliver Van Alyea
1960. Walter Theobald	Anderson Hilding
1961. Julius W. McCall	P. E. Ireland
1962. Paul M. Moore	Jerome A. Hilger
1963. Paul M. Holinger	Lester A. Brown
1964. G. Slaughter Fitz-Hugh	Daniel C. Baker
1965. C. E. Munoz-MacCormick	Arthur J. Cracovaner
1966. Lawrence R. Boies	G. Edward Tremble

Secretaries and Treasurers

1879. G. M. Lefferts	1895. H. L. Swain
1882. D. Bryson Delavan	1900. P. E. Newcomb
1889. C. H. Knight	1911. Harmon Smith

Secretaries

1912. Harmon Smith	1939. Charles J. Imperatori
1918. D. Bryson Delavan	1942. Arthur W. Proetz
1919. J. M. Ingersoll	1947. Louis H. Clerf
1920. George M. Coates	1952. Harry P. Schenck
1933. William V. Mullin	1957. James H. Maxwell
1935. James A. Babbitt	1959. Lyman G. Richards

Treasurers

1912. J. Payson Clark	1939. Frederick T. Hill
1923. George Fetterolf	1948. Gordon F. Harkness
1932. William V. Mullin	1953. Fred W. Dixon
1933. James A. Babbitt	1958. Francis E. LeJeune
1935. Charles J. Imperatori	1962. Alden H. Miller

Librarians

1879. F. H. Bosworth	1930. John F. Barnhill
1883. T. R. French	1934. Burt R. Shurly
1903. J. H. Bryan	1935. George M. Coates

Librarian and Historian

1936. George M. Coates	1944. Louis H. Clerf
------------------------	----------------------

Librarian, Historian and Editor

1947. Harry P. Schenck	1955. Edwin N. Broyles
1952. Bernard J. McMahon	1960. Francis W. Davison
1964. F. Johnson Putney	

PAST FELLOWS

Dates indicate original election to the Association

**Deceased*

Honorary Fellows

- *1908. Barnhill, John F., Miami Beach, Florida.
- *1893. Birkett, Herbert S., Montreal, Canada.
- *1878. Bosworth, Francke H., New York City.
- *1917. Coates, George M., Philadelphia, Pa.
- *1918. Dean, Lee Wallace, St. Louis, Mo.
- *1881. Delavan, D. Bryson, New York City.
- *1893. deRoaldes, Arthur W., New Orleans, La.
- *1890. De La Sota Y. Lastra, Ramon, Seville, Spain.
- *1923. Fenton, Ralph A., Portland, Oregon
- *1879. French, Thomas R., Brooklyn, N. Y.
- *1880. Garcia, Senior Manuel, London, England.
- *1903. Harris, Thos. J., New York City.
- *1907. Jackson, Chevalier, Schwenksville, Pa.
- *1878. Johnston, Samuel, Baltimore, Md.
- *1878. Lefferts, George Morewood, Katonah, N. Y.
- *1914. Levy, Robert, Denver, Colo.
- *1918. Lewis, Fielding O., Media, Pa.
- *1883. Mackenzie, John N., Baltimore, Md.
- *1881. Mackenzie, Sir Morel, London, England.
- *1910. Masser, Ferdinand, Naples, Italy.
- *1904. Mosher, Harris P., Marblehead, Mass.
- *1910. Moure, J. J. E., Bordeaux, France.
- *1937. Nager, F. R., Zurich, Switzerland.
- *1918. Oliver, H. K., Boston, Mass.
- *1906. Pierce, Norval Harvey, San Diego, Calif.
- *1924. Proetz, Arthur C., St. Louis, Mo.
- *1909. Semon, Sir Felix, Great Missenden, England.
- *1878. Solis-Cohen, J., Philadelphia, Pa.
- *1889. Swain, Henry L., New Haven, Conn.
- *1914. Thomson, Sir St. Clair, London, Eng.
- *1903. Tilley, Herbert, London, England.
- *1914. Wagner, Clinton, New York City.
- *1890. Wright, Jonathan, Pleasantville, N. Y.

Corresponding Fellows

- *1892. Browne, Lennox, London, England.
- *1938. Blair, Vilray P., St. Louis, Missouri.
- *1940. Colledge, Lionel, London, England.
- *1901. Collier, Mayo, Kearsney Abbey, Kent, England.
- *1893. Desvernine, Carlos M., Havana, Cuba.
- *1930. Emerson, Francis P., Franklin, Mass.
- *1961. Faaborg-Andersen, Knud, Nykobing, Denmark.
- *1936. Fraser, John S., Edinburgh, Scotland.
- *1901. Grant, Sir James Dundas, London, England.
- *1887. Cougenheim, A., Paris, France.
- *1894. Holden, Edgar, Newark, N. J.
- *1919. Kelly, Adam Brown, Helensburgh, Scotland.
- *1881. Labus, Carlo, Milan, Italy.
- *1950. Larsell, Olof, Portland, Oregon.
- *1931. LasSagna, Francesco, Parma, Italy.
- *1926. Law, Frederick M., New York, N. Y.
- *1921. LeMaitre, Ferdinand, Paris, France.
- *1902. Lermoyez, Marcel, Paris, France.
- *1897. Luc, H., Paris, France.
- *1896. MacDonald, Greville, Haslemere, Surrey, England.
- *1894. MacIntyre, John, Glasgow, Scotland.
- *1903. McBride, P., York, England.
- *1920. McKenzie, Dan, London, England.
- *1919. McKernon, James F., New Canaan, Conn.
- *1880. Meyer, Wilhelm, Copenhagen, Denmark.
- *1910. Moure, J. J. E., Bordeaux, France.
- *1896. Mygind, Holger, Copenhagen, Denmark.
- *1950. Neil, James Hardie, Auckland, New Zealand.
- *1919. Paterson, Donald Rose, Cardiff, Wales.
- *1941. Patterson, Norman, Herts, England.
- *1919. Rogers, John, Jr., New York City.
- *1894. Sajous, C. E. DeM., Philadelphia, Pa.
- *1896. Schmiegelow, Ernst, Copenhagen, Denmark.
- *1946. Segura, Eliseo, Buenos Aires, Argentina.
- *1940. Soto, E. Fernandez, Havana, Cuba.
- *1881. Thornton, Pugin, London, England.
- *1913. Turner, A. Logan, Edinburgh, Scotland.
- *1880. Whistler, W. McNeil, London, England.
- *1901. Wingrave, Wyatt, Lyme Regis, Dorset, England.
- *1894. Wolfenden, R. Norris, Kent, England.

Emeritus Fellows

- *1936. Ballenger, Howard C., Winnetka, Ill.
- *1923. Barlow, Roy A., Nova Scotia, Canada.
- *1915. Barnes, Harry Aldrich, Kingston, Mass.
- *1928. Beck, Joseph C., Chicago, Illinois.
- *1921. Berry, Gordon, Worcester, Mass.
- *1941. Bowers, Wesley C., New York, N. Y.
- *1901. Brown, J. Price, Toronton, Canada.
- *1891. Bryan, Joseph H., Washington, D. C.
- *1913. Butler, Ralph, Philadelphia, Pa.
- *1930. Campbell, Edward H., Philadelphia, Pa.
- *1897. Clark, J. Payson, Boston, Mass.
- *1899. Cobb, Frederick C., Bradenton, Florida.
- *1939. Cody, Claude C., Jr., Houston, Texas.
- *1905. Coffin, Lewis A., New York City.
- *1893. Coolidge, Algernon, Boston, Mass.
- *1937. Crowe, Samuel J., Baltimore, Maryland.
- *1941. Cunning, Daniel S., New York City.
- *1913. Dabney, Virginus, Washington, D. C.
- *1882. De Blois, Thomas Amory, Boston, Mass.
- *1941. Dixon, Fred W., Shaker Heights, Ohio.
- *1892. Farlow, John W., Boston, Mass.
- *1922. Forbes, Henry H., New York City.
- *1933. Foster, John H., Houston, Texas.
- *1905. Freer, Otto T., Chicago, Ill.
- *1940. Gatewood, E. Tribble, Richmond, Va.
- *1880. Gleitsmann, Joseph W., New York City.
- *1922. Goldsmith, Perry G., Toronto, Canada.
- *1898. Goodale, Joseph L., Ipswich, Mass.
- *1932. Graham, Harrington B., San Francisco, California.
- *1906. Greene, D. Crosby, Jr., Boston, Mass.
- *1917. Greene, Joseph B., Asheville, N. C.
- *1950. Hall, Colby, Encino, Calif.
- *1905. Halsted, Thomas H., Los Angeles, Calif.
- *1896. Hardie, Thomas Melville, Chicago, Ill.
- *1915. Hastings, Hill, Los Angeles, Calif.
- *1944. Havens, Fred Z., Rochester, Minn.
- *1888. Hinkel, Frank Whitehill, Buffalo, New York.
- *1895. Hopkins, Frederick E., Springfield, Mass.
- *1930. Houser, Karl M., Ardmore, Pa.
- *1927. Hubbard, Thomas, Toledo, Ohio.

- *1919. Hurd, Lee Maidment, Rowayton, Conn.
- *1920. Imperatori, Charles J., Essex, N. Y.
- *1904. Ingersoll, John Marvin, Miami, Fla.
- *1928. Jarvis, DeForest C., Barre, Vt.
- *1939. Johnston, William H., Santa Barbara, Calif.
- *1918. Kenyon, Elmer L., Chicago, Ill.
- *1921. Kernan, John D., New York
- *1929. Kistner, Frank B., Portland, Oregon.
- *1885. Knight, Charles H., New York City.
- *1939. Large, Secord H., Cleveland, Ohio.
- *1894. Leland, George A., Boston, Mass.
- *1922. Lillie, Harold I., Rochester, Minn.
- *1943. Lincoln, William R., Cleveland, Ohio.
- *1928. Lyman, Harry Webster, St. Louis, Mo.
- *1886. MacCoy, Alexander W., Philadelphia, Pa.
- *1941. Martin, Robert C., San Francisco, Cal.
- *1896. Mayer, Emil, New York City.
- *1951. McCart, Howard W. D., Toronto, Canada.
- *1939. McCaskey, Carl H., Indianapolis, Indiana.
- *1943. McCullagh, Samuel, New York, N. Y.
- *1923. McKinney, Richmond, Memphis, Tenn.
- *1928. MacPherson, Duncan, New York, N. Y.
- *1939. Myers, John L., Kansas City, Mo.
- *1922. New, Gordon B., Rochester, Minn.
- *1878. Porter, William, Ocean Springs, Miss.
- *1901. Myles, Robert C., New York City.
- *1923. Newhart, Horace, Minneapolis, Minn.
- *1903. Packard, Francis R., Philadelphia, Pa.
- *1942. Potts, John B., Omaha, Nebr.
- *1903. Renner, W. Scott, Buffalo, N. Y.
- *1897. Rhodes, John Edwin, Chicago, Ill.
- *1884. Rice, Clarence C., New York City.
- *1905. Richards, George L., South Yarmouth, Mass.
- *1878. Robinson, Beverly, New York City.
- *1921. Sauer, William E., St. Louis, Mo.
- *1923. Sewall, Edward C., Palo Alto, Cal.
- *1930. Seydell, Ernest M., Wichita, Kansas
- *1907. Shambaugh, George E., Chicago, Ill.
- *1908. Smith, Harmon, New York City.
- *1923. Spencer, Frank R., Boulder, Colo.
- *1927. Tobey, Harold G., Boston, Mass.

- *1925. Tucker, Gabriel, Haverford, Pa.
- *1892. Wagner, Henry L., San Francisco, Calif.
- *1892. Watson, Arthur W., Philadelphia, Pa.
- *1948. Whalen, Edward J., Hartford, Conn.
- *1922. White, Francis W., New York, N. Y.
- *1939. Wilson, J. Gordon, Old Bennington, Vt.
- *1905. Wood, George B., Wynnewood, Pa.

Active Fellows

- *1880. Allen, Harrison, Philadelphia, Pa.
- *1917. Arrowsmith, Hubert, Brooklyn, N. Y.
- *1879. Asch, Morris J., New York City.
- *1942. Ashley, Rae E., San Francisco, Cal.
- *1923. Babbitt, James A., Philadelphia, Pa.
- *1906. Ballenger, William L., Chicago, Ill.
- *1880. Bean, C. E., St. Paul, Minn.
- *1949. Beck, August L., New Rochelle, N. Y.
- *1904. Berens, T. Passmore, New York City.
- *1924. Bigelow, Nolton, Providence, R. I.
- *1938. Blassingame, Charles D., Memphis, Tenn.
- *1893. Bliss, Arthur Ames, Philadelphia, Pa.
- *1951. Boyden, Guy L., Portland, Oregon
- *1895. Boylan, J. E., Cincinnati, Ohio.
- *1932. Brown, John Mackenzie, Los Angeles, Calif.
- *1892. Brown, Moreau R., Chicago, Ill.
- *1933. Buckley, Robert E., New York City.
- *1915. Canfield, R. Bishop, Ann Arbor, Mich.
- *1934. Carmack, John Walter, Indianapolis, Ind.
- *1924. Carmody, Thomas E., Denver, Colo.
- *1889. Casselberry, William E., Chicago, Ill.
- *1883. Chamberlain, C. W., Hartford, Conn.
- *1917. Chamberlin, William B., Cleveland, Ohio.
- *1896. Chappell, W. F., New York City.
- *1882. Chapman, S. Hartwell, New Haven, Conn.
- *1902. Coakley, Cornelius G., New York City.
- *1913. Coffin, Rockwell C., Boston, Mass.
- 1918. Cox, Gerald H., New York City.
- *1880. Cushing, E. W., Boston, Mass.
- *1878. Cutter, Ephraim, West Falmouth, Mass.
- *1880. Daly, W. H., Pittsburgh, Pa.
- *1878. Davis, F. H., Chicago, Ill.
- *1941. Davis, Warren B., Philadelphia, Pa.

1926. Dennis, Frank Lownes, Colorado Springs, Col.
*1901. Dickerman, E. T., Chicago, Ill.
*1878. Donaldson, Frank, Baltimore, Md.
*1947. Engler, Clarence W., Cleveland, Ohio.
*1954. Equen, Murdock S., Atlanta, Ga.
*1935. Eves, Curtis C., Philadelphia, Pa.
*1919. Faulkner, E. Ross, New York City.
*1914. Fetterolf, George, Philadelphia, Pa.
*1901. Freeman, Walter J., Philadelphia, Pa.
*1917. Friedberg, Stanton A., Chicago, Ill.
1940. Fuchs, Valentine H., New Orleans, La.
*1897. Frothingham, Richard, New York City.
1909. Getchell, Albert C., Worcester, Mass.
*1907. Gibb, Joseph S., Philadelphia, Pa.
*1940. Gill, William D., San Antonio, Texas.
*1878. Glasgow, William Carr, St. Louis, Mo.
*1913. Goldstein, Max A., St. Louis, Mo.
*1905. Grayson, Charles P., Philadelphia, Pa.
*1934. Grove, William E., Milwaukee, Wisconsin.
*1933. Harkness, Gordon F., Davenport, Iowa.
*1878. Hartman, J. H., Baltimore, Md.
*1945. Hickey, Harold L., Denver, Colo.
*1879. Holden, Edgar, Newark, N. J.
*1907. Holmes, Christian R., Cincinnati, Ohio.
*1882. Hooper, Franklin H., Boston, Mass.
*1893. Hope, George B., New York City.
*1938. Hourn, George E., St. Louis, Mo.
*1939. Hunt, Westley Marshall, New York, N. Y.
*1901. Hyatt, Frank, Washington, D. C.
*1925. Iglaue, Samuel, Cincinnati, Ohio.
*1878. Ingals, E. Fletcher, Chicago, Ill.
*1882. Ives, Frank L., New York City.
*1938. Jackson, Chevalier L., Philadelphia, Pa.
*1880. Jarvis, William C., New York City.
*1878. Johnson, Hosmer A., Chicago, Ill.
*1879. Johnson, Woolsey, New York City.
*1960. Johnston, Kenneth C., Chicago, Ill.
*1944. Jones, Marvin F., New York City.
*1879. Kealhofer, R. H., St. Louis, Mo.
*1942. King, Edward D., North Hollywood, Calif.
*1901. King, Gordon, New Orleans, La.

- *1885. Knight, Charles H., New York City.
- *1878. Knight, Frederick Irving, Boston, Mass.
- *1898. Kyle, D. Braden, Philadelphia, Pa.
- *1880. Langmaid, Samuel W., Boston, Mass.
- *1878. Lincoln, Rufus P., New York City.
- *1911. Lockard, Lorenzo B., Denver, Colo.
- *1913. Loeb, Hanau W., St. Louis, Mo.
- *1897. Logan, James E., Kansas City, Mo.
- *1935. Looper, Edward A., Baltimore, Maryland.
- *1888. Lowman, John H., Cleveland, Ohio.
- *1919. Lynah, Henry L., New York City.
- *1952. Lynch, Mercer G., New Orleans, La.
- *1915. Lynch, Robert Clyde, New Orleans, La.
- *1879. McBurney, Charles, New York City.
- *1927. McGinnis, Edwin, Chicago, Ill.
- 1936. McGregor, Gregor, Toronto, Canada.
- *1913. McKimmie, O. A., Washington, D. C.
- *1945. McLaurin, John G., Dallas, Texas.
- *1885. McSherry, H. Clinton, Baltimore, Md.
- *1914. Mackenty, John E., New York City.
- *1898. Makuen, G. Hudson, Philadelphia, Pa.
- *1881. Major, G. W., Montreal, Canada.
- *1948. Maxwell, James H., Ann Arbor, Mich.
- *1954. Meltzer, Philip E., Boston, Mass.
- *1881. Morgan, E. C., Washington, D. C.
- *1950. Morrison, Lewis F., San Francisco, Calif.
- *1940. Morrison, William W., New York City.
- *1886. Mulhall, J. C., St. Louis, Mo.
- *1925. Mullin, William V., Cleveland, Ohio.
- *1914. Munger, Carl E., Waterbury, Conn.
- *1892. Murray, T. Morris, Washington, D. C.
- *1881. Mynter, H., Buffalo, N. Y.
- *1893. Newcomb, James E., New York City.
- *1895. Nichols, J. E. H., New York City.
- *1927. Orton, Henry B., Newark, N. J.
- *1894. Park, William H., New York City.
- *1892. Porcher, W. Peyre, Charleston, S. C.
- *1927. Porter, Charles T., Boston, Mass.
- *1908. Randall, B. Alexander, Philadelphia, Pa.
- *1882. Rankin, D. N., Allegheny, Pa.
- *1902. Richardson, Charles W., Washington, D. C.

- *1930. Ridpath, Robert E., Philadelphia, Pa.
- *1879. Roe, John O., Rochester, N. Y.
- *1945. Robb, James M., Detroit, Michigan.
- *1953. Roberts, Sam E., Kansas City, Mo.
- *1881. Robertson, J. M., Detroit, Mich.
- *1913. Roy, Dunbar, Atlanta, Ga.
- *1878. Rumbold, T. F., St. Louis, Mo.
- *1879. Seiler, Carl, Philadelphia, Pa.
- *1928. Shea, John Joseph, Memphis, Tennessee.
- *1893. Shields, Charles M., Richmond, Pa.
- *1909. Shurly, Burt R., Detroit 1, Mich.
- *1878. Shurly, E. L., Detroit, Mich.
- *1892. Simpson, William Kelly, New York City.
- *1919. Skillern, Ross H., Philadelphia, Pa.
- *1909. Sluder, Greenfield, St. Louis, Mo.
- *1879. Smith, Andrew H., Geneva, N. Y.
- *1932. Smyth, Duncan Campbell, Boston, Mass.
- *1928. Sonnenschein, Robert, Chicago, Ill.
- 1924. Stein, Otto J., Chicago, Ill.
- 1934. Stevenson, Walter, Quincy, Ill.
- *1911. Staut, George C., Philadelphia, Pa.
- *1879. Tauber, Bernhard, Cincinnati, Ohio.
- *1924. Taylor, Hermon Marshall, Jacksonville, Fla.
- *1903. Theisen, Clement F., Albany, N. Y.
- *1899. Thorner, Max, Cincinnati, Ohio.
- *1892. Thrasher, Allen B., Cincinnati, Ohio.
- *1937. Tobey, George L., Jr., Boston, Mass.
- *1888. Van der Poel, S. O., New York City.
- *1938. Vail, Harris H., Cincinnati, Ohio.
- *1936. Voislowsky, Antonie P., New York City.
- *1933. Wanamaker, Allison T., Seattle, Wash.
- 1896. Ward, Marshall R., Pittsburgh, Pa.
- *1879. Ward, Whitfield, New York City.
- *1886. Westbrook, Benjamin F., Brooklyn, N. Y.
- *1924. Wherry, William P., Omaha, Neb.
- *1924. White, Leon E., Boston, Mass.
- *1939. Williams, Horace J., Philadelphia, Pa.
- *1942. Wishart, D. E. Staunton, Toronto, Canada.
- *1922. Wishart, David J. G., Toronto, Ontario.
- *1940. Wood, V. Visscher, St. Louis, Mo.
- *1896. Wollen, Green V., Indianapolis, Ind.
- *1953. Wilkerson, William W., Nashville, Tenn.

INDEX

to the

TRANSACTIONS

of the

AMERICAN
LARYNGOLOGICAL ASSOCIATION

1967

I N D E X

A

Acquarelli, Mario	
Carcinoma of Trachea (with William W. Lee and Edward J. Passaro)	158
Adams, F.	
Physiology of the Fetal Larynx and Lung (with Donald T. Desilets and Bernard Towers)	24
Address	
Guest of Honor: McNally, William J.	20
President: Pressman, Joel J.	11
Airway Problems, treatment in the newborn (Ferguson)	55
Anomalies	
Larynx, congenital (Holinger)	35
Application of Voiceprint Techniques to	
Vocal Tract Analysis (Kersta)	106
Asai Technique for Vocal Rehabilitation after Total Laryngectomy (Miller)	141

B

Banovetz, John	
(see Priest, Robert E.)	83
Biomechanics of Injury to the Larynx and Adjacent Structures (Nahum)	78
Bryce, Douglas P.	
Trough Method of Repair of Laryngo-tracheal Injuries	91

C

Carcinoma of Trachea (Acquarelli, Lee and Passaro)	158
Cardiovascular Reflexes from the Larynx and Pharynx (Kirchner and Suzuki) ..	71
Cilia	
Respiratory, electron studies (Tremble)	148

Congenital	
Congenital anomalies of the larynx (Holinger)	35

D

Desilets, D. T.	
(see Adams, F.)	24
Dunbar, J. Scott	
Laryngomalacia: Its Radiologic Demonstration	68

E

Electron Studies	
Reference to Respiratory Cilia (Tremble)	148
Esophagostomy	
Cervical, elective (Fitz-Hugh and Sly)	114
Esophagus	
Elective cervical esophagostomy (Fitz-Hugh and Sly)	114

F

Ferguson, C. F.	
Treatment of Airway Problems in the Newborn	55
First Experiences with the Asai Technique for Vocal Rehabilitation after Total Laryngectomy (Miller)	141
Fitz-Hugh, G. Slaughter	
Elective cervical esophagostomy (with Donald Sly)	114

H

Huff, John S.	
(see Priest, Robert E.)	83

I

Infant	
Inflammatory diseases of larynx (Davison)	45

- Treatment of Airway Problems
(Ferguson) 55
- Inflammatory Diseases of the Larynx of
Infants and Small Children (Davison) 45
- Injuries
- Biomechanics of, to the larynx and
 adjacent structures (Nahum) 78
- Laryngotracheal (Priest, Huff and
 Banovetz) 83
- Repair of laryngotracheal by trough
 method (Bryce) 91
- K**
- Kersta, L. G.
- Application of Voiceprint Techniques
 to Vocal Tract Analysis 106
- Kirchner, John A.
- Cardiovascular Reflexes from the
 Larynx and Pharynx (with
 Masafumi Suzuki) 71
- L**
- Laryngectomy
- Asai Technique for Vocal
 Rehabilitation (Miller) 141
- Laryngomalacia: Its Radiologic
Demonstration (Dunbar) 68
- Laryngotracheal Injuries (Priest, Huff
and Vanovetz) 83
- Repair by Trough Method (Bryce) 91
- Larynx
- Biomechanics of Injury (Nahum) 78
- Cardiovascular reflexes from (Kirchner
 and Suzuki) 71
- Congenital Anomalies (Holinger) 35
- Inflammatory Diseases of the Larynx
 of Infants and Small Children
 (Davison) 45
- Physiology of the Fetal Larynx and
 Lung (Adams, Desilets and Towers) 24
- Lee, William W.
 (see Acquarelli, Mario) 158
- Lung
- Physiology of the Fetal Larynx and
 Lung (Adams, Desilets and Towers) 24
- M**
- McNally, William J.
- Address of Guest of Honor 20
- Miller, Alden H.
- First Experiences with the Asai Tech-
 nique for Vocal Rehabilitation after
 Total Laryngectomy 141
- N**
- Nahum, Alan
- Biomechanics of Injury to the Larynx
 and Adjacent Structures 78
- P**
- Passaro, Edward J.
- (see Acquarelli, Mario) 158
- Pedicle Flap
- Use of Tubed in Head and Neck
 Surgery (Weaver) 120
- Pharynx
- Cardiovascular reflexes from (Kirchner
 and Suzuki) 71
- Physiology
- Fetal Larynx and lung (Adams,
 Desilets and Towers) 24
- Pressman, Joel J.
- Address of President 11
- Priest, Robert E.
- Laryngotracheal injuries (with John S.
 Huff and John Banovetz) 83
- R**
- Radiology
- Laryngomalacia, demonstration by
 (Dunbar) 68

Recent Electron Studies, with Special
Reference to Respiratory Cilia
(Tremble) 148

Reflexes

Cardiovascular from the larynx and
pharynx (Kirchner and Suzuki) 71

Repair

Laryngotracheal Injuries by Trough
Method (Bryce) 91

Respiratory

Electron Studies with reference to Cilia
(Tremble) 148

S

Sly, Donald

(see Fitz-Hugh, G. Slaughter) 114

Surgery

Use of Tubed Pedicle Flap in Head and
Neck Surgery (Weaver) 120

Suzuki, Masafumi

(see Kirchner, J. A.) 71

T

Towers, B.

(see Adams, F.) 24

Trachea

Carcinoma (Acquarelli, Lee and
Passaro) 158

Treatment of Airway Problems in the
Newborn (Ferguson) 55

Tremble, G. Edward

Recent Electron Studies, with Special
Reference to Respiratory Cilia 148

Trough Method of Repair of Laryngo-
tracheal Injuries (Bryce) 91

Tubed Pedicle Flap

Use in Head and Neck Surgery
(Weaver) 120

U

Use of Tubed Pedicle Flap in Head and
Neck Surgery (Weaver) 120

V

Vocal Rehabilitation

Asai Technique of Total Laryngectomy
(Miller) 141

Voiceprint Technique

Application to vocal tract analysis
(Kersta) 106

W

Weaver, Delmar F.

Use of Tubed Pedicle Flap in Head and
Neck Surgery 120



