Transactions

American Laryngological Association

———

NINETY-FIRST VOLUME

"DOCENDO DISCIMUS"

TRANSACTIONS

OF THE

NINETY-FIRST ANNUAL MEETING

OF THE

American Laryngological Association

1970

HELD AT

THE HOLLYWOOD BEACH HOTEL

HOLLYWOOD, FLORIDA

APRIL 24 AND 25, 1970

PUBLISHED BY THE ASSOCIATION

ST. LOUIS, MO.

1970

Contents.

PAGE

List of Officers 7

Registration 9

Presidential Address, Alden H. Miller, M.D. 11

Introduction of the Guest of Honor
Alden H. Miller, M.D. 20

Address of the Guest of Honor
When Color Came to Laryngeal Movies.
Francis E. LeJeune, M.D. 22

Cervical Osteophytes and Dysphagia.
William H. Saunders, M.D. 25

Esophageal Motility Studies in Globus Sensation.
David D. Caldarelli, M.D., Albert H. Andrews, Jr., M.D.,
Arthur J. Derbyshire, Ph.D. 32

Discussion of Papers by Dr. Saunders and Dr. Caldarelli, et al.
Francis L. Lederer, M.D. 34
John A. Kirchner, M.D. 34
Robert B. Lewy, M.D. 35
Albert H. Andrews, Jr., M.D. 35
Dr. Saunders (closing) 35
Dr. Caldarelli (closing) 35

The Diagnosis and Surgical Management of Congenital Tracheoesophageal Fistula without Atresia of the Esophagus. Seymour R. Cohen, M.D. 36

Discussion:
Charles F. Ferguson, M.D. 42
Alden H. Miller, M.D. 43

CONTENTS

PAGE

The Radiological Treatment of Juvenile Nasopharyngeal Angiofibromas.
T. D. R. Briant, M.D., P. J. Fitzpatrick, M.D., Howard Book, M.D. 44

Discussion:

John A. Kirchner, M.D. 49
Daniel Miller, M.D. 49
John S. Lewis, M.D. 49
Stanton A. Friedberg, M.D. 50
Rollyn M. Butler, M.D. 50
Dr. Briant (closing) 50

Reconstructive Surgery Related to Laryngology.
Richard T. Farrior, M.D. 52

Laryngeal Edema: An Experimental Study.
Hugh F. Biller, M.D., Robert C. Bone, M.D.,
Joseph E. Harvey, M.D., Joseph H. Ogura, M.D. 68

Discussion:

Douglas P. Bryce, M.D. 71
Charles F. Ferguson, M.D. 71
Dr. Biller (closing) 71

Laryngotracheal Trauma in Combat Casualties.
Lt. Col. Lee H. Miller, M.C. 72

Discussion:

Douglas P. Bryce, M.D. 74
Francis L. Lederer, M.D. 75
Herbert Harris, M.D. 75
Richard T. Farrior, M.D. 75
William W. Montgomery, M.D. 76
Lt. Col. Miller (closing) 76

Polychondritis in a Newborn Presenting as Tracheomalacia.
Carl H. Johner, M.D., Paul A. Szanto, M.D. 77

CONTENTS

PAGE

Vocal Cord Transplantation in Dogs.
Jerrie Cherry, M.D., W. Davis, M.D., A. Rosenblatt, B.A.,
R. Coleman, Ph.D. 80

Discussion:

Joseph H. Ogura, M.D. 86

Douglas P. Bryce, M.D. 86

Herbert H. Dedo, M.D. 86

Dr. Cherry (closing) 86

The Two Stage Asai Technique of Laryngectomy. (Movie)
F. Johnson Putney, M.D., Carter S. Bagley, M.D. 89

Human Larynx Homotransplantation. (Movie)
Professor Paul Kluyskens 93

Supracricoid Laryngectomy. (Movie)
Takeshi Kitamura, M.D., Kiyoshi Togawa, M.D., Toshio Kaneko, M.D.,
Tokuji Unno, M.D. 94

Discussion of Presentations by Drs. Putney, Kitamura, and Kluyskens:

Alden H. Miller, M.D. 99

Joseph L. Goldman, M.D. 100

Joseph H. Ogura, M.D. 100

Preoperative Radiation of Larynx: Analysis of Serial Sections.
Emanuel M. Skolnik, M.D., Burton J. Soboroff, M.D.,
M. Eugene Tardy, Jr., M.D., Ralph J. Levin, M.D.,
Louis T. Tenta, M.D. 101

Discussion:

John A. Kirchner, M.D. 109

Dr. Soboroff (closing) 109

CONTENTS

PAGE

A Correlation of Clinical Staging, Pathological Findings and Five Year End Results in Surgically Treated Cancer of the Larynx. Charles M. Norris, M.D., Gabriel F. Tucker, Jr., M.D., Burns F. Kuo, M.D., William F. Pitser, M.D. 110

Discussion:

John A. Kirchner, M.D. 125

Charles N. Norris, M.D. 125

Dr. Tucker (closing) 126

Memorials:

Frederick Adam Figi, M.D. 128

Albert Carl Furstenberg, M.D. 131

Frederick Thayer Hill, M.D. 134

Fletcher Drummond Woodward, M.D. 137

Executive Sessions and Reports of Officers and Committees 140

Presentation of Newcomb Award 152

Presentation of de Roaldes Award 152

List of Fellows, 1970 154

Active Fellows 154

Honorary Fellows 160

Corresponding Fellows 160

Emeritus Fellows 161

Benefactors 164

Recipients of the de Roaldes Award 165

Recipients of the Casselberry Award 166

Recipients of the Newcomb Award 167

Past Officers 168

Past Fellows 173

Index 184



THOSE IN ATTENDANCE AT THE NINETY-FIRST ANNUAL MEETING

First Row: Reed, Montgomery, Sanders, Lederer, Clerf, Van Alyea, Davison, Lathrop, LeJeune, A. Miller, Murtagh, Putney, Bordley, Friedberg, Atkins, Norris, Harris, Schenck, Hart, Fitz-Hugh, Woodman. *Second Row:* Lewis Trible, Baker, Dickinson, Weille, D. Miller, Kline, Austin Smith, Andrews, Tremble, Hilding, Ferguson, Priest, Brown, Goldman, Saunders, Frazer, Kirchner. *Third Row:* Moore, Ogura, Skolnik, Farrior, Chandler, Tucker, Sisson, Bryce. *Fourth Row:* Arnold, Cocke, Suehs, Hanckel, Knight, Hutcheon, O'Neil, Alexander, Jones, Pratt, Holmes, Ballenger, Lewy, Brewer, Munoz-MacCormick, Henry, Pang, Conley.

OFFICERS FOR 1969-1970

PRESIDENT

ALDEN H. MILLER, M.D.

FIRST VICE-PRESIDENT

JOSEPH P. ATKINS, M.D.

SECOND VICE-PRESIDENT

STANTON A. FRIEDBERG, M.D.

SECRETARY

FRANK D. LATHROP, M.D.

TREASURER

CHARLES M. NORRIS, M.D.

LIBRARIAN, HISTORIAN AND EDITOR

F. JOHNSON PUTNEY, M.D.

COUNCIL

The above Ex-officio and

PAUL H. HOLINGER, M.D.

FRANCIS A. SOOY, M.D.

LAWRENCE R. BOIES, M.D.

FRANCIS W. DAVISON, M.D.

TRANSACTIONS OF THE
NINETY-FIRST ANNUAL MEETING

OF THE

American Laryngological Association

HELD AT

THE HOLLYWOOD BEACH HOTEL

HOLLYWOOD, FLORIDA

APRIL 24 AND 25, 1970

———

The Ninety-first Annual Meeting of the American Laryngological Association was called to order by the President Dr. Alden H. Miller, at the Hollywood Beach Hotel, Hollywood, Florida on April 24, 1970, at 8:20 A.M.

REGISTRATION

ALEXANDER, FRED W.
ALFARO, VICTOR R.
ANDREWS, ALBERT H., JR.
ARNOLD, GODFREY E.
ATKINS, JOSEPH P.
AUSBAND, JOHN R.
BAKER, DANIEL C., JR.
BAXTER, JAMES D.
BORDLEY, JOHN E.
BREWER, DAVID W.
BROWN, LESTER A.
BRYCE, DOUGLAS P.
CARDWELL, EDGAR P.
CHANDLER, J. RYAN
CLERF, LOUIS H.
CLEVES, CARLOS C.
COCKE, EDWIN W.
CONLEY, JOHN J.
DALY, JOHN F.
DAVISON, FRANCIS W.
DICKINSON, JOHN T.
EAGLE, WATT W.
FARRIOR, RICHARD T.
FEARON, BLAIR

Ferguson, Charles F.

Fitz-Hugh, G. Slaughter

Friedberg, Stanton A.

Goldman, Joseph L.

Hanckel, Richard W., Jr.

Harris, Herbert

Hart, Verling K.

Henry, G. Arnold

Hilding, Anderson C.

Hilger, Jerome A.

Holmes, Edgar M.

Hoople, Gordon D.

Jones, Edley H.

Keim, W. Franklin

King, James T.

Kline, Oran R.

Kirchner, John A.

Knight, John S.

Lathrop, Frank D.

Lederer, Francis L.

LeJeune, Francis E.

Lewis, John S.

Lewy, Robert B.

McCall, Julius W.

Miller, Alden H.

Miller, Daniel

Montgomery, William W.

Moore, Paul M.

Munoz-MacCormick, Carlos E.

Murtagh, John A.

Norris, Charles M.

Ogura, Joseph H.

O'Neil, James J.

Pang, Lup Q.

Pratt, Loring W.

Priest, Robert E.

Putney, F. Johnson

Reed, George F.

Sanders, Sam H.

Saunders, William H.

Schenck, Harry P.

Silcox, Louis E.

Sisson, George A.

Skolnik Emanuel M.

Smith, Austin T.

Suehs, Oliver W.

Thornell, William C.

Tremble, G. Edward

Trible, William MacL.

Van Alyea, Oliver E.

Walsh, Theodore E.

Weaver, Delmar F.

Weille, Francis L.

Williams, Henry L.

Woodman, DeGraaf

SCIENTIFIC SESSION

FRIDAY MORNING, APRIL 24, 1970

The first Scientific Session of the Ninety-first Annual Meeting of the American Laryngological Association, Inc., held at the Hollywood Beach Hotel, Hollywood Beach, Florida, convened in the Pageant Room on Friday morning, April 24, 1970, at eight forty-five o'clock, Alden H. Miller, M.D., Los Angeles, California, President of the Association, presiding.

PRESIDENTIAL ADDRESS

An unforgettable event in my life was election to this society. Being its President for a year is surely a pinnacle of achievement for me. For this I am most grateful and sincerely thank the Fellows of the society. I began this year with awe and worries about putting together a program that could equal the productions of our past Presidents. This fear was unnecessary. The Council, our members of long standing and those of recent years swamped me with offers of papers and help in getting papers. I am convinced the program you are about to hear is the finest. That's the tradition of the American Laryngological Association.

Tradition is founded on history. This society has a glorious history of contributions to the advancement of our society. Sometimes we wait too long to document history and then that history is lost by default. In order to prevent this our Council has appointed Doctor Larry Boies and a committee as historians. They will need the help of all of you. I would like the prerogative of these remarks to stimulate and remind you to send to Doctor Boies or to me anything — pictures, papers, programs, anecdotes, instruments, artifacts and memorabilia that might build that history. Maybe my little research into the history of laryngology of the Far West will help. Maybe some of the anecdotes, the recollections will remind you of bits of history of our Association.

This interest of mine began when I set about documenting the history of medicine in the Far West through the paintings of Western artists. These painters, beginning in the early 19th century, pictured the peoples and actual events at the very time the events were happening and thus were most authentic, not guess work. Such a search is made easy by the fact that medicine is really much less than 200 years old in the West and otolaryngology is barely 80 years old in the West. Our American Laryngological Association is 91 years old. Now, let me use some of these Western paintings to tell you of laryngology in the Far West.

Following is a chronology of medicine as it and its practitioners appeared in the Far West:

Indian medicine men
Spanish ship surgeons, 1542
(Don Pedro Prat, 1769)
Explorers: Sir Francis Drake, 1579,
Russians, 1786
Franciscan missionaries
Fur traders and mountain men,
1790's
Lewis and Clark, 1803 - 1805
Garrison surgeons, 1822 - 1848
Medical missionaries, 1837 - 1839
Gold Rush, 1848
Mirror Laryngoscopy, 1854
Medical Societies, 1856

Of course, the natives (the Indians) had always practiced some kind of medicine. At first this was probably done by any of the adult members of the tribes, just as today we practice medicine at home using home remedies and proprietaries. Sooner or later, however, some experts or professionals, the Indian medicine men, made their appearance and practiced their profession in varying degrees and believe it or not in various specialties in each tribe. All of us with knowledge of the West, especially those of us who were born or raised there, know about the Indian medicine men and we will speak more of these interesting doctors and laryngologists later.

The first real surgeons, the first real doctors, to make any appearance were the Spanish ship surgeons in about 1542. However it was not until 1769 that one of these, Don Pedro Prat, became the first doctor actually to practice medicine ashore. The others probably hardly ever stepped ashore but practiced their medicine just aboard their ships. There were also other explorers (Sir Francis Drake, 1579; the Russians around 1786, and later a few Portuguese) who also had surgeons on their ships. But, like the Spaniards, these men came ashore for only a day or two and really did not practice or bring any medicine to the West. Certainly no laryngology.

Next came the Franciscan missionaries who established their chain of missions up the Pacific Coast. They too had no doctors with them. The Fathers themselves ministered to the sick and injured with the knowledge gained at their home bases and from Indian lore of the area about their missions.

Next we enter a most fascinating period, that of the fur traders and the mountain men. It was actually these mountain men, the trappers, who opened the West. If it were not for the fact that the gentlemen of the East liked beaver hats, we would not have had these trappers ranging through our western territories after furs. Possibly the Northwest, maybe all of the West, might not now be a part of the United States but for these men and their explorations and mappings as they carried on their trade of trapping. It was late in the 1790's that these fur traders, and guides first appeared. Later you will see how they practiced laryngology.

Many writers insist that the West was really opened by the Lewis and Clark expedition in 1803 - 1805. It is interesting that the Lewis and Clark expedition had no doctor in its company. President Jefferson, who commissioned them, instructed Lewis and Clark to go to the grand old man of American medicine of that time, Dr. Benjamin Rush and learn from him how to be their own physicians for this two-year trip. Dr. Rush gave them two sheets of paper. On one he listed all the drugs that they should buy. These were purchased for a total cost of $90.69. On the other page he gave them the treatment for all the diseases and conditions that they might encounter. Thus this expedition brought a short segment of medicine and laryngology to the West. Maybe their basic laryngology saved the expedition.

From 1822 to 1848 there were a few doctors, the garrison surgeons of the Spanish (when the Spaniards were still occupying the far western territories) who practiced some medicine on land not only in their garrisons but among the peoples in the neighboring villages and may have brought with them the laryngology of the east coast of that time.

There was another short historical period, which concerns the Oregon territory. This was the time of the medical missionaries. Marcus Whitman came across the plains, the mountains, and the prairies to settle in Walla Walla, Washington in 1837. He was the first real M.D. to cross the Rockies. He was the first real doctor to do surgery west of the Rockies. He not only established a mission and preached his gospel, but practiced medicine among the Indians and the few explorers, trappers, and settlers in his area. The end of his ill-fated career came after only eleven years. He, his family, and his mission, were all massacred, presumably be-

cause he had been unable to cope with a measles epidemic among his Indians. Another medical missionary, Elijah White, appeared some two years later than Whitman to practice in Salem, Oregon. He, too, was well trained and brought some of the first real medicine to the Northwest.

Another name is famous in the history of early medicine of the Northwest. Doctor John McLoughlin, a Scottish doctor, was the chief factor of the Hudson's Bay Trading Company beginning in 1824. He was probably a better physician than the others mentioned but spent most of his time running the affairs of his company. However, he too had a great influence in bringing good medicine to the Northwest. He used mostly herbs in his treatment of disease.

Then came the gold rush in 1848. Snowballing from the handful of doctors practicing or merely present in the West at this time, there suddenly were 1500 or more "doctors." These "doctors" will be the subject of more of my remarks later on. About the same time mirror laryngology was discovered.

Finally, events moved very fast and it will be noted that the West began to get real medicine soon after the start of the gold rush. This advancement received its greatest impetus from the formation of the first medical societies in the West in about 1856.

I will now try to entertain you with the results of some of my research. Remember, however, the frontier that was opened by Lewis and Clark was closed in 1893. So my findings will cover just this period.

Let us go back now to Don Pedro Prat. Most historians place him as the first doctor in the Far West because he was the first of the ship surgeons to come ashore actually to practice medicine. This came about because more than 90 percent of the passengers and company of his ship got scurvy and were dying rapidly by the time they were off the coast of Southern California. He was put ashore near San Diego to try to save the few lives remaining. He stayed ashore, working unsuccessfully with his men, and later practiced medicine with the natives in the area. Soon he joined the Franciscan missionary, Father Junipero Serra, and made some excursion with him on land. He died, demented, at the end of just one year. This coming ashore of Dr. Prat and his men dying of scurvy is quite ironical. He did not know, as the English did, about the use of oranges and limes in the treatment and prevention of scurvy. He established the first hospital in the West, just a framework of willows, covered with bark and hides, and tried unsuccessfully to save the lives of his men and yet failed, in the very area that was to become the greatest citrus-growing area in all the United States.

Let us now consider the Indian medicine men. Most of us, Westerners or not, as children, and later on, learned a great deal about these interesting men from our history books. To me, it is most fascinating that most of these Indian medicine men were short of priest-doctors. In general there was an intertwining of religious beliefs and the practice of medicine. This varied greatly from tribe to tribe and their historians and artists, who pictured them, reveal them in slightly differing roles. Among the Cheyennes, the medicine man was a healer and a joke maker. The Cherokees found that their greatest necessity for religion was the eradication of disease. The majority of the 35 principal ceremonies of the Navahoes were concerned with disease. The Plains Indians, who were the most populous of the Indians, many times made the medicine man their chief, and vice versa. In others, he was a sub-chief. Sometimes he was a war leader. Actually, specialization began with these Indians. I found a note of one medicine man who was a specialist in treating just headaches and another just sore throats. In some tribes the practice and the lore of the medicine man was passed down from chieftain father to son. In others the role of medicine man was assumed after a brave had had a dream or a vision in

which he was told to practice this art. In other tribes he was a magician and a sleight-of-hand artist who passed on his tricks of wizardry and magic to his son or selected brave.

Charles Russell, the most famous of the cowboy artists, usually depicted his medicine men as priests more than as just doctors. To these chiefs came the members of his tribe not only for help medically but spiritually. He was a seer and counseled wisely in all matters and decisions. Yet, in another of his canvases, Russell pictures the medicine man of a different tribe as being a leader of that tribe, a chief or the head chief. Frederic Remington, the other great early Western artist, pictured his medicine men more as magicians and war leaders. One of his most famous paintings, that of Yellow Bird the Medicine Man, shows him throwing dirt in the air as a signal to start the firing in one of the greatest tribal wars.

The medicine lodge or tepee or hut was the first doctor's office in the Far West. Here the medicine man practiced most of his medicine. Early paintings usually depict a patient as lying prone on the ground floor of the lodge. Hanging about were the instruments. These probably consisted of gourd rattles, feather wands, spears, animal or hideous masks, drums and pipes. Hanging from the center pole of the tepee was probably the first medicine bag or kit. Most of these first medicine men kept the tricks of their trade in these bags. In them one would probably find tiny snakes, lizards, insects, rocks, bits of wood or bark, hides or metals, or almost any other material or object. To the surprise of Eastern doctors, one would many times find also an object that these doctors were using themselves in the East. This was usually an animal bone or horn which was hollow and which resembled greatly the cupping tubes of the Eastern practitioner. Somehow these Indian medicine men had learned the art of cupping. In this practice, the larger of the oval ends of the tube was placed over the diseased part, such as the neck, and then the medicine man, or the doctor, would apply the smaller end to his mouth or a bag and apply suction. Sore throat, quinzy, diphtheria were treated this way. The Indian medicine men, with their mastery of sleight-of-hand, excelled in their ability to slip from their hand to the horn or to their mouth one of those little snakes, lizards, insects, or rocks which they kept in their medicine bags. After applying the cupping horn they were able to produce these objects from the patient and assure and convince him that this was the cause of his disease and thus effect a cure. The same objects, palmed in the hand, were also shown to the patient after skin incisions by the medicine man as if they had been thus removed. Maybe we should consider some of this in treating aphonia and dysphonia.

George Catlin, the first of the great painters of the West, depicted a Blackfoot medicine man treating his patient by attempting to frighten evil spirits from the patient with menacing gestures and dances and frightening noise. Some medicine men insisted that their dances and chants were for the purpose of instilling good spirits into the medicine man himself so that he might perform his miracles. I like to think this wasn't a tonsillectomy, tracheotomy or laryngofissure.

Among the Indians, or for that matter anyone else practicing medicine in the Far West during this period, medicine consisted almost completely in the use of herbs, of cupping, of bleeding or scarification, and of the use of sweat baths. Rudolph Kerr depicts an Hidatsa Indian sweat bath in one of his paintings. Tuberculosis and diphtheria in our field were so treated. I can remember as a boy in Montana, living just off the Fort Belknap Indian Reservation, that we had great sport in trying to find out, in the Spring of the year, where these Indian steam baths were constructed. We would hide and wait at the proper time, sometimes tipped off by our friends among the Indian boys, for the tribe to start taking their annual spring complete cleansing baths. The tiny hogans or huts were small, low, rounded

structures made of a framework of saplings over which was stretched either hides or dense foliage. Inside was a hole in the ground into which red-hot stones could be placed. An Indian then entered with a pail of water and someone else closed the tight, small door of the hut. The Indian inside then poured the water on the red-hot rocks producing steam and great heat. He stayed inside as long as he could and then would suddenly pop out of the little door, screeching, yelling and running to plunge into a nearby ice cold stream. These were the reddest red men I have ever seen. Sometimes the medicine man went in the sweat bath with his patient. Croup and asthma could have been treated this way.

Some of the largest tribes of Indians are found in the Southwest. For instance, the Navahoes are the largest single tribe. Among these Indians, the medicine men play a prominent part. They used song, dance, ceremonials, and prayers in their treatment of the sick. Some also used smoke in their rituals and as inhalant therapy, for sore throats, croup and diphtheria. Many of them relied heavily on sand paintings. There is very little recorded history of medicine concerning the Hopis. We have all read about their Kachinas but these beings were really priests. Most of their ceremonials, dances, and prayers were for rain, for their crops, for good luck in all ventures, bountiful harvests, and for the receiving of presents as a reward for the good conduct required of all members of the tribe. However my research so far shows that 3 or 4 dances were used in healing. In pictures of their ceremonial dances, I was able to find only once the appearance of the symbol of their medicine man, a paddle with a zigzag painted stripe. Medicine men of Southern California were called the Hechiceros. The other tribes spreading up the coast into the Northwest and into Canada called their medicine men the shamans. Among the latter, the mask played a large part in their practice of medicine. Ernest Berke drew many of these masks as they were used in the Southwest to scare away the spirits of sickness. In the medicine mask dance of the Clallam Indians on Vancouver Island, one sees masks being used almost identical to those of the Southwest and of the Iroquois False Face Societies.

Let us now leave the Indians and go on to the mountain men. These were the most resourceful, courageous, and often most intelligent of pioneers, explorers, and trail blazers. These were the fur traders, trappers, and guides. They numbered among them such men as Pegleg Smith, Jedediah Smith, Hugh Glass, Kit Carson, and Jim Bridger. They practiced medicine mostly with herbs and maybe a few medicines that they had stuck in their pockets just before they left the Midwest to come West to set and collect from their trap lines.

Especially, they learned the lore of the medicine of the Indian medicine men. They practiced their surgery with a hunting knife, an axe, or a branding iron or other hot metal for cautery. Imagine my surprise to find the description of a tracheotomy done by one of these hunting-knife surgeons in 1820 upon a trapper companion. Diphtheria was quite prevalent in the Far West and this trapper was almost dead from his laryngeal obstruction. His partner slit open his trachea and held the tracheotomy open with two fishhooks placed on each side of the slit and connected around the back of the neck with a thong of buckskin. Near the end of my source material I ran into an old instrument book printed in 1879. In that book was advertised a gadget made up almost exactly the same, with two hooks and an elastic band connecting them, to hold open a tracheotomy incision. These trappers also provided me with the first instance of ear surgery I could find. One of these mountain men, Jedediah Smith, was seized by a grizzly bear who clamped Smith's head in his teeth and tore off one of his ears. His companion, James Kleeman, applied the ear to Smith's head and stitching through and through, over and over, he matched and reattached the parts as

best as he could. Believe it or not, history shows that it took. Not laryngology, but head and neck reconstruction.

Our next most interesting period was that of the gold rush. These medicine men were adventurers, gold seekers, anyone calling himself a doctor, a dentist, or a veterinarian. He could be, and often was, a quack, a faith healer, a gambler, a horse thief, or a convict. Often a saloon or a gambling joint was his office. A pool table or some planks put over whiskey kegs was his operating table and the contents of the kegs were also most often used as both his anesthetic and his antiseptic. Many fascinating anecdotes of these "doctors" have been chronicled. The one I like best tells of one of these doctors of 1850 who, like so many others, could not make a living practicing just medicine, so had the side line of stage coach robbing. In one such event, a member of his gang shot a passenger who was a little slow in handing over his valuables, in the neck. As the passenger dropped to the ground screaming, the stage coach robber said, "Keep your nerve, man, all you need is a physician, and I just happen to be a doctor myself." With that he took out his Bowie knife and dug out the bullet. He bandaged the wound with strips torn from his own shirt, flagged down a wagon going the other way, and used ten dollars of the loot just stolen from the passenger to hire the driver to take the wounded man back to town. There were also many interesting picturesque quotations from this period which paint a picture of that doctor of that period as seen by his patients and other fellow townsmen. One was, "It's necessary to round up a drunken doctor like an old bronc on the prairie and keep him under guard until sober enough to do the job for which he was needed." Another one, "Anyone can take a hand in the practice of medicine; the sky is the limit in practice and in fees." Another man said, "The M. D. after these doctors' names really meant Money Down." Many of the gold rush doctors, and those who followed, wore the cutaway coats and the striped trousers they had seen doctors wearing back East. Some also wore stove pipe hats and long high polished boots. However, others were clothed in the ragged and dirty clothes of their contemporaries.

We cannot leave this period of the early 1850's without saying a bit about the phlebotomists, or bloodletters. As you remember, bloodletting was an important part of the practice of medicine everywhere at this time. And in the West, just as in the East, many barbers were practicing this procedure. Here is the wording of an advertisement that appeared in a Los Angeles newspaper in 1851. Peter Briggs, a barber and the first Negro to come to Los Angeles, placed this advertisement: "Gentlemen will be waited on and shaved and hair dressing will be prepared in the finest style of the art while cupping, bleeding, and teeth extractions will also be attended to." These bloodletting barbers have supplied us with another fascinating bit of history. Competition was keen among them for patients. When their patients returned for the first dressing after a bloodletting, it was the custom of the barbers to wrap the bloody bandages around the hitching posts in front of their shops as an advertisement of their trade. Hence, the brightly colored candy striped barber poles of today.

Next we come to another period of Western medical history: that of the doctor on horseback. Usually the old-fashioned doctor is pictured as traveling in a fine buggy with a well-bred, prancing, fine horse. Maybe he did in the East and in the Midwest but in the Far West this was not so. The practice of medicine was not lucrative enough, the roads were not good enough, and the buggies were not there. The doctor of the Far West did his traveling and made his house calls on horseback. Many of his calls covered 50 to 60 miles. Many times he was up all day and all night to reach just one patient. His calls were made in all kinds of weather and over all kinds of terrain. His horse was usually a fine fast one. Sometimes he

wore the fancy boots, the frock coat, and the modified stove pipe hat of the East but at other times he wore the same riding garb as his fellow townsmen. Always, he had two large saddle bags. On one side he carried his drugs, on the other, his instruments. In the drug compartment he most often had Dover's powder, liniment, sticking plaster, quinine, castor oil, blue mass, dragon's blood, Peruvian bark, and calamine. In the bag on the other side he had his knives, saws, mortar and pestle for making up his own drugs from roots and herbs, and his small stock of prepared drugs, syringes, cupping and scarifying equipment.

Soon after the gold rush and during its waning came a new kind of "medicine man." Patent medicines fluorished after the Civil War and flooded especially the West.

It is of interest to us that a New Jersey tailor came out with a pulmonic syrup for "clergyman's sore throat — terror to the clergy and members of the bar and all who talk too much." He started with a barrel of Sea Weed Tonic and ended with a huge fortune, all the result of luck, pluck, molasses and ipecac. "One-Minute Cough Syrup" cured croup, hoarseness, and choking to death. "Cubeb" cigarettes cured colds, catarrh, hay fever, and throat diseases. "Green Mountain Ointment" was very good for quinsy, croup, and inflammations of the eye. Even Buffalo Bill Cody pushed "White Beavers Cough Cream" for colds and sore throats and endorsed "Kickapoo (juice) Indian Sagwa" for almost anything. Snake oil doctors, faith healers, charlatans, mystics, and quacks of all kinds, using all manner of compounds, concoctions, and gadgets came West by the thousands. Usually, they traveled in their own "medicine wagons." These wagons were the traveling stages for their shows to entice the suckers, and the counters from which they dispensed their drugs and cures to these same suckers. Their products, made of common and cheap ingredients, were usually stirred up in a bucket behind the wagon. In addition to their performances and acts, they used fancy costumes from all parts of the world, and fancy titles and garish advertisements. Their tailgate medicine was practiced after high and low pitches with song, dance, and ballyhoo. Luckily, one of our Western artists, Bodner, painted one of these old wagons, as it now is just a ghost of the old medicine of the Far West.

In 1885 the University of Southern California began its medical school. Andrew F. Darling was the first head of the eye, ear, nose and throat specialities. Two years later, another otolaryngologist, William Babcock, joined the faculty and brought with him the first intubation set seen in the West.

Laryngologists were mentioned as far back as 1850. The first teaching of the throat specialties in the West is listed as beginning in 1865. The larynx had been scarified for edema as early as 1848 but this was done by touch and not under direct vision.

Specialization, which of course began in ophthalmology and otolaryngology, reached the West soon after it did the East. Laryngology began with Garcia's discovery of the laryngoscope (mirror) in 1854. It is noted from early pictures that the first head mirror had no head band but was held in the doctor's teeth.

Tonsil surgery began in 1870, and sinus surgery in 1890. Cocaine was first used in 1884.

These brief notations of treatment in our specialties bring me to an important part of this presentation. I know that to be successful a paper must bring you some prescriptions and treatments which you can take home with you. So, now, please note the following treasures gleaned from many historical sources and passed on to you for their evident worth in laryngology.

The first is a treatment for headache. To cure a headache take a live frog and bind it to your head until the headache goes away. For throat infections, use this wonderful gargle: Infusion of Raiz Colorado or "Merchants Gargling Oil —

a liniment for Man and Beast." Please notice that, if these don't work, one-fourth of a gill of buffalo gall in a pint of water is good for almost anything.

The treatment for acute tonsillitis has a fascinating bit of early history. All of you will remember from the account of the Lewis and Clark expedition that they and their men would never have made it across the last great heights of the bitter, cold, snow-swept Rocky Mountains if it had not been for the guiding of the Indian princess, Sacajawea. She was married to Charbonneau, a French Canadian trader who was one of the hired guides and interpreters. You will also remember that when all seemed lost in the highest of these Western Montana mountain passes, this same Indian princess recognized the area from the memories of her childhood and was able to guide the expedition to the familiar surroundings of the home area of her tribe. She had been captured as a girl of 13 from her Shoshone tribe by a Minnetarees war party. The first Indians the expedition came upon were some of her own family. They were almost missed because her 15-month-old son had just become very ill with acute tonsillitis and severe cervical adenitis. For a while, it had seemed that the party could not go on. Here is the treatment that was used on the boy and which probably saved the West for all of us: A dose of cream of tartar and flowers of sulphur, a hot poultice of boiled onions about his neck, and then the rubbing on of a plaster of salve made from the resin of the long leaf pine, beeswax, and bear fat oil.

Diphtheria and croup, which were probably brought to the West by some of the earliest explorers, were frequently encountered. Some treatments for croup were licorice root, the balm of Gilead, vinegar, the sirup of skunk cabbage root, tincture of lobelia; if these failed, all you then had to do was "tie the right front foot of a mole around the neck." We learned earlier that the tracheotomy was used for diphtheria. Our first doctors, after performing a tracheotomy, would often try to clean out the trachea by sucking on the tracheotomy tube through a handkerchief. As you can guess, many of them contracted diphtheria and many died. Historical records show that a great number of these martyrs were decorated by their government posthumously for their bravery. Another treatment for diphtheria was the boiling of a teaspoon of sulphur in a half pint of lime water, which was then dripped from a feather quill into the nostrils drop by drop. Still another treatment for diphtheria advised: "Hold child upside down by the feet and tickle congested throat with feathers soaked in goose-grease."

In the time (early 1850's) of the vigilante trials there was a shortage of lawyers for judges. Many times another professional man, the doctor, was drafted to be the judge. A laryngologist, I presume, sentenced a convicted horse thief to be hanged. The jury that had brought in the verdict moved down to the end of the gambling hall used as the courtroom to the end of the room with open beams. The rope was thrown over a rafter, the thief stood on a whiskey barrel, the noose placed around his neck and the barrel kicked out from under him. Alas, the knot had been improperly placed and instead of breaking his neck it was slowly strangling him with great kickings of his arms and legs. The compassionate doctor cut him down, did a tracheotomy, brought him back to life and "properly" hanged him the next morning.

What about foreign bodies? Yes, they occurred in those days and the history of their treatment is quite fascinating. I found the actual description of the extraction of a grain of corn from a child's trachea by the manipulations of two hair-pins fastened to slender twig branches. This of course was done blindly. Another foreign body was removed from the larynx or trachea with a turkey quill. A number of times a feather is mentioned as being used to remove a foreign body from the air or food passages. The mechanics for its use were first the passing downward of

a feather with the large quill end first. After passing the likely area of the foreign body, the feather was withdrawn so that its fronds would be spread outward and thus enmesh the foreign body and permit its withdrawal along with the feather.

This was also the period of the use of the probang. At one end of a rigid rod was a round spherical mass of gummy rubber. This end of the probang was passed down the esophagus, for instance, in an attempt to remove a pin by having its sharp point stick in the rubber ball. Another probang, or the other end of the same one, had a small double swinging metal basket. This was passed under or over and beyond a coin or a button with the object of retrieving the foreign body as the probang was pulled back up past it, and hopefully it would fall into the little basket. Another probang was constructed on the principle of the ribbings of two tiny umbrella-like frameworks of bristles which were fashioned as if the two handles were placed end to end. This probang was passed down beyond the foreign body, with the umbrella ribbings tightly collapsed. As the probang was withdrawn, the two umbrella frameworks were released so that their tightly compressed bristles would now fan out and enmesh the foreign body.

Recently I read that the medicine chief of the Nez Perce Indians highly coveted and valued the scalp of a Negro as "the best medicine for sore ears and sore throats."

Much of the above I learned from the paintings of the early Western artists who depicted the Indians, the trappers, and the early settlers of the West. In closing, I should like to tell you of a painting by George Catlin which I am sure must have been that of one of the first of all presidential addresses. It has a lesson. It pictures a medicine man speaking to a ring of Indians seated before him in a circle. There are tepees in the background and the sky is that of falling night. Worst of all, it is snowing and significantly all of the Indians are covered with snow except for a bit of their heads and feathers. The title of the painting is "The Long Speech" and I would like to read the caption that goes with the title: "The pompous chief still gestures and declaims and, though one brave manages to keep the calumet going, barely the scalp locks of the rest of his audience show above the drifting snow." Luckily, you are in Florida where it seldom snows.

INTRODUCTION OF
GUEST OF HONOR, FRANCIS E. LeJEUNE, M.D.

PRESIDENT ALDEN H. MILLER, M.D.

When I was elected to this society some years ago I was greatly impressed and fascinated by some of its more senior members who, to me, were the "Mr. Laryngologies" of that time. Francis Ernest LeJeune is one of these with whom I was so proud to become associated. Working with him on committees, programs, and the Council, and listening to his presentations in our society has proven the correctness of my early impressions and assessment of him. My association and your's with Doctor LeJeune has been a fine extra dividend of membership in the American Laryngological Association family.

I am so pleased that he graciously accepted as Guest of Honor for this meeting. He honors us not only by being here today but by his contributions to our society and our specialty. In addition he and that charming, beautiful lady, Anna Lynne, his wife, have been the most gracious hosts whenever our society and others have been in the South. The two of them personify what is finest in an American medical family.

I am sure you would like to have some inside information on Doctor LeJeune's history, talents and interests. He was born just before the turn of the century in Thibodaux, Louisiana, a town on the Bayou La Forche. His parents were of French origin. Some of their forefathers came to Louisiana directly from France while others settled in Acadia, Nova Scotia, Canada when it was a French possession. In 1755 these French settlers were sent into exile by the English. Some 4,000 of these Acadians eventually found their way to the "Bayou country" of southern Louisiana where their descendents still reside and are popularly called "Cajuns" (nickname for Acadians). They continued to use the French language and customs and Francis LeJeune, in this environment, learned to speak French before learning English.

He grew up a country boy in this fascinating bayou country environment of jaw-snapping alligators and water moccasins, laying the foundation for his future interests in bird shooting and large game fishing. At the age of six years he accompanied his father, a sugar engineer, and his mother to El Higo sugar plantation in Mexico about 100 miles north of Tampico on the Panuco River. Here began his excellence in mastering the Spanish language. Eight years later he accompanied his parents to Puerto Rico where for two years he attended and lived at the Colegio San Pablo in San Juan. Francis LeJeune returned to Louisiana in 1910 where he attended Jefferson College at Convent, Louisiana from which he graduated in 1914. He then entered into Tulane University's School for Mechanical Engineering but hastily changed to medicine and received his medical degree from Tulane in 1920.

Upon graduating from Tulane he interned at the Louisiana State Charity Hospital in New Orleans. He served his residency in Otolaryngology at the Eye, Ear, Nose and Throat Hospital in New Orleans, and then became associated with Dr. Robert Clyde Lynch. He has been a member of the faculty of the Tulane Medical School since 1922 and served as professor and Head of the Department of Otolaryngology from 1936 to 1951. He was the surgeon-in-charge of the ear, nose, and throat department of the EENT Hospital in New Orleans for many years.

In 1942 he was a co-founder and partner of the Ochsner Clinic of New Or-

leans serving as Head of the Department of Otolaryngology from 1942 to 1965. He still has an active daily practice at the clinic and is still a Trustee of the Alton Ochsner Medical Foundation.

During World War I, he was a private in the United States Army Medical Corp. He served with the United States Selective Service System for 20 years.

His many contributions to the medical literature of our specialty, his many talks, instruction courses, and lectures are too numerous to count. He has added much to our instrumentarium and scope of techniques especially in Laryngology.

Dr. LeJeune, of course, has had a dominant role in all our societies and has given unselfishly of himself to our working organizations such as the Residency Review Committee for Otolaryngology and the American Board of Otolaryngology as well as in the staging of many meetings of our societies. The high esteem in which he is held by his Fellows is attested to by the fact that he has served as President of the American Academy of Ophthalmology and Otolaryngology, of the American Laryngological Association, of the American Triological Society and of the American Broncho-Esophagological Association. As the official host of these societies annual meetings, and as the unofficial host of many other meetings when they occurred in New Orleans, he has had at his side the beautiful and charming Anna Lynne LeJeune mentioned before who has made all of these occasions unforgettable and warm, pleasant memories.

In 1936 Francis LeJeune was the recipient of the Casselberry Award of this, the American Laryngological Association, and in 1963 received its Newcomb Award.

What more could be added to this impressive list of honors? Only this, we think. We hope that making him a Guest of Honor will convey to him our great love, admiration, and thanks for the stature and image that he has given our specialty and our society. Dr. Clerf please escort Dr. LeJeune to the stage.

WHEN COLOR CAME TO LARYNGEAL MOVIES

FRANCIS E. LEJEUNE, M.D.

I am most appreciative and grateful to you, Mr. President, for inviting me to serve as your Guest of Honor today. I am equally grateful to you for suggesting that I relate my early efforts in the development of color movies of the larynx made in 1933 and presented to the profession in 1935. At first, I was a bit reluctant to present to this audience ancient movies taken 37 years ago with poor equipment, inadequate illumination and very little knowledge on my part of refined photographic technique.

Since I had preserved these color movies most carefully, I surmised that it would be relatively simple to reactivate a few scenes for presentation today. So I readily agreed to Mr. President's suggestion, not knowing what headaches were in store for me. On reviewing these films taken 30 odd years ago, many had, like old soldiers, just faded away. When I attempted to project these films, I quickly discovered they would no longer run through the projector without tearing and stripping the sprocket perforation on each side of the film, rendering the film useless. Next I learned that films stored for years, however carefully, had a tendency to shrink lengthwise. This indicated to me that a search would be necessary for the negative films and then the making of new prints, if possible. By diligent work, some of the negatives of the pictures taken in the early days were reactivated and I shall show these today. The special projector which I used at that time had, like Rip van Winkle, lain dormant for 30 odd years, and in spite of recent and adequate lubrication, the mechanism sounds creaky, wobbly and noisy. In short, I think you will agree that this piece of equipment could very well take its place among the antiques on Royal Street in my own home town.

The history of photography of the larynx has been documented on numerous occasions. However, when color came to laryngeal movies, it presented a notable advance in the teaching of laryngology. It is recorded that Panconcelli-Calzia[1] obtained the first "still" color pictures of the vocal cords in 1929, and that Russell and Tuttle[2] using a fonopharyngoscope and working in conjunction with the Eastman Laboratories and the General Electric Company obtained color motion pictures of the larynx in 1930. Russell and Tuttle were principally interested in phonetics and they hoped movies of vocal cords would give them additional information on this subject. They were followed by Clyde Heatly[3], who in 1931 obtained color motion pictures of the larynx. Heatly also reported using a quartz rod to convey illumination to the vocal cords. He was able to obtain a fair picture of a normal larynx and three views showing pathology on vocal cords. Apparently the interest of Russell and Tuttle and Heatly in photography of the larynx was short lived, as no subsequent attempts to obtain additional pictures are reported.

My[4] interest in photography of the larynx developed in 1930 and using a Bell & Howell Camera with an f 4.5 Goertz Dagmar 4 inch telephoto lens, and a Goertz reflex focuser, I obtained a large collection of black and white motion pictures showing pathological lesions of the vocal cords, but my ultimate goal was to obtain color movies of the larynx showing pathology. Kodacolor films became available in the early thirties. This type of film gave good rendition of color, but required fully 30 times more illumination than the black and white film and duplicates of these pictures were not available. My enthusiasm to obtain color pictures of the larynx received a stimulus when Bell and Howell Company brought forth the

Morgana method for color photography in 1933. With this new method, ordinary black and white film was used and the mechanism was such that a red and green filter was located within the camera between the lens and the film. Its function was to expose one frame of the film through the red filter and the next frame through the green filter ad infinitum. The developed film showed no evidences of color, but on close inspection it was noted that the frames of the film alternated in being light and dark. The special Morgana projector was equipped with a color wheel consisting of five colors and was located in front of the projection lens. The color wheel rotated synchronously as the picture was being projected. Good color rendition was obtained, and for that period of time, the pictures were considered good. Under general anesthesia, the larynx and vocal cords were exposed by means of suspension laryngoscopy. Illumination was a major problem and was partly solved by using two 200 candle power projection type bulbs mounted in a lamp house. These lamp houses were placed on each side of a turret-like tube through which the lens of the camera was focused.

After obtaining a good color view of a normal larynx, all efforts were directed at obtaining views of pathological lesions found on the vocal cords and the larynx, hoping thereby that these films would become a means of recording and teaching clinical pathology to the student. A series of pathological lesions was gradually obtained which made a creditable showing, and these were first presented to our local medical organizations. On October 28, 1935,[4] 800 feet of color pictures showing all types of pathology, were presented at the Clinical Congress of the American College of Surgeons meeting in San Francisco. These same movies were presented at the A. M. A. meeting in Kansas City, May 11, 1936, and at the Eastern Sectional meeting of the Triological Society at the Waldorf Astoria in New York, January 1937. Subsequently these color pictures of normal and pathological lesions of the vocal cords were presented to various medical groups throughout the country where they were well received. These pictures were all made by the Morgana process. It served me well and I continued to use this method until the Eastman Laboratories made available their vastly improved Kodachrome A film. This film was faster, of greater clarity, and offered better color rendition and duplicates were available. I immediately discarded the Morgana method and started using the Kodachrome A film with the same equipment previously used. I did, however, constantly endeavor to improve the illumination which is still a problem.

I continued color photography of the larynx until my retirement in 1965 during which time I was able to add many interesting pictures to my collection of pathology of the larynx.

Meanwhile, other investigators became interested in color photography of the larynx. By 1940, Dr. Joel J. Pressman[6] had produced excellent color pictures of the larynx stressing action and physiology. He continued his investigative work and completed a most excellent film in 1968 entitled, "The Action of the Larynx". I was the recipient of a copy of this film which I prize highly. He was denied the opportunity of presenting this work at a national Otolaryngological meeting by his untimely death in 1968.

In 1939, one of our members, Dr. Edward Tremble[11,12] of Montreal presented his contribution to color movies of the larynx. The pictures were good, but he apparently lost interest in this phase of laryngology as he reported no further work.

Dr. Gabriel Tucker, Sr.,[5] another laryngologist, pre-eminent in other areas of laryngology, also became interested and made important contributions to photography of the larynx in 1939. Most of all, I would pay tribute to Paul Holinger and J. D. Brubaker[7], who in 1941 reported and presented the first of a superb series of color movies of the larynx. These color movies were immediately acclaimed as the ultimate in perfection. Holinger's[8,9] subsequent

presentations in 1942, 1946, and 1947 were equally brilliant in definition, color rendition and exposure. How comprehensively Holinger and Brubaker[10] covered the field of color photography can be inferred, I think, from the fact that from 1947-1960 there is not a single article on photography of the larynx in any medical index. To Paul Holinger we owe a debt of gratitude for simplifying the teaching of laryngology to the student.

And now for the next few minutes, I would like to show some of the early color pictures of the larynx as I shared in its development 35 years ago when color came to movies of the larynx.

REFERENCES

1. Panconcelli-Calzia G: Die naturfarbenkinematographie von phonationsvorgangen, insbesondere im Kehlkopf. Ztschr f Laryng Rhin 18: 100-101 and 376-377, 1929

2. Russell GO, Tuttle CH: Color movies of vocal cord action: an aid to diagnosis. Laryngoscope 40: 549-552, 1930

3. Heatly CA: Motion picture studies of larynx. Ann Otol 40: 434-447, 1931

4. LeJeune FE: Motion picture study of laryngeal lesions. Surg Gynec and Obstet 62: 492-495, 1936

5. Tucker G: Technique for motion picture photography of larynx in color. Tr Am Laryng A 61: 259-263, 1939

6. Pressman JJ, Hinman A: Further advances in technique of laryngeal photography. Laryngoscope 50: 535-546, 1940

7. Brubaker JD, Holinger P: Larynx, Bronchi and Esophagus in Kodachrome. J Biol Photographic A 10: 83-91, 1941

8. Holinger PH: Photography of larynx, trachea, bronchi and esophagus. Tr Am Acad Ophth (1941) 46: 153-156, 1942

9. Holinger PH, Merideth HW: Simplified apparatus for laryngeal cinematography. Ann Otol 51: 215-219, 1942

10. Brubaker JD, Holinger PH: Endoscopic color camera for otolaryngology and bronchoesophagology. J Biol Photographic A 15: 73-93, 1946

11. Tremble, GE: Simple technique for taking movies of the larynx. Canad Med Assn J 41: 72-73, 1939

12. Tremble, GE: Moving pictures of the larynx with telephoto lens. J Laryng Otol 54: 664-668, 1939

CERVICAL OSTEOPHYTES AND DYSPHAGIA

WILLIAM H. SAUNDERS, M.D.

COLUMBUS, OHIO

How often and to what extent do osteophytes protruding anteriorly from the cervical spine cause dysphagia or other esophageal or tracheal symptoms? When read closely many of the reports dealing with the subject leave doubt as to the relationship between osteophytes and esophageal symptoms. For example, one patient with dysphagia was reported as having both cervical osteophytes and advanced pseudobulbar palsy. Whether the osteophytes caused her dysphagia seemed questionable. Another report described a patient with dysphagia who had an osteophyte removed but who later was found to have carcinoma of the esophagus.

Mosher[6] wrote about two cases of dysphagia he believed to be caused by cervical osteophytes. Although he thought he was the first to describe this entity, he was not, since others[7] had written similar accounts 20 years earlier. Hilding and Tachdjian[3] reviewed the literature and reported that 36 cases of dysphagia due to cervical osteophytes had been described. They added three cases of their own. Since 1960 about 20 other cases have been reported.

This report describes two additional cases. The first is an unequivocal example of esophageal compression caused by osteophytes. The second is a patient with cervical osteophytes in whom the relationship between osteophytes and dysphagia is less certain.

Pathology. The osteophytic lesion is related to degeneration of an intervertebral disc, an expression of osteoarthritis or cervical spondylosis. Disc degeneration occurs chiefly where there is the greatest vertebral movement between C 5-6 and C 6-7. It is a disease of the elderly and is unrelated to trauma. Along with narrowing of the interspace, there is a sclerosis of the articular surfaces and hypertrophic spurring of the margins of the articular surfaces.

Symptoms. In the cases reported in otolaryngic literature the most common complaint associated with cervical osteophytes is dysphagia. Other symptoms attributed to cervical osteophytes include a sensation of foreign body, pain on swallowing and hoarseness. Cough and a need to clear the throat repeatedly are also listed. In the 36 cases reviewed by Hilding and Tachdjian dysphagia was the major symptom in only 50 percent.

In the orthopedic literature cervical osteophytes also have been implicated as a cause of neck pain and limited neck motion. Spastic paraplegia from cord compression is reported. Vertebral artery insufficiency[1] has been described as resulting from cervical spurring and there is even one report[4] of a case of Horner's syndrome attributed to this disease. Clinical manifestations will depend on the site of the lesion, that is, whether anterior or posterior osteophytes predominate.

Signs. In an advanced case one may see a mass protruding into the pharynx or hypopharynx. Of course, these masses are bony hard and seem to be part of the vertebral column. The mass in the hypopharynx may preclude a clear view of the larynx by either direct or indirect laryngoscopy.

Commonly the diagnosis is made up-

From the Department of Otolaryngology, University Hospitals, Columbus, Ohio.

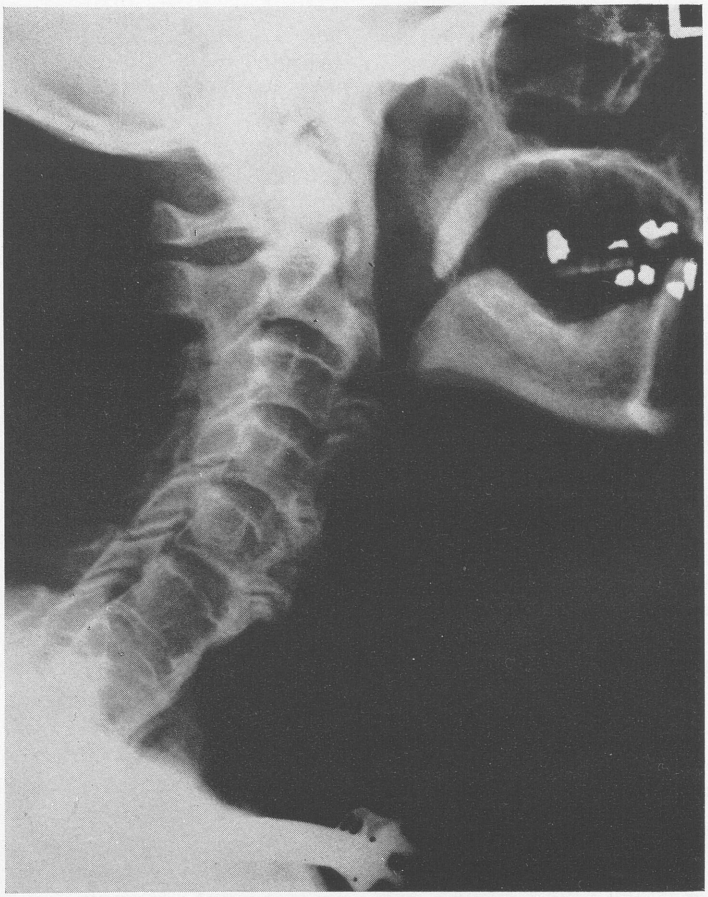

Fig. 1.—Case 1. Spurring associated with C 3-4 and C 5-6. Tracheotomy in place.

on seeing a lateral cervical roentgenogram in which one or more osteophytes project from the anterior surfaces of the vertebrae. Frequently two vertebrae appear to be fused. Any of the cervical vertebrae may be affected but most frequently the fifth and sixth.

REPORT OF CASES

Case 1

History. A 75-year-old white male with fatigue for 18 months. Anemia was discovered and he was treated with transfusions, but no cause for the anemia was assigned. He continued with fatigue and developed weight loss of 40 pounds over an eight month period. Progressive dysphagia most marked for solid food was also a complaint. Recently he had weakness of voice, stridor and shortness of breath on slight exertion. There was a persistent cough productive of some green sputum. He did not smoke.

The patient brought with him a letter from his doctor listing psychoneurosis as his only diagnosis and assuring him of his general good health.

Physical Examination. Emaciated elderly man with great weakness, dyspnea and stridor. When the patient was given water to drink, it was aspirated.

Pharynx. A mass in the posterior pharynx could be seen when the patient opened his mouth. It protruded from the pharyngeal wall and was bony hard. Lower in the hypopharynx was an even

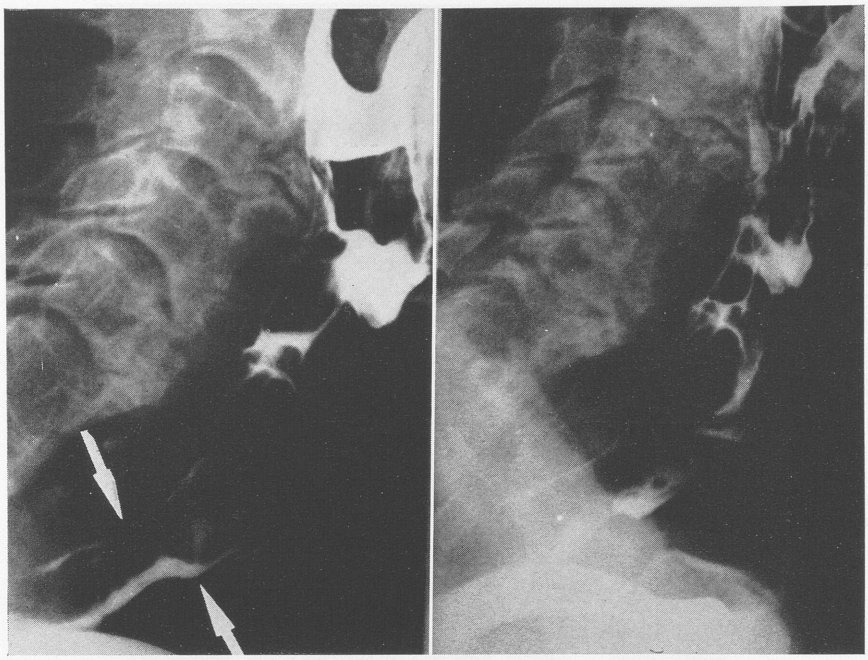

Fig. 2.—Case 1. Attempted barium esophagram. Arrow pointing upward aims at trachea filled with barium, none of which entered esophagus. Arrow pointing downward occupies the space behind trachea thought to be the site of neoplasm.

larger mass which partially hid the larynx. The thyroid cartilage seemed expanded and one felt that the larynx was pressed anteriorly by a mass from behind.

Larynx. Because of the cervical exostoses the larynx was difficult to see by mirror or direct laryngoscopy. Both vocal cords appeared paralyzed. Neither moved toward abduction and there was only minimal adduction. The glottic chink was estimated as 3 mm. There was pooling in both pyriform recesses and edema in the arytenoid areas. A laryngoscope could not be passed into the cervical esophagus nor could a smaller esophagoscope. There seemed to be a solid obstruction at the level of the larynx.

Diagnosis. The initial clinical diagnoses were cervical osteophytes and esophageal carcinoma producing bilateral laryngeal paralysis.

Hospital Course. Cervical roentgenograms with and without a barium esophagram were obtained. Massive osteophytes of the cervical spine at the level of C 2-3, C 3-4, C 4-5, C 5-6 were seen (Fig. 1). The radiologist noted that barium spilled into the trachea and none entered the esophagus (Fig. 2). A soft tissue mass seemed to indent the posterior wall of the larynx and led the radiologist to speculate that esophageal carcinoma was a distinct diagnostic possibility.

Because of increasing respiratory difficulty, a tracheotomy was done through the fourth tracheal ring. His airway improved. The plan at this time was to explore the cervical esophagus through a lateral pharyngotomy since it could not be viewed in any other fashion. On the basis of the roentgenograms, the laryngeal paralysis and great weight loss, a diagnosis of carcinoma seemed reasonable. Before anything was done (except tracheotomy) the patient took a turn for the worse and died. He was under medical observation during his last several hours but no pertinent cause for death could be assigned. A complete

Fig. 3.—Case 1. Postmortem view of anterior spine showing exostoses at C 3-4 and C 5-6.

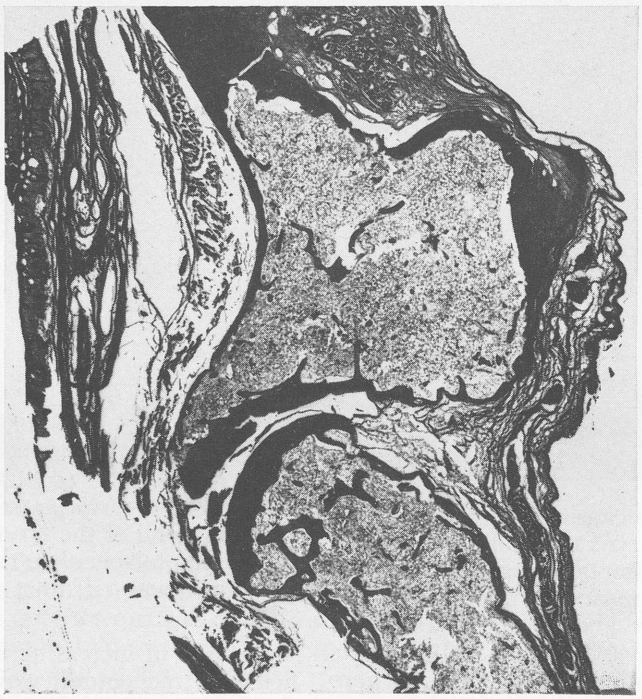

Fig. 4.—Case 1. Cricoarytenoid joint. Much of the cartilage has been replaced by bone.

autopsy was performed. The germane findings listed below did not satisfy the clinician regarding the immediate cause of death.

1. Degenerative osteoarthritis of the cervical spine, severe. Advanced hypertrophic changes of cervical vertebrae 3, 4, 5 and 6, resulting from osteoarthritis (Fig. 3). The majority of the exostosis was located anteriorly. The cut surface of these cervical vertebral bodies indicated mark compression and deformity. The intervertebral discs were extremely atrophic. The thoracic vertebrae showed no grossly significant changes. The lumbar vertebrae showed only mild to moderate osteophytic changes.

2. Arthritis of the cricoarytenoid joint with exostoses of the arytenoid cartilages. Larynx and circoarytenoid joint (Fig. 4): both cricoid and arytenoid

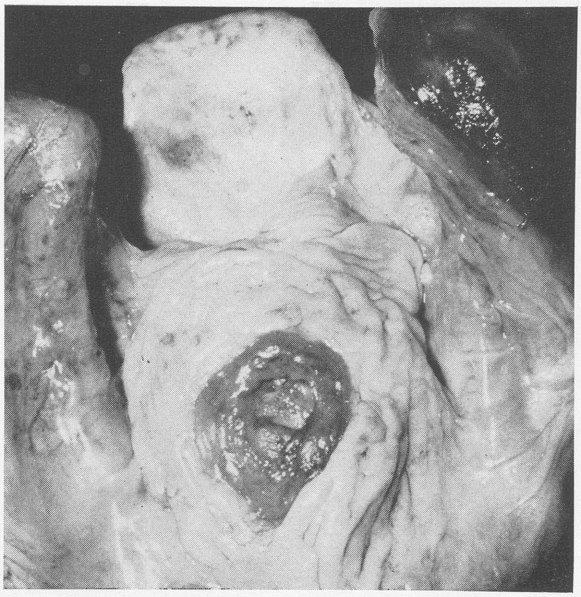

Fig. 5.—Case 1. Ulcerated wall of esophagus.

cartilages showed an advanced ossification. Only a small amount of cartilaginous tissue could be seen over the periphery of both cartilages. At the posterior edge of the joint the arytenoid cartilage was exostotic. The articular cartilage of the arytenoid was atrophic, particularly in the anterior portion. The cricoid showed a relatively larger amount of articular cartilage. The meniscus and the posterior joint capsula showed degeneration.

3. Respiratory obstruction due to compression of the membranous portion of the trachea by the deformed cervical spine and local edema. (Note: at the time of autopsy the tracheostomy tube had been removed so that its role in improving the airway could not be assessed.) The immobility of the vocal cords was due to limitation of the movement of the aryteno-cricoid joint. No abnormalities were noted in the vocal cords, ligaments or recurrent nerves. The respiratory difficulty can be explained by the compression of the posterior membranous portion of the trachea by the hypertrophic lower cervical spine.

4. Esophagus and larynx: Massive anterior exostoses of C 3, 4, 5 and 6 vertebral bodies displaced the larynx and hypopharynx forward narrowing the lumen. The anterior wall of the upper esophagus showed an ulceration over the exostotic lesion of the arytenoid cartilage (Fig. 5). A sharp bony protrusion was noted within the ulcer of the esophagus. The ulcer was at the level of the C 3 and C 4 vertebrae and it measured 1.5 cm in diameter. The posterior wall of the esophagus was smooth and shiny all the way down. The recurrent nerves were normal.

Heart: Section of interventricular septum showed foci of interstitial fibrosis and surrounding hypertrophic myocardial fibers. (The brain, lungs, liver and other contents of the chest and abdomen, and all other parts were essentially normal.)

DISCUSSION

The diagnosis of cricoarytenoid ankylosis, the true cause of the immobility of the vocal cords in this case, was missed because it was not suspected. Instead, in an elderly patient with apparent laryngeal paralysis, great weight loss, and almost complete esophageal obstruction, the diagnosis of carcinoma

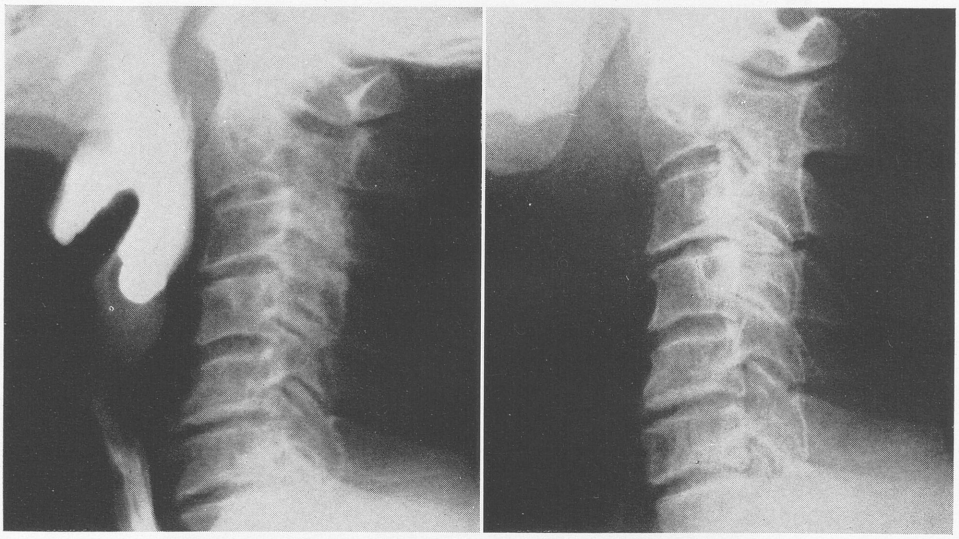

Fig. 6.—Case 2. Spurring of C 5-6. Note also the hypopharyngeal diverticulum after laryngectomy.
Fig. 7.—Case 2. Postoperative view. Spurs clearly removed.

of the cervical esophagus was made. The roentgenologist, in reporting the findings of a barium esophagram, stated: "A small amount of barium was given to the patient and he was unable to pass this into the esophagus. Some aspiration into the trachea occurred. Although the upper esophagus is not well visualized, a soft tissue mass is seen to indent upon the posterior larynx and trachea and seems to obstruct the passage of barium. Carcinoma is a distinct consideration."

At the time of laryngoscopy the endoscopist was unable to pass the laryngoscope into the cervical esophagus. The operative note stated: "The true vocal cords were free of mucosal disease but were paralyzed. There was very minimal adduction and no abduction with an estimated glottic chink of 3 mm. The arytenoids and posterior commissure area were distinctly edematous but no erosion or neoplastic process was noted. The upper portions of both pyriform recesses were normal except that the laryngoscope could not be passed as far as expected. The impression was that there existed a solid block in the uppermost cervical esophagus, none of which could be visualized." Had the endoscopist used the passive immobility test to detect fixation of the arytenoids the correct cause for lack of motion of the vocal cords would have been established.

The exact cause of death was not determined antemortem and neither was it determined by the complete postmortem examination that was done. The patient had a tracheotomy tube in place through the fourth tracheal ring and had been fed by nasogastric tube for several days prior to death. His blood volume was normal and electrolyte studies were normal. An EKG 48 hours before death and one hour before death showed no essential abnormality. The autopsy pathologist did note that there was tracheal compression but this should have been corrected by the tracheotomy.

This case illustrates that complete or near complete esophageal obstruction and even tracheal compression can be produced by exostoses of the cervical spine.

Case 2

History. A 70-year-old white male. In 1965, laryngectomy and right radical neck dissection for carcinoma of the

larynx; in 1968 right upper lobectomy for carcinoma of the bronchus.

For two years or more the patient had complained of inability to swallow solid food but had lost no weight. An esophagoscopy was done. There was difficulty in passing a normal adult esophagoscope and a child size scope had to be substituted. The mucosa was normal. X-rays of the cervical spine on three occasions with and without barium esophagram showed indenting of the cervical esophagus by a prominent anterior osteophyte at the level of C 5-6. One typical report described: " . . . a large indentation in the posterior esophagus at the level of C 5-6. A larger anterior osteophyte projects from the anterior bodies of C 5 and C 6 disc space. Lateral films also show a large diverticulum-like structure filled with barium in the area of the vallecula" (Fig. 6).

In May, 1968, through a lateral neck incision, an approach to the anterior cervical osteophyte was made and the large osteophytes associated with C 5-6 were removed with a rongeur. Healing occurred uneventfully. The postoperative roentgenogram of the cervical spine is seen in Figure 7 showing the osteophytes removed.

In May, 1969, the patient was alive and well. He stated that his dysphagia improved for six months after the operation to remove his cervical osteophytes, but recently dysphagia for solid food had been increasing.

DISCUSSION

The question arises whether or not dysphagia was produced more by the large osteophytes or by the pouch in the hypopharynx. Here, as in other recorded instances, there was difficulty in accurately evaluating symptoms produced by cervical osteophytes. There are, of course, many patients with cervical osteophytes who have no esophageal symptoms whatsoever. LeRoux,[5] in evaluating a series of 1200 patients with dysphagia, did not find osteophytes to be a cause in any. Other patients with dysphagia, a lump in the throat, a sensation of foreign body, or chronic cough, all symptoms attributed to cervical osteophytes, had no osteophytes at all and no other apparent organic cause for their symptoms. In my opinion, at least one-third of the cases of dysphagia reported in the literature as being caused by cervical osteophytes are not bona fide examples of this condition.

Many authors are careful to point out the dangers of esophagoscopy in patients with cervical osteophytes. Some say that esophagoscopy should not even be attempted. There are instances of rupture of the esophagus when esophagoscopy was done. In any case a roentgenogram showing a lateral view of the cervical spine is important before esophagoscopy.

The value of surgical removal of osteophytes is not entirely clear. At least a few patients have improved after surgery but others have not. Resection often is not possible because of the poor general condition of the patient or because of technical difficulties. In any case before proposing surgery one must be certain that the patient's symptoms are caused by his osteophytes and not by another condition, organic or functional.

UNIVERSITY HOSPITALS, COLUMBUS, OHIO 43210

REFERENCES

1. Hardin CA: Vertebral artery insufficiency produced by cervical osteoarthritic spurs. Arch Surg 90: 629-33, 1965

2. Heck CV: Hoarseness and painful deglutition due to massive cervical exostoses. Surg Gynec Obstet 102: 657-660, 1956

3. Hilding DA, Tachdjian MO: Dysphagia and hypertrophic spurring of the cervical spine. New Eng J Med 263: 11-14, 1960

4. Khurana KM, et al: Horner's syndrome produced by hypertrophic spurs from the cervical spine. Brit J Radiol 48: 227-9, 1964

5. Le Roux BT: Dysphagia and its causes. Geriatrics 17: 560, 1962

6. Mosher HP: Exostoses of cervical vertebrae as cause for difficulty in swallowing. Laryngoscope 36: 181, 1926

7. Zahn H: Ein fall von abrickung der speiseahre durch vertebrale ekchondrose. Munch Med Whnschr 52: 1680, 1905

ESOPHAGEAL MOTILITY STUDIES IN GLOBUS SENSATION

David D. Caldarelli, M.D.

Albert H. Andrews, Jr., M.D. Arthur J. Derbyshire, Ph.D.

Chicago, Ill.

Numerous esophageal diseases possess characteristic esophageal motility patterns.[1,3,4] No prior investigations, however, have utilized intraluminal esophageal motility measurements to elucidate the physiologic activity of the cricopharyngeal muscle in globus hystericus.

Etiologically, the globus sensation is often assumed to be psychic in origin. This investigation, utilizing intraluminal esophageal motility measurements, proposes to ascertain if cricopharyngeal muscle spasm is the peripheral determinant of the globus sensation. It was hypothesized that the globus sensation was consequent to cricopharyngeal spasm as defined by an increased resting pressure, increased positive contraction pressure and a prolonged relaxation phase or return to resting pressure.

METHODS

Ten patients were studied (age 24 to 62 years) who complained of a lump in the throat without associated dysphagia, pain, hoarseness or cough. The symptom duration ranged from 12 to 18 months. Physical examination excluded the possibility of occult laryngeal, esophageal or neck disease. Additionally, a cineesophagogram failed to demonstrate either narrowing or slowing of the barium flow, enlarged cervical osteophytes or hypopharyngeal diverticuli.

Controls were six adults (age 23 to 60 years) without history or physical evidence of laryngeal, esophageal or neck disease.

All subjects were non-fasting and without premedication. Three polyethylene catheters, each with an internal diameter of 0.03 inch, were fused and sealed at their tips with a lateral orifice in each tube at intervals of 5 cm. These tubes were swallowed and filled with water to allow cricopharyngeal pressure changes to be instantaneously transmitted to individual external transducers. The outputs of the transducers were amplified and recorded by an 8-channel Grass polygraph leading to inkwriting oscillographs. Respirations were registered through a pneumograph and the onset of swallowing was signalled by electromyographic activity derived from an active electrode placed at the level of the hyoid bone and an inactive lead on the forehead.

Intraluminal cricopharyngeal pressures were obtained during and between swallows with the following dimensions of the pressure wave being analyzed:

a) *Anatomical Distance.* Measured in cm from upper incisors to the position of the lateral orifices in the swallowed tubes.

b) *Tube.* Each tube was connected to a separate pressure transducer and amplifier system.

c) *Resting Pressure.* The pressure level (in cm water) prior to the onset of a swallow measured relative to the cervical esophageal pressure.

d) *Negative Wave.* The position of the lateral orifice of the tube was accepted as being within the cricopharyngeal area whenever a negative pressure wave preceded contraction. The negative wave was measured as fall from resting level to the bottom of the negative wave.

e) *Height of Contraction.* The maximum rise in pressure measured relative to the initial resting level.

f) *Duration of Relaxation.* The time required for relaxation pressure to fall to two-thirds of the value of the maximal height. This end point was chosen to avoid the error involved in estimating the end of a prolonged slow relaxation to a variable shifting resting pressure level (an asymptote). The end point chosen assumes that the last third of re-

---

From the Department of Otolaryngology, Abraham Lincoln School of Medicine, College of Medicine, University of Illinois at the Medical Center, Chicago.

This work supported by NIH Grant #5-T1NB05229.

TABLE I

COMPARISON OF DIMENSIONS OF SWALLOWS AT THE CRICOPHARYNGEAL LEVEL BETWEEN CONTROLS AND PATIENTS WITH GLOBUS SENSATIONS

	Distance (cm)		*Resting pressure ($cm\ H_2O$)*		*Loss of tonic resting level ($cm\ H_2O$)*		*Height of contraction ($cm\ H_2O$)*		*Duration of contraction (seconds)*		*Number of swallows measured*
	Mean	*SD*	*Mean*	*SD*	*Mean*	*SD*	*Mean*	*SD*	*Mean*	*SD*	
CONTROLS	18.0	(±2.8)	18.4	(±17.0)	22.7	(±23.5)	56.8	(±27.9)	2.4	(±4.8)	69
PATIENTS	18.0	(±3.1)	14.5	(±12.4)	23.6	(±14.5)	45.7	(±28.0)	2.0	(±2.1)	87
COMPARISON of $\overline{X}s$ (t)	0.0		1.59		0.28		2.49*		0.64		
COMPARISON of S^2 (F)		1.2		1.9*		2.6*		1.0		5.1*	

* = Significant at 1.0% confidence level

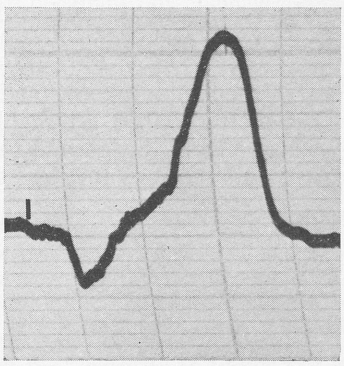

Fig. 1.—Normal crocopharyngeal pressure wave during a swallow. Vertical lines at one second intervals. Main horizontal lines represent 10 cm water pressure. Small vertical bar represents onset of swallow.

laxation contains no more significant data relating to the globus sensation than the first two-thirds of the relaxation.

g) *Type of Swallow.* Swallowing was made with nothing in mouth (dry) or with 5 cc of water in mouth (wet).

RESULTS

The data was obtained by direct measurements from records typified by the tracing in Figure 1. The measurements are given in Table I.

The important features of this Table are as follows:

a) Anatomic distance from upper incisors to cricopharyngeus was not significantly different between the patients and controls for either mean or scatter.

b) Resting Pressure. No significant difference was found between the resting pressure of controls and patients. However, the spread was significantly greater in controls than in patients (F test).

c) Negative Wave. There was no significant difference between the mean values of controls and patients, but there was significantly less scatter in the patient population.

d) Height of Contraction. The mean height of contraction was significantly greater in the controls than in the patients, but the scatters were identical.

e) Duration of Relaxation. The means of the two populations were not significantly different, but variation was greater in the controls.

f) There was no difference between either means and scatter of dry and wet swallows for the two populations.

DISCUSSION

Based upon previously established cricopharyngeal pressure patterns,[2] as well as our own work with simultaneous cinefluoroscopy and esophageal motility studies, we were confident that the negative wave was a physiologic characteristic of the cricopharyngeus muscle and associated structures. In both populations the mean resting pressures were slightly lower than Code et al.[2] (18.4

and 14.5 cm water pressure in ours; 20 to 30 cm water pressure in theirs). The assumption that the pattern of the last third of the relaxation wave was the same as the first two-thirds is a point of criticism. However, visual inspection of the recordings of the last third of the relaxation wave did not suggest a significant difference between patients and controls.

Our hypothesis that the globus sensation was consequent to cricopharyngeal spasm as described by the previously defined parameters was clearly not confirmed by this data. In fact when this data was explored we found exactly the opposite of our hypothetical predictions. Not only were the values for the patients' swallows less than the controls with the significant exception of the height of contraction, but also the variation of values was significantly less in the patient population again in all but the height of contraction. This pattern leads to a totally different concept, namely, that the cricopharyngeal function in the patient with globus sensations is a more restricted phenomenon than in normals.

CONCLUSIONS

The conclusions from this study do not eliminate the possibility that the globus sensation has a pathophysiologic basis in the cricopharyngeus muscle, but we feel confident that it is not related to increased resting pressure, increased contraction pressure and slow relaxation to two-thirds of the contraction pressure.

The observation of the reduced contraction pressure and reduced scatter of resting pressures, negative pressure and duration of relaxation to two-thirds suggests that in the globus group physiologic variance from the normal may be significant and requires further study.

1855 West Taylor Street, Chicago, Illinois 60612

Acknowledgment—The authors wish to express their appreciation for the technical assistance of Mr. Stan B. Osenar.

Request for reprints should be sent to David D. Caldarelli, M.D., 1855 West Taylor Street, Chicago, Illinois 60612.

REFERENCES

1. Butin JW, Olsen AW, Moersch HJ, et al: A study of esophageal pressures in normal persons and patients with cardiospasm. Gastroenterology 23: 278-291, 1953

2. Code CF, Creamer B, Schlegel JF, et al: An atlas of esophageal motility in health and disease. Springfield, Illinois, Charles C. Thomas, 1958, p. 23-27

3. Creamer B, Andersen HA, Code CF: Esophageal motility in patients with scleroderma and related diseases. Gastroenterology 86: 763-775, 1956

4. Creamer B, Donoghue FE, Code CF: Pattern of esophageal motility in diffuse spasm. Gastroenterology 34: 782-796, 1958

DISCUSSION OF PAPERS BY DR. SAUNDERS AND DR. CALDARELLI, ET AL.

Francis L. Lederer, M.D.: The significant ulceration post-cricoid is worthy of comment on the basis that it is the indwelling tube that you put in patients who are debilitated to the degree that this one was and postoperative people who have inanition, and so on. It is significant that the nasogastric tube, by its up-and-down motion, may cause this type of ulceration. This was shown by Holinger in a series of patients reported about 30 years ago and I think it is worthy of thought because the tube for feeding is so frequently used. By the way, it is the Levin tube, not the Levine tube, that is the culprit.

I just put that out as a feeler for Dr. Saunders in regard to this ulceration which he has so beautifully shown in his Kodachrome picture.

John A. Kirchner, M.D.: I would like to propose that another possible cause of this dysphagia was an acute neurological disturbance affecting the constrictor muscles and the pathologist, I think, would have done well to get the brain stem on this patient and see whether there had been an infarction or a vascular lesion of some of the bulbar nuclei. We have had a number of these elderly patients who are admitted with an acute onset of dysphagia, with aspiration, with a mass visible on X-ray in the same place as yours. These people are sometimes

admitted with a working diagnosis of carcinoma of the upper end of the esophagus. Esophagoscopy in some patients has shown nothing at the level of the mass and I suspect that the mass is simply an atonic cricopharyngeus muscle which is relaxed and which can be seen on the films.

I suspect that the osteophytes in this case were of long standing.

ROBERT B. LEWY, M.D.: Does an orthopedic surgeon or does an otolaryngologist remove the osteophytes?

When they are removed, what is the route of access to them?

Does the route of access create any danger to the recurrent laryngeal nerve? It has in some instances by some orthopedic approaches.

DISCUSSION OF PAPER BY DR. CALDARELLI, ET AL.

ALBERT H. ANDREWS, JR., M.D.: Francis L. Lederer, M.D. of Chicago has emphasized that the term globus hystericus is sometimes used for diagnosis of various subjective disorders in swallowing. We had hoped, in this study, to define globus hystericus in definite functional terms as determined by esophageal pressure studies. This was not accomplished.

I wish to emphasize that the point of recovery from swallowing, in the cricopharyngeal area, was a drop to two-thirds of the contraction pressure. This is a conventional means of recording changes in phenomenon which start rapidly and end slowly such as the logarithmic curve of discharge or charging rates of capacitors. It might be that more significant physiological data would have been obtained if the observations had included the remaining one-third, as Dr. Caldarelli pointed out in his conclusions.

DISCUSSION OF PAPER BY DR. SAUNDERS

DR. ANDREWS: Patients having dysphagia because of proliferation of bone on the anterior surface of the cervical vertebra have been quite rare in our experience. The cases we have considered suitable for surgery have shown obstructive signs on barium fluoroscopy and lateral x-rays of the neck have shown bony proliferation significantly larger than Dr. Saunders has shown us in his excellent presentation. These patients have been operated by Charles V. Heck, M.D. of the University of Illinois and the clinical results have been excellent.

DR. SAUNDERS (closing): Thank you, Dr. Lederer for pointing out the possible relationship of a nasal-gastric feeding tube to the ulceration in this patient. It just may be that was the cause.

In answer to Dr. Kirchner, the brain and brain stem were examined in this patient, as was the esophagus and the entire larynx, and the brain and brain stem were normal, both grossly and on the microscopic examination. There also was no tumor in the upper esophagus.

We do feel that this is a definite example of almost total obstruction of the esophagus and partial obstruction of the trachea by the osteophytic mass.

In our institution the osteophytes are removed by the laryngologist.

DR. CALDARELLI (closing): We have done a study prior to this that has shown, using intraluminal electromyography and myself as the subject, that the cricopharyngeus does relax during swallowing. Whether there is an increased tension that we cannot pick up in the esophageal motility studies may well be true, and it may have to be done by more sophisticated means, such as intraluminal myographic studies where the myograph is a bit smaller and easier to swallow.

THE DIAGNOSIS AND SURGICAL MANAGEMENT OF CONGENITAL TRACHEOESOPHAGEAL FISTULA WITHOUT ATRESIA OF THE ESOPHAGUS

SEYMOUR R. COHEN, M.D.

LOS ANGELES, CALIF.

It is almost a century since Lamb[15] first described a case of tracheoesophageal fistula without esophageal atresia, and only slightly over 30 years since Imperatori[9] performed the first successful correction of this lesion through a transtracheal approach. Less than 20 years ago Knox[14] performed the first lateral cervical approach to the correction of this very unusual congenital lesion and since then the number of successful corrections of H-type tracheoesophageal fistulas has increased dramatically. Since Johnston and Hastings[11] reported 13 cases of isolated tracheoesophageal fistulas from the Childrens Hospital of Los Angeles, nine more cases were reviewed and all were surgically corrected by the left cervical approach.

It is the purpose of this paper to present the technique of and important endoscopic findings in this very unusual disease together with a summary of the surgical approach to the management of the lesion. A review of the literature reveals varied opinions regarding the effectiveness of endoscopy in the diagnosis of isolated tracheoesophageal fistulae. Since this type of examination is a most important aid in the diagnosis of diseases of the hollow viscus, the endoscopist frequently has the responsibility for the recognition of the lesion. In spite of the increased success with the surgical management of this very esoteric disease, the diagnosis of the lesion still remains a distinct challenge and the accurate localization of the level of the lesion is of utmost importance in selecting the surgical approach for its correction or repair. Endoscopy is particularly important where all other methods of demonstrating the fistulous tract have failed and yet the history and physical findings are very suggestive of the lesion. It should be stressed that no single modality or test is infallible in the recognition of this anomaly.

ETIOLOGY AND EMBRYOLOGY

Ferguson[1] has given a most detailed consideration of the congenital anomaly from the embryologic, etiologic and developmental viewpoints. The readers are referred to other articles[2,4,6,10,12,18] for an extensive review. Suffice it to say that the beginning of the embryologic development of the esophagus and trachea is an outgrowth from the entodermal alimentary canal. The pulmonary system develops as an outpouching of the ventral wall of the esophagus throughout its length. When the embryo has reached the approximate length of 4 mm there are two lateral indentations or grooves which appear on either side of the entodermal sac which gradually become deeper, and when they meet in the midline form the partition which will divide the entodermal sac into an anterior tube, which forms the respiratory tract, and a posterior tube which forms the upper alimentary system. The septum becomes complete caudally first and extends up-

From the Department of Surgery, Division of Otolaryngology, Childrens Hospital of Los Angeles, University of Southern California School of Medicine.

wards into the cranial direction, and when the embryo has reached the 11 mm length the septum is complete. Any developmental arrests or failures in the completion of this septum will obviously result in a tracheoesophageal fistula.[3] Since the esophagus increases in length at a faster rate and more than the trachea, the fistula stretches in an upward curve.

CLINICAL PICTURE OF THE DISEASE

Infants who present the following triad of symptoms should be suspected of having a tracheoesophageal fistula. The triad has been described as 1) paroxysmal coughing initiated by feedings, 2) distention of the gastrointestinal tract particularly during straining and crying, and 3) recurrent pneumonitis or pulmonary infections which fail to clear with usual forms of treatment.[7]

A tracheoesophageal fistula should be considered in the differential diagnosis of a newborn infant presenting with symptoms of coughing, cyanosis and choking after administration of water or a feeding. In the older infant it is not uncommon for the symptom complex to subside when the feedings are thickened. Where gavage or gastrostomy feedings are given, the symptom complex disappears although it is frequently noted that the infant has considerable increase in saliva and mucus retained in the mouth for long periods of time. During feedings auscultation of the chest will often be productive of rales in the lung field when the swallowing act is initiated.[19]

Aspiration pneumonitis may occur within the first four to eight hours of life and persistent or recurrent atelectasis and pneumonitis, most often in the right upper lobe, are present so frequently as to be of diagnostic value. The observation that gastric distention occurs when the infant cries or strains is now recognized as a distinctive feature of this anomaly. Accumulation of air with prominence of the epigastrium is much greater than seen in any normal infant. Helmsworth[7] states that "rapid direct inflation of the stomach during coughing is pathognomonic of a fistula between the tracheobronchial tree and upper alimentary tract." There have been children with this anomaly whose true diagnosis had escaped recognition and had been erroneously diagnosed as megacolon, and have had surgery performed because the abdominal distention had been so marked as to confuse the true diagnosis. A roentgenogram of the abdomen showing distention of the stomach is practically diagnostic in the infant with aspiration problems. A nasogastric feeding tube passed into the stomach may show a continuous flow of air from this organ accentuated by coughing and crying. The stool can be so frothy and filled with air as to resemble a bath sponge, but this is an inconstant finding.[20] The absence of pneumonia does not rule against the diagnosis of a fistula. Because delay in surgery represents extreme hazard to the infant, it is incumbent on the diagnostician to have an accurate approach to the diagnosis of this quite elusive of congenital lesions. Because of a very high index of suspicion aroused by the triad of symptoms so characteristic of this anomaly, diagnoses and cures have increased in number.

ASPECTS OF DIAGNOSIS

The persistent demand for corroborative roentgenographic and endoscopic evidence in the diagnosis of a tracheoesophageal fistula without atresia has led to many technical advances. Repeated efforts to demonstrate the lesion often prove to be strenuous procedures that are not without danger to the tiny infant. While in the past[17] diagnoses may have been made more often at the autopsy table than during life, there has been a reversal of this aspect of the anomaly by improvement in radiographic and endoscopic techniques. One of the most important changes which has recently become common knowledge is that a congenital H-type tracheoesophageal fistula is characteristically high, being near or above the thoracic inlet. Failures in the past may very well have been due to the difficulties in approaching the lesion by thoracotomy. A review of the different op-

erative approaches for the repair of an H-type tracheoesophageal fistula reveals that the failure rate is greater when the transthoracic rather than the transcervical repair is used.[13]

RADIOLOGIC ASPECTS OF DIAGNOSIS

The esophagram is the most common diagnostic means used in confirming the diagnosis of a suspected tracheoesophageal fistula. Pneumonitis may be seen on the routine chest roentgenogram and usually involves the right upper lobe. The infant is fluoroscoped in the left oblique position so that the space between the esophagus and trachea is radiographically separated. Lipiodol® or a thin barium mixture is swallowed in an attempt to visualize the fistula. Abnormal peristalsis in the distal esophagus has been reported as an important clue that a fistula may be present.[5] Some authors[16] recommend that the examination be done in the prone or anterior oblique position so that the contrast media will flow anteriorly into the trachea. Careful observation during fluoroscopy is a necessity and where cinefluororadiography is used less irradiation is necessary and a greater degree of accuracy in diagnosis of the fistula can be expected. Some authorities instill the contrast media into the esophagus via an esophageal tube. Leigh and associates[16] recommend a tracheogram by injecting the Lipiodol by direct laryngoscopic guidance and films are taken in the AP, PA and both lateral projections. It is said that these studies may succeed since the tracheal opening is less likely to collapse and close the fistula. Schneider and Becker[21] feel that the most definitive method of making or excluding the diagnosis of a tracheoesophageal fistula without atresia is by cineradiography. Since at cineradiography the fistula has been noted to fill and empty almost instantaneously, routine esophagrams may fail to document the lesion. It is a truism that not all fistulae can be diagnosed by roentgenographic techniques of any type (Fig. 1).

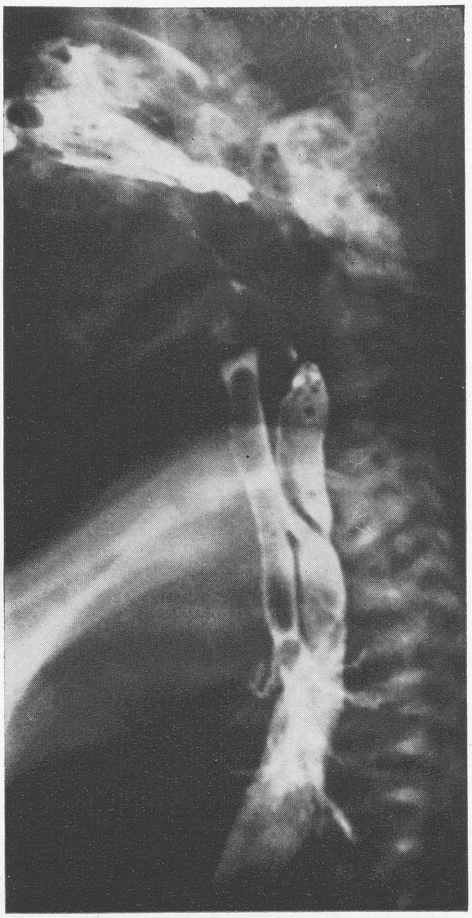

Fig. 1.—Esophagram showing tracheoesophageal fistula. Note the distal end is lower (esophageal) and the caudal end is higher (tracheal). A tracheobronchogram was obtained simultaneously with the swallowing of the radiopaque dye.

ENDOSCOPIC DIAGNOSIS

Laryngoscopy, bronchoscopy and esophagoscopy either alone or in combination are of immeasurable help in the diagnosis of tracheoesophageal fistula. Not only are the procedures of therapeutic value but they aid in the diagnosis in cases where all other modalities have failed.

While many authors indicate[1,8,21,22] that bronchoscopy or tracheoscopy have the greatest probability of delineating a fistulous tract because of the anatomy of the trachea, this has not been true in the author's experience. Esophagoscopy, they feel, is less effective because of anatomic folds which

obscure visualization of the fistulous tract. This author's experience is that esophagoscopy is the most direct method of finding the site and level of the fistula.

Preliminary laryngoscopy will give a good indication of the mobility of the pharynx and larynx and whether there is retention of secretions which may reflux into the trachea. It also rules out the presence of a cleft of the larynx which could simulate a tracheoesophageal fistula. Bronchoscopy will be of benefit to the child who has aspirated secretions or feedings, since by removing obstructive secretions and obtaining cultures and sensitivity tests, therapy of the patient is enhanced and more effective. The typical bronchoscopic finding in a tracheoesophageal fistula of the H-type varies from the appearance of a fistulous tract associated with atresia. In the latter the fistula is usually visible at a level just above the carina and may even be within the right or left mainstem bronchus. This type of fistula has the characteristic appearance of a spur of a segmental bronchus, while the H-type fistula appears on the tracheal side as a volcano-like projection, usually in the midline, and a small opening may be seen within the crater. The opening is not a consistent finding and hyperextension of the neck can produce the projection of the posterior wall creating difficulties in interpretation of the lesion on the tracheal side. To attempt cannulization through the tracheal opening is difficult and could be hazardous. The volcano-like projection is characteristically quite high being almost immediately under the vocal cord area and well above the thoracic inlet. This mounding of the posterior wall will persist in spite of flexion of the head and reduction of the curvature of the neck.

The characteristic esophageal findings of tracheoesophageal fistula without atresia is best found with the patient under general anesthesia and a Cole type endotracheal tube in place, with the patient being given positive pressure ventilation. A fold is seen appearing as an inverted V with the apex facing the mouth of the esophagoscope

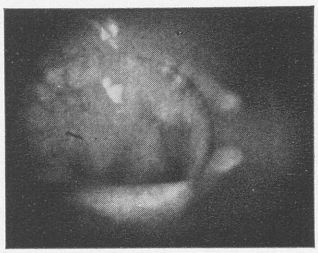

Fig. 2.—Illustrates inverted V or triangle, at the apex of which is the fistula.

on the anterior wall of the esophagus (Fig. 2). The endoscopist will see a fistulous tract at the apex of the folds pouting and if the tracheobronchial tree has a suppurative process from repeated aspirations, secretion can be seen to blow through the fistulous tract into the esophagus. Synchronous with the positive pressure ventilation the anterior wall of the esophagus is seen to bulge down into the esophagus, narrowing the lumen. This effect is due to air filling the fistulous tract and separating the tracheal and esophageal party walls. Following instillation of 0.5 cc of methylene blue dye[5] into the trachea through the endotracheal tube, and ventilating the patient, the dye will pass into the esophagus through the apex of

Fig. 3—Illustrates the appearance of methylene blue dye through the apex of the inverted V, the site of the distal or esophageal end of the fistula.

the folds of the inverted V (Fig. 3). Great caution, particularly in the very tiny infant, must be taken not to compress the anterior wall of the esophagus by too large an esophagoscope. If necessary a small bronchoscope may be preferable especially in the very small or premature infant. Even without the appearance of suppurative material or

methylene blue dye from the trachea, one can diagnose the presence of a fistulous tract by hearing a blast of air synchronous with the ventilation of the patient. This, however, is not to be considered as prima facie evidence of a fistulous tract since leaking of air from around the endotracheal tube could be mistaken for the air blast being in the esophagus. When a fistula is suspected and demonstration is not possible by roentgenographic studies, endoscopy is an essential part of the patient's examination. Fears of intolerance of these procedures are unwarranted. In the hands of expert endoscopists there is less risk than the repeated flooding of the tracheobronchial tree from attempts to demonstrate a fistula with radiopaque dyes. An interesting concept regarding the folds which are seen in the areas of the fistulous tract is that it may be due to a tenting of the fistulous tract as it is suspended from the trachea. This presumably is due to the stretching of the fistula with obliquity caused by the more rapid growth of the esophagus as compared with the trachea during their embryology. The fistulas found on x-ray for which endoscopic procedures were necessary for other reasons than the demonstration of a fistula were invariably found by endoscopic techniques. As is seen in the case reported herein failure to demonstrate the fistula with four radiologic examinations was finally successful with the use of the above described endoscopic techniques.

REPORT OF CASE

A ten-month-old Caucasian female was referred to the Childrens Hospital of Los Angeles for diagnosis and treatment. She was the product of a nine month pregnancy complicated by polyhydramnios. She breathed spontaneously but did not cry and had increased secretions requiring frequent suctioning. She subsequently had recurring upper respiratory tract infections and three episodes of pneumonia with one episode of meningitis. She choked and gagged on feedings and had to be propped up after each attempt at feeding. Her voice first developed at two months of age as a low pitched cry and she was babbling by ten months of age. Developmentally she sat, pulled herself up, and walked with support by ten months of age but did not sit alone until nine months of age. Three esophagrams failed to reveal any abnormality although a tracheoesophageal fistula or some neurologic disturbance was suspected. Physical examination revealed an alert but pale, thin, white female with a high pitched cry with suprasternal and substernal retractions, and inspiratory and expiratory wheezes and rhonchi bilaterally with rales over the right chest. There was no heart murmur and a neurologic examination was within normal limits. The Tine test was negative. Laboratory data showed the hemoglobin to be 11.8 gms with a white count of 21,800 with a normal differential. The BUN was less than 5. A chest x-ray and electrocardiograph were reported as normal.

Laryngoscopy and bronchoscopy were performed and a partial posterior cleft of the larynx with tracheobronchial suppuration was found. A culture of the material in the bronchial tree revealed hemophyllus influenza not type A or B. Esophagoscopy revealed the typical inverted V-shaped folds just below the cricopharyngeus area. At the apex of this V a fistulous tract could be seen through which an air blast was heard. Purulent material was seen to blow into the esophagus during ventilation of the patient through the fistulous opening. Methylene blue inserted into the trachea through the Cole endotracheal tube following ventilation appeared in the esophagus (Fig. 3). The diagnosis of tracheoesophageal fistula without atresia was made and an esophagram was repeated. This fourth esophagram, and the only one done at Childrens Hospital, was reported as normal. The tracheoesophageal fistula was repaired and the postoperative course was uneventful with the exception of an esophageal cutaneous fistula which closed spontaneously. The child was discharged as improved, having gained weight, was feeding normally and was without evidence of disease. A follow-up examination showed no feed-

ing problems and the persistent partial posterior cleft of the larynx caused no difficulty with the voice or feeding.

SURGICAL APPROACH

The surgical approach will depend upon the level of the fistula and this should be ascertained prior to surgical intervention. With the use of all of the well known modalities, especially radiologic and endoscopic techniques, it should be rarely necessary for surgical exploration to be indicated without prior diagnosis.

In the event that there is a rare instance where the fistula is suspected but cannot be demonstrated by any of the known techniques, the cervical approach should be first since the majority of lesions will be accessible by this route. It may be necessary at times to approach the lesion through the thoracic route but only a small percentage of these fistulae will require this approach. As has been stated before, failures to identify and correct the H-type tracheoesophageal fistula may very well have been due to the use of the wrong surgical approach. It is noteworthy that all of the fistulae seen at the Childrens Hospital of Los Angeles were at the sixth and seventh cervical and first thoracic vertebral level and, therefore, could be surgically approached through the neck. Only one, of well over 20, was at the second thoracic level.

The left cervical approach is most successful and should be used in all cases except those instances where the patient has a right aortic arch. In this condition with the trachea being deflected to the left, a right cervical approach might be indicated. A transverse incision is made in the skin in the lower third of the left anterior portion of the neck, the head having been rotated to the right and the neck hyperextended. Incision is made through the platysma and down to the deep cervical fascia. Incision of the deep cervical fascia along the anterior border of the sternocleidomastoid muscle is then made with exposure of the muscle itself. The muscle can then be transected to give better exposure, and the carotid sheath is retracted laterally followed by identification of the tracheoesophageal groove. Upon retracting the thyroid gland dissection in the groove with gentle retraction of the trachea anteriorly and to the right is then carried out and identification of the recurrent laryngeal nerve is made. Retraction of the nerve and trachea then makes possible the visualization of the ballooning of the esophagus which is due to air passing through the trachea into the esophagus during the ventilation of the patient. Dissection is carried out from the lower part of the neck up to the area of the fistula which can be as high as the cricoid cartilage. After identification, the fistula is doubly ligated and cut. Closure of the esophageal end to insure against leakage is then performed and if possible, fascia is interposed between esophagus and the trachea. Closure is then accomplished and the wound is drained.

COMPLICATIONS

In most instances there will be no complications, but left cord paralysis may occur temporarily from traction on the recurrent laryngeal nerve. Where bilateral vocal cord paralysis occurs it is due to extensive dissection and the use of tapes around the esophagus for traction purposes. An esophagocutaneous fistula may occur but it will close spontaneously within a short period of time. The cervical approach has fewer respiratory complications than when the thoracic approach is used.

SUMMARY

1. The clinical picture of tracheoesophageal fistula is reviewed.

2. The radiologic and endoscopic findings, together with the techniques of demonstration of the H-type tracheoesophageal fistula, are described.

3. The surgical approach to the correction of the usual H-type fistula is described.

4. A case is reported where four roentgenologic examinations failed to reveal a fistula found by the use of the endoscopic techniques herein described.

CHILDRENS HOSPITAL OF LOS ANGELES, LOS ANGELES, CALIF.

ACKNOWLEDGMENTS—Gratitude is expressed to Jordan Weitzman, M.D. of the Department of Pediatric Surgery for his invaluable aid in reviewing this paper and for having performed the surgery in the case reported; also to Drs. George Lewis, Edward Scott and Wayne Herbert of the Department of Anesthesiology.

Request for reprints should be sent to 6221 Wilshire Blvd., Los Angeles, California 90048.

REFERENCES

1. Ferguson CF: Congenital tracheoesophageal fistula not associated with atresia of the esophagus. Laryngoscope 61: 718, 1951

2. Fluse Z, Poppen K: Embryogenesis of tracheoesophageal fistula and esophageal atresia. Arch Path 52: 168, 1951

3. Gengenbach FP, Dobos EI: Congenital tracheoesophageal fistula. J Pediat 19: 644, 1941

4. Gruenwald P: Case of atresia of esophagus combined with tracheoesophageal fistula in 9 MM. human embryo and its embryological explanation. Anat Rec 78: 293, 1940

5. Gwinn JL: Tracheoesophageal fistula with and without esophageal atresia - special aspects. Prog Pediat Radiol 2: 170, 1969

6. Haight C: Congenital tracheoesophageal fistula without esophageal atresia. J Thorac Surg 17: 600, 1948

7. Helmsworth J, Pryles C: Congenital tracheoesophageal fistula without atresia. J Pediat 38: 601, 1951

8. Herweg J, Ogura J: Congenital tracheoesophageal fistula without esophageal atresia. J Pediat 47: 293, 1955

9. Imperatori C: Congenital tracheoesophageal fistula without atresia of the esophagus. Arch Otolaryng 30: 352, 1939

10. Ingalls TH, Prindle RA: Esophageal atresia with tracheoesophageal fistula: epidemiologic and tetralogic implications. New Eng J Med 240: 987, 1949

11. Johnston PW, Hastings N: Congenital tracheoesophageal fistula without esophageal atresia. Amer J Surg 112: 233, 1966

12. Keith A, Spicer JE: Three cases of malformation of the tracheoesophageal septum. J Anat Physiol 41: 52, 1906-1907

13. Killen D, Greenlee H: Transcervical repair of H-type congenital tracheoesophageal fistula. Ann Surg 162: 145, 1965

14. Knox G: Congenital tracheoesophageal fistula without esophageal atresia. Surgery 30: 1016, 1951

15. Lamb DS: A fatal case of congenital tracheoesophageal fistula. Phila Med Times 3: 705, 1873

16. Leigh TF, Abbott OA, Hopkins WA: Roentgenologic considerations in tracheoesophageal fistula without esophageal atresia. Radiology 57: 871, 1951

17. Mullard KS: Congenital tracheoesophageal fistula without atresia of the esophagus. J Thorac Surg 24: 39, 1954

18. Rosenthal AH: Congenital atresia of the esophagus with tracheoesophageal fistula: report of eight cases. Arch Path 12: 756, 1931

19. Rothman P: The clinical manifestations of tracheoesophageal fistula without esophageal atresia. Med. Bull. Childrens Hosp. Los Angeles, 11: 49, 1964

20. Rothman P: Personal correspondence

21. Schneider H, Becker J: The "H-type" tracheoesophageal fistula in infants and children. Surgery 51: 671, 1962

22. Seiber W, Girdany B: Tracheoesophageal fistula without esophageal atresia, congenital and recurrent. Pediatrics 18: 935, 1956

DISCUSSION

CHARLES F. FERGUSON, M.D.: Twenty years ago when we first reported the H-type fistula, as Dr. Cohen noted, most of them for some reason or other were found to be much lower down. These youngsters were, therefore, subjected to thoracotomies for the ligation of

the fistula. In recent years, of course, most of them have been found to be at an upper level, so that they can be more easily reached through an incision in the neck.

They are very difficult to diagnose, as Dr. Cohen mentioned, and many children have had esophagoscopies, bronchoscopies and various dye injections without being able to delineate the fistula. The fistula usually is seen much more easily through the bronchoscope than it is through the esophagoscope because the tracheal lumen is constantly open and larger. The fistula comes into view better as one looks down; but the esophagogram usually will show it better than the bronchogram.

One method that I used many years ago before I started using the dye injection technique, (which Dr. Cohen has illustrated) was to put a balloon way down into the esophagus and inflate it. I then put another obstructing balloon down just above the suspected fistula with a catheter going down lateral to it. Through the catheter I could inject lipiodol very easily under pressure and see it come into the trachea. Because the esophagus was obstructed by the balloon we didn't get a "spill-over" through the larynx. This method demonstrated many of such fistulae which were otherwise undemonstrable by the usual techniques. It is difficult sometimes to bring a small fistula into view and I would agree that the dye injection which Dr. Cohen has illustrated, in that particular position, is of great advantage.

ALDEN H. MILLER, M.D.: At Children's Hospital the first experiences there were through the chest surgeon. What happened not too many years ago the chest surgeon went in on such a patient and to his amazement he could not find the fistula through the thoracotomy approach. This child unfortunately expired not too soon thereafter, but the autopsy showed the bar of the H taking off just below the true cords and with that, the next case that came along one of our chest surgeons did the first surgical approach through the neck just about as you see it here.

DR. COHEN (closing): This is a difficult and very elusive lesion to demonstrate and any help from any area is most encouraging.

No child need die or have a prolonged morbidity with communication between the trachea and esophagus because surgically this is a correctable lesion.

THE RADIOLOGICAL TREATMENT OF JUVENILE NASOPHARYNGEAL ANGIOFIBROMAS

T. D. R. Briant, M.D.

P. J. Fitzpatrick, M.D. Howard Book, M.D.

Toronto, Canada

The juvenile angiofibroma is a relatively rare, histologically benign, but clinically troublesome neoplasm occurring in adolescent males. It does appear to occur in females although some authors[4] dispute this, claiming that any similar lesion in the female is by definition not an angiofibroma. Dibble and King,[1] and New and Figi,[5] report an incidence of one female in 14 males which is approximately the incidence in our own group (Table I).

TABLE I

INCIDENCE P.M.H.

27 Males
2 Females
14:1 (Dibble & King)

The age incidence in our patients is similar to other published series such as Marten et al.[4] of approximately 16 years of age (15.9). The average period from the onset of symptoms and definitive diagnosis was 14.4 months.

The etiology of this tumor is unknown but is exhaustively dealt with in other publications.[8-10] The main theories center about endocrine abnormalities, although there is little to support this supposition at the present time. All our hormonal investigations in patients have failed to reveal any significant abnormality.

Clinically and pathologically the tumor arises in the nasopharynx often having multiple attachments and a wide base of origin (Fig. 1). Histologically it consists of wide vascular spaces lined by a single endothelial layer. These channels are surrounded by a collagenous tissue network, and usually lack a complete muscular layer. It is probable that this deficiency in the muscular layer predisposes this tumor to its characteristic hemorrhagic tendencies. Typically, the tumor presents with severe recurrent epistaxis and/or nasal obstruction in an adolescent male. In 29 cases seen at the Princess Margaret Hospital (Table II), varying degrees

TABLE II

SYMPTOMS – 29 CASES

Nasal Obstruction	27
Epistaxis	22
Facial Deformities	10
Cranial Nerve Palsy	1

of nasal obstruction were present in 27 patients while severe epistaxis was a presenting symptom in 22 cases. Less commonly, facial deformity, proptosis and cranial nerve palsies may be present.

The recent literature has favored surgery as the treatment of choice in juvenile angiofibromata.[3,7] Pressman wrote that all cases of juvenile angiofibromata associated with severe hemorrhage should be considered surgical problems. He states that "of all methods (of treatment) surgery alone has proven effective."

From the Department of Otolaryngology, Univ. of Toronto, Princess Margaret Hospital and Toronto General Hospital, Toronto, Canada.

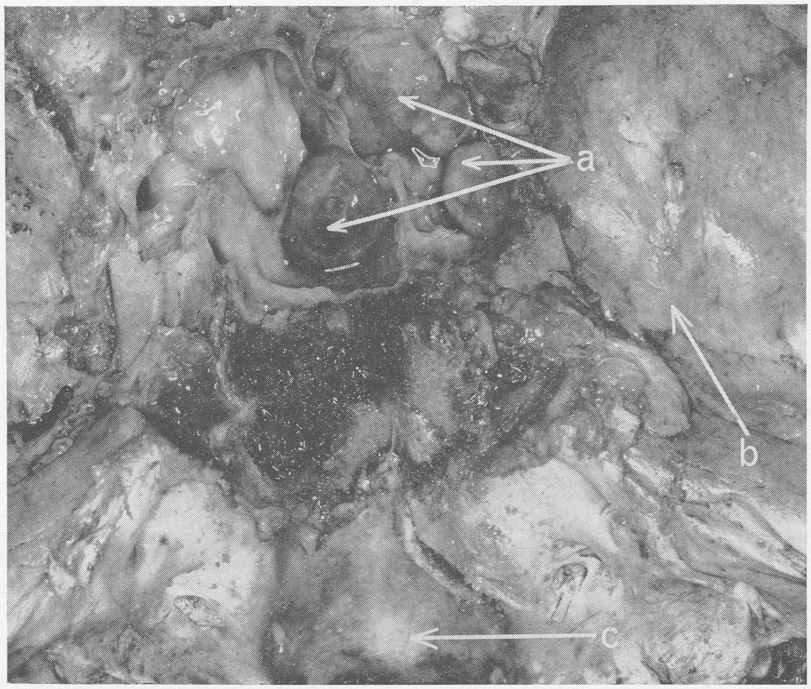

Fig. 1.—Postmortem specimen showing tumor in the sinuses as viewed from above with the roof of the sphenoid and ethmoid sinuses removed. a) tumor in ethmoid and sphenoid sinus; b) middle cranial fossa; c) clivus and foramen magnum.

Patterson,[6] after using both surgical, radiation and a mixed treatment of this tumor, concluded that "complete surgical removal of larger lesions with multiple attachments is virtually impossible." Ehrick[2] writes that "there are too many anatomical irregularities in the nasopharynx to permit complete removal of the tumour, regardless of the approach and with incomplete removal the tumour may recur." Any adequate surgical follow-up figures in the literature tend to substantiate this comment.

CLINICAL MATERIAL

Twenty-nine patients with the histologic diagnosis of angiofibroma of the nasopharynx presented themselves at the Princess Margaret Hospital. One patient died of a hyperthermic reaction from a general anesthetic during angiography before any treatment was instituted. Twenty-eight patients received radiotherapy. Twenty cases have been followed for more than two years and 18 cases for longer than three years (Table III). Thirteen patients received radiotherapy as a primary mode of treatment, while seven received radiotherapy after prior surgical intervention.

TABLE III
CLINICAL MATERIAL – FOLLOW UP

20 Cases – more than 2 yrs.
18 Cases – more than 3 yrs.

METHOD

At the Princess Margaret Hospital cobalt irradiation is usually given by two opposing (R) and (L) fields 6 cm by 6 cm to 8 cm by 8 cm. A total tumor dose of 3,000 rads is given over a three week period (Fig. 2).

After irradiation there is almost always a latent period before the tumor begins to regress. The latent period may be as short as three weeks or as long as three months. Complete regression of the tumor may take as long as one year (Table IV).

TABLE IV

Latent Period	3 wks – 3 months
Regression Time	up to 1 year

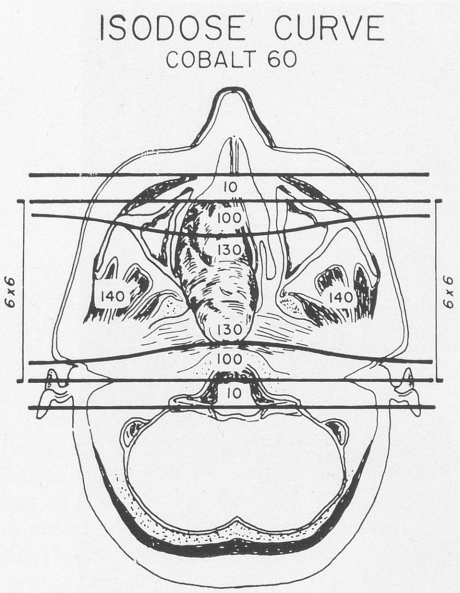

Fig. 2.—Ports and isodose curves used in treatment.

Although irradiation may induce malignant changes, because of the time-dosages that are used, we hope that this possibility is minimized. Necrosis of the base of the skull has been reported where large doses of irradiation have been used.[11] The level of radiation used at the Princess Margaret Hospital is such that even dryness of the mucous membrane is avoided, with follow-ups as long as 12 years.

FINDINGS

Plain skull and sinus x-rays were augmented by polytomography and angiography. It is of the utmost importance to know the extent of the lesions as an additional anterior radiation field may become necessary if there is extensive involvement of the sphenoid sinus. We believe that the failure to radiate tumor present in the sphenoid was responsible for two of the failures of the initial dose of radiation (Cases 7 and 15).

In 29 cases, investigation showed that tumor was present in the ethmoids in three cases. Sphenoidal extension was

Fig. 3.—Facial deformity noted with juvenile angiofibroma.
Fig. 4.—Nasal widening due to a nasopharyngeal angiofibroma.

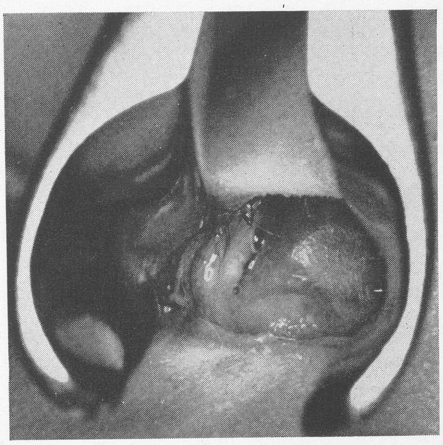

Fig. 5.—Large nasopharyngeal angiofibroma presenting in the nares.

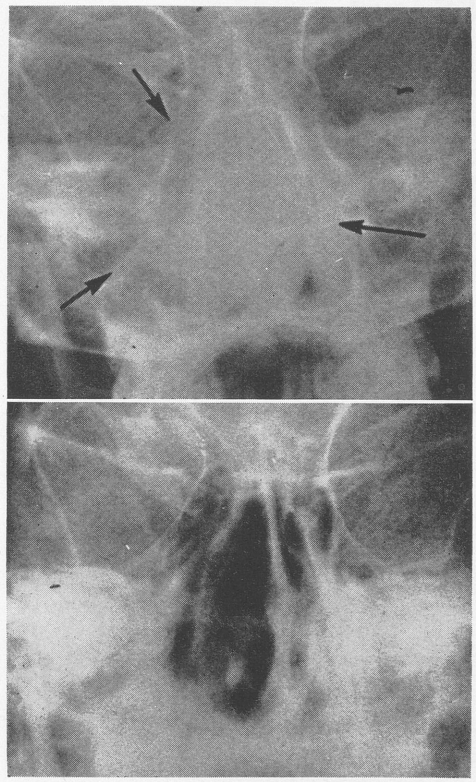

Fig. 6.—Pre- and post-treatment x-rays showing disappearance of very large vascular angiofibroma.

present 14 times in patients. Extension into the pterygomaxillary space and antrum was seen in 12 cases. Cranial nerve palsy was noted in one case and

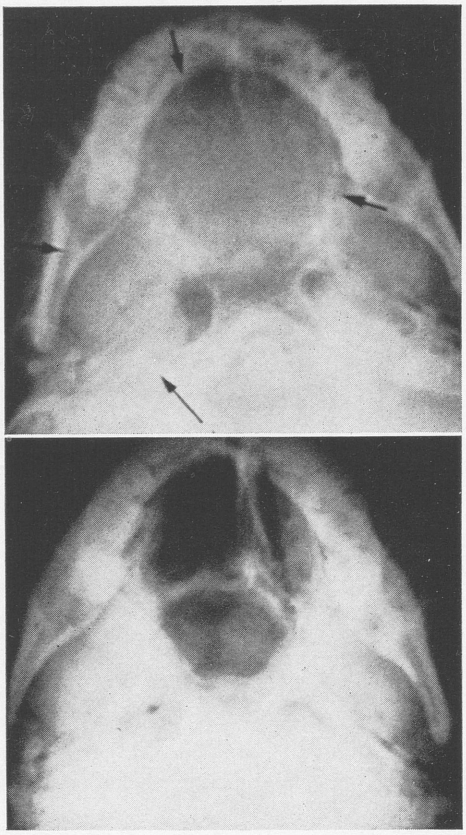

Fig. 7.—Pre- and post-treatment x-rays showing complete remission of tumor following 3,000 rads.

orbital extension was seen in two cases (Fig. 3, Table V).

TABLE V

STRUCTURES INVOLVED

Sphenoid	14
Antrum	12
Ethmoids	3
Orbit	2
Cranial Nerve	1

RESULTS

In our series of cases surgery was undertaken 19 times and was successful only once, i.e., in only two instances was no further treatment necessary. One patient was left with residual tumor after his last surgical procedure but went on to a spontaneous remission some three years later. Radiation was undertaken 22 times and was successful

TABLE VI

NASOPHARYNGEAL ANGIOFIBROMA
RESULTS OF TREATMENT

Cases seen at the Princess Margaret Hospital 1946 - 1967

Patient No.	*Treatment*	
1	S R	
2	S R	
3	R	
4	R	
5	R	
6	R	
7	S S R S S S R	
8	S S R S*	
9	R	
10	S S S S S S R	
11	S S R	R . . . Radiation
12	R	
13	S R S	S . . . Surgery
14	Died	
15	R R	
16	R	
17	R	
18	R	
19	R	
20	R	
21	R	

* Spontaneous regression of residual tumor

in 17 instances. It is to be noted that of those 13 patients who had irradiation as the primary mode of treatment only one patient required further treatment (Figs. 4, 5, 6 and 7; Table VI).

CONCLUSIONS

It appears that a high percentage of patients with nasopharyngeal angiofibroma are cured with a relatively small dose of radiation. It seems that the likelihood of cure is higher if radiation is the primary mode of therapy. The remission of the tumor may not begin until three months following the radiation. There may be a one year interval before total remission is obtained. In view of this it seems wise to wait at least one year prior to any surgical interference for tumors that do not appear to regress satisfactorily after radiation.

SUMMARY

Our experience at the Princess Margaret Hospital with a total of 29 cases of juvenile angiofibroma, 20 of whom have been followed for more than two years and as long as 12 years, shows radiation to be an efficient and effective method of treatment in a high percentage of tumors without any unwanted side effects as yet.

PRINCESS MARGARET HOSPITAL, TORONTO, CANADA

REFERENCES

1. Dibble PA, King HC: Juvenile angiofibroma. Laryngoscope 72: 218-31, 1962

2. Ehrick JB: Juvenile fibromas of the nasopharynx. Ann Otol 62: 277-281, 1955

3. Martin Treat et al: Juvenile angiofibroma. Ann Surg 127: 513-536, 1948

4. Martin, Ehrlick HE, Abels JC: Juvenile nasopharyngeal angiofibromas. Ann Surg 127: 513, 1948

5. New GB, Figi FA: Treatment of fibromas of the nasopharynx - Report of 32 cases. Amer J Roentgen 122: 340-343, 1924

6. Patterson CN: Juvenile angiofibromas. Arch Otolaryng 81: 1965

7. Pressman J: Juvenile angiofibromas. Arch Otolaryng 76: 167-173, 1962

8. Redoglia D: Hypogenetalism syndrome polycythermia and nasopharyngeal fibroma Italde. Arch Otolaryng 61: 77, 1950

9. Ringerty N: Pathology of malignant tumours arising in the nasal and paranasal sinuses and maxilla. Acta Oto-laryng Suppl 27, 157, 1959

10. Vermeuil: Quoted by H. Beasch Bertrage zur beauthectung der cherrergischen behandling der nasenrachenpolyper. Breslau, E. Morganstein

11. Wudiger Sir B: Juvenile angiofibromas. Bull Acad Med of Toronto, 1964

DISCUSSION

JOHN A. KIRCHNER, M.D.: In those tumors that invade the sphenoid sinus and fill it, the pituitary gland must necessarily be included in the field of treatment. Have these boys had any disturbance in their growth?

DANIEL MILLER, M.D.: The first tendency is to think that the disease north of the St. Lawrence River is different than what it is below it. However, this is an impressive list of cases and I certainly am very much impressed.

We have had experience with external radiation with failure except in a rare patient. It is like the other tumors, the cylindromas, that are radio-resistant for the most part but occasionally are very radio-sensitive. I don't know the nature of this tumor in Canada; however, I will say this, that we have continued to use local implantation of one millicurie radon seeds as our method of radiation for many, many years. We feel that there is less chance for involvement of the growth centers than in youngsters who are given external radiation and the hot areas that are produced in the tumor by radon seeds eventually end with scar tissue and retraction.

In the event that a patient is presented to us with nasopharyngeal fibroma, our plan has been to order these one millicurie radon seeds to be available if necessary. Since we have utilized the surgical techniques of transantral or transpalatal approach, we have ready a palatal prosthesis in the event of any problem in the closure and protection of the palate; we have the radon seeds and we have liquid nitrogen available, using cryosurgery as a handle technique to hold on to these tumors as we dissect them.

Yours is a beautiful description of the multilobular appearance of this tumor, and its extension into the sphenoid and into the antrum. However, it depends on the amount of collagen fibers in the tumor, whether it will respond well to radiation therapy or not. It is true that the younger the tumor the plumper the endothelial cells and therefore there are probably more radio-sensitive tumors than the more mature tumor with its greater amount of collagen fibers and it may be that most of your tumors are in the younger immature category.

I am most happy to hear this paper because it does tell us that radiation therapy, whether in the form of external radiation or radon seeds locally applied, is still part of the armamentarium for the treatment of this rather disturbing tumor.

JOHN S. LEWIS, M.D.: I think one thing that Dr. Miller, as President here today, has emphasized is the importance of looking back historically to the treatment and management of this problem.

May I have the first slide? I have brought several slides of our experience at Memorial Hospital.

(Slide) At Memorial Hospital some 50 cases of juvenile angiofibroma were treated over a period of about 25 years and this is an extract of a report made by Dr. Apostle and Dr. Frazell from this institution.

Thirty-two cases were treated by surgical excision and I bring this slide forward to indicate that nine cases were treated by radiation therapy.

(Slide) Now, these were patients who were treated by Dr. Hays-Martin some 25 years ago and reported by him in his famous article that he and Dr. Ehrlich presented in 1948. There were nine cases treated by radiation. I must emphasize, however, that the radiation

given was in the nature of 4000 r. given through several ports and, as you can see, most of these patients had – many of these had complications and these are the complications outlined.

I think that the management of this type of tumor is by preference one of surgery when they are bulky and causing epistaxis, nasal obstruction and deformity, supplemented by the use of radon seeds.

STANTON A. FRIEDBERG, M.D.: Some years ago we thought that the use of radon seeds in these lesions seemed, on a histological basis at least, to promote maturation and, as you all know, these things do subside spontaneously if you can wait long enough. Whether or not the irradiation is actually the cause of the regression or whether it initiates regression is another factor.

R. M. BUTLER, M.D.: Approximately five years ago I presented a paper at the Academy on the surgical approach to angiofibroma, and since then I have had personal contact with approximately 17 of these patients.

I advocated the use of stilbesterol followed, or during the work-up time, with arteriography, which I think is extremely important, and then surgical excision, never entering the tumor. If you enter the tumor, much as with the mixed tumor of the parotid gland, you will not remove it totally, in my estimation. I recently saw one removed piecemeal in six pieces. That was last summer and the patient has been re-operated recently.

I have some hesitation in advocating the use of stilbesterol at the present time, although there have been no serious adverse reactions from the stilbesterol. I have operated upon several patients where they could not tolerate the stilbesterol due to gastric instability, and we have had minimal blood loss.

I have also used temporary ligation of the external carotid artery. I still feel this is very important and emphasize again, only temporary ligation to avoid the development of collateral circulation from the vertebral to the internal maxillary artery, which can never be controlled adequately when you have to re-enter for these tumors.

I am very impressed with Dr. Briant's presentation and his list of patients. We were inclined to use radiation therapy in the severe patients early in our study where we inadequately removed the tumor. We were not impressed at any point that the irradiation significantly diminished the size of the tumor and on repeat surgical exploration it usually contributed to more bleeding.

I really don't know how to interpret his results. I don't think we can accomplish this at U.C.L.A. and at U.C.L.A. we will continue to use surgery as our main approach.

I have only one criticism of his presentation of statistics. He mentioned that there were 12 involvements of the maxillary sinus. In the 17 that I have encountered I have only had one small rosebud of a tumor coming through the posterior wall of one maxillary sinus. I would suspect that most of these are extending into the pterygomaxillary space posterior to the maxillary sinus.

DR. BRIANT (closing): There are many questions I have in my own mind about this group. All I can do is report them.

With regard to the pituitary gland, those, who like myself, do a lot of pituitary surgery know how difficult this gland is to injure or to oblate and 3000 r., I would say, has no effect whatsoever on the pituitary gland.

We have not seen any changes in growth centers and some of these boys are in their late twenties now and they look perfectly normal and their mucous membrane looks really quite normal with 3000 r.

I can say we have not seen unwanted side effects. This young lad that you saw here has crusting on one side of his nose and the reason, I believe, is that the tumor was very, very large and had compressed the septum into the lateral wall of the opposite side of the nose. It compressed the lateral wall, or the medial wall of the antrum to the lateral wall of the antrum, making a huge cavity on that side, and when the tumor regressed it left a very large cavity, from which he has to remove crusts from time to time. It is really the only instance of crusting. The other side of his nose looks normal and, other than being narrow, it functions well.

In regards to hormones, we have used testosterone only and found no help from it. We have not used stilbesterol. We have been rather interested in it but have been afraid of closing the epiphyses on these young boys with the use of stilbesterol, creating dwarfs. This may be just a theoretical problem and not seen in practice.

With regards to local implantation of radon seeds versus cobalt, our radiotherapists feel that they can better control the cobalt. They have a better idea of how much radiation the patient is receiving, and they prefer to give external radiation in non-cancercidal doses of 3000 r.

We have seen one patient who was treated in 1917 elsewhere with radon seeds and various other forms of local radiation and he recently presented at our institution with a nasopharyngeal carcinoma, so that this must be kept in mind. In reviewing the amount of radiation this patient received, it appeared as though he received somewhere in the neighborhood of 20,000 rads locally, so that this is not a comparable dose to what we are giving.

RECONSTRUCTIVE SURGERY RELATED TO LARYNGOLOGY

RICHARD T. FARRIOR, M.D.

TAMPA, FLA.

The "compleat" laryngologist by modern standards must necessarily be schooled in the principles and techniques of reconstructive surgery. For total rehabilitation of the laryngeal cripple, early and often primary reconstructive procedures are instituted.

The preservation or restoration of the airway and voice to a normal or near normal state is the primary objective. With continued advances, ever increasing improved voice quality may be anticipated. When total eradication of the voice box is required, then the related reconstruction of the alimentary canal, in the area of the cervical esophagus, becomes the objective.

It is not the purpose of this presentation to delve into the treatment of various medical and surgical conditions of the larynx. Rather, it is the purpose to discuss the broad principles and applications of reconstruction to this anatomic area. The reconstructive management of particular cases will be shown because of the unique circumstances or complications.

In addition to restoration of function with available local tissue, fundamentals of tissue transplantation extending from the free skin graft to actual organ or partial organ transplantation, must be in the laryngologist's spectrum of thinking. This, then, leads to a consideration of microsurgery and vascular surgery. The use of implant materials, autogenous to synthetics, and the need for prosthetic devices, in particular circumstances broadens the scope of this work. The laryngologist must be intimately familiar with these surgical principles and the teaching of these fundamentals must be done throughout the entire training program in the specialty. With such a background, the need for additional fellowship years would lessen, or if taken, would be infinitely more valuable in that the advanced trainee could then concentrate on more sophisticated techniques and devote time to the development of new techniques and the promotion of futuristic research.

PRINCIPLES OF RECONSTRUCTIVE SURGERY

For purposes of this presentation, we are concerned with the repair of tissue defects from whatever cause, whether it be simply lining that is required, or the reconstruction of supporting structures, contour, motion, or sphincter action.

Tissue grafts, whether skin, mucous membrane, fascia, nerves, blood vessels, cartilage, or bone, may be divided into those bearing their own blood supply and free grafts.[14,17] For an understanding of the principles of grafting, the laryngologist must have some knowledge of tissue transplantation in general, the principles of the preparation of a satisfactory recipient site, and basic immunology regarding the acceptance and rejection of tissue. Precise dressings and splinting are essential.

The free graft must receive its nutrition from the recipient site. Splinting, contouring to the recipient bed and immobilization are important and present unique problems in the area of the laryngopharynx. This exists also on the anterior external neck, where movement of the larynx from speech and swallowing occurs. Movement may at times be

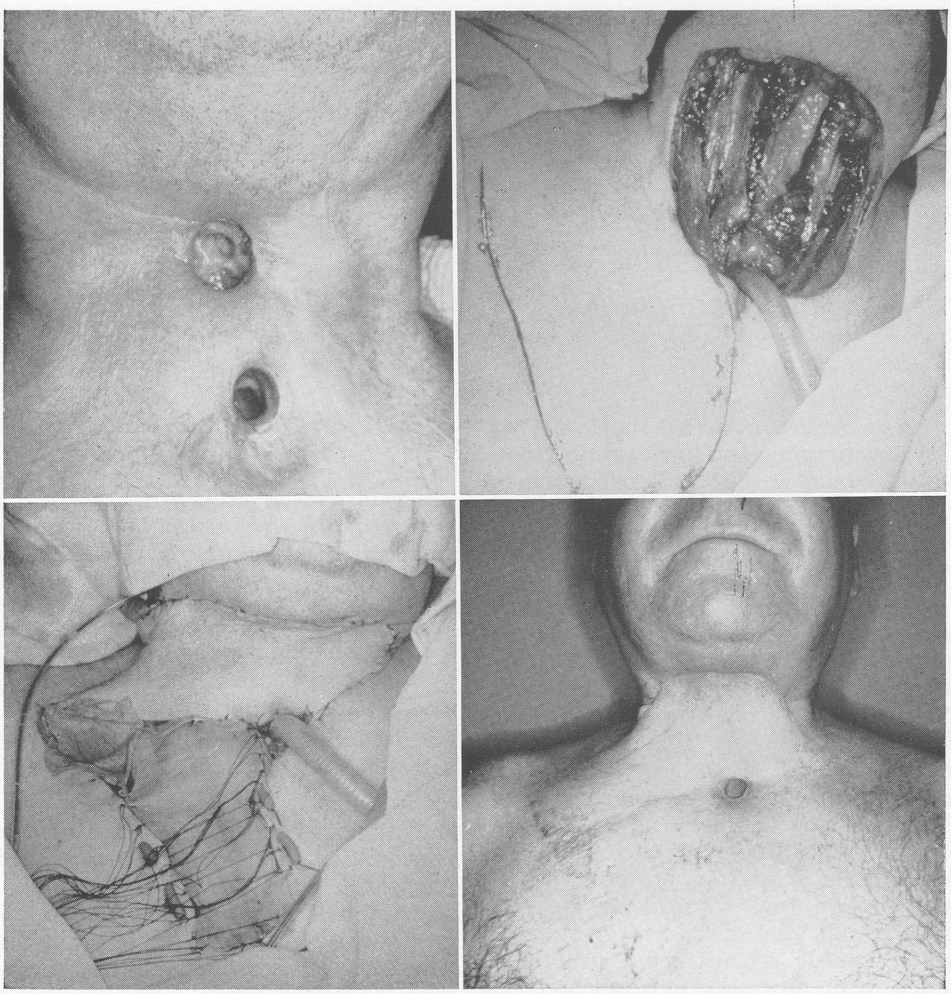

Fig. 1.—One Stage Transposition Flap. A) Radionecrosis with malignant breakdown; through-and-through defect. B) Surgical defect and design of one stage transposition flap. C) Transposition; closure of donor area with split thickness skin graft. D) Postoperative result.

quite violent, as with severe or explosive cough. Unique to this area also, is the fact that the graft is constantly bathed with both bronchial and alimentary secretions.

With the increased use of radiation, as combined therapy, there is a need for the transfer of healthy tissue carrying its own blood supply into the defect.[14] With current advances in techniques, most often this can now be accomplished as a primary single stage procedure. Prior radiation is not a contraindication to primary reconstruction, but preplanning is essential and careful assessment of the vascularity, tissue quality, etc. is necessary (Fig. 1).

The same imagination may be used for mucous membrane as for skin and the preparation of mucous membrane advancement, transposition, rotation and bipedicle flaps.

The otolaryngologic reconstructive surgeon must be knowledgeable in regard to wound healing. In the larynx, healing is modified in the frequent production of hyperplastic tissue and

abundance of granulations on the one hand, and the creation of scar contractures and stenosis on the other. Often, the laryngologist is not confronted with the closed wound for ideal healing by primary intention, but with a raw surface to be bathed constantly with secretions. The establishment of primary covering with free grafts or pedicle flaps is most desirable.

The principle of the Z-plasty with transposition of flaps of mucous membrane, is applicable to this anatomic location.

Microsurgery is most applicable to the anastomosing or grafting of blood vessels[25] and nerves.[12] Refinements in the techniques will be essential for further evaluation of organ transplantation and reconstitution of nerve function.

Historically, we should, perhaps, start with the free skin graft.[17] This method of tissue transplantation has been around a long time and has met with considerable success, not only in the larynx and pharynx, but as a readily available and abundant source for covering the donor sites after the creation of major skin flaps. This form of combined grafting has multiple applications. Free skin grafts are often essential for external resurfacing, internal lining, and the release of contracted or previously reconstructed structures. Even with advances in surgical technique and greater sophistication in the use of pedicle flaps of different designs, there remains a definite role for the free skin graft in laryngology. The free skin graft does have some disadvantages in that splinting must be maintained sometimes for long periods with disturbance in the airway, speech and swallowing. Even with splinting, unpredictable and undesirable contracture can occur.

Bone and cartilage from adjacent tissue, such as the hyoid, cricoid and trachea have been successfully used.[11,16,30] As free implants, adequate coverage with skin or mucous membrane with its own blood supply is necessary.

The use of solid synthetic implants in the larynx has not been adequately explored. For these implants, the deeper they are placed in the tissue, the greater the possibility of success.[16]

CONDITIONS REQUIRING RECONSTRUCTION

Any tissue defect or void must be considered for reconstruction. The tissue void may be from trauma, the excision of scar, the excision of malignant and nonmalignant tumors, or resulting from the removal of congenital anomalies.

The treatment of chronic laryngeal stenosis and reconstruction following the many modifications of partial laryngectomy have provided, perhaps, the main grounds for modern advancements in reconstructive surgery. At the other end from conservation surgery are the extended ablative techniques such as mediastinal resection and the need for the utilization of major pedicle flaps.

There is an increased instance of, and recognition of, injuries to the larynx. Trauma may also be postsurgical extending from simple endoscopic procedures through tracheotomy.

Chronic Laryngeal Stenosis. Persistent stenosis after proper initial and medical management for purposes of this presentation requires either incision and release of the stenosis, or excision of scars, stenotic bands, etc. Chronic laryngeal stenosis presents unique problems, whether from crushing injuries, lacerations, or caustic burns. Either condition leaves a defect, either of mucous membrane or framework. Dilatation may be used, but for the larynx and the hypopharynx with thick scar tissue bands or stenosis, in my hands the results have been generally unsatisfactory.

The chief advances are in the use of improved splints, for both the larynx and pharynx, and the application of mucosal and skin grafts and flaps. Where possible, direct anastomosis may be utilized.[35] In severe cases of stenosis of the hypopharynx, especially with the larynx intact, more use should perhaps be made of external skin flaps, especially to the posterior pharyngeal wall. Such flaps may require creation of a temporary external fistula or could per-

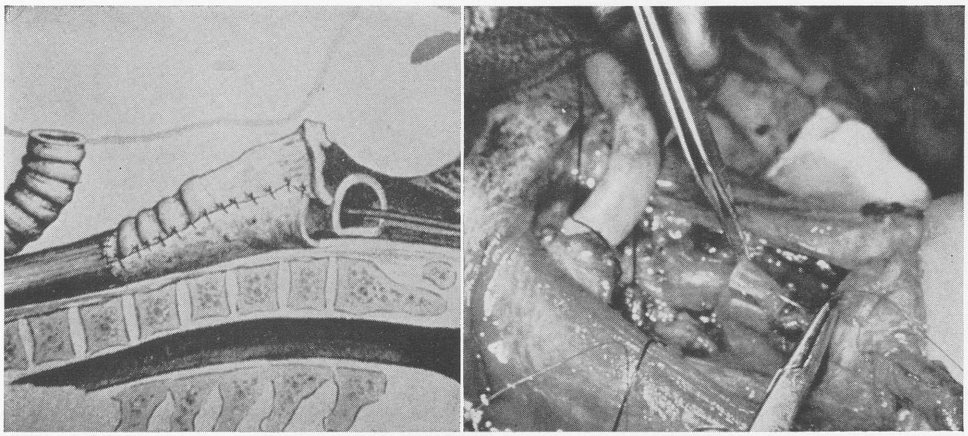

Fig. 2.—Laryngoesophagectomy. A) Coronal resection using anterior laryngotracheal pedicle and split thickness skin graft over stent (Courtesy M. Som[43]). B) Author's full lumen reconstruction of the cervical esophagus with remaining trachea tubed and the tracheal rings cross-hatched before suturing to the esophagus. No skin graft was used.

haps more often be accomplished with dermal shaves or utilizing the principle of the island flap to allow primary closure of the pharyngostome. The colon swing[36] is particularly applicable to benign conditions creating stenosis of the hypopharynx and cervical esophagus with the larynx preserved. In personal communication, Dr. Ogura more often uses the horizontal chest flap for reconstruction of the cervical esophagus when the larynx has been removed.

The Z-plasty has many applications and can be particularly useful in chronic stenosis for release of contractures, interdigitating to prevent angular scars, and two-plane flaps as described above. The geometrics of the tetrahedral Z-plasty (Furnas) to release webs and restore a normal notch or commissure has its place.

Partial Laryngectomy. Good speech was frequently obtained with a satisfactory cicatricial vocal band following the simple laryngofissure operation or cordectomy. These same type cases now are assigned to radiotherapy. With extension of the procedure to include the indicated excision of cartilage, especially over the anterior commissure, more anterior webs and less satisfactory voice occurred. With more extensive hemilaryngectomies, the removal of the arytenoid, and more radical excision of thyroid cartilage, healing by secondary intention is inadequate.

Covering the resulting larger defect has lead to some ingenious forms of the laryngoplasty with mucosal flaps[10,33,38] and musculoplasty procedures[3,33,38] to fill out the defect of the operated side. Although success has been good for correcting air waste for vocal cord paralysis by the injecting of RTV silicone and Teflon®,[1,16,31] in my hands, the results have been wanting for postoperative defects from partial laryngectomy. This then leads to the possible advisability of secondary open or external surgical procedures for reconstruction of these cases operated by older methods or unsatisfactory results. Most often this has not been the actual practice.

Musculoplasty has been accomplished with bipedicle,[3] unipedicle,[33] transposition of muscle and with free muscle grafts.[38] Coverage for the muscle may be with mucosal flaps and skin grafts[17] or the use of pericondrium.[3]

Free skin grafts for simple thyrotomy and partial laryngectomy provide a large percentage of takes, but often a wide open glottic area with increased air waste and poor voice quality. With

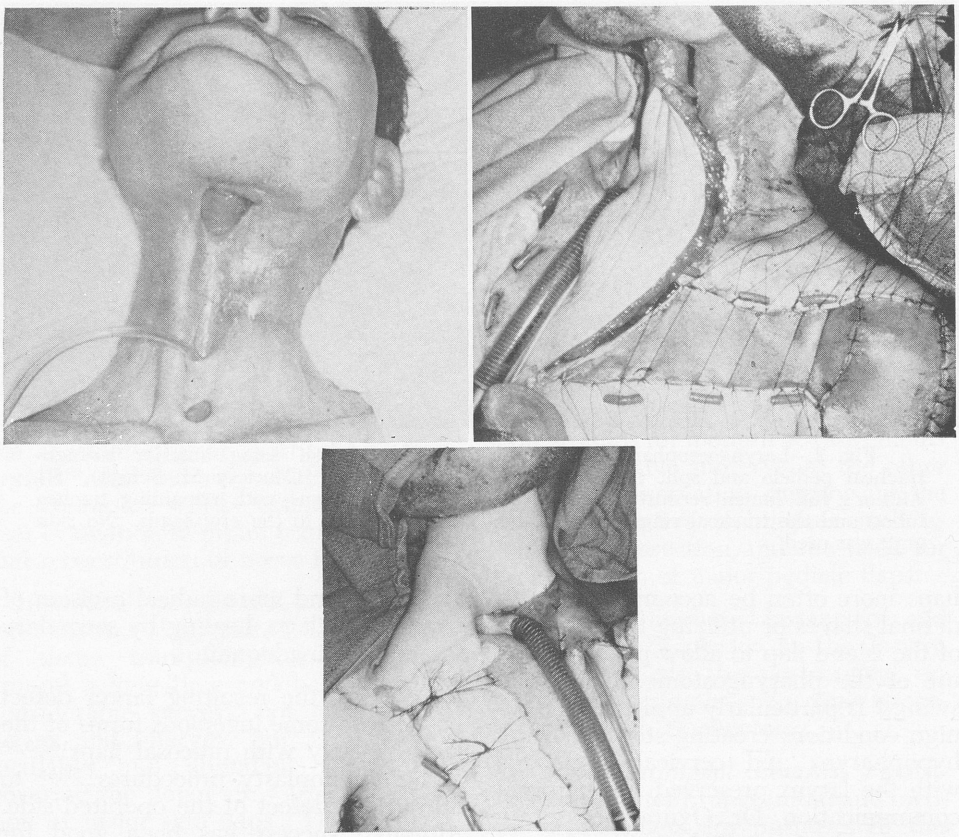

Fig. 3.—Pharyngolaryngectomy; Simultaneous Horizontal and Vertical Chest Flaps. A) Pharyngostome and esophagostome with no satisfactory cervical skin. B) Horizontal chest flap tubed for reconstruction, split thickness skin graft to the donor area. C) Simultaneous vertical chest flap for coverage of the raw surface and replacement of cervical skin (see text).

improved techniques, simple skin grafting at the present time is not adequate.

Conservation Surgery. The validity and desirability of conservation surgery for carcinoma has been established. This approach in itself leads to innovations regarding reconstruction of the surgical defect and reconstitution of the airway, cervical esophagus and the best possible speech.

In more extensive procedures, skin grafts were initially thought to be necessary, as for supraglottic laryngectomy. More often a direct closure, bringing the tongue to the level of the cords, can be accomplished. The tongue may be filleted, advancing mucous membranes slightly, or mucosal flaps from the tongue and pharyngeal area may be created. I prefer direct closure with mucosa carrying its own blood supply to free grafts.

Conservation surgery also applies to lesions of the hypopharynx and cervical esophagus in selected cases. With these, the need for the total pharyngolaryngectomy is lessened and preservation of the entire larynx may be possible. We have had experience with the use of the coronal resection of the larynx as indicated by Som,[43] utilizing the preserved larynx and trachea, actually a pedicle graft with blood supply from above for total reconstruction of the cervical esophagus (Fig. 2).

Pharyngolaryngectomy. More aggres-

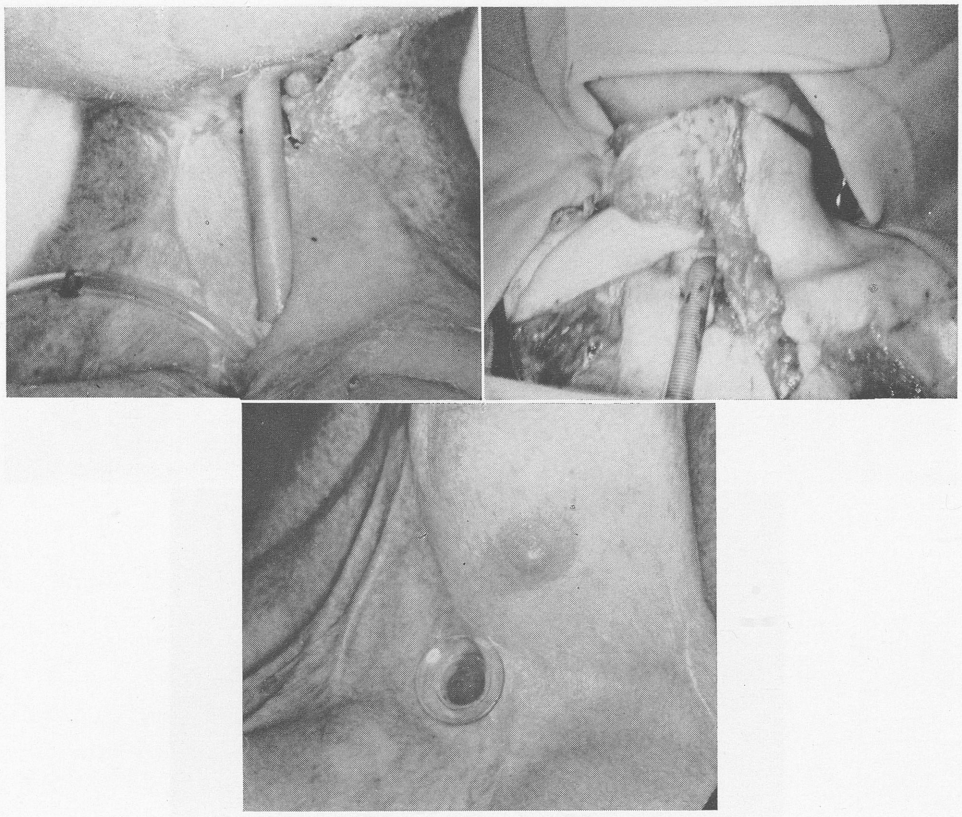

Fig. 4.—Complication of Horizontal Chest Flap. A) Dissolution of the irradiated cervical skin after primary transfer of the horizontal chest flap. Tubed flap retracted from tongue and opened out. B) Secondary reconstruction with a lined vertical chest flap and additional split thickness skin graft in the hypopharynx. C) Final result with satisfactory gullet and esophageal speech (see text).

sive lifesaving radical procedures have led to a unique variety of cervical and chest skin flaps. In almost every procedure, some form of combined split thickness skin graft is used either to assist in lining, as backing for the flap, or to cover the donor area. The principle of dermal shaves and island flaps will lead to a decreasing need for the creation of a temporary fistula or pharyngostome.

Reconstruction of the cervical esophagus may be by transposition or free grafts of intestine,[21] or the utilization of cervical or nearby skin.[7,17,40] The free transplantation of segments of jejunum, although successful, when failure occurs, creates added grief. I would promote the philosophy for utilization of local, if not immediately adjacent tissue in reconstruction.

I have had success and temporary setbacks with horizontal[4] and vertical chest flaps.[7] Figures 3 and 4 illustrate cases requiring "scrambling." Each of these cases were complicated by repeated courses of x-ray therapy. One case (Fig. 3) illustrates the combined use of the two major chest flaps in one operation. In this case, there was no useable skin in the cervical area. The second (Fig. 4) demonstrates the complications of dissolution of the cervical skin over a reverse tubed horizontal chest flap with the tube flap pulling away from the base of the tongue and opening out. The secondary vertical chest flap (nipple flap) was lined with

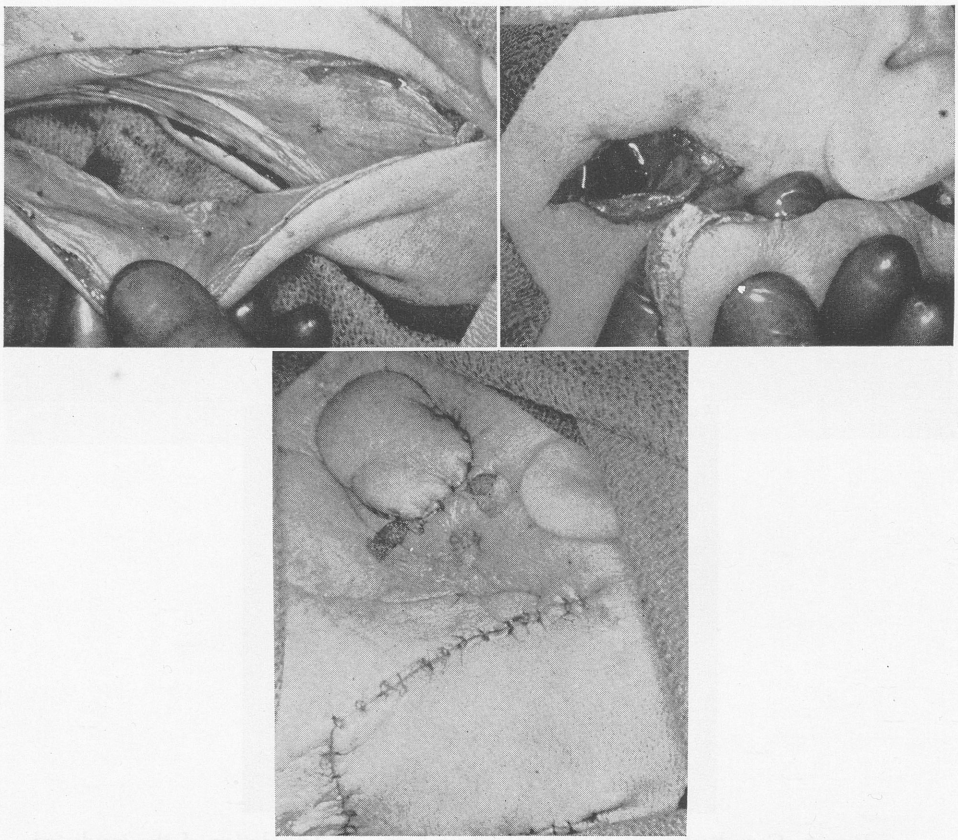

Fig. 5.—Staged Occipitomastoid Flap. A) Lined occipital mastoid flap and donor area. B) Staged transfer of the lined pedicle with de-epithelialization for imbrication about margins of defect. C) Return of thick hair-bearing skin to neck, staged section and imbrication for closure of defect.

a split graft and after delay, additional split graft was used on the posterior aspect of the hypopharyngeal wall. The patient has a good food passage and satisfactory esophageal speech.

The postsurgical fistula, so often a complication of preoperative x-ray therapy, may be closed with enfolding of the margins and covering as a single procedure or delayed to carry a split thickness skin graft for lining, as in the use of the occipitomastoid flap (Fig. 5).[46]

Sternal Split or Resection and Mediastinal Dissection. Stomal recurrence, inferior metastases and paratracheal invasion lead to resections which most often require removal of surrounding skin. These surgical defects require the use of pectoralis musculoplasties to protect the major vessels and skin flaps and grafts of various designs.[42] This case (Fig. 6) illustrates such a defect and the utilization of a large bipedicle chest flap which I generally prefer. A variety of flaps may be fashioned utilizing the blood supply of the internal mammary (medially based) or thoracoacromial (laterally based) vessels.[4,7,40] The sternum split mediastinal dissection provides an excellent opportunity for cross specialty cooperation with the cardiovascular surgeons.

Other ablative surgery extending superiorly includes combined resection of the larynx with the tongue and mandible. Here again, the pedicle flap for reconstruction of the tongue, floor of

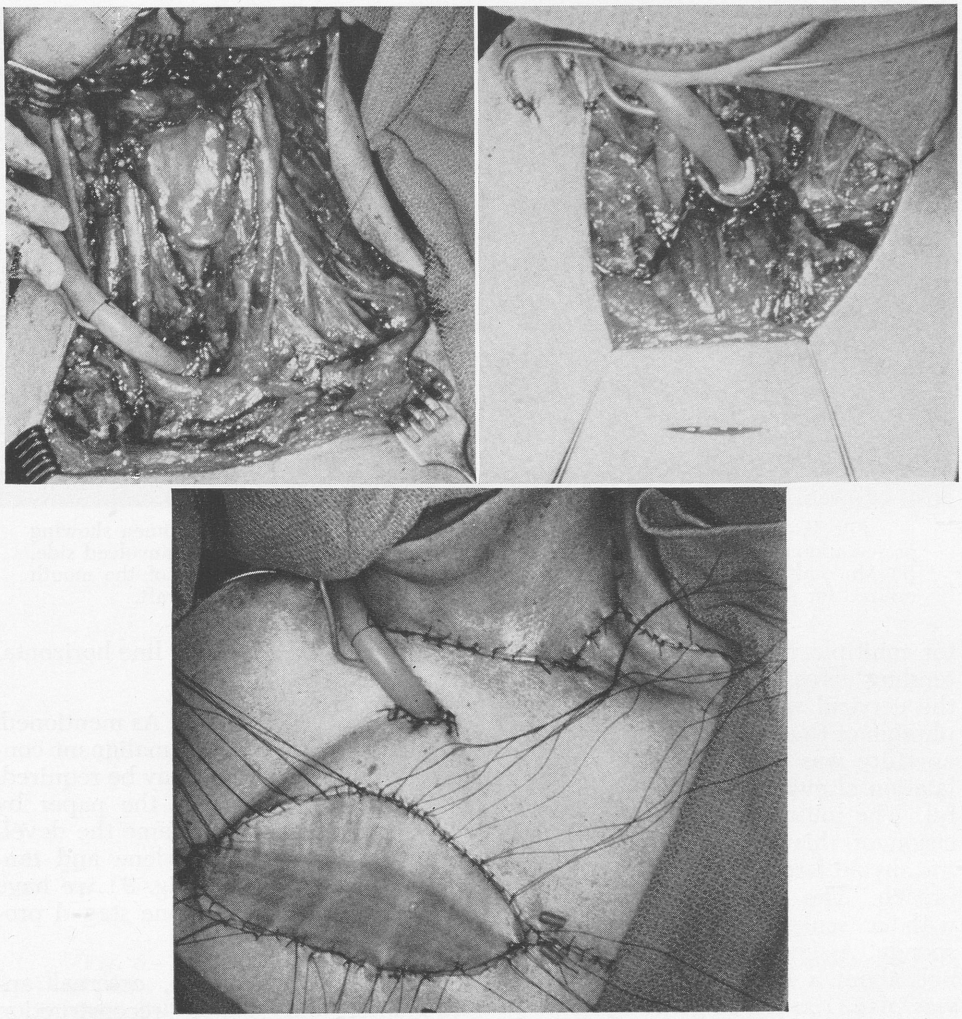

Fig. 6.—Mediastinal Dissection. A) Resection of clavicle and manubrium. Dissection to aortic arch. B) Pectoralis musculoplasty. Bipedicle chest flap. C) Closure of skin defect and covering donor site.

the mouth, and hypopharynx, has many uses, both for lining and covering external defects. In each of these cases, some imagination should be used to create mucosal flaps, decreasing the size of the necessary skin graft (Fig. 7).

Injuries. Initial treatment of laryngeal injuries[18,19] requires the same attention as for maxillofacial injuries. Soft tissue repair, closure in layers, open and closed reduction of fractures and dislocations, and spliting, all come into play. Direct interosseous or intercartilaginous wiring in conjunction with splinting is necessary to stabilize the fragments. With tissue avulsions, primary mucosal grafts and flaps and skin grafts and flaps may be required.

Principles covered above in chronic stenosis apply to the delayed complications of injury. Loss of laryngeal and tracheal framework require replacements, preferably with autogenous material.[11,24] Such implants require adequate soft tissue coverage, as developed in the preceding section.

Figure 8 illustrates delayed treatment

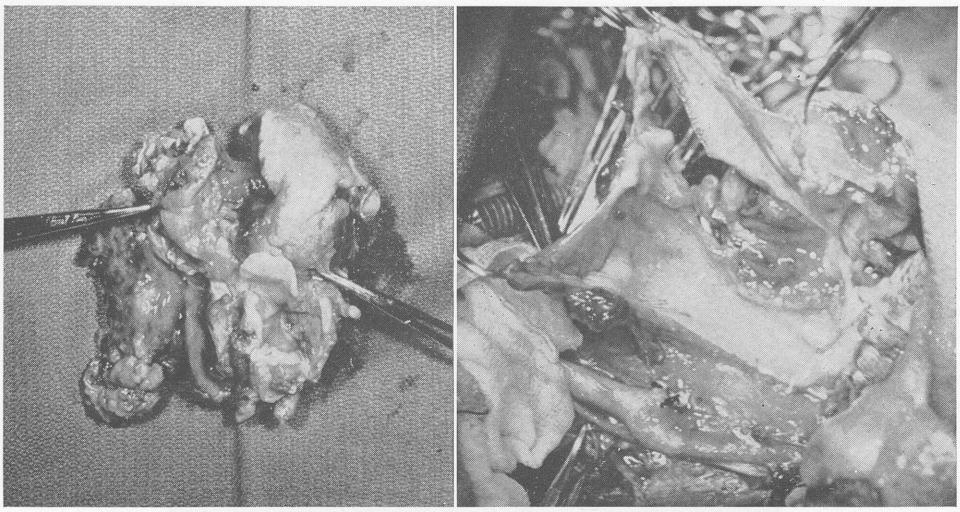

Fig. 7.—Glossectomy, Mandibulectomy and Laryngectomy. A) Specimen showing preservation of the pyriform sinus and floor of mouth mucosa from the uninvolved side. B) Mucosal flaps from the posterior pharyngeal wall and opposite floor of the mouth utilized for primary closure and reconstruction of pharynx without skin graft.

for multiple transverse lacerations extending across the supraglottic area to the cervical spine. A supraglottic diaphragm of thick scar tissue with a 5 mm aperture was present. Attempts at dilatation elsewhere had been unsuccessful. The initial procedure required excision of this circumferential scar via transhyoid-lateral pharyngotomy approach. The larynx graft was stented with a sculptured fine cell silicone sponge. A separate molded sponge funnel, about a large mushroom catheter was placed in the large pharyngeal defect. This pharyngeal stent was expelled in five days. The skin graft took, but there was slowly progressing stenosis of the hypopharynx. An interval attempt at sectioning the contracted graft endoscopically was unsuccessful. A secondary external procedure revealed satisfactory laryngeal lining and the residual contracted graft in the pharynx. After regrafting, the hypopharynx was then stented with a modified silastic Som-Negus[32,43] splint with good initial results. It should be mentioned that by advancing hypopharyngeal and cervical mucous membrane, a Z-plasty and direct anastomosis could be accomplished on the posterior pharyngeal wall. A Z-plasty lengthened the contracting band and prevented a straight line horizontal scar.

Congenital Anomalies. As mentioned, after the excision of nonmalignant conditions, reconstruction may be required. From the discussion of the paper by Lynch and Le Jeune[26] came the development of the polyethylene and tantalum keels or flags (Fig. 9) we have been using allowing a one staged procedure.

As a rule of thumb, external approaches and major reconstruction should not be performed in the child, awaiting growth of the larynx.[5] As with injuries and other congenital anomalies, the question always arises in regard to whether the abnormal condition or structure itself, would not interfere with growth as much as the reconstructive surgery with correction of the abnormality.

Trachea. The same considerations exist for the trachea. For less extensive damage or stenosis, reconstruction by direct anastomosis, with or without splinting, in particular cases is desirable. Many forms of autogenous supporting materials have been advocated, including rib grafts.[30] We have had

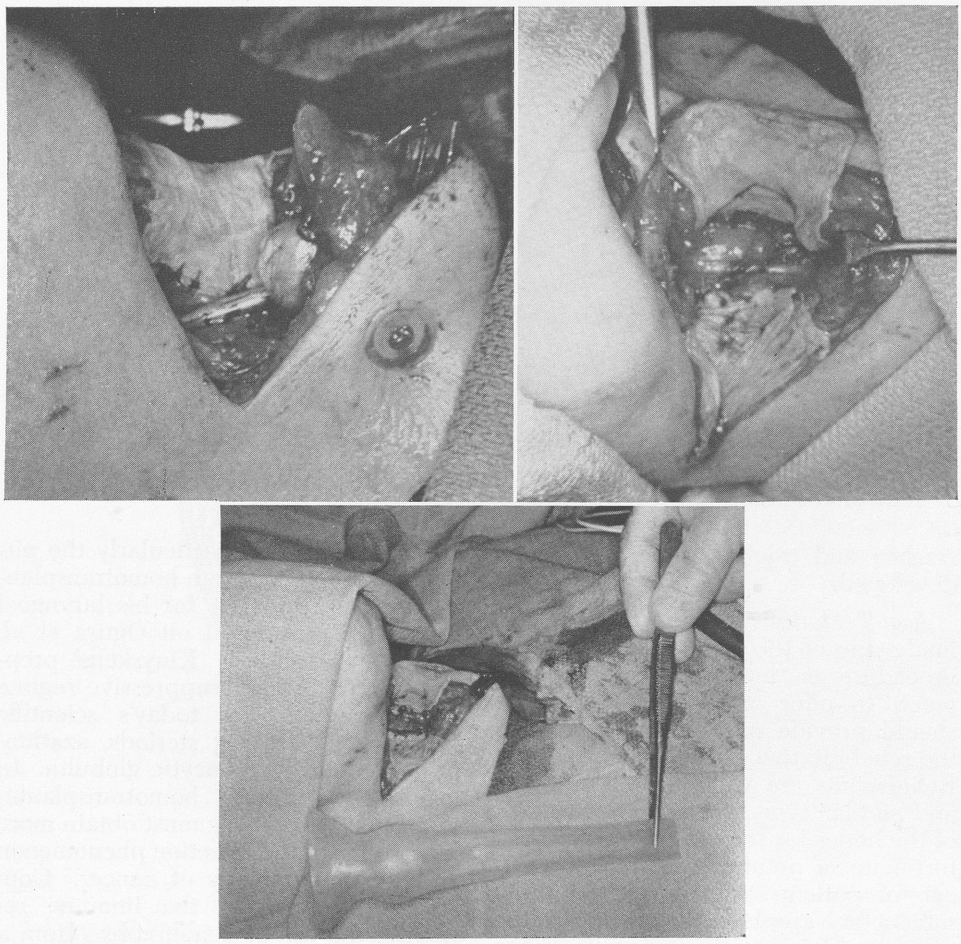

Fig. 8.—Laryngeal Trauma; Transverse Laceration with Supraglottic Stenosis and Diaphragm. A) Secondary repair following unsuccessful dilatation for thick supraglottic stenosing diaphragm. Split thickness skin graft over continued fine cell silicone sponge in the larynx. Split thickness skin graft lining the hypopharynx. Molded sponge over catheter was used for a stent in the hypopharynx. This was extruded (see text). B) Repeat procedure with posterior pharyngeal wall advancement and mucosal Z-plasty and secondary skin graft in the hypopharynx. C) Utilization of the modified silastic Som-Negus splint.

some experience using the hyoid bone when there was adequate mucous membrane coverage.[24] Techniques for lining, including pedicle flaps, are similar to those for the larynx. Synthetics have been used, both clinically and experimentally, with some good results.[13,27] I would like to propose a simple dual study in dogs for attempting a composite graft of the trachea to the cervical esophagus for microscopic follow-up relative to survival of the cartilage, and at the same time, testing different materials for reconstruction of the trachea.

Tracheostome. The stoma of the trachea following laryngectomy primarily requires precise plastic surgery technique with meticulous closure to prevent postoperative stenosis. With stenosis, when dilatation and modified plastic appliances have not proven successful, the multiple two-dimensional Z-plasty offers the best results. Methods in more severe cases for elongating the opening by a diagonal section of the

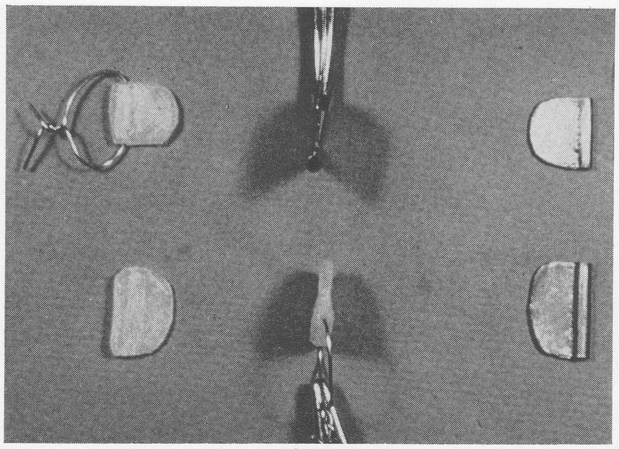

Fig. 9.—Polyethylene and tantalum flag keels. Keel inserted endoscopically as one stage procedure.

trachea and tracheal rings have been developed.

Asai Technique. Figure 10 shows the final stage of the Asai technique. This procedure or modifications[2,22,28,29] has much to offer and with refinements should provide much improvement in the rehabilitation of the laryngectomee. Refinements are yet required and this and similar type reconstruction is one of the hopes for the future. I have been fortunate in obtaining a high percentage of patients who developed quite satisfactory esophageal speech. Of the rare remaining patients, none have been candidates for this very interesting procedure. As a result, I have no personal experience with the operation. In my private practice situation, I have been conservative awaiting long-term results, development of control of aspiration, etc. As a technical exercise, I have been anxious to try the procedure and develop modifications.

Organ Transplantation. Revascularization and the technical and physiologic difficulties are less for the larynx than other main organs, such as the heart and kidney. On the other hand, the larynx is relatively superficially located, and, in fact, is essentially within the open food and air passages and is constantly bathed with unsterile secretions. Kluyskens[23] has made a bold step which teaches us many of the technical considerations and particularly the pitfalls with human organ homotransplantation. The premises for his laryngeal transplant was based on Ogura et al. laboratory studies.[37] Kluyskens' preparation and immunosuppressive regime was acceptable for today's scientific knowledge including steriods, azathioprine and antilymphocytic globulin. In my opinion, human homotransplantation is premature. We must obtain more knowledge of the rejection phenomenon and the immunology of cancer. Considering, especially, the immune response, the use of xenographs (from a different species) to me, is quite remote, or for the distant future.[9]

I am hopeful that less dramatic partial replacements will become more and more feasible. Autographs, as from other portions of the larynx or trachea,[11,15] may prove more useful.

Of course, there are many other conditions which require reconstructive procedures. Many of these procedures arise at the operating table and the more oriented to reconstruction and the greater the armamentarium of the surgeon, the more able he is to think on his feet and improvise in order to provide the best possible result for his patient.

THE FUTURE

The future is exciting. We are on the threshold of many new advances in re-

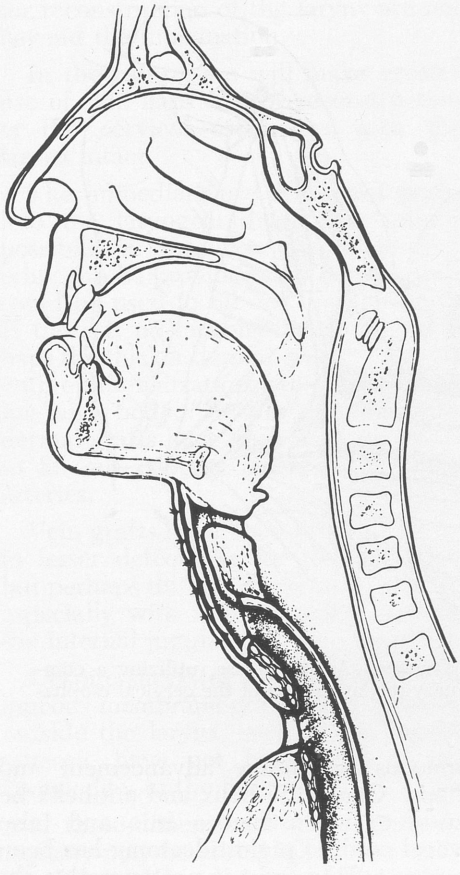

Fig. 10.—Asai Technique. Final stage of Asai technique. (Courtesy A. Miller, M.D.[28])

constructive surgery of the laryngopharyngeal area and I am convinced the strides will be quite rapid in the immediate future, though much work has to be done.

The most exciting and perhaps newsworthy prospects for the future relate to homotransplantation of the larynx, partial or total. This has been discussed with authority during this year's meeting of the Triological Society. The future will require improved methods of altering the immune response. Perhaps, evental cross-matching, as for blood, will allow the selection of appropriate donor and recipient. Development of immunosuppressive drugs and desensitization of the host, will require much advanced research. Success in regard to function will depend also on selective and precise microsurgical nerve grafting.[12] With a static larynx, you must be able to insure that the cords remain in the proper position for an adequate airway and satisfactory speech. Vascular surgery has made great strides, but acceptance of such a homotransplant is more sophisticated than the mechanical accomplishment of blood supply. Success must await further understanding of the rejection phenomenon.

For human homotransplantation, I recommend putting on the brakes and caution. In regard to reconstruction, on the other hand, I would urge full speed ahead.

The work of Miller and Kitamura will lead to additional modifications for bringing air into the oropharynx for phonation. I would like to propose, for selected occasional cases, a supracricoid-infraepiglottic rim resection with the creation of a diaphragm from the mucosa of the hypopharynx leaving a small aperture below the overhanging epiglottis. If necessary, any denuded area below the diaphragm could be skin grafted. The goal would be to eliminate the need for the dermal tube.

The future will see progress in the reanastomosing, rerouting, and grafting of nerves, especially for neuropathy of the recurrent laryngeal nerve. Nerve-muscle transplantation may provide action as well as substance, when transposed into the larynx.

I would like to present a potpourri of suggestions with the hope of stimulating some of you to further work. The use of single or bipedicle membrane-muscle flaps from the lateral pharyngeal wall for covering and substance, but more particularly for adequate covering for implant materials, has promise.

I would propose an increased use of these mucous membrane flaps carrying underlying muscle and fascia to the larynx. These flaps have been used most successfully in the pharynx as with the posterior pharyngeal flap for velopharyngeal insufficiency. The objective

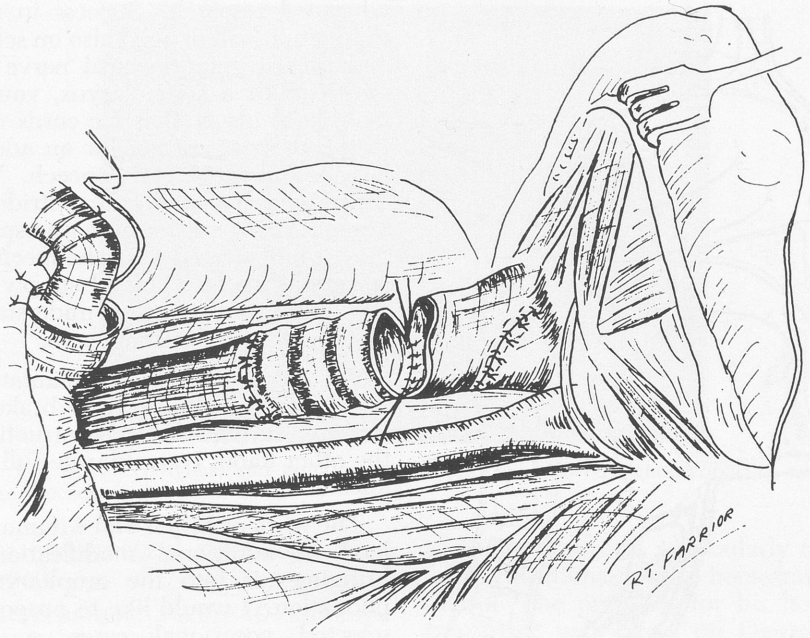

Fig. 11.—Free Composite Graph of the Trachea. Author's case, utilizing a composite autograft and mucosal flap graph for primary reconstruction of the cervical esophagus.[15]

is to obtain, perhaps, some muscle action, more body or substance, and thicker covering, especially for underlying free transplants of bone, cartilage or alloplastic materials. Better covering is also supplied for exposed laryngeal framework.

Implants, including perhaps contoured silicone rubber, could be used to more nearly simulate the normal structure of the glottic and supraglottic areas. These, I believe, are entirely feasible in partial reconstruction.

Free composite grafts of skin and cartilage have been used elsewhere with great success[45] to provide lining, prevent contracture, and give contour. I would propose the use of the ear skin and cartilage of limited size to cover especially smaller endolaryngeal defects. The use of skin on one surface and the sharp convexity of the inferior crus of the ear to place in the vocal cord area as a free graft after a partial laryngectomy is most intriguing to me. To accept such a graft of limited size, a larger defect could be made smaller by mucous membrane advancement and flaps. Could the helix and antihelix be used to reconstruct a true and false vocal cord? Epiglottidectomy has been suggested[5] to assist in postoperative observation. Could the cartilage and its mucosa be better utilized in reconstruction either as a free composite graft or a pedicle graft?

I reported a case of a free composite tracheal graft for primary reconstruction of the cervical esophagus to the American Society for Head and Neck Surgery in 1963,[15] (Fig. 11). Despite justifiable criticism of the use of this previously irradiated tissue, the graft took per primum. This led to the suggestion of the grafts of tracheal rings with their mucous membrane into the laryngeal area and closure of the donor area by direct anastomosis. Such cartilage grafts could be crimped to simulate vocal cords, or at least create appropriate narrowing of the glottic chink. Again, this is more feasible for partial laryngectomy, however, such combined composite and free cartilage implants

for reconstruction of the larynx are not beyond the imagination.

In the future, we will make greater use of skin flaps[4,7,40] for reconstruction of the cervical esophagus with the larynx intact.

The immediate use of dermal grafts into the laryngeal defect has several possibilities. If mucous membrane covering can be provided, the dermal graft could be used to fill out the cord area. If there is no mucous membrane, perhaps the thicker dermal graft[39,41] would, with epithelialization, provide both lining and body. In the cervical area, dermal grafts have been used primarily to fill out contour and protect major arteries.

Vein grafts have been used for lining in lesser defects, as for papillomata,[44] but perhaps this use could be expanded, especially with a larger graft, as from the internal jugular.

Despite sucessful use elsewhere, free mucous membrane grafts from a source outside the larynx, such as the buccal mucosa, have not been used to my knowledge, in the larynx.

A three-dimensional (two surface) Z-plasty may be useful in anterior webs or cicatricial bands in the larynx. For the anterior web, it is entirely possible to separate the two surfaces of the web, basing the flaps on opposite sides and suturing the flaps in position on opposite sides, the superior flap being swung downward and the inferior flap upward. Splinting then may or may not be necessary.

For anterior contractures and webs, modified splints, including wedges of synthetic sheets holding the cords slightly apart, but allowing an adequate airway, may be designed with ease. With newer plastic materials creating minimal tissue reaction and the inventive sculpturing of the surgeon, the possibility for new and more satisfactory splints is almost unlimited both for the larynx and pharynx. We have yet to see the final design for full lumen contoured laryngeal splints. Such splints could be made of thin walled sheeting of any desired consistency and contoured precisely. These warrant further development and provide an area of cooperation with industry.

CONCLUSION

The modern laryngologist must *THINK* reconstruction.

The broad application of the principles of reconstructive surgery to the field of laryngology should be apparent. We are applying not only the principles, the techniques, or the disciplines of reconstruction, but, if you will allow, the philosophy of reconstructive surgery, the philosophy of primary reconstruction initiating rehabilitation at the time of the extirpative surgery for cancer, the philosophy of preservation of function where possible, the philosophy of management of the whole patient, etc.

The disciplines and techniques of "plastic surgery" must incorporate skin grafting, repair of soft tissue injuries, the use of implant materials, and the considerations of organ transplantation.

With this approach the traditional specialty lines, as we have known them, must be crossed. Disciplines from all of medicine must be included and cooperation between specialties must be fostered, if we are to attain progress in patient rehabilitation.

The established laryngologist in the major institutions with available research facilities must embrace these concepts. The rising laryngologist, I hope, is, or can be, motivated to use his youthful imagination and ingenuity to press towards refinement and better restoration of voice quality, total laryngeal reconstruction, and the abandonment of the need to exteriorize either the larynx or pharynx.

Refinements and attention to detail are the bywords for future developments. The area of nerve function, the problems of initiating swallowing, the prevention of aspiration, and, at the same time, the maintaining of the normal airway, requires both clinical and laboratory study. It is, I think, entirely feasible, by one method or another, that

one day the patient with total laryngectomy will be able to breathe, speak and eat through the reconstructed food and air passages without obstruction or aspiration of secretions.

The bright young man with a thorough background in reconstructive procedures and laryngeal physiology will provide many accomplishments, to keep us all actively interested and proud of our specialty.

In the light of these concepts, and recent and future innovations, the future looks bright.

TAMPA GENERAL HOSPITAL, TAMPA, FLORIDA 33606

REFERENCES

1. Arnold GE: Alleviation of aphonia or dysphonia through intrachordal injection of teflon paste. Ann Otol 72: 384, 1963

2. Asai R: Laryngoplasty for phonation. Monogram, 1960

3. Bailey BJ: Partial laryngectomy and laryngoplasty: A technique and review. Trans AAOO 70: 559-574, 1966

4. Bakamjian Y: A two stage method for pharyngoesophageal reconstruction with primary pectoral skin flap. Plast Reconstr Surg 36: 173-184, 1965

5. Baker D: Chronic laryngeal stenosis. Trans Amer Laryng Assoc 90: 60-67, 1969

6. Conley J: One stage radical resection of cervical esophagus, larynx and pharynx with immediate reconstruction. Arch Otolaryng 58: 645, 1953

7. Conley J: The use of regional flaps in head and neck surgery. Ann Otol 69: 1223-1234, 1960

8. Conley J: Glottic reconstruction and wound rehabilitation procedures in partial laryngectomy. Arch Otolaryng 74: 239-42, 1961

9. Converse JM: Transplantation. Trans AAOO 71: 391-397, 1967

10. Dedo H, Sooy F: Surgical repair of late glottic stenosis. Trans Amer Laryng Assoc 80: 107-113, 1968

11. Delahunty J, Alonso WA, Bordley JE: Cricoid arch transplantation. Laryngoscope 80: 137-144, 1970

12. Doyle PJ, Brummet RE, Everts EC: Results of surgical section and repair of the recurrent laryngeal nerve. Trans Amer Laryng Rhinol Otol Soc 742-754, 1967

13. Edgerton MT, Zovickian A: Reconstruction of the trachea and infraglottic larynx. Plast Reconstr Surg 13: 167-193, 1954

14. Farrior RT: Cancer of the head and neck; primary and reconstructive surgery. Arch Otolaryng 71: 891-905, 1960

15. Farrior RT: Primary reconstruction of cervical esophagus. Arch Otolaryng 79: 258-268, 1964

16. Farrior RT: Synthetics in head and neck surgery with particular reference to silicone. Seventh Annual Meet Amer Soc Head Neck Surg 1965, New York

17. Farrior RT: Rehabilitation by skin grafting. Arch Otolaryng 83: 120-134, 1966

18. Fitz-Hugh GS, Wallenborn W, McGovern F: Injuries of the larynx and cervical trachea. Ann Otol 71: 419, 1962

19. Holinger PH, Johnston KC: The management of chronic laryngeal stenosis. Ann Otol 67: 496, 1958

20. Iglauer S: New procedure for treatment of web in the larynx. Arch Otolaryng 22: 597, 1945

21. Jurikiewicz MJ: Vascularized intestinal graft for reconstruction of the cervical esophagus and pharynx. Plast Reconstr Surg 36: 509-517, 1965

22. Kitamura T, et al: Supracricoid laryngectomy, a new technique for vocal rehabilitation. Laryngoscope 80: 300-308, 1970

23. Kluyskens P: First larynx transplant patient is in good voice. Med World News pr. 25, August, 1969

24. Looper EA: Use of the hyoid bone as a graft in laryngeal stenosis. Arch Otolaryng 28: 106-111, 1938

25. Lore JM, Jr: Vascular surgery of head and neck. Trans Amer Otol Rhino Laryng Soc 631-634, 1965

26. Lynch MC, LeJeune RE: Laryngeal stenosis. Laryngoscope 70: 315-317, 1960

27. Miglets AW, Jr: A combined autogenous and marlex tracheal graft. Arch Otolaryng 87: 68-74, 1968

28. Miller A: Asai technique. Ann Otol 76: 829, 1967

29. Miller A: Further experiences with the Asai technique of vocal rehabilitation after laryngectomy. Trans AAOO 72: 779-781, 1968

30. Montgomery WM: Reconstruction of cervical trachea. Ann Otol 73: 1-15, 1964

31. Mullison EG: Silicones and their uses in plastic surgery. Arch Otolaryng 81: 264, 1965

32. Negus V: Reconstruction of pharynx after pharyngo-esophago-laryngectomy. Brit J Plast Surg 6: 99-101, 1953

33. Ogura J: Glottic reconstruction following extended frontolateral hemilaryngectomy. Laryngoscope 79: 2181-2184, 1969

34. Ogura J, Dedo HH: Glottic reconstruction following subtotal glottic-supraglottic laryngectomy. Laryngoscope 75: 865-878, 1965

35. Ogura J, Powers WE: Functional restitution of traumatic stenosis of larynx and pharynx. Laryngoscope 74: 1081, 1964

36. Ogura J, Roper C, Burford T: Functional restoration of the food passages in extensive stenosing caustic burns of the pharynx and esophagus. Laryngoscope 71: 885-902, 1961

37. Ogura J, Shumrick D, Lapidot A: Some observation on experimental laryngeal substitution in laryngectomized dogs. Trans Amer Laryng Assoc 83: 77-95, 1962

38. Quinn H, Jr: A new technique for glottic reconstruction after partial laryngectomy. Laryngoscope 79: 1980-2011, 1969

39. Reed GF, et al: Self-epithelization of dermal grafts. Arch Otolaryng 87: 92-95, 1968

40. Shumrick DA: Closure of large surgical defects in head and neck surgery. AAOO Instruction Course, Chicago, 1968

41. Sisson G, Markovich JJ: Intraoral resurfacing with dermal graft. Arch Otolaryng 87: 89-91, 1968

42. Sisson G, Straehley C, Johnson N: Mediastinal dissection for recurrent cancer after laryngectomy. Trans Amer Otol Rhinol Laryngol Soc 428-441, 1962

43. Som M: Laryngoesophagectomy. Arch Otolaryng 63: 474-479, 1956

44. Tabb H, Kirk R: Vein grafts in the management of laryngeal papillomas. Trans Amer Otol Rhinol Laryng Soc 419-427, 1962

45. Walter C: Reconstruction procedures on the auricle. Trans AAOO 73: 266-73 1969

46. Zovickian A: Pharyngeal fistulas: repair and prevention using mastoid-occiput based shoulder flaps. Plast Reconstr Surg 19: 355-373, 1957

LARYNGEAL EDEMA
AN EXPERIMENTAL STUDY

HUGH F. BILLER, M.D. ROBERT C. BONE, M.D.
JOSEPH E. HARVEY, PH.D. JOSEPH H. OGURA, M.D.
ST. LOUIS, MO.

The clinical and histopathologic sequelae involving the larynx, which may occur following endotracheal intubation, have been well documented.[1,5]

Clinically, steroids appear to hasten resolution of posttraumatic laryngeal edema, but adequate experimental and controlled clinical studies supporting this impression are lacking.[2] Way and Sooy[6] showed, in monkeys, that intubation with an excessively large tube, produced significant histologic changes. They found that a single intramuscular dose of steroids had no effect, histologically, on edema formation.

The purpose of this study is twofold: 1) to establish an experimental method of quantitating traumatic laryngeal edema, and 2) to evaluate the effect of steroids in the prevention and treatment of traumatic laryngeal edema.

MATERIALS AND METHODS

Young squirrel monkeys, weighing 0.6 to 0.7 kg, were anesthetized with intramuscular pentobarbital (Diabutal®) and intrapleural diazepam (Valium®), 30 mgs/kg and 1.5 mg/kg, respectively. The cervical trachea was exposed and a #18 polyethylene catheter inserted into the subglottic area. The position of the catheter was verified by direct laryngoscopy. The catheter was connected to a Statham P 23 AC pressure transducer. Potentials were led through a Model 7 Grass polygraph. Measurements of the subglottic respiratory pressure excursion, in cm of water, were recorded on a pen oscillograph. The pressure transducer was standardized before each series of experiments with an aneroid sphygmomanometer, at 100 mm mercury.

Following a 15 minute baseline recording of the subglottic pressure, the monkey was intubated with graduated polyethylene tubes. The tube which barely met resistance was chosen in the first experiment, and in the second experiment, a tube one size larger was chosen.

After two hours of intubation the endotracheal tube was removed and the subglottic pressure recorded every 15 minutes. Two different experiments were conducted:

1. Six monkeys were given 4 mgs dexamethasone phosphate (Decadron®) intravenously at the time of extubation. Six control monkeys received no steroids. Subglottic pressure was recorded every 15 minutes for four hours postextubation.

2. Seven monkeys received 4 mg dexamethasone one hour following extubation, which was the time of maximum subglottic pressure excursion. Six control monkeys received saline intravenously one hour following extubation. Subglottic pressure was recorded every 15 minutes for four hours postextubation.

Laryngoscopy was performed at hourly intervals to check catheter position, to suction secretions and to evaluate the degree of edema.

Two monkey larynges were removed from Experiment 2 for histologic section at two hours postextubation, one from the control group and one from the steroid group.

RESULTS

All monkeys developed maximum increase in subglottic pressure within one hour following extubation.

The monkeys receiving steroids at the time of extubation showed a smaller increase in subglottic pressure excursion compared to the control group (Fig. 1). The difference at one and two hours

From the Department of Otolaryngology, Washington University School of Medicine, St. Louis, Mo.
Supported by NIH Training Grant 5 T01 NS 5190 and NS 06200.

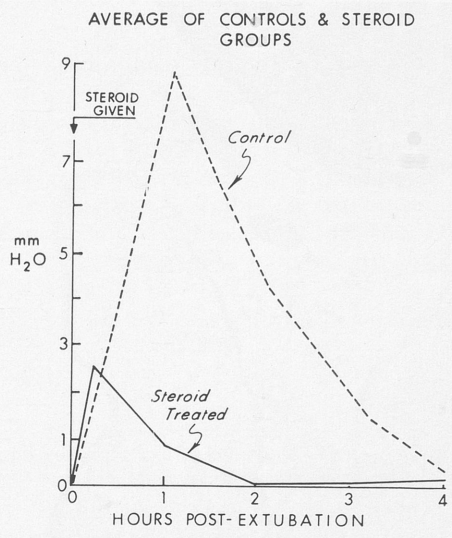

Fig. 1.—Steroids given at the time of extubation produced a smaller increase in subglottic pressure excursion than in the control group.

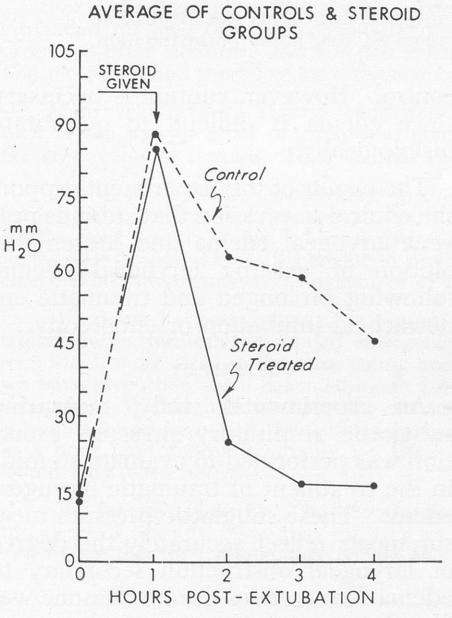

Fig. 2.—Steroids given at the maximum subglottic pressure excursion produced a rapid decrease in subglottic pressure.

postextubation is significant between these two groups ($P = < 0.05$).

The monkeys receiving steroids at the maximum increase in subglottic pressure, one hour postextubation, showed a more rapid decline in subglottic pressure compared to the control group (Fig. 2). The differences from one hour to two hours, one hour to three hours, and one hour to four hours, between the two groups is significant ($P = < 0.005$, < 0.005, < 0.025, respectively).

Visual examination of the larynges correlated well with subglottic pressure determination as to the degree of edema. At maximum subglottic pressures, the supraglottis, glottis and subglottis were grossly edematous. The resolution of the edema in the steroid group paralleled the decrease in subglottic pressure.

Histologic sections of the vocal fold at two hours postextubation indicated less tissue mass in the steroid treated monkey than in the control (Figs. 3 and 4).

MODE OF ACTION OF STEROIDS

The anti-inflammatory effect of steroids is thought to occur by inhibiting local cellular damage, thereby interrupting the chain reaction of cellular destruction and edema formation.[4] That steroids also have an effect in diminishing capillary dilatation and permeability has also been documented.[3] In mice, cortisol exhibits an affinity for inflamed tissue and concentrations at the inflamed site are present ten minutes after intravenous injection. Steroid concentrations at the injured tissue 40 minutes after intravenous injection, equal the immediate postinfusion serum level.

The half-life of hydrocortisone in human blood is 70 minutes. Inflammation has been shown to be suppressed for longer periods of time than the hormone is present in the blood. It is likely, therefore, that the hormone alters local cells which are then capable of resisting continuing inflammation.

DISCUSSION

The measurement of change in sub-

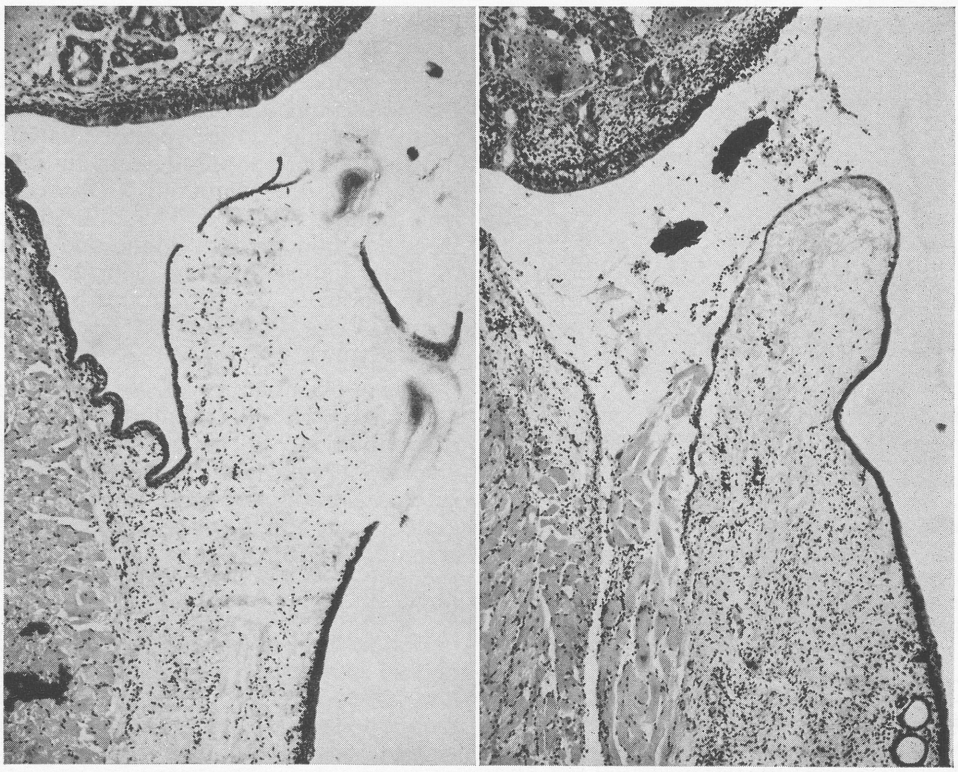

Fig. 3.—Section of vocal fold of control monkey, two hours postextubation.
Fig. 4.—Section of vocal fold of steroid monkey, two hours postextubation.

glottic pressure excursion accurately reflects the degree of laryngeal obstruction secondary to edema. That the obstruction was secondary to edema was demonstrated by direct visualization. The occurrence of edema was rapid, all monkeys exhibiting maximum laryngeal obstruction within one hour following extubation.

Steroids administered immediately following extubation prevented significant laryngeal obstruction. Steroids administered when laryngeal obstruction was greatest, one hour following extubation, produced rapid resolution of the obstructing edema. The time interval from steroid injection to measurable decrease in subglottic pressure varied from 15 to 60 minutes.

The histologic sections appear to indicate that laryngeal edema was less in the steroid treated larynx than in the control. However, caution is necessary since edema is difficult to quantitate histologically.

The results of this experiment support the clinical impression that steroids prevent laryngeal edema and hasten resolution of existing laryngeal edema, following prolonged and traumatic endotracheal intubation or endoscopy.

SUMMARY

An experimental study, measuring subglottic respiratory pressure excursion was performed to evaluate steroids in the treatment of traumatic laryngeal edema. These subglottic pressure measurements reflect accurately the degree of laryngeal obstruction secondary to edema. Intravenous dexamethasone was found to prevent traumatic laryngeal edema and to hasten resolution of existing traumatic laryngeal edema.

517 South Euclid, St. Louis, Missouri 63110

REFERENCES

1. Baron SH, Kahlmoos HW: Laryngeal sequelae of endotracheal anesthesia. Ann Otol 60: 767-792, 1951

2. Deming MV, Oech SR: Steroid and antihistaminic therapy for post intubation subglottic edema in infants and children. Anesthesiology 22: 933-936, 1961

3. Dougherty TF: The mechanism of action of adrenocortical hormones in allergy. Progr. Allergy 4. Basel-New York, S. Karger, 1954, pp 319-360

4. Dougherty TF, Brown HE, Berliner DC: Metabolism of hydrocortisone during inflammation. Endocrinology 62: 455-462, 1958

5. Lu AT, Tamura Y, Koobs DH: The pathology of laryngotracheal complication. Arch Otolaryng 74: 323-332, 1961

6. Way WL, Sooy FA: Histologic changes produced by endotracheal intubation. Ann Otol 74: 799-813, 1965

DISCUSSION

Douglas P. Bryce, M.D.: This experiment does indeed support our clinical impressions and certainly in the acute phase in our Respiratory Unit the use of steroids has been dramatic in the relief of very severe stridor resulting from this type of edema.

It was a few years ago that the use by the anesthetists of the very large endotracheal tubes got us into trouble, with immediate subglottic edema, sometimes requiring tracheotomy, and subsequent to the tracheotomy very often the edema would subside and things would return to normal.

I think by the use of steroids at the present time we have avoided the necessity for immediate tracheotomy in almost all cases.

Charles F. Ferguson, M.D.: This is the type of work which we have been expecting and profiting by for a long time from Dr. Ogura's clinic. This is a study which we have actually been waiting for, in order to give some scientific basis for clinical impressions from our experiences in the use of steroids.

For some time, of course, we have been using steroids in the operating room following intubation for long operative procedures on tiny infants, especially premature infants. Here surgery is often necessary and is much more safely carried out under endotracheal intubation. The morbidity and mortality have thereby been greatly reduced.

Many years ago we started using steroids in the acute infectious diseases of the larynx, such as the various types of croup and epiglottis, and I have been extremely impressed with the great value of steroids. Their use has cut down our morbidity and mortality tremendously.

One of my associates is working up our cases of acute respiratory obstruction due to infection. The incidence of tracheotomy in the last few years since we have been using steroids on the very severe croups who otherwise might need tracheotomy has been reduced from somewhere around 11 or 12 percent to practically zero. (I think it is now less than one percent). The only change in management of these cases has been the use of steroids.

When we have an infant or a young child come in with an acute epiglottic infection, which always formerly demanded emergency tracheotomy, or with subglottic edema which is seen much more often in the very young and the operating room is all set up and ready to go, we have given him some dexamethasone (one milligram per ten pounds of body weight intravenously). Within half an hour the retraction usually subsides and the clinical appearance is tremendously improved. Sometimes a second dose is necessary within a half to three-quarters of a hour, and almost invariably we have avoided tracheotomy, which I am sure otherwise would have been necessary.

Dr. Biller (closing): The stimulus for this project was the pediatricians, who doubted the effect of steroids. Now that we have an experimental model it appears we could go ahead and utilize this for inflammatory edema as well as traumatic edema.

LARYNGOTRACHEAL TRAUMA IN COMBAT CASUALTIES

LEE H. MILLER, LT. COL., MC

SAN FRANCISCO, CALIF.

During the past two years we have had the opportunity to evaluate and treat over 35 cases of trauma to the larynx and trachea at a general hospital in Japan. All of these patients had received some initial treatment in the Republic of Viet Nam by either otolaryngologists or general surgeons. Follow-up is now available on over one-half of these patients.

Papers on this subject have become more frequent in the medical literature in recent years as traffic accidents take their ever increasing toll. If the unfortunate sequelae of laryngeal or tracheal stenosis with permanent tracheostomy and a poor or non-existent voice are to be avoided, then prompt and judicious treatment of this injury by specialists is mandatory.[1,2,3,6,13,14]

In the present conflict, trained otolaryngologists have generally been assigned to the evacuation hospitals in Viet Nam and primary specialized care has been achieved in the majority of cases. Lederer and Howard[10] stated that " . . . wartime laryngeal injuries not only produce some bizarre pictures but reflect in some instances poor surgical judgment and ignorance of the management of laryngeal traumas and their complications." Several cases in this series were treated by non-specialists and the above observation is as applicable today as 25 years ago.[9]

Penetrating wounds of the neck are not only the domain of the military surgeon. Fogelman and Stewart[7] reported 100 cases in 1956 with ten tracheal and laryngeal wounds. Two of these patients died from complications from failure to recognize the extent of the injury to the airway.

Curtin et al.[4] have aptly stated that injuries to the larynx require adherence to the basic principles of all trauma surgery, namely, restore the parts to as nearly normal position as possible and splint them in the position of function. Structures should be preserved as much as possible. Minimal debridement of only grossly non-viable tissue is performed. If there is any chance of survival of the tissue, especially cartilage, it should be saved.[11]

In civilian type injury the traumatic agent is most often blunt as in the case of the wheel or dashboard. The natural flexibility of the laryngeal structures helps in its protection. In this series all the wounds were inflicted by high or medium velocity missiles, either fragments of metal in 25 of the cases or bullets in the remaining ten.

The resilient suspension of the larynx is a result of the relations between the cartilaginous structures themselves and the adjacent muscle groups. The inferior cornu of the thyroid cartilage articulates with the cricoid which is its only direct articulation. Its relationships with other structures are all maintained by muscles and ligaments. Severe blunt trauma will result in compression of these structures against the cervical spine with fracture of the larynx and soft tissue disruption.[12]

High velocity missiles will cause varying degrees of trauma, from very minimal pathology such as a mucosal tear visible on laryngoscopy, to severe destruction. One gunshot wound took seven cm of cervical trachea and a portion of the anterior cricoid. The patient survived this insult but later succumbed following attempted reconstruction of

this defect. The degree of trauma to the larynx and trachea varies directly with the size of the missile and its velocity at the time of impact. In another case a large, irregular fragment lodged in the anterior larynx causing extensive soft tissue and cartilaginous disruption.

Symptoms and signs of trauma to the upper airway are variable. The most frequent symptoms are dyspnea, dysphonia, ranging from mild hoarseness to aphonia, and hemoptysis. There may be dysphagia, and stridor may be present in severe injuries. A gunshot wound will be evident, but a small fragment may have penetrated with little external evidence. Subcutaneous emphysema is frequently present and gross fractures of the larynx may be palpable.

Indirect examination of the larynx should be performed if this is feasible. A good appreciation of the degree of trauma can be obtained and cord mobility can be ascertained. Radiographic examination is very useful and even plain films may be quite demonstrative. Tomographic studies give a good deal of information showing the laryngotracheal air shadow, the false and true cords and laryngeal ventricles and the subglottic area. This particular case showed edema of the left false cord and also showed the pyriform sinuses well when the modified Valsalva maneuver was performed. Contrast studies give added detail but are not as well tolerated by the wounded patient. Direct examination is most often indicated and always precedes an open exploration.

The aim of treatment is to restore and maintain an adequate airway and provide a functionally acceptable voice. Also, the larynx should close satisfactorily to prevent aspiration of food or fluids during deglutition.[8] It is distressing indeed to receive a patient with a statement such as this on a transfer summary: "Both vocal cords were destroyed and the larynx was closed in layers. The patient was advised of the need of a permanent tracheostomy." This particular patient had a repairable injury and ultimately returned to duty with a good voice and airway.

In the case of minor hematomas or lacerations with minimal compromise of the airway, the patient should be treated conservatively with close observation, humidification, broad spectrum antibiotics and facilities for a tracheotomy on hand. Thirty of 35 patients in this series required a tracheotomy. If cartilaginous fractures are palpable and laryngoscopy reveals extensive mucosal lacerations, the larynx must be explored if the complex problems of chronic stenosis are to be avoided. If there is uncertainty about the exact nature of the injury, it is probably wiser to explore. Mucosal lacerations are approximated with fine chromic catgut, the endolarynx having been exposed through the wound itself or through a thyrotomy. If the cartilaginous skeleton is fractured and unstable or if there are circumferential lacerations, a stent must be placed in order to maintain the support for an adequate airway. Various materials are available for this and we have been using one that is readily available and which has yielded satisfactory results.[5] It consists of a finger cot containing modeled foam rubber to give a triangular cross section simliar to that of the glottic chink. This is inserted into the laryngeal inlet and brought down into the subglottic area. It is free superiorly in the hypopharynx presenting below the tip of the epiglottis. It is secured into position using #24-gauge stainless steel wire which is passed through an 18-gauge spinal needle above and below the level of the cords and brought out laterally over booties. If loss of mucosa is extensive, a split thickness skin graft from the thigh can be placed around the stent. Fractured segments of thyroid cartilage are approximated and sutured with fine wire. Occasionally a defect will be present but adjacent soft tissue can be brought over this area and healing will occur. More anatomic acrylic and sialastic stents are available commercially. These stents should be left in place for six to eight weeks. The use of tubes with a circular cross section is not good. If these tubes are not occluded, the patient will aspirate through them. Also,

an anterior web will most probably develop.

RESULTS

Nineteen of the 35 patients reviewed required exploration of the larynx. In 16 of these a stent was deemed necessary. Of the 18 cases for which follow-up is available, all but one were able to shed their tracheotomy tubes and all spoke with varying levels of proficiency. The degree of residual hoarseness varied directly with the extent of the initial trauma. The case in which stenosis ensued had a significant subglottic injury which was not appreciated by the initial examiner. No exploration was performed. A stent was placed three weeks after the initial injury when the patient arrived in Japan. At last report the young man was to undergo further repair of the subglottic stenosis. Two patients have required treatment of an anterior web with a keel procedure. One received a Teflon® injection to give bulk to a paralyzed and retracted cord. The severe avulsive injury to the cervical trachea was treated by freeing up the thoracic trachea and establishing an end-to-end anastomosis with the cricoid remnant. However, five days postoperatively the patient exsanguinated from erosion of the innominate artery.

SUMMARY

The experience of two years of observation and active treatment of combat incurred wounds to the larynx and trachea is reviewed. Early recognition of the extent of trauma is extremely important. Treatment may be conservative with close observation and supportive measures or through surgical exploration with repair of laryngeal structures and appropriate stenting as indicated. In this manner, the unfortunate sequelae of chronic stenosis of the larynx and trachea can be avoided and rehabilitation of the voice and airway can, to a certain degree, be achieved.

Box 5931, 249th General Hospital, APO San Francisco 96267

REFERENCES

1. Bennett T: Laryngeal trauma. Laryngoscope 70: 973-982, 1960

2. Bryce DP: Traumatic laryngotracheal injury. Canad Med J 75: 400-405, 1956

3. Burton J, Anderson H: Injuries of the larynx and trachea. South Surg 15: 579-583, 1949

4. Curtin JW, Holinger PH, Greely PW: Blunt trauma to the larynx and upper trachea. J Trauma 6: 493-502, 1966

5. Downey WL, Owen RC, Ward PH: Traumatic laryngeal injury - its management and sequelae. South Med J 60: 756-761, 1967

6. Fitz-Hugh GS, Wallenborn W, McGovern F: Injuries of the larynx and cervical trachea. Ann Otol 71: 419-442, 1962

7. Fogelman MJ, Stewart RD: Penetrating wounds of the neck. Amer J Surg 91: 581-596, 1956

8. Holinger PH, Johnston KC: Laryngeal trauma and its complications. Amer J Surg 97: 513-517, 1959

9. Knight JS: Injuries to the trachea and esophagus incurred in combat. Ann Otol 55: 656-666, 1946

10. Lederer FL, Howard JC: Wartime laryngeal injuries. Arch Otolaryng 43: 331-343, 1946

11. Lynch M: Repair of the traumatized larynx. Laryngoscope 61: 51-65, 1951

12. Pennington CL: Glottic and supraglottic laryngeal injury and stenosis from external trauma. Laryngoscope 74: 317-345, 1964

13. Priest RE, Huff J, Banovetz J: Laryngotracheal injuries. Ann Otol 76: 786-791, 1967

14. Shumrick DA: Trauma of the larynx. Arch Otolaryng 86: 691-696, 1967

DISCUSSION

Douglas P. Bryce, M.D.: I think that a record of 19, I believe it was, cases of severe injury, 19 who had to be operated on and 16 who have had stents inserted, and all of these with an adequate airway and a good voice, or a husky voice, is a remarkably good record and I think it is to be commended.

I am sure that this also demonstrates very much the importance of getting the injured larynx and looking after it immediately. Presumably the trouble that the rest of us have with similar cases (and I am sure our results are not as good as this) is due to the fact that we very often get them late.

I was going to ask Dr. Miller: we fortunately in Canada do not have at the present time any military injuries to deal with except those associated with hockey. Injury to the larynx by hockey sticks is quite a common problem. I have been impressed in two or three recent cases with a common picture which perhaps he has seen and might comment on. Injury to the larynx is received on one thyroid ala and on viewing the larynx there is obvious tear of the cord or supraglottis at the junction of the vocal process of the arytenoid and the cord and granulations form at this point. There are degrees of fixation or paralysis of the vocal cords resulting from this injury and also in the severity of the fracture of the ala. However, in the cases in question the ala itself is not demonstrably fractured and yet there is a tear in the vocal cord anterior to the vocal process. In one of these cases there was paralysis or fixation of the cord and in the other there was not. This is a relatively common picture and I would like to ask Colonel Miller if he has any comment on this finding.

FRANCIS L. LEDERER, M.D.: I believe in this day and age of transport, that the results of laryngeal injury which we have witnessed here should be different. Of course, the prophylaxis against this present traumatic disease is the abolition of these wars. But there are things other than shrapnel that play a role in laryngeal problems.

There are the burns. Before this very Society many years ago, following World War I, Lafayette Page presented a paper on the importance of gases of one type or another. I know that they are now supposed to be tabu but they sneak in once in a while in wartime pictures, aboard ship fires, accidental rupture of containers, and so on, so these too constitute a wartime injury.

With the rapid transport as presently operational, you can get somebody to a medical base, with apologies to Dr. Miller who is present, more quickly than you can get them off the freeway in Los Angeles when there is an automobile accident. The initial difficulty is the treatment of the casualties immediately at the scene. These consist of high tracheotomies, improper poor care at that area, but certainly beyond that you have Colonel Miller, our essayist, waiting for you. You have many certified otolaryngologists on hand, but unfortunately there are a number of inexperienced people who are all thumbs who just mess up the thing and this is what in further care of the larynx seems to lead to difficulty.

I want to speak on the type of larynx that defies reconstruction. I know that Dr. Ogura and others of you will never quit, but we saw a casualty in Miller's series, a young man who died while undergoing a procedure where reconstruction was attempted. There are times when you have to submit patients to laryngectomy. I have seen fragments of the larynx so distorted and larynges so destroyed that the better part of valor would have been not to try to reconstruct what isn't there; also those with pharyngeal stomas, patients who had gastrostomies, fed by this route for nine months. I am not always sure at stations in Japan or elsewhere that they can make a new larynx at these bases. If one wishes to eliminate reports about wartime laryngeal injuries it seems that until we come to our senses and stop these wars we will still have the need to talk about it.

HERBERT HARRIS, M.D.: I would like to ask one question: At what time did he see most of these for primary repair?

Most of you will note that the supraglottic injuries became infected and they were the only ones that became infected and I think the time element is a great thing. If you could get these within a few hours, the better. Twenty-four hours on the two or three cases that became infected ended up disastrously.

Recently I discharged a cheer leader with a rather severe supraglottic injury. Forty hours after the injury I saw her and within one hour I had her on the operating table. She was discharged with an adequate airway after three weeks of stenting and split thickness skin graft but with aspiration. I am hoping the aspiration will clear up. The larynx looked very good. It is surprising what six hours of hard work will do.

RICHARD T. FARRIOR, M.D.: There are several little thoughts, some technical hints and one or two questions:

The first question, which I direct to the audience as well as to Dr. Miller, is the availability in anyone's mind of a truly satisfactory contoured full lumen stent. I believe this is very much needed. Most of the contoured stents are solid. I know Dr. Fitz-Hugh, when I talked to him last about this, was using the lumened stent but it was, again, round, it wasn't really accurately contoured. I think this needs to be worked on and I am sure it will be perfected. I think we should think in terms of some of the newer synthetic materials.

Accurate closure of severe lacerations must be done in layers. He mentioned stabilization and it is the same as in a maxillofacial surgery. You start by doing a soft tissue repair or working yourself out in layers and I would like to mention direct stabilization and cartilagenous stabilization, again perhaps with some of the newer synthetic materials that will hold longer and I think would prevent probably some of the postoperative distortions.

Secondly, I would like to ask, correlating with Dr. Biller's paper, whether or not he uses steroids. If he mentioned it, I didn't pick this up.

The larynx is kind of peculiar and I would like to have a follow-up perhaps with Dr. Biller's studies, too, about doing two things: it creates hyperplastic tissue, as you all know, with a great deal of granulations sometimes, and on the other hand it produces a tremendous amount of cicatrization scar tissue and stenosis—not necessarily are the two related.

WILLIAM W. MONTGOMERY, M.D.: I just couldn't resist asking Dr. Farrior this question. He has mentioned twice this morning that he would like a hollow contoured laryngeal stent. We have a soft silicone conforming laryngeal stent and I wonder why he would like this to be hollowed. If it were hollowed, the patient would aspirate and there would be no voice, so why not just leave the tracheotomy in place without a stent?

LT. COL. MILLER (closing): In response to Dr. Bryce's question about the tear in the mucosa in the arytenoid area and subsequent paralysis, I have seen several cases of paralysis from smaller fragmentation wounds and I certainly would wait up to a year before considering that the nerve had been lacerated and was completely non-viable before deciding to do anything about that. I have had reports from the stateside hospitals to which these patients have been evacuated that many of the cases of paralysis subsequent to fragment wounds have recovered after six to twelve months.

We have the advantage of seeing patients who are rapidly evacuated and above all patients who are young and in the prime of life.

As to the time of primary repair, 16 of these patients out of 19 required stents and I treated ten of these in Japan. Six of these were done initially in Viet Nam. The evacuation schedule runs about like this: I receive patients anywhere from two to seven days after the initial injury, so this is a delayed type of repair that I am doing. Six of the cases, which will be further delineated in the paper, were seen initially and treated within the first 24 hours.

I haven't had any experience with ice hockey players but I did have the opportunity to see a Japanese SUMO wrestler, who is an American citizen, and there is one Hawaiian who wrestles in Japan, with a hoarse voice. After I saw him and consulted with a Japanese otolaryngologist, he assured me that one of the blows in SUMO wrestling is to the anterior neck and that all SUMO wrestlers spoke with the same hoarse voice.

POLYCHONDRITIS IN A NEWBORN PRESENTING AS TRACHEOMALACIA

CARL H. JOHNER, M.D.

PAUL A. SZANTO, M.D.

CHICAGO, ILL.

Tracheomalacia continues to be a difficult problem. The clinical picture is well known. However, definitive pathology in this entity has been lacking. The purpose of this report is to describe a case which presented as tracheomalacia. A sound, color motion picture was obtained for teaching purposes and at autopsy pathology of the tracheobronchial tree was obtained.

REPORT OF CASE

This infant was a full term birth of an uncomplicated pregnancy, weighing nine pounds, six ounces. The mother was not a diabetic and there were two other siblings, ages one and two, who were in good health. Breathing was spontaneous at birth but "respiratory distress" was described. Bilateral club feet were noted, but otherwise the infant appeared normal. On the first day of birth "severe respiratory distress" was described and the infant was "resuscitated with oxygen by mask." Ampicillin and kanamycin were started. Serum electrolytes, urea nitrogen, carbon dioxide, chest x-ray and barium swallow were normal. The infant continued to require periodic oxygen by tent and mask and circumoral cyanosis with feeding was described. Cardiology consultation revealed no cardiac abnormality. On the fourth day of life the liver was noted to be enlarged four cm below the right costal margin. On the seventeenth day of life consultation was requested from the Department of Otolaryngology, and the clinical impression was that of tracheomalacia. There was a normal but weak cry. Moderate sternal, substernal and intercostal retraction was noted. Direct laryngoscopy at this time revealed a normal larynx. The infant continued to have intermittent distress requiring occasional oxygen by incubator, but maintained his weight. Cultures of the throat grew out normal flora. On the forty-sixth day of life, direct laryngoscopy was again performed and revealed a normal larynx. Bronchoscopy revealed collapse of the trachea and bronchi on inspiration but an otherwise normal tracheobronchial tree. Tracheotomy was performed with slight improvement. Twelve hours posttracheotomy insertion of a longer Portex tracheotomy tube, which reached the level of the carina, resulted in some improvement in breathing. Despite the tracheotomy and close supervision, the infant continued to deteriorate with respiratory arrests and convulsions. Repeat laryngoscopy and bronchoscopy on the seventy-fourth day of life revealed a patent tracheobronchial tree with a collapse on inspiration as previously noted. The infant died on the seventy-eighth day of life. Autopsy was performed shortly after death and the entire tracheobronchial tree was examined.

Numerous sections were taken of the trachea and of the bronchi distal to the bifurcation of the trachea. In addition to the cartilaginous changes, sections

---

From the Department of Otolaryngology and Maxillofacial Surgery, Northwestern University Medical School, and the Department of Pathology, Cook County Hospital, Chicago, Illinois.

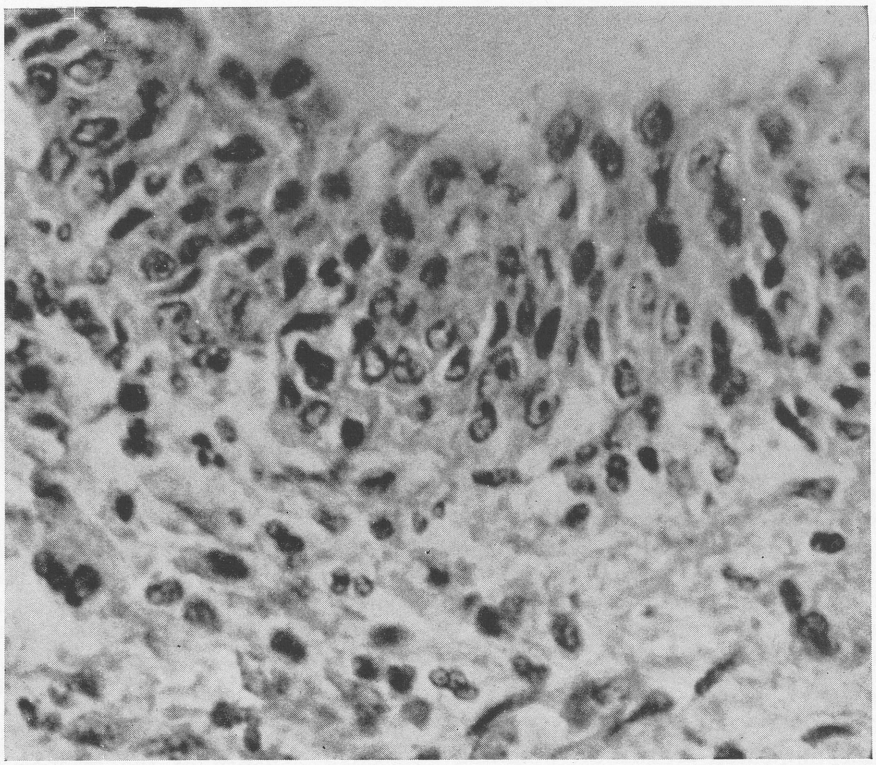

Fig. 1.—Section of trachea showing pseudostratification of the respiratory epithelium with inflammatory cells.

from the trachea revealed the following picture: 1) focal areas of pseudostratification of the respiratory epithelium; 2) foci of squamous metaplasia; 3) heavy infiltration of the tracheal wall by inflammatory cells, namely, lymphocytes, plasma cells and histiocytes with focal accumulations of eosinophilic leukocytes predominating the picture.

The most important finding, however, was the change in the cartilaginous tissue. Some of the cartilages showed empty lacunae, i.e., absence of nuclei in the lacunae as evidence of necrosis of the cartilaginous tissue. These cartilages were surrounded by heavy inflammatory exudate which invaded the periphery of the dead, necrotic, cartilaginous tissue. Similar changes were seen in the cartilages of the main bronchi. While the normal cartilage stained intensely with elastic tissue stain, the pathologic cartilage was practically negative for elastic tissue stain. Approximately 80 percent of the cartilage of the tracheobronchial tree was affected. Areas of normal cartilage were dispersed throughout the tracheobronchial tree. Cartilage just below the tracheotomy site appeared normal. Other than bilateral club feet, the remainder of the postmortem examination was essentially normal (Figs. 1, 2 and 3).

SUMMARY

The histopathologic findings are compatible with the diagnosis of polychondritis affecting the tracheobronchial tree. The inflammatory reaction is interpreted partly as secondary to the primary involvement of the cartilaginous tissue and partly as a result of the superimposed infection.

There are two pathogenetic hypotheses concerning this condition: 1) the perichondrial inflammation is primary and the destruction of cartilage is secondary; 2) and much more likely, the

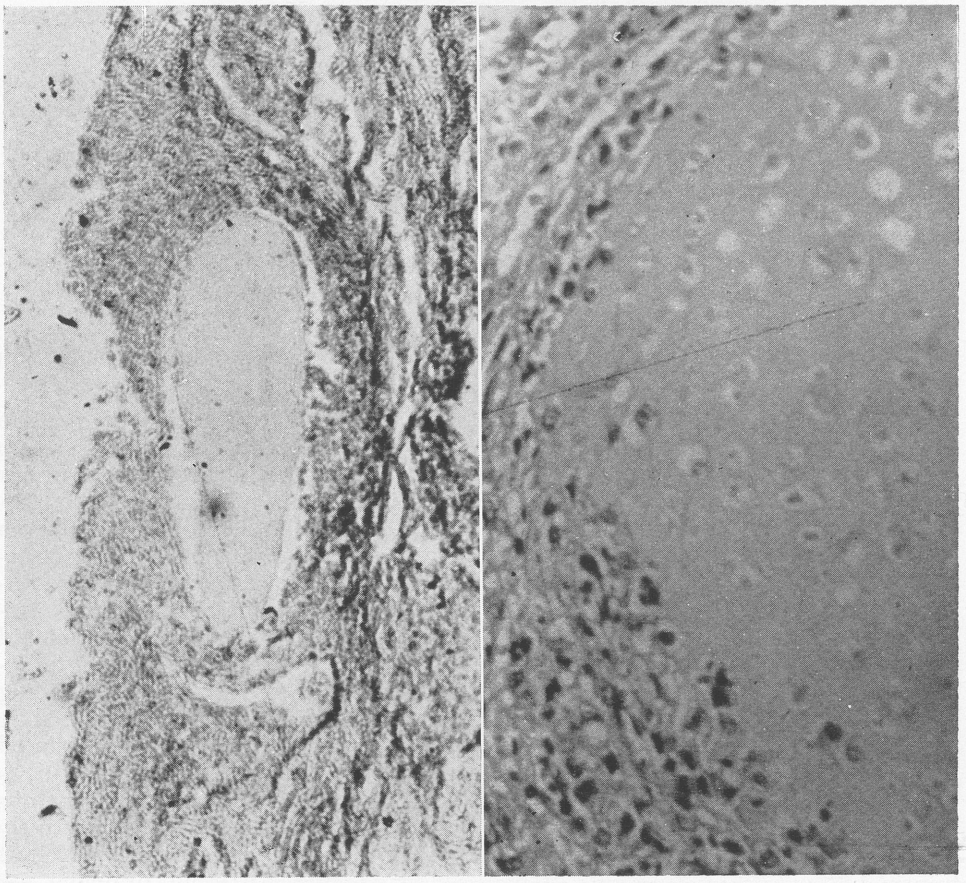

Fig. 2.—Cartilage, low power, showing involved cartilage, devoid of nuclei in cells, surrounded by a ring of inflammatory cells.
Fig. 3.—High power view of Fig. 2.

disease process affects first the cartilage and the perichondrial reaction is secondary. Experimentally, intravenous injection of the proteolytic enzyme papain into rabbits induces cartilage changes similar to those seen in human polychondritis. This would be the first case reported of polychondritis affecting a newborn.

It is hoped that additional histologic material may be obtained in cases of clinical tracheomalacia to further define the basic pathology.

636 Church Street, Evanston, Illinois 60201

VOCAL CORD TRANSPLANTATION IN DOGS

J. Cherry, M.D. W. Davis, M.D.

A. Rosenblatt, B.A. R. Coleman, Ph.D.

Nashville, Tenn.

Throughout the world our recent attention has been directed to those history making events surrounding the heart transplants in humans. Certainly these events of the last few years have captured the imagination of the entire world. The accomplishments of these masterfully conceived and executed surgical procedures have, however, pointed out to all that the problems associated with the rejection phenomenon have not been solved.[6] Yet these daring surgical moments have forced ahead our knowledge of immunology toward the day of complete control of the rejection reaction.

Unfortunately, we have so focused our attention on those transplants of vital organs that we may have neglected transplants of nonvital organs. It is quite clear, as pointed out by Dr. Shambaugh in his recent editorial in The Archives of Otolaryngology,[7] that one is not justified in using many of the immuno suppressive agents with transplantations of nonvital organs. To jeopardize a patient's life with many of the immuno suppressive agents when transplanting an organ not absolutely necessary for life does not seem warranted. Yet transplantations of nonvital structures are, and have been, important.[4,8,12] The most significant examples have been corneal transplants which have been done with great success throughout the world for the past 50 years, without the use of immuno suppressive agents. The cornea does not normally have a blood supply of its own and as an avascular structure often survives the events of homotransplantation in a normal physiologic state.

Reasoning that other tissue of relative avascularity might behave similarly to corneal tissue, and knowing that in our specialty certain highly specialized tissue cannot easily be reconstructed from surrounding tissue, led us to try transplants of true vocal cords in dogs without immuno suppressive agents. Immunologists for some time have pointed out that certain graft sights seem to behave as "privileged sights" withstanding transplantation in a more normal state than other tissue. As Weiser has pointed out, avascular sights may be "privileged" because immune agents, such as lymphocytes, reach them less effectively than in more vascular tissue.[1,3,11] Graft sights lacking lymphoid drainage are also presumed to be "privileged sights" because antigen does not escape in amounts sufficient to elicit an effective immune response. The true vocal cords are unique in that they are both relatively avascular and almost entirely free of lymphatic channels.

METHOD

Fifteen mongrel dogs were used in this experiment and no attempt at tissue typing was done.[5,9,10] These animals were all anesthetized with IV Nembutal®. The larynx of each dog was opened by a midline thyrotomy. Two animals were operated on simultaneously and the left vocal cord of each animal was resected and transplanted at once into the other animal. No attempt at tissue preservation was done. The left true vocal cord was resected from the anterior commissure to the anterior aspect of the vocalis process in a three dimensional fashion, each grafted vocal cord was sutured in place by three and sometimes four sutures of

From the Division of Otolaryngology, Vanderbilt University School of Medicine.

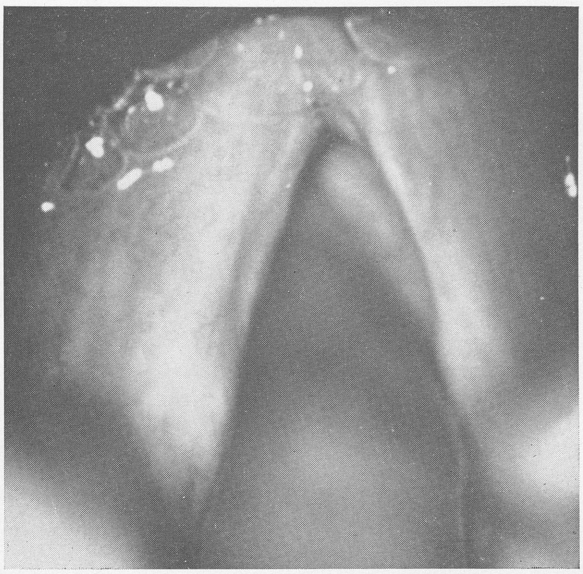

Fig. 1.—Endoscopic view left vocal cord grafted one year.

Fig. 2.—Left vocal cord grafted three weeks.

silk. These sutures were removed ten days postoperatively through a laryngoscope. The thyrotomies were closed with silk and the anterior neck wounds were closed in layers.[2] No drains were used and no tracheostomies were performed. One animal developed a wound infection which resulted in a granuloma of the anterior commissure, but did not alter either the healing of the grafted cord or its function.

These animals were all laryngoscoped postoperatively from one week to one year. Long-term animals had their vocal outputs recorded and each animal had careful evaluations of the gross changes following grafting by laryngoscopy under IV Nembutal anesthesia.

At postmortem color photographs were made of each grafted vocal cord for comparison with

its nongrafted mate. One of the two dogs with the grafted vocal cord in place for one year had a color motion picture made of its mobility (Fig. 1).

The animals were sacrificed at two weeks, three weeks, four weeks, five weeks, seven weeks, nine weeks, ten weeks, twelve weeks, seven months, and one year. Three animals were kept for seven months and two animals were kept for one year.

RESULTS

As Table I shows, the vocal cords which were studied within the first three months after grafting all showed varying degrees of rather typical patterns of nonspecific inflammatory response characterized by edema, perivascular lymphocytic infiltration, with some polymorphonuclear cells scattered throughout the subepithelial layers. The height of the reaction seemed to be reached about four weeks after grafting (Figs. 2 and 3) at which time the epithelium looked grossly reddened, but was obviously viable with only a few cells clearly in an abnormal state.

By the seventh month the gross appearance of these vocal cords was nor-

TABLE I

Dog No.	*Graft Time*	*Microscopic Appearance*	*Gross Appearance*	*Vocal Output*
1079	2 wks.	Acute inflammation-viable.	Injected and swollen	Poor
1083	3 wks.	Lymphocytic perivascular infiltration-viable.	Injected and slightly swollen	Poor
1085	4 wks.	Acute inflammation with hemorrhage-viable.	Slightly injected, slightly swollen	Fair
1055	4 wks.	Minimal inflammation-viable.	Mild injection	Fair-Good
1003	5 wks.	Mild inflammation subepithelial fibrosis-viable.	Injected and swollen	Fair-Good
1027	7 wks.	Perivascular lymphocytic infiltration-viable.	Slightly injected	Fair-Good
1025	9 wks.	Chronic inflammation, fibrosis-viable.	Minimal tissue loss	Fair
1024	10 wks.	Chronic inflammation with hemorrhage, fibrosis-viable.	Injected	Good
1084	12 wks.	Persistent subepithelial inflammation-viable.	Very slight injection	Good
1017	12 wks.	Chronic inflammation, subepithelial absorption-viable.	Anterior granuloma slight tissue loss	Good
1065	30 wks.	Mild chronic inflammation, mild fibrosis-viable.	Normal	Good
1039	31 wks.	Mild fibrosis-viable.	Normal	Good
1030	31 wks.	Slight subepithelial fibrosis-viable.	Normal	Good
1010	1 year	Slight subepithelial fibrosis-viable.	Normal	Good
1080	1 year	Subepithelial fibrosis-viable.	Normal	Good

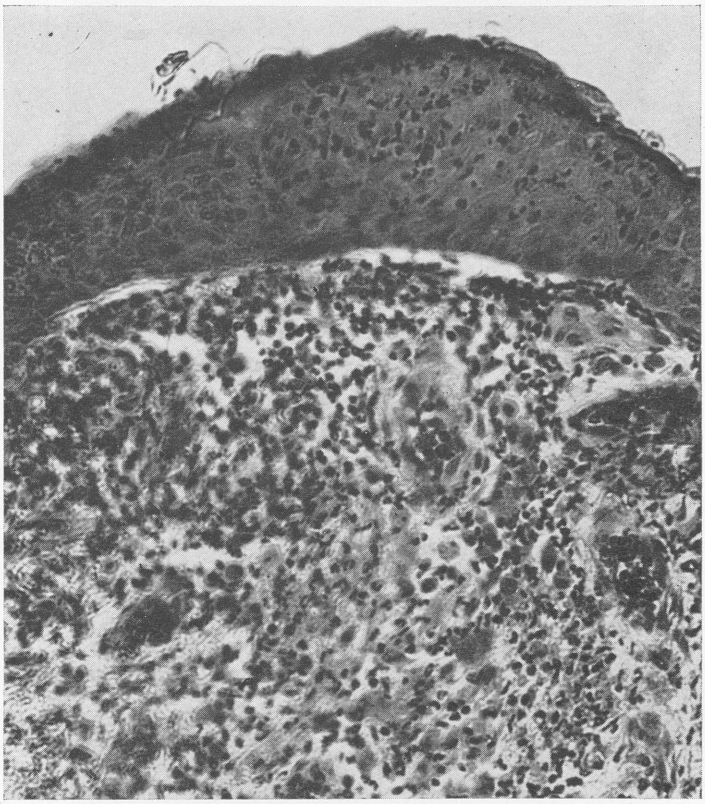

Fig. 3.—Three week graft; shows perivascular infiltrates of lymphocytes.

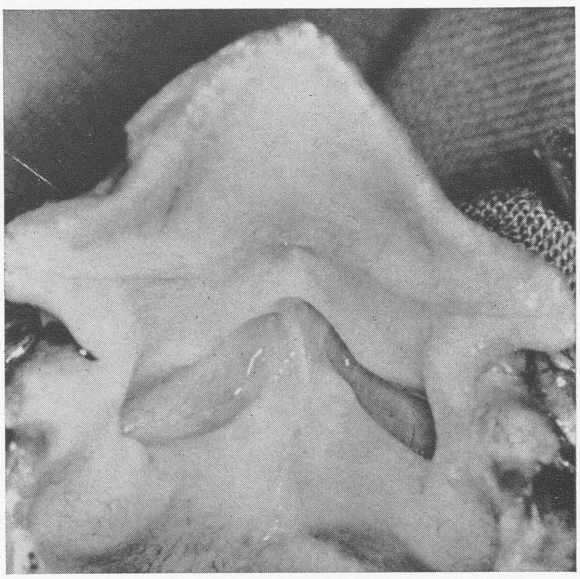

Fig. 4.—Left vocal cord grafted for seven months.

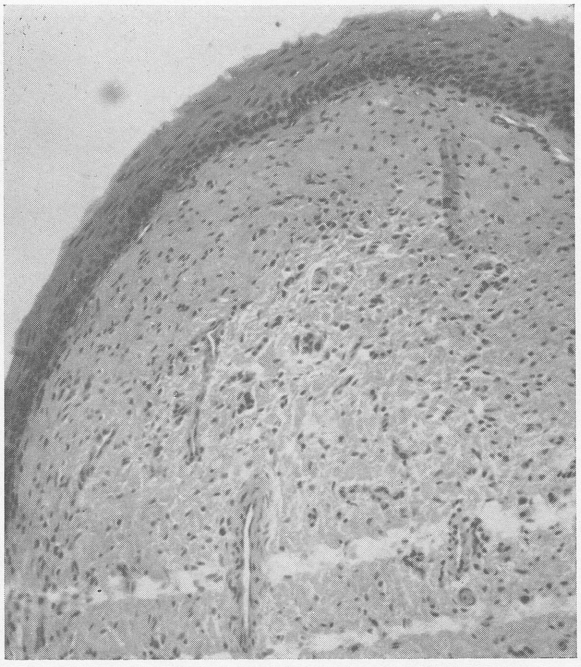

Fig. 5.—Microscopic appearance of the seven month graft with minimal reaction.

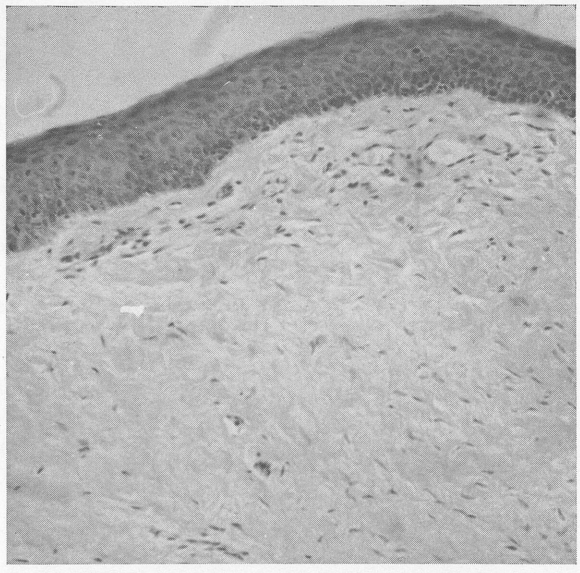

Fig. 6.—Microscopic appearance of a grafted vocal cord at one year.

mal (Fig. 4) and the vocal output of the dogs was good. Both the seven month grafts (Fig. 5) and the 12 month grafts histologically showed minimal evidence of subepithelial fibrosis, but both were otherwise normal (Figs. 6 and 7).

The vocal output of these animals improved as their wounds healed and the operative soreness subsided. This may

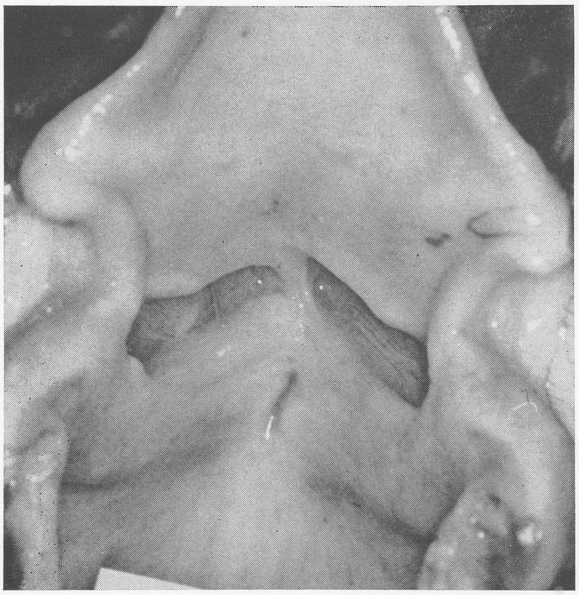

Fig. 7.—Normal appearing left vocal cord at one year.

have been advantageous, for had these animals barked vigorously postoperatively, their sutured left vocal cord grafts would certainly have been dislodged. The fact that no graft was dislodged in this series indicated that early tissue adhesiveness surely developed and that early vascularization must have occurred to have prevented dislodgement.

It seems clear that an inflammatory reaction develops in response to the grafted vocal cord, but this reaction is relatively mild and did not result in rejection. There was no evidence of tissue death either on gross or microscopic examination. Throughout the year no animal at any stage developed tissue slough of the grafted vocal cord.

As has been shown above, the general appearance of the grafted vocal cords following the initial reaction was normal. The motion of the five long-term (7 to 12 months) grafted vocal cords was excellent and the final result, i.e., the vocal output, was essentially normal. The two animals kept for one year had high fidelity recordings made of their vocal outputs and they are being analyzed to be reported at another time. These animals did have a normal volume and tone range for growls, whines, barks and yelps.

SUMMARY

Fifteen randomly selected mongrel dogs had their left true vocal cords homografted without the use of immuno suppressive agents. These animals were studied intensively over a 12 month period.

Early evidence of an immune response was seen but no rejection occurred and the five long-term animals, three at seven months and two at one year, had normal appearing vocal cords with minimal evidence of histologic changes while their vocal outputs were nearly normal.

It appears then that one can transplant canine vocal cords without immuno suppressive agents and obtain a good long-term functional result.

VANDERBILT UNIV. SCHOOL OF MEDICINE, NASHVILLE, TENN. 37203

REFERENCES

1. Davis B, Dulbecco, et al: Principles of Microbiology and Immunology. Harper and Row, 1967

2. Delahunty JE, Brookhauser PE, Cherry J: A preliminary report of vocal cord transplantation in dogs. Laryngoscope 79: 2081-2075, 1969

3. Dixon FJ, Kunkel HG: Advances in Immunology. Academic Press, 1967

4. Ogura JH, Kawaski M, Takenouchi S, et al: Replantation and transplantation of the canine larynx. Ann Otol 75: 295-312, 1966

5. Patel R, Mickey M, Terasaki P: Serotyping for hemotransplantation: XVI analysis of kidney transplant from unrelated donors. New Eng J Med 279: 501-506, 1968

6. Russell PS, Monaco AP: The biology of tissue transplantation. New Eng J Med 271: 502-783, 1964

7. Shambaugh GE: Organ transplantation. Arch Otolaryng 89: 567-568, 1969

8. Takenouchi S, Ogura JH, Kawaski M: Autogenous transplantation of the canine larynx. Laryngoscope 77: 1644-1667, 1967

9. Terasaki P. et al: Serotyping for homotransplantation XX selection of recipients for cadaver donors transplants. New Eng J Med 279: 1101-1103, 1968

10. Van Road JJ: Tissue typing and organ transplantation. Lancet I: 1142-1146, 1969

11. Weiser RS, Myrvik QN, Pearsal NN: Fundamentals of Immunology. Philadelphia, Lea and Febiger, 1969

12. Yagi M, Ogura JH, Kawaski M, et al: Physiological studies of the replanted canine larynx. Ann Otol 75: 849-865, 1966

DISCUSSION

JOSEPH H. OGURA, M.D.: Obviously, from the implications here, the parts of the vocal cord that have been transplanted are rather weakly or non-antigenic. I don't believe it is non-antigenic, but at least it is weakly antigenic.

I would like to ask if, in the absence of immunosuppressive drugs, were any electromyography studies done? I know the cords are moving here, but the problem is the muscles that have been transplanted. The thyroarytenoid muscle has a high oxygen consumption rate, very similar to the extraocular muscles, about 200 times that of normal striated muscle, and transplantation of muscles of lower order with a lower metabolic rate, cannot be accepted in transplantation with good function unless the nerve supply is intact.

Here you have transplanted a vocal cord and I suppose the thyroarytenoid muscle and if this muscle is transplanted, then it must re-enervate rather quickly, at least the distal portions of it.

There is some evidence for this because in our nerve/muscle transplants if you can transplant the distal pieces of the nerve and muscle to a peripheral motor end-plate, function returns, and this is the thing that we would like to know.

DOUGLAS P. BRYCE, M.D.: I have a question for Dr. Cherry: I don't think he told us how much of the vocal cord was actually transplanted. I would have felt happier had there been some controls, in other words, had he used some dogs in which the cord was removed and nothing further was done, because we all know the regeneration following a simple laryngofissure and cordectomy is sometimes very difficult to tell from the normal side. This is a point I am sure that you can give us information upon.

HERBERT H. DEDO, M.D.: In regard to the controls, did you consider the amount of cricothyroid effect that can be contributing to the closure during adduction? We have observed that when the recurrent nerve was paralyzed, especially after a period of a few weeks, it became even more noticeable that a significant amount of adductive action in the vocal cord is achieved from the cricothyroid.

DR. CHERRY (closing): The total substance of the vocal cord was transplanted in three dimensions to include a portion of the thyroarytenoid muscle.

We did in fact have controls, animals that had their vocal cords resected in the same fashion and the same amount of tissue removed as we had described in the paper, from the

anterior commisure to the mid-portion of the vocalis process in a three-dimensional fashion, and both of these animals had a very raspy, breathy vocal output. I should have included a portion of their vocal output at the termination of the film strip, and in removing this amount of tissue in a three-dimensional fashion there was epithelial regeneration but the substance of the cords did not increase in thickness and their vocal outputs were markedly diminished, almost as though one had de-barked these animals with a unilateral cord resection.

In answer to Dr. Dedo's comments, the cricothyroid effect was not considered.

MOVIE PRESENTATIONS

THE TWO STAGE ASAI TECHNIQUE OF LARYNGECTOMY

F. Johnson Putney, M.D.

Charleston, S. C.

Carter S. Bagley, M.D.

Asheville, N. C.

HUMAN LARYNX HOMOTRANSPLANTATION

Professor Paul Kluyskens

Gent, Belgium

SUPRACRICOID LARYNGECTOMY

Takeshi Kitamura, M.D. Toshio Kaneko, M.D.

Kiyoshi Togawa, M.D. Tokuji Unno, M.D.

Chiba, Japan

THE TWO STAGE ASAI TECHNIQUE OF LARYNGECTOMY

F. Johnson Putney, M.D.
Charleston, S.C.
Carter S. Bagley, M.D.
Asheville, N.C.

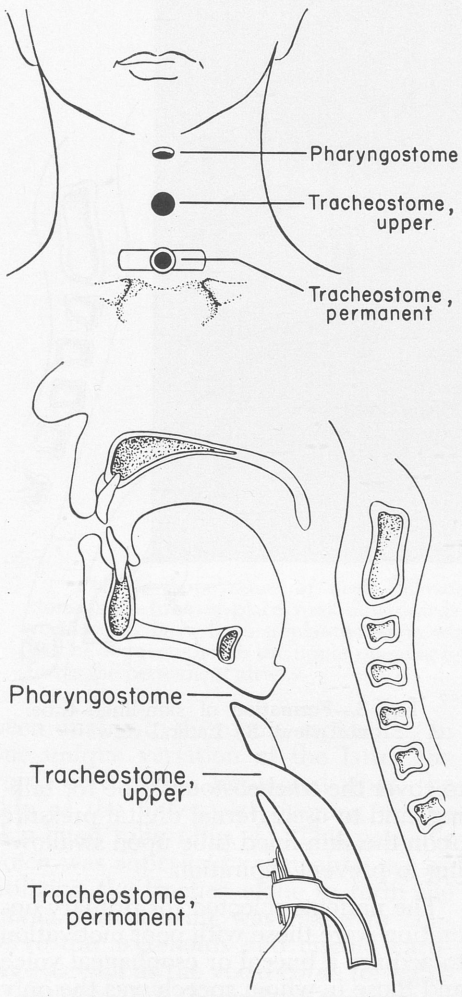

Fig. 1.—Position of tracheal and pharyngeal openings following the first stage Asai. A) Frontal view; B) Lateral view.

The operation designed by Asai[1] and introduced into this country by Miller[2] has for its purpose the rehabilitation of laryngectomized patients so that the expired, pulmonary airflow can be utilized for talking in a normal manner. The original operation performed in three stages can be reduced to two with the same results. This procedure used with modifications in a limited number of selected patients over the past several years has not supplanted the conventional laryngectomy with complete pharyngeal closure. Since the larynx is amputated just below the cricoid cartilage the technique is contraindicated in lesions with subglottic extension or involvement.

The tracheal stoma, which is constructed after laryngectomy, is placed as high on the neck as possible and narrowed to about 1 cm. At the same time, a pharyngeal stoma is created at the superior portion of the opening into the pharynx. A permanent tracheostomy is then made below the level of the laryngeal amputation, as low as the fifth tracheal ring in some instances (Fig. 1). A plastic tube is maintained through the nose, pharyngeal fistula, and both tracheal openings for 10 to 14 days during the healing process to maintain the tract (Fig. 2). A gastric tube via the nasal or cervical esophagostomy route provides the means of feeding.

At the second stage, the skin-lined tube fashioned between the upper tracheal opening and the pharyngeal fistula, follows Asai's original procedure of incising the skin vertically on each

From the Department of Otolaryngology, Medical University of South Carolina, Charleston, S.C.

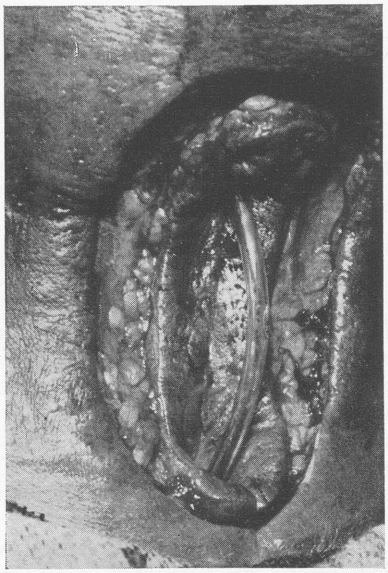

Fig. 2.—Indwelling pliable tube through the pharyngeal and superior tracheal opening before second stage closure. Permanent tracheal stoma not shown.

side of the center of the neck, and suturing the cut edges in the midline below the upper tracheal and above the pharyngeal stoma (Fig. 3). The remaining skin margins are approximated in the midline. The plastic tube is continued in place for an additional two weeks.

Difficulty has been encountered in establishing the ideal angle of the pharyngeal fistula so that the opening in the pharynx is at a lower level than the skin, yet this has not constituted a major problem in rehabilitation. The critical area as pointed out by Miller is the bridge of skin between the two tracheal openings, and unless this can be maintained and stabilized, breakdown in this area results in failure. The problem of dispensing with the permanent tracheostomy tube has not been overcome, although the use of a fenestrated tube has been useful. This directs the expired air through the upper portion of the tracheostomy tube itself rather than emerging around the outside of the distal end of the tube to reach the pharynx. It has been necessary for the patients

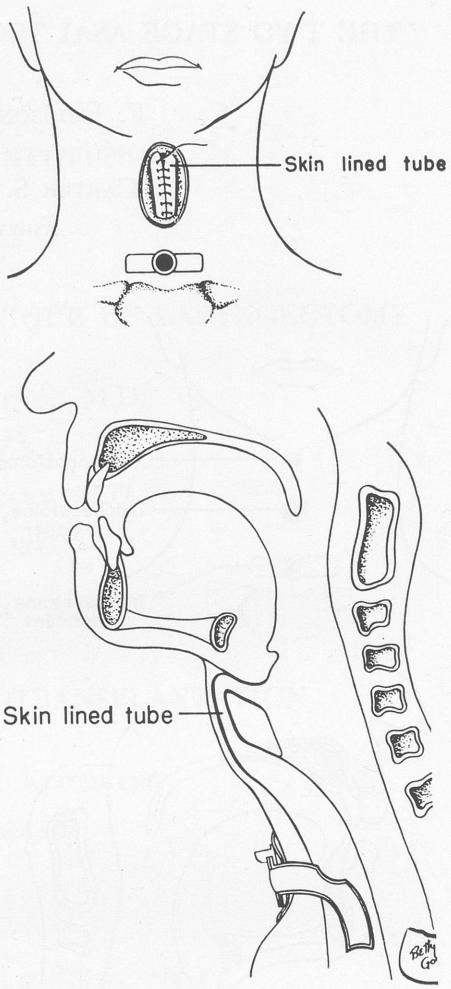

Fig. 3.—Formation of skin-lined tube. A) Frontal view; B) Lateral view.

to cover the tracheostomy tube for talking, and to use external digital pressure upon the skin-lined tube upon swallowing to prevent aspiration.

The patients selected for primary operation were those with poor motivation to acquire a buccal or esophageal voice and those in whom speech was the only means of communication. Except for these few cases our thinking at present is to apply this technique to convert those patients who have not developed a satisfactory voice following a conventional laryngectomy, or who have had supraglottic laryngectomies and have

Fig. 4.—Appearance of neck following first stage Asai. The upper pharyngeal stoma with tube in place runs downwards from the skin surface to the pharynx. The vocal cords have been implanted upon the skin to form the middle opening and later will be connected with the upper opening by a skin-lined tube. The lower tracheal stoma forms the permanent airway.

been unable to overcome aspiration. In one unique variation of the latter the vocal cords were implanted upon the skin as the lowermost opening of the skin-lined tube (Fig. 4). This patient's voice was superior to that obtained by utilizing the trachea alone to form the stoma. An attempt was made to conserve the arytenoids and cricoid cartilage as well as the vocal cords for cordal mobility, but the bulk of the remaining larynx prevented its use in this fashion.

Several complications developed. Aspiration of fluid and food was such a problem in one patient who developed pneumonitis frequently, and on one occasion had a lung abscess, that it was necessary to change the Asai to a standard laryngectomy. In two patients there was necrosis of the skin between the tracheal apertures creating a common opening, so that the second stage connecting the trachea to the pharynx could not be performed. Growth of hair in the skin-lined tube has been inconsequential and removal has not been needed because of obstruction.

SUMMARY

The original three stage Asai technique for the rehabilitation of laryngectomized patients can be performed in two stages. This operation has not

replaced the conventional laryngectomy, and was used as a primary procedure only in selected disadvantaged patients. Patients with a standard laryngectomy unable to develop a satisfactory voice were converted by this method provided sufficient trachea remained. In the conversion of patients after supraglottic laryngectomy implantation of the uninvolved vocal cords into the skin-lined tube, produced a better voice with less aspiration.

The complications that developed in the order of frequency were aspiration of fluid and food, necrosis of the skin between the tracheal openings, and growth of hair within the skin-lined tube.

80 Barre Street, Charleston, South Carolina 29401

Request for reprints should be sent to 80 Barre Street, Charleston, S. C. 29401.

REFERENCES

1. Asai R: Cited by Miller

2. Miller AH: First experiences with the Asai technique for vocal rehabilitation after total laryngectomy. Ann Otol 76: 829-833, 1967

HUMAN LARYNX HOMOTRANSPLANTATION

PROFESSOR PAUL KLUYSKENS

GENT, BELGIUM

(SYNOPSIS OF MOVIE)

The technical aspects of larynx homotransplantation are only a part of the problem. Whereas the transplantation of a vital organ is at this moment generally accepted, larynx transplantation is fundamentally different from others as the larynx is not a vital organ. Considering the fact that in case of rejection laryngectomy would be possible, we have done this transplantation only after hopeful results in experimental research. The risk of immunosuppression has not been overcome. As it appears from our case immunosuppression occurs if the histocompatibility is not good, and the immunosuppression might be expected to increase the risk of cancer.

The exoperichondral laryngectomy is the best way to keep good vascularization of the transplanted larynx. The laryngeal perichondrium is incised in the median line and detached on both sides together with the anterior insertions of the cricopharyngeal museles. The dissection is extended bilaterally up to the posterior margin of the thyroid cartilage. The larynx is isolated anteriorly and laterally from the perichondrium and removed from underneath by incising the trachea, freeing the posterior wall of the larynx from its insertions in the hypopharyngeal mucous membrane and finally incising the pharyngeal mucous membrane around the laryngeal vestibule. The transverse section at the base of the epiglottis makes it possible to retain a large part of the epiglottis and the thyrohyoid membrane.

In the meantime a total laryngectomy has been performed in the donor, removing the perichondrium of this larynx also. No attempt was made to suture the recurrent nerve but an arytenoidopexy was performed as in a case of bilateral recurrent paralysis. The section of the thyroid cartilage and epiglottis was adjusted to the place in the perichondrium of the receiver. A tracheostomy tube and a feeding tube remained in place till the patient was able to swallow. Three months after the operation the patient was in good shape, only breathing through the larynx was insufficient.

I want to stress that at the time we did this operation we were confident that the cancer would not be activated by immunosuppression. This was wrong. Eight months after the operation there was cancer at the level of the stoma, and all efforts could not prevent the fatal issue.

Our observation makes it questionable whether transplantation with the necessity for immunosuppression has any place in the treatment of cancer patients even if one feels that the tumor has been entirely removed.

Interesting and encouraging technical aspects, such as, recovery of deglutition, voice and breathing have been observed, but we must conclude that more experimental research in the field of immunosuppression and cancer needs to be done.

SUPRACRICOID LARYNGECTOMY

TAKESHI KITAMURA, M.D. TOSHIO KANEKO, M.D.
KIYOSHI TOGAWA, M.D. TOKUJI UNNO, M.D.
CHIBA, JAPAN

The larynx has three major functions: respiration, phonation and sphincter function. In the treatment of laryngeal cancer many ingenious surgical techniques have been devised for preservation of these functions.[1-5]

The partial laryngectomy, either vertical or horizontal, aims at complete removal of the tumor with preservation of these functions by conserving the mobile portions of the larynx controlled by the nerve. Although radiotherapy and chemotherapy for malignant tumors have markedly progressed, some cases still need to be treated by total laryngectomy. They lose all of the functions. Postoperative phonation in such cases has to be restored by an artificial instrument or esophageal voice.

Asai accomplished voice production by reconstructing a pseudoglottis after total laryngectomy. However, inflow of saliva and foods through this opening to the air passage is annoying.

As far as the extension of the tumor is concerned, there is a distinction between the indication for total laryngectomy and that for partial laryngectomy. In cases in which cancer extends to the contralateral side or downwards below the glottis, vertical partial laryngectomy or supraglottic horizontal laryngectomy is not indicated. An extirpation of the laryngeal portion above the cricoid cartilage, supracricoid laryngectomy was designed for such cases. Cancer invading the cricoarytenoid joint is not suitable for this original method but a modification in which the upper half of the cricoid is dissected with the soft tissue has relatively limited indications (Table I).

METHOD

Under local anesthesia a vertical incision is made from 1 cm above the hyoid bone to 1.5 cm below the cricoid cartilage. Tracheotomia media is performed at the lower end of the skin incision. General anesthesia is given, using a V-shaped tube inserted through this tracheostoma.

The middle part of the hyoid bone and the anterior part of the thyroid cartilage are exposed, and the perichondrium is stripped off the outer surface of the cartilage. The bilateral prelaryngeal muscles and the mylohyoid muscle are detached from the hyoid bone (Fig. 1a). Two-thirds of the hyoid bone must be dissected. Following the above procedure it becomes relatively easy to separate the perichondrium from the thyroid cartilage, particularly at the upper half of the lateral margin. The inferior cornu of the thyroid cartilage may be cut at the base with scissors. The cricothyroid ligament should be transected 3 mm above the arch of the cricoid cartilage. The subglottic wall is circularly incised and separated from the lamina of the cricoid cartilage (Fig. 1b). The subglottic space is opened a sufficient distance from the inferior border of the tumor to ascertain the tumor margin after the space is opened. An upward and forward traction of the supracricoid portion of the larynx makes the procedure easy by projecting the inferior cornua from the depth (Fig. 2a). These cornua are then cut off. The hypopharyngeal wall is then separated from the posterior surface of the thyroid cartilage. The arytenoid cartilage will be seen about 1 cm from the upper margin of the lamina by traction of the supracricoid portion. Separation of the inner surface of the thyroid cartilage should be completed to the base of the superior cornu. The bilateral superior laryngeal nerves and arteries may come into view

From the Department of Otolaryngology, Chiba University School of Medicine, Chiba, Japan.

TABLE I

CLASSIFICATION OF LARYNGEAL OPERATION FOR CANCER

	Function	*Surgical point*
1. Cordectomy	R P S	a
2. Vertical Partial Laryngectomy	R P S	a′ b′
3. Horizontal Partial Laryngectomy	R P S	a′ b′
4. Supracricoid Laryngectomy	P S	b c
5. Total Laryngectomy with Laryngoplasty (Asai)	P	b c′

R: Respiration; P: Phonation; S: Sphincter function.

a: Preservation of mobile portion (a′: partial); b: Resection of mobile portion (b′: partial); c: Creation of pseudoglottis (c′: esophageal voice).

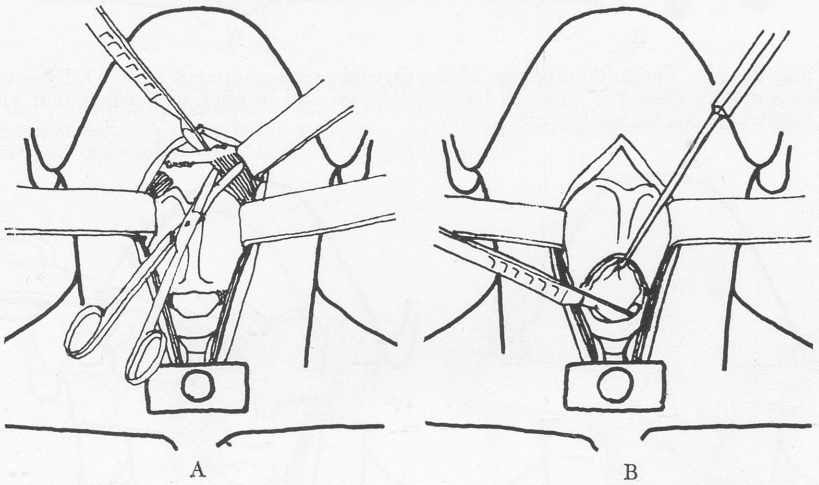

Fig. 1.—a) Bilateral prelaryngeal muscles and the mylohyoid muscle are detached from the hyoid bone. b) The subglottic wall is circularly incised and separated from the lamina of the cricoid.

after cutting the superior cornua (Fig. 2b). The arteries are doubly ligated and cut. After opening the hypopharynx between the arytenoid cartilages and the lamina, the wall is cut upwards symmetrically and the suprahyoid portion is cut from the base of the tongue (Figs. 3a and b).

Closure of the hypopharynx and suture of the skin incision require the following procedure. The central portion of the base of the tongue is sutured to the upper end of the vertical skin incision. A silk thread is passed through the skin and mucous membrane of the pharynx on each side 0.5 cm below the upper end to facilitate an adhesion (Fig. 4a). The space between them is the expected pseudoglottis. Suture of the other part of the pharyngeal wall is as usual (Fig. 4b). The skin is adhered to the pharyngeal wall by passing threads through both the skin and the pharyngeal wall (Fig. 5a). The subglottic inner space of the cricoid cartilage should be opened upwards at the lower portion of the vertical skin suture. This leaves a small bare wound on the upper part of the lamina, but the arch is covered with skin. (Fig. 5b).

The completed portion at this stage shows a vertical groove between banks of prelaryngeal muscles. The groove, upwards, ends in the pharyngeal stoma which opens at the base of the tongue, and downwards, continues into the subglottic space. In order to keep this groove, a roll of gauze is placed in it, and the upper end is sharpened and inserted into the pharyngeal stoma.

The secondary operation to form the dermal tube is performed three to four weeks later. Its inner diameter is expected to be 0.5 cm. A spindle-shaped incision, placed 1.5 to 2 cm from the vertical suture in the groove, and 0.5 cm from the upper pharyngeal opening and the lower subglottic opening, is suitable. Separa-

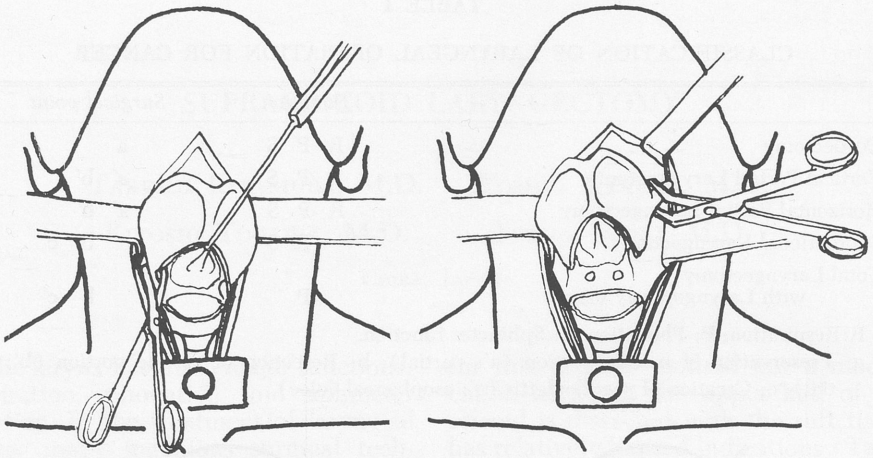

Fig. 2.—a) The inferior cornua of the thyroid cartilage are cut off. b) By cutting of the superior cornu the superior laryngeal nerve and arteries may come into view. The arteries are ligated and cut off.

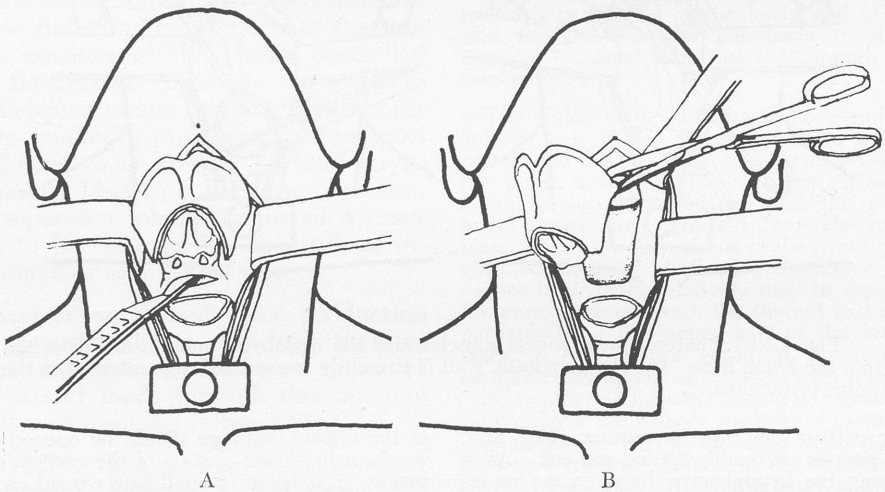

Fig. 3.—a) The hypopharynx is opened between the arytenoid cartilage and the lamina of the cricoid. b) The hypopharyngeal wall is cut symmetrically and the suprahyoid portion is cut off last from the base of the tongue.

tion of the skin layer from the surrounding soft tissues is done so that the incised edges of both the inner and outer layers easily contact each other. A silk thread is first passed through one side of the inner layer at the level of the expected pseudoglottis, second, at the upper end above the opening, and third, on the other side at the corresponding level. (Fig. 6a). The left end of the thread is then passed through the right edge of the outer layer, and the right to the left. This suture technique makes the pseudoglottis open at the base of the tongue crooked to the axis of the dermal tube. The remaining part of the tube is made by doubly suturing the inner and outer layers using the same threads (Fig. 6b). Those of the inner layer can also be taken off as the threads are removed from the outer layer. The space is not sufficient to pass air immediately after the surgery, but the diameter of the tube will dilate after the removal of the threads on the seventh day (Fig. 7a).

RESULTS AND COMMENTS

Nine cases were treated with this technique. Preoperative irradiation

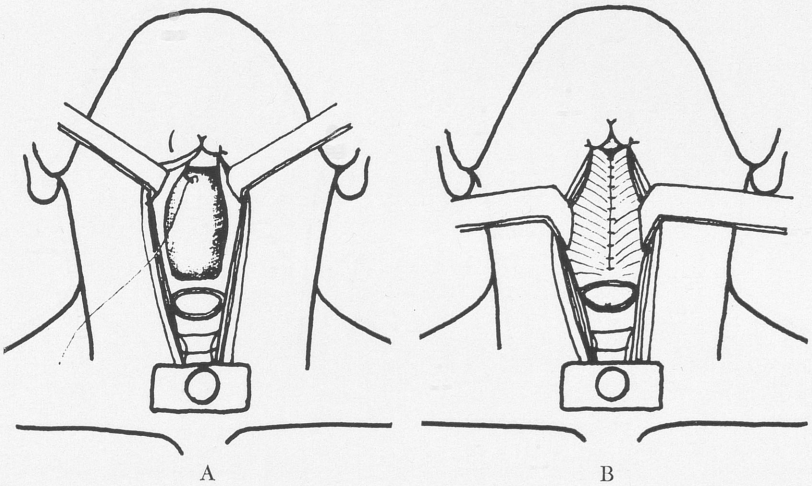

Fig. 4.—a) Central portion of the base of the tongue is sutured with the upper end of the vertical skin incision. Then each one stitch is made on both sides 0.5 cm below the upper end. A space between them is an expected pseudoglottis. b) Suturing of the other part of the pharyngeal wall is performed as usual.

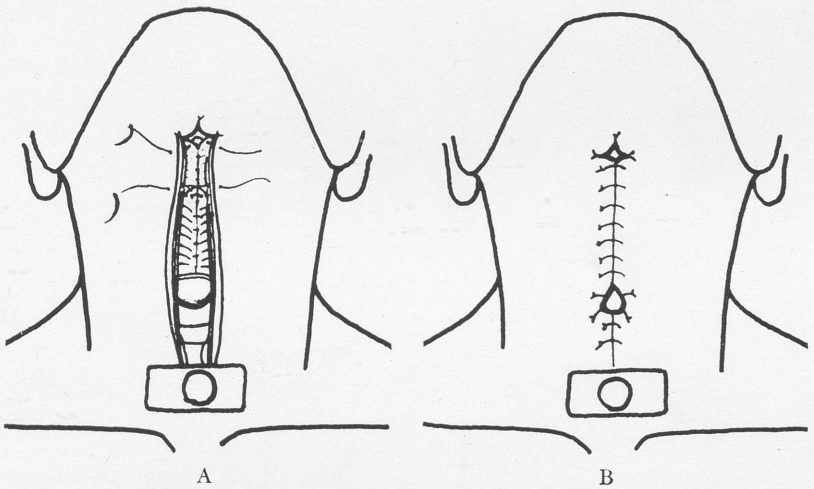

Fig. 5.—a) For better adhesion of the skin with the pharyngeal wall double layer sutures are made. b) A small bare wound remains on the upper part of the cricoid lamina, but the arch is covered with skin.

amounting to 4,000 or 5,000 rads did not disturb or delay the wound healing. Only one case had local recurrence, which was followed with total laryngectomy and radical neck dissection.

Patients can speak without any training about two weeks after the second operation. They are not able to inhale air through the pseudoglottis, but can speak by closing the tracheostoma with a finger (Fig. 7b). A small pseudoglottis prolongs the duration of phonation with a weak voice and high pitch. A large pseudoglottis shortens the duration with a loud voice and low pitch. The vibration occurs at the margin of the pseudoglottis, which is stiffer than that of Asai's operation. In his technique the pharyngostoma is set low in

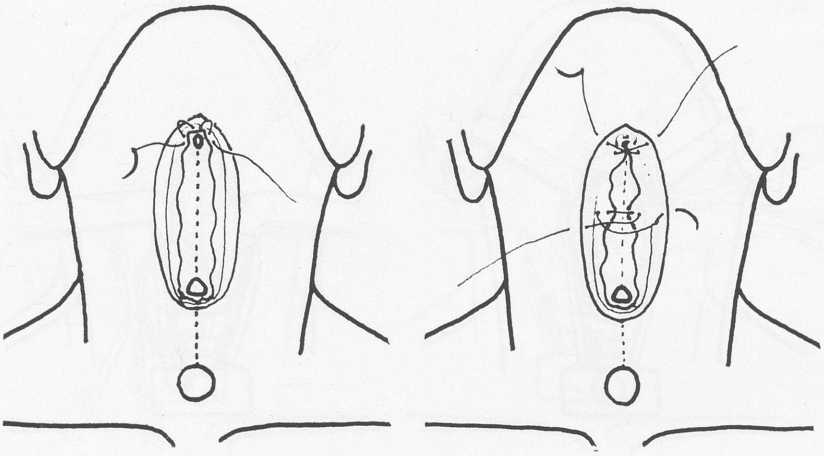

Fig. 6.—a) A thread is first passed through one side of the inner layer at the level of the expected pseudoglottis, second at the upper end above the opening, and third at the other side at a corresponding level. b) Dermal tube is made by double sutures of the inner and outer layers.

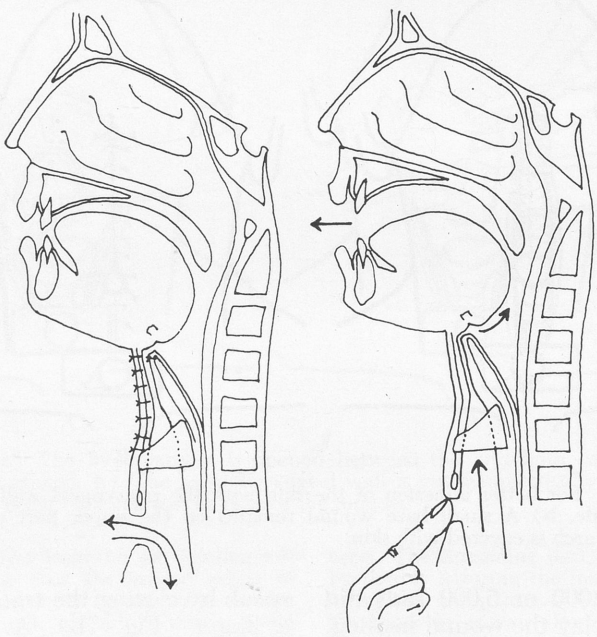

Fig. 7.—Profile scheme at the end of the second stage operation. a) Respiration. b) Phonation.

the hypopharynx, which creates a sound similar to that of the esophageal voice. The pseudoglottis, in this technique, is set high at the base of the tongue. It is hidden by the base of the tongue and retracted upwards on swallowing, so that no aspiration of saliva or food enters the air passage. Patients can swallow food without pressing the dermal tube with a finger, which enables them to use both hands at the table. With Asai's operation it is necessary to press the dermal tube during the swallowing act.

Preservation of the cricoid lamina and the strap muscles support phonation by keeping the dermal tube patent.

The passage time of food through the hypopharynx remains within the normal range after this technique. It is prolonged considerably after total laryngectomy.

The positive intraluminal pressure at the pharyngoesophageal junction (PEJ) also remains within normal, and is markedly diminished after total laryngectomy.

This technique is not indicated for all types of laryngeal cancers but should be limited to cases which cannot be operated upon by hitherto employed techniques of partial laryngectomy, and are not so extensive as to require total laryngectomy.

The same idea is now being carried out in total laryngectomy by leaving a small opening at the base of the tongue and a tracheal cut-end above the tracheostoma. These two openings are closed later by the second operation.

The technique is simple and easy to obtain good results by surgeons who have had experience in total and partial laryngectomies.

SUMMARY

A new technique for laryngeal cancer, the supracricoid laryngectomy, is introduced. The surgical procedure and some clinical characteristics of this method are demonstrated. The technique is simple and easy enough to obtain good results by any experienced laryngologist. The indication for this method should be limited to cases in which the cancer extends to the contralateral side anteriorly and posteriorly, or downwards below the glottis, so that neither vertical partial nor supraglottic horizontal laryngectomy is indicated but not so extensive as to be treated by total laryngectomy.

CHIBA UNIV. SCHOOL OF MEDICINE, CHIBA, JAPAN

REFERENCES

1. Asai R: Asai's new voice production method. Substitution for human speech. Proceed VIII Internat Cong Oto-Rhino-Laryng ICS 113: 730, 1966, Excerpta Medica Foundation

2. Hoffman-Saguez R: La laryngectomie reconstitutive. Acta Oto-laryng 71: 405, 1954

3. Kitamura T, et al: Supracricoid laryngectomy. A new technique for vocal rehabilitation. Laryngoscope 80: 300, 1970

4. Leroux-Robert J: Indications et resultats apres 5 ans dela chirurgie conservatrice fonctionelle des cancers du larynx et al I'hypopharynx. Progres en oto-rhino-laryngologie IX, Rapport II. Paris 1961

5. Miller AH. First experiences with the Asai technique for vocal rehabilitation after total laryngectomy. Ann Otol 76: 829, 1967

DISCUSSION OF PRESENTATIONS BY DRS. PUTNEY, KITAMURA, AND KLUYSKENS

ALDEN H. MILLER, M.D.: I was so happy especially to see that film of Dr. Putney's. As you all know, I was very, very enthusiastic in my first efforts with the ASAI technique and I still am. Just as Dr. Putney said, I talked a number of friends into also trying this procedure.

As these three or four years have gone by not all of those friends have given me the most friendly reports on their experiences. I was afraid of what Dr. Putney was going to have

on his movie, but there you are, and that was to me a darned good voice. Anybody who can count to forty vindicates that procedure, so far as I am concerned, over esophageal voice.

I am almost as enthusiastic as I was at the beginning. I still offer it to the patients and let them make their own decision.

Both films have taught me now that I am sure we can experiment with trying to make the three openings all at one stage.

Finally, just a word on Professor Kluyskens' movie. I was absolutely fascinated to see this movie and what counts most with me are those last footages which showed you a live patient breathing through a larynx and swallowing without trouble.

JOSEPH GOLDMAN, M.D.: I would like to make a few brief remarks about Professor Kluyskens' film.

Anybody who attempts to do a first operation of this kind must have courage. This is part of the history of medicine. Professor Kluyskens comes from an institution that is involved in a good deal of transplantation and they are very knowledgeable in the area of immunology of transplantation; so he has had the background and obviously is experienced in this work.

Somebody along the line had to do the first operation, the first transplantation of the larynx. Fortunately it was a person like Professor Kluyskens who comes here and makes a report with complete honesty, with humility and makes a contribution to the history of laryngology.

As Dr. Miller mentioned, we have learned a good deal from this film. We see that a transplantation can occur, can be effective to the extent that the patient has good swallowing function, has a voice.

We have learned through this that there are effects from the immunosuppressive drugs that are unfortunate, that they are undesirable effects which should tend to discourage us to continue this kind of transplantation until better drugs appear on the scene, Professor Kluyskens has emphasized this.

This doesn't mean that, for instance, in very severe injuries of the larynx, in rare situations of destructive lesions of the larynx which cannot be cured by partial procedures, that possibly there may be a place for transplantation. In any event, I think we have heard a step, and a very important step, in the history of the evolution of laryngeal surgery and for this we are indebted to Professor Kluyskens.

JOSEPH H. OGURA, M.D.: When Dr. Kluyskens presented this work in Mexico City I asked if I could visit and see this patient. I visited his patient eight months after the transplantation, and went over the record very carefully and I think he has made a significant contribution. At that time he felt that the immunosuppressive drugs might spread cancer, this patient had cancer recurrent at that time. This patient received irradiation and at the time I examined the patient I saw no evidence of recurrence. The patient was then off of immunosuppressive drugs about eight months. The examination of the larynx was quite surprising. There was evidence of perhaps some perichondritis but the surprising feature was that without revascularization, without re-ennervation, vocal cords were there and the patient could swallow.

I think Professor Kluyskens has stated here that at the present time we need more experimental work and certainly we should pursue the immunosuppressive aspects, weigh the drugs versus other methods for immunosuppression, and revascularization and re-innervation.

PREOPERATIVE RADIATION OF LARYNX
ANALYSIS OF SERIAL SECTIONS

EMANUEL M. SKOLNIK, M.D.

BURTON J. SOBOROFF, M.D. M. EUGENE TARDY, JR., M.D.

RALPH J. LEVIN, M.D. LOUIS T. TENTA, M.D.

CHICAGO, ILL.

The value of serial sections of the entire larynx in the analysis of laryngeal tumors has been carefully documented.[3,5,7] In 1961 Goldman and Silverstone[2] reported the use of combined preoperative irradiation and surgical therapy for cancer of the larynx and laryngopharynx. Since that time Goldman et al.[3,4] have reported their experience with this method of treatment of extensive cancer of the larynx. In 1963 a protocol for combined irradiation and surgical treatment of advanced carcinoma of the larynx and laryngopharynx was initiated at the University of Illinois Hospital. Coincident with this study a continuing serial section analysis of the laryngeal specimens was begun. The objectives of this study were to 1) evaluate the three-dimensional anatomic extent of each cancer; 2) assess the histopathologic effects of preoperative irradiation on the tumor and larynx; and 3) correlate the preoperative evaluation of the extent of the tumor with actual tumor boundaries as determined by serial section analysis.

A total of 54 laryngeal specimens were examined in serial sections. Twenty-four patients had received the 2000 Rad (R) tumor dose by supravoltage technique, followed by surgery without delay. Twenty-four patients received 5000 R protracted over a period of four to five weeks, followed by surgery four to six weeks later to permit the acute postirradiation inflammation to subside. Six patients, not initially included in the combined therapy protocol, underwent laryngectomy after a complete course of irradiation therapy (5000 to 6000 R) failed to effect a cure, and these laryngeal specimens were available for study.

Of the entire group, 46 patients had primary laryngeal tumors (Fig. 1) and eight had primary tumors in the pyriform sinuses with extension that involved the larynx.

METHODS AND MATERIALS

The larynx specimens were received from the Pathology Department in 4% formalin after removal of tissue for report. The surrounding neck tissue was removed and the larynx was placed in 500 cc of formic acid-sodium citrate decalcifying solution for three weeks, changing the solution every second day. It was then washed 24 hours and dehydrated through ascending percentages of alcohol, 70 to 95%-absolute alcohol. and finally immersed in a 1:1 solution of ether-absolute alcohol. The specimen was retained in each solution for 24 hours. The larynx was then slowly infiltrated with celloidin by immersion in 4, 8 and 12% celloidin solutions for three weeks in each concentration and later hardened in the 12% solution by placing the bottle with the specimen in a dessicator containing $CaSO_4$ and allowing the celloidin to dry slowly. Drying took approximately two or three weeks. Parlodion (Mallinckrodt) was used for the celloidin solutions. The block was trimmed and stored in 80% alcohol.

The larynx was sectioned with an AO-Spencer Sliding Microtome using a bone knife. Sections were 26 microns thick, cut serially in the coronal plane, posterior to anterior. Every fifteenth section was removed

From the Department of Otolaryngology, Abraham Lincoln School of Medicine, and the Eye and Ear Infirmary, University of Illinois Hospital, University of Illinois at the Medical Center, Chicago.

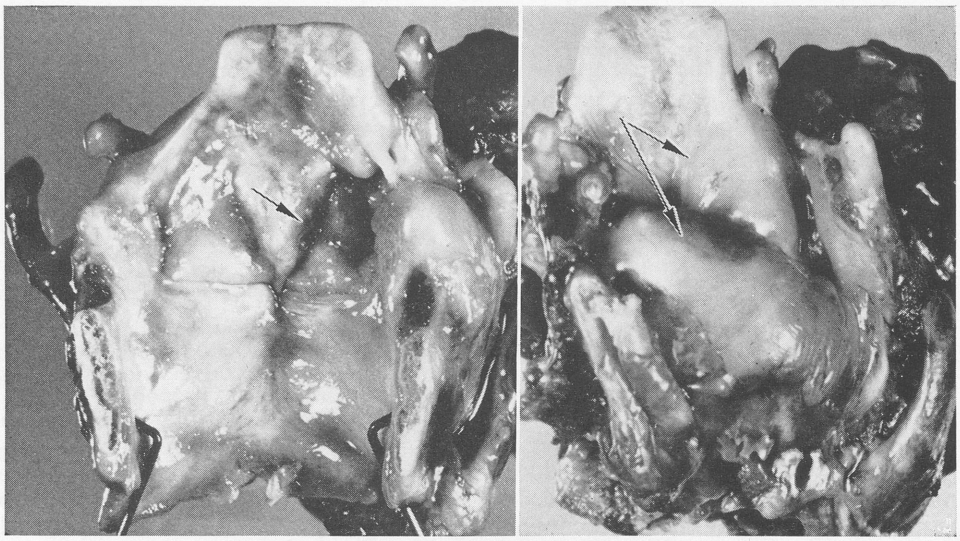

Fig. 1.—Primary laryngeal carcinoma involving right aryepiglottic fold, false cord and true cord after irradiation therapy (2000 rads).

Fig. 2.—Larynx specimen showing huge edema following irradiation therapy (5000 rads) given over a period of 33 days.

for staining and histopathologic analysis. The sections were stained unmounted with Harris' hematoxylin and alcoholic eosin, cleared in a 1:1 solution of terpineol xylene and mounted

In analyzing each case, photographs of the surgical specimen (taken prior to removal of any tissue by the Pathology Department), the Pathology Department routine slides, and the serial sections were reviewed by at least two of the authors. The clinical records of all patients were reviewed and abstracted.

ANALYSIS OF SECTIONS

Tumor Extent. Every experienced laryngologist is painfully aware of the limitations of the clinical determination of the true extent of most extensive cancers of the larynx. Tucker[7] demonstrated this clearly in several studies. He used the term "paraglottic" to describe spread of a tumor lateral to the conus elasticus and ventricle and between the muscle of the false cord and the thyroid ala. Tumor may spread here far below the level of the glottis without involving the subglottic mucosa.

Kirchner[5] showed that large transglottic lesions often reached or penetrated the cricothyroid or thyrohyoid membranes in the depth of the specimen.

Edema of the tissues surrounding or overlying the tumor masks the margins effectively and may obscure large portions of the growth (Fig. 2). Postirradiation edema may be even more severe and completely obscure large areas of infiltrating tumor. Therefore, direct inspection of the gross specimen at surgery may not reveal the true boundaries of the tumor extension. Carcinoma in this area notoriously spreads beneath the mucosa into muscular planes, through cartilage, and may penetrate the cricothyroid and thyrohyoid membranes. In our series, frequent pathways of spread were lateral to the ventricle (paraglottic) (Fig. 3) and posteriorly across the interarytenoid area, neither of which were always grossly evident (Fig. 4).

Serial sections consistently demonstrated that the cartilaginous components of the laryngeal framework were not impenetrable barriers to tumor spread. Supraglottic tumors were often found to invade and penetrate the epiglottis and the thyroid cartilage.

Interestingly, serial sections demonstrated the presence of residual tumor in four of six specimens reported as negative for tumor by routine pathologic examination; each of these from

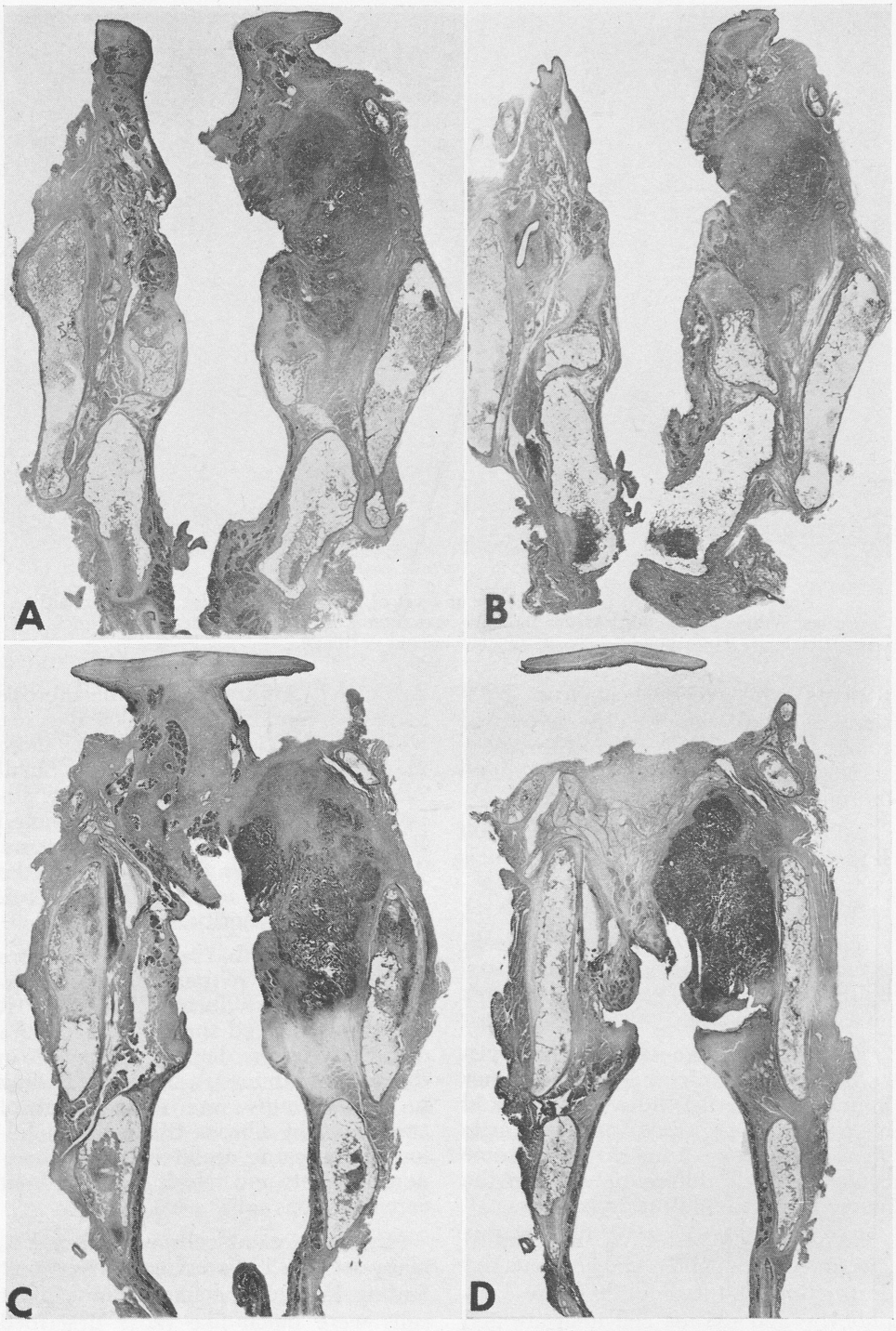

Fig. 3.—Serial sections show residual tumor in right side of larynx involving base of epiglottis, false cord and paraglottic region after completion of 5085 rads of irradiation therapy. Section A posteriorly at arytenoid; Sections B, C, D successively anteriorly in the larynx.

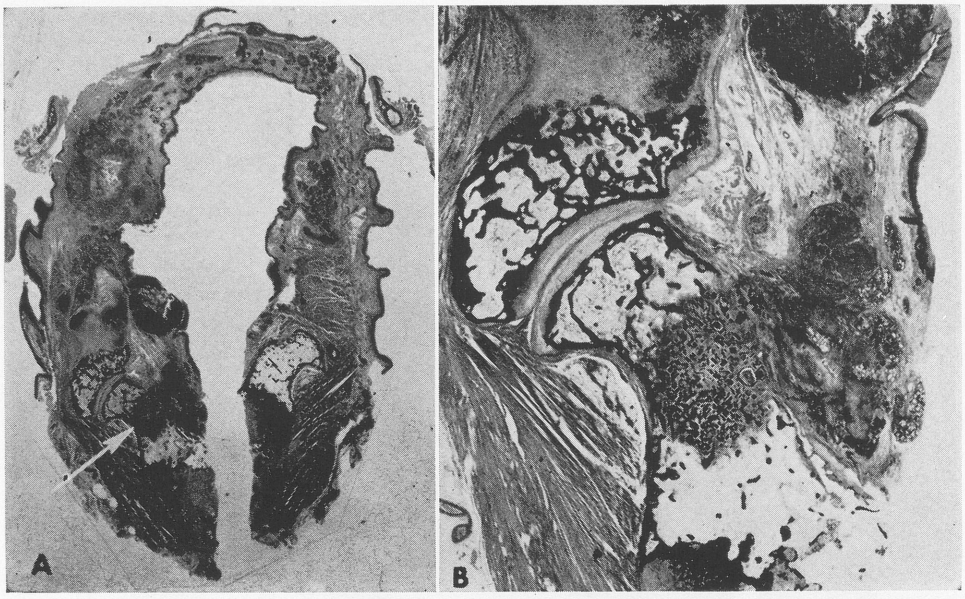

Fig. 4.—A) Serial section posteriorly at level of cricoarytenoid joint in patient with extensive invasive tumor. Arrow indicates carcinoma invading and destroying cricoid cartilage. B) High power view of invaded cricoid cartilage.

patients who received at least 5000 Rads of irradiation therapy. Nests of tumor cells could be found in these serial sections which permitted more thorough study (Fig. 5).

All patients who received the 2000 Rad dose of irradiation had tumor demonstrable by both routine histologic analysis and serial section analysis.

Serial sections were also valuable in demonstrating transitions from normal epithelium to in situ carcinoma to frank invasive carcinoma.

Because we were often able to visualize the circumference of the tumor in one plane on the slides, tumors could be seen to be discrete and expansile ("pushing" type tumors) and some could be easily differentiated from the more invasive, infiltrating tumors.

Radiation Effects. Five thousand R specimens frequently showed marked destruction of tumor with dense lymphocytic and plasma cell infiltrate and replacement by fibrous tissue. "Ghosts" of previous tumor cells were noted in both 2000 and 5000 R specimens. The small cell infiltrate and the fibrosis were less marked in the 2000 R cases, while "ghost" tissue of tumor was more marked in these same specimens. Small islands of isolated carcinoma surrounded by fibrous tissue were noted frequently in the 5000 R specimens. The 2000 R cases failed to show the same diminution of recognizable carcinoma in the majority of instances.

The larynges that received the more intense therapy frequently showed massive edema and fibrosis. The 2000 R specimens showed similar changes to a definitely lesser degree; however, in the nodes examined, a frequent finding in both groups was replacement of carcinoma by fibrous tissue which followed the same architecture of carcinoma (sheets and whirls), but without carcinomatous cells.

Histocytic giant cells were found in many sections but were not a consistent finding in each specimen. These giant cells were much like those described by Goldman et al.[3] and were found surrounding destroyed cancer cells. Apparently they function to remove the

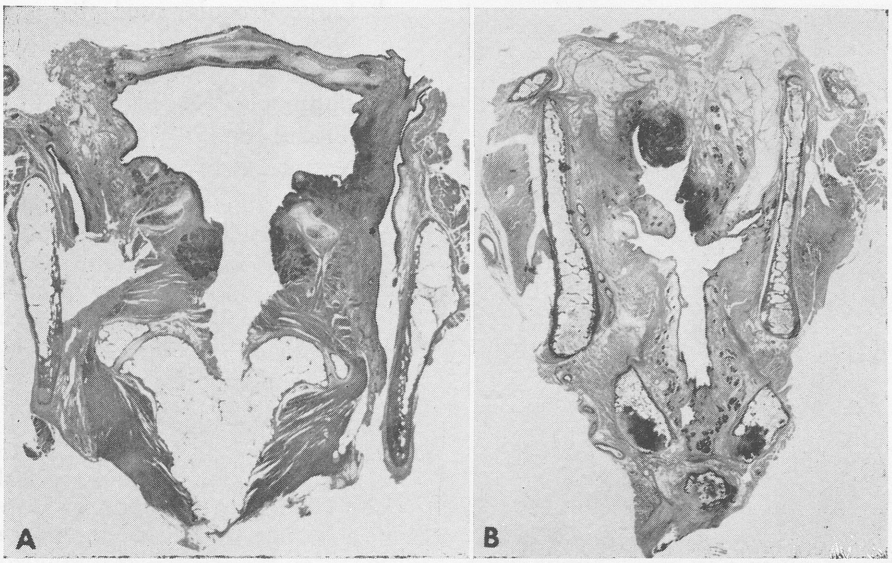

Fig. 5.—Individual sections in two cases showing residual tumor in different areas of the larynx. A) A posterior section showing persistent tumor at the cricoid region. B) Section anteriorly showing the true and false cords with persistent tumor at the base of the epiglottis and right false cord.

debris of the disintegrated tumor cells. Large infiltrations of lymphocytes and then plasma cells precede the proliferation of fibroblasts in adjacent areas. Tumor giant cells and syncytial carcinoma were infrequent (Fig. 7).

Occasional reversion of carcinomatous epithelial cells deep within the stroma to a more well differentiated epithelium was seen. This gave the illusion of normal epithelium deep in the stroma, beyond areas where tangential sectioning might account for this effect. The significance of this is not clear.

Radiation often produced lymph node changes such that on cursory examination, reticulum cells and marginal sinus cells could be mistaken for carcinoma. Careful scrutiny was needed to identify these cells as part of the reticular stroma of the node.

Squamous metaplasia of the epithelium of the laryngeal and tracheal glands and ducts has been described by others and was not an uncommon finding in our cases. Whether or not this is secondary to radiation is not possible to determine without thorough study of a control group of nonradiated carcinomas.

During and following the sloughing of the tissue detroyed by radiation, the surviving epithelial cells proliferated rapidly in the healing process. Cellular changes reflecting this rapid growth are expressed in coarsely granular chromatin, large nucleoli, nuclear pleomorphism, enlargement, multinucleation and variation in the cell sizes and shapes. All these features may create serious difficulties in differentiating these regenerating cells from persisting tumor cells.

The masses of tumor cells show mainly degenerative changes. Marked swelling of the nuclei and cytoplasm accentuates their abnormal morphology. Bizarre forms or groupings are common. Multinucleation of the cells is increased. Tissue necrosis resulting from radiation therapy elicits a massive histiocytic response (Fig. 8).

Effects of irradiation are expressed in the atrophic changes of the epithelium, decreased number of epithelial layers, absence of mitosis, liquefaction, degeneration of some epithelial cells,

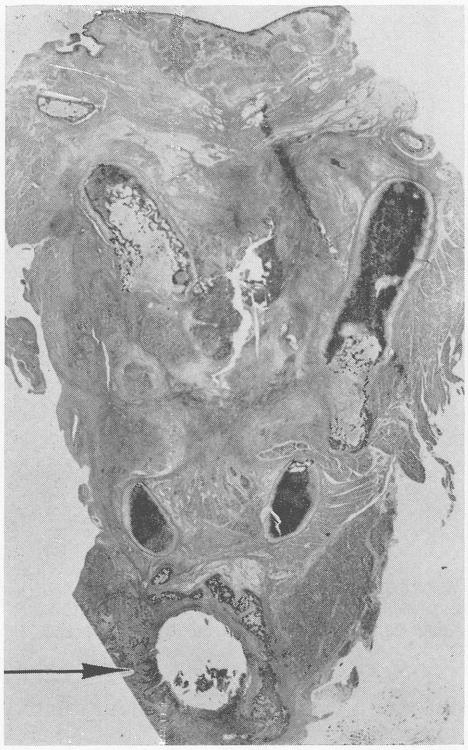

Fig. 6.—Anterior section in one patient whose serial sections revealed invasive carcinoma about the tracheal stoma (arrow) separate from the large invasive carcinoma superiorly.

and abnormal enlarged nuclei. Edema may obscure the appearance of intercellular bridges. The submucosa, also, shows edema with fibrosis and inflammatory infiltrate in the stroma.

1. Radiation changes of benign cells
   a. Enlargement of the cells
   b. Pleomorphism of cells and nuclei
   c. Many bizarre forms
   d. Vacuolization and homogenization of cytoplasm
   e. Vascuolization of nuclei
   f. Disintegration of chromatin network
   g. Large nucleoli
2. Radiation changes of malignant cells
   a. Remarkable nuclear monstrosities
   b. Hydropic generation of nuclei
   c. Enlargement of the cells and nuclei
   d. Large irregular nucleoli
   e. Alteration of staining reaction
   f. Increased number of multinucleated cells
   g. Bizarre forms
   h. Necrotic debris
   i. Histiocytic response

Preoperative Clinical Assessment Versus Histologic Tumor Extent in Serial Sections. Serial sections affirmed the fact that even a detailed clinical definition of tumor extent does not accurately correlate with the histopathologic tumor boundaries. Eight of the 54 patients demonstrated a histologic pattern which could have been treated by less than total laryngectomy. It is apparent that despite good indirect or direct inspection of the larynx and thorough x-ray studies, tissue edema and submucosal spread of tumor renders precise tumor margins indistinct. This supports the laryngic descriptive discrepancy documented by Lederer.[6] Particularly difficult to evaluate accurately preoperatively are tumors involving the anterior larynx, with penetration through cartilage into the pre-epiglottic space, glottic tumors extending below the level of the true vocal cords to the subglottic area as well as pyriform sinus, and false cord tumors that invade the paraglottic region and spread downward in the deep layers of the larynx.

DISCUSSION

Although our purpose is not to demonstrate clinical differences in survival and cure, there was little difference between the 2000 R and 5000 R groups. Ten of 26 patients who had clinically negative neck nodes were found to have histologically positive nodes. Of 28 patients who were felt to have clinically positive nodes prior to radiation therapy, 18 did in fact have histologically positive nodes in their specimens, and in the remaining 10 no positive nodes were found. This may be accounted for by the presence of inflammatory nodes clinically, suggesting metastatic disease, failure to identify all nodes in the specimen, and/or the conversion of positive nodes into negative nodes by irradiation therapy.

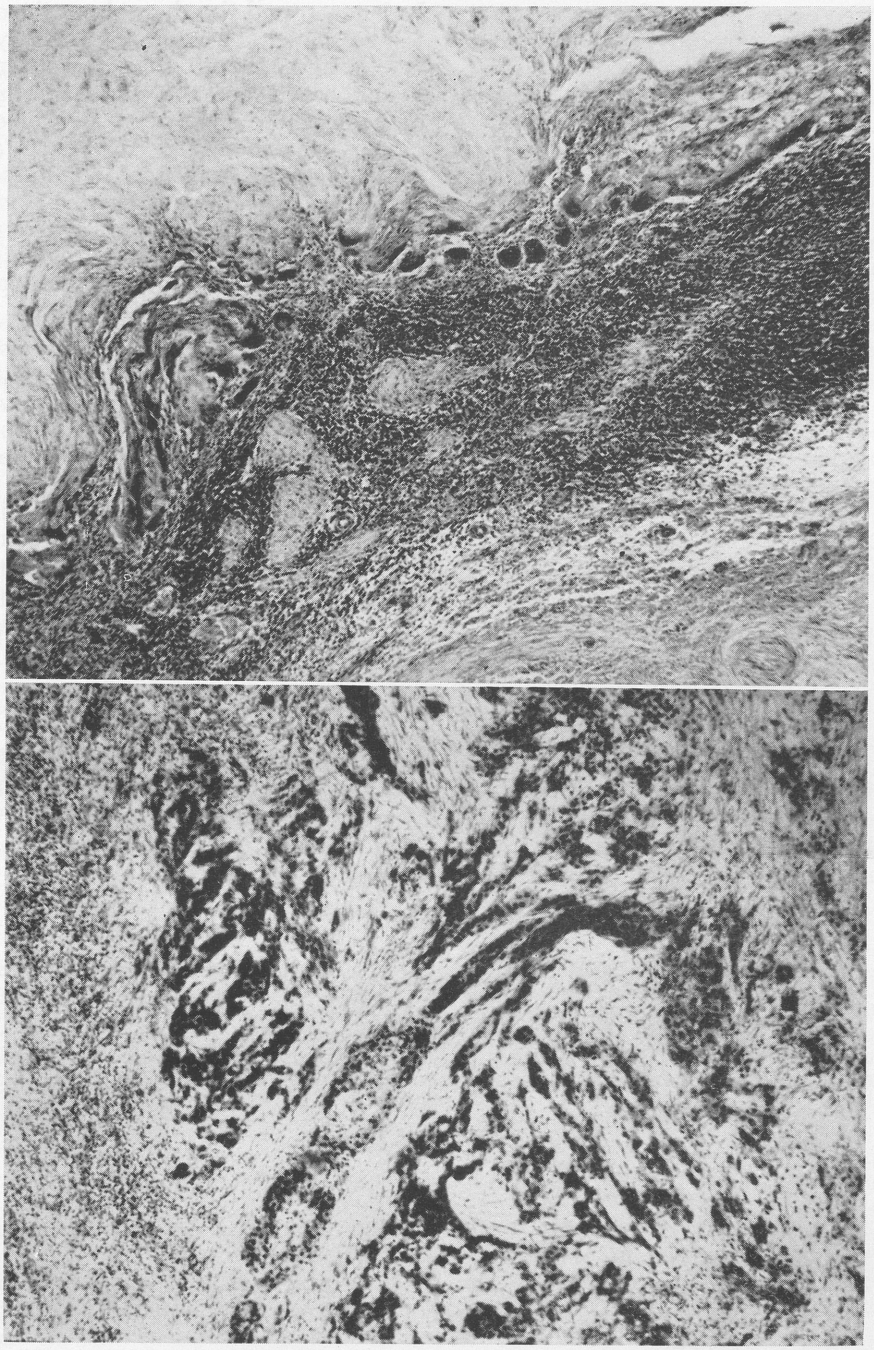

Fig. 7.—High power view of tissue response to tumor invasion after irradiation therapy. Slide shows necrosis of tumor, a zone of dense lymphocytic infiltration and many multinucleated giant cells.

Fig. 8.—Changes in tumor masses and stroma commonly found after irradiation therapy. Tumor cell outlines appear more indistinct and the stroma shows a marked fibroblastic response.

Three cases of second primary carcinomas were identified. Two patients developed primary bronchogenic carcinoma following laryngectomy, and one patient had previously been treated for a base of tongue carcinoma prior to the development of a second primary in the larynx.

Serial sections demonstrated a less extensive procedure might have eradicated the tumor in eight instances, but in most other cases tumor was far more extensive than could be determined clinically. Therefore, we do not advocate performing a partial conservation procedure if the preradiation clinical evaluation does not justify it, no matter what the post-irradiation clinical picture demonstrates.

Predictions as to where tumor recurrence was likely could be made in those patients whose specimens revealed inadequate tumor margins. Unfortunately, these predictions were substantiated by review of the clinical records. Stomal recurrence, anterior neck recurrence, base of tongue recurrence, and pharyngeal recurrence could be anticipated in these patients in whom there was tumor at or near the specimen margins. Neck recurrences were seen in patients with anterior laryngeal lesions which had penetrated the thyroid cartilage or lesions which had crossed the thyrohyoid and cricothyroid membranes. Stomal recurrence was evident in those patients whose specimens showed carcinoma invading the subglottic and tracheal submucosal tissues. It was seen on one occasion that carcinoma existed in a previously performed tracheotomy in which there was no apparent histologic connection with the laryngeal carcinoma above (Fig. 6).

Our study of the serial sections of the larynges of patients treated by irradiation and surgery confirms many of the findings of other investigators in this field. Irradiation effects are variable from patient-to-patient, vary with the dosage applied and may even differ from one site to another in the individual patient. The location and extent of advanced tumors of the larynx often cannot be accurately assessed clinically so that wide resection is essential if better results are to be obtained.

Serial section study provides one means of accurate detailed evaluation of the spread and extent of carcinoma of the larynx, and correlation with clinical results may help improve results of treatment.

1855 West Taylor, Chicago, Illinois 60612.

Acknowledgment—The authors acknowledge with grateful thanks the invaluable assistance of Mrs. Maria Ikenberg in the preparation of illustrative material, and the technical work of Miss Fannie L. Billups of the laboratories of the Department of Otolaryngology, Abraham Lincoln School of Medicine of the University of Illinois at the Medical Center, Chicago, in the preparation of the serial sections for this study. We wish also to thank Mr. Paul Burlakow, Patho Technologist of the Oral Diagnosis Department, College of Dentistry of the University of Illinois at the Medical Center.

REFERENCES

1. Alexander FW: Micropathology of radiation reaction in the larynx. Ann Otol 72: 831-841, 1963

2. Goldman JL, Silverstone SM: Combined radiation and surgical therapy for cancer of the larynx and laryngopharynx. Trans AAOO 496-507, 1961

3. Goldman JL, Cheren RV, Zak FG, et al: Histopathology of larynges and radical neck specimens. Ann Otol 75: 313-335, 1966

4. Goldman JL, Silverstone SM, Rosin HD, et al: Combined radiation and surgical therapy for cancer of the larynx and laryngopharynx. Trans Amer Laryng Rhinol Otol Soc 602-625, 1964

5. Kirchner JA: One hundred laryngeal cancers studied by serial section. Ann Otol 78: 689-709, 1969

6. Lederer FL: Laryngic descriptive discrepancy. Ann Otol 72: 396-415, 1963

7. Tucker G, Jr: Some clinical inferences from the study of serial laryngeal sections. Laryngoscope 73: 728-748, 1963

DISCUSSION

JOHN A. KIRCHNER, M.D.: I think Dr. Soboroff has come a long way with these sections. I have been in this field myself for a bit and we have sectioned over 150 laryngeal specimens now, removed for cancer, and those of you who have not done this work could scarcely appreciate how much care and attention it takes on the part of the investigator. You can't just turn this over to the technician. She can do the color, the beautiful color that you saw here, but orienting the specimen so that, for instance, you get the tip of the vocal process on each side calls for more than technical assistance.

I am glad also to see that his conclusions are paralleling those that we are coming up with and that the idea of something less than total laryngectomy is emerging from this work. Many cases should have had conservation surgery.

The supraglottic lesions—and I would like to ask you specifically about this one— I think I heard a statement that some of the supraglottic lesions invaded the thyroid ala. I also reported this last year in our series and in going back over these I found that the only supraglottic lesions that invade the thyroid ala are those that cross at the anterior commissure, at the petiole of the epiglottis. Now, you still, I suppose, call these epiglottic lesions. I don't know what to call them if most of the epiglottis is destroyed and the lower end happens to cross at the anterior attachment of the vocal cords, but unless this happens the thyroid ala in none of our specimens has ever been invaded. The epiglottis may be completely destroyed, the pre-epiglottic space may be full of cancer, but there is no invasion of the thyroid ala if the anterior commissure is not crossed. The concept of supraglottic laryngectomy is still a sound concept as we go through our sections.

The one other point I would like to make is that the infraglottic, or subglottic extension of tumor below cord is something that is very significant and is associated in a very high degree of cases with invasion of the cricoid cartilage and the lower edge of the thyroid ala and the reason I bring this out is that any operation that requires stripping the external perichondrium off the thyroid ala is a dangerous procedure. You will get stomal recurrences, I am afraid, and when you see a cord lesion or an epiglottic lesion that has crossed at the commissure in a vertical dimension and gone below it, I think any procedure that is designed in a way that the external perichondrium has to be stripped back, I am afraid you are going to be in trouble.

DR. SOBOROFF (closing): We would be in agreement on the place that the supraglottic conservation procedure still maintains, that epiglottic lesions may be limited in that way and not invade the thyroid cartilage. The protocol for combined irradiation therapy and surgery was set up for advanced lesions and so this series is a study of T-3 and T-4 lesions, many of which were deeply invasive and were at the base of the epiglottis and false cord and invaded into the thyroid cartilage.

A CORRELATION OF CLINICAL STAGING, PATHOLOGICAL FINDINGS AND FIVE YEAR END RESULTS IN SURGICALLY TREATED CANCER OF THE LARYNX

CHARLES M. NORRIS, M.D. GABRIEL F. TUCKER, JR., M.D.

BURNS F. KUO, M.D. WILLIAM F. PITSER, M.D.

PHILADELPHIA, PA.

Shortly after the presentation of the basic coronal section methodology to the American Laryngological Association nine years ago, it was decided to relocate our studies at the Department of Laryngology and Bronchoesophagology, Temple University, (The Chevalier Jackson Clinic).

In anticipation of the move, surgical specimens were saved for coronal sectioning from January of 1942. In 40 months 100 laryngeal carcinomas were received in the laboratory for processing by the technique brought from Johns Hopkins.

Five years have now elapsed since the surgical removal of the one hundredth carcinoma. We are now in a position to present a study which measures the significance of clinical and laboratory findings against the ultimate yardstick, patient survival.

LABORATORY PROCESSING

The most significant variation from the previously published routine[9] was the decision to open the resected specimen and photograph the mucosal presentation of the lesion. This was originally done to preserve the continuity of the collection of specimen photographs established in the Jackson Clinic. Its value in providing an exact record of the specimen as it appeared to the operating surgeon has proven itself.

Thus, by serially sectioning (25μ) each nitrocellulose-embedded specimen and staining every fortieth section, a tracer series was obtained in which each section studied was one mm distant from its neighbor. Each specimen thus yielded 30 to 40 coronal sections for detailed study.

The only larynx brought from the Hopkins laboratory, a single normal specimen in a serial coronal tracer series, provided the basis of a working atlas of coronal section laryngeal anatomy. This anatomic guide was in turn used to chart the location of cancer within the specimen studied. Also of value was the uninvolved portion of any given specimen since it was readily available for comparison (within the limits of symmetry and distortion by tumor) with its mirror image in the same coronal section.

ANATOMIC CONCEPTS

The involvement of a specific anatomic structure has been tabulated in accordance with the relationship of that

---

From the Department of Laryngology and Bronchoesophagology (The Chevalier Jackson Clinic), Temple University Health Sciences Center, Philadelphia, Pennsylvania.

This study was supported by NIH Grants Nos. C6206, CA 10464 and CA 06743.

TABLE I

EXTENSION BEYOND SUBMUCOSA WITHIN THE LARYNX

Total			Degree					
			P_2		P_3		P_4	
No. Cases	% 5 yr. Survival		No. Cases	%	No. Cases	%	No. Cases	%
		ANTERIOR TO LARYNGEAL LUMEN						
		Supraglottic						
19	73	Epiglottic Cartilage	3	100	10	80	6	50
26	73	Pre-Epiglottic Space	1	100	13	92	12	50
6	83	Hyoepiglottic Ligament	0	0	1	100	5	60
		Glottic						
31	39	Anterior Commissure Tendon	2	100	12	50	17	23
23	44	Thyroid Cartilage (Ant.)	0		7	86	16	25
		Subglottic						
30	43	Ant. Subglottic Submucosa	2	100	10	60	18	28
24	38	Cricothyroid Ligament	0		7	58	17	29
17	35	Cricothyroid Muscle (Med)	0		3	67	14	28
5	20	Cricothyroid Node	0		2	0	3	33
		LATERAL TO LARYNGEAL LUMEN						
41	66	Quadrangular Membrane	2	100	24	75	15	40
41	51	Ventricular Ligament	1	100	22	61	18	33
31	36	Thyroglottic Ligament	1	100	14	50	16	19
43	44	Reinke's Space	6	83	18	50	19	26
39	41	Vocal Ligament	3	100	17	53	19	21
29	34	Space of Pressman	0		11	45	18	28
35	37	Conus Elasticus	2	100	14	36	19	32
19	47	Arytenoid Cartilage (body)	1	100	9	67	9	22
67	58	Paraglottic Space	6	100	37	65	24	38
48	50	Vocalis Muscle	4	100	24	58	20	30
32	44	Thyroarytenoid Muscle (Lat)	0		15	67	17	24
14	29	Cricothyroid Muscle (Lateral)	0		3	67	11	18
37	43	Cricoarytenoideus Lateralis M	0		20	60	17	23
20	60	Pyriform Submucosa	1	100	8	88	11	37
12	50	Thyrohyoid Membrane	0	0	2	100	10	40
12	25	Thyroid Cartilage (Lateral)	0		0		12	25
22	36	Cricoid Cartilage	0		7	58	15	27
15	33	Cricoarytenoid Joint	0		7	58	8	13
2	0	Cricothyroid Joint	0		0		2	0
		POSTERIOR TO LARYNGEAL LUMEN						
10	40	Interarytenoideus Muscle	0		3	67	7	29
15	40	Space Under Interarytenoideus Muscle	0		4	50	11	36
7	29	Cricoarytenoideus Posticus Muscle	0		3	67	4	0
10	30	Post Cricoid Submucosa	0		2	50	8	25

structure to the laryngeal lumen (Table I). The normal atlas which delineates the detailed anatomic relationships is to be published elsewhere and, therefore, only a few of the less familiar terms will be summarized here.

Those unpaired structures listed as anterior to the laryngeal lumen are in fact not anatomically bisected in the midsagittal plane. Especially to be

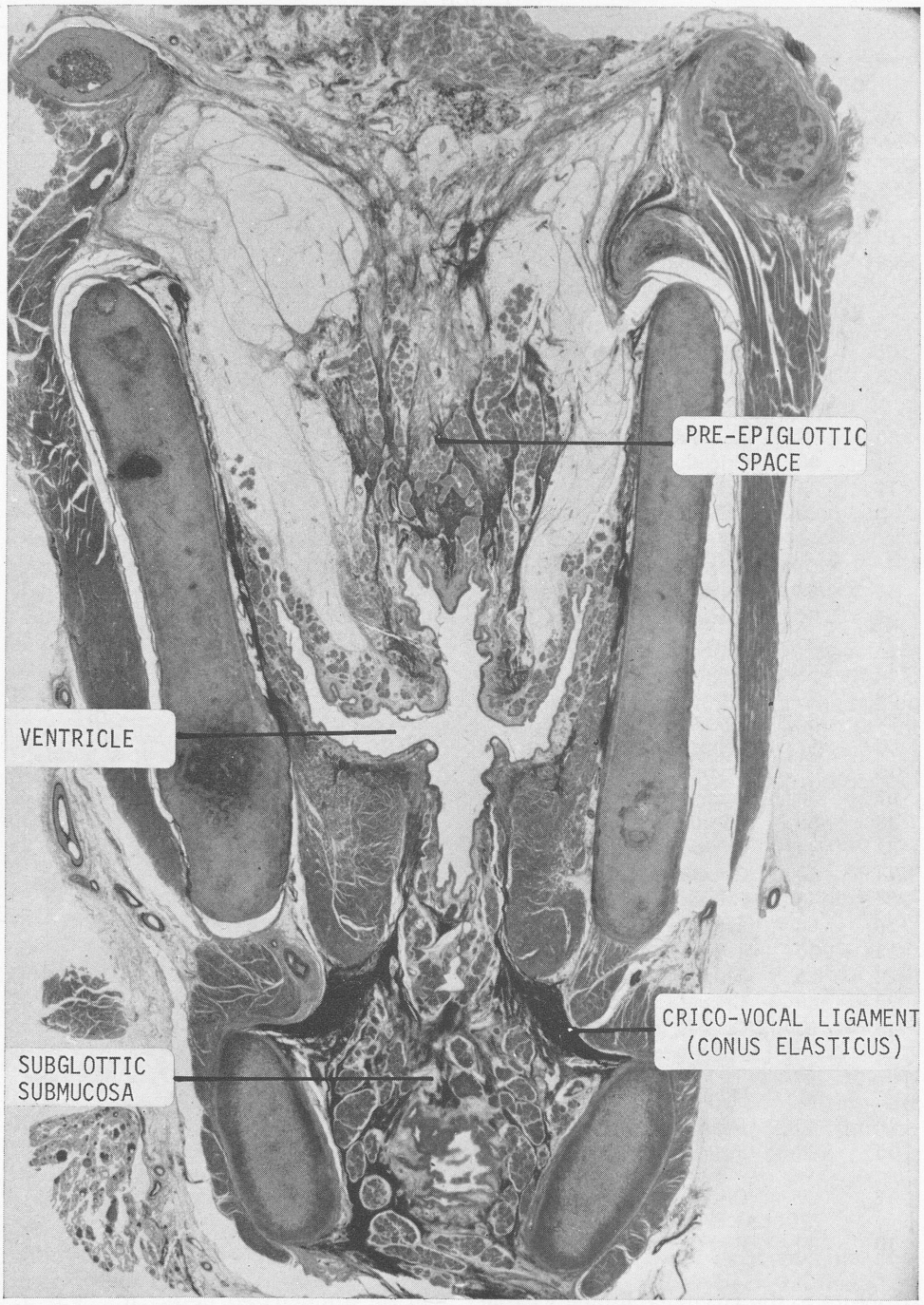

Fig. 1.—Coronal section of the larynx, just behind the cricothyroid membrane anteriorly.

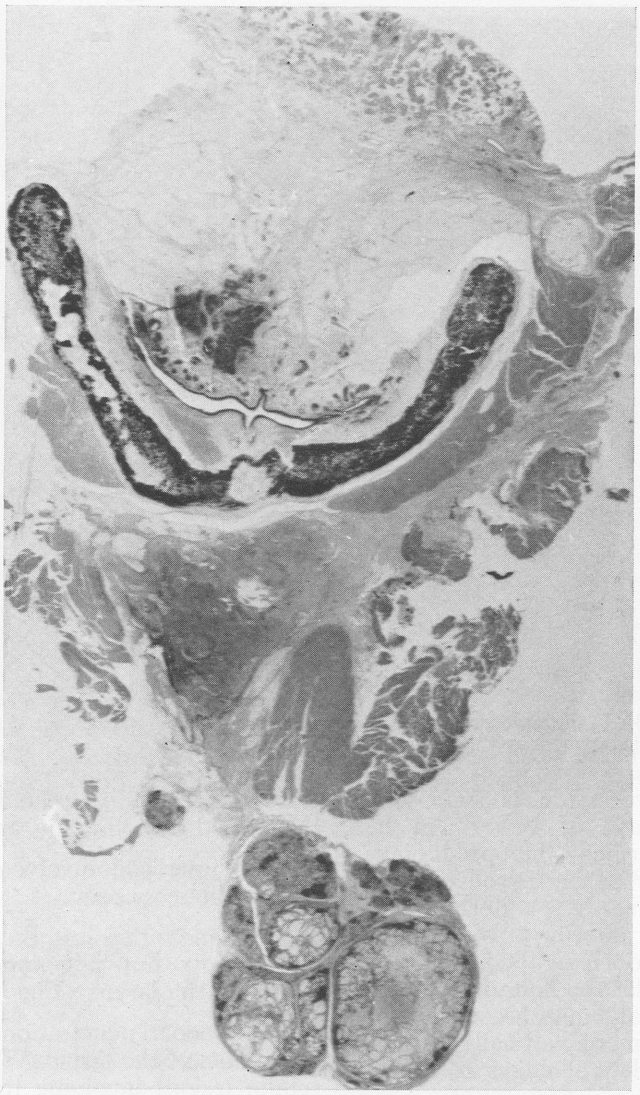

Fig. 2.—P_2 supraglottic tumor just above the anterior ventricular commissure dissecting forward from the medical face of the false cord.

noted in this regard are the epiglottis, pre-epiglottic space, cricothyroid membrane, and the anterior subglottic mucosa and submucosa (Fig. 1).

The concept of the paraglottic space has been previously presented.[10,11] Since the glottis is an aperture bounded by vocal mucosa, there is no anatomic basis for extending the glottis beyond the mucosa. Those structures lateral to the glottis have, therefore, been grouped in a "paraglottic" space bounded by the conus elasticus, quadrangular membrane, pyriform submucosa, and the thyroid ala.

The endocricoid area bounded by the cricoid cartilage, the conus elasticus, and the fibroglandular layer under the subglottic submucosa, was first described by Pressman as the "cricoid area";[7] it is thus designated as the "space of Pressman."

The pre-epiglottic space has been variously described; a number of de-

Fig. 3.—P_3 supraglottic tumor occupies the pre-epiglottic space but is well clear of the hyoepiglottic ligament and the thyroid cartilages.

scriptions have made is synonymous with the "space of Boyer", in fact, Boyer[1,2] described the pre-laryngeal bursa, anterior to the thyrohyoid membrane. In this study it is defined as the midline space anterior to the epiglottis bounded superiorly by the hyoepiglottic ligament (under the floor of the vallecula); its lateral limits are those fibers which travel more vertically from the hyoid to the lateral edges of the epiglottis.

The thyrohyoid membrane is included as a part of the larynx. The thyrohyoid muscles are, however, classified as extra-laryngeal. Tumor involving the lateral portion of the cricothyroid muscle is not considered as confined to the larynx.

In an attempt to quantitate the pathologically demonstrable extent of a lesion perpendicular to the mucosa, the following "P" stages were devised (without limitation by primary site).

P_0: No tumor found; only one case fell into this category treated by planned combined radiotherapy and surgery.

P_1: Superficial involvement; mucosa and submucosa only.

P_2: Penetration into the substance of the larynx but not approaching the limits of the larynx (Figs. 2, 5 and 8).

P_3: Deeper penetration approaching the limits of the larynx. This would include lesions involving the submucosa of the valleculae, pyriform sinuses and postcricoid laryngopharynx (Figs. 3, 6 and 9).

P_4: Extension beyond the larynx (Figs. 4, 7 and 10) to include the above mucosal areas also the trachea, tongue, constrictor and strap muscles. Also included in this group are those lesions which penetrate through the thyroid or cricoid cartilages and the thyrohyoid membrane and cricothyroid membrane or muscle (lateral, Table II).

It should be further noted that the specific involvement of any one sub-

TABLE II

EXTRA-LARYNGEAL INVOLVEMENT (27 CASES)

	No. Cases	*%5 Yr. Survival*
Vallecula	4	75%
Pyriform Mucosa (Med)	0	
Pyriform Mucosa (Lat)	0	
Trachea	5	20%
Esophagus	0	
Party Wall	8	25%
Postcricoid Mucosa	3	33%
Constrictor Muscles	4	25%
Strap Muscles	13	23%
Thyroid Gland	7	14%
Anterior Extension Through Cricothyroid Membrane	2	50%
Through Anterior Thyroid Cartilage	2	50%
Through Lateral Thyroid Cartilage	4	50%
Paratracheal Node	1	0%
Lateral Cricothyroid Muscle	1	0%
Base of Tongue	2	100%

mucosal structure, as tabulated in Table I, correlates best with survival when the lesions are tabulated by degrees of submucosal extent (i.e. "P").

PRELIMINARY STUDIES

Early in 1968 at the request of the American Joint Committee Task Force on Larynx 200 consecutive primarily treated laryngeal carcinomas seen at Temple prior to August 1963 were tabulated on an experimental protocol and submitted. The computerized experimental clinical staging of these cases is not yet available from the Task Force, but the submitted figures were reviewed. Availability of material from these cases to the laboratory is summarized in Table III.

TABLE III

TREATMENT	NO. CASES	PARAFFIN	NITROCELLULOSE
Radiotherapy	79	0	0
Partial Laryngectomy	35	33	2
Laryngectomy and LgND	84	0	34

TABLE IV

PARTIAL LARYNGECTOMY

From Paraffin	*No. Cases*	*%5 yr. Surv.*
P_1	13	100
P_2	15	93
P_3	5	100
P_4	1	0
Total	34	94

The radiotherapy cases were, of course, not available for detailed pathologic study. Partial laryngectomy specimens are routinely embedded in paraffin; thus, at least selected paraffin sections were available to provide a basis for tentative pathologic staging (Table IV). Of the original 200 cases submitted to the Task Force less than 40 determinate cases had been processed in nitrocellulose and were thus available for detailed pathologic review and staging.

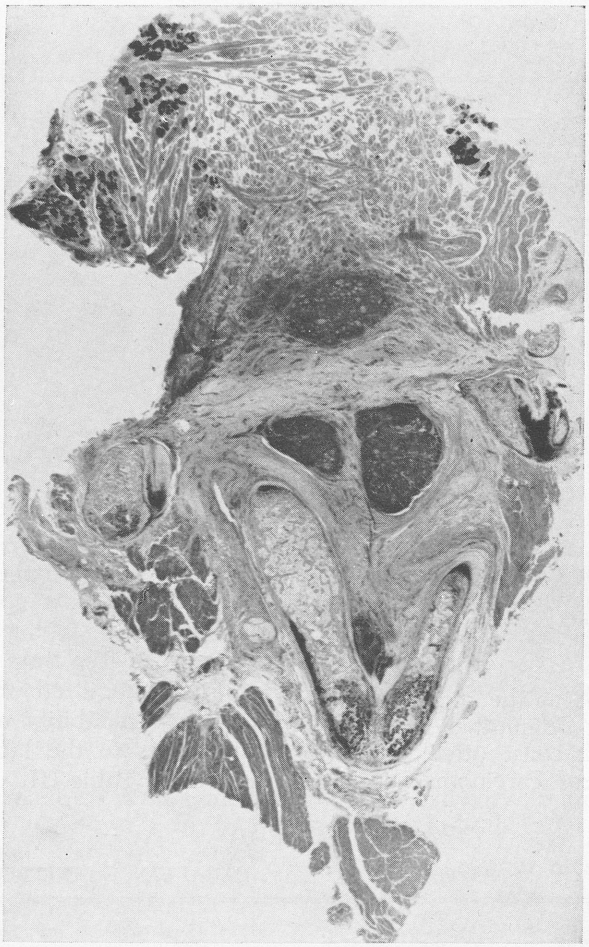

Fig. 4.—P_4 supraglottic tumor can be seen deep in the thyroid notch just inside the thyroid ala. It is also seen just below the hyoepiglottic ligament and again just above the hyoepiglottic ligament in the base of the tongue.

Perusal of this data (Table V) suggested an increased correlation between pathologic staging and follow-up, as compared to the relationship between the conventional "T" values and patient survival. It was hoped that by emphasizing those lesions which were relatively more extensive and thus had a lesser patient survival, the relationship between these parameters would be more readily demonstrable.

SELECTION OF CASES

During the 40 months (January 1962 through April 1965) 157 laryngeal carcinomas were treated surgically and 118 laryngeal cases were treated by radio-

TABLE V

T	No. Cases	%5 yr. Surv.	P	No. Cases	%5 yr. Surv.
1	1	100	1	0	
2	6	67	2	5	100
3	26	65	3	19	65
4	3	67	4	12	50

TABLE VI
PRE-TREATMENT DATA (100 CASES)

AGE	Under 40		1
	41-50		14
	51-60		42
	61-70		36
	71-80		6
	81-90		1
	TOTAL 38-86		100
SEX	Male		90
	Female		10
RACE	White		99
	Non White		1
	Yes	No	
TOBACCO	93	7	
ALCOHOL	75	25	
NEITHER		4	
BIOPSY			
	Well Differentiated		39
	Moderately Well		55
	Poorly Diff.		5
	Spindle Cell		1

CLINICAL STAGE			
T_1 (and 1 insitu)			6
T_2			20
T_3			58
T_4			13
T_4 (Pyriform)			4
SUPRAGLOTTIC			43
GLOTTIC			47
SUBGLOTTIC			6
VOCAL CORD MOTION			
Impaired or unknown			37
Fixed			35
PALPABLE NODES			19
PRE-OP TRACHEOTOMY			20
Elective Pre-Partial	3		
Previous Partial	6		
PLANNED PRE-OP RADIATION			3
RADIATION FAILURES			15
SURGERY: Lg			44
LgND			51
Partial Lg			5

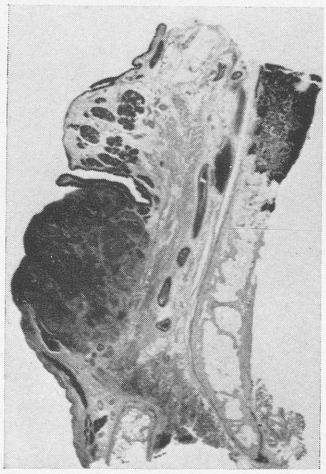

Fig. 5.—P_2 glottic tumor has replaced the vocalis muscle. Is well into the inferior portion of the paraglottic space but is well clear of the outer limits of the larynx.

therapy. Case selection was limited primarily by the laboratory's ability to process larynges at a rate of 20 to 25 specimens per year. Quality of preservation, specimen photography, and adequacy of presurgical radiographs all played a part in the decision to process a particular specimen in the research laboratory. Laryngeal carcinomas were preferred over laryngopharyngeal lesions; only four lesions primary in the pyriform sinus were included in the initial 100. Five partial laryngectomy specimens were included. Also included were some cases in which there was prior initial treatment. The pretreatment data are summarized in Table VI. It should be re-emphasized that the data presented herein are primarily for the purposes of this study; close comparison with other more rigorously controlled patient populations (i.e. the 200 consecutive primarily treated cases mentioned in the preliminary study) would in all likelihood be misleading.

DETAILED ANALYSIS OF CASES

In 1965 an exhibit was presented[1,2] demonstrating the disparity between the mucosal presentation of a tumor and its true soft tissue extent in a number of cases. While reviewing these cases Dr. Joel Pressman suggested that the data should be recorded on punched cards for analysis. Incorporating a number of valuable suggestions by Kirchner,[5] whose data was presented last year, a protocol was drawn up incorporating the clinical, pathologic and follow-up data on cards containing 88 double punched entries. Pre-treatment data which constitute the basis of therapy have been tabulated (Table VI). Assignment of "T" values has been in strict accordance with the criteria published

Fig. 6.—P_3 glottic tumor extends down the medial face of the cord to involve some subglottic mucosa; its greatest bulk, however, seems to lie paraglottic as the ventricle is obliterated. Tumor is lateral to the false cord and approaching the internal perichondrium of the thyroid cartilage.

for the TMN System,[8] without regard for data accumulated in the research laboratory.

Determinate Cases (81). All cases were followed five years. Fifteen patients, dead of other causes within this period, are thus excluded. Also excluded are the four cases with primary pyriform lesions which are by TMN definition beyond the larynx.

The correlation shown in Table VII is elaborated in more detail in Table

TABLE VII
COMPARISON OF "T" AND "P" VALUES WITH % SURVIVAL (81 CASES)

Degree	*0*	*1*	*2*	*3*	*4*	
T		60	73	58	62	AVERAGE 62
P	100		92	66	41	

TABLE VIII

NO. DETERMINATE CASES INVOLVED AND PERCENT SURVIVAL WITHOUT DISEASE

Location	T_1		T_2		T_3		T_4		*Total*	
SUPRAGLOTTIC	4	75%	7	86%	20	70%	9	67%	40	75%
GLOTTIC	1	0	8	62	24	34	2	50	35	49
SUBGLOTTIC					4	50	2	50	6	50
TOTAL	5	60	15	73	48	58	13	62	81	62
	P_0		P_1		P_2		P_3		P_4		*Total*	
SUPRAGLOTTIC	1	100%			5	100%	23	78%	11	55%	40	75%
GLOTTIC					6	84	16	56	13	23	35	49
SUBGLOTTIC					1	100	2	0	3	67	6	50
TOTAL	1	100			12	92	41	66	27	41	81	62

VIII. The superior correlation of cases classified by degree of deep extent with survival over the standard "T" is obvious. Could the increased correlation thus obtained from "P" values be due to an incorrect or inaccurate application of the TMN system?

To test this hypothesis "corrected" "T" values were assigned using the retrospective microscopically proven mucosal involvement (Table IX). These are compared with the values found in Table VII.

TABLE IX

MUCOSAL INVOLVEMENT

(81 Determinate Cases)

Cases Primary in This Site			*All Cases Involving This Site*	
No. Cases	*%5 Yr. Survival*		*No. Cases*	*%5 Yr. Survival*
		SUPRAGLOTTIC (Anterior)		
0		Epiglottis - tip	3	67
23	83	Epiglottis - Laryngeal Surface	35	74
0		Anterior Ventricular Commissure	29	48
		(Lateral)		
7	100	Aryepiglottic Fold	29	72
2	100	Ventricular Band	48	60
18	50	Ventricle	41	51
0		Saccule	11	73
		GLOTTIC		
3	33	Anterior Commissure	42	48
0		True Cord Free Edge	40	48
1	0	True Cord Superior Face	41	46
19	47	True Cord Medial Face	38	42
0		Arytenoid - Vocal Process	40	45
0		Arytenoid - Medial Face	37	38
0		Posterior Commissure	13	39
		SUBGLOTTIC		
0		Anterior Subglottic	27	41
7	57	Lateral Subglottic	31	42
1	100	Posterior Subglottic	9	33

The corrected "T" values (Table X) do not significantly change the original clinically designated "T". It might even be suggested that such a retrospective evaluation tends to confirm the accuracy of the clinically derived "T".

TABLE X

Degree	0	1	2	3	4
T	–	60	73	58	62
T Corr.	50	100	78	50	67
P	100	–	92	66	41

The high correlation (Table XI) between local recurrence and primary disease beyond the larynx (P_4) should be especially noted. This in turn would seem to suggest that, even if grossly adequate, surgical margins may have been in fact inadequate. Such margins are not in the usual sense merely mucosal but involve again a consideration by the surgeon of possible extension into those soft tissues which will be used to construct the hypopharyngeal closure and the tracheostome.

TABLE XI

ANALYSIS OF TREATMENT FAILURES (81 CASES)

25 Dead of Disease

T_1	T_2	T_3	T_4	*Cause*	P_2	P_3	P_4
0	1	6	1	Distant Metastases	0	5	3
1	0	9	2	Local Recurrence	0	1	11
0	1	3	1	Uncontrolled Neck Nodal Metastases	0	3	2
				6 LIVING			
1	2	1	1	Secondary Neck Nodes (all alive and well with further treatment)	1	4	0
0	0	1	0	Local Recurrence (4½ yr) alive with disease		1	0

The survival of those cases with epiglottic involvement (Table XII) would seem to mitigate against the common practice of lumping together all cases of "cartilaginous involvement". It should also be noted that the ossified cricoid and thyroid "bone" were involved by tumor, never cartilage. The predisposition of such ossified cartilage to become involved, even by metastatic breast tumor, has been previously reported by Ellis.[3]

TABLE XII

INVOLVEMENT OF "CARTILAGE"

Epiglottis	19 Cases	90% Survival
Thyroid (Ossified)	30	42%
Cricoid (Ossified)	28	37%

Fig. 7.—P_4 glottic tumor has extended to involve both sides of the subglottic larynx. It has penetrated the right thyroid and cricoid cartilages and extended beyond the larynx at the level of the inferior rim of the thyroid ala.

The increased incidence of local recurrence in those patients requiring preoperative tracheotomy has been noted by Keim[4] and others. Analysis of such cases in the light of "P" values would suggest (Table XIII) that the cause of

TABLE XIII

ANALYSIS OF CASES REQUIRING PRE-OPERATIVE TRACHEOTOMY

Pre-Surgical Tracheotomy (11 Cases)

	No. Cases	*%5 yr. Surv.*		*No. Cases*	*%5 yr. Surv.*
T_3	8	50%	P_3	2	100%
T_4	3	67%	P_4	9*	44%

* 4 dead of local recurrence
1 dead of distant metastases

Fig. 8.—P_2 subglottic tumor involves the mucosa and submucosa of the medial face of the right cord penetrating the right space of Pressman.

such recurrence lies not in the performance of the tracheotomy but in the extralaryngeal extent of the initial lesion. The survival rate of the "P_4" cases requiring tracheotomy (44%) is, however, comparable to the overall "P_4" survival (41%).

GLOTTIC - SUBGLOTTIC INVOLVEMENT

In all the Tables presented, wherein tumor has been designated primarily as glottic, subglottic or supraglottic, this has been done in strict accordance with the TMN practice. However, in examining such Tables it should be noted that glottic cure rates in general are poorer than either the supraglottic or subglottic. Two explanations can be offered for this: 1) the fact that a great percentage of the usual population of primary glottic tumors, which are relatively early and thus treated by radiotherapy or partial laryngectomy, are not subject to this analysis, and 2) if one follows the practice suggested by Norris[6] and reclassifies the glottic lesions by their worst extent, it is found that all the "P_4" glottic lesions become subglottic and all but two of the "P_3" glottic lesions become subglottic.

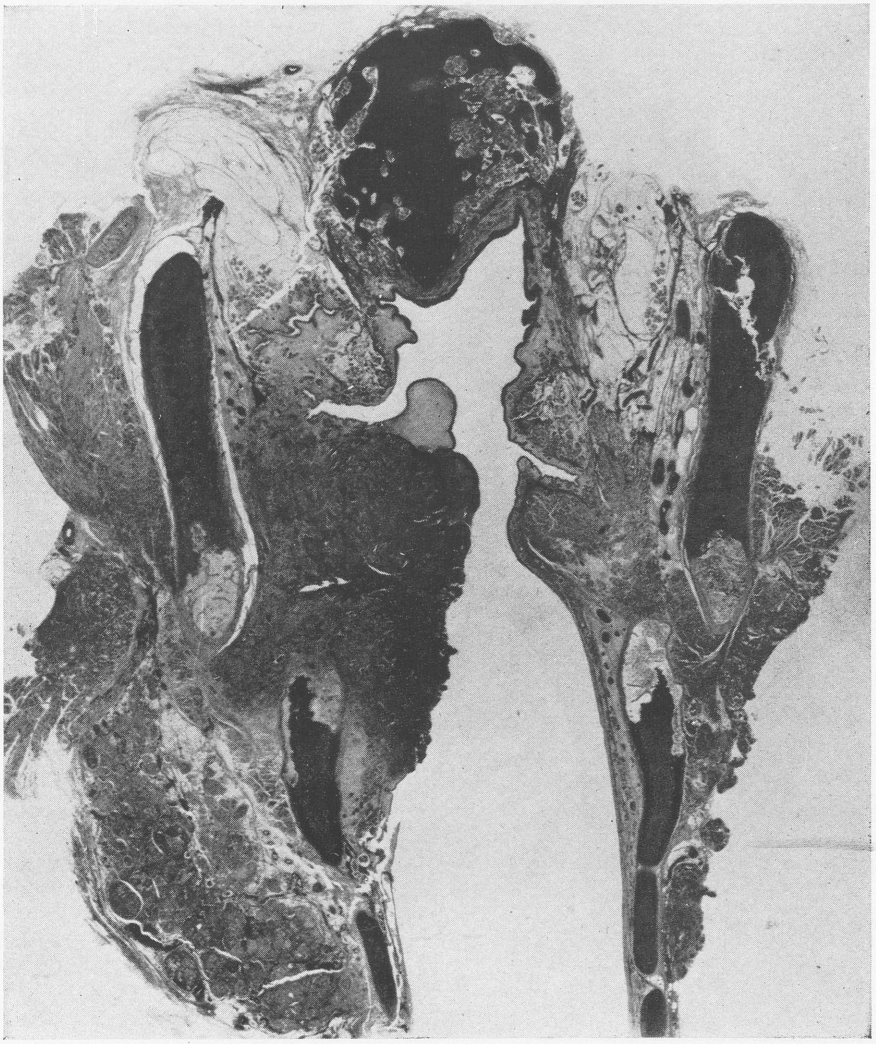

Fig. 9.—P_3 subglottic tumor involves only the upper rim of the cricoid. The ventricular floor and cord edge are displaced intact upward. Tumor approaches the outer rim of the larynx below the inferior rim of the thyroid ala. Comparison with the opposite side suggests that this is the region of the cricothyroid muscle.

SUMMARY

An attempt has been made to quantitate the deep soft tissue extent of tumors studied in serial coronal sections, by assigning a series of increasing "P" values based on the pathologically demonstrable parameter of the tumor perpendicular to the mucosal surface. The data thus collected have been summarized in the published Tables. The more significant of the items tabulated have been further commented upon. A number of items have either not been tabulated or commented upon where the numbers involved seemed too small to provide firm grounds for specific conclusions.

In the data studied the "P" values would certainly seem to correlate much more closely with the clinical course of the cases studied than the conventional "T" values previously in use.

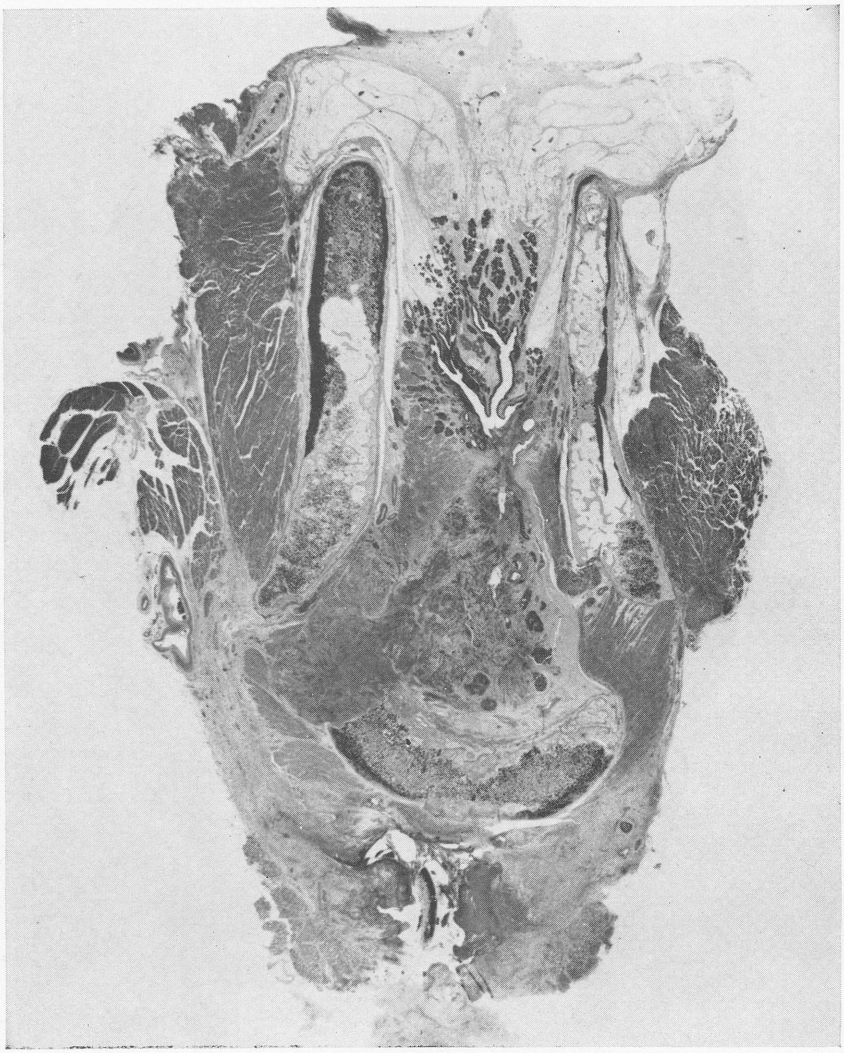

Fig. 10.—P_4 subglottic tumor can be seen penetrating the cricothyroid membrane, also extending through the superior rim of the right portion of the cricoid cartilage into soft tissue.

CONCLUSION

A true appreciation of the deep soft tissue extent of the malignant process is necessary to more precisely evaluate a given cancer.

As our ability to evaluate the clinical and radiographic manifestations of a tumor improves, it is hoped that our system of classification and staging will be extended to embrace the third dimension of the tumor, as it extends deep to the mucosa, and through and beyond the larynx.

One could then hope to plan treatment to encompass all three dimensions of the tumor more adequately.

3401 North Broad Street, Philadelphia, Pa. 19140

Acknowledgment—Dr. Tucker was Principal Investigator on NIH Grants Nos. C6206, CA 10464 and CA06743. Dr. Kuo was a visiting Fellow from the China Medical Board from 1967 to 1969; Doctor Pitser was a visiting Fellow on leave from the State University of New York, Syracuse, 1969 to 1970 and supported by NINDS Grant No. T-01-NB05276.

The full and generous cooperation of the Department of Pathology was essential to these studies. Gross descriptions of the surgical specimen were all recorded within the Department of Pathology. Final review of all sections for the pathologic record was done by Dr. John Yerger who worked with this project continuously as a Resident and later as a member of the full-time staff.

Dr. Augustin R. Peale, Head of the Department of Surgical Pathology was most generous with his help and advice. All problems requiring any final decision had been referred to Dr. Peale. Mr. Rhine Luha, Senior Medical Technologist, was responsible for the direction of the laboratory and the production of all sections used in this study. Mr. Douglas Ditmars, Research Assistant, provided invaluable help in the collation of data; he was of special help as the liaison to the Department of Medical Illustration and overseeing the many details necessary to the preparation of the atlas.

REFERENCES

1. Boyer A: Traite d'anatomie. Fourth Edition, Paris 1815

2. Dobson J: Anatomical Eponyms. Second Edition, E and S Livingstone Ltd., 1962, p. 33

3. Ellis M, Winston P: Secondary Carcinoma of the Larynx. Reports - Institute of Laryngology and Otology, London, 1957-8, pp. 82-90

4. Keim WF, et al: Study of post laryngectomy stomas recurrence. Arch Otolaryng 82: 183-186, 1965

5. Kirchner JA: One hundred laryngeal cancers studied by serial section. Ann Otol 78: 689-709, 1969

6. Norris CM: Problems and classification and staging of cancer of the larynx. Ann Otol 72: 83, 1963

7. Pressman JJ, Simon MB, Monell C: Anatomical studies related to the dissemination of cancer of the larynx. Trans AAOO 64: 628-638, 1960

8. Smith RR, et al: End results of 600 laryngeal cancer using the American Joint Committee's proposed method of stage classification and end results reporting. Surg Gynec Obstet 435-443, Oct., 1961

9. Tucker GF, Jr: A histological method for the study of the spread of carcinoma within the larynx. Ann Otol 70: 910-921, 1961

10. Tucker GF Jr, Smith HR, Jr: A histological demonstration of the development of laryngeal connective tissue compartments. Trans AAOO 308-318, 1962

11. Tucker GF, Jr: Some clinical inferences from the study of serial laryngeal sections. Laryngoscope 73: 728-748, 1963

12. Tucker GF, Jr, Norris CM: Submucosal spread of laryngeal carcinoma: A clinical pathological study employing serial coronal sections of the whole larynx. Trans AAOO 812, (Exhibit S-22) 1965

DISCUSSION

JOHN A. KIRCHNER, M.D.: This is a beautiful bit of correlation and it is this kind of work that is going to support more and more the concept of conservation of function in the surgical treatment of laryngeal cancer.

If our only treatment for laryngeal cancer were total laryngectomy or radiotherapy, then this type of study really would have less significance, but if we are going into the larynx and save a cord here, or both cords, with supraglottic precedures, we must know the kind of detail that is coming out of Dr. Tucker's work

The one other comment is that the staging system that is now being used I think is being shown to be somewhat questionable because these P-3 and 4 tumors that Dr. Tucker has showed us really must have had some degree of fixation of tissue and any staging system that does not allow for fixation is really missing the boat, isn't it?

There are, of course, several reasons for fixation but apart from invasion of the crico-arytenoid joint on bulk of tumor, fixation of the tissues certainly must enter into any system of classification.

CHARLES M. NORRIS, M.D.: I would like to make just one comment, hopefully without further confusing the already confused subject of classification and staging, which may be appropriate in this setting because it does apply somewhat to the application of classification and staging to the group of cases that has just been presented.

One problem which has been mentioned in previous publications in connection with the more extensive lesions has been the customary practice of basing the classification of these on the site of origin and it is in this connection that I would like to offer a proposal.

(Slide) I think everyone would agree that the selection of treatment as well as prognosis in lesions such as this depends not on the fact that it undoubtedly had a glottic origin but on the fact that it has a fairly large subglottic component. Would it not, then, be more meaningful to classify this as a subglottic T-3, N-1, N-0, Stage 3 lesion, rather than a glottic T-3 and N-1, thus emphasizing that the component of the lesion determining the requirements for treatment is not that corresponding to its origin but rather that representing its extension to a region with a greater propensity for recurrence or metasasis?

After all, our ultimate practical objective in using a system of classification and staging is to establish criteria for selection of treatment based on the results of clearly defined groups and I think that it would be more meaningful if this type of alteration in the classification could be considered.

The validity of this concept, if there is one, would seem to be justified in our present series since the failure of initial treatment in the T-3 and T-4 glottic cases were, with only two exceptions, those in which there was an appreciable subglottic component.

Dr. Tucker (closing): I hope that I haven't obscured with a lot of numbers and letters what I trust is a very simple message and this is that those of us who have been looking at laryngeal carcinoma for years as a mucosal process must recognize that it is truly three-dimensional and work from there.

Memorial

FREDERICK ADAM FIGI, M.D.

(1892 - 1970)

Dr. Frederick A. Figi, nationally known plastic surgeon and a member of the staff of the Mayo Clinic from 1923 to 1957, died at Saint Mary's Hospital in Rochester, Minnesota, on March 21, 1970.

He was born on August 28, 1892, in Sutton, Nebraska, the son of Abbie Hannah Clark Figi and Melchior Figi. He was a student at Doane College in Crete, Nebraska, from 1912 to 1914, and he received the degree of doctor of medicine from the University of Nebraska in 1918. In 1917 and 1918 he was an intern in the Wise Memorial Hospital in Omaha, Nebraska.

Dr. Figi came to Rochester, Minnesota, on June 16, 1918, as a fellow in urology of the Mayo Graduate School of Medicine. Later he transferred his graduate training to otolaryngology. He entered the U. S. Naval Medical Corps on October 23, 1918, with the grade of lieutenant, and served at the Naval base hospital in Hampton Roads, Virginia, until September of 1919. He then returned to Rochester to resume his fellowship. He took graduate work in general medical and surgical diagnosis and surgical pathology, and spent 39 months in special training in laryngology and oral and plastic surgery. In September, 1920, he was appointed a first assistant in laryngology, oral and plastic surgery in the Mayo Graduate School of Medicine, and in July, 1923, he became a member of the staff of the Mayo Clinic. In 1925 he was appointed an instructor in otolaryngology in the Mayo Graduate School of Medicine and in 1929 he was advanced to assistant professor. In 1932 he was promoted to associate professor of laryngology, and in 1948 he was named professor of plastic surgery. He became head of the Section of Plastic Surgery and Laryngology of the Mayo Clinic on April 1, 1950, and senior consultant on April 1, 1955. He retired from the Mayo Clinic on October 1, 1957.

Dr. Figi was concerned primarily with plastic surgery for most of his career, in the course of which he encountered a wide variety of conditions ordinarily not seen by a surgeon in that specialty. His first published paper, for instance, concerned actinomycosis of the tongue; subsequent papers dealt with such comparatively rare lesions as sarcomas, lipomas and chondromas of the larynx, dermoid cysts of the mouth and other infrequently seen conditions. His attention was early turned to malignant lesions of the mouth, nose, lips and throat, and he did much work in the surgical treatment of carcinoma of the larynx. He was also an early worker in the use of pedicle flaps and skin grafts in reconstructive surgery.

Dr. Figi was certified as a specialist in otolaryngology in 1926 by the American Board of Otolaryngology, Inc., and as a specialist in plastic surgery in 1939 by the American Board of Plastic Surgery, Inc. He served as chairman of the board of directors of the later board, of which he was a charter member. He was elected secretary-treasurer of the American Association of Plastic Surgeons in 1940 and in 1948 he became president of that organization. At a meeting of the American Academy of Dermatology, Inc., in 1952, Dr. Figi's exhibit on "Hemangiomas — Types and Methods of Treatment," prepared with Dr. John B. Erich, of the Mayo Clinic, was given first award by that academy. In 1954 he was named president of the American Society of Plastic and Reconstructive Surgeons, Inc., and in the same year the University of Nebraska conferred on him the honorary



FREDERICK ADAM FIGI, M.D.

degree of doctor of science in recognition of his work as "An extensive contributor to knowledge in the medical field on surgery of cancer of the ear, nose and throat."

In 1956 members of the American Society of Plastic and Reconstructive Surgeons, Inc., presented Dr. Figi with a plaque bearing the following inscription: "In appreciation of his outstanding leadership and original scientific contributions in the field of plastic surgery, presented by fellow members at the President's Dinner, October 25, 1956."

A silver bowl, engraved with the signatures of 34 former fellows of the Mayo Foundation whom Dr. Figi trained or helped to train in plastic surgery, also was presented to him on the same occasion.

In 1957 Doane College, Crete, Nebraska, where Dr. Figi was an undergraduate, conferred on him the honorary degree of doctor of science for the distinction he had achieved in the field of plastic surgery. In the same year he was made an honorary fellow of the International College of Surgeons.

Dr. Figi became a fellow of the American College of Surgeons in 1927. He was a member of the American Medical Association; the American Academy of Ophthalmology and Otolaryngology; the American Laryngological, Rhinological and Otological Society, Inc.; the Alumni Association of the Mayo Graduate School of Medicine; the Society of the Sigma Xi, the Alpha Omega Alpha national honor medical society and the American Laryngological Association. He was an honorary member of the Mississippi Valley Medical Society, the Nebraska State Dental Association and the North Dakota Academy of Ophthalmology and Otolaryngology. On September 9, 1955, the president of the Republic of Cuba made Dr. Figi an officer of the "Orden Nacional De Merito Carlos J. Finlay."

Dr. Figi was married on January 1, 1920, to Miss Bertha M. Olinger, of Sutton, Nebraska. Two children were born to them: Mary Ellen (Mrs. C. M. Judd, of Colorado Springs, Colorado); and Marjorie Anne (Mrs. Spencer K. Phillips, of Freeport, Illinois).

J.E.

ALBERT CARL FURSTENBERG, M.D.

(1890 - 1969)

On April 21, 1969 Doctor Albert C. Furstenberg experienced a subarachnoid hemorrhage. He died October 23, 1969 after being in St. Joseph Mercy Hospital for six months. This marked the passing of one of the great titans of medicine and particularly in Otorhinolaryngology.

Doctor Furstenberg was born in Saginaw, Michigan on May 27, 1890. He attended the University of Michigan as an undergraduate and later the Medical School, graduating from Michigan in 1915. He joined Doctor Roy Bishop Canfield's staff and steadily advanced academically. After Doctor Canfield's death in 1932 he was appointed Professor and Chairman of the Department of Otorhinolaryngology.

Doctor Furstenberg was a tireless worker throughout his life. In fact he was a dedicated physician, teacher and administrator carrying on all three careers simultaneously for many years.

His first and foremost role was as physician and in this role he carried on for a number of years after his retirement from his University duties. His patients always considered him a compassionate physician, friend and advisor. He was an outstanding clinician and surgeon.

His second career was that of teacher. His interests in teaching extended throughout his whole career and were broad based. Undergraduate, medical, graduate and postgraduate education came under his scrutiny. As Chairman of the Department of Otorhinolaryngology for 25 years the department flourished. In addition to this clinical orientation he contributed to the scientific knowledge of the fascial planes of the neck, laryngeal neurophysiology, osteomyelitis of the skull, salivary gland diseases and Meniere's Disease. In the capacity as teacher he was able to instill confidence in all who came in contact with him. His knack of motivating students and physicians associated with him was superb and they today are his greatest legacy.

At the age of 45, in 1935, Doctor Furstenberg started his third career, when he assumed the position of Dean of the University of Michigan Medical School. He served in this capacity for 28 years and at the same time retained his role as physician and teacher.

Under Doctor Furstenberg's administration the Medical School continued as a foremost institution. Many innovations were introduced into medical education and the medical classes were increased to 200 students, anticipating medical manpower needs by many years. Expansion of physical facilities was high on his list of priorities as noted by Medical Science Building I, the Outpatient Building and Hospital renovations. In addition to state and national government monetary support for these expansions, Doctor Furstenberg's efforts for further financial aid through the Kresge and Mott Foundations and other philanthropic sources are well known. As a direct result the Kresge Medical Library, Kresge Research Building, the Kresge Hearing Research Institute and the Mott Children's Hospital became realities. In his later retirement years the Kresge Hearing Research Institute was the scene of many enjoyable hours spent by him in association with staff members. Literally through his foresight the course of the Medical School's future has been directed for those who have followed.



ALBERT CARL FURSTENBERG, M.D.

While all these activities would exhaust more than the usual persons' capabilities Doctor Furstenberg, in addition, participated fully in national and international medical affairs. He contributed both scientifically and educationally. He received many awards and honors. He served as president of many national specialty societies and was honored as President of: The American Laryngological, Rhinological and Otolaryngological Society, Inc. during 1945 and 1946, The American Otological Society, Inc. during 1953, The American Academy of Ophthalmology and Otolaryngology during 1956, The American Laryngological Association during 1964. From the American Laryngological Association he received the deRoaldes award in 1959 and the Newcomb award in 1958. In 1945 he was President of the American Association of Medical Colleges. He carried on this assignment with dignity and foresight. He was a member of the Collegium Oto-Rhino-Laryngologicum Amicitiae Sacrum.

In spite of his busy schedule he found time to ride horseback and hunt. His favorite sites for these activities were the countryside and forest.

He is survived by his wife, Mrs. Elizabeth Nancy Furstenberg, and children, Doctor Nancy E. Furstenberg, Mrs. (Julie) John David Owens and William L. Furstenberg.

W.P.W.

FREDERICK THAYER HILL, M.D.

(1890 - 1969)

Frederick Hill died in Waterville, Maine on April 22, 1969, a few days before his 80th birthday.

Not everything that could be said of this man will be recorded here. His life was so lived that he crowded into it much more than most do. But some comment is appropriate for Frederick T. Hill was a remarkable person.

It should be mentioned first that he was rarely addressed or spoken of as Frederick T. Hill. His patients probably referred to him as Dr. Hill but, otherwise, almost universally, he was known as Ted. This appellation was used endearingly for he was a much loved person.

He was born the son of a doctor. His family was well sprinkled with doctors. It was natural for him to choose medicine as his life's work. Early in his medical life, he studied to equip himself for the practice of Otolaryngology. And, it was in this specialty that he compiled a remarkable record. He was a pupil of Dr. Harris P. Mosher of Harvard University. Dr. Mosher saw the potential in Frederick T. Hill and devoted much attention to the younger man's training from which Ted profited greatly. A feeling of mutual respect developed, which lasted until Dr. Mosher died at the age of 86. To those of us who were privileged to witness this relationship there was a quality to it which was both useful and lovely. Ted had the ability to be aware of the best and he showed it in his relationship with this distinguished physician.

Ted's career as an otolaryngologist was exemplary. He was a most competent and complete Otorhinolaryngologist. His many well-documented papers on various aspects of his specialty are testimony to this fact. He was quick to take up what was new in his field but it had to be without serious faults for he was just as quick to discover and denounce the fraudulent. Practicing in Waterville, Maine, isolated as it is, he could easily have remained quiet and let the new come and go as it would. Ted adopted the more difficult way. He was a part of the life of his day and he assumed the role of a dedicated participant.

Ted Hill was not gregarious in the sense that he had to participate just to keep busy. Rather his sense of committment made him respond when he saw a need. Thus, he was medically active in his State, at one time being President of the Maine Medical Society. He became deeply involved in the way medicine was practiced in hospitals. This led to his notable work on many committees of the American Hospital Association and his election to the regional presidency of that national organization. He was a leader in his own community in hospital matters. This interest was so impelling he became the guiding light in the development of his own hospital which is now one of the leading medical institutions of the northeast.

For a good number of years Ted Hill was a trustee of his Alma Mater, Colby College. For almost as many years, Ted was the trustee who sponsored and guided graduate education at Colby. He was a leader in the erection of new buildings on a new campus for his school. As a result of this, Colby is now one of the finest of the many small colleges in the United States.



FREDERICK THAYER HILL, M.D.

Ted Hill's leadership in Otolaryngology was recognized by his election to three choicest presidencies of his specialty: President of the American Board of Otolaryngology, President of the American Laryngological Association, and President of the American Otological Society. His contributions while he occupied these offices were significant indeed.

Ted Hill's interests ranged widely. Illustrative of this is the fact that he was a valued member of the Colby College orchestra for many years and was still an active player in it until shortly before his death. At the same time, he was a 33rd degree Mason.

No summary of Ted's many faceted life would be complete without mention of his stature as a husband and a father. His interest in his home and his family was even more important to him than any of his many activities.

Perhaps one of the most significant tributes to this exceptional man was at his funeral. The service was appropriately held in the Colby College Chapel. The sanctuary was crowded to the doors with family, friends, and admirers, an unusual occurrence for one who had lived so long.

It can safely be said that Ted loved the American Laryngological Association. Over many years he gave of his energy and thought to the solution of its problems and the betterment of its programs. We would not be on the solid foundation we are today without the efforts of this valued friend.

Here was an unusual man. He stood high above his fellows. He was a sincere promoter all his adult life and this aspect of his living was always directed toward the best. He had great integrity. A tireless worker, a kind and dedicated doctor, an admirable American, and a Yankee in the best tradition, we shall not soon see his like again.

G.D.H.

FLETCHER DRUMMOND WOODWARD, M.D.

(1895 - 1969)

Dr. Fletcher D. Woodward, of Charlottesville, Virginia, was born in Saluda, Virginia, on January 30th, 1895, son the late William Wallace, a lawyer, and Katharine Drummond Woodward. He died on July 2nd, 1969.

He was educated at Hampton High School, Virginia Military Institute, and the University of Virginia, where he received his medical degree in 1919. After completing an 18 month surgical internship at the University of Virginia Hospital, he was a resident surgeon at the Manhattan Eye, Ear, Nose, and Throat Hospital from 1920 until 1923. He practiced in Newport News, Virginia, until 1925 when he joined the Eye, Ear, Nose, and Throat Department at the University of Virginia and was placed in charge of the ear, nose, and throat section. Dr. Woodward became the first Chairman of the Department of Otolaryngology in 1938 and served until 1951 when he resigned for reasons of health. He continued as Clinical Professor of Otolaryngology until 1966 when he retired.

A partial list of his society affiliations and offices held includes: American Academy of Ophthalmology and Otolaryngology, Past Council Member and Guest of Honor, 1952; American Board of Otolaryngology, Past Director; American College of Chest Physicians, Past Associate Member; American Broncho-Esophageal Association, Past Vice-President; American Laryngological Society, Past Council Member and Vice-President; American Laryngological, Rhinological, and Otological Society, Past President 1960-61, Past Council Member, and Chairman of Southern Section; American College of Surgeons, life member; American Medical Association, Past Chairman of Section on Laryngology, Rhinology, and Otology, First Chairman of Committee on the Medical Aspects of Automobile Injuries and Deaths; American Otological Society, Past Council Member; National Research Council; and The Seven Society of the University of Virginia.

Dr. Woodward contributed frequently to the medical literature and also found time to write two non-medical books. He wrote "A Man's Guide to Breakfast" a cook book) and "If I Were King" in which he discussed many topics such as water pollution, drugs, smoking, sex, and highway safety.

He was an avid sportsman and conservationist. Hearing conservation, pollution control, and prevention of automobile accident injuries and deaths were fields in which he was very actively engaged. The Speech and Hearing Department of the University of Virginia and the Virginia Hearing and Speech Foundation were co-founded by Dr. Woodward.

Survivors include his wife, Mildred Hart Woodward, three children, and seven grandchildren.

W.McK.W.



FLETCHER DRUMMOND WOODWARD, M.D.

Executive Sessions

EXECUTIVE SESSION

Friday Morning, April 24, 1970

The Opening Session of the Ninety-first Annual Meeting of the American Laryngological Association, Inc., held at the Hollywood Beach Hotel, Hollywood Beach, Florida, convened in the Pageant Room on Friday morning, April 24, 1970, at eight-twenty o'clock, meeting in Executive Session, Alden H. Miller, M.D., Los Angeles, California, President of the Association, presiding.

The following candidates were elected to Fellowship:

Active Fellowship

Dr. John J. Ballenger, Chicago, Ill.

Dr. John P. Frazer, Rochester, N.Y.

Dr. Gabriel F. Tucker, Jr., Philadelphia, Pa.

Emeritus Fellowship

Dr. Robert L. Goodale

Dr. Gordon D. Hoople

Dr. P. E. Ireland

Dr. F. E. LeJeune

Dr. William J. McNally

Dr. G. Stewart Nash

Honorary Fellowship

Dr. Henry L. Williams, II

Corresponding Fellowship

Sir George C. Halliday, M.D.

Jack Hutcheon, M.D.

The Nominating Committee was then elected from the floor as follows:

Anderson Hilding, M.D., Duluth, Minn., Chairman

Robert Priest, M.D., Minneapolis, Minn.

James O'Neil, M.D., Omaha, Nebraska

James Harrill, M.D., Winston-Salem, N.C.

Slaughter Fitz-Hugh, M.D., Charlottesville, Va.

ANNUAL BUSINESS MEETING

SATURDAY MORNING, APRIL 25, 1970

The meeting reconvened in the Pageant Room for the Annual Business Meeting of the Association on Saturday morning, April 25, 1970, at eight-seventeen o'clock, President Miller presiding.

REPORT OF THE SECRETARY

The Ninetieth Annual Meeting of the American Laryngological Association was held on March 23 and 24, 1969, in the Roosevelt Hotel, New Orleans, Louisiana. The President, Dr. Francis W. Davison, shared the duties of presiding over the sessions with Vice-Presidents Drs. DeGraaf Woodman and John Murtagh. Thirteen scientific papers were presented and Dr. Lyman G. Richards was memorialized by Dr. Charles F. Ferguson. The attendance at this meeting was the largest recorded by this organization, 89 Fellows and 201 guests being present.

The Librarian, Historian and Editor, Dr. F. Johnson Putney, reported the deaths of the following:

Emeritus Fellows: Dr. Thomas R. Gittins

Dr. Joseph D. Kelly

Active Fellows: Dr. Joel J. Pressman

The Newcomb Award was presented to Dr. John A. Kirchner.

The following were elected to Fellowship:

Active

Dr. Albert H. Andrews, Jr., Chicago, Ill.

Dr. John R. Ausband, Winston-Salem, N.C.

Dr. John T. Dickinson, Pittsburgh, Pa.

Emeritus

Dr. Edgar P. Cardwell, Wilmington, N.C.

Dr. Watt W. Eagle, New Bern, N.C.

Dr. Albert C. Furstenberg, Ann Arbor, Mich.

Dr. Aubrey G. Rawlins, San Francisco, Calif.

Dr. Austin T. Smith, Philadelphia, Pa.

The following officers were elected for the coming year:

President: Dr. Alden H. Miller

First Vice-President: Dr. Joseph P. Atkins

Second Vice-President: Dr. Stanton A. Friedberg

Secretary: Dr. Frank D. Lathrop

Treasurer: Dr. Charles M. Norris

Librarian, Historian and Editor: Dr. F. Johnson Putney

First Councilor: Dr. Paul H. Holinger

Second Councilor: Dr. Francis A. Sooy

Third Councilor: Dr. Lawrence R. Boies

Fourth Councilor: Dr. Francis W. Davison

The next Annual Meeting will be held at the San Francisco Hilton, San Francisco, California, on the mornings of May 23 and 24, 1971. The Triological Society will hold their meeting during the forenoons of May 25, 26 and 27, and the American Otological Society on the mornings of May 28 and 29. The Broncho-Esophagological Association will hold their meetings during the afternoons of May 25 and 26, and those of the American Academy of Facial and Plastic Reconstructive Surgery will be held the afternoons of May 27 and 28. The American Society for Head and Neck Surgery will not meet with these organizations in 1971 as they will be holding their meeting in conjunction with the Annual Meeting of the American Medical Association.

Since the last Annual Meeting the Association has lost through death the following:

Sir Terence Cawthorne, a Corresponding Fellow since 1968, who died on January 22, 1970.

Dr. Andrew A. Eggston, a Corresponding Fellow since 1943, who died on January 26, 1970.

Dr. Albert C. Furstenberg, elected to Active Fellowship in 1932, Emeritus Fellowship in 1969 and President of the Association in 1964, who died on October 23, 1969.

Dr. Frederick T. Hill, elected to Active Fellowship in 1928, Honorary Fellowship in 1960 and President of the Association in 1948, who died on April 22, 1969.

Dr. Fletcher D. Woodward, elected to Active Fellowship in 1935 and Emeritus Fellowship in 1951, who died on July 2, 1969.

The present Fellowship of the Association is:
Active 94, Honorary 9, Corresponding 8, Emeritus 26, Total 137.

Respectfully submitted,

Frank D. Lathrop, M.D., Secretary

(On a motion by Dr. Lederer seconded by Dr. Hoople, the secretary's report was accepted.)

REPORT OF THE TREASURER

Exhibit A

AMERICAN LARYNGOLOGICAL ASSOCIATION
GENERAL FUND
OPERATING STATEMENT AND FUND BALANCE
FISCAL YEAR ENDED MARCH 31, 1970

Income			
Dues (90 members at $75.00, 3 new members at $115.00)		$7,095.00	
Registration Desk—Annual Meeting, New Orleans		1,155.00	
Sales of "Transactions"		625.00	
Interest on certificates of deposit	500.00		
savings accounts	205.61	705.61	$ 9,580.61
Expenses			
1969 Annual Meeting:			
Banquet and Cocktail Party	$4,129.96		
Reporting	322.98		
Projection	139.65		
Miscellaneous	120.64		
Total annual meeting expense		4,713.23	
Council meeting expense		2,216.22	
Cost of "Transactions"		2,725.12	
General Expense:			
Stationery, printing and postage	905.83		
Clerical hire	450.00		
Auditing	195.00		
Treasurer's Bond	55.00		
Dues International Federation of Otological Societies	100.00		
Donation—American Council Otolaryngology	500.00		
Gift	14.94		
Bank charges and foreign exchange	24.28		
Seal for Certificates of Fellowship	70.00		
Total general expense		2,315.05	
Total expenses			11,969.62
Net income (loss) for the year			(2,389.01)
Fund Balance, March 31, 1969			9,567.10
Fund Balance, March 31, 1970			$ 7,178.09

Exhibit B

AMERICAN LARYNGOLOGICAL ASSOCIATION
TRUST FUND
OPERATING STATEMENT AND FUND BALANCE
FISCAL YEAR ENDED MARCH 31, 1970

Income			
Interest on U. S. Government Bonds	$ 285.21		
Dividends on common stock (less 1.04 Can. Exch.)	269.91		
Dividends from mutual fund (reinvested)	2,067.56	$ 2,622.68	
Donation to Memorial Fund (Dr. Verling Hart)		100.00	
Bequests to Memorial Fund			
Dr. Frederick T. Hill	$1,000.00		
Dr. August C. Beck	2,000.00	3,000.00	
Net Income for the year			$ 5,722.68
Fund Balance, March 31, 1969			59,420.00
Fund Balance, March 31, 1970 (Exhibit C)			$65,142.68

TRUST FUND ASSET

Cash			$13,568.77
Accounts Receivable (E. F. Hutton and Co.)			14.80
Investments (Exhibit D):			
U. S. Savings Bonds, Series H (at cost, par and maturity values)		$ 6,500.00	
Common Stocks:			
Purchased (at cost)	$5,672.38		
Donated (market value at date of donation)	2,362.00	8,034.38	
Mutual Fund Stock (at cost)		37,024.73	51,559.11
Total Trust Fund Assets			$65,142.68

CASH SUMMARY

Cash in Commercial Account, (Girard Trust Bank, Phila.)	$ 1,505.71	
Cash in Savings Accounts, (Girard Trust Bank, Phila.)	8,698.87	
(Bank of America)	542.28	$10,746.86
Cash in Time Certificates of Deposit, (Bank of America)		10,000.00
Total Cash		$20.746.86
Allocation:		
General Fund (Exhibit A)	$ 7,178.09	
Trust Fund (above)	13,568.77	
	$20,746.86	

Exhibit C

AMERICAN LARYNGOLOGICAL ASSOCIATION
INDIVIDUAL TRUST FUNDS
MARCH 31, 1970

	Principal and Retained Earnings 3/31/69	*Earnings**	*April 1, 1969 to March 31, 1970 Bequests Donations -*	*Awards*	*Principal and Retained Earnings 3/31/70*
Casselberry	$ 8,731.23	$ 385.53			$ 9,116.76
Johnston	8,266.83	365.04			8,631.87
de Roaldes	5,689.64	250.22			5,939.86
Newcomb Trust	3,245.58	143.31			3,388.89
Newcomb Prize	757.54	33.45			790.99
Research	25,825.20	1,140.31			26,965.51
Memorial	6,903.98	304.82	3,100.00		10,308.80
	$59,420.00	$2,622.68	$3,100.00		$65,142.68

* Net income for the year is allocated to each fund in the ratio it bears to the total balance of the trust funds at the beginning of the year.

Exhibit D

AMERICAN LARYNGOLOGICAL ASSOCIATION
TRUST FUND INVESTMENTS
MARCH 31, 1970

U. S. GOVERNMENT BONDS

Six $1,000.00 Series H Bonds (at cost)	$6,000.00	
One $500.00 Series H Bond (at cost)	500.00	
Total U. S. Government Bonds		$ 6,500.00

COMMON STOCKS:

	Number of Shares	*Cost*	*Market Value at Date of Donation*	
American Telephone & Telegraph Co.	70	$4,845.02		
International Business Machine Corp.	1		$ 517.00	
International Business Machine Corp.[1]	7	803.98		
McDonnell Douglas Corp.[2]	112		1,170.00	
McDonnell Douglas Corp.[3]	14	23.38		
McIntyre-Porcupine Mines, Ltd.	15		675.00	
		$5,672.38	$2,362.00	8,034.38
MUTUAL FUND—Massachusetts Investors Trust (at cost)				37,024.73
Total Trust Fund Investments				$51,559.11

[1] Includes 5¼ shares received in stock dividends.

[2] Includes 86 shares received in stock dividends.

[3] Includes 13.44 shares received in stock dividends, and exercised rights to purchase .56 share.

ACCOUNTANT'S REPORT

To the Members of the American Laryngological Association.

Gentlemen:

We have examined the statements of cash receipts and disbursements of the AMERICAN LARYNGOLOGICAL ASSOCIATION, including Trust Funds, for the fiscal year ended March 31, 1970. Our examination was made in accordance with generally accepted auditing standards, and accordingly included such tests of the accounting records and such other auditing procedures as we considered necessary in the circumstances.

Cash receipts and disbursements were verified as recorded to date, and all securities were examined or accounted for as of this date.

In our opinion, the accompanying statements of cash receipts and disbursements present fairly the financial position of the American Laryngological Association and its Trust Funds at March 31, 1970, and the results of its operations for the year then ended, in conformity with generally accepted accounting principles applied on a basis consistent with that of the preceding year.

Respectfully submitted,

NEMORE, GRAHAM & COMPANY

Certified Public Accountants

(On a motion by Dr. Hoople duly seconded from the floor, the report was accepted.)

REPORT OF THE NOMINATING COMMITTEE

ANDERSON C. HILDING, M.D. (Duluth, Minnesota; Chairman of the Nominating Committee): The Nominating Committee respectfully submits the following slate for your consideration for officers for the coming year:

DeGraaf Woodman, M.D.

Robert Lewy, M.D.

Oliver Suehs, M.D.

Frank Lathrop, M.D.

Charles Norris, M.D.

Johnson Putney, M.D.

Francis Sooy, M.D.

Lawrence Boies, M.D.

Francis Davison, M.D.

Alden Miller, M.D.

There were no further nominations from the floor. It was moved, seconded and duly passed that the report be accepted.

REPORT OF THE LIBRARIAN, HISTORIAN AND EDITOR

The Ninetieth Meeting of the American Laryngological Association was held on March 23 and 24, 1969 at the Roosevelt Hotel, New Orleans, Louisiana. There were 89 fellows and 201 guests in attendance. The meeting as ably reported by the Martin C. Johnson Reporting Service whose representative, Mrs. Annabelle Square, gave efficient and dependable service as usual. The completed papers, with one exception, were sent to the Annals Publishing Company within three weeks and were published in the August issue of the Annals. All of the material for the 1969 Transactions, together with the corrected discussions, were mailed to the membership in early December, 1969.

In accordance with the agreement with Dr. Ben Senturia, Editor of the Annals, that the publication priorities are rotated through the American Otological Association, American Broncho-Esophagological Association and the American Laryngological Association, our material this year will be second in the sequence.

Because of the large number of unused volumes in previous years copies of the 1969 Transactions were reduced from 250 to 225. One hundred-four books were sent from the publisher to the active and honorary members, the Library of Congress, the National Library of Medicine for the Index Medicus and the families of the deceased members.

There were 42 standing orders for the Transactions and 31 additional single orders. Orders for 46 back issues were filled.

The cost of the 1969 Transactions was $2,650.93 which represented a decrease of $752.96. This reduction was accomplished largely through the efforts of Dr. Senturia and his staff in lowering the printing charges. The cost will probably rise sharply within the next few years and to anticipate and reduce the projected increase, the council has approved a change in the format of the Transactions. The page size will be enlarged to conform with those of the Annals. The height and width of the page will be changed from 9 x 6 inches to 10 x 6¾ inches. In this way the same type setting can be utilized for both publications without resetting the type to fit the page size of the present Transactions. The change is expected to result in more prompt publication as well as a financial saving.

The council also approved a request from the Audio-Digest Foundation to record the 1970 meeting of the American Laryngological Association. They are currently taping the proceedings of the American Laryngological, Rhinological and Otological Association in addition to several other national and regional medical society meetings and have been given permission to tape the papers of the American Broncho-Esophagological Association and the American Otological Society as well.

Respectfully submitted,

F. Johnson Putney, M.D.,

Librarian, Historian and Editor

(On a motion by Dr. LeJeune, seconded by Dr. Munoz-MacCormick the report was accepted.)

REPORT OF THE AMERICAN BOARD OF OTOLARYNGOLOGY

REPORT TO THE AMERICAN LARYNGOLOGICAL ASSOCIATION

BY THE REPRESENTATIVES FROM THE

AMERICAN BOARD OF OTOLARYNGOLOGY

Since the last Annual Meeting of the American Laryngological Association the American Board of Otolaryngology has held three examinations. The first of these was held in Los Angeles, California in May 1969 where 96 candidates were examined. Seventy-seven of these candidates were granted certificates and 19 either failed or were conditioned. One-hundred eighteen candidates were examined during the second examination which was held in Chicago, Illinois, in October following the meeting of the American Academy of Ophthalmology and Otolaryngology. Of these 118 candidates, 89 were granted certification, 25 were conditioned and four failed. The third examination was held in New Orleans, Louisiana, in February 1970. Certification was granted to 79 of the 93 candidates examined while 12 were conditioned and two failed.

An Examination Committee was appointed by the President of the American Board of Otolaryngology, Dr. Walter P. Work, some time ago to investigate the possibility that some alteration or modification of the present method of oral and clinical examinations might more effectively evaluate a candidate for certification. The necessity for considering such action has been brought about, at least in part, by the relatively few hospitals in this country capable of offering sufficient clinical material for the candidates to examine. This committee is chaired by Dr. George Reed.

Dr. Reed and his committee-members have met with Mr. LeRoy Nattress who has been involved in the intensive research conducted by the American Board of Orthopedics relative to their examination for certification. It appeared to the Committee that the examination techniques and organization as described by Mr. Nattress indicated that the American Board of Otolaryngology should seriously explore the possibility of introducing some of these techniques into their examination. Therefore, it was decided to concentrate attention on the use of multiple choice-written techniques and structured orals. At the moment, it is planned to eliminate one clinical and substituting for it one structured oral examination as well as substituting multiple choice examinations for two oral examinations as part of the October 1970 examination of the American Board of Otolaryngology.

Respectfully submitted,
Paul H. Holinger, M.D.
Frank D. Lathrop, M.D.

(On a motion by Dr. Norris seconded by Dr. Woodman the report was accepted.)

REPORT FROM THE BOARD OF GOVERNORS

AMERICAN COLLEGE OF SURGEONS

The meeting of the Board of Governors was called to order at 9:00 A. M. by the Chairman, Dr. Charles McLaughlin, Jr., who introduced the executive officers of the College, who in turn reported on the activities of the College during the preceding year.

Dr. Jonathan Rhoads, Chairman of the Board of Regents, stated that the assets of the College were about $11,000,000 with a budget of $2,172,000 in 1968.

He also commented on the unresponsive attitude of the government toward the College's posture regarding Medicare and Medicaid and indicated that this was tied in with government's attitude towards surgical education. He also mentioned the Quinn report to the AMA which advocated direct feedback from the councils of the various surgical specialties to the House of Delegates. This requires a change in the by-laws of the AMA and presumably will be accomplished in December 1969.

Dr. John F. North, Director of the College, remarked on the efforts to improve communication between the administrative level of the College and its members by instituting a combined newsletter and bulletin beginning in January 1970. He also stated that the average age of the new members coming into the College was 37-40 while the average age of the Board of Governors was 60. A Committee is studying this gap and the needs of education for the new members.

Dr. Charles McLaughlin, Jr., Chairman of the Board of Governors, then commented on the financial requirements of the College. A Committee, of which your representative was a member, studied these needs during the past year and on the basis that the College would operate in the red in 1969 due to rising costs, recommended an increase in the dues to $90.00 a year. This report was accepted by the Board of Governors and recommended to the Regents for implementation. Dr. McLaughlin also reported on the size of the Board of Governors and the recommendations of a committee to limit this size in the future. The College is also concerned about the increase in malpractice suits and premiums for liability coverage. A Committee studying this has made certain recommendations to try to limit the increasing impact on the individual physician and will continue its studies during the coming year. One other committee report involved improving relations with the various surgical specialty societies. It recommended appointment of a standing committee by the Regents with representatives from each of the specialty societies.

Retirement of Dr. Paul North was announced, Dr. C. Rollins Hanlon was installed.

In view of the suggested restriction of the size of the Board of Governors, the Academy will have one less representative, making a total of two rather than three, one from Ophthalmology and one from Otolaryngology. Dr. Burton Soboroff is the Governor from the Academy representing otolaryngology.

The total number of Active Fellows in the College (as of November 24, 1969) is 26,916, of which 13,901 are general surgeons and 13,015 are specialists. Of interest is the fact that the total number of 1969 initiates who are specialists far exceeds those who are general surgeons (1523 total initiates of whom 930 are classified as specialists and 593 as general surgeons). Eighty-seven otolaryngologists were initiated in 1969.

During the afternoon the governors met in seven study groups to review various activities of the College. Your representative was in the group that discussed how to increase involvement of the surgical specialists in College activities and came up with a number of recommendations among the most important of which was better program planning with selection of topics of concern to two or more specialties. It was felt that the development of these relations between specialties would lead not only to better dissemination of information but also to

better rapport between specialties that have common areas of interest. The College was also urged through its public relations office, to deliver the message of the College more effectively to the specialty groups.

Respectfully submitted,

W. Franklin Keim, M.D.

(On a motion by Dr. Lederer seconded by Dr. Andrews the report was accepted.)

REPORT OF THE LARYNGOLOGICAL RESEARCH FUND COMMITTEE

The Laryngological Research Fund Committee wishes to report that during the past year only three applications for research grants were received.

The first of these applications simply consisted of a letter stating the object of the research problem and requesting $1,000.00. A letter was written to the applicant requesting further information on the proposed research so as to submit this to Committee members. To date, no reply has been received from the individual.

The second applicant presented a very thorough description of his research problem requesting the sum of $1,866.00. This request was circulated to the Committee. Only three replies were received, two in favor and one against the application.

The third application for financial help to continue further research in the use of human amniotic membrane to restore the oral and pharyngeal region in extensive surgery of these areas was presented by a doctor from India. This was submitted to the Committee and received three affirmative votes. Our cash position has increased and we are ready to receive and approve grants at the approval of the Committee.

Respectfully submitted,

Francis E. LeJeune, M.D., Chairman

(On a motion by Dr. Munoz-MacCormick seconded by Dr. Norris the report was accepted.)

NEW BUSINESS

After lengthy discussion concerning the need for additional revenue and whether this should come from (1) a raise of dues, (2) a registration fee, or (3) a charge for the annual banquet. Dr. Bordley moved that the members of the Association pay a fair fee for the banquet without increasing the dues or levying a registration fee. The motion was seconded by Dr. Andrews and passed.

SECRETARY LATHROP: Certificates of Fellowship have been prepared for those men requesting them at two dollars ($2.00) each and can be obtained from me at the end of the business meeting.

EXECUTIVE SESSION

SATURDAY MORNING, APRIL 25, 1970

The meeting reconvened in Executive Session in the Pageant Room on Saturday morning, April 25, 1970, at twelve-twelve o'clock, President Miller presiding.

(On a motion by Dr. Atkins seconded by Dr. Alfaro the new Council was unanimously elected.)

PRESIDENT MILLER: Gentlemen, your elected Councilors have met and have set up the organization of the officers as follows:

President: Dr. DeGraaf Woodman

First Vice President: Dr. Robert Lewy

Second Vice President: Dr. Oliver Suehs

Secretary: Dr. Frank Lathrop

Treasurer: Dr. Charles Norris

Editor: Dr. Johnson Putney

First Councilor: Dr. Francis Sooy

Second Councilor: Dr. Lawrence Boies

Third Councilor: Dr. Francis Davison

Fourth Councilor: Dr. Alden Miller

PRESIDENT MILLER: DeGraaf, all I have to say is that you have the most wonderful year of your life ahead of you.

(President Miller handed the gavel to President-elect Woodman, who then assumed the Chair.)

PRESIDENT WOODMAN: Gentlemen, I am overwhelmed. A lot of wonderful things have happened in the last 18 hours in this Association. Yesterday they threw a bombshell at our honored guest and he was speechless, they gave a great accolade to Louis Clerf and he was almost speechless, and on the way to dinner Andy Hilding tapped me on the shoulder and said, "Would you serve as President?" Would I serve! How could anybody who loves this Association as much as I do and has any red blood in his cells refuse? It is the most wonderful honor that has happened to me.

I accept this humbly and I do hope that you will all support me and with the wonderful slate you have left me, particularly our Secretary, Frank Lathrop, we can't help but go ahead and keep the high standards we have had in the past.

Alden, will you come up here, please?

(Immediate Past President Miller came to the platform, as requested.)

Alden, you have been an inspiration to me and have given us a wonderful year, and I think one of the finest programs we have ever had. As a friend and as a man whom I have admired in the way you have operated in this organization, I would like to present you with a token of confidence and appreciation for what you have done for this Association. (Presenting a small box to Immediate Past President Miller.)

(The meeting was adjourned at twelve twenty-one o'clock.)

THE NEWCOMB AWARD

The Newcomb Award is presented each year by the American Laryngological Association to a fellow who has made outstanding contributions to the literature of Laryngology and/or as a mark of esteem and appreciation for services to the Association.

The recipient for 1970 is eminently qualified since he fulfilled both of the requirements.

Having already received the highest award of the Association, the deRoaldes Award, in 1954 it is fitting that Dr. Louis H. Clerf be again honored by the Association for his continued interest and efforts in its behalf. Although he has been elevated to Honorary Fellowship he still attends each meeting and his vigor and enthusiasm has been and still is an inspiration to the younger men.

The presentation of the Newcomb Award to Dr. Clerf carries with it the sincere congratulations of the Fellows of the Association on this well deserved honor.

DE ROALDES AWARD

I have been given the privilege of announcing the winner of the deRoaldes Award for 1970.

This is a coveted award, only 12 men in the long history of the Society have received it. It has been given on an average of only once every four or five years.

All of the previous recipients could be classified as great rhinolaryngologists. I feel that the 1970 recipient is a great otolaryngologist who ranks in the class with the previous recipients.

If we take the initial letters of the word G R E A T , the winner this year is both gracious and generous. He is a real person. He is rational and he is respected. He has an exemplary character. He is an eager worker and is educationally inclined having taught most of his active years. He is able and ambitious in the best sense of the word. He is tactful, he is technically qualified; and, he is one of our most talented members.

The records show that only one man in the history of the Society has received all three of our honors; i.e., the deRoaldes Award, the Casselberry Award, and the Newcomb Award. The 1970 Award goes to a man who has previously won both the Casselberry and Newcomb Awards. There are only four men who are, thus, eligible for the Award. One possible recipient is the 1970 Guest of Honor, Dr. Francis LeJeune, but tradition in the American Laryngological Association is that only one award be given in any one year to any one member. However, in 1970, there is an exception to this rule and the recipient of the deRoaldes Award for 1970 is Dr. Francis LeJeune.

List of Fellows

LIST OF FELLOWS

Date Indicates Year Admitted to Active Fellowship

Attendance at meetings is shown by figures following each name.
Asterisk (*) indicates year paper was read.

Active Fellows

1962. ALEXANDER, FRED W., 10515 Carnegie Ave., Cleveland 6, Ohio, 1962, '63*, '64, '66, '68, '69, '70.

1958. ALFARO, VICTOR R., 917 - 20th St. N. W., Washington 6, D.C., 1958, '59, '60, '61, '62, '63, '64, '65, '66, '67, '69, '70.

1969. ANDREWS, ALBERT H., 122 S. Michigan Ave., Chicago, Ill., 1970.

1962. ARNOLD, GODFREY E. T., 2500 N. State St., Jackson 6, Mississippi, 1962, '63*, '64*, '66, '69, '70.

1958. ATKINS, JOSEPH P., 3400 Spruce St., Philadelphia 4, Pa., 1958, '59*, '60, '61, '62, '63, '64, '65, '67, '68, '69, '70.

1969. AUSBAND, JOHN R., Bowman Gray School of Medicine, Winston-Salem, N. C., 1970.

1956. BAKER, DANIEL CLIFTON, JR., 180 Fort Washington Ave., New York 21, N.Y., 1956, '57, '58, '59*, '60, '61, '62*, '63, '64, '65, '66, '69*, '70.

1970. BALLENGER, JOHN J., 723 Elm St., Winnetka, Ill. 60093.

1963. BAXTER, JAMES D., 1509 Sherbrooke St. West, Montreal, P.Q., Canada, 1963, '65*, '66, '67, '68, '69, '70.

1944. BOIES, LAWRENCE R., University Hospital, Minneapolis 14, Minnesota, 1944, '46, '47, '48*, '49, '50*, '51*, '53, '54, '55, '56, '57, '58, '59, '60, '61, '62, '63, '64, '65, '66, '67, '68*, '69.

1955. BORDLEY, JOHN E., Johns Hopkins Hospital, Baltimore 5, Maryland, 1955, '56, '57, '59, '60, '62, '63, '64, '65, '66, '67, '69, '70.

1959. BREWER, DAVID W., 1100 E. Genesee St., Syracuse 10, N. Y., 1959, '60*, '61, '62*, '63*, '66, '70.

1955. BROWN, LESTER ALEXANDER, 490 Peachtree Street, N.E., Atlanta 8, Georgia, 1955, '56, '57, '58, '59, '61, '63, '65, '68, '69, '70.

1940. BROYLES, EDWIN N., 11 East Chase St., Baltimore 2, Maryland, 1940, '41*, '42, '46, '48*, '49, '50, '51*, '52, '53, '54, '55, '56, '58, '59*, '60, '61*, '63, '64, '65, '67.

1963. BRYCE, DOUGLAS P., 170 St. George St., Room 320, Toronto, Canada, 1963*, '64, '66*, '67*, '68*, '69, '70.

1968. CHANDLER, J. R., 1700 N.W. 10th Ave., Miami, Fla., 1968, '69*, '70.

1967. COCKE, EDWIN W., 899 Madison, Memphis, Tenn., 1967, '68, '69, '70.

1964. CODY, CLAUDE C., III, 1600 Memorial Professional Building, Houston, Texas, 1964, '65, '67, '69.

1957. CONLEY, JOHN J., 139 East 36th Street, New York 16, N. Y. 1958*, '60*, '61, '62*, '63*, '64, '65, '70.

1957. CONVERSE, JOHN MARQUIS, 722 Park Avenue, New York 21, N. Y., '60, '62*, '67.

1959. CRACOVANER, ARTHUR J., 103 E. 78th St., New York 21, N. Y., 1959, '60, '61*, '62, '63, '65, '66, '67, '68, '69.

1960. DALY, JOHN F., Faculty Practice Offices, 566 First Ave., New York 16, N. Y., 1960, '61*, '62, '63, '64, '65, '66, '67, '68, '69, '70.

1951. DAVISON, FRANCIS W., Geisinger Medical Center, Danville, Pa., 1951, '52, '53*, '54, '55, '56, '57, '58, '59, '60, '61, '62, '63*, '64, '65, '66, '67*, '68, '69*, '70.

1966. DEVINE, KENNETH D., Mayo Clinic, Rochester, Minn., 1966, 1948*, '49, '51, '53, '54, '56, '57, '59, '62, '64, '65*, '66, '67, '68.

1968. DEWEESE, DAVID D., 3181 S.W. Sam Jackson Park Rd., Portland, Ore., 1968, '69*.

1969. DICKINSON, JOHN T., 1501 Locust St., Pittsburgh, Pa., 1970.

1952. ERICH JOHN B., Mayo Clinic, 102 Second Avenue, Rochester, Minn. 1953, '56*, '57, '65.

1968. FARRIOR, RICHARD T., 509 Bay St., Tampa, Fla., 1968, '69, '70*.

1964. FEARON, BLAIR, Medical Arts Building, Toronto 5, Ontario, Canada, 1964, '66, '67, '68, '69, '70.

1963. FERGUSON, CHARLES F., 300 Longwood Ave., Boston 15, Mass., 1963, '64*, '66, '67*, '68, '69*, '70.

1955. FITZ-HUGH, GLASSELL SLAUGHTER, 2003 Spottswood Road, Charlottesville, Virginia, 1955, '57, '59, '60, '61, '62*, '64, '65, '66, '67*, '68, '69, '70.

1970. FRAZER, JOHN P., 260 Crittenden Blvd., Rochester, N. Y. 14620.

1956. FRIEDBERG, STANTON A., 1725 West Harrison St., Chicago, Ill., 1956, '57*, '58, '59, '60, '61, '62, '63, '64, '65*, '67, '68, '69, '70.

1959. GOLDMAN, JOSEPH L., 1050 Park Ave., New York, N. Y., 1959, '60*, '61, '62, '63, '64, '65, '66, '67, '68, '69 '70

1965. HANCKEL, RICHARD W., 55 Doughty St., Charleston, S. C., 1965, '66, '67, '69, '70.

1957. HARRILL, JAMES A., Bowman Gray School of Medicine, Winston-Salem, N. C., 1957, '58, '59, '61, '62, '63, '64, '66, '67, '68, '69.

1960. HARRIS, HERBERT, 907 Hermann Professional Building, Houston 25, Texas, 1960, '61*, '62, '63, '64, '65*, '66, '67, '68, '69, '70.

1959. HART, VERLING K., 1600 East Third St., Charlotte, N. C. 28204, 1959, '60, '62, '66, '68, '69, '70.

1959. HENRY, G. ARNOLD, 170 St. George St., Toronto, Canada, 1959, '61, '63, '66, '67, '69, '70.

1943. HILDING, ANDERSON C., Research Laboratory, St. Luke's Hospital, Duluth 11, Minnesota, 1944*, '46, '47, '48*, '49, '50, '51, '53, '55, '56*, '57, '60, '61, '62*, '63, '64*, '65, '66, '67, '68, '69, '70.

1955. HILGER, JEROME A., Suite 6A, 393 Dunlap St., St. Paul, Minnesota 55104, 1955, '56*, '57, '58, '59, '60, '62, '63, '64, '65, '66, '68, '69, '70.

1945. HOLINGER, PAUL H., 700 North Michigan Ave., Chicago 11, Illinois, 1946, '47, '49, '50*, '51*, '52, '53, '54*, '55, '56, '57, '58*, '59, '60, '61*, '62*, '63, '64, '65, '66*, '68, '69*.

1957. HOLMES, EDGAR M., 2000 Washington St., Newton, Mass. 02164, 1957, '59, '61, '63, '68, '70.

1961. JONES, EDLEY H., 1301 Washington St., Vicksburg, Miss. 39108, 1961, '62, '63*, '65, '66, '67, '68, '69, '70.

1964. KEIM, W. FRANKLIN, 75 Union St., Montclair, N. J., 1964, '66, '67, '68*, '69, '70.

1965. KING, JAMES T., Baptist Professional Building, Atlanta, Ga., 1965, '66, '67, '69, '70.

1963. KIRCHNER, JOHN A., 333 Cedar St., New Haven 4, Conn., 1963, '65*, '67*, '68, '69*, '70.

1965. KNIGHT, JOHN S., 305 West 43rd St., Kansas City, Mo., 1965, '66*, '67, '69, '70.

1963. LATHROP, FRANK D., R.F.D. No. 1, Pittsford, Vt., 1963, '64*, '67*, '69, '70.

1953. LEDERER, FRANCIS LOEFFLER, 1855 W. Taylor St., Chicago, Illinois 60612, 1953, '54, '55, '56, '57*, '58, '60, '61, '62, '63*, '64, '65, '66, '68*, '69, '70.

1966. LEWIS, JOHN S., 3 East 71st Street, New York 21, N. Y., 1966, '67, '68, '69*, '70.

1961. LEWY, ROBERT B., 25 East Washington St., Chicago 2, Ill., 1961, '62*, '63, '65*, '67, '68, '69, '70.

1966. MCCABE, BRIAN F., Dept. of Otolaryngology, University Hospital, Iowa City, Iowa, 1966, '69.

1963. MCGOVERN, FRANCIS H., 139 South Main St., Danville, Virginia, 1963, '64, '66, '68.

1951. MCHENRY, LAWRENCE C., 301 N. W. 12th St., Oklahoma City 2, Okla., 1953*, '62, '63, '64, '65, '66, '68.

1952. MILLER, ALDEN H., 1407 N. Vermont Ave., Los Angeles 27, Calif., 1952, '53*, '55, '57, '58*, '61, '62, '64, '66, '67*, '68, '69, '70.

1965. MILLER, DANIEL, Deaconess Medical Building, 110 Francis St., Boston, Mass., 1965, '66, '67, '68, '69*, '70.

1964. MONTGOMERY, WILLIAM W., 243 Charles St., Boston 14, Mass., 1964, '65*, '66*, '68*, '70.

1958. MONTREUIL, FERNAND, Hospital Notre Dame, 1560 E. Sherbrooke, Montreal 24, Canada, 1958, '60, '64, '67, '69.

1954. MOORE, PAUL M., 10515 Carnegie Ave., Cleveland 6, Ohio, 1954, '55*, '56, '57, '59, '60, '61, '62, '63, '64, '65, '66, '68, '70.

1957. MUNOZ-MACCORMICK, CARLOS EDUARDO, 71 Park Terrace, Santurce, Puerto Rico, 1957, '58, '59, '60, '61, '62, '63, '64, '65, '66, '67, '68, '69, '70.

1953. MURTAGH, JOHN A., 2 Maynard Street, Hanover, New Hampshire, 1953, '54, '55, '56*, '57, '58, '59, '61, '62, '63, '65, '66, '67, '69, '70.

1956. NORRIS, CHARLES MORGAN, 3401 North Broad Street, Philadelphia 40, Pennsylvania, 1956, '57, '58*, '59, '60, '61*, '62, '63, '64, '66, '67, '68*, '69, '70*.

1961. OGURA, JOSEPH H., 640 So. Kingshighway, St. Louis 10, Mo., 1961*, '62*, '63, '64*, '65, '66*, '67, '68*, '69, '70.

1958. O'KEEFE, JOHN J., 255 S. 17th St., Philadelphia 3, Pa., 1958, '59*, '60, '62, '64, '67.

1961. O'NEIL, JAMES J., 612 Medical Arts Building, Omaha, Nebraska, 1961, '62*, '64, '67, '69, '70.

1961. PANG, LUP Q., 1374 Nuuanu Ave., Honolulu 17, Hawaii, 1961, '62*, '64, '66, '67, '70.

1961. PASTORE, PETER N., 5503 Riverside Drive, Richmond 25, Va.. 1961, '62*, '64, '66, '67, '69.

1967. PRATT, LORING W., 177 Main St., Waterville, Maine, 1967, '68, '69, '70.

1951. PRIEST, ROBERT E., 79 S. Ninth St., Minneapolis 2, Minn., 1951, '53*, '54*, '56, '59, '60*, '61, '65, '67*, '68, '69, '70.

1951. PUTNEY, F. JOHNSON, 80 Barre St., Charleston, S. C. 29401, 1951, '52, '53*, '54, '55, '56, '58*, '59, '60, '61, '62, '63*, '64*, '65, '66, '67, '68*, '69*, '70*.

1963. REED, GEORGE F., 766 Irving Ave., Syracuse, N. Y., 1963, '65*, '66, '68, '69*, '70.

1956. RICHARDSON, JOHN ROBERT, P.O. 52, Searsport, Maine 04974, 1957, '58, '59, '60, '63, '64, '67, '69.

1959. SANDERS, SAM H., 1268 Peabody Ave., Memphis 3, Tenn., 1959, '60, '61, '62, '63, '65, '70.

1964. SAUNDERS, WILLIAM H., N-820 University Hospital, Columbus, Ohio, 1964, '65, '66, '68*, '69, '70*.

1959. SILCOX, LOUIS E., 102 Lankenau Med. Bldg., Philadelphia 31, Pa., 1959, '60, '61, '62, '63, '64, '65, '66, '67, '68, '69, '70.

1958. SIMONTON, KINSEY M., Mayo Clinic, Rochester, Minn., 1958, '59*, '62, '64, '66, '67, '69.

1962. SISSON, GEORGE A., Northwestern U. Medical School, 303 Chicago Ave., Chicago, Ill. 60611, 1962, '63*, '65, '66, '68, '69, '70.

1964. SKOLNIK, EMANUEL M., 1853 West Polk Street, Chicago, Ill., 1964*, '65, '66*, '67, '68, '69, '70*.

1954. SOOY, FRANCIS A., University of California Hospital, 3rd and Parnassus Ave., San Francisco, Calif., 1954, '56*, '58, '60, '62, '63, '64, '65*, '67, '68*

1961. SUEHS, OLIVER W., 14 Medical Arts Square, Austin, Texas, 1961, '62*, '63, '64, '66, '68, '69, '70.

1963. TABB, HAROLD G., 1430 Tulane Ave., New Orleans 12, La., 1963, '65, '66, '67, '69.

1954. THORNELL, WILLIAM C., 2508 Auburn Avenue, Cincinnati 19, Ohio, 1955*, '57, '59, '60, '63, '68, '70.

1963. TOLAN, JOHN F., 1118 Ninth Ave., Seattle 1, Washington, 1963, '64, '65, '66, '67, '69

1967. TRIBLE, WILLIAM MACL., 1234 19th St., N.W., Washington, D.C., 1967, '68, '69*, '70.

1970. TUCKER, GABRIEL F., JR., 3401 North Broad St., Philadelphia, Pa., 19140, 1970*.

1954. WALSH, THEODORE E., 640 S. Kingshighway Blvd., St. Louis 10, Missouri, 1954, '55*, '56, '57, '58, '59, '60, '61, '62, '63, '64, '65, '66, '67, '68, '69, '70.

1962. WEAVER, DELMAR F., 571 Fisher Building, Detroit 2, Michigan, 1962, '63, '64*, '65, '67*, '69, '70.

1940. WEILLE, FRANCIS L., 247 Commonwealth Avenue, Boston 16, Massachusetts, 1940, '41, '42, '44, '46*, '47, '48, '49, '50, '51, '52, '53, '54, '55, '56*, '57, '58, '59, '60, '61, '62, '63, '64, '65*, '66, '67, '68, '69, '70.

1951. WOODMAN, DEGRAAF, Talbottown Lane, P.O. Box 560, Easton, Md., 1951, '53, '54, '55*, '56, '58, '59, '60, '61, '62, '63, '64, '65, '66, '67, '68, '69, '70.

1953. WORK, WALTER P., University Hospitals, Ann Arbor, Michigan, 1953, '54, '56, '58, '59*, '62, '63*, '65, '67, '68, '69.

Honorary Fellows

1946. Alonso, Regules Justo E., Mercedes 1233, Montivideo, Uruguay.

1957. (1925) Clerf, Louis H., 5575 Eighth Avenue, North, St. Petersburg 2, Florida, 1957, '58, '59, '60, '61, '63, '64, '65, '66, '68, '69, '70.

1968. (1936) Galloway, Thomas C., 636 Church St., Evanston, Ill., '69.

1957. Huizinga, Eelco, Noorderhaven 7, Groningen, The Netherlands, 1957.

1967. (1933) Lierle, Dean M., University Hospitals, Iowa City, Iowa, 1967, '68.

1957. (1930) Negus, Sir Victor E., Hill Farm Lodge, Haslemere, Surrey, England, 1957*.

1966. (1957) Ono, Jo, 75 Zaimoku-cho, Azabu, Minato-ku, Tokyo, Japan.

1937. Portmann, Georges, 25 bis Cours de Verdun, Bordeaux, France, 1947.

1957. Ruedi, Luzius, Ramistrasse 100, Zurich, Switzerland, 1957.

1970. (1948) Williams, Henry L., II, 90 Imperial St., West St. Paul, Minn. 55118.

Corresponding Fellows

1959. Barretto, Plinio de Mattos, Ru Cons Torres, Homer 371, Sao Paulo, Brazil, 1960, '69.

1959. Bateman, Geoffrey H., 55 Harley Street, London, W. 1, England

1942. Batson, Oscar V., 203 South DeKalb St., Philadelphia 4, Pennsylvania, 1942*, '54*

1964. Cleves, Carlos, Carrera 14 No. 44-54 Apto. 202, Bogota, Colombia, S. A., '70.

1966. Dohlman, Gosta, Dept. of Otolaryngology, University of Toronto, Toronto, Canada, 1966.

1970. HALLIDAY, SIR GEORGE C., 143 Macquarrie St., Sydney, N.S.W. Australia.

1970. HUTCHEON, JACK, Morris Towers, 149 Wickham Terrace, Brisbane, Australia.

1968. NAKAMURA, FUMIO, Kyoto Prefectural U. Medicine, Kawara-Mach 1, Kamikyo-Ku, Kyoto, Japan

1964. PEREZ, ALFREDO C., Institito Celis Perez, Avenida Montes Deoca, Apartado 163, Velencia, Venezuela, S. A., 1965.

1924. SCHAEFER, J. PARSONS, 4634 Spruce Street, Philadelphia 39, Pennsylvania, 1934.

1952. TAPIA ACUNA, RICARDO, Av. Insurgentes Sur 300, Mexico 7 D.F., 1953, '57, '60*, '67.

1936. VIALLE, JACQUES, 27 Rue de France, Nice (Alpes Maritimes), France.

Emeritus Fellows

1951. (1944) BEATTY, HUGH G., 390 Oak St., Apt. No. 35, Columbus 15, Ohio, 1951, '52, '53.

1966. (1945) CAMPBELL, PAUL A., 321 Park Hill Drive, San Antonio, Texas.

1965. (1942) CANFIELD, NORTON, Harwood Hospital, Christiansted, St. Croix, Virgin Is.

1969. (1959) CARDWELL, EDGAR P., 2415 Oleander Drive, Wilmington, N. C.

1969. (1947) EAGLE, WATT W., 703 Professional Drive, New Bern, N. C.

1970. (1940) GOODALE, ROBERT L., 141 Argilla Rd., Ipswich, Mass. 01938.

1963. (1928) GOODYEAR, HENRY M., 2012 Edgecliff Point, Cincinnati, Ohio 45206.

1960. (1940) HANSEL, FRENCH, 634 N. Grand Blvd., St. Louis 3, Missouri, 1962, '65.

1968. (1942) HEATLY, CLYDE A., 11 North Goodman St., Rochester 7, N. Y., 1942, '46*, '49, '50, '52, '53*, '54, '55, '57, '58, '60, '61, '65.

1970. (1944) HOOPLE, GORDON D., 1100 E. Genesee St., Syracuse, N. Y. 13210.

1970. (1952) IRELAND, P. E., 60 Smart St., P.O. Box 91, Bowmanville, Ontario, Canada.

1961. (1950) KLINE, ORAM R., 896 Lake Ave., Woodbury Heights, N. J. 08097, 1961, ' 63, '70.

1970. (1936) LEJEUNE, FRANCIS E., Ochsner Clinic Bldg., 1519 Jefferson Highway, New Orleans, La. 70121.

1967. (1949) LINDSAY, JOHN R., 950 E. 59th St., Chicago 37, Ill.. 1967.

1954. (1927) LUKENS, ROBERT M., 141 West Heather Road, Wildwood Crest, N. J.

1964. (1952) MCCALL, JULIUS W., 610 Rose Building, Cleveland 15, Ohio, 1964, '66, '68, '69, '70.

1966. (1933) MCMAHON, BERNARD J., 150 North Meramec Ave., Clayton, Mo.

1970. (1931) MCNALLY, WILLIAM J., 1509 Sherbrooke St. West, Montreal, Canada.

1959. (1927) MYERSON, MERVIN C., 436 Roxbury Drive, Beverly Hills, Calif.

1970. (1937) NASH, C. STEWART, 708 Medical Arts Bldg., Rochester, N. Y. 14607.

1957. (1948) PHELPS, KENNETH A., 7200 34th St., South, St. Petersburg, Fla.

1969. (1951) RAWLINS, AUBREY G., 384 Post St., San Francisco, Calif.

1958. (1938) SALINGER, SAMUEL, 1260 East Alejo Road, Palm Springs, Calif., 1958, '59, '61, '62, '63, '64, '65, '66 '67, '68, '69.

1962. (1932) SCHALL, LEROY A., Scudder Lane, Barnstable, Mass., 1964, '66, '68, '69.

1964. (1934) SCHENCK, HARRY P., 326 South 19th Street, Philadelphia 3, Pa., 1964, '65*, '66, '68, '69, '70.

1965. (1939) SIMPSON, W. LIKELY, 351 South Highland St., Memphis, Tenn.

1969. (1950) SMITH, AUSTIN T., 330 S. 9th St., Philadelphia, Pa., 1970.

1966. (1947) THEOBALD, WALTER H., 307 N. Michigan Ave., Chicago 11, Ill., 1966, '68, '69.

1968. (1950) TREMBLE, G. EDWARD, 1390 Sherbrooke St. W., Montreal, Quebec, Canada, 1950, '51, '52, '53, '54, '55*, '56, '57, '58, '60, '61, '62, '63, '65, '66, '67*, '68, '69, '70.

1965. (1943) VAN ALYEA, OLIVER E., 135 South LaSalle St., Chicago 3, Ill., 1965, '66, '68, '69, '70.

1961. (1941) VIOLE, PIERRE P., 241 South Windsor, Los Angeles, Calif., 1964.

BENEFACTORS

Dr. John F. Barnhill
Dr. August L. Beck
Dr. Gordon Berry
Dr. Edwin N. Broyles
Dr. William E. Casselberry
Dr. Louis H. Clerf
Dr. Cornelius G. Coakley
Dr. & Mrs. Francis W. Davison
Dr. & Mrs. Lee Wallace Dean
Dr. Arthur W. deRoaldes
Dr. Fred W. Dixon
Dr. William E. Grove
Dr. Gordon F. Harkness
Dr. Frederick T. Hill
Dr. & Mrs. George E. Hourn
Dr. Samuel Johnston
Mrs. Lila Fetterolf Kennedy
Dr. James E. Newcomb
Dr. Henry B. Orton
Dr. & Mrs. Lyman G. Richards
Dr. Samuel Salinger
Dr. Sam H. Sanders
Dr. Harry P. Schenck
Dr. Burt R. Shurly
Mr. Lester T. Sunderland
Dr. H. Marshall Taylor
Dr. Walter H. Theobald

Obverse of the deRoaldes medal

RECIPIENTS OF THE DEROALDES AWARD

1928. Dr. Chevalier Jackson

1931. Dr. D. Bryson Delavan

1934. Dr. Harris P. Mosher

1937. Dr. Lee Wallace Dean

1943. Dr. Ralph A. Fenton

1949. Dr. George M. Coates

1951. Dr. Arthur W. Proetz

1954. Dr. Louis H. Clerf

1959. Dr. Albert C. Furstenberg

1960. Dr. Dean M. Lierle

1961. Dr. Frederick T. Hill

1966. Dr. Paul H. Holinger

1970. Dr. Francis E. LeJeune

RECIPIENTS OF THE CASSELBERRY AWARD

1923. Dr. George Fetterolf and Dr. Herbert Fox

1928. Dr. Ralph A. Fenton and Dr. O. Larsell

1929. Dr. Richard A. Kern and Dr. Harry P. Schenck

1929. Dr. Edward H. Campbell

1931. Dr. Arthur W. Proetz

1934. Dr. Anderson C. Hilding

1936. Dr. Francis E. LeJeune: Dr. Joel J. Pressman

1939. Dr. H. Marshall Taylor: Dr. Brien T. King

1940. Dr. French K. Hansel

1941. Dr. Noah D. Fabricant

1946. Dr. Paul H. Holinger

1949. Dr. Henry B. Orton

1962. Dr. Hans von Leden

1966. Dr. John A. Kirchner and Mr. Barry D. Wyke

1968. Dr. Joseph H. Ogura

RECIPIENTS OF THE NEWCOMB AWARD

1941. Dr. Burt R. Shurly
1942. Dr. Francis R. Packard
1943. Dr. George M. Coates
1944. Dr. Charles J. Imperatori
1947. Dr. Harris P. Mosher
1948. Dr. Gordon Berry
1949. Dr. Gordon B. New
1950. Dr. H. Marshall Taylor
1951. Dr. John D. Kernan
1952. Dr. William J. McNally
1953. Dr. Frederick T. Hill
1954. Dr. Henry B. Orton
1955. Dr. Thomas C. Galloway
1956. Dr. Dean M. Lierle
1957. Dr. Gordon F. Harkness
1958. Dr. Albert C. Furstenberg
1959. Dr. Harry P. Schenck
1960. Dr. Joel J. Pressman
1961. Dr. Chevalier L. Jackson
1962. Dr. Paul H. Holinger
1963. Dr. Francis E. LeJeune
1964. Dr. Fred W. Dixon
1965. Dr. Edwin N. Broyles
1966. Dr. Lyman G. Richards
1967. Dr. Joseph H. Ogura
1968. Dr. Walter P. Work
1969. Dr. John A. Kirchner
1970. Dr. Louis H. Clerf

PAST OFFICERS

Presidents

(Year of Election)

1879. Louis Elsberg
1880. J. Solis-Cohen
1881. F. I. Knight
1882. G. M. Lefferts
1883. F. H. Bosworth
1884. E. L. Shurly
1885. Harrison Allen
1886. E. Fletcher Ingals
1887. R. P. Lincoln
1888. E. C. Morgan
1889. J. N. Mackenzie
1890. W. C. Glasgow
1891. S. W. Langmaid
1892. M. J. Asch
1893. D. Bryson Delavan
1894. J. O. Roe
1895. W. H. Daly
1896. C. H. Knight
1897. T. R. French
1898. W. E. Casselberry
1899. Samuel Johnston
1900. H. L. Swain
1901. J. W. Farlow
1902. J. H. Bryan
1903. J. H. Hartman
1904. C. C. Rice
1905. J. W. Gleitsman
1906. A. W. deRoaldes
1907. H. S. Birkett
1908. A. Coolidge, Jr.
1909. J. E. Logan
1910. D. Braden Kyle
1911. James E. Newcomb
1912. George A. Leland
1913. Thomas Hubbard
1914. Alexander W. MacCoy
1915. G. Hudson Makuen
1916. Joseph L. Goodale
1917. Thomas H. Halstead
1918. Cornelius G. Coakley
1919. Norval H. Pierce
1920. Harris P. Mosher
1921. Harmon Smith
1922. Emil Mayer
1923. J. Payson Clark
1924. Lee Wallace Dean
1925. Greenfield Sluder
1926. Chevalier Jackson
1927. D. Bryson Delavan
1928. Charles W. Richardson
1929. Lewis A. Coffin
1930. Francis R. Packard
1931. George E. Shambaugh
1932. George Fetterolf
1933. George M. Coates
1934. Dunbar Roy
1935. Burt R. Shurly
1936. William B. Chamberlain
1937. John F. Barnhill
1938. George B. Wood

1939. James A. Babbitt
1940. Gordon Berry
1941. Thomas E. Carmody
1942-3. Charles J. Imperatori
1944-5. Harold I. Lillie
1946. Frank R. Spencer
1947. Arthur W. Proetz
1948. Frederick T. Hill
1949. Ralph A. Fenton
1950. Gordon B. New
1951. H. Marshall Taylor
1952. Louis H. Clerf
1953. Gordon F. Harkness
1954. Henry B. Orton
1955. Bernard J. McMahon
1956. LeRoy A. Schall
1957. Harry P. Schenck
1958. Fred W. Dixon
1959. William J. McNally
1960. Edwin N. Broyles
1961. Dean M. Lierle
1962. Francis E. LeJeune
1963. Anderson C. Hilding
1964. Albert C. Furstenberg
1965. Paul H. Holinger
1966. Joel J. Pressman
1967. Lawrence R. Boies
1968. Francis W. Davison
1969. Alden H. Miller

Vice-Presidents

1879. F. H. Davis
1880. W. C. Glasgow
1881. E. L. Shurly
1882. C. Seiler
1883. S. W. Langmaid
1884. J. H. Hartman
1885. H. A. Johnson
1886. E. C. Morgan
1887. J. N. Mackenzie
1888. W. C. Glasgow
1889. F. Holden
1890. J. O. Roe
1891. M. J. Asch
1892. S. Johnston
1893. J. C. Mulhall
1894. C. C. Rice
1895. J. Wright
1896. T. M. Murray
1897. A. W. MacCoy
1898. J. W. Farlow
1899. T. A. DeBlois
1900. H. L. Wagner
J. O. Roe
W. Porter
E. F. Ingals
S. Johnston
W. H. Daly
G. W. Major
J. N. Mackenzie
S. W. Langmaid
C. E. DeM. Sajous
C. E. Bean
J. H. Hartman
S. Johnston
J. C. Mulhall
W. E. Casselberry
S. H. Chapman
A. W. deRoaldes
D. N. Rankin
H. S. Birkett
F. W. Hinkel
M. R. Brown
A. A. Bliss

1901. J. W. Gleitsmann
1902. G. A. Leland
1903. J. H. Lowman
1904. Thomas Hubbard
1905. J. L. Goodale
1906. G. H. Makuen
1907. J. P. Clark
1908. E. Mayer
1909. C. G. Coakley
1910. Robert C. Myles
1911. F. C. Cobb
1912. A. W. Watson
1913. F. E. Hopkins
1914. Clement T. Theisen
1915. J. Gordon Wilson
1916. Thomas H. Halsted
1917. John Edwin Rhodes
1918. G. E. Shambaugh
1919. Francis R. Packard
1920. Harmon Smith
1921. Dunbar Roy
1922. George Fetterolf
1923. Hubert Arrowsmith
1924. Ross H. Skillern
1925. John E. Mackenty
1926. Lewis A. Coffin
1927. Charles W. Richardson
1928. Robert Clyde Lynch
1929. William B. Chamberlin
1930. Harris P. Mosher
1931. Joseph B. Greene
1932. Gordon Berry
1933. E. Ross Faulkner
1934. Gordon B. New
1935. Edward C. Sewall
1936. William P. Wherry
1937. Frank R. Spencer
1938. Ralph A. Fenton
1939. John H. Foster
1940. Charles H. Porter
D. Braden Kyle
T. Melville Hardie
W. Peyre Porcher
W. J. Freeman
C. W. Richardson
A. R. Thrasher
J. E. Rhodes
F. R. Packard
H. P. Mosher
J. M. Ingersoll
B. R. Shurly
W. Scott Renner
Geo. F. Shambaugh
Lewis A. Coffin
Christian R. Holmes
Greenfield Sluder
D. Crosby Greene
John R. Winslow
Harmon Smith
W. B. Chamberlin
Robert C. Lynch
Lorenzo B. Lockard
Joseph B. Greene
Gordon Berry
Robert Levy
William V. Mullin
Hill Hastings
Francis P. Emerson
Ralph Albert Fenton
James A. Babbitt
E. Ross Faulkner
Frank A. Spencer
Thomas S. Carmody
Samuel McCullagh
H. Marshall Taylor
Harold I. Lillie
Bernard J. McMahon
Frederick T. Hill
Thomas R. Gittins
Gordon F. Harkness

1941.	Arthur W. Proetz	Henry B. Orton
1942-3.	Harold I. Lillie	Dean M. Lierle
1944-5.	John J. Shea	Thomas C. Galloway
1946.	H. Marshall Taylor	C. Stewart Nash
1947.	John J. Shea	Frederick A. Figi
1948.	Henry B. Orton	Anderson C. Hilding
1949.	LeRoy A. Schall	Fletcher D. Woodward
1950.	W. Likely Simpson	Lyman G. Richards
1951.	Wm. J. McNally	Thomas C. Galloway
1952.	J. Mackenzie Brown	Edwin N. Broyles
1953.	Claude C. Cody	Daniel S. Cunning
1954.	James H. Maxwell	Clyde A. Heatly
1955.	Robert L. Goodale	Paul H. Holinger
1956.	Henry M. Goodyear	Robert E. Priest
1957.	Francis E. LeJeune	Pierre P. Viole
1958.	Charles Blassingame	Chevalier L. Jackson
1959.	James Maxwell	Oliver Van Alyea
1960.	Walter Theobald	Anderson Hilding
1961.	Julius W. McCall	P. E. Ireland
1962.	Paul M. Moore	Jerome A. Hilger
1963.	Paul M. Holinger	Lester A. Brown
1964.	G. Slaughter Fitz-Hugh	Daniel C. Baker
1965.	C.E. Munoz-MacCormick	Arthur J. Cracovaner
1966.	Lawrence R. Boies	G. Edward Tremble
1967.	John F. Daly	Stanton A. Friedberg
1968.	DeGraaf Woodman	John Murtagh
1969.	Joseph P. Atkins	Stanton A. Friedberg

Secretaries and Treasurers

1879.	G. M. Lefferts	1895.	H. L. Swain
1882.	D. Bryson Delavan	1900.	P. E. Newcomb
1889.	C. H. Knight	1911.	Harmon Smith

Secretaries

1912.	Harmon Smith	1939.	Charles J. Imperatori
1918.	D. Bryson Delavan	1942.	Arthur W. Proetz
1919.	J. M. Ingersoll	1947.	Louis H. Clerf
1920.	George M. Coates	1952.	Harry P. Schenck
1933.	William V. Mullin	1957.	James H. Maxwell
1935.	James A. Babbitt	1959.	Lyman G. Richards

1968. Frank D. Lathrop

Treasurers

1912. J. Payson Clark
1923. George Fetterolf
1932. William V. Mullin
1933. James A. Babbitt
1935. Charles J. Imperatori
1939. Frederick T. Hill
1948. Gordon F. Harkness
1953. Fred W. Dixon
1958. Francis E. LeJeune
1962. Alden H. Miller
1969. Charles M. Norris

Librarians

1879. F. H. Bosworth
1883. T. R. French
1903. J. H. Bryan
1930. John F. Barnhill
1934. Burt R. Shurly
1935. George M. Coates

Librarian and Historian

1936. George M. Coates
1944. Louis H. Clerf

Librarian, Historian and Editor

1947. Harry P. Schenck
1952. Bernard J. McMahon
1955. Edwin N. Broyles
1960. Francis W. Davison
1964. F. Johnson Putney

PAST FELLOWS

Dates indicate original election to the Association

**Deceased*

Honorary Fellows

*1908. Barnhill, John F., Miami Beach, Florida.
*1893. Birkett, Herbert S., Montreal, Canada.
*1878. Bosworth, Francke H., New York, N. Y.
*1917. Coates, George M., Philadelphia, Pa.
*1918. Dean, Lee Wallace, St. Louis, Mo.
*1881. Delavan, D. Bryson, New York, N. Y.
*1893. deRoaldes, Arthur W., New Orleans, La.
*1890. De La Sota Y. Lastra, Ramon, Seville, Spain.
*1923. Fenton, Ralph A., Portland, Oregon.
*1879. French, Thomas R., Brooklyn, N. Y.
*1880. Garcia, Senior Manuel, London, England.
*1903. Harris, Thos J., New York, N. Y.
*1928. Hill, Frederick T., Waterville, Me.
*1907. Jackson, Chevalier, Schwenksville, Pa.
*1878. Johnston, Samuel, Baltimore, Md.
*1878. Lefferts, George Morewood, Katonah, N. Y.
*1914. Levy, Robert, Denver, Colo.
*1918. Lewis, Fielding O., Media, Pa.
*1883. Mackenzie, John N., Baltimore, Md.
*1881. Mackenzie, Sir Morel, London, England.
*1910. Masser, Ferdinand, Naples, Italy.
*1904. Mosher, Harris P., Marblehead, Mass.
*1910. Moure, J. J. E., Bordeaux, France.
*1937. Nager, F. R., Zurich, Switzerland.
*1918. Oliver, H. K., Boston, Mass.
*1906. Pierce, Norval Harvey, San Diego, Calif.
*1924. Proetz, Arthur C., St. Louis, Mo.
*1909. Semon, Sir Felix, Great Missenden, England.
*1878. Solis-Cohen, J., Philadelphia, Pa.

*1889. Swain, Henry L., New Haven, Conn.
*1914. Thomson, Sir St. Clair, London, Eng.
*1903. Tilley, Herbert, London, England.
*1914. Wagner, Clinton, New York, N. Y.
*1890. Wright, Jonathan, Pleasantville, N. Y.

Corresponding Fellows

*1892. Browne, Lennox, London, England.
*1938. Blair, Vilray P., St. Louis, Missouri.
*1968. Cawthorne, Sir Terence, London, England.
*1940. Colledge, Lionel, London, England.
*1901. Collier, Mayo, Kearsney, Abbey, Kent, England.
*1893. Desvernine, Carlos M., Havana, Cuba.
*1930. Emerson, Francis P., Franklin, Mass.
*1943. Eggston, Andrew A., New York, N. Y.
*1961. Faaborg-Andersen, Knud, Nykobing, Denmark.
*1936. Fraser, John S., Edinburgh, Scotland.
*1901. Grant, Sir James Dundas, London, England.
*1887. Cougenheim, A., Paris, France.
*1894. Holden, Edgar, Newark, N. J.
*1919. Kelly, Adam Brown, Helensburgh, Scotland.
*1881. Labus, Carlo, Milan, Italy.
*1950. Larsell, Olof, Portland, Oregon.
*1931. LaSagna, Francesco, Parma, Italy.
*1926. Law, Frederick M., New York, N. Y.
*1921. LeMaitre, Ferdinand, Paris, France.
*1902. Lermoyez, Marcel, Paris, France.
*1897. Luc, H., Paris, France.
*1896. MacDonald, Greville, Haslemere, Surrey, England.
*1894. MacIntyre, John, Glasgow, Scotland.
*1903. McBride, P., York, England.
*1920. McKenzie, Dan, London, England.
*1919. McKernon, James F., New Canaan, Conn.
*1880. Meyer, Wilhelm, Copenhagen, Denmark.
*1910. Moure, J. J. E., Bordeaux, France.
*1896. Mygind, Holger, Copenhagen, Denmark.
*1950. Neil, James Hardie, Auckland, New Zealand.

*1919. Paterson, Donald Rose, Cardiff, Wales.
*1941. Patterson, Norman, Herts, England.
*1919. Rogers, John, Jr., New York, N. Y.
*1894. Sajous, C. E. DeM., Philadelphia, Pa.
*1924. Schaefer, J. Parson, Philadelphia, Pa.
*1896. Schmiegelow, Ernst, Copenhagen, Denmark.
*1946. Segura, Eliseo, Buenos Aires, Argentina.
*1940. Soto, E. Fernandez, Havana, Cuba.
*1881. Thornton, Pugin, London, England.
*1913. Turner, A. Logan, Edinburgh, Scotland.
*1880. Whistler, W. McNeil, London, England.
*1901. Wingrave, Wyatt, Lyme Regis, Dorset, England.
*1894. Wolfenden, R. Norris, Kent, England.

Emeritus Fellows

*1936. Ballenger, Howard C., Winnetka, Ill.
*1923. Barlow, Roy A., Nova Scotia, Canada.
*1915. Barnes, Harry Aldrich, Kingston, Mass.
*1928. Beck, Joseph C., Chicago, Illinois.
*1921. Berry, Gordon, Worcester, Mass.
*1941. Bowers, Wesley C., New York, N. Y.
*1901. Brown, J. Price, Toronto, Canada.
*1891. Bryan, Joseph H., Washington, D. C.
*1913. Butler, Ralph, Philadelphia, Pa.
*1930. Campbell, Edward H., Philadelphia, Pa.
*1897. Clark, J. Payson, Boston, Mass.
*1899. Cobb, Frederick C., Bradenton, Florida.
*1939. Cody, Claude C., Jr., Houston, Texas.
*1905. Coffin, Lewis A., New York, N. Y.
*1893. Coolidge, Algernon, Boston, Mass.
*1937. Crowe, Samuel J., Baltimore, Maryland.
*1941. Cunning, Daniel S., New York, N. Y.
*1913. Dabney, Virginia, Washington, D. C.
*1882. De Blois, Thomas Amory, Boston, Mass.
*1941. Dixon, Fred W., Shaker Heights, Ohio.
*1892. Farlow, John W. Boston, Mass.
*1930. Figi, Frederick A., Rochester, Minn.
*1922. Forbes, Henry H., New York, N. Y.
*1933. Foster, John H., Houston, Texas.

*1905. Freer, Otto T., Chicago, Ill.
*1932. Furstenberg, Albert C., Ann Arbor, Mich.
*1940. Gatewood, E. Trible, Richmond, Va.
*1928. Gittins, Thomas R., Sioux City, Iowa.
*1880. Gleitsmann, Joseph W., New York, N. Y.
*1922. Goldsmith, Perry G., Toronto, Canada.
*1898. Goodale, Joseph L., Ipswich, Mass.
*1932. Graham, Harrington B., San Francisco, California.
*1906. Greene, D. Crosby, Jr., Boston, Mass.
*1917. Greene, Joseph B., Asheville, N. C.
*1950. Hall, Colby, Encino, Calif.
*1905. Halsted, Thomas H., Los Angeles, Calif.
*1896. Hardie, Thomas Melville, Chicago, Ill.
*1915. Hastings, Hill, Los Angeles, Calif.
*1944. Havens, Fred Z., Rochester, Minn.
*1888. Hinkel, Frank Whitehill, Buffalo, New York.
*1895. Hopkins, Frederick E., Springfield, Mass.
*1930. Houser, Karl M., Ardmore, Pa.
*1927. Hubbard, Thomas, Toledo, Ohio.
*1919. Hurd, Lee Maidment, Rowayton, Conn.
*1920. Imperatori, Charles J., Essex, N. Y.
*1904. Ingersoll, John Marvin, Miami, Fla.
*1928. Jarvis, DeForest C., Barre, Vt.
*1939. Johnston, Willam H., Santa Barbara, Calif.
*1942. Kelly, Joseph D., New York, N. Y.
*1918. Kenyon, Elmer L., Chicago, Ill.
*1921. Kernan, John D., New York, N. Y.
*1929. Kistner, Frank B., Portland, Oregon.
*1885. Knight, Charles H., New York, N. Y.
*1939. Large, Secord H., Cleveland, Ohio.
*1894. Leland, George A., Boston, Mass.
*1922. Lillie, Harold I., Rochester, Minn.
*1943. Lincoln, William R., Cleveland, Ohio.
*1928. Lyman, Harry Webster, St. Louis, Mo.
*1886. MacCoy, Alexander W., Philadelphia, Pa.
*1941. Martin, Robert C., San Francisco, Calif.
*1896. Mayer, Emil, New York, N. Y.
*1951. McCart, Howard W. D., Toronto, Canada.

*1939. McCaskey, Carl H., Indianapolis, Indiana.
*1943. McCullagh, Samuel, New York, N. Y.
*1923. McKinney, Richmond, Memphis, Tenn.
*1928. MacPherson, Duncan, New York, N. Y.
*1939. Myers, John L., Kansas City, Mo.
*1901. Myles, Robert C., New York, N. Y.
*1922. New, Gordon B., Rochester, Minn.
*1923. Newhart, Horace, Minneapolis, Minn.
*1903. Packard, Francis R., Philadelphia, Pa.
*1878. Porter, William, Ocean Springs, Miss.
*1942. Potts, John B., Omaha, Nebr.
*1903. Renner, W. Scott, Buffalo, N. Y.
*1897. Rhodes, John Edwin, Chicago, Ill.
*1884. Rice, Clarence C., New York, N. Y.
*1905. Richards, George L., South Yarmouth, Mass.
*1878. Robinson, Beverly, New York, N. Y.
*1921. Sauer, William E., St. Louis, Mo.
*1923. Sewall, Edward C., Palo Alto, Calif.
*1930. Seydell, Ernest M., Wichita, Kansas.
*1907. Shambaugh, George E., Chicago, Ill.
*1908. Smith, Harmon, New York, N. Y.
*1923. Spencer, Frank R., Boulder, Colo.
*1927. Tobey, Harold G., Boston, Mass.
*1925. Tucker, Gabriel, Haverford, Pa.
*1892. Wagner, Henry L., San Francisco, Calif.
*1892. Watson, Arthur W., Philadelphia, Pa.
*1948. Whalen, Edward J., Hartford, Conn.
*1922. White, Francis W., New York, N. Y.
*1939. Wilson, J. Gordon, Old Bennington, Vt.
*1905. Wood, George B., Wynnewood, Pa.
*1935. Woodward, Fletcher D., Charlottesville, Va.

Active Fellows

*1880. Allen, Harrison, Philadelphia, Pa.
*1917. Arrowsmith, Hubert, Brooklyn, N. Y.
*1879. Asch, Morris J., New York, N. Y.
*1942. Ashley, Rae E., San Francisco, Calif.
*1923. Babbitt, James A., Philadelphia, Pa.

*1906. Ballenger, William L., Chicago, Ill.
*1880. Bean, C. E., St. Paul, Minn.
*1949. Beck, August L., New Rochelle, N. Y.
*1904. Berens, T. Passmore, New York, N. Y.
*1924. Bigelow, Nolton, Providence, R. I.
*1938. Blassingame, Charles D., Memphis, Tenn.
*1893. Bliss, Arthur Ames, Philadelphia, Pa.
*1951. Boyden, Guy L., Portland, Oregon.
*1895. Boylan, J. E., Cincinnati, Ohio.
*1932. Brown, John Mackenzie, Los Angeles, Calif.
*1892. Brown, Moreau R., Chicago, Ill.
*1933. Buckley, Robert E., New York, N. Y.
*1915. Canfield, R. Bishop, Ann Arbor, Mich.
*1934. Carmack, John Walter, Indianapolis, Ind.
*1924. Carmody, Thomas E., Denver, Colo.
*1889. Casselberry, William E., Chicago, Ill.
*1883. Chamberlain, C. W., Hartford, Conn.
*1917. Chamberlin, William B., Cleveland, Ohio.
*1896. Chappell, W. F., New York, N. Y.
*1882. Chapman, S. Hartwell, New Haven, Conn.
*1902. Coakley, Cornelius G., New York, N. Y.
*1913. Coffin, Rockwell C., Boston, Mass.
1918. Cox, Gerald H., New York, N. Y.
*1880. Cushing, E. W., Boston, Mass.
*1878. Cutter, Ephraim, West Falmouth, Mass.
*1880. Daly, W. H., Pittsburgh, Pa.
*1878. Davis, F. H., Chicago, Ill.
*1941. Davis, Warren B., Philadelphia, Pa.
1926. Dennis, Frank Lownes, Colorado Springs, Colo.
*1901. Dickerman, E. T., Chicago, Ill.
*1878. Donaldson, Frank, Baltimore, Md.
*1947. Engler, Clarence W., Cleveland, Ohio.
*1954. Equen, Murdock S., Atlanta, Ga.
*1935. Eves, Curtis C., Philadelphia, Pa.
*1919. Faulkner, E. Ross, New York, N. Y.
*1914. Fetterolf, George, Philadelphia, Pa.
*1901. Freeman, Walter J., Philadelphia, Pa.
*1917. Friedberg, Stanton A., Chicago, Ill.
1940. Fuchs, Valentine H., New Orleans, La.
*1897. Frothingham, Richard, New York, N. Y.

1909. Getchell, Albert C., Worcester, Mass.
*1907. Gibb, Joseph S., Philadelphia, Pa.
*1940. Gill, William D., San Antonio, Texas.
*1878. Glasgow, William Carr, St. Louis, Mo.
*1913. Goldstein, Max A., St. Louis, Mo.
*1905. Grayson, Charles P., Philadelphia, Pa.
*1934. Grove, William E., Milwaukee, Wisconsin.
*1933. Harkness, Gordon F., Davenport, Iowa.
*1878. Hartman, J. H., Baltimore, Md.
*1945. Hickey, Harold L., Denver, Colo.
*1879. Holden, Edgar, Newark, N. J.
*1907. Holmes, Christian R., Cincinnati, Ohio.
*1882. Hooper, Franklin H., Boston, Mass.
*1893. Hope, George B., New York, N. Y.
*1938. Hourn, George E., St. Louis, Mo.
*1939. Hunt, Westley Marshall, New York, N. Y.
*1901. Hyatt, Frank, Washington, D. C.
*1925. Iglauer, Samuel, Cincinnati, Ohio.
*1878. Ingals, E. Fletcher, Chicago, Ill.
*1882. Ives, Frank L., New York, N. Y.
*1938. Jackson, Chevalier L., Philadelphia, Pa.
*1880. Jarvis, William C., New York, N. Y.
*1878. Johnson, Hosmer A., Chicago, Ill.
*1879. Johnson, Woolsey, New York, N. Y.
*1960. Johnston, Kenneth C., Chicago, Ill.
*1944. Jones, Marvin F., New York, N. Y.
*1879. Kealhofer, R. H., St. Louis, Mo.
*1942. King, Edward D., North Hollywood, Calif.
*1901. King, Gordon, New Orleans, La.
*1885. Knight, Charles H., New York, N. Y.
*1878. Knight, Frederick Irving, Boston, Mass.
*1898. Kyle, D. Braden, Philadelphia, Pa.
*1880. Langmaid, Samuel W., Boston, Mass.
*1878. Lincoln, Rufus P., New York, N. Y.
*1911. Lockard, Lorenzo B., Denver, Colo.
*1913. Loeb, Hanau W., St. Louis, Mo.
*1897. Logan, James E., Kansas City, Mo.
*1935. Looper, Edward A., Baltimore, Md.
*1888. Lowman, John H., Cleveland, Ohio.

*1919. Lynah, Henry L., New York, N. Y
*1952. Lynch, Mercer G., New Orleans, La.
*1915. Lynch, Robert Clyde, New Orleans, La.
*1879. McBurney, Charles, New York, N. Y.
*1927. McGinnis, Edwin, Chicago, Ill.
1936. McGregor, Gregor, Toronto, Canada.
*1913. McKimmie, O. A., Washington, D. C.
*1945. McLaurin, John G., Dallas, Texas.
*1885. McSherry, H. Clinton, Baltimore, Md.
*1914. Mackenty, John E., New York, N. Y.
*1898. Makuen, G. Hudson, Philadelphia, Pa.
*1881. Major, G. W., Montreal, Canada.
*1948. Maxwell, James H., Ann Arbor, Mich.
*1954. Meltzer, Philip E., Boston, Mass.
*1881. Morgan, E. C., Washington, D. C.
*1950. Morrison, Lewis F., San Francisco, Calif.
*1940. Morrison, William W., New York, N. Y.
*1886. Mulhall, J. C., St. Louis, Mo.
*1925. Mullin, William V., Cleveland, Ohio.
*1914. Munger, Carl E., Waterbury, Conn.
*1892. Murray, T. Morris, Washington, D. C.
*1881. Mynter, H., Buffalo, N. Y.
*1893. Newcomb, James E., New York, N. Y.
*1895. Nichols, J. E. H., New York, N. Y.
*1927. Orton, Henry B., Newark, N. J.
*1894. Park, William H., New York, N. Y.
*1892. Porcher, W. Peyre, Charleston, S. C.
*1927. Porter, Charles T., Boston, Mass.
*1954. Pressman, Joel J., Los Angeles, Calif.
*1908. Randall, B. Alexander, Philadelphia, Pa.
*1882. Rankin, D. N., Allegheny, Pa.
*1934. Richards, Lyman G., Wellesley Hills, Mass.
*1902. Richardson, Charles W., Washington, D. C
*1930. Ridpath, Robert E., Philadelphia, Pa.
*1879. Roe, John O., Rochester, N. Y.
*1945. Robb, James M., Detroit, Michigan.
*1953. Roberts, Sam E., Kansas City, Mo.
*1881. Robertson, J. M., Detroit, Mich.
*1913. Roy, Dunbar, Atlanta, Ga.

*1878. Rumbold, T. F., St. Louis, Mo.
*1879. Seiler, Carl, Philadelphia, Pa.
*1928. Shea, John Joseph, Memphis, Tennessee.
*1893. Shields, Charles M., Richmond, Pa.
*1909. Shurly, Burt R., Detroit, Mich.
*1878. Shurly, E. L., Detroit, Mich.
*1892. Simpson, William Kelly, New York, N. Y
*1919. Skillern, Ross H., Philadelphia, Pa.
*1909. Sluder, Greenfield, St. Louis, Mo.
*1879. Smith, Andrew H., Geneva, N. Y.
*1932. Smyth, Duncan Campbell, Boston, Mass.
*1928. Sonnenschein, Robert, Chicago, Ill.
1924. Stein, Otto J., Chicago, Ill.
1934. Stevenson, Walter, Quincy, Ill.
*1911. Staut, George C., Philadelphia, Pa.
*1879. Tauber, Bernhard, Cincinnati, Ohio.
*1924. Taylor, Hermon Marshall, Jacksonville, Fla.
*1903. Theisen, Clement F., Albany, N. Y.
*1899. Thorner, Max, Cincinnati, Ohio.
*1892. Thrasher, Allen B., Cincinnati, Ohio.
*1937. Tobey, George L., Jr., Boston, Mass.
*1888. Van der Poel, S. O., New York, N. Y.
*1938. Vail, Harris H., Cincinnati, Ohio.
*1936. Voislawsky, Antonie P., New York, N. Y.
*1933. Wanamaker, Allison T., Seattle, Wash.
1896. Ward, Marshall R., Pittsburgh, Pa.
*1879. Ward, Whitfield, New York, N. Y.
*1886. Westbrook, Benjamin F., Brooklyn, N. Y.
*1924. Wherry, William P., Omaha, Neb.
*1924. White, Leon E., Boston, Mass.
*1939. Williams, Horace J., Philadelphia, Pa.
*1942. Wishart, D. E. Staunton, Toronto, Canada.
*1922. Wishart, David J. G., Toronto, Canada.
*1940. Wood, V. Visscher, St. Louis, Mo.
*1896. Wollen, Green V., Indianapolis, Ind.
*1953. Wilkerson, William W., Nashville, Tenn.

INDEX

to the

TRANSACTIONS

of the

AMERICAN
LARYNGOLOGICAL ASSOCIATION

1970

INDEX

A

Address
Guest of Honor:
LeJeune, Francis E. 22

President: Miller, Alden H. 11

Analysis of Serial Sections
in Preoperative Radiation of Larynx
(Skolnik et al.) 101

Andrews, Albert H., Jr.
(see Caldarelli, D. D.) 32

Angiofibromas
Treatment of Juvenile Nasopharyngeal
by Radiotherapy (Briant et al.) 44

Asai Technique of Laryngectomy
(Putney and Bagley) 89

B

Bagley, Carter S.
(see Putney, F. J.) 89

Biller, Hugh F.
Laryngeal Edema: An Experimental
Study 68

Bone, Robert C.
(see Biller, H. F.) 68

Book, Howard
(see Briant, T. D. R.) 44

Briant, T. D. R.
Radiological Treatment of Juvenile
Nasopharyngeal Angiofibromas (with
P. J. Fitzpatrick and H. Book) 44

C

Caldarelli, David D.
Esophageal Motility Studies in
Globus Sensation 32

Cervical Osteophytes and Dysphagia
(Saunders) 25

Cherry, Jerrie
Vocal Cord Transplantation in Dogs
(with W. Davis, A. Rosenblatt and
R. Coleman) 80

Cohen, Seymour R.
Diagnosis and Surgical Management
of Congenital Tracheoesophageal
Fistula without Atresia of the
Esophagus 36

Coleman, R.
(see Cherry, J.) 80

Correlation of Clinical Staging, Path-
ological Findings and Five Year End
Results in Surgically Treated Cancer
of the Larynx (Norris-Tucker et al.) 110

D

Davis, W.
(see Cherry, J.) 80

Derbyshire, Arthur J.
(see Caldarelli, D. D.) 32

Diagnosis and Surgical Management of
Congenital Tracheoesophageal Fistula
without Atresia of the Esophagus
(Cohen) 36

Dysphagia
and Cervical Osteophytes
(Saunders) 25

E

Edema
Experimental Study in Laryngeal
(Biller et al.) 68

Esophageal Motility Studies in Globus
Sensation (Caldarelli et al.) 32

F

Farrior, Richard T.
Reconstructive Surgery Related to
Laryngology 52

Fistula
Diagnosis and Surgical Management of
Congenital Tracheoesophageal without
Atresia (Cohen) 36

Fitzpatrick, P. J.
(see Briant, T. D. R.) 44

H

Harvey, Joseph E.
(see Biller, H. F.) 68

Human Larynx Homotransplantation
(Kluyskens) 93

J

Johner, Carl H.
Polychondritis in a Newborn Presenting as Tracheomalacia (with P. Szanto) 77

K

Kaneko, Toshio
(see Kitamura, T.) 94

Kitamura, Takeshi
Supracricoid Laryngectomy (with T. Kaneko, K. Togawa and T. Unno) 94

Kluyskens, Paul
Human Larynx Homotransplantation 93

Kuo, Burns F.
(see Norris, C. M.) 110

L

Larynx
Correlation of Clinical Staging, Pathological Findings and Five Year End Results in Surgically Treated Cancer of Larynx (Norris et al.) 110

Edema, Experimental Study
(Biller et al.) 68

Human, Homotransplantation
(Kluyskens) 93

Reconstructive Surgery (Farrior) 52

Serial Sections Analysis in Preoperative Radiation (Skolnik et al.) 101

Supracricoid Laryngectomy
(Kitamura et al.) 94

Two Stage Asai Technique of Laryngectomy (Putney and Bagley) 89

Laryngotracheal Trauma in Combat Casualties (Miller) 72

LeJeune, Francis E.
Address of Guest of Honor 22

Levin, R. J.
(see Skolnik, E. M.) 101

M

Miller, Alden H.
Address of President 11

Miller, Lee H.
Laryngotracheal Trauma in Combat Casualties 72

Motility Studies
Esophageal, in Globus Sensation
(Caldarelli et al.) 32

N

Nasopharynx
Radiological Treatment of Juvenile Angiofibromas (Briant et al.) 44

Norris, Charles M.
Correlation of Clinical Staging, Pathological Findings and Five Year End Results in Surgically Treated Cancer of Larynx (with G. F. Tucker, W. F. Pitser and B. F. Kuo) 110

Ogura, Joseph H.
(see Biller, H. F.) 68

Osteophytes
Cervical, and Dysphagia (Saunders) 25

P

Pathological Findings
Correlation of Clinical Staging and Five Year End Results in Surgically Treated Cancer of Larynx (Norris-Tucker et al.) 110

Pitser, William F.
(see Norris, C. M.) 110

Polychondritis in a Newborn Presenting as Tracheomalacia (Johner and Szanto) 77

Preoperative Radiation of Larynx: Analysis of Serial Sections
(Skolnik et al.) 101

Putney, F. J.
Two Stage Asai Technique of Laryngectomy (with C. S. Bagley) 89

R

Radiation
Analysis of Serial Sections of Larynx in Preoperative (Skolnik et al.) 101

Radiological
Treatment of Juvenile Nasopharyngeal Angiofibromas (Briant et al.) 44

Reconstructive Surgery Related to Laryngology (Farrior) 52

Rosenblatt, A.
(see Cherry, J.) 80

S

Saunders, William H.
Cervical Osteophytes and Dysphagia ... 25

Skolnik, Emanuel M.
Preoperative Radiation of Larynx: Analysis of Serial Sections (with B. J. Soboroff, L. T. Tenta, M. E. Tardy, Jr., and R. J. Levin) 101

Soboroff, Burton J.
(see Skolnik, E. M.) 101

Szanto, Paul A.
(see Johner, C. H.) 77

Staging
Correlation of Pathological Findings and Five Year End Results in Surgically Treated Cancer of Larynx (Norris-Tucker et al.) 110

Supracricoid Laryngectomy
(Kitamura et al.) 94

T

Tardy, M. E., Jr.
(see Skolnik, E. M.) 101

Tenta, L. T.
(see Skolnik, E. M.) 101

Togawa, K.
(see Kitamura et al.) 94

Tracheoesophageal Fistula
Diagnosis and Surgical Management of Congenital without Atresia (Cohen) 36

Tracheomalacia
Polychondritis in a Newborn Presenting as (Johner and Szanto) 77

Transplantation
Vocal Cords in Dogs (Cherry et al.) ... 80

Treatment of Juvenile Nasopharyngeal Angiofibromas by Radiology
(Briant et al.) 44

Tucker, Gabriel F., Jr.
(see Norris, C. M.) 110

Two Stage Asai Technique of Laryngectomy (Putney and Bagley) 89

V

Vocal Cord Transplantation in Dogs
(Cherry et al.) 80