


Transactions

American Laryngological Association

NINETY-THIRD VOLUME

1972

PUBLISHED BY THE ASSOCIATION
CHARLES FOSS FERGUSON, M.D., Editor



"DOCENDO DISCIMUS"

TRANSACTIONS

OF THE

NINETY-THIRD ANNUAL MEETING

OF THE

American Laryngological Association

1972

HELD AT

THE BREAKERS

PALM BEACH, FLORIDA

APRIL 28 AND 29, 1972

PUBLISHED BY THE ASSOCIATION

ST. LOUIS, MISSOURI

CHARLES FOSS FERGUSON, M.D., Editor

1972

Contents.

	PAGE
Officers for 1971-72	7
Annual Photograph	8
Registration of Fellows for Annual Meeting	9

SCIENTIFIC SESSION

Presidential Address — Carcinoma of the Larynx: Analysis of 311 Cases Treated Surgically. F. Johnson Putney, M. D., Clifford E. Chapman, M.D.	11
Introduction of Guest of Honor, Louis H. Clerf, M.D., by F. Johnson Putney, M.D.	21
Remarks of Guest of Honor, Louis H. Clerf, M.D.	22
Address of Guest of Honor — Jacob DaSilva Solis-Cohen: Pioneer Laryngologist. Louis H. Clerf, M.D.	23
Early Development of the Human Laryngeal Muscles. Malcolm H. Hast, Ph.D.	27
Observations on the Embryology of the Human Larynx. John A. Tucker, M.D., Ronan O'Rahilly, M.D.	35
Steroid Treatment of Hemangioma of the Head and Neck in Children. Seymour R. Cohen, M.D., Chung-I Wang, M.D.	39
Discussion: Edley H. Jones, M.D.	45
Seymour R. Cohen, M.D. (closing)	45
Pharyngeal, Laryngeal, and Tracheal Injuries in the Pediatric Age Group. Paul H. Holinger, M.D., Joyce A. Schild, M.D.	46
Decannulation Problems in Infants. Daniel C. Baker, M.D., Lawrence Savetsky, M.D.	54
Surgical Correction of Subglottic Stenosis of the Larynx: Preliminary Report of an Experimental Surgical Technique. Blair Fearon, M.D., Robin Cotton, M.B.	57
Discussion of preceding presentations: Robert E. Priest, M.D.	62
William W. Montgomery, M.D.	62
Joseph P. Atkins, M.D.	63
Sabino Baluyot, M.D.	63
Alden H. Miller, M.D.	63
Herbert G. Birk, M.D.	63
Paul H. Holinger, M.D. (closing)	63
Blair Fearon, M.D. (closing)	64
Radiographic Findings in Adenoid Cystic Carcinoma of the Head and Neck. Gerald D. Dodd, M.D., Bao-Shan Jing, M.D.	65
Discussion: Walter P. Work, M.D.	72
Gerald D. Dodd, M.D. (closing)	72

CONTENTS

	PAGE
Management of Total Nasal Blockage by Polyps of Allergic and Infectious Origin. Sam H. Sanders, M.D.	73
Allergic Laryngitis. Russell I. Williams, M.D.	85
Discussion of preceding presentations:	
Richard T. Farrior, M.D.	92
William H. Wilson, M.D.	92
Sam H. Sanders, M.D. (closing)	92
Russell I. Williams, M.D. (closing)	93
Extraparotid Disease Simulating Parotid Masses. Richard D. Nichols, M.D.	94
External Trauma of the Larynx and Trachea: Immediate Management. Claude L. Pennington, M.D.	100
Discussion:	
Herbert H. Harris, M.D.	108
John A. Kirchner, M.D.	109
John J. Ballenger, M.D.	109
Douglas P. Bryce, M.D.	109
Joseph H. Ogura, M.D.	109
Claude L. Pennington, M.D. (closing)	109
Treatment of Vocal Cord Carcinoma by Vertical Hemilaryngectomy. James R. Leonard, M.D., Gordon P. Holt, M.D., Arnold G. Maran, M.D.	111
Discussion:	
Gabriel F. Tucker, Jr., M.D.	120
Richard T. Farrior, M.D.	120
Gordon P. Holt, M.D. (closing)	121
Reconstructive Laryngectomy: Report on the First 35 Cases. Prof. Michele Arslan, M.D.	122
Discussion:	
Joseph H. Ogura, M.D.	130
Abraham Lapidot, M.D.	130
Prof. Arslan, M. D. (closing)	130
Role of Surgery in the Management of Postcricoid and Cervical Esophageal Neoplasms. D. F. N. Harrison, M.D. (Read by Alden H. Miller, M.D. in Prof. Harrison's absence.)	132
Changes in the Respiratory Activity of the Cricothyroid Muscle with Intrathoracic Interruption of the Vagus Nerve. Hiroyuki Fukuda, M.D., John A. Kirchner, M.D.	136
Bilateral Vocal Cord Paralysis of Undetermined Etiology: Clinical Course and Outcome. H. Bryan Neel, M.D., Gary L. Townsend, M.D., Kenneth D. Devine, M.D.	142
Discussion of preceding presentations:	
Francis L. Lederer, M.D.	147
Charles M. Norris, M.D.	147
H. Bryan Neel, M.D. (closing)	147

CONTENTS

	PAGE
High Dosage Preoperative Radiation and Surgery for Carcinoma of the Larynx and Laryngopharynx.	
Joseph L. Goldman, M.D., Frederick G. Zak, M.D., Eric A. Birken, M.D., Jeffrey D. Roffman, M.D.	148
Discussion:	
Daniel Miller, M.D.	155
John A. Kirchner, M.D.	156
Joseph L. Goldman, M.D. (closing)	156
Complications Associated with Combined Therapy of Oral and Pharyngeal Neoplasms.	
Robert G. Smits, M.D., Charles J. Krause, M.D., Brian F. McCabe, M.D.	157
Discussion:	
Douglas P. Bryce, M.D.	161
Dilemma of Delayed Radiation Injury of the Larynx.	
Thomas C. Calcaterra, M.D., Floyd Stern, M.D., Paul H. Ward, M.D.	162
Memorials:	
Hugh G. Beatty, M.D.	170
Verling K. Hart, M.D.	172
W. Franklin Keim, M.D.	174
Bernard J. McMahon, M.D.	177
Executive Sessions	182
Reports of:	
Secretary, Frank D. Lathrop, M.D.	183
Treasurer, Charles M. Norris, M.D.	185
Librarian, Historian and Editor, Charles F. Ferguson, M.D.	188
Nominating Committee	189
American Board of Otolaryngology	190
American College of Surgeons, Board of Governors	190
Laryngological Research Fund Committee	191
Routine business	192
Benefactors	195
Recipients of de Roaldes Award	196
Recipients of Casselberry Award	197
Recipients of Newcomb Award	198
Past Officers	200
Past Fellows	205
Roster of Present Fellows, 1972	216
Active	216
Honorary	222
Corresponding	222
Emeritus	223
Officers for 1972-1973	226
Index	
Authors	228
Subjects	229

OFFICERS FOR 1971-1972

* * * *

PRESIDENT

F. JOHNSON PUTNEY, M.D.

FIRST VICE-PRESIDENT

JAMES A. HARRILL, M.D.

SECOND VICE-PRESIDENT

JAMES D. BAXTER, M.D.

SECRETARY

FRANK D. LATHROP, M.D.

TREASURER

CHARLES M. NORRIS, M.D.

LIBRARIAN, HISTORIAN AND EDITOR

CHARLES F. FERGUSON, M.D.

* * * *

COUNCIL

The above Ex-officio and

LAWRENCE R. BOIES, M.D.

FRANCIS W. DAVISON, M.D.

ALDEN H. MILLER, M.D.

DeGRAAF WOODMAN, M.D.



FELLOWS IN ATTENDANCE AT THE NINETY-THIRD ANNUAL MEETING

First Row (starting at bottom of picture): Prof. Arslan, Putney, Clerf, Schall, Ferguson, Lathrop, Norris, Cocke, Lewis, Woodman, Sanders. *Third Row*: Simonton, R. Williams, A. Miller, Atkins, Brown, Lederer, Hilding, Fearon, Ballenger, Holinger, Knight, Farrior, Weille. *Fourth Row*: Hanckel, Tabb, Goldman, Baker, Cohen, Tribble, Andrews, Cracovaner, Alexander, Fitz-Hugh, Weaver, Bryce. *Fifth Row*: Alfaro, Priest, A. Smith, Kirchner, Baxter, Jones, Morse, Sanders, D. Miller, Montgomery. *Sixth Row*: Arnold, Frazer, Murtagh, Suehs, Harris, Soboroff, Pang, Tucker, Pratt, Holmes, Friedberg, Ogura, McNally, Munoz-MacCormick.

TRANSACTIONS OF THE
NINETY-THIRD ANNUAL MEETING

OF THE

American Laryngological Association

HELD AT

THE BREAKERS

PALM BEACH, FLORIDA

APRIL 28 AND 29, 1972

* * * *

The Ninety-third Annual Meeting of the American Laryngological Association was called to order by the President, Dr. F. Johnson Putney, at The Breakers, Palm Beach, Florida, on Friday, April 28, 1972 at 8:05 A.M.

REGISTRATION OF FELLOWS

ACTIVE

ALEXANDER, FRED W.
ALFARO, VICTOR R.
ANDREWS, ALBERT H., JR
ARNOLD, GODFREY E.
ATKINS, JOSEPH P.
AUSBAND, JOHN R.
BAKER, DANIEL C., JR.
BALLENGER, JOHN J.
BAXTER, JAMES D.
BORDLEY, JOHN E.
BROWN, LESTER A.

BRYCE, DOUGLAS P.
COCKE, EDWIN W., JR.
COHEN, SEYMOUR R.
CRACOVANER, ARTHUR J.
DALY, JOHN F.
DAVISON, FRANCIS W.
DICKINSON, JOHN T.
FARRIOR, RICHARD T.
FEARON, BLAIR
FERGUSON, CHARLES F.
FITZ-HUGH, GLASSELL S.
FRAZER, JOHN P.

FRIEDBERG, STANTON A.	SANDERS, SAM H.
GOLDMAN, JOSEPH L.	SAUNDERS, WILLIAM H.
HANCKEL, RICHARD W.	SILCOX, LOUIS E.
HARRIS, HERBERT	SIMONTON, KINSEY M.
HILDING, ANDERSON C.	SKOLNIK, EMANUEL M.
HOLINGER, PAUL H.	SOBOROFF, BURTON J.
HOLMES, EDGAR M.	SUEHS, OLIVER W.
JONES, EDLEY H.	TABB, HAROLD G.
KIRCHNER, JOHN A.	THORNELL, WILLIAM C.
KNIGHT, JOHN S.	TRIBLE, WILLIAM M.
LATHROP, FRANK D.	TUCKER, GABRIEL F., JR.
LEDERER, FRANCIS L.	WEAVER, DELMAR F.
LEWIS, JOHN S.	WEILLE, FRANCIS L.
LILLIE, JOHN C.	WILLIAMS, RUSSELL I.
MCGOVERN, FRANCIS H.	WOODMAN, DEGRAAF
MILLER, ALDEN H.	WORK, WALTER P.
MILLER, DANIEL	HONORARY
MONTGOMERY, WILLIAM W.	CLERF, LOUIS H.
MORSE, HARRY R.	CORRESPONDING
MUNOZ-MACCORMICK, CARLOS E.	ARSLAN, MICHELE
NORRIS, CHARLES M.	EMERITUS
OGURA, JOSEPH H.	HOOPLE, GORDON D.
PANG, LUP Q.	KLINE, ORAM R.
PENNINGTON, CLAUDE L.	MCCALL, JULIUS W.
PRATT, LORING W.	MCNALLY, WILLIAM J.
PRIEST, ROBERT E.	MURTAGH, JOHN A.
PUTNEY, F. JOHNSON	SCHALL, LEROY A.
REED, GEORGE F.	SMITH, AUSTIN T.

SCIENTIFIC SESSION

FRIDAY MORNING, APRIL 28, 1972

The first Scientific Session of the Ninety-third Annual Meeting of the American Laryngological Association, Inc., held in the Venetian Room at The Breakers, Palm Beach, Florida, convened on Friday morning, April 28, 1972, at 8:30 A.M., F. Johnson Putney, M.D., of Charleston, South Carolina, President of the Association, in the chair.

PRESIDENTIAL ADDRESS

CARCINOMA OF THE LARYNX: ANALYSIS OF 311 CASES TREATED SURGICALLY

F. JOHNSON PUTNEY, M.D.

CHARLESTON, SOUTH CAROLINA

CLIFFORD E. CHAPMAN, M.D.

BRADENTON, FLORIDA

Realizing that the sheer mass of statistics can be overwhelming, an analysis was made of 311 consecutive unselected patients with carcinoma of the larynx treated surgically by the senior author from 1955 to 1960 and followed for a minimum of five years. Direct survival rates were used to determine the end results. The 20 patients that died prior to five years of causes unrelated to carcinoma while clinically free of the disease were considered failures. Of the latter, two were classified Stage I, 15 Stage II, 2 Stage III, and one Stage IV. While the actuarial or "life-table-analysis" provides information on patient depletion and turns out a survival profile, the minimum survival method as used in this study is the simplest procedure. It provides an accurate means of assessing results by removing as many variables as possible.

The TNM staging is based on the clinical impression of the origin of the tumor and is not correlated either with the invasiveness of the lesion or the pathologic specimen. This is the fault of any method of clinical evaluation, and this classification is intended as a guide to therapy rather than a description of the nature and extent of the tumor. In this series the lesions were classified according to the clinical involvement at the time of the initial

diagnosis and treatment rather than speculating about the origin of the tumor.

ETIOLOGY

Sex and Age. Of the 311 patients, 293 (96%) were males and 12 (4%) were females. The youngest patient was 33 and the oldest 83 years of age, with the majority being in the fifth decade of life.

Symptoms. Hoarseness was the predominant presenting symptom (92%) which is similar to that previously reported.¹ Other primary complaints were pain in the throat, difficulty swallowing and pain in the ear. Thirty-six patients (11%) had additional symptoms equally divided between difficulty in breathing and cough with a smaller number having hemoptysis (Fig. 1).

Smoking Habits. Cigarette smoking increased from 70% to 77% over a report 18 years ago.¹ The majority (53%) smoked two to three packs with an appreciable number (28%) consuming three to four packs daily. The mean was two and one-half packs per day. The nonsmokers made up 16% (Fig. 2).

Histology. The histologic diagnosis in all patients was squamous cell carcinoma graded as follows: low (Grade

From the Department of Otolaryngology, Medical University of South Carolina, Charleston, S. C.

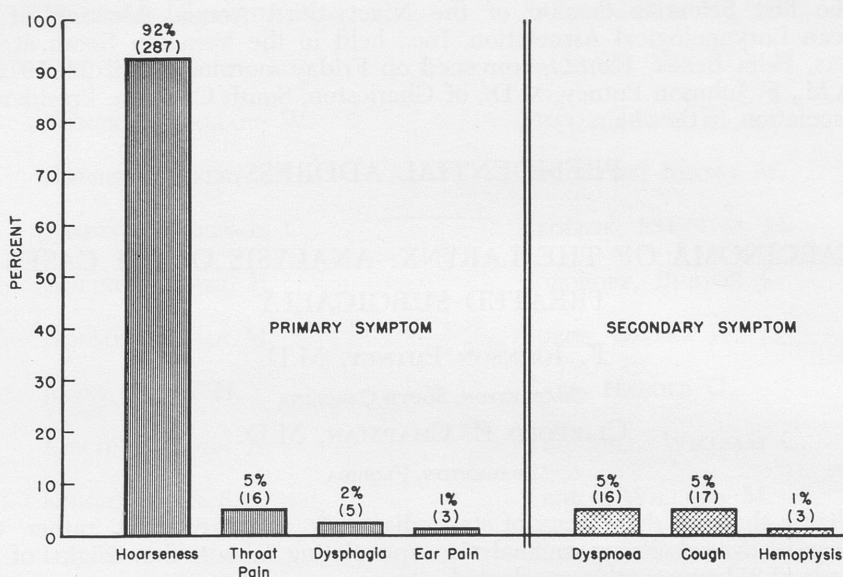


Fig. 1. Symptoms of laryngeal carcinoma in 311 patients.

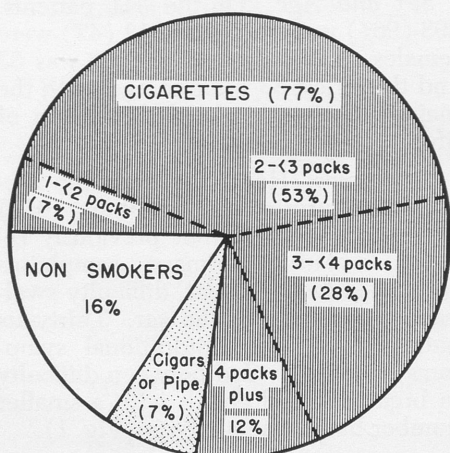


Fig. 2. Smoking habits of 311 patients with laryngeal carcinoma.

I) 24%; intermediate (Grades II and III) 73%; and high (Grade IV) 3%.

CLASSIFICATION

Staging by TNM categories as recommended by the American Joint Committee on Cancer Staging and End Results Reporting was used with modifications.² All lesions were placed in the more unfavorable prognostic location, for the selection of treatment must be

related to this factor rather than the site of origin. While this method is not entirely satisfactory and has its failings as brought out by Norris³ and others,⁴ it probably is an improvement over the original provisions. Involvement of contiguous anatomic sites made it difficult to accurately fix the source, e.g., a tumor invading the glottic and supra-glottic areas would be designated T³ and could be placed in either group. When areas adjacent to the glottis were involved, they were placed in the supra-glottic division. Transglottic has been used by some authors to categorize this situation.

The behavior of tumors in varying locations within the same stage also created a problem. A lesion of the anterior one-third of the vocal cord is dissimilar and has a different prognosis from one involving the arytenoid or posterior segment of the cord, yet both are designated as Stage I.

RECURRENCE AND METASTASIS

Seventy-three percent of the recurrences/metastases appeared within the first year and only 6% after three years. Those that developed in 78/311

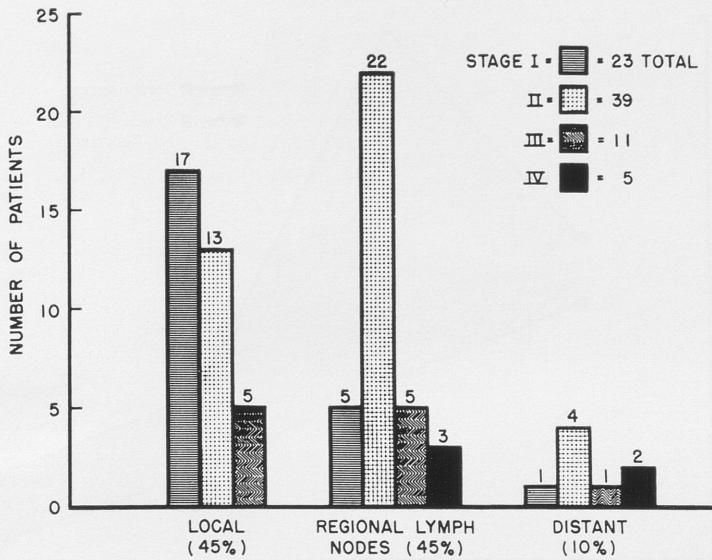


Fig. 3. Site of recurrence in 78 patients.

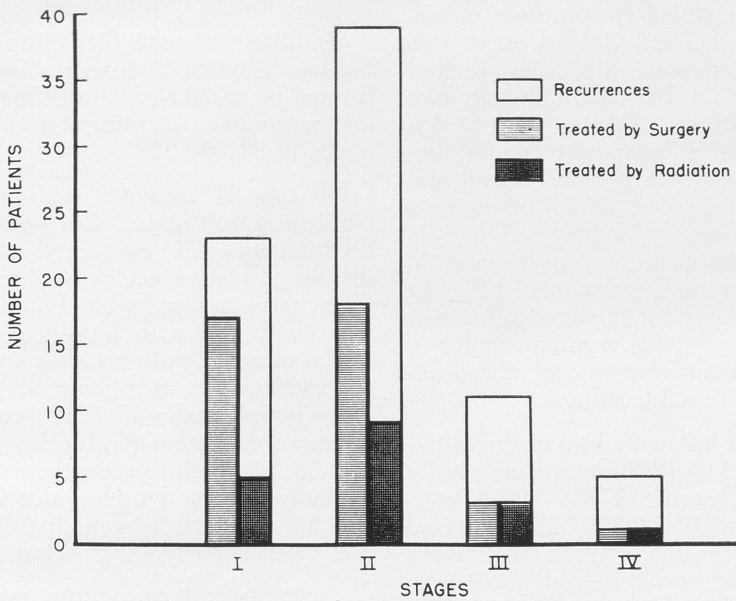


Fig. 4. Method of treatment of 78 patients with recurrences related to stages

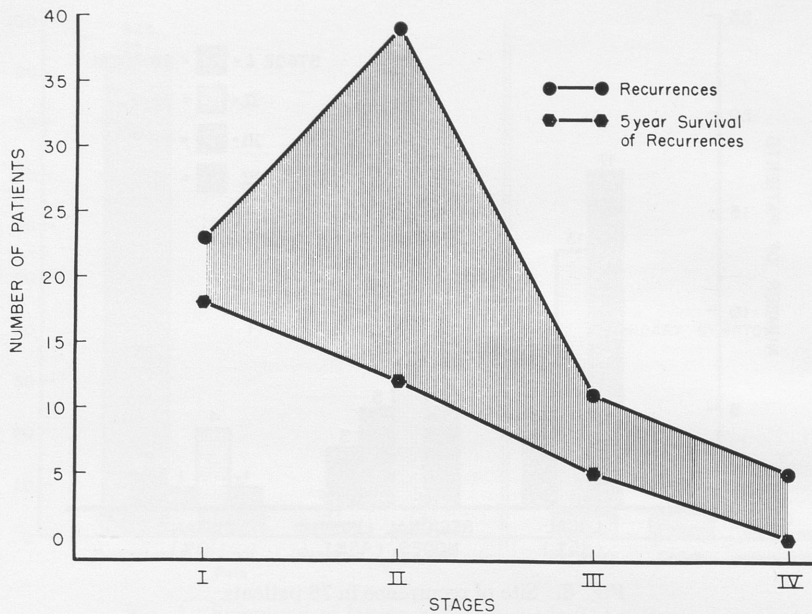


Fig. 5. Recurrences and five year survivals related to stages.

(25%) of the patients was almost equally divided between local recurrence and regional lymph node metastases (Fig. 3), and yielded an overall five year survival rate after further treatment of 31/78 (31%). Twenty-two of the 78 patients (28%), eight with distant metastases, were not treated because of the extent of involvement, and died of their disease. Of the 56 patients treated principally in Stages I and II additional surgery was performed in 39 and radiation therapy in 17 (Fig. 4) with a 63% five year salvage. Early discovery was probably a salient factor in the subsequent recovery of those receiving additional treatment.

In Stage I lesions failure of the initial therapy 28/118 (24%) was due mainly to local recurrence 17/28 (60%) with a salvage rate of 14/28 (50%), whereas in Stage II the majority of the failures 39/157 (25%) resulted from metastasis to regional lymph nodes 22/39 (56%), with a resultant salvage of 12/39 (31%). It was not surprising that the salvage rate in Stage III of 3/14 (21%) was less than the 31% in Stage II lesions, although the greater number of failures

occurred in Stage II (Fig. 5).

REGIONAL LYMPH NODE METASTASIS

Simultaneous neck dissection and definitive laryngeal surgery was performed on 96/311 (31%) of the patients, and carcinoma was present in the lymph nodes of 29/96 (30%).

Of the 34 patients with palpable cervical lymph nodes, 4 of which were bilateral, 16 (47%) contained metastatic disease. Elective neck dissection when there were no palpable lymph nodes was combined with laryngeal surgery in the other 62 patients with subglottic or supraglottic involvement, and of these lymph nodes 13 (21%) contained microscopic cancer (Table I). In a report in 1961,⁵ the percentage of histologically positive lymph nodes was 26%, so that metastasis in nonpalpable lymph nodes was slightly less in this series.

RESULTS OF SURGICAL TREATMENT

Two hundred thirty-three of the 311 patients (75%) survived five years or longer. The minimum five year survivals including salvage according to location were as follows: Supraglottic

TABLE I
HISTOLOGY OF CERVICAL LYMPH NODES

	<i>Palpable</i>	<i>Nonpalpable</i>	<i>Total</i>
Carcinoma Present	16/34 (47%)	13/62 (21%)	29/96 (30%)

TABLE II
OVERALL SURVIVALS RELATED TO LOCATION

<i>Supraglottic</i>	<i>Glottic</i>	<i>Subglottic</i>	<i>Total</i>
77/124 (62%)	142/167 (85%)	14/20 (70%)	233/311 (75%)

77/124 (62%); glottic 142/167 (85%); and subglottic 14/20 (70%) (Table II).

Stage I ($T_1N_0M_0$) — 90/118 — 76% five year survivals after initial surgery; 104/118 — 88% salvage after additional treatment.

One hundred eighteen patients (38%), located as follows: supraglottic 11, glottic 106, subglottic 1, had Stage I lesions. Ninety patients survived five years or longer after the initial surgery and 14 patients were salvaged by further surgery (Table III). Of the 14 deaths, 3 were located supraglottically, 9 glottically, and 2 died of other causes.

Stage II — 98/157 — 62% five year survivals after initial surgery; 110/157 — 70% salvage after further treatment.

In the $T_2N_0M_0$ group of 60 patients, 42 (70%) survived five years after the initial treatment and 46 (77%) after further treatment, in 18 of whom the tumor was supraglottic and 28 glottic (Table IV).

In the 84 $T_3N_0M_0$ patients, 52 (62%) survived five years after the initial treatment and 60 (72%) after further treatment. These were classified into supraglottic 32, glottic 15, and subglottic 13 (Table V).

TABLE III
SURVIVALS RELATED TO STAGE AND LOCATION

		<i>Supraglottic</i> (11)	<i>Glottic</i> (106)	<i>Subglottic</i> (1)	<i>Total</i> (118)
STAGE I					
$(T_1N_1M_0)$	Primary	8 (73%)	81 (76%)	1	90 (76%)
	Salvage	0	14	0	104 (88%)

TABLE IV
PRIMARY SURVIVALS RELATED TO STAGE AND LOCATION

	<i>Supraglottic</i> (86)	<i>Glottic</i> (55)	<i>Subglottic</i> (16)	<i>Total</i> (157)
STAGE II				
$T_2N_0(M_0)$	14/24 (58%)	28/36 (78%)		42/60 (70%)
T_3N_0	28/49 (57%)	13/19 (68%)	11/16 (69%)	52/84 (62%)
T_4N_0	4/13 (31%)			4/13 (31%)
Total	46/86 (54%)	41/55 (75%)	11/16 (69%)	98 (62%)

TABLE V
SURVIVALS INCLUDING SALVAGE RELATED TO STAGE AND LOCATION

	Supraglottic (86)	Glottic (55)	Subglottic (16)	Total (157)
STAGE II				
T ₂ N ₀ (M ₀)	18/24 (75%)	28/36 (78%)		46/60 (77%)
T ₃ N ₀	32/49 (63%)	15/19 (79%)	13/16 (81%)	60/84 (72%)
T ₄ N ₀	4/13 (31%)			4/13 (31%)
Total	54/86 (63%)	43/55 (78%)	13/16 (81%)	110/157 (70%)

TABLE VI
SURVIVALS RELATED TO STAGE AND LOCATION

		Supraglottic (20)	Glottic (5)	Subglottic (2)	Total (27)
STAGE III	Primary				13 (48%)
	Salvage				16 (59%)
T ₁ N ₁ (M ₀)	Primary	2			2/4 (50%)
	Salvage	1			3/4 (75%)
T ₂ N ₁	Primary	2	3		5/8 (63%)
	Salvage		1		6/8 (75%)
T ₃ N ₁	Primary	6			6/15 (40%)
	Salvage	1			7/15 (47%)

There were 13 T₄N₀M₀ lesions, all of which were supraglottic with 4 (31%) five year survivals.

The 15 other Stage II failures were in patients that died of other causes.

Stage III — 13/27 — 48% five year survivals after initial surgery; 16/27 — 59% salvage after additional treatment.

Of the four T₁N₁M₀ lesions, the two survivals were supraglottic; of the 8 T₂N₁M₀ lesions the five survivals were two in the supraglottic and three in the

glottic group; and of the 15 T₃N₁M₀ lesions the six survivals were all supraglottic (Table VI). One patient in each category was salvaged by further surgical therapy. Two deaths were from other causes.

Stage IV — 3/9 — 33% five year survivals.

In the two T₄N₁M₀ and the one T₁N₂M₀ patient survivals of the nine cases, the tumor was situated supraglottically (Table VII). One patient

TABLE VII
SURVIVALS RELATED TO STAGE AND LOCATION

		Supraglottic (7)	Glottic (1)	Subglottic (1)	Total (9)
STAGE IV	Primary				3 (33%)
	Salvage				0
T ₄ N ₁ (M ₀)	Primary	2			2/4 (50%)
	Salvage	0			0
T ₁ N ₂	Primary	1			1/2 (50%)
	Salvage	0			0

TABLE VIII
PRIMARY SURVIVALS RELATED TO SURGICAL PROCEDURES

<i>Stages</i>	<i>I (118)</i>	<i>II (157)</i>	<i>III (27)</i>	<i>IV (9)</i>	<i>Total (311)</i>
Partial Laryngectomy					98/129 (76%)
Thyrotomy	70/92	7/10			77/102 (75%)

died of other causes. There was no patient salvage.

TYPE OF SURGICAL TREATMENT

Partial laryngectomy (thyrotomy, supraglottic laryngectomy, and vertical hemilaryngectomy) with or without neck dissection was performed in 129 patients (42%), and total laryngectomy with or without neck dissection was chosen in the remaining 182 patients (58%).

The overall five year survival rate for those patients treated by all forms of partial laryngectomy without recurrence was 98/129 (76%). This type of surgical treatment was employed mainly in the T₁N₀M₀ and T₂N₀M₀ groups with 78% and 68% survivals, respectively.

One hundred two patients (33%) were treated by thyrotomy, and of these, 92 were in Stage I representing 78% of the Stage I lesions, with 70/92 (76%) primary survivals. Ten, or 6% of the Stage II lesions provided seven (70%) survivals after the initial surgery (Table VIII).

Supraglottic laryngectomy was performed in seven patients (2%). One patient with a Stage I lesion had a supraglottic laryngectomy alone, while in the five Stage II and the one Stage III

lesion it was combined with neck dissection (Table IX). The low incidence of this type of surgery is attributed to the fact that only during the latter years of the study was this surgical procedure utilized.

Vertical hemilaryngectomy accounted for 20 operations (6%), and of the 18 survivals, 6 were Stage I and 12 Stage II lesions. It was combined with neck dissection in one Stage II and one Stage III lesion (Table X).

Total laryngectomy alone was performed in 12 Stage I (10%) lesions with 9 primary survivals, and 78 Stage II (50%) lesions with 47 (60%) primary survivals. Laryngectomy with simultaneous neck dissection was carried out in 7 (6%) Stage I, 51 (33%) Stage II, 25 (93%) Stage III, and all 9 of the Stage IV lesions with the primary survivals 4 (57%), 30 (60%), 13 (52%), and 3 (33%), respectively (Table XI).

DISCUSSION

As expected, the recurrences and metastases increased and the survival rates decreased progressively from Stage I to IV. The five year survival rates were considerably greater for glottic lesions 142/167 (85%), and the

TABLE IX
PRIMARY SURVIVALS RELATED TO SURGICAL PROCEDURES

<i>Stages</i>	<i>I (118)</i>	<i>II (157)</i>	<i>III (27)</i>	<i>IV (9)</i>	<i>Total (311)</i>
Partial Laryngectomy					98/129 (76%)
Supraglottic Laryngectomy					3/7 (43%)
Alone	1/1				1/1
With Radical Neck		2/5	0/1		2/6

TABLE X
PRIMARY SURVIVALS RELATED TO SURGICAL PROCEDURES

Stages	I (118)	II (157)	III (27)	IV (9)	Total (311)
Partial Laryngectomy					98/129 (76%)
Vertical Hemilaryngectomy					18/20 (90%)
Alone	6/6	11/12			17/18
With Radical Neck		1/1	0/1		1/2

small group of subglottic lesions had a higher survival 14/20 (70%) than the supraglottic lesions 77/124 (62%).

Of the 78/311 (25%) recurrences or metastases, 28/78 (36%) developed in Stage I and 39/78 (50%) in Stage II lesions. Of these, approximately three-fourths were given further surgical treatment with a composite five year survival rate of 29/78 (37%). The high incidence of uncontrolled disease indicates that the primary surgical procedures were inadequate, albeit tempered somewhat by the resultant salvage.

In the recurrent Stage I lesions the salvage was 14/28 (50%) while in Stage II it dropped to 12/39 (31%). Some of the difference can be accounted for by the fact that in Stage I lesions failure of the initial therapy was chiefly due to local recurrences which were easier to control, whereas in Stage II the majority 22/39 (56%) resulted from metastasis to lymph nodes.

Stage II lesions require meticulous care in assessing the extent of the disease, and the treatment afforded this group of patients should be carefully individualized to insure optimum treatment. There was only a 5% difference between the survival rates of the patients in the $T_2N_0M_0$ (77%) and the $T_3N_0M_0$ (72%) classifications. The 31%

five year survivals in the $T_4N_0M_0$ group followed the initial surgery with no salvage. Of the patients dying of other causes clinically free of cancer, 15/20 (75%) were Stage II.

Twenty-two percent of all patients in Stage II treated by operations not including radical neck dissection developed cervical lymph node metastasis later, while 17% of those treated with elective neck dissection had positive lymph node involvement on histologic study. This suggests that the incidence of occult cervical metastasis in Stage II lesions is somewhere within this range. The significant number of metastases in the cervical lymph nodes of patients in the Stage II classification brings up the desirability of increasing the number of elective neck dissections in this category, yet 4/8 (50%) of the distant metastasis occurred in Stage II, and elective neck dissection would not have prolonged life in these patients.

In Stage III the five year survival rate with no recurrence/metastasis of 13/27 (48%) was further divided into $T_1N_1M_0$ (2/4), $T_2N_1M_0$ (5/8) and $T_3N_1M_0$ (6/15) lesions. Three of the 14 recurrent/metastatic cases were salvaged after further treatment. When combined with the primary survivals the integrated five year surgical survival rate was 16/27 (59%).

TABLE XI
PRIMARY SURVIVALS RELATED TO SURGICAL PROCEDURES

Stages	I (118)	II (157)	III (27)	IV (9)	Total (311)
Laryngectomy					
Alone	9/12	47/78			56/90 (62%)
With Radical Neck	4/7	30/51	13/25	3/9	50/92 (54%)

Even though the number of patients was small the survival of 3 out of 9 Stage IV lesions indicates that radical surgical therapy should be undertaken in these patients. Of the 6 failures, 3 died of cervical lymph node metastasis, 2 of distant metastasis, and one of causes not related to carcinoma. No patients were salvaged in this stage.

Radiation, either as the primary treatment or in combination with surgery was not employed in this group of 311 cases. The findings are indicative of the results obtained by surgical treatment.

When the surgical survival figures are corrected by eliminating those patients dead of other causes to conform to the manner Lathrop⁶ used in reporting the 10 year results of supervoltage radiation, a basis for comparative figures in Stages I and II can be obtained. The minimum five year survival rates for lesions treated initially by surgery and by radiation exclusive of salvage was identical: in Stage I ($T_1N_0M_0$) 76% by both surgery and radiation; in Stage II ($T_2N_0M_0$ and $T_3N_0M_0$ only) the figure was 70% for each.

Wang and Schulz⁷ treated 276 patients primarily by radiation therapy with an overall minimum five year survival rate of 51% as compared with this surgical series of 75%. When broken down further according to stages without recurrences, the results with the radiation preceding the surgical figures were as follows: Stage I, 73% to 76%; Stage II, 65% to 62%; Stage III, 42% to 48%; and Stage IV, 12% to 33%. Except for Stage IV lesions the results are alike.

SUMMARY

Three hundred eleven consecutive unselected patients with carcinoma of the larynx, treated surgically during a five year period and followed for a minimum of five years, were evaluated. Minimum survival rates were used to determine the end results following the TNM classification as presented by the American Joint Committee. The over-

all five year survival rate for the series was 233/311 (75%).

The five year survival rates including those salvaged by further treatment according to stages were:

Stage I — 104/118 (88%); Stage II — 110/157 (70%); [$T_2N_0M_0$ — 46/60 (77%); $T_3N_0M_0$ — 60/84 (72%); $T_4N_0M_0$ — 4/13 (31%)] Stage III — 16/27 (59%); [$T_1N_1M_0$ — 3/4 (75%); $T_2N_1M_0$ 6/8 (75%); $T_3N_1M_0$ 7/15 (47%)] and Stage IV — 3/9 (33%).

Analyzed according to location the five year survival rate in supraglottic lesions was 77/124 (62%); glottic 142/167 (85%); and subglottic 14/20 (70%).

In relation to the operation employed, partial laryngectomy yielded 98/129 (76%) primary five year survivals. Of these, thyrotomy provided 77/102 (75%), supraglottic laryngectomy with or without neck dissection 3/7 (43%), and vertical hemilaryngectomy alone or with neck dissection 18/20 (90%). Laryngectomy alone afforded 56/90 (62%) and laryngectomy with neck dissection 50/92 (54%) survivals.

In the 78/311 (25%) of patients developing recurrence or metastasis, eight of which were distant, a 31% overall five year survival rate was obtained after further treatment.

In Stage I lesions the salvage following additional surgery was 14/28 (50%). In Stage II the majority of failures resulted from metastasis to regional lymph nodes 22/39 (56%) with a subsequent 12/39 (31%) salvage after surgery.

The cases with recurrence/metastasis in Stage III were too small to be statistically significant, yet the 3/14 (21%) salvage indicated that further treatment was not futile.

Surgical treatment controlled 3/9 (33%) of the Stage IV lesions for five years or longer, and there was no later salvage in this group.

REFERENCES

1. Baltzell WH, Putney FJ: Cancer of the larynx. *Arch Otolaryng* 60: 478-481, 1954
2. Smith R, Caulk RM, Russell WO, et al: End results in 600 laryngeal cancers using the American Joint Committee's Proposed Method of Stage Classification and End Results Reporting. *Surg Gynec Obstet* 113: 435-444, 1961
3. Norris CM: Problems in Classification and staging of cancer of the larynx. *Ann Otol* 72: 83-96, 1963
4. Conley J: *Cancer of the Head and Neck*. Washington, Butterworths, 1967, p. 375-379
5. Putney FJ: Elective versus delayed neck dissection in cancer of the larynx. *Surg Gynec Obstet* 112: 736-742, 1961
6. Lathrop FD: Evaluation of supervoltage radiation therapy for carcinoma of the larynx. *Ann Otol* 77: 493-507, 1968
7. Wang CC, Schulz MD: Treatment of cancer of the larynx by irradiation. *Ann Otol* 72: 637-646, 1963

INTRODUCTION OF GUEST OF HONOR, LOUIS H. CLERF, M.D.

PRESIDENT F. JOHNSON PUTNEY, M.D.

Twenty years ago Dr. Louis H. Clerf was elected President of the American Laryngological Association, and today he is our Guest of Honor. Actually this is all that needs to be said, for Dr. Clerf means many things to many people. He has endeared himself to the members of this Association and to enumerate his accomplishments in the field of Laryngology would be uncalled for before this audience.

I might mention just a few of his other achievements that may not be as well known. During the early 1950's Dr. Clerf served as interim Dean of the Jefferson Medical College. During this time he devoted much of his energy to the duties of the college, but relinquished these to give his full time to clinical and scientific medicine, realizing that he could not do justice to teaching and medical practice while occupied with administrative matters. He served as President of the Pennsylvania State Medical Society and the Philadelphia County Medical Society from which he received its select Strittmatter award.

We all know his skill in endoscopic foreign body removal, and this ability was carried over to the extraction of coins from the pockets of his fellow alumni, for he not only initiated and set up the organization necessary for the annual Jefferson Alumni Giving Fund but guided it through its first three critical years. The success of the drive during this early period established a firm foundation from which continued success has made it the largest Alumni Fund in the country

with a current annual donation in excess of one third of a million dollars.

His proficiency in the field of medical photography is well known, and his background as a naturalist and sportsman have enabled him to continue his interest in the photography of wildlife in its natural habitat. He has always been deeply interested in the birds and can identify many of their calls as well as imitate them. An ardent garden lover, he knows the botanical names of flowers and plants and can give quite a dissertation on leaves and bits of shrubs relating to growth and the various sections of the country where they are found.

The esteem in which he is held by the men whom he has trained is a mark of his inspirational influence, and I cannot let this moment pass without paying my own personal tribute. He has been my friend, teacher and advisor, and his example has been my guide line. Even though he was prohibited from practicing aspects of Otolaryngology other than Laryngology and Bronchoesophagology in his early years, his keen insight recognized the need for practicing the broad aspects of the specialty which resulted in my residency at the Manhattan Eye, Ear and Throat Hospital. His advice regarding medical societies was to join these as early as possible before one makes too many enemies.

I am happy to present Dr. Clerf as the guest of honor, and in honoring him we are also honoring the American Laryngological Association.

REMARKS OF GUEST OF HONOR

LOUIS H. CLERF, M.D.

I enjoyed very much what Dr. Putney said about me. In fact, I wish he had continued. I would have learned more about myself. He is a good genealogist and that reminds me of a story.

This man wished to trace his ancestors and consulted a genealogist. The family tree revealed that a grand-uncle

had been convicted of a felony and was electrocuted at Sing Sing. He, therefore, wished to have this relative removed from the tree but finally accepted the genealogist's revised version. It stated that "a grand uncle had occupied the chair of Applied Electricity at a famous institution in a large eastern city. He died in harness."

ADDRESS OF GUEST OF HONOR, LOUIS H. CLERF, M.D.

JACOB DASILVA SOLIS-COHEN, M.D.
PIONEER LARYNGOLOGIST

LOUIS H. CLERF, M.D.
ST. PETERSBURG, FLORIDA

Mr. President and Fellows of the American Laryngological Association, it is a great privilege to be the Guest of Honor and I am grateful to you.

This Association was founded in 1878, about the time that surgical measures were being considered for treatment of cancer of the larynx. The first recorded laryngectomy for cancer was performed in 1873 by Theodor Billroth of Vienna. The frequency of fatal aspiration pneumonia with a mortality rate of nearly 100% did much to discourage its general acceptance. It is gratifying, therefore, to hear our President report surgical experiences and a statistical analysis of his cases of cancer, and then attempt to visualize in retrospect the progress made in surgical treatment of this disease since Billroth's operation 99 years ago.

In Thomson and Negus' textbook "Diseases of the Nose and Throat"¹ section on Laryngectomy, reference is made to the high mortality among the early cases. They stated, "Later on, much better operative results were obtained, particularly in so far as immediate danger from the operation is concerned, by adopting Solis-Cohen's method of completely severing the trachea, and detaching it from the larynx, pharynx and esophagus. The orifice of the trachea is then secured to the skin in the middle of the neck."

As one reads medical literature on cancer of the larynx it is noted that many of the major contributions to im-

proved diagnostic methods and notably surgical treatment and postoperative care have been made by Fellows of this Association. The first of these was Dr. Jacob DaSilva Solis-Cohen. Our President expressed interest in Solis-Cohen's work in this field so if you will bear with me I shall present a brief biography of this distinguished laryngologist.

Jacob Solis-Cohen was born in New York City on February 28, 1838. The family moved to Philadelphia in 1840 where he secured his early education, attended lectures at Jefferson Medical College and then received his medical degree from the University of Pennsylvania in 1860. After serving part of his residency at Old Blockley, he enlisted as a private in the U.S. Army. He was soon transferred to the Medical Corps as an Assistant Surgeon, resigned his commission after one year of service and accepted an appointment as Assistant Surgeon in the U.S. Navy.

At the termination of the Civil War he returned to Philadelphia to resume practice and took up laryngology as a specialty. He used Morell Mackenzie's little volume "The Use of the Laryngoscope" as a textbook. He was greatly interested in the laryngeal mirror as a diagnostic aid and became proficient in its use. Having established himself as a specialist in laryngology, in 1866 he instituted regular organized lectures on laryngology at the Philadelphia School of Anatomy; this was the first systematic course in laryngology for undergrad-

uates in America, and later he was appointed lecturer on laryngology and diseases of the throat and chest at Jefferson Medical College. A clinical service in the Collegiate course was established within two years, and in 1882 he was elected honorary Professor of Laryngology. He continued to supervise the throat clinic until the late 90's when he retired from teaching. When the Philadelphia Polyclinic was established in 1883 he was one of the founders, became a Professor of diseases of the throat and chest and established a laryngological clinic.

In 1872 he published his classical work, "Diseases of the Throat," a guide to the diagnosis and treatment of affections of the pharynx, esophagus, trachea, larynx and nares, a volume of 583 pages. This gave a full exposition of all then known concerning the subjects of that specialty. Delavan² considered it more complete and comprehensive than anything that had appeared in this country or in Europe.

Dr. Solis-Cohen's surgical experience in the Civil War proved invaluable. During 1867 he did a laryngotomy for a large fibrous tumor of the vocal cord, a procedure which had been performed by others for benign lesions. On February 25, 1868 he performed the first successful laryngotomy in the world for cancer of a vocal cord.^{3,4} Two biopsies had confirmed the diagnosis. A preliminary tracheotomy was performed by Dr. Cohen assisted by Dr. D. Hayes Agnew who later became Professor of Surgery at the University of Pennsylvania. The laryngotomy was performed under chloroform anesthesia with the assistance of several prominent surgeons and in the presence of a distinguished audience including Professors Samuel D. Gross and William Pancoast. The patient made a good recovery and visited Dr. Cohen at his office on the tenth postoperative day. There was no recurrence and the patient was reported as having died from apoplexy over 20 years later. The procedure as performed by Dr. Cohen was quoted by Professor Von Bergmann as his proposed opera-

tion to remove the tumor of the vocal cord of Crown Prince Frederick of Prussia in 1887.

Dr. Delavan⁵ credits Dr. Cohen with performing the first really complete laryngectomy in America and introducing the now well recognized technique "by which the severed end of the trachea is caused to emerge from the lower part of the neck and is there attached." In a discussion of Mackenty's paper on one-stage laryngectomy,⁶ Delavan, referring to the work of Professor Gluck of Berlin stated: "He (Gluck) adopted in the main, the principles utilized by Solis-Cohen in his celebrated case, the first of its kind operated upon in this country in 1884, the patient surviving eleven years and dying without recurrence." In 1887 Cohen presented before the American Laryngological Association "A Description of a Modified Laryngectomy."⁷ This was really a partial laryngectomy. There is no reference in the article about performing this operation on a living patient. His first report in the literature about laryngectomy on a living patient appeared in 1892 and was reported to the American Laryngological Association at its meeting in Boston.

Dr. D. Bryson Delavan of New York, a contemporary and great admirer of Solis-Cohen was elected to this Association in 1881, became its Secretary in 1882 and was elevated to the Presidency in 1893. He was active in the field of laryngology, attended many foreign and international meetings and was more conversant with progress made in the field of laryngology than the average laryngologist. It would appear, therefore, that in spite of failure to find any published report by Dr. Solis-Cohen of a laryngectomy performed by him prior to 1892, one can accept Delavan's report of the 1884 operation as authentic.

During March, 1892, Solis-Cohen did a laryngectomy on a patient⁸ who had been treated for papilloma of the larynx by Dr. George M. Lefferts in 1876. The patient consulted Dr. Solis-Cohen during January, 1892. He found marked




Fig. 1. Jacob DaSilva Solis-Cohen, M.D.

obstruction of the larynx by what appeared to be papilloma, and an attempt was made to remove it by laryngotomy. The lesion recurred promptly and a total laryngectomy was performed. He was assisted by Dr. W. W. Keen, Professor of Surgery, and Dr. Orville Horowitz, Professor of Urology. In his postoperative notes Dr. Cohen stated "I stayed with him for sixteen hours and during that time I instructed a number of young men connected with the throat and surgical clinics of the hospital how to take charge of the case. Two members of the Staff were with him constantly for eighty hours." He commented further that it was due to the close attention of these young men for the first 80 hours that this man owed his life. He continued this practice of assuming the immediate after-care of patients throughout his surgical career. This practice was emulated by Mackenty⁶ who enumerated certain surgical principles when he reported to this As-

sociation in 1925, 77 consecutive cases of total laryngectomy without a surgical death.

Fourteen months after the laryngectomy in 1892, Solis-Cohen⁹ presented this patient at the annual meeting of the Association held in New York in 1893 as a case of pharyngeal voice, one who phonates without a larynx and without the use of his lungs. Many of the Fellows examined the patient and in the discussion Dr. Lefferts, who had removed a large papilloma from the patient's larynx 18 years previously, and others, expressed the opinion that the voice was produced by the tongue and lips. Dr. Solis-Cohen agreed that the articulation was performed in this manner but that the phonetic reed was lower down.

As a founder of the American Laryngological Association his influence was profound. Elected its second President, the first two meetings held under his

auspices marked the beginning of its remarkable history. Commenting on the marvelous advances made in laryngology, Delavan considered Solis-Cohen as its first and greatest leader, "at the head of his compatriots, there never was a time in the active years of his long march when he was not the acknowledged Chief." With his surgical experience gained during the war years he excelled in surgery of the upper air passages. In a paper on "Surgical Treatment of Cancer of the Larynx"¹⁰ he stated "The after treatment of the patient requires the combined services of a laryngological and surgical mind, and I am one of those who believe that every laryngologist should do as much as possible of his own surgery. I have always advocated it, and if he is in doubt about his ability to do those operations, he should have by his side the proper assistance and do the oper-

ation on general surgical principles. At all events he should not allow all his surgical cases to go to the surgeons."

Time and space do not permit listing all the textbooks and medical articles he wrote, his membership in medical and scientific societies, his activities in civic and religious organizations and the many honors bestowed upon him. A profound scholar, a facile writer, his contributions indicated a high degree of scientific ability and led to many interests not strictly related to his profession.

Dr. Solis-Cohen died in Philadelphia on December 22, 1927 about two months before his ninetieth birthday. Again quoting Delavan, "he departed with the last days of the dying year, days most appropriate for the closing of a perfectly finished life."

5575 EIGHTH AVENUE, NORTH, ST. PETERSBURG, FLA. 33710

ACKNOWLEDGMENT—My thanks to the Staff of the Scott Library, Jefferson Medical College, for their assistance.

REFERENCES

1. Thomson and Negus: Textbook, Diseases of the Nose and Throat. London, 4th Ed., 1937
2. Delavan DB: Trans. A.L.A. 156, 1918
3. Solis-Cohen J: Surgical affections of the larynx. Med Record 4: 244, 1869-70
4. Solis-Cohen, Meyer: The Old Philadelphia Laryngological Society. Ann Med History 3: 118, 1941
5. Delavan DB: Trans. A.L.A. 110, 1928
6. Mackenty JE: Plea for one-staged operation for total laryngectomy. Trans. A.L.A. 152, 1925
7. Solis-Cohen J: Description of a modified laryngectomy. Trans. A.L.A. 38: 1887
8. Solis-Cohen J: Two cases of laryngectomy for carcinoma of larynx. Trans. A.L.A. 60: 1892
9. Solis-Cohen J: Pharyngeal voice. Trans. A.L.A. 114: 1893
10. Solis-Cohen J: Surgical treatment of laryngeal cancer. Trans. A.L.A. 75: 1900

EARLY DEVELOPMENT OF THE HUMAN LARYNGEAL MUSCLES

MALCOLM H. HAST, PH.D.

CHICAGO, ILLINOIS

In the study of the developmental anatomy of the human, one of the most neglected organs has been, and still is, the larynx. This has been particularly true for the period covering the last half century. Quantitatively, and in most cases, qualitatively, the greater part of the research on the developmental anatomy of the larynx has been contributed by those who worked in the "golden age" of embryology, the late nineteenth and early twentieth centuries. I refer, of course, to the classical work of His,¹ Strazza,² Kallius,³ Soulié and Bardier,⁴ Frazer,⁵ and Lissner.⁶ With the exception of a few pieces of work, Blumberg et al.⁷ for example, research from the recent past has contributed findings based principally on the study of the fetal stage of development and growth. In addition, where study of the earlier stages was made by the "classical" investigators, conclusions can be tenuous since findings were derived from an examination of only 5 to 10 representative specimens covering all stages of development. For the important experimental requirements of validity and reliability to be secured, many specimens at each stage of development must be studied.

The purposes of this study were: 1) to determine the development of the human laryngeal muscles from primordium to differentiation in the later embryonal stages, employing a large series of embryos; and 2) to compare the findings of this investigator to those

reported in the literature.

METHODS AND MATERIAL

A study was made of serial sections of 50 human embryos, crown rump (CR) 4.7 to 29 mms (4 to 8 weeks) from this author's collection and those of four other institutions, the Universities of Washington (Seattle), Illinois, Michigan and Harvard.* Specimens from this collection were obtained from the Central Laboratory for Human Embryology, University of Washington School of Medicine. Before delivery to our laboratory, the fresh specimens were graded according to quality, measured, (crown rump) and gestational age determined either from clinical records or derived by a standard method.^{8,9}

After fixation, all specimens were embedded in celloidin, sectioned serially either in the sagittal or horizontal plane at 6 to 20 μ and every section stained by using either a standard H and E method or trichrome stain (acid fuchsin, orange G and fast green).

After a careful study of all embryos by light microscopy, photomicrographs were taken of selected sections from this collection and, where possible, from those of other institutions. In addition, tracings were made of sections of the larynx with the use of a binocular drawing apparatus, and the penciled drawings transferred to sheets of celluloid with India ink. The images of each section were then stacked to form a transparent model which when held in front of a light source gave a multidimensional view of the larynx.

OBSERVATIONS AND DISCUSSION

Histological examination of the embryos revealed that development of the laryngeal muscle can be divided into six embryonic stages: Stage I CR 4 to 6 mms, Stage II CR 7 to 9 mms, Stage III CR 10 to 12.5 mms, Stage IV CR 13 to 15 mms, Stage V CR 16 to 18 mms, and

* The author will provide a detailed list of the embryos studied upon request.

From the Department of Otolaryngology and Maxillofacial Surgery, Northwestern University Medical School, Chicago, Ill.

This study was supported by PHS Research Grants NS 08733 and HD 00836.

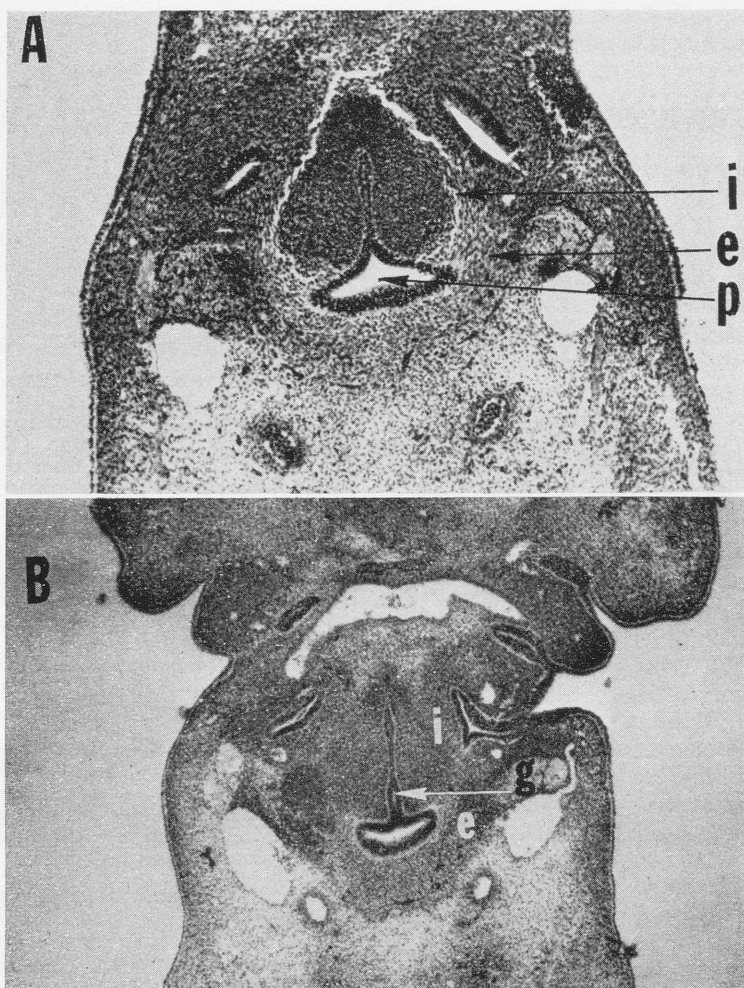


Fig. 1. A) Embryonic larynx of CR 7 mms (32 days); i: anlage of internal constrictor; e: anlage of external constrictor; p: pharynx. B) Embryonic larynx of CR 9.5 mms (5½ weeks); i: anlage of internal constrictor; e: anlage of external constrictor; g: glottis.

Stage VI CR 19 to 23 mms. It is, of course, realized that these are arbitrary working categories and that their boundaries are overlapping rather than defined.

In the first stage (4 to 6 mms), the primitive glottic slit is observed surrounded by condensations of undifferentiated mesenchyme; the cells are denser at the glottis and appear to be migrating peripherally. It is at this stage that Frazer⁵ recognizes two planes of "circularly disposed cells," defining

them as the *inner* constrictor of the fifth arch and the *external* constrictor of the fourth arch. Although I agree with Frazer⁵ that an external constrictor, the anlage of the inferior constrictor muscle, may be observed at this stage, I find no recognizable form of inner constrictor of muscle cells. It is in the second stage at 7 mms, where the anlage of the cricoid and arytenoid cartilages can be recognized, that one can differentiate both inner and external constrictors (Fig. 1). It is Frazer's hypothesis that this inner constrictor is

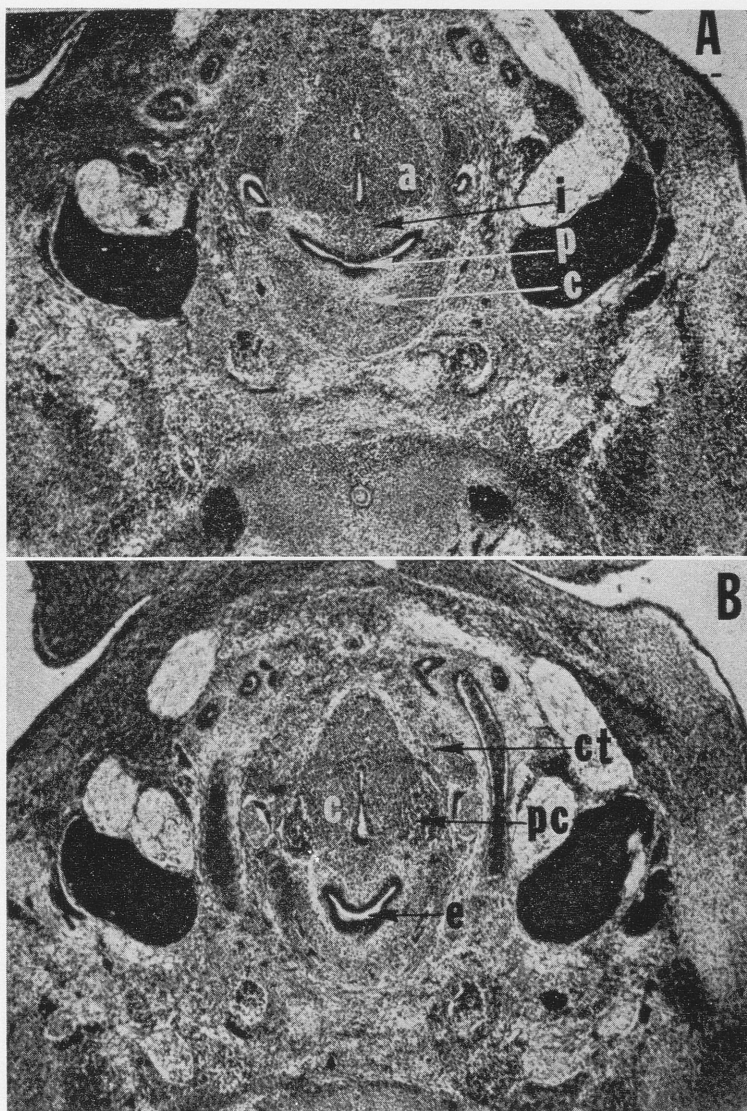


Fig. 2. Embryonic larynx of CR 13 mms (42 days). A) a: anlage of arytenoid cartilage; c: pharyngeal constrictor; i: anlage of interarytenoid muscle; p: pharynx. B) c: anlage of cricoid cartilage; ct: anlage of cricothyroid muscle; pc: anlage of posterior cricoarytenoid muscle; e: esophagus.

the primordium for all of the intrinsic laryngeal muscles of the larynx except for the cricothyroid, a derivative of the fourth arch.⁵ I agree and confirm this hypothesis; a similar view was also held by Strazza² that the earliest indication of a laryngeal mass of muscles is found as an inner constrictor.

The inner and external planes of cells

are more clearly defined at the beginning of the third stage (10 to 12.5 mms) and with difficulty, one can even differentiate several individual laryngeal muscles by the 12 mm embryo. Lisser⁶ believed that the muscles develop independently and not as a sphincter, and that all the laryngeal muscles are visible at this stage. He found some fibers

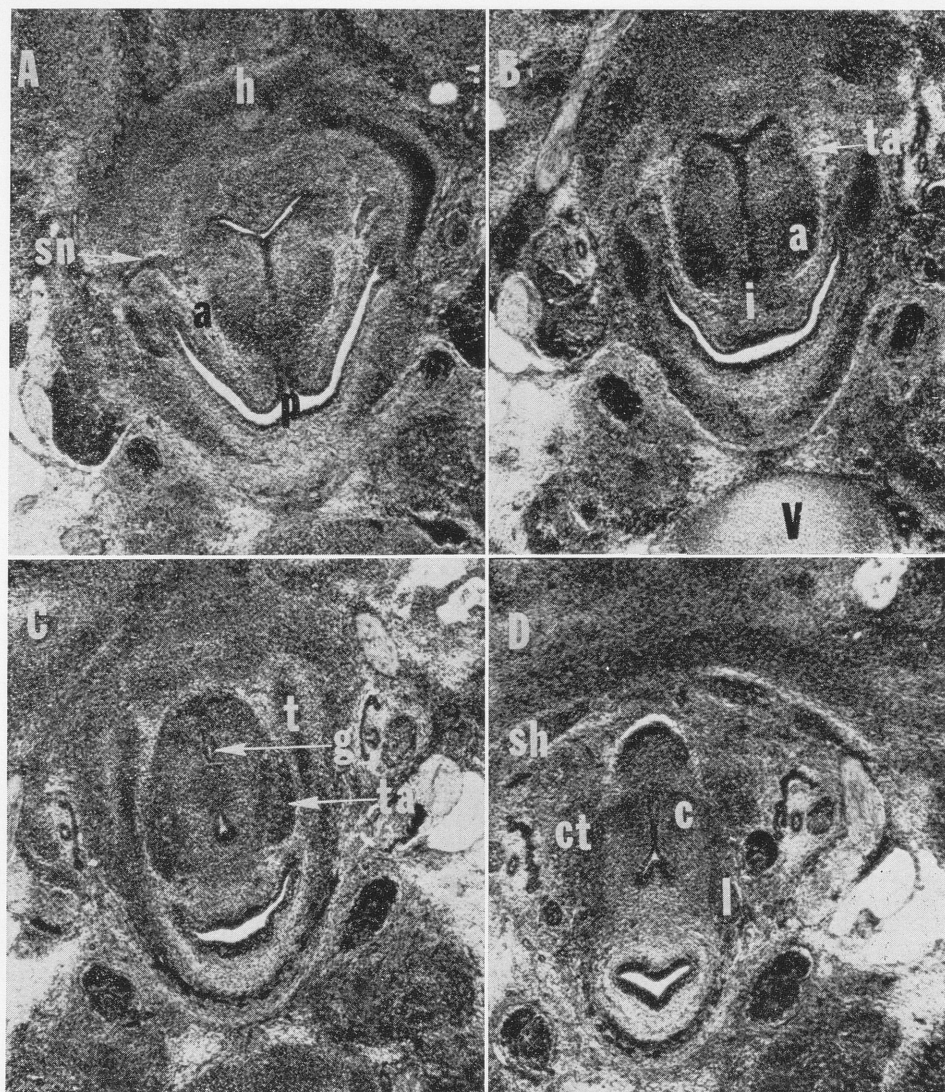

Fig. 3. Embryonic larynx of CR 15 mms (44 days). A) h: hyoid bone; sn: superior nerve; a: anlage of aryepiglottic muscle; p: pharynx. B) ta: anlage of thyroarytenoid muscle; a: arytenoid cartilage; i: interarytenoid muscle; V: cervical vertebrae. C) t: anlage of thyroid cartilage; g: glottis; ta: anlage of thyroarytenoid muscle. D) sh: sternohyoid muscle; ct: anlage of cricothyroid muscle; c: cricoid cartilage; l: anlage of lateral cricoarytenoid muscle.

of the lateralis and thyroarytenoid but not clearly differentiated from each other; no interarytenoid muscle was found until the 12.5 mm embryo. Lisser also observed that the cricothyroid could not be separated from the lateralis.

I question the positive identification

of any laryngeal muscle as early as 10.5 mm. Strazza² would agree with Lisser that the first muscle to develop separately is the posterior cricoarytenoid but he could not differentiate this muscle until the 16 mm embryo; the present investigator could positively identify it in the 13 mm embryo (Fig.

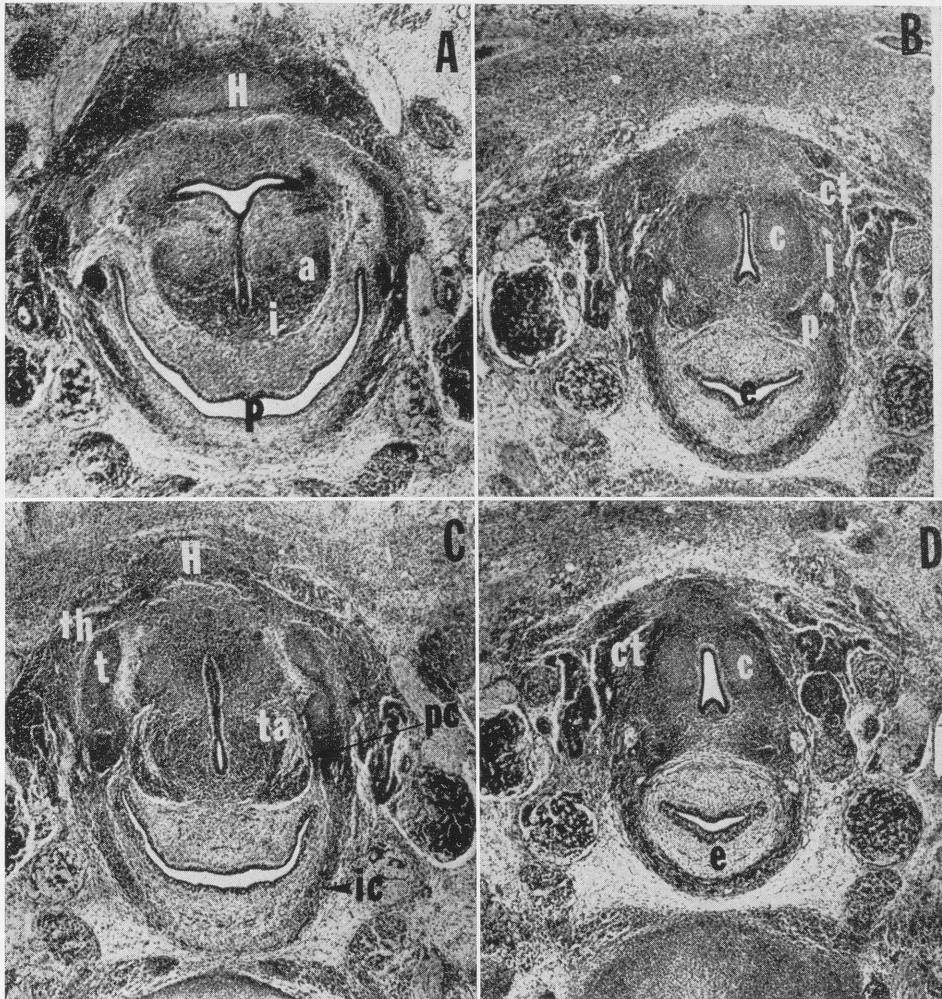


Fig. 4. Embryonic larynx of CR 18 mms (46 days). A) H: hyoid bone; a: arytenoid cartilage; i: interarytenoid muscle; p: pharynx. B) ct: cricothyroid muscle; p: posterior cricoarytenoid muscle; c: cricoid cartilage; l: lateral cricoarytenoid muscle. C) H: hyoid bone; th: thyrohyoid muscle; t: thyroid cartilage; ta: thyroarytenoid muscle; pc: posterior cricoarytenoid muscle; ic: inferior constrictor. D) ct: cricothyroid muscle; c: cricoid cartilage; e: esophagus.

2). I agree with Frazer that the posterior cricoarytenoid muscle is merely more easily recognized from its position and "certainly it is not present when the inner constrictor is well marked."⁵

The present author also fell into the same error as Lissner, when, in his last paper¹⁰ he stated that the first muscles to develop in a recognizable form (9 mm embryo) were the interarytenoid and posterior cricoarytenoid. It is easy

to assume that particular myoblasts are the primordia of specific muscles when one expects these muscles to appear in certain relationships in the laryngeal organ. What this investigator has learned and believes, after further study, is that the primordium of the laryngeal muscles appears first as an intrinsic sphincter, lying within the anlage of the thyroid cartilage and at the level of the cricoid. In this, the present researcher agrees with Frazer

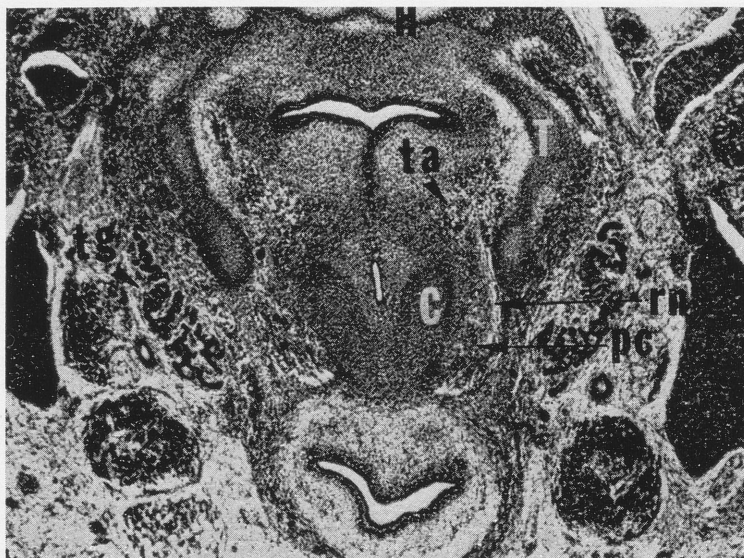

Fig. 5. Embryonic larynx of CR 21 mms (47 days). H: hyoid bone; T: thyroid cartilage; ta: thyroarytenoid muscle; C: cricoid cartilage; rn: recurrent nerve; pc: posterior cricoarytenoid muscle; tg: thyroid gland.

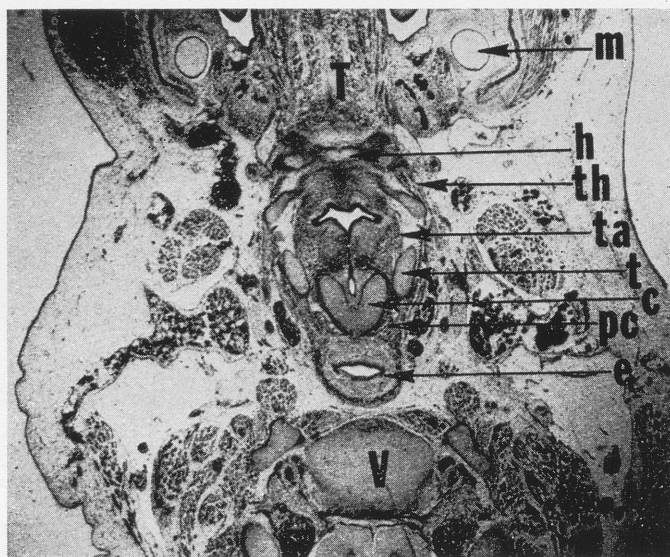


Fig. 6. Fetal larynx of CR 26 mms (51 days). T: tongue; m: Meckel's cartilage; h: hyoid bone; th: thyrohyoid muscle; ta: thyroarytenoid muscle; t: thyroid cartilage; c: cricoid cartilage; pc: posterior cricoarytenoid muscle; e: esophagus; V: cervical vertebrae.

and Strazza and disagrees with Lisser that "the very first indication of the laryngeal musculature shows several independent masses."⁶ From this author's studies, it appears that the laryngeal myoblasts are strung in the form of a

ring or sphincter in the 7 to 10 mm embryo (Fig. 1). As development continues, this sphincter of muscle fibers separates into individual masses of muscle, those that constrict the glottic slit and epiglottic sphincter (interary-

tenoid, aryepiglottic and lateral cricoarytenoid muscles) and that pair of muscles which opens the glottic sphincter, the posterior cricoarytenoid.

Until we reach the fourth stage of development (13 to 15 mms), judgments as to the recognition of individual muscles are more speculative than reliable. For it is during the fourth and the fifth stages (16 to 18 mms) when the development of the cartilages has advanced to a more easily recognizable form, that the muscles can be definitely differentiated.¹¹ In the 13 mm embryo, the most well developed muscles are the interarytenoid, cricothyroid and posterior cricoarytenoid (Fig. 2). The primordium of aryepiglottic musculature can also be distinguished at this stage. The cricothyroid, like the thyroarytenoid muscle is still difficult to differentiate reliably until the 15 mm embryo (Fig. 3), although the cricothyroid probably separates from the pharyngeal constrictor as a separate mass in the third stage.

The lateral cricoarytenoid is more reliably differentiated from the thyroarytenoid in the 18 mm embryo (Fig. 4), a finding that is similar to Lissner's. This observation follows the reasoning presented above, that this adductor, functionally one of the principle muscles of the primitive sphincter, is one of the early ones to develop as an independent muscle.

The above findings are similar to those of Lewis¹² who was able to distinguish most muscles in the 14 mm embryo but does not agree with Strazza who could not distinguish any muscle until the 16 mm embryo. It is also interesting to note that Soulié and Bardier⁴ first recognized the appearance of the laryngeal muscles in the 19 mm embryo. This is not surprising since their reported collection contained no specimens between 8 and 19 mms.

It is during the sixth stage (19 to 23 mms) that laryngeal muscles pass through their last stages of embryonic development and differentiation (Fig. 5). All intrinsic muscles are now clearly recognizable, with the interarytenoid, posterior cricoarytenoid and cricothyroid muscles still dominant. For the larynx, in general, this stage marks the end of the embryonic period. The next stage (24 to 30 mms) marks the first fetal stage of laryngeal growth (Fig. 6). It is during this period that the larynx takes on much of the adult form.

CONCLUSIONS

The principle conclusions to be drawn from this study on the developmental anatomy of the human laryngeal muscles are:

1. Intrinsic laryngeal muscles develop from one of two common sphincters of muscle cells and not as separate masses of muscles.
2. The cricothyroid muscle is derived from the inferior pharyngeal constrictor, a muscle of the fourth arch, and all other muscles are derived from the primordium of the internal constrictor of the sixth arch.
3. The first laryngeal muscles to be identified in the early embryonic stages are the interarytenoid, aryepiglottic, posterior cricoarytenoid and cricothyroid. These muscles continue as the most well developed ones throughout the embryonic period. The least developed muscle appears to be the thyroarytenoid.
4. The anlage of individual intrinsic muscles was first recognized in the 13 mm embryo, with the development of all muscles completed by the 23 or 24 mm embryo.
5. This study confirms, in general, the findings and theories of Strazza and Frazer on the developmental anatomy of the laryngeal muscles.

303 EAST CHICAGO AVE., CHICAGO, ILL. 60611

ACKNOWLEDGMENT—The author is indebted to Dr. Thomas H. Shepard, Head, Central Laboratory for Human Embryology, University of Washington School of Medicine, Seattle, for providing the specimens that compose the author's embryonic and fetal collection.

REFERENCES

1. His W: Anatomie menschlicher Embryonen. Heft 3, Leipzig, 1885
2. Strazza G: Zur Lehre über die Entwicklung der Kehlkopfmuskeln. Med Jahrb, Wien ser 3, 2: 105-116, 1888
3. Kallius E: Beiträge zur Entwicklungsgeschichte des Kehlkopfes. Anat Hefte 9: 302-363, 1897
4. Soulié A, Bardier E: Recherches sur le développement du larynx chez l'homme. J Anat Physiol 43: 137-240, Paris, 1907
5. Frazer JE: The development of the larynx. J Anat Physiol 44: 156-191, 1910
6. Lisser H: Studies on the development of the human larynx. Amer J Anat 12: 27-66, 1911
7. Blumberg JB, Stevenson JK, Lemire RJ et al: Laryngotracheoesophageal cleft, the embryonic implications: review of the literature. Surgery 57: 559-566, 1965
8. Arey LB: Developmental Anatomy. Philadelphia, WB Saunders Co, 1965
9. Iffy L, Shepard TH, Jakobovits A, et al: The rate of growth in young human embryos of Streeter's Horizons XIII to XXIII. Acta Anat 66: 178-186, 1967
10. Hast MH: The developmental anatomy of the larynx. Otolaryng Clin Amer 3: 413-438, 1970
11. Bardeen CR: The development of the skeleton and of the connective tissues. In: Keigel F and Mall FP (eds) Manual of Human Embryology, vol 1. Philadelphia, JB Lippincott Co, 1910, pp 422-424
12. Lewis WH: The development of the muscular system. In: Keibel F and Mall FP (eds) Manual of Human Embryology, vol 1. Philadelphia, JB Lippincott Company, 1910, p 518

OBSERVATIONS ON THE EMBRYOLOGY OF THE HUMAN LARYNX

JOHN A. TUCKER, M.D.

PHILADELPHIA, PENNSYLVANIA

RONAN O'RAHILLY, M.D.

BALTIMORE, MARYLAND

Although the larynx was the first portion of the respiratory tree to be studied developmentally in the human, it has not previously been described in a closely graded series of specifically staged human embryos.

The human larynx has been investigated in varying detail during this century by at least a dozen authors.¹ Among these, perhaps the best known works are those of Soulié and Bardier,² and Frazer.³ The most recent account is that by Wind.⁴

Contrary to common usage, it does not in point of fact suffice to arrange individual embryos in a series that supposedly indicates their order of development. With regard to age, it is exceedingly rare that the precise age of an embryo is known and, moreover, arrangement by age would not necessarily coincide with morphological development; some individuals progress more rapidly than others, prenatally as well as postnatally. Similarly, in the case of size, embryonic length is merely one index, is highly variable, and is all too readily influenced by artifactual conditions, such as fixation and shrinkage. Once again, arrangement by size would not necessarily coincide with morphological development; taller individuals

are not always more developed than shorter ones.

The best system so far devised is that of arranging embryos in groups, not in an arbitrary manner but based on their morphological development. In the Carnegie system of embryonic staging, morphological criteria such as the appearance of the eyes and the limb buds are employed in a scheme of 23 stages, formerly termed "developmental horizons" by Streeter. Because the system is not based directly on such variable factors as length and presumed age, it allows much greater precision in the establishment of the sequence and timing of developmental events. This has been shown, for example, in the case of the nervous system.⁵

The 23 stages cover the embryonic period proper, that is, the first eight weeks of human development. At the end of that time, the embryo is approximately 30 mm in crown-rump length (sitting height) and ready to enter the fetal period. It should be stressed that such expressions as "the 16 mm stage" have no place in present day embryology, where the term "stage" should be reserved for those levels of development that pertain to a recognized staging system.

From the Departments of Otolaryngology, Bronchology, Esophagology and Laryngeal Surgery, Graduate Hospital of the University of Pennsylvania, Philadelphia, Pennsylvania; the Department of Embryology, Carnegie Institute of Washington, Baltimore, Maryland, and the Department of Anatomy, Wayne State University, Detroit, Michigan.

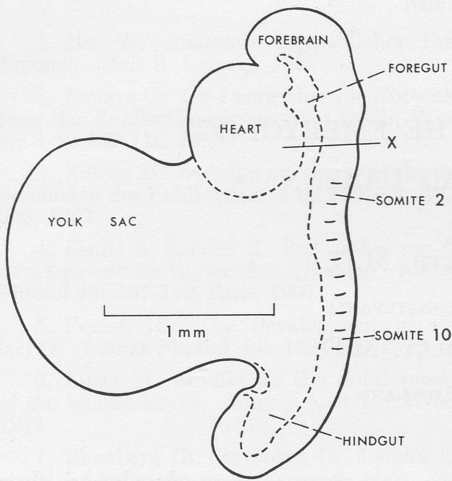


Fig. 1. Left lateral view of a human embryo of 3 weeks (Stage 10), 3.3 mm in greatest length and possessing 10 pairs of somites. The gut is indicated by an interrupted line. The line marked X shows the plane of section of the photomicrograph on Fig. 6.

The observations presented here, which are limited to the embryonic period proper, are based on serial sections of 40 staged, human embryos in the Carnegie collection. Their lengths ranged from 1.25 to 31 mm; they were sectioned in various planes and stained according to various procedures. Particular attention will be devoted here to the early stages (between 3 and 4 weeks); the later stages (5 to 8 weeks), which will be summarized, are still under active investigation.

Stages 1 to 8. During the first week of development, the human organism changes from a single, free cell to an implanting, hollow sphere known as a blastocyst. During the second week, the embryonic disc acquires bilateral symmetry and presents rostral and caudal ends as well as dorsal and ventral surfaces.⁶ During the third week, the embryonic disc becomes more curved (convex dorsally), particularly at its rostral and caudal ends, and a neural groove begins to appear in the median plane.⁵

Prior to Stage 8 (about 18 days), no sign of the foregut is visible and hence

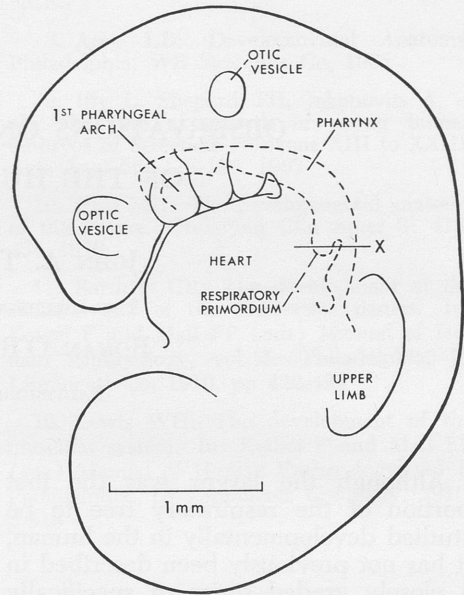


Fig. 2. Left lateral view of a human embryo of 4 weeks (Stage 13), 4 mm in greatest length and possessing 30 pairs of somites. The foregut is indicated by an interrupted line. Compare with Fig. 8. The line marked X shows the plane of section of the photomicrograph on Fig. 9.

no indication of the respiratory system is seen. In the chick embryo, however, radio-autographic mapping has enabled the presumptive pulmogenic regions to be plotted at very early stages which would probably correspond to about two weeks in the case of the human embryo.⁷

Stage 9. At this stage the embryo is approximately 20 days in age, 1.5 to 2.5 mm in length, and has 1 to 3 somite pairs. The foregut is visible as a recess of the yolk sac. A median pharyngeal groove (Fig. 5) presages the first indication of the respiratory system and includes the future larynx.

Stage 10 (Fig. 1). The embryo is approximately 25 days in age, is 2 to 3.5 mm in greatest length, and has 4 to 12 somite pairs. The respiratory groove begins to become circumscribed (Fig. 6) and its caudal end is the site of the respiratory primordium.

Stage 11. The embryo is approxi-

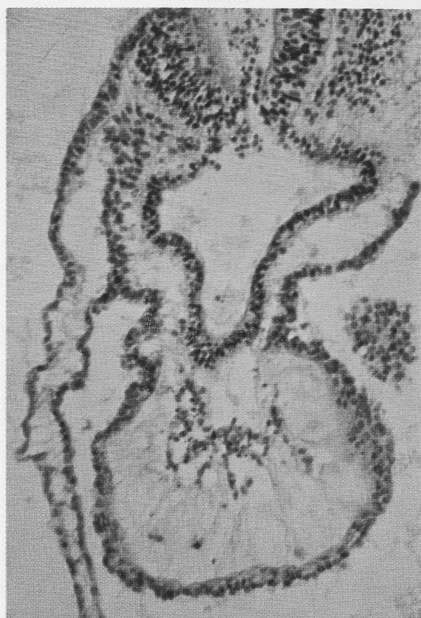


Fig. 6. Section through the neural tube, dorsal aortae, and pharynx at Stage 10 (3.3 mm). The thick epithelium of the ventral wall of the foregut is noticeable, and the respiratory groove can be seen just dorsal to the dorsal mesocardium and heart. The plane of section is marked X in Fig. 1. →

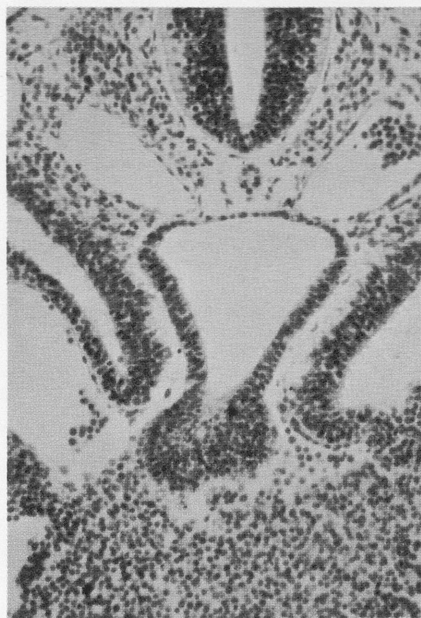


Fig. 5. Section through the pharynx (above) and heart (below) of a human embryo of Stage 9 (3 weeks), 1.38 mm in length. The median pharyngeal groove can be seen immediately dorsal to the heart. In the latter, the so-called epimyocardial mantle, the cardiac mesenchyme ("jelly"), and the endocardium can be identified.

←

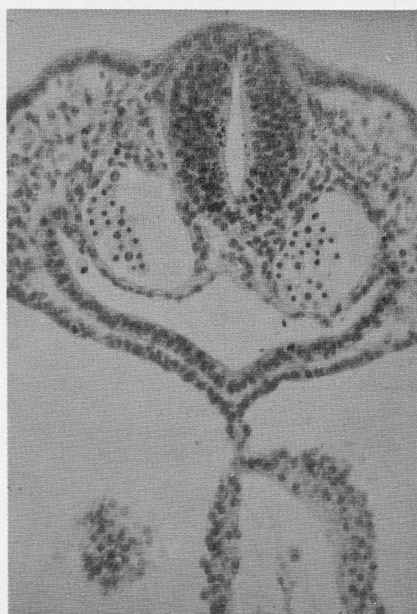

Fig. 7. Section through the pharynx at stage 11 (3.1 mm). The apex of the pharyngeal wall (pointing ventrally) shows the division of the respiratory primordium into right and left lobes. The notochord can be seen lying between the pharynx and the neural tube.

←

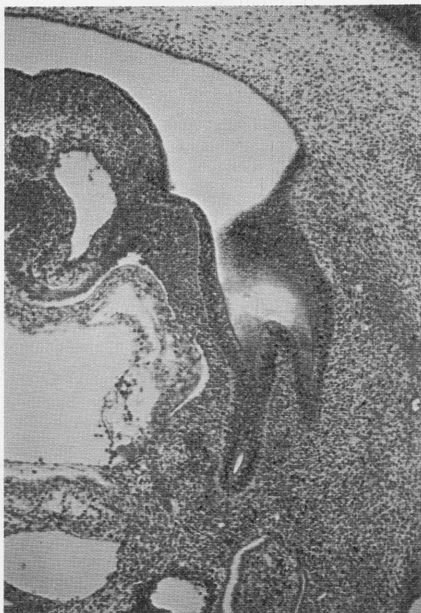


Fig. 9. The separation of the respiratory (below) and digestive (above) canals at Stage 13 (5.3 mm). In this cross section at higher magnification, the endodermal cells that divide the originally single foregut tube can be seen. No indication of external pressure is found in this formation of the tracheoesophageal septum. The plane of section is marked X in Fig. 2. →

Fig. 8. Median section through the pharyngeal region at Stage 13 (4.5 mm). The respiratory diverticulum can be seen descending from its origin in the foregut. Its close relationship to the heart is evident. The site of the tracheoesophageal septum is clearly visible.
←

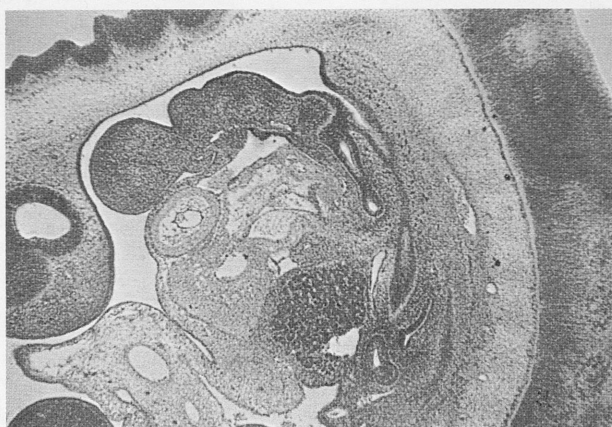
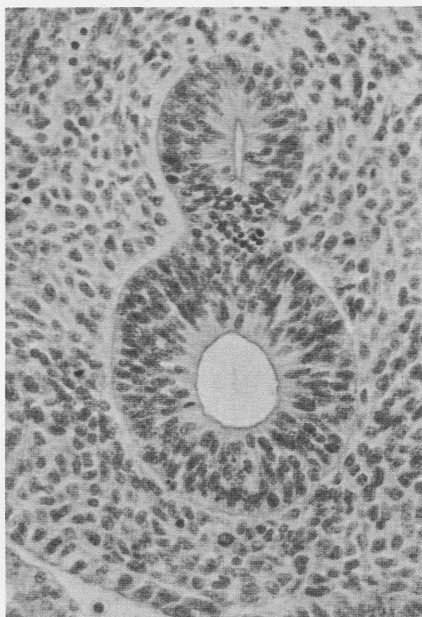


Fig. 10. Sagittal section near the median plane at Stage 14 (5.85 mm). Portions of the neural tube are visible in the periphery in this low power view, and the heart and liver can be seen near the center. The respiratory tube, now appreciably longer, is evident ventral to the digestive canal, and the site of the inlet of the embryonic larynx is ascertainable.

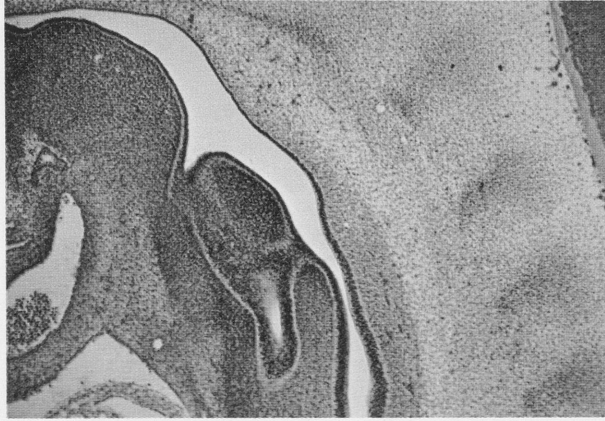


Fig. 11. Sagittal section at Stage 16 (8.1 mm) to show the epithelial lamina of the larynx. Further details can be made out in Fig. 12.

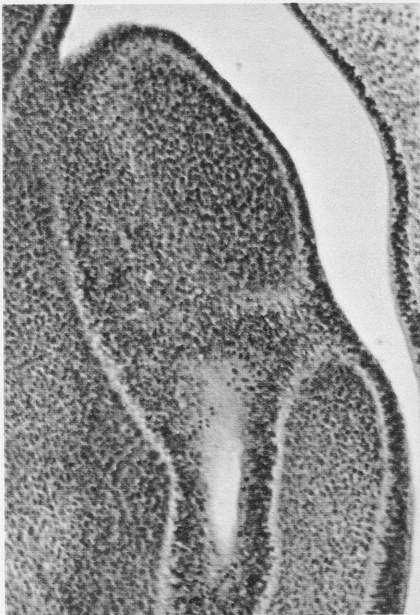


Fig. 12. High power view of the epithelial lamina of the larynx shown in Fig. 11. The closed vestibulotracheal canal can be identified on the left-hand side of the lamina, and the closed pharyngotracheal canal can be discerned below the lamina on the right-hand side of the photograph.

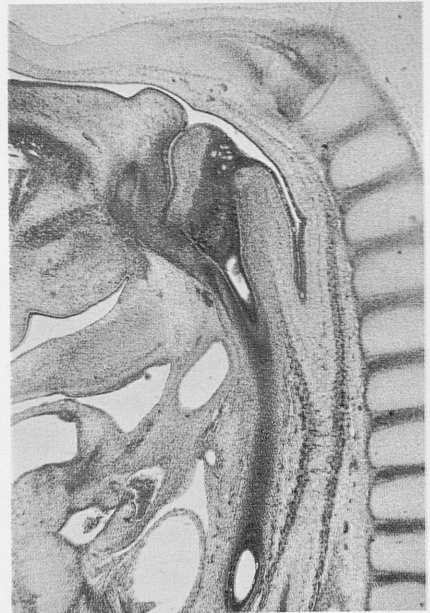

Fig. 13. Sagittal section, approximately in the median plane, at Stage 19 (18 mm). The vertebral centra can be seen on the right, and the base of the skull (containing a part of the notochord) at the top of the photograph. Compare with Fig. 3. Below the epiglottis, the cartilaginous hyoid condensation is visible.

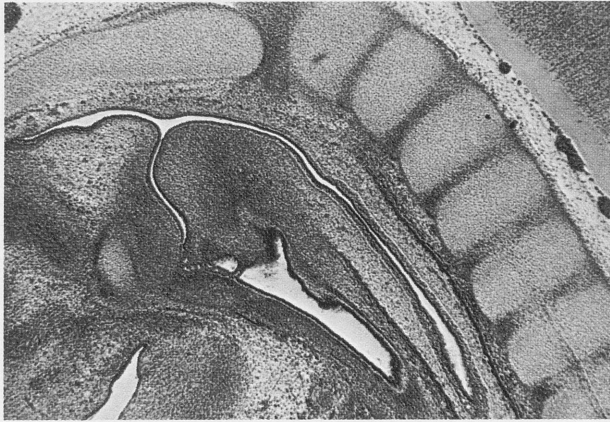

Fig. 14. Sagittal section, near the median plane, at Stage 20 (18 mm). The base of the skull and the vertebral centra are evident. A portion of the notochord is visible in the lower right-hand corner, and a part of the neural tube in the upper right-hand corner. The cartilaginous hyoid is evident below the epiglottis.

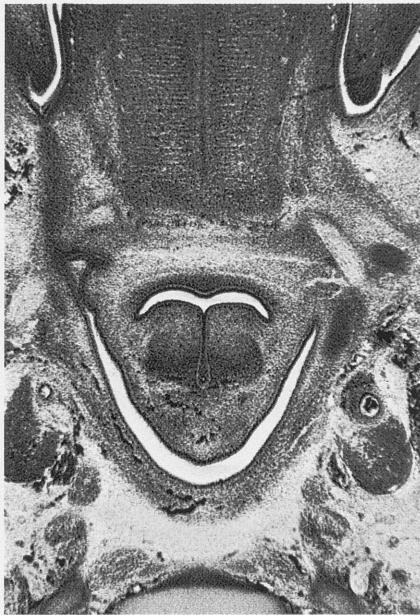


Fig. 15. Transverse section through the pharynx and larynx at Stage 20 (21 mm). The tongue is shown uppermost. The T-shaped cavity of the larynx is evident, and the arytenoid condensations can be determined. The blood vessels have been injected with India ink.

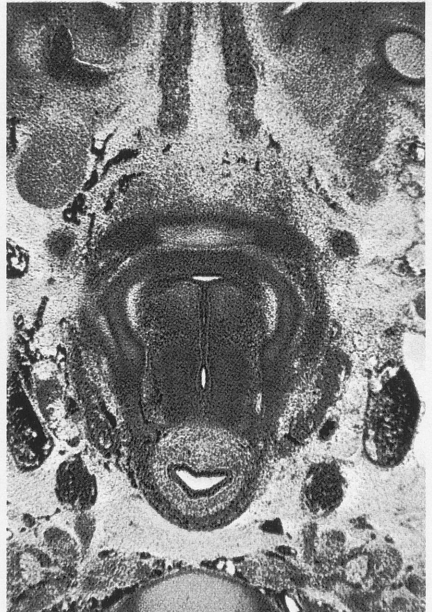


Fig. 16. Transverse section at Stage 20, taken a little further caudally than that shown in Fig. 15. The hyoid and thyroid cartilages can be identified, and also the right and left lobes of the thyroid gland. The blood vessels have been injected with India ink.

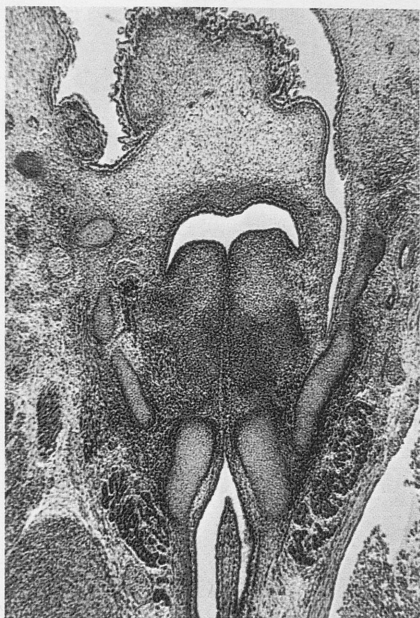


Fig. 17. Coronal section through the larynx at Stage 21 (22.5 mm). The tongue is shown uppermost. The cartilaginous nodules on the left-hand side are (from above downwards) the hyoid, thyroid (twice), and cricoid. Above the cricoid cartilage bilaterally, muscular condensations (e.g., thyroarytenoid) are present. Lateral to the cricoid cartilage bilaterally, the right and left lobes of the thyroid gland appear as dark areas. Inferolateral to the hyoid cartilage, the hypoglossal nerve is discernible.

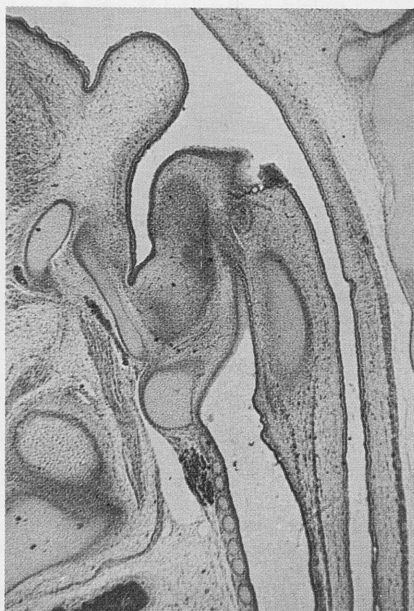

Fig. 18. Sagittal section through the larynx at Stage 23 (8 weeks), 30 mm. The epiglottis can be seen above. The following cartilaginous elements are visible: hyoid, thyroid lamina, cricoid arch and lamina, and trachea (several rings). In addition, the manubrium sterni and the medial end of a clavicle are evident. The isthmus of the thyroid gland and the thymus appear as dark areas. Compare with Fig. 4.

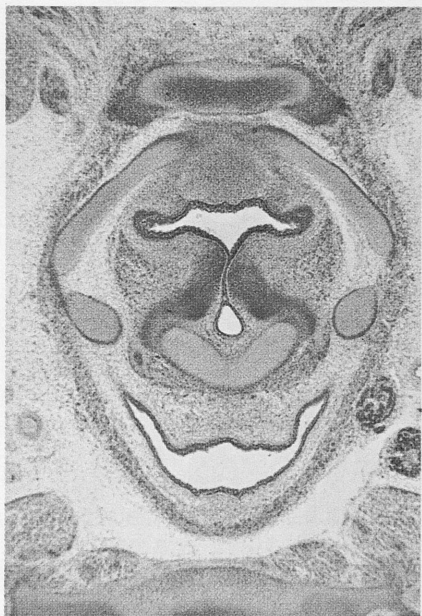

Fig. 19. Transverse section through the pharynx and larynx at Stage 23 (30.7 mm). The hyoid body is shown uppermost, and the laminae and greater horns of the thyroid cartilage can be seen on each side. The T-shaped cavity of the larynx is evident, bounded dorsally (below in the photograph) by the lamina of the cricoid. The thyroarytenoid and posterior cricothyroid muscles can be detected.

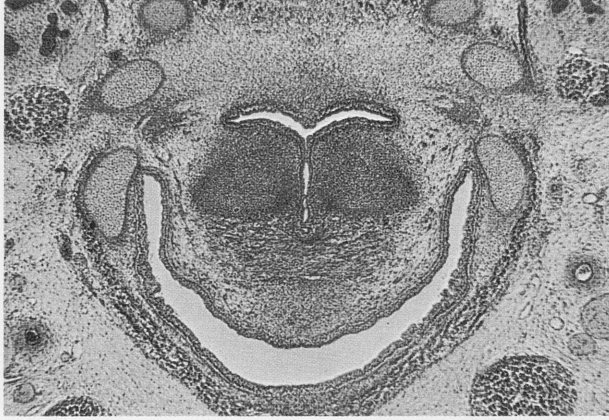

Fig. 20. Transverse section through the pharynx and larynx of another embryo of Stage 23 (31 mm). The three cartilaginous nodules on each side belong to the styloid, hyoid, and thyroid elements, respectively. The vestibule of the larynx, the rostral limit of the arytenoid cartilages, and the transverse arytenoid muscles are clearly shown.

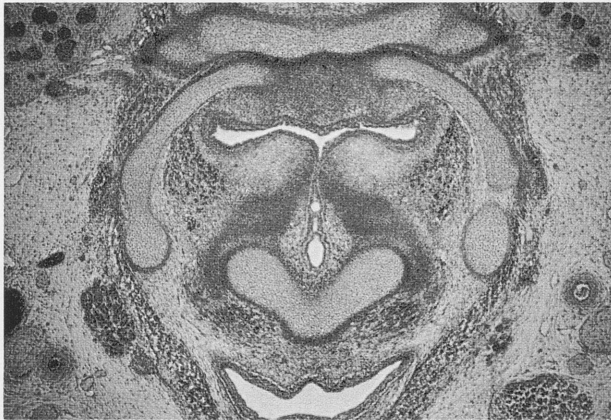

Fig. 21. Transverse section through the larynx shown in Fig. 20, taken a little further caudally. The hyoid, thyroid, and cricoid cartilages are evident. The section is just caudal to the arytenoid cartilages and is close to the cricoarytenoid joints. The thyroarytenoid and posterior cricoarytenoid muscles can be detected.

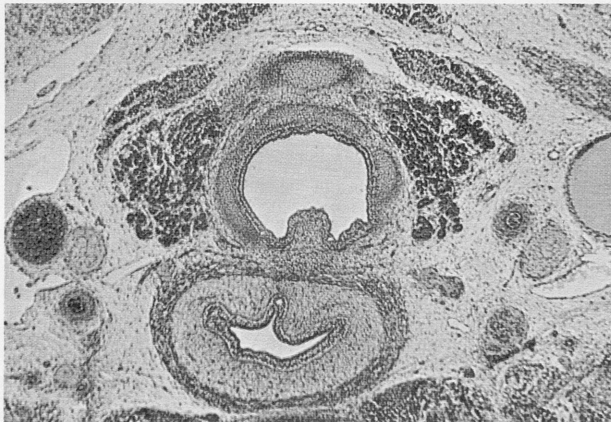


Fig. 22. Transverse section to demonstrate the rostral limit of the trachea and esophagus at Stage 23. The caudal limit of the arch of the cricoid is shown uppermost, and the cartilaginous rings of the trachea are visible. A dorsal folding of the wall of the trachea projects into the lumen. The right and left lobes of the thyroid gland are evident, and several of the nearby muscles can be seen. The mucous, submucous, and muscular coats of the esophagus are readily discernible.

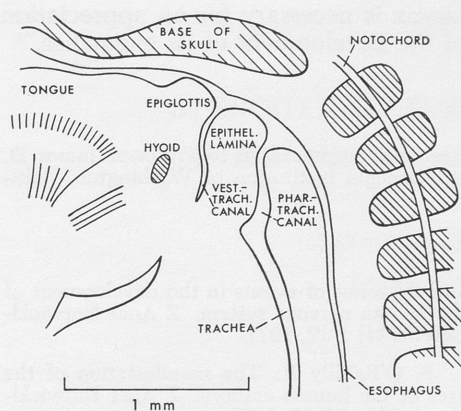


Fig. 3. Median section through the neck of a human embryo of 7 weeks (Stage 19), 18 mm crown-rump length. Compare with Fig. 13.

mately 24 days in age, 2.5 to 4.5 mm in length, and has 13 to 20 somite pairs. The respiratory primordium divides into right and left lobes (Fig. 7).

Stage 12. The embryo is approximately 26 days in age, 3 to 5 mm in length, and has 21 to 29 somite pairs. The tracheoesophageal septum makes its first appearance at this stage.

Stage 13 (Fig. 2). The embryo is approximately 28 days in age, 4 to 6 mm in length, and has 30 or more somite pairs. Tracheoesophageal separation is well under way (Figs. 8 and 9), and the right and left bronchial buds are clearly defined. The coelomic epithelium is still actively giving cells to envelop the esophagus and the respiratory primordium in a common visceral coat of mesenchyme. This forms the basis of the vascular, muscular, and supporting tissues of these organs.

Stage 14. The embryo is approximately 32 days in age and 5 to 7 mm in length. The hypopharyngeal eminence is seen as a median elevation of the floor of the pharynx between the third pharyngeal arches. Medial to the fourth pharyngeal arches, the right and left arytenoid swellings appear as bilateral mounds. Between these is the as yet small epithelial lamina of the larynx. The inlet of the embryonic larynx is

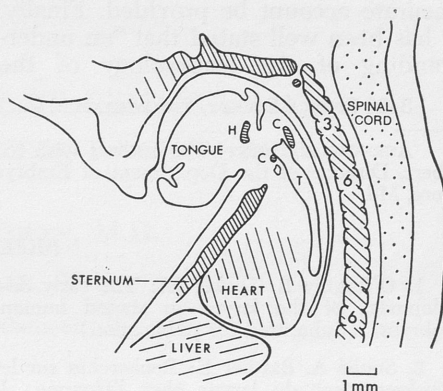


Fig. 4. Median section through the neck and thorax of a human embryo of 8 weeks (Stage 23), 30 mm crown-rump length, at the end of the embryonic period proper. Compare with Fig. 18. C: cricoid cartilage; H: hyoid; T: trachea.

now identifiable (Fig. 10). The coelomic epithelium at this stage ceases to contribute to the esophagus and the respiratory tubes. Angiogenesis is beginning in the mesenchyme and serves to mark off the esophageal from the bronchial investment.

Stages 15 to 23 (Figs. 3 and 4). The stages from 5 to 8 weeks, during which the crown-rump length increases from about 8 to approximately 30 mm, are at present under active investigation and are merely summarized here in the form of a series of photomicrographs. (Figs. 11 to 17). By the end of the embryonic period proper (Figs. 18 to 22), the larynx is a well developed organ in which the various cartilages have distinctive shapes and in which the major muscles are clearly delineated. It should be noted, however, that the epiglottis still contains no sign of cartilaginous tissue at this time.

In conclusion, it may be pointed out that the respiratory system begins early in development and that its location can be detected as early as Stage 9 (20 days). The necessity of employing a recognized staging system in order to study the precise sequence of developmental events has been stressed. Only by such a procedure can a detailed and

accurate account be provided. Finally, it has been well stated that "an understanding of the embryology of the larynx is necessary for an appreciation of the development of its anomalies."⁸

3400 SPRUCE STREET, PHILADELPHIA, PA. 19104

ACKNOWLEDGMENT—The authors wish to express their appreciation to Professor James D. Ebert, Director of the Department of Embryology, Carnegie Institution of Washington, Baltimore, Md.

REFERENCES

1. O'Rahilly R, Tucker JA: The early development of the larynx in staged human embryos. (Submitted for publication)
2. Soulié A, Bardier E: Recherches sur le développement du larynx chez l'Homme. *J Anat Physiol (Paris)* 43: 137-240, 1907
3. Frazer JE: The development of the larynx. *J Anat Physiol* 44: 156-191, 1910
4. Wind J: On the Phylogeny and the Ontogeny of the Human Larynx. Groningen, Wolters-Noordhoff, 1970
5. O'Rahilly R, Gardner E: The timing and sequence of events in the development of the human nervous system. *Z Anat Entwickl-Gesch* 134: 1-12, 1971
6. O'Rahilly R: The manifestation of the axes of the human embryo. *Z Anat Entwickl-Gesch* 132: 50-57, 1970
7. Rosenquist GC: The origin and movement of prelung cells in the chick embryo as determined by radioautographic mapping. *J Embryol Exp Morph* 24: 497-509, 1970
8. Holinger PH, Johnston KC, Schiller F: Congenital anomalies of the larynx. *Ann Otol* 63: 581-606, 1954

STEROID TREATMENT OF HEMANGIOMA OF THE HEAD AND NECK IN CHILDREN

SEYMOUR R. COHEN, M.D.

CHUN-I WANG, M.D.

LOS ANGELES, CALIFORNIA

Hemangioma is the most common benign tumor of infancy. The natural history of infantile hemangiomata is one of rapid growth beginning at two to three months of age and continuing until approximately one to two years of age. Regression of the lesion takes place over a period of several years. Active treatment is therefore unnecessary unless there is major interference with the normal function of vital organs. Treatment must be instituted when there is: A) mechanical obstruction of the airway; B) hemorrhage with or without thrombocytopenia; C) infection and loss of tissue; and D) threatened cardiovascular decompensation.

Conventional methods of treatment aimed at initiating early regression of the tumor include cryotherapy, injection of sclerosing agents, x-ray irradiation, ligation of feeding blood vessels or surgical resection.¹ All of these methods have disadvantages in the treatment of hemangiomata of the head and neck. Ulcerations, hemorrhage and scarring are most undesirable. Permanent airway obstruction can result from injudicious application of these methods. Thyroid carcinoma later in life is a well known hazard from irradiation. Any hemorrhage or injury to the tumor may precipitate sequestration of thrombocytes and thereby cause a life threatening thrombocytopenia.

The favorable experience of Katz and Askin² that steroid therapy dramatically reduced the size of multiple hemangiomata during treatment for thrombocytopenia prompted this study. In the presence of airway obstruction steroid treatment might preclude the necessity for a tracheostomy or shorten the duration of cannulation. This report concerns ten patients observed between 1968 and 1972.

Selection of Patients for Steroid Treatment. Infants referred to the Childrens Hospital of Los Angeles for acute respiratory distress secondary to hemangioma of the head and neck were carefully evaluated clinically. Routine laboratory tests including a platelet count and/or bleeding and coagulation studies were done when indicated. Bacterial infections were treated with antibiotics. Tracheostomy was performed when necessary. Treatment with steroid in these patients was based upon: 1) severe airway obstruction; 2) excessive rapid growth of the hemangioma; 3) hemorrhage and ulceration with or without thrombocytopenia; and 4) severe deformity as a result of the growth of hemangioma. Each of the ten patients selected is presented in detail in order to demonstrate the intricate problems involved.

Six of the ten patients thus selected had respiratory distress from airway ob-

From the Division of Otolaryngology and the Division of General Pediatrics of the Childrens Hospital of Los Angeles, University of Southern California, School of Medicine, Los Angeles, Calif.

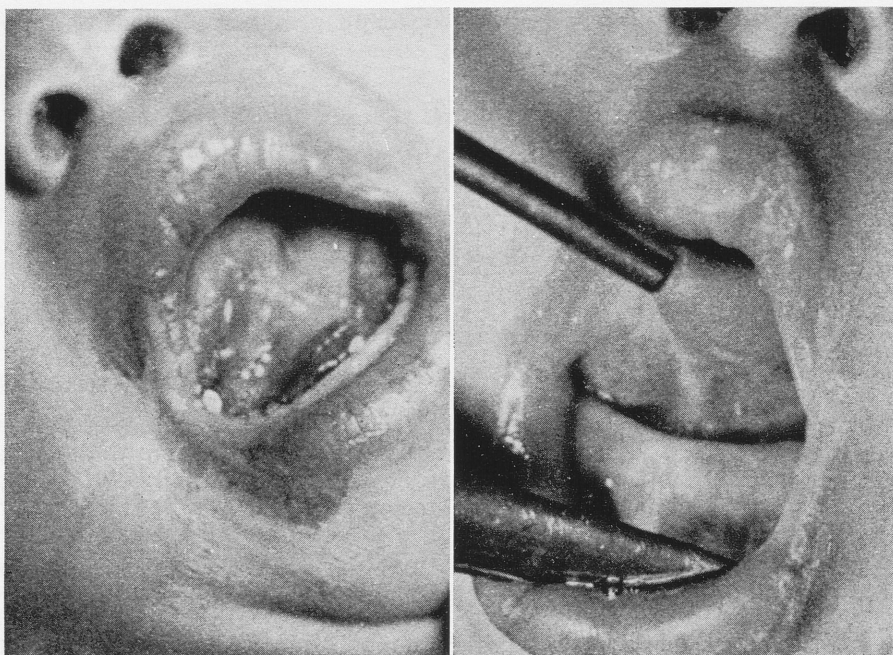

Fig. 1. A and B) Cystic mass elevating floor of mouth and tongue before and after steroid therapy (Case 1).

struction. Four had subglottic hemangioma (Cases 1, 2, 3 and 5) and two had extensive cavernous hemangiohygroma of the tongue and the floor of mouth rendering difficulty in breathing (Cases 1 and 6). One patient with subglottic hemangioma presented with the symptoms of hemoptysis and difficulty in swallowing (Case 4). The remaining four patients had hemangioma of the parotid gland, of the external auditory canal, and of the face and chin (Cases 7 to 10).

Prednisone was given orally at a dose of 60 mg/M² per day initially and later lowered to two-thirds or one-half of the dose daily or every other day. The duration of therapy was individualized according to the clinical symptoms, response to the steroid administration and the presence of complications such as ulceration, bleeding, infection, etc. None of the patients except one, (Case 2) became Cushingoid. This patient also received the longest course of steroid therapy.

REPORT OF CASES

Case 1. This patient was a male infant four months of age, who was admitted to the Childrens Hospital of Los Angeles in January, 1971. At two months of age he was noted to have a firm mass below the angle of the left jaw, which rapidly increased in size. One week prior to admission his tongue became severely swollen and he developed progressive dysphagia and noisy respiration. The mother's pregnancy and labor were essentially unremarkable.

Physical examination revealed a mass in the left side of the floor of the mouth, elevating the tongue to the level of the hard palate. A large firm mass was noted in the left submandibular area (Fig. 1A). The left side of the tongue was severely enlarged and blanched with pressure. The surface of the tongue was ulcerated and bled easily. A lateral film of the neck revealed a soft tissue mass in the submandibular area. The mandible and skeletal survey were normal. Because of the rapidly enlarging mass with increasingly severe respiratory difficulty, a tracheostomy was performed at which time a large cystic hygroma was found encircling the trachea extending from the submandibular mass. Prednisone was started two days later which resulted in rapid diminution in the size of the tumor (Fig. 1B). However, because of the severe vascularity of the tongue mass which resulted in bleeding

when the infant was fed, a feeding gastrostomy was performed.

A daily dose of 16 mgs of prednisone was given for ten days. Within a few days there was remarkable reduction in size and vascularity of the hemangiohygromatous mass, allowing a resumption of oral feedings. The gastrostomy tube was removed and the site closed spontaneously. The dose of prednisone was reduced to 10 mgs daily for another week, and further reduced to 10 mgs every other day for the next eight weeks.

Direct laryngoscopy one month after admission revealed the hypopharynx to still be narrowed by a large cystic mass arising from the base of the tongue and from the valleculae and pharyngoepiglottic folds. The cystic mass was incised with multiple punctures and clear fluid was evacuated. The larynx otherwise was essentially normal. At six months of age, approximately three months after admission to the hospital, the tracheotomy tube was removed and the neck healed spontaneously. When seen at 16 months of age, the infant had no respiratory or feeding difficulties, and the submandibular mass was barely palpable.

Case 2. This patient was a male infant three and one-half months of age who was admitted to the Childrens Hospital of Los Angeles in June, 1969. A large cavernous hemangioma was present over the left side of the face and scalp. His chief complaint was severe respiratory difficulty with stridor, fever, and evidence of severe laryngeal obstruction.

Physical examination on admission revealed an acutely ill infant with a temperature of 41°, pulse rate 140, and respirations of 40 to 60 per minute. Because of bilateral acute otitis media he was treated with methicillin intravenously. Respiratory obstruction was so severe repeated doses of Decadron® were given. His airway obstruction improved rapidly. The platelet count, coagulation studies, and the cerebrospinal fluid were normal. Chest x-rays revealed hyperaeration without pulmonary infiltrates.

Direct laryngoscopy on the fifth day of admission revealed a subglottic hemangioma causing laryngeal obstruction. The patient was given 20 mgs of prednisone daily, and within two weeks there was progressive reduction of the size of the facial and laryngeal hemangioma. Prednisone was continued for a total of six weeks, but four days after discontinuing the drug the stridor reappeared, and direct laryngoscopy revealed the subglottic area to be patent to only 1½ mms because of the obstructive hemangioma. Fifteen mgms of prednisone daily was resumed and within two months direct laryngoscopy revealed the hemangioma to have diminished remarkably in size.

Steroid therapy was continued over the next two months and the dose was reduced to

10 mgms every other day until the child was 11 months of age. Examination of the larynx at this time revealed the subglottic airway to have increased to half of its normal size. No respiratory difficulty was present except with stress, but the child appeared somewhat Cushingoid with reduced muscle tone. His blood pressure was normal and there were no other evidences of the Cushingoid syndrome. Over the next 14 months the infant returned to a normal appearance with increase in muscle strength, developed normally, and the hemangiomata of the face and scalp were flattened with large blanched areas. At age three, direct laryngoscopy revealed the larynx to be almost completely normal, with only residual vascular areas in the subglottic and on the cordal levels.

Case 3. This patient was a female infant three and three-fourths months of age who was admitted to the Childrens Hospital with a diagnosis of croup in February, 1968. At birth she was noted to have scattered speckles and irregular areas of hemangioma over the right side of the neck. Inspiratory and expiratory stridor, for which she had been hospitalized elsewhere had been present since the first day of life. At two months of age respiratory difficulty and severe enlargement of the hemangioma of the neck occurred.

Physical examination upon admission revealed an infant in moderately severe distress with inspiratory and expiratory stridor. A large hemangioma was present over the right occiput and right posterior portion of the neck. A chest x-ray was normal, but a lateral x-ray of the neck revealed a subglottic mass. Direct laryngoscopy revealed a subglottic hemangioma (Fig. 2A). Respiratory distress responded to multiple doses of Decadron but airway obstruction remained a serious problem. A tracheotomy was performed. Repeated laryngoscopies revealed the problem of the hemangioma to remain unchanged over the next four months.

At eight months of age, prednisone was given orally at doses of 20 mgs every other day. Immediate response was noted with reduction in the size of the cutaneous hemangioma. Prednisone was continued for a period of six weeks, and the hemangiomata became considerably smaller (Fig. 2B). With the discontinuation of the steroid, the hemangiomata increased in size and the prednisone was resumed for a period of eight weeks, using 20 mgs every other day. The hemangiomata again receded, and the treatment was discontinued. At nineteen months of age, the patient was decannulated. Only mild stridor occurred with stress as the only residual symptom until the patient was two years of age. When last seen at three and one-fourth years of age, no respiratory obstruction was noted and the cutaneous hemangioma had completely subsided except for residual capillary streakings.

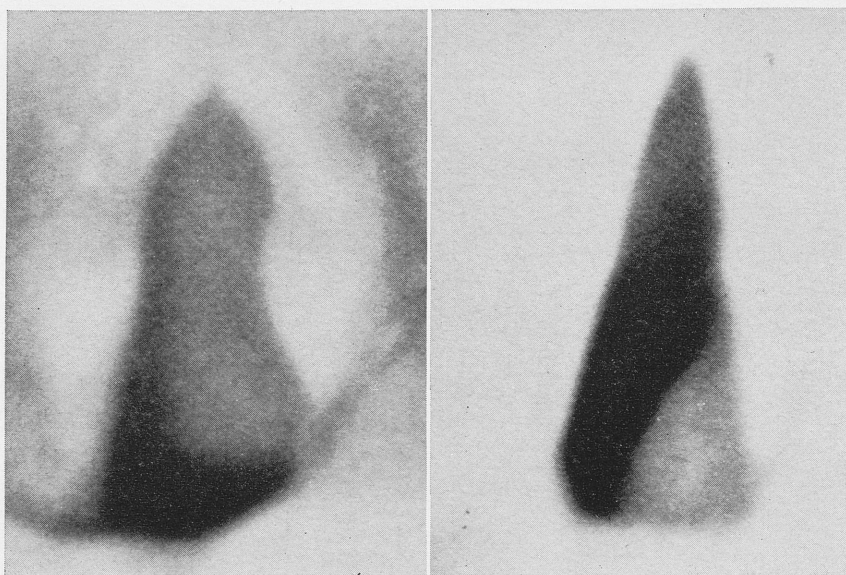


Fig. 2. A and B) Rapid reduction in size of laryngeal hemangioma before and after steroid therapy (Case 3).

Case 4. This patient was a female infant nine weeks of age, who was admitted to the Childrens Hospital in February, 1969, because of hemoptysis of 36 hours duration. At five weeks of age intermittent cough and hemoptysis had occurred. The mother's pregnancy and the birth history were essentially normal. Physical examination revealed a well developed, and well nourished infant in no distress, who had a nevus flammeus over the left eyelid and on the nape of the neck. Rales were present over both sides of the chest, and there was no evidence of hepatosplenomegaly. Laboratory tests, including coagulation studies, were all within normal limits. Her Hgb was 9.3 gms%, and the wbc was 13,800 per cubic mm. The differential count was normal. An x-ray of the chest revealed bilateral infiltrates and the child was given parenteral penicillin and kanamycin. The lungs cleared on this treatment.

Because of slow feeding and difficulty in swallowing, a lateral film of the neck was taken which revealed subglottic density posterior to the airway. Direct laryngoscopy revealed a subglottic hemangioma narrowing the airway; 15 mgs of prednisone was given daily for the next five weeks. Direct laryngoscopy at the completion of the treatment with steroids revealed the hemangioma to have completely resolved. When seen at five and one-half months of age, the child was asymptomatic.

Case 5. This patient was a female infant two months of age who was admitted to the Childrens Hospital in March, 1969, because of a rapidly enlarging hemangioma of the left

side of the face, auricle, upper lip, and hard and soft palate. Intermittent wheezing and rapid respirations were noted. The infant was born after an uneventful pregnancy and delivery. Hospitalization was necessary elsewhere at two and one-half weeks of age because of bloody diarrhea which spontaneously subsided. X-rays of the gastrointestinal tract were reported as normal. Eight weeks prior to admission, the hemangioma of the face had grown rapidly and the infant's respiratory obstruction increased. Physical examination revealed a well developed, well nourished infant with a pulse rate of 150 and respirations of 86 per minute. The facial hemangioma was noted with a soft mass over the parotid area. The general physical examination was otherwise unremarkable. Laboratory tests revealed the Hgb to be 9.4 gms% with a normal white count and differential. A trace of occult blood was found in the stool.

Direct laryngoscopy revealed a subglottic and posterior tracheal hemangioma. Lumen was not occluded; 15 mgs of prednisone was given daily and within a week the facial hemangioma had flattened. Direct laryngoscopy revealed diminished vascularity of the hemangioma of the larynx and trachea. The treatment was continued for ten weeks, and then discontinued. During the next three months, the facial hemangioma were noted to have increased in size. At eight months of age, the infant again developed noisy breathing and difficulty in swallowing; 15 mgs of prednisone were given daily for the next four weeks, which resulted in only slight improvement in the feeding problem. Direct laryn-

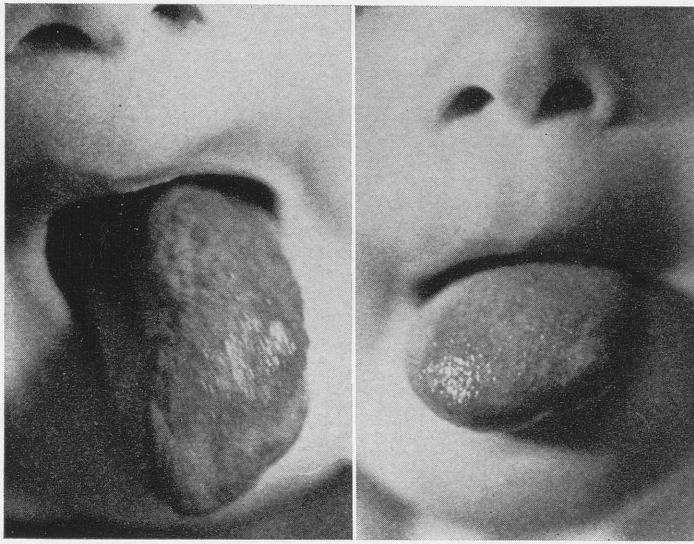


Fig. 3. A and B) Cavernous hemangioma of the tongue before and after steroid therapy (Case 6).

gосcopy was deferred because of a low hemoglobin of 7.7 gms%. The infant was given iron supplement and followed elsewhere.

At 18 months of age she was again seen with bleeding into the left cheek, parotid area, and dental arch. The platelet count was reduced to 28,000 to 39,000 per cubic mm; 20 mgms of prednisone was given daily for the next three months. One month after discontinuing the steroid therapy, rapid growth of the facial hemangioma was again evident. Ulceration of the temporal area from trauma occurred, and a loud bruit was heard over the hemangioma. A systolic murmur was present over the precordium. The presence of arteriovenous communications were demonstrated by arteriography. Growth and development of the child were within normal limit. No treatment was recommended for the arteriovenous communications and at two and one-half to three years of age the hemangioma had become smaller but the bruit and systolic murmur were still present.

Case 6. This patient was a female two and one-fourth years of age who was first seen because of a hemangioma involving the left half of her tongue, left anterior pillar, and floor of the mouth. The larynx was not involved. Involvement of the dental arch with malocclusion caused by the large oral mass was noted. Respiratory difficulty occurred with each upper respiratory infection, 20 mgms of prednisone was given daily and continued for eight weeks. During therapy the tongue became smaller, less vascular, and very flabby (Figs. 3A and B). When prednisone was discontinued, the tongue gradually increased in size. At two years and seven months of age, prednisone was again given in

doses of 20 mgms every day for another six weeks. This resulted in marked reduction in the size of the tongue.

At three and one-half years of age an adenoidectomy was performed, following which the tongue swelled remarkably and the airway became obstructed. Prednisone was given in doses of 20 mgms daily for the next four weeks, during which the tongue rapidly returned to its preoperative size. During the following year there was no change in the size of the tongue.

Case 7. This patient was a female infant eight months of age who was first seen in May, 1968. A mass was noted in the left external auditory canal at five months of age. This was diagnosed elsewhere as an infection and treated with oral and local antibiotics. A myringotomy resulted in severe bleeding and prolonged drainage. Mastoid x-rays showed reduced pneumatization but without bone destruction. The biopsy done elsewhere suggested cholesteatoma.

Examination at eight months of age revealed a red tumor mass which filled the external auditory canal. A small hemangioma was noted over the occipital area. Biopsy of the aural mass at Childrens Hospital of Los Angeles revealed an inflamed capillary hemangioma. Following the excisional biopsy the hemangioma of the ear grew rapidly. Fifteen mgms of prednisone were given daily and within two weeks of therapy there was marked regression of the mass. Steroid therapy was continued for three months, after which medication was tapered and then discontinued. The patient was last seen at three and three-fourths years

of age at which time residual hemangioma of the external canal and middle ear was noted.

Case 8. This patient was an infant four and one-half months of age who was first admitted to the Childrens Hospital in August, 1968. A mass was first noted at two months of age which became progressively enlarged and was diagnosed erroneously as mumps because of a history of exposure to this disease. One day prior to admission, bleeding was noted from the right ear. Physical examination was essentially normal except for a half dollar sized compressible mass over the right parotid area. X-rays of the jaw and skull were normal. Routine laboratory tests including a platelet count were normal.

A left parotid sialogram showed the primary and secondary ducts to be displaced by a centrally located mass. An angiogram revealed dilated and tortuous arteriovenous channels over the center of the gland representing a hemangiomatous lesion; 20 mgms of prednisone was given daily for a period of four weeks. The dose was then reduced to 15 mgms daily for the next two and one-half weeks, and then to 10 mgms daily for another one and one-half weeks. Periodic examination revealed the hemangioma to have completely disappeared by the end of seven weeks. A scalp venogram at the completion of therapy was reported as normal.

Case 9. This patient was a female infant five and one-half months of age who was admitted to the Childrens Hospital in March, 1971. She was the product of a normal pregnancy and labor. At birth a large facial hemangioma was noted. This rapidly increased over the first two months of life. Physical examination revealed a huge hemangiohygromatous mass over the right side of her face covering the neck and chin. Two areas of ulceration were noted over the surface of the tumor. There was a loud bruit behind the right ear. There was a systolic murmur. Remainder of the physical examination and laboratory findings were within normal limits.

An angiogram revealed large feeding vessels from the common and external carotid artery. In view of the rapidly enlarging mass and loud bruit, 20 mgms of prednisone was given daily for one week and then reduced to 20 mgms every other day for the next seven weeks. The mass became smaller, softer, and the ulcerations healed. When steroid therapy was discontinued for six weeks, the mass increased in size. At nine months of age, prednisone therapy was given to prepare the patient for surgical ligation of the large feeding vessels, but again the mass became smaller and softer, and surgery was cancelled. Steroid therapy was continued for six weeks at a dosage of 20 mgms every other day. The patient was followed elsewhere after that course of steroid therapy.

Case 10. This female child was first seen at Childrens Hospital in October, 1964 at

seven months of age. She was born with multiple hemangiomata and cystic hygromata over the lower half of her face, left chin, neck, and sublingual area. There was an extensive hemangioma over the lower lip and tongue. A tracheostomy had been done at another institution because of respiratory difficulty due to bleeding from sublingual hemangioma. Subsequently, surgery was attempted to ligate the feeding arteries, but the infant sustained a cardiac arrest. She was resuscitated and had a stormy postoperative course with sepsis and pneumonia. X-ray therapy was given without any noticeable effect. The infant was transferred to the Childrens Hospital of Los Angeles for further care.

During the next two years she had had repeated partial resections of the cystic hygroma and injections of a sclerotic substance into the tongue. The tracheostomy was removed at 21 months of age. Although the surgical procedures were helpful, the hemangioma and cystic hygroma remained quite large. Injection of sclerotic substance over the lower lip failed to reduce the size of the hemangioma.

At four years of age, the teeth over the mandible became loose and the lower gum bled easily. There was x-ray evidence of loss of bone in the mandible. A decision to try steroid therapy was made and 20 mgms of prednisone was given daily for seven weeks. No changes were noted. The treatments were discontinued for six weeks. Resumption of steroid therapy at the same dose for another six weeks failed to produce any noticeable changes in the appearance of the hemangioma or the size of the cystic hygroma. Surgery and plastic reconstruction was performed.

DISCUSSION

All methods of treatment have a certain degree of success or failure.³⁻⁵ Any treatment modality should be based on reduction of morbidity and mortality of the disease. Steroid therapy, while not entirely free of side effects, can relieve impending airway obstruction and avoid serious complications such as loss of tissue, scarring or thrombocytopenia. The case reports and follow-up would indicate that the earliest possible institution of steroid therapy could reduce the need for tracheostomy in lesions involving the airway, diminish the growth potential of other head and neck lesions, and initiate resolution of the tumor.

The mechanism of steroid therapy is obscure. Experience of the cases reported indicated a direct action on the resolution of the tumor. In many instances the withdrawal of steroid ther-

apy resulted in regrowth of the tumor. It is of interest that greater effect is noted in the younger infants. Eight of the ten patients were infants below nine months of age and five of the eight were between two and four and one-half months of age when steroid therapy was instituted. The ages of the two older children were two years, four months and four years respectively. The latter two children responded poorly or not at all. Capillary hemangiomata appeared to respond more promptly than the cavernous lesion. That cystic hygroma in early infancy may be treatable in infancy is indicated by the success noted in Case 1.

SUMMARY

Ten cases of vascular lesions of the head and neck treated with corticosteroids are presented. Early institution of steroid therapy can be effective in reducing the morbidity of hemangiomata

of the airway resulting in either early decannulation or eliminating the need for tracheotomy. Steroid therapy is not suggested as a substitute for tracheotomy where this procedure is indicated or necessary. Failures of steroid therapy occurred in the older patient and in the cavernous type of hemangioma.

The effectiveness of corticosteroids was noted in terms of cessation of rapid growth of the tumor, institution of regression of the tumor, more rapid healing of infected and ulcerated tissues, and improvement of airway obstruction. In the instances of bleeding, hemorrhage was controlled. No significant complications occurred. Drop in blood pressure, glycosuria, bony lesions, etc. were not noted in any of the cases reported. In all instances, preoperative steroids were given before anesthesia was instituted for any operative procedure.

UNIV. OF SOUTHERN CALIFORNIA SCHOOL OF MEDICINE, LOS ANGELES, CALIF. 90024

ACKNOWLEDGMENT—The authors express their appreciation for the follow-up data provided by Dr. James E. Ekegren of San Luis Obispo; the Medical staff of Childrens Hospital Medical Center of East Bay; and C.C.S. of California.

Request for reprints should be sent to Seymour R. Cohen, M.D., 6221 Wilshire Blvd., Los Angeles, Calif. 90048.

REFERENCES

1. Walsh TS Jr, Tompkins VN: Some observations on the strawberry nevus of infancy. *Cancer* 9: 869-904, 1956
2. Katz HP, Askin J: Multiple hemangiomata with thrombopenia. *Amer J Dis Child* 115: 351-357, 1968
3. Fost NC, Esterly NB: Successful treatment of juvenile hemangiomas with prednisone. *J Pediat* 72: 351-357, 1968
4. Zarem HA, Edgerton MT: Induced resolution of cavernous hemangiomas following prednisone therapy. *Plast Reconstr Surg* 39: 76-83, 1967
5. Cohen SR: Unusual lesions of the larynx, trachea and bronchial tree. *Ann Otol* 78: 476-490, 1969

DISCUSSION

EDLEY H. JONES, M.D.: I would like Dr. Cohen to repeat the dosage.

SEYMOUR R. COHEN, M.D. (closing): Sixty mgs per meter square per day. A 20 pound infant is equal to approximately a half-meter square. A 60 pound child is equivalent to a

meter square. The average adult is about 1½ to 1.75 meters square. This is equivalent to the therapy that the rheumatologist uses for the treatment of diseases such as lupus erythematosus and the various collagen diseases. It is a little less than those used by the renal people for the treatment of nephrosis.

PHARYNGEAL, LARYNGEAL AND TRACHEAL INJURIES IN THE PEDIATRIC AGE GROUP

PAUL H. HOLINGER, M.D.

JOYCE A. SCHILD, M.D.

CHICAGO, ILLINOIS

Trauma of the larynx and the immediately adjacent anatomical structures in infants and children varies with different age groups. Three groups are considered: infants from birth to one and one-half years, children from one and one-half to 12 years, and adolescents from 13 to 18 years of age.

ETIOLOGY

In an analysis of the problem of laryngeal injuries, consideration is given to both internal and external trauma. The etiology of internal trauma consists largely of the effects of aspirated foreign bodies, burns, and prolonged in-

tubation; screamer's nodes caused by vocal abuse is not included in this discussion.¹ External trauma is produced by the physical violence of childhood, sports and the rapidly increasing category of automobile accidents (Table I).

Trauma of the pharynx, larynx and trachea in infants below the age of 18 months is largely the result of internal injury; and except for aspirated foreign bodies it is primarily iatrogenic. This group consists of 42 infants, 16 males and 26 females. In 15 of the infants the laryngeal findings were associated with prolonged endotracheal intubation.²

TABLE I
ETIOLOGY

	No.	M	F	Prolonged intubation	Auto accidents	Foreign bodies	Other
Infants, 0 - 1½ yrs.	42	16	26	15	0	22	5
Children, 1½ to 12 yrs.	57	33	24	13	11	19	14
Adolescents, 13 to 18 yrs.	31	17	14	3	21	4	3
Totals	130	66	64	31	32	45	22
Young adults, 19 to 25 yrs.	29	16	13	1	26	1	1

From the Departments of Laryngology and Bronchoesophagology, The Children's Memorial Hospital, Rush Presbyterian-St. Luke's Hospital, and the Abraham Lincoln School of Medicine of the University of Illinois, Chicago.

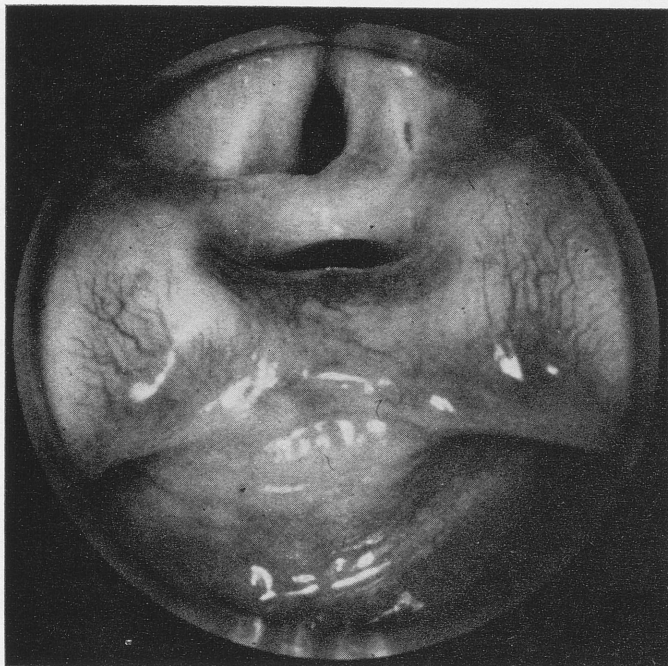


Fig. 1. Postintubation synechia between the arytenoids of a four-month-old infant.

This followed extensive surgical procedures for congenital cardiovascular, esophageal or other anomalies, for the respiratory distress syndrome, neonatal tetanus, or tracheobronchitis (Fig. 1). The trauma in two newborns was the result of vigorous attempts at pharyngeal aspiration that caused laryngeal edema, hypopharyngeal perforations and mediastinitis (Fig. 2). A one-year-old infant aspirated lighter fluid and required an emergency tracheotomy. In a 17-month-old infant, the trauma was due to the attempted removal of a bronchial foreign body using a bronchoscope too large for his age, while in another, the injury was a part of the battered child syndrome. In 22 cases the trauma was due to aspirated foreign bodies, impacted in, or perforating the larynx or subglottic structures. These foreign bodies consisted of safety pins in the larynx, common pins, bits of glass, eggshells, parts of plastic toys, etc.

There are 57 children with laryngeal or anatomically related injuries in the one and one-half to 12 year age group, 33 males and 24 females. Foreign

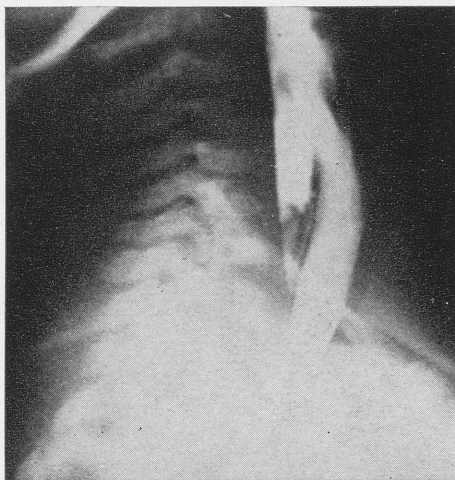


Fig. 2. Pseudodiverticulum of the laryngopharynx of a seven-week-old infant, apparently the result of vigorous attempts at pharyngeal aspiration.

bodies account for the injury in 19 of these children. In 13, the injury was associated with prolonged intubation, either postsurgical or in attempts to avoid tracheotomy for skull fracture, tetanus or acute inflammatory obstruc-

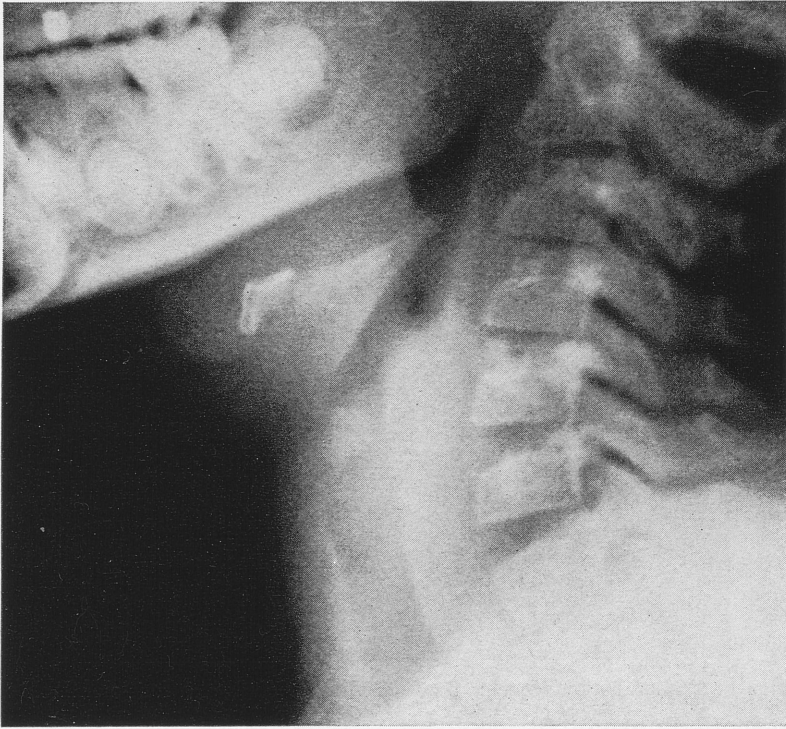


Fig. 3. Laryngeal granuloma following a fall onto the handle bars of a bicycle.

tion. Sixteen reflect the more varied activities of childhood: fall off a roof, out of a tree, downstairs, through a glass door or over the handle bars of a bicycle (Fig. 3); a blow by a baseball bat, strangulation in farm machinery, in a garage door, or laryngeal burns; two received a laryngeal injury as part of the battered child syndrome; 11 were associated with automobile accidents, either while riding in a car or when struck by one.

Thirty-one adolescents constitute the 13 to 18-year age group, 17 males and 14 females. Twenty-one were involved in automobile accidents, again either as passengers or pedestrians. One laryngeal injury was the result of traumatic attempts to retrieve a lost endotracheal tube; one boy drove into a barbed wire fence with a motor bike, an injury which severed both the trachea and esophagus; three stenoses followed prolonged intubation for tetanus, a skull fracture, and an extensive, debilitating

abdominal infection and repeated surgery (Fig. 4). Four were due to laryngeal foreign bodies — a sand burr, two with evergreen twigs, and one straight pin lying anteroposteriorly across the larynx, penetrating the posterior wall of the laryngopharynx.

Of interest in reviewing the etiology of injuries to the larynx of infants and children is a fourth group of 29 young adults (16 males and 13 females), 19 to 25 years of age. All except three were involved in high speed automobile accidents. The three exceptions were a football injury, a postintubation laryngeal stenosis and aspiration of a piece of glass.

DIAGNOSIS

The diagnosis of internal trauma of the larynx is usually made following a history of hoarseness, voice change, stridor, failure of extubation following intubation or tracheotomy for acute laryngeal obstruction. In external trau-

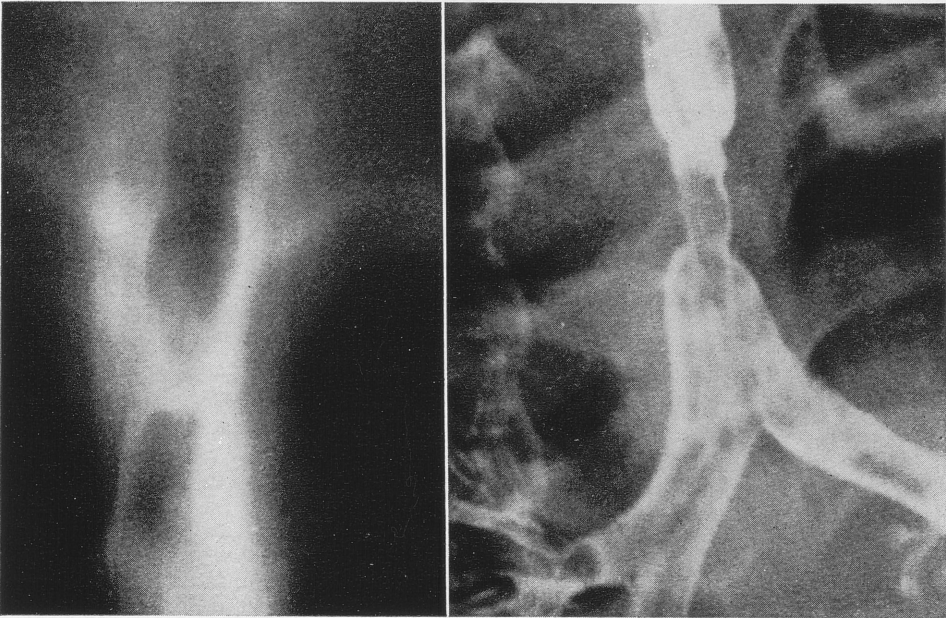


Fig. 4. Cuff-tube tracheal destruction and stenosis in a 13-year-old boy following prolonged intubation for extensive and repeated abdominal surgery. A) Laminogram of the trachea and bifurcation shows ballooning of the trachea and stenosis at the point of the distal end of the tube. B) Tracheogram.

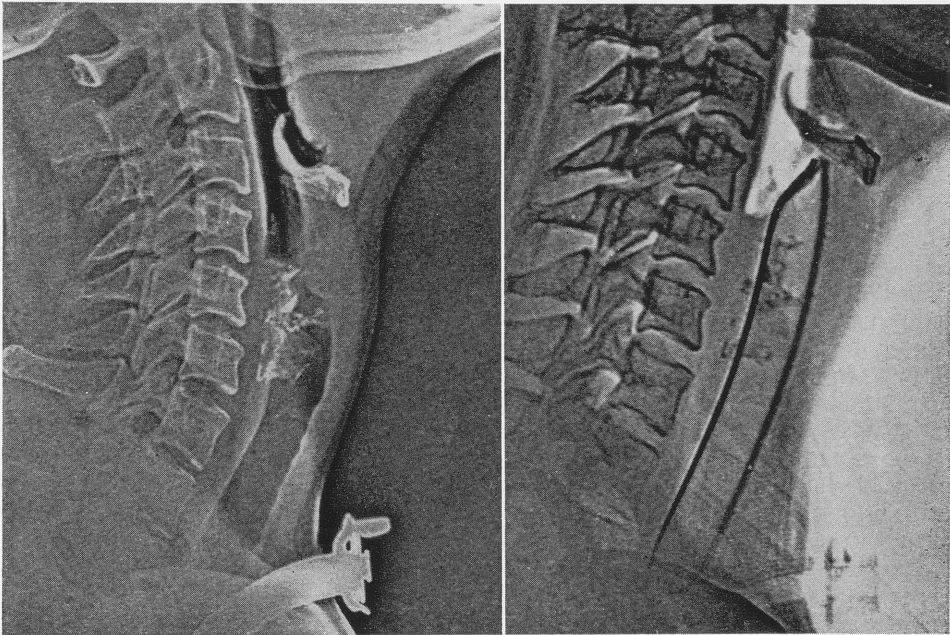


Fig. 5. Xeroradiogram of a recent anterior compressing automobile fracture of the supraglottic larynx. B) Plastic mold used to split the supraglottic structures and insure healing in a functional position.

TABLE II
MANAGEMENT
(OTHER THAN FOREIGN BODIES)*

	No.	Seen early	After 1 mo.	Trach.	Dilatations & removal of granulations	Intra- laryngeal mold	External surgical repair	Other	Deaths
Infants, 0 - 1½ yrs.	20	18	2	16	7	0	0	0	8
Children, 1½ to 12 yrs.	38	19	19	29	32	8	3	0	6
Adolescents, 13 to 18 yrs.	27	6	21	24	22	5	6	6**	1
Totals	85	43	42	69	61	13	9	6	15
Young adults, 19 to 25 yrs.	25								

* These figures include multiple procedures in some cases.

** Arytenoidectomy (2), Keel (3), Intrathoracic anastomosis (1).

ma, the recognition of crepitation is significant, confirmed by x-rays which show evidence of subcutaneous, mediastinal or pericardial emphysema. Additional information is obtained from lateral x-rays or xeroradiograms³ of the neck (Fig. 5), anteroposterior planograms of the larynx and trachea, and occasionally laryngograms or tracheograms. In all groups, accurate confirming diagnosis is dependent on indirect or direct examinations of the pharynx and larynx, with or without tracheoscopy or bronchoscopy as conditions warrant.

PATHOLOGY

In the 42 injuries, up to one and one-half years of age 15 of which were caused by prolonged intubation, the laryngeal pathology consisted of edema, ulceration and granulations on the posterior surface of the epiglottis, the cords, or the tracheal mucosa. Late development of glottic and subglottic stenosis, including synechia formation, fixation of the cricoarytenoid joints and the complication of exuberant granuloma formation in the subglottic areas were responsible for most of the long-term tracheotomies in this age group. Two newborns (one at four days and one at seven weeks) had hypopharyngeal perforations from vigorous pharyngeal suc-

tion; in both, exudate and beginning granulations were found around a laceration of the laryngopharynx with a subsequent mediastinitis; both recovered with medical management.⁴ Thirty-eight of the 42 infants in this age group were seen within the first month following recognition of the trauma (Table II). Only two of the 22 with laryngeal foreign bodies were first seen more than a month after a foreign body accident; late recognition of the impacted foreign bodies was responsible for ulceration, edema and laryngeal stenosis. Two of the 20 whose injuries were due to other than foreign body accidents were seen more than a month after the trauma: one developed a laryngeal stricture from prolonged intubation following operation for an esophageal atresia and tracheoesophageal fistula as well as tracheal granulations at the site of the fistula closure; the second had tracheal stenosis and exuberant granulations above the tracheostomy following tracheotomy for acute laryngotracheobronchitis. He was referred for extubation three months after the acute episode.

The pathology in the one and one-half to 12-year-old children showed evidence of childhood violence. The simplest pathology consisted of hematomas and edema causing hoarseness,

dyspnea and dysphagia. The more severe were crushing fractures of the thyroid, cricoid and tracheal cartilages, avulsion of the larynx or trachea, tears of the thyrohyoid membrane with loss of support of the epiglottis, and dislocation of the arytenoids. Twenty-two of the 57 children in this age group were seen more than a month after the laryngeal injury, and these all had varying degrees of scar tissue contracture or actual laryngeal or tracheal atresia. Granulomas within the larynx and trachea were common complications as were unilateral or bilateral vocal cord fixation or paralysis.⁵ None in this group had foreign bodies in the larynx whose recognition was delayed more than a month.

The most destructive trauma is recorded in the 13 to 18-year-old adolescents, the great majority of whose injuries were part of a multiple injury automobile accident. In addition to the pathology of this type of accident described in the previous group, two had traumatic tracheoesophageal fistulas. Seventeen of the 21 whose injuries were associated with automobiles were first seen more than a month after the accident when cicatricial stenoses were recognized after other fractures had healed, and extubation could not be accomplished. Of the ten whose injuries were caused by other than automobile accidents, three were from prolonged intubation. These were found to have edema, ulceration and laryngeal, subglottic or tracheal stenoses; two had extensive tracheal deformities with absence of cartilage due to cuffed endotracheal tubes (one for skull fracture, one for tetanus).^{6,7} The four laryngeal foreign bodies caused only local edema, but in one, a common pin penetrated the larynx and cervical esophagus.

The 29 young adults 19 to 25 years of age are not discussed in detail as they are considered beyond the pediatric age group. Since all but three were the result of automobile accidents, their injuries were severe, requiring primary repair when seen early, or extensive reconstruction when seen late.

TREATMENT AND RESULTS

On diagnosis³ the management of the foreign bodies in the larynx in all groups was prompt endoscopic removal. Tracheotomy was necessary in four of the 22 cases in the infant group because of a delay in diagnosis causing obstructing edema or granulomas. The management of the remaining 20 cases of trauma in this age group not due to foreign bodies was almost entirely conservative. Sixteen of the 20 infants had tracheotomies. Active treatment in those with subglottic stenosis consisted of occasional laryngeal or tracheal dilatations or the endoscopic removal of granulations. The two infants with hypopharyngeal perforations received antibiotics and were fed by nasogastric tubes inserted under direct vision. There were eight deaths, most of them associated with the primary condition which necessitated respiratory assistance, namely, respiratory distress syndrome, congenital heart disease, or other extensive congenital anomalies incompatible with life.

None of the 19 children with laryngeal foreign bodies in the one and one-half to 12 year age group required a tracheotomy; however, 29 of the remaining 38 children did require a tracheotomy. Nineteen of the 38 were seen during the first month following the laryngeal trauma, and 19 were seen between the second month and three years later. Nine of those seen late had granulation tissue between the larynx and the tracheal stoma that required one or more endoscopic removals before the airway was cleared, 23 had one or more laryngeal and tracheal dilatations, and eight had plastic molds (Fig. 5B) or a tantalum keel (Fig. 6) inserted as intralaryngeal and tracheal splints following relatively recent injuries. These effectively avoided healing with stenosis. In three of the 19 "late" cases, thyrotomies, the removal of scar tissue and the insertion of skin grafts were necessary, the skin grafts held in place first by foam rubber and subsequently by plastic molds. This necessitated the prolonged wearing of an intralaryngeal mold and

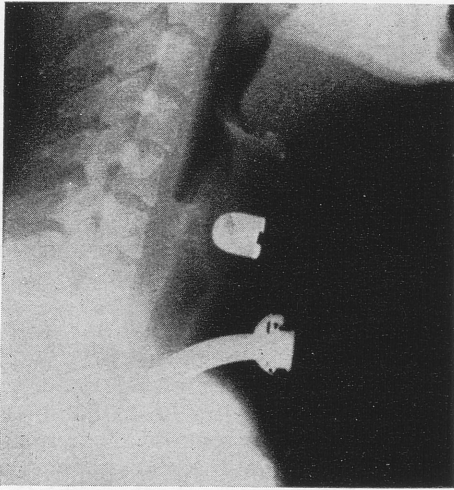

Fig. 6. Tantalum keel in the larynx of a 10-year-old girl who had a posttraumatic adhesion of the anterior two-thirds of the cords.

subsequent periodic dilatations before extubation could be accomplished. There were six deaths in the group, all but one in the younger ages, generally following prolonged endotracheal intubation. This is not to be construed as a condemnation of endotracheal intubation; these were children with brain tumors or skull fractures, or children having prolonged intubation following extensive surgery.

The 27 adolescents between 13 and 18 years, exclusive of the four with laryngeal foreign bodies, constitute the most severe injuries, and in these a more active approach was followed. Twenty-four of the 27 had tracheotomies or were tracheotomized when first seen. Twenty-one were first seen more than one month after the laryngeal trauma, and a number more than a year later. Open reduction or resection of the scarred or deformed cartilages and end-to-end anastomosis was utilized in five. A thyrotomy and skin graft was necessary in another five, followed by the insertion of a plastic mold for varying intervals of time to avoid reformation of a cicatrix. Two with bilateral laryngeal paralysis following the severance of the trachea could be extubated following an arytenoidectomy and partial

corpectomy. Repeated endoscopic dilatations were used as primary therapy only in four but constituted some part of the therapy in 22. Four of the 24 tracheotomized are still wearing their tracheal tubes. There was one death in this group, a child with a skull fracture who eventually was tracheotomized after prolonged intubation.

DISCUSSION

Trauma of the pharynx, larynx and trachea is a serious problem often requiring long term management with numerous operative procedures. In infants who have had unusually long operations followed by difficult extubation which eventually necessitated a tracheostomy, laryngeal and tracheal stenosis can usually be treated conservatively with dilatations, since normal growth assists in permitting eventual extubation. Reasonably early dilatations aid in maintaining the lumen, whereas lack of this effort results in the formation of a more rigid stricture that does not respond as well. The question of how long an oro- or nasotracheal tube may be maintained without laryngeal injury is dependent on many factors and cannot be answered with a simple rule of thumb: the size of the tube in relation to the size of the child; its chemical content and the agents used for cleaning and sterilization; the ease or difficulty encountered in the intubation; the degree of associated bronchopulmonary infection; and the general condition of the patient. The more extensive laryngeal injuries caused by external blunt trauma in children may be approached aggressively and a more favorable outcome can be anticipated through early repair. Unfortunately, while an initial tracheotomy is life-saving, definitive repair often is delayed through procrastination, necessitating extensive reconstructive procedures. However, unless the child is seen within the first month after the injury, the extensive procedures are not as effective in the younger age groups, and it would seem expedient in many cases to postpone them until the child is considerably beyond puberty when the larynx has achieved its full growth.

Generally, the most satisfactory results can be obtained in the early age group with conservative dilatation procedures, waiting for the ultimate repair until after puberty. It is felt that because of the small airway in children and the need for retaining the tracheotomy tube until an anastomosis site is completely healed and free of granulations, the more definitive surgical procedures should be reserved for those having passed puberty.

The preponderance of automobile accident injuries of the larynx and trachea in children in the adolescent age group is significant.⁸⁻¹⁰ The trauma is more severe and corrective measures are often postponed awaiting the outcome of associated injuries. However, it is evident that early correction of severe trauma should follow the same principles used for treatment of any fracture, namely, to reduce the fracture and splint it in a position of function.¹¹

SUMMARY

Trauma of the larynx and immediately adjacent anatomical structures of infants and children is divided into three age groups: infants 0 to 1½ years, children from 1½ to 12 years, adolescents 13 to 18 years. Trauma in the

first group is largely the result of impacted intralaryngeal foreign bodies, traumatic or prolonged tracheal intubation, and hypopharyngeal aspiration; in the second group foreign bodies and intubation play a lesser role while the activities of childhood (falls, misadventures in sports) become more prominent; automobile injuries increase with older children in this group while in adolescents, automobile-related injuries far outweigh all others in incidence of etiology. Those in the first group were seen early in relation to the time of injury; in the other two groups, diagnosis was usually delayed, and therefore, definitive treatment could be instituted only late. The pathology of edema, stenoses, lacerations, fractures of cartilages, tracheal separations and trauma from cuff tubes was encountered. Treatment in the early age groups was conservative; in the older groups immediate repair or intralaryngeal splinting was done if seen early; if seen late, conservative measures such as occasional dilatation were employed in the prepuberty age levels; more active surgical reconstruction was utilized in the older adolescents, consisting of thyrotomy and resection of scar with skin grafting, or direct tracheal anastomoses, arytenoidectomy, or the use of a tantalum keel.

700 N. MICHIGAN AVE., CHICAGO, ILLINOIS 60611

REFERENCES

1. Holinger PH, Schild JA, Maurizi DJ: Internal and external trauma to the larynx. *Laryngoscope* 78: 944-954, 1968
2. Pracy R: The problems of a stenosed lower respiratory tract in children. *J Laryng* 85: 1263, 1971
3. Holinger PH, Lutterbeck EF: Xero-radiography of the larynx. (In press)
4. Edison B, Holinger PH: Traumatic pharyngeal pseudodiverticulum in the newborn. (In press)
5. Mulder DS, Rubush JL: Complications of tracheostomy: relationship to long-term ventilatory assistance. *J Trauma* 9: 389, 1969
6. Fearon B, Ellis D: The management of long term airway problems in infants and children. *Ann Otol* 80: 667-766, 1971
7. Ogura J: Management of traumatic injuries of the larynx and trachea, including stenosis. *J Laryng* 85: 1259, 1971
8. Olson NR, Miles WK: Treatment of acute blunt laryngeal injuries. *Ann Otol* 80: 704-709, 1971
9. Nahum AM: Immediate care of acute blunt trauma. *J Trauma* 9: 112-125, 1969
10. Fitz-Hugh GS, Wallenborn WM, McGovern F: Injuries of the larynx and cervical trachea. *Ann Otol* 71: 419-442, 1962
11. Curtin JW, Holinger PH, Greeley PW: Blunt trauma to the larynx and upper trachea: immediate treatment, complications and late reconstructive procedures. *J Trauma* 6: 493, 1966

DECANNULATION PROBLEMS IN INFANTS

DANIEL C. BAKER, JR., M.D.

LAWRENCE SAVETSKY, M.D.

NEW YORK, NEW YORK

There have been many papers written concerning the difficulties of tracheostomy decannulation in infancy. Many factors have been implicated and this discussion will try to emphasize what some of the important critical points are. The increasing use of nasotracheal intubation for short-term respiratory problems has added a new dimension and caused a decreased need for tracheostomy in such problems. On the other hand, prolonged oro- or nasotracheal intubation has caused laryngeal or tracheal stenosis requiring subsequent tracheostomy and long-term care. Patients with obstruction at the level of the larynx do better with tracheostomy. Those patients with airway obstruction below the larynx benefit most from intubation.¹

This paper will not go into all the causes necessitating tracheostomy. However, in infancy, there are special anatomical problems which predispose to airway obstruction. In the subglottic space the mucosa has more loose connective tissue between it and the cartilage and is prone to develop edema easily.² A 1 mm widening of the mucosa reduces the tracheal lumen by 50% in a 12-month-old infant, whereas this would cause a 20% reduction in adults. Other anatomical factors are the relative softness of the cartilaginous larynx and trachea and the short aryepiglottic fold with the overhanging epiglottis in infants, and micrognathia. These anatom-

ical conditions, peculiar to infants, predispose them to upper airway problems.

For whatever reason a tracheostomy is indicated, the critical factor in avoiding a subsequent decannulation problem begins at this point. The tracheostomy must be performed in the proper location, the proper sized tracheostomy tube must be used and good surgical technique be followed to avoid excessive trauma.

The tracheostomy is performed, if possible, over a bronchoscope or endotracheal tube. The bronchoscope allows a rigid tube to outline the trachea and an internal light to help in identification. Use of either tube insures a good airway control and introduction of oxygen to the patient. A tracheostomy opening below the thyroid isthmus in the fourth to sixth tracheal ring is recommended. This avoids the subglottic area and possible subsequent stenosis.³ The larynx is high in the neck (C4) in infants and exposure of these rings without pleural puncture is not difficult. The incision in the trachea can be vertical, cruciate, or removal of a window, with care being paid to fitting the size of the opening to the size of the cannula. If a window is removed the lower one-half of the upper ring and upper one-half of the lower ring is removed so as to not fully transect the cartilage of one whole ring. After a proper sized tube is inserted, it is important to fix the tube firmly to the neck to avoid motion and tracheal

From the Department of Otolaryngology, College of Physicians and Surgeons, Columbia University, New York, N.Y.

irritation. X-ray study to determine the position of the tube should be performed as early as possible.

Following the tracheostomy, good clean tracheostomy care with sterile technique contributes to avoiding infection about the stoma and subsequent decannulation problems. Tubes should be changed daily. The most important single factor in avoiding decannulation problems is to perform a surgically precise tracheostomy and follow it with good postoperative care.

Once a tracheostomy is established the next important procedure is to decannulate as early as possible.⁴ The longer the tube is in place, the greater the incidence of granulations, infection, tracheomalacia and scarring. Once the underlying condition has been cleared and the secretions are no longer a problem, the procedure of decannulation is begun. Introducing smaller sized tubes or fenestrated tubes to allow glottic breathing and corking are all time honored techniques. It occasionally becomes necessary to induce general anesthesia and examine the trachea via endoscopy before decannulation can proceed. This will help to assess the lumen. It may be necessary as part of the decannulation procedure to introduce a nasotracheal anesthesia tube for several hours to carry the infant over the critical early hours of decannulation.⁵ Persistent subglottic edema is a common cause for difficult decannulation. It is best treated by allowing the larynx to grow.

In many institutions an increasing number of infants with lower airway or respiratory problems, which are thought to be of a short term nature, are being treated with nasotracheal intubation. This must be introduced atraumatically, fit properly and without cuff⁶ (which frequently has been reported to cause stenosis in infants) and be rigidly fixed to the face so that no motion of the tube occurs. If a nasotracheal tube needs to be in place for longer than four days, it should be removed under general anesthesia, the

larynx and trachea inspected endoscopically and either reintubation or tracheostomy performed, depending upon the condition of the airway and the expected length of time intubation is necessary. In extubating an endotracheal tube one may make use of positive pressure assistance to ventilation (intermittent positive pressure) while introducing racemic epinephrine (Vaponefrin®) as a mist. This is done for 10 to 15 minute periods, which may be repeated until it is felt that a good airway is present. The medication acts as a topical decongestant to shrink mucosal edema and the racemic form of the epinephrine supposedly has less of a cardiac effect.

To review, how do we avoid decannulation problems?

1. Most important is an accurate tracheostomy, which fits properly and is fixed firmly to the infant's neck to avoid motion. An x-ray study of the position of the tube is imperative.

2. Be certain the underlying condition is cleared. Many of the infants who cannot be successfully decannulated have subglottic stenosis, vocal cord paralysis or other abnormalities for which the tracheostomy maintenance is critical.

3. Do not attempt decannulation if excessive secretions requiring constant suctioning are still present.

4. Decannulate as early as possible to avoid late sequelae such as granulations, infection, tracheomalacia and stenosis. Long-term tracheostomies have much peristomal scar tissue formation. On decannulation, the stoma closes very rapidly and airway obstruction one or two days later may occur requiring a secondary tracheostomy. Dr. Fearon⁷ uses a plastic stent to maintain the tracheal stoma for up to three months to avoid the possible necessity of a secondary tracheostomy and to allow suctioning if a respiratory infection occurs soon after decannulation.

There are some unknown factors in difficult decannulation problems but

often described psychic dependence, emotional factors, etc. are of little importance in the infant. The problem is

a physiological and mechanical one and providing a patent airway is the main criteria for successful decannulation.

630 WEST 168TH STREET, NEW YORK, N. Y. 10032

REFERENCES

1. Baker DC Jr, Savetsky L: Congenital partial atresia of the larynx. *Laryngoscope* 76: 616-620, 1966
2. Diamant H, Kinnman J, Okmian L: Decannulation in children. *Laryngoscope* 71: 404-414, 1961
3. Westgate HD, Roux KL Jr: Tracheal stenosis following tracheostomy: incidence and predisposing factors. *Anesth Analg* 49: 393-401, 1970
4. MacLachlan RF: Decannulation in infancy. *J Laryng* 83: 991-1003, 1969
5. Greenberg LM, Davenport HP, Shimo G: Method for difficult decannulation in children. *Arch Otolaryng* 81: 72-76, 1965
6. Pearson FG, Goldberg M, De Silva AJ: Tracheal stenosis complicating tracheostomy with cuffed tubes. *Arch Surg* 97: 380-394, 1968
7. Fearon B, Ellis D: The management of long term airway problems in infants and children. *Ann Otol* 80: 669-677, 1971

SURGICAL CORRECTION OF SUBGLOTTIC STENOSIS OF THE LARYNX

PRELIMINARY REPORT OF AN EXPERIMENTAL SURGICAL TECHNIQUE

BLAIR FEARON, M.D.

ROBIN COTTON, M.B.

TORONTO, CANADA

Having been involved with the problem of subglottic stenosis of the larynx in the infant and child for over 20 years, we often pondered how this problem could be corrected by a one-stage surgical procedure in order to avoid the prolonged need for tracheotomy, and the prolonged periods of hospitalization usually necessary for these patients. Last year at the twenty-second annual meeting of the American Laryngological Association, one of us (Fearon) described the management of the long-term airway problems including subglottic stenosis.¹ So far no satisfactory procedure, surgical or otherwise, to correct subglottic stenosis has been devised, and the generally accepted opinion is that the child may possibly need a tracheotomy for many years. The airway can be improved by repeated dilations, and eventually decannulization can be accomplished.

Some years ago we came to the conclusion that the cricoid ring was the crux of the problem, and that if this ring could be enlarged to a considerably greater size than normal, then the airway obstruction could be corrected. We decided that this could be best brought about by dividing the cricoid cartilage anteriorly and the cut ends separated by using rigid or semi-rigid tissue from elsewhere in the patient's

body. In addition, it would be necessary to use an internal splint covered with a graft using skin, or preferably mucus membrane, to surface the interior of the cricoid lumen (much as in the manner we described for endo-esophageal skin graft).²

Ten years ago we elected to carry out the above procedure on a patient with a particularly severe subglottic stenosis referred from a distant province. Through an anterior neck incision the cricoid was split in the midline and a piece of cartilage with one surface retaining the skin, was removed from the pinna of the ear and interpositioned between the cut ends of the cricoid cartilage. In addition, a skin graft was placed around a Knight Silastic tube and this was introduced into the stenotic area after the latter was dilated to a 30 French size. The device was left in place for six weeks and the stent removed. Laryngoscopy at this point showed a marked edematous and granular reaction of the laryngeal mucosa proximal to the stent, although the subglottic space appeared quite satisfactory. However, in a few weeks the subglottic stenosis recurred perhaps worse than before. The procedure was repeated using a piece of cartilage from the other ear, but again the stenosis recurred after the stent was removed.

From the Department of Otolaryngology, Hospital for Sick Children, and University of Toronto.

Assisted by a grant from the Medical Research Council of Canada.

It was obvious that this tissue was simply not sufficiently rigid for the purpose.

In the next attempt to correct the stenosis, a piece of rib cartilage was used as the interposition graft, and buccal mucosa instead of skin for the internal surfacing, and using the same type of stent in the subglottic space. When the stent was removed, the result appeared to be quite satisfactory, although the tissue reaction in the larynx proximal to the stent was much greater than before. Subsequent reexamination of the larynx and trachea showed the subglottic space to be quite small although readily dilated to a 28 French, allowing a 6 mm bronchoscope to be advanced in the trachea quite easily. Now it was apparent that the cartilage graft had slipped out of position and thus projected into the lumen. This seemed to be the result of the tracheotomy tube pressing on the graft, and to circumvent this problem a tracheotomy was performed as low in the neck as possible. In spite of this the tracheotomy tube migrated cephalad until a second tape was attached to the tube and tied under the arms at the back, as described by Holinger and Johnson.³

The airway at this point was considerably improved but the patient would not tolerate the tube being plugged for any length of time. However, we felt he was in no danger and he was allowed to go home for three years, and then to return for further evaluation and treatment. Reexamination on this readmission showed the subglottic space to be much the same as when discharged from hospital, in that the lumen at the cricoid level was small but nonetheless could be dilated readily to a 30 French in size. It was decided that the cartilage was still viable and could be used for its original purpose. The latter was repositioned and maintained in place by using a short silicone tube 30 French in size, and held in position with a stainless steel wire through the lower thyroid cartilage anteriorly. The stent was left in place for six weeks and shortly thereafter the

tracheotomy tube was removed. For the first time the patient was able to use his vocal cords for speech and to date (5 months) he has had no problem.

Although it is not within the scope of this presentation to discuss the etiology of subglottic stenosis, it should be pointed out that prior to 1965 at least Holinger reported that congenital subglottic stenosis formed "the largest single group of congenital laryngeal anomalies requiring tracheotomy under one year of age."⁴ In 1965 MacDonald and Stocks⁵ advocated the practice of long-term intubation for the management of airway problems. Since then the number of cases of subglottic stenosis of the acquired type secondary to prolonged intubation has increased quite seriously. To our knowledge there is no way of knowing just how long an endotracheal tube may be left in place without damage to the larynx, even though the majority of cases in which this modality of treatment has been used have tolerated intubation for long periods without any apparent damage to the larynx.⁶ The following case history is a rather unusual example of a severe subglottic stenosis following a relatively short period of intubation.

REPORT OF CASE

A seven-year-old boy was struck by a car, suffering fractures of his right humerus and right femur, as well as a hemopneumothorax and severely contused right lung. At this time treatment was carried out in a hospital in another city. Included in the early treatment was nasotracheal intubation for a period of 36 hours. This tube was removed uneventfully. Four weeks later he was readmitted to the hospital because of severe respiratory distress. An emergency tracheotomy was performed and examination of the larynx showed a severe subglottic stenosis. The patient was referred to us for further treatment and follow-up. Direct laryngoscopy showed a completely closed subglottic space (Fig. 1). However, a #10 Jackson laryngeal dilator passed readily through the obstruction, and in fact it

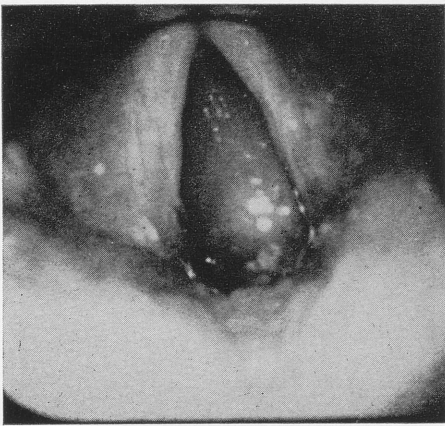


Fig. 1. Initial microlaryngoscopic appearance of an acquired complete subglottic stenosis after 36 hours of intubation.

was possible to continue the dilatation up to a 26 French without difficulty. Bronchoscopy with a 6 x 35 bronchoscope showed no significant pathology in the tracheobronchial tree.

Postoperatively the patient could breathe well and speak normally with the trachotomy tube blocked. In 12 days the obstruction recurred and dilatation of the stenosis was again performed. Subsequently he has had to be dilated every three weeks. He is able to carry on normally at home and in school with the tracheotomy tube plugged until the point is reached where the obstruction to his airway necessitates him breathing through the tube. Not having encountered a lesion of this nature before in the subglottic space we intend to carry on with the boy's treatment in this manner unless further progress is made by this modality.

In order to correct the problem of subglottic stenosis whether it be congenital or acquired, it seemed obvious that a plan of action different from the methods used previously was needed. We believed that the principle of dividing the cricoid cartilage and holding the cut ends of the cricoid cartilage apart with a rigid interposition graft was sound, but in view of the problems

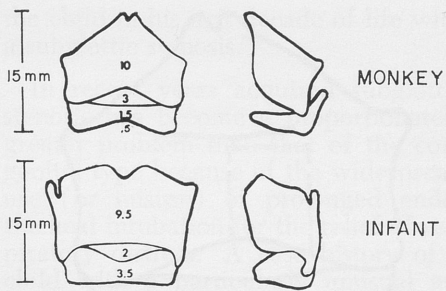


Fig. 2. Comparative dimensions of the larynx of a newborn infant and a monkey of similar weight.

encountered with the patient first described, a different method was needed to solve the problem in a one-stage procedure.

In 1968, Lapidot⁷ described the use of a thyrochondrial flap rotated in a "trap door" manner to replace a resected segment of cricoid cartilage in piglets. This provided the idea to use a segment of thyroid cartilage, not to replace the resected cricoid cartilage, but to enlarge the cricoid lumen. Not only would the thyroid cartilage be a suitable material for this purpose but it could be left partially attached by its perichondrium, thus making it more stable and perhaps eliminate the need for an internal surface graft. We decided that the most useful animal for this research project was the monkey. Our thesis was presented to the Medical Research Council of Canada and we were most gratified to be awarded a grant from the Research Council to proceed with this project.

Thanks to the cooperation of the veterinary staff of the Connaught Laboratories in Toronto, where monkeys are used for the preparation of polio vaccine, we were able to obtain a plentiful supply of larynges of three species, namely the Rhesus (*Macaca Mulatta*), the African Green (*Cercopithecus Aethiopes Sabaeus*), and the Cynomolgus (*Macaca Irus*). These were examined and dissected in order to compare the anatomy with that of the larynx of the human infant (Fig. 2). Laryngoscopies and bronchoscopies

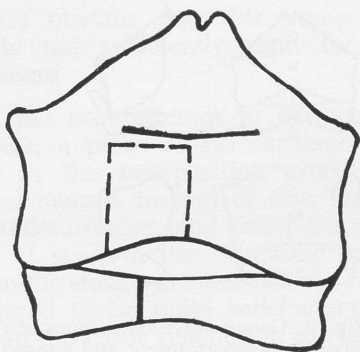


Fig. 3. Larynx of monkey to show the segment of thyroid cartilage to be used (broken lines) and the location of the cricoid transection. Solid horizontal line illustrates the vocal cord level.

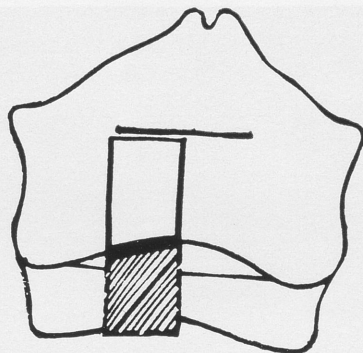


Fig. 4. Position of the thyrochondral flap in the "trap door" method.

were then carried out on representatives of each of these species under general anesthesia. We found that the larynx of each was quite similar to that of an infant of a comparable weight. The African Green monkey was chosen as being the most suitable for our research study. The weight of the animals selected was approximately 3 kgs.

Three different ways of using a part of the thyroid cartilage were considered. The first was to incise a block of the thyroid ala about 5 mm square beginning from the midline anteriorly and avoiding the attachment of the vocal cords. This cartilage was elevated from the inner perichondrium leaving the latter intact inferiorly. The cricoid cartilage would be then divided antero-laterally and the cartilage flap rotated like a trap door to fit between the cut edges of the cricoid. The block of cartilage was then sutured with 7.0 and 10.0 plastic suture material (Figs. 3 and 4).

The second method proposed was to cut a block of cartilage in a similar manner, but to rotate the cartilage block on a pedicle based at the anterior inferior margin of the incised area, and the block fitted between the cut ends of the cartilage and fixed in position as described above.

The third procedure would be to free

a similar block cartilage from the thyroid cartilage completely and fix it between the cut ends of the cricoid, as in the two previous procedures, to serve as a control for comparison.

In addition to using sutures to maintain the graft in position, tissue glue has been tried as an alternative to the sutures. Isobutyl cyanoacrylate was applied in small quantities to the edges of the cartilages, and this was found to bond the graft in place amazingly well and in a very short time. Unfortunately, there is a question of toxicity from this agent, although this has not been apparent in our usage. In spite of the excellent results when first used by us it was decided to abandon this material and instead we have used polyurethane tissue adhesive.* In its application so far it seems to be effective and without obvious complications.

To date 14 animals have been operated on using the above described techniques. Included are four in which a subglottic stenosis was created. All have been examined endoscopically and in the first six of the series the neck incision has been reopened in order to examine the operated areas. In all of these the graft seemed to be doing well.

Since primates are difficult to keep alive for any long period of time when tracheotomized, we have been fortunate in that none of the animals has had to

* Supplied by Ethicon Sutures, Ltd.

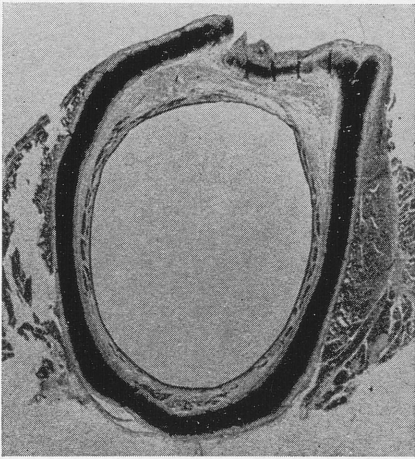


Fig. 5. Cross section of the cricoid from a monkey in which the "trap door" method was used.

have a tracheotomy for the maintenance of its airway. In one animal a tracheotomy was performed electively and the postoperative management was so difficult that the tracheotomy tube was removed the following day.

Only one animal, the first experimental model, in which the "trap door" thyrochondrial flap was used, has been sacrificed and the larynx sectioned (Fig. 5). The cross section of the specimen showed the graft to be in good position and firmly attached at either end. Furthermore, the internal diameter of the cricoid lumen was significantly larger.

SUMMARY

Subglottic stenosis in the infant and small child, whether it be congenital or acquired, has been an ageless challenge to the otolaryngologist. To keep the patient alive, there has been no alternative but tracheotomy with its inherent problems. Long periods of hospitalization and special tracheotomy care for many months or often many years are essential in the management of the patient. Lapidot et al.⁷ have stated that "we have been unable to find a report in the literature which describes a method for reconstruction and subsequent decannulation in the infant or in

the child in his first decade of life with a subglottic stenosis."

In recent years acquired subglottic stenosis has become a proportionately greater problem than that of the congenital type because of the widespread use (or misuse) of prolonged endotracheal intubation for the relief of respiratory distress. A case history of a child with a particularly unusual acquired subglottic stenosis is described.

Ten years ago we made an attempt to correct a particularly severe stenosis in a child on the assumption that if the cricoid ring could be enlarged, the problem might be solved. The cricoid with the underlining fibrous tissue was divided anteriorly, cartilage was taken from one auricle to serve as an interposition graft between the cut ends of the cricoid, and an internal skin graft over a stent was used internally. Because the auricular cartilage was not rigid enough, the procedure failed. After several procedures and only after a period of years was a satisfactory result obtained (with the advice and assistance of Dr. A. W. Farmer, former Chief of Surgery, Hospital for Sick Children).

A research project to attempt to correct subglottic stenosis of either type, using a thyrochondrial flap as an interpositional graft to enlarge the cricoid lumen was initiated by the authors. Because of its similarity to the human infant larynx, the monkey (African Green) was chosen as the research model. The choice was made after a study was carried out on the larynges obtained at postmortem of a number of monkeys. In addition, endoscopic evaluation on several anesthetized live monkeys assisted in the choice of size and species to be used.

Only 14 animals have been operated on to date using the three techniques described earlier. Six have been examined by reopening the neck incision; all have been bronchoscoped. The larynx of the first in the series has been sectioned, illustrating an apparent suc-

cessful result. One monkey died of a completely unexpected complication.

The authors emphasize that this is merely a preliminary report, but is to be an ongoing study of a method to

correct the heretofore unsolved problem of subglottic stenosis in the infant and child. Incidentally, the vocal cords in the monkeys operated on were not affected.

170 ST. GEORGE STREET, TORONTO 5, ONTARIO, CANADA

ACKNOWLEDGMENT—Sections of the larynx, as well as those to be done in the future, by Dr. Andrew Maguire.

REFERENCES

1. Fearon B, Ellis D: The management of long term airway problems in infants and children. *Ann Otol* 80: 669, 1971
2. Fearon B, Farmer AW: Endo-esophageal skin graft in corrosive strictures. *Arch Otol* 67: 374, 1958
3. Fearon B, MacDonald RE, Smith C, et al: Airway problems in children following prolonged endo-tracheal intubation. *Ann Otol* 75: 975, 1966
4. Holinger PH: Congenital subglottic stenosis. *J Laryng* 75: 1, 1964
5. Holinger PH, Johnson K: The management of chronic laryngeal stenosis. *Trans Amer Laryng Assn* 79: 38, 1958
6. Lapidot A, Sodagar R, Ratanaprashtporn S, et al: Experimental repair of subglottic stenosis in piglets. *Arch Otolaryng* 88: 529, 1968
7. McDonald IH, Stocks J: Prolonged nasotracheal intubation. *Brit J Anaesth* 37: 161, 1965

DISCUSSION

ROBERT E. PRIEST, M.D.: I enjoyed the papers very much and I'm sure the rest of you did. I wanted to say just two things about Dr. Holinger's paper, mainly to ask him some questions.

About 12 years ago I would think, at this Association's annual meeting, I and some others from the University of Minnesota presented three patients, three children who had had arytenoidectomies. One of them was my case. The other two were cases of other staff members. These other two were polio cases and were older children. My case was five years of age, having had a tracheotomy at the age of two weeks. We wanted to decannulate her and so we did the arytenoidectomy. Dr. Holinger asked me a day or two ago if I knew how she was. I saw her within the last month. She is now a sophomore or junior in college. She's a perfectly fine young lady and her voice is usable, so she has gone perhaps 14 years after her arytenoidectomy. I thought this might be of some interest because apparently there aren't too many arytenoidectomies in children of this age.

The second thing is a question to Dr. Holinger about the use of a keel in laryngeal trauma cases. I've heard statements on both sides as to the efficacy of the keel in these cases and I would appreciate his comment on this point.

WILLIAM W. MONTGOMERY, M.D.: I, too, enjoyed these papers very much. In my experience, bouginage as therapy for laryngeal and tracheal stenosis has not been effective, and often damaging. Recently, I repaired a

combined laryngeal and tracheal stenosis in an eight year-old young lady who had been unsuccessfully treated by repeated bouginage for six years. As a result of our surgery, her tracheotomy tube has been removed, but her voice quality is poor. Perhaps the latter could have been avoided had the bouginage been eliminated and her larynx been allowed to develop unmolested. If endoscopic measures are to be undertaken attempting to relieve subglottic stenosis, I feel it much more practical to resect the fibrous or granulation tissue and infiltrate the sites of their origin with Triamcinolone Diacetate.

Dr. Daniel Baker mentioned in his very fine presentation that decannulation problems are often associated with subglottic edema. If this edema is acute or subacute, it will frequently subside in response to high dosages of steroid therapy. One mg of prednisone (or its equivalent of another steroid) per pound per day is given per os for one week, or longer if necessary, prior to decannulation. This same dosage is continued for one week following decannulation and gradually tapered during the subsequent three weeks.

Chronic subglottic edema is a different disease entity. It is the result of a circumferential intraluminal involvement with fibrous tissue rather than edema. Widening of the cricoid arch anteriorly using a sialastic or cartilage block, is at times valuable as a supplement to the direct attack against the subglottic pathology. This attack, which must be designed to remove fibrous tissue and reestablish mucosal continuity, is accomplished by elevating local flaps, mucosal grafting, or some form

of wedge or sleeve resection of the lower cricoid and upper trachea. Stenting with a laryngeal or tracheal prosthesis is mandatory following this repair.

JOSEPH P. ATKINS, M.D.: I have enjoyed these papers very much. There is one thing that the essayists have not mentioned and I think it is of some importance. In considering why patients sometimes are difficult to decannulate, we must take cognizance of the disease that causes their problems. If the disease which is producing a severe inflammatory process in the subglottic larynx leaves us with fibrosis, I think we are wrong to think of the stenosis as due to a technical error on our part. In some of these cases certainly we must have some concern for the disease itself.

SABINO BALUYOT, M.D.: I'm Sabino Baluyot from Cincinnati. I'd like to make a comment about the tracheostomy. We're involved in laryngeal reconstruction at the present time and we are able to keep baboons, not monkeys, (I don't know what kind of monkey you use) for a period of up to 90 days with a tracheostomy. However, this becomes very expensive because we have to hire people to suction this animal 24 hours a day.

The other thing I want to bring to your attention to is the fact that there is an otolaryngologist, Dr. B. Grahne, from Finland, who sections the cricoid, both anterior and posterior lamina, for treatment of subglottic stenosis. A stent is inserted and left for four months. He reported seven cases with two years follow-up. (*Acta Oto-laryng* 72: 134-137)

ALDEN H. MILLER, M.D.: Dr. Priest sort of got there a little bit before me. I would like to ask Dr. Holinger what the earliest age is at which he does arytenoidectomies or arytenoidopexies? What is the earliest age at which he puts in tantalum keels? At Children's Hospital in Los Angeles, we like to get rid of tracheotomies before the child goes to school. Therefore, we're doing arytenoidopexies at the age of four and one-half years and up. While it isn't covered in his paper, would it make any difference how soon you do it?

We go through all the other things we can think of with the traumatic cases, but would there be a difference with the patient with bilateral abductor paralysis as to when you do an arytenoidectomy?

HERBERT G. BIRCK, M.D.: Mr. President, I am in agreement with Dr. Holinger. I'm in disagreement with Dr. Baker. Dr. Baker mentioned that he prefers tracheotomies in the patient for upper airway obstruction. We have in Children's Hospital in Columbus practically given up tracheotomies for croup of any type, be it epiglottitis or the subglottic type. We feel that intubation is the method of choice. The reason is that if we have a complication, which is rare with good intubation technique, we have the stent available as shown by me in a movie a few years ago in Chicago. We

have used stents now in more than 30 cases and had actually only two failures. A stenosis in the trachea presents a more severe problem. Excision of tracheal rings are a problem in most hands.

The other remark I'd like to make is regarding arytenoidectomies. I have done two arytenoidectomies in children; both of them had esophageal surgery. I don't know if in your institutions you find a lot of recurrent nerve paralysis after this type of surgery. We certainly do, and I'm wondering sometimes what is wrong.

The youngest child I operated was three and the other one was three and one-half years old. Both of them were done without tracheotomies. We did the arytenoidectomy with the suspension laryngoscope and the microscope, and left an intubation tube in place for four days following surgery.

PAUL H. HOLINGER, M.D. (closing): I appreciate the discussants' questions and I believe there is considerable reason for elaboration on some of these points. Dr. Priest mentioned an arytenoidectomy in a patient five years of age. I was very much impressed when I heard the paper, but must admit that we have not been successful in this operation in children. Dr. Priest and Dr. Birck have indicated that they were able to do these procedures successfully. Our failures have influenced our decision to wait until after puberty; so in answer to Dr. Priest's question, we do prefer to wait until after puberty until the larynx has reached its maximum growth.

One child we had was on a motor scooter and hit a wire which severed his trachea and esophagus. He ran home, was taken to the hospital and a tracheotomy tube was put into the incised trachea. The esophagus was closed subsequently and we saw the patient later for his bilateral paralysis. We did the arytenoidectomy after puberty at about 17 or 18 years of age, and he's breathing satisfactorily.

As far as the keel is concerned, we reserve that operation for simple fusion when the cartilaginous structure of the larynx is normal. The larynx of the case mentioned had been cauterized for extensive papilloma elsewhere, and we subsequently found the child with a completely fused larynx. The therapy was to simply open it and insert the keel to prevent reformation of the scar.

Dr. Montgomery's remarks about subglottic stenosis indicate he finds no result from bouginage. This may be very true; some don't respond to bouginage but nevertheless we prefer to keep the larynx open until a more definitive procedure can be done after the child has reached puberty.

I don't understand his dosage of steroids. He said 150 mgs of prednisone (1 mg per pound per day). That means a 150 pound patient, hardly a child! He also indicated that

skin grafts should be avoided; I don't agree they're entirely unsatisfactory. The skin grafts that we have used in the older group have been reasonably successful. Of course, there are some failures, and patients still have a tracheotomy; they require some dilation and eventually they too, will be extubated.

Dr. Miller again asked the question about the earliest age that we would do some of the external procedures and we said until after puberty. This refers to patients seen "late." His results in an arytenoidectomy at four and one-half years are very startling and agree with those of Dr. Priest. Maybe we are quite wrong in our contention, but we still reserve the extensive external surgery for the patient until his larynx has assumed its growth. I appreciate Dr. Atkins' remarks too.

BLAIR FEARON, M.D. (closing): Thank you, Dr. Putney. I should like to mention that in light of Dr. Montgomery's comments, most patients with subglottic stenosis that we see are extubated within a year. Before extuba-

tion, we make very certain that the patients are able to breathe through the larynx normally by making use of the stent in the tracheotomy as I have described before. This is left in place for at least three months before removal in order to avoid the tragedy of asphyxia in the child that may be fine without a respiratory infection, but if he gets a cold, he may not be able to cough up secretions adequately. When the stent is removed, the tube can be replaced, thus relieving the distress.

As it has been shown, tracheotomy can be done at any age. Even prematures can be extubated as soon as the disease is over without any decannulation problems if, as has been pointed out, the tracheotomy is done low enough. The project we described is an ongoing one and this is only a very preliminary report. We hope that we won't need internal grafts. By incising through the scar completely, and spreading it widely enough with the interposition graft, we hope to avoid the use of internal stents and the necessity of internal grafts.

RADIOGRAPHIC FINDINGS IN ADENOID CYSTIC CARCINOMA OF THE HEAD AND NECK

GERALD D. DODD, M.D.

BAO-SHAN JING, M.D.

HOUSTON, TEXAS

Throughout the mucosa of the oral cavity and the upper respiratory tract there are small glands which are similar to major salivary glands (parotid, submaxillary, and sublingual glands). These small glands are called minor salivary glands. The anatomical distribution of these glands may be simplified as shown in Table I.¹

TABLE I

NORMAL DISTRIBUTION OF MINOR SALIVARY GLANDS

Oral Cavity	
Labial glands	Lesser sublingual glands
Retromolar glands	Glosso-palatine glands
Buccal glands	Palatine glands
Glands of the floor of the mouth	Lingual glands
	Tonsillar glands
Nose	
Small glands in respiratory and olfactory epithelium	
Pharynx	
Scattered glands throughout the naso, oro and hypopharynx	
Paranasal Sinuses	
Glands are present in all the paranasal sinuses	
Larynx	
Glands are present in the epithelium throughout the larynx	
Trachea	
The lamina propria contains many small glands	
Bronchi	
Glands are found as far out as the terminal bronchioles, usually under the muscle layer	
Lacrimal Glands	
Anatomically the lacrimal glands resemble minor salivary glands	

Adenoid cystic carcinoma (cylindroma, pseudoadenomatous basal cell carcinoma) is a malignant tumor of the salivary glands. It constitutes approximately 8% of all salivary gland tumors and arises with a relatively greater frequency in minor salivary glands where the incidence is 66%.² This observation is quite in agreement with the figures at M. D. Anderson Hospital (Tables II and III).^{3,4}

TABLE II

TYPES OF TUMORS OF THE PAROTID GLAND (153 PATIENTS)

Type	No. of Patients
Malignant mixed tumor	32
Mucoepidermoid carcinoma	33
Squamous cell carcinoma	8
Adenocarcinomas	
Adenoid cystic	14
Acinic cell	8
Miscellaneous	16
Benign mixed tumor	36
Papillary cystadenoma	
lymphomatosum	5
Oxyphil adenoma	1
Total	153

TABLE III

TYPES OF MALIGNANT TUMORS OF THE MINOR SALIVARY GLANDS

Type	No. of Patients
Adenoid cystic carcinoma	48
Mucoepidermoid carcinoma	17
Malignant mixed tumor	11
Miscellaneous type of adenocarcinoma	11
Total	87

From the Department of Diagnostic Radiology, The University of Texas at Houston M. D. Anderson Hospital and Tumor Institute, Houston, Tex.

The intra-oral glands represent the most frequent site of origin, notably the hard palate. In the upper respiratory tract, the maxillary sinus is by far the most common primary site (Table IV).³

TABLE IV
SITES OF ORIGIN OF TUMORS OF
THE MINOR SALIVARY GLANDS

Site	Benign	Malignant
Hard palate	9	29
Paranasal sinuses	0	18
Base of tongue	2	6
Gum	1	5
Buccal mucosa	0	6
Larynx	0	6
Lip	0	5
Oropharynx and hypopharynx	0	4
Floor of mouth	0	3
Oral tongue	0	2
Nasopharynx	0	2
Tonsil	0	1
Soft palate	1	0
Total	13	87

Pathologically, adenoid cystic carcinoma is composed of small deeply stained cells with large ovoid nuclei and a relatively sparse cytoplasm. The cells are arranged in contiguous anastomosing cords between which are rounded acellular cystic areas containing basophilic amorphous and eosinophilic hyaline material. Mitotic figures are characteristically absent.⁴ There is no agreement as to the histogenesis of the tumor. Most observers believe that these tumors originate in the ductal cells of the salivary glands.

Clinically, adenoid cystic carcinoma is a slow-growing and invasive malignancy. There is a very strong tendency to recurrence after surgical extirpation and radiation therapy. A peculiar characteristic is the affinity to spread along the perineural lymphatics. Distant metastasis occurring late in the disease may be found in the lungs and bones. Because of the frequent local recurrence and relentless course, the prognosis is usually guarded even in the

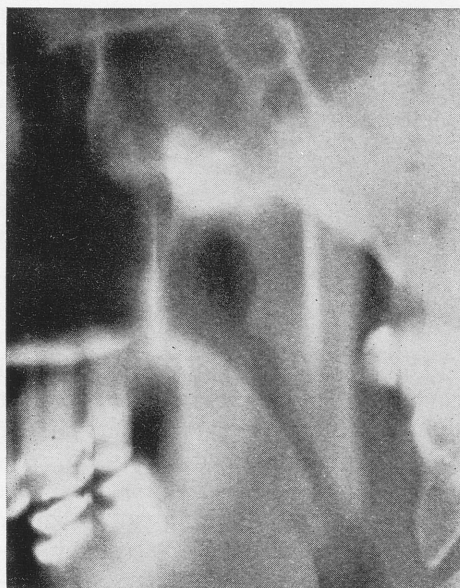

Fig. 1. Adenoid cystic carcinoma of the nasopharynx. Lateral tomogram of the nasopharynx. Considerable thickening of the superoposterior soft tissue shadow of the nasopharynx. There is a small well defined soft tissue mass protruding to the airway of the nasopharynx.

small apparently localized lesion, and the five-year survival rate is approximately 5% to 10%.⁵ There is no sex predilection and the age range is wide, peaking in the fourth and fifth decades.

RADIOGRAPHIC DIAGNOSIS

Radiographic Technique. Radiographic technique for investigation of adenoid cystic carcinoma varies with the location and extent of the lesion. We have routinely employed the following series: 1) conventional projections comprising lateral soft tissue films of the neck, submentovertical view of the base of the skull and routine views of the mandible and of the paranasal sinuses; 2) tomography including lateral tomograms of the nasopharynx, anteroposterior frontal tomograms of the paranasal sinuses, axial tomograms of the base of the skull, and anteroposterior frontal tomograms of the larynx; and 3) angiography in selected cases.

Radiographic Findings. The major salivary glands are readily accessible

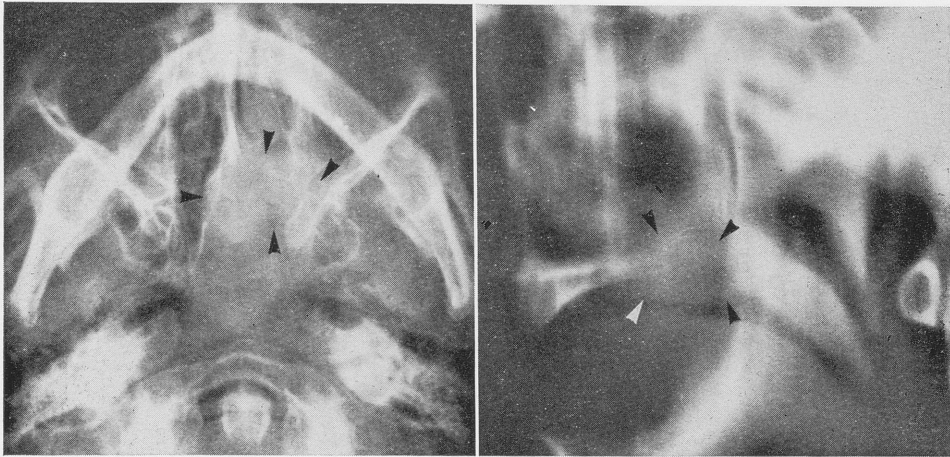


Fig. 2. Adenoid cystic carcinoma of the hard palate. A) Base view: Destruction of the left hard palate and of the posterior part of the nasal septum. There is an associated soft tissue mass in the diseased area (arrows). B) Lateral tomogram: Destruction of the hard palate is shown to good advantage. Regional soft tissue mass is clearly seen (arrows).

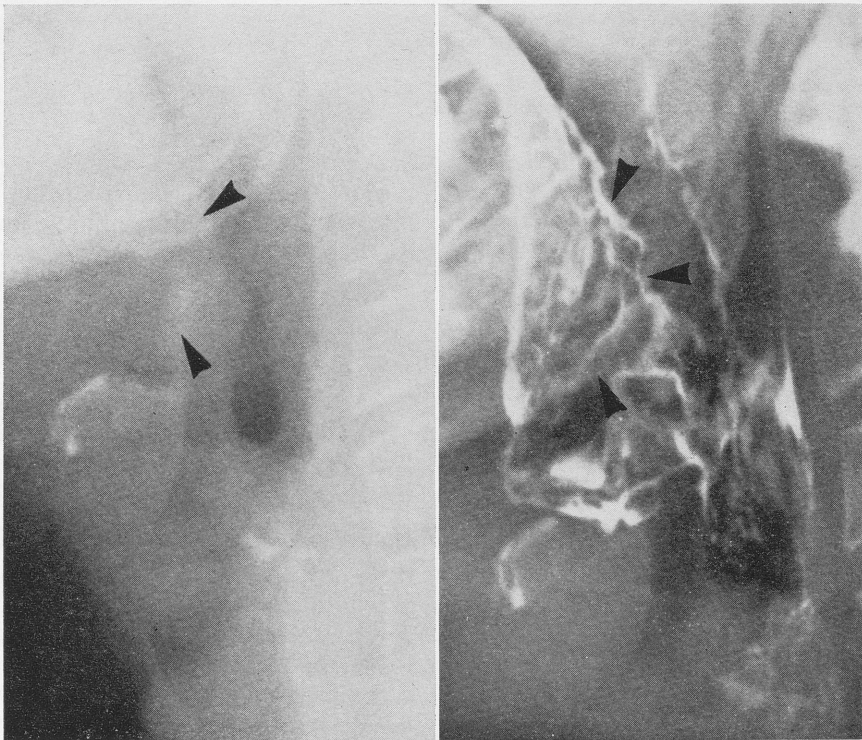


Fig. 3. Adenoid cystic carcinoma of the base of the tongue. A) Lateral soft tissue film: An exophytic tumor mass arising from the base of the tongue (arrows). B) Barium swallow: The soft tissue tumor mass is well outlined by the barium (arrows).

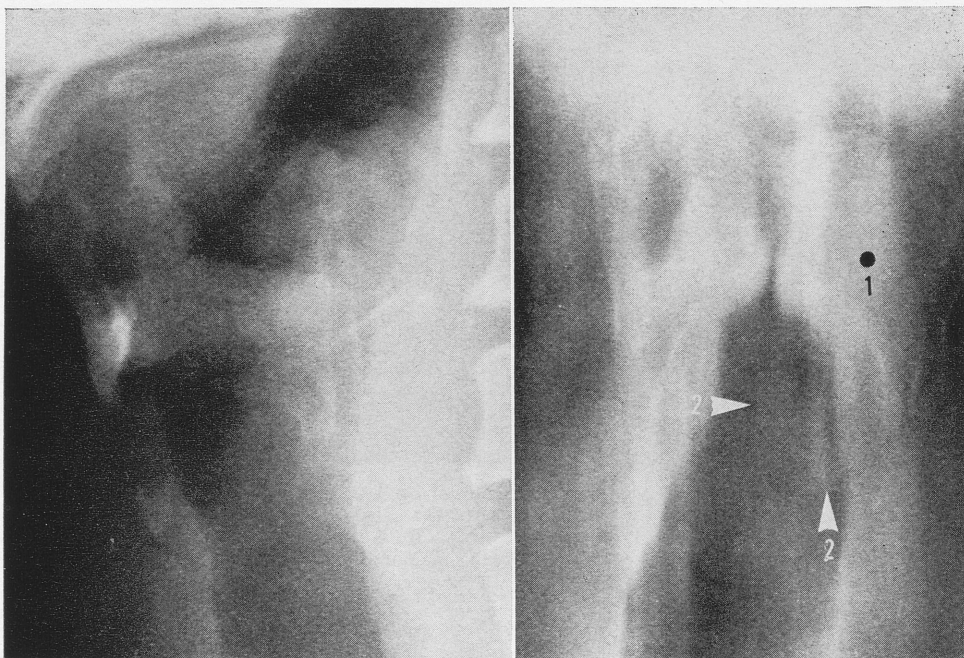


Fig. 4. Adenoid cystic carcinoma of the left arytenoid. A) Lateral soft tissue film: Soft tissue tumor mass of the arytenoid with anterior displacement of the thyroid cartilage. There is an extension to the post-cricoid area with anterior displacement of the cricoid and to the subglottic region. B) Anteroposterior tomogram: Tumor mass of the left arytenoid with involvement of the left pyriform sinus (1). There is downward extension to the subglottic region and upper trachea (2).

for clinical examination, and radiographic investigation is seldom needed. Radiographic examination is a valuable adjunct in diagnosis and management of adenoid cystic carcinoma of the minor salivary glands. The radiographic findings depend upon location and extent of the lesion.

NASOPHARYNX

Adenoid cystic carcinoma usually presents as a submucosal soft tissue mass arising from the superoposterior soft tissue or the lateral wall of the nasopharynx (Fig. 1). In the advanced stage, there may be an extension of the lesion to the clivus, the sphenoid sinuses, and the floor of the middle cranial fossa. Base view of the skull and axial tomograms of the base of the skull are often of value to delineate the extent of the involvement.

ORAL CAVITY AND OROPHARYNX

In adenoid cystic carcinoma of the

oral cavity, clinical examination with mirror and digital palpation supplies most of the information. For lesions of the hard palate and gum, radiographic examination can precisely determine the location and size (Fig. 2). When a local extension of the lesion is present, radiographic study is imperative and tomograms are most useful. For lesions of the oropharynx, lateral soft tissue films of the neck often demonstrate the location and size (Fig. 3).

LARYNGOPHARYNX (Larynx and Hypopharynx)

Lateral soft tissue films of the neck can reveal the lesion located mainly in the sagittal plane. In addition, the soft tissue film is a valuable tool with which to detect cartilage destruction. An anteroposterior tomogram of the larynx is useful in the evaluation of the lesion, especially in profile (Fig. 4).

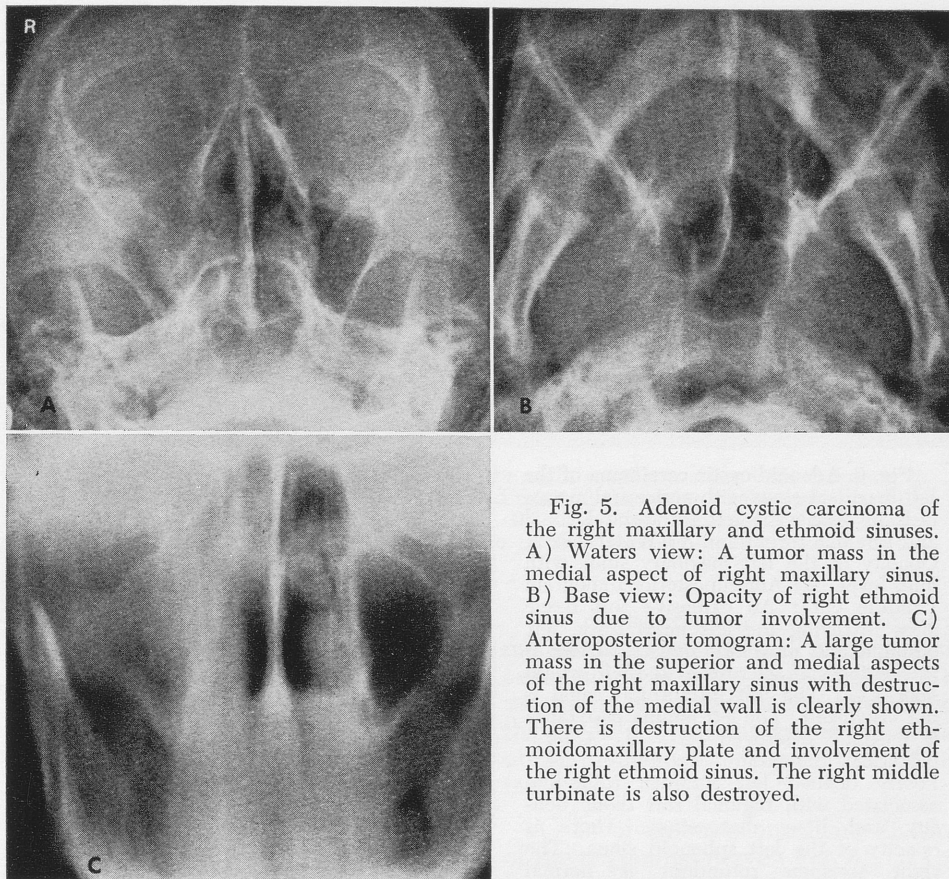


Fig. 5. Adenoid cystic carcinoma of the right maxillary and ethmoid sinuses. A) Waters view: A tumor mass in the medial aspect of right maxillary sinus. B) Base view: Opacity of right ethmoid sinus due to tumor involvement. C) Anteroposterior tomogram: A large tumor mass in the superior and medial aspects of the right maxillary sinus with destruction of the medial wall is clearly shown. There is destruction of the right ethmoidomaxillary plate and involvement of the right ethmoid sinus. The right middle turbinate is also destroyed.

PARANASAL SINUSES (Fig. 5)

The radiographic evidence of adenoid cystic carcinoma of the paranasal sinuses consists of: 1) Presence of a soft tissue mass. A soft tissue mass arising from the sinus and extending beyond the confines of the sinus is highly suggestive of a malignant process. However, it can be simulated by benign tumors or an infectious granulomatous process. 2) Pressure erosion of the bony wall of the sinus. This is caused by expansion of the soft tissue mass within the sinus. Generally, erosion occurs because of a benign expanding tumor of the sinuses. However, it is often observed in a slow-growing and expanding adenoid cystic carcinoma. 3) Destruction of the bony wall of the sinus. This indicates the invasive nature of the lesion and is reliable evi-

dence of a malignant tumor. Early bony destruction may be recognized by fading or discontinuity of the bony wall. It should be borne in mind that the medial wall of the maxillary sinus is sometimes apparently absent in a normal person because of a thin bony wall combined with an unusual degree of obliquity. In estimating destruction of the medial wall, great care must be taken not to confuse this normal variation with actual bony destruction. It is worth noting that absence of destruction of the bony wall does not exclude any early invasion of the bony wall by a malignant process. In adenoid cystic carcinoma, pressure erosion is often associated with bony destruction. Occasionally, erosion of the wall of the sinus is more apparent. 4) Invasion of the surrounding structures. This is usually seen in an advanced stage of adenoid

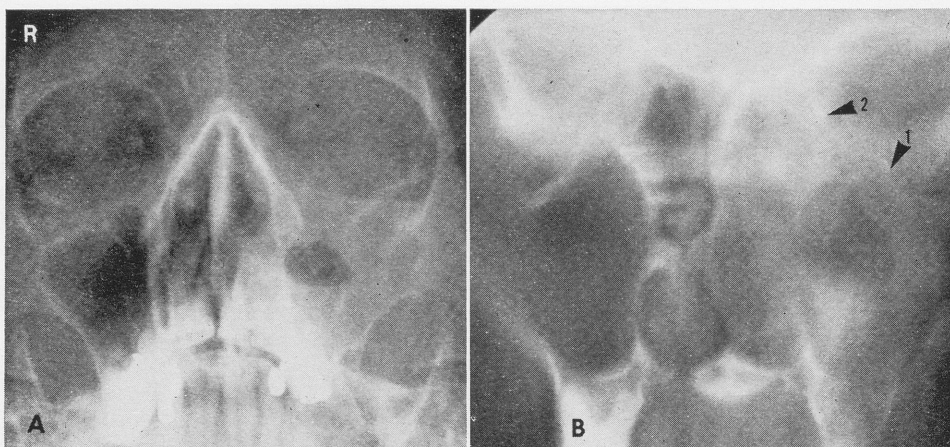


Fig. 6. Adenoid cystic carcinoma of the left maxillary sinus with perineural metastasis involving the left infraorbital canal and foramen rotundum. A) Waters view: Opacity of the left maxillary sinus with fluid level. B) Anteroposterior tomogram (middle cut): An extensive soft tissue mass involving the left nasal fossa, left ethmoid and maxillary sinuses. There is thickening and sclerosis of the left orbital floor (1). The left infraorbital canal is not visualized. The left lamina papyracea is partially destroyed (2). C) Anteroposterior tomogram (posterior cut): Poorly defined left foramen rotundum associated with regional soft tissue density and bony destruction. There is opacity of the left sphenoid sinus. The right foramen rotundum is normal (arrow).

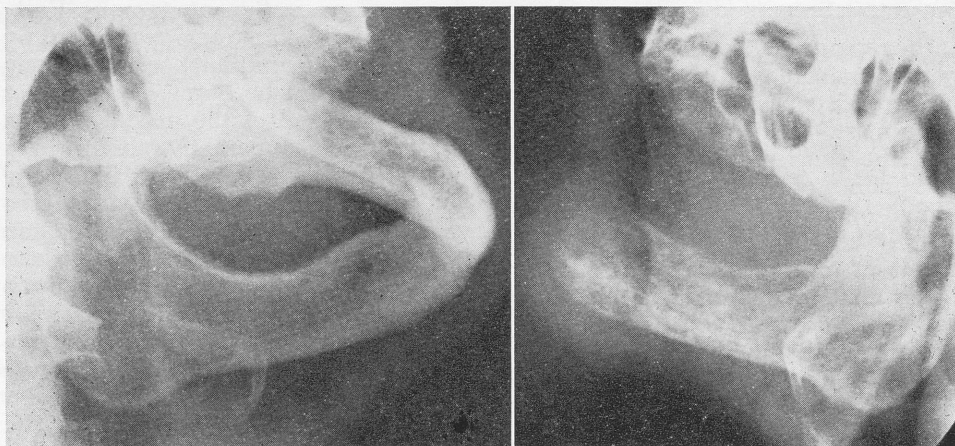


Fig. 7. Adenoid cystic carcinoma of the left lower lip with perineural metastases on both sides. A) Oblique view of the left hemimandible: Loss of definition of the left mandibular canal with regional bony erosion, mainly in the posterior two-thirds of the body of the hemimandible. B) Oblique view of the right hemimandible (six months later): Diffuse mottled destruction of the right hemimandible. The right mandibular canal is not visualized. There is postoperative status on the left side.

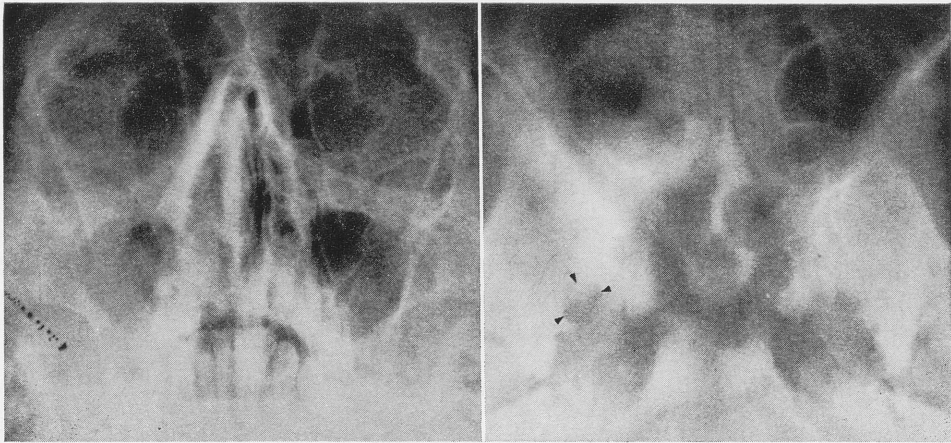


Fig. 8. Adenoid cystic carcinoma of the right maxillary sinus with extension to Gasserian ganglion. A) Waters view: Marked mucosal thickening of the right maxillary sinus without evidence of bony destruction. B) Base view: Enlargement and erosion of the right foramen ovale (arrows). There is bony sclerosis and destruction in the vicinity of the foramen.

cystic carcinoma with a regional extension.

PERINEURAL METASTASIS

Perineural metastasis is an important but neglected route of spread of malignant tumors of the head and neck and contributes to treatment failures in many instances. Certain cranial nerves, both centrally and peripherally, are confined to bony foramina and canals; enlargement of the nerves by malignant permeation of the perineural spaces may be reflected by erosion of the surrounding bony envelopes. The cranial nerves most amenable to radiographic demonstration of malignant involvement are the trigeminal and facial nerves. The remaining ten cranial nerves, though often involved, traverse large foramina and fissures which do not enclose the nerve trunk tightly enough to permit erosion.

In adenoid cystic carcinoma of salivary glands, perineural metastasis is a rather frequent route of spread. It usually occurs along the maxillary and mandibular divisions of the trigeminal nerve. In advanced cases, the foramen ovale and foramen rotundum may be involved with extension of the lesion to the Gasserian ganglion.

For demonstration of the perineural metastasis, conventional radiographic examination is often nonrevealing. Tomography is imperative for detection of the lesion and delineation of the extent of the involvement. The pertinent findings are:

A) Involvement of maxillary division of the trigeminal nerve (Fig. 6). 1. Enlargement and erosion of the infra-orbital foramen and canal. 2. Destruction of the floor of the orbit in the vicinity of the intraorbital canal. 3. Enlargement, erosion, or destruction of the foramen rotundum in advanced lesions.

B) Involvement of mandibular division of the trigeminal nerve (Fig. 7). 1. Enlargement and erosion of the mental foramen. 2. Enlargement and erosion of the mandibular canal and foramen. 3. Destruction of the mandible in the vicinity of the canal or foramen. 4. Enlargement and erosion of the foramen ovale.

C) Extension of the lesion to the Gasserian ganglion. 1. Enlargement and erosion of the foramen ovale with bony destruction in its vicinity may indicate a central spread of the lesion to the Gasserian ganglion (Fig. 8).

SUMMARY

For the diagnosis of adenoid cystic carcinoma of the head and neck, radiographic examination is a valuable adjunct. In interpreting roentgenograms of the head and neck, a knowledge of the regional anatomy of the head and neck and of the routes of spread of the disease is imperative. For a presumptive diagnosis, demonstration of a soft tissue mass is essential. Detection of

bony erosion and destruction is of great importance since these are reliable evidence of malignant disease. Enlargement and erosion of the canals and foramina of the base of the skull and of the mandible are often indicative of perineural metastasis. For final diagnosis of adenoid cystic carcinoma of the head and neck, the radiographic findings must be confirmed by tissue biopsy.

M. D. ANDERSON HOSPITAL & TUMOR INSTITUTE, HOUSTON, TEX. 77025

REFERENCES

1. Ranger D, Thackray AC, Lucas RB: Mucous gland tumors. *Brit J Cancer* 10: 1-16, 1956
2. Harris K: A study of ectopic mixed salivary tumors. *Ann Roy Coll Surg* 18: 99-122, 1956
3. Bardwil JM, Reynolds CT, Ibanez L, et al: Report of one hundred tumors of the minor salivary glands. *Amer J Surg* 112: 493-497, 1966
4. Luna RA, Stimson PG, Bardwil JM: Minor salivary gland tumors of the oral cavity. *Oral Surg, Oral Med, Oral Path* 25: 71-86, 1968
5. Batsalsis JG: Mucous gland tumors of the nose and paranasal sinuses. *Ann Otol* 79: 557-562, 1970

DISCUSSION

WALTER P. WORK, M.D.: This is a delightful presentation and it's a very difficult subject. I wonder if Dr. Dodd would say something about the therapy. I know it's a long subject.

Also could something be said about the relationship of surgery and x-ray therapy? Since this is such an interesting type of tumor, any additional information is worthwhile.

GERALD D. DODD, M.D. (closing): At the present time, at the M. D. Anderson Hospital, the treatment of these tumors is primarily surgical. Radiation is reserved for those individuals who have recurrences which are not feasible for further surgical extirpation. In other words, they're in an area where it would be either too deforming or would interfere with the vital structures, so surgery is not

advisable. That is the first category where radiation is used. The second category is that individual in whom residual tumor is present at the margin of excision or the tumor is so close to the point of excision that postoperative radiation is felt wise.

The surgical procedures that are carried out in these patients are extensive. They're as radical as one can possibly get because of the nature of these tumors, as regards basic characteristics and so on, and irradiation is fairly radical.

The usual is 1000 r to 6500 r over a period of four to six weeks. There are a fair number of complications that can be expected from this type of treatment postirradiation.

MANAGEMENT OF TOTAL NASAL BLOCKAGE BY POLYPS OF ALLERGIC AND INFECTIOUS ORIGIN

SAM H. SANDERS, M.D.

MEMPHIS, TENNESSEE

Nasal polyps are the results of pathology changes in the nasal and sinus mucosa. The cause of these pathological changes are reactions to allergens, pathogenic organisms, or a combination of allergy and infection, as well as certain systemic conditions. Nasal polyps are not a disease entity.

Systemic conditions can influence the production of nasal polyps. They occur frequently in patients with cystic fibrosis. These patients can also have allergy and the majority have sinus infection; in fact, they have practically no resistance to infection. One would expect to find pathogenic bacteria in the patient with cystic fibrosis and a nonfunctioning nose, but this is no reason to suspect all nasal polyps are due to cystic fibrosis. Nasal polyps most commonly seen by the otolaryngologist are caused by a combination of allergy and infection.

Respiratory mucosa reacting abnormally to allergens produce polyps and lose some of their resistance to pathogenic organisms. Therefore, the majority of patients with polyps totally blocking the nose are found to have a superimposed infection in the involved respiratory mucosa (Fig. 1A). Solitary polyps that form from a prolapse of the antral mucosa are caused by infection, not allergy (Figs. 1B and 3A,B,C and D).

The term respiratory mucosa is being used frequently because we are dealing with the respiratory system which includes the nose, sinuses, pharynx,

larynx, trachea and bronchopulmonary tree. Chronic pathological changes in the nose and sinuses caused by allergy and infection does not exist without some degree of involvement of the entire respiratory tract.

One may see total nasal obstruction in acute pollenosis with polyps, but the obstruction is due to the allergic rhinitis more than the polyps. Removal of these polyps will not relieve the nasal obstruction. Therefore, acute cases are not considered in this discussion.

Nasal polyposis most frequently begins from a pollenosis. As long as the patient is exposed to the causative allergen without hyposensitization, the polyps will increase in size and number. Sensitivities to other allergens increase with exposure. One does not "outgrow" an allergy. The "shock organ" changes. The changes in the shock organ leads one to believe the allergy is no longer present. Hyposensitization prevents the allergic reactions from progressing. Antihistamines reduce the nasal reaction and congestion, but do not prevent progress of the allergy. Corticosteroid reduces these allergic reactions temporarily regardless of how administered, but when discontinued the pathological changes seem to develop more rapidly than in the patient who has not been administered corticosteroids.

The more severe the allergic reaction, the more likely the interstitial fluid is to "pool" in the nasal mucosa. This occurs first in the roof of the nose. The

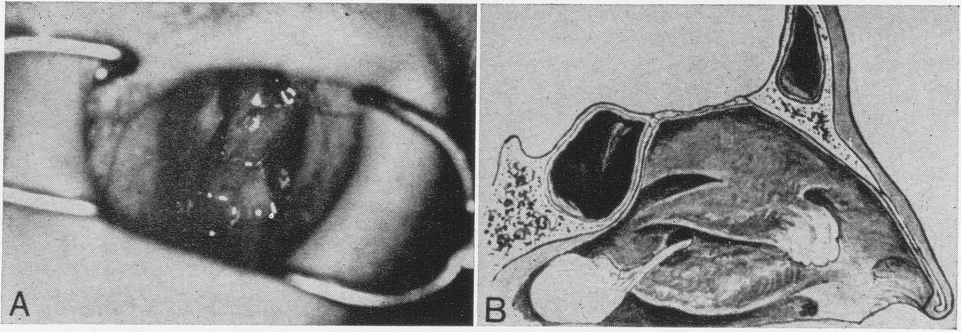


Fig. 1. A) Total blockage of the nose by polyps of allergic origin with superimposed infection. B) Prolapse of antral mucosa from infection produces the polyp.

pull of gravity and weight of the extracellular fluid causes the tissue to give, forming an epithelial covered sack of fluid. This is the first stage of a polyp caused by an allergic reaction to pollen. As the roof area is filled, polyps develop from the mucosa of the middle and superior turbinate. Occasionally, polyps may arise from the septal mucosa. If the cause of the allergic reaction is removed sufficiently early, the tissue changes may return to normal.

The degree of sensitivity to the allergen and the duration of exposure to it determine the degree of pathological change in the respiratory mucosa. The longer the tissue changes exist, the less likely they are to return to normal. Unless the tissue changes return to normal within approximately three months chronic inflammatory reactions develop, followed or accompanied by invasion of pathogenic organisms.

The infiltration by cells of these acute and chronic changes becomes irreversible causing a more permanent type of nasal blockage. The allergens may be eliminated or neutralized, but the polyps remain.

Allergy is not usually superimposed on an infection, but infection can certainly cause a sub-clinical allergy to produce clinical symptoms.

Infection causes the allergic patient's sensitivity to vary from day to day. The endpoint is not stable. This necessitates a change in the dosage of the allergens

frequently. Consequently, it is very difficult to hyposensitize a patient with an infection in the respiratory tract.

Pathogenic organisms are not eliminated by a nonfunctioning nose as well as they are in a functioning one. Pathogenic organisms invade this tissue of low resistance. The infection then extends from the polyps into the sinuses.

With the onset of inflammatory changes the nasal passage is further reduced. The ethmoids are infected first and polypoid degeneration develops. The pathology extends into the frontal and sphenoid blocking their ostia. Later the maxillary ostium will be occluded. The maxillary ostium is obstructed last because the polyps, due to allergy, originate in the roof of the nose.

Pressure from the polyps can be demonstrated radiologically by a lateral widening of the ethmoid labyrinth (Fig. 2A). There is also a uniform density, less than that which occurs in infection without an allergic component (Fig. 2A and B). The changes can also be demonstrated radiologically by a uniform density. When the density is uniform the frontal pathology is often overlooked. The bilateral uniformity in density is thought to be due to many things other than pathology, the most common being a shallow frontal. The nasal findings are of utmost importance in the interpretation of frontal sinus x-rays.

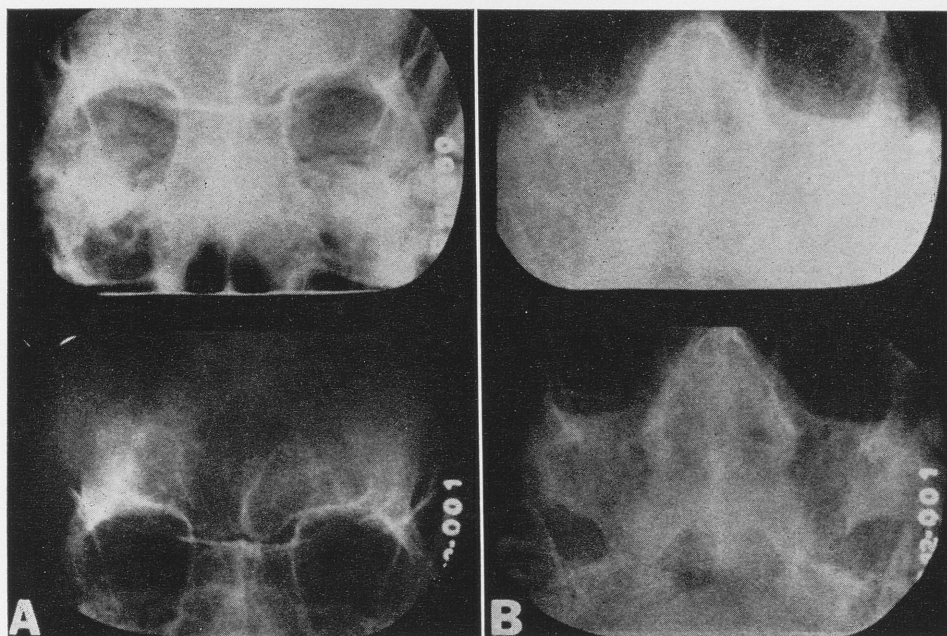


Fig. 2. Bilateral pansinusitis, allergy with infection. Light and dark exposures. A) Lateral widening of the ethmoid labyrinth. B) Erosion of bone in the floor of the right antrum.

Hyperplastic sinusitis follows allergy in the production of nasal polyps. Hyperplastic sinusitis is a pathological classification, not a disease entity. The term as used applies to the tissue reaction caused by a nonpus forming pathogenic organism, be it viral or bacterial.

Pyogenic organisms also produce nasal polyps. Virulent pyogenic organisms will produce ethmoidal polyps in the middle meatus in a short while. The edematous reaction of acute infection due to pus forming organisms subsides rapidly and fibrotic changes take place. When polyps caused by infection do form, they are most likely to appear in the ethmoid. Polypoid changes occur in the more acute suppurative sinusitis and regress into atrophic changes with long standing chronic infection. One seldom sees sinus infections due to one strain of organism. A combination of pyogenic and nonpyogenic organisms occur more frequently.

The purpose in bringing out the difference between the pathological

changes produced by suppurative and nonsuppurative organisms is to show that it is the pathological change in the tissue that produces the polyps. Allergy, bacterial infections and systemic conditions individually or in combination are responsible for the development of these changes in the tissue of the nose and sinuses.

The most common site for polyps caused by infection is the middle meatus. The maxillary, anterior ethmoid and frontal opens into the middle meatus. When the cellular partitions of the ethmoid are destroyed, gross changes in the nasal mucosa of the middle meatus can be seen. By this time the infection has extended into the frontal sinus. Similar tissue changes take place in the maxillary sinuses and eventually the lining mucosa prolapses into the nose at the point of least resistance, which is the natural ostium (Figs. 1B and 3A,B,C and D). The weight of the tissue, the constriction by the ostium (Fig. 3B and C), and the push and pull of the air currents in the

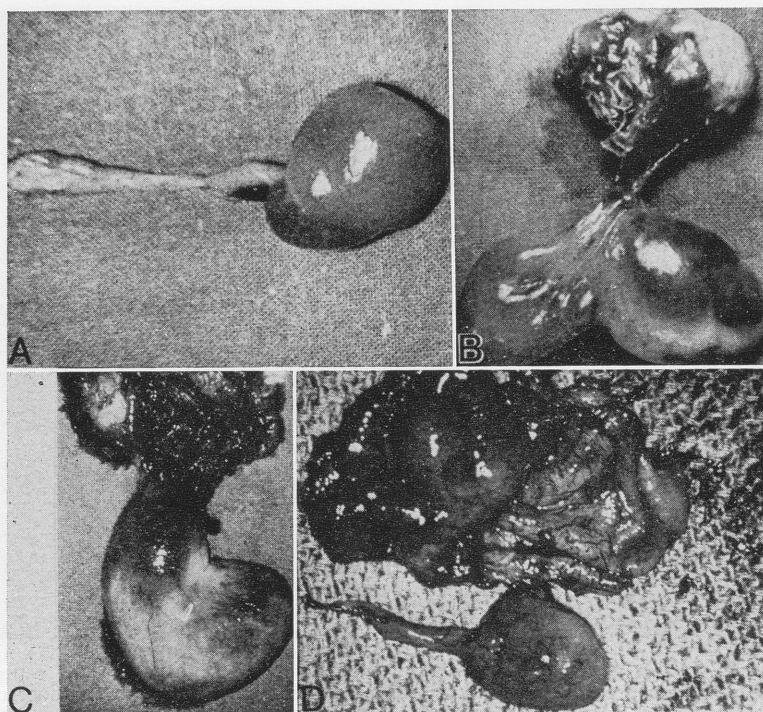


Fig. 3. A) Prolapsed antral mucosa. Polyp with pedicle. B) Antral mucosa with nasal polyp. C) Antral mucosa with nasal polyp. D) Antral mucosa with polyp forming in center. Below, frontal polyp with pedicle.

nose cause the antral mucosa to form a pedicle. This pedicle hugs the lateral nasal wall and is often overlooked. The polyp increases in size and blocks the nostril or nasopharynx (Fig. 3A). If seen in the early stages, the polyp appears as pathological sinus mucosa in the middle meatus. As more sinus mucosa prolapses through the natural ostium, the polyp becomes pedunculated from weight and the pull of the air currents. As the polyp increases in size, it fills the posterior part of the nose and nasopharynx (Fig. 3).

If this polyp is snared off in the nose it will return (Fig. 3A). To prevent recurrence the antrum should be opened in the canine fossa, the lining mucosa carefully elevated from the bony wall to the natural ostium. The antral mucosa with the attached membranous middle meatus is excised. The antral mucosa with the membranous middle meatal mucosa is pushed into the nose (Fig.

3A, B and C). The polyp and the attached antral mucosa can be delivered through the nasopharynx. On examining the specimen one can see why the polyp will recur when removed from the nasal cavity. It is continuous with the antral mucosa. Allergy is not a factor in the development of this type polyp.

When one sees polypoid changes developing in the middle meatus, one can be certain of an ethmoidal infection, even though there is no purulent discharge. Polyps caused by allergy do not originate in the middle meatus. If an allergy component exists the polyps will form faster. One is not likely to see solitary polyps in the ethmoid, as in the antrum, as each ethmoid cell contributed its part to the gross findings. The ethmoidal cell walls are broken down in the pathological process. The diseased ethmoidal mucosa is then separated from the nasal chamber only by

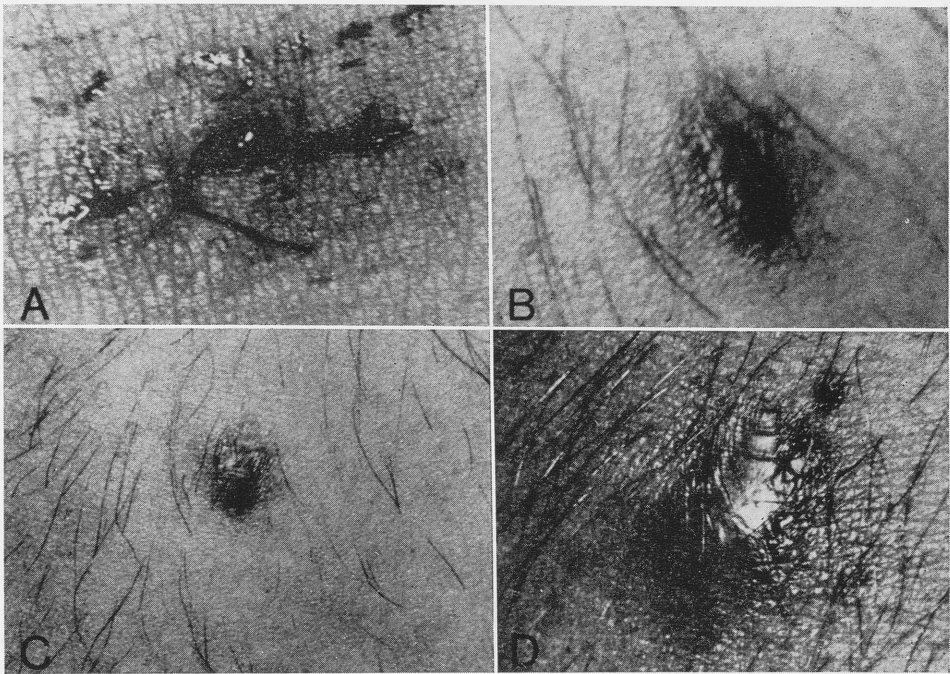


Fig. 4. A) Implant of pathological frontal sinus mucosa in the forearm of a patient with infection superimposed on allergy complicated with advanced obstructive lung disease. B) Inflammatory reaction following an exacerbation of lung infection. C) Implant covered by skin. Notice the atrophic appearance of the skin. D) Inflammatory reaction during acute tonsillitis.

the nasal mucosa of the middle meatus. The nasal mucosa becomes involved and the ethmoid mucosa of the individual cells prolapse into the middle meatus, resulting in multiple polyp formation. As the infection progresses, the middle turbinate may become involved, especially so, if it contains cells.

ROLE OF FRONTAL IN NASAL POLYPOSIS

The frontal mucosa is a part of one continuous mucosal lining of the sinus and nasal cavity. The same principles of diagnosis and treatment must be applied to the frontals as is applied to the other sinuses. Irreversibly diseased frontal sinus mucosa produces polyps and must be treated the same as all other sinuses. When irreversibly diseased, the lining mucosa must be totally removed. A nasofrontal duct is not desired following the complete removal of the frontal sinus mucosa. The size of the frontal is not a factor. The following

clinical observations may be somewhat convincing.

CLINICAL OBSERVATIONS

A 24-year-old male with total obstruction of the nose with nasal polyps presented himself for diagnosis and treatment. He had received previous hyposensitization, antibiotics, antihistamines, corticosteroids and a host of other medications with very little, if any, relief. He had an advanced obstructive lung disease, a nose full of polyps, and small frontals. His allergies were reevaluated using the intradermal titration technique and provocative food tests; cultures were taken and nasal smears, sensitivity tests and x-rays were made. His allergy was treated through the pollen season by elimination or hyposensitization to all offending allergens, and corticosteroids were given at intervals. Improvement was noticeable. After three months of therapy the fol-

lowing surgical procedures were carried out.

Left Side (antral, transantral and intranasal, ethmoid and sphenoid). Removal of all the lining mucosa of the antrum, ethmoid and sphenoid. Removal of the polyps.

Right Side (pansinus procedure three weeks later). Removal of all the lining mucosa of the antrum, ethmoid, sphenoid and frontal. Edematous tissue was seen in the middle meatus around the nasofrontal duct on the left side. Two months later polyps were found in the middle meatus on the left side; the right side was free of polyps.

Left Side (external frontal and exploration of the ethmoid, three months later). Removal of the lining mucosa of the frontal and supraorbital cells, polyps and mucosa of the nasofrontal duct. The ethmoid was carefully examined to see if any ethmoid cells were overlooked in the previous surgery. None was overlooked. After removal of the lining mucosa of all sinuses the polyps have not returned over a period of years.

CONCLUSIONS FROM CLINICAL OBSERVATIONS

The polyps recurred on the left side as a result of the diseased frontal mucosa that was not removed. This was proved by the removal of the mucosa of the small frontal which eliminated formation of the polyps.

These observations were made in early 1934. Since then similar observations have been made many times on the allergic as well as the nonallergic patient, with large or small frontals. The size of the frontal does not have a bearing on this phenomena.

Experiment No. 2. In May, 1970, a patient with a bilateral pansinusitis, nasal passage obstructed by polyps, caused by allergy and infection, and advanced obstructive lung disease was referred. He had been treated for years by both otolaryngologist and allergist with all modern drugs, hyposensitiza-

tion and surgery. The last surgery was incision and drainage of the left frontal in October, 1969.

After reevaluation of his allergies, hyposensitization and other treatment was started, a bilateral pansinus procedure was recommended. A left pansinus procedure was performed on May 25, 1970. The same procedure was performed on the right side on June 1, 1970. The patient agreed to the implantation of the frontal sinus mucosa in the forearm (Fig. 4A). Two pieces were implanted. An incision was made through the skin and the mucosa sutured to the skin with the epithelium on the outer surface. The second implant was imbedded under the skin. Unfortunately, the surface implant was torn off three weeks later. The imbedded implant has been observed and photographed frequently since implantation (Fig. 4C). Acute exacerbations of the obstructive lung disease have occurred. With each there has been evidence of active inflammation in the implant (Fig. 4B). Antibiotics that improve the chest symptoms also reduce the inflammatory reaction in the implant.

The patient developed an acute tonsillitis, the implant became inflamed, painful and later fluctuated, subsiding with control of the tonsil infection (Fig. 4D). A portion of the implant was removed on April 12, 1971 and submitted for microscopic examination. Bacteria were not grown from the tissue. Microscopic study revealed nothing conclusive. The tissue is to be studied with the electron microscope. The remaining portion of the implant is being observed clinically.

In the author's opinion these observations are further proof that the sinus mucosa does undergo irreversible pathological changes. Therefore, after the allergy is under partial control, complete removal of the lining mucosa of all involved sinuses and the irreversible pathological tissues in the nasal chamber, is the treatment of choice for total nasal blockage by polyps caused by al-

lergy and infection. It should be emphasized that hyposensitization or elimination of the allergenic factors must be accomplished prior to and continued after surgery for an indefinite period. Prior to any surgery all patients should have a thorough physical examination with special emphasis on the respiratory system. Good x-rays of the chest and sinuses are essential. A thorough allergy study is next in order. This includes a good history, intradermal skin test using the Rinkle titration technique for inhalents; the provocative food test as described by Lee should also be done. These can be correlated with the cytotoxic tests if desired. The offending allergens should be eliminated if practical. Hyposensitization to inhalents and neutralization of food should be carried out for a minimum of two months prior to surgery and continued indefinitely. If the patient's endpoint is above a Number 5 dilution, a minimum of three months therapy prior to surgery is preferable.

CONTRAINDICATIONS

Major Surgery. No major surgery should be performed during the patient's pollen season.

Elimination, hyposensitization and accepted allergy should be carried out for the necessary period partially controlling the allergy.

Any acute infection or exacerbation of chronic infection are mandatory contraindications.

In asthmatic patients it is necessary to decide how much surgery can be safely tolerated.

Pansinus Procedure. The surgery of choice is termed a bilateral pansinus procedure. Surgery should be done on one side at a time. The other side may be operated after one or more weeks. The time between surgery depends on the general condition of the patient, the degree of sensitivity, the duration of symptoms, the extent of corticosteroid therapy, the degree of obstructive lung disease and the season of the year.

The preferable anesthetic is local.

The entire lining mucosa of all the paranasal sinuses is removed through a combined external and intranasal approach. A compromise means failure.

The maxillary sinus is entered through a small triangular opening in the canine fossa. The frontal and supra-orbital cells are approached through an external incision on the lateral wall of the nose and floor of the frontal approximately 1-½ cms in length. The ethmoid, sphenoid and nasal polyps are approached externally, transantrally and intranasally. Every vestige of lining mucosa is removed from one sinus at a time. The middle turbinate is not removed. Only that portion of the mucosa of the middle turbinate thought to be irreversibly diseased is removed.

Preoperative Preparation. Antibiotics and cortisone are administered three days prior to surgery. The amount of cortisone depends on when and how much cortisone has been previously administered.

Preoperative Medication. For the average patient, ¼ gr of morphine is administered subcutaneously one hour prior to surgery. Forty five minutes later ¼ gr of morphine and 1/150 of atropine is given. The dose will vary accordingly to the age, weight of the patient and the existence of asthma; morphine or Demerol® is given during the operation, if necessary; barbituates are never given.

Local Anesthesia. Topical anesthesia is obtained by carefully packing the nose with strips of cotton moistened in equal parts of 4% cocaine and 1 to 1000 adrenalin. Xylocaine® 1%, with 1 to 100,000 ephedrine is used for infiltration of the skin and subcutaneous tissues.

Operative Procedure. The entrance to the antral cavity is gained by a small triangular opening in the canine fossa (Fig. 5A). The lining mucosa is elevated at the opening and gauze pushed under the mucosa with an elevator to separate the mucosa from the bony wall

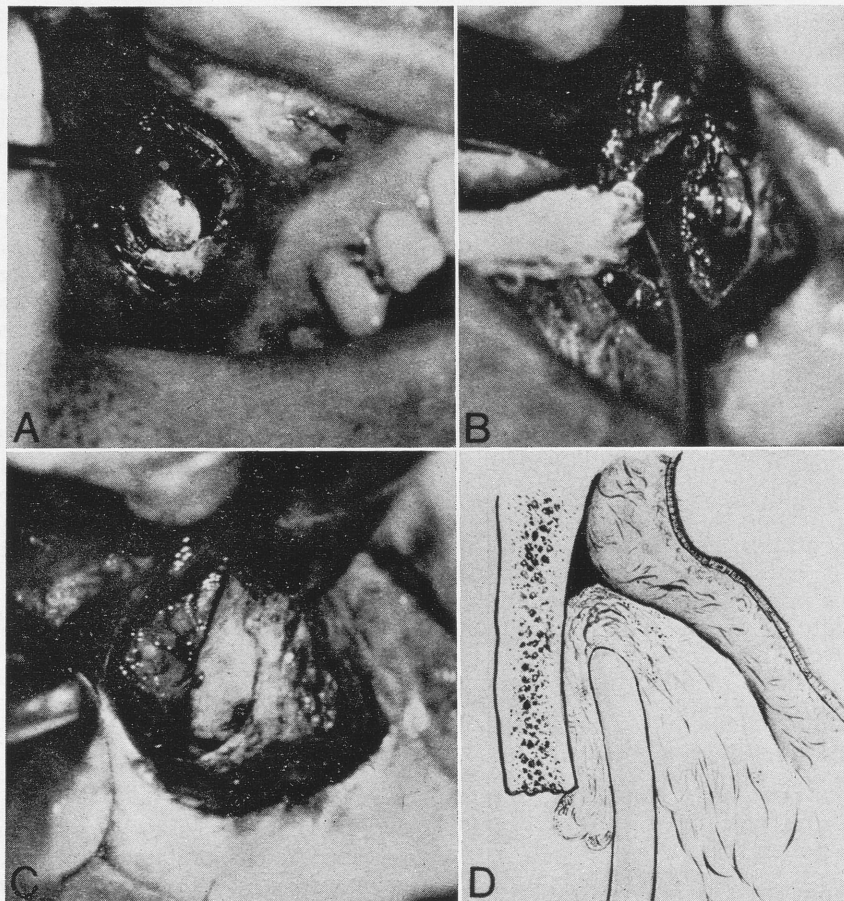


Fig. 5. A) Elevation of antral mucosa at the triangular opening in the canine fossa. B) Gauze pushed between the lining mucosa and bone to elevate mucosa. C) Antral mucosa elevated from bone. Attached only at membranous middle meatus. White area is the bone of the nasoantral wall of the inferior meatus. D) Drawing illustrating procedure in B.

(Fig. 5B and D). Only the mucosa around the natural ostium cannot be elevated as it is attached to the nasal mucosa (Fig. 5C).

The nasal and antral mucosa of the middle meatus must be removed as they cannot be separated. The bone of the inferior meatus is taken down and a corresponding flap of nasal mucosa attached at the base is cut to lay on the antral floor (Fig. 5C). This flap serves as a graft of nasal mucosa which migrates to meet the ingrowing nasal mucosa of the middle meatus. The entire antral cavity is covered with modified nasal mucosa in approximately

three months. The antral cavity is inspected, using a mirror to view the recesses of the cavity for possible remnants of mucosa.

The posterior ethmoid cells are entered transantrally. The lining mucosa and any polyps falling into the ethmoid space are removed.

The anterior bony wall of the sphenoid is taken down transantrally.

The frontal is entered through an incision on the lateral wall of the nose and floor of the frontal approximately 1-½ cms in length (Fig. 6). Bleeding is controlled.

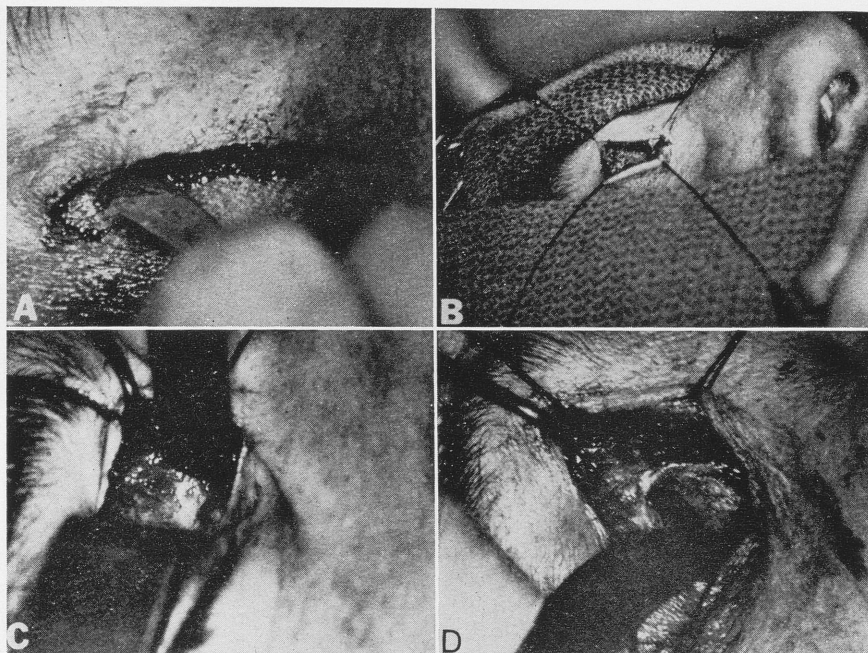


Fig. 6. A) Incision for external frontal ethmoid and sphenoid. B) Retraction sutures in place. C) Gouge used to enter the floor of the frontal and ethmoid. D) Trochlea attached to rim of orbit superiorly. Retractor exposing the ethmo-orbital wall.

The attachment of the trochlea and the anterior ethmoidal vessels and nerves are exposed (Fig. 4D). The trochlea is detached and its position noted for reattachment later. The anterior ethmoidal vessels are cut, and bleeding controlled. The floor of the frontal and the supraorbital cells are totally removed. The ethmo-orbital wall is partially removed. The mucosa of the frontal, supraorbital and midline cells is removed (Fig. 8A).

The cavity is inspected using a mirror for viewing all crevices for any remnants of remaining lining mucosa. The remaining ethmoids, except the most anterior are exenterated and their lining mucosa removed through the external approach. Polyps attached to the middle turbinate, if any, are removed. Any remaining anterior wall of the sphenoid is taken down. The lining mucosa of the sphenoid is carefully elevated and removed. The nasal cavity is inspected intranasally (Fig. 7C). The middle turbinate is held against the septum

with a three inch nasal speculum. The few remaining anterior ethmoid cells are exenterated and the nasal mucosa extending from the middle turbinate to the bulla is removed. The ethmoid space is inspected from the nasal approach (Fig. 7C), using the three inch nasal speculum. The speculum is then inserted between the middle turbinate and the septum. Any remaining polypoid tissue is removed. The opening into the sphenoid is reinspected.

After the surgeon has inspected all sinuses from all approaches and is satisfied that every vestige of lining mucosa has been removed, adaptic packing is inserted. The ethmoid space is packed to hold the middle turbinate against the septum. The packing must not extend into the frontal. The flap of the nasal mucosa in the inferior meatus is held down with packing. No packing is placed in the antral cavity. The trochlea is reattached to the periosteum above its previous detachment. The frontal incision is closed in two layers

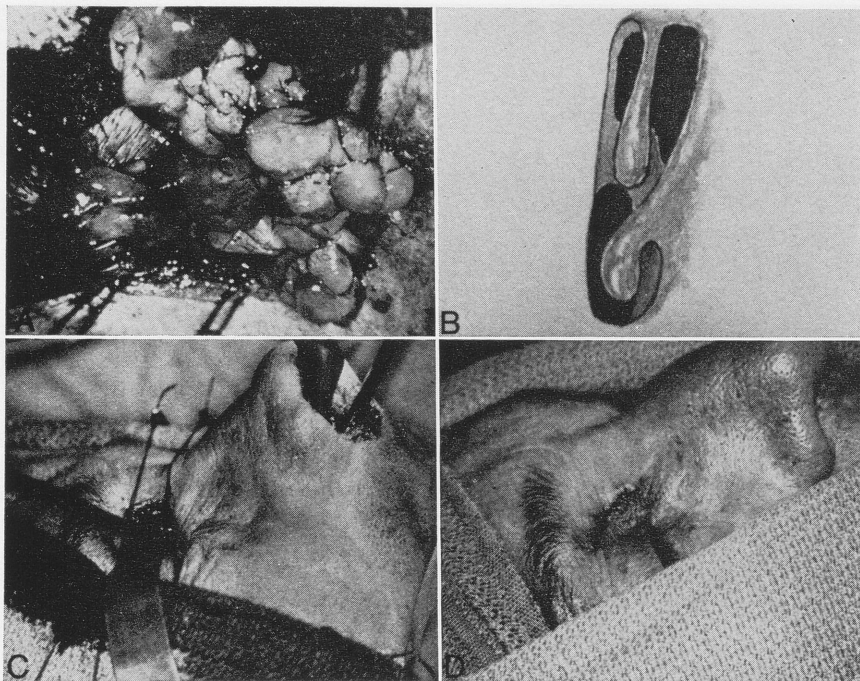


Fig. 7. A) Polypoid frontal sinus mucosa (caused by allergy and infection) under pressure in the frontal. B) Middle turbinate above. Ethmoid space and sphenoid represented by black area on each side of middle turbinate. Black area below represents choana. C) Inspecting the ethmoid and sphenoid from intranasal and frontal approach. D) Frontal incision after closure.

making sure that the 6-0 silk skin suture engages the skin only. Catgut may be used to close the buccal mucosa.

Postoperative Care. The packing and sutures are removed on the third day. Practically no postoperative treatment is necessary. If desired the antrum may be washed two or three times at weekly intervals. It is desirable to have the middle turbinate remain in the normal position. This leaves an ethmoid and antral cavity which will later be lined with modified nasal mucosa.

Healing Process. The frontal will seal off and fill in with granulation tissue, which changes to connective tissue. This connective tissue produces the same density as that of bone on x-ray. A six month postoperative x-ray of a frontal where all of the lining mucosa has been removed shows a complete obliteration of the frontal. The density which is produced by the cicatricial

tissue is the same as of bone. Exploration of operated frontals also verify the healing process as described.

If all of the lining mucosa is not removed, one or more areas of less density will be seen in the x-ray. A mucocoele or pyocoele will develop from any buried epithelial covered tissue. The nasal mucosa migrates over the bare surface of the middle turbinate as that on the lateral wall migrates over the ethmo-orbital wall to join on the roof of the ethmoid. This adds more nasal mucosa to the nasal cavity than was there prior to surgery. As granulation tissue forms in the antral cavity, nasal mucosa begins migrating over these granulations from the opening in the inferior and middle meatus. When the granulations are covered by the migrating nasal mucosa, connective tissue changes take place. The result is an antral cavity smaller than normal covered with modified nasal epithelium with a naso-antral

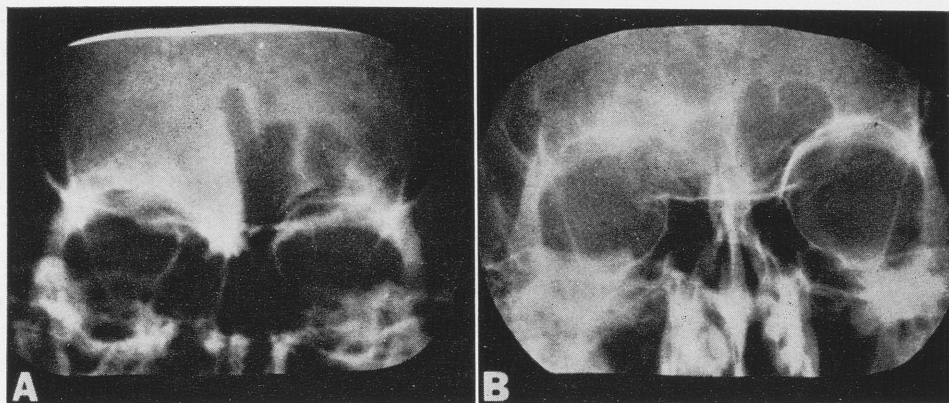


Fig. 8. A) One year postoperative right frontal completely filled with connective tissue. X-ray shadow equivalent to that of bone. B) Right postoperative frontal after eight years. Lighter areas due to incomplete removal of lining mucosa. Potential mucocoeles.

opening in the middle and inferior meatus.

A six month postoperative x-ray will show that the antral cavity has been partially filled with tissue casting a shadow equal to that of bone. Areas of less density indicate incomplete removal of the lining mucosa (Fig. 8). When this procedure is properly performed, the nasal cavity has a normal appearance. There are no raw surfaces, the turbinates are in a normal position, there is no crusting and there is more surface covered with nasal mucosa than prior to surgery.

Undesirable Surgical Sequelae. There are several undesirable sequelae from the pansinus procedure. These are annoying, but rarely cause any real physical disability. These possible side effects should be explained to the patient before surgery.

Diplopia is the most common side effect; it follows detachment of the trochlea from the orbital rim. The diplopia can be prevented by carefully reattaching the trochlea to the periosteum of the orbital rim with 000 chromic catgut. Usually when it does occur the diplopia is transitory. In several hundred cases there has been only one case which required prism to correct this ailment.

Anesthesia of the forehead occurs postsurgically if the supraorbital nerve is cut. This can be prevented in most cases by elevating the nerve from the supraorbital notch and preserving it.

Enophthalmos may occur when the frontals and supraorbital cells are extremely large and a large portion of the ethmo-orbital wall is taken down with the floor of the frontal. Preservation of a portion of the ethmo-orbital wall will prevent this. If it is necessary to remove all the floor of the large supraorbital cells, fat can be used to fill in the space, thus preventing the enophthalmos.

Complications. Pain and swelling of the eyelids and forehead may occur following the pansinus procedure. This is secondary to transudation of serum into the frontal sinus and soft tissue. The accompanying edema usually subsides in 7 to 14 days. A small probe should be passed through the incision into the frontal.

Osteomyelitis is apparently a postoperative complication of the past.

Mucocoeles, pyocoeles, postoperative antral cyst and chronic purulent discharge are all the result of incomplete removal of the lining mucosa of one or more sinuses. These conditions should

be credited to poor surgery, not complications.

Polyps will return in the nose if the allergy is not kept under control.

CONCLUSIONS

The pathogenesis of nasal polyps has been discussed and it has been stressed that the polyp formation is the result of a mucosal reaction in the nose and sinuses, produced by bacteria, allergy, or a combination of these. The etiological agent must be controlled or eliminated in handling the nasal polyps. This may include hyposensitization injection for allergy, systemic therapy, sinus surgery or a combined therapeutic regimen.

1286 PEABODY AVE., MEMPHIS, TENN. 38104

When surgery is indicated by chronicity of the sinus disease, it is necessary to remove all the diseased sinus mucosa from all diseased sinuses. Simple removal of the nasal polyps will not suffice. The underlying disease, whether allergy or infection must be controlled or eliminated.

An accurate diagnosis of the etiology of the polyps is all important. A carefully taken history, unhurried physical examination, sinus x-ray, skin tests and nasal smear will achieve this diagnosis in the majority of cases.

The complications of the pansinus procedure are discussed.

Some of the results of poorly executed surgery has been mentioned.

ALLERGIC LARYNGITIS

RUSSELL I. WILLIAMS, M.D.

CHEYENNE, WYOMING

The mucosa of the nose, accessory nasal sinuses, nasopharynx and bronchi are well documented as shock organs for the allergic reaction involving the respiratory system. The larynx, however, being an integral portion of the respiratory system, has seldom been mentioned in the voluminous reports on allergy of the upper and lower respiratory system. Curiously, few of the many individuals who suffer from perennial and seasonal manifestations of allergy complain of impairment of vocal function, except in the professional user of the voice, i.e., a singer, auctioneer, radio or television announcer or lecturer.

Allergic reaction in the larynx exists more often than the pertinent literature indicates. Because of its elusive nature, it is frequently undiagnosed or misdiagnosed. Obstructed nasal passages, conjunctival itching, watering and irritation will take precedence over a mild-to-severe, nonpainful laryngitis and resulting hoarseness. For these reasons, involvement of the larynx occupies a position of lesser importance. Only in the case of sudden, severe, anaphylactic reaction in the form of edematous swelling of the uvula, arytenoids, epiglottis or vocal cords, producing a sudden impairment of the airways, is attention directed toward the larynx. Edema of allergic etiology occurs in the larynx, usually very rapidly, producing a real state of anxiety and apprehension.

Since there is a paucity of information in the literature, the basis of this presentation involved replies to questionnaires sent to my colleagues, who represent many years of actual experience

in Otorhinolaryngology and otorhinolaryngologic allergy. My thanks go to them for their unhesitating cooperation in sharing their knowledge, without which this paper could not have been prepared.

REVIEW OF LITERATURE

A general survey reveals very little information regarding allergic manifestations of the larynx as a single entity.

Tuft¹ has an excellent review of otorhinolaryngologic allergy, but he does not specify laryngeal involvement. Brodnitz² mentions a Russian author, Alimov, who states that in 69 of 245 acute and chronic laryngitis cases, allergy was found to be the underlying cause. Brodnitz also suggests the need for and the merits of hyposensitization. Moses³ mentions the case of a 9-year-old excessive eater of ice cream and candy bars, with edematous vocal cords and nodules, improved by discontinuance of these foodstuffs. Paparella⁴ reports a case of severe laryngeal edema due to a bee sting in the left arytenoid cartilage. Wolf⁵ and many others have stressed the importance of allergic factors in the etiology of spasmodic croup and laryngotracheitis. Of 48 cases presented, 42 showed signs of allergy in infancy. He stressed repeated attacks of laryngotracheitis and spasmodic croup as themselves indicators of underlying allergy. Hansel⁶ cites cases of allergic edema as pointed out by Osler.⁷ Halsted⁸ reported three interesting cases of edema of the larynx and pharynx, but gives no indications as to what might have been the cause.

There is a strong possibility that many cases of unexplained death could be due to sudden edema of the laryngeal structures. Hansel mentions cases reported by numerous others of severe laryngeal edema and alarming dyspnea. Oddly enough, most of these cases were reported prior to 1900.

Frank⁹ reports a case of chicle sensitivity producing a severe laryngeal edema. Chicle is used in the manufacture of chewing gum. This case fortunately responded favorably to injection of 10 minims of adrenalin. Jacobs and Hansel¹⁰ report a case of beef sensitivity which was characterized by hoarseness and a marked respiratory distress about 20 minutes after eating beef, and which responded to an epinephrine spray 1:100 and epinephrine subcutaneously. Laryngeal edema can occur from antibiotic therapy, as reported by Anderson,¹¹ severe enough to require tracheotomy in two cases. These were due to penicillin sensitivity. Hansel¹² suggests that drugs, foods and inhalants are the most common etiological factors in laryngeal edema. Among the drugs, he mentions the coal tar products, such as acetosalicylic acid (aspirin) and similar preparations as the most commonly encountered in a series of 53 cases. The inhalant factors concerned animal danders, house dust and cosmetics. He does not incriminate any particular food.

MECHANISM OF ALLERGIC LARYNGITIS

The mechanism is primarily edema formation in varying degrees, which may involve the entire larynx or specific portions of the larynx. The more severe forms involve the entire larynx, including the epiglottis, arytenoids and vocal cords and create a real medical emergency, which requires immediate restoration of the airways, in the form of intubation or tracheotomy. The less severe allergic reactions, which produce mild to severe hoarseness, are usually the result of edema of the contact surfaces of the true vocal cords. Miller¹³ demonstrated on cadaver specimens the various means by which edema could occur in various portions of the

larynx and he pointed out that submucous areolar tissue extends from the base of the tongue upward as high as the tip of the epiglottis. He makes no mention of the mechanism of edema of the contact surfaces of the vocal cords.

Hoarseness is a quality of the voice that is harsh, more or less discordant and usually of lower pitch than is normal for the individual.¹⁴ To the average individual, hoarseness is of little importance, but to the professional voice user, this is indeed a severe situation. He will seek immediate relief if at all possible. Methods of relief will be discussed under "treatment."

The mechanical elements involved in production of sound include three important steps: setting of the air column into vibration or motion; approximation of the vocal cords; and firming up or hardening of the cordal edges. These are the basic steps necessary for phonation and interference in any stage would naturally affect the quality of the voice. Here again, this becomes most important to the professional vocalist, wherein only a very slight change in the consistency of the cordal edges and submucosal tissues presents a very serious handicap. The slightest edema of one or both vocal cords will change the size, and more important, the rigidity of the vibrating mass. This, in turn, will interfere with the pitch and proprioceptive sensations by which a singer controls his voice.

ETIOLOGY

The etiological factors are varied and numerous. The perennial inhalants are house dust, molds, feathers, animal danders (dog, cat, house pets, birds, etc.) and volatile oils or emanations from plants, commonly termed terpenes. Seasonal problems are due to the various pollens of the plant kingdom, such as trees, grass, Plantain, Atriplex, Mesquite, Pigweed, Kochia, Russian thistle, Chenopods, Ragweed, Sage, Cocklebur, Dandelion, Burweed, Hemp, Sorrels, etc., all of which have a relatively specific date of pollination, which in turn helps to determine the pollen

or pollens causing the trouble.

Food antigens may also produce mild to severe edema of the laryngeal structures. Foods as well as inhalants may demonstrate a specificity of reaction; that is to say, one particular food produces edema of the epiglottis only, another produces edema of the uvula, another of the arytenoids or another the contact surfaces of the vocal cords. In order to understand how certain foods may involve the larynx in the form of an allergic reaction, a basic concept of food allergy, originally advocated by Rinkel et al.¹⁵ should be explained. There are three basic types of food allergy: fixed, cyclic and thermal. Fixed food allergy is defined as one which will still produce symptoms on each ingestion, regardless of the time it has been eliminated from the diet or the amount ingested. In the cyclic concept of food allergy, usage tends toward sensitization and symptoms, while omission tends toward tolerance or adaptation and abeyance or improvement of symptoms. If one accepts the cyclic concept, it is possible to control symptoms by elimination or rotation of a food or foods in the diet. I presume this would also be the case with inhalants if we were able to eliminate the offenders, but this is an impossibility.

Thermal food allergy¹⁶ may be defined as a type of sensitization which is nil or slight except when the patient is exposed to the low temperature critical for that patient. There are two sequelae: 1) fever; and 2) purulent secretions. Clinically, this type of sensitization is responsible for most cases of chronic "colds" and "sinus disease" each winter, if food is a factor at all. There are three clinical forms of cyclic food allergy: perennial; primary; and concomitant and thermal. Cyclic food allergy exists in a series of six stages. These are: masking; a short period of omission; hyperacute reaction; acute reaction; latent reaction, and tolerance. A brief description, emphasizing the clinical significance of these stages, is given at this time.¹⁷

First and most important is the stage of masking. A patient may know that a certain food produces a specific kind of symptoms, but its omission will not relieve him. He continues to have identical symptoms, but is unable to locate the cause. Suspected foods, when eaten in copious quantities to prove they are a cause of symptoms, may actually improve the patient. This is the reason that many food-sensitive patients present themselves for study. Their confusion is frequently due to masking. Masking is a term created to describe the reduction or ablation of symptoms due to ingestion of a specific food, while one is still having symptoms from the previous ingestion of the identical food. The confusion to the patient is due to the fact that he may actually feel better for several hours after consuming the etiologic food. Not all foods will mask their reactions. Masking may be imperfect in that symptoms will be controlled for a few hours, with recurrence of the reaction, or it may be perfect, when symptoms are eradicated with no recurrence or delayed reaction.

The second stage of cyclic food allergy occurs when the food is avoided for at least 96 hours. The patient's reaction to the food will change from the stage of masking to the stage of hyperacute reaction (an accentuated reaction compared to the previous masked reaction). It is important to realize that masking and omission, with production of the hyperacute reaction, can and do occur without any thought or knowledge of this fundamental feature of food allergy. This feature only adds to the confusion of the patient and the physician and emphasizes the absolute necessity of understanding the cyclic concept of food allergy.

In a short period of time, the combination of masking, the period of omission, and reeating of the food which produces hyperacute reaction, collectively constitutes Phase I of food allergy. The accidental reaction of all stages of Phase I is usually the specific cause of severe reactions. In taking the history, it is not uncommon for a patient

to describe masking, accidental omission and ingestion of the food after 96 or more hours of omission, with production of symptoms during the hyperacute phase. If a food to which a patient is sensitive is omitted except for occasional testing, it will be found that he passes through three successive stages: active sensitivity; latent sensitivity; and finally, tolerance.

Active sensitization implies that the food causes symptoms every time it is eaten. Latent sensitivity, which usually develops between three and nine months after omission, is typified by the fact that ingestion of a food on, let us say Monday, produces no symptoms, but when repeated on Friday, it provokes a mild reaction. This stage of sensitization can be very confusing to both the patient and the physician. Continued omission of the food will eventually lead to tolerance, which is relative and probably never absolute. These last three stages collectively constitute Phase II of cyclic food allergy. It is the phase of decreasing degree of sensitivity. It occurs spontaneously due to seasonal or economic reasons. It can be diagnosed if one will study the eating habits of his patients.

Once tolerance is obtained, if the mistake is made of assuming that the food is no longer allergenic and that it will not become allergenic, and it is therefore returned to the diet with the original frequency, the patient will pass through three stages: tolerance (usually lasting two to three weeks); then latent sensitization; and active sensitization. If the food is used as often as once in every 72 hours, or with greater frequency, the patient may return to the masking stage. It will be seen that a patient has passed through a complete cycle of the various phases of sensitization; hence, the term cyclic food allergy.

Phase II deserves more emphasis. It is a progressive change from active sensitization to tolerance. The period over which these stages occur can be variable, from as little as 12 days to as long as two years. One must realize

that one cannot make a correct diagnosis in the last stage of this phase because the degree of sensitivity may be very low. A single food test may not be adequate. One must consider the possibility of tolerance to foods when a patient is advised about the use of foods which have been omitted for a period of time. Test the food and determine if it produces a clinical reaction; if it does not, feed the food at intervals of five days for six feedings. If it is still agreeable, move the food up to once daily every third day. It is equally valuable to the patient to have his tolerance preserved as it was to have the original diagnosis of the sensitization.

A brief reference to Phase III: By all means, try to preserve tolerance for the food. This is a paramount duty of the physician. He must recognize that a food fed once every 72 hours may mask itself. The insidious development and increase of symptoms over a period of several weeks is highly suggestive of a recurrence of sensitization.

In the clinical application of the cyclic concept, one must consider seasonal factors such as the concomitant reactions in the presence of various pollens or dust. One should also be on the alert for thermal food reactions. Remember that the critical stages vary geographically, and in some instances, individually, for different foods. Primary food allergies are not geographic in their reactions. Geographic variations in the degree and type of presenting symptoms implies that concomitant factors are a distinct element in the causation of symptoms. The degree of sensitivity determines the severity of symptoms, but it is the frequency of usage that determines the constancy of the reaction.

Food allergy is dynamic, not static. A single test or a single evaluation is usually not sufficient. Food studies will only become efficient when they encompass all of the dynamic factors; this implies that new sensitizations are being avoided by not overeating a food; that concomitant factors are eliminated in

season; and finally, that tolerance is preserved for foods which have been previously incriminated and omitted for the purpose of gaining tolerance.

The facts pointed out above underscore the necessity of teaching the patient how to eat, for even Hippocrates knew¹⁸ that a patient might react by the simple process of eating a food twice in the day if he had been accustomed to eating it but once. The duration of the reaction may be very brief, up to a maximum of 72 hours if there are no thermal factors. In the presence of thermal reactions, the duration can be extended to five days. If the reader is interested in further information on thermal reactions, he is referred to Rinkel's "The Management of Clinical Allergy."¹⁶

The diagnosis of food allergy can only be made by a demonstrable effect. If a food allergy exists, you can prove it; *if you cannot prove it by deliberate feeding tests, the chances are that a food allergy does not exist.*

The best treatment of food allergy is the complete avoidance of the food until tolerance is gained. Then the physician should ascertain the interval of safe usage. Second choice would be injections of the neutralizing dosage as determined by the provocative food test, once or twice weekly until tolerance is gained. Sublingual therapy can also be employed. With certain food allergies, the patient must be given information outlining possible contacts. This statement refers to wheat, corn, egg, milk, soy beans, cottonseed, Karaya gum, and flaxseed, to mention a few. For further information on food allergy, the interested physician is referred to "Food Allergy," by Rinkel et al.¹⁵

Infection of bacterial origin also plays a role in manifestations of laryngeal symptoms, and if present or superimposed upon an allergic mucosa, may be quite confusing as to the exact forms of treatment. Suffice it to say that at this time treatment must be directed toward allergy as well as the infectious process. Laryngeal croup in the young

is a typical example.

DIFFERENTIAL DIAGNOSIS

Edema of any portion of the larynx, which produces a pale, glistening appearance, is highly suggestive of allergic etiology. When infection is present, we see a tendency to hyperemia or redness in varying degrees. In the early phases of acute inflammatory reaction, it would be difficult to differentiate as one seldom sees exudate. In later phases, differentiation becomes easier. If we limit our remarks to the vocal cords, inflammatory reactions show diffuse hyperemia with edema and varying degrees of redness, according to the severity of the inflammatory process. Inflammation can be allergic or infectious. If it is infectious, we see the varying degrees of hyperemia and redness; if it is allergy, the contact surfaces of the vocal cords are swollen and rather white and they appear more glistening than in the normal state. When one can visualize by indirect laryngoscopy and have the patient say "eeee" or, preferably, "ha ha ha ha ha," the presence of edema of the contact surfaces of the vocal cords is readily recognized. This brings up the question whether polypi of the vocal cords are of allergic or dual origin, i.e., inflammation plus allergy.

Contact ulcers are not necessarily of allergic etiology and are, in my opinion, usually associated with inflammation. Vocal nodules, I believe, usually represent misuse of the vocal cords, but here again, an allergic reaction may be a factor. Allergens vary greatly in specificity in individuals in that in one instance it may involve the nasal mucosa, in another the uvula, or mild nasal stuffiness occurs, and there may be marked edema of the vocal cords. The allergens may be inhalants or may be due to ingestion or inhalation of a food antigen. We must not overlook the possibility of hypothyroidism, in which we may see varying degrees of swelling of the contact surfaces of the vocal cords, and more commonly, bowing of the cords.

REPORT OF CASES

A questionnaire was mailed to 23 colleagues, of whom 19 have replied at this writing. Specific questions included: 1) Do you have any authenticated cases in which inhalants produced allergic laryngitis? 2) Do you have any authenticated cases of food allergy producing allergic laryngitis? If so, are you able to reproduce the reaction by provocation and are you able to relieve the complication by neutralizing the provoked symptoms?

The reference to "authenticated cases" involves those of proven etiology, i.e., reproduction and relief of symptoms by deliberate provocation.

Following is a brief summary of the reports submitted to me by my colleagues.

Eleven physicians reported no authenticated cases; eight reported a total of 22 authenticated cases of allergic laryngitis.

Of the 11 reporting nonauthenticated cases, all but two reported cases of allergic laryngitis in which they were reasonably sure of the etiology. The etiology in nonauthenticated cases involved inhalants such as dust, molds, animal emanations, seasonal pollens and drugs (penicillin and neomycin) as well as foods.

The etiology of the 22 authenticated cases involved dust, molds, seasonal pollens, T.O.E. (trichophyton, oidiomycin and epidermophyton), wheat, corn, egg, milk, beef, yeast, tobacco smoke, chocolate and tomato.

In my experience, the afore-mentioned inhalants are of primary importance. The most common foods capable of producing allergic edema are wheat, corn, egg, beef, milk, yeast, tomato, potato, soy, lettuce, celery, chicken and fruit juices.

TREATMENT

The ideal in treatment of any laryngeal involvement ranges from absolute voice rest to specific limitations of use.

If the contact surfaces of the vocal cords are involved, the ideal in treatment is absolute voice rest. This would be particularly applicable in the patient who uses his voice professionally, i.e., a singer, lecturer, auctioneer, announcer, etc. Where emergency treatment is indicated as a life-saving measure, one can use steroids, epinephrine by injection or inhalation, antibiotics and consideration of tracheotomy to provide a satisfactory airway.

PROPHYLACTIC TREATMENT

Preventive treatment is of primary importance and can assume several forms: desensitization; elimination of offending antigens such as house dust, molds, etc., so far as possible. Some favor strict dust elimination in the patient's home, using mattress and pillow covers, no curtains, no rugs, etc., but to traveling artists, this is impossible. Mold control in the patient's home can be accomplished to a large extent by using small amounts (5 to 10ccs) of formaldehyde (37%) in small Petri dishes, glass ashtrays or saucers, one for about every 50 square feet of floor space. This is of special help in shower stalls or moist basements.

All individuals should have the benefit of hyposensitization for the antigens to which they are sensitive. Avoidance of an antigen can sometimes be accomplished. When foods are a problem, elimination of a food, or injection therapy will offer the best results. The physician must know the constituents of various prepared foods in order to advise the patient how to eliminate a particular food from his diet.

Singers could arrange appearances so as not to coincide with any particular pollen season. For instance, Ragweed reaches its peak in the early fall in the United States and is relatively low in December and January in all parts of the country. Grass, however, is ubiquitous all over the world. Antihistamines should be used with caution as there is the possibility of drying effects on the mucous membranes and because of the tendency to slow down muscular re-

action time. For this reason alone, they should not be prescribed for the professional.

Steroids in the acute phase or in the chronic phase often provide dramatic relief, but the patient should be required to adhere to close supervision and be adequately advised of possible complications of their continued use. Prednisone and prednisolone can be used in dosages of 5 to 10 mgs, t.i.d., for three days, then 5 to 10 mgs daily for three to five days.

Desensitization may be accomplished by aqueous extracts or emulsion. Aqueous injections are given at 5 to 10 day intervals; emulsions may be given at 30, 60 or 90 day intervals. There are those who feel emulsion therapy provides better protection from animal dangers than aqueous injections, but the particular technic employed will depend upon the prescribing physician and the convenience of the program to the patient.

1605 EAST 19TH STREET, CHEYENNE, WYO. 82001

ACKNOWLEDGMENT—My thanks and grateful appreciation are extended to the following physicians who were most cooperative in reporting their cases: E.L. Binkley Jr., Wade H. Brannon, D. Eugene Cowen, David A. Dolowitz, Leonard Draper, Everett Gaillard, French K. Hansel, Carleton H. Lee, John G. MacLennan, S. C. Missal, L. Q. Pang, W. Hugh Powers, Theron G. Randolph, Sam H. Sanders, Samuel J. Silverberg, Richard H. Stahl, Claude M. Warren Jr., James W. Willoughby and William H. Wilson.

REFERENCES

1. Tuft L: In: Otolaryngology. Hagerstown, Md. W. F. Prior Co., Harper and Row, Inc., 1969, Vol. 5, Chapt. 29, p. 1-126
2. Brodnitz, FS: ORL Clin North Amer Oct 1971, p. 582
3. Moses P: The Voice of Neurosis. New York, Grune & Stratton, Inc., 1954, p. 121
4. Paparella MM: Unusual foreign body of trachea and intrinsic bee sting of larynx. J Laryng 78: 89-92, 1964
5. Wolf IJ: Allergic factors in the etiology of spasmodic croup and laryngo-tracheitis. Amer Allergy 24: 79-82, 1966
6. Hansel, FK: Clinical Allergy. St Louis, C.V. Mosby Co., 1953, p. 655
7. Osler W: Hereditary angioneurotic edema, Amer J Med Sci 95: 362, 1888
8. Halsted, TH: Angioneurotic edema involving the upper respiratory tract. Trans Amer Laryng Assn 27:7, 1905
9. Frank, DI: Angioneurotic edema of the larynx due to sensitivity to chicle. Arch Otolaryng 32-1067, 1940
10. Jacobs CC, Hansel FK: Allergic edema of the larynx, Bull Hansel Foundation 1: 61, 1952
11. Anderson, OE: Laryngeal obstruction due to antibiotic therapy. Arch Otolaryng 54: 34, 1951
12. Hansel, FK: Clinical Allergy. St. Louis, C.V. Mosby Co., 1953, p. 658
13. Miller VM: Edema of the larynx. A study of the loose areolar tissues of the larynx. Arch Otolaryng 31: 256, 1940
14. Jackson C, Jackson CL: Diseases of Nose, Throat and Ear. Philadelphia, W.B. Saunders Co., 1946, p. 444
15. Rinkel HJ, Randolph TG, Zeller M: Food Allergy. Springfield, Ill., Charles C. Thomas Co., 1951

16. Rinkel HJ: The management of clinical allergy. *Arch Otolaryng* 77: 47-48, 1963

17. Rinkel HJ: The management of clinical

allergy. *Arch Otolaryng* 77: 304-306, 1963

18. Adams, F: *The Genuine Works of Hippocrates*. Baltimore, Williams & Wilkins Co.

DISCUSSION

RICHARD T. FARRIOR, M.D.: I'm rising primarily to endorse Dr. Sanders' presentation and to ask two particularly general questions. For those of you in the audience (the younger men) who don't know, Dr. Sam Sanders has treated as many cases of combined allergy and infection as anyone probably in the world, borrowing some from Dr. Robb who was at the end of a big active practice, at the end of the antibiotic era. He stated he had done probably more mastoid and more major sinus surgery than anyone had ever done or would ever do again, because he felt like there would be less of it done in the future. I hope that Dr. Sanders is going to live so long that he will exceed any records. I'm speaking of management more than surgery. I suggest that you younger men listen to what you heard from Dr. Sanders today and if you read his article take full advantage of his 44 years of experience.

As many of you know, my practice is limited really to Oncology and to facial plastic and reconstructive surgery. The sinus cases I get usually from otolaryngologists are all advanced and all have total obstruction. My nature would be to do osteoplastic flaps and to try all the techniques of reconstruction of the nasofrontal duct and all the types of reconstructive procedures.

You mentioned, Dr. Sanders, and I'm sure you didn't have time, that you felt they should have allergic management probably around three months preoperatively. I'm sure you individualized all these cases according to their response, but for my sake and for the resident physician's sake, could you give some rules of thumb about how long you manage them preoperatively; what you do when they actually come into the hospital for surgery? Do you change your management at all, and what do you do when you restart your therapy after surgery?

Secondly, how confused does this all become now with steroid therapy? If you're going to do major surgery or if you should elect to do it under general anesthesia, do you stop the steroid medication at any time, and do you increase it during surgery, or do you continue it during the postoperative course?

The final question is with regard to antibiotics. Do you give these preoperatively and also during the immediate postoperative period?

WILLIAM WILSON, M.D.: I would like to report an unusual example of a larynx acting as a shock organ in an allergic diathesis. Last summer, I performed a Woodman procedure on a 40 odd year old woman because of a

bilateral abductor paralysis of four years duration. During this time, she had worn a tracheostomy tube. The paralysis was the result of a thyroidectomy. Her postoperative course was uneventful. I saw her several times postoperatively, the last time in January of this year. Her airway remained adequate. She called me the latter part of March and reported that she had had rather marked respiratory distress for five consecutive mornings. She lived approximately 200 miles away but was asked to come into the office immediately. There was little to see on examination that afternoon, but her history was reviewed and it became apparent she had had hay fever for approximately a week during the height of the tree pollination season. Testing proved she was hypersensitive to tree pollen. By optimal dosage therapy she hyposensitized readily. I kept her in Denver for several days during which time she had no further respiratory distress. She was sent home on hyposensitization therapy and continued to do well. I checked her just ten days ago and found her free of symptoms. I thoroughly enjoyed Dr. Williams' paper.

SAM H. SANDERS, M.D. (closing): The purpose of the incision is to gain access to the mucous membrane of the frontal, supraorbital and ethmoidal cells so it can be totally removed. I prefer the 1-½ cms incision on the lateral wall of the nose and floor of the frontal for many reasons. Should one prefer the osteoplastic flap procedure, well and good. The purpose of the procedure is to remove every vestige of the lining mucosa of the involved sinuses. In my opinion, the approach recommended gives better access to the outer angle of the supraorbital and ethmoid cells. It is a less extensive procedure and can be performed readily under local anesthesia.

The osteoplastic flap procedure may be indicated in tumors, osteomyelitis or when complications exist from involvement of the posterior wall of the frontal. In chronic pansinusitis caused by allergy and infection so much exposure is not necessary for me, and less trauma is produced.

I have never seen a chronic frontal sinusitis in which surgery was indicated where the supraorbital and ethmoid cells were not also irreversibly diseased. It is not necessary to fill the postoperated sinus cavity with fat. The frontal will be filled with granulation tissue which progresses to cicatricial tissue. The cicatricial tissue produces a density of bone on x-ray. At six months, postoperative x-rays will show complete obliteration of the frontal if all of the mucous membrane has been removed. If not, there will be areas of less

density indicating potential mucocoeles. When the frontal is filled with fat, postoperative x-ray will show a zone of lesser density between the fat and periphery of the frontal. This indicates retraction of the implanted fat and incomplete filling of the frontal.

As to the method of use and when to use steroids, this is a subject within itself. As Dr. Williams mentioned, we use steroids with caution and great care. Many of the patients we see have been on steroids in varying amounts and for various lengths of time. All of them have obstructive lung disease of various degrees. The steroids should be withdrawn gradually. This can be done in most cases if the allergy and an infection can be kept under control. Trauma of the involved mucosa aggravates the allergic symptoms. Sometimes removal of one polyp or just packing the nose will cause asthma. Consequently, no surgery should be done on the allergic patient during pollen season. The amount of surgery that can be done on the severely allergic is limited and should be recognized. The administration of steroids prior to surgery is beneficial and is essential in those having had large doses previously.

When to do surgery? Never operate on the allergic patient during his allergy season even though the allergy is thought to be controlled. When to operate depends a great deal on the degree of sensitivity and exposure to allergens

other than pollen. Limit surgery to drainage procedures during acute infection. The allergy and infection should be in quiescence at the time of surgery. The patient's tolerance for surgery should be determined and not violated. The original paper will go into more detail.

RUSSELL I. WILLIAMS, M.D. (closing): I rise to congratulate Dr. Sanders on crowding 40 years of experience into such a short period of time. Some 30 odd years ago, I spent considerable time in Memphis with Dr. Sanders and I rise to wholeheartedly endorse everything that he has said, especially the minute removal of all the membrane in the various sinuses. This is especially true in the frontal.

Pre- and postoperative allergic management will certainly pay dividends if one will only take the time to do it.

Maybe I have missed it in the literature, but this is the first time I've heard of the hypothesis of dual etiology of polypi, i.e., polypi with their origin from the roof of the nose being of allergic nature, while those from the middle and superior meatuses are basically infectious. This is indeed an interesting hypothesis. If it could be proved, we would know how to manage polyps.

I thank you for the privilege of being with you and again I would like to compliment Dr. Sanders on a wonderful presentation.

EXTRAPAROTID DISEASE SIMULATING PAROTID MASSES

RICHARD D. NICHOLS, M.D.

DETROIT, MICHIGAN

Preauricular masses logically suggest parotid pathology, the common cause of swelling in this region. However, the physician must guard against the tendency to think only of the parotid when presented with the patient who has either a diffuse swelling or discrete mass in this area. Diagnostic consideration must also be given to conditions which cause enlargement of the structures that surround and traverse the gland. Lesions of skin and subcutaneous tissue, parotid lymph nodes, muscles of mastication, mandible, parapharyngeal space, and the cervical spine may present as lateral facial swelling. Because of this, such patients offer a truly challenging and fascinating problem in differential diagnosis.

DIAGNOSIS

The final diagnosis may have to wait on the removal of tissue for biopsy, but the initial objective is to identify the precise location of the lesion. Inspection and palpation, the classic maneuvers of physical diagnosis, are clearly the most important means of attaining that objective. The history may be very helpful, particularly if the mass is a local manifestation of systemic disease. If the physical examination indicates that the abnormality is in some area of the bony skeleton, radiographs, including laminograms, are often indispensable. A parotid sialogram may give useful information, but we have found the parotid isotope scan to have limited application in evaluating patients of this type.

PHYSICAL EXAMINATION

The anatomical boundaries of the parotid are so characteristic that the examiner may be able, by inspection alone, to state that a lesion does or does not involve the parotid. The bulk of the gland is closely applied to the external canal, extends well beneath the lobule of the ear, is limited above by the zygomatic arch, and does not extend anterior to the masseter, particularly in its inferior extent. A diffuse swelling limited by these classic boundaries, then, is in the parotid. A discrete mass in this area may or may not arise in the gland. Generally, discrete masses are superficial lesions, arising in the skin, parotid or the masseter. Diffuse swelling is seen with involvement of deeper structures.

Diseases which affect the parotid lymph nodes, producing circumscribed masses, may be clinically indistinguishable from true parotid tumors. However, the history and physical examination may suggest the presence of a local or systemic disease, one manifestation of which is the lateral facial swelling.

Following inspection of the head and neck, bimanual palpation is done, initially with the masseter muscle as the base of reference. The masseter is chosen because it is a readily identified "floor" of the soft tissues lateral to the mandible and because its dynamic character may give additional clues to the location of the lesion. For example, a mass located within the substance of the masseter may seem to disappear when the muscle is contracted.

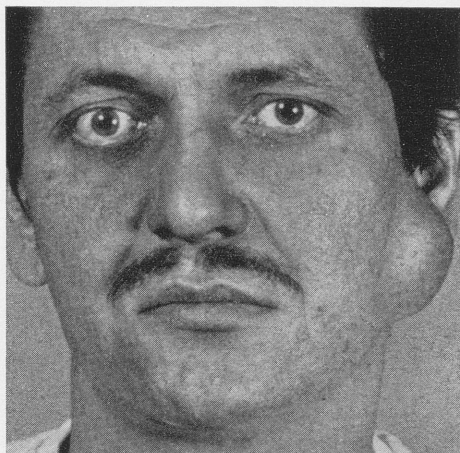


Fig. 1. Epithelial cyst of face.

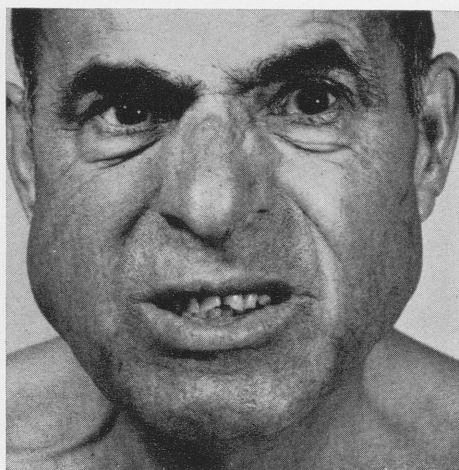


Fig. 3. Bilateral masseter hypertrophy.

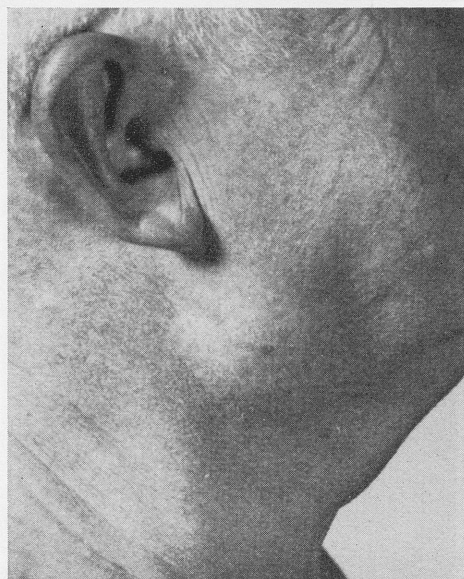


Fig. 2. Melanoma metastatic to parotid lymph node.

With the masseter alternately contracted and relaxed, the intraoral examining finger palpates external to the masseter, anterior, and finally medial to the muscle. The inner aspect of the mandible, the area of the tonsil, and the angle of the pharynx are then manually examined. These maneuvers are designed to selectively investigate the tissue lateral to the muscle, the muscle itself, the interval between the mandible

and the muscle, the mandible, and the areas medial to the mandible. This should allow rather precise localization of the mass.

REPORT OF CASES

The following brief case presentations are of several patients in whom a primary diagnosis of parotid disease was considered. Using the fundamentals outlined, we were able to determine, in most instances, that the lesion was outside the gland.

Figure 1 shows a very discrete mass located within the boundaries of the parotid, superficial to the masseter. A parotid sialogram showed medial compression of the ductal system by a soft tissue mass. An epidermoid inclusion cyst, superficial to the gland was removed at operation.

In Figure 2, the clinical diagnosis was parotid tumor. A planned superficial parotidectomy was extended to a "complete" parotidectomy, with preservation of the facial nerve, because the mass was felt to be malignant. This diagnosis was based on examination of frozen tissue sections. The mass was later confirmed to be a lymph node replaced by metastatic amelanotic melanoma. The primary tumor could not be found.

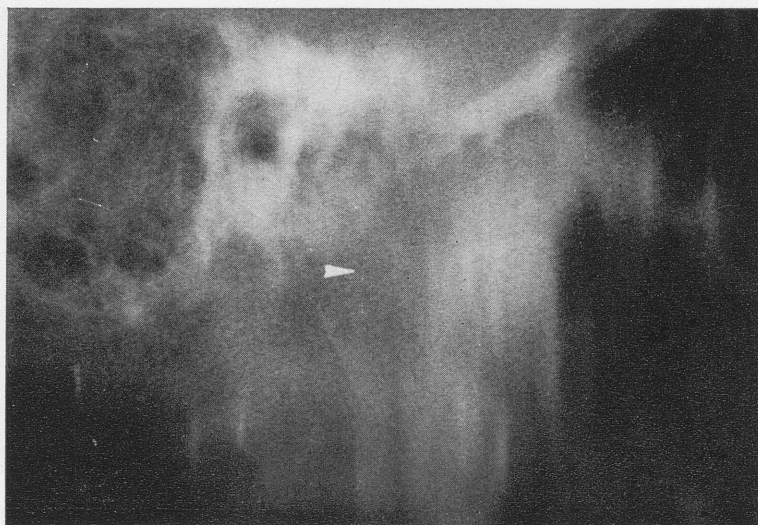


Fig. 4. Osteolytic changes (arrow) in the mandible; metastatic adenocarcinoma.

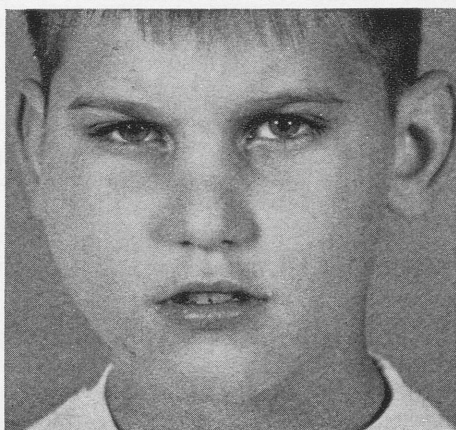


Fig. 5. Eosinophilic granuloma of mandible.

A 63-year-old male was referred as an example of a malignant parotid tumor. He demonstrated a 4 x 4 cm firm mass at the angle of the mandible. Facial function was normal. A complete head and neck examination revealed an epidermoid carcinoma beneath the anterior portion of the tongue. The facial mass was a metastasis from that primary tumor.

A 19-year-old black male complained of painless swelling in the left parotid area and neck. Examination showed a

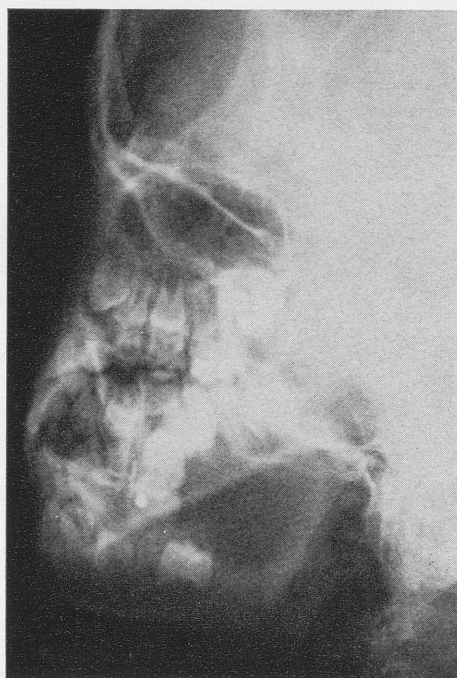


Fig. 6. Circumscribed osteolytic change in mandible; eosinophilic granuloma.

2 x 3 cm irregular mass felt to be in the parotid gland, and small nodes located in the cervical region. The chest x-ray was normal. Examination of parotid tissue removed for biopsy

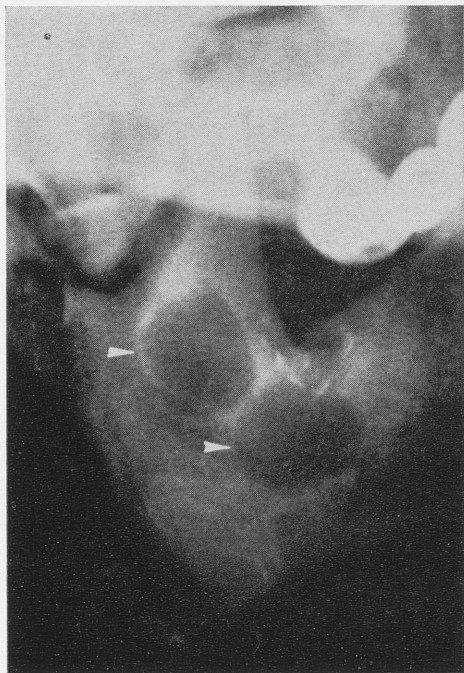


Fig. 7. Bilobed (arrows) osteolytic defect in mandible; infected dentigerous cyst.

showed a caseating granuloma in parotid lymph nodes. Microbacterium tuberculosis was isolated from a culture of the tissue.

Figure 3 is a classic example of bilateral masseter hypertrophy. This patient was being evaluated for joint pain and "bilateral parotid swelling." By inspection however, the masses were anterior to the normal location of the parotid. The tissue lateral to the masseter, judged by bimanual palpation with the masseter contracted, was normal. Radiographs showed "winging" of the mandible, a finding commonly associated with this condition.

A 70-year-old female complained of a painful mass in the lateral facial area. Physical examination indicated that the lesion was medial to the masseter muscle within the mandible. The laminogram (Fig. 4) shows loss of the normal architecture of the ascending ramus and condyle. Tissue taken for biopsy showed metastatic adenocarcinoma.

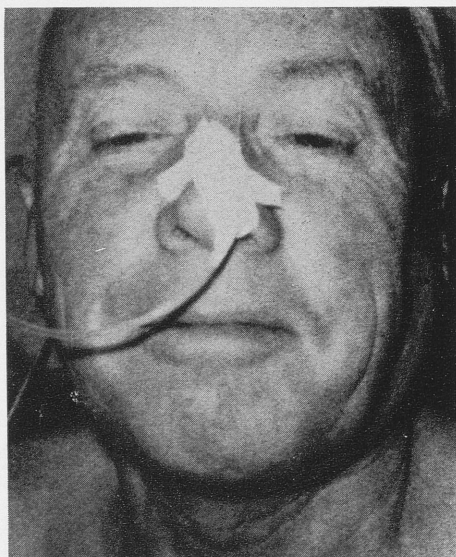


Fig. 8. Neurilemoma of parapharyngeal space on the left.

Figure 5 illustrates a 7-year-old boy who was thought to have mumps. When the facial swelling failed to resolve, a parotid sialogram was done and interpreted as "normal." The boy was referred as an example of parotid enlargement of uncertain etiology. Inspection revealed that the mass was anterior to the parotid and, by palpation, medial to the masseter. A radiograph (Fig. 6) of the mandible showed a large lytic lesion. Tissue for biopsy taken from this mass was characteristic of an eosinophilic granuloma.

Review of radiographs done one year before his admission showed a previously overlooked lytic lesion of the greater trochanter of the left femur. Follow-up films demonstrated spontaneous reossification of this area. He later developed an area of involvement in the skull. Both skull and mandibular lesions completely regressed after radiation therapy. He has developed no signs or symptoms of systemic histiocytosis three years after his last treatment.

A 30-year-old oriental female presented with a painful, diffuse, lateral facial swelling and trismus. The swell-

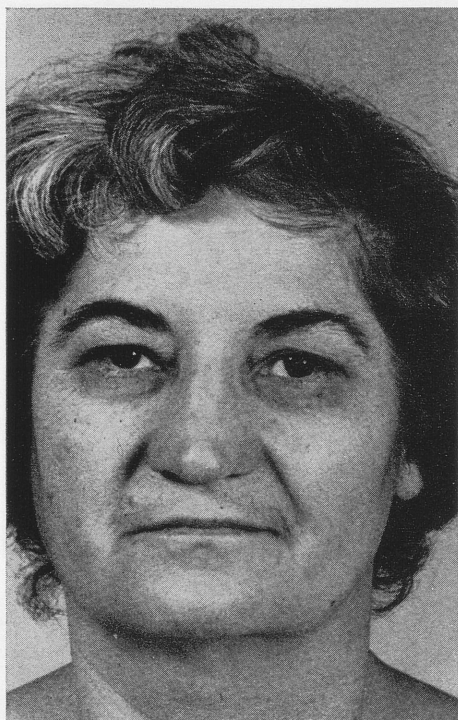

Fig. 9. Osteochondroma of cervical spine.

ing was centered anterior to the normal distribution of the parotid and seemed to be medial to the masseter muscle. We felt that this was a tumor, probably malignant, of the mandible. A radiograph (Fig. 7) showed a bilobed lytic defect which proved to be an infected dentigerous cyst.

Figure 8 illustrates that because of lateral facial swelling, this patient had had tissue taken for biopsy from the parotid gland. This examination, done two years prior to his evaluation at Henry Ford Hospital, showed no pathology. At the time of his admission he complained of swelling in the oral cavity as well. Examination showed a large mass causing medial displacement of the tonsil and deformity of the soft palate. The carotid artery pulsation could be identified anterior to this mass. There was atrophy and fasciculation of the left side of the tongue, and diffuse swelling of the parotid area. A 4 x 6

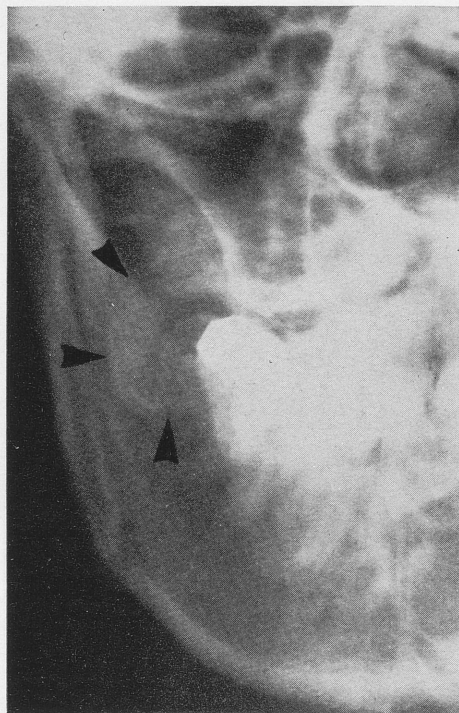


Fig. 10. Osteochondroma (arrows) originating from C₁ and C₂.

cm neurilemoma was removed from the parapharyngeal space by an external approach. This tumor originated from the vagus nerve and the partial paralysis of the tongue was caused by stretching of the XII nerve over the mass.

A 42-year-old female complained of right facial swelling progressing slowly over a two year period (Fig. 9). By inspection, the swelling was very diffuse, but examination of the angle of the pharynx on the right revealed a bony, hard projection. Radiographs (Fig. 10) showed a calcified mass originating from the lateral processes of the first two cervical vertebrae. The mass was incompletely removed for biopsy through a neck incision. The histological appearance was characteristic of osteochondroma.

CONCLUSION

Lateral facial swelling can be caused by a variety of pathological conditions

involving many structures of the head and neck. A complete and systematic patient evaluation, with emphasis on the physical examination, will result in more accurate diagnoses and expeditious treatment.

HENRY FORD HOSPITAL, DETROIT, MICH. 48202

EXTERNAL TRAUMA OF THE LARYNX AND TRACHEA

IMMEDIATE TREATMENT AND MANAGEMENT

CLAUDE L. PENNINGTON, M.D.

MACON, GEORGIA

In the past decade the use of seatbelts has significantly reduced mortality in automobile accidents, but paradoxically this has resulted in a greater number of survivors with laryngotracheal injury. Evidence of this increase is substantiated by a number of significant contributions to the literature on this subject during this period.¹⁻¹¹ This report is a summation of my own experience with 22 such patients who required open surgical treatment of their injury (Table I).

The spectrum of severity of this injury extends from mild to severe, characterized clinically by symptoms ranging from hoarseness to severe airway

obstruction. The primary examiner should determine his patient's position in this spectrum and proceed with treatment accordingly. Obvious respiratory embarrassment dictates an immediate tracheotomy. After tracheotomy is performed, the possibility of neurological, abdominal, thoracic and orthopedic problems should be considered. Other immediate problems such as blood loss should be treated and, as soon as the patient is out of danger, the extent of the laryngeal injury should be ascertained.

The single best means of evaluation is the mirror examination of the larynx, if this is possible. I have found x-rays

TABLE I
SITES AND PREVALENCE OF LARYNGEAL INJURY
IN ORDER OF FREQUENCY IN 22 PATIENTS WHO
WERE TREATED BY OPEN REPAIR

	No. Cases	%
Vertical midline fracture of the thyroid cartilage	18	81
Posterior displacement of the base of the epiglottis and rupture of the thyroepiglottic ligament	11	50
Severe tears and abrasions of the mucosal surfaces of the ventricular folds and true cords	10	45
Separation of the vocal ligaments and thyroarytenoid muscular attachments	6	27
Laryngotracheal separation and recurrent laryngeal nerve damage	4	18
Pyriiform sinus and cervical esophageal tears	3	13
Gross arytenoid disruption	2	9

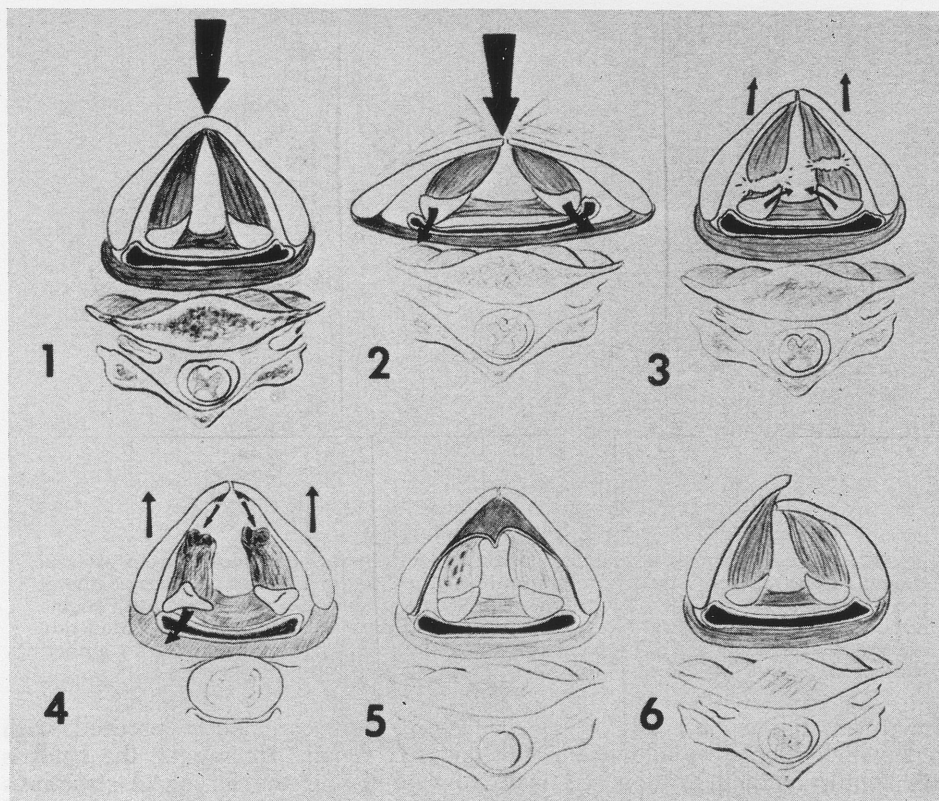


Fig. 1. Biodynamics of laryngeal injury at the transglottic level. 1) Direction of antero-posterior force to produce injury. 2) Thyroid cartilage crushed against cervical vertebra. Arytenoids displaced posteriorly. 3) Thyroid cartilage rebounds and thyroarytenoid tears occur posteriorly. 4) Separation of thyroarytenoid muscles and vocal ligaments anteriorly. 5) Internal thyroid cartilage perichondrium separated anteriorly. Interstitial hemorrhage of left thyroarytenoid muscle. 6) Thyroid cartilage overlap narrowing transglottic lumen.

to be of limited value in the assay of the acute injury to the larynx, but examination of the cervical spine is very important. If the patient will tolerate palpation of the thyroid cartilage, this should be done. The presence of a palpable fracture, inability to discern the thyroid notch and subcutaneous emphysema are ominous signs of severe injury in most instances and indicate the need for open repair. If indirect laryngoscopy is not possible, direct laryngoscopy under anesthesia using the tracheotomy tube as a port for anesthesia should be performed. Direct laryngoscopy and repair should either be performed immediately, within the first two to three hours after injury, or delayed for three to five

days, for edema and hematoma in the intervening period make accurate tissue identification and repair very difficult. Little is to be gained by endoscopic incision and drainage of isolated minimal intracordal hematomas. A thyroid cartilage fracture without displacement, which on laryngeal examination shows good cord movement, minimal intracordal hemorrhage and edema, can be managed by voice rest, corticosteroid therapy, and antibiotics. Large bilateral intracordal and ventricular hematomas with excessive abrasion of the ventricular folds, cords and epiglottis, but without other injury, may require placement of an endolaryngeal splint using a piece of Portex endotracheal tube or a pre-

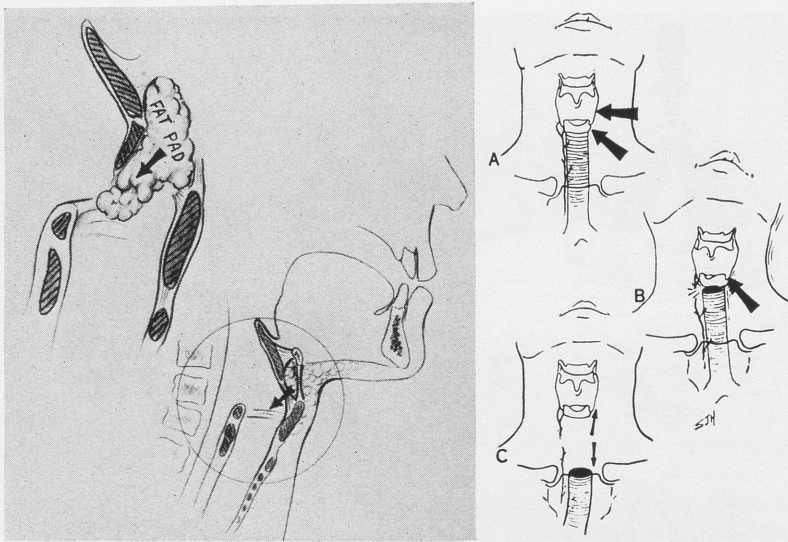


Fig. 2. Biodynamics of common supraglottic and subglottic injuries from external trauma. Left: antero-posterior force ruptures thyroepiglottic ligament. Adipose tissue of preepiglottic space and the base of the epiglottis are pushed into anterior glottis. Right: A) Either anterior or lateral blows may produce cricotracheal separation; B) Moderate cricotracheal separation; C) Typical extent of cricotracheal separation as seen by author. Note nerve injury.

formed silastic or acrylic laryngeal mold, which should be allowed to remain until epithelialization is well underway. At direct laryngoscopy, the findings of grossly disrupted ventricular folds, arytenoids, posterior displacement of the base of the epiglottis, or exposed cartilage make open repair of the injury mandatory.

BIODYNAMICS OF LARYNGEAL INJURY FROM EXTERNAL TRAUMA

When the interior of the larynx is exposed through the anterior thyrotomy approach in the repair of the acute laryngeal crush injury, the surgeon may encounter a confusing and bewildering array of hemorrhagic, edematous, distorted tissues. A better understanding of the injury is possible by visualizing the sequence of events, or injury mechanism, which seems to occur consistently and which results in anatomical distortions which are obvious to the discerning eye even in the presence of swollen and disorganized tissue. By anticipating these specific injuries to laryngeal tissues, the surgeon can quickly orient himself in the injured

larynx and confidently proceed with orderly repair. At impact, the head is extended and the laryngeal structures are exposed and fixed upon the cervical vertebrae. With high anterior-posterior blows, the "hammer and anvil" effect occurs as the thyroid and cricoid cartilages are crushed against the cervical vertebrae posteriorly (Fig. 1). A mid-line vertical thyroid fracture is almost invariably present. Lateral fractures of either alae are less common. Cartilage in the midline and around the notch is most commonly pulverized. The thyroarytenoid musculature may be separated at any point along its length producing tears in the cords and ventricular bands, as well as the aryepiglottic folds. Frequently thyroarytenoid ligaments at the macula flava anterior are separated from the thyroid cartilage. Infrequently the arytenoids may be displaced posteriorly and laterally or into the glottis. Pyriform sinus and upper cervical esophageal lacerations are not unusual. Interstitial hemorrhage into the internal laryngeal musculature and gross hemorrhage into the laryngeal compartments are frequent. During the splaying ac-

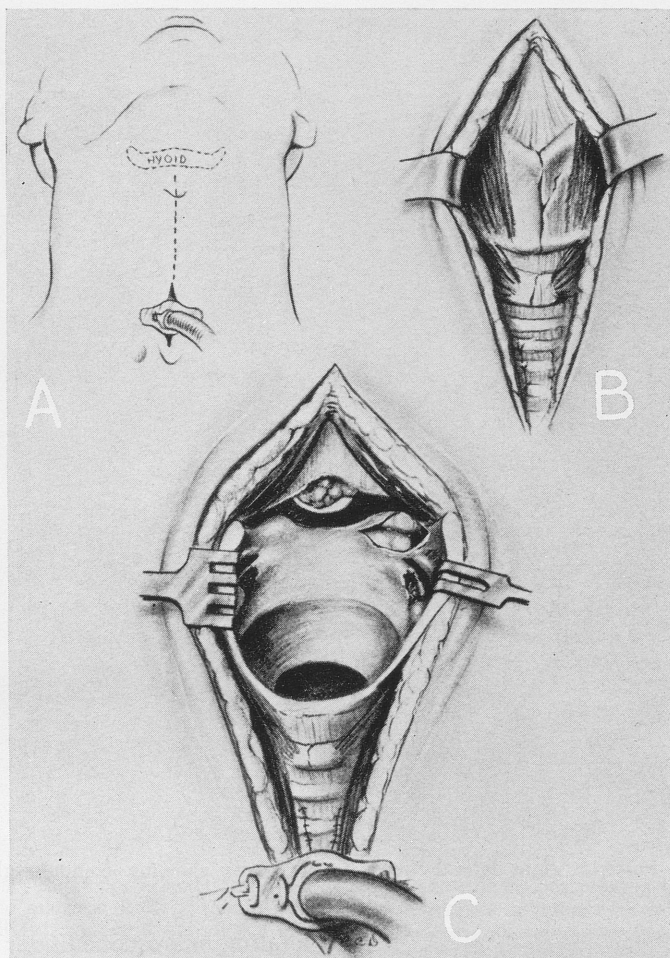


Fig. 3. Open repair of laryngeal injury. A) Midline incision. B) Entrance through fracture site often possible. C) Interior of larynx showing displaced epiglottis and pre-epiglottic adipose tissue, arytenoid displacement and cordal tears.

tion of the thyroid cartilages, the internal perichondrium may occasionally be "peeled" from the inner surface of the thyroid cartilage. When the cartilage springs back, one segment of it may not return to its normal position thereby encroaching on the transglottic laryngeal space. Most common of injuries is rupture of the thyroepiglottic ligament with herniation of dense areolar and adipose tissue of the pre-epiglottic space into the laryngeal lumen accompanied by posterior displacement of the base of the epiglottis (Fig. 2).¹² Lower anterior-posterior blows will produce cricoid fractures,

as well as laryngotracheal separation which is usually attended by bilateral recurrent laryngeal nerve injury (Fig. 2).^{13,14}

TECHNIQUE OF OPEN SURGICAL REPAIR

A vertical incision gives one an uncompromised view of the surgical field from the hyoid bone to the sternal notch. The larynx is easily opened since the fracture is usually, though not always, near the midline (Fig. 3). Adequate time should be spent to study and then surgically align the tissues in the glottic and supraglottic levels properly. At this time, the use of a binocular

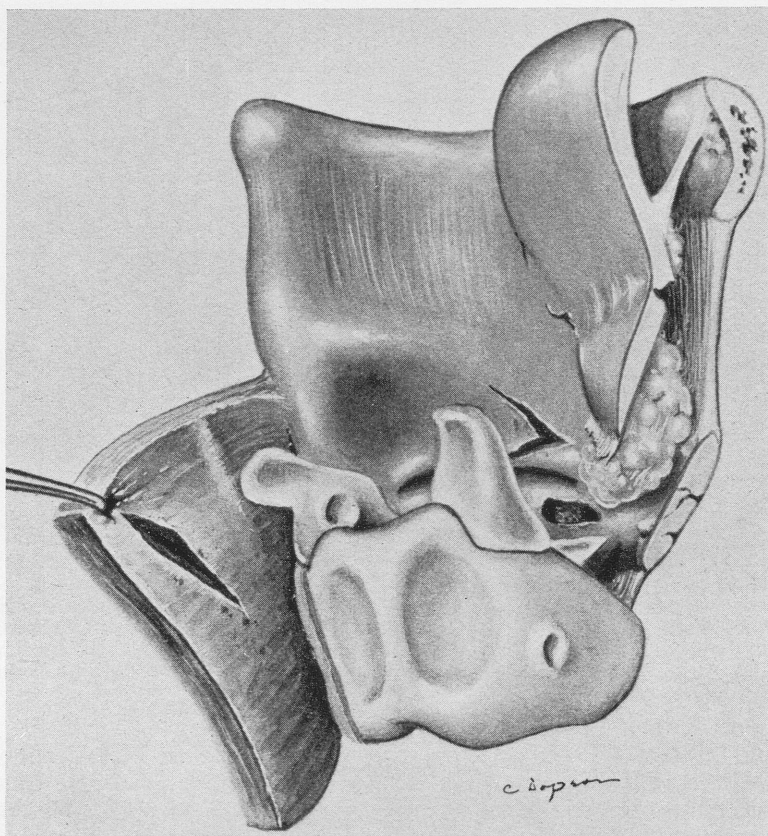
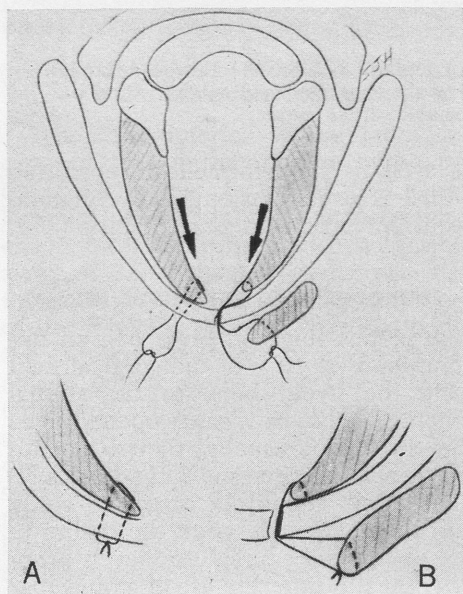


Fig. 4. Posterior right lateral view of the larynx showing common glottic and supraglottic injuries.



operating microscope under six magnifications will greatly facilitate examination and repair. Long, delicate, toothed neurological tissue forceps are useful in handling the tissue fragments (Fig. 4).

Repairs of tears in the pyriform sinuses and cervical esophagus should be made first. The inferior thyroarytenoid ligament attachments are next identified and if torn, they are repaired by passing a suture through the anterior aspect of the vocal ligament, or macula flava anterior. The suture is brought through the fracture if it is close to the

Fig. 5. Placement of sutures in thyroarytenoid musculature and vocal ligaments to correct an anterior separation of these structures. A) Fixation suture through the thyroid cartilage. B) Fixation suture through fracture site to external laryngeal structures.

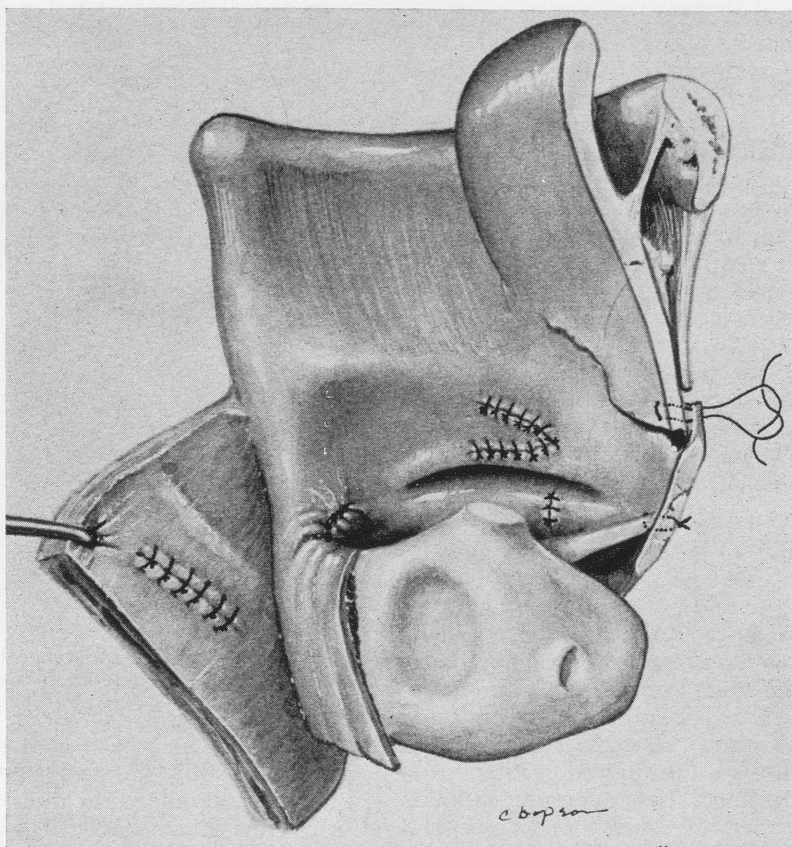


Fig. 6. Right posterior lateral view of larynx showing reconstruction of glottic and supraglottic injuries. Left arytenoid removed, joint surface covered with pyriform sinus mucosa. Right arytenoid not shown to allow better view of remaining laryngeal structures.

midline and attached to an extra laryngeal structure such as the thyroid cartilage or adjacent external laryngeal musculature.

If a lateral fracture of the thyroid cartilage is present, a suture through the cartilage, to fix the vocal ligament at the appropriate level anteriorly, should be placed. It is important to establish the position of the vocal ligaments anteriorly, since it reestablishes the proper relationship of the remainder of the thyroarytenoid musculature. Tears in the middle and posterior third of the thyroarytenoid musculature are then repaired with 3-0 Chromic sutures on a small curved atraumatic needle (Fig. 5).

Evaluation of arytenoid function immediately after injury is extremely difficult, since inadequate function may be secondary to local nerve and muscular injury from contusions, as well as from hematoma and effusion within the cricoarytenoid joint. If almost total arytenoid disruption is present, it would be best to remove it. However, if the arytenoid is only partially disrupted, replacement in its normal position on the convex cricoarytenoid joint surface by suturing the mucoperichondrial tears under the operating microscope would seem best, for midline cord fixation on that side would be a good condition if unilateral cord paresis were present on the same side. If both arytenoids are damaged, meticulous repair using the

magnification of the binocular operating microscope would be better than immediate removal. A secondary arytenoidectomy by the external approach for airway may be performed at a later date without difficulty if necessary.¹⁵ Large posterior intraluminal cricoid subglottic lacerations and abrasions and arytenoidal avulsions can be managed by primary closure using pyriform sinus mucosa, which can be dissected from the posterior aspect of the cricoid and pulled over bare cartilage and sutured with 3-0 Chromic suture.¹⁶ Skin grafts have not been necessary in this series of patients since primary mucosal closure of all major defects was possible through the techniques outlined above (Fig. 6).

The use of a preformed laryngeal splint to hold the internal laryngeal musculature and perichondrium against the inner surface of thyroid cartilage, and to maintain separation of abraded ventricular folds and epiglottic surfaces is desirable.¹⁷ The splint is held in place by an 18 gauge stainless steel suture passed through the thyroid cartilage to the skin surface. Less adequate splints in this order are Portex endotracheal tube of proper size or a finger cot filled with sponge.

After insertion of the mold, adipose tissue at the base of the epiglottis is trimmed away and the base itself may be partially amputated if necessary. It is then retracted inferiorly and sutured to the external perichondrium of the superior border of the thyroid cartilage, or to the lower border of the incised thyrohyoid membrane using 3-0 Chromic suture (Fig. 7). Thyroid cartilage perichondrium and extra laryngeal muscles are sutured to hold the thyroid cartilage fracture in alignment; however, if the perichondrium has been avulsed or grossly disrupted and the cartilage fragments will not remain in proper position, multiple fine sutures of #32 stainless steel wire may be used. If thyroid cartilage anteriorly is inadequate due to pulverization, Looper's technique using a graft of hyoid bone placed between the thyroid alae and

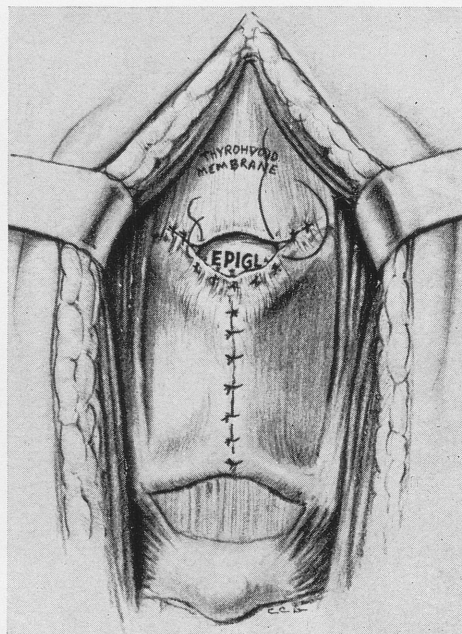


Fig. 7. Surgical view of laryngeal closure. Base of epiglottis sutured to thyrohyoid membrane or external laryngeal perichondrium.

sutured with #32 stainless steel wire will maintain an adequate anterior-posterior glottic dimension.¹⁸ The lumen of the subglottic larynx is inspected for fracture and mucosal tears. Multiple cricoid fractures are uncommon. They should be repaired with #32 stainless steel wire. Mucosal tears in the cricoid region should be carefully approximated with 3-0 Chromic suture, and an intraluminal Portex endotracheal tube splint of proper size should be placed.

Cricotracheal separation has accounted for 18% of open repairs in this series. To aid in approximation of larynx and trachea, traction sutures are placed around the cricothyroid musculature and sutured inferiorly to the lateral neck musculature, while similar sutures are placed on the trachea below and tied superiorly. The mucosa is closed from within posteriorly, and the tracheal perichondrium from without anteriorly using 3-0 Chromic sutures (Fig. 8). A splint of Portex endotracheal tube in the adult is optional, but it is definitely indicated in children because of the

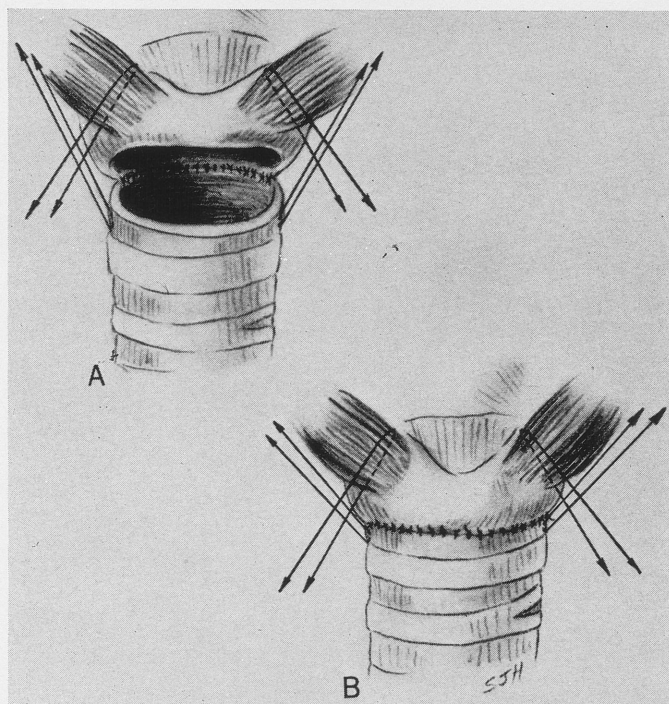


Fig. 8. A) Repair of cricotracheal separation. Traction sutures of heavy silk relieve tension in closure. Mucosal closure posteriorly and internally. B) Perichondrial closure of defect anteriorly.

smaller tracheal cross section. A piece of 18 gauge surgical wire passed through the tracheal walls and splint and brought out laterally to the skin surface will allow endoscopic removal of this splint.^{13,14} Severe tracheal cartilage damage is uncommon, but when encountered may be managed by resection of one or two tracheal rings and reanastomosis because of the elasticity of the trachea.¹⁴ The possibility of recurrent laryngeal nerve injury and its repair should be considered in every case of laryngotracheal separation. In the acute injury it is also possible that in working in edematous and hemorrhagic tissues additional damage to an intact nerve rendered temporarily nonfunctional by contusion, but not separated, might occur. I have never been able to identify the exact site of injury in any patient in this report.

POSTOPERATIVE MANAGEMENT

Timing of the removal of the splint is important. If adequate closure of

mucosal surfaces has been achieved, as little as ten days to two weeks of splint wear is necessary; but if severe abrasion and edema are present, a period of two to four weeks may be indicated. Frequent mirror observations will aid in timing of splint removal. Feeding is accomplished through a nasogastric tube placed at the time of surgery. Broad spectrum antibiotics and corticosteroids have been routinely given before and after surgery. These drugs seem to reduce the incidence of infection and granulation tissue and to hasten the resolution of interstitial edema and hemorrhage.

The use of Oral Zinc Sulfate, three times a day, has recently been advocated, since zinc deficiency after severe injury may be a cause of delayed healing, but this was not given to any patient in this report.¹⁹

POSTOPERATIVE LARYNGEAL FUNCTION

In the supraglottic and transglottic injury, immediate repair in 18 cases has

resulted in a good airway, adequate airway protection and a very satisfactory voice in all. One patient in this group developed a small mucous cyst in the vallecula after surgery, but her voice and airway are normal. Four persons with cricotracheal injury in this series had bilateral recurrent nerve injury. After repair, all four had a good airway, fair airway protection, but a very poor voice. One of these patients regained bilateral adductor function 18 months following surgery necessitating an ary-

tenoidectomy for airway improvement.

CONCLUSION

Laryngeal crush injuries have a predictable injury mechanism and pattern of injury, the knowledge of which aids in an orderly repair by the surgeon.

Open repair of the larynx within eight days in severe crush injury allows microscopically accurate anatomic reconstruction of the larynx with maximum preservation of laryngeal functions.

800 FIRST STREET, MACON, GA. 31201

REFERENCES

1. Fitz-Hugh GS, Wallenborn WM, McGovern FH: Injuries of the larynx and cervical trachea. *Ann Otol* 71: 419, 1962
2. Fitz-hugh GS: Instruction Course #445 in laryngeal Trauma. AAOO, Chicago, 1966
3. Harris HH, Ainsworth JZ: Immediate management of laryngeal and tracheal injuries. *Laryngoscope* 75: 533-569, 1965
4. Harris HH, Tobin HA: Acute injuries of the larynx and trachea in 49 patients (observations over a 15 year period). *Laryngoscope* 80: 1376-1384, 1970
5. Holinger PH, Schild JA, Mauriel DG: Internal and external trauma to the larynx, *Laryngoscope* 78: 944-954, 1968
6. Knight JS: Laryngeal stenosis. *Laryngoscope* 74: 564, 1964
7. Miles WK, Olson NR, Rodriguez: Acute treatment of experimental laryngeal fractures. *Trans Amer Laryng Assn* 92: 104-116, 1971
8. Ogura JH, Biller HF: Reconstruction of the larynx following blunt trauma. *Trans Amer BronchoEsoph Assn*, 1971, p. 74-88
9. Ogura JH, Powers WE: Functional restitution of traumatic stenosis of the larynx and pharynx. *Laryngoscope* 74: 1081-1110, 1964
10. Ogura JH, Roper CL: Surgical correction of traumatic stenosis of larynx and pharynx. *Laryngoscope* 72: 468, 1962
11. Olson NR, Miles WK: Treatment of acute blunt laryngeal injuries. *Trans Amer Laryng Assn* 92: 98-103, 1971
12. Montgomery WW: The surgical management of supraglottic and subglottic stenosis. *Ann Otol* 77: 534-546, 1968
13. Chodosh PL: Cricoid fracture with tracheal avulsion. *Arch Otolaryng* 87: 461-466, 1968
14. Dallas WM Jr: Rupture separation of the cervical trachea as a result of blunt trauma. *Amer Surg* 29: 529-531, 1969
15. Woodman D: A modification of the extralaryngeal approach to arytenoidectomy for bilateral abductor paralysis. *Arch Otolaryng* 43: 63-65, 1946
16. Dedo HH, Sooy A: Surgical repair of late glottic stenoses. *Ann Otol* 77: 435-441, 1968
17. Pennington CL: Glottic and supraglottic laryngeal injury and stenosis from external trauma. *Laryngoscope* 74: 317-345, 1964
18. Looper EA: Use of hyoid bone as a graft in laryngeal stenoses. *Arch Otolaryng* 28: 106-111, 1938
19. Pullen F, Smith LA: Scientific Exhibits S-16, Laryngotracheal Trauma. AAOO, Las Vegas, Nevada, October, 1970

DISCUSSION

HERBERT HARRIS, M.D.: I do not think that I have anything to add to Dr. Pennington's paper. Within a very few minutes he has demonstrated to us a great deal of ability and information in the management of laryngeal and tracheal injuries. I do feel that we are in perfect agreement on the management of this problem. I have no comments to make except to praise him for his very outstanding work in this area of trauma.

JOHN A. KIRCHNER, M.D.: I would like to add my word of commendation to Dr. Pennington's presentation. I think it was beautifully documented, but I think a couple of points he brought out are worth emphasizing. One is the meticulous repair of soft tissues that he showed so nicely. It is so important, to get the framework covered with soft tissue as well as the early repair, of course.

I wanted to ask him two questions. Do these preformed splints come in standard sizes or do they have to be whittled and shaped? Are they silastic or what? Secondly, I should like to ask him if he is still satisfied with a vertical incision in the midline of the neck? I have always felt, that except for an emergency tracheotomy, there is really very rarely an indication for a vertical incision in the neck. Once you clear the platysma, the field is the same with a horizontal incision as it is with a vertical and you certainly get a lot less scar contracture.

JOHN BALLENGER, M.D.: Dr. Kirchner has already asked my question. I enjoyed Dr. Pennington's paper, but I'm interested in how he is splinting, not only those within the larynx but those that are in the trachea itself. Is a portex tube sufficient? How snugly does that fit in, and is there any pneumoinflation (inflated cuff) or not? Does he leave the portex tube in? I assume he takes it out.

DOUGLAS P. BRYCE, M.D.: Mr. Chairman, I wish to congratulate Dr. Pennington on his paper. I was a little late in coming in to the meeting and I am not sure whether he gave the absolute indications which would lead to an open reduction of a laryngeal injury.

In my experience, the decision to carry out an open reduction may be very difficult in some cases. I would appreciate his comments.

JOSEPH OGURA, M.D.: I want to congratulate Dr. Pennington. Mr. Chairman, this is an excellent paper. I, too, got in late and I wonder if you would comment on the timing, when you consider this should be opened. You didn't mention anything about your 22 cases. What, for example, was the longest time that you still consider an acute fracture? And, the second question I would like to ask, what do you do when you have concomitant infection, the acute infection that comes into you several days late, acute?

CLAUDE L. PENNINGTON, M.D. (closing): I would like to thank Dr. Harris and the other discussants for their comments. In regard to Dr. Kirchner's questions about splints: the splint that I have used is an acrylic one that was made by taking an impression from cadaver larynges and from several larynges during thyrotomy. I realize that this is a splint that is reproduced from a nonpathological larynx, but in an emergency it is better than nothing at all. I believe that it is better than taking an impression from the injured larynx because then you are reproducing the laryngeal defect itself in the splint. I have tried both methods and I feel that a prefabricated acrylic splint made by a dental technician is the best. I have made four sizes that range from the infant larynx to the adult male larynx. In my earlier injury cases I used the horizontal incision because this was more cosmetic, but I found myself in difficulty in a number of these cases, particularly in the ones that you

would most like to do the cosmetic horizontal incision upon, that is, the young adult female who has a long neck. Unfortunately these are the people that commonly get the severest injuries. You may assume that the location of the injury is limited to the supraglottic area, but find that it involves lower structures also. You may then find yourself using multiple "ladder" incisions to completely care for the injury. If a hyoid bone graft is necessary, it is very difficult to make an incision in some necks over the midportion of the thyroid cartilage and take the hyoid graft without difficulty. For that reason, I have gone back to the vertical incision where the entire laryngo-tracheal complex can easily be inspected for injury. I would rather have a good voice and a good airway than a good scar.

Dr. Ballenger asked about the size of the endotracheal tube used in the subglottic injury. I do not place a tube that is snug, but rather one that is small enough to be removed by direct laryngoscopy at a later date. It is held in place by a piece of surgical steel wire, which is passed through the adjacent soft tissues so that the splint moves with the area that is splinted rather than being attached at some distance, which results in a sliding motion of the splint within the tracheal complex. This results in additional injury which may cause additional scarring and unnecessary additional contracture. I believe that a tube in the subglottic injury minimizes contracture, but I would not put in a splint so large that it would be difficult to remove by direct laryngoscopy.

To Dr. Bryce's question about indications: I thought I covered it as well as I could in a ten minute presentation in the first three minutes of the talk, but to reiterate the indications for open repair, they are: palpable thyroid fractures, inability to discern the thyroid notch, subcutaneous emphysema, hemorrhage and, at direct laryngoscopy, evulsion and/or exposure of cartilages and ventricular folds. The presence of large amounts of raw tissue in the laryngeal lumen would certainly indicate open exploration in my opinion.

In response to Dr. Ogura's questions: as far as the timing of the procedure is concerned, obviously the sooner it is done the better (with certain reservations). The earliest I have done one is within one to two hours after the injury.

I live in a city on a large interstate highway. I think this accounts for the number of people that I have seen shortly after this injury. The highway was not connected above or below the city for about ten years and it was necessary for the traffic to bypass on a country road. I think the mentality of changing from a four lane highway perhaps accounted for a large number of these injuries. The sooner the repair is done the better (up to five hours). After this period, just as in a nasal fracture or other facial injury, it may be best to wait five

to six days before attempting reconstruction because of rapidly ensuing edema, hemorrhage and distortion. I have not had a patient with late injury and acute infection of any severity that required more than routine antibiotics. Most injuries seen late, say at 12 to 14 days, have been covered with antibiotics for other multiple injuries from the onset of injury. This perhaps minimized the infection in this series.

I do not have an exact idea of when you would classify these injuries as acute, subacute, or chronic, but I would consider an injury of 10 to 12 days duration as an acute injury. After that, you are dealing with tissue distortion from healing and I would consider them subacute or chronic at that point. Certainly the repair of an injured larynx after 10 or 12 days is much more difficult and really is an entirely different problem.

TREATMENT OF VOCAL CORD CARCINOMA BY VERTICAL HEMILARYNGECTOMY

JAMES R. LEONARD, M.D.

GORDON P. HOLT, M.D.

PHILADELPHIA, PENNSYLVANIA

ARNOLD G. MARAN, M.D.

DUNDEE, SCOTLAND

Vertical hemilaryngectomy for selected patients of carcinoma of the vocal cord is a well recognized form of treatment. A little more than one-half of the larynx can be resected in a vertical direction with preservation of the respiratory, phonatory, and sphincteric functions of the larynx.

The purpose of this report is to present our clinical experience over an eight year period, 1963 to 1970 inclusive. We shall review 75 cases from the authors' personal experiences in which we try to document patient selection, surgical technique, and long-term results in terms of survival and function.

The historical development of partial laryngectomy and the technical aspects of vertical hemilaryngectomy have been well documented by many authors¹⁻³ and will not be repeated here. Bailey³ in a recent article, particularly covers these aspects well.

CASE SELECTION AND CRITERIA

Success in curing cancer by partial laryngectomy depends upon very accurate anatomical localization of the neoplasm and any metastasis, meticulous technique in removal of the affected portion of the larynx and metastasis, sometimes reconstruction of the excised area, and careful patient selec-

tion to insure toleration of the surgical procedure.

Localization of the carcinoma depends upon careful history, indirect examination of the larynx and hypopharynx, laryngography (air contrast, positive contrast, or tomography), and direct laryngoscopy and biopsy. Except for subglottic extension, the laryngologist should be able to accurately evaluate a vocal cord lesion by indirect and direct laryngoscopy.

While evaluating a patient and confirming the diagnosis of carcinoma, the physician is obligated to assess the total patient to ascertain that he can withstand the impending treatment. Following any form of partial laryngectomy, there is the possibility of aspiration which may result in injury to the cardiac and pulmonary systems, and therefore, these two organ systems must be evaluated before treatment. Particularly important is the ability of the lungs to withstand small amounts of aspiration until adequate deglutition can be re-established. We regard no specific age with good cardiac and pulmonary function, and therefore, pay little attention to a patient's age as long as the heart and lungs are healthy. The criterion for hemilaryngectomy in our clinic (during the years studied) is the presence of a malignant neoplasm (usually squamous

From the Department of Otolaryngology and Maxillofacial Surgery, Jefferson Medical College, Philadelphia, Pa., and the Dundee Royal Infirmary, Dundee, Scotland.

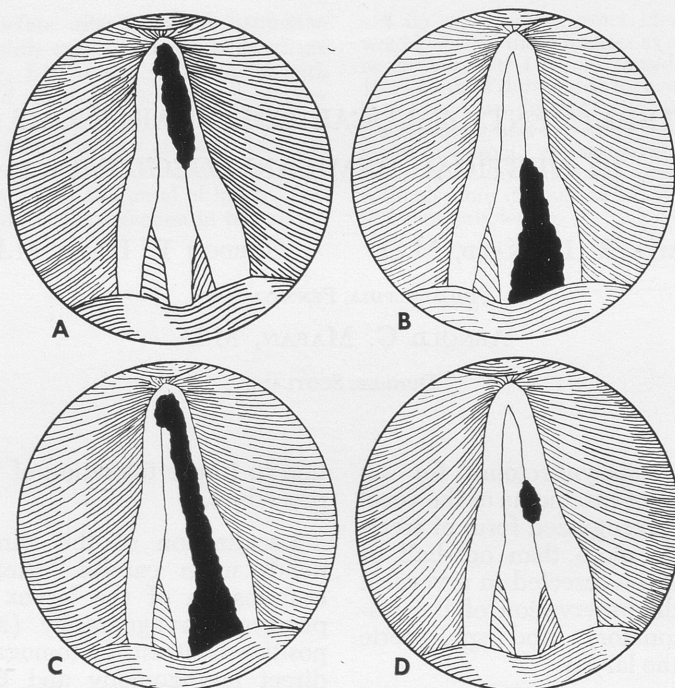


Fig. 1. A) Artist's drawing of Ca. of right vocal cord, extending to anterior commissure. B) Ca. right vocal cord extending to vocal process of arytenoid. C) Ca. right vocal cord involving anterior commissure and arytenoid. D) Small Ca. of right vocal cord, easily cured by radiation therapy.

carcinoma) on the true vocal cord that involves either the anterior commissure and/or the vocal process of the arytenoid. The mobility of the cord must be normal (or perhaps just slightly reduced, and further comment will be made on this point) (Fig 1A, B and C). Vocal cord carcinoma that does not involve the anterior commissure or the vocal process (potential cartilaginous involvement) is treated by radiation therapy (Fig. 1D). We have considered carcinoma of the vocal cord with complete fixation of the cord as an indication for total laryngectomy.

Although we consider for partial laryngectomy of one type or another, many other patients with carcinoma of the supraglottic larynx, the aryepiglottic fold, superior surface of the arytenoid, and others, the purpose of this presentation is to review only those involving the true vocal cord with extension to

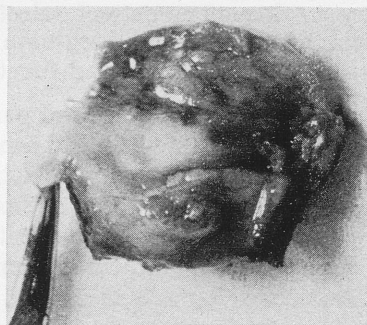


Fig. 2. Typical hemilaryngectomy specimen. Clamp at anterior end. Ca. right vocal cord extending to vocal process.

either the anterior commissure or vocal process, or both.

METHOD OF STUDY

We selected 75 patients with carcinoma of the vocal cord that met the criteria, and in which complete follow-up data was available. All patients were treated by the authors at University

Hospitals, Iowa City, Iowa, Thomas Jefferson University affiliated hospitals, Philadelphia, Pennsylvania, or at the Royal Infirmary in Dundee, Scotland. All 75 of these patients had a vertical hemilaryngectomy performed in the years 1963 through 1970 (Fig. 2). All patients had a minimum follow-up of one year, and the vast majority were beyond the two year point (Table I).

TABLE I
SUMMARY

Number	Survival			Total
	1 Yr.	2+ Yrs.	5+ Yrs.	
75	6	23	30	59(79%)
	Died with Ca.	Died without Ca.		
	9	7		

It bears repeating, all 75 of these patients were treated with a vertical hemilaryngectomy and met the following criteria: the lesion involved the true vocal cord and had spread to either the anterior commissure or the vocal process of the arytenoid, or both; the vocal cord exhibited normal mobility; the lesion had extended no more than 1 cm below

the medial edge of the vocal cord, and no more than 4 to 5 mm below the medial edge posteriorly (where it overrides the cricoid arch); the lesion had spread to involve no more than one-third of the opposite vocal cord anteriorly.

FINDINGS

Some general comments can be made first in reviewing this group of 75 patients. The age range was from 40 to 81 years with most falling between 50 and 65 years. All of the patients except one were cigarette smokers (most more than one pack per day), and the one non-smoker was a female. The overall ratio of males to females was 12 to 1, but we noticed in the first five years of the study the ratio was 18 to 1, and in the last three years it was 8 to 1. Perhaps this indicates that the disease is increasing in females as they put in longer years of smoking. Hoarseness was invariably present and was usually the presenting symptom. We found hoarseness present anywhere from one to eighteen months prior to a diagnosis being made, with the average about three months.

TABLE II
RECURRENT CARCINOMA FOLLOWING HEMILARYNGECTOMY

Site of Recurrence or second primary	Time Interval after Hemi	Treatment of Recurrence	Follow-up
Larynx	12 Mos.	Tot. laryngectomy	Alive and well at 1 yr.
Larynx	6 Mos.	Tot. laryngectomy	Died in 2 mos. of Ca.
Larynx	18 Mos.	Tot. laryngectomy	Alive and well at 6 mos.
Larynx	4 Yrs.	Irradiation	Died of aortic aneurysm 12 mos. later, free of Ca.
Larynx	14 Mos.	Tot. laryngectomy and radical neck	Died in 5 mos. of lung metas.
Larynx	6 Mos.	None	Died in 6 mos. of Ca.
2nd primary in tonsil	12 Mos.	Irradiation	Died in 4 mos. of Ca.
2nd primary in lung	12 Mos.	Unresectable	Died in 3 mos. of Ca.
Larynx	2-½ Yrs.	Pt. refused further treatment	Died in 1 mo. of Ca.
Larynx	6 Mos.	Pt. refused further treatment	Died in 8 mos. of Ca.
Larynx	7 Mos.	Irradiation (refused tot. laryngectomy)	Died in 11 mos. of Ca.
Larynx	18 Mos.	Irradiation (refused tot. laryngectomy)	Died in 7 mos. of Ca.

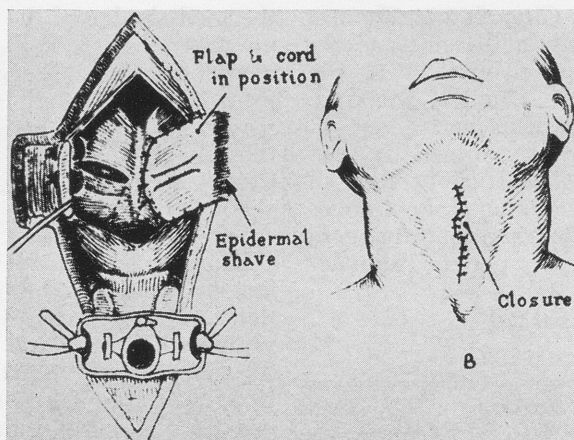


Fig. 3. Reconstruction of a "pseudocord" by skin flap. (With permission of the Publisher)

Sixty-one of seventy-five patients (81%) were alive and well more than one year following hemilaryngectomy. If one disregards the six patients that have only been followed one year, then 55 of 69 patients (79.8%) were alive and well two or more years postoperatively. It is interesting that these figures are almost identical with an earlier report by one of the authors (J.R.L.),² in which the number of patients was approximately one half as many. A typical hemilaryngectomy surgical specimen is shown in Figure 2.

In addition to the simple raw survival data that is available, certain other information is worth examining. In this group of 75 patients, only one was found to have residual disease in the margins of the resected specimen. This one patient was treated with radiation therapy to full tumorocidal dosage and now, one and one-half years after treatment, no evidence of neoplasm is present. Twelve patients that were treated by hemilaryngectomy have developed recurrent disease. Four of these have been treated by total laryngectomy, four by radiation therapy, and four received no additional treatment.

Table II summarizes those 12 patients who developed recurrent (or second primary) carcinoma following hemilaryngectomy. Of the four hemi failures

treated later by radiation, three died of persistent carcinoma within one year, and one died at 12 months of a ruptured aortic aneurysm (free of carcinoma). Of the four hemi failures that were treated subsequently by total laryngectomy, two died of carcinoma within six months, and the other two were alive and well, free of carcinoma, at six and twelve months, respectively (50% salvage rate).

Among the entire group of 75 patients accepted for hemilaryngectomy, seven were recurrent lesions following radiation therapy. Of these seven initial radiation failures who underwent hemi, two developed further recurrence, refused total laryngectomy and died of carcinoma within eight months; seven

TABLE III
DEATHS FOLLOWING
HEMILARYNGECTOMY WITH NO
EVIDENCE OF RECURRENT
CARCINOMA

<i>Time interval after Hemilaryngectomy</i>	<i>Cause of Death</i>
6 Mos.	Myocardial infarction
12 Mos.	Myocardial infarction
6 Wks.	Myocardial infarction
6 Mos.	Congestive heart failure
13 Mos.	Cerebral vascular accident
18 Mos.	Aspiration pneumonia
12 Mos.	Ruptured aortic aneurysm

TABLE IV
RECONSTRUCTION OF LARYNX

	No Reconstruction	Type and Number Bipedicle Muscle	Unipedicle Muscle	Free Muscle
Voice (Survivors only)	34	34	4	3
Good to Excellent	10	27	3	2
Fair	21	7	1	1
Poor	2	0	0	0

patients of the 75 died without clinical or postmortem evidence of carcinoma (Table III).

During the latter half of the time period covered by this study we were a little more finite in our surgical technique. For example, when the lesion involved only the anterior part of the cords including the anterior commissure (did not extend to the vocal process of the arytenoid) the arytenoid was not removed. Of our last 38 cases, 18 have been anteriorly placed lesions and in only six of those was the arytenoid removed. It was probably unnecessary in those few. Twelve cases had posteriorly placed lesions and in all 12 cases the arytenoid was removed. Eight patients had lesions that involved both the anterior commissure and the vocal process and in all eight the arytenoid was removed.

One of the authors (JRL)⁴ has studied radiographically the incidence and degree of postoperative aspiration after various partial laryngectomy procedures. While it is generally not a major problem following hemilaryngectomy, in the debilitated patient with poor reflexes and unhealthy lungs, this can be a hazard. We believe that in all instances when the arytenoid cartilage is removed, some attempt at reconstruction should be made. In Table IV we have assessed the voice function in the surviving patients. By and large when the voice is good, there is little or no aspiration, and when the voice is poor, there is greater risk of the patient aspirating (especially clear liquids).

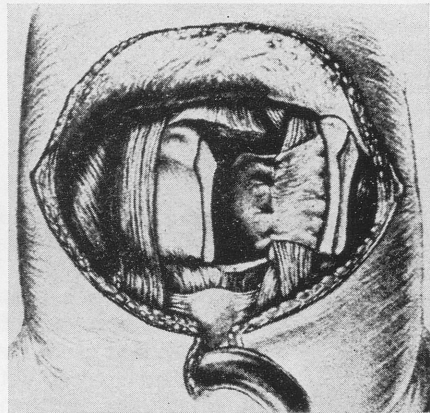


Fig. 4. Bipedicle muscle flap as proposed by Pressman and Bailey. (With permission)

Most of the patients with no reconstruction were in the early part of the study and during the latter years only those patients that did not have the arytenoid removed did not undergo reconstructive procedures. Reconstructive techniques have been presented by Conley⁵ (Fig. 3), Pressman,⁶ Bailey⁷ (Fig. 4), Ogura and Dedo⁸ (Fig. 5), Maran et al.⁹ (Fig. 6), Ogura and Biller¹⁰ (Fig. 7), Quinn¹¹ (Fig. 8C and D), and others.

As can be seen in Table IV our experience has mostly involved using the bipedicle muscle transposition, but we do believe that the unipedicle muscle and free muscle grafts may be as effective or better. Some form of pedicle muscle would seem to be superior to

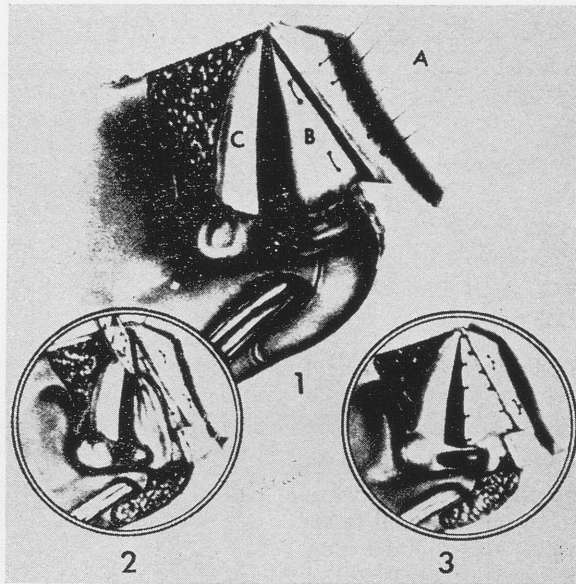


Fig. 5. Pseudocord constructed from thyroid cartilage and covered with mucosa from pyriform sinus. (With permission of the Publisher)

free muscle graft except that when one pedicles the muscle it makes air tight closure more difficult. When used, free muscle should certainly be covered with mucosa either by advancing pyriform sinus or by free mucosa graft. Biller¹² has recently suggested the use of the tendonous portion, pedicled, of the omohyoid muscle. This idea is appealing to us.

DISCUSSION AND CONCLUSIONS

Ideally, one would like to compare the results of treating carcinoma of vocal cord as presented in this work with treatment of the same type lesions by other modalities. There are no significant series available in recent years in which total laryngectomy has been performed on a large number of patients like these, as most laryngeal surgeons do not perform that extensive surgery for these limited lesions. Therefore, valid comparisons cannot be made. The authors have made several attempts in recent years to find comparable series in which patients were treated with radiation therapy, but one simply cannot find significantly large series in which the anatomic location is suffi-

ciently documented to make valid comparisons. However, despite these limitations, we will try to make some comparisons.

While we do not agree with some radiotherapists that radiation therapy is particularly innocuous, it can be clearly stated that if comparable results could be had with radiation therapy that would probably be the treatment of choice. Certainly the patient is spared an operation, the voice is better, and the anatomy looks essentially the same in posttreatment follow-up. However, some patients are reluctant to spend six weeks receiving treatments, others tolerate the treatments poorly, and it should be clearly stated that radiation therapy is not without its morbidity and occasional mortality.

It is our clinical impression that had these same 75 patients been treated with total laryngectomy, the survival figures would have been only slightly higher than the 81% seen. We would estimate that the survival figures might be in the range of 85%. In addition, we believe that patients that are treated by vertical hemilaryngectomy can be fol-

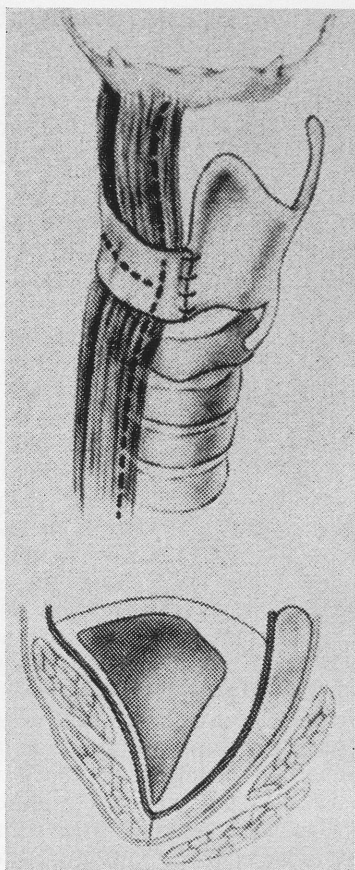


Fig. 6. Muscle reconstruction after Maran, Hast and Leonard.

lowed sufficiently well and when recurrences do appear, proper treatment, either radiation therapy or laryngectomy, or both, can be performed. The end result should yield almost as high survival figures, had the more radical operation been performed in the first place.

In comparing our own figures first with other authors, Som has written a number of articles on vertical hemilaryngectomy for similar carcinoma. In one of his latest papers,¹³ he indicates that when there is a free vocal cord lesion without subglottic extension or involvement of the anterior commissure or vocal process, he performs a cordecotomy. When either the anterior commissure or vocal process or both are

involved, he performs a vertical hemilaryngectomy and reports a 75% five-year survival out of 125 cases. Among these cases there were nine residuals or recurrences and 14 patients developed metastases to the neck later. Of 38 patients that had strictly anterior commissure (horseshoe) lesions, he reports a 68% cure rate, but does not indicate the number of years follow-up. Kirchner and Som¹⁴ state that a fixed vocal cord is not necessarily a contraindication to hemilaryngectomy. They list the reasons for "fixation" to be either replacement of the thyroarytenoid muscle by tumor, spread of carcinoma along the top of the vocal cord extending to the thyroid cartilage, subglottic extension, especially posteriorly, binding the vocal cord to the cricoid arch, or combination of radiation fibrosis and residual tumor in the vocalis muscle. In 22 such patients treated by hemilaryngectomy, they report a two year survival of 60%. Of the nine patients that had recurrences, three were "salvaged" by total laryngectomy.

Biller et al.¹⁵ presented their experience recently and their indications for hemilaryngectomy are essentially identical with our own except that they do consider cases with reduced mobility (not fixation) as still candidates for hemilaryngectomy. They reported that of 58 patients that met this criteria, 77% demonstrated "tumor control" at the end of three years, and 69% at the end of five years. Bailey,³ in an excellent article, reviewed the history of vertical hemilaryngectomy, methods of reconstructing the partially resected larynx (both clinical and experimental results), and reports a series of 31 patients. His indications for hemilaryngectomy are not stated specifically nor does he comment on mobility of the vocal cord. He reports a 90% survival rate at three years. Included in the 90% survival are three patients that required total laryngectomy for recurrence at six months, two and one-half years, and four and one-half years. In addition, there are three patients included in this figure that had radiation therapy, two for

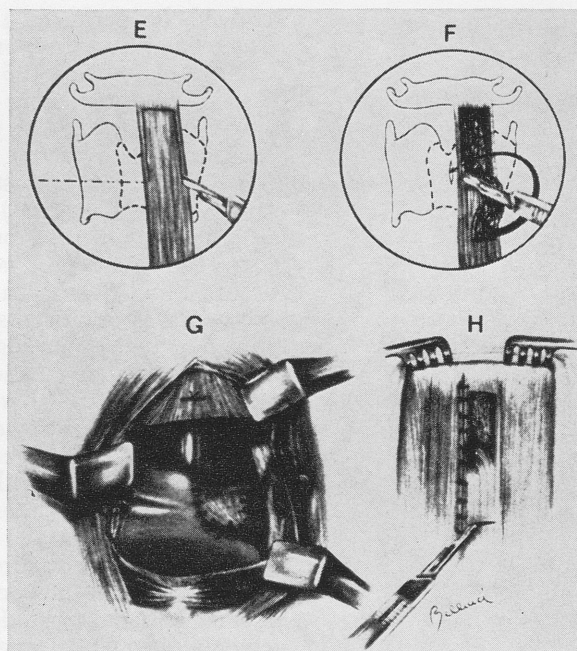


Fig. 7. Unipedicled muscle flap, covered by mucosa. (With permission of the Publisher)

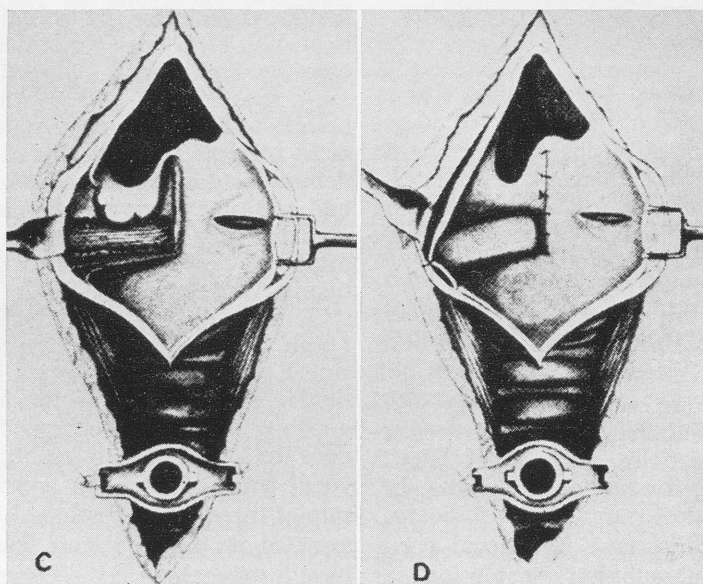


Fig. 8. muscle graft (C), covered by mucosa (D). (With permission of the Publisher)

residual disease and one for recurrence. We now believe that reduced cord mobility is not a contraindication to hemilaryngectomy, but are not advocating the operation in cases of "fixed" vocal cord.

A search of the literature for comparison with treatment of similar lesions by radiation therapy reveals two significant facts. First, radiotherapists do not describe the lesions quite as precisely anatomically as necessary to make valid comparisons (or at least they did not five years ago in order to have significant follow-up); and second, there are very few reported series of pure glottic carcinoma with sufficient numbers of patients to make valid comparisons. However, a few references should be mentioned. Garland¹⁶ states that epidermoid carcinoma of the free edge of the mobile vocal cord, without involvement of the anterior commissure or vocal process, yields approximately 90% five-year survivals when treated with radiation therapy; however, he does not give material to substantiate this. He further states that when the carcinoma involves the anterior commissure or the vocal process of the arytenoid, the chances of radiation cure are lessened somewhat but does not state exactly what the survivals are expected to be, nor does he give exact figures. He does state that glottic carcinoma shows 54% five-year survivals; presumably this means all lesions of the vocal cord without extension to involve other parts of the larynx. It would, therefore, include lesions in which the cord is both fixed and mobile. Lederman¹⁷ showed a 48% five-year survival obtained in glottic carcinoma. One is led to assume that his series includes all cases of carcinoma of the true cord whether large or small, or whether or not the cord was mobile. MacComb et al.¹⁸ reported a 78% three-year survival rate among 162 patients with stage I glottic cancers treated by radiation therapy. No further breakdown as to anatomic locus was given. McCabe and

Magielski¹⁹ compared the experience of 14 authors and found an average five-year cure rate of 75% for carcinoma of the vocal cord treated by radiation therapy. Boles and Komorn,²⁰ in a much more recent article, report some similar lesions treated with radiation therapy. They report 17 vocal cord lesions involving the anterior commissure with a two-year survival of 76% (13/17). Of four lesions of the vocal cord having spread posteriorly to involve the vocal process of the arytenoid, there were no cures for 0%. The report covers 108 cases, but when these are divided into various appropriate subcategories no further valid comparisons can be made. Many of the patients in the study had larger lesions, many with decreased mobility or fixation of the vocal cord.

SUMMARY

In summary, the authors are able to report an 80% two-year survival rate for treatment of carcinoma of the vocal cord with the extension to involve the anterior commissure and/or the arytenoid, when treated by hemilaryngectomy. While true comparisons with similar lesions being treated by radiation therapy are lacking, it is our clinical impression that if these same patients had been treated by radiation therapy, the survival figures would have been considerably lower, in the range of approximately 55% to 60%. We further believe that while many of the radiation therapy failures could have been salvaged, a number would have required total laryngectomy. It is our distinct impression that laryngeal cancer, like all cancer of the head and neck, is best treated by a team of specialists, including the chemotherapist, the radiotherapist, and the surgeon. All of the patients should be evaluated by the group before any therapy is initiated. In this way, exact anatomical localization can be made, regardless of the type treatment ultimately rendered.

REFERENCES

1. Som ML, Arnold LM: Hemilaryngectomy. In: *Otolaryngology*. W. F. Prior and Co., 5: 31-58, Revised 1964
2. Leonard JR, Litton WB: Selection of the patient for conservation surgery of the larynx. *Laryngoscope* 81: 232, 1971
3. Bailey BJ: Partial laryngectomy and laryngoplasty. *Laryngoscope* 81: 1742, 1971
4. Litton WB, Leonard JR: Aspiration following hemilaryngectomy: a cineradiographic study. *Laryngoscope* 79: 887, 1969
5. Conley JJ: Glottic reconstruction and wound rehabilitation. *Arch Otolaryng* 74: 21, 1961
6. Pressman JJ: Ca. of the larynx: laryngoplasty. *Arch Otolaryng* 59: 395, 1954
7. Bailey BJ: Partial laryngectomy and laryngoplasty. *Trans AAOO* 70: 559, 1966
8. Ogura JH, Dedo HH: Glottic reconstruction. *Laryngoscope* 75: 865, 1965
9. Maran AG, Hast MH, Leonard JR: Reconstruction surgery for improved glottic closure. *Laryngoscope* 78: 1916, 1968
10. Ogura JH, Biller HF: Glottic reconstruction. *Laryngoscope* 79: 2181, 1969
11. Quinn HJ: A new technique for glottic reconstruction after partial laryngectomy. *Laryngoscope* 79: 1980, 1969
12. Biller HF: Personal communication, 1972
13. Som ML: Partial Laryngectomy for Carcinoma. *Proc Natl Ca Conf* 6: 659, 1970
14. Kirchner JA, Som ML: Clinical significance of the fixed vocal cord. *Laryngoscope* 81: 1029, 1971
15. Biller HF, Ogura JH, Pratt LL: Hemilaryngectomy for T₂ glottic cancers. *Arch Otolaryng* 93: 238, 1971
16. Garland LH: Radiation Treatment of Carcinoma of the Larynx. In: *Otolaryngology*. W. F. Prior and Co., 5: 1-26, Rev. 1963
17. Lederman M: Place of radiotherapy in treatment of cancer of the larynx. *Brit Med J* 1: 1639, 1961
18. MacComb WS, Fletcher GH, Gallager HS et al: Larynx, in *Head and Neck Cancer*. Baltimore, Williams and Wilkins, 1967, p. 285
19. McCabe BF, Magielski JE: Carcinoma of the Larynx. *Ann Otol* 69: 1013, 1960
20. Boles R, Komorn R: Carcinoma of the laryngeal glottis. *Laryngoscope* 79: 909, 1969

DISCUSSION

GABRIEL F. TUCKER, JR., M.D.: I wish first of all to sincerely compliment Dr. Holt on a fine presentation. I do, however, have a question to raise which isn't so much a personal question for Dr. Holt or Dr. Leonard, but is something I'm afraid is much too widespread today — the problem of imprecise language. I would hope that in this most distinguished forum, the American Laryngological Association, we could be more precise in the use of surgical terminology.

(Slide) — Gluck, in the early part of this century, described hemilaryngectomy. The figure is from Kirschner's *Operative Surgery*, and I think shows the midline splint of the thyroid and cricoid quite well. (Fig. 385, *Operative Surgery* by M. Kirschner, translated by Ravdin & Coates, Philadelphia, Lippincott, 1937.)

Now, maybe it would be best at this point merely to quote from Dr. Jackson because he ran into this problem as evidenced by this quotation from his book on "Cancer of the Larynx" in 1939 and I quote:

Partial laryngectomy: Inasmuch as part of the larynx is removed by laryngofissure the operation is obviously a partial laryngectomy. If the removal of tissue approximates half of the larynx the operation could

be justly called a hemilaryngectomy. But this term has for so long been applied to an operation that involves removal of the arytenoid and often part of the cricoid along with the lateral mass that it seems preferable *not* to use the word for any other procedure.

RICHARD FARRIOR, M.D.: I also want to congratulate the authors from Philadelphia and Scotland, and perhaps to appeal a little bit to your imagination in what I like to term laryngoplasty, using the same imagination we've come to apply to skin flaps or the various mucosal flaps that can be used with some word of caution about edema or redundancy, which modifies the voice quality.

Secondly, to think in terms of what other materials to use if we are going to get the best possible voice by, in essence, both covering and giving some bulk to this side of the larynx and thinking in terms of using perhaps dermal grafts. Dermal grafts can be rolled for more bulk, or a dermal fat graft, which would be basically deepithelialized bulkier tissue, can be used as a free graft.

We made the appeal to this Society two years ago for someone to be thinking about using composite grafts from the ear with the skin on only one surface and taking advantage of the contour surface of the anterior portion

of the ear to simulate vocal folds or at least to give some bulk to this side. I think that particular technique of graft has many applications and can be applied both to the larynx and to defects — to coordinate with Dr. Pennington's paper — where you need some lining and some cartilage for reconstruction, say, of the trachea.

The other thing I had in mind was some concern about our reconstruction. This is an area that gives me great concern when you're extending your technique now — still conservative surgery. You're still preserving a voice. I get to worry more and more about preservation of voice function than voice quality, but the extensive or more advanced T-2 lesion bothers me. These are the ones where I'm afraid we might cut too close and/or with our desire for reconstruction may actually have some recurrences that you ordinarily wouldn't see without the mucosal flaps or without the various muscle flaps and other types of coverage.

I have a little concern that we may in our philosophy cut our margins down trying to take a larger lesion out. I'd like to coordinate this same concern with the two excellent

papers from Virginia and New York on x-ray therapy. This area bothers me. If we know that we can with the T-2 lesion increase or extensively increase the cure rate, should we not also consider in the extensive lesion doing combined therapy, extensive T-2, where you can preserve voice function?

PRESIDENT F. JOHNSON PUTNEY, M.D.: If I may be permitted to reiterate my own personal experience with this procedure, as I presented it yesterday, it's an excellent operation. Out of 20 patients on whom I employed the procedure, 18 have survived five years or longer. These are again absolute, or I prefer minimum, survival rates.

GORDON P. HOLT, M.D. (closing): I appreciate Dr. Tucker's comments. I did not go into surgical technique of the definition he gave for hemilaryngectomy which would fit the procedures that we did. We didn't take any cricoid cartilage, but other than that, everything else that you mentioned in your definition, with the exception of the body of the arytenoid. But in anterior commissure lesions, the whole process was taken and sometimes the body of the arytenoid was left. Other than that, it was the whole larynx on that side.

RECONSTRUCTIVE LARYNGECTOMY

REPORT ON THE FIRST 35 CASES

MICHELE ARSLAN, M.D.

PADUA, ITALY

Total laryngectomy has considerably improved the prognosis of patients affected by malignant neoplasias of this organ, but from the start there has been the problem of the rehabilitation of laryngectomized patients and their reinsertion in a normal social life. Although orthophonic reeducation has made it possible for operated patients to express themselves clearly enough with their esophageal voices, the characteristics of their phonation (decidedly unpleasant), the abnormal noisy breathing and the esthetic damage due to the presence of the tracheostoma represent a serious handicap for a normal social life.

The need for a surgical technique which would preserve a passage for respiration by natural airways after radical exeresis of the larynx (the radicality of the destruction is the basic principle of all oncological surgery) has long been felt by those interested in this kind of pathology.

Various clinical and experimental researches in this field are reported in medical literature. An attempt has been made to solve the problem by substitutive prosthesis of the larynx;¹⁻¹⁵ by transplantation;¹⁶⁻¹⁹ *by surgical reconstruction* of a simplified but functionally adequate organ.²⁰⁻²⁵

Experimental Research on Animals. Five years ago we began work on the problem of preserving a passage for respiration by natural airways after

total laryngectomy in a series of experiments on dogs and monkeys.²⁶⁻²⁸ The results we obtained by our method of laryngectomy, which allowed restoration of trachealpharyngeal canalization without jeopardizing the resumption of normal deglutitive processes, were decidedly positive in the operated animals. In fact it was possible at an early stage to abolish the temporary tracheostoma thus allowing resumption of respiration by natural airways; spontaneous resumption of phonation was observed in every case and there was no difficulty in normal alimentation. These functions were also analyzed with radiographical and electro-acoustic studies. Direct necroscopy of the "neo-larynx" in a dog operated on and sacrificed three months after the operation, revealed the excellent structure of the newly formed organ. Observation of the operated animals over a period of three years made it possible to ascertain the constancy of these functional characteristics of the "neo-larynx."

Clinical Application and Indications. The encouraging results obtained in animals induced us to study the possibility of using this method in clinical surgery. With this in mind, research was done on a corpse and it was shown that from a technical point of view, this technique could be extended to man. But for man other problems of an oncological order arise in particular with regard to the need to achieve the most radical surgical destruction possible of the organ, since the technique

From the Otorhinolaryngological Clinic, University of Padua, Padua, Italy.

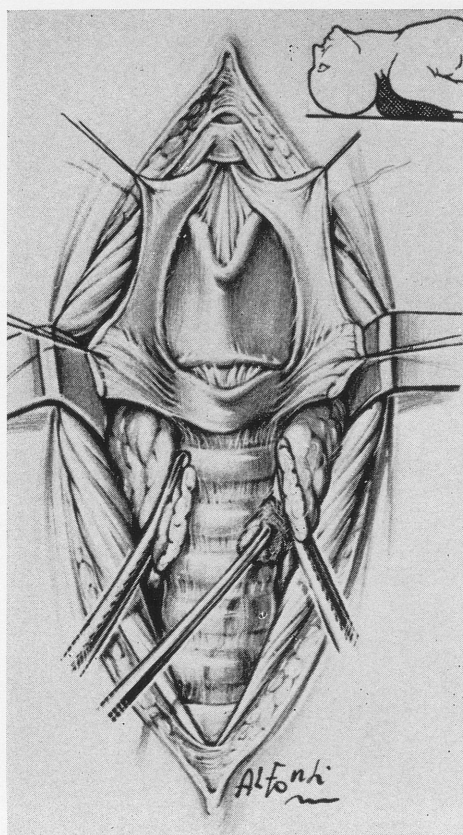


Fig. 1. Having exposed the larynx and the trachea, the external perichondrium is incised vertically on the midline and detached bilaterally together with the insertions of the cricopharyngeal muscle. The isthmus of the thyroid gland is dissected and its lobes are detached from the trachea and divaricated. Tracheotomy is performed at the level of the fifth tracheal ring.

we propose should follow almost total exeresis of the larynx, quite unlike some partially destructive techniques successfully experimented in recent years. The technique of reconstructive laryngectomy we propose may be adopted in cases of strictly intrinsic laryngeal carcinoma, where no partially destructive operation is possible.

Since January 1970 we have adopted this surgical technique in 35 patients suffering from laryngeal spinocellular epithelioma where total laryngectomy was indicated. In all cases, given the

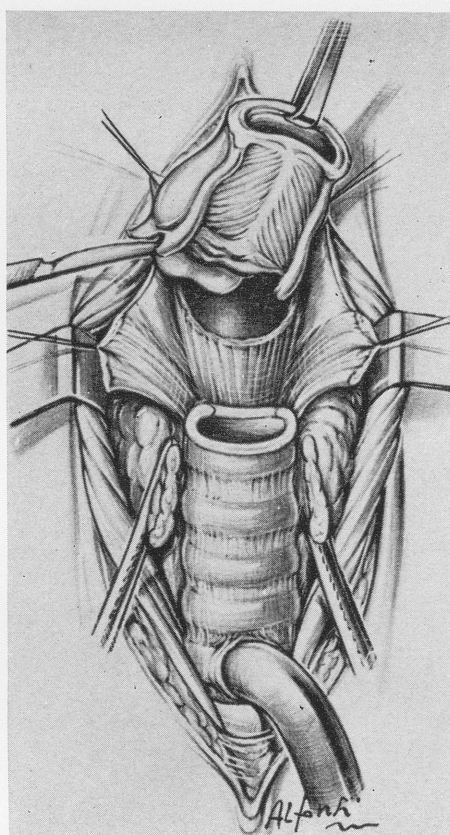


Fig. 2. The larynx is removed, proceeding from the lower part to the upper-part, without touching the free extralaryngeal part of the epiglottis, which remains *in situ* in the anterior portion of the pharyngeal opening.

strictly intrinsic localization, the integrity of the epiglottis and the absence of clinically observable laterocervical metastases, application of this personal method of reconstructive laryngectomy was indicated.^{29,30}

OPERATIVE PROCEDURE

The operational technique is identical to that experimented in animals. Its surgical phases may be described as follows: a median vertical precervical incision is made extending from the hyoid bone to the jugulum. The fascia and the raphe between the pharyngeal muscle are then incised and separated to expose the anterior surface of the larynx and the upper tract of the tra-

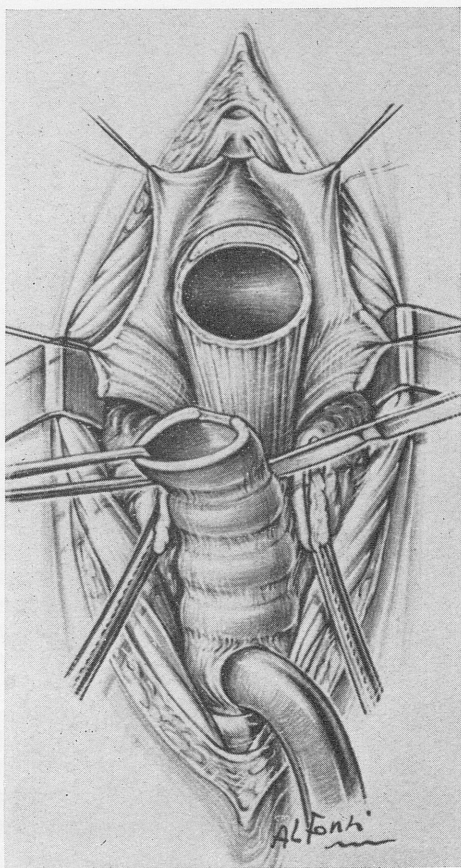


Fig. 3. The posterior wall of the trachea is carefully detached from the anterior wall of the esophagus up to the level of the fifth to sixth tracheal ring.

chea; dissection of the isthmus of the thyroid gland and suture of the two raw surfaces allows separation of the two thyroid lobes, thus obtaining ample opening of the trachea to the jugulum. Once a vertical incision on the median line of the external laryngeal perichondrium has been made, the latter is cut away bilaterally to the posterior edges of the thyroid cartilage and the cricoid setting; the perichondrium and the insertions of the cricopharyngeal muscle are also cut. The blood vessels are then carefully electrocauterized. At the end of this phase the larynx is completely isolated anteriorly and laterally (Fig. 1).

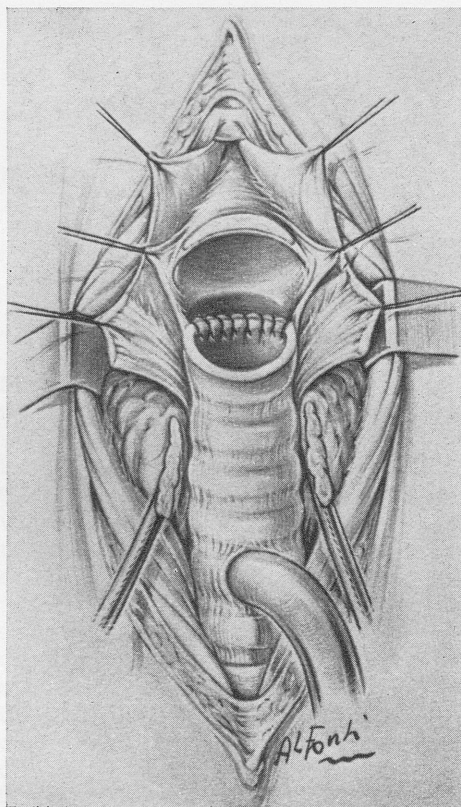


Fig. 4. Suture of the inferior edge of the pharyngeal opening to the posterior edge of the tracheal opening.

Tracheostoma through the fifth tracheal ring is now carried out (in some cases this operation had been undertaken beforehand as an emergency) after which the anesthetic tube is inserted into the opening. The larynx from the lower part upwards is separated from the first tracheal ring, detached from the anterior portion of the cervical esophagus and then removed; complete exeresis of the larynx is achieved by dissecting the hypopharyngeal wall all around and externally to the laryngeal vestibulum and the epiglottis duct 5 cms above the upper edge of the thyroid cartilage; the body of the epiglottis thus remains in place while its stem is removed with the larynx (Fig. 2).

Reconstruction takes place as follows: anastomosis between the tracheal

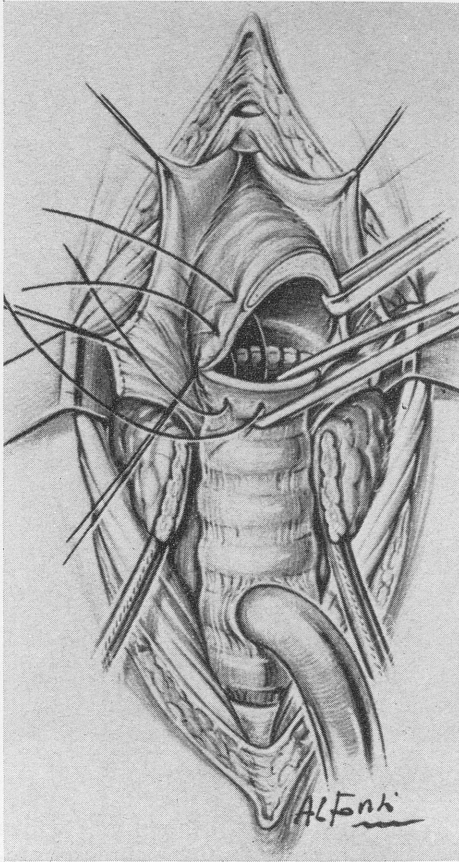


Fig. 5. Raising of the trachea using suture stitches between the hyoid bone and the first tracheal ring.

opening and the hypopharyngeal stoma is begun from behind by a suture with stitches detached from the lower edge of the pharyngostoma with the posterior edge of the tracheostoma. When a suitable flexion of the head has been found the pharyngeal stoma is reduced in diameter using two symmetrical lateral sutures with introflexed stitches and by reconstructing the anterior wall at the entrance to the piriform sinuses. An alimentary nasoesophageal probe is inserted through one of the piriform sinuses just reconstructed (Figs. 3 and 4).

Tracheopharyngeal anastomosis is completed anteriorly by a suture with introflexed stitches which allows the anterior half of the first tracheal ring to

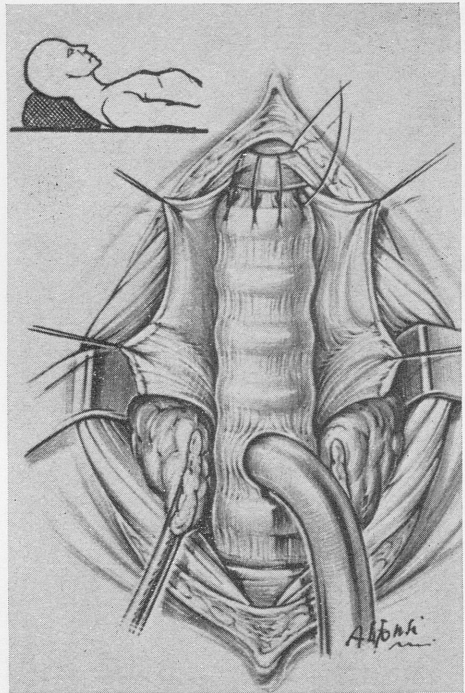


Fig. 6. Completion anteriorly of the suture between the tracheal opening and the hypopharyngeal opening.

be fixed to the inferior raw edge of the epiglottis. In this way the trachea is raised and the pharyngeal stoma with the epiglottis is lowered (Fig. 5).

The trachea-epiglottic clasp which has just been completed in the previous phase is attached to the hyoid bone by four suture stitches of very robust chromium plated catgut, and when these have been pulled tight it is possible to raise the trachea still further until its opening is at the level of the primitive laryngeal vestibulum (Fig. 6).

The external laryngeal perichondrium and both sides of the cricopharyngeal muscle which had been isolated in the first part of the operation are now folded over the upper segment of the trachea and sutured on the median line with stitches into the thickness of the tracheal wall (Fig. 7).

Finally, the prelaryngeal muscle is sutured on the median line and the

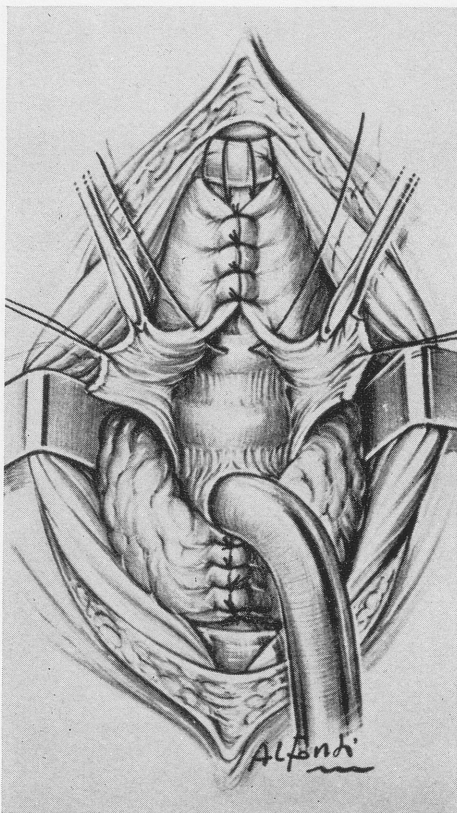


Fig. 7. Median suture of the laryngeal perichondrium which is fixed to the trachea anteriorly. Median suture of the thyroid isthmus which is fixed to the anterior wall of the trachea immediately below the temporary tracheostoma (fifth to sixth ring).

fascia are sutured cutaneously. The wound requires no transcutaneous draining. A tracheotomic cannula fitting the diameter of the tracheal opening at the level of the fifth ring is inserted (Fig. 8).

When the operation is concluded, the trachea has been lifted by about 4 cms and is kept in position during the scarring period by various stitches attaching it to the hypopharyngeal mucous membranes, the epiglottis, the body of the hyoid bone, the external laryngeal perichondrium and, by means of this, to the pharyngolaryngeal muscles (constrictor and elevator of the pharynx and larynx); the tracheotomic cannula also helps to keep the trachea in

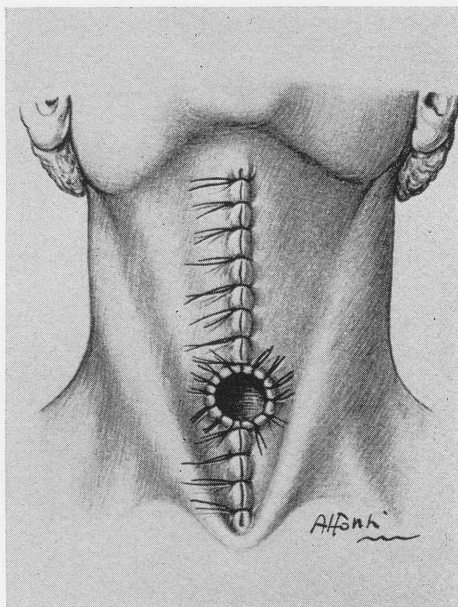


Fig. 8. The superficial levels and the skin are sutured. The edges of the tracheostoma are fixed to the skin in the middle third of the surgical wound with a few suture stitches.

the desired position (Fig. 8).

The "neo-larynx" therefore, which has been formed by the technique proposed above is composed of the upper segment of the trachea, the body of the epiglottis over the opening, the external laryngeal perichondrium with the lower constrictor muscles of the pharynx (thyropharyngeal and cricopharyngeal bundles) and the elevator of the pharynx and larynx (stylopharyngeal muscle). It fills the space left by removal of the larynx, since the epiglottis and the tracheal opening now correspond to the seat of the normal laryngeal vestibulum.

Postoperative Course. In the postoperative period the patients were treated with broad spectrum antibiotics administered parenterally; and with derivatives of belladonna to reduce salivation; in addition, antibiotics were administered by inhalation through the tracheostoma.

For the first few days after the opera-

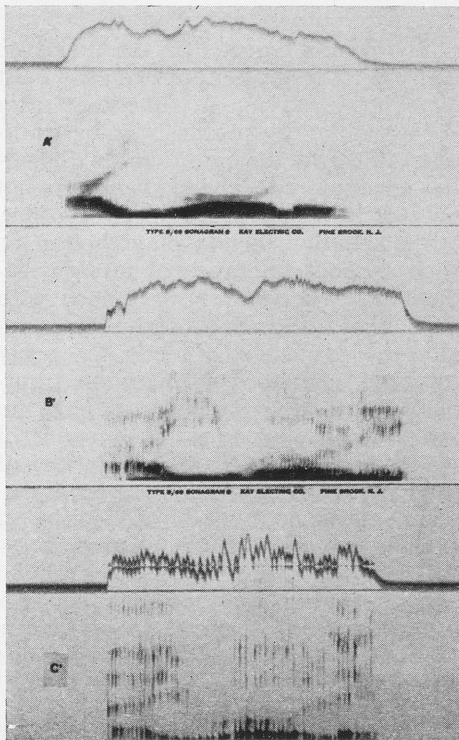


Fig. 9. Narrow band sonograms (A-B-C) of the word "aiuolo" produced in the following three conditions: A) in a normal subject fundamental and harmonics in regular succession among themselves are clearly recognizable as well as perfect arrangement of formants; B) in patient operated by our technique one can observe the presence of a fundamental, 2 to 3 upper harmonics and a regular arrangement of vocal formants; and C) in the esophageal voice the spectrum shows complete absence of a regular succession of fundamentals and harmonics with the typical aspect of "noise" even if there is a fairly regular arrangement of vocal formants.

tion a certain amount of bronchorrhea was observed together with expulsion of mucus mixed with saliva through the tracheal cannula accompanied by fits of coughing. The majority of patients were practically without fever during the whole postoperative period. Radiography of the thorax was done every three days and showed a persistent absence of bronchopulmonary lesions.

During the first week all patients were given two blood transfusions to

help scarring. The wound healed at once in all cases and the stitches of the cutaneous suture were removed on the eighth day. At the end of the first week expulsion of expectoration material was considerably reduced in the tracheostomic cannula and at least partial resumption of respiration through natural airways had begun. The tracheal cannula was substituted with another of smaller caliber. Antibiotic therapy was also reduced. The naso-esophageal alimentary probe was removed in all patients between the tenth and the fifteenth day and natural alimentation resumed. On day 16 antibiotic therapy was suspended.

Postoperative Complications, Recurrences, Metastases. The period of time since the first operation is still short; our first patient was operated two years ago January, 1970, and the last patient only eight months ago, so we can only report our first results in this communication.

With time and an adequate number of cases operated on by this technique, it will be possible to obtain sufficient data regarding both functional resumption and definitive recovery from neoplastic illness. The first results are, however, so encouraging that we have decided to make them known at once (Tables I and II).

TABLE I
SEQUELAE IN THE
POSTOPERATIVE PERIOD

1° — Postoperative Mortality	0
2° — Fistula	0
3° — Cervical Infection	0
4° — Bronchopneumonia (cured)	3
5° — Cervical Metastases (operated subsequently with neck dissection)	8
6° — Local Recurrences	4

Functional Results. In the course of the first week after operation, spontaneous resumption of phonation was observed in all patients; initially the voice was not very sonorous but it improved

rapidly bringing a marked increase in the fundamental tone of speech, in the intensity of emission and in the timbre.

The patient's voice became comprehensible even at a distance and was not unpleasant; electro-acoustic studies of the voice production revealed harmonics approaching those of normal speech and quite unlike the esophageal voice (Fig. 9).

Natural alimentation was also rapidly resumed 12 to 15 days after the operation when the alimentary probe was removed. Patients found they could swallow solid and semisolid food without difficulty but liquids were a problem at first due to aspiration of alimentary traces into the trachea. The fact that the normal swallowing mechanism was maintained demonstrates the upward and forward movement of the "neo-larynx" each time food or saliva was swallowed. We used roentgencine-radiography to follow the swallowing mechanism (latero-lateral projection).

Ten days after operation, resumption of respiration by natural airways had begun; the expiratory phase appeared first, while inspiration remained initially more difficult due to edema of the mucous membranes at the level of the tracheal opening. Spirometer tests carried out in patients after closure of the tracheostoma revealed an excellent respiratory function through natural air-passages.

TABLE II
RESTORATION OF LARYNGEAL
FUNCTIONS

Deglutition	90% 2-3 weeks after operation
Phonation	100% in the 1st week after operation
Respiration	
Expiration	100% in the 1st week after operation
Inspiration	40% in the 1st month after operation

DISCUSSION

The results reported in the literature concerning restoration of even the most elementary laryngeal functions after laryngectomy by prothesis or by transplant illustrate the considerable difficulties encountered. The obstacles are not only of a technical or surgical order, other negative factors play their part, such as poor tolerance of foreign elements, the difficulties for tissues with poor blood supply to thrive in a region that is decidedly septic, the reject reactions common to all organ transplants, and the possible damage to lower respiratory tracts as a result of scanty protection from aspiration of food particles. But for a larynx transplant, even when all the difficulties of a technical and physiopathological order have been overcome, the problem of finding and preserving the organs for transplantation is certainly a further obstacle to wide diffusion of this method.

Considering the data reported by various authors and the results of our own experiments, the method with the greatest chance of success and diffusion in the future is the surgical reconstruction, after total laryngectomy, of a simplified organ formed by structures and tissues salvaged during the destruction.

Phonetic Research on the Voice of the Human Neo-larynx. The voiced component which appears in the emission of patients operated upon using the new technique of reconstructive laryngectomy has been demonstrated by means of an electro-acoustical study of the voice of these patients. This voiced component was caused by the vibratory phenomena of the structures of the neo-larynx, and was excited by the flux of exhaled air.

The qualities noted when listening directly to the voice produced by patients operated upon using the reconstructive technique must be confirmed by the presence of voiced components recorded by magnetic registration (Sonograph, Fig. 9). The problem

seems to be a vast and complex one; an examination should be made of different types of emission, choosing opportune phonemes or syllables in order to construct a complete picture of the phonetic situation. In our research we

limited ourselves to the examination of a number of vocal signals so as to draw some conclusions from them. It is foreseeable that, on account of the nature of the operation, the voice emitted will be partly voiced and partly unvoiced.

37 VIA ALTINATE, PADOVA, ITALY

REFERENCES

1. Briani AA: Riabilitazione fonetica di larigectomizzati a mezzo della corrente aerea espiratoria polmonare. *Arch Ital Otol* 63: 469, 1952
2. Conley JJ, De Amesti F, Pierce MK: A new surgical technique for the vocal rehabilitation of the laryngectomized patient. *Ann Otol* 67: 655, 1958
3. Barton RT: A review of attempted physiological restoration of voice following total laryngectomy. Read before the 8th Internat Cong Otorhinolaryngology. Tokyo, 1965
4. Asai R: Asai's new voice production method: a substitution for human speech. Read before the 8th Internat Cong Otorhinolaryngology. Tokyo, 1965
5. Miller AH: First experiences with Asai's technique for vocal rehabilitation after total laryngectomy. *Ann Otol* 76: 829, 1967
6. Porres R, Mersol VF: Tracheopharyngeal shunt after total laryngectomy. *Arch Otolaryng* 88: 413, 1968
7. Montgomery WW: Voice rehabilitation after laryngectomy. *Arch Otolaryng* 88: 499, 1968
8. Czerny V: Versuche über Kehlkopf-Extirpation. *Med Wschr* 27: 559, 1870
9. Billroth T: Quoted by Gussenbauer¹⁰
10. Gussenbauer C: Über die erste durch Th. Billroth an Menschen ausgeführte Kehlkopf-Extirpation und die Anwendung eines Künstlichen Kehlkopfes. *Verh Otsch Ges Chir* 1: 250, 1874
11. Caselli A: Atti Soc. Med. Chir., Bologna, 7 Dic. 1879. Quoted by Jemmi, C.: Azzio Caselli (1847-1898) precursore della faringo-laringectomia e geniale ideatore della protesi laringea. Atti 44° Cong Soc Ital ORL, Bologna, 1956
12. Rosewell P: A case of total extirpation of the larynx. *Ann Surg* 3: 28, 1886
13. De Vincentiis I, De Santis M: Le replacement du larynx chez le chien avec prothèse composée. *Ann Oto-Laryngol* (Paris) 73: 57, 1956
14. McCall JW, Whitaker CW: The use of prosthesis in the larynx and trachea. A preliminary report. *Ann Otol* 71: 397, 1962
15. Ogura JH, Shumrick D, Lapidot A: Some observations on experimental laryngeal substitution in laryngectomized dogs. *Ann Otol* 71: 532, 1962
16. Ogura JH, Kawasaki M, Takenouchi S, et al: Replantation and transplantation of the canine larynx. *Ann Otol* 25: 295, 1966
17. Work WP, Boles R: Larynx: replantation in the dog. *Arch Otolaryng* 82: 401, 1965
18. Silver CE, Liebert PS, Som ML: Autologous transplantation of the canine larynx. *Arch Otolaryng* 86: 95, 1967
19. Mounier-Kuhn P, Haguenaux JP, Inuyama, et al: Les possibilités de greffe autologue du larynx chez le chien. *Ann Oto-Laryngol* (Paris) 85: 7, 1968
20. Kluyskens P, Boedts D, Dhont G, et al: Note préliminaire sur la transplantation du larynx. *Acta Oto-Rhino-Laryngol Belg* 23: 5, 1969
21. Foderl S: Quoted by Laurens²²
22. Laurens G: *Chirurgie d'ORL*, (Ed) Masson, Paris, 1966
23. Hoffmann-Saguez M: Nouveau cas de laryngectomie sub-totale. (Présentation de malade opéré selon notre technique). *Ann Oto-Laryngol* (Paris) 68: 736, 1951
24. Majer EH, Rieder W: Technique de laryngectomie permettant de conserver la perméabilité respiratoire. (La crico-hyoidopexie). *Ann Oto-Laryngol* (Paris) 76: 677, 1959
25. Lapidot A, Kouyoumgian J, Ramm C: Reconstruction of the larynx following total laryngectomy. Preliminary report of unsuccessful application of new onestage technique. *Arch Otolaryng* 82: 38, 1965
26. Serafini I: Studio sperimentale sulle possibilità di attuare nel cane la laringectomia totale con restaurazione della respirazione per le vie naturali. Primi risultati. *Minerva Otorinolaring* 17: 119, 1967
27. Serafini I: Ripristino della respirazione per le vie naturali, della deglutizione e della fonazione in cani sottoposti a laringectomia

totale. *Ann Laring Otol Rinol e Faring*, Torino, 66: 241, 1967

28. Serafini I: Restoration of laryngeal function after laryngectomy. Experimental research in animals. *Advances in Oto-Rhino-Laryngology*, L. Rüedi, (Ed) S. Karger, Basel/New York, 16: 95, 1969

29. Arslan M, Serafini I: La laryngectomie

totale avec rétablissement de la phonation et de la respiration naturelles. *Premiers résultats* (4 cas). *Ann Oto-Laryngol* (Paris) 87: 509, 1970

30. Serafini I: Laryngectomia totale con mantenimento della respirazione per le vie naturali. *Resoconto sul primo caso operato*. *Minerva Otorinolaring* 20: 73, 1970

DISCUSSION

JOSEPH OGURA, M.D.: Mr. Chairman, I rise to discuss this paper because this is not the first time I have heard it. This is certainly an area for the exciting advances in the replacement of the larynx after removal of the larynx. I really want to congratulate Professor Arslan because I think this is a great contribution for future consideration of this technique.

When I first heard this in Milan when I was there two years ago, and again at Rotterdam this past summer, I thought that there should be a word of caution. Any procedure which is new has to be weighed in terms of what are we accomplishing. The risks of cancer are well known. Its applicability has been spelled out only for glottic cancers with subglottic extension.

You will note in the 35 cases there were eight cervical node metastases and there were four local recurrences. Since in partial surgery, you have to have glottic closure for function, this really represents an open larynx and in the total assessment of this, swallowing is one of the most important functions. He has demonstrated this for solids and I would like to ask him what the results are with liquids.

You are able to remove the tracheostomy tube in only 20% of the cases. This means that the tracheostomy must be present in the remaining 80%, some partially, some totally. The total dependence on it, I think he said, was 30% and the others were partially dependent on it.

We are now back to the narrow field subglottal removal since he leaves the epiglottis in. This is therefore not applicable for epiglottic cancers. I would like to ask him what happened to his neck dissection cases.

Finally, I would like to say he mentioned something about the dog research. We described this ten years ago. I did this operation, a modified form, in three patients, in humans. I have it on film but I never published it because I was not satisfied with the total requirements and that is complete extubation of the tube and satisfactory swallowing which means fluids as well. The airway and the voices he has adequately shown are satisfactory.

ABRAHAM LAPIDOT, M.D.: Dr. Arslan is to be congratulated for these endeavors in a field in which it has been so difficult to obtain the desired results; replacing laryngeal function

after total laryngectomy. I would like to make two comments: The first request is to ask Dr. Arslan to refrain from the use of the word total laryngectomy because in essence this has *not* been a total laryngectomy since the epiglottis has been preserved. I would like to think that this would be referred to as a *sub-total* laryngectomy rather than total laryngectomy and reconstruction.

Because of the inspiration and opportunity given to some of us by Dr. Ogura who started this work in St. Louis as far back as ten years ago, some of us have persisted in these efforts and have been very hesitant to repeat this operation in a human because we live in a country with a high risk of criticism, both from the public and the medical profession.

However, our efforts have been to perform a total laryngectomy and construct a mechanism that would protect the tracheal inlet after total laryngectomy. We have described a dorsum of tongue flap which we used to subserve the function of an epiglottis after total laryngectomy. This has been partially satisfactory. Some of our dogs have lived as long as nine months, and in the eighth month there was no evidence of pneumonia in these dogs that have maintained a significant part of their weight by oral feeding only after they have been extubated.

Our most effective effort to date is a pseudo-epiglottis from the portion of the tongue which is innervated by and contains the hypoglossal nerve. This has been in progress for one year.

MICHELE ARSLAN, M.D. (closing): I thank Professor Ogura very much, as it is very important for us to have his criticism; we know all his work and his papers which we have read so many times; the work on the new problems carried out by Professor Ogura is the background of our ideas and of all our work.

For what concerns his question, it is true that every patient has postoperatively in the first weeks some difficulty swallowing liquids, but gradually this difficulty disappears: everything depends on the will of the patient and on his accuracy in taking care not to swallow when the mouthful is big and when there is a danger of leakage. We have had only one case (so far as I remember) who had great difficulty in swallowing, but month after month liquids and swallowing improved.

Second question: the patients who were operated with neck dissection had no complications at all concerning the problem of neck dissection, but during the operation we were very careful to respect the median part of the neck. The tracheotomy tube still remains in 20% to 30% of the cases, but even this problem can be minimized with time.

In many cases we always preferred to maintain a small closed tube, as in this way patients are more safe and more sure, and they can speak perfectly with the closed tube. With time the tube can be more and more reduced in diameter.

The cases not yet decannulated have edema of the upper part of the trachea of the neolarynx: we are very prudent as we do not wish to cause any dilation of the trachea nor to provoke irritation and perhaps recurrences of the tumor.

What Dr. Lapidot said is true; our operation is not total laryngectomy: it is a total laryngectomy with the maintaining of the epiglottis. We are very anxious to hear his technique of forming a new epiglottis with the tongue, and we will certainly apply this technique in the next cases.

ROLE OF SURGERY IN THE MANAGEMENT OF POSTCRICOID AND CERVICAL ESOPHAGEAL NEOPLASMS

D. F. N. HARRISON, M.D.

LONDON, ENGLAND

Although neoplasms involving the postcricoid region of the hypopharynx and the cervical esophagus are relatively uncommon, there are few human cancers which carry a worse prognosis. The reasons for this unfavorable outlook have been explored by the author¹ and relate to delay in diagnosis, the advanced nature of the primary lesion, and inadequate management. Many patients are diagnosed only when the tumor has extended outside the muscular wall or when cervical lymph node metastasis produces easily detectable neck swellings.

Palliation, if one can be excused for using this much misused word, is rarely possible, and the unfortunate patient eventually succumbs with gastrostomy and tracheostomy. A recent personal follow-up on 54 such patients revealed that 13% died from hemorrhage and 61% from bronchopneumonia and cachexia. The average expectation of life from diagnosis to death was 15 months, ranging from four months to three and one-half years.²

For many years radiotherapy has been the primary mode of treatment, although most published reports give five year cure rates of less than 10%. Pearson³ reported 29% for 38 cases, which must be unique, particularly as he initially reserved radiotherapy for inoperable lesions! The sequelae to successful radiotherapy is frequently a fibrous stricture, leaving the patient with severe or total dysphagia. Surgery in such cases is technically difficult or

impossible if the limited access afforded by a pharyngolaryngectomy is attempted. In recent years attention has once again been focused on the possibilities of more effective primary surgery — in some Centers combined with preoperative radiotherapy.

The traditional procedure of pharyngolaryngectomy, combined when necessary with partial esophagectomy is frequently inadequate because of the extent of the primary lesion. The deficiencies of this operation are well known to all who have studied serially sectioned operative specimens. Even the most skillful surgeon cannot avoid leaving residual disease in the esophageal stump, esophagotracheal party wall (Fig. 1) or paratracheal lymph nodes in the more commonly seen extensive neoplasms. Published series have emphasized that at least 50% of patients treated by this limited procedure develop "local" recurrences prior to closure of the pharyngoesophageal gap. One can understand the sense of satisfaction that comes with completion of a multi-stage skin repair; only the uncritical surgeon, however, remains unaware of his far more frequent unhappy failures.

Measurements by Hiroto⁴ and the author of the histological extent of submucosal spread of tumors arising in the lower hypopharynx and upper esophagus, reveal an average figure of 5 mm at the lower margin. It is also important to remember that an association has been noted between tobacco and al-

In the absence of Dr. Harrison, Dr. Alden H. Miller read this paper.

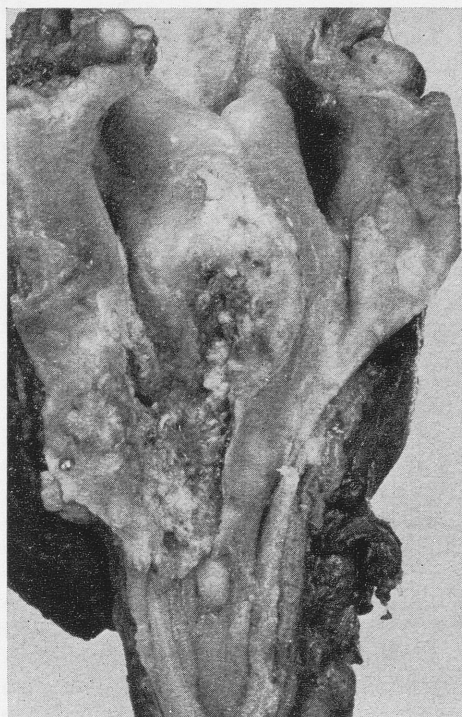


Fig. 1. Specimen removed by pharyngolaryngoesophagectomy opened posteriorly to show microscopical extent of the tumor.

cohol consumption and a liability to esophageal cancer,⁵ while the incidence of neoplasms in this region is undoubtedly greater in patients with the Patterson-Brown Kelly syndrome. Consequently, the whole pharyngoesophagus may be considered "at risk", although a personal study of 32 serially sectioned whole esophagi removed surgically has not revealed a second primary.

Many imaginative techniques have been developed to close the gap left after pharyngolaryngectomy. All suffer from the inherent defect of inadequate primary resection, which logically should be designed to remove both the primary lesion and potentially involved lymph nodes en bloc. Even when successful with early tumors, which may well be more suitable for primary radiotherapy, stenosis at the skin-esophageal junction is frequent.

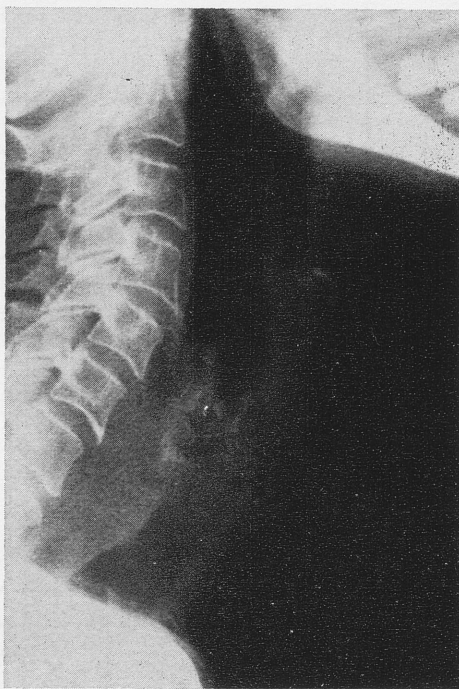


Fig. 2. Lateral radiograph showing indentation of the posterior tracheal wall by a pharyngoesophageal neoplasm.

The success of pedicled grafts of stomach and colon for the management of strictures and neoplasms of the middle and lower esophagus, where the mortality rate of 10% is accepted as reasonable, stimulated interest into the feasibility of extending these grafts up to the pharynx. When combined with pharyngolaryngoesophagectomy this approach offers an ideal opportunity of resecting the primary lesion widely and offering the patient primary repair. Detailed accounts of the various surgical techniques are available in the literature;⁶ sufficient to say that this is a team effort requiring skill, experience and adequate support facilities for good results to be expected.

The stomach has proved to be more reliable, safer, and gives better post-operative swallowing than the colon. It is brought up through the vacant posterior mediastinum without opening the chest. Removal of the manubrium may be necessary to clear the paratracheal

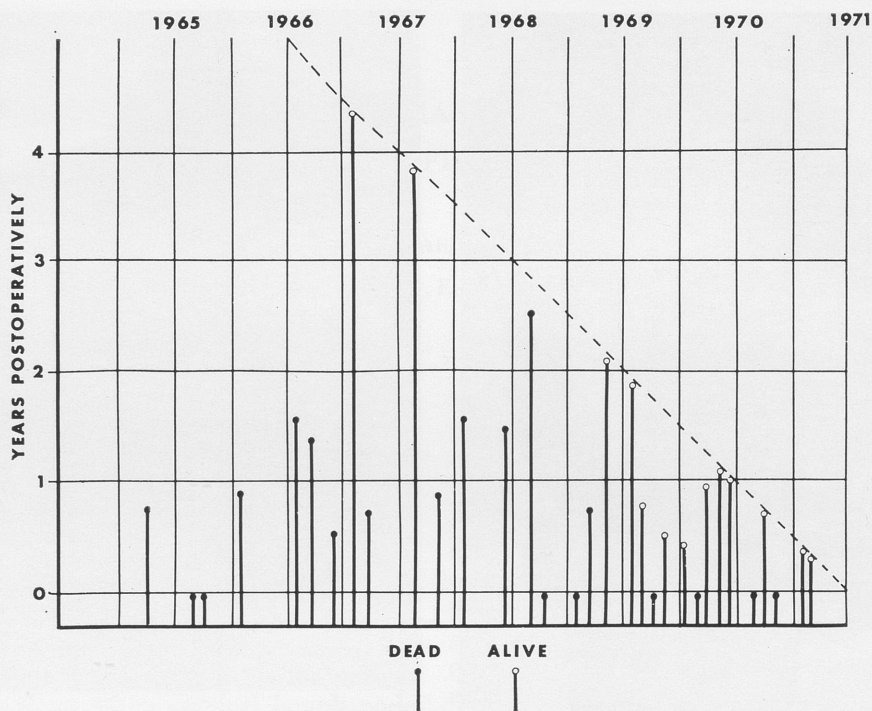


Fig. 3. Survival figures following primary pharyngogastric anastomosis of pharyngo-esophageal and cervical esophageal carcinoma.

lymph nodes and to insure that the trachea is resected well below the tumor. This is essential if disease is not to be left in the tracheoesophageal party wall (Fig. 2). The feasibility of radical resection can only be determined with certainty by operation, for extension of the tumor outside the esophagus is difficult to detect clinically, particularly at the thoracic inlet. Consequently, some patients must inevitably be exposed to the preliminary stages of surgery, but eventually prove to be inoperable. In my experience of 35 gastric "pull-ups" six proved to be inoperable. Palliative resections were performed with primary pharyngogastric anastomosis. All died within six months from carotid hemorrhage, though able to swallow adequately by mouth for this entire period.

Aside from the few patients developing systemic metastasis, failure to control cancer in this region when the tumor is operable is primarily related to failure to control cervical lymph node

metastasis. Considerable confusion has been created in recent years when discussing the merits of prophylactic neck dissection by failure to emphasize that the problem varies with the site of the primary lesion. The policy of "wait to feel" is highly dangerous with neoplasms in the posteriocard and cervical esophagus. Firstly, nodes in the paratracheal chain are almost impossible to palpate, and secondly, metastatic deposits in the cervical lymph nodes usually appear at the limits of any potentially curable neck dissection. Patients who present with enlarged cervical and paratracheal lymph nodes, who one must presuppose have metastatic deposits, are difficult to cure by any modality. To miss the opportunity of curing those without palpable deposits is criminal.

Ideally, bilateral neck dissection should be performed at the time of primary resection. This must seriously increase the risk of an already formida-

ble operation, and at present my own policy is to stage the neck dissection, with three weeks between the sides. Since the primary lesion is invariably circumferential it is immaterial which side is performed first, although any suspicion of lymph node enlargement would influence this decision.

Increasing experience of effective one-stage procedures with a consequent improvement in cure rates must clarify the problem of lymph node management. It may prove possible to preserve the accessory nerve supplying the dominant shoulder, thus minimizing problems of postoperative rehabilitation. Certainly, detailed examination of all neck dissection specimens, an integral part of our clinical research program, provides information relating to pathways of spread and the incidence of undetected deposits. Such information is then related to clinical management, a more logical means of improving patient care than the vagaries consequent upon "clinical impressions." To merely remove single nodes, placing ones faith on the patient's own immunological defenses to deal with residual microscopic deposits will simply increase the already unnecessarily poor cure rate. This policy is best left to those surgeons who no longer have to treat cancer at this site.

During the past nine years, 63 patients with postcricoid or cervical esophageal cancer have been treated surgically. Thirty-five (55%) had primary pharyngogastric anastomosis. As yet it is difficult to analyze the effectiveness of this operation, for there have been a number of important developments in surgical technique in recent years as

well as better case selection. Figure 3 illustrates the outcome of 32 of these cases between the years 1965 and 1971 and should be interpreted with these facts in mind. In experienced hands and with reasonably fit patients operative mortality should be less than 10%. However, many patients are undernourished and elderly, some having been subjected to a long course of radiotherapy and without adequate dietary control. Myocardial degeneration accounted for the death of three such patients in my own series, and if strict selectivity is not adhered to an overall mortality rate of 20% may be more realistic. One must, of course, remember that many of these patients would never have survived the repeated anesthetics of a multi-stage repair. Indeed, the primary lesion would probably have been considered as inoperable in many of these patients. From the experience gained with this group one must conclude that at present the best chance for cure of patients with cancer at this site lies in pharyngolaryngoesophagectomy with staged control of cervical lymph nodes. Whether the primary repair is carried out with stomach or colon depends largely on the experience of the surgical team. In either case the route of choice should be the posterior mediastinal tunnel. There will, however, continue to be patients best treated by multi-stage repair after a more limited resection, where previous abdominal surgery makes stomach or bowel mobilization impossible, or where no experienced surgical team is available. Even more important is the realization that many patients will still be seen where any surgical intervention could only worsen their unhappy state. They should be helped to die in peace and with dignity.

330/332, GRAY'S INN ROAD, LONDON, WC1X 8EE, ENGLAND

REFERENCES

1. Harrison DFN: Pathology of hypopharyngeal cancer in relation to surgical management. *J Laryng* 84: 349-67, 1970
2. Harrison DFN: The management of some cancers of the head and neck. (In press)
3. Pearson JG: The value of radiotherapy in the management of squamous oesophageal cancer. *Brit J Surg* 58: 794-798, 1971
4. Hiroto H: Hypopharyngoesophageal cancer, its surgical treatment. *Kurume Med J* 10: 162-172, 1963
5. Langman MJS: Epidemiology of cancer of the oesophagus and stomach. *Brit J Surg* 58: 792-793, 1971
6. Harrison DFN: Surgical management of cancer of the hypopharynx and cervical oesophagus. *Brit J Surg* 56: 95-103, 1969

CHANGES IN THE RESPIRATORY ACTIVITY OF THE CRICOTHYROID MUSCLE WITH INTRATHORACIC INTERRUPTION OF THE VAGUS NERVE

HIROYUKI FUKUDA, M.D.

JOHN A. KIRCHNER, M.D.

NEW HAVEN, CONNECTICUT

Why does the paralyzed vocal cord sometimes lie in a partly abducted or intermediate position if the interruption of its motor innervation occurs within the chest rather than in the neck? The paramedian position that results from interruption of the recurrent laryngeal nerve (RLN) within its cervical portion has been amply documented and is generally attributed to the adductor action of the cricothyroid muscle.

A more lateral position of the paralyzed cord is often seen in cases of esophageal or bronchogenic carcinoma, involving the nerve at its point of origin from the vagus. This partly lateralized position has been reported for over a century and was attributed by early observers to a gradually progressive paralysis of the adductor and abductor muscles culminating in an intermediate or "cadaveric" position of the cord.¹⁻³ Cricothyroid muscle (CT) activity was generally overlooked as a source of vocal cord adduction.

A later explanation is that of Hofer who reported a cadaveric position in each of two cases of bronchogenic carcinoma; in one, carcinoma of the esophagus and in one, aortic aneurysm. In these cases the left vagus nerve was completely surrounded by cancer or, in the aneurysm, splintered out into

fine branches. Hofer observed that a paralyzed vocal cord assumes the intermediate position if the vagus nerve is interrupted. If only the RLN is interrupted, however, the cord position is paramedian. He proposed the explanation that tigrolytic degeneration of the ganglion cells in the nucleus ambiguus results from vagal interruption, and that this might lead to paralysis of the cricothyroid muscle.⁴

One major objection to this explanation is that the intermediate position of the paralyzed cord may be observed almost immediately after injury to the motor nerve supply within the chest, as after a cardiothoracic operation.⁵ These patients are sometimes seen in the recovery room completely aphonic and unable to close the glottis enough to prevent aspiration when swallowing liquids. The recovery of vocal cord function within a few weeks or months, in many of these patients, also suggests a cause that is mechanical or reflex rather than degenerative.

The mechanical or reflex concept gains further support from the observations of Suzuki et al. who demonstrated that the motor activity of the CT muscle changes quickly in response to variations in intrathoracic pressure. Whether the source of afferent stimuli is in the

From the Section of Otolaryngology, Department of Surgery, Yale University School of Medicine.

Supported by USPHS Grant 2 RO1-NS-05465.

lung or in the chest wall was not determined in that study.

If the regulatory mechanism depends on pressure receptors within the lung itself, then the CT muscle should be influenced by the Hering-Breuer mechanism just as other respiratory muscles. More important, an intact vagus nerve would be essential for its function, since it conveys the necessary afferent information from the lung to the central nervous system.

The present study was undertaken to determine whether vagal afferents originating in the lung influence CT muscle activity and, therefore, vocal cord position.

METHODS

Thirty-one healthy adult cats weighing more than 2 kg were anesthetized with intraperitoneal pentobarbital sodium (Nembutal®), dosage 25 to 35 mg/kg body weight. A constant level of anesthesia was maintained by subsequent injections. A median cervical incision was performed to expose the larynx and trachea. The sternohyoid and sternothyroid muscles were removed for exposure of the CT muscle. Electromyogram (EMG) of the CT muscle was recorded by using special spiral copper wire electrodes to eliminate movement artifacts.

Both recurrent and vagus nerves were freed of surrounding tissues very carefully so as to avoid injury. For blocking the vagi, topical anesthesia with 2% Xylocaine® was used. Tension was applied by pulling the vagi with thread. Pressure was applied by pinching the nerve with fine forceps. Respiration was monitored by recording the EMG of the external intercostal muscles simultaneously with that of the CT muscle.

The electrical activity of the CT muscle and the external intercostal muscle was displayed on Tektronix 561 and 564 oscilloscopes after amplification by the Tektronix 122. Photographs of sweeps on the oscilloscope were taken with the Grass camera.

RESULTS

Pressure on Ipsilateral, Contralateral and Bilateral Vagus Nerves. A remarkable decrease in CT activity was observed during pressure applied to the vagus. The decrease was most marked when both vagi were compressed simultaneously and least marked when the contralateral vagus was compressed (22 of 31 cases) (Fig. 1).

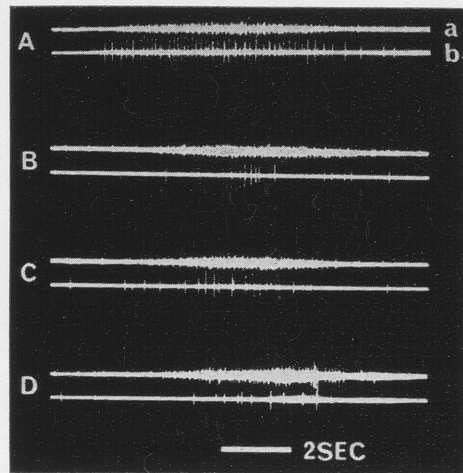


Fig. 1. Inhibition of cricothyroid muscle activity as a result of pressure applied to the vagus in the lower neck. a) Upper beams: EMG of external intercostal muscle; b) Lower beams: EMG of cricothyroid muscle. A) Activity of cricothyroid muscle after section of both RLN's vagi are intact. B) Pressure applied to ipsilateral vagus. C) Pressure applied to contralateral vagus. D) Pressure applied to both vagi.

Differences Between Tension and Pressure. Tension, applied by pulling the vagus with a thread, abolished spontaneous activity in the CT muscle but only while tension was being applied. It had no inhibitory effect on the activity during the ensuing inspiration, even with strong tension (Fig. 2).

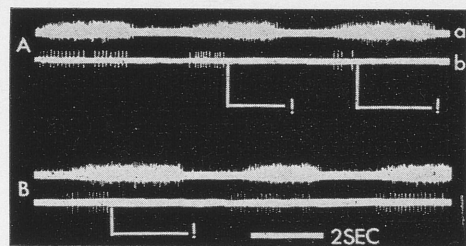


Fig. 2. Inhibition of cricothyroid muscle activity by tension applied to ipsilateral vagus nerve. a) Upper beams: EMG of external intercostal muscle; b) Lower beams: EMG of cricothyroid muscle. (Solid lines show duration of tension). A and B) Continuous recordings. Note that cricothyroid activity is inhibited only while tension is being applied to the vagus. The ensuing inspiratory phase is not affected.

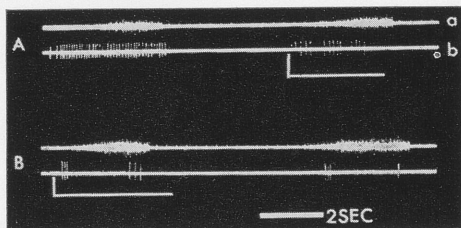


Fig. 3. Inhibition of cricothyroid muscle activity by pressure applied to ipsilateral vagus. (Solid line shows duration of pressure). a) Upper beams: external intercostal muscle; b) Lower beams: cricothyroid muscle. A) Light pressure. B) Strong pressure. Note that strong pressure causes greater inhibition of cricothyroid muscle activity while being applied and, in addition, inhibition of the ensuing inspiratory phase.

By contrast, pressure applied to the ipsilateral vagus with a fine forceps inhibited the ensuing activity of the CT muscle for one or more inspiratory phases, depending on the strength of pressure (Figs. 3 and 4). If the forceps pressure was sufficient to injure the nerve there was permanent abolition of CT activity.




Fig. 4. Prolonged inhibition of cricothyroid muscle activity by strong pressure applied to ipsilateral vagus nerve. (Solid line indicates duration of pressure). A and B) Continuous tracings. Note that cricothyroid activity is abolished for four inspiratory cycles.

Effect of Topical Anesthesia. Two percent Xylocaine was carefully applied to the vagus, so as not to affect other nerves or the muscle itself. Activity of the CT muscle disappeared for almost two hours. A constant level of general anesthesia was maintained during this time, so that CT muscle activity returned to the same level after the effect

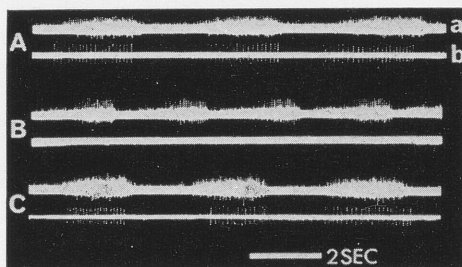


Fig. 5. Disappearance of cricothyroid muscle activity after topical anesthesia applied to ipsilateral vagus (2% Xylocaine). a) Upper beams: EMG of external intercostal muscle; b) Lower beams: EMG of cricothyroid muscle. A) Before topical anesthesia. B) Immediately after topical anesthesia. C) After two hours.

of the topical anesthesia had worn off (Fig. 5).

Effect of Vagal Pressure on the Activity of the Cricothyroid Muscle Induced by Obstruction of the Tracheal Cannula. Respiratory activity of the cricothyroid muscle shows a remarkable increase with artificially produced dyspnea.⁶ If the tracheotomy cannula was obstructed, cricothyroid muscle activity appeared within a second or two and gradually increased. After about 60 seconds it became irregular and at the same time it was observed that the $p\text{CO}_2$ level had exceeded 40 mm Hg. Although pressure applied to the vagus reduced CT muscle activity when this

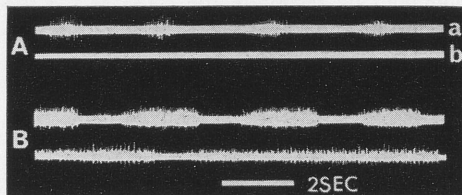


Fig. 6. Increased cricothyroid muscle activity with hypercapnia. a) Upper beams: EMG of external intercostal muscle; b) Lower beams: EMG of cricothyroid muscle. A) After tracheotomy obstruction there is no cricothyroid activity at moderate or deep anesthesia. B) After about 70 seconds of obstruction, irregular activity appeared in the cricothyroid muscle and persisted in spite of pressure applied to the ipsilateral vagus nerve throughout the duration of this tracing. $p\text{CO}_2$ at this time was over 40 mm Hg.

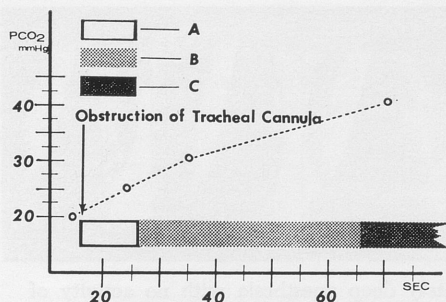


Fig. 7. Graph of activity shown in Fig. 6. Along the baseline: A) Immediately after obstruction of the tracheal cannula at deep levels of anesthesia. No activity is seen at first in the cricothyroid muscle. B) Spontaneous activity appearing in the cricothyroid muscle can now be inhibited by pressure on the ipsilateral vagus. C) At about 70 seconds, the cricothyroid activity becomes irregular and is not influenced by pressure on the vagus. Note that $p\text{CO}_2$ levels during "C" are 40 mm Hg or over.

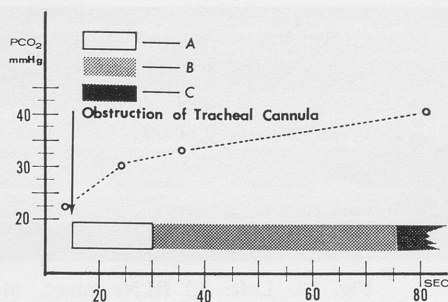


Fig. 9. Graph of case shown in Fig. 8. As in Fig. 7 the irregular contractions of the cricothyroid muscle began after about 75 seconds and at the time that $p\text{CO}_2$ was 40 mm Hg or above. Again, the contractions were not influenced by pressure on the vagus under conditions of hypercapnia.

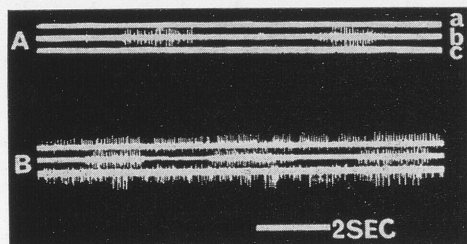


Fig. 8. Control of CT muscle activity by hypercapnia. a) Upper beams: EMG of right cricothyroid muscle; b) Middle beams: EMG of external intercostal muscle; c) Lower beams: EMG of left cricothyroid muscle. A) No activity of cricothyroid muscles immediately after tracheotomy and obstruction during deep anesthesia. B) After 75 seconds irregular activity appeared in the cricothyroid muscle and persisted in spite of pressure applied to the ipsilateral vagus. At this time $p\text{CO}_2$ was over 40 mm Hg.

activity was regular, it had no effect on CT activity once it had become irregular. The regularity of CT activity was closely related to $p\text{CO}_2$ levels (Figs. 6, 7, 8 and 9).

Vocal Cord Position Related to Vagal Afferents from the Thorax. Vocal cord position was observed during these vagus blocking maneuvers. First, the cords were observed preoperatively. With moderate or deep anesthesia vocal

cord position was almost intermediate, with little respiratory movement. With light anesthesia cord movement increased. The left RLN was then cut in the neck, whereupon respiratory movements of the left vocal cord ceased abruptly. The left vocal cord occupied a paramedian position and EMG activity of the CT muscle appeared. The ipsilateral vagus was then compressed with forceps, whereupon the CT activity stopped immediately and the vocal cord moved to a more lateral position (Fig. 10A and B).

The change in position of the vocal cord is difficult to photograph, partly because of the necessity of exposing the glottis with a laryngoscope, a maneuver which stretches and distorts the vocal cords. For this reason, subglottal pressure was recorded in four cats after bilateral RLN section as an indicator of glottal area. When the CT muscle contracted, a difference of 12 mm H_2O was observed in subglottal pressure between inspiration and expiration. When the CT muscle was inactive, the pressure difference never exceeded 6 mm H_2O . As one would expect, glottal space decreases when the CT muscle contracts alone, and increases when it relaxes (Fig. 11).

DISCUSSION

The present study indicates that with normal blood gases and with a uni-

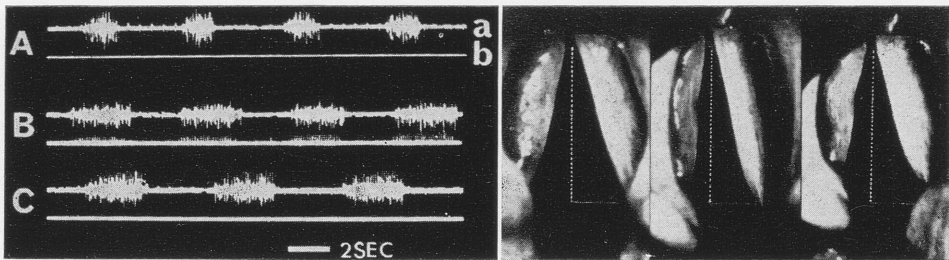


Fig. 10. Left: A) RLNs intact. Moderately deep anesthesia with no activity of cricothyroid muscle (b). EMG of diaphragm shown in (a). B) Cricothyroid activity appears as general anesthesia becomes light. Left RLN cut. Vocal cord moves closer to midline. C) Ipsilateral vagus nerve now compressed. The cricothyroid activity abolished. Vocal cord moves to a more lateral position. Right: Vocal cord positions related to tracings to the left.

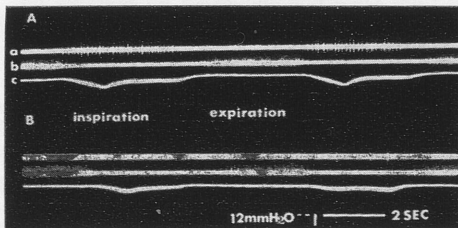


Fig. 11. Variations in subglottal pressure during inhibition of cricothyroid muscle activity. Both RLN are cut, trachea intact. Subglottal pressure measured by needle inserted through anterior tracheal wall. a) EMG of cricothyroid muscle; b) EMG of internal intercostal muscle, signalling expiration; c) subglottal pressure. A) Cricothyroid muscle contracts during inspiration and subglottal pressure drops 12 mm H₂O. B) The ipsilateral vagus nerve is being compressed and cricothyroid activity is inhibited. Under these conditions subglottal pressure drops only 6 mm H₂O.

lateral RLN paralysis, interruption of the ipsilateral vagus in the chest or low in the neck inactivates the CT muscle and allows the vocal cord to assume a more lateral position.

In the present study, blocking the vagus produced entirely different effects in the activity of the CT muscle and of the intercostal muscles. Whereas CT

activity was markedly depressed when the vagus nerve was blocked low in the neck, intercostal muscle activity was not affected.

A more powerful regulatory influence on the respiratory activity of the CT muscle appears under abnormal conditions, with changes in the blood gases. Whereas vagal blocking reduces CT activity at normal levels of pCO₂ (25 mm Hg) it has no effect when pCO₂ is 40 mm Hg or more. It appears then that as pCO₂ rises beyond normal limits, the resultant chemical changes in the blood exert a more powerful influence on the respiratory center than does information arising in pulmonary pressure receptors.

Injuries or diseases which interrupt the vagus in the neck or in the thorax in such a way as to involve both the recurrent and vagus nerves can result in a paralysis of the vocal cord in a partly abducted or intermediate position. This may be responsible for the aphonia, aspiration and absence of cough often observed in patients with cancer of the upper esophagus or lung, or in patients immediately after cardiovascular operations.

YALE UNIV. SCHOOL OF MEDICINE, NEW HAVEN, CONN. 06510

REFERENCES

1. Gerhardt C: Studien und Beobachtungen über Kehlkopf lähmung. Virchow's Arch 27: 88, 1863
2. Mackenzie M: Diseases of the Throat and Nose. Philadelphia, P. Blakiston, 1880, p. 440
3. Semon F: On the proclivity of the abductor fibres of the recurrent laryngeal nerve

to become affected sooner than the adductor fibres. Arch Laryn II: 197-222, 1881

4. Hofer G: Untersuchungen bei Lähmungen der motorischen Kehlkopfnerven. Acta Oto-laryng 43:100, 1953

5. Lewy RB, Mathews R: Immediate temporary restoration of glottic valve function. Laryngoscope 75: 1348-1351, 1965

6. Suzuki M, Kirchner JA, Murakami Y: The cricothyroid as a respiratory muscle. Ann Otol 79: 76-984, 1970

BILATERAL VOCAL CORD PARALYSIS OF UNDETERMINED ETIOLOGY CLINICAL COURSE AND OUTCOME

H. BRYAN NEEL, III, M.D.

GARY L. TOWNSEND, M.D.

KENNETH D. DEVINE, M.D.

ROCHESTER, MINNESOTA

Vocal cord paralysis generally is a sign of disease involving the recurrent laryngeal nerve somewhere in its pathway from the jugular foramen to the larynx. Less often, such paralysis reflects central nervous system disease. The causes and classification of vocal cord paralysis have been discussed extensively in the literature.^{1,2} Although vocal cord paralysis is readily detected by indirect laryngoscopy, thorough examination may fail to disclose the cause. The outcome of patients with unilateral vocal cord paralysis of undetermined origin has been reported,^{2,3} but the outcome of patients with bilateral vocal cord paralysis of undetermined origin has not been adequately studied. The physician naturally wonders how thorough the clinical examination need be in attempting to find a cause of the vocal cord paralysis in such patients. Hence, this study was undertaken to assess the incidence, clinical course, and ultimate outcome of patients with bilateral vocal cord paralysis of undetermined cause.

In the 15 year period, 1956 through 1970, 1,088 patients with vocal cord paralysis were seen at the Mayo Clinic. Of these, 202 (18%) had bilateral paralysis. In 13 (6% of 202), no cause for the paralysis was found initially after thorough examination (Table I). These nine males and four females ranged

from 32 to 73 years of age with a fairly equal distribution over the range.

TABLE I
CLASSIFICATION OF VOCAL CORD
PARALYSIS ACCORDING TO CAUSE

Cause	Patients	
	No.	%
Thyroid operation	153	76
Cancer	17	8
Neurologic disease	13	6
Idiopathic	13*	6
Cardiovascular	3	1
Trauma	2	1
Congenital	1	<1
Total	202	

* Definite cause subsequently found in one, and probable cause in two others.

METHOD

All patients had general medical and neurologic examinations and laboratory studies consisting of a hemogram, urinalysis, fasting blood sugar, serologic test for syphilis (VDRL), and thoracic roentgenogram. Most had determinations of blood urea nitrogen and serum creatinine, electrolytes, and total and free thyroxine. When indicated, esophagrams, suspension laryngoscopy, bronchoscopy, and esophagoscopy were performed. At bronchoscopy, secretions were aspirated for cytologic study and cultures. When the VDRL was positive or when central nervous system disease was suspected, lumbar punctures were performed and appropriate examinations of the cerebrospinal fluid were performed.

In 11 cases, follow-up information was obtained one to ten years after

diagnosis at this clinic. One patient was lost to follow-up four months after initial diagnosis, and no follow-up could be obtained for another. The following case reports illustrate pertinent or unusual findings, particularly in regard to the upper parts of the respiratory and digestive systems.

REPORT OF CASES

Case 1. A 36-year-old male had had increasing exertional dyspnea and nocturnal aerophagia for five years. He had smoked one pack of cigarettes per day for most of his life. According to the patient, direct laryngoscopy one year after the onset of symptoms showed paralysis of the left vocal cord. Indirect mirror examination of the larynx at this clinic showed fixation of both vocal cords in the paramedian position. No other abnormalities were seen. Results of laboratory studies, including a thoracic roentgenogram, were normal. Tomograms of the larynx and trachea showed questionable thickening of soft tissues in the region of the vocal cords. Direct laryngoscopy and bronchoscopy showed only the fixed vocal cords. Because his normal activities were uncompromised, the patient was dismissed. He was advised to have complete physical and laryngologic examinations at six month intervals. His condition was unchanged nine years later.

Comment. This is a typical case of bilateral vocal cord paralysis for which no cause could be found.

Case 2. A 32-year-old geologist had noted gradually increasing muscular weakness and mild exertional dyspnea for four years. Because of sudden onset of nonfluctuating hoarseness, direct laryngoscopic examination was performed; after this procedure, tracheotomy was required to relieve airway obstruction. He then sought consultation at the Mayo Clinic. On examination here, both vocal cords were fixed in the midline. Results of neurologic and laboratory examinations, including electromyographic studies of peripheral muscles, were normal. Although there was no objective evidence for a diagnosis of myasthenia gravis, subjective improvement in breathing occurred after the administration of edrophonium (Tensilon®). On the basis of this response, he was treated for myasthenia gravis.

He failed to return for regular examinations but six years later he was referred for arytenoidectomy. His symptoms had not changed, and both cords were immobile and in the midline. Neurologic findings were again unremarkable except for the vocal cord paralysis. Suspension laryngoscopy was advised. A hard mass was found in the postcricoid region and a biopsy of it revealed grade 2 adenocystic carcinoma. Laryngectomy was performed sub-

sequently. Tumor was found involving the inferior surfaces of both true vocal cords, most of the subglottic region, and the right lobe of the thyroid gland. He remained free of disease for three years and then several subcutaneous nodules of tumor appeared around the tracheal stoma. The area was tender and painful, so cobalt-60 therapy was given, four years after the diagnosis was made.

Comment. This is the only patient in the group in whom a definite cause for the vocal cord paralysis developed. In retrospect, the direct laryngoscopic examination should have been repeated when no objective evidence for myasthenia gravis could be obtained. This case also exemplifies the hazard of direct laryngeal manipulation in patients with compromised vocal cord function, namely, airway obstruction which sometimes requires immediate tracheal cannulation.

Case 3. A 60-year-old attorney had an elective cholecystectomy under general anesthesia (cuffed endotracheal tube) at this clinic. Increasing inspiratory stridor 15 to 20 minutes after extubation progressed to upper airway obstruction, cyanosis, and respiratory arrest. Ventilation with oxygen by mask and administration of atropine and Prostigmin® produced immediate relief of the airway obstruction, and spontaneous respiration resumed. The patient noted the onset of exertional dyspnea, wheezing, and a dry cough shortly after dismissal from the hospital; two and one-half years later, when he was hospitalized for treatment of bronchopneumonia, audible stridor and hoarseness began.

At the time of examination here, three and one-half years after the cholecystectomy, he complained of persistence of symptoms as well as copious clear sputum in the morning and moderate dyspnea on exertion. Although indirect mirror examination of the larynx one year prior to the endotracheal intubation had revealed nothing abnormal, examination now showed complete paralysis of both vocal cords in the paramedian position and a 3 mm glottic space. Except for the vocal cord paralysis, hypertension, and inguinal hernias, findings on physical examination were unremarkable. All laboratory values were normal except for the serum creatinine which was 1.85 mg/100 ml, presumably as the result of hypertensive renal changes. A thoracic roentgenogram showed left ventricular hypertrophy, unchanged since his first visit to this clinic. No therapy for the vocal cord paralysis was advised at that time.

The patient returned to this clinic for elective herniorrhaphy five years after his first visit. Bilateral vocal cord paralysis was again noted. Thoracic roentgenograms and laboratory data were unchanged. Operation was performed with general anesthesia administered by mask, and postoperative recovery was uneventful.

This patient may have had underlying but asymptomatic vocal cord disease which first became apparent after endotracheal intubation. On the other hand, because the patient had no laryngeal symptoms prior to endotracheal intubation, the vocal cord paralysis could have been related to the intubation. Symptoms of airway compromise began after this and became worse during a respiratory infection. Reexamination five years after endotracheal intubation again showed the bilateral vocal cord paralysis.

Comment. When feasible, either local or spinal anesthesia is advised in patients with known bilateral vocal cord paralysis. Otherwise, the surgeon must be prepared to perform a tracheotomy at the termination of the procedure. The following case is illustrative.

Case 4. A 43-year-old female was hospitalized for evaluation of exertional dyspnea, hoarseness, and a persistent but nonproductive cough. Her symptoms had begun three months earlier during a febrile illness described as "the flu." No primary cardiac or pulmonary disease was detected. All laboratory studies, including thyroid scan, thoracic roentgenograms, mediastinal tomograms, and esophagram, gave normal results. Pulmonary function data were compatible with a mild obstructive ventilatory defect; on two occasions the maximum breathing capacity was 31% of predicted, while total vital capacity was 109% of predicted. Indirect laryngoscopy showed complete midline paralysis of the right vocal cord but some movement of the left cord. These findings were confirmed at direct laryngoscopy and no other laryngeal abnormalities were noted. Postoperatively, a tracheotomy was required to reestablish an adequate airway. She was dismissed ten days later with the tracheotomy tube *in situ* and was referred to the Mayo Clinic for consultation.

Except for bilateral midline vocal cord paralysis, otolaryngologic and neurologic findings were unremarkable. The patient was advised that arytenoidectomy could be considered at a later date. At follow-up (by letter) one year later, the tracheal tube had been removed and she had made a partial recovery. Dyspnea and hoarseness continue to recur with upper respiratory infections.

Comment. Four other patients in this series noted that their laryngeal symptoms followed upper respiratory infection. One of these required immediate hospitalization and tracheotomy for midline abductor paralysis and severe respiratory distress. This patient regained partial vocal cord function, and the tracheal tube was removed about six months later. Three of these five patients recovered partial vocal cord function within one year of the onset of paralysis but two have shown no improvement at one, and one and one-half years, respectively. One other patient has had

partial return of vocal cord function, making a total of four in the entire series.

Case 5. For two months, a 74-year-old male had had hoarseness and difficulty swallowing solids. These had begun immediately after a three day febrile illness characterized as "flu and chest cold." Hoarseness subsequently progressed to aphonia. At direct laryngoscopy, both vocal cords were fixed in the cadaveric position. Other than the vocal cord paralysis, there were no abnormal neurologic findings. Airway resistance was symptomatically unchanged by edrophonium (Tensilon). Electromyographic studies of extremity muscles showed normal conduction velocities and distal motor latencies. Esophageal motility studies showed much motor incoordination and a weak upper sphincter. A serum VDRL was reactive at one dilution. Cerebrospinal fluid was normal, and a Kolmer serologic test was negative. A thoracic roentgenogram was normal except for tenting of the left hemidiaphragm, thought to be due to old pleural adhesions. Roentgenograms of the skull were negative. Tracheobronchial aspiration and nasopharyngeal reflux of contrast medium occurred with swallowing during an esophagram. At bronchoscopy and esophagoscopy, nothing was seen to explain the bilateral vocal cord paralysis.

The patient was advised to return in six months for reexamination but has not been seen since his initial examination.

Comment. This case illustrates the concomitant occurrence of bilateral vocal cord paralysis and primary upper esophageal dysfunction.

Case 6. A 51-year-old female was first seen at the Mayo Clinic for nervousness, fatigue, migratory joint pains, and low grade fevers. While complete examination failed to provide a definite diagnosis, the symptoms suggested early collagen disease. She returned four years later, complaining of intermittent sensations of a "lump in the throat," hoarseness, and dyspnea on exertion which began after a febrile illness three months earlier. When she ate, nasopharyngeal regurgitation occurred with ingestion of liquids, and solids met an obstruction in the throat. She had noted a 4.5 kg (10 lb) weight loss.

Indirect laryngoscopy showed midline fixation of the left vocal cord but normal movement of the right cord. There were no findings on physical examination to explain the cord paralysis. Laboratory studies, including thoracic roentgenograms and protein electrophoresis, gave normal results. Roentgenograms of the cervical region of the spinal column and base of the skull demonstrated narrowing of the fourth and fifth interspaces and secondary hypertrophic changes. An esophagram showed a small sliding hiatal hernia. Neither subglottic nor endotracheobronchial disease was found at bronchoscopy.

The small hiatal hernia with minimal esophagitis was seen at esophagoscopy. Antacids and bed elevation were prescribed for this and she was dismissed.

She returned six months later because of nocturnal aerophagia, increasing dyspnea on exertion, stridor, and dysphonia. For two months she had been unable to swallow solids and had restricted her diet to soft foods and liquids. The findings on physical examination were suggestive of a brain stem lesion producing involvement of cranial nerves IX and X bilaterally and cranial nerve XI on the right. While the airway was adequate, there was bilateral paramedian vocal cord paralysis, weakness of the soft palate, and weakness of the right sternocleidomastoid and neck flexor muscles.

All laboratory studies, including a complete examination of cerebrospinal fluid, a PBI determination, and serum thyroxines (total and free), gave normal results. Electromyographic studies of facial and extremity muscles were noncontributory. Esophageal motility studies showed neuromuscular weakness of the upper esophagus and upper sphincter as well as the presence of a hiatal hernia. A myelogram and rhombencephalogram provided no evidence of tumor and were normal. Reexamination six months later provided no new findings and again showed bilateral vocal cord paralysis.

Comment. Difficulty in swallowing experienced by patients with vocal cord paralysis usually consists of episodes of choking and coughing. This has been explained on the basis of laryngeal spasm following aspiration of food or liquids. However, in 4 of our 13 cases, primary esophageal dysfunction was noted. It was documented in two by studies of esophageal motility; in the other two, although motility studies were not done, esophagrams showed pharyngeal and esophageal motor dysfunction as well as tracheobronchial aspiration of contrast material.

DISCUSSION

A diagnosis of vocal cord paralysis of undetermined origin requires that demonstrable causes be excluded. How thorough should the clinical examination be in attempting to uncover known causes? One patient with bilateral vocal cord paralysis was excluded from the study because a definite history of diphtheria in childhood was obtained, and symptoms compatible with upper airway obstruction began with that illness. Basic procedures consist of a history, physical examination, and a stereoscopic roentgenogram of the thorax. Although indirect laryngoscopy dis-

closes the cord paralysis, it may be impossible to visualize all areas of the larynx, particularly the subglottic area, in the presence of vocal cord paralysis. In these cases, or when abnormalities requiring biopsy are seen, direct laryngoscopy should be performed. If roentgenographic examination of the thorax discloses abnormal shadows, an intensive investigation, consisting of examination of the sputum and bronchoscopy, is indicated as emphasized by Huppler et al.³

Definite cause for the vocal cord paralysis was found subsequently in one (Case 2) of the 13 patients studied. One patient (Case 6) was thought to have slowly evolving central nervous system (bulbar) disease after five years of observation. Five patients associated the onset of their laryngeal disease with an upper respiratory infection; these could be classified as "infectious" paralyzes, but we think that such cases are best considered idiopathic until an identifiable agent is directly associated with the vocal cord paresis.

In Case 3 the first evidence of vocal cord paralysis appeared after endotracheal intubation. To our knowledge, the patient had had no laryngeal symptoms prior to operation and had been anesthetized via an endotracheal tube with a cuffed balloon. The surgical procedure did not involve the neck, and there was no visible evidence of trauma from the intubation. This patient therefore fulfills the criteria for vocal cord paralysis following endotracheal intubation recently described by Hahn et al.⁴ who reported five cases of *unilateral* vocal cord paralysis. Based on a report by Gould and Seldon⁵ defective pneumatic cuffs on the endotracheal tube could be implicated; when inflated, such cuffs are irregular and allow direct compression of peripheral branches of the recurrent laryngeal nerves by the endotracheal tube itself or by the smaller inflating tube. Other possible causes are: 1) overextension of the neck during intubation and operation; 2) overexpansion of the cuff; 3) anatomic variations and vulnerability of the

nerve; 4) influence of muscle relaxants; and 5) gas sterilization of the endotracheal tubes.^{4,5,7}

Although the cases of Hahn et al.⁴ were unilateral vocal cord paralysis, it would seem possible that terminal branches of laryngeal nerves to both vocal cords could be injured, particularly since there is marked variation in the branching of the posterior (abductor) branch of the recurrent laryngeal nerve.⁶ Holley and Gildea⁷ have recently reported four cases of bilateral vocal cord paralysis after endotracheal intubation, but one patient had noted symptoms of airway obstruction preoperatively, two had had thyroidec-tomies, and one had had poliomyelitis. The consideration that such patients, including our patient, could have had underlying but asymptomatic disease related to vocal cord function should not be overlooked.

Esophageal dysfunction, characterized by swallowing difficulty without choking and "weakness" of the upper esophagus and upper esophageal sphincter, appearing with bilateral vocal cord paralysis, suggests that there is disease concurrently involving cranial nerves IX and X or the central nervous system. In Case 6, clinical examination showed bilateral involvement of cranial nerves IX and X and probably XI, compatible with central nervous system disease originating in the bulbar area. Motility studies⁸ showing weakness of the upper esophagus and upper sphincter confirmed the clinical impression of involvement of cranial nerve IX. There was no evidence of central nervous system tumor, syphilis, metabolic disease,

or exposure to toxic substances.

The presence of motor activity, albeit weak, throughout the esophagus indicates that cranial nerves IX and X to the esophagus are intact but does not exclude partial loss of innervation. The motor incoordination seen in Case 5 and during esophagrams in two other patients with bilateral vocal cord paralysis is also compatible with involvement of cranial nerves IX and X. It appears that, at least in some patients with concomitant vocal cord paralysis and esophageal dysfunction, the common origin is bulbar disease of unknown etiology.

Treatment for bilateral vocal cord paralysis of undetermined cause depends on the position of the vocal cord and whether stridor is present. In general, if stridor is apparent during normal activity, the glottic space is less than 3 mm and tracheotomy is required. Five patients in this series required tracheotomies; of these, two had adequate airways until direct laryngeal examination precipitated complete upper airway obstruction. In three, transoral arytenoidectomy was performed and the airway was permanently restored. Four patients have had partial return of vocal cord function, all within six months of the onset of upper airway symptoms. For this reason, patients with bilateral cord paralysis of undetermined cause are advised that laryngeal function may return but that arytenoidectomy can be considered at a later time, usually six months to one year after onset of symptoms unless, of course, either airway embarrassment supervenes or recovery occurs.

MAYO CLINIC, ROCHESTER, MINN. 55901

ACKNOWLEDGMENT—We thank Howard A. Andersen, M.D., for interpreting the esophageal motility studies and reviewing the manuscript.

REFERENCES

1. Gorman JB, Woodward FD: Bilateral paralysis of the vocal cords: management of twenty-five cases. *South Med J* 58: 34-37, 1965
2. Huppler EG, Schmidt HW, Devine KD, et al: Causes of vocal-cord paralysis. *Mayo Clin Proc* 30: 518-521, 1955
3. Huppler EG, Schmidt HW, Devine KD, et al: Ultimate outcome of patients with vocal-cord paralysis of undetermined cause. *Am Rev Resp Dis* 73: 52-60, 1956

4. Hahn FW Jr, Martin JT, Lillie JC: Vocal-cord paralysis with endotracheal intubation. *Arch Otolaryngol* 92: 226-229, 1970

5. Gould AB, Jr, Seldon TH: An unusual complication with a cuffed endotracheal tube. *Anesth Analg* 47: 239-240, 1968

6. Hollinshead WH: *Anatomy for Surgeons: The Head and Neck*. New York,

Harper & Row, 1968, pp 489-490

7. Holley HS, Gildea JE: Vocal cord paralysis after tracheal intubation. *JAMA* 215: 281-284, 1971

8. Andersen HA: Dysfunction of the esophagus. *Otolaryng Clin N Amer* June, 1968, pp 195-217

DISCUSSION

FRANCIS L. LEDERER, M.D.: Having stood trial about six weeks ago, laryngeal paralysis is very close to my heart. I think I should share with you some aspects of our behavior as physicians, what we say, what we write and the way we discuss things. The case need not be detailed. There is one aspect however that came out of this same clinic reporting here today that I should make known to you.

The deposition given by a member of this clinic stated that in any case where the etiology was not recognized immediately, exploratory surgery of the neck should be performed. We went over our last 100 cases of recurrent laryngeal paralysis and had found only three cases of thyroid carcinoma, and the case in point in this jury trial was one of them. Therefore, I was in a position to state to the jury that the neck would have had to have been explored 97 times unnecessarily.

I think these remarks by surgeons are ill advised, and when we write up these cases, we must have an awareness that these things can come back to haunt us. I would urge the authors to exercise due care and I would want to exercise the same care in observation of recurrent laryngeal paralysis, many of which have obscure origins. Sometimes the origin is never apparent in the lifetime of the clinician and very frequently in the lifetime of the patient. This is only one facet but it's a rather traumatic experience and I would like to spare the prospective defendant from this.

CHARLES M. NORRIS, M.D.: One aspect of the problem of cord paralysis in which we have recent interest in is the possible correlation of uncontrolled diabetes with cord paralysis otherwise unexplained. The number of

cases we've seen is not large. I believe it's seven at the moment; these have been instances in which thorough study, including thyroid scan and the usual roentgen and endoscopic studies were negative. They were unilateral cases except for one instance of bilateral paralysis, and following control of diabetes there was some return of function in three cases.

Diabetes can be associated with motor neuropathy as we all know and this may occasionally involve the motor nerves of the larynx. I may have missed something in Dr. Neel's beautiful slides and his very fine presentation, but I wonder if any of his patients might have had diabetes previously unrecognized.

This certainly has been a very nice review and I'm very pleased to have heard it.

H. BRYAN NEEL, M.D. (closing): I thank you for the very kind comments. We did look for diabetes, but most of the patients did not have glucose tolerance tests. All of them had fasting blood sugars and in no instance was diabetes implicated. We were aware of the reports associating diabetes and vocal cord paralysis and had been looking for it, but in none of our cases was diabetes implicated.

It has not been since 1955 that our unilateral cases were reviewed by Huppler and Devine and they made no comment concerning diabetes. There were 181 idiopathic cases in the group of 633, and I hope we'll have an opportunity to review those charts, and also undertake a more meticulous clinical study, including in all examinations a glucose tolerance test. Diabetes is certainly something that should be looked for.

HIGH DOSAGE PREOPERATIVE RADIATION AND SURGERY FOR CARCINOMA OF THE LARYNX AND LARYNGOPHARYNX

JOSEPH L. GOLDMAN, M.D.

FREDERICK G. ZAK, M.D.

JEFFREY D. ROFFMAN, M.D.

ERIC A. BIRKEN, M.D.

NEW YORK, NEW YORK

The Combined Therapy Program, initiated in the Department of Otolaryngology at The Mount Sinai Hospital in 1958, represents a long term unified and uncompromising plan of preoperative radiation and surgery for the treatment of advanced cancer of the larynx and laryngopharynx. A detailed discussion of the protocol and statistical analysis of the results of treatment is the subject of another publication.¹

In order to determine precisely the effect of preoperative radiation, an extensive histopathological study of resected larynges and neck specimens was undertaken in 1961. These specimens have been serially sectioned en bloc, in the coronal plane, in celloidin, according to a modification of a technique originally described by Tucker.² The details of this technique have been published elsewhere.³ Each larynx studied consisted of about 1,500 sections and each radical neck yielded approximately 2,500 sections. Each section was cut at approximately 20 microns in thickness and every tenth section was stained with hematoxylin and eosin and examined. Thus, approximately 150 slides were read for each larynx and approximately 250 slides for each radical neck specimen. In order to eliminate the possibility of missing minute foci of cancer in a specimen read as negative, early in this study every fifth section was examined if every tenth section showed no evidence of cancer. It was learned that

no additional information could be obtained by studying every fifth section. Each specimen was studied in its entirety by the pathologist in this program.

In this paper we present the findings obtained from the histological examinations of the radiated laryngeal and radical neck specimens studied. It is hoped that this information will reveal the accomplishments of preoperative radiation and show indications why preoperative radiation provides advantages to the combined therapy method.

METHODS

Between November 1958 and March 1, 1972, 64 patients were treated with combined therapy. All patients were classified as Stage III according to the VII International Congress of Cancer on the basis of initial clinical evaluation. After reclassification according to the criteria of the American Joint Committee for Cancer Staging and End Results Reporting,⁴ there were 20 cases of Stage II (T₂N₀ excluded), 12 cases Stage III and 32 cases Stage IV. All patients had a biopsy proven diagnosis of squamous cell carcinoma.

Combined therapy encompassed three distinct but mutually dependent phases. The first stage consisted of radiotherapy in the form of 5,500 rads of cobalt 60 teletherapy aimed at the primary tumor and neck by parallel opposing portals given alternately to each side of the neck over a five to six week period. The second phase involved a three to six week rest period to allow for healing of radiation reactions. The third stage was the radical surgical procedure which consisted of a wide field laryngectomy, ipsilateral hemithyroidectomy and radical neck dissection. The extent of the operation was determined by the pre-

From the Department of Otolaryngology, The Mount Sinai Medical Center, New York, N.Y.

radiation clinical examination using drawn maps and the radical procedure was performed as if no radiation had been given. A contralateral neck dissection was done whenever indicated.

This report will be concerned with the histological studies and evaluation of 26 larynges and 21 radical neck specimens.

RESULTS

Studies Of Laryngeal Specimens. The larynges of 26 patients treated by combined therapy were serially sectioned and studied according to the methods described. Thirteen patients showed no gross evidence of tumor on indirect laryngoscopy after radiation. Eight of these extirpated larynges, however, had cancer foci on serial section, while three showed evidence of destroyed cancer and there was no indication of any cancer in two specimens. There were nine patients who, in our opinion, presented clinical evidence of residual tumor after radiation. Eight of these larynges did reveal residual cancer, but one specimen contained destroyed cancer. The presence or absence of cancer could not be determined clinically in four patients. Of these, one larynx harbored microscopic evidence of residual tumor and three revealed destroyed cancer remnants on serial section. Thus, of the 26 serially sectioned larynges, 17 revealed residual cancer, seven showed evidence of destroyed cancer, and two showed no evidence of any cancer (Table I). From this analysis it can be seen that nine of the 26 larynges were sterilized by radiation. In other words, our histopathological examinations in-

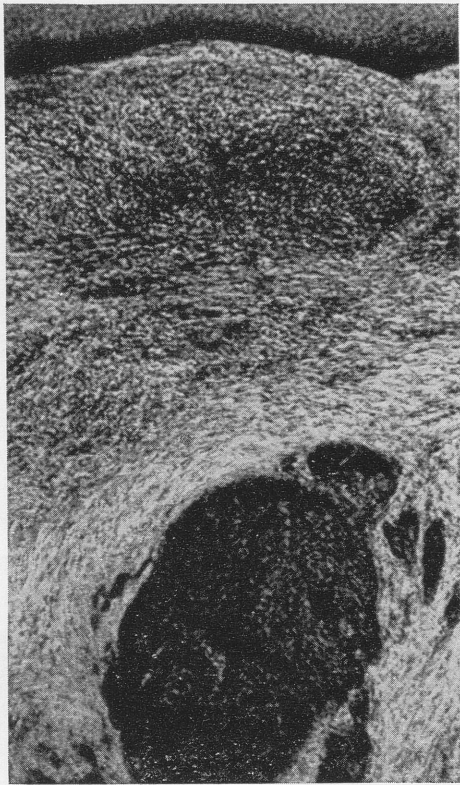


Fig. 1. A nest of residual cancer beneath an intact mucous membrane.

dicated that 34.6% of the larynges studied were free from residual cancer after radiation. It is of interest that four of the sterilized larynges were from Stage II (four of nine or 44%) of the American Classification, two from Stage III (two of seven or 29%) and three from Stage IV (three of ten or 30%). It is of further importance that of the two sterilized larynges in Stage IV and the one in Stage III, the corresponding radical neck specimens contained evidence of metastatic cancer in lymph nodes.

The type of response of the tumor to radiation, as observed histologically, has considerable clinical significance. There were 17 larynges with residual tumor which appeared most often as very small nests of cells scattered anywhere at random throughout the original tumor site. These islands were frequently found at a distance beneath intact mucous membranes (Fig. 1).

TABLE I
SUMMARY OF SERIALY SECTIONED
LARYNGES (26)

Residual cancer	17
Destroyed cancer	7
No evidence of any cancer	2
DISTRIBUTION OF STERILIZED LARYNGES	
9 of 26 = 34.6%	
Stage II	4 of 9 = 44%
Stage III	2 of 7 = 29%
Stage IV	3 of 10 = 30%

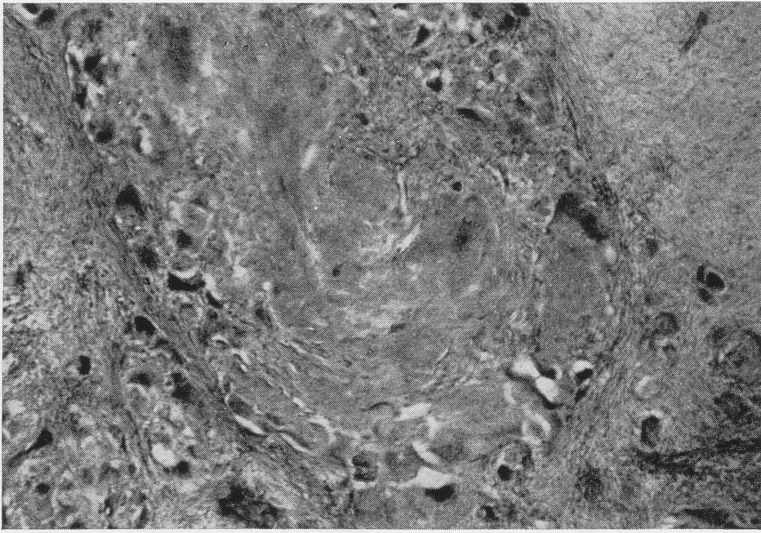


Fig. 2. Necrotic cancer represented by keratinous debris.

TABLE II
SIZE OF RESIDUAL TUMOR
ON SERIAL SECTION

0 - 0.5 mm	1
0.5 - 1 mm	4
1 - 5 mm	7
5 - 10 mm	1
More than 10 mm	4

These nests were abundant, of variable size, often as small as 0.5 mm or even less (Table II). The widespread distribution of the tumor nests contradicts the suggestion of many that cancer responds to radiation in a centripetal fashion, leaving a central core of tumor.

The serial section studies have been most informative as to the nature of the radiobiologic process involved in the destruction of laryngeal cancer. The radiation effects on the tumor ranged from intracellular changes in architecture to complete cellular obliteration by fibrous tissue. Initially, tumor cells were seen with pyknotic irregular nuclei and associated cytoplasmic vacuolization. A further stage of cellular deterioration resulted in loss of nuclei and cytoplasm, forming empty or "ghost" cells. When complete destruction of the cancer cells occurred, a core of keratinous debris remained (Fig. 2). As a response to

cellular destruction, a tissue reaction composed of histiocyte and multinucleated foreign body giant cells eventuated, which surrounded the keratinous material, the so-called "tombstone granuloma" (Fig. 3). The end stage of the radiation reaction consisted of complete replacement of necrotic cancer foci with fibrous tissue. The fibrosis seen had replaced all the muscle, mucus glands and connective tissues that previously were infiltrated with cancer (Fig. 4).

There have been several interesting incidental pathologic findings seen in the noncancerous bearing host tissues of the irradiated larynges. The occurrence of extensive mucosal melanosis in one specimen,⁵ and the observation of paraganglia in multiple specimens⁶ have been the subjects of other publications.

Studies Of Radical Neck Specimens. Twenty-one radical neck specimens were serially sectioned. There were 16 specimens with clinically palpable nodes (obligatory neck dissections) and five with no palpable nodes (elective neck dissections) prior to radiation. Ten of the 16 specimens with palpable nodes showed histological evidence of meta-

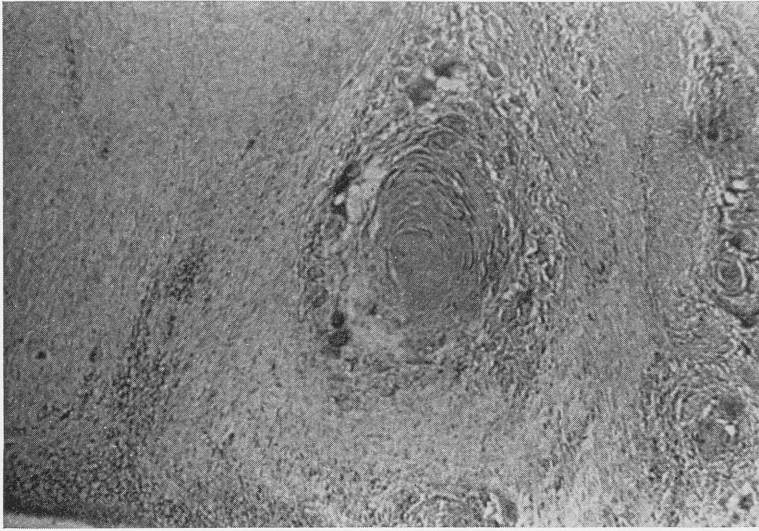


Fig. 3. Central core of keratinous material surrounded by multinucleated foreign body giant cells, "Tombstone Granuloma."

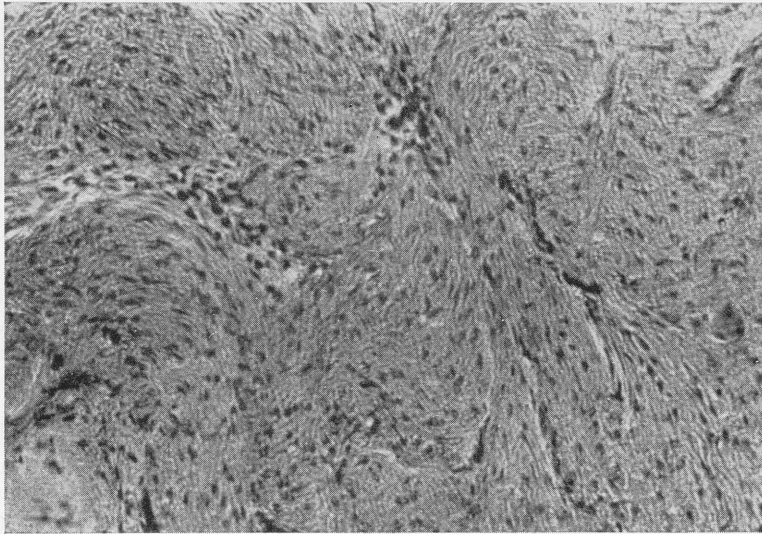


Fig. 4. Replacement of previous cancer by scar tissue.

static cancer; seven revealed cancer cells and three destroyed cancer. The other six specimens had no evidence of any cancer on serial sections. Of the five elective neck specimens, four showed no evidence of any cancer while one specimen contained a lymph node with microscopic evidence of cancer cells (Table III).

The above analysis revealed that

there were ten neck specimens which lacked any evidence of cancer on serial section. Four of these were elective neck specimens and it is presumed that these specimens never harbored occult cancerous nodes. The other six were obligatory neck dissections, and in this group the absence of any cancer implies that these nodes were either inflammatory or the metastatic cancer left no

TABLE III
SERIAL SECTIONED RADICAL
NECK DISSECTION SPECIMENS: 21 (20 PATIENTS)

Clinically palpable nodes preradiation	16
No. clinical palpable nodes preradiation	5
Of 16 neck specimens with clinically palpable nodes preradiation	
Palpable nodes postradiation	11
No palpable nodes postradiation	5
On serial section	
Cancer	7
Destroyed cancer	3
No evidence of any cancer	6
Of 5 neck specimens with no clinically palpable nodes preradiation (elective necks)	
On serial section	
Cancer	1
Destroyed cancer	0
No evidence of any cancer	4

histological evidence of its previous existence (Table IV).

It should be stressed that in all the radical necks studied no evidence of any cancer was found outside the lymph nodes. This observation assumes importance when one considers the effect of preoperative radiation on the incidence of cervical recurrences. Table V lists all the cervical recurrences among 64 patients in the Combined Therapy Program. In this series there were 44 patients with clinically palpable nodes on initial examination. Six patients in this group developed cervical recurrence, a 14% recurrence rate (Table VI).

TABLE IV
SUMMARY OF RADICAL NECK
DISSECTION SPECIMENS (21)

	Obligatory	16
	Elective	5
On serial section		
Cancer	8	(1 elective)
Destroyed cancer	3	of 11 histologically positive)
No evidence of any cancer	10	(4 elective 6 obligatory)

If one recognizes that clinically palpable neck masses occasionally represent inflammatory nodes, it would be important to consider cervical recurrence rates among those patients whose neck specimens contained histological proof of cancer. For this study, a review of both serially sectioned and routinely processed neck specimens revealed a total of 32 patients with histological evidence of cancer in cervical nodes. The neck recurrence rate for this group was 19% (6 of 32, Table VII).

DISCUSSION

The survival rates of patients with advanced cancer of the larynx and laryngopharynx treated with combined therapy have been gratifying. The good results seen in the American Classification Stage IV cases have been the subject of much discussion. We believe that the success achieved in the program has been due to two main factors: 1) the use of high dosage preoperative radiation, and 2) a uniform, consistent and uncompromising method of therapy.

The histological study of our larynges strongly suggests that the absence of gross tumor in the larynx on clinical ex-

TABLE V
CERVICAL RECURRENCE, 64 PATIENTS

	Number	Percent
Ipsilateral cervical recurrence	2	3.1%
Contralateral cervical recurrence	3	4.7%
Both ipsilateral and contralateral recurrence	1	1.6%
Total	6	9.4%

1 patient with ipsilateral cervical recurrence also had distant metastases.

1 patient with contralateral cervical recurrence also had distant metastases.

amination after radiation does not preclude the existence of residual cancer. As has already been indicated, of 13 larynges which grossly appeared free of cancer after radiation, eight showed residual tumor on histological sections. Thus, our serial section studies demonstrate that a negative appearing larynx after radiation can be deceptive and, consequently, a decision not to perform radical surgery can prove disadvantageous to the patient. The fact that the residual nests of tumor were often too small to be seen by the naked eye and that these foci were found under

intact mucous membranes justifies the need to perform surgery on all cases. In addition, cell viability studies using tritiated thymidine have shown that DNA activity occurred in these cancer nests after 5,500 rads had been administered;⁷ also, mitotic figures have been demonstrated in cancer cells after this dosage was given.

The observation that residual squamous cell carcinoma appeared in radiated larynges as small nests of cells distributed randomly throughout the original tumor bed further emphasizes the necessity to remove the same amount of tissue as if no radiation had been given. Maps drawn from the pre-radiation examination should be used for this purpose. These findings indicate that radiation does not cause a centripetal regression of the tumor and emphasizes that surgery can never be reduced in its extent. We feel that our strict adherence to this policy has played a significant role in improving the survival rates of our patients.

Another area of interest has been the effect of preoperative radiation on cervical recurrences. We believe that combined therapy with tumoricidal doses of preoperative radiation contributes to greater cure rates by reducing the incidence of cervical recurrences. The 14% neck recurrence rate among six patients of 44 with clinically palpable nodes prior to treatment tends to substantiate Strong and co-workers⁸ findings of a reduced cervical recurrence rate in patients who received preoperative radiation as part of the treatment of various primary head and neck cancers. In their series, the recurrence rate was

TABLE VI
CERVICAL RECURRENCE
44 PATIENTS WITH CLINICALLY
PALPABLE NODES

Stage	Cases	Cerv. Recur.	%
III	12	1	8.5
IV	32	5	15.6
Combined Total	44	6	13.6

TABLE VII
CERVICAL RECURRENCE
32 PATIENTS WITH
HISTOLOGICALLY PROVED
METASTATIC NODES

Stage	Cases	Cerv Recur.	%
II	2	0	0
III	7	1	15
IV	23	5	22
		(Two patients with distant metastases)	
Total	32	6	19

22% in patients treated with moderately high dosages of preoperative radiation (2,000 rads given over five successive days), versus a 33% neck recurrence rate in nonradiated patients.

The cervical recurrence rate among patients classified as Stage IV by the American Joint Committee for Cancer Staging and End Results Reporting is 16% (5 of 32). This is substantially lower than Ogura and Billers⁹ recent finding of a 46% recurrence rate (6 of 13 patients) in their retrospective study of Stage IV patients receiving 1,500 to 3,000 rads of preoperative radiation in the treatment of advanced cancer of the larynx and laryngopharynx.

As already stated, it is important to consider cervical recurrence rates among those patients whose neck specimens contained histological evidence of cancer. There were 32 patients in this category and the cervical recurrence rate was 19% (6 of 32). Table VII also shows the recurrence rate to be 22% for Stage IV cases. Again, these results compare favorably with Strong and co-workers who reported a 50% recurrence rate in nonradiated patients and a 31% recurrence rate in the radiated group, realizing that their cases represented a variety of head and neck cancers.

The histological findings of our serially sectioned specimens seem to offer possible explanations for our good results. While we have seen areas of apparently typical squamous cell cancer in radiated cervical lymph nodes, the great majority of cancer foci seen in nodes is either necrotic or encapsulated in fibrous tissue. We postulate that higher dosages produce more of these advanced radiation effects, and thus provides greater protection against local spread within the host tissues.

In view of the findings of our serial sections, it might be contended, and correctly so, that we have removed a

number of larynges free from cancer. The observation of histologically sterilized cancer in radiated larynges has been reported by other investigators,¹⁰ and has been one reason for the concept of treating only with radiation and following with surgery if recurrent disease appears. However, as stated previously, in the two serially sectioned larynges in which no cancer could be found and in one larynx with destroyed cancer, the corresponding serially sectioned radical neck specimens contained cancer cells. We believe that this observation is highly significant as it serves to emphasize our contention that it is virtually impossible to predict clinically who will be spared from developing recurrence or metastatic disease. Furthermore, it is well known that the salvage rate is markedly diminished for the treatment of recurrences.

It is our opinion that our study offers sufficient evidence to warrant continuation of our protocol. However, review of our material has made us realize that this study has presented a number of provocative and important issues which are related to the concept of high dosage preoperative radiation. They are 1) the finding of sterilized larynges in 34% of serially sectioned specimens and their relatively uniform distribution among Stage II, III and IV; 2) the random distribution of residual cancer nests throughout the original tumor bed after radiation; 3) the presence of metastatic cancer in the radical neck specimens of three associated sterilized larynges; 4) the observation that radiation sterilized three of eleven histologically proven positive neck specimens, and 5) the dose related effect of radiation on the incidence of neck recurrence. Accordingly, we have decided to continue our histological study so that we can ultimately analyze a higher percentage of radiated larynges and related radical neck specimens.

FIFTH AVE. AND 100TH ST., NEW YORK, N. Y. 10029

Dr. Zak is Attending Pathologist at Methodist Hospital in Brooklyn, N. Y.

REFERENCES

1. Goldman JL, Silverstone SM, Roffman JD, et al: High dosage preoperative radiation and surgery for carcinoma of the larynx and laryngopharynx — a 14 year program. (To be published)
2. Tucker GF Jr: A histological method for the study of the spread of carcinoma within the larynx. *Ann Otol* 70: 910-921, 1961
3. Goldman JL, Cheren RV, Zak FG, et al: Histopathology of larynges and radical neck specimens in a combined radiation and surgery program for advanced carcinoma of the larynx and laryngopharynx. *Ann Otol* 75: 313-335, 1966
4. Smith RR, Caulk RM, Russell WO, et al: End results in 600 laryngeal cancers using the American Joint Committee's proposed method of stage classification and end results reporting. *Surg Gynec Obstet* 113: 435-444, 1961
5. Goldman JL, Lawson W, Zak FG, et al: The presence of melanocytes in the human larynx. (In press)
6. Zak FG, Lawson W: Glomic (paraganglionic) tissue in the larynx and capsule of the thyroid gland. *Mount Sinai J Med* 39: 82-90, 1972
7. Goldman JL, Friedman WH: The intranuclear tracer, cell viability and preoperative irradiation. *Laryngoscope* 77: 1315-1327, 1967
8. Strong EW, Henschke UK, Nickson JJ, et al: Preoperative x-ray therapy as an adjunct to radical neck dissection. *Cancer* 19: 1509-1516, 1966
9. Ogura JH, Biller HF: Preoperative irradiation for laryngeal and laryngopharyngeal cancers. *Laryngoscope* 80: 802-810, 1970
10. Bryce DP, Rider WD: Preoperative irradiation in the treatment of advanced laryngeal carcinoma. *Laryngoscope* 81: 1481-1490, 1971

DISCUSSION

DANIEL MILLER, M.D.: I feel like the Internal Revenue Service following Dr. Goldman around from the Triological to here, but I must confess as a result of a few slides I will show you, his skirts are really clean! We are quite impressed with what Dr. Goldman has contributed to this field.

There is a prognostic value to one section of his paper which I'd like to discuss briefly and that relates to the significance of the nodes, whether histologically positive or negative.

(Slide) — This is a series which we present only briefly. What I want to say about the nodes is that if you have a patient with supraglottic carcinoma with N-O nodes he has a 70% chance for cure. With N-1 it is reduced to 50% chance for cure, but when we find nodes that are N-2 and N-3 (15 in our series), as we add these up, only 20% in this group actually were cured. So we have a much better chance of cure with N-O or N-1 nodes.

What happened to these clinically positive nodes? As Dr. Goldman has so well shown, if you look at the clinical staging, N-O which is when the clinical observer did not feel there were any nodes present, he called it N-O. As you see at neck surgery 48 were still N-O but 12 were found to be positive, and this slide shows that 56 of 80, or 70% of this group, were cured despite the histology of the nodes. This is an important figure for prognostication for cure as we shall show now.

We find in 50 clinical N-1 patients, where palpation revealed definite nodes, there were 32 positive of these 50 at the surgically recovered specimen, and 18 were found to be negative nodes. Now Dr. Goldman has in-

ferred that some of these may have been inflammatory, and they very well may have been, but if we extrapolate about 20% clinical palpation error here, we still have a very fair number of nodes that were sterilized by radiation therapy, and we used only 4500 r in our specimens.

(Slide) — And, here to show there is less significance to the finding of the histological status of the primary prognostically versus the finding of positive nodes, we note that in those patients with positive residual primary and residual positive nodes, we had only a 33% cure rate.

If we had no residual positive primary, but a positive node, the figure was still only 37%. If we had a positive residual primary and negative nodes, it is a significantly different matter. The presence of tumor still in the nodes is still the most important thing, because even with the primary still being residual, plus negative nodes, we had a 68% cure date. If both nodes and primary were negative, the cure rate for supraglottic carcinoma rose to 86%.

What we have found here in this brief review is that if the clinically palpable nodes in the specimen were sterilized by radiation, the chances are that you have double the chance for a cure — that is, if the nodes were made negative rather than if they were still positive. From our studies 34% of the patients with nodes that were still positive at surgery, and 74% whose nodes were or had been made negative were cured. One can be assured that the chance of cure as a result of this study is twice that than if the radiotherapist had steril-

ized the nodes with irradiation, or they were negative at the onset.

Therefore, to go back to Dr. Goldman's premise: preoperative radiation has a definite curative effect on the neck specimen even with involved nodes, as well as on the primary. His report is significant proof for the continuation of this work.

JOHN A. KIRCHNER, M.D.: I have just one question. I really enjoyed these papers and I have to congratulate Dr. Goldman on his beautiful sections, and both essayists on their follow-ups and studies. I'd like to ask however what is a sterilized larynx? What, Dr. Miller, are sterilized nodes? I've been impressed with one thing as I've looked through my own sections, that if you find nests of obvious cancer cells, then you have something definite. If you don't find nests of cancer cells, you really don't know anything! You can't say there is no cancer there. What is a sterilized larynx? Is this a larynx where not

a single cell was found, or is this a larynx where "burned-out" cancer cells were found?

I particularly liked Dan Miller's follow-up because the only thing that counts in cancer is whether your patient is alive at five years without cancer, regardless of what your sections show.

I think these sections are very important. I'm doing it myself and I'm very much impressed with the information we're getting, but can we really say that a T3 or T4 lesion has been cured by radiotherapy?

JOSEPH L. GOLDMAN, M.D. (closing): I appreciate Dr. Miller's and Dr. Kirchner's comments. What is a sterilized larynx? We tried to show a number of sections that we studied and we believe that if you examine every tenth section and do not find any cancer cells, no cancer is present. We can also prove this mathematically. First we examined every fifth section, but we found this was unnecessary.

COMPLICATIONS ASSOCIATED WITH COMBINED THERAPY OF ORAL AND PHARYNGEAL NEOPLASMS

ROBERT G. SMITS, M.D.

CHARLES J. KRAUSE, M.D.

BRIAN F. McCABE, M.D.

IOWA CITY, IOWA

The use of preoperative radiotherapy in the treatment of certain head and neck neoplasms has become standard therapy in many centers today. Although controversy still exists as to the exact dosage of preoperative radiation to be used, it is generally felt that use of a combination of radiation therapy and surgery in treating certain head and neck neoplasms may result in improved survival rates. Attendant with the use of combined therapy has been an increase in postoperative complications.¹⁻³ This paper reviews our experience with postoperative morbidity in patients who have been treated with combined therapy. Our methods of preventing the complications, and their management when they occur, will be presented.

Combined therapy in this institution consists of a planned preoperative course of Cobalt 60 therapy in a dosage of 4400 to 4600 rads given in four to five weeks, followed by surgical resection four weeks later. The surgical resection margins are planned prior to initiating radiation therapy. Neither the dosage used, nor the resection margins are altered by the tumor response to radiotherapy.

CASE MATERIAL

The records of 193 patients undergoing combined therapy for carcinoma of the oral cavity and laryngopharynx from 1965 to 1971 were studied. This included 129 patients with oral cavity neoplasms and 64 patients with neo-

plasms of the laryngopharynx. All patients received 4400 to 4600 rads through parallel opposed fields, ranging in size from 8 x 10 cm to 10 x 17 cm. Cobalt 60 was used in all patients. Initially, the radiation fields included only the primary tumor and adjacent neck. As our therapy evolved, however, the fields were enlarged to include the entire neck regardless of the presence of nodal disease. Patients who received initial radiation therapy elsewhere, or whose initial therapy was for cure, were excluded from this study. All patients subsequently underwent en bloc surgical resection of the primary neoplasm along with the ipsilateral neck dissection four to five weeks following completion of radiation therapy.

COMPLICATIONS

A total of 60 patients developed major complications. Of course, more than one complication was present in many patients. Table I lists the complications and the frequency of their occurrence.

TABLE I
MAJOR COMPLICATIONS

	Oral Cavity	Laryngo- pharynx	Total
Wound Infection	15	25	40 (21%)
Fistula	14	23	37 (19%)
Flap Necrosis	9	13	22 (12%)
Carotid Rupture	0	5	5 (3%)
Osteoradionecrosis	6	1	6 (3%)
Total Major Complications			110

Wound Infection. This was the most common complication seen in our patient population, occurring in 40 of the 193 patients. Wound infection is here defined as a collection of pus beneath the flaps. Patients who subsequently developed a fistula, flap necrosis or carotid rupture are also tabulated in the group with wound infections, as the infection usually preceded the more serious complication.

Pseudomonas aeruginosa was the most commonly cultured organism, followed closely by *Staphylococcus aureus* and *Klebsiella-Aerobacter*. The close association of infection with more serious complications is evidenced by the finding that in only eight patients was a wound infection present without a subsequent fistula or flap necrosis.

Fistula. A salivary fistula developed in 37 of the 193 patients. Fistula formation occurred much more frequently in patients following laryngopharyngectomy or resections of part of the pharynx than following resection of a portion of the oral cavity. Salivary leakage beneath the flaps no doubt predisposed to fistula formation. Salivary leak may be secondary to an inadequate mucosal closure, excessive tension at the suture line, or stress to the suture line on deglutition. Table II presents the time of fistula formation in our patients. The high number of fistulas which ap-

peared after the tenth postoperative day may be related to delayed healing following irradiation.

Flap Necrosis. Extensive necrosis of neck flaps occurred in 22 of the 193 patients. Extensive is here defined as tissue loss greater than 2 x 2 cm. Ten of these patients also had an associated pharyngo-cutaneous fistula. Flap necrosis was associated with a preexisting infection in 19 of the 22 patients. In the other three patients, extensive areas of dry necrosis developed in previously seated flaps.

Carotid Rupture. Spontaneous carotid rupture occurred in five patients. A pharyngo-cutaneous fistula was present in all patients at the time of the carotid rupture. One patient died during the acute episode, while the other four patients were treated with emergency ligation of the common carotid artery without neurologic sequelae. In all five patients, a dermis graft had been used to cover the carotid at the time of resection.

Osteoradionecrosis occurred in six patients in this series. In five of the patients, the primary resection included a portion of the mandible. The sixth patient developed a sequestrum extruding through the skin two years posttherapy.

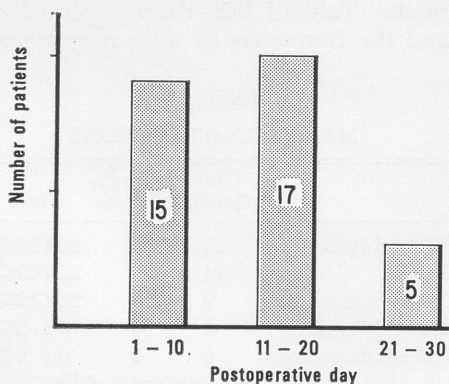
ADDITIONAL COMPLICATIONS

Additional complications included a chylous fistula in three patients, and flap hematoma in two patients. One patient died of a cardiovascular accident on the sixth postoperative day, while two patients died of pneumonia during radiation therapy. An additional complication which is not necessarily related to combined therapy but which was noted in ten patients, was institutionalization for alcoholism during the first postoperative year.

DISCUSSION

Because of the high incidence of complications in our combined therapy patients, a number of techniques have evolved which are designed to reduce the complication rate.

TABLE II
FISTULA FORMATION



The maintenance of good oral hygiene is of paramount importance in the combined therapy patients. Oral moniliasis, mucositis, xerostomia, dental caries, and osteoradionecrosis are all adverse effects of irradiation of the oral cavity. Prior to initiating radiation therapy, all patients undergo a complete dental examination consisting of a) a radiographic examination, b) visual and digital examination of the soft tissue, c) charting of teeth, restorations, carious lesions, and periodontal pockets, and d) evaluation of patient's past home care, and psychological attitude toward maintaining optimum oral hygiene. The majority of the patients included in this study underwent a full mouth tooth extraction prior to initiation of radiation therapy. Radiation therapy is not started until five to seven days post-extraction to allow for soft tissue closure over the exposed mandibular bone.

In the past two years we have modified our dental treatment plan to allow for retention of teeth not in the direct beam of the radiation field if they are physiologically sound, i.e., no evidence clinically or radiographically of disease of the tooth itself or the supporting structures. The patient must also show evidence of the proper motivation to follow a home treatment plan, consisting of daily home fluoride treatment with fluoride gel, monthly dental examinations with application of a more concentrated fluoride solution, and immediate treatment of any carious lesions which appear.

During the hospital treatment period the patient receives conservative periodontal treatment including removal of all local irritants and topical fluoride application as part of the prophylaxis procedure. Whenever possible, a careful attempt is made to shape the upper margin of the radiation field in such a way that some salivary tissue is outside of the direct field. It is our opinion that with improved radiation techniques and proper dental management, many teeth may be saved to aid the patient in post-operative rehabilitation.

All patients are maintained on a high calorie, high protein diet and their weight is monitored twice weekly during radiation therapy. Patients not maintaining their weight are supplemented with nasogastric tube feedings of a balanced formula. Patients are also monitored during the interval between completion of radiation therapy and surgery. Any patient not maintaining his weight or oral hygiene is admitted for dietary supplementation.

Antibiotics are started preoperatively to establish a therapeutic blood level at the time of surgery, and are continued in the postoperative period for seven to ten days.

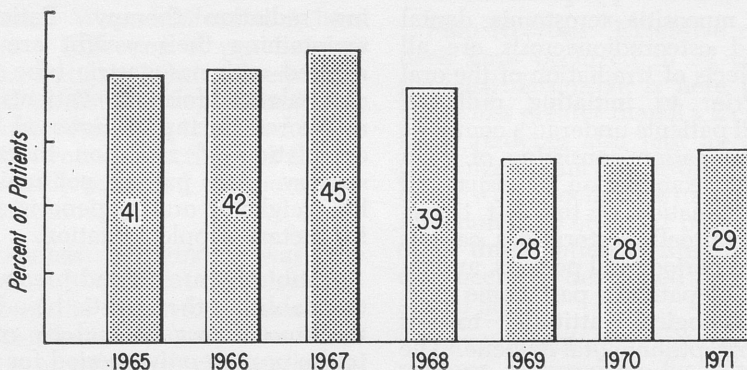
The hypopharynx and oral cavity are closed in three layers without tension. Regional flaps are used when necessary to obtain good closure without tension. A forehead flap is our choice in the oral cavity, and a deltopectoral flap is the most frequently used for closure of large hypopharyngeal defects.

We feel that carotid coverage is mandatory in postirradiation patients. A levator muscle swing was employed early in our series. For the past several years we have used dermis graft exclusively, covering the entire length of the carotid artery.

Hemovac suction drainage is used in all patients undergoing an extensive surgical resection. During the first 48 hours postoperatively the drainage system is carefully monitored and the flaps palpated for evidence of hematoma formation. A collection of fluid beneath the flap in this critical period, if allowed to remain, will usually result in an extensive wound infection. Should a hematoma develop, the patient should be returned to the operating room and the hematoma evacuated. Small collections of fluid which develop later in the postoperative course are usually not as serious, and may be evacuated by aspiration or placement of a small penrose drain.

A nasogastric tube is inserted prior to the surgical procedure and is used

TABLE III
PATIENTS WITH POSTOPERATIVE COMPLICATIONS



for tube feedings in the postoperative period. This decreases stress to the suture line and is continued for at least ten days.

Skin sutures are left in place for 12 to 14 days. If any evidence of a wound infection is present, the sutures may be left even longer, as wound dehiscence may occur even after 14 days in the presence of infection.

TREATMENT

Despite the use of the methods described above, complications did occur. Our present treatment regimen is outlined below.

Wound infection: Wound infections are treated with time-honored methods; establish adequate drainage, provide local wound debridement, and establish therapeutic levels of culture-specific antibiotics.

Fistula: Most fistulas close spontaneously with meticulous wound care and diverting oral intake. Adequate dietary intake may be maintained by nasogastric tube feeding. Persistent fistulas are closed using regional pedicle flaps from outside the radiation field. The use of small local flaps of irradiated tissue alone is rarely successful.

Flap necrosis: Small areas of tissue loss will frequently close spontaneously. Areas of flap loss which expose the dermis graft covering the carotid artery,

heal by reepithelialization of the exposed dermis. Though quite sizeable areas of necrosis will eventually heal, much hospitalization time may be saved by covering the defect with a pedicle flap. In our series of 22 flap sloughs, 12 of the patients went on to spontaneous healing, while ten required either a split thickness skin graft or a pedicle flap.

Carotid rupture: Spontaneous carotid rupture is usually heralded by a small warning bleed prior to the major rupture. At the time of the warning bleed or when the patient has a large area of carotid artery exposed, a carotid rupture protocol is instigated. A cuff is placed on the patient's tracheotomy or laryngectomy tube and a Lore adaptor is inserted. The nursing personnel are advised of the impending emergency and cross-matched blood is readied. A surgical ligation pack is kept at the patient's bedside. Should a carotid rupture occur, bleeding is controlled with digital pressure and the patient is taken immediately to the operating room. The artery is ligated well above and below the rupture site. The four patients in this series who survived the acute episode, lived an average of 11 months with no neurologic deficit. This suggests that salvage of these patients is worthwhile.

Osteoradionecrosis: A strict "hands off" principle is essential in dealing with

this very difficult complication. Good oral hygiene and maintenance of proper nutrition are important, as the bone is allowed to sequestrate spontaneously. Active debridement of bone may result in a progression of necrosis, and eventually loss of the entire mandible. Following sequestration, the defect is covered with a regional flap when necessary.

Table III presents the percentage of patients experiencing postoperative complications for the years 1965 through 1971. With the evolution of the techniques outlined above, our complication rate has decreased from a high of 45% to its present level of 28%.

Although preoperative radiation of 4400 to 4600 rads is associated with an increased complication rate, we feel that this may be reduced to an acceptable level by meticulous preoperative, intraoperative, and postoperative care.

UNIV. OF IOWA HOSPITALS, IOWA CITY, IOWA 52240

SUMMARY

The complications occurring in 193 patients undergoing combined therapy for carcinoma of the oral cavity and laryngopharynx are presented. All patients had received 4400 to 4600 rads of planned preoperative irradiation followed by surgical resection of the primary tumor and ipsilateral neck. Sixty patients (31%) developed significant postoperative complications. Significant is defined as that causing prolonged hospitalization. Wound infection was the most common complication, followed by fistula formation, flap necrosis, and carotid rupture. Methods used to prevent the development of complications are described, and the management of complications that do occur are outlined. The importance of close cooperation between the otolaryngologist, radiologist and dentist handling these problems is stressed.

REFERENCES

1. Goldman JL, Silverstone SM, Rosin HD, et al: Combined radiation and surgical therapy for cancer of the larynx and laryngopharynx. *Laryngoscope* 74: 1111-1134, 1964
2. Rolander TL, Everets EC, Shumrick DA: Carcinoma of the tonsil: A planned combined therapy approach. *Laryngoscope* 81: 1199-1207, 1971
3. Goldman JL, Gunsberg MJ, Friedman WH, et al: Combined therapy for cancer of the laryngopharynx. *Arch Otolaryng* 92: 221-225, 1971

DISCUSSION

DOUGLAS BRYCE, M.D.: I would like to compliment the speaker on this presentation. I think it's interesting because a little earlier this week, we heard three presentations in which preoperative radiotherapy apparently caused no troubles. I commented this was not our experience. I see that it's not the experience of this reporting group.

I think we tend sometimes to forget that before radiotherapy was used preoperatively there were complications of fistula, necrosis,

and infection. I think it would be important to find a series that could be compared with this type of report to see how much the radiation can be blamed for these problems.

In our experience the complication rate with planned preoperative radiotherapy is not nearly as high or as serious as that when surgery is carried out many months after radiotherapy, and when it is not carried out as a planned procedure.

DILEMMA OF DELAYED RADIATION INJURY OF THE LARYNX

THOMAS C. CALCATERRA, M.D.

FLOYD STERN, M.D.

PAUL H. WARD, M.D.

LOS ANGELES, CALIFORNIA

Some degree of laryngeal edema often accompanies curative-dose radiation therapy for laryngeal cancer. Usually the edematous response subsides in four to six weeks; however, in some patients, laryngeal edema will persist for several months or recur after the acute radiation edema response has subsided. Eleven patients from the UCLA and Harbor General Hospitals were reviewed for this study who had sustained either persistent or recurrent laryngeal edema six months after completion of radiation therapy for laryngeal carcinoma.

The pathogenesis of the acute edematous response after high-dose irradiation has been investigated by histologic studies of irradiated larynges.¹ There is a major inflammatory reaction with leukocytic infiltration, vascular thrombosis, and obliteration of the lymphatic channels (Fig. 1). The blocked vascular and lymphatic outflow, in addition to increased vascular permeability, results in the accumulation of excess interstitial fluid (Fig. 2). Several factors may be responsible for a delayed or recurrent edematous response after irradiation. Late obstruction of small laryngeal veins and lymph channels secondary to hyalin degeneration of the vascular walls and proliferation of endothelial cells results in elevated capillary pressure and decreased lymphatic fluid outflow. The result is increased interstitial fluid which sub-

sides as the vascular permeability decreases and new capillaries are formed.

Irradiated laryngeal tissues are more susceptible to infection, probably because of the decreased blood supply. Edema may result from infection of the submucosal tissue, perichondrium, or cartilage. Late infection or necrosis of the laryngeal cartilage after irradiation is well known, and intervals as long as 25 years have been reported.² Cartilage does not demonstrate much early irradiation change because of its hypocellularity, but one does see later loss of chondrocytes and abnormal giant cells. Perichondrium, the sole nutrient source for the cartilage, undergoes thickening and fibrosis (Fig 3). In addition, the advanced age of most patients with laryngeal cancer usually is associated with arteriosclerotic vascular disease which further reduces the blood supply to the larynx. Thus, an irreversible perichondritis or chondritis that does not respond to antibiotics and local management may be precipitated by a mild viral laryngitis or mucocitis secondary to smoking.

The gross characteristics and anatomic location of the laryngeal cancer will affect the healing process after irradiation. Those tumors that are deeply ulcerative, particularly with penetration to the cartilage, tend to heal more slowly than do the superficially invasive types.³ Despite tumor sterilization, delayed edema and mucosal ulcer-

From the Department of Surgery/Head and Neck, UCLA School of Medicine, Los Angeles, Calif.

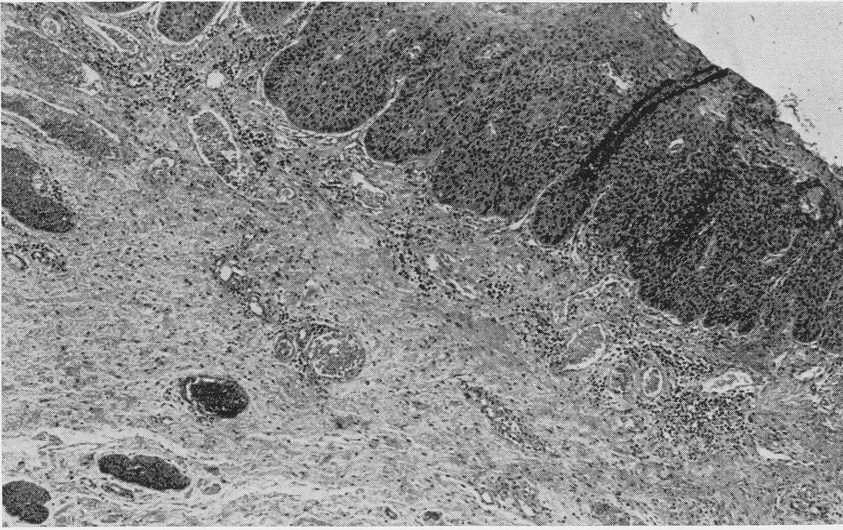


Fig. 1. Leukocytic infiltration and vascular thrombosis characteristic of radiation change.

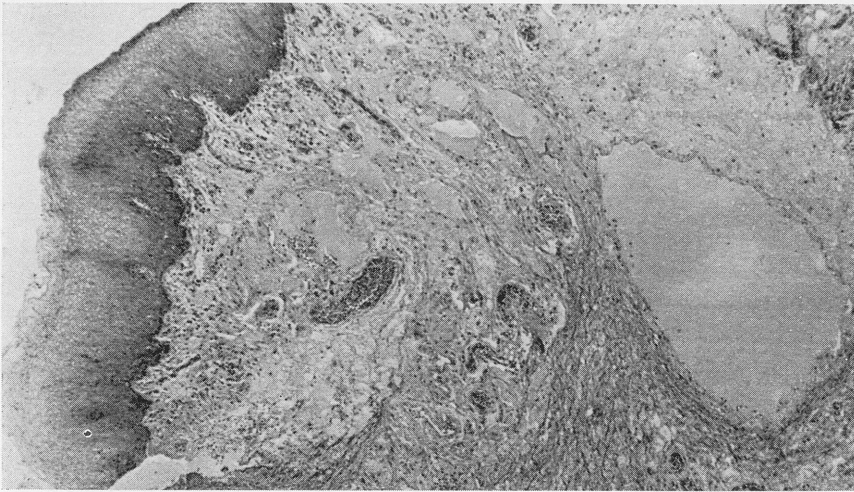


Fig. 2. Typical pools of edema fluid beneath the mucosa.

ation may occur because of persistent bacterial contamination of the deep laryngeal tissues. Laryngeal cancers that are associated with edema prior to irradiation also tend to heal poorly because of the early slough of laryngeal mucosa during the irradiation that allows bacterial invasion of the sub-mucosal tissues. Supraglottic cancers

tend to heal less well and frequently are complicated by edema following irradiation.³

Radiation therapy has been increasingly refined during the past several years with larger generators and fractionation and shielding techniques, but occasionally "hot spots" may result. The

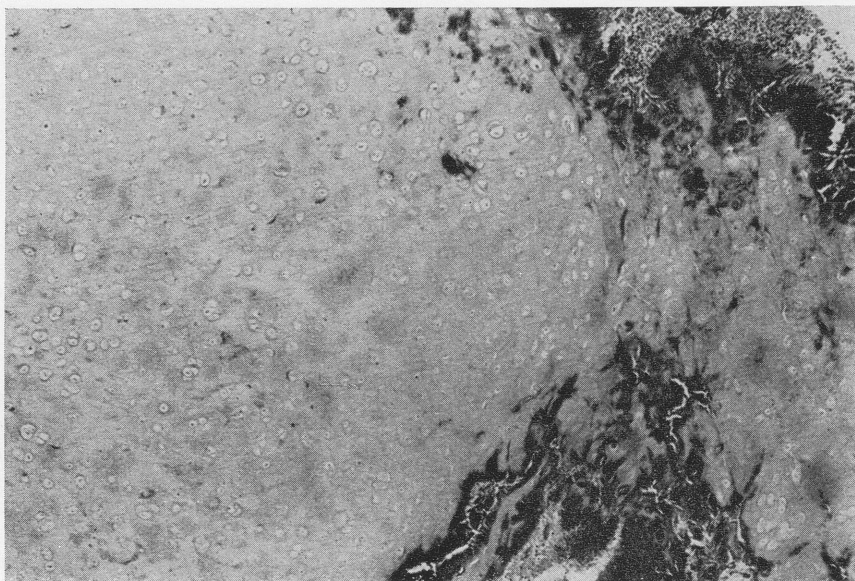


Fig. 3. Laryngeal cartilage undergoing radiation necrosis.

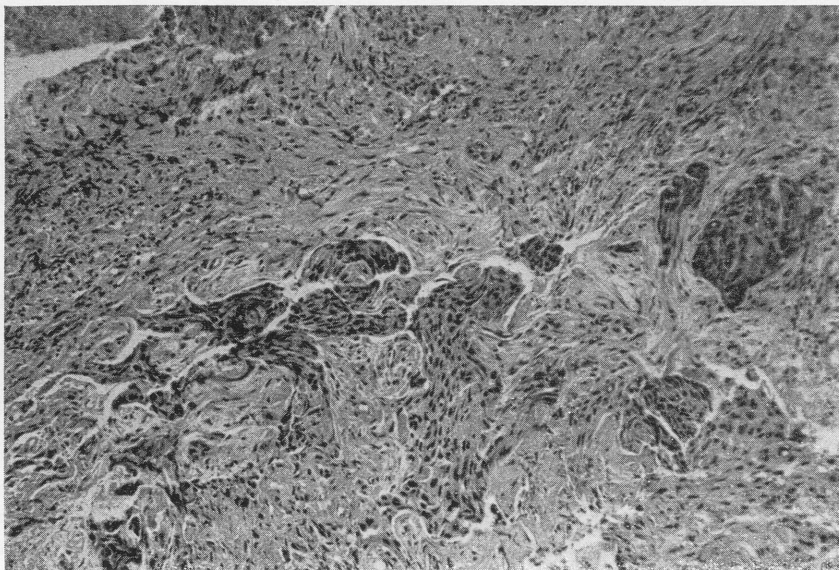


Fig. 4. Microscopic nests of tumor cells in the submucosal tissue.

anterior commissure and entire angle of the thyroid cartilage may receive excessive irradiation which delays healing or results in radionecrosis of the cartilage.⁴ Experience has shown that larger daily doses with shorter total duration of treatment has resulted in an increased incidence of prolonged edema. Larger portal sizes also tend to produce more edema.

Intact, healthy cartilage can tolerate irradiation well, even with relatively high doses. However, factors that compromise the integrity of the cartilage such as tumor invasion, infection, or previous surgical intervention markedly increase the incidence of persistent edema which is often the precursor of radiation necrosis. In our series, the majority of patients who had undergone previous laryngeal operations developed persistent edema.

The laryngologist is confronted with a diagnostic dilemma when evaluating a patient with delayed laryngeal edema after irradiation. The larynx may be tumor-free, and the factors enumerated above may be responsible for the edema. This leads to a reluctance to biopsy the edematous larynx because of the possibility of inciting a fulminating chondritis. More importantly, the value of multiple deep biopsies that do not demonstrate tumor is limited because of the known histopathology of the larynx after irradiation for cancer.⁵ If there is residual tumor, it is often present as tiny nests less than 0.5 mm distributed inconsistently throughout the previous tumor site (Fig. 4). The mucous membrane overlying the residual tumor may appear entirely normal except for the edema. Thus, there is a possibility that the residual tumor may be missed entirely by the biopsies. Conversely, if one chooses to observe the delayed edematous larynx until tumor manifestations are clinically apparent, the chances for a surgical cure may be markedly diminished or lost.

ANALYSIS OF CASES

Moderate to severe edema was seen at least six months after completion of

the radiation therapy in all patients in the present series. Eight of these patients eventually were proven to have residual or recurrent carcinoma. Of the remaining three patients, two had severe cartilage necrosis with a laryngocutaneous fistula as well as a problem with aspiration that necessitated total laryngectomy (Table I).

Although the edema of several patients was localized to an isolated region of the larynx, in the majority of patients, diffuse edema with patchy superficial ulceration was present. In no patient was progressive perichondritis observed after deep biopsy. In three patients, multiple biopsies were required to obtain a diagnosis of residual carcinoma, four laryngoscopies with biopsies being performed on one patient. Only one patient had laryngeal edema documented before radiation therapy. Thus, multiple and repeated biopsies should be performed in suspicious cases to confirm the presence or absence of residual tumors.

When protracted edema was seen following irradiation, antibiotics and steroids were usually instituted before or immediately after laryngoscopy and biopsy. Initial diminution of the laryngeal edema with improvement of the patient's general condition was usually encountered; however, this proved to be transient and of little diagnostic value. When frank necrosis of the laryngeal cartilage occurred without concomitant carcinoma, the progression was relentless despite intensive medical therapy. In these cases laryngectomy was performed to prevent pulmonary complications.

Although partial laryngectomy has been recommended following irradiation therapy for laryngeal carcinoma,⁶ all patients with residual carcinoma in this series underwent total laryngectomy. Surgical intervention was successful in only two of eight patients. Thus, because it is difficult to identify tumor-containing areas in patients who have undergone irradiation and because it can be assumed that edema resulting

TABLE I
CASES: DELAYED RADIATION INJURY OF THE LARYNX

Case No.	Age & Sex	1° Lesion and Staging	Radiation — Modality — Total Dose — Duration	Followings Postradiation Laryngeal Edema Follow-up	Results
1	48 M	Ca-in-situ both true vocal cords (T ₀ N ₀ M ₀)	250 KV 3600 R Duration unknown	6 mos. DL-BX No tumor 9 mos. DL-BX Residual carcinoma Total laryngectomy	Tumor-free 10 years
2	57 M	Carcinoma anterior 1/2 (R) true cord to ant. commissure (T ₁ N ₀ M ₀)	Co ⁶⁰ 6106 R 40 days	10 mos. DL-BX Residual carcinoma. Total laryngectomy with (R) RND	Tumor-free 2 years
3	46 M	Carcinoma (L) vocal cord extending sub- glottically (T ₂ N ₀ M ₀)	Co ⁶⁰ 6422 R 74 days	41 mos. DL-BX carcinoma present Total laryngectomy	Died (2 yrs. postop) with stomal re- currence and chest metastases
4	60 M	Carcinoma (R) true cord to ant. commissure and (L) true cord (T ₂ N ₀ M ₀)	Co ⁶⁰ 6105 R 40 days	11 mos. DL-BX recurrent residual carcinoma Total laryngectomy and neck dissection discontinued because of extension to base of skull	Died postop acute renal failure
5	61 M	Carcinoma entire (R) and anterior 1/3 (L) true cords (T ₂ N ₀ M ₀)	Co ⁶⁰ 6174 R 40 days	4 DL-BX's all nega- tive for tumor until 19 mos. after therapy when he developed a neck mass Total laryngectomy and RND. Tumor found in neck only	Alive with recurrent disease

6	75 M	Carcinoma of base of tongue and supraglottic larynx (T ₄ N ₀ M ₀)	Co ⁶⁰ 7193 R 57 days	9 mos. DL-BX tumor of larynx and tongue Nonresectable	Died with tumor
7	48 M	Exophytic carcinoma of epiglottis, (L) vallecula, pyriform sinus, false cord. No palpable nodes (T ₄ N ₀ M ₀)	6 MeV linear accelerator 3400 R 24 days; 14 day rest. 3600 R 21 days Total 7000 R 59 days	Severe laryngeal edema and necrosis 5-1/2 mos. after therapy Total laryngectomy No carcinoma in specimen	Died with carotid rupture in late postop period
8	58 M	Carcinoma of (R) true vocal cord, false cord and epiglottis - moderate edema present (T ₃ N ₁ M ₀)	6 MeV linear accelerator 3144 R 19 days; Refused surgery. 3186 R 19 days Total 6330 R 65 days	12 mos. DL-BX Residual carcinoma Total laryngectomy with (R) RND	Alive with stomal recurrence 1 year
9	50 M	Primary site: larynx, anatomic extent not available from referral records	Co ⁶⁰ 5694 R 38 days	Severe laryngeal edema and necrosis 6 mos. after radiation, BX negative, with induration and draining sinuses of neck requiring tracheostomy. Total laryngectomy 16 mos. later; no tumor in specimen 24 mos. DL-BX No recurrence	Tumor-free 7 years Died CVA Tumor-free
10	46 F	Poorly differentiated epidermoid carcinoma of larynx with bilat. neck metastasis (T ₃ N ₂ M ₀)	Co ⁶⁰ 6560 R 44 days		
11	61 M	Both true vocal cords (T ₂ N ₀ M ₀)	X-ray 1958 outside details unavailable	3 year post-radiation DL-BX carcinoma	Died

DL-BX: direct laryngoscopy with biopsy; RND: radical neck dissection; R: rads

from such therapy associated with residual carcinoma presages an unfavorable prognosis, we recommend aggressive surgical extirpation of larynx in these patients.

SUMMARY

Delayed or recurrent laryngeal edema following curative-dose irradiation for laryngeal cancer presents a diagnostic problem for the laryngologist. Although the edema may merely represent a pro-

longed response to irradiation, the possibility of residual carcinoma must be considered. Some reluctance to laryngeal biopsy has been exercised to avoid inciting a fulminant perichondritis. A series of 11 patients with delayed irradiation edema is presented, eight of whom had residual carcinoma. Earlier and frequent laryngeal biopsies are recommended for these patients because of the high incidence of residual carcinoma with its poor prognosis.

UNIV. OF CALIF. SCHOOL OF MEDICINE, LOS ANGELES, CALIF. 90024

REFERENCES

1. Manara M: Histological changes of the human larynx irradiated with various technical therapeutic methods. *Arch Ital Otol* 79: 596-635, 1968
2. Robson SC, Daws JDK: A case of perichondritis and necrosis of laryngeal cartilage 25 years after treatment with radium. *J Laryng* 75: 997-998, 1961
3. Goodrich WA, Lenz M: Laryngeal chondronecrosis following roentgen therapy. *Amer J Roentgen* 60: 22-28, 1948
4. Murphy WG: Radiation Therapy. Philadelphia, W. B. Saunders Co., 1959, Chapter 16
5. Goldman JL, Cheren RV, Zak FG, et al: Histopathology of laryngeal and radical neck specimens in a combined radiation and surgery program for advanced carcinoma of the larynx and hypopharynx. *Ann Otol* 75: 313-321, 1966
6. Biller HF, Barnhill FR Jr, Ogura JH, et al: Hemilaryngectomy following radiation failure for carcinoma of the vocal cords. *Laryngoscope* 80: 249-253, 1970

Memorials

HUGH GIBSON BEATTY, M.D.

1880 - 1971

Hugh G. Beatty, a member of this Association since 1932, and a senior member since 1956, died August 31, 1971. At the time of his death, he was Professor Emeritus in Otolaryngology at The Ohio State University College of Medicine.

Dr. Beatty was born at Jasper Mills in Fayette County on September 12, 1880. He was graduated from The Ohio State University where he earned a Bachelor of Science degree in 1904. He received the Doctor of Medicine degree in 1910 from the Starling-Ohio Medical College. From 1910 to 1911 he served as an intern at Mount Carmel Hospital in Columbus after which he took post-graduate study in New York, Vienna and Berlin.

Dr. Beatty began his practice in Otolaryngology in Columbus in 1913. He was instrumental in founding speech and surgical clinics at St. Francis University and Mt. Carmel hospitals between 1915 and 1920. From 1929 to 1958 he was chairman of the Department of Otolaryngology at The Ohio State University.

Dr. Beatty was a founding member of the Columbus Eye, Ear, Nose and Throat Society and the American Board of Plastic Surgery. His medical memberships included Columbus Academy of Medicine; Ohio State Medical Association; American Medical Association; American Laryngological, Rhinological and Otolological Society; American Laryngological Association; American Academy of Ophthalmology and Otolaryngology; American Society of Ophthalmic and Otolologic Allergy; American College of Surgeons; and, International College of Surgeons.

Dr. Beatty was a charter member of the Scioto Country Club, Columbus Club and University Club and the Columbus Athletic Club. Surviving is his brother, Ralph, whose home is in California.

W.H.S.



HUGH G. BEATTY, M.D.

VERLING KERSEY HART, M.D.

1894 - 1971

Dr. Verling K. Hart, of Charlotte, North Carolina, died December 7, 1971. He was born at Fort Francis E. Warren, Wyoming, June 12, 1894.

His early education was obtained at the University of Colorado and he graduated from the University of Pennsylvania School of Medicine in 1921. He was awarded the Master of Science degree in 1923 for work in the School of Medicine at the University of Iowa. His early postgraduate medical training was obtained at the Presbyterian Hospital in Philadelphia and he did further graduate work in Bronchoesophagology at the University of Pennsylvania and in Otolaryngology at the University of Vienna.

He came to Charlotte in 1928 and in that year married Noel Pridgen, who survives him. He was a driving force in the building program of the Charlotte Memorial Hospital and was a member of the staff of that hospital, later in an emeritus capacity, as well as the staffs of other hospitals in Charlotte, and was a consultant to the North Carolina Tuberculosis Sanatorium. His closest ties were to the Charlotte Eye, Ear and Throat Hospital, and he was to a great degree responsible for the high level of medical care available to all at that institution.


He was a member of all appropriate Medical Societies. His leadership was recognized by his election to many high offices. He was made President of the Mecklenburg County Medical Society, President of the North Carolina Eye, Ear, Nose and Throat Society and Chairman of the Section of Otolaryngology of The Medical Society of the State of North Carolina.

He was elected to membership in the American Broncho-Esophagological Association in 1937, was President in 1959, Guest of Honor at the annual meeting in 1965 and was recipient of the Chevalier Jackson Award in 1968.

He was a pioneer in Bronchoesophagology in the South and in his adopted state. His work was above reproach and his reports and papers given on many occasions were models of preparation and presentation. He was a master story teller and entertained his listeners with accounts of difficult cases or just as frequently, a humorous story, most often with an important point as the punch line.

In addition to the demands of his practice, he gave of his time and many talents to the Charlotte YMCA, Rotary Club of Charlotte and Christ Episcopal Church. He served for over fifteen years on the Board of Directors of Hospital Savings Association and was Chairman of the State Medical Society Committee on Voluntary Medical and Health Insurance Plans. He will be sorely missed by patients, friends, and colleagues.

J.R.A.



VERLING K. HART, M.D.

W. FRANKLIN KEIM, M.D.

1910 - 1971

W. Franklin Keim died suddenly on Friday, July 2, 1971 while on a holiday in Maine where he was enjoying the sports he loved most, sailing and tennis. He was 61 years of age and at a point in his career when many of the goals he had worked for were coming to fruition. Under his guidance, a strong academic residency training program in Otolaryngology in the State of New Jersey seemed close at hand in the negotiations which he was carrying on with the New Jersey State College of Medicine. As President of the Mountainside Medical staff, he had just brought that institution through a difficult and turbulent year. As a principal contributor to the guidelines for the training of otolaryngologists in head and neck surgery, he had seen the acceptance of his ideas by the membership of the American Society for Head and Neck Surgery. In all of his efforts he stood for excellence and would not compromise his high values for expediency.

This dedication to a set of principles, moral values and ideals in his pursuit of quality as a life style may be traced to his family background and early education. His family were of Bavarian ancestry and both of his parents were practicing physicians in New Jersey, a State known for its conservatism. He graduated from Princeton University and spent the summer before matriculating to medical school on a trip touring Europe with a group of his classmates. He received his M.D. degree from the College of Physicians and Surgeons of Columbia University in New York City, following which he served an internship at the Newark City Hospital where he received his general surgical training. For his Graduate training, he had a residency in Pathology and in Otolaryngology at Columbia Presbyterian Hospital and Medical Center in New York City. On completion of his residency training, he returned to Newark and opened up his practice. He became associated with Dr. Henry Orton, a leading national figure in Laryngology and Bronchoscopy. This association channelled his interests in that direction. The developments in surgery of the head and neck caught his interest. He joined the staff of Memorial Hospital for Cancer and Allied Diseases in New York City as an Attending to pursue these interests further. Realizing that the field of head and neck surgery was an all-demanding one, he decided to limit his activities to this field and became one of the few Otolaryngologists in the East to confine his work to this area.

In the nineteen-fifties his efforts were directed towards developing a strong Otolaryngology Training Program in New Jersey at the Martland General Hospital, Presbyterian Hospital, Newark Eye and Ear and Mountainside Hospitals. These latter Hospitals became known as the United Hospitals of Newark. This became the first approved residency in Otolaryngology in the State of New Jersey. The conferences which he ran at the Black Stevenson Memorial Clinic at Presbyterian Hospital became well known for their excellence in teaching. He made many contributions to the field of head and neck surgery. His early work on surgery of the parotid gland was presented as an exhibit at the Academy of Ophthalmology and Otolaryngology. He also wrote on the value of aspiration biopsy and on the diagnosis of occult tumors and also on stomal recurrence and alveolar carcinoma of the oral cavity.



W. FRANKLIN KEIM, M.D.

He was a member of many societies and was, at one time, President of the Academy of Medicine of New Jersey and of the American Society for Head and Neck Surgery. He was also Past President of the New York Laryngological Society and the New York Bronchoscopic Club. He was a member of the American Laryngological Association, The Triological Society, American Broncho-Esophagological Association and the Society of Head and Neck Surgeons. He was also a Fellow of the American College of Surgeons.

Dr. Keim had many interests outside the field of medicine. He was a student of Bach; he loved opera and art and German literature and he was a collector of objects d'art. He was a man of broad cultural interests. He was an excellent sailor and sailed the New England coastal waters and also off the New Jersey coast, and in recent years, sailed the Caribbean. A few years ago he led a flotilla of yachtsmen friends among the Islands of the Caribbean.

Dr. Keim gave willingly and unstintingly of his time and effort to the many medical societies to which he belonged. Those of us who had worked with him on committees depended upon his judgment for fairness and prudence. Dr. Keim is survived by his wife, the former Nadine Easter. Surviving also are three children by his first marriage and three stepsons, seven grandchildren and a sister.

His life was a full one; his accomplishments were many; his friends were numerous; he was greatly admired by his colleagues and he added something to the life of everyone who came in contact with him. He was, indeed, a quiet man of great stature whose work will long be held in the memory of his colleagues and friends.

J.F.D.

BERNARD JOHN McMAHON, M.D.

(1892-1972)

Bernard John McMahon was born in St. Louis, Missouri, May 10, 1892. He was educated in the schools of this city and received his A.B. degree at St. Louis University in 1913, and his M.D. in 1917. He was elected to the honorary fraternity Alpha Omega Alpha while in medical school. His internship was at St. Louis City Hospital the succeeding year, followed by two years in the Medical Corps of the United States Army as a First Lieutenant.

Following the war years, he attended the Graduate School of the University of Pennsylvania, 1920 to 1924, doing postgraduate study in the field of Otolaryngology. In 1926, he was awarded the degree of Master of Science (Medicine) in Otolaryngology.

In 1924, Dr. McMahon returned to St. Louis and joined the faculty of Washington University School of Medicine as an Assistant in the Department of Otolaryngology. He was advanced to Instructor in 1927, and in 1934 became an Assistant Professor of Clinical Otolaryngology, a position he held until 1943. Concurrently, he was a member of the medical staff of Barnes Hospital and St. Louis Children's Hospital from 1924 to 1943. He was on the medical staff of St. Luke's Hospital from 1925 to 1947.

In 1943, Dr. McMahon severed his connections with Washington University School of Medicine and its associated hospitals in order to accept appointment to the faculty of St. Louis University as Associate Professor of Clinical Otolaryngology. Two years later he was appointed Chairman of the Department of Otolaryngology of St. Louis University School of Medicine, succeeding the late Dr. William E. Sauer. In 1950, Dr. McMahon was promoted to Professor of Clinical Otolaryngology at St. Louis University. He retired from the Chairmanship of the Department in 1960, but continued in private practice until 1968, when he retired altogether because of failing health.

Upon coming to St. Louis University in 1943, Dr. McMahon was appointed to the staff of the St. Mary's group of hospitals; at that time, this group included St. Mary's Hospital, Firmin Desloge Hospital, Mt. St. Rose Hospital and the old St. Mary's Infirmary. These were the "teaching hospitals" of St. Louis University. In 1956, the Cardinal Glennon Memorial Hospital for Children was constructed, and became the newest addition to the group. Dr. McMahon was active in the planning of this beautiful and highly efficient hospital for children. He served as consulting bronchoscopist for the St. Louis City Hospital from 1925 to 1940, and as a consultant in Otolaryngology from 1947 to 1960. In 1956, he joined the medical staff of the new St. John's Mercy Hospital and after his retirement from the University in 1960, confined his private practice to St. John's Mercy Hospital.

Dr. McMahon was a member of all the honorary societies in our specialty. Beside membership in the American Medical Association and the Southern Medical Association, he was a member, or fellow, of the following societies: American Laryngological Association, American Academy of Ophthalmology and Otolaryngology, American Laryngological, Rhinological and Otological Society, and American Otological Society. He was president of the American Otological



BERNARD JOHN McMAHON, M.D.

Society in 1948, and in that same year he received that Society's "Award of Merit" for outstanding work in the field of Otolaryngology. Dr. McMahon was President of the American Laryngological Association twice: in 1947 and again in 1955. He was Librarian, Historian and Editor of this Association's Transactions from 1952 to 1954.

Dr. McMahon was appointed to membership on the American Board of Otolaryngology in 1942, and served faithfully in the arduous tasks of this Board during the next 18 years. He was President of the American Board of Otolaryngology from 1959 to 1960. Dr. McMahon was a member of the Ear, Nose and Throat Club of St. Louis, and served as its Secretary for many years.

During his entire career in medicine, Dr. McMahon was deeply involved in research, teaching and writing. His bibliography comprises 29 in the field of Otolaryngology. During his early years, 1926 to 1931, he wrote a number of papers on fundamental histopathology of nasal sinuses and mastoids, and all during his career he was deeply concerned with fundamental histopathology.

This was followed by work on phagocytosis, and the spread of particulate matter on nasal mucosa, and the effects of "ionization," a procedure which enjoyed considerable popularity at that time. With the advent of the sulfonamides and antibiotics, Dr. McMahon undertook basic studies on the effects of these agents on infected sinus mucosa of experimental animals. There followed a number of papers on the entire subject of antibiotic therapy in otolaryngological infections. In 1950, he returned to his first interest, histopathology, and produced a classic dissertation on the basic pathology of acute frontal sinusitis (*Annals of Otolaryngology, Rhinology and Laryngology* 59: 439-445, 1950). His last paper, which he read at the general meeting of the American Laryngological, Rhinological and Otolaryngological Society, in St. Louis in 1959, was a study of the relationship between adenotonsillectomy and deafness in children.

Dr. Bernard John McMahon died at St. John's Mercy Hospital on January 4, 1972, after a prolonged illness. Funeral Mass was held in his parish church, and he was interred in Calvary Cemetery in St. Louis, Missouri. He is survived by his wife, Alice Malay McMahon, and four children.

To those of us who knew Dr. McMahon, his demise seems like the end of an era. He was one of a goodly number of truly dedicated, devoted men who were our teachers and mentors of long ago. I think everyone who knew him had tremendous admiration and respect for this man. He had great natural dignity. His scholarly approach to medicine, his sincerity, honesty and modesty endeared him to his colleagues, to his house officers and to his students.

W.B.H.

Executive Sessions

EXECUTIVE SESSION

FRIDAY MORNING, APRIL 28, 1972

The Executive Session of the Ninety-third Annual Meeting of the American Laryngological Association convened at 8:05 A.M. in the Venetian Ball Room of The Breakers, at Palm Beach, Florida, Dr. F. Johnson Putney, President of the Association presiding. The first item was the election of the following candidates:

For Active Fellowship:

Dr. B. J. Soboroff
Dr. C. L. Pennington, Jr.
Dr. J. C. Lillie
Dr. H. R. Morse

For Emeritus Fellowship:

Dr. J. B. Erich
Dr. J. R. Richardson

For Corresponding Fellowship:

Dr. Michele Arslan

By ballot all candidates were duly elected to Fellowship.

ANNUAL BUSINESS MEETING

SATURDAY MORNING, APRIL 29, 1972

The Annual Business Meeting of the Ninety-third Annual Meeting of the American Laryngological Association convened at 8:05 A.M. Saturday morning, April 29, 1972 in the Venetian Ball Room of The Breakers, Palm Beach, Florida, President F. Johnson Putney, M.D., presiding.

REPORT OF THE SECRETARY

The Ninety-second Annual Meeting of the American Laryngological Association was held May 23 and 24, 1971, in the San Francisco Hilton, San Francisco, California. President DeGraaf Woodman alternated with Vice-Presidents Robert B. Lewy and Oliver W. Suehs in presiding over various portions of the program. The meeting was well attended, 88 Fellows and 220 Guests registering.

The program arranged by President Woodman was excellent. Fifteen scientific papers were presented with the majority oriented toward laryngeal disease. All papers were presented exceptionally well and were well received. Unfortunately, the printed programs shipped to the San Francisco Hilton for the meeting never arrived. However, the San Francisco Hilton came to our rescue in that they were able to arrange for a substitute program in sheet form for distribution at the meeting.

Dr. Edwin N. Broyles was the Honored Guest. He was presented with a suitably engrossed certificate as the Honored Guest by President Woodman.

The President's Reception and Dinner was held on Monday evening, May 24, in the Bohemian Club. The menu was excellent and the postprandial entertainment presented by a school of Hawaiian Dancing was well received.

The Librarian, Historian and Editor, Dr. F. Johnson Putney, reported the deaths of Dr. C. Stewart Nash and Dr. Theodore E. Walsh. Since this report, the Association has lost through death, Dr. W. Franklin Keim, Dr. Hugh G. Beatty, Dr. Verling K. Hart and Dr. Bernard J. McMahon.

The Newcomb Award was presented to Dr. Daniel C. Baker, Jr., New York, N.Y. at the Annual Dinner.

The following were elected to Fellowship:

Active:

Dr. Seymour R. Cohen, Los Angeles, Calif.

Dr. Russell I. Williams, Cheyenne, Wyo.

Emeritus:

Dr. Verling K. Hart, Charlotte, N.C.

Dr. Paul M. Moore, Cleveland, Ohio

Dr. John A. Murtagh, Fort Lauderdale, Fla.

Corresponding:

Mr. D. F. N. Harrison, London, England

Mr. R. G. MacBeth, Oxford, England

Dr. A. Rethi, Budapest, Hungary

The following officers were elected for the coming year:

President: Dr. F. Johnson Putney

First Vice-President: Dr. James A. Harrill

Second Vice-President: Dr. James D. Baxter

Secretary: Dr. Frank D. Lathrop

Treasurer: Dr. Charles M. Norris

Librarian, Historian and Editor: Dr. Charles F. Ferguson

First Councilor: Dr. Lawrence R. Boies

Second Councilor: Dr. Francis W. Davison

Third Councilor: Dr. Alden H. Miller

Fourth Councilor: Dr. DeGraaf Woodman

During the Annual Business Meeting, at the suggestion of the Council, the Fellowship approved an increase in the annual dues from \$75 to 100.

The next annual meeting will be held at The Breakers, Palm Beach, Florida, on the mornings of April 28 and 29, 1972.

The dates and locations for future meetings are as follows: 1973, April 1 and 2, Chase Park Plaza, St. Louis, Missouri; 1974, not yet decided; 1975, April 12 and 13, Regency Hyatt House, Atlanta, Georgia.

The current Fellowship of the Association is as follows:

Active	88
Emeritus	30
Corresponding	13
Honorary	10
	—
	141

Respectfully submitted,

Frank D. Lathrop, M.D., Secretary

(This report was duly accepted by the Fellows.)

REPORT OF THE TREASURER

Exhibit A

AMERICAN LARYNGOLOGICAL ASSOCIATION
GENERAL FUND
OPERATING STATEMENT AND FUND BALANCE
FISCAL YEAR ENDED MARCH 31, 1972

Income

Dues (85 @ \$100; 2 new members @ \$150)	\$8,800.00	
Sale of Transactions	1,064.00	
Sale of Banquet Tickets and Photographs	2,470.75	
Interest on Savings Account	844.52	\$13,179.27
		<hr/>

Expenses

Annual Meeting 1971		
Reception and Banquet	\$3,350.49	
Reporting	455.42	
Projection	368.25	
Programs and Memb. Certs.	491.64	
Guest of Honor	80.35	
	<hr/>	
Total Annual Meeting Expense	4,746.15	
Council Meeting Expense	3,167.73	
Transactions and Editorial Expense	3,653.72	
General Expense		
Stationery, Printing, Postage	1,111.09	
Clerical Hire	450.00	
Auditing	100.00	
Treasurer's Bond	55.00	
Dues - International Federation of Otolaryngological Societies	100.00	
Contribution American Council Otolaryngology Bank Charges and Foreign Exchange	200.00 4.65	
	<hr/>	
Total General Expense	2,020.74	
	<hr/>	
Total Expenses		13,588.34
		<hr/>
Net Income (Loss) for the year		(409.07)
Fund Balance March 31, 1971		5,393.92
		<hr/>
Fund Balance March 31, 1972		\$ 4,984.85
		<hr/>

Exhibit B

AMERICAN LARYNGOLOGICAL ASSOCIATION
TRUST FUND
OPERATING STATEMENT AND FUND BALANCE
FISCAL YEAR ENDED MARCH 31, 1972

Income

Interest on U. S. Series H Bonds	\$ 341.46	
Dividends on Common Stocks and Mutual Fund	4,737.64	
Sale Rights (ATT) and Fract. Share (McD-D)	<u>44.44</u>	
		\$ 5,123.54
Donation to Memorial Fund (Dr. Woodman)		<u>500.00</u>
Total Income		<u>\$ 5,623.54</u>

<i>Expense</i>		0.00
Net Income for Fiscal Year		5,623.54
Fund Balance March 31, 1971		<u>71,750.22</u>
Fund Balance March 31, 1972		<u>77,373.76</u>

TRUST FUND ASSETS

Cash		\$ 9,869.51
Savings Certificate (First Federal Savings and Loan Assn. of Philadelphia)		10,000.00
Investments (Exhibit D)		
U. S. Bond Series H at cost, par and maturity values	\$ 6,500.00	
Common Stocks		
Purchased 2/10/72 130 sh. A.T.T. at cost	\$5,945.14	
Purchases previous years	5,672.38	
Donated (market value at donation)	<u>2,362.00</u>	
Mutual Fund (Massachusetts Investment Trust) at cost	13,979.52	
Total Trust Fund Assets	<u>37,024.73</u>	57,504.25
		<u>77,373.76</u>

CASH SUMMARY

Cash in Commercial Account (Girard Bank, Philadelphia)		2,084.90
Cash in Savings Account (Girard Bank, Philadelphia)		<u>12,769.46</u>
		<u>14,854.36</u>
Allocation:		
General Fund (Exhibit A)	\$ 4,984.85	
Trust Fund (above)	<u>9,869.51</u>	
		14,854.36

Exhibit C

AMERICAN LARYNGOLOGICAL ASSOCIATION
INDIVIDUAL TRUST FUNDS
MARCH 31, 1972

	<i>Principal and Retained Earnings 3/31/71</i>	<i>Earnings*</i>	<i>Donations</i>	<i>Awards</i>	<i>Principal and Retained Earnings 3/31/72</i>
Casselberry	\$ 9,627.18	\$ 687.42			\$10,314.60
Johnston	9,115.15	650.89			9,766.04
DeRoaldes	6,070.01	433.46			6,503.47
Newcomb Trust	3,578.61	255.57			3,834.18
Newcomb Prize	835.27	59.59			894.86
Research	28,475.24	2,033.43			30,508.67
Memorial	14,048.76	1,003.18	500.00		15,551.94
	<u>\$71,750.22</u>	<u>\$5,123.54</u>	<u>\$500.00</u>	<u>\$0.00</u>	<u>\$77,373.76</u>

* Net income for the year is allocated to each fund in the ratio it bears to the total balance of the trust funds at the beginning of the year.

Exhibit D

AMERICAN LARYNGOLOGICAL ASSOCIATION
TRUST FUND INVESTMENTS
MARCH 31, 1972

Savings Certificate (First Federal Savings and Loan of Philadelphia)	\$10,000.00	\$10,000.00
U. S. Government Bonds		
Six \$1,000.00 Series H Bonds (at cost)	6,000.00	
One \$500.00 Series H Bond (at cost)	500.00	
Total U. S. Government Bonds		\$6,500.00

Common Stocks:

	<i>Number of Shares</i>	<i>Cost</i>	<i>Market Value at Donation</i>	
American Telephone and Telegraph Co.	200	\$10,790.16		
International Business Machine Corp.	1		517.00	
International Business Machine Corp. (1) ...	7	803.98		
McDonnell Douglas Corp. (2)	112		1,170.00	
McDonnell Douglas Corp. (3)	14	23.28		
McDonnell Douglas Corp. (4)	3			
McIntyre-Porcupine Mines, Ltd.	15		675.00	
		<u>\$11,617.52</u>	<u>\$ 2,362.00</u>	13,979.52
Mutual Fund—Massachusetts Investors Trust (at cost)				37,024.73
Total Trust Fund Investments				<u>\$67,504.25</u>

Notes: (1) Includes 5¼ shares received in stock dividends.

(2) Includes 86 shares received in stock dividends.

(3) Includes 13.44 shares received in stock dividends, and exercised rights to purchase .56 share.

(4) Shares received as 3% stock dividend 1972; fractional share sold.

Respectfully submitted,
Charles M. Norris, M.D., Treasurer

(This report was duly accepted by the Fellows.)

REPORT OF THE ACCOUNTANT

To the Members of the American Laryngological Association
Gentlemen:

We have examined the statements of cash receipts and disbursements of the AMERICAN LARYNGOLOGICAL ASSOCIATION, including Trust Funds, for the fiscal year ended March 31, 1972. Our examination was made in accordance with generally accepted auditing standards, and accordingly included such tests of the accounting records and such other auditing procedures as we considered necessary in the circumstances.

Cash receipts and disbursements were verified as recorded to date, and all securities were examined or accounted for as of this date.

In our opinion, the accompanying statements of cash receipts and disbursements present fairly the financial position of The American Laryngological Association and its Trust Funds at March 31, 1972, on a cash basis, and the results of its operations for the year then ended, in conformity with generally accepted accounting principles applied on a basis consistent with that of the preceding year.

NEMORE, GRAHAM & COMPANY

Respectfully submitted,
Certified Public Accountants

April 14, 1972

REPORT OF THE LIBRARIAN, HISTORIAN AND EDITOR

The Ninety-second Annual Meeting of the American Laryngological Association was held on May 23 and 24, 1971 at the San Francisco Hilton Hotel, San Francisco, California. Eighty-eight Fellows, (69 Active, 5 Honorary, 3 Corresponding and 11 Emeritus) and 220 guests were registered.

Three factors during the past year posed somewhat unusual problems for your new Editor. First, this year the meeting was held so late in the season it was already Holiday time for many of the men when they received their discussions for correction, so the Editor had to do some extra editing on his own to get the material on to the publishers without too much further delay. Second, our dependable and always faithful reporter from the Martin-Johnson Reporting Service, Mrs. Annabelle Square, who personally knew so many of the discussors, was unfortunately not able to be at her usual post to give us her customary rapid and efficient service. However, we are very pleased to note how quickly her successor has assumed her duties and has already learned the names of so many of our members. Third, the Editor's chair had a new occupant. His initiation this year might have been a real headache had he not had five years of similar experience with the American Broncho-Esophagological Association, or had he not received such wholehearted cooperation and grateful assistance from our erstwhile Editor, this year our distinguished President. My sincere appreciation to him and to his able spouse who also gave much of her time and talent to the business end of the TRANSACTIONS.

The completed transcript of the meeting was finally received on July 7, 1971 from the Martin-Johnson Reporting Agency. Through the appreciated cooperation of most of the discussors, a great deal of the material could be sent to the publishers in St. Louis ten days later, on July 17, and the final completed manuscripts, with a few of the discussions edited by the Editor himself, sent to Dr. Senturia's

office on July 22. The papers presented at the meeting were all published in the December issue of *The ANNALS*.

Galley proof, however, was not received until October 28, but was returned corrected on November 1. The *TRANSACTIONS* were ready to be mailed out by mid-December, but shipping was wisely deferred by the publishers until after the mail rush of the Holiday Season. Two hundred and twenty-five copies were ordered, as for the previous year, and mailed out as follows: Active Members 93; Honorary Members 10; complimentary 2 (Library of Congress and National Library of Medicine for the *Index Medicus*); family of deceased 1; standing orders 42; and single orders 26; Total: 174.

The total cost of publishing the 1971 *TRANSACTIONS* was \$3,653.72, as against \$3,221.12 for the previous year. \$1,069.00, from the sale of the *TRANSACTIONS*, has been turned over to the Treasurer.

The meeting was recorded by the Audio-Digest Foundation, and a complete tape of the presented papers sent to the Editor.

The Librarian still has in his custody surplus volumes for many of the past years, which he will be only too glad to send to members who may wish to add to their libraries free of charge, except for postage-collect. Three Fellows have availed themselves of this opportunity.

For this meeting I am glad to report that the essayists have been most co-operative, so that out of 21 papers scheduled for presentation, 19 have already been placed in the hands of the Editor of *The ANNALS* Publishing Company, hopefully for early publication in the August issue, as this year the American Laryngological Association has priority of publication. The two remaining papers are promised very shortly.

Respectfully submitted

Charles F. Ferguson, M.D.

Librarian, Historian and Editor

(This report was duly accepted by the Fellows.)

REPORT OF THE NOMINATING COMMITTEE

DR. STANTON A. FRIEDBERG, Chairman (Chicago, Ill.): The Nominating Committee met yesterday and now presents the following slate for members of the Council for 1972-3:

Frank D. Lathrop, M.D.

Francis L. Weille, M.D.

Sam H. Sanders, M.D.

John F. Daly, M.D.

Charles M. Norris, M.D.

Charles F. Ferguson, M.D.

Francis W. Davison, M.D.

Alden H. Miller, M.D.

DeGraaf Woodman, M.D.

F. Johnson Putney, M.D.

(Th's report was duly accepted by the Fellowship.)

REPORT OF THE AMERICAN BOARD OF OTOLARYNGOLOGY

As one of the representatives of the American Board of Otolaryngology to the American Laryngological Association, I am pleased to report to you on the activities of the American Board of Otolaryngology.

Beginning with the examination in the Fall of 1971, the American Board of Otolaryngology will, henceforth, give only one examination a year. This decrease in the number of examinations necessary to examine the large number of applicants of recent years has been made possible through a change in the format of the examination which eliminates the clinical and alters the oral portions of the examinations utilized in years past. One-half of the present examination consists of a series of multiple choice questions and the other half of a patient simulation examination. Pathology is woven into the overall examination. In this way it is expected that the examination will be more objective in nature and yet retain the personal and oral contact of the examiner with the candidate. In addition, a profile of the candidate's examination will be furnished each candidate so that he may utilize it, if he so desires, in correcting any areas of weakness demonstrated through the examination. Furthermore, this format permits the examination of a large number of candidates.

The examination for 1971 was held in the Palmer House, Chicago, Illinois, from October 29 to November 4, 1971. Approximately 440 candidates took the examination. Three hundred and thirty-two of the candidates passed the examination.

Respectfully submitted,
Frank D. Lathrop, M.D.
Paul H. Holinger, M.D.
Representatives

(This report was duly accepted by the Fellows.)

REPORT FROM THE BOARD OF GOVERNORS
AMERICAN COLLEGE OF SURGEONS

The numerous and important activities of otolaryngologists in the American College of Surgeons are gratifying and significant. Participation in policy making decisions affecting the specialty is essential and is increasing through the attendance at committee meetings by your representatives.

One of the major projects of the College is the ongoing Study of Surgical Services for the United States (SOSSUS). The purpose of SOSSUS is to provide a means for involving the profession in a dialogue with government and opening the way for the profession to contribute to legislative plans affecting health care delivery and surgical care in the United States. One of the results which has clearly emerged is an operational philosophy. This Study about the delivery of surgical services and care for the United States will be conducted by surgeons. It is specifically the intent of these two associations (ACS and American Surgical Association) to have the Study represent the thinking of the surgical community rather than that of a contracted firm or the federal government. The collection of data, its analysis and postulation of recommendations will be done by members of the surgical community. External resource support will be sought only in those areas where existing institutions can more productively provide special skills and statistical information.

In a very high level meeting with HEW the College presented factual data concerning the professional liability question, which was obtained from the computerized summaries of the answers to the more than 15,000 questionnaires that were returned by the Fellows of the College. This has been an impressive presentation to HEW, since it is the first factual material that has been received, the rest of it having generally been hearsay or packed with emotion from both sides of the issue.

It is the recommendation of the Advisory Council for Otolaryngology of the College of Surgeons that the societies that make recommendations for Governors from their specialty recommend those who are interested in the College of Surgeons and are willing to serve as Governors, rather than to consider this simply an honorary appointment. Unless a Governor attends the meetings, there is no representation when policy decisions are being made. It would even be appropriate to consider as a recommended appointee a member who is also a member of the executive committee of his society.

Respectfully submitted,

Paul H. Holinger, M.D.

(In substitution for Dr. Frank Keim, deceased,
Governor on the Board of Governors of the ACS
representing the ALA.)

(This report was duly accepted by the Fellows.)

LARYNGOLOGICAL RESEARCH FUND COMMITTEE

The Research Committee met at The Breakers, Palm Beach, Florida, on April 28, 1972. During the past year, one application for a research grant was received. Dr. Victor L. Schramm, Jr., of Washington University, St. Louis, Mo., applied for a grant to make a pilot study on Nasopulmonary Functions in Upper Respiratory Infections. The plan of study was well laid out in considerable detail. Each member of the Committee received a copy to study. As a result, the Committee voted to recommend to the Council that the application be granted. The Council has not yet taken action but will at the next Council meeting.

The Committee still feels that it is not necessary to make a grant annually. There is approximately \$28,000.00 in the Research Fund, from which an income of about \$2,000.00 can be expected annually. If this income can be allowed to accumulate for three or four years, a substantial sum can be granted when a promising project is submitted for consideration.

Respectfully submitted,

A. C. Hilding, M.D., Chairman

(This report was duly accepted by the Fellows.)

FIRST EXECUTIVE SESSION

APRIL 29, 1972

The First Executive Session of the American Laryngological Association Annual Meeting convened at 8:02 A.M. Secretary Frank D. Lathrop discussed plans for the 1974 meeting. It had been previously decided by the Triological Society, with the other Associations giving preliminary approval, that Acapulco be the site of the 1974 meetings. However, after this decision there had been considerable feeling that this was not as desirable a location as might be considered, and did not meet with the approval of all of the Councils of the other societies. There was a very strong feeling that The Breakers in Palm Beach had done a good job this year, and that a meeting here in 1974 should be considered if such arrangements could be made. Dr. Victor Alfaro, current President of the Triological Society, spoke on the advantages of the Princess Hotel at Acapulco, with its 250 rooms, all brand new, and with its excellent meeting facilities. He stated, however, that the Triological Society was perfectly willing to change its commitment; and he thought that the commitment could easily be changed, if it were the consensus of the various societies attending this present meeting to do so.

A show of hands resulted in the information that no one was for Acapulco in 1974, but a unanimous decision was for The Breakers in Palm Beach. It was voted to convey this feeling of the present Fellowship to Dr. Louis Silcox, Secretary of the Triological Society.

SECOND EXECUTIVE SESSION

APRIL 29, 1972

The executive session of the American Laryngological Association reconvened at 11:55 A.M., President F. Johnson Putney, M.D., presiding.

PRESIDENT PUTNEY: Before beginning with election of the Council, Dr. Alfaro would like to say a few words. While Dr. Alfaro is coming to the podium, I'd like to take this opportunity to express my gratitude to the Triological Society for their cooperation and help in matters pertaining to the program and I'm especially indebted to Dr. Alfaro, who has helped me in the preparation of the program and the fact that we were able to obtain Professor Arslan on our program. He was most cooperative, and I think he deserves our appreciation. (Applause).

DR. ALFARO: Thank you, very much. I'm here primarily to clarify a couple of things that John Bordley said this morning and to propose action at the Society level.

The National Institute of Neurological Diseases and Stroke, is about to be dismembered by having the Section on Stroke transferred to the Heart Institute, and in so doing this concerns those who are affiliated with the National Institute of Neurological Diseases and Stroke over the fact that ongoing research will be in some way affected unfavorably. There are at the present time something like 16 research projects which are being supported for Otolaryngology. Dr. Bordley is on that committee.

Now, if this is transferred to Institute of Heart Disease, we stand a pretty good chance of losing some of the support which we are getting through NINDS. Therefore, a part of what he wishes done is to petition Congressman Paul Rogers

of Florida to oppose this transfer of the Stroke Section of NINDS to Heart and let it remain as it is at the present time.

I brought up at the meeting of the Council of the Triological Society that, in addition to the grassroots approach by writing to the congressman individually as physicians, we should as Societies lend the prestige of that Society itself in writing to Congressman Rogers and suggested that the Secretary of our Society, the Triological, communicate with him in the preparation of a meaningful communication. I spoke with him further about this this morning and he felt that this would be feasible for all the Societies. I will propose, therefore, that this Society go on record as opposing the transfer of the Section on Stroke of NINDS to Heart and that we so state in a letter which should go under the signature of the new President of the Society (since the date will be after the election of your new President) and that this letter be composed with the help of Dr. Bordley.

The second part applies strictly to the affect on Otorhinolaryngology. The second part of the petition for Congressman Rogers is in reference to the separation of Health from the Department of Health, Education, and Welfare and this applies not only to Otorhinolaryngology but to all medical societies and all medical men. I think the need for this is very obvious. We have outgrown this partnership of Health with Education and Welfare which have divergent interests to a great extent. We would have a much stronger voice in the government if we had a Secretary of Health rather than an Under Secretary in the Department. This part could go in the same letter to Mr. Rogers. It's on a different subject and one which we hope will be taken up by other Societies.

I would therefore make the motion, Mr. Chairman, that this Society go on record as approving these recommendations and that with the help of Dr. Bordley, this letter be composed and sent.

PRESIDENT PUTNEY: Thank you, Dr. Alfaro. You have heard the motion. Is there a second?

DR. WOODMAN: Second.

PRESIDENT PUTNEY: All in favor say "aye"; opposed "no."

Thank you. It's so ordered.

Our next item of business is election of the Council. You will see on the blackboard the slate that the Nominating Committee provided this morning. The Nominating Committee report was accepted. Now, I need a motion that the officers recommended by the Nominating Committee be elected as a Board of Directors of this Society.

DR. TUCKER: So moved.

PRESIDENT PUTNEY: Is there a second?

DR. WOODMAN: Second.

PRESIDENT PUTNEY: All in favor say "aye"; opposed "no."

So carried. Now, if the new Board of Directors would assemble for a few minutes, I think the organization will proceed.

(Whereupon the newly elected Board of Directors had a brief organizational meeting.)

The Board of Directors has organized with a motion and a second, and as you see the slate on the blackboard, I think you probably already know the order of succession.

President: Dr. Frank D. Lathrop

First Vice-President: Dr. Francis L. Weille

Second Vice-President: Dr. Sam H. Sanders

Secretary: Dr. John F. Daly

Treasurer: Dr. Charles M. Norris

Librarian, Historian and Editor: Dr. Charles F. Ferguson

First Councilor: Dr. Francis W. Davison

Second Councilor: Dr. Alden H. Miller

Third Councilor: Dr. DeGraaf Woodman

Fourth Councilor: Dr. F. Johnson Putney

So, Frank, if I might have you come to the podium!

(Whereupon Dr. Lathrop came to the podium as requested.)

I will be most happy to turn over the gavel of this Association to you; as we all know Frank has been an excellent, faithful and very dedicated Secretary. He has always been available, except in one instance and I must tell you about it. When the blacksmith comes, Frank is tied up and will do no other business but take care of him and the horses. So we hope next year, blacksmiths will not come too often! ! It's a great pleasure to turn the gavel over to you, Frank. (Applause)

DR. FRANK LATHROP (Newly-elected President): Thank you, very much. I sincerely appreciate this honor and I know I shall find it difficult to follow in the footsteps of our Past President in developing such an excellent program which we have had today.

Well, the blacksmith has to come about every six weeks, unfortunately, and it's amazing — the number of times that you're occupied in something that's either personal or very important when you get called to the phone. This has happened to me many times, but the only time it has happened with the blacksmith was with Put!


Now, it is my first duty as President of this organization to bestow upon our Past President, Dr. Putney, a key in recognition of his services to this organization during the past year. Dr. Putney, would you come here please! I have here a key symbolic of the organization. It is given to you in recognition of your services to this organization. (Whereupon President Lathrop then presented the key to Past President Putney.)

PAST PRESIDENT PUTNEY: Thank you, very much, Mr. President and thank you, Fellows.

(The meeting was adjourned at 12:06 P.M.)

BENEFACTORS

DR. JOHN F. BARNHILL	DR. & MRS. GEORGE E. HOURN
DR. AUGUST L. BECK	DR. SAMUEL JOHNSTON
DR. GORDON BERRY	MRS. LILA FETTEROLF KENNEDY
DR. EDWIN N. BROYLES	DR. JAMES E. NEWCOMB
DR. WILLIAM E. CASSELBERRY	DR. HENRY B. ORTON
DR. LOUIS H. CLERF	DR. & MRS. LYMAN G. RICHARDS
DR. CORNELIUS G. COAKLEY	DR. SAMUEL SALINGER
DR. & MRS. FRANCIS W. DAVISON	DR. SAM H. SANDERS
DR. & MR. LEE WALLACE DEAN	DR. HARRY P. SCHENCK
DR. ARTHUR W. DEROALDES	DR. BURT R. SHURLY
DR. FRED W. DIXON	MR. LESTER T. SUNDERLAND
DR. WILLIAM E. GROVE	DR. H. MARSHALL TAYLOR
DR. GORDON F. HARKNESS	DR. WALTER H. THEOBALD
DR. FREDERICK T. HILL	DR. DEGRAAF WOODMAN



Obverse of the deRoaldes medal

RECIPIENTS OF THE DEROALDES AWARD

- 1928. DR. CHEVALIER JACKSON
- 1931. DR. D. BRYSON DELAVAN
- 1934. DR. HARRIS P. MOSHER
- 1937. DR. LEE WALLACE DEAN
- 1943. DR. RALPH A. FENTON
- 1949. DR. GEORGE M. COATES
- 1951. DR. ARTHUR W. PROETZ
- 1954. DR. LOUIS H. CLERF
- 1959. DR. ALBERT C. FURSTENBERG
- 1960. DR. DEAN M. LIERLE
- 1961. DR. FREDERICK T. HILL
- 1966. DR. PAUL H. HOLINGER
- 1970. DR. FRANCIS E. LEJEUNE

RECIPIENTS OF THE CASSELBERRY AWARD

1923. DR. GEORGE FETTEROLF AND DR. HERBERT FOX
1928. DR. RALPH A. FENTON AND DR. O. LARSELL
1929. DR. RICHARD A. KERN AND DR. HARRY P. SCHENCK
1929. DR. EDWARD H. CAMPBELL
1931. DR. ARTHUR W. PROETZ
1934. DR. ANDERSON C. HILDING
1936. DR. FRANCIS E. LEJEUNE: DR. JOEL J. PRESSMAN
1939. DR. H. MARSHALL TAYLOR: DR. BRIEN T. KING
1940. DR. FRENCH K. HANSEL
1941. DR. NOAH D. FABRICANT
1946. DR. PAUL H. HOLINGER
1949. DR. HENRY B. ORTON
1962. DR. HANS VON LEDEN
1966. DR. JOHN A. KIRCHNER AND MR. BARRY D. WYKE
1968. DR. JOSEPH H. OGURA

RECIPIENTS OF THE NEWCOMB AWARD

- 1941. DR. BURT R. SHURLY
- 1942. DR. FRANCIS R. PACKARD
- 1943. DR. GEORGE M. COATES
- 1944. DR. CHARLES J. IMPERATORI
- 1947. DR. HARRIS P. MOSHER
- 1948. DR. GORDON BERRY
- 1949. DR. GORDON B. NEW
- 1950. DR. H. MARSHALL TAYLOR
- 1951. DR. JOHN D. KERNAN
- 1952. DR. WILLIAM J. McNALLY
- 1953. DR. FREDERICK T. HILL
- 1954. DR. HENRY B. ORTON
- 1955. DR. THOMAS C. GALLOWAY
- 1956. DR. DEAN M. LIERLE
- 1957. DR. GORDON F. HARKNESS
- 1958. DR. ALBERT C. FURSTENBERG
- 1959. DR. HARRY P. SCHENCK
- 1960. DR. JOEL J. PRESSMAN
- 1961. DR. CHEVALIER L. JACKSON
- 1962. DR. PAUL H. HOLINGER
- 1963. DR. FRANCIS E. LEJEUNE
- 1964. DR. FRED W. DIXON
- 1965. DR. EDWIN N. BROYLES
- 1966. DR. LYMAN G. RICHARDS
- 1967. DR. JOSEPH H. OGURA
- 1968. DR. WALTER P. WORK
- 1969. DR. JOHN A. KIRCHNER
- 1970. DR. LOUIS H. CLERF
- 1971. DR. DANIEL C. BAKER, JR.
- 1972. DR. ALDEN H. MILLER

List of Fellows

PAST OFFICERS

Presidents

(Year of Election)

1879. Louis Elsberg	1909. J. E. Logan
1880. J. Solis-Cohen	1910. D. Braden Kyle
1881. F. I. Knight	1911. James E. Newcomb
1882. G. M. Lefferts	1912. George A. Leland
1883. F. H. Bosworth	1913. Thomas Hubbard
1884. E. L. Shurly	1914. Alexander W. MacCoy
1885. Harrison Allen	1915. G. Hudson Makuen
1886. E. Fletcher Ingals	1916. Joseph L. Goodale
1887. R. P. Lincoln	1917. Thomas H. Halstead
1888. E. C. Morgan	1918. Cornelius G. Coakley
1889. J. N. Mackenzie	1919. Norval H. Pierce
1890. W. C. Glasgow	1920. Harris P. Mosher
1891. S. W. Langmaid	1921. Harmon Smith
1892. M. J. Asch	1922. Emil Mayer
1893. D. Bryson Delavan	1923. J. Payson Clark
1894. J. O. Roe	1924. Lee Wallace Dean
1895. W. H. Daly	1925. Greenfield Sluder
1896. C. H. Knight	1926. Chevalier Jackson
1897. T. R. French	1927. D. Bryson Delavan
1898. W. E. Casselberry	1928. Charles W. Richardson
1899. Samuel Johnston	1929. Lewis A. Coffin
1900. H. L. Swain	1930. Francis R. Packard
1901. J. W. Farlow	1931. George E. Shambaugh
1902. J. H. Bryan	1932. George Fetterolf
1903. J. H. Hartman	1933. George M. Coates
1904. C. C. Rice	1934. Dunbar Roy
1905. J. W. Gleitsman	1935. Burt R. Shurly
1906. A. W. deRoaldes	1936. William B. Chamberlain
1907. H. S. Birkett	1937. John F. Barnhill
1908. A. Coolidge, Jr.	1938. George B. Wood

1939. James A. Babbitt	1956. LeRoy A. Schall
1940. Gordon Berry	1957. Harry P. Schenck
1941. Thomas E. Carmody	1958. Fred W. Dixon
1942-3. Charles J. Imperatori	1959. William J. McNally
1944-5. Harold I. Lillie	1960. Edwin N. Broyles
1946. Frank R. Spencer	1961. Dean M. Lierle
1947. Arthur W. Proetz	1962. Francis E. LeJeune
1948. Frederick T. Hill	1963. Anderson C. Hilding
1949. Ralph A. Fenton	1964. Albert C. Furstenberg
1950. Gordon B. New	1965. Paul H. Holinger
1951. H. Marshall Taylor	1966. Joel J. Pressman
1952. Louis H. Clerf	1967. Lawrence R. Boies
1953. Gordon F. Harkness	1968. Francis W. Davison
1954. Henry B. Orton	1969. Alden H. Miller
1955. Bernard J. McMahon	1970. DeGraaf Woodman
1971. F. Johnson Putney	

Vice-Presidents

1879. F. H. Davis	J. O. Roe
1880. W. C. Glasgow	W. Porter
1881. E. L. Shurly	E. F. Ingals
1882. C. Seiler	S. Johnston
1883. S. W. Langmaid	W. H. Daly
1884. J. H. Hartman	G. W. Major
1885. H. A. Johnson	J. N. Mackenzie
1886. E. C. Morgan	S. W. Langmaid
1887. J. N. Mackenzie	C. E. DeM. Sajous
1888. W. C. Glasgow	C. E. Bean
1889. F. Holden	J. H. Hartman
1890. J. O. Roe	S. Johnston
1891. M. J. Asch	J. C. Mulhall
1892. S. Johnston	W. E. Casselberry
1893. J. C. Mulhall	S. H. Chapman
1894. C. C. Rice	A. W. deRoaldes
1895. J. Wright	D. N. Rankin
1896. T. M. Murray	H. S. Birkett
1897. A. W. MacCoy	F. W. Hinkel
1898. J. W. Farlow	M. R. Brown
1899. T. A. DeBlois	A. A. Bliss
1900. H. L. Wagner	

1901. J. W. Gleitsmann	D. Braden Kyle
1902. G. A. Leland	T. Melville Hardie
1903. J. H. Lowman	W. Peyre Porcher
1904. Thomas Hubbard	W. J. Freeman
1905. J. L. Goodale	C. W. Richardson
1906. G. H. Makuen	A. R. Thrasher
1907. J. P. Clark	J. E. Rhodes
1908. E. Mayer	F. R. Packard
1909. C. G. Coakley	H. P. Mosher
1910. Robert C. Myles	J. M. Ingersoll
1911. F. C. Cobb	B. R. Shurly
1912. A. W. Watson	W. Scott Renner
1913. F. E. Hopkins	Geo. F. Shambaugh
1914. Clement T. Theisen	Lewis A. Coffin
1915. J. Gordon Wilson	Christian R. Holmes
1916. Thomas H. Halsted	Greenfield Sluder
1917. John Edwin Rhodes	D. Crosby Greene
1918. G. E. Shambaugh	John R. Winslow
1919. Francis R. Packard	Harmon Smith
1920. Harmon Smith	W. B. Chamberlin
1921. Dunbar Roy	Robert C. Lynch
1922. George Fetterolf	Lorenzo B. Lockard
1923. Hubert Arrowsmith	Joseph B. Greene
1924. Ross H. Skillern	Gordon Berry
1925. John E. Mackenty	Robert Levy
1926. Lewis A. Coffin	William V. Mullin
1927. Charles W. Richardson	Hill Hastings
1928. Robert Clyde Lynch	Francis P. Emerson
1929. William B. Chamberlin	Ralph Albert Fenton
1930. Harris P. Mosher	James A. Babbitt
1931. Joseph B. Greene	E. Ross Faulkner
1932. Gordon Berry	Frank A. Spencer
1933. E. Ross Faulkner	Thomas S. Carmody
1934. Gordon B. New	Samuel McCullagh
1935. Edward C. Sewall	H. Marshall Taylor
1936. William P. Wherry	Harold I. Lillie
1937. Frank R. Spencer	Bernard J. McMahon
1938. Ralph A. Fenton	Frederick T. Hill
1939. John H. Foster	Thomas R. Gittins
1940. Charles H. Porter	Gordon F. Harkness

1941. Arthur W. Proetz	Henry B. Orton
1942-3. Harold I. Lillie	Dean M. Lierle
1944-5. John J. Shea	Thomas C. Galloway
1946. H. Marshall Taylor	C. Stewart Nash
1947. John J. Shea	Frederick A. Figi
1948. Henry B. Orton	Anderson C. Hilding
1949. LeRoy A. Schall	Fletcher D. Woodward
1950. W. Likely Simpson	Lyman G. Richards
1951. Wm. J. McNally	Thomas C. Galloway
1952. J. Mackenzie Brown	Edwin N. Broyles
1953. Claude C. Cody	Daniel S. Cunning
1954. James H. Maxwell	Clyde A. Heatly
1955. Robert L. Goodale	Paul H. Holinger
1956. Henry M. Goodyear	Robert E. Priest
1957. Francis E. LeJeune	Pierre P. Viole
1958. Charles Blassingame	Chevalier L. Jackson
1959. James Maxwell	Oliver Van Alyea
1960. Walter Theobald	Anderson Hilding
1961. Julius W. McCall	P. E. Ireland
1962. Paul M. Moore	Jerome A. Hilger
1963. Paul M. Holinger	Lester A. Brown
1964. G. Slaughter Fitz-Hugh	Daniel C. Baker
1965. C.E. Munoz-MacCormick	Arthur J. Cracovaner
1966. Lawrence R. Boies	G. Edward Tremble
1967. John F. Daly	Stanton A. Friedberg
1968. DeGraaf Woodman	John Murtagh
1969. Joseph P. Atkins	Stanton A. Friedberg
1970. Robert B. Lewy	Oliver W. Suehs
1971. James A. Harrill	James D. Baxter

Secretaries and Treasurers

1879. G. M. Lefferts	1895. H. L. Swain
1882. D. Bryson Delavan	1900. P. E. Newcomb
1889. C. H. Knight	1911. Harmon Smith

Secretaries

1912. Harmon Smith	1939. Charles J. Imperatori
1918. D. Bryson Delavan	1942. Arthur W. Proetz
1919. J. M. Ingersoll	1947. Louis H. Clerf
1920. George M. Coates	1952. Harry P. Schenck
1933. William V. Mullin	1957. James H. Maxwell
1935. James A. Babbitt	1959. Lyman G. Richards
1968. Frank D. Lathrop	

Treasurers

1912.	J. Payson Clark	1939.	Frederick T. Hill
1923.	George Fetterolf	1948.	Gordon F. Harkness
1932.	William V. Mullin	1953.	Fred W. Dixon
1933.	James A. Babbitt	1958.	Francis E. LeJeune
1935.	Charles J. Imperatori	1962.	Alden H. Miller
	1969.	Charles M. Norris	

Librarians

1879.	F. H. Bosworth	1930.	John F. Barnhill
1883.	T. R. French	1934.	Burt R. Shurly
1903.	J. H. Bryan	1935.	George M. Coates

Librarian and Historian

1936.	George M. Coates	1944.	Louis H. Clerf
-------	------------------	-------	----------------

Librarian, Historian and Editor

1947.	Harry P. Schenck	1960.	Francis W. Davison
1952.	Bernard J. McMahon	1964.	F. Johnson Putney
1955.	Edwin N. Broyles	1971.	Charles F. Ferguson

PAST FELLOWS

Dates indicate original election to the Association

**Deceased*

Honorary Fellows

- *1908. Barnhill, John F., Miami Beach, Florida.
- *1893. Birkett, Herbert S., Montreal, Canada.
- *1878. Bosworth, Francke H., New York, N. Y.
- *1917. Coates, George M., Philadelphia, Pa.
- *1918. Dean, Lee Wallace, St. Louis, Mo.
- *1881. Delavan, D. Bryson, New York, N. Y.
- *1893. deRoaldes, Arthur W., New Orleans, La.
- *1890. De La Sota Y. Lastra, Ramon, Seville, Spain.
- *1923. Fenton, Ralph A., Portland, Oregon.
- *1879. French, Thomas R., Brooklyn, N. Y.
- *1880. Garcia, Senior Manuel, London, England.
- *1903. Harris, Thos J., New York, N. Y.
- *1928. Hill, Frederick T., Waterville, Me
- *1907. Jackson, Chevalier, Schwenksville, Pa.
- *1878. Johnston, Samuel, Baltimore, Md.
- *1878. Lefferts, George Morewood, Katonah, N. Y.
- *1914. Levy, Robert, Denver, Colo.
- *1918. Lewis, Fielding O., Media, Pa.
- *1883. Mackenzie, John N., Baltimore, Md.
- *1881. Mackenzie, Sir Morel, London, England.
- *1910. Masser, Ferdinand, Naples, Italy.
- *1904. Mosher, Harris P., Marblehead, Mass.
- *1910. Moure, J. J. E., Bordeaux, France.
- *1937. Nager, F. R., Zurich, Switzerland.
- *1918. Oliver, H. K., Boston, Mass.
- *1906. Pierce, Norval Harvey, San Diego, Calif.
- *1924. Proetz, Arthur C., St. Louis, Mo.
- *1909. Semon, Sir Felix, Great Missenden, England.
- *1878. Solis-Cohen, J., Philadelphia, Pa.

- *1889. Swain, Henry L., New Haven, Conn.
- *1914. Thomson, Sir St. Clair, London, Eng.
- *1903. Tilley, Herbert, London, England.
- *1914. Wagner, Clinton, New York, N. Y.
- *1890. Wright, Jonathan, Pleasantville, N. Y.

Corresponding Fellows

- *1892. Browne, Lennox, London, England.
- *1938. Blair, Vilray P., St. Louis, Missouri.
- *1968. Cawthorne, Sir Terence, London, England.
- *1940. Colledge, Lionel, London, England.
- *1901. Collier, Mayo, Kearsney, Abbey, Kent, England.
- *1893. Desvernine, Carlos M., Havana, Cuba.
- *1930. Emerson, Francis P., Franklin, Mass.
- *1943. Eggston, Andrew A., New York, N. Y.
- *1961. Faaborg-Andersen, Knud, Nykobing, Denmark.
- *1936. Fraser, John S., Edinburgh, Scotland.
- *1901. Grant, Sir James Dundas, London, England.
- *1887. Cougenheim, A., Paris, France.
- *1894. Holden, Edgar, Newark, N. J.
- *1919. Kelly, Adam Brown, Helensburgh, Scotland.
- *1881. Labus, Carlo, Milan, Italy.
- *1950. Larsell, Olof, Portland, Oregon.
- *1931. LaSagna, Francesco, Parma, Italy.
- *1926. Law, Frederick M., New York, N. Y.
- *1921. LeMaitre, Ferdinand, Paris, France.
- *1902. Lermoyez, Marcel, Paris, France.
- *1897. Luc, H., Paris, France.
- *1896. MacDonald, Greville, Haslemere, Surrey, England.
- *1894. MacIntyre, John, Glasgow, Scotland.
- *1903. McBride, P., York, England.
- *1920. McKenzie, Dan, London, England.
- *1919. McKernon, James F., New Canaan, Conn.
- *1880. Meyer, Wilhelm, Copenhagen, Denmark.
- *1910. Moure, J. J. E., Bordeaux, France.
- *1896. Mygind, Holger, Copenhagen, Denmark.
- *1950. Neil, James Hardie, Auckland, New Zealand.

- *1919. Paterson, Donald Rose, Cardiff, Wales.
- *1941. Patterson, Norman, Herts, England.
- *1919. Rogers, John, Jr., New York, N. Y.
- *1894. Sajous, C. E. DeM., Philadelphia, Pa.
- *1924. Schaefer, J. Parson, Philadelphia, Pa.
- *1896. Schmiegelow, Ernst, Copenhagen, Denmark.
- *1946. Segura, Eliseo, Buenos Aires, Argentina.
- *1940. Soto, E. Fernandez, Havana, Cuba.
- *1881. Thornton, Pugin, London, England.
- *1913. Turner, A. Logan, Edinburgh, Scotland.
- *1880. Whistler, W. McNeil, London, England.
- *1901. Wingrave, Wyatt, Lyme Regis, Dorset, England.
- *1894. Wolfenden, R. Norris, Kent, England.

Emeritus Fellows

- *1936. Ballenger, Howard C., Winnetka, Ill.
- *1923. Barlow, Roy A., Nova Scotia, Canada.
- *1915. Barnes, Harry Aldrich, Kingston, Mass.
- *1944. Beatty, Hugh G., Columbus, Ohio
- *1928. Beck, Joseph C., Chicago, Illinois.
- *1921. Berry, Gordon, Worcester, Mass.
- *1941. Bowers, Wesley C., New York, N. Y.
- *1901. Brown, J. Price, Toronto, Canada.
- *1891. Bryan, Joseph H., Washington, D. C.
- *1913. Butler, Ralph, Philadelphia, Pa.
- *1930. Campbell, Edward H., Philadelphia, Pa.
- *1897. Clark, J. Payson, Boston, Mass.
- *1899. Cobb, Frederick C., Bradenton, Florida.
- *1939. Cody, Claude C., Jr., Houston, Texas.
- *1905. Coffin, Lewis A., New York, N. Y.
- *1893. Coolidge, Algernon, Boston, Mass.
- *1937. Crowe, Samuel J., Baltimore, Maryland.
- *1941. Cunning, Daniel S., New York, N. Y.
- *1913. Dabney, Virginia, Washington, D. C.
- *1882. De Blois, Thomas Amory, Boston, Mass.
- *1941. Dixon, Fred W., Shaker Heights, Ohio.
- *1892. Farlow, John W. Boston, Mass.
- *1930. Figi, Frederick A., Rochester, Minn.
- *1922. Forbes, Henry H., New York, N. Y.

- *1933. Foster, John H., Houston, Texas.
- *1905. Freer, Otto T., Chicago, Ill.
- *1932. Furstenberg, Albert C., Ann Arbor, Mich.
- *1940. Gatewood, E. Tribble, Richmond, Va.
- *1928. Gittins, Thomas R., Sioux City, Iowa.
- *1880. Gleitsmann, Joseph W., New York, N. Y.
- *1922. Goldsmith, Perry G., Toronto, Canada.
- *1898. Goodale, Joseph L., Ipswich, Mass.
- *1932. Graham, Harrington B., San Francisco, California.
- *1906. Greene, D. Crosby, Jr., Boston, Mass.
- *1917. Greene, Joseph B., Asheville, N. C.
- *1950. Hall, Colby, Encino, Calif.
- *1905. Halsted, Thomas H., Los Angeles, Calif.
- *1896. Hardie, Thomas Melville, Chicago, Ill.
- *1959. Hart, Verling K., Charlotte, N. C.
- *1915. Hastings, Hill, Los Angeles, Calif.
- *1944. Havens, Fred Z., Rochester, Minn.
- *1888. Hinkel, Frank Whitehill, Buffalo, New York.
- *1895. Hopkins, Frederick E., Springfield, Mass.
- *1930. Houser, Karl M., Ardmore, Pa.
- *1927. Hubbard, Thomas, Toledo, Ohio.
- *1919. Hurd, Lee Maidment, Rowayton, Conn.
- *1920. Imperatori, Charles J., Essex, N. Y.
- *1904. Ingersoll, John Marvin, Miami, Fla.
- *1928. Jarvis, DeForest C., Barre, Vt.
- *1939. Johnston, Willam H., Santa Barbara, Calif.
- *1942. Kelly, Joseph D., New York, N. Y.
- *1918. Kenyon, Elmer L., Chicago, Ill.
- *1921. Kernan, John D., New York, N. Y.
- *1929. Kistner, Frank B., Portland, Oregon.
- *1885. Knight, Charles H., New York, N. Y.
- *1939. Large, Secord H., Cleveland, Ohio.
- *1894. Leland, George A., Boston, Mass.
- *1922. Lillie, Harold I., Rochester, Minn.
- *1943. Lincoln, William R., Cleveland, Ohio.
- *1928. Lyman, Harry Webster, St. Louis, Mo.
- *1886. MacCoy, Alexander W., Philadelphia, Pa.
- *1941. Martin, Robert C., San Francisco, Calif.

- *1896. Mayer, Emil, New York, N. Y.
- *1951. McCart, Howard W. D., Toronto, Canada.
- *1939. McCaskey, Carl H., Indianapolis, Indiana.
- *1943. McCullagh, Samuel, New York, N. Y.
- *1923. McKinney, Richmond, Memphis, Tenn.
- *1933. McMahon, Bernard J., St. Louis, Mo.
- *1928. MacPherson, Duncan, New York, N. Y.
- *1939. Myers, John L., Kansas City, Mo.
- *1901. Myles, Robert C., New York, N. Y.
- *1937. Nash, C. Stewart, Rochester, N. Y.
- *1922. New, Gordon B., Rochester, Minn.
- *1923. Newhart, Horace, Minneapolis, Minn.
- *1903. Packard, Francis R., Philadelphia, Pa.
- *1878. Porter, William, Ocean Springs, Miss.
- *1942. Potts, John B., Omaha, Nebr.
- *1903. Renner, W. Scott, Buffalo, N. Y.
- *1897. Rhodes, John Edwin, Chicago, Ill.
- *1884. Rice, Clarence C., New York, N. Y.
- *1905. Richards, George L., South Yarmouth, Mass.
- *1878. Robinson, Beverly, New York, N. Y.
- *1921. Sauer, William E., St. Louis, Mo.
- *1923. Sewall, Edward C., Palo Alto, Calif.
- *1930. Seydell, Ernest M., Wichita, Kansas.
- *1907. Shambaugh, George E., Chicago, Ill.
- *1908. Smith, Harmon, New York, N. Y.
- *1923. Spencer, Frank R., Boulder, Colo.
- *1927. Tobey, Harold G., Boston, Mass.
- *1925. Tucker, Gabriel, Haverford, Pa.
- *1892. Wagner, Henry L., San Francisco, Calif.
- *1892. Watson, Arthur W., Philadelphia, Pa.
- *1948. Whalen, Edward J., Hartford, Conn.
- *1922. White, Francis W., New York, N. Y.
- *1939. Wilson, J. Gordon, Old Bennington, Vt.
- *1905. Wood, George B., Wynnewood, Pa.
- *1935. Woodward, Fletcher D., Charlottesville, Va.

Active Fellows

- *1880. Allen, Harrison, Philadelphia, Pa.
- *1917. Arrowsmith, Hubert, Brooklyn, N. Y.

- *1879. Asch, Morris J., New York, N. Y.
- *1942. Ashley, Rae E., San Francisco, Calif.
- *1923. Babbitt, James A., Philadelphia, Pa.
- *1906. Ballenger, William L., Chicago, Ill.
- *1880. Bean, C. E., St. Paul, Minn.
- *1949. Beck, August L., New Rochelle, N. Y.
- *1904. Berens, T. Passmore, New York, N. Y.
- *1924. Bigelow, Nolton, Providence, R. I.
- *1938. Blassingame, Charles D., Memphis, Tenn.
- *1893. Bliss, Arthur Ames, Philadelphia, Pa.
- *1951. Boyden, Guy L., Portland, Oregon.
- *1895. Boylan, J. E., Cincinnati, Ohio.
- *1932. Brown, John Mackenzie, Los Angeles, Calif.
- *1892. Brown, Moreau R., Chicago, Ill.
- *1933. Buckley, Robert E., New York, N. Y.
- *1915. Canfield, R. Bishop, Ann Arbor, Mich.
- *1934. Carmack, John Walter, Indianapolis, Ind.
- *1924. Carmody, Thomas E., Denver, Colo.
- *1889. Casselberry, William E., Chicago, Ill.
- *1883. Chamberlain, C. W., Hartford, Conn.
- *1917. Chamberlin, William B., Cleveland, Ohio.
- *1896. Chappell, W. F., New York, N. Y.
- *1882. Chapman, S. Hartwell, New Haven, Conn.
- *1902. Coakley, Cornelius G., New York, N. Y.
- *1913. Coffin, Rockwell C., Boston, Mass.
- *1918. Cox, Gerald H., New York, N. Y.
- *1880. Cushing, E. W., Boston, Mass.
- *1878. Cutter, Ephraim, West Falmouth, Mass.
- *1880. Daly, W. H., Pittsburgh, Pa.
- *1878. Davis, F. H., Chicago, Ill.
- *1941. Davis, Warren B., Philadelphia, Pa.
- *1926. Dennis, Frank Lownes, Colorado Springs, Colo.
- *1901. Dickerman, E. T., Chicago, Ill.
- *1878. Donaldson, Frank, Baltimore, Md.
- *1947. Engler, Clarence W., Cleveland, Ohio.
- *1954. Equen, Murdock S., Atlanta, Ga.
- *1935. Eves, Curtis C., Philadelphia, Pa.
- *1919. Faulkner, E. Ross, New York, N. Y.
- *1914. Fetterolf, George, Philadelphia, Pa.
- *1901. Freeman, Walter J., Philadelphia, Pa.

- *1917. Friedberg, Stanton A., Chicago, Ill.
- 1940. Fuchs, Valentine H., New Orleans, La.
- *1897. Frothingham, Richard, New York, N. Y.
- *1909. Getchell, Albert C., Worcester, Mass.
- *1907. Gibb, Joseph S., Philadelphia, Pa.
- *1940. Gill, William D., San Antonio, Texas.
- *1878. Glasgow, William Carr, St. Louis, Mo.
- *1913. Goldstein, Max A., St. Louis, Mo.
- *1905. Grayson, Charles P., Philadelphia, Pa.
- *1934. Grove, William E., Milwaukee, Wisconsin.
- *1933. Harkness, Gordon F., Davenport, Iowa.
- *1878. Hartman, J. H., Baltimore, Md.
- *1945. Hickey, Harold L., Denver, Colo.
- *1879. Holden, Edgar, Newark, N. J.
- *1907. Holmes, Christian R., Cincinnati, Ohio.
- *1882. Hooper, Franklin H., Boston, Mass.
- *1893. Hope, George B., New York, N. Y.
- *1938. Hourn, George E., St. Louis, Mo.
- *1939. Hunt, Westley Marshall, New York, N. Y.
- *1901. Hyatt, Frank, Washington, D. C.
- *1925. Iglauer, Samuel, Cincinnati, Ohio.
- *1878. Ingals, E. Fletcher, Chicago, Ill.
- *1882. Ives, Frank L., New York, N. Y.
- *1938. Jackson, Chevalier L., Philadelphia, Pa.
- *1880. Jarvis, William C., New York, N. Y.
- *1878. Johnson, Hosmer A., Chicago, Ill.
- *1879. Johnson, Woolsey, New York, N. Y.
- *1960. Johnston, Kenneth C., Chicago, Ill.
- *1944. Jones, Marvin F., New York, N. Y.
- *1879. Kealhofer, R. H., St. Louis, Mo.
- *1964. Keim, W. Franklin, Montclair, N. J.
- *1942. King, Edward D., North Hollywood, Calif.
- *1901. King, Gordon, New Orleans, La.
- *1885. Knight, Charles H., New York, N. Y.
- *1878. Knight, Frederick Irving, Boston, Mass.
- *1898. Kyle, D. Braden, Philadelphia, Pa.
- *1880. Langmaid, Samuel W., Boston, Mass.
- *1878. Lincoln, Rufus P., New York, N. Y.
- *1911. Lockard, Lorenzo B., Denver, Colo.

- *1913. Loeb, Hanau W., St. Louis, Mo.
- *1897. Logan, James E., Kansas City, Mo.
- *1935. Looper, Edward A., Baltimore, Md.
- *1888. Lowman, John H., Cleveland, Ohio.
- *1919. Lynah, Henry L., New York, N. Y.
- *1952. Lynch, Mercer G., New Orleans, La.
- *1915. Lynch, Robert Clyde, New Orleans, La.
- *1879. McBurney, Charles, New York, N. Y.
- *1927. McGinnis, Edwin, Chicago, Ill.
- 1936. McGregor, Gregor, Toronto, Canada.
- *1913. McKimmie, O. A., Washington, D. C.
- *1945. McLaurin, John G., Dallas, Texas.
- *1885. McSherry, H. Clinton, Baltimore, Md.
- *1914. Mackenty, John E., New York, N. Y.
- *1898. Makuen, G. Hudson, Philadelphia, Pa.
- *1881. Major, G. W., Montreal, Canada.
- *1948. Maxwell, James H., Ann Arbor, Mich.
- *1954. Meltzer, Philip E., Boston, Mass.
- *1881. Morgan, E. C., Washington, D. C.
- *1950. Morrison, Lewis F., San Francisco, Calif.
- *1940. Morrison, William W., New York, N. Y.
- *1886. Mulhall, J. C., St. Louis, Mo.
- *1925. Mullin, William V., Cleveland, Ohio.
- *1914. Munger, Carl E., Waterbury, Conn.
- *1892. Murray, T. Morris, Washington, D. C.
- *1881. Mynter, H., Buffalo, N. Y.
- *1893. Newcomb, James E., New York, N. Y.
- *1895. Nichols, J. E. H., New York, N. Y.
- *1927. Orton, Henry B., Newark, N. J.
- *1894. Park, William H., New York, N. Y.
- *1892. Porcher, W. Peyre, Charleston, S. C.
- *1927. Porter, Charles T., Boston, Mass.
- *1954. Pressman, Joel J., Los Angeles, Calif.
- *1908. Randall, B. Alexander, Philadelphia, Pa.
- *1882. Rankin, D. N., Allegheny, Pa.
- *1934. Richards, Lyman G., Wellesley Hills, Mass.
- *1902. Richardson, Charles W., Washington, D. C.
- *1930. Ridpath, Robert E., Philadelphia, Pa.
- *1879. Roe, John O., Rochester, N. Y.

- *1945. Robb, James M., Detroit, Michigan.
- *1953. Roberts, Sam E., Kansas City, Mo.
- *1881. Robertson, J. M., Detroit, Mich.
- *1913. Roy, Dunbar, Atlanta, Ga.
- *1878. Rumbold, T. F., St. Louis, Mo.
- *1879. Seiler, Carl, Philadelphia, Pa.
- *1928. Shea, John Joseph, Memphis, Tennessee.
- *1893. Shields, Charles M., Richmond, Pa.
- *1909. Shurly, Burt R., Detroit, Mich.
- *1878. Shurly, E. L., Detroit, Mich.
- *1892. Simpson, William Kelly, New York, N. Y.
- *1919. Skillern, Ross H., Philadelphia, Pa.
- *1909. Sluder, Greenfield, St. Louis, Mo.
- *1879. Smith, Andrew H., Geneva, N. Y.
- *1932. Smyth, Duncan Campbell, Boston, Mass.
- *1928. Sonnenschein, Robert, Chicago, Ill.
- *1924. Stein, Otto J., Chicago, Ill.
- 1934. Stevenson, Walter, Quincy, Ill.
- *1911. Staut, George C., Philadelphia, Pa.
- *1879. Tauber, Bernhard, Cincinnati, Ohio.
- *1924. Taylor, Hermon Marshall, Jacksonville, Fla.
- *1903. Theisen, Clement F., Albany, N. Y.
- *1899. Thorner, Max, Cincinnati, Ohio.
- *1892. Thrasher, Allen B., Cincinnati, Ohio.
- *1937. Tobey, George L., Jr., Boston, Mass.
- *1888. Van der Poel, S. O., New York, N. Y.
- *1938. Vail, Harris H., Cincinnati, Ohio.
- *1936. Voislowsky, Antonie P., New York, N. Y.
- *1954. Walsh, Theodore E., St. Louis, Mo.
- *1933. Wanamaker, Allison T., Seattle, Wash.
- *1896. Ward, Marshall R., Pittsburgh, Pa.
- *1879. Ward, Whitfield, New York, N. Y.
- *1886. Westbrook, Benjamin F., Brooklyn, N. Y.
- *1924. Wherry, William P., Omaha, Neb.
- *1924. White, Leon E., Boston, Mass.
- *1939. Williams, Horace J., Philadelphia, Pa.
- *1942. Wishart, D. E. Staunton, Toronto, Canada.
- *1922. Wishart, David J. G., Toronto, Canada.
- *1940. Wood, V. Visscher, St. Louis, Mo.
- *1896. Wollen, Green V., Indianapolis, Ind.
- *1953. Wilkerson, William W., Nashville, Tenn.

Roster of Present Fellows

1972

LIST OF FELLOWS

Date Indicates Year Admitted to Active Fellowship

Attendance at meetings is shown by figures following each name.

Asterisk (*) indicates year paper was read.

Active Fellows

1962. ALEXANDER, FRED W., 3461 Warrensville Center Rd., Shaker Heights, Ohio 44122, 1962, '63*, '64, '66, '68, '69, '70, '71, '72.
1958. ALFARO, VICTOR R., 916 - 19th St., N. W., Washington, D.C. 20006, 1958, '59, '60, '61, '62, '63, '64, '65, '66, '67, '69, '70, '71, '72.
1969. ANDREWS, ALBERT H. JR., 122 S. Michigan Ave., Chicago, Ill., 60603, 1970, '71, '72.
1962. ARNOLD, GODFREY E., 2500 N. State St., Jackson, Mississippi 39216, 1962, '63*, '64*, '66, '69, '70, '72.
1958. ATKINS, JOSEPH P., 3400 Spruce St., Philadelphia, Pa. 19104, 1958, '59*, '60, '61, '62, '63, '64, '65, '67, '68, '69, '70, '71*, '72*.
1969. AUSBAND, JOHN R., Bowman Gray School of Medicine, Winston-Salem, N. C. 27103, 1970, '71, '72.
1956. BAKER, DANIEL CLIFTON, JR., 180 Fort Washington Ave., New York, N. Y. 10032, 1956, '57, '58, '59*, '60, '61, '62*, '63, '64, '65, '66, '69*, '70, '71*, '72*.
1970. BALLENGER, JOHN J., 723 Elm St., Winnetka, Ill. 60093, 1971, '72.
1963. BAXTER, JAMES D., 687 Pine Ave. West, Montreal, 112, Quebec, Canada, 1963, '65*, '66, '67, '68, '69, '70, '71, '72.
1944. BOIES, LAWRENCE R., Box 396, University Hospital, Minneapolis, Minnesota 55455, 1944, '46, '47, '48*, '49, '50*, '51*, '53, '54, '55, '56, '57, '58, '59, '60, '61, '62, '63, '64, '65, '66, '67, '68*, '69, '71.
1955. BORDLEY, JOHN E., Johns Hopkins Hospital, Baltimore, Maryland 21205, 1955, '56, '57, '59, '60, '62, '63, '64, '65, '66, '67, '69, '70, '71, '72.
1959. BREWER, DAVID W., 1100 E. Genesee St., Syracuse, N. Y. 13210, 1959, '60*, '61, '62*, '63*, '66, '70.

1955. BROWN, LESTER ALEXANDER, 490 Peachtree Street, N.E., Atlanta, Georgia 30308, 1955, '56, '57, '58, '59, '61, '63, '65, '68, '69, '70, '71, '72.
1940. BROYLES, EDWIN N., 11 East Chase St., Baltimore, Maryland 21202, 1940, '41*, '42, '46, '48*, '49, '50, '51*, '52, '53, '54, '55, '56, '58, '59*, '60, '61*, '63, '64, '65, '67, '71.
1963. BRYCE, DOUGLAS P., O.P.D. Toronto General Hospital, Toronto, Canada, 1963*, '64, '66*, '67*, '68*, '69, '70, '71, '72.
1968. CHANDLER, J. R., 1700 N.W. 10th Ave., Miami, Fla. 33136, 1968, '69*, '70, '71, '72.
1967. COCKE, EDWIN W., JR., 899 Madison, Memphis, Tenn. 38102, 1967, '68, '69, '70, '72.
1964. CODY, CLAUDE C., III, 1600 Memorial Professional Building, Houston, Texas 77002, 1964, '65, '67, '69, '71.
1971. COHEN, SEYMOUR R., 6221 Wilshire Blvd., Los Angeles, Calif. 90048, 1971, '72*.
1957. CONLEY, JOHN J., 139 East 36th Street, New York, N. Y. 10016, 1958*, '60*, '61, '62*, '63*, '64, '65, '70, '72.
1957. CONVERSE, JOHN MARQUIS, 722 Park Avenue, New York, N. Y. 10021, 1960, '62*, '67.
1959. CRACOVANER, ARTHUR J., 103 E. 78th St., New York, N. Y. 10021, 1959, '60, '61*, '62, '63, '65, '66, '67, '68, '69, '72.
1960. DALY, JOHN F., Faculty Practice Offices, 566 First Ave., New York, N. Y. 10016, 1960, '61*, '62, '63, '64, '65, '66, '67, '68, '69, '70, '71, '72.
1951. DAVISON, FRANCIS W., Geisinger Medical Center, Danville, Pa. 17812, 1951, '52, '53*, '54, '55, '56, '57, '58, '59, '60, '61, '62, '63*, '64, '65, '66, '67*, '68, '69*, '70, '71, '72.
1966. DEVINE, KENNETH D., Mayo Clinic, Rochester, Minn. 55901, 1966, 1948*, '49, '51, '53, '54, '56, '57, '59, '62, '64, '65*, '66, '67, '68, '72*.
1968. DEWEESE, DAVID D., 3181 S.W. Sam Jackson Park Rd., Portland, Ore. 97202, 1968, '69*.
1969. DICKINSON, JOHN T., 1501 Locust St., Pittsburgh, Pa. 15219, 1970, '71, '72.

1968. FARRIOR, RICHARD T., 509 Bay St., Tampa, Fla. 33606, 1968, '69, '70*, '72.
1964. FEARON, BLAIR, 308 Medical Arts Building, Toronto 5, Ontario, Canada, 1964, '66, '67, '68, '69, '70, '71*, '72*.
1963. FERGUSON, CHARLES F., 300 Longwood Ave., Boston, Mass. 02115, 1963, '64*, '66, '67*, '68, '69*, '70, '71, '72.
1955. FITZ-HUGH, GLASSELL SLAUGHTER, 2003 Spottswood Road, Charlottesville, Virginia 22903, 1955, '57, '59, '60, '61, '62*, '64, '65, '66, '67*, '68, '69, '70, '71, '72.
1970. FRAZER, JOHN P., 260 Crittenden Blvd., Rochester, N. Y. 14620, 1971, '72.
1956. FRIEDBERG, STANTON A., 1725 West Harrison St., Chicago, Ill. 60612, 1956, '57*, '58, '59, '60, '61, '62, '63, '64, '65*, '67, '68, '69, '70, '71*, '72.
1959. GOLDMAN, JOSEPH L., 1050 Park Ave., New York, N. Y. 10028, 1959, '60*, '61, '62, '63, '64, '65, '66, '67, '68, '69, '70, '71, '72*.
1965. HANCKEL, RICHARD W., 80 Barre St., Charleston, S. C. 29401, 1965, '66, '67, '69, '70, '71, '72.
1957. HARRILL, JAMES A., Bowman Gray School of Medicine, Winston-Salem, N. C. 27103, 1957, '58, '59, '61, '62, '63, '64, '66, '67, '68, '69, '71.
1960. HARRIS, HERBERT, 907 Hermann Professional Building, Houston, Texas 77025, 1960, '61*, '62, '63, '64, '65*, '66, '67, '68, '69, '70, '71, '72.
1959. HENRY, G. ARNOLD, 170 St. George St., Toronto, Canada, 1959, '61, '63, '66, '67, '69, '70.
1943. HILDING, ANDERSON C., Research Laboratory, St. Luke's Hospital, Duluth, Minnesota 55805, 1944*, '46, '47, '48*, '49, '50, '51, '53, '55, '56*, '57, '60, '61, '62*, '63, '64*, '65, '66, '67, '68, '69, '70, '71, '72.
1955. HILGER, JEROME A., Suite 6A, 393 Dunlap St., St. Paul, Minnesota 55104, 1955, '56*, '57, '58, '59, '60, '62, '63, '64, '65, '66, '68, '69, '70, '71.
1945. HOLINGER, PAUL H., 700 North Michigan Ave., Chicago, Illinois 60611, 1946, '47, '49, '50*, '51*, '52, '53, '54*, '55, '56, '57, '58*, '59, '60, '61*, '62*, '63, '64, '65, '66*, '68, '69*, '72*.

1957. HOLMES, EDGAR M., 2000 Washington St., Newton, Mass. 02162, 1957, '59, '61, '63, '68, '70, '71, '72.
1961. JONES, EDLEY H., 1301 Washington St., Vicksburg, Miss. 39180, 1961, '62, '63*, '65, '66, '67, '68, '69, '70, '71, '72.
1965. KING, JAMES T., Baptist Professional Building, Atlanta, Ga. 30312, 1965, '66, '67, '69, '70, '71.
1963. KIRCHNER, JOHN A., 333 Cedar St., New Haven, Conn. 06510, 1963, '65*, '67*, '68, '69*, '70, '71*, '72*.
1965. KNIGHT, JOHN S., 305 West 43rd St., Kansas City, Mo. 64111, 1965, '66*, '67, '69, '70, '71, '72.
1963. LATHROP, FRANK D., R.F.D. No. 1, Pittsford, Vt. 05763, 1963, '64*, '67*, '69, '70, '71, '72.
1953. LEDERER, FRANCIS LOEFFLER, 1300 Lake Shore Drive, Apt. 32D, Chicago, Illinois 60610, 1953, '54, '55, '56, '57*, '58, '60, '61, '62, '63*, '64, '65, '66, '68*, '69, '70, '72.
1966. LEWIS, JOHN S., 3 East 71st Street, New York, N. Y. 10021, 1966, '67, '68, '69*, '70, '71, '72.
1961. LEWY, ROBERT B., 25 East Washington St., Chicago, Ill. 60602, 1961, '62*, '63, '65*, '67, '68, '69, '70, '71.
1972. LILLIE, JOHN C., 200 First St., S.W., Rochester, Minn. 55905, 1972.
1966. McCABE, BRIAN F., Dept. of Otolaryngology, University Hospitals, Iowa City, Iowa 52240, 1966, '69, '72*.
1963. McGOVERN, FRANCIS H., 139 South Main St., Danville, Virginia 24541, 1963, '64, '66, '68, '71, '72.
1951. McHENRY, LAWRENCE C., 301 N. W. 12th St., Oklahoma City, Okla. 73103, 1953*, '62, '63, '64, '65, '66, '68, '71.
1952. MILLER, ALDEN H., 1407 N. Vermont Ave., Los Angeles, Calif. 90027, 1952, '53*, '55, '57, '58*, '61, '62, '64, '66, '67*, '68, '69, '70, '71, '72.
1965. MILLER, DANIEL, Deaconess Medical Building, 110 Francis St., Boston, Mass. 02215, 1965, '66, '67, '68, '69*, '70, '71, '72.
1964. MONTGOMERY, WILLIAM W., 243 Charles St., Boston, Mass. 02114, 1964, '65*, '66*, '68*, '70, '71, '72.

1958. MONTREUIL, FERNAND, Hospital Notre Dame, 1560 E. Sherbrooke, Montreal 24, Canada, 1958, '60, '64, '67, '69.
1972. MORSE, HARRY R., Geisinger Memorial Hospital, Danville, Penn. 17821, 1972.
1957. MUNOZ-MACCORMICK, CARLOS EDUARDO, 71 Park Terrace, Santurce, Puerto Rico, 1957, '58, '59, '60, '61, '62, '63, '64, '65, '66, '67, '68, '69, '70, '71, '72.
1956. NORRIS, CHARLES MORGAN, 3401 North Broad Street, Philadelphia, Pennsylvania 19140, 1956, '57, '58*, '59, '60, '61*, '62, '63, '64, '66, '67, '68*, '69, '70*, '71, '72.
1961. OGURA, JOSEPH H., 640 So. Kingshighway, St. Louis, Mo. 63110 1961*, '62*, '63, '64*, '65, '66*, '67, '68*, '69, '70, '71*, '72.
1958. O'KEEFE, JOHN J., 255 S. 17th St., Philadelphia, Pa. 19103, 1958, '59*, '60, '62, '64, '67, '71.
1961. O'NEIL, JAMES J., 612 Medical Arts Building, Omaha, Nebraska 68102, 1961, '62*, '64, '67, '69, '70, '71.
1961. PANG, LUP Q., 1374 Nuuanu Ave., Honolulu, Hawaii 96817, 1961, '62*, '64, '66, '67, '70, '71, '72.
1961. PASTORE, PETER N., 5503 Riverside Drive, Richmond, Va. 23225, 1961, '62*, '64, '66, '67, '69, '71, '72.
1972. PENNINGTON, CLAUDE L., JR., 829 First St., Macon, Ga. 31201, 1972.
1967. PRATT, LORING W., 325-B Kennedy Memorial Drive, Waterville, Maine 04901, 1967, '68, '69, '70, '71, '72.
1951. PRIEST, ROBERT E., 79 S. Ninth St., Minneapolis, Minn. 55402, 1951, '53*, '54*, '56, '59, '60*, '61, '65, '67*, '68, '69, '70, '71, '72.
1951. PUTNEY, F. JOHNSON, 80 Barre St., Charleston, S. C. 29401, 1951, '52, '53*, '54, '55, '56, '58*, '59, '60, '61, '62, '63*, '64*, '65, '66, '67, '68*, '69*, '70*, '71, '72*.
1963. REED, GEORGE F., 766 Irving Ave., Syracuse, N. Y. 13210, 1963, '65*, '66, '68, '69*, '70, '71, '72.
1959. SANDERS, SAM H., 1286 Peabody Ave., Memphis, Tenn. 38104, 1959, '60, '61, '62, '63, '65, '70, '71, '72.

1964. SAUNDERS, WILLIAM H., N-820 University Hospital, Columbus, Ohio 43210, 1964, '65, '66, '68*, '69, '70*, '71, '72*.
1959. SILCOX, LOUIS E., 108-111 Lankenau Med. Bldg., Philadelphia, Pa. 19151, 1959, '60, '61, '62, '63, '64, '65, '66, '67, '68, '69, '70, '71, '72.
1958. SIMONTON, KINSEY M., 705 Juniper St., N.E., Atlanta, Ga. 30308, 1958, '59*, '62, '64, '66, '67, '69, '72.
1962. SISSON, GEORGE A., Northwestern U. Medical School, 303 Chicago Ave., Chicago, Ill. 60611, 1962, '63*, '65, '66, '68, '69, '70, '71, '72.
1964. SKOLNIK, EMANUEL M., 1853 West Polk Street, Chicago, Ill. 60612, 1964*, '65, '66*, '67, '68, '69, '70*, '71, '72.
1972. SOBOROFF, BURTON J., 307 N. Michigan Ave., Chicago, Ill. 60601, 1972.
1954. SOOY, FRANCIS A., University of California Hospital, 3rd and Parnassus Ave., San Francisco, Calif. 94122, 1954, '56*, '58, '60, '62, '63, '64, '65*, '67, '68*, '71.
1961. SUEHS, OLIVER W., 14 Medical Arts Square, Austin, Texas 78705, 1961, '62*, '63, '64, '66, '68, '69, '70, '71, '72.
1963. TABB, HAROLD G., 1430 Tulane Ave., New Orleans, La. 70112, 1963, '65, '66, '67, '69, '71, '72.
1954. THORNELL, WILLIAM C., 2340 Auburn Avenue, Cincinnati, Ohio 45219, 1955*, '57, '59, '60, '63, '68, '70, '72.
1963. TOLAN, JOHN F., 1118 Ninth Ave., Seattle, Washington 98101, 1963, '64, '65, '66, '67, '69, '71.
1967. TRIBLE, WILLIAM MACL., 1234 19th St., N.W., Washington, D.C. 20036, 1967, '68, '69*, '70, '71, '72.
1970. TUCKER, GABRIEL F., JR., 3401 North Broad St., Philadelphia, Pa. 19140, 1970*, '71, '72.
1962. WEAVER, DELMAR F., Med. Profess. Bldg., Culpeper, Va. 22701, 1962, '63, '64*, '65, '67*, '69, '70, '72.
1940. WELLS, FRANCIS L., 247 Commonwealth Avenue, Boston, Massachusetts 02116, 1940, '41, '42, '44, '46*, '47, '48, '49, '50, '51, '52, '53, '54, '55, '56*, '57, '58, '59, '60, '61, '62, '63, '64, '65*, '66, '67, '68, '69, '70, '71, '72.

1971. WILLIAMS, RUSSELL I., 1605 East 19th St., Cheyenne, Wyo. 82001, 1971, '72*.
1951. WOODMAN, DEGRAAF, Talbottown Lane, P.O. Box 560, Easton, Md. 21601, 1951, '53, '54, '55*, '56, '58, '59, '60, '61, '62, '63, '64, '65, '66, '67, '68, '69, '70, '71, '72.
1953. WORK, WALTER P., University Hospitals, 1405 E. Ann St., Ann Arbor, Michigan 48104, 1953, '54, '56, '58, '59*, '62, '63*, '65, '67, '68, '69, '72.

Honorary Fellows

1968. (1946) ALONSO, REGULES JUSTO E., Mercedes 1233, Montivideo, Uruguay.
1957. (1925) CLERF, LOUIS H., 5575 Eighth Avenue, North, St. Petersburg, Florida 33710, 1957, '58, '59, '60, '61, '63, '64, '65, '66, '68, '69, '70, '71, '72*.
1968. (1936) GALLOWAY, THOMAS C., 636 Church St., Evanston, Ill. 60201, 1969, '71.
1968. (1957) HUIZINGA, EELCO, Noorderhaven 7, Groningen, The Netherlands, 1957.
1967. (1933) LIERLE, DEAN M., University Hospitals, Iowa City, Iowa 52240, 1967, '68, '71.
1957. (1930) NEGUS, SIR VICTOR E., Flat 4, Nutcombe Height, Portsmouth Road, Hindhead, Surrey England, 1957*.
1966. (1957) ONO, JO, 75 Zaimoku-cho, Azabu, Minato-ku, Tokyo, Japan, 1971.
1968. (1937) PORTMANN, GEORGES, 25 bis Cours de Verdun, Bordeaux, France, 1947.
1968. (1957) RUEDI, LUZIUS, Ramistrasse 100, Zurich, Switzerland, 1957.
1970. (1948) WILLIAMS, HENRY L., II, 90 Imperial St., West St. Paul, Minn. 55118, 1971.

Corresponding Fellows

1972. ARSLAN, PROF. MICHELE, Univ. Hospital, Nuovo Polyclinico, Padua, Italy 35100, 1972.
1959. BARRETTO, PLINIO DE MATTOS, Rua Cons Torres, Homer 371, Sao Paulo, Brazil, 1960, '69.

1959. BATEMAN, GEOFFREY H., 55 Harley Street, London, W. 1, England.
1942. BATSON, OSCAR V., 3926 Pine St., Philadelphia, Pennsylvania 19104, 1942*, '54*.
1964. CLEVES, CARLOS, Carrera 14 No. 44-54 Apto. 202, Bogota, Colombia, S. A., 1970.
1966. DOHLMAN, GOSTA, Dept. of Otolaryngology, University of Toronto, Toronto, Canada, 1966.
1970. HALLIDAY, SIR GEORGE C., 143 Macquarrie St., Sydney, N.S.W. Australia.
1971. HARRISON, D. F. N., 330/332 Gray's Inn Road, London, W.C.1, England, 1971.
1970. HUTCHEON, JACK, Morris Towers, 149 Wickham Terrace, Brisbane, Australia, 1971.
1971. MACBETH, RONALD G., Radcliffe Infirmary, Oxford, England, 1971.
1968. NAKAMURA, FUMIO, Kyoto Prefectural U. Medicine, Kawara-Mach 1, Kamikyo-Ku, Kyoto, Japan.
1964. PEREZ, ALFREDO C., Instituto Celis Perez, Avenida Montes Deoca, Apartado 163, Valencia, Venezuela, S. A., 1965.
1971. RETHI, AUREL, Liszt Str 10, Budapest 6, Hungary.
1952. TAPIA ACUNA, RICARDO, Av. Insurgentes, Sur 300, Mexico 7 D.F., 1953, '57, '60*, '67.
1936. VIALLE, JACQUES, 27 Rue de France, Nice (Alpes Maritimes), France.

Emeritus Fellows

1966. (1945) CAMPBELL, PAUL A., 321 Park Hill Drive, San Antonio, Texas 78212.
1965. (1942) CANFIELD, NORTON, Harwood Hospital, Christiansted, St. Croix, Virgin Is.
1969. (1959) CARDWELL, EDGAR P., P.O. Box 581, Shell Island, Wrightsville Beach, N. C. 28480.
1969. (1947) EAGLE, WATT W., 703 Professional Drive, New Bern, N. C. 28560.

1972. (1952) ERICH, JOHN B., 102 Second Ave., Rochester, Minn. 55901.
1970. (1940) GOODALE, ROBERT L., 141 Argilla Rd., Ipswich, Mass. 01938, 1971.
1963. (1928) GOODYEAR, HENRY M., 2012 Edgecliff Point, Cincinnati, Ohio 45206.
1960. (1940) HANSEL, FRENCH K., 6828 Oakland Av., St. Louis, Missouri 63139, 1962, '65.
1968. (1942) HEATLY, CLYDE A., 11 North Goodman St., Rochester, N. Y. 14607, 1942, '46*, '49, '50, '52, '53*, '54, '55, '57, '58, '60, '61, '65.
1970. (1944) HOOPLE, GORDON D., 1100 E. Genesee St., Syracuse, N. Y. 13210, 1971, '72.
1970. (1952) IRELAND, P. E., 60 Smart St., P.O. Box 91, Bowmanville, Ontario, Canada.
1961. (1950) KLINE, ORAM R., 896 Lake Ave., Woodbury Heights, N. J. 08097, 1961, '63, '70, '72.
1970. (1936) LEJEUNE, FRANCIS E., Ochsner Clinic Bldg., 1519 Jefferson Highway, New Orleans, La. 70121, 1971.
1967. (1949) LINDSAY, JOHN R., 950 E. 59th St., Chicago, Ill. 60621, 1967.
1954. (1927) LUKENS, ROBERT M., 141 West Heather Road, Wildwood Crest, N. J. 08260.
1964. (1952) MCCALL, JULIUS W., 22880 Canterbury Lane, Shaker Heights, Ohio 44122, 1964, '66, '68, '69, '70, '71, '72.
1970. (1931) McNALLY, WILLIAM J., 1509 Sherbrooke St. West, Montreal, Canada, 1972.
1971. (1954) MOORE, PAUL M., 10515 Carnegie Ave., Cleveland, Ohio 44106, 1954, '55*, '56, '57, '59, '60, '61, '62, '63, '64, '65, '66, '68, '70, '71.
1971. (1953) MURTAGH, JOHN A., 2161 N.E. 68th St., Fort Lauderdale, Fla. 33308, 1953, '54, '55, '56*, '57, '58, '59, '61, '62, '63, '65, '66, '67, '69, '70, '72.
1959. (1927) MYERSON, MERVIN C., 518 N. Palm Drive, Beverly Hills, Calif. 90210.

1957. (1948) PHELPS, KENNETH A., 1788 Oak Creek Drive, Palo Alto, Cal. 94304, 1971.
1969. (1951) RAWLINS, AUBREY G., 384 Post St., San Francisco, Calif. 94108, 1971.
1972. (1956) RICHARDSON, JOHN R., P.O. Box 52, Searsport, Maine 04974.
1958. (1938) SALINGER, SAMUEL, 1260 East Alejo Road, Palm Springs, Calif. 92262, 1958, '59, '61, '62, '63, '64, '65, '66, '67, '68, '69, '71.
1962. (1932) SCHALL, LEROY A., 121 Winfield Road, Princeton, N. J. 08540, 1964, '66, '68, '69, '72.
1964. (1934) SCHENCK, HARRY P., 1235 Wyngate Rd., Wynnewood, Pa. 19096, 1964, '65*, '66, '68, '69, '70.
1965. (1939) SIMPSON, W. LIKELY, 702 Second Ave., Des Moines, Iowa 50309.
1969. (1950) SMITH, AUSTIN T., 330 S. 9th St., Philadelphia, Pa. 19107, 1970, '71, '72.
1966. (1947) THEOBALD, WALTER H., 222 East Chestnut St., Chicago, Ill. 60611, 1966, '68, '69.
1968. (1950) TREMBLE, G. EDWARD, 1374 Sherbrooke St. W., Montreal, Quebec, Canada, 1950, '51, '52, '53, '54, '55*, '56, '57, '58, '60, '61, '62, '63, '65, '66, '67*, '68, '69, '70, '71.
1965. (1943) VAN ALYEA, OLIVER E., 135 South LaSalle St., Chicago, Ill. 60603, 1965, '66, '68, '69, '70, '71.
1961. (1941) VIOLE, PIERRE P., 241 South Windsor, Los Angeles, Calif. 90004, 1964.

OFFICERS 1972-1973

PRESIDENT

FRANK D. LATHROP, M.D.

FIRST VICE-PRESIDENT

FRANCIS L. WEILLE, M.D.

SECOND VICE-PRESIDENT

SAM H. SANDERS, M.D.

SECRETARY

JOHN F. DALY, M.D.

TREASURER

CHARLES M. NORRIS, M.D.

LIBRARIAN, HISTORIAN AND EDITOR

CHARLES F. FERGUSON, M.D.

COUNCIL

The above Ex-officio and
FRANCIS W. DAVISON, M.D.
ALDEN H. MILLER, M.D.
DeGRAAF WOODMAN, M.D.
F. JOHNSON PUTNEY, M.D.

INDEX

to the

TRANSACTIONS

of the

AMERICAN LARYNGOLOGICAL ASSOCIATION

1972

AUTHOR'S INDEX

A		L	
Arslan, Prof. Michele	122	Leonard, James R.	111
B		M	
Baker, Daniel C., Jr.	54	Maran, Arnold G.	111
Birken, Eric A.	148	McCabe, Brian F.	157
C		N	
Calcaterra, Thomas C.	162	Neel, H. Bryan	142
Chapman, Clifford E.	11	Nichols, Richard D.	94
Clerf, Louis H.	23	O	
Cohen, Seymour R.	39	O'Rahilly, Ronan	35
Cotton, Robin	57	P	
D		Pennington, Claude L.	100
Devine, Kenneth D.	142	Putney, F. Johnson	11
Dodd, Gerald D.	65	R	
F		Roffman, Jeffrey D.	148
Fearon, Blair	57	S	
Fukuda, Hiroyuki	136	Sanders, Sam H.	73
G		Savetsky, Lawrence	54
Goldman, Joseph L.	148	Schild, Joyce A.	46
H		Smits, Robert G.	157
Harrison, D. F. N.	132	Stern, Floyd	162
Hast, Malcolm H.	27	T	
Holinger, Paul H.	46	Townsend, Gary L.	142
Holt, Gordon P.	111	Tucker, John A.	35
J		W	
Jing, Bao-Shan	65	Wang, Chun-I	39
K		Ward, Paul H.	162
Kirchner, John A.	136	Williams, Russell I.	85
Krause, Charles J.	157	Z	
		Zak, Frederick G.	148

SUBJECT INDEX

A		Esophageal Neoplasms, Postcricoid and Cervical, Role of Surgery in Management of (Harrison)	132
Addresses:		Extraparotid Disease Simulating Parotid Masses (Nichols)	94
Guest of Honor,		External Trauma of the Larynx and Trachea: Immediate Management (Pennington)	100
Louis H. Clerf, M.D.	23		
Presidential,			
F. Johnson Putney, M. D.	11		
Allergic Laryngitis (Williams)	85		
B		G	
Bilateral Vocal Cord Paralysis of Undetermined Etiology: Clinical Course and Outcome (Neel et al.)	142	Guest of Honor Address,	
Blockage, Total Nasal, by Polyps of Allergic and Infectious Origin (Sanders)	73	Louis H. Clerf, M.D.	23
C		H	
Carcinoma, Adenoid Cystic of Head and Neck, Radiographic Findings in (Dodd and Jing)	65	Hemangioma of the Head and Neck in Children, Steroid Treatment of (Cohen and Wang)	39
Carcinoma of the Larynx and Laryngopharynx, High Dosage Preoperative Radiation and Surgery for (Goldman et al.)	148	Hemilaryngectomy, Vertical, Treatment of Vocal Cord Carcinoma by (Leonard et al.)	111
Carcinoma of the Larynx: Analysis of 311 Cases Treated Surgically (Putney and Chapman)	11	I	
Carcinoma, of Vocal Cord, Treatment of by Vertical Hemilaryngectomy (Leonard et al.)	111	Infants, Decannulation Problems in (Baker)	54
Changes in the Respiratory Activity of the Cricothyroid Muscle with Intrathoracic Interruption of the Vagus Nerve (Fukuda and Kirchner)	136	Injuries, Pharyngeal, Laryngeal and Tracheal, in Pediatric Age Group (Holinger and Schild)	46
Complications Associated with Combined Therapy of Oral and Pharyngeal Neoplasms (Smits et al.)	157	Injury of the Larynx, Dilemma of Delayed Radiation (Calcaterra et al.)	162
D		Intrathoracic Interruption of the Vagus Nerve, Changes in the Respiratory Activity of the Cricothyroid Muscle with (Fukuda and Kirchner)	136
Decannulation Problems in Infants (Baker)	54	L	
Development, Early, of the Human Laryngeal Muscles (Hast)	27	Laryngeal Muscles, Early Development of the Human (Hast)	27
Dilemma of Delayed Radiation Injury of the Larynx (Calcaterra et al.)	162	Laryngectomy, Reconstructive: Report on the First 35 Cases (Arslan)	122
E		Laryngitis, Allergic (Williams)	85
Early Development of the Human Laryngeal Muscles (Hast)	27	Larynx	
Embryology of the Human Larynx, Observations on the (Tucker and O'Rahilly)	35	Carcinoma of: Analysis of 311 Cases Treated Surgically (Putney and Chapman)	11
		Dilemma of Delayed Radiation Injury of the (Calcaterra et al.)	162
		Injuries, Laryngeal, Pharyngeal and Tracheal in the Pediatric Age Group (Holinger and Schild)	46

- Observation on the Embryology of the Human (Tucker and O'Rahilly) 35
- Surgical Correction of Subglottic Stenosis of the: Preliminary Report of an Experimental Surgical Technique (Fearon and Cotton) 57
- Trauma, External, of the Larynx and Trachea, Immediate Management (Pennington) 100
- ### M
- Management of Total Nasal Blockage by Polyps of Allergic and Infectious Origin (Sanders) 73
- Muscles, Laryngeal, Human, Early Development of the (Hast) 27
- ### N
- Nasal Blockage by Polyps of Allergic and Infectious Origin, Management of (Sanders) 73
- Neoplasms, Oral and Pharyngeal, Complications Associated with Combined Therapy of (Smits et al.) 157
- Neoplasms, Postcricoid and Cervical Esophageal, Role of Surgery in the Management of (Harrison) 132
- ### O
- Observations on the Embryology of the Human Larynx (Tucker and O'Rahilly) 35
- Oral and Pharyngeal Neoplasms, Complications Associated with Combined Therapy of (Smits et al.) 157
- ### P
- Paralysis, Bilateral Vocal Cord, of Undetermined Etiology, Clinical Course and Outcome (Neel et al.) 142
- Parotid, Extra, Disease Simulating Parotid Masses (Nichols) 94
- Pharyngeal, Laryngeal and Tracheal Injuries in the Pediatric Age Group (Holinger and Schild) 46
- Polyps of Allergic and Infectious Origin, Management of Total Nasal Blockage by (Sanders) 73
- Postcricoid and Cervical Esophageal Neoplasms, Role of Surgery in the Management of (Harrison) 132
- Presidential Address, F. Johnson Putney, M.D. 11
- ### R
- Radiation, Delayed, Injury of the Larynx, Dilemma of (Calcaterra et al.) 162
- Radiographic Findings in Adenoid Cystic Carcinoma of the Head and Neck (Dodd and Jing) 65
- Radiation, High Dosage Preoperative, and Surgery for Carcinoma of the Larynx and Laryngopharynx (Goldman et al.) 148
- Radiographic Findings in Adenoid Cystic Carcinoma of the Head and Neck (Dodd and Jing) 65
- Reconstructive Laryngectomy: Report on the First 35 Cases (Arslan) 122
- Role of Surgery in the Management of Postcricoid and Cervical Esophageal Neoplasms (Harrison) 132
- ### S
- Solis-Cohen, Dr.: Pioneer Laryngologist (Clerf) 23
- Stenosis, Subglottic, of the Larynx, Surgical Correction of: Preliminary Report of an Experimental Surgical Technique (Fearon and Cotton) 57
- Steroid Treatment of Hemangioma of the Head and Neck in Children (Cohen and Wang) 39
- Subglottic Stenosis, of the Larynx, Surgical Correction of: Preliminary Report of an Experimental Surgical Technique (Fearon and Cotton) 57
- Surgery, Role of in Management of Postcricoid and Cervical Esophageal Neoplasms (Harrison) 132
- Surgical Correction of Subglottic Stenosis of the Larynx: Preliminary Report of an Experimental Surgical Technique (Fearon and Cotton) 57
- ### T
- Trachea, Decannulation Problems in Infants (Baker) 54
- Trachea, Larynx and, External Trauma of the: Immediate Management (Pennington) 100
- Tracheal, Laryngeal and Pharyngeal, Injuries in the Pediatric Age Group (Holinger and Schild) 46
- Trauma, External, of the Larynx and Trachea: Immediate Management (Pennington) 100
- Treatment of Vocal Cord Carcinoma by Vertical Hemilaryngectomy (Leonard et al.) 111
- Treatment, Steroid, of Hemangioma of the Head and Neck in Children (Cohen and Wang) 39
- ### V
- Vocal Cord Carcinoma, Treatment of by Vertical Hemilaryngectomy (Leonard et al.) 111
- Vocal Cord Paralysis of Undetermined Etiology, Bilateral: Clinical Course and Outcome (Neel et al.) 142

