

TRANSACTIONS

American Laryngological Association

NINETY-SIXTH VOLUME

1975

PUBLISHED BY THE ASSOCIATION
CHARLES FOSS FERGUSON, M.D., Editor



"DOCENDO DISCIMUS"

TRANSACTIONS
OF THE
NINETY-SIXTH ANNUAL MEETING
OF THE
American
Laryngological Association
1975

HELD AT
HYATT REGENCY ATLANTA
ATLANTA, GEORGIA
APRIL 6 AND 7, 1975

PUBLISHED BY THE ASSOCIATION
ST. LOUIS, MISSOURI
CHARLES FOSS FERGUSON, M.D., Editor

1975

Contents

	PAGE
Officers for 1974-1975	7
Annual Photograph	8
Registration of Fellows for Annual Meeting	9
* * * *	
Presidential Address, Joseph H. Ogura, M.D.	11
Introduction of Guest of Honor, Francis E. LeJeune, M.D., by Joseph H. Ogura, M.D.	13
Address of Guest of Honor, Francis E. LeJeune, Sr., M.D. Continuing Education: A Challenge and a Necessity	14
The First Daniel Clifton Baker, Jr., M.D. Memorial Lecture:	
Photograph	18
Memorial	19
Some Reflections on Our Specialty, John J. Conley, M.D.	20

* * * *

SCIENTIFIC SESSION

Frey's Syndrome — A Technical Remedy. Roy B. Sessions, M.D., David T. Roark, M.D., and Bobby R. Alford, M.D.	25
Preoperative Embolization of Juvenile Angiofibromas of the Nasopharynx. James D. Pletcher, M.D., Thomas H. Newton, M.D., Herbert H. Dedo, M.D., and David Norman, M.D.	31
Nontraumatic, Nonneoplastic Subglottic Stenosis. Mohsen Djalilian, M.D., Thomas J. McDonald, M.D., Kenneth D. Devine, M.D., and Louis H. Weiland, M.D.	38
Discussion:	
Alan M. Nahum, M.D.	44
J. Ryan Chandler, M.D.	44
John F. Daly, M.D.	45
Ricardo Tapia-Acuna, M.D.	45
Injuries to the Neonatal Larynx from Long-term Endotracheal Tube Intubation and Suggested Tube Modification for Prevention. Arthur S. Hengerer, M.D., Marshall Strome, M.D., and Burton F. Jaffe, M.D.	46
Cleft Larynx. A Report of Seven Cases. Seymour R. Cohen, M.D.	53

CONTENTS

	PAGE
Second Primary Cancer After Irradiation of Laryngeal Cancer. William Lawson, M.D., and Max Som, M.D.	63
Experimental Granuloma of the Larynx. Fernando R. Kirchner, M.D.	68
Tracheal Incision as a Contributing Factor to Tracheal Stenosis. An Experimental Study. Gary C. Lulenski, M.D., and John G. Batsakis, M.D.	73
Discussion: D. D. Rabuzzi, M.D.	78
Characterization of Tumor Antigen in Epidermoid Carcinoma. Charles J. Krause, M.D., John Nysather, and Brian F. McCabe, M.D.	79
Pyriform Sinus Cancer: A Clinical and Laboratory Study. John A. Kirchner, M.D.	85
Radiation Failures in Cancer of the Larynx. Emanuel M. Skolnik, M.D., Lawrence Martin, M.D., King F. Yee, M.D. and Michael A. Wheatley, M.D.	96
Discussion of previous three papers: Daniel Miller, M.D. Douglas P. Bryce, M.D. Max L. Som, M.D. Joseph H. Ogura, M.D. J. Ryan Chandler, M.D. Emanuel M. Skolnik, M.D. (closing)	103 103 104 104 104 104
Rehabilitation of the Shoulder After Radical Neck Dissection. W. H. Saunders, M.D., and E. W. Johnson, M.D.	105
Carcinoma of the Nasopharynx in Children. James B. Snow, Jr., M.D.	110
Discussion of previous two papers: Emanuel M. Skolnik, M.D. Herbert H. Harris, M.D. Daniel Miller, M.D. James B. Snow, Jr., M.D. (closing)	119 120 120 120
Observations on the Primate Hyoepiglottic Complex. Gabriel Tucker, Jr., M.D., and John A. Tucker, M.D.	122
Incidence, Predisposing Factors and Outcome of Pharyngocutaneous Fistulas Complicating Head and Neck Cancer Surgery. Douglas D. Dedo, M.D., William A. Alonso, M.D., and Joseph H. Ogura, M.D.	128
Discussion of previous two papers: John A. Kirchner, M.D. John J. Conley, M.D. Max L. Som, M.D. Douglas P. Bryce, M.D. Gabriel F. Tucker, Jr., M.D. (closing) Joseph H. Ogura, M.D. (closing)	136 136 136 136 136 137

CONTENTS

PAGE

Executive Sessions:

First Session (April 6)	139
Second Session (April 7)	140

Reports of:

Secretary, John F. Daly, M.D.	140
Treasurer, Charles M. Norris, M.D.	142
Accountant	145
Librarian, Historian and Editor, Charles F. Ferguson, M.D.	145
American Board of Otolaryngology, Frank D. Lathrop, M.D.	146
American Council of Otolaryngology, John F. Daly, M.D.	147
American College of Surgeons Governors, William M. Tribble, M.D.	148
National Society for Medical Research, Albert H. Andrews, M.D.	150
Nominating Committee, Arthur J. Cracovaner, M.D.	151

Memorials:

Sir Victor E. Negus	153
James J. O'Neil, M.D.	156
Walter H. Theobald, M.D.	158
Oliver E. van Alyea, M.D.	164
Francis L. Weille, M.D.	166
Henry L. Williams, II, M.D.	161

Memorial Fund; Laryngological Research Fund	168
---	-----

Recipients of deRoaldes Award	169
-------------------------------------	-----

Recipients of Casselberry Award	170
---------------------------------------	-----

Recipients of Newcomb Award	171
-----------------------------------	-----

Roster of Fellows	172
-------------------------	-----

Officers, 1975-1976	183
---------------------------	-----

Index

Authors	185
Subjects	186

OFFICERS 1974-1975

* * * *

PRESIDENT

JOSEPH H. OGURA, M.D.

FIRST VICE-PRESIDENT

JOHN A. KIRCHNER, M.D.

SECOND VICE-PRESIDENT

DOUGLAS P. BRYCE, M.D.

SECRETARY

JOHN F. DALY, M.D.

TREASURER

CHARLES M. NORRIS, M.D.

LIBRARIAN, HISTORIAN AND EDITOR

CHARLES F. FERGUSON, M.D.

* * * *

COUNCIL

The above ex officio and

FIRST COUNCILOR

DeGRAAF WOODMAN, M.D.

SECOND COUNCILOR


F. JOHNSON PUTNEY, M.D.

THIRD COUNCILOR

FRANK D. LATHROP, M.D.

FOURTH COUNCILOR

G. SLAUGHTER FITZ-HUGH, M.D.



FELLOWS IN ATTENDANCE AT THE NINETY-SIXTH ANNUAL MEETING

First Row: McCall, Tapia-Acuna, S. Sanders, Woodman, Galloway, Lathrop, Norris, J. Kirchner, Ogura, LeJeune, Bryce, Daly, Ferguson, Fitz-Hugh, Schall, Cocke, Jones, McCabe. *Second Row:* Cohen, Dedo, Lewy, Tabb, Brown, Sprinkle, Hudson, Munoz-MacCormick, Clerf, Goodale, Priest, Biller, Som, Duvall, Nahum, Ward. *Third Row:* Skolnik, Hilger, Harrill, Pastore, Cracovaner, Harris, O'Keefe, Alexander, J. Tucker, Fearon, Cody, Ritter, DeWeese, Pang, Putney, Pratt, D. Miller, Conley, Work. *Fourth Row:* Simonton, Frazer, Lillie, Montgomery, Soboroff, Friedberg, Holmes, Davison, G. Tucker, Chandler, Strong, Bal-
lenger, Saunders, Snow, F. Kirchner, Goldman, Lewis, Tribble, Bailey, Andrews, McNally.

TRANSACTIONS OF THE
NINETY-SIXTH ANNUAL MEETING

OF THE

American Laryngological Association

HELD AT THE

HYATT REGENCY ATLANTA

ATLANTA, GEORGIA

APRIL 6 AND 7, 1975

* * * *

The Ninety-sixth Annual Meeting of the American Laryngological Association was called to order by the President, Joseph H. Ogura, M.D., of St. Louis, Missouri, in the Phoenix Ballroom of the Hyatt Regency Atlanta, Atlanta, Georgia, on Sunday, April 6, 1975, at 8:15 A.M.

REGISTRATION OF FELLOWS

ACTIVE

ALEXANDER, FRED W.
ANDREWS, ALBERT H.
ARNOLD, GODFREY E.
AUSBAND, JOHN R.
BAILEY, BYRON J.
BALLENGER, JOHN J.
BILLER, HUGH
BOLES, ROGER
BORDLEY, JOHN E.

BROWN, LESTER A.
BRYCE, DOUGLAS P.
CHANDLER, J. RYAN
COCKE, EDWIN W., JR.
CODY, CLAUDE C., III
COHEN, SEYMOUR R.
CONLEY, JOHN J.
CRACOVANER, ARTHUR J.
DALY, JOHN F.
DAVISON, FRANCIS W.

DEDO, HERBERT H.
 DEWEESE, DAVID D.
 DICKINSON, JOHN T.
 DUVALL, ARNDT J., III
 FEARON, BLAIR
 FERGUSON, CHARLES F.
 FITZ-HUGH, G. SLAUGHTER
 FRAZER, JOHN P.
 FRIEDBERG, STANTON A.
 GOLDMAN, JOSEPH L.
 HARRILL, JAMES A.
 HARRIS, HERBERT
 HILGER, JEROME A.
 HOLMES, EDGAR M.
 HUDSON, WILLIAM R.
 JONES, EDLEY H.
 KING, JAMES T.
 KIRCHNER, FERNANDO R.
 KIRCHNER, JOHN A.
 LATHROP, FRANK D.
 LEWIS, JOHN S.
 LEWY, ROBERT H.
 LILLIE, JOHN C.
 MCCABE, BRIAN F.
 MCGOVERN, FRANCIS H.
 MILLER, DANIEL
 MONTGOMERY, WILLIAM W.
 MORSE, HARRY R.
 MUNOZ-MACCORMICK, CARLOS
 NAHUM, ALAN
 NORRIS, CHARLES M.
 OGURA, JOSEPH H.
 O'KEEFE, JOHN J.
 PANG, LUP Q.
 PASTORE, PETER N.
 PENNINGTON, CLAUDE L.
 PRATT, LORING W.
 PRIEST, ROBERT E.

PUTNEY, F. JOHNSON
 REED, GEORGE F.
 RITTER, FRANK N.
 SANDERS, SAM H.
 SAUNDERS, WILLIAM H.
 SILCOX, LOUIS E.
 SIMONTON, KINSEY M.
 SKOLNIK, EMANUEL M.
 SNOW, JAMES B., JR.
 SOBOROFF, BURTON J.
 SOM, MAX L.
 SPRINKLE, PHILIP M.
 STRONG, M. STUART
 SUEHS, OLIVER W.
 TABB, HAROLD G.
 TRIBLE, WILLIAM MACL.
 TUCKER, GABRIEL F., JR.
 TUCKER, JOHN A.
 WARD, PAUL H.
 WOODMAN, DeGRAAF

EMERITUS

GOODALE, ROBERT L.
 LEJEUNE, FRANCIS E.
 MCCALL, JULIUS W.
 McNALLY, WILLIAM J.
 SCHALL, LEROY A.
 WORK, WALTER P.

HONORARY

CLERF, LOUIS H.
 GALLOWAY, THOMAS C.
 HILDING, ANDERSON C.

CORRESPONDING

TAPIA-ACUNA, RICARDO

PRESIDENTIAL ADDRESS

JOSEPH H. OGURA, M.D.

It is indeed a great honor to serve during this year as President of the American Laryngological Association, one of the oldest medical societies in America.

For many years, papers presented before this Society, before the advent of antibiotics, were concerned with infections, oncology, tumors, endoscopy, and surgery of the nasal sinuses and larynx. Naturally, research was then not as well developed as today because sophisticated methods of investigation were not available. It is an interesting and profitable experience to peruse through the *Transactions* of this Association. In the late forties and fifties we entered a period of recession where the training programs were threatened by a lack of good potential candidates. We were frankly worried about our future.

Fortunately, with the help of NINDS training programs during the fifties, the improvement of our training prepared many programs for a greater thrust in research. The potential candidates for training greatly increased, until now we are substantially overcrowded in the many urban communities.

With the gradual evolution and changing concepts of graduate education, rhinology and laryngology have assumed their positions among the surgical disciplines in the broad field of head and neck surgery. Our membership reflects an increasing number of newer members whose primary interests are in this area.

It is only natural that otolaryngologists, whose consuming interest is concerned with organic pathology, with increasing experience would gravitate toward clinical research and patient care of benign and malignant diseases of the head and neck. Thirty years ago, not many of us handled the broad field, but

in the last twenty years increasing numbers of residents are better trained and in some institutions exceptionally well trained.

Uniformity of training, while ideal, is practically an impossibility. Today the pressing problem of training young men to be competent in the broad field of head and neck seems insurmountable. There is just not enough clinical material to equally train everyone. One cannot "squeeze blood out of a turnip." There are only 30,000 new head and neck cancers a year for the 350 new otolaryngologists a year, 1,200 new general surgeons, and 100 plastic surgeons. This is a grand total of 1,650 residents. If every patient was a surgical candidate, these 30,000 cases, evenly divided, would give 20 cases per resident. Since the overwhelming number of cases are private, the numbers dwindle between otolaryngologists, general surgeons, plastic surgeons, and radiotherapists. The factual evidence of individual resident experience, as seen on the Residency Review Committee for otolaryngology, must certainly exist for general surgery and plastic surgery; uniform experience for candidates taking their respective board examinations must be far short of adequate for competency. Perhaps, in the long run, with PSRO legislation, those few who do have adequate experience will be recognized as competent. The sheer evidence points to one conclusion and that is that the future of head and neck surgery will be medical-center-oriented. With rapid and available transportation, there is little need to do complicated operations in small community hospitals where adequate medical backup care is not available.

Basic and clinical research of a more sophisticated level has been appearing

in our programs. This is good. We need more of it.

As our specialty continues to evolve, the three surgical disciplines have come together on a national level in Washington under the auspices of the National Cancer Advisory Board (of which I am your representative) to formulate the National Head and Neck Cancer project to develop better ways of combating cancer. This national cadre is composed of radiotherapists, pathologists, and epidemiologists seeking answers as quickly as possible to apply to patient care.

Through such an interdisciplinary cooperative study, we hope to establish better methods for determining better care through pooled information which is carefully studied, the results implemented, and the information disseminated in a manner no one individual can achieve in a lifetime.

I do not pretend to know all the answers nor what is best for our specialty. But our cooperative approach on a national level with identification on equal basis seems best for all of us. Indeed, the future of otolaryngology is bright.

INTRODUCTION OF GUEST OF HONOR,
FRANCIS E. LEJEUNE, SR., M.D.

JOSEPH H. OGURA, M.D., PRESIDENT

I have the great pleasure of introducing our guest of honor to the American Laryngological Association. He was born in Louisiana in 1894 and graduated from Tulane University Medical School in 1920. He completed his training in Louisiana and rapidly rose through the ranks of Assistant Professor and Associate Professor to Professor of Otolaryngology at Tulane University. He was appointed and served as chairman of that department from 1938 to 1953. In 1942 he was cofounder of the Oschner Clinic and became head of the Department of Otolaryngology where he continues to serve as a consultant. He has had an illustrious life and has been a generous contributor to the scientific literature in the field of laryngology. Not only was he an Alpha Omega Alpha scholar, but he was president of the Triological Society in

1953 and became President of the Laryngological Association in 1963. He has received the Casselberry, Newcomb and deRoaldes awards of the American Laryngological Association and is a member of 21 medical organizations. He is the one man who has given me the most sage advice which I hope he will be able to convey to the younger academic men. His wonderful advice was given to me back in 1952 when I was in New Orleans and I thought of moving my ties there. At the time such advice was given, I appreciated it; but as time wore on it became more valuable to me. I hope he will give some of these pearls of wisdom now as he gave them to me then. When I selected him as our guest of honor, I had forgotten he was the guest of honor several years ago, so he is a "two-timer." I present to you Francis E. LeJeune.

ADDRESS OF GUEST OF HONOR

CONTINUING EDUCATION: A CHALLENGE AND A NECESSITY

FRANCIS E. LEJEUNE, SR., M.D.

I am deeply grateful to you, Dr. Ogura, for the great honor of being selected as your guest on this occasion.

When you first contacted me, I wondered what impelled you to select me for such an honor. After studying this question, I realized that I was reaping the benefits of advice given years ago. I vividly recall that in the early fifties you visited New Orleans at the invitation of the Tulane Medical School which was searching for a full-time Head of the Department of Otolaryngology. You were one of the leading contenders for this lofty position, and in my interview with you, I discouraged you from considering this offer and strongly advised you to remain where you were. Your keen interest in research, particularly in laryngology, convinced me that it was just a matter of time before this work would propel you into national prominence and leadership in your chosen profession. You were so well equipped with the tools of research that I feared it would take a long time to duplicate them at Tulane. As you departed, I feared I had lost a good friend because of my negative advice; however, my arguments must have been convincing for you chose to remain at Washington University where you are now Professor and Head of the Department of Otolaryngology and where I have admired the wonderful work you are doing. You have expanded your research, published your findings, and today you are enjoying the most prestigious position and honor that can be bestowed upon a laryngologist: President of the American Laryngological Association.

When I inquired as to the subject matter of the presentation, I was instructed by you, Mr. President, to dwell upon advice to the younger men: academics and teaching.

I first thought it would be easy to jot down a few words of advice. All of the younger men to whom I speak have long ago learned that nothing is easy in medicine. I need only remind them of the midnight oil burned learning the intricacies of anatomy, embryology, and neurology, to mention only a few of the difficulties encountered and conquered. And now I am at the point of acting as an advisor, but before I embark upon this point, it must be clearly understood that any advice given is not intended for members of the Laryngological Association or any of my contemporaries.

Early in my career, it was impressed upon me that "medicine was a jealous mistress and that she brooked no interference." Continuous study was a requisite for success in this chosen field. This old thought has recently been revived, expanded, reinstated, and much is being written about it under various titles. It all boils down to the simple phrase, "continuing education." I cannot offer any better words of advice and wisdom than that expressed by continuing education because without it regression is inevitable.

The tremendous acceleration of medical knowledge gained by intensive and excellent research in all phases of medicine makes continuing education mandatory. A tremendous amount of knowledge with newer concepts in the treatment of

many diseases demonstrates clearly the necessity of continually searching and reviewing current medical and surgical literature to keep abreast with the changing aspects of medicine. Much interest today is being manifested in self-assessment, relicensing, certification, and recertification, so we should be intensely interested in knowing how the different organizations plan to implement methods that will help deliver competence and quality medical care. In offering advice to the younger men, I have borrowed thoughts from many articles, endeavoring to give credit to them all, and added a few original thoughts of my own.

Boyce¹ served as chairman of a discussion on "Continuing Surgical Education," sponsored by the American College of Surgeons in which Derbyshire² reviewed the current movement to legislate recertification of physicians. It is well understood, according to him, that our government has the responsibility and authority to issue privileged licenses for various activities, including the practice of medicine. Our high governing bodies have long recognized the capabilities of the medical profession, and authority has been delegated to them to examine and certify the competence of recent graduates of medical schools. The awarding of licenses, therefore, was granted to the State Examining Boards and the license was intended for life. With the movement of periodic recertification, lifelong licenses will soon become a thing of the past.

Giffen and Derbyshire's³ recent article on "Continuous Education and Recertification" should be read by all interested in this subject, and I shall quote freely from this interesting paper. They remind us that once a doctor obtains a license in a state, it is his for life unless he becomes guilty of violating certain laws; and as long as he pays his registration fee, he has nothing to worry about. The authors have participated in many discussions over the last 15 years in regard to re-examination, relicensure, and recertification. They do not advocate re-examination but do advocate continuing

education. They were highly pleased when the Academy of Family Practice initiated its program requiring continuing education to remain a member, and requiring recertification of competence after six years. Additional Boards are currently considering similar programs. The Oregon Medical Association adopted the same policy as that of the Academy of Family Practice, and showed they meant business when they suspended 11 of their members at the end of the reporting period. Most of these members have been reinstated by fulfilling the requirements. Several states have followed the lead of Oregon, and now there are some eight states that require continuing education in order to remain members of their medical associations. I think it is safe to predict that within five years there will be an end to automatic renewal of lifelong licenses issued by the respective State Boards of Medical Examiners.

If national health insurance is introduced through federal legislation and the Medicare program is expanded, it is likely that increasing sophistication in the evaluation of clinical competence, certification and recertification of individual physicians will then be required.⁴ Furthermore, it is likely that documented evidence of the continuing competence of physicians will become mandatory, especially if there is widespread subsidization of health care in hospitals, clinics, and health organizations.

The State legislatures of New Mexico, Maryland, Kentucky, and Kansas have already passed laws requiring periodic licensure and this law has been implemented in New Mexico and Maryland. New Mexico is now in its third year of licensure. With the deadline for compliance coming up, it will be one of the first to enforce this law.

Postgraduate education has never been as popular as it is at the present time. At least once a week, the mail brings announcements of courses being given by well organized groups in one of the specialties, and the teaching personnel consists of men who stand high in their

respective specialties. In an excellent article, "The Value of Postgraduate Education," Alton Ochsner⁵ stated, "The progress of medicine is, in fact, so swift that it is impossible for a physician to remain stationary. If he does not progress, he regresses." Brunk⁶ added to this by saying, "The need for continuous study by a doctor of medicine is but one of the penalties of his profession." Not only is continuous study essential, but also attendance and participation in medical meetings where new concepts and changes are reported and discussed. Brunk further stated that the man who fails to keep up with current literature or attend county and state medical meetings and postgraduate courses will "find that after a period of five years he is stale, serving medicine which is not up to date; at the end of ten years he is perpetrating a fraud on his patients." To prevent such from occurring is one of the reasons for advocating self-assessment and recertification.

Probably with this in mind, the American Board of Surgery has made public a statement to the effect that every certificate issued after September 1, 1975, will have a notation on it stating that the certificate is good for only ten years. At the end of that period, it will be necessary to obtain recertification. Other organizations are working on methods to help all medical personnel keep abreast with new developments in the field of medicine. The American Academy of Ophthalmology and Otolaryngology not only suggests but outlines a program for "lifelong" learning. Reed,⁷ in an interesting editorial, advocates postgraduate education starting early and continuing throughout the years of active practice until retirement. Reed further tells us that seven state medical societies require participation in continuing education and 40 other state medical societies are considering adopting this same plan. In a recent Newsletter⁸ published by the American Council of Otolaryngology, it was stated that the American Board of Otolaryngology and 21 other primary Boards have formally announced for recertification in principle. The Board

Committee on Recertification has been studying methods to accomplish the objective and has considered alternative mechanisms. The easiest would be to use an established self-assessment examination such as the American Board of Internal Medicine has done.

In 1971 the American College of Surgeons presented a "Surgical Education and Self-Assessment Program," better known as SESAP-1. In the years that followed and up to the present time, 15,000 surgeons registered and took this course of self-assessment and strongly feel that their surgical knowledge has been vastly improved. SESAP-2, a superior program, is now being offered as a successor to SESAP-1.⁹

The American Academy of Otolaryngology and Ophthalmology announced that a self-improvement program is scheduled to start in May, extending through November. The American Medical Association plans to launch its new program of regional continuing education for physicians in the near future with meetings in Florida, Arizona, Minnesota, and Virginia.

In a very recent issue of *Pediatric News*, Dr. Robert C. Brownlee, Jr., President of the American Board of Pediatrics, stated that the first recertification procedure in Pediatrics may be held as early as 1980 though no definite date has been set. Dr. Brownlee is of the opinion that these certifying Boards will do much to improve the quality of care delivered in this country.

We may also keep abreast of medical progress by steadily reading current medical literature, attending and participating in State and National meetings, and contributing to the literature, which necessitates research that always adds to our knowledge. Besides our national medical journals, I would recommend your reading the *Collected Letters* of the National Society of Ophthalmology and Otolaryngology which consists of problem questions sent in to the Editor who in turn forwards them to a number of colleagues. The help and sug-

gestions offered by these colleagues make good, interesting, and instructive reading.

Academics and teaching are linked together and early association with an institution of national standing carries with it a certain amount of prestige. It must be clear to all that the security received in these early years permits teaching and research which the individual in private practice can ill afford. In addition, access to a well organized and free clinic assures seeing diversified pathological cases and an opportunity to study and perform interesting surgical procedures. Publication of well documented research projects the author into prominence and his rise is, as a rule, more rapid in his profession. Teaching and lecturing to students requires constant preparation and current knowledge of the literature.

And now to answer a question that is frequently asked of me: how to select a location to practice. My answer is always the same: select a place where you and your family would like to live,

and move in. If possible, select a medical environment that would continually stimulate your interest. Progress at first will be slow, but consistent effort, diligence, integrity, and a compassionate desire to deliver the best of medical care will reap benefits and assure success.

Finally, since it is to the younger men of our profession that my remarks have been primarily directed, I should like to assure these men that we look to them as the future leaders of our profession. The confidence and great respect which I have for them is aptly expressed by Judah ha-Nassi,¹⁰ one of the wisest men of his time. Toward the end of his fruitful life he humbly said, "I have learned much from my masters, more from my colleagues, but most of all from my pupils." With this statement I am in complete accord, and I offer this beautiful tribute to the younger men here and to their generation. I am confident they will be the ones who will accept the challenge, and perpetuate Continuing Education within our profession.

REFERENCES

1. Boyce WH: Role of college in continuing surgical education. *Bulletin of the American College of Surgeons* 60:20, 1975
2. Derbyshire RC: Role of college in continuing surgical education. *Bulletin of the American College of Surgeons* 60:20, 1975
3. Giffen MJ, Derbyshire RC: Continuous education and recertification. *Bulletin of the American College of Surgeons* 59:14, 1974
4. National Board of Medical Examiners: *Evaluation in the Continuance of Medical Education*. June 1973, pp 37-40
5. Ochsner A: The value of postgraduate education. *Postgrad Med* 21:205-208, 1957
6. Brunk AS: A doctor's life. *J Mich State Med Soc* 44:1053-1056, 1945
7. Reed G: Editorial. *Trans Am Acad Ophthalmol Otolaryngol* 78:339-340, 1974
8. American Council of Otolaryngology: *Newsletter*, 7:1, 1975
9. SESAP-1 & SESAP-2. Surgical education and self-assessment. *Prospectus of American College of Surgeons*
10. Judah ha-Nassi: Taanit, in *The Talmud*. C. E. 135-220



PORTRAIT BY MOLLY GUION

DANIEL CLIFTON BAKER, JR., M.D.

DECEMBER 19, 1908 — JUNE 2, 1974

Doctor Baker was first and foremost a laryngologist; if indeed, that title should be reserved for anyone, he singularly deserved it.

Born and educated in Philadelphia, graduating from the University of Pennsylvania in 1929, and from Jefferson Medical College in 1933, it was natural that the ferment of activity in that city's great medical teaching centers should provide the stimulus and inspiration for his career in medicine. It was a time when Chevalier Jackson, Louis Clerf and Gabriel Tucker were turning out a constant flow of advances in laryngology and bronchoesophagology. Philadelphia had become the mecca for laryngologists and bronchoesophagologists the world over. To become part of this exciting, developing field was a much sought after opportunity; it came to the young Dr. Baker when Dr. Louis Clerf offered him an appointment to his staff. Later, Dr. Baker was to work in Dr. Harris P. Mosher's laboratory at Harvard; then to St. Louis, and finally he received a Fellowship under Dr. John D. Kernan, Professor of Otolaryngology at Columbia University, College of Physicians and Surgeons in New York. He received a Master of Science degree from that University in 1939.

In World War II he served as Lieutenant Commander at the National Naval Medical Center in Bethesda, Maryland.

After the war, he returned to New York and joined the staff of Presbyterian Hospital and became a member of the faculty of the College of Physicians and Surgeons, Columbia University.

The ensuing years were full and productive for Dr. Baker; papers, reports, lectures, teaching assignments, a Directorship of the American Board of Otolaryngology, offices in many national organizations came his way.

In 1964 he was appointed Professor and Chairman of Otolaryngology at the College of Physicians and Surgeons, Columbia University, one of the most prestigious Chairs of Otolaryngology in America.

His honors came with his achievements; among them, he prized most highly the Distinguished Alumnus Award from the College of Physicians and Surgeons and the Newcomb Award of the American Laryngological Association.

Dr. Baker had a special fondness for the American Laryngological Association, a fondness returned in full measure by its Fellows who honored him and elected him to the Presidency in 1974.

It is with a feeling of joy and happiness that we, his friends and colleagues, dedicate this Lecture in Laryngology to the memory of Daniel Clifton Baker, Jr., whose presence among us touched and enriched our lives; a quiet, sincere, religious man of compassion and integrity; a true physician.

John F. Daly, M.D.

SOME REFLECTIONS ON OUR SPECIALTY

JOHN J. CONLEY, M.D.

NEW YORK, NEW YORK

Dr. Baker was basically conservative. His progressive attitudes were mixed with pragmatism, idealism, and reality. He would approve of this opportunity to ask some questions regarding Otolaryngology and to search for some answers. Three basic questions may shock you and, I hope, stimulate you:

1. Is there need today for the specialty of Otolaryngology?
2. How should it be structured and organized?
3. What are its responsibilities?

There has not been the slightest suggestion from any sector that Otolaryngology should not exist, but there is strong debate about its area of activity. The reasons for this are not as complex as they are confused. In the evolution of one doctor taking care of one patient for all his ills on a one-to-one ratio to the contemporary status of empires, principalities, and regional territories, we have developed authorities, interests, and boundaries that are subject to change as a result of scientific discoveries, leadership personalities, training facilities, and administrative structuring. All of the specialties which have so far been recognized are still evolving and this, understandably, causes friction. Perhaps some of this friction is a good thing, even though its primary roots may be associated with the ego, personal power, and economic factors. These human imperatives have become the ingredients of

progress but have never been assayed in American medicine.

The structure and organization of Otolaryngology has been a mixture of a well-established foundation that has been amazingly successful and a superstructure that has accommodated new concepts and new discoveries. Some of the changes in otolaryngology have been spectacular. The original specialist was preoccupied with infections in the ear and mastoid, sinuses, and throat. Many of the conditions were both common and potentially fatal. The specialist who could handle them was preeminent. The specialty flourished. The great discoveries of antibiotics eliminated the vast majority of infections and fundamentally changed the involvement and the training of specialists in the area of otolaryngology. This occurred about 35 years ago and was a critical turning point in the life of otolaryngology. Those specialists were obligated to diversify their interests and their professional activity. Some became interested in allergy, some in plastic and cosmetic surgery, some in trauma and maxillofacial surgery, some in cancer of the head and neck, some in the restoration of hearing, some in laryngology and bronchoesophagology and some in general otolaryngology. These changes embraced several varieties of specialization within the original group. ENT was beginning to develop into regional specialties, with its own framework of specialization. Rules to restrict professional development which are in-

consistent with responsibility and realism are unproductive.

There was nothing artificial about this trend, as otolaryngology was apparently the most logical starting point for all of these new developments. Natural "growing pains," territorial conflicts, and disputes regarding training and qualifications accompanied the metamorphosis. These understandable areas of differences of operation were debated, and many of the problems have been solved; others await historical assistance.

If regional and organ surgery are rational concepts and well-accepted principles for the practice of surgery, why shouldn't there be a regional surgeon in the area of the head and neck? This query is immediately answered by the fact that the original otolaryngologist was a regular surgeon, and this is complemented by the fact that two organ specialty groups practice in this area. They are the neurosurgeons and ophthalmologists, whose training and acceptance have long ceased to be a point of controversy. The other areas of the nasal cavity, oral and pharyngeal cavities, larynx and neck have been a part of Otolaryngology since its inception. It is quite natural to expand from this established orientation position to the adjacent structures in this area as new concepts and operations are developed.

One might claim that this is taking over other specialty prerogatives. As otolaryngologists we must recognize that we hold no sacred right or dictatorial control over these regions; neither is any other group so ordained. The general surgeon and his august role have been fractionalized by specialization, regional surgery, and organ surgery. He has not been excluded from the head and neck, however, when his interests persist in the thyroid gland, head and neck cancer, reconstructive surgery, and trauma. The general plastic surgeon is involved in all areas of the body, but many in that group are concentrating on congenital anomalies, maxillofacial problems, cosmetic surgery, trauma, and neoplasia. In many respects, this path is

quite parallel to otolaryngology. Maxillofacial surgery, at one time, was quite active in the area of the oral cavity and made significant contributions. Unfortunately, in the United States and England their role was severely down graded by the general plastic surgeon, who wished to dominate this area. Recent attempts to resuscitate maxillofacial surgery by political and administrative maneuvering of the general plastic surgical group to serve their own purposes will hopefully give the maxillofacial group the opportunity they deserve to identify their need and their role. Oral surgeons, also, represent an area of specialization that is expanding and filling the deficiencies of their present structure.

It would appear logical that if regional surgery had any credence, the efforts of all of these specialists should be combined and coordinated within the framework of the head and neck surgeon. All of these various specialty groups would be relatively autonomous, would have combined meetings, overlapping interests, and an interdisciplinary relationship. Historically, the otolaryngologist has been the most involved specialist in this area. One may complain that in some instances his training has been deficient and that not all otolaryngologists are interested or equipped to cope with some of these problems, and this is true. But everyone must admit that he is a specialist who has received the basic training and exposure to the anatomy, physiology, pathology, and treatment of the various conditions in this area. The otolaryngologists are the specialists who, in their daily practice, are involved in the examination, diagnosis and treatment of these regions in the head and neck. No other specialist can claim this.

In one sense, otolaryngology is in the position that general surgery was in forty years ago. The intense interest in various regions and organs of the body led to the identity and then the autonomy of specialty groups in almost every region of the body. In most institutions, the wellspring of their background was

general surgery. As these specialties became more identified, they rearranged their training programs, and none now requires the complete training in general surgery. This in no measure detracts from the value and enrichment of complete training in general surgery as preparation for any specialty. The majority of these specialties require one, two, or three years of training in general surgery, augmented by two, three, or four years of additional, specialized training. The variations in the number of years of preparation is determined by the specialty group to accommodate the minimum requirements of qualification. The thrust of the scientific expansion in specialization could not be contained within the framework of general surgery, and new societies proliferated to represent new interests. Perhaps, if the general surgeon had been more sensitive to these developments, he could have organized the movement and molded it within his own framework. It is interesting that, within the past two decades, the specialty societies have been developed within the structure of the American College of Surgeons and now comprise more than 50% of the membership.

There is such an opportunity for otolaryngologists at this moment. The question is whether we can recognize it and take the necessary steps to develop it. First, we must be aware that we are basically regional surgeons in the area of the head and neck, and that within this region are the specialties of general otolaryngology and medical otolaryngology, regional plastic and reconstructive surgery, head and neck cancer surgery, otology, trauma, cosmetic surgery, endoscopy, rhinology and laryngology, and maxillofacial and oral surgery. It is as impossible for the otolaryngologist to master all of the refinements in his region of activity as it is for the general surgeon to master all of the refinements of total body surgery and for the general plastic surgeon to master all of the plastic and reconstructive procedures of all of the regions of the body. His degree of excellence will be the product of his interest and his experience. Specialists

in small communities understandably have a different involvement than those in large metropolitan areas and those in teaching and university centers. A general, broad involvement must be maintained, and upon this foundation super-specialization may be developed. In most instances, this is not determined during the general training period, but gradually formulates itself on the basis of professional growth and opportunity. It is indeed fortunate if a young doctor can determine which course he will follow during his residency program, so that he can have additional training at that time in a special branch of head and neck surgery. It is folly to believe that every otolaryngologist, every plastic surgeon, and every general surgeon can, or should, be trained to a high degree in all of these aspects of head and neck surgery. A broad spectrum of specialization, with overlapping and coordinating interests, would be the main objective of the structure of training and practice.

The biggest *external* problem in the above concept is the confrontation with other specialty groups that desire to not only participate in some aspects of this surgery, but actually to control it. The biggest *internal* problem is the recognition of the concept, then the taking of the necessary administrative measures to give it viability. In respect to the latter problem, we are faced with the reluctance to alter the *status quo*, the failure to provide leadership, and the difficulties of the struggles with vested professional interests. Otolaryngologists have been sluggish in many of these matters, and their basic program has consisted mainly of responding to a positive thrust of another society or to be led by the new specialty societies developing within their own house to accomplish change. This may be partially explained by a feeling of professional security and a tradition of superb leadership. There must be a plan and an objective, however, that is rational and correct, that we can approach in a professional manner, with dignity, in the highest traditions of our medical ethic.

The external problems are created by the response of other specialty societies to the developing role in otolaryngology. The response is a proclamation that otolaryngologists should not perform certain operations in the region of the head and neck. The reasons adduced for such a statement are that otolaryngologists are not suitably or well trained, and that other surgeons either do or would like to do these same operations without interference. The majority of training programs in otolaryngology that teach surgery in the area of the head and neck have both strong and weak points. Some are strong in cancer, some in otology, some in plastic and reconstructive surgery, some in maxillofacial surgery, some in cosmetic surgery, some in endoscopy, some in research, and some in general ENT. These situations fluctuate with the availability of material and the interest of the doctors. All other specialty groups that train surgeons in these areas have strong and weak points which are even more apparent. Some have glaring deficiencies, yet it may be claimed that because a young doctor has attained a certain type of specialty certificate, this proclaims him to be superior and competent. There are circumstances where this is totally false. It is hoped that the sincere leaders in the various specialty groups will recognize this fact and resist the ploy to manipulate this type of cynicism. A charade of this character can never prove professional competency.

The basic weakness, and strength, in most programs is that in their growth over the past four decades they have expanded upon the basis of local need, new operative techniques, leadership action, and competitive resistance. The first three are indigenous to otolaryngology, and the fourth is within the realm of other specialty groups practicing in the area of the head and neck. Many of our programs have failed to specifically identify the special role otolaryngology plays in cancer of the head and neck, facial plastic surgery, cosmetic surgery and trauma to the face, gullet, and airway. It is essential that their role in these subjects be fairly documented and taught in

the finest manner, as these are the areas of competitive interests from other specialists. The leaders in otolaryngology are responsible for improvement in their training programs as this specialty evolves. The possibility of their doing this is not easy. One simple method would be some form of interspecialty cooperation. This is almost unheard of, because we are involved in a power struggle which is self-destructive and deceptive.

There must be a plan of organization to accompany this. Plans do not have to be exclusive, as new cooperative efforts may improve training and reduce friction. Interdisciplinary, cooperative efforts might prove very satisfactory, if attainable. A period of temporary transfer to a stronger program or a preceptorship may be the solution. Otology is unique in this analysis, being so highly specialized it enjoys a noncompetitive position and almost total autonomy.

Although the Residents Training Program has been very effective in maintaining minimum standards for training, there has been no national movement to improve weaknesses or to coordinate strengths.

We must give serious consideration to the qualities to be recognized as an otolaryngologist. In the past, a set of minimum standards were established, including academic and surgical training and formal examination. These well-founded requirements are not challenged, but need modification to accommodate other specialists with strong professional backgrounds who might wish to become otolaryngologists. Modifications should recognize the general otolaryngologist and the specialized otolaryngologist. There is no discrimination in this type of classification if it represents the truth.

One must admire the adaptation and improvisation of the general plastic surgeon in reducing the number of years of training in general surgery to three and giving three years' credit to the otolaryngologist and orthopedic surgeon entering into a plastic surgery training pro-

gram. It was sagacious of them to rehabilitate and absorb the maxillofacial surgeon, whether we approve of their motives or their means. They are also addressing themselves to the role of the oral surgeon. Otolaryngology could have gained much by comparable adjustments and adaptations.

It is therefore time for otolaryngologists to reevaluate their training programs in respect to their future development and other specialty training programs. Our American Boards should consider adaptations and changes in respect to the broad scope of otolaryngology and the very sophisticated type of specialists within it. There should be a minimum set of qualifications and also specific qualifications for the various specialties within its framework. Neither should establish exclusive rights. The American Academy of Otolaryngology should be restructured to specifically represent the various specialties functioning inside general otolaryngology. It should also have representatives from the younger doctors and the general ENT specialists. These conglomerate specialty groups should be coordinated with the internal teaching program, with other specialty groups, and with the administrative aspects of the new "Federated Society." They should retain relative autonomy. Scientific meetings should be organized with the thought of embracing all aspects of surgery in the head and neck. There should be certification of competency for the specialists in otolaryngology who have spent extra time in training in one of the divisions of the specialty. There should be recertification every five years. Recognition should be given to the self-

made specialist who gains competency outside of the residency program. In a sense, we are all self-made, and this driving force and motivation may be more productive than a residency. There must be a built-in flexibility rather than a built-in rigidity to the entire program. There must be a central authority that can coordinate socioeconomic, political, and legal activity. Fortunately, the American Council of Otolaryngology is moving in this direction.

It must be admitted that a number of the above suggestions are gradually taking place and are in the minds of the leaders. Accommodation, resistance, and some progress have been generated. There is, however, no overall plan projecting into the next five or ten years. This exposes otolaryngology to a potentially diminished role in this area in the future, and even to the possibility of being finessed out of the important aspects of head and neck surgery by more astute planners. If we fail in this, it could lead to restrictions in hospital appointments, limitations in the state and national societies, a control on insurance payments, and a loss of a most-favored position in the National Health Program. Such a chain of events would almost obliterate certain aspects of Otolaryngology.

A positive and coordinated program, consisting of a federation of all of the otolaryngological societies, academies, associations, councils, and committees in a cohesive and unified structure embracing the other specialty groups in the area of the head and neck, would create a small renaissance in the administrative capabilities of our specialty.

SCIENTIFIC SESSIONS

The first Scientific Session of the Ninety-sixth Annual Meeting, held in the Phoenix Ballroom of the Hyatt Regency Atlanta, Atlanta, Georgia, convened on Sunday, April 6, 1975, at 8:30 A.M. The First Vice-President of the Association, John A. Kirchner, M.D., of New Haven, Connecticut, was in the Chair for the first session.

FREY'S SYNDROME - A TECHNICAL REMEDY

ROY B. SESSIONS, M.D.

DAVID T. ROARK, M.D.

BOBBY R. ALFORD, M.D.

HOUSTON, TEXAS

SUMMARY — The symptoms of Frey's syndrome are occasionally of sufficient magnitude to warrant curative treatment. In four patients, a fascia lata graft was placed under the involved skin in an attempt to offer permanent relief from the cutaneous discomfort suffered during eating. Two of these patients have excellent long-term results. The other two patients were lost to long-term follow-up but were asymptomatic several months following grafting.

Facial cervical gustatory sweating is relatively common following surgery or injury on or about salivary gland tissue but is usually not of sufficient magnitude to warrant surgical treatment. In a small percentage of patients, however, the flushing, sweating, and associated discomfort are of such intensity that curative treatment is desirable.¹ Herein is described a technique of symptom correction which has, thus far, proven reliable, effective, and lasting.

The symptoms of flushing, sweating, and cutaneous discomfort associated with mastication of food apparently were first described in 1757² in a patient in which the parotid gland had been injured. In the ensuing years, other reports of such an occurrence were made; and in 1923, Lucie Frey³ pointed out that the sweating in such cases was confined to the area of distribution of the auriculotemporal nerve. The now well-known syn-

drome bears her name. Since that time, abnormal gustatory sweating has been noted following parotid and submaxillary gland surgery,⁴ radical neck dissection,⁵ and transposition of chest wall pedicle flaps to the lateral facial area.⁶

The neuroanatomy pertinent to this subject is somewhat involved but fairly well understood.⁶ Anatomic alteration of autonomic nervous system relations is the basis by which abnormal gustatory sweating occurs. Preganglionic parasympathetic neurons which are destined to end in parotid gland tissue begin in the inferior salivatory nucleus of the brain stem. These fibers leave by way of the glossopharyngeal nerve, enter the tympanic plexus in the middle ear from whence they exit without synapse, then run in the middle cranial fossa as the lesser superficial petrosal nerve, and finally reach the otic ganglion by way of the foramen ovale. In the otic ganglion,

From the Department of Otorhinolaryngology and Communicative Sciences, Baylor College of Medicine, Houston, Texas.

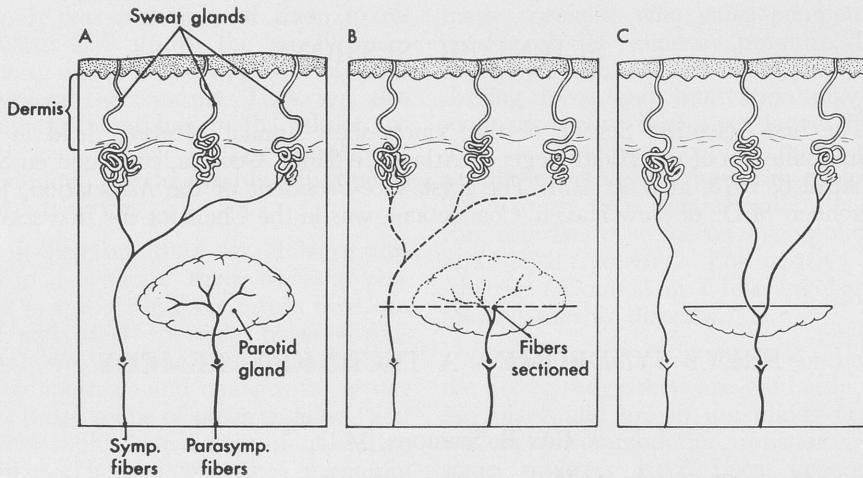


Fig. 1. A) Normal innervation of sweat glands. B) Surgery. C) Abnormal regeneration following surgery.

they synapse with postganglionic parasympathetic fibers which then join the auriculotemporal nerve and leave this nerve during its course in the parotid gland. These postganglionic parasympathetic fibers are secretomotor to the glandular tissue of the parotid and in addition cause vasodilation of the blood vessels of the gland. This is a cholinergic system, i.e., the fibers liberate acetylcholine which acts on the glandular tissue as the chemical mediator of the nerve impulses.⁶

The sympathetic innervation of the parotid controls vasoconstriction of the vessels of the glandular tissue. The preganglionic sympathetic fibers which ultimately affect the parotid gland originate in the spinal cord, in the first and second thoracic segments, in the lateral horn of white rami communicans, and go on to the cervical sympathetic ganglia where they synapse with postganglionic fibers. Most of these fibers join the internal and external carotid arteries and ultimately are carried with the auriculotemporal nerve to the parotid gland and sweat glands in the adjacent skin. Most postganglionic sympathetic fibers release noradrenaline or adrenalin rather than acetylcholine as is seen with parasympathetic fibers and are therefore adrenergic. The sympathetic fibers

to the sweat glands are exceptions, however, and they release an acetylcholine-like substance which makes them functionally cholinergic.⁶ It is this peculiarity in nerve physiology which allows the development of the abnormal neural regeneration which leads to gustatory sweating. Following parotid surgery or injury, both the sympathetic fibers to the sweat glands and the parasympathetic fibers to the parotid glandular tissue are injured. The most acceptable theory of development of gustatory sweating involves a misdirected regeneration of the injured parasympathetic fibers to the sweat glands of the adjacent skin⁷ (Fig. 1A, B, and C). The fact that both the parotid parasympathetic and sweat gland sympathetic fibers are cholinergic allows this altered neural transmission. Thus, gustatory sweating is explainable both from a neurohumoral and an anatomic standpoint. With chewing of food, the parasympathetic secretomotor stimulation is directed to the sweat glands rather than the intended salivary gland tissue.

Laage-Hellman⁸ demonstrated a very high incidence of subclinical gustatory sweating in persons who had undergone parotid surgery. That this occurs is not commonly recognized because the starch-iodine test is normally not per-

formed on patients without symptoms. Myers and Conley⁶ have made the distinction between normal and abnormal gustatory sweating. Normal gustatory sweating is seen on the lip area in some persons after looking at or smelling spicy foods.⁹ Uprus, *et al*¹⁰ pointed out that in persons with abnormal gustatory sweating the act of mastication was necessary and the mere presence of food in the mouth did not normally induce the symptoms. Also, Freedberg¹¹ noted that in patients with abnormal gustatory sweating, the chewing of a bland substance such as paraffin does not produce the phenomenon, whereas the chewing of food does.

TREATMENT

Various methods of treatment, some medical, most surgical, have been utilized in those patients with sufficient symptomatology to warrant therapy. Scopolamine hydrobromide cream (3%)¹² applied topically is often beneficial but its application is at times associated with blurring of vision, dry mouth, and urinary retention. Systemic atropine has also been recommended, but because of its annoying side effects, has been used only sparingly.

Section of the auriculotemporal nerve¹³ is fraught with hazards to the nearby facial nerve because of the scarring from previous surgery. In addition, many patients have a recurrence of symptoms within 6-12 months following this procedure.^{14,15}

Intracranial section of the glossopharyngeal nerve is apparently successful in relieving symptoms but seems too formidable a procedure for the symptoms. Excision of the involved skin offers only a temporary relief from the sweating and, in addition, is deforming.¹⁶ Others¹⁷ have advocated ablation of the sweat glands by radiation therapy. The dose level needed to accomplish this is high, and this method seems impractical.

Sectioning of the parasympathetic fibers in the tympanic plexus for the purpose of interrupting the secretory

fibers to the parotid was first suggested by Hemenway.¹⁸ Golding-Wood¹⁹ later introduced the name "tympanic neurectomy" for this procedure. According to several reports since, this method is generally effective in treating gustatory sweating, although the symptoms are often not completely eliminated. Smith *et al*¹ summarized a collection of various data and stated that the results were "excellent" in 36% of the cases treated with tympanic neurectomy, "satisfactory" in 54% and "unsatisfactory" in 10%. The time of follow-up on these patients was not included in his writing.

Because of a possible connection between parasympathetic fibers in the chorda tympani nerve and the parasympathetic fibers in the otic ganglion, some authors have advocated combining excision of the chorda with tympanic neurectomy.¹⁶

The imperfections of past surgical efforts and a search for a more direct, reliable, effective, and longlasting method of eliminating the symptoms of Frey's syndrome led us to implanting fascia under the affected skin in four patients suffering from gustatory sweating in an effort to relieve their symptoms.

The following two case histories illustrate the benefits of this procedure.

CASE REPORTS

Case 1. A 29-year-old female underwent a left superficial parotidectomy for a benign tumor in 1965. Within months, the symptoms of gustatory sweating appeared over the operated site and in the following year increased to the extent that she had to mop her face with a towel during meals. Erythema and pain of the preauricular area also developed with mastication of food. The starch-iodine test was positive. Two years following surgery, she underwent a left tympanic neurectomy. Immediately following surgery she was free of symptoms, and no observable sweat was present in the skin during mastication of food. A starch-iodine test was not per-

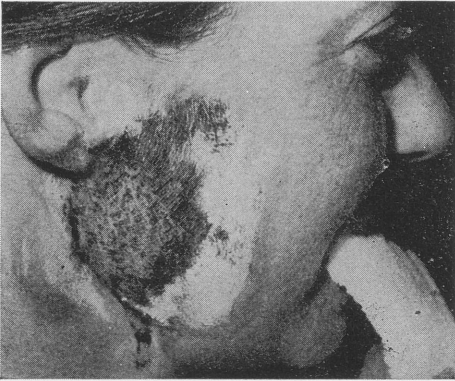

Fig. 2. Starch-iodine test demonstrating gustatory sweating.

formed. Within three months following tympanic neurectomy, however, clinically apparent sweating recurred. In the fall of 1969, a facial flap was elevated along the line of previous parotid surgery; and a large piece of fascia lata which had been removed from the same patient's thigh was placed and sutured on to the

tissue bed which corresponded to the undersurface of the affected skin. No symptoms have been noted in 5½ years since surgery, and the starch-iodine test remains negative.

Case 2. A 49-year-old male had a left superficial parotidectomy in July 1970 for a benign tumor. Two months later he developed cutaneous tenderness and sweating of the left cheek with mastication. The starch-iodine test was positive. In April 1971, a left tympanic neurectomy was performed with initial elimination of symptoms. Several months following the tympanic neurectomy, the symptoms of gustatory sweating reappeared in the same distribution as before surgery. In July 1972, a fascia lata graft was implanted beneath the involved skin, utilizing the previous parotidectomy incision. The elimination of all symptoms followed this procedure, and 2½ years later he is symptom-free and the starch-iodine test is negative.

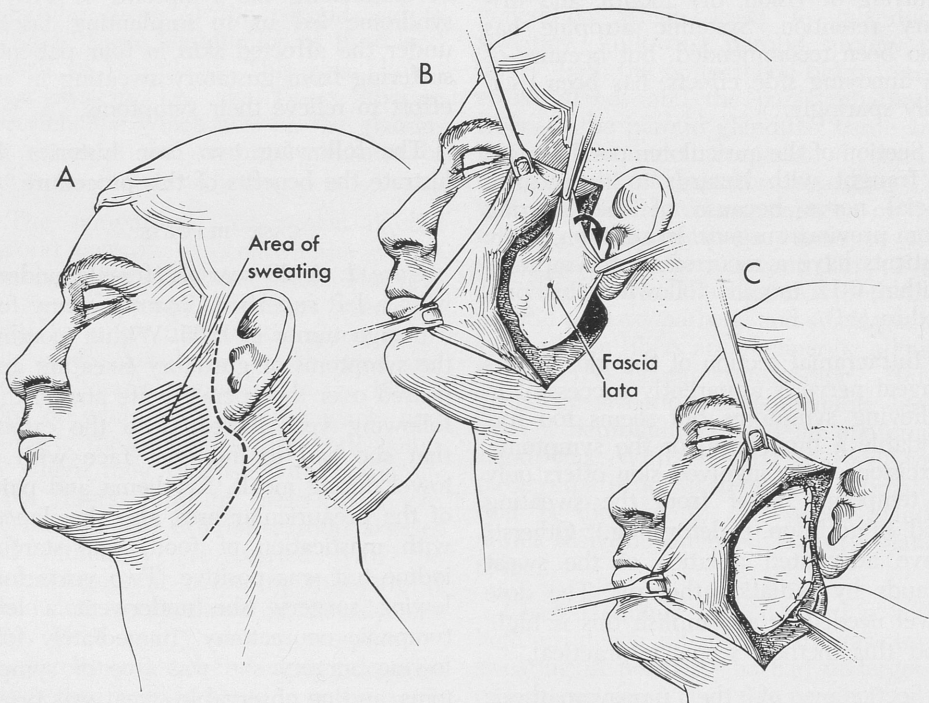


Fig. 3. A) Involved skin and proposed incision. B) Facial flap elevation and fascial graft being placed on parotid bed. C) Graft sutured to underlying tissue bed.

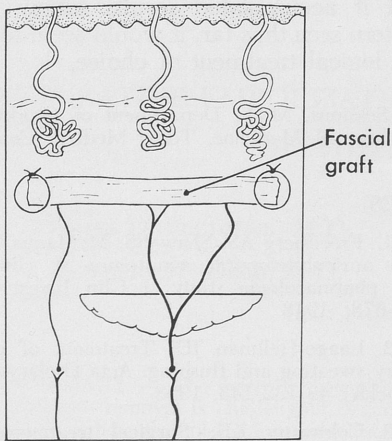


Fig. 4. Diagram showing placement level of graft and method of blocking abnormal regeneration of parasympathetic fibers.

SURGICAL TECHNIQUE

The area involved with gustatory sweating is carefully studied by the starch-iodine test method of demonstrating facial sweating (Fig. 2). The boundaries of the involved skin are tattooed with methylene blue on a needle point. At surgery, a thin skin flap, with a small amount of subcutaneous tissue attached, is designed. A large piece of fascia lata is removed from the lateral aspect of thigh. The fascia is then fashioned to the appropriate shape and size and is sutured to the subcutaneous and scar tissue bed from the previous surgery (Fig. 3A, B, and C). The facial skin flap is then returned, the incision closed, and a bulky dressing applied to insure hemostasis, flap security, and graft attachment to the overlying skin.

DISCUSSION

It seems sensible to interrupt the attachment of parasympathetic fibers to sweat glands at the most peripheral level, *i.e.* just beneath the skin, and to interfere with subsequent regrowth or reinnervation to the sweat glands (Fig. 4). To accomplish this safely and effectively, a material of a consistency that will prevent regrowth of nerves through it into the skin is required. Dermis would

not fulfill this requirement and has some potentially undesirable sequelae (formation of cysts, *etc.*). The implantation of synthetic materials introduces the hazards of infection, skin slough, and rejection. Fascia, on the other hand, appears to provide a sufficient barrier and, in addition, is an autogenous material. Fascia lata is easily obtained, thicker than most fascial layers in the body, and its removal does not produce a significant disability to the patient. It should be removed from the lateral part of the thigh, for it is here that this fascia is the thickest.

It would seem important to avoid perforating the fascial graft so as not to allow penetration of nerve fibers. Also, it is obviously essential to implant one continuous piece of fascia which covers an area larger than the corresponding area of involved skin. Suturing the graft in place prevents sliding under the skin flap. The tough tissue to which the fascia is sutured offers a strong attachment site for the graft.

It is known that the ultimate results of treatment of gustatory sweating must be measured over a period of several years.⁶ The two patients described above have been symptom-free and have also had negative starch-iodine tests for 5½ and 2½ years, respectively. Although recurrence of gustatory sweating seems unlikely at this late date, their outcome should be carefully followed. As noted, each had undergone a tympanic neurectomy with only temporary relief and had a recurrence of symptoms a few months later. In addition to these two patients, we have performed fascial implants on two additional patients with the same excellent result, but they were followed for only a few months before they were lost to follow-up.

CONCLUSION

We do not have sufficient experience with subcutaneous fascia lata grafting to advocate its use instead of either tympanic neurectomy alone or tympanic neurectomy in conjunction with chorda tympani neurectomy as standard treat-

ment for abnormal gustatory sweating occurring after parotidectomy. The procedure is, however, reliable and safe;

and if accumulated results follow the pattern seen thus far, it would seem to be the logical treatment of choice.

Request for reprints should be sent to Roy B. Sessions, M.D., Department of Otorhinolaryngology and Communicative Sciences, Baylor College of Medicine, Texas Medical Center, Houston, Texas.

REFERENCES

1. Smith RO, Hemenway WG, Stevens KM, et al: Jacobson's Neurectomy for Frey's Syndrome. *Am J Surg* 120:478-481, 1970
2. Duphenix cited by Spiro RH, Martin H.⁵
3. Frey L: Le syndrome du nerf auriculotemporal. *Rev Neurol (Paris)* 30:97-104, 1923
4. Young AG: A further report on the chorda tympani syndrome. *Br Med J* 5173: 620-621, 1960
5. Spiro RH, Martin H: Gustatory sweating following parotid surgery and radical neck dissection. *Ann Surg* 165:118-127, 1967
6. Myers EN, Conley J: Gustatory sweating after radical neck dissection. *Arch Otolaryngol* 91:534-542, 1970
7. Andre-Thomas: Le double reflex vasodilatateur et sudoral de la face consecutif aux blessures de la loge parotidienne; les parareflexes. *Rev Neurol (Paris)* 1:447-460, 1927
8. Laage-Hellman JE: Gustatory sweating and flushing after conservative parotidectomy. *Acta Otolaryngol (Stockh)* 48:234-252, 1957
9. List CF, Peet MM: Sweat secretions in man. *Arch Neurol Psychiat* 39:1228-1237, 1938
10. Uprus V, Gaylor JB, Carmichael EA: Localized abnormal flushing and sweating on eating. *Brain* 57:443-463, 1934
11. Freedberg AS, Shaw RS, McManus MJ: The auriculotemporal syndrome: A clinical and pharmacologic study. *J Clin Invest* 27: 669-678, 1948
12. Laage-Hellman JE: Treatment of gustatory sweating and flushing. *Acta Otolaryngol (Stockh)* 49:132-143, 1958
13. Coldwater KB: Surgical treatment of the auriculotemporal syndrome. *Arch Surg* 69:54-57, 1954
14. Glaister D, et al: The mechanism of postparotidectomy gustatory sweating. *Br Med J* 2:942-946, 1958
15. Chisa N, et al: Auriculo temporal syndrome. *Arch Dermatol* 90:457-459, 1964
16. Blumenfeld RJ, Friedman JE: Intratympanic Surgical Treatment of Frey's Syndrome. *Arch Otolaryngol* 86:28-33, 1967
17. Needles W: The auriculotemporal syndrome with suggestions regarding therapy. *Arch Neurol Psychiat* 35:357-360, 1963
18. Hemenway WG: Gustatory sweating and flushing. *Laryngoscope* 70:84-90, 1960
19. Golding-Wood PH: Tympanic neurectomy. *J Laryngol Otol* 76:683-693, 1962
20. Friedman WH, Swerdlow RS, Pomarico JM: Tympanic neurectomy: a review and an additional indication for this procedure. *Laryngoscope* 84:568-576, 1974

PREOPERATIVE EMBOLIZATION OF JUVENILE ANGIOFIBROMAS OF THE NASOPHARYNX

JAMES D. PLETCHER, M.D.

THOMAS H. NEWTON, M.D.

HERBERT H. DEDO, M.D.

DAVID NORMAN, M.D.

SAN FRANCISCO, CALIFORNIA

SUMMARY — The juvenile nasopharyngeal angiofibroma is a vascular tumor. Careful and complete removal is challenging because of the brisk bleeding during surgery. The means applied to reduce this blood loss have included preoperative estrogens, ligation of feeding vessels, silicone embolization of feeding vessels, and cryosurgery. We have used preoperative Gelfoam® embolization of the internal maxillary artery in seven patients. Our clinical impression of significant reduction in loss of blood was confirmed by comparison with 16 previous patients. The average amount of blood lost in the embolized group was half that of the control group. A study of this type comprises many variables; however, the results do suggest that preoperative embolization of the internal maxillary artery is of advantage in the surgical treatment of juvenile angiofibromas.

The juvenile nasopharyngeal angiofibroma is a fibrovascular tumor that arises in the nasopharynx of young males. The treatment of choice is complete surgical removal. The location of the tumor, however, may cause difficulty in the surgical exposure, and the vascular nature of the lesion often results in massive intraoperative hemorrhage. The use of preoperative embolization in an attempt to reduce intraoperative bleeding and thus facilitate complete surgical removal, is here evaluated.

METHODS AND MATERIALS

Preoperative embolization of branches of the external carotid artery was employed in seven consecutive young male patients in whom juvenile angiofibroma was diagnosed. In two patients, in whom the tumor was supplied by both the right and left external carotid arteries, both external carotid arteries were embolized. Embolization was performed two to three hours before the surgical procedure in two patients; in the remainder, the embolization was employed on the afternoon preceding the surgical procedure.

The embolization was performed under local anesthetic by means of the transfemoral catheter technique.¹ After percutaneous puncture of the femoral artery, a polyethylene catheter (I.D. 0.045 inches; O.D. 0.065 inches) was advanced into the abdominal aorta by the Seldinger technique. With fluoroscopic control, the catheter was maneuvered into the common carotid artery. The catheter was then advanced into the external carotid artery under horizontal-beam fluoroscopy. Next, the catheter was further advanced into the vessel that had been identified on previous angiography to be the major blood supply to the tumor. In most instances, this vessel proved to be the internal maxillary artery. A selective, internal maxillary arteriogram was then obtained to define accurately the position of the catheter (Fig. 1A and B). Small fragments of Gelfoam®* (1 to 2 mm in diameter) were then injected through the catheter using saline as a bolus. The position of the catheter tip and the effect of embolization on the blood supply to the tumor were frequently checked fluoroscopically with injections of contrast media. Serial angiograms were obtained during the embolization procedure to determine the reduction of blood flow to the tumor. The procedure was terminated when angiograms showed obliteration or pronounced reduction in the vascularity of the tumor (Fig. 1C).

*Upjohn Company, Kalamazoo, Michigan.

From the Departments of Otolaryngology and Radiology, University of California, San Francisco, California.

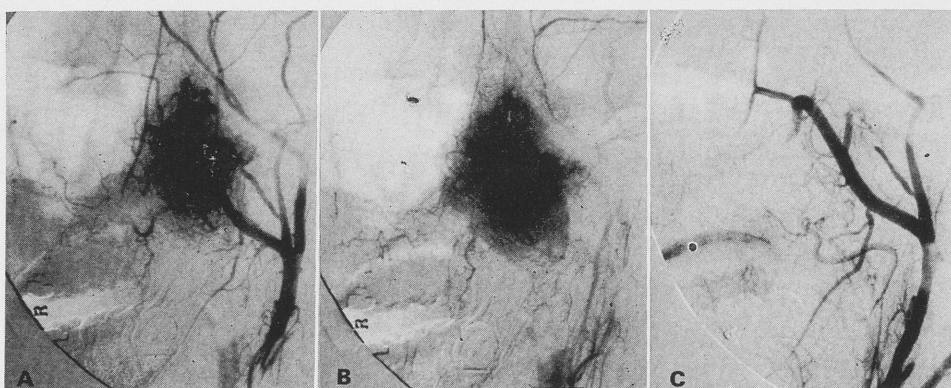


Fig. 1. Juvenile nasopharyngeal angiofibroma. Selective external carotid arteriogram, lateral projection. A) Early and B) late arterial phases before embolization. The highly vascular tumor in the nasopharynx is well shown. C) Postembolization arteriogram. The vascular neoplasm is no longer opacified.

TABLE I

SUMMARY OF 7 PATIENTS TREATED WITH PREOPERATIVE EMBOLIZATION

<i>Case</i>	<i>Age</i>	<i>Symptoms</i>	<i>Site of Tumor</i>	<i>Operative Approach</i>	<i>Estimated Blood Loss</i>
Tumors Limited to Nasopharynx					
1	15	Nasal obstr., 4 mo	Nph.	Transp.	500 cc
2	19	Nasal obstr., 1 yr; intermittent epist., 3 mo	Nph.	Transp.	500 cc
3	15	Nasal obstr., 4 yr; severe epist. — 1 episode	Nph., nose	Transp.	670 cc
4	16	Nasal obstr.; inter- mittent epist., 1 yr	Nph., nose	Transp.	1275 cc
Average:					736 cc
Tumors Extending Beyond Nasopharynx					
5	17	Nasal obstr. and recurrent epist., 1 yr	Nph., sph.	Transp.	1500 cc
6	17	Nasal obstr., 2 yr	Nph., nose, sph., ptmax. space	Transp.	1300 cc
7	16	Nasal obstr., recur- rent epist., 6 mo	Nph., sph., ptmax. space; max. sinus	Transp. Cald- well-Luc	2500 cc
Average:					1767 cc

Obstr. — Obstruction.

Epist. — Epistaxis.

Nph. — Nasopharynx.

Transp. — Transpalatal.

Sph. — Sphenoid.

Ptmax. — Pterygomaxillary.

Max. — Maxillary.

TABLE II
SUMMARY OF 16 PATIENTS TREATED WITHOUT PREOPERATIVE EMBOLIZATION

<i>Case</i>	<i>Age</i>	<i>Symptoms</i>	<i>Site of Tumor</i>	<i>Operative Approach</i>	<i>Estimated Blood Loss</i>
Tumors Limited to Nasopharynx					
1	13	Nasal obstr.	Nph.	Transp.	400 cc
2	13	Epist., left nasal obstr.	Nph.	Transp.	700 cc
3	17	Nasal obstr., 2 mo	Nph.	Transp.	800 cc
4	8	Recurrent epist., 1 yr	Nph., nose	Transp.	1000 cc
5	18	Recurrent epist.	Nph.	Transp.	1000 cc
6	15	Excessive bleeding following "polyp" removal	Nph.	Transp.	2000 cc
7	15	Epist.	Nph.	Transp.	2500 cc
Average:					1200 cc
Tumors Extending Beyond Nasopharynx					
8	17	Recurrent epist.	Nph., minimal sph. extension	Transp.	600 cc
9	17	Left nasal obstr.; left cheek swelling	Nph., left max. sinus; pterygomaxillary fossa	Transp. lip splitting incision, external carotid ligation	1000 cc
10	10	Recurrent epist.	Nph., nose, sph.	Transp.	1700 cc
11	14	Nasal obstr., 1 yr	Nph., sph.	Transp.	2000 cc
12	12	Nasal obstr., epist., foul nasal discharge	Nph., nose, sph.	Transp.	4000 cc
13	16	Nasal obstr.	Nph., sph., lateral pharyngeal space	Transp.	4500 cc
14	16	Nasal obstr., recurrent epist.	Nph., left max. antrum	Transp., lateral rhinotomy	4500 cc
15	17	Recurrent epist.	Nph., sph.	Transp.	5500 cc
16	14	Epist., nasal obstr. 6 wk	Nph., max. sinus; right cheek; floor of orbit	Transp.; Caldwell-Luc	6000 cc
Average:					3311 cc

The age, presenting symptoms, site of tumor, operative approach, and estimated blood loss in the series of seven male patients are shown in Table I. In none of these patients had removal of the tumor been attempted previously. The tumor was limited to the nasopharynx and nose in four of the patients, and

in three it had extended beyond these confines. The transpalatine surgical approach was employed in all patients. A Caldwell-Luc procedure also was needed in one patient to remove the extension of a tumor that filled the maxillary sinus.

An attempt was made to estimate carefully

the blood loss encountered during the operative procedure in the seven patients. The records of 16 patients with angiofibroma treated in this institution in the past 15 years were then reviewed to determine the estimated loss of blood in patients who had not been prepared with preoperative embolization. The estimated loss of blood as stated in the operative report was compared with the number of units of blood used in replacement transfusion. The loss was determined by the higher of the two figures. The anatomic extent, operative approach, and estimated blood loss in this group of patients are shown in Table II. The transpalatine exposure was the primary approach to the tumor in both groups of patients.

RESULTS

The average amount of blood lost during surgical removal in the seven patients was 1300 cc. In the four patients in whom the tumor was limited to the nasopharynx, the estimated blood loss averaged 736 cc. The amount lost during the exposure was estimated at 300 cc, and that during the closure as 200 cc. The average blood loss resulting from removal of the tumor was therefore estimated as only 236 cc. In the three patients in whom the tumor extended outside the confines of the nasopharynx and nose, the average blood loss increased to about 1767 cc. This increase was largely the result of oozing from the nasopharynx during the Caldwell-Luc procedure, and the antral and nasal bleeding during the closure of the palate.

The average total blood loss in the 16 patients who had undergone surgical removal of the tumor without preoperative embolization was about 2400 cc. In the seven patients of that group, in whom the tumor was limited to the nasopharynx, the loss of blood averaged 1200 cc. In the nine patients in whom the tumor extended beyond the nasopharynx, the blood was estimated as 3311 cc.

DISCUSSION

The juvenile nasopharyngeal angiofibroma is a highly vascular neoplasm typically found in pubescent males. It has been reported, however, in patients as early as eight years of age and as late as 50 years.² The origin of the tumor and the hormonal factors that may influence

its activity have been discussed by previous authors.³⁻⁵ These as yet undefined hormonal factors may account for the regression of a tumor, as occasionally observed in the postpubertal period.

Grossly, the tumor consists of a smooth, reddish or purple, nonulcerated, lobulated, firm mass which arises eccentrically from the roof of the anterior nasopharynx or from the posterior nasal fossa. Its base is usually rather broad, and it is not easily moved by the examining finger. This tumor must be distinguished from adenoid tissue, choanal polyps, nasopharyngeal cysts, nasopharyngeal carcinoma, and rhabdomyosarcoma. It may reach considerable size; its extensions tend to be polydirectional along natural foramina and fissures.⁶ As the tumor enlarges, extensions from it project anteriorly into the posterior nares, laterally into the pterygomaxillary fossa, and superiorly into the sphenoid sinus. Particularly aggressive tumors may erode into the apex of the orbit or may extend intracranially through the base of the skull.

The usual presenting symptoms are those of nasal obstruction and epistaxis. The bleeding is intermittent and its control difficult, frequently requiring hospitalization and transfusions. Since the tumor is benign, pain is rarely an early symptom.

Roentgenograms of the sinuses and tomography of the skull base help to determine the extent of the tumor and the degree of bone involvement. Arteriography is essential to establish the diagnosis, to outline the blood supply to the tumor, and to demonstrate its anatomic extent. In the early stages of the disease, the blood supply to the tumor is almost exclusively from the ascending pharyngeal and internal maxillary branches of the external carotid artery. Selective external carotid arteriography shows dense contrast-medium staining of the tumor during the capillary phase of angiography. The maximum accumulation of contrast material in the tumor is usually seen three to six seconds after injection is begun. When the tumor ex-

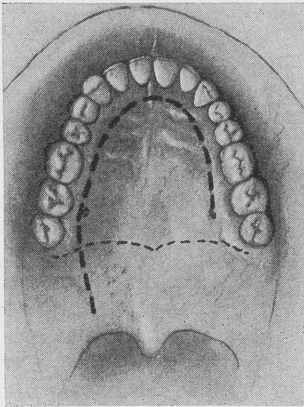


Fig. 2. Transpalatal incision with soft palate extension on one side to expose the nasopharynx.

tends intracranially, dural branches of the internal carotid artery and even cortical branches of the anterior or middle cerebral artery may contribute to the blood supply. Tumors that invade the ethmoid sinus or orbit may receive their blood supply in part from branches of the ophthalmic artery. Larger tumors may also receive contributions from the contralateral external or internal carotid arteries. Bilateral selective internal and external carotid arteriograms are advisable, therefore, in all patients with suspected nasopharyngeal angiofibromas. These studies are most easily accomplished by means of transfemoral catheter techniques. Magnification and subtraction techniques aid in the angiographic evaluation of these lesions.

The treatment of choice is complete surgical removal. Some authors^{3,7} have recommended supportive measures until the tumor regresses spontaneously. Unfortunately, significant complications, such as life-threatening hemorrhage, infection, and intracranial extension of the tumor may precede spontaneous regression. Although Briant *et al*⁸ recommended primary radiation therapy, we prefer to reserve such therapy for tumor recurrence or for those tumors which are inoperable because of intracranial extension.⁹

The transpalatine approach to the na-

sopharynx has provided good exposure, particularly when the incision is extended to the soft palate. The transpalatine incision starts just anterior to the greater palatine foramen on the side of the lesser tumor involvement. It curves around the dental arch, staying about 5 to 7 mm inside the gum line of the teeth continuing to the opposite greater palatine foramen (Fig. 2). The incision should pass lateral to this foramen since the vessels are divided on this side. From here the incision is extended posteriorly past the edge of the hard palate and 2 to 3 cm into the soft palate, stopping 1.5 to 2 cm from the free edge of the soft palate. This extension into the soft palate greatly improves the mobility of the palatal flap and is the key to excellent exposure of the entire nasopharynx. One of the greater palatine vessels is preserved to provide adequate blood supply to the flap. This transpalatine approach may be combined with an immediate or a delayed Caldwell-Luc procedure when the tumor has extended into the maxillary sinus. It may also be combined with a lateral rhinotomy in instances of extension into the ethmoid or pterygomaxillary fossae.

Despite adequate surgical exposure, however, the actual removal of the tumor is usually attended by brisk and often alarming hemorrhage. Such hemorrhage causes difficulty in the orderly, complete operation required to prevent recurrence. Many surgeons have attempted to reduce surgical blood loss by ligating the external carotid or internal maxillary arteries.¹⁰ External carotid arterial ligation, however, has not proved to be particularly helpful because of the extensive collateral blood supply to the tumor. A hypotensive anesthetic with depression of the systolic blood pressure to 40 to 60 mm Hg may be of benefit.¹¹ Preoperative estrogen therapy has been advocated by several authors.^{5,12,13} Angiograms showed decreased vascularity in three patients treated with estrogens.¹³ Jafek *et al*¹² reported an average blood loss of 1970 cc in 9 patients treated with preoperative estrogen, compared to an average loss of 2960 cc in 25 patients not treated in this manner. Work *et al*¹⁴

concluded that cryotherapy might be an effective adjunct to surgery but that it was not a substitute for standard surgical techniques. Cryotherapy might prove beneficial for small recurrences, but most tumors are too large for this technique.¹⁵

Embolization has proved to be a useful adjunct in the preoperative management of patients with juvenile angiofibromas. Roberson and coworkers¹⁶ used barium-impregnated silastic spheres in the preoperative embolization of the internal maxillary artery in four patients with juvenile angiofibromas. Embolization must not be compared to proximal arterial ligation. The aim of embolization in these patients is to place the embolic material within the distal arterial branches or within the tumor itself. Gelfoam® has proved to be particularly suitable since it may be injected through the catheter in a compressed state. Soon after being exposed to blood, the injected fragments gradually swell to a larger size. Gelfoam®, therefore, has allowed the employment of relatively small catheters which can be introduced into the internal maxillary artery without causing arterial spasm. Reflux of the emboli into the cerebral circulation or inadvertent direct injection of emboli into the internal carotid artery represents the primary risk of this procedure. To avoid this complication, the catheter tip should be placed into the distal internal maxillary artery without obstructing its flow. Throughout the procedure, test injections with radiopaque contrast media are made

to insure maintenance of the proper position of the catheter. Horizontal beam fluoroscopy is important to avoid rotation of the neck of the patient which could result in accidental displacement of the catheter. Small plugs of Gelfoam®, up to 100 or more, are injected to obstruct the small distal arterial branches that supply the tumor. The procedure is terminated when the circulation to the tumor has been obliterated or greatly diminished. Vigilance must be exercised toward the end of the procedure when flow in the internal maxillary artery is slowed, to prevent reflux of emboli into the internal carotid circulation. To date, we have had no complications from this procedure. Complications that involve the central nervous system remain a potential risk, especially when the embolization techniques are not applied carefully.

SUMMARY

Preoperative Gelfoam® embolization of the internal maxillary artery in seven male patients with juvenile nasopharyngeal angiofibroma is described. The average blood loss associated with removal of the tumor was reduced with this technique from an estimated 1200 cc to 736 cc when the tumor was limited to the nasopharynx. With tumors that extended beyond the confines of the nasopharynx, embolization reduced the average estimated blood loss from 3311 to 1767 cc. Preoperative embolization allows controlled surgical removal of the tumor and better visualization of its superior and lateral extensions.

Request for reprints should be sent to Herbert H. Dedo, M.D., Department of Otolaryngology, Room 495U, University of California, San Francisco, Third Avenue and Parnassus, San Francisco, California 94143.

REFERENCES

1. Newton TH, Kerber CW: Techniques of catheter cerebral angiography, Ch. 45, in Newton TH, Potts DG (eds): *Radiology of the Skull and Brain*. St. Louis, C. V. Mosby Co., 1974
2. Rosen L, Hanafee W, Nahum A: Nasopharyngeal angiofibroma: an angiographic evaluation. *Radiology* 86:103-107, 1966
3. Jereb B: Juvenile nasopharyngeal angiofibroma: a clinical study of 69 cases. *Acta Radiol (Ther.)* (Stockh) 9:302-310, 1970
4. Wilson WR: Juvenile nasopharyngeal angiofibroma. *Laryngoscope* 82(2):985-997, 1972
5. Schiff M: Juvenile nasopharyngeal angiofibroma. *Laryngoscope* 69:981-1016, 1959
6. Wilson GH, Hanafee WN: Angiographic findings in 16 patients with juvenile naso-

pharyngeal angiofibroma. Radiology 92:279-284, 1969

7. Martin H, Ehrlich HE, Abels JC: Juvenile nasopharyngeal angiofibroma. Ann Surg 127:513-536, 1948

8. Briant TDR, Fitzpatrick PJ, Book H: The radiological treatment of juvenile nasopharyngeal angiofibromas. Ann Otol Rhinol Laryngol 79:1108-1113, 1970

9. Ward PH, Thompson R, Calcaterra T, *et al*: Juvenile angiofibromas: A more rational therapeutic approach. Laryngoscope 84: 211-2194, 19874

10. Williams JD, Chisholm D: Internal maxillary artery ligation for the removal of juvenile nasopharyngeal angiofibroma. J Laryngol Otol 87(2): 1153-1158, 1973.

11. Daly J: Personal Communication.

12. Jafek BW, Nahum AM, Butler RM, *et al*: Surgical treatment of juvenile nasopharyngeal angiofibroma. Laryngoscope 83: 707-720, 1973

13. Christiansen TA, Duvall AJ, Rosenberg Z, *et al*: Juvenile nasopharyngeal angiofibroma. Trans Am Acad Ophthalmol Otolaryngol 78:140-147, 1974

14. Work WP, Boles R, Nichols RD: Angiofibromas: diagnosis and treatment including cryosurgery. Trans Am Acad Ophthalmol Otolaryngol 70:1108-1113, 1970

15. Conley J, Healey WV, Blaugrund SM, *et al*: Nasopharyngeal angiofibromas in the juvenile. Surg Gynecol Obstet 126:825-837, 1968

16. Roberson G, Biller H, Sessions R, *et al*: Pre-surgical internal maxillary artery embolization in juvenile nasopharyngeal angiofibroma. Laryngoscope 82(2):1524-1532, 1972

NONTRAUMATIC, NONNEOPLASTIC SUBGLOTTIC STENOSIS

MOHSEN DJALILIAN, M.D.

THOMAS J. McDONALD, M.D.

KENNETH D. DEVINE, M.D.

LOUIS H. WEILAND, M.D.

ROCHESTER, MINNESOTA

SUMMARY — During a 20-year period, 12 patients with nontraumatic, nonneoplastic subglottic stenosis were seen at the Mayo Clinic. The etiologic factors were relapsing polychondritis, amyloidosis, sarcoidosis, and Wegener's granulomatosis. Because of the diverse initial presentation of the disease, the clinician should consider that the stenosis is a manifestation of a systemic disorder and carry out an otolaryngologic and physical examination with the appropriate roentgenograms and blood and urine tests. Treatment, if a systemic disease is proved, consists of appropriate medication. Surgery may be necessary, depending on the nature of the lesion. Small strictures may not need to be treated.

Subglottic stenosis can be defined as any narrowing of the subglottic area. Its most common cause is use of cuffed tracheotomy tubes. Less common causes are external trauma to the larynx (for example, in automobile accidents), a high tracheotomy incision, and congenital stenosis, as in infants. Subglottic stenosis can also result from extension of neoplastic disease from other sites to the subglottic area.¹

But what of subglottic stenosis in the adult or adolescent without preceding trauma? The diagnosis in such cases may be perplexing, and treatment is often difficult. The purpose of this report is to describe 12 cases of nontraumatic, nonneoplastic subglottic stenosis recorded during the last 20 years. The etiologic factors were: 1) relapsing polychondritis; 2) amyloidosis; 3) sarcoidosis; and 4) Wegener's granulomatosis. Features of each condition are illustrated in the case reports that form the basis of this report.

CASE REPORTS

RELAPSING POLYCHONDritis

Case 1. A 47-year-old female presented at the Mayo Clinic with a history of increasing

shortness of breath for about 18 months. She stated that she had undergone bronchoscopy elsewhere and that her breathing had temporarily become easier. At the Mayo Clinic, indirect laryngoscopy revealed subglottic stenosis with mobile vocal cords, confirmed by tracheal tomograms. A saddle-nose deformity was noted. Results of screening blood tests, including serologic studies, were normal; the erythrocyte sedimentation rate (ESR) was 36 mm in 1 hour (Westergren). Tracheotomy followed by laryngoscopy was then performed. A 7 mm bronchoscope was passed through the area of subglottic stenosis, the diameter of which was 6 mm. The trachea below the stenotic area was normal. Representative biopsies were taken, and the area was injected with 1 ml of triamcinolone. Histopathologic examination produced evidence of chronic subepithelial inflammation with fibrosis. At follow-up examination 3 months later, the area of stenosis was found to be much smaller. At her next visit, 3 months later, she was again dyspneic, and recurrence of the stenosis was noted. She has continued to require a tracheotomy.

Case 2. A 26-year-old male had a two-year history of respiratory distress. Cortisone, given before he was seen at the Mayo Clinic, had given him no relief. His past history included intermittent episodes of conjunctivitis since childhood, particularly on the right side. Ophthalmic examination showed that his vision was normal, but chronic marginal corneal degeneration was noted bilaterally. Rhinolaryn-

From the Mayo Clinic and Mayo Foundation, Rochester, Minnesota.

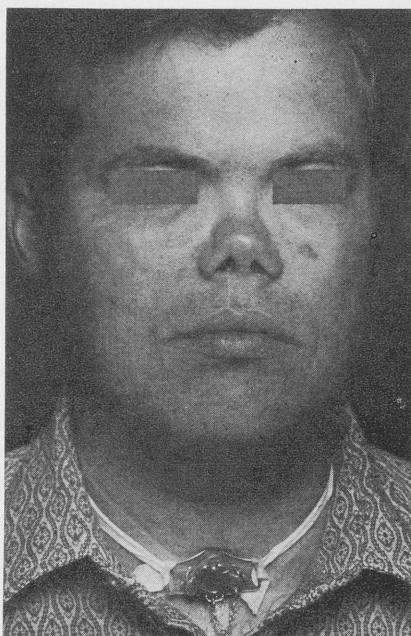


Fig. 1 (Case 2). Relapsing polychondritis. Note saddle-nose deformity and valved speaking tube.

gologic examination revealed a saddle deformity of the nose (Fig. 1) with mucosal crusting and, on indirect laryngoscopy, normal vocal cords with a narrowing of the subglottic area. Tracheal tomograms confirmed subglottic stenosis (Fig. 2). Results of screening blood tests, including serologic studies, and the ESR were normal. Direct laryngoscopy and bronchoscopy were followed by biopsy of the stenotic area; a mild, nonspecific fibroblastic reaction was reported. A speaking tracheotomy tube was inserted five days later; the portion of tracheal cartilage removed during this procedure disclosed inflammatory changes. The speaking tube was tolerated well.

Case 3. A 55-year-old female presented at the Mayo Clinic with recent progressive respiratory obstruction. A general medical examination revealed no abnormalities except a saddle-nose deformity, and results of screening blood tests, including serologic studies, and the ESR were normal. Indirect laryngoscopy showed subglottic stenosis, the upper limit of which was detected 1 cm below the true vocal cords; overall, the subglottic area was narrowed to about 4 mm. Tomograms of the trachea confirmed the subglottic narrowing. When she underwent tracheotomy and thyrotomy four months later, the stricture, at the level of the cricoid ring, was found to be formed chiefly by a band of scar supported by thick fibrous tissue on the posterior wall of the trachea; the 4 mm width of the sub-

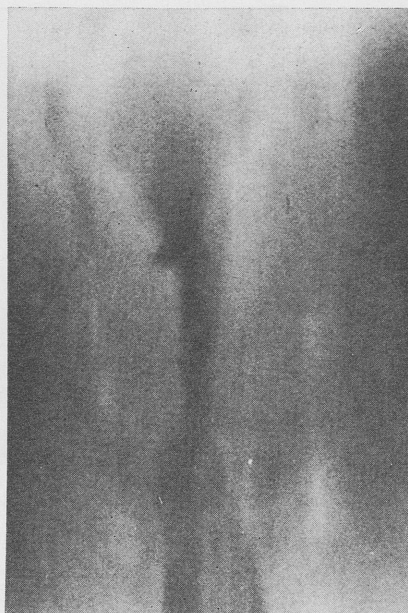

Fig. 2 (Case 2). Relapsing polychondritis. Note long area of subglottic narrowing.

glottis noted earlier was confirmed. The scar tissue was removed and the denuded area (4 by 3 cm) was covered with a skin graft around a sponge rubber stent. This was removed by laryngoscopy, and decannulation three weeks later was easy. The airway since has been good.

Case 4. A 17-year-old male had noted a slowly progressive voice change and dyspnea on exertion for one year. Examination showed a saddle-nose deformity, a deformity of each external ear, and a dish-shaped deformity of the sternum. Tracheal tomograms showed narrowing from a point 2 cm below the true vocal cords to about the level of the clavicle. At the narrowest point, the diameter was about 6 mm. Results of screening blood tests, including serologic studies, and the ESR were normal. The larynx and subglottic region were opened through a vertical midline incision. The cricoid ring was incised and the cartilage outfractured in order to enlarge the airway. The new aperture was then skin grafted. Follow-up examination revealed much improved exercise tolerance and a good airway.

COMMENT

We believe that the lesions in these four patients were those of the quiescent phase of relapsing polychondritis. The term "relapsing polychondritis" was coined by Pearson, et al² in 1960, though

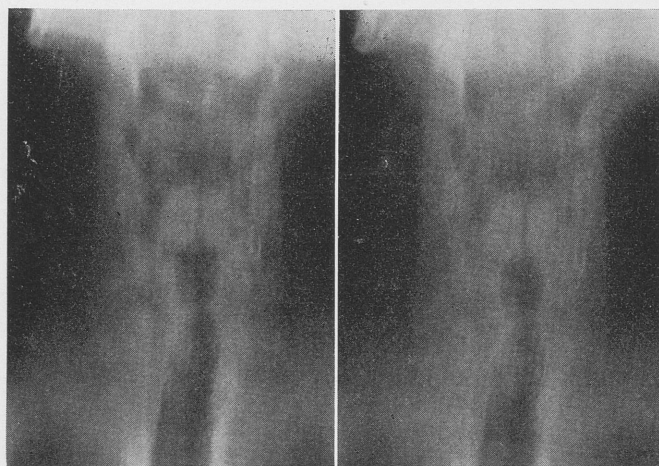


Fig. 3 (Case 5). Amyloidosis. Note focal narrowing of trachea about 3 cm below glottis.

Jaksch-Wartenhorst³ in 1923 had described a condition, termed "polychondropathy" by him, that was characterized by inflammatory changes in cartilages in different anatomic sites. Clinically, the usual sites of involvement are the cartilages of the external ear, the nasal septal cartilages, the larynx, and the tracheal bronchial tree. Cartilaginous involvement may occur simultaneously or at different times.

Even more interesting from an otolaryngologist's point of view are the audiovestibular manifestations of relapsing polychondritis. Daly⁴ described these in one patient, and Cody and Sones⁵ reviewed the records of 40 patients seen at the Mayo Clinic with relapsing polychondritis, among whom 11 had hearing loss due to the disease itself. The hearing loss may be either conductive or sensorineural.

The clinical picture in the acute phase is characterized by pain, swelling, redness, and tenderness of the external ear. The acute audiovestibular manifestations are those of tinnitus and dizziness; these are similar to the manifestations of endolymphatic hydrops of Ménière's disease or of Cogan's syndrome. With nasal involvement, the acute symptoms are pain, swelling, redness, and tenderness of the nose. Involvement of the tracheobron-

chial tree can lead to acute narrowing of the trachea with airway obstruction and possibly death. Ocular manifestations may also occur, including iritis, conjunctivitis, scleritis, and episcleritis.⁶

PATHOLOGY

Typically, inflammation causes fragmentation of the cartilage owing to necrosis and chondrolysis. In some areas, cartilage is separated by inflammatory cells; in others, cartilage is replaced by fibrous connective tissue.⁷

TREATMENT

In the acute phase, corticosteroids are of value; they may even be life saving, especially in cases with involvement of the tracheobronchial tree. Surgical intervention by "coring out" of the stenosed area and lining the area with skin or dilating it may or may not be necessary, depending on the degree of obstruction. A valved speaking tracheotomy tube is a useful compromise for those patients who do not want to undergo an operative procedure.

AMYLOIDOSIS

Case 5. A 54-year-old male complained of recurrent "colds" and progressive malaise. Despite normal results of a clinical otolaryngologic examination, tomograms of the trachea showed focal narrowing of the upper trachea at a point about 3 cm below the vocal

cords (Fig. 3). Bronchoscopic examination revealed a subglottic mass that, on biopsy, proved to be amyloid. Results of the general medical examination were normal and a rectal biopsy was negative for amyloid tissue. He did not require a tracheotomy.

Case 6. A 49-year-old female had a one-year history of hoarseness. She had recently complained of dysphagia and hemoptysis. Indirect laryngoscopy revealed subglottic and upper tracheal stenosis. Results of screening blood tests, including serologic studies, and the ESR were normal. Tomograms of the larynx and trachea showed localized narrowing in the subglottic area. Biopsy showed amyloidosis. Coring out of as much tissue as possible at the center of the mass resulted in a good airway and improvement in the voice.

COMMENT

The term "amyloid" (starchlike) was coined by Virchow, who noted that amyloid treated by iodine and sulfuric acid turned blue-black, as did starch. The respiratory tract is the most common part of the body to be affected by localized amyloidosis; in the respiratory tract, the larynx is the most frequent site. The disease occurs most commonly in the fifth, sixth, and seventh decades of life, and men are afflicted more frequently than women (ratio, 2:1). Symmers⁸ classified amyloidosis clinicopathologically as follows: 1) primary systemic amyloidosis not associated with known predisposing factors and affecting the heart, tongue, larynx, and skin; 2) generalized secondary amyloidosis usually associated with a predisposing disease, such as tuberculosis or lung abscess with empyema; 3) localized tumor-forming amyloid; and 4) amyloidosis associated with multiple myeloma.

In the larynx, the most common sites of amyloidosis are the ventricles, the false cords, the aryepiglottic fold, and the subglottic area, in that order.⁹ The treatment of amyloidosis consists of removing the amyloid tumor if it causes obstruction. Although localized amyloid tumors are rarely associated with plasma-cell dyscrasias, the appropriate studies probably should be done to exclude multiple myeloma or solitary myeloma.

SARCOIDOSIS

Case 7. A 55-year-old male had a history of stridor. Indirect laryngoscopy revealed a smooth, slightly reddened symmetric bulge in the subglottic area. Biopsy material, taken after a tracheotomy had been performed, revealed inflammatory tissue only. Five months later, the larynx was explored through a thyrotomy incision; the subglottic thickening was excised, and a skin graft was applied to the denuded area. Pathologic examination of the excised tissue disclosed noncaseous granuloma consistent with sarcoidosis. Cultures for microorganism were negative. Decannulation later was easy; the airway was good. He died in 1958 with carcinoma of the kidney.

COMMENT

In this patient, biopsy on several occasions did not reveal the granulomatous nature of the disease in the larynx. It was not until the subglottic thickening was removed at an open operation that the true nature of the lesion in the subglottis became known. If this problem had been known before the open operation, intralaryngeal injection of cortisone acetate perhaps would have made thyrotomy and skin grafting unnecessary.¹⁰ Judging from experience in this case, it is probably safe to excise as much of the offending tissue as necessary in order to improve the airway without fear that the operation will exacerbate the local disease.

WEGENER'S GRANULOMATOSIS

Case 8. A 45-year-old female gave a history of nasal obstruction for approximately three years. She had more recently complained of midfacial pain associated with nasal obstruction and bloody nasal drainage. Intranasal examination revealed crusting and granulation. Laboratory findings included the following: ESR, 80 mm in 1 hour (Westergren); hematuria; proteinuria, grade 3; and a normal chest roentgenogram. The histologic features of nasal biopsy material were consistent with those of Wegener's granulomatosis. She was treated with prednisone and cyclophosphamide and improved until she again presented with stridor three months later. Tomograms of the larynx showed definite narrowing of the upper trachea and subglottic area (Fig. 4). Direct laryngoscopy confirmed subglottic stenosis. Examination of the biopsy material revealed inflammatory tissue only. Her trachea was dilated at the same time and the condition of her airway was satisfactory thereafter. Therapy with

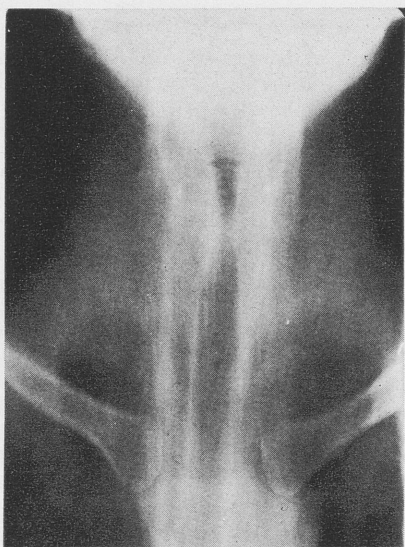


Fig. 4 (Case 8). Wegener's granulomatosis. Note narrowing of upper tracheal and subglottic areas.

cyclophosphamide and prednisone was continued; currently, she is doing well.

Case 9. A 50-year-old female required tracheotomy for upper airway obstruction. During a fissure operation, an ulcerative lesion involving the posterior two-thirds of the circumference of the trachea was excised; this lesion proved to consist of fibrous tissue only. The area was skin grafted, with a good result. At that time the ESR was 120 mm in 1 hour (Westergren), and hematuria was detected. Nearly two years later, she again presented with nasal pain, redness over the nasal dorsum, and nasal drainage but no diagnosis was then made. Then, six years later, she was found to have hemoptysis associated with a lesion in the right lung and also a nasal septal perforation with marked nasal atrophy and intranasal crusting. The diagnosis of Wegener's granulomatosis was made at that time by biopsy. The disease is currently controlled with steroids; the airway is satisfactory and the subglottis appears normal.

Case 10. A 53-year-old female had a five-year history of nasal crusting. Examination revealed an external saddle deformity, a large anterior cartilaginous septal perforation, and atrophy of both middle turbinates. Results of serologic studies were normal, as were the ESR and chest roentgenogram. She had noticed recent upper airway obstruction and she did have some degree of stridor. Indirect laryngoscopy revealed bulging of the tracheal wall below the cords with some impairment of the airway. Tomograms of the larynx and upper trachea showed no abnormalities. Laryn-

goscopy revealed extreme narrowing of the airway; it was almost impossible to pass an endotracheal tube through the subglottic region. The narrowing was due to a weblike thickening in the anterior subglottic region, a little more on the left than the right. The pink overlying mucosa was intact. Biopsied tissue consisted of inflammatory fibrosis only. Numerous pieces of tissue were also taken from the ethmoid area on both sides, around the septal perforation, and from the right maxillary antrum; histologic features of this tissue were consistent with those of Wegener's granulomatosis. Tracheostomy was unnecessary and no further treatment was started.

Case 11. A 24-year-old female, who was seen at the Mayo Clinic in 1973, had a history of removal of a left pseudotumor from the left orbit at the age of seven years, in 1956. In 1968 she had noticed the onset of dyspnea, which by 1970 had progressed to the point of acute airway obstruction that necessitated a tracheotomy, on which she continues to rely. Five repeated laryngoscopies had been done elsewhere and a biopsy report suggested the diagnosis of Wegener's granulomatosis. She had been treated with steroids and cyclophosphamide; she was receiving the latter when she presented at the Mayo Clinic.

Case 12. A 31-year-old female presented at the Mayo Clinic in 1972 with the following history: In 1956 a pseudotumor had been removed from the left orbit; she was treated with cortisone acetate. In 1960, the left eye was enucleated. She then had no symptoms for ten years when a pseudotumor developed in the right eye. The biopsy report on tissue taken from the right eye suggested the diagnosis of Wegener's granulomatosis. She was again treated with steroids. She was first seen in the Department of Otorhinolaryngology in 1970 with intranasal mucosal crusting, scales, and granulation tissue; the biopsy report gave a diagnosis of Wegener's granulomatosis. In 1972, she presented with a history of recurrent swelling of the right eye; at this point, she had stridor with hemoptysis. Indirect laryngoscopy revealed subglottic narrowing with a dry, crusty-looking subglottic mucosa. Narrowing was also revealed by tomograms (Fig. 5). Because of the adequacy of the airway, however, no biopsy was done and no treatment was considered necessary. She is now being observed for the diminishing vision in her remaining right eye.

COMMENT

These five patients with Wegener's granulomatosis who also had subglottic stenosis are part of a larger group of 52 patients with Wegener's granulomatosis seen at the Mayo Clinic whose cases were recently reported.¹¹

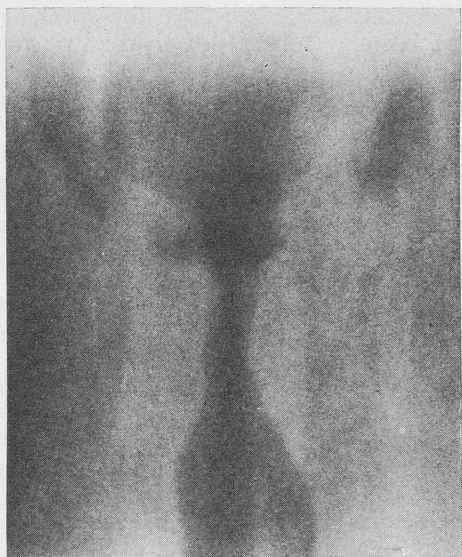

Fig. 5 (Case 12). Wegener's granulomatosis. Note subglottic narrowing.

PATHOLOGY

Wegener described the entity known as Wegener's granulomatosis in 1936¹² and again in 1939.¹³ It has since been identified as a disease characterized by necrotizing granulomas and vasculitis of the upper and lower respiratory tract, focal necrotizing glomerulonephritis, and systemic angitis. Among those patients who constituted the recent Mayo Clinic series, some were found to have necrotizing granulomas and vasculitis involving the respiratory tract, but without evidence of nephritis, and still others may have no evidence of involvement of the respiratory tract. This form of nonsystemic or localized Wegener's granulomatosis has been reported previously.¹⁴ Among the 52 patients whose records were reviewed, 31 patients had nasal lesions, either alone or in combination with other sites. The five patients with subglottic stenosis whose cases are described in the present report are among these 31 patients with nasal involvement.

Despite the finding of only fibrous tissue on biopsy from the subglottic area in these five patients, it is reasonable to speculate that the fibrous tissue actually represents the end result of an inflam-

matory lesion as part of Wegener's granulomatosis possibly modified by previous treatment. If any of these five patients could have been seen in a so-called acute phase, biopsy at that time might well have revealed the evidence of vasculitis and necrotizing granulomas.

TREATMENT

Wegener's granulomatosis is a treatable disorder; steroids with or without cyclophosphamide are the treatment of choice. Since airway involvement is common, it is essential that the otolaryngologist remain alert to the possibility of this condition, because favorable prognosis depends on early recognition and treatment.

DISCUSSION

Much remains to be learned about connective tissue disorders. Despite recent and promising advances, we still do not understand the phenomena precipitating the complex biochemical, immunologic, and anatomic changes that manifest as these diseases. Initially, these diseases may present with signs and symptoms that mimic numerous otolaryngologic disorders. For instance, one of our patients who proved to have amyloidosis complained of recurrent head colds and another patient complained of a voice change. The initial symptom of one of our patients with proved Wegener's disease was unilateral proptosis. Moreover, all of the 31 patients with nasal involvement who constituted part of the group of 52 patients with Wegener's disease reported on recently¹⁰ had "nasal obstruction" as the first and insidious symptom.

The clinician's obligation, therefore, when faced by a patient with subglottic stenosis of nonneoplastic, nontraumatic origin is to consider the stenosis as a possible manifestation of a systemic disorder. Consequently, a careful otolaryngologic examination is followed by a general examination, together with various investigations including chest and tracheal roentgenograms, a complete blood count, ESR, serologic studies, serum creatinine concentration, and urin-

alysis. Endoscopic examination of the larynx and trachea with biopsy then follows.

With respect to treatment, if systemic disease is proved, appropriate medication is initiated. The surgical management of the obstructed trachea depends not only on the nature of the lesion but also on the patient's wishes. For example, one of the patients with probable poly-

chondritis elected to have the speaking tracheotomy tube rather than an operation.

For small strictures with adequate airway, treatment may not be necessary. For others, endoscopic dilatation may suffice. The "coring out" of a long stenotic area followed by a skin graft is very successful and has advantages over resection and end-to-end anastomosis.

Request for reprints should be sent to Thomas J. McDonald, M.D., Mayo Clinic and Mayo Foundation, Rochester, Minnesota 55901.

REFERENCES

1. Djalilian M, Beahrs OH, Devine KD, *et al*: Intraluminal involvement of the larynx and trachea by thyroid cancer. *Am J Surg* 128:500-504, 1974
2. Pearson CM, Kline HM, Newcomer VD: Relapsing polychondritis. *N Engl J Med* 263:51-58, 1960
3. Jaksch-Wartenhorst R: Polychondropathia. *Wien Z Inn Med* 6:93-100, 1923
4. Daly JF: Relapsing polychondritis of the larynx and trachea. *Arch Otolaryngol* 84: 570-573, 1966
5. Cody DTR, Sones DA: Relapsing polychondritis: audiovestibular manifestations. *Laryngoscope* 81:1208-1222, 1971
6. Purcelli FM, Nahum A, Monell C: Relapsing polychondritis with tracheal collapse. *Ann Otol Rhinol Laryngol* 71:1120-1129, 1962
7. Kaye RL, Sones DA: Relapsing polychondritis: clinical and pathologic features in fourteen cases. *Ann Intern Med* 60:653-664, 1964
8. Symmers WSC: Primary amyloidosis: a review. *J Clin Pathol* 9:187-211, 1956
9. Leroux RJ: Tumeurs amyloides du larynx. *Ann Otolaryngol Chir Cervicofac* 79: 249-270, 1962
10. Devine KD: Sarcoidosis and sarcoidosis of the larynx. *Laryngoscope* 75:533-569, 1965
11. McDonald TJ, DeRemee RA, Kern EB, *et al*: Nasal manifestations of Wegener's granulomatosis. *Laryngoscope* 84:2101-2112, 1974
12. Wegener F: Über generalisierte, septische Gefässerkrankungen. *Verh Dtsch Ges Pathol* 29:202-210, 1936
13. Wegener F: Über eine eigenartige rhinogene Granulomatose mit besonderer Beteiligung des Arteriensystems und der Nieren. *Beitr Pathol* 102:36-68, 1939
14. Carrington CB, Liebow AA: Limited forms of angiitis and granulomatosis of Wegener's type. *Am J Med* 41:497-527, 1966

DISCUSSION

ALAN NAHUM, M.D. (San Diego, California): I have a comment about Dr. Dedo's very fine paper. A couple of years ago we presented several cases *vis-a-vis* this technique for nose bleed and we subsequently used it for angiofibroma. It is extremely effective for both techniques, but particularly for intractable nose bleed.

I would like to indicate, however, that we have had two cases of hemiplegia associated with the procedure; one was transient, occurring at the time of angiography; the second was relatively long lasting, occurring in a young boy on his dominant hemisphere and gradually regressed over a period of approximately two months.

We never did satisfactorily account for the

reasons, and, of course, with angiography there are other reasons besides the use of emboli, but I would urge people who use the technique to make careful observations about the methods that they use and, hopefully, we will accumulate some more information about this potentially very valuable technique.

J. RYAN CHANDLER, M.D. (Miami, Florida): It is a privilege to discuss that delightful presentation of Dr. Dedo. I have discussed the practicality and advisability of embolizing arteries in patients with nasopharyngeal fibromas and severe epistaxis with our neuro-radiologist. He is rather reluctant to do that for just the reasons that Dr. Dedo and Dr. Nahum told you.

I would like to suggest a practical alterna-

tive to embolization which we use in all of our cases of nasopharyngeal fibroma and intractable epistaxis and is a part of the operative procedure. An antrotomy provides access to the antrum, determination of the extent of the tumor in the maxillary sinus and the pterygomaxillary fossa before the transpalatal route is begun. If the tumor is in the antrum and in the pterygomaxillary fossa, the exposure which is necessary is already obtained. If the tumor is not there and one need not worry about it, then the internal maxillary artery can be ligated prior to beginning the actual extirpation of the tumor.

In our hands, this is a very satisfactory technical procedure which can be done at the time of surgery and decreases blood loss without the serious complications about which we have just heard.

JOHN DALY, M.D. (New York, New York): Dr. Dedo and his colleagues have developed and perfected a technique which, in their hands, is safe and I think for those who do not have this kind of neuroradiological setup, you might consider another technique.

With hypotensive technique you can accomplish the same results in control of the blood loss by dropping the blood pressure to between 40 and 60 systolic.

We have used this on well over a thousand cases without any of these complications. I think you have got to remember that if you do angiography, the incidence of untoward results is one in two hundred and that must be calculated. If there is a simpler way of doing it that is safe, then this is the best technique for you.

RICARDO TAPIA-ACUNA, M.D. (Mexico City, Mexico): I have had, as Dr. Kirchner said, enormous experience with this kind of tumor, juvenile angiofibroma.

I liked Dr. Dedo's paper very much but I do not agree with the utility of suppressing the irrigation of the external carotid artery, because in my experience we have not seen reduction of blood loss in this operation. As a matter of fact, I have seen cases in which both external carotids have been obstructed, and the bleeding has been increased.

I have described a technique I like very much (transpalatine incision) but I agree with Dr. Dedo that in some cases we have to use some other approach, such as lateral rhinotomy, or through the mouth. Sometimes the worst cases I see are those in which there are intracranial tumors. They are a real problem.

INJURIES TO THE NEONATAL LARYNX FROM LONG-TERM ENDOTRACHEAL TUBE INTUBATION AND SUGGESTED TUBE MODIFICATION FOR PREVENTION

ARTHUR S. HENGERER, M.D.

ROCHESTER, NEW YORK

MARSHALL STROME, M.D.

BURTON F. JAFFE, M.D.

BOSTON, MASSACHUSETTS

SUMMARY — Since the early 1960's nasotracheal tubes have been used for neonates with primary respiratory diseases which necessitated positive pressure ventilation. This therapy may be required for extended periods of weeks to months meaning prolonged trauma to the neonatal larynx. The initial injury and long-term effects of the endotracheal tube in this age group have not been adequately investigated. The acute findings can be arytenoid and posterior commissure ulcerations and, in some cases, cartilage erosion. Long-term follow-up in these children to age 3.5 years showed a persistent arytenoid defect with chronic hoarseness. The consideration of a change in the structure of the endotracheal tube is suggested as a possible means of avoiding these injuries.

The first reported use of the endotracheal tube was by McEwen in 1880.¹ Since then its use in anesthesia and for support in airway problems has become common. One group of patients who require intubation are the premature infants born with respiratory distress syndrome. They require assisted ventilation with positive end expiratory pressure (PEEP) to maintain adequate respiratory function. It is the purpose of this paper to discuss the acute injuries that result from the prolonged intubation in this neonatal group and to report on the chronic changes that persist in some of the surviving children.

METHODS AND MATERIALS

A group of 17 newborns admitted to the neonatal division of the Children's Hospital Medical Center in Boston for treatment of respiratory distress were used in this clinical study. A period of nasotracheal intubation

for the administration of positive pressure breathing was the only criterion used for inclusion in the study. In all cases 2.5 or 3.0 mm Portex tubes of the Magill shape were inserted, with no trauma, into the larynx. All the infants were classified as premature and suffered from respiratory distress syndrome. In addition, some had associated medical disorders.

Once a child was included in the study, he was followed until his discharge or death. After extubation, if any hoarseness persisted more than 24 hours, permission for a direct laryngoscopy without anesthesia was requested to assess the glottic and subglottic areas for injuries.

Three children with chronic hoarseness, who had required the above treatment regimen and were now one, two, and three and one-half years of age, underwent direct laryngoscopy to document the long-term changes.

The larynx from each child who expired and underwent an autopsy was removed and examined. The arytenoid cartilages were later removed and studied, using the dissection microscope.

From the University of Rochester School of Medicine, Rochester, New York, and Harvard Medical School, Boston, Massachusetts.

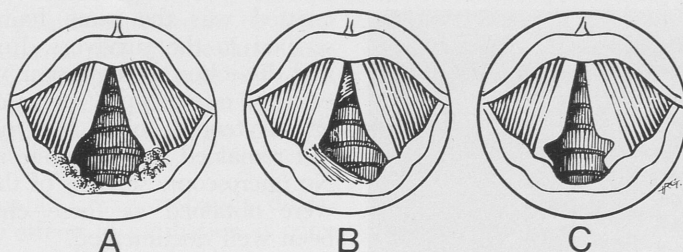


Fig. 1. Laryngeal findings of three patients in Group III: A) M.R. B) A.L. C) J.R.

RESULTS

The group of 17 infants can be separated into three distinct categories:

I. Surviving Short-Term Intubations. Five children were intubated for six days or less and when they were extubated had normal cries within 24 hours. Direct laryngoscopies were performed on three of these infants who had been intubated for three days and no abnormalities were found in the larynx.

II. Surviving Long-Term Intubations. This group is comprised of six infants who are survivors of long-term intubations. They are the most important subgroup in this study since four of these children manifest chronic laryngeal changes and hoarseness as a result of the treatment.

The first infant (M.R.) had Respiratory Distress Syndrome (RDS) and later manifested bronchopulmonary dysplasia which required intubation for 57 days with PEEP being used for 55 days. Aphonia was present for four days after extubation before he gradually developed a weak, hoarse cry that persisted until the time of a direct laryngoscopy at 2½ months of age (*i.e.*, 3 weeks after extubation). The operative findings showed granulations over the arytenoids with notching of the medial surface of the right arytenoid. There was fixation of the left true vocal cord from limited movement in the left cricoarytenoid joint. The subglottic area was normal (Fig. 1A). This child is now ten months of age and persists with a breathy cry that is slightly stronger than when he was examined.

The second infant (B.B.D.) with RDS is now six months old and was intubated for assisted ventilation with PEEP for a total of 38 days. Following extubation he required intermittent short term intubations for persistent bronchopulmonary dysplasia that has required continuous hospitalization. His cry

following extubation was moderately hoarse but has been gradually improving in strength. A direct exam was performed at 5½ months of age after his pulmonary condition had stabilized. However, only a brief exam was possible without anesthesia because of rapidly developing cyanosis secondary to his pulmonary disease. The findings showed a normal larynx with mobile vocal cords and no arytenoid notching or granulation tissue. No anatomic cause for his hoarseness was found and further assessment was deferred.

The third child (A.L.) is 13 months old and required intubation for 44 days with PEEP for RDS and a patent ductus arteriosus that was ligated. When she was extubated, she remained aphonic for two days before a weak breathy cry developed. The child was discharged from the hospital, however, before a direct exam could be performed. After one year her voice remained weak and breathy, and a direct laryngoscopy under general anesthesia was recommended. The exam revealed bilateral arytenoid vocal process erosion giving the appearance of bowing of the posterior half of the true cords, resulting in incomplete glottic closure on adduction and phonation. There was decreased motion of the right true vocal cord with no cricoarytenoid joint fixation, and a scar band that extended across the posterior commissure to join the left vocal process. In the subglottic area a thin fibrous band had formed on the anterior wall (Fig. 1B).

The fourth patient (J.R.) is now 3½ years old. At birth he had RDS which required a nasotracheal tube for 27 days for assisted ventilation. When extubated he was severely hoarse, but no direct laryngoscopy was performed. Since then he has had a slow growth and development and his voice remained breathy without signs of improvement. For this reason a direct laryngoscopy was performed under general anesthesia. The exam revealed marked grooving of the medial surfaces of both the vocal processes from previous cartilage erosion, allowing significant air escape with the cords in full adduction. The anterior commissure and membranous true cords plus the subglottic area were normal as was the cord motion (Fig. 1C).

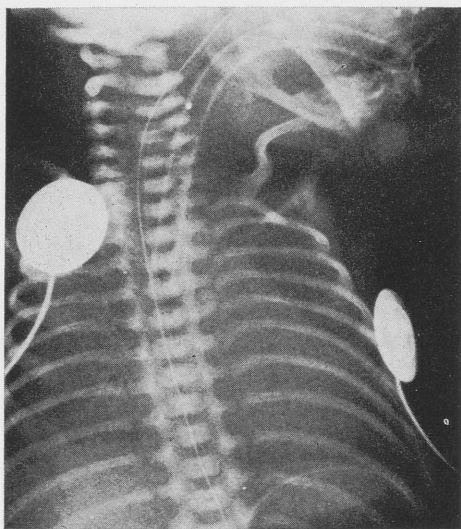


Fig. 2. X-ray of patient in supine position demonstrating lack of tube flexibility in laryngeal region.

The other two patients in this group were intubated for 15 days, respectively, and both had mild hoarseness when extubated. Now both are 18 months old, and one continues with mild inspiratory and expiratory stridor that is gradually improving. The second child is now asymptomatic. Neither of the children was examined, as their findings were disappearing with increasing age. This has been the usual finding in other studies regarding post-extubation hoarseness.

III. *Nonsurviving Intubations.* The remaining six children in the study expired during the neonatal period while still intubated and receiving assisted ventilation. Postmortem exams were performed on three of these patients, with the larynx removed for gross and microscopic examination. The first specimen was from a one-day-old infant intubated for 22 hours before death. The larynx showed no ulceration or erosion of the arytenoid vocal processes grossly, and minimal edema and reaction on microscopic sections.

The remaining two laryngeal specimens were from patients intubated 8 and 54 days, respectively. Grossly, both showed ulceration of the mucosa over the vocal processes and exposed cartilage which was grooved by erosion from the tube. The resulting glottic defect this

created was the same found and described in the survivors. Further exam and dissection of the larynx with the operating microscope revealed that the cricoarytenoid joints had not fibrosed but remained freely mobile and normal. No microscopic sections of the cartilages were obtained as these changes have been well documented.

The three remaining cases had no autopsy; thus, findings could not be established.

DISCUSSION

During the past ten years the methods and knowledge of the neonatologists treating RDS have resulted in an increasing number of healthy, surviving infants, including the low birth weight group.^{2,3} The usual criteria for using positive pressure ventilation in the treatment are a PaO₂ of less than 40 mm Hg in 100% oxygen and/or apnea or slow gasping inadequate respirations. In order to deliver the assisted ventilation, the uniform method has become tracheal intubation with a thin walled Portex tube either by the nasal or oral passage. Initially, tracheotomy is not used or recommended.

Once intubation is required, the treatment regimen follows a program outlined in neonatal texts to maintain normal blood gases and pH. The endotracheal tubes require changing about twice weekly to maintain a secretion free lumen, which can usually be carried out with a minimum of laryngeal trauma.

At this hospital, intubation continues until pulmonary function warrants tube removal. There were no long-term intubations who were considered for a tracheotomy to replace the tube. As a result the length of intubation via the nasotracheal route varied from 1 to 57 days in these 17 patients. In adults, as the duration of intubation increases, the potential for problems in the glottic and subglottic areas rises. Previous studies in the adult have shown that intubation for 48-72 hours is usually tolerated without significant tissue damage to the larynx, after which the significance of vocal cord

ulcerations, granulomas, webs, or stricture formation of the glottic and subglottic areas increase.⁴⁻⁶ Thus, the usual practice is conversion to a tracheotomy for continued airway assistance after 72 hours.

The neonatal larynx responds differently to the effects of intubation as compared to the adult larynx and, as a result, the recommended duration of neonatal intubation can be extended. The neonate is often intubated for periods of up to one week with no significant findings of laryngeal injuries. However, this initial seven days may represent only the first stage of an intubation that may last many weeks as occurred in the cases presented. It is in these patients with prolonged laryngeal irritation that the consequences of intubation can become manifest. At present no definite length of time for the development of the laryngeal injuries with persisting hoarseness has been determined, as in adults.^{3,6-9} The pediatric literature in general states that hoarseness immediately postextubation is associated with a normal direct laryngoscopy and virtually all the patients will have a normal cry by one month following extubation. This has not been the finding in the long-term intubations reported here.

It has been well established in the examination of postmortem specimens by Clement¹⁰ and animal studies by Way⁸ that the endotracheal tube rests in the posterior commissure of the glottis. The continuous pressure and tube movement due to PEEP and head motion causes changes to occur in the tissue of that area. The most marked finding has been ulceration and erosion of the medial surface of the arytenoid vocal process. There also may be thickening and granulation tissue formation of the interarytenoid region. It has been our experience with pathologic specimens, as well as surviving patients, that these changes occur in a significant number of neonates and do not always resolve completely as previously suggested.

The patients presented who remained hoarse after one year had significant

laryngeal changes resulting from the neonatal period. These chronic changes as previously mentioned are located primarily in the posterior commissure and arytenoid region. In the four children with persistent hoarseness from six months to 3½ years postextubation, the consistent finding has been the residual grooving defect of the vocal process, leaving an incomplete glottic closure. One of these patients also had unilateral vocal cord paralysis with a mobile arytenoid, and another had unilateral arytenoid fixation. Both these problems were thought to be due to the prolonged intubation, but a congenital anomaly is still a possible explanation.

Although there was gradual improvement in the cry and voice production with increasing age, it was not completely normal in any of the long-term follow-ups that had been aphonic or severely hoarse at extubation. Thus, it appears that the degree of hoarseness at extubation may be an indication of the present damage and the future rate of recovery. If the patient is aphonic when extubated, the chance of finding significant laryngeal changes and long-term hoarseness is likely. Milder degrees of hoarseness show no significant laryngeal changes and tend to have faster and complete recovery. However, the duration of the intubation cannot be used as the lone indicator of what the eventual degree of injury and resulting voice production will be. The patient now 3½ years old who was intubated for 27 days still has a breathy voice with poor volume, while another intubated 38 days had less severe hoarseness at extubation and is showing steady improvement. In one study⁶ of 57 infants (with 19 intubated longer than 72 hours), normal cries were present in all by one month postextubation although no mention was made of the sound of their cries initially. Another article³ reported 2 of the 22 patients who were intubated for 11 and 45 days, respectively, were aphonic at extubation. Both these patients had direct laryngoscopy performed while neonates and the operative findings were reported as normal. Their hoarse-

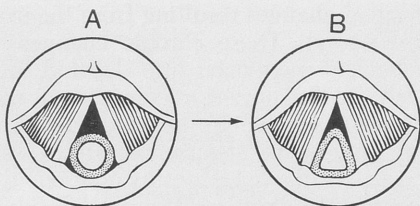


Fig. 3. Illustration of suggested tube change to decrease arytenoid pressure and ulceration.

ness had gradually cleared over a four-year period although the report did not say they now had normal voices. It is too early to say whether the group of patients we have followed will have the same successful recovery rate when they were aphonic or severely hoarse at extubation. The findings indicate that unless aphonia exists at extubation a direct laryngoscopy is not necessary, and the likelihood of a normal voice before one year of age can be anticipated. If aphonia is present after extubation, a direct exam should be performed when convenient to document the expected arytenoid changes so that the family can be advised that long-term voice problems are likely.

The complications from endotracheal tubes has been extensively analyzed, and the following causal factors were found: 1) The tube used has a gradually curving shape known as the Magill Design. This shape results in significant pressure on the posterior commissure from the weight of the tongue resting on the tube. Neck flexion also increases the posterior coiling of the tube against the posterior glottis in the supine patient. The tube wall stiffness can decrease the ability of the tube to bend and conform to the natural curves of the hypopharynx and larynx adding additional pressure (Fig. 2). 2) The posterior commissure and arytenoid area is a triangular anatomic space that is filled with a round tube. This inappropriate matching of shapes subjects several areas in the larynx to injury, especially the vocal processes of the arytenoids and the midline of the posterior commissure (Fig. 3). This effect is verified by the round grooves found in

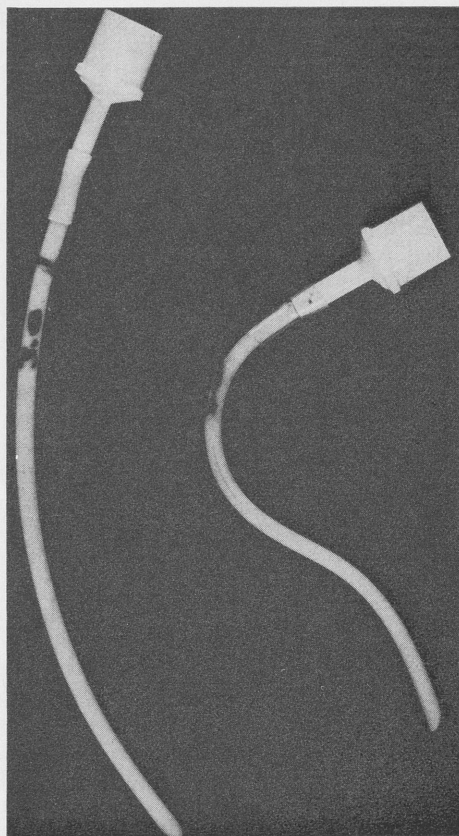


Fig. 4. Portex uncuffed endotracheal tubes, 3.0 mm. Left: Magill design in common use. Right: same tube with constant reverse curve alteration.

the vocal processes that lead to the incomplete glottic closure and breathy voice. 3) The usual method used in choosing the tube size may cause a problem. The size selected must easily pass through the glottis or be one size smaller in hopes of decreasing the degree of pressure.¹¹ The size of the tube has definitely been shown to influence the inflammation and eventual arytenoid ulceration.⁸ However, in clinical practice the neonates usually require PEEP, and the resulting positive pressure is more effective if a fairly tight seal is created at the glottis. This is easily obtained by inserting a slightly larger tube than needed, which enhances the possibilities for irritation and ulceration.

These factors have led to the consider-

ation of making two alterations in the shape of the present endotracheal tubes: 1) Change the shape of the tube from round to triangular over a 2 cm length that passes through the larynx, in an attempt to decrease the grooving of the vocal process. This change can be added to the present Magill design without affecting the ease of intubation or significantly decreasing the airway. 2) Add a reverse curve to the tracheal end of the present Magill tubes as described by Clement, *et al* in 1949¹⁰ (Fig. 4). This change will permit the tube to conform more easily to the usual anatomic shape of the hypopharynx, thus resulting in less posterior laryngeal pressure that creates the chronic glottic defects. The latter alteration does have a drawback in that a stylet will be needed for insertion, making the intubation more difficult and increasing the possibility of laryngeal injuries if used improperly. For this reason this tube should not be considered for use in the initial stages of intubation but reserved for the latter stages of the long-term patients when the chronic injuries are likely. The incorporation of the triangular design into this new tube, plus all the presently used Portex tubes, may be of value. As yet no clinical experience has been obtained with the above described tubes, but future trials are planned.

CONCLUSIONS

During the past decade an increasing number of premature infants have survived because of diligent treatment and

frequent use of respirators and endotracheal tubes. Although this management is becoming more successful, it is resulting in an increasing number of infants with potentially long-term laryngeal defects that to date have not been stressed. At present there is no definite means of preventing all these complications if we are to preserve life. However, the following regimen modifications could be used to decrease these complications: 1) The most important is the use of as soft and as small a tube as possible to minimize the glottic pressure. Taping the tube securely to limit the piston action transmitted from the respirator will also decrease the creation of ulcerations. 2) Adequate hydration to help prevent drying of the secretions in the tube and the membranes adjacent to it is necessary.¹²

In addition to these precautions, one should observe the sound of the cry while changing the tube, and if significant hoarseness or aphonia is noted, a smaller diameter tube (or eventually the alternative tube described in this paper) should be inserted.

No standard time interval for such a change can be given, but it will depend on each patient and the response of the patient's tissues to the intubation. The point to be stressed is that long-term intubation in the neonate is not innocuous. The above factors require constant supervision to avoid the chronic laryngeal injuries and breathy voices that can persist in some infants and children.

Request for reprints should be sent to Arthur S. Hengerer, M.D., The Rochester Otolaryngology Group, P.C., 1641 East Avenue, Rochester, N. Y. 14610.

REFERENCES

1. McEwen, cited by Dwyer CS, Krownberg S, Saklad M: The endotracheal tube: a consideration of its traumatic effect with a suggestion for the modification thereof. *Anesthesiology* 10:714-728, 1949
2. Harrod JR, L'Heureux P, Wangenstein OD, *et al*: Long term follow-up of severe respiratory distress syndrome treated with IPPB. *J Pediatr* 84:277-286, 1974
3. Johnson JD, Malachowski NC, Grobstein R, *et al*: Prognosis of children surviving with the aid of mechanical ventilation in the newborn period. *J Pediatr* 84:272-277, 1974
4. Stetson JB: Prolonged endotracheal tube intubation. *Brit J Anesth* 40:712-713, 1968
5. Schlorf RA, Duvall AJ: Post intubation granulomas of the larynx. *Minn Med* 52:717-720, 1969
6. Lindholm C: Prolonged endotracheal intubation. *Acta Anesthesiologica Scand* 13: (Suppl 33) 1-125, 1969

7. Coppel DL, Bennett EJ, Ahlgren EW, *et al*: The prophylactic use of a nasotracheal tube in infants under three months of age. *Surgery* 69:354-359, 1971
8. Way WL, Sooy, FA: Histologic changes produced by endotracheal intubation. *Ann Otol Rhinol Laryngol* 74:799-811, 1965
9. Davenport HT: Prolonged endotracheal intubation in children — A perspective. *Int Anesthesiol Clin* 8:909-924, 1970
10. Dwyer CS, Kronenberg S, Saklad M: The endotracheal tube: A consideration of its traumatic effects with a suggestion for the modification thereof. *Anesthesiology* 10:714-728, 1949
11. Slater EA: Endotracheal tube sizes for infants and children. *Anesthesiology* 16:950-961, 1955
12. Fearon B, MacDonald RE, Smith C, *et al*: Airway problems in children following prolonged endotracheal intubation. *Ann Otol Rhinol Laryngol* 75:975-986, 1966

CLEFT LARYNX

A REPORT OF SEVEN CASES

SEYMOUR R. COHEN, M.D.

LOS ANGELES, CALIFORNIA

SUMMARY — The purpose of this paper is to familiarize the otolaryngologist with a difficult and frequently missed anomaly. It is hoped that this will increase the number of successfully managed patients with this affliction. Of the seven herein reported cases, four were posterior clefts limited to the cricoid lamina. Three were more extensive laryngotracheoesophageal clefts. Seven cases are thus added to the approximately 30 cases reported in the world literature. The limited cricoid lamina defect can only be diagnosed by endoscopic examination, and is treated medically. Feedings must be given by gastrostomy only. A tracheotomy is indicated only when oral secretions are aspirated into the tracheobronchial tree. The more extensive laryngotracheoesophageal cleft requires surgical repair through a lateral pharyngotomy approach. When the cleft is extensive and extends into the chest, surgery must include a thoracic approach. The occurrence of cleft larynx in association with tracheoesophageal fistulae, with or without atresia, may be more frequent than generally realized. A search should be made for this anomaly in patients who aspirate after atresia repair has been accomplished, before attributing this symptom to severe stricture formation, or recurrence of the fistula. The problem of aspiration in posterior cleft larynx is due to the lateral and posterior displacement of the arytenoids. This malposition is due to the absence or deficiency of the interarytenoidius muscle so that the posticus muscle is unopposed. The term "posterior cleft larynx" should be used only where the defect is limited to the cricoid lamina, while laryngotracheoesophageal cleft should be applied to the more extensive defect.

While laryngotracheoesophageal cleft is an uncommon anomaly, partial clefts limited to the cricoid lamina would appear rare. A review of the literature reports very few cases of posterior cleft larynx. Only 2 or possibly 3 of approximately 30 reported laryngotracheoesophageal clefts were limited to the larynx. Since the more extensive cleft is incompatible with life unless surgically repaired, the assessment of its occurrence in the general population may statistically be more accurate by clinical, surgical, or autopsy reports. Posterior cleft limited to the larynx is an anomaly compatible with life. Its occurrence, therefore, cannot be truly evaluated, since with careful medical management and with growth and development of the child, symptoms of this anomaly usually completely subside.

Since Shapiro and Falla reported the second successfully treated case of laryngotracheoesophageal cleft in 1966,¹ the number of reported cases of this anomaly has increased rapidly. Of the 30 reported cases, only 7 or 8 have been repaired successfully. This paper will deal with four cases of partial clefts, or posterior cleft larynx, without evidence of tracheoesophageal defect, and will also add three cases of laryngotracheoesophageal clefts which were repaired surgically. Two of the surgically treated children are alive, and the third, the first case seen by the author in 1962, succumbed from inadequate surgery done after central nervous system and lung damage had occurred. In all cases the diagnosis was made by endoscopic evaluation.

From the Division of Otolaryngology of the Children's Hospital of Los Angeles, University of Southern California, School of Medicine, Los Angeles, California.

CLINICAL PICTURE

The chief presenting symptoms of a cleft larynx is aspiration, usually associated with some voice change. Where the defect is large and includes the tracheoesophageal septum, aspiration of secretions, especially when oral feedings are attempted, causes severe choking and cyanosis, followed by x-ray evidence of aspiration pneumonitis. When the cleft involves only the cricoid lamina, endogenous secretions may be handled fairly well, but feedings, being only liquids in the neonate, will produce choking and associated airway obstruction from aspirated secretions, and severe pneumonias. When solid or thickened feedings are added, they do not produce choking or aspiration.

While voice change is usually notable, it may not be severe enough to be clinically evident. Stridor, unless other lesions are present, is usually of the expiratory type, and is due to tracheobronchial obstruction from aspirated secretions. Laryngeal obstruction has not been a prominent presenting symptom in the cases herein reported.

Chest x-rays early show aspiration-type pneumonic infiltrates and hyperaeration. The cine-esophagram, best carried out by swallowing rather than injection through an indwelling catheter, will usually show spilling of contrast medium into the trachea, frequently interpreted as dyskinesia of swallowing. The study may be negative unless carefully performed.

The endoscopic examination must be depended upon to make the definitive diagnosis. While the literature indicates problems in diagnosis by either laryngoscopy, bronchoscopy, esophagoscopy, or by a combination of these procedures, failure to diagnose the lesion is due to inexperience or failure to observe what may be very esoteric changes within the larynx. This unusual anomaly and its extent cannot be diagnosed in any other way except by direct visualization.

DIFFERENTIAL DIAGNOSIS

Differential diagnosis of aspiration problems in the neonate is complex and involves many medical disciplines.

Central nervous system lesions associated with prematurity, abnormal development, hypoxia, or birth trauma may produce evanescent or permanent defects of the swallowing mechanism. Anatomic defects of the nose, nasopharynx, larynx, or esophagus and trachea, and laryngeal paralysis may produce aspiration by impairing the normal mechanism of deglutition. Diseases of the esophagus, such as cricopharyngeus spasm or patulous cricopharyngeal sphincter, non-sphincteric spasm of the esophagus, cardiospasm, or strictures, may produce aspiration. The latter are readily diagnosed by x-ray studies. Neuromuscular disorders such as myesthesia gravis, amyotonia congenita, and autonomic dysfunction of Riley-Day, must always be considered in aspiration problems. Prior to endoscopy, therefore, the pregnancy and birth history should be known. A complete physical examination including the neurological status of the patient should be performed. X-ray studies of the chest and of the swallowing mechanism with barium or other contrast media, followed by very careful endoscopic examination of the larynx, tracheobronchial tree, and esophagus, will yield the highest success rate in definitive diagnosis.

EMBRYOLOGY

One of the most important functions of the larynx is protection of the airway from foreign material. Any defect which prevents spasmodic closure of the larynx will produce severe dysfunction resulting in aspiration pneumonitis and failure to thrive. Since a cleft which involves the larynx alone or in conjunction with a defect of the tracheoesophageal septum can be a major problem resulting from faulty development of the larynx, it is appropriate to repeat the normal embryological development of this organ and indicate the abnormalities which result in this cleft type anomaly.²⁻⁵

Of primary interest in the developmental anatomy of the larynx are the visceral arches 3, 4, 5, and 6. The respiratory primordium, which will give rise to the larynx, trachea, and bronchi, starts as a ventromedian diverticulum of the foregut caudal to the pharyngeal pouches. The tracheobronchial groove appears in the 3 mm embryo at approximately 25 days. Lateral furrows develop on each side of the diverticulum, along the line of union of the groove and esophagus. As the furrows become deeper, eventually to join, the laryngotracheal tube is formed. The anterior and cranial bud of the tube develops into the primitive laryngeal additus or slit. The slit appears at about the 4 mm stage, and comes to be more definitely formed between the fourth and sixth branchial arches. The caudal end develops into the lung buds. Also, during this stage, the margin of the laryngotracheal groove begins to fuse in a caudocranial direction to form the tracheoesophageal septum. This separates the laryngotracheal tube from the esophagus.

During the fifth and sixth weeks, the laryngeal additus, or slit, is altered by the growth of the masses which are the primordia of the epiglottis (arches 3 and 4) and the two swellings of mesenchymal tissue that are the anlage of the arytenoid cartilages (arch 6) which, approximating each other medially, move towards the base of the tongue. This adds a transverse component to the top of the sagittal slit, and the additus becomes T-shaped. At the fifth to sixth weeks stage, the tracheoesophageal septum has developed to at least the first tracheal ring and the level of the future fusion of the posterior lamina of the cricoid cartilage. If the rostral advancement of the tracheoesophageal septum is arrested, preventing the dorsal fusion of the cricoid cartilage, a laryngotracheoesophageal cleft will result.³

Since the cricoid cartilage first develops as bilateral centers of cartilage fusing ventrally at about six weeks and

dorsally at about seven weeks, the pathogenesis of the dorsal cleft will probably be found at the 9 mm stage. This cleft should not be confused with the large interarytenoid notch which persists even into the stage of three-month embryos.

The muscles of the larynx depend for their differentiation on the development and growth of the cartilage. The first muscle to develop into a recognizable form is the interarytenoid muscle which arises from the sixth arch at the 9 mm stage. Also, at this stage, the anlage of the cricoarytenoid muscle is visible. In clefts of the larynx, the interarytenoid notch remains deep, and the interarytenoid and posticus muscles are defective. It is apparent from the cases reported that failure or defects of posterior cricoid fusion may be an isolated defect not dependent on progression of closure of the tracheoesophageal septum.

CASE REPORTS

Case 1. A Caucasian female infant born on June 28, 1962, was admitted to the Children's Hospital of Los Angeles at six weeks of age. She had been treated elsewhere for pneumonia, with oxygen, penicillin, and Declomycin®.* The infant was suspected of having a tracheoesophageal fistula without atresia and was transferred for therapy. X-rays of the chest revealed displacement of the mediastinum to the right and diffuse infiltration of the right lung. A barium swallow showed barium to be present in both bronchi (Fig. 1).

The family history is sketchy since the mother had numerous marriages and divorces, and the infant had been put out for adoption. She was a product of a seven-month gestation, with a normal delivery, weighing 2.04 kg at birth. There was no distress immediately after her delivery, with no jaundice and no cyanosis. The infant was noted to cough and turn blue with her first feeding, and this was repeated after each attempt at oral feedings. She had recurrent aspiration pneumonias.

*Lederle Laboratories, Pearl River, N. Y.

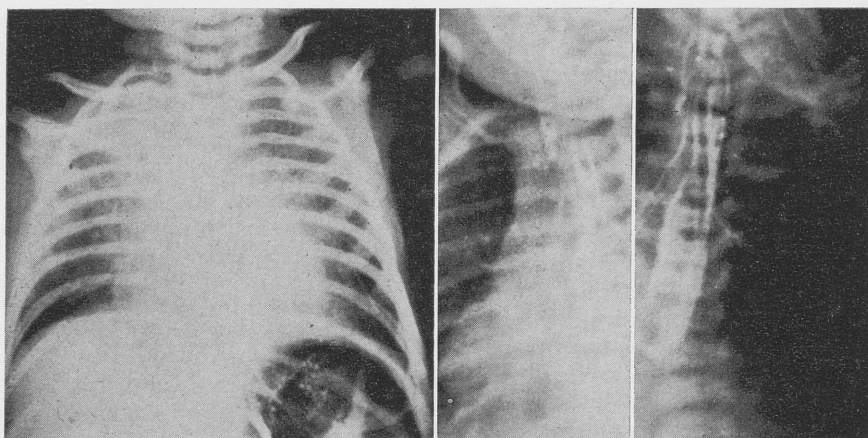


Fig. 1. Aspiration pneumonia with Barium esophagram showing high overflow of contrast medium into the trachea and esophagus.

On admission, the findings were relatively normal except for crackling rales in the right upper lung field, with no evidence of cardiomegaly or neurological deficit. With antibiotics she showed some improvement, and a gastrostomy was performed for feeding purposes. Additional studies with contrast media did not show evidence of a tracheoesophageal fistula. A feeding gastrostomy had been done, and while the infant had been admitted on August 9, 1962, endoscopic consultation had not been obtained until August 22, 1962. Direct laryngoscopy revealed the larynx to be defective posteriorly. In addition to the cricoid defect, the arytenoids were noted to hang from their anterior attachments like elephant ears. The larynx and esophagus could be examined through this defect at the same time, and a tracheoesophageal defect was noted.

On August 31, 1962, a tracheobronchogram was performed which showed a high division of the trachea in the neck, with an anomalous left mainstem bronchus (Fig. 2). Following bronchoscopy and the clearing of all secretions, she improved tremendously. She continued to have difficulty with secretions, and on September 7, 1962, after numerous episodes of apnea requiring artificial

resuscitation, a tracheotomy was performed.

Immediately after tracheotomy, the child gradually improved, having fewer episodes of respiratory difficulty. Attempts to close the cricoid defect by injecting Teflon®* into the area were unsuccessful. Because of repeated apneic spells and failure to thrive, on July 24, 1963, a laryngofissure was performed, and closure of the large laryngotracheoesophageal cleft was attempted. Her immediate postoperative course was uneventful, but on the third postoperative day she expired. Autopsy diagnosis was chronic interstitial pneumonia, tracheostomy, jejunostomy, congenital anomaly of the larynx and upper trachea, secretory inactivity of the adrenals, atrophy of the thymus, and acute bronchopneumonia.

The chief autopsy findings were limited to the larynx and lungs. The larynx was in normal position. On opening the esophagus posteriorly, a long, narrow defect (1.3 X 0.3 cm in size) of the posterior wall of the larynx and upper tracheoesophageal septum was noted. The larynx and esophagus communicated freely. The defect was located in the midline of the posterior wall, from the ligaments connecting the corniculate

*Ethicon Laboratories, Somerville, New Jersey.

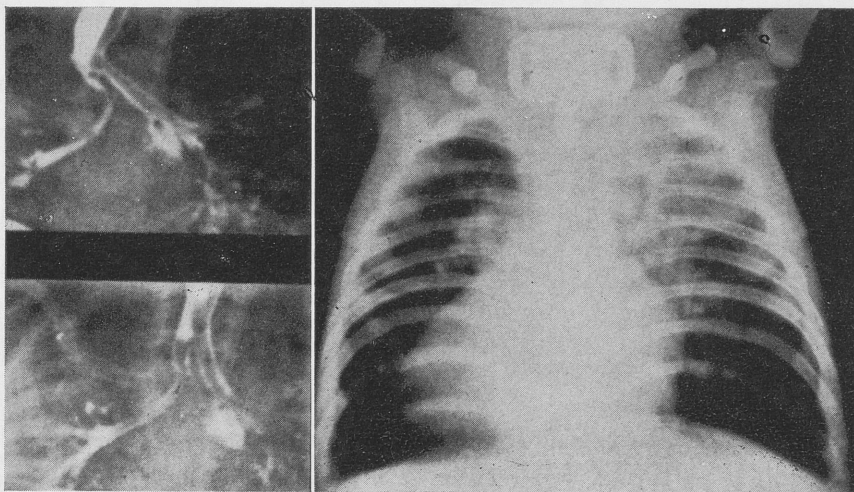


Fig. 2. Tracheobronchogram showing the trachea bifurcates in the neck and defective bronchi.

cartilages, extending downward through the ligaments connecting the arytenoid cartilage to the posterior portion of the cricoid cartilages. Silk sutures were seen in the margins, but the cleft was wide open, and the larynx and esophagus communicated freely through the defect. The vocal cord was not abnormal, and the larynx showed no evidence of stenosis or obstruction.

Case 2. An infant born on April 25, 1968, was admitted to the Children's Hospital of Los Angeles on March 10, 1969. The chief complaints were failure to thrive and recurrent pneumonia. The infant was a product of a nine-month gestation in a para 5 gravida 5 mother. Pregnancy was complicated by recurrent respiratory infections and dependent edema, and polyhydramnios. The infant breathed spontaneously but could not cry. She weighed 3.2 kg at birth. Because of difficulty in feeding and problems with oral secretions, the child was tube fed. At two months of age she had meningitis, and at three months of age she had a staphylococcal pneumonia. A second episode of pneumonia occurred at six months of age, and her third episode occurred at eight months of age. She had been treated for all these illnesses prior to her transfer. Noted on the

chart was, "Has difficulty catching breath when drinking liquids. Occasionally will choke on her food." Her general development was slower than normal. Examination on admission showed an alert, but very thin and pale child, with a high pitched wheezing cry. She weighed 6.2 kg. There were suprasternal and substernal retractions, with an audible wheeze. The cry was weak, and there was a to-and-fro wheeze. The abdomen was soft, full, and protuberant. The impression was recurrent pneumonia of undetermined origin. Another esophagram still showed no evidence of abnormality, and a sweat chloride was found to be normal. An H-type tracheoesophageal fistula was suspected.

On March 12, 1969, direct laryngoscopy, bronchoscopy, and esophagoscopy revealed an H-type tracheoesophageal fistula. In addition, the laryngeal picture was one of an unusual anomaly. The arytenoids were displaced anteriorly, and on closure of the larynx there was a patent posterior cleft. The posterior cricoid lamina appeared abnormal. Interarytenoid closure was faulty (Figs. 3 and 4). On March 19, 1969, the tracheoesophageal fistula was closed. The child was discharged in good condition on April 12, 1969.

Direct laryngoscopy on May 7, 1973, showed the larynx to be normal other than the partial posterior cleft of the larynx. The vocal cords moved normally, and the posterior aspect of the larynx was elongated because of failure of fusion of the entire arytenoid to the cricoid cartilage. The cleft appeared to be well compensated for, and closure of the larynx was seen to be excellent. This patient's followup has been one worthy of note. She has had no problems feeding, no recurrent fistulae, no pneumonitis, and her development and growth has been excellent.

Case 3. A white male infant was admitted at five hours of age on April 22, 1969. He was the second of twins born by a delivery complicated by premature rupture of membranes. The amniotic fluid was meconium stained. Soon after birth, the child was noted to have marked increase in oral secretions. An esophagram showed a blind upper esophageal pouch, and he was transferred to the Children's Hospital of Los Angeles. The upper pouch was much narrower than is usually seen in atresia, and he was suspected of having an associated tracheoesophageal fistula with the upper pouch as well as the usual lower pouch fistula. Immediately after the infant was admitted to the hospital, a gastrostomy was performed under local anesthesia. At a later date, a small amount of contrast medium was introduced into the upper esophageal pouch, and the material was noted to immediately spill into the trachea. The significance of this was not recognized until the patient had undergone direct laryngoscopy and bronchoscopy on April 28, 1969, at which time a laryngotracheoesophageal cleft was visualized.

After treatment for seven days for pneumonitis, surgical correction of the esophageal atresia was performed. At thoracotomy, atresia with continuity of the esophageal muscle associated with two tracheoesophageal fistulas was found. The distal esophageal fistula and a fistula from the upper esophageal segment were interrupted, and an end-to-

end esophagoesophagostomy was performed.

The postoperative course was complicated by right upper lobe atelectasis and episodes of respiratory distress. Two weeks after the operation, esophageal dilatations were begun, but because of repeated difficulties with aspirated secretions, a tracheostomy was performed four weeks after the thoracotomy.

On June 28, 1969, when the infant was nine weeks of age and weighed 3 kg, the laryngotracheoesophageal fistula was repaired by a lateral pharyngotomy route. The larynx was rotated anteriorly, and the cleft which extended through the cricoid cartilage and inferiorly through the third tracheal ring was repaired. The margins of the cleft were split and a double layer closure with 6-0 silk sutures was performed. The cleft was repaired to the level of the arytenoids. The larynx was replaced in its normal position, and the esophagus was then closed with interrupted silk sutures. The wound was drained and the skin was closed. The infant's postoperative course was uneventful, and feedings were continued via the gastrostomy, until healing occurred.

Direct laryngoscopy and esophagoscopy on October 8, 1969 (Fig. 5), revealed that closure of the tracheoesophageal cleft was complete, but another tracheoesophageal fistula was found immediately below the repaired cleft. Two weeks later, through a vertical cervical incision, the fistula was interrupted at its location at the level of the fourth tracheal ring. Again, the postoperative course was uneventful, and two weeks after the last surgery, direct laryngoscopy revealed closure of the cleft was intact. Oral feedings were begun, and esophageal dilatations were resumed.

The child was discharged from the hospital on January 3, 1970, at 8½ months of age, weighing 5.1 kg. Since then he has had regular esophageal dilatations for a narrowed anastomotic esophageal site, and repeated bronchoscopies for correction of lower tracheal

and bronchial stenotic lesions. To the date of this writing, he still wears a tracheotomy tube, has developed normally, eats and drinks without choking, and it is anticipated that the tracheotomy tube will be removed when it is no longer necessary for tracheobronchial toilet after correction of the bronchial stenotic lesions.⁶

Case 4. A white male infant born November 11, 1969, was admitted to the Children's Hospital of Los Angeles on the sixth day of age. He was the product of a forty-five week gestation of a twenty-four-year-old gravida 2 para 1 mother. Membranes had ruptured at thirty-eight weeks, with leakage of fluid. There was no history of fever, labor was eight hours in duration, and delivery was by Frank breech presentation. The child cried weakly at birth, and weighed 2.4 kg. His Apgar was 8, with slight cyanosis and some respiratory difficulty. He was admitted with a diagnosis of atresia and tracheoesophageal fistula.

On November 17, the day of his admission, a gastrostomy was performed. On November 21, the esophageal atresia was corrected, and the tracheoesophageal fistula was interrupted. Leakage occurred at the site of anastomosis, with episodes of apnea and some cyanosis on attempts to feed him. This was thought to be due to strictured esophagus.

On December 22, 1969, direct laryngoscopy was performed and a posterior cleft of the larynx was found (Fig. 6A, B, C). On December 30, 1969, a tracheotomy was performed after the child required intubation for an apneic spell. Bronchoscopy performed at that time showed lower tracheostenosis and severe bronchial stenosis.

Following the tracheotomy, the child improved gradually and steadily. He was discharged from the hospital on January 28, 1970, and to this date, he still has a tracheotomy tube for the purpose of tracheobronchial toilet. Repeated bronchial infections secondary to a stenotic trachea and left mainstem bronchus

have required intensive antibiotic therapy. His most recent bronchoscopy revealed improvement in the status of the tracheobronchial tree, and it is anticipated that he will be decannulated soon. He eats and drinks normally, except when gulping liquids, which causes coughing.

Case 5. A white female infant was transferred to the Children's Hospital of Los Angeles on April 19, 1973, with the history of laryngeal obstruction. She was the product of a full term pregnancy, whose mother was a gravida 4 para 3. Labor was two hours, and delivery was accomplished with pudendal anesthesia. The Apgar was 5 at one minute without any spontaneous respirations. The patient was intubated in the delivery room, and remained pink after the tube was placed into the trachea. She then breathed without difficulty. The cry was extremely weak, and the larynx was noted to be abnormal. On admission to the Children's Hospital of Los Angeles, a nasotracheal tube was noted to be in place, and her examination, other than rhonchi in both sides of the chest, showed no evidence of abnormalities. An x-ray showed the endotracheal tube to be in place, and there was a right-sided pneumonic infiltrate.

On April 20, 1973, laryngoscopy and bronchoscopy were performed, and a cleft larynx with severe stenosis of the larynx and trachea were noted. The arytenoids were seen to be extremely edematous, and the endotracheal tube was seen to pass through a laryngotracheoesophageal cleft into the trachea. The immediate subglottic and upper trachea were severely stenosed, and a tracheotomy was performed on April 23, 1973. X-rays showed a normal esophagus without evidence of stricture. A gastrostomy was performed on April 24, 1973, and feedings were given with the infant gaining and doing well. The final diagnosis after endoscopy was laryngotracheal esophageal cleft with stricture of the esophagus. The esophagoscope could not be passed into the esophagus,

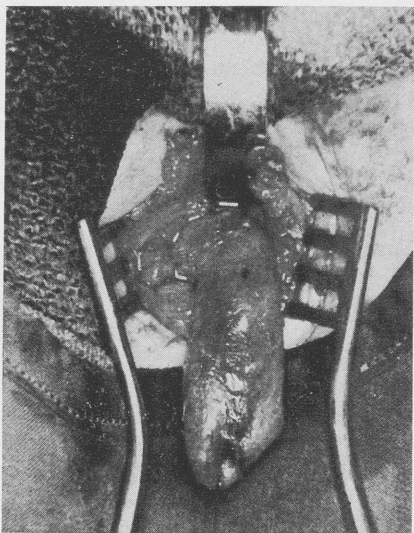


Fig. 7. Shows large diverticulum of esophagus which when opened revealed large laryngotracheoesophageal cleft.

and with a bronchoscope the cleft was seen.

On August 23, 1973, exploration of the neck showed a large esophageal diverticulum (Fig. 7) and a laryngotracheal esophageal cleft, and closure was accomplished. Her postoperative course was uneventful. An esophagram showed minor leaking of barium over the larynx but oral feedings were taken well. On October 3, 1973, she was discharged from the hospital and has returned periodically for esophageal and laryngeal

dilatations. The laryngeal and upper tracheal stenosis was partly congenital and partly secondary to closure of the large tracheoesophageal cleft. On April 29, 1974, the gastrostomy was closed. The child eats and drinks well without aspiration. Her weight gain and development have been normal. It is anticipated that she will require a tracheostomy for a prolonged period of time and will return to the hospital for dilatations of the larynx and trachea.

Case 6. A three-year, six-month-old female Caucasian was first seen by the author on September 4, 1974, for closure of a persistent tracheocutaneous fistula. This child, birth date March 20, 1971, was the second born of a normal pregnancy and uneventful delivery, weighing 3 kg. From the first day, feeding was noted to cause choking and aspiration, and she was hospitalized with x-ray findings of an aspiration pneumonia and airway obstruction from secretions. She was transferred to an Eastern Children's Hospital for diagnosis and correction of a suspected tracheoesophageal fistula, but exploration of the neck after numerous studies were done, failed to reveal the suspected fistula. Examination on April 15, 1971, after surgery, showed a bilateral vocal cord paralysis, and a tracheotomy was performed. A diagnosis of neuromuscular dysfunction of swallowing was made, and a feeding gastrostomy was performed. Her discharge

Fig. 3. A normal larynx for comparison.

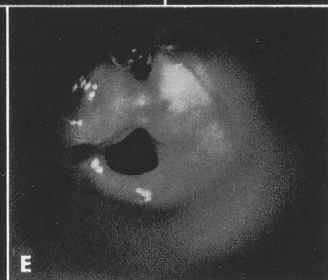
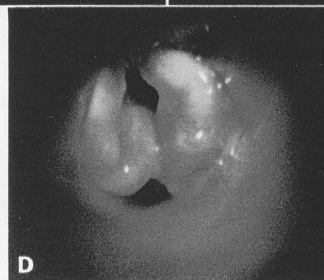
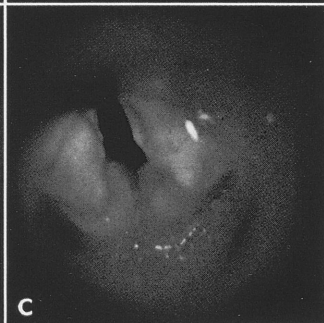
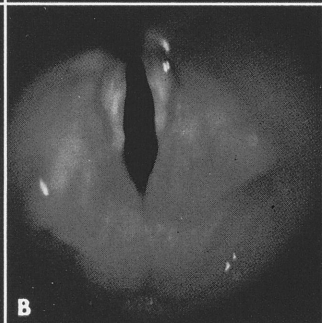
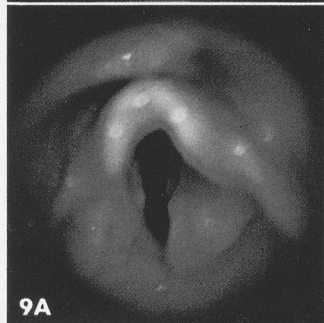
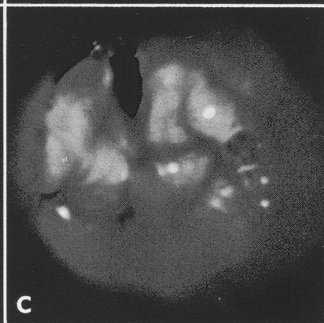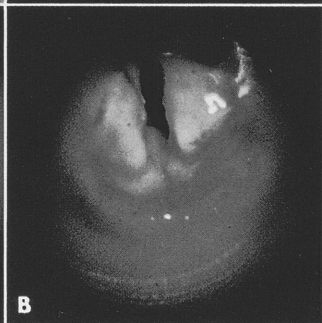
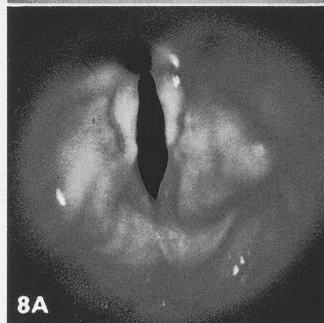
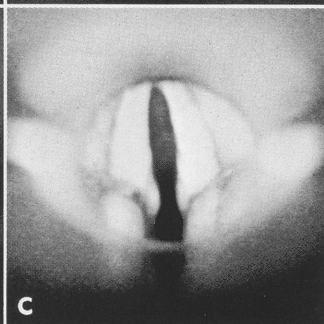
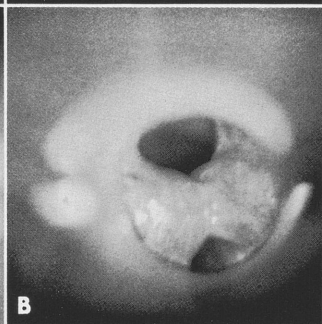
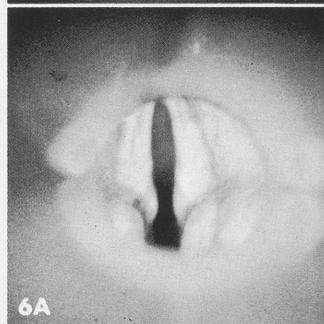
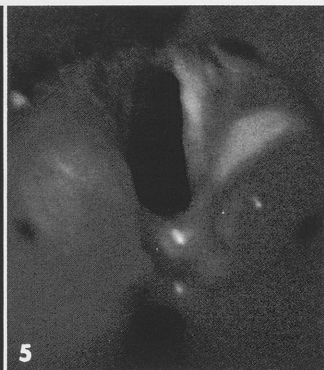
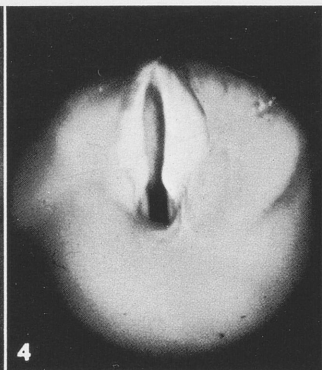
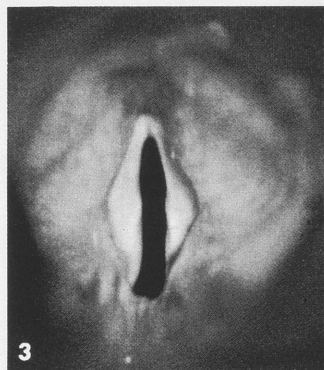
Fig. 4. Shows persistent deep interarytenoid keyhole type defect seen even during spasmodic closure associated with partial laminal cleft.

Fig. 5. Arytenoids laterally displaced showing surgically repaired laryngotracheal cleft. The lamina of cricoid is defective with a healed fibrous septum. Esophagus is seen posteriorly.

Fig. 6. A) Deep interarytenoid cleft. Arytenoids appear laterally and posteriorly displaced. B) Closeup view of arytenoids. Larynx anteriorly dislocated by speculum of scope. Top opening larynx; posterior opening esophagus. C) Arytenoids separated and cricoid defect is noted — viewed is the caudal end of tracheoesophageal septum.

Fig. 8. A) Larynx on first inspection appears normal except for posterolateral position of arytenoids. B) Elevated anteriorly view of larynx showing deep interarytenoid cleft and fissure of cricoid. C) Separation of the arytenoids shows cleft and caudal end of tracheoesophageal septum (anteriorly).

Fig. 9. A) Top view of larynx. Note posteriolateral position of arytenoids. B) Larynx looks almost normal except for abnormal position of arytenoids (deep interarytenoid space). C) Part of the defect of cricoid is seen. D) Fibrous septum of defect of cricoid lamina comes into view on separating arytenoids. E) Cleft is visible and seen to be partial — separation connected by fibrous septum.



from the hospital on May 24, 1971 was with the diagnosis of pseudobulbar palsy, with cricopharyngeal spasm and a left partial recurrent paralysis, and a right complete recurrent paralysis. All feedings were given by gastrostomy until 15 months of age, and on August 29, 1972, it was felt that her airway was adequate and she was extubated. It was noted that solids were taken well, but gulping liquid caused choking. On May 15, 1974, a laryngoscopy and bronchoscopy showed a good airway with a persistent tracheocutaneous fistula. The family then moved to the West Coast.

On October 27, 1974, as is usual prior to closure of a tracheocutaneous fistula, she was admitted to the Children's Hospital of Los Angeles for evaluation of the airway. Direct laryngoscopy showed a partial cleft of the posterior portion of the larynx (Fig. 8A, B, C). The esophagus was normal, and the tracheobronchial tree was normal. It is important to note that this child still chokes when she quickly gulps liquids but eats and drinks normally. On January 27, 1975, the tracheocutaneous fistula was excised, and the plastic repair of the defect was performed. Her postoperative course was uneventful.

Case 7. A female Caucasian born August 9, 1974, in Taiwan was admitted to the Children's Hospital of Los Angeles on September 10, 1974, with a history of trouble swallowing and aspiration immediately upon attempts to feed her. Persistent aspiration pneumonia was present. This patient weighed 3.2 kg at birth, tolerated her first feedings of 5 cc at eight hours of age, but at twelve hours, when given 30 cc, turned blue, choked, aspirated, and developed a pneumonitis. She was able to handle her own secretions well, and did not vomit. A barium esophagram was reported as normal. An x-ray of the chest showed bilateral pulmonary infiltrates. All attempts to feed the child produced cyanosis, gagging, and choking. Oral feedings were stopped, and gavage feedings were given and taken well. She was transferred to the Children's Hospital of

Los Angeles for definitive diagnosis and treatment.

The child's delivery was normal and the mother's pregnancy was also normal. The family history is unremarkable. Examination on admission showed a normal infant with a nasogastric feeding tube in place. The cry was slightly weak, but she had a good suck and the moro and grasp reflex were normal. There were no abnormal neurological findings. A direct laryngoscopy was performed by four specialists in Taiwan, and only the pediatrician felt that the larynx was abnormal.

A direct laryngoscopy done at the Children's Hospital of Los Angeles revealed the larynx to be grossly abnormal with a cleft of the posterior larynx involving the cricoid (Fig. 9A, B, C). The arytenoids could be separated, revealing the tracheoesophageal septum, indicating a defect of the cricoid lamina. The larynx was somewhat edematous. Bronchoscopy showed the tracheobronchial tree to have inflammatory changes, and the mainstem bronchi were seen to be smaller than usual, interpreted as congenital cartilaginous defects. Esophagoscopy showed a normal esophagus, and diligent search for a tracheoesophageal fistula showed no such defect. The patient did well postoperatively, and had no problems with her secretions. She was fed by nasogastric feeding tube until a Stamm gastrostomy was done on September 20, 1974. The patient gained weight, and on October 3, 1974, she was discharged and returned to Taiwan.

Discharge diagnosis at the U. S. Naval facility in Taiwan was a term infant with congenital dysfunction of deglutition and aspiration pneumonitis.

The infant was again seen on February 21, 1975, at six months of age, weighing 5.4 kg and having no problems. Feedings were by gastrostomy. She still has a husky voice, and oral feedings will be withheld three more months, after which thickened feedings will be tried.

ASSOCIATED ANOMALIES

Of the cases reported, two (6 and 7) had no other anomalies. Two cases (3 and 4) had atresia of the esophagus and type C tracheoesophageal fistulae. Both of these cases also had associated bronchial stenosis and one (3) had multiple

tracheoesophageal fistula. A severe laryngeal and tracheal stenosis and a large diverticulum were found in one case (5). One case (2) had an H type tracheoesophageal fistula. Tracheal and bronchial anomalies were found in one case (1), with the trachea bifurcating in the neck.

Request for reprints should be sent to Seymour R. Cohen, M.D., 1300 North Vermont Avenue, Los Angeles, California 90027.

REFERENCES

1. Shapiro MJ, Falla A: Congenital posterior cleft larynx. *Ann Otol Rhinol Laryngol* 75:961, 1966
2. Arey LB: *Developmental Anatomy*, ed 5, Philadelphia and London, W B Saunders Company, 1946, p 385
3. Blumberg JB, Stevenson JK, Lamire RJ, et al: Laryngotracheoesophageal cleft: The embryologic implications. Review of the literature. *Surgery* 57:559, 1965
4. Streeter GL: Developmental horizons in human embryos; Descriptions of age group XIII, embryos about 4 or 5 mm. long, and age group XIV, period of indentation of the lens vesicle. *Contributions to Embryology* 31: 27, 1945
5. Streeter GL: Developmental horizons in human embryos: Description of age groups XV, XVI, XVII, and XVIII. *Contributions to Embryology* 32:133, 1948
6. Mahour GH, Cohen SR, Wooley MM: Laryngotracheoesophageal cleft associated with esophageal atresia and multiple tracheoesophageal fistulas in a twin. *J Thorac Cardiovasc Surg* 65: No. 2:223, 1973

SECOND PRIMARY CANCER AFTER IRRADIATION OF LARYNGEAL CANCER

WILLIAM LAWSON, M.D.

MAX SOM, M.D.

NEW YORK, NEW YORK

SUMMARY — Thirty (5.6%) of 535 patients followed 5-25 years after treatment of cordal carcinoma (T1A,B) developed a second primary laryngeal carcinoma. When analyzed by treatment modality, 3.9% of operated cases and 9% of irradiated cases formed new laryngeal or laryngopharyngeal malignancies. An explanation by radiation-induced carcinogenesis for this statistically significant difference between the two groups is discussed. It is also suggested that supervoltage radiation directed to the laryngeal mucosa may produce the diminished latent period observed between the appearance of the second primary carcinoma.

While numerous studies cite the incidence of second primary tumors within the oropharynx, there is little published about their occurrence in the larynx. The therapy of cordal carcinoma by either irradiation or partial laryngectomy allows the whole or major part of the organ to remain for the various chemical, physical, and cellular factors as well as the genetic predisposition of the host to function in the development of a new growth. Additionally, comparison of the incidence of second primary malignancies in the surgical and radiotherapy groups may permit consideration of a possible etiologic role for radiation in carcinogenesis in the larynx.

RESULTS

Cordal carcinoma (T1A,B) is generally accepted to be equally curable by surgery or radiotherapy. We have found that lesions of the membranous portion of the true cord are eminently suitable for radiation therapy and have treated 225 patients in this way. One hundred ninety of these patients received supervoltage therapy, with the remaining 35 having conventional 250 kv orthovoltage.

Horseshoe lesions of the vocal cord or those extending onto the vocal process or the anterior face of the arytenoid itself are best treated by partial laryngectomy by either the hemilaryngectomy or anterior commissure technique. Cordectomy instead of radiotherapy was employed early in this period before the advent of supervoltage therapy and generally reserved as a prime modality in younger and more elderly patients, in diabetics, in verrucous cancer, or after radiation failure. We have treated 310 cases by hemilaryngectomy, anterior commissure technique, or cordectomy.

Among the 535 treated cases of cordal cancer followed from 5-25 years, second primary laryngeal carcinomas occurred in 30 (5.6%). In the group of 310 patients receiving surgery, 12 (3.9%) second laryngeal primaries occurred. Among the 225 patients receiving radiotherapy, 18 (8%) new laryngeal malignancies appeared. Six tumors occurred in 35 patients having orthovoltage, and 12 occurred in 190 patients receiving supervoltage. If two hypopharyngeal tumors developing within the field of radiation are included, the incidence rises to 9% (Table I). This difference in the inci-

From the Department of Otolaryngology, the Mount Sinai Medical Center, New York.

TABLE I
INCIDENCE OF SECOND PRIMARY CARCINOMAS OF THE LARYNX
535 CORDAL LESIONS (T1a,b)

Corpectomy	71 (5)	Orthovoltage	35 (6)
Ant. comm. tech.	58 (1)	Supervoltage	190 (12)
Hemilaryngectomy	181 (6)		225 (18) (8%*)
	310 (12) (3.9%)		

*9% if 2 hypopharyngeal lesions in the field of radiation are included.

dence of second primary carcinomas in the radiotherapy and surgery groups was found to be statistically significant ($X^2 = 5.73$, $P = .017$).

The interval before the second laryngeal carcinoma appeared in the 12 operated cases was five to eight years in five and 9-14 years in seven. The latent period in the radiotherapy groups was five to eight years in 13 cases, 9-14 years

produce malignant neoplasms is a well-established phenomenon at such sites as the skin, thyroid gland, blood, bone and lung, with a causal relationship established by epidemiologic studies in susceptible human populations (*e.g.*, atomic bomb survivors, radiologists, and other occupational groups exposed to radiation and radioactive materials), as well as by the experimental induction in animals.¹⁻⁴ While radiation carcinogenesis is rare at mucosal sites, sufficient evidence has accumulated to support its existence within the larynx. By 1951 Goolden⁵ had collected nine cases of malignant neoplasms of the larynx and hypopharynx (including four cases of his own) in patients previously radiated for benign disease.

TABLE II
LATENT PERIOD UNTIL APPEARANCE
OF SECOND LARYNGEAL PRIMARY

	<i>Surgery</i>	<i>Radiotherapy</i>
5-8 Years	(5)	(13)
9-14 Years	(7)	(4)
15-25 Years	(0)	(1)
	(12)	(18)

in four cases and 21 years in one case (Table II).

Concerning the development of extra laryngeal malignancies, there were seven bronchogenic carcinomas, one adenocarcinoma of the prostate, and one melanoma in the surgery group. Among the radiotherapy patients there occurred three bronchogenic carcinomas, one adenocarcinoma of the rectum, one squamous cell carcinoma of the ear, and two carcinomas of the hypopharynx, yielding an incidence for malignant tumors occurring outside the larynx of 3% in both groups (Table III).

DISCUSSION

The ability of ionizing radiation to

TABLE III

INCIDENCE OF SECOND PRIMARY
MALIGNANCIES OUTSIDE LARYNX

<i>Surgery (310)</i>	<i>Radiotherapy (225)</i>
Lung 7	Lung 3
Prostate 1	Ear 1
Melanoma 1	Rectum 1
9 (3%)	Hypopharynx 2
	7 (3%)

He proposed the following criteria for radiation induced carcinomas: 1) a history of irradiation for a benign condition; 2) the elapse of sufficient time for the development of the malignancy (latent period); 3) evidence of radiation injury (vascular or atrophic skin changes); and 4) histologic proof of the malignant character of the new tumor. In 1955 Som and Peimer⁶ found 18 cases and by 1957 Goolden⁷ reviewed 25

cases in the world literature of malignant tumors of the larynx, hypopharynx, or esophagus following radiation to the neck for benign conditions. We have discovered 20 additional cases recorded between 1957 and 1974.⁸⁻¹⁷ Review of these 45 cases reveals that all were squamous cell carcinomas with the exception of two fibrosarcomas reported by Goolden⁵ and Holinger and Rabbett.¹⁸ The distribution of these lesions was 12 in the larynx, 33 in the hypopharynx, and two in the esophagus. Virtually all the patients received radiation for benign thyroid disease (goiter, thyrotoxicosis) or tuberculous cervical adenitis and showed telangiectasis or ulceration of the overlying skin as evidence of radiation damage. In five patients of this group multicentric malignant tumors developed. All three patients of McGraw and McKenzie¹³ developed adenocarcinomas of the thyroid as well as squamous cell carcinoma of the hypopharynx, and one patient had a skin cancer within the portal of radiation as well. The patient of Cronin¹⁷ developed carcinoma of both the larynx and the hypopharynx 30 years after irradiation for thyroid disease. In the case of Baker (1959), laryngeal and laryngopharyngeal malignancies developed 30 and 36 years after radiotherapy in addition to basal and squamous cell carcinomas in the irradiated skin. All the patients in this group received orthovoltage radiation with the latent period for the development of the second malignancy ranging from 8-51 years, averaging 27 years. In this group of patients were two children treated for laryngeal papillomatosis with radiotherapy who developed carcinoma of the hypopharynx 30 and 40 years later.^{13,15} The ability of radiation to transform benign papillomas themselves into malignant tumors is another example of the oncogenetic effect of ionizing radiation directed to the larynx. Rabbett¹⁹ accumulated nine instances of carcinoma of the larynx following orthovoltage radiation for juvenile laryngeal papillomatosis. The latent period for the development of a laryngeal malignancy ranged from 4-28 years, averaging 12 years.

The development of radiation-induced carcinomas of the larynx and laryngopharynx following therapeutic irradiation of the larynx for malignant disease was first recorded by Som and Peimer⁶ who described two malignant tumors of the hypopharynx arising 17 and 20 years after such treatment. Thomas²⁰ reported three cases of laryngeal carcinoma recurring 12, 18, and 30 years after treatment (of which one patient had received surgery and the other two radiation) but acknowledged that the latter two tumors may have been radiation induced. Schindel and Castoriano²¹ reported five cases of hypopharyngeal carcinoma occurring 7-12 years after the successful radiotherapy for an endo-laryngeal malignancy. They favored radiation induction as the histogenesis of these tumors rather than multicentricity because of the occurrence of all five lesions in the postcricoid area of males, an uncommon site of primary malignancies in this sex, but a region that was within the zone of radiation. All of these nine cases of a second primary carcinoma of the larynx and laryngopharynx arising in patients irradiated for a laryngeal malignancy received orthovoltage therapy, with a latent period of 7-30 years, averaging 15 years. We know of another case of a postcricoid lesion arising 12 years after radiotherapy with cobalt for a cordal carcinoma.

The five year survival of glottic carcinomas treated either by partial laryngectomy or radiation is quite good when compared to tumors arising at other laryngeal and hypopharyngeal sites. However, the advanced age of many of the patients precluded the protracted follow-up interval of 15-30 years generally regarded as the latent period of radiation-induced neoplasms. Consequently, we believe the increased incidence of second primary laryngeal carcinoma in the radiotherapy group to assume greater significance as many patients did not survive long enough to develop other tumors.

It may be argued that some of the lesions actually represent the delayed recurrence of the initial tumor. While in

the head and neck area certain salivary gland tumors (adenocystic adenocarcinoma), papillary adenocarcinoma of the thyroid, and carotid body tumors may show an extremely indolent growth, a five year disease-free interval with squamous cell carcinoma virtually signifies cure, particularly with T1 lesions.

CONCLUSIONS

Reports of carcinoma of the larynx and hypopharynx developing after radiation to the neck for benign and malignant conditions have suggested an etiologic role for radiation in the histogenesis, but have not established a causal relationship. Baker and Weissman²² (1971) treated seven patients with laryngeal malignancies who had received radiotherapy 5 to 25 years previously for another laryngeal carcinoma. This prompted them to suggest that radiation not be used in the treatment of laryngeal cancer in persons 45 years of age or less. Our study shows that second primary carcinomas arise spontaneously in the larynx at a low rate. However, the demonstration of a statistically sig-

nificant increased incidence of second primary laryngeal carcinomas in the radiotherapy group definitely points to a role for ionizing radiation in the formation of some of these tumors. Although the latent period for the development of a laryngeal or hypopharyngeal carcinoma after orthovoltage therapy of benign disorders of the neck averaged 27 years, it dropped to 12 to 15 years when the beam was directed to the larynx itself in the treatment of papillomatosis or carcinoma. We have found in our material the average latent period for the development of a second laryngeal primary with supervoltage therapy to be seven years which may represent the enhanced radiobiologic effect of this form of ionizing radiation when directed to the laryngeal mucosa. Consequently, thought must be directed to the selection of the prime modality of treatment of cordal carcinoma. This decreased latent period of supervoltage therapy in the face of an increased life expectancy suggests that radiation be withheld in individuals under 50 years of age.

Request for reprints should be sent to Max L. Som, M.D., 121 East 60th Street, New York, New York 10021.

REFERENCES

1. Chisleag GH, Baran E, Petroveanu C: Radiation-induced tumours in man, in *Proceedings of a Symposium on Radiation-Induced Cancer*. Athens, 1969, International Atomic Energy Agency, Vienna, 1969, pp 459-467
2. Rosen VJ, Cole LJ: Radiation carcinogenesis: experimental and clinical aspects, in Berdjis CC (ed): *Pathology of Irradiation*. Baltimore, Williams and Wilkins, 1971, pp 120-145
3. Upton AC: Radiation carcinogenesis, in Dalrymple GU, et al (eds) *Medical Radiation Biology*. Philadelphia, Saunders Co., 1973, pp 213-225
4. Prasad KN: *Human Radiation Biology*. Maryland, Harper and Row, 1974, pp 341-356
5. Goolden AW: Radiation cancer of the pharynx. *Br Med J* 2:1110-1112, 1951
6. Som ML, Peimer R: Postcricoid carcinoma as a sequel to radiotherapy for laryngeal carcinoma. *Arch Otolaryngol* 62:428-431, 1955
7. Goolden AW: Radiation cancer. A review with special reference to radiation tumours in the pharynx, larynx and thyroid. *Br J Radiol* 30:626-640, 1957
8. Lane N: Pseudosarcoma (polypoid sarcoma-like masses) associated with squamous cell carcinoma of the mouth, fauces, and larynx. Report of 10 cases. *Cancer* 10: 19-41, 1957
9. Baker DC: Pseudosarcoma of the pharynx and larynx. *Ann Otol Rhinol Laryngol* 68:471-477, 1959
10. Krahel P: Nil Nocere: Hypopharynx-und Larynx-Karzinoma als Spätfolge nach Röntgenbestrahlung Gutartiger Hautbzw. Lymphknotenerkrankungen im Halsgebiet. *Munch Med Wochenschr* 102:1911-1914, 1960
11. Wlodyka J: The cancerogenic effect of x-ray on the larynx. *Arch Otolaryngol* 76:372-376, 1962
12. Nehls K: Das Strahlentrauma als tumorauslösender Faktor. *Z Laryngol Rhinol Otol* 44:648-660, 1965

13. McGraw RW, McKenzie AD: Carcinoma of the thyroid and laryngopharynx following irradiation: A report of three cases. *Cancer* 18:692-696, 1965
14. Takahashi S, Kitabatake T: Skin and neck cancer following radiation therapy for benign disease. *Tohoku J Exp Med* 84:349-359, 1965
15. Piquet JJ, Dessaulty A, Decroix G: Les radio-cancers (A propos de deux observations). *Ann Otolaryngol Chir Cervicofac* 84:125-129, 1967
16. Gerlings PG: Stralentrauma van pharynx en larynx (Stralencarcinoom en laryngitis radiotherapeutica). *Ned Tijdschr. Geneesk* 113:1045-1050, 1969
17. Cronin J: Radiation-induced cancer of larynx and pharynx. *J Laryngol Otol* 85:621-622, 1971
18. Holinger PH, Rabbett WF: Late development of laryngeal and pharyngeal carcinoma in previously irradiated areas. *Laryngoscope* 63:105-112, 1953
19. Rabbett WF: Juvenile laryngeal papillomatosis: the relation of irradiation to malignant degeneration in this disease. *Ann Otol Rhinol Laryngol* 74:1149-1163, 1965
20. Thomas R: Late recurrence of laryngeal cancer. *J Laryngol Rhinol Otol* 78:1123-1124, 1964
21. Schindel J, Castoriano IM: Late-appearing (radiation-induced) carcinoma. *Arch Otolaryngol* 95:205-210, 1965
22. Baker DC, Weissman B: Post irradiation carcinoma of the larynx. *Ann Otol Rhinol Laryngol* 80:634-637, 1971

EXPERIMENTAL GRANULOMA OF THE LARYNX

FERNANDO R. KIRCHNER, M.D.

KANSAS CITY, KANSAS

SUMMARY — This paper describes a series of experiments that were performed in dogs, attempting to reproduce in the laboratory a chronic granulomatous reaction of the larynx. The purpose of this work was to learn about the possible pathogenesis of these lesions and to find the reasons behind their chronicity and recurrence. The practical aspects of this research were to formulate and, hopefully, to develop reasonable diagnostic and therapeutical approaches that could be used in the treatment of patients. The positive and negative results of these experiments indicate that the granulomatous response is probably influenced not only by external factors, but also by intrinsic factors. Clinically these findings led to the concept of not circumscribing judgment to the peripheral changes only, but to the assessment of all facts surrounding each individual case.

The goals of modern laryngology are twofold: first and foremost, the eradication of the disease; and second, the preservation of function. These aims are best achieved through the individual assessment of the patient and knowledge of the fundamental facts behind the pathological process. Basic information about the larynx and the pathological conditions that may afflict this organ are, therefore, essential. Historically this information has been obtained from three main sources: clinical observations, examination of surgical and autopsy specimens, and from animal experiments.^{1,2} All of these sources have contributed to advancement of the state of the art. In spite of this development there is still much to be learned about the health and diseases of the larynx. The studies in this report were prompted by a group of patients afflicted with different degrees of laryngeal impairment, in whom the outstanding finding was a persistent and recurrent granulomatous process. Experiments were carried out in dogs in an attempt to study and reproduce these chronic granulomas. The purpose of this work was to learn about the possible pathogenesis of these lesions and to find

the reasons for their chronicity and recurrence. The practical aspects of this research were to formulate and, hopefully, to develop reasonable diagnostic and therapeutic approaches that could be used in the treatment of patients.

METHODS AND RESULTS

Anterior Commissure and Vocal Cords. In a representative group of animals, extensive studies were carried out about the possible induction of a chronic granulomatous process in the anterior commissure and vocal cords by: a) extensive epithelial denudation, b) reaction to surgical sutures, and c) artificially produced cartilaginous sequestra.

Superficial epithelial denudation of these structures was attempted in six mongrel dogs. In two of these animals this removal was performed mechanically with a cup forceps, in two other dogs with the thermocautery, and in the remaining two, by means of high frequency fulguration. The larynges of these animals were inspected directly every week with the operating microscope. At the end of five weeks all of these larynges appeared to be recovered by normal

From the Department of Otolaryngology, University of Kansas Medical Center, Kansas City, Kansas.

epithelium. One animal that was treated by fulguration developed a small blunting of the anterior commissure. This dog's larynx was further inspected every week for two additional months. For three weeks no changes were observed, but on the fourth week a small exophytic granuloma was discovered arising from the superior aspect of the small anterior web. In the examination that was carried out six days later, no traces of the granuloma were encountered, and no other recurrences were observed up to the time that the dog was sacrificed. The histological examination of this larynx discovered a small sinus track of epithelium surrounded by the cicatricial tissue forming the web. It is reasonable to assume from these findings that the transient granulomatous reaction was possibly produced by infection of debris entrapped in this epithelial sinus.

The production of granulomas in the anterior commissure by three suture materials, catgut, stainless steel wire, and braided silk, was studied in three animals. These sutures were purposely introduced through an external approach transversing the anterior commissure

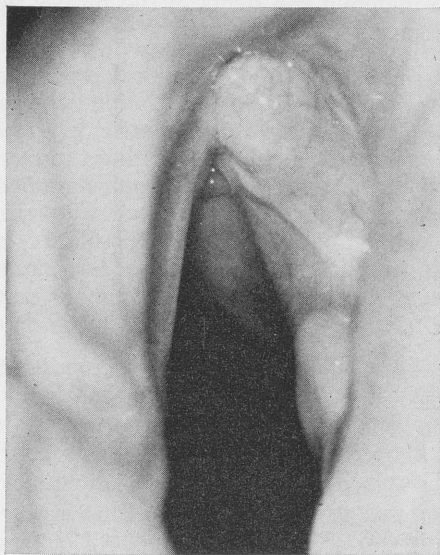


Fig. 1. Granuloma of the anterior commissure produced by a silk suture that was experimentally placed transversing the anterior commissure.

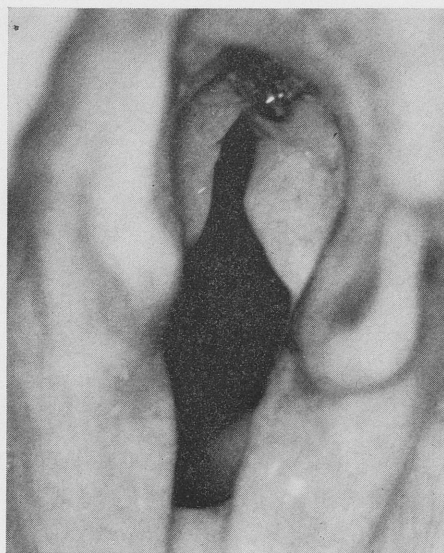


Fig. 2. Silk suture in the anterior commissure after the granulomatous reaction spontaneously subsided.

after drilling two holes in the thyroid cartilage. The larynges of these animals were also observed every week with the operating microscope. One of the animals was discarded in the first week because the catgut suture became extruded after becoming untied. Contrasting the lack of changes found in the larynx of the dog with the stainless wire suture during the full period of eight weeks of observation, the animal with the braided silk suture developed a granulomatous reaction concomitantly with a neck abscess almost immediately (Fig. 1). These two changes improved spontaneously, and at the end of two weeks the neck and larynx appeared to be well healed, in spite of the fact that the silk suture remained plainly visible on direct examination for the remaining eight weeks (Fig. 2).

The possible effect of an artificially produced cartilaginous sequestra implanted in the area of the anterior commissure was studied in one dog. In this animal the anterior keel of the thyroid cartilage was removed through an external approach. This segment of cartilage, measuring about 3 mm wide, was then fixed for one hour in a solution of 10%

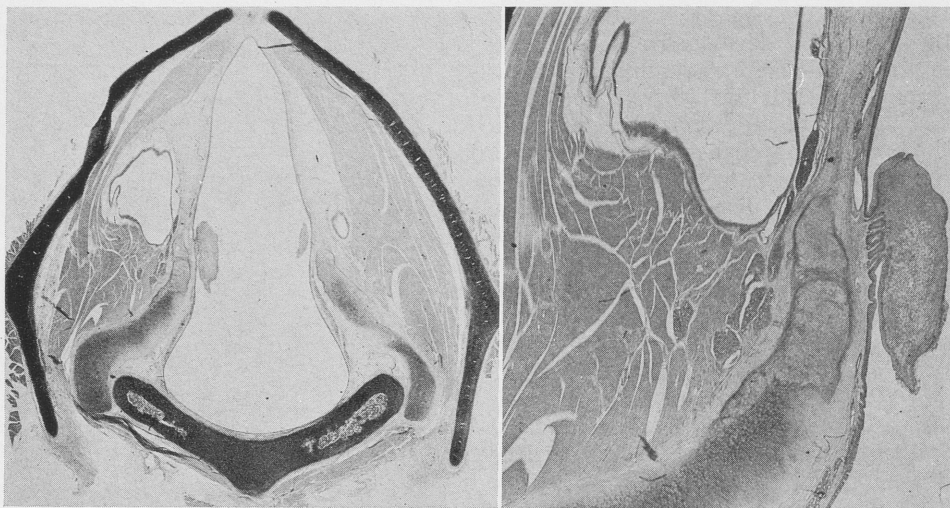

Fig. 3. A) Experimental granulomas arising at the level of the vocal process of the arytenoids during the stage of pediculation and spontaneous resolution. B) Experimental granuloma arising from an area of perichondritis in the vocal process of the arytenoid during the early stages of resolution. Notice the epithelium attempting to restore the normal contours of this portion of the posterior commissure.

formaldehyde. This piece of cartilage was then reimplanted into its original position and held in place by suturing the overlying strapped muscles. No changes were observed in the larynx of this animal at any time during the ensuing two months. The histological examination of this larynx demonstrated the complete replacement of this wedge of cartilage by connective tissue.

Posterior Commissure. The posterior commissures of eight animals were subjected to the following experimental conditions: a) pressure necrosis produced by stents made of Teflon[®]*, b) focal necrosis of the vocal process of the arytenoid cartilage with minimal epithelial denudation, and c) necrosis of vocal process of the arytenoid cartilage following extensive denudation.

Two dogs were used in the first experiments. In these animals a tubeless canine tracheostomy, as described by Miles,³ was first instituted. With the airway secured in such a manner, tapering, shaped stents made of heavy Teflon[®] material were wedged in the posterior commissure

against the vocal process of the arytenoids. The distal end of these implants was secured to the superior edge of the permanent tracheal stoma by means of wire sutures. These experiments were promptly discontinued because of failure to maintain the stents in the proper position.

Focal necrosis of the vocal process of the arytenoid cartilages, with minimal epithelial removal, was attempted in three animals. In two of these animals this structure was focally fulgurated. The other dog was subjected to submucosal injection of a 10% solution of lactic acid. Both of these techniques failed to produce a granulomatous reaction.

Three dogs were finally subjected to extensive denudation with the thermocautery of the epithelium covering the posterior one-third of the vocal cords, the vocal process, and the posterior commissure. The cartilage thus exposed was then deeply fulgurated. All of these animals developed large prominent granulomas in the third week. During

*E. I. du Pont de Nemours & Co., Inc., Wilmington, Del.

this stage one of the dogs was sacrificed, and its larynx was excised and processed for histological examination. The two other dogs were left alive and further examined with the dissecting microscope. On the seventh week the pedicle of the granulomas appeared less broad, and the bulkiness of these reactions was greatly reduced (Fig. 3A). At this stage a second dog was sacrificed. The third animal was sacrificed at the end of nine weeks when the larynx of this dog appeared to be grossly healed. The histological sections of these larynges were examined and the following results obtained.

The granulomas were composed of a core of fibroblasts intermingled with numerous neoformed vascular vessels. Some leukocytic infiltration was noticeable throughout the fibrous stroma.

The dog's larynx that was excised at the early stage of the experiment showed a prominent granuloma completely deprived of epithelial lining. This lining was found to be extending to the periphery of the lesions only. The granulomatous reaction was clearly arising from areas of necrotic cartilage of the vocal process of the arytenoid. Some differences were encountered in the examination of the second specimen. This granuloma was less bulky and had a clearly defined pedicle. This constriction was found to be formed by epithelium attempting to regenerate the normal contour of the adjacent laryngeal surfaces. The fibrous stroma was less exuberant and the areas of focal perichondritis less diffuse and more permeated by cicatricial tissue (Fig. 3B). In the third specimen only the cicatricial changes in the cartilage were evident.

DISCUSSION

These experiments support the observations made by several authors^{4,5,6} about the pathogenesis of nonspecific granulomas of the larynx, particularly

those encountered in the posterior commissure. The multifactor etiology of these lesions is strongly suggested by some of the positive, as well as negative, results obtained in these studies. The concept that, in the author's opinion, is quite outstandingly depicted in this work is the necessity in the clinical practice to appreciate and assess all circumstances, and not to circumscribe judgment only to the peripheral changes.

Representative of this concept are the following two clinical cases. These patients were referred because of persistent granulomas after undergoing, elsewhere, apparently adequate reductions of laryngeal fractures. In one patient a chronic granuloma arising from the anterior commissure obstructing the airway, was found to be produced by a surgical suture. The endoscopic removal of this stitch stopped the recurrence of this granuloma. The second patient was also afflicted with a recurrent granuloma located anteriorly in the subglottic space. Several inflammatory bouts and neck abscesses arising in this area led the referring physician to believe in a possible perichondritis. The histological examination of this granuloma revealed, however, epithelial cells and the typical clefts that are encountered when skin is displaced and entrapped into other tissues.⁷ This granuloma ceased to recur after a tract of displaced epithelium was excised through a simple external approach.

CONCLUSIONS

Granulomas of the larynx appeared to be produced by a particular type of overgrowth of granulation tissue. The conclusions obtained from experiments conducted in dogs, attempting to reproduce these lesions, indicate that their responses appeared to be influenced by a variety of external factors. These studies also suggest the dependency of these lesions to still-unproven intrinsic factors.

Request for reprints should be sent to Fernando R. Kirchner, M.D., Department of Otolaryngology, University of Kansas Medical Center, Kansas City, Kansas 66103.

REFERENCES

1. Delahunty JE, Cherry J: Experimentally produced vocal cord granulomas. *Laryngoscope* 78:1941-1947, 1968
2. Biller HF, Harvey JE, Bone RC, et al: Laryngeal edema: an experimental study. *Arch Otolaryngol* 79:1084-1087, 1970
3. Miles WK: Tubeless canine tracheostomy for laryngeal experimentation. *Arch Otolaryngol* 92:124-127, 1970
4. Jackson C: Contact ulcer of larynx. *Ann Otol Rhinol Laryngol* 37:227-230, 1928
5. Jackson C: Contact ulcer granuloma and other laryngeal complications of endotracheal anesthesia. *Anesthesiology* (Philadelphia) 14: 425-436, 1953
6. Snow JC, Harano M, Balogh K, et al: Postintubation granuloma of the larynx. *Anesth Analg* (Cleve) 45:425-429, 1966
7. Hughes M, Kirchner JA, Branson RJ: A skin-lined tube as a complication of tracheostomy. *Arch Otolaryngol* 94:568-570, 1971

TRACHEAL INCISION AS A CONTRIBUTING FACTOR TO TRACHEAL STENOSIS

AN EXPERIMENTAL STUDY

GARY C. LULENSKI, M.D.

JOHN G. BATSAKIS, M.D.

ANN ARBOR, MICHIGAN

SUMMARY — Tracheostomies were performed on 25 mongrel dogs, employing either a vertical or inverted U flap incision in the trachea. Following cannulation for 14 days, the animals were maintained for three months and endolaryngeal photographs were taken. At the time of autopsy, comparisons of the gross specimens were carried out, as well as histological sectioning through the tracheal stomal area. Both endolaryngeal examination and study of the gross specimens at autopsy revealed less distortion of the tracheal lumen following the flap versus vertical tracheostomy, especially in those animals having the flap of cartilage resewn to the trachea at the time of decannulation. Measurements of the cross sectional area at the tracheal stoma were also made. In animals having a flap tracheostomy, the stomal lumen was preserved, regardless of resuturing the flap. However, animals having a vertical tracheostomy lost an average of 18% of the tracheal area when compared with those having a flap incision. Histological examination revealed cartilaginous growth across the tracheostomy incision only in animals having the flap tracheostomy. Support for the flap tracheostomy is provided from animal experimentation.

Stenosis of the trachea, as a complication following endotracheal intubation or tracheostomy, has been the subject of considerable recent investigation.¹⁻³ Following tracheostomy, two sites of tracheal stenosis have been described: at the site of the stoma or tracheal incision and at the area of the tracheostomy tube cuff or tip.⁴⁻⁶ Infection, excessive cuff pressure, and movement of the tracheostomy tube have been documented as contributing factors to the development of the latter stenotic area, but the factors leading to stomal narrowing are less clear.^{1,6-8} This is true despite evidence that stenosis at the stoma may well be the more common injury.^{1,9}

Some of the possible causative factors of tracheal stomal stenosis have been studied. Nelson indicates that intubation with uncuffed tracheostomy tubes will

lead to significant stenosis if the tubes are left in place for ten days or longer.¹⁰ The stenosis is accompanied by necrosis and deformity of the cartilaginous rings and replacement by fibrous connective tissue. The type of tracheostomy incision (vertical, cruciate, or window) did not appear to be significant in his study. Goldberg also found significant tracheal narrowing when uncuffed tubes were used. He suggests a lack of cartilage support and the size of the cannula as pertinent factors.¹¹ In this summary of the experimental findings, he states: "The defect at the stoma heals with fibrous tissue and the cartilage does not regenerate . . . therefore the dissolution of cartilage is a chronic process."

Refinements in the cuffed tracheostomy tube have produced low pressure systems allowing for reduction of steno-

From the Departments of Otolaryngology and Pathology, the University of Michigan Medical Center, Ann Arbor, Michigan.

sis at the tracheostomy cuff site as the pressure delivered to the tracheal wall can be measured directly.¹² Reduction in the tracheal stomal stenosis awaits further explanation of its etiology.

The flap tracheostomy has been recently described and some evidence exists that it does not lead to tracheal stomal stenosis. An inverted V or U tracheal incision which can be sewn to the skin of the anterior neck has advantages in protecting the airway in the immediate postoperative period and in facilitating tracheal tube changing.^{13,14} Strong recommendations have been made to replace this flap of cartilage at the time of decannulation. When done as a formal procedure in the operating room or at the bedside the flap tracheostomy has not led to stomal stenosis.^{15,16} To date, the fate of the tracheal cartilage remains unclear and the necessity of replacing it at a formal surgical procedure is not supported by experimental data.

In the present report, we present morphological data derived from an experimental study designed to compare the influence on postoperative stomal stenosis of the flap tracheostomy incision and the time-honored, conventional, vertical tracheal incision.

METHODS AND MATERIALS

Twenty-six mongrel dogs, weighing 13 to 16 kilograms were used in this study. After appropriate inoculations, the animals under-

went tracheostomy using pentobarbital and a combination of droperidol and fentanyl for anesthesia. One animal was used as a control and underwent no operative procedure.

The test animals were divided into three groups (Table I) according to the type of tracheal incision used for tracheostomy: vertical versus a flap. In each animal a No. 6 tracheostomy tube* was inserted after the low pressure cuff had been removed by sharp dissection, and left in place for 14 days. The cuff was removed because a pilot study had shown that animals would die from respiratory obstruction, being unable to breathe around the outer cannula if the cuff were present and the inner cannula were to become obstructed. To obviate this problem further, the inner cannula was changed twice daily during the period of cannulation. The vertical incision was made through the least number of tracheal rings required to allow insertion of the tube. In nearly all instances this involved three tracheal rings. The flap tracheostomy was based inferiorly and was made through two rings, and the flap of cartilage was sewn to the skin of the anterior back above the suprasternal notch.

The animals in Groups I and II underwent flap tracheostomy with the following differences: Group I animals had the flap of cartilage freed at the time of decannulation under anesthesia and reapproximated to the anterior trachea with 3-0 chromic sutures; Group II animals had their cannulae removed, and the flap of cartilage was simply left in the granulating wound.

In the period following decannulation (30 or 60 days following tube removal) selected photographs of the animals' tracheae were taken using the Brubaker-Holinger camera. Additional gross photographs were taken at the time of necropsy (90-95 days following decannulation) when the stomal area and an adjacent area of the trachea were excised. This area was then processed, mounted in celloidin, and 10 micron sections made for microscopic examination.

Measurement of the tracheal lumens were made at the midstomal point and at a point removed from the tracheostomy incision by at least two tracheal rings. Measurements taken were the anteroposterior and lateral diameters and the cross-sectional area. The latter was calculated using a planimeter, with three separate measurements taken of each area in each animal and averaged.

RESULTS

Five of the 26 animals in the study expired in the immediate postoperative

TABLE I

EXPERIMENTAL GROUPS RELATING TRACHEAL INCISION TO TRACHEAL STENOSIS

Group	No. of Experimental Dogs	No. of Dogs Surviving	Tracheal Incision
I	9	7	flap (flap re sewn)
II	9	7	flap (flap not re sewn)
III	7	6	vertical

*Shiley Laboratories, Inc., Santa Ana, Calif.

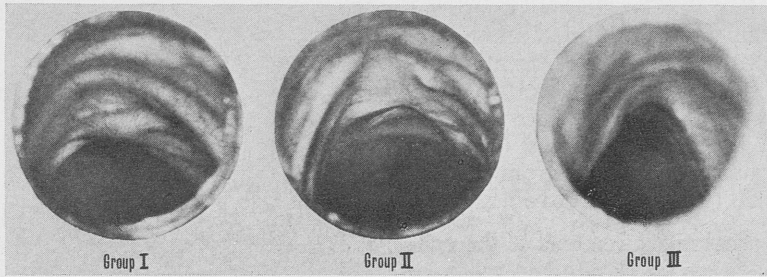


Fig. 1. Endotracheal appearance of the stomal area one month following decannulation. Group I animals underwent flap tracheostomy with the flap resealed; in Group II the flap was not resealed; and in Group III a vertical incision was done.

period, despite antibiotic therapy and changing of the inner cannula twice daily. Mechanical obstruction of the airway appeared to be the cause of death and confirms the problem found in this type of research by others.

The endolaryngeal photographs of selected animals in each study group demonstrated rather striking findings. As shown in Figure 1, animals from the two Groups (I and II) who had flap tracheostomies did not manifest significant distortion of their tracheae at the stomal area. Animals who had vertical tracheostomies (Group III) exhibited a loss of the anterior concavity of the trachea. This was not an isolated observation, as can be seen when comparing typical gross specimens from necropsy (Fig. 2) in which

the animals are different from the three depicted in Figure 1.

Measurements of the tracheal stomas are summarized in Table II. A definite loss of the lateral diameter of the tracheae at the stoma was found in the Group III (vertical incision) animals. Compared

TABLE II
AVERAGE TRACHEAL STOMAL
MEASUREMENTS

Group	A-P Diameter (mm)	Lateral Diameter (mm)	Cross Sectional Area (cm ²)
I	14.8	16.3	2.13
II	14.7	16.4	2.12
III	15.0	12.5	1.76

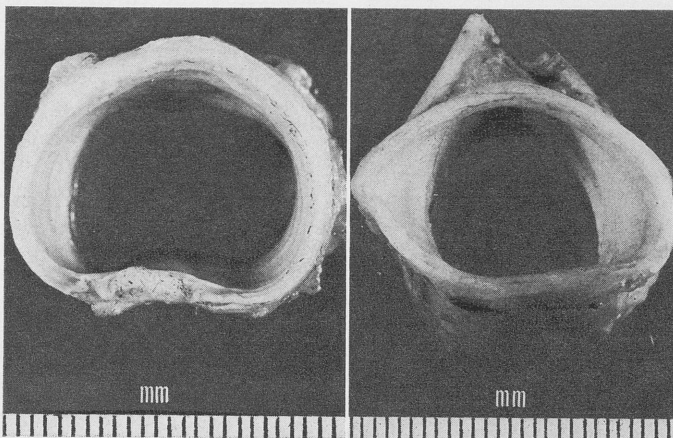


Fig. 2. A) Representative gross specimen of the tracheal stomal area from an animal in Group I. B) Similar area from an animal in Group III, showing distortion of cartilage (See Table I for description of groups).

with the flap tracheostomy Groups (I and II), this Group exhibited an 18% decrease in cross-sectional area. In addition, these animals undergoing vertical tracheostomy also had a reduced lateral tracheal diameter at a point at least two cartilaginous rings removed from the tracheal stoma (15.4 versus 16.3).

The tracheal measurements of the control animal were similar to the mean of those found in Groups I and II, an antero-posterior measurement of 15.0 mm and a lateral measurement of 16.4 mm.

MICROSCOPIC EXAMINATION

Each of the three Groups was histologically separate with an overlap of change occurring only between Groups II and III.

Tracheae from the Group I animals manifested the least histological abnormality (Fig. 3) and, in contrast to

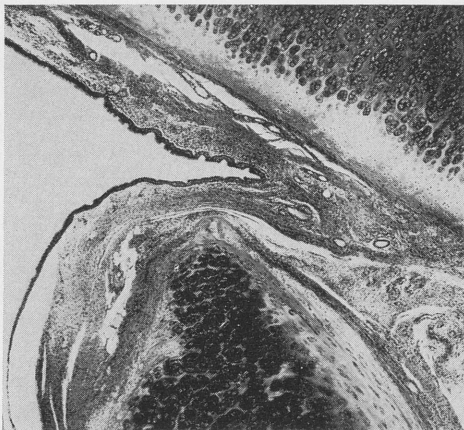

Fig. 3. Prototype appearance of Group I tracheae. Note the virtual absence of scarring and perichondrial reaction. The overlying cartilage is hyperplastic, yet normal in configuration (H. and E., X65).

Groups II and III, exhibited no stromal, vascular, perichondrial, or cartilaginous changes. The cartilage of the flap and the nearby tracheal ring are clearly viable.

The predominant histological abnormality found in the Group II tracheae

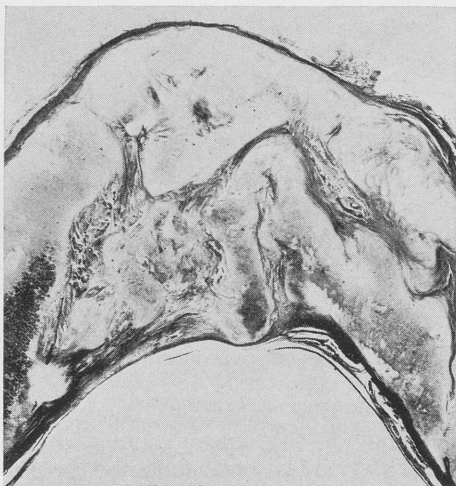

Fig. 4. Marked, disorderly proliferation of cartilage produces bulbous distortion of the tracheal wall. This histological appearance typified the reaction seen in Group II tracheae (H. and E., X65).

was a reactive deformity of the tracheal cartilage. This was present in all sections examined and in several instances was pronounced (Fig. 4). The tracheal lumen, however, was not significantly altered.

Group III animals responded to the vertical incision by a proliferation of soft tissue (vascular connective tissue) and submucosal scarring with perichondrial proliferation (Fig. 5). Two animals also manifested the cartilaginous overgrowth that typified Group II animals. In this Group III alone was there evidence of a subacute inflammatory reaction in the peritracheal soft tissue.

DISCUSSION

Three points of consideration may be derived from this study: the effect of the type of tracheal incision on the development of tracheal narrowing, the mechanism of healing at the site of tracheostomy, and the temporal management of the flap tracheostomy.

Tracheal Incisions and Stomal Stenosis. Only the vertical tracheal incision was associated with tracheal narrowing in this study. The flap tracheostomy in-

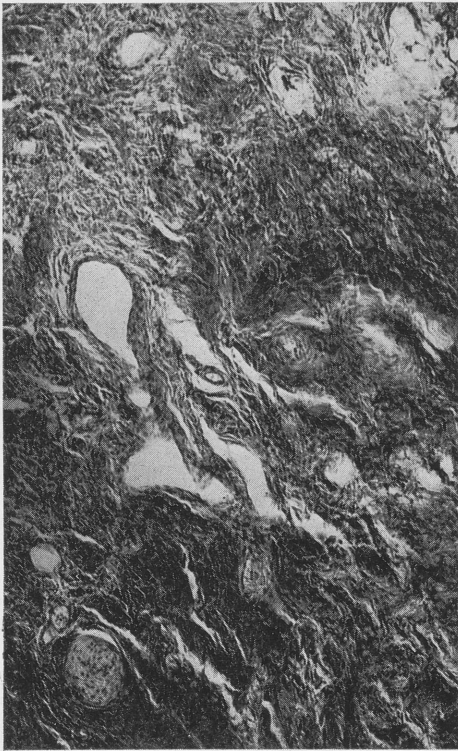

Fig. 5. Vascularized connective tissue with entrapped nerve and fibroadipose tissue represented the tissue response in Group III. This tissue was interposed between cartilage and in some instances extended into the lumen of the trachea (H. and E., X100).

cision, inferiorly based, did not result in any tracheal stenosis. In the vertical tracheostomy there was narrowing at the tracheal stoma as well as distal to the stoma, and the findings were consistent.

Healing at the Tracheal Stoma. The interpretation of results in previous studies concerning healing at the tracheal stoma are not supported by our data. Our studies indicate that gross and microscopic difference in the healing process are related to the type of incision used for tracheostomy. Distortion of cartilage as well as interposition of inflammatory tissue between margins of the remaining cartilage are consistently found following vertical tracheal incisions. This is contrasted to the rather smooth healing of the cartilage defect

following the flap incision. The flap of cartilage remained viable despite a two-week period of cannulation, stomal infection, and a three-month period following decannulation. This was true even if the flap of cartilage was not returned to its original position. The lack of inflammatory reaction about the cartilage suggests that pressure against the cartilage inhibits normal healing. By necessity, the vertical incision results in the tracheostomy tube forcibly opening the tracheal rings. This is minimized by the somewhat circular opening of the flap tracheostomy and constitutes one of the major differences between the two incisions. Gross examination clearly shows the adverse effects of pressure upon the tracheal cartilage (Fig. 2).

Management of the Flap Tracheostomy. The recommendation has previously been given that the flap of cartilage raised to form the tracheostome should be resealed at the time of decannulation as a formal operative procedure. This recommendation is said to offer a better alignment of the anterior wall of the trachea, but it insures the risks of an operative procedure, and on the basis of the tracheal measurements in this study may not be warranted. Resuturing does, however, promote a smoother contour of the trachea. Further investigation by the present authors is focusing on the feasibility of a bedside procedure of releasing the flap of cartilage in promoting this more normal healing process. Another factor being studied in the management of the flap tracheostomy is the time necessary for skin healing, dependent on the handling of the flap at the time of decannulation.

SUMMARY

The morphological changes at tracheostomy stomas were investigated in this study. The only variable was the type of tracheal incision. Both in terms of preservation of the tracheal lumen and the healing at the stoma, it was demonstrated that the inferiorly based flap tracheostomy provided functional advantages over the more typically used vertical incision.

Request for reprints should be sent to Gary C. Lulenski, M.D., Department of Otolaryngology, University of Michigan Medical Center, Ann Arbor, Michigan 48104.

REFERENCES

1. Andrews MH, Pearson FG: The incidence and pathogenesis of tracheal injury following cuffed tube tracheostomy with assisted ventilation — An analysis of a three year prospective study. *Ann Surg* 173:244-263, 1971
2. Davidson IA, Cruickshank AM, Dutheil WH, *et al*: Lesions of the trachea following tracheostomy and endotracheal intubation. *Proc R Soc Med* 64:886-891, 1971
3. Freeman GR: A comparative analysis of endotracheal intubation in neonates, children, and adults: complications, prevention, and treatment. *Laryngoscope* 82:1385-1398, 1972
4. Pearson FG, Goldberg M, De Silva AJ: Tracheal stenosis complicating tracheostomy with cuffed tubes. *Arch Surg* 97:380-394, 1968
5. Grillo HC, Cooper JD, Griffin B, *et al*: A low pressure cuff for tracheostomy tubes to minimize tracheal injury. A comparative clinical trial. *J Thorac Cardiovasc Surg* 62:898-907, 1971
6. Cooper JD, Grillo HC: The evolution of tracheal injury due to ventilatory assistance through cuffed tubes. A pathologic study. *Ann Surg* 169:334-348, 1969
7. Cooper JD, Grillo HC: Experimental production and prevention of injury due to cuffed tracheal tubes. *Surg Gynecol Obstet* 165:1235-1241, 1969
8. Bryant LR, Trinkle JK, Dubilier L: Reappraisal of tracheal injury from cuffed tracheostomy tubes. *JAMA* 215:625-628, 1971
9. Gibson P: Aetiology and repair of tracheal stenosis following tracheostomy and intermittent positive pressure respiration. *Thorax* 22:1-6, 1967
10. Nelson TC: *Tracheostomy: A Clinical and Experimental Study*. Baltimore, Williams and Wilkins, 1958
11. Goldberg M, Pearson FG: Pathogenesis of tracheal stenosis following tracheostomy with a cuffed tube — an experimental study in dogs. *Thorax* 27:678-691, 1972
12. Cheng NP, Ayres SM, Paegle RP, *et al*: The contribution of cuff volume and pressure in tracheostomy tube damage. *J Thorac Cardiovasc Surg* 62:402-410, 1971
13. Acuna PT: Tracheostomy: A simplified technique. *Ann Otol Rhinol Laryngol* 75:826-829, 1966
14. Bjork VO: Partial resection of the only remaining lung with the aid of respiratory treatment. *J Thorac Cardiovasc Surg* 39:179-188, 1960
15. Dukes HM: Tracheostomy. *Thorax* 25: 573-576, 1970
16. Chew JY, Cantrell RW: Tracheostomy. *Arch Otolaryngol* 96:538-545, 1972

DISCUSSION

D. D. RABUZZI, M.D. (Syracuse, New York): I just wish to make a comment on Dr. Lulenski's paper. It is a very good paper and very well documented.

We have done a similar study (Dr. Emil Ghalib and I), in Syracuse, using the vertical incision versus a fenestrated incision which tends to be the one we favor as opposed to the flap incision.

We found that there was no stenosis with the fenestrated incision. This was done on 12 dogs and not only was there no stenosis with the fenestrated incisions, but indeed there was narrowing of a similar type as was shown here very beautifully with the vertical incision, i.e., the anterior tenting.

We also found contrary to Nelson (which Dr. Lulenski commented upon) that there was some cartilage regeneration at the incisions.

CHARACTERIZATION OF TUMOR ANTIGEN IN EPIDERMOID CARCINOMA

CHARLES J. KRAUSE, M.D.

JOHN NYSATHER

BRIAN F. McCABE, M.D.

IOWA CITY, IOWA

SUMMARY — Tumor antigens have been isolated from nine epidermoid carcinomas of the head and neck. The most strongly reactive antigens have a molecular weight of $\approx 25,000$ -50,000 daltons, though other antigens weighing $\approx 120,000$ -400,000 daltons were noted in six of the tumors. The most strongly reactive antigens from three of the tumors were further purified by isoelectric focusing. Each of these antigens had a pI between 8.36 and 8.40. The cross reactivity of these antigens will be studied next. It is hoped that the purified tumor antigen will be useful in the development of an immunodetection system for epidermoid carcinoma.

The growth of knowledge about immunobiologic processes has brought about a better appreciation of the complex interaction between the host immune system and a neoplasm. Methods are being sought to effectively monitor a patient's immunosurveillance system for early evidence that a malignancy is present. Such a system might be useful as a screening method for cancer, and most certainly would increase the accuracy of posttherapeutic detection of residual cancer.

An immunodiagnostic method might assay for either circulating tumor specific antigens (TSA) or for antitumor antibodies. TSA appear to be released into the general circulation but in such minute quantities that detection is difficult. Radioimmunoassays (RIA) have been developed which are capable of demonstrating nanogram/ml levels of fetal antigens. The two major circulating fetal antigens which have been found to be associated with carcinomas are carcino-embryonic antigen (CEA) and alpha-fetoprotein (AFP). Unfortunately, these antigens are not specific for cancer and

have been found in a variety of benign, as well as malignant, conditions.

Both humoral and cellular-fixed anti-tumor antibodies are demonstrable in cancer patients. Difficulty in detecting antitumor antibodies in patients with early lesions and lack of specificity of the antibodies continues to be a problem which limits the general usefulness of such techniques.

This study was designed to purify and characterize tumor specific antigens from epidermoid carcinoma arising in the head and neck. The purified tumor antigens will then be utilized to develop an RIA capable of detecting circulating tumor antigens or assay techniques for antibody titers directed against the specific tumor antigens. Such an immunoassay system would provide an early detection method so important for effective cancer control.

Considerable evidence now exists that specific antigens are present on the cell membranes of cancer cells which are different from antigens present on normal cells. These TSA have been isolated

From the Department of Otolaryngology and Maxillofacial Surgery, University of Iowa Hospitals, Iowa City, Iowa 52242.

from a variety of tumors in animals¹⁻⁴ and man⁵⁻⁷ alike. Billings and Terasaki⁸ found purified tumor antigens isolated from human lymphomas to have a molecular weight of $\approx 27,000$.

Early studies^{9,10} suggested that tumor antigens found in chemically-induced solid tumors were different from those in other similarly induced tumors. However, more recently Ankerst and his associates¹¹ demonstrated cross reactivity in chemically induced rat mammary fibroadenomas, as did Steel and Sjogren¹² in rat colon cancer.

Cross reactivity of some solid tumors in man has also been found. The Hellstroms¹³ demonstrated very nicely that lymphocytes from patients with various types of cancer will destroy not only their own cancer cells but also cells from cancers of the same histologic type found in other patients. Utilizing the same cytotoxicity method, Kennedy¹⁴ working in our department found that lymphocytes from 12 patients with epidermoid carcinoma of the head and neck destroyed cells in culture from a single epidermoid carcinoma of the larynx, whereas non-sensitized lymphocytes from control patients did not. Of interest, cell mediated antibody was present in one additional female patient who had no recurrence of her head and neck cancer, but did have epidermoid cancer of the cervix. This finding suggested that cross reactivity existed between the epidermoid carcinoma of the cervix and that of the head and neck.

Gold and Freedman¹⁵ isolated an antigen from adenocarcinomas of the colon that is normally found in the human fetus but not in the normal adult. This glycoprotein, called carcinoembryonic antigen (CEA), could be identified within the general circulation of most patients with colon carcinoma. However, CEA has also been found in a variety of other gastrointestinal tract malignancies and benign conditions as well.

Another circulating antigen associated with fetal development, as well as with carcinoma, is AFP, which was described

by Tatarinov.¹⁶ This globulin is normally produced by the fetal liver but disappears from the general circulation shortly after birth. Though most commonly associated with hepatomas, levels of circulating AFP have been demonstrated in a variety of malignant and nonmalignant conditions. With both of these fetal antigens, lack of specificity has limited their usefulness in the immunodiagnosis of cancer.

Antibody response to these tumor antigens is extremely complex. The response of the host T-lymphocyte system appears to be of paramount significance in tumor destruction. Sensitized lymphocytes which destroy specific tumor cells remain in the peripheral circulation for about 24 months¹⁴ after removal of a tumor, then disappear unless a recurrence of the tumor develops.

Humoral antibodies against tumor antigens are associated with B-lymphocytes. High antibody titers directed against the Epstein-Barr virus have been found in patients with nasopharyngeal carcinoma as well as with some other head and neck carcinomas.¹⁷ These elevated antibody titers rapidly fall to normal in patients who are free of tumor after treatment.¹⁸ Hollinshead, *et al*¹⁹ demonstrated elevated antibody titers against herpes simplex virus nonvirion antigens in a series of patients with head and neck cancer.

The role of antibody in the rejection of tumor is at present poorly understood. In some situations it appears that antibodies or antigen-antibody complexes may actually impair or block the action of sensitized lymphocytes against the tumor cells.

METHODS AND MATERIALS

A block of fresh tumor cells is removed from the specimen core at the time of surgical resection of head and neck epidermoid carcinoma. The remaining specimen is processed in standard fashion to obtain H. and E. slides for histologic identification. The tumor specimen is minced and the protein and glycoprotein molecules enzymatically cleaved from the cell surface utilizing 2.5% solution of trypsin.²⁰

After centrifugation of the specimen at

TABLE I
SUMMARY OF DATA ON INDIVIDUAL PATIENTS WITH EPIDERMOID CARCINOMA

Sex	Age	Tumor Site	Protein Fractions Yielding
			Positive Skin Tests (Molecular Weight — Daltons)
F	66	Neck	200,000 42,000
M	55	Floor of mouth	34,500 25,000
F	73	Buccal mucosa	260,000
F	88	Gingivo-buccal sulcus	40,000 32,000
F	58	Pyriform sinus	200,000 34,000
M	58	Floor of mouth	140,000 26,500
M	55	Alveolar ridge	400,000 30,000
F	41	False vocal cord	34,000
F	80	Tongue	400,000 42,000 29,000

2,000 rpm for 15 minutes, the supernatant is mixed with an equal volume of a saturated solution of ammonium sulfate (SAS) and centrifuged for 30 minutes at 15,000 rpm at 2 C.

The supernatant is discarded, and the tumor extract thus precipitated is suspended in an aliquot of PBS and dialyzed exhaustively against PBS at 2 C. The crude tumor extract is then applied to the Biogel A-1.5 m column. Protein concentrations as measured by optical density at 280 nm are plotted versus molecular weight, resulting in a curve as illustrated in Figure 1.

Fractions from each peak are dialyzed exhaustively against normal saline solution at 2 C, and adjusted to 250 μ g protein/0.05 ml.

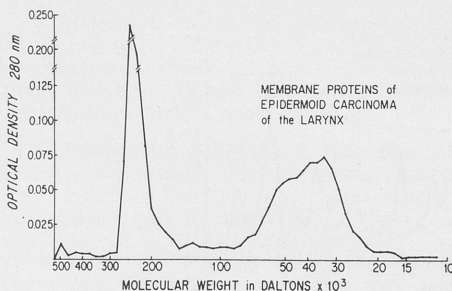


Fig. 1. Typical protein concentration curve following passage of crude tumor extract through Biogel A-1.5m column.

The fractions are then sterilized via membrane filtration (pore size 0.22 μ), and 0.05 cc is injected intradermally into the volar aspect of the forearm. An area of erythema 5 mm in diameter or greater at 48 hours is considered a positive reaction.

Those fractions which resulted in a positive skin test reaction are then applied to an isoelectric focusing column resulting in a separation of protein complexes relative to their isoelectric point (pI). The fractions thus separated are then dialyzed against normal saline solution and the concentration adjusted to 250 μ g/0.05 cc. Each specimen is sterilized via membrane filtration as before, and 0.05 cc is injected intradermally. The reaction is read at 48 hours. Those portions to which the patient demonstrates a positive skin test are thought to represent highly purified tumor antigens.

RESULTS

Preparation of Tumor Extract. Epidermoid carcinoma specimens from nine patients were processed. Table I lists the patients' age, sex, tumor site, and molecular weight of antigenic fractions. Trypsin was utilized to cleave antigens from the cell membranes resulting in a crude tumor extract containing a variety of antigens.

Gel Filtration. Initial purification of

the tumor extract utilized passage through a Biogel A - 1.5m column. The results of this method were remarkably consistent with each tumor, showing a high peak at $\approx 200,000 - 280,000$ daltons and lesser peaks at $\approx 25,000 - 50,000$ daltons.

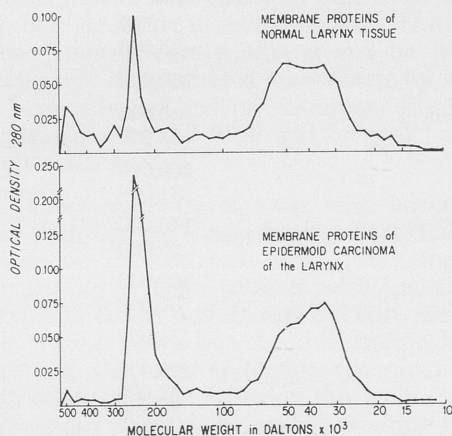


Fig. 2. Comparison of curves produced by tumor and normal tissue extracts in the same patient. Greater concentration of protein in the tumor extract at $\approx 220,000$ and $34,000$ represents tumor antigens.

When normal tissue extracts were compared with tumor extracts from the same patient (Fig. 2), major peaks appeared at similar molecular weights. However, the protein concentration at two of the major peaks was considerably greater in the tumor extract suggesting that these two peaks contain normal antigens as well as tumor antigens.

Skin Tests. If the patient is capable of mounting a hypersensitivity skin reaction, he should develop no reaction when normally occurring autochthonous antigens (such as HL-A) are injected intradermally but should react with a secondary response (within 48 hours) to injected tumor antigens.²¹ Preparations from each individual peak were sterilized and injected intradermally into the host. Table I lists the molecular weight of each fraction to which positive skin tests (5 mm diameter at 48 hours) oc-

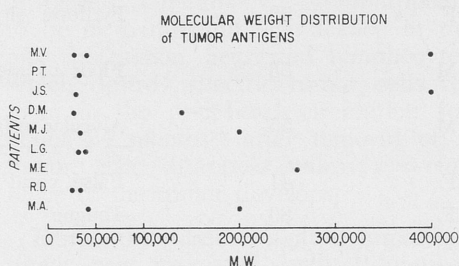


Fig. 3. Molecular weight of protein fractions to which each patient developed a positive delayed hypersensitivity skin reaction. These fractions contain tumor antigens.

curred. In eight of the nine patients a strongly positive reaction developed to antigens with molecular weights in the $25,000 - 50,000$ dalton range. Six of the patients also had secondary reactions to antigens in the $120,000 - 400,000$ dalton range, though less strongly so (Fig. 3). None of the patients developed positive reactions when skin tested with extracts from normal tissue. Interestingly, three patients were skin tested initially before

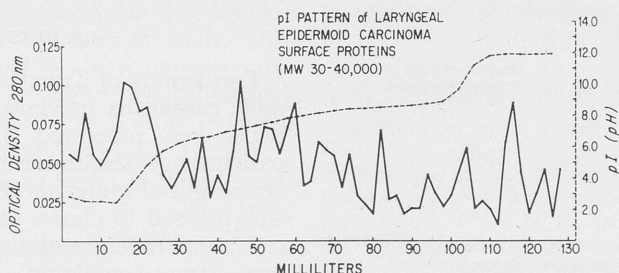


Fig. 4. Typical isoelectric pattern of surface antigens with molecular weight in the range of $30,000 - 40,000$. Fraction from each peak was injected intradermally in three patients.

surgical removal of the tumor. None of the patients developed positive skin reactions. Each of these patients was again skin tested after removal of the primary tumor and developed a positive skin test which appears to indicate immunosuppression by the tumor.

Isoelectric Focusing. In three patients the most strongly antigenic extracts (26,500 - 34,000) have been further purified utilizing an isoelectric focusing column (Fig. 4). Again, individual peaks were adjusted for concentration and injected

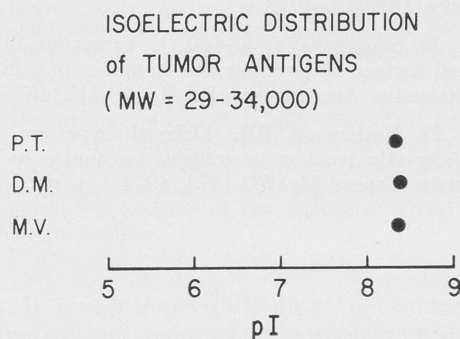


Fig. 5. Positive skin test reaction occurred in each of the three patients to a fraction with isoelectric point between 8.36 and 8.40.

intradermally. All three patients reacted only to fractions with a pI of 8.36 to 8.40 (Fig. 5), which is within the limits of accuracy for the technique.

DISCUSSION

This is a report of some early information obtained about tumor antigens found in epidermoid carcinoma of the head and neck. Though only a small number of tumors have been processed, the results are strikingly consistent, suggesting that this will prove to be a very effective method of obtaining highly purified tumor antigens. The most strongly reactive antigens appear to have a molecular weight in the range of $\approx 25,000$ to 50,000 daltons and to have a pI of about 8.4. Other tumor antigens may be present in the molecular weight range of $\approx 120,000$ - 400,000, though these appear to be less strongly antigenic.

The cross reactivity of these tumor antigens is now being studied. These purified antigens will be used to develop sensitive immunoassays for circulating tumor antigen and antitumor antibody titers in patients. It is hoped that such a method of immunodetection will be capable of identifying cancer when it is still quite small and readily curable.

Request for reprints should be sent to Charles J. Krause, M.D., Department of Otolaryngology and Maxillofacial Surgery, University of Iowa Hospitals, Iowa City, Iowa 52242.

REFERENCES

1. Kolb JP, Poupon MF, Lespinats G: Tumor-associated antigen (TAA) and antibodies in the serum of BALB/c mice with plasmacytomas. *J Natl Cancer Inst* 52:723-727, 1974
2. Jones DB, Moore M: Antigens of tumours induced by naturally occurring murine sarcoma virus (MSV-FBJ). I. Detection of group and type specific antigens by complement fixation. *Br J Cancer* 29:21-30, 1974
3. Bystryń JC, Schenkein I, Baur S, *et al*: Partial isolation and characterization of antigens associated with murine melanoma. *J Natl Cancer Inst* 52:1263-1269, 1974
4. Baldwin RW, Glaves D, Harris JR: Tumor specific antigens associated with aminazo-dye induced rat hepatomas. *Transplant Proc* 3:1189-1190, 1971
5. Lewis MG: Proceedings: Tumor specific antigens in melanoma. *Proc Natl Cancer Conf* 7:77-83, 1973
6. Nordquist RE: Specific antigens in human alveolar carcinoma. *Cancer Res* 33:1790-1795, 1973
7. Edynak EM, Hirschaut Y, Old LJ, *et al*: Antigens of human breast cancer. *Proc Am Assoc Cancer Res* 12:75, 1971
8. Billings R, Terasaki PI: Human leukemia antigen. II. Purification. *J Natl Cancer Inst* 53:1639-1643, 1974
9. Foley EJ: Antigenic properties of methylcholanthrene-induced tumors in mice of the strain of origin. *Cancer Res* 13:835, 1963
10. Prehn RT, Main JM: Immunity to methylcholanthrene-induced sarcomas. *J Natl Cancer Inst* 18:769, 1957
11. Ankerst J, Steel G, Sjogren HO: Cross-

reacting tumor-associated antigens of adenovirus type 9-induced fibroadenomas and a chemically induced mammary carcinoma in rats. *Cancer Res* 34:1794, 1974

12. Steel G, Sjogren HO: Cross-reacting tumor-specific transplantation antigens in chemically induced rat colon carcinomas. *Cancer Res* 34:1801, 1974

13. Hellstrom I, Hellstrom KE, Sjogren HO, *et al*: Demonstration of cell-mediated immunity to human neoplasms of various histological types. *Int J Cancer* 7:1, 1971

14. Kennedy JT: *A Search for Common Tumor Specific Antigen and Serum Blocking Factor in Head and Neck Epidermoid Carcinomas*, thesis. University of Iowa, Iowa City, 1973

15. Gold P, Freedman SO: Demonstration of tumor-specific antigens in human colonic carcinomata by immunological tolerance and absorption techniques. *J Exp Med* 121:439, 1965

16. Tatarinov YS: Content of embryo-specific alpha-globulin in fetal and neonatal sera

and sera from adult humans with primary carcinoma. *Fed Proc (Transl Suppl)* 25:344, 1966

17. Henle W, Henle G, Ho H, *et al*: Antibodies to Epstein-Barr virus in nasopharyngeal carcinoma, other head and neck neoplasms and control groups. *J Natl Cancer Inst* 44: 225-231, 1970

18. Henle W, Ho HC, Henle G, *et al*: Antibodies to Epstein-Barr virus related antigens in nasopharyngeal carcinoma. Comparison of active cases with long term survivors. *J Natl Cancer Inst* 51:361, 1973

19. Hollinshead AC, Chretien PB, Rawls WE, *et al*: Antibodies to herpesvirus non-virion antigens in squamous carcinomas. *Science* 182:713, 1973

20. Slimowska V, Kawiak J: Liberation of cell surface material by the insoluble trypsin derivative. *Acta Biochim Pol* 20:113-118, 1973

21. Herberman RB: Delayed hypersensitivity skin reaction to antigens on human tumors. *Cancer* 34:1469-1473, 1974

PYRIFORM SINUS CANCER: A CLINICAL AND LABORATORY STUDY

JOHN A. KIRCHNER, M.D.

NEW HAVEN, CONNECTICUT

SUMMARY — In our patient population, cancer of the hypopharynx arose 19 times as often in the pyriform sinus as in the postcricoid space (152:8). Most of the growths were far advanced when first seen (90% T3), and enlarged cervical nodes were present in 66% of the patients. Three year survival rates free of disease were as follows: primary surgical treatment (laryngectomy, radical neck dissection) (8/28) 29%; primary radiotherapy (2/55) 4%; and combined preoperative radiation (12/33) 36%. Serial section studies of 51 surgical specimens indicate that T1 and T2 lesions, especially those confined in the medial wall, are probably curable by radiotherapy. Larger lesions invade deeply into the larynx and resemble transglottic growth in their pattern of spread. Conservation surgery would have been inadequate for all but perhaps one growth in this series of 51 lesions, because of the high rate of invasion by cancer into and through the thyroid cartilage and cricoid ring (22/51). Although surface presentation of this group of pyriform sinus cancers rarely reflected the extent of invasion, each of the 22 growths that invaded portions of the thyroid or cricoid cartilages was characterized by clinical involvement of the apex and lateral wall of the pyriform sinus on laryngoscopy or barium swallow.

It is sometimes difficult to determine the starting point of a hypopharyngeal cancer if it has spread beyond its point of origin to invade adjoining structures. This study includes only those growths whose major bulk occupied the pyriform sinus or those in which the pyriform sinus contained an ulcerating neoplasm with induration extending into the larynx or base of tongue. Epiglottic lesions have not been included nor have those originating in the lateral pharyngeal wall or postcricoid area.

The period of study starts in 1958 when supervoltage radiation equipment was acquired at Yale New Haven Hospital and ends in 1971 to provide a minimum three year follow-up period. All diagnoses were confirmed histologically.

The patient population comprises those admitted to the Yale New Haven Hospital and another group admitted to

the USVA Hospital at West Haven. Radiation therapy for the two institutions was given at Hunter Radiation Center at Yale New Haven Hospital. Surgery was performed by members of the otolaryngology staff of the Yale New Haven Hospital.

Of the 152 pyriform sinus cancers seen at the Yale New Haven Hospital between 1958 and 1971, 36 were not included in this study for the following reasons: treatment incomplete (19); first treatment elsewhere (16); and treated with ortho-voltage radiation¹ (Table I).

Survival rates have been calculated on the basis of a three-year period with no evidence of disease. Other status categories have been listed as follows:

Died Free of Disease. Patients were free of discernible disease at the time of death from other causes, usually in less than three years.

From the Department of Surgery, Section of Otolaryngology, Yale University School of Medicine, New Haven, Connecticut.

Supported by USPHS 9 RO1-NS-10551-08.

TABLE I
PYRIFORM SINUS CANCER
1958-1971

Total No. Cases	152
Not included	36
Incomplete treatment	(19)
First treatment elsewhere	(16)
250 KV	(1)
Case Material	116

Died of Other Causes. This includes one group of patients who died of other causes at intervals varying from a few weeks after operation up to seven months. Another group died of a second cancer three years or more after treatment.

Died with Disease. Death resulted from the original cancer, usually in a period of less than three years.

TABLE II
PYRIFORM SINUS CANCER (116)

Primary Surgery	28
T1	(2)
T2	(2)
T3	(24)

Each tumor was originally staged according to the American Joint Commission (A.J.C.) classification available at the time. For the present report, the original staging of each tumor was expressed according to the 1973 supplement to the TNM classification of the International Union Against Cancer (I.U.A.C.) and A.J.C.¹

Although there are as many small lesions as large ones in each of the three treatment categories (surgery, radiother-

TABLE III
PYRIFORM SINUS CANCER (116)
1958-1971

Radiotherapy	55
T1	(2)
T2	(2)
T3	(51)

TABLE IV
PYRIFORM SINUS CANCER (116)

Combined Treatment	33
T1	(2)
T2	(1)
T3	(30)

apy, and combined treatment), an element of selection must be allowed for in assessing results in treatment as with any retrospective study (Tables II, III, IV).

CASE MATERIAL

During the period 1958-1971 when 152 cases of pyriform sinus cancer were seen at Yale New Haven Hospital and USVA Hospital, eight cases of postericoid cancer were also seen (Table V). This re-

TABLE V
CANCER OF HYPOPHARYNX

Pyriform sinus	152
Postericoid	8
Posterior wall	17

sults in a 19:1 ratio of pyriform sinus to postericoid cancer, in striking contrast to the distribution in northern Europe where postericoid cancer forms a much higher percentage of hypopharyngeal growths. Harrison's group of 67 hypopharyngeal cancers, for instance, included 40 postericoid growths, 60% of the total. This may not reflect incidence rates precisely, as Harrison points out, but rather a degree of artificial selection related to the particular interest of his group in the surgical management of postericoid cancer.² Jacobsson's series, however, shows a similar distribution among patients treated at Radiumhemmet in Stockholm.³

If the 152 cases of pyriform sinus cancer, 143 were in men. Unlike the sex distribution in northern Europe, six of the eight postericoid cancers were in men (Table VI).

Most pyriform sinus cancer is diagnosed only after the disease is far advanced. Of the 116 cases making up this

TABLE VI
CANCER OF HYPOPHARYNX
1958-1971

	Male	Female
Pyriform sinus (152)	143	9
Postericoid (8)	6	2
Posterior wall (17)	14	3

TABLE VII
PYRIFORM SINUS CANCER
1958-1971

Total No. Cases	116
T1	6
T2	5
T3	105

study, 105 were in the most advanced category (T3) at the time of diagnosis (Table VII). Seventy-seven of the 116 patients had palpably enlarged cervical lymph nodes on admission, and in 19 others histologically positive nodes developed after treatment by surgery or radiation (Table VIII).

TABLE VIII
PYRIFORM SINUS CANCER

Total Number of Cases	116
Palpable Cervical Nodes (35/49 pos.) — 74%	77
No Nodes Palpable (9/20 pos.) — 45%	20
Nodes Not Sectioned	19

Lymph node metastasis showed little if any relation to the stage of the primary tumor. Of six T1 lesions, three were associated with palpably enlarged nodes, of which two cases were histologically positive. Of five T2 lesions, three had regional metastasis and of 105 T3 lesions, 55 were shown histologically to have lymph node metastasis among 63 neck specimens available for study. Many of the remaining 42 cases were treated by radiotherapy and never had a neck dissection or biopsy of the neck nodes (Table IX).

For the same reason, the relationship

TABLE IX
PYRIFORM SINUS CANCER (116)

Primary	Nodes Palpable	Nodes Pos.
T1	3/6	2/3
T2	2/5	3/3*
T3	72/105	55/63

*One N-O.

between cervical node metastasis and histological differentiation of the primary tumor is not entirely reliable (Table X).

TABLE X
PYRIFORM SINUS CANCER (116)
GRADED (85)
LYMPH NODE METASTASES

Primary	No. Cases	Pos. Nodes	%
Well differentiated	30	15	50
Mod. differentiated	21	9	43
Poorly differentiated	34	13	38

TREATMENT AND RESULTS

Primary surgical treatment was employed in 28 cases and consisted of laryngectomy and radical neck dissection. Of these 28 patients, nine survived three years or more free of disease. Fourteen died of disease, including ten who had been treated by postoperative irradiation. Of the other five, three died of other causes, one is alive with cancer, and one died at three years with no evidence of disease. There were thirteen local or regional recurrences among these 28 patients (Table XI).

TABLE XI
PYRIFORM SINUS CANCER (116)

Primary Surgery	(28)
N.E.D.* > 3 years	(9)
Alive with disease	(1)
Died	(18)
with disease	(14)
other causes	(3)
N.E.D.* 3 years	(1)

*N.E.D.: No evidence of disease.

Supervoltage radiation therapy was used as the primary treatment in 55 cases. Of these, there were only two survivors after three years. Forty-four patients died with disease; nine died of other causes within three to twenty-eight months after treatment. One T1 and one T3 made up the survivors. Seven patients had laryngectomy for uncontrolled disease after radiotherapy, but none survived. There were 28 local or regional recurrences in this group of 55 (Table XII).

TABLE XII
PYRIFORM SINUS CANCER (116)

Primary Radiotherapy	(55)
N.E.D. > 3 years	2
Died	53
with disease	(44)
other causes	(8)
CVA* at 4 mo.	(1)

*Cerebro-vascular accident.

Combined therapy was employed in 33 cases and consisted of planned pre-operative irradiation, usually 4,000 rads in four weeks followed by laryngectomy and radical neck dissection in four to eight weeks (15 patients). Eighteen patients had other irradiation doses: ten were below 4,000 rads, averaging 3,600, and eight above, between 5,000 and 5,600 rads.

TABLE XIII
PYRIFORM SINUS CANCER (116)

Combined Treatment	(33)
N.E.D. > 3 years	12
N.E.D. < 3 years	1
Died	20
with disease	(16)
N.E.D. 3 years	(4)

Of the 33 patients, twelve survived three years or more free of disease. This group includes both of the two patients with T1 and ten with T3. One patient with T2 and fifteen with T3 died with disease; five other patients with T3 died of other causes. There were six local or regional recurrences among these 33 patients (Tables XIII, XIV, XV).

TABLE XIV
PYRIFORM SINUS CANCER (116)

Local Recurrence After Treatment	(66)
Primary Surgery	13/28 46%
Primary Radiotherapy	42/55 76%
Combined	11/33 33%

Serial Section Studies. Fifty-one of the pyriform sinus cancers removed by laryngectomy and radical neck dissection were studied by whole organ serial section of the larynx. It was our intention to find answers to such questions as the following: Are there any predictable patterns of growth and spread of cancer from the pyriform sinus? Are there any characteristics of the primary growth that indicate likelihood of invasion of the thyroid cartilage, cricoid cartilage, or thyroid gland? How reliable is the gross appearance of a pyriform sinus cancer in estimating safe margins for resection?

TABLE XV
PYRIFORM SINUS CANCER (116)

	No. Cases	N.E.D.	Surv. Rate
Primary Surgery	28	8	29%
Primary			
Radiotherapy	55	2	4%
Combined	33	12	36%

How safe would "conservation surgery" have been in this group?

These 51 cases were treated as follows: primary surgery, 26; preoperative radiation, 19; and surgery for radiation failure, 6.

In the nonirradiated group there was very little about the gross appearance of any one of these 26 pyriform sinus cancers that indicated its potential for local or regional spread. This is due largely to the advanced stage in which most of these lesions were first seen. Of the 26 specimens serially sectioned, 24 had been staged in the most advanced group, T3, so that the exact point of origin within the pyriform sinus could not be determined. In the remaining 25 specimens,

the growth pattern as observed in serial sections was distorted by preoperative radiotherapy.

Of the six radiation failures, two had no identifiable cancer on serial section beyond the biopsy site. Of the 19 combined treatment cases, ten had identifiable residual cancer; five showed a few small nests of "burned out" cells that probably represented the original disease and in four there was no identifiable cancer. On the other hand, most of these 19 cases still had positive cervical nodes.

There was an opportunity of studying the accuracy of lymph node staging in all but four of these 51 cases. In over half the cases in which the nodes were clinically negative, (N0, N1a, N2a) cervical metastasis was found histologically (13/22) (Table XVI).

TABLE XVI
FIFTY-ONE SERIALY SECTIONED
SPECIMENS. CERVICAL NODE
INVOLVEMENT

	Number	Histo- logically Positive	Unknown
Clinically Negative	22	13	3
Clinically Positive	29	21	1

Of the 29 clinically positive necks, 21 were proven histologically. The other cases were among those treated by radiotherapy or preoperative irradiation so that the disease in the nodes may have been cured or masked.

Pyriform sinus cancer may spread medially into the larynx, displacing and fixing the lateral wall of the larynx so as to suggest a transglottic cancer, particularly one that may have arisen in the ventricle (Fig. 1). Vocal cord immobility may also be due to infiltration of the posterior crico-arytenoid muscle by cancer, to invasion of the crico-arytenoid joint, or to invasion of the recurrent laryngeal nerve trunk by cancer.⁴ These

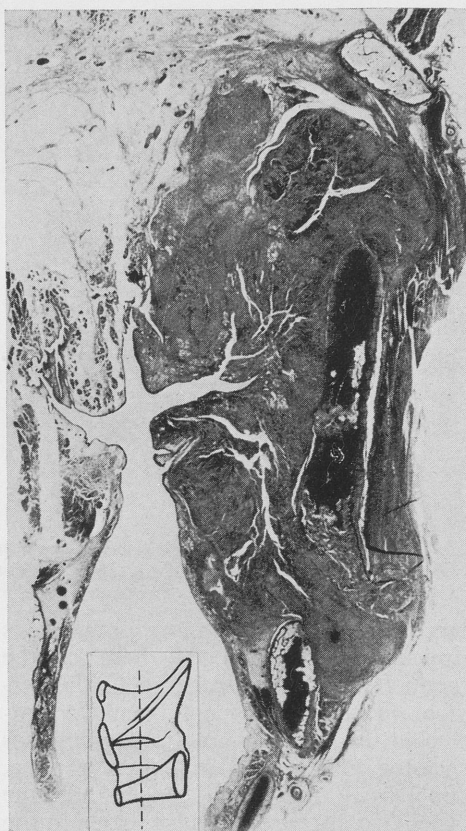


Fig. 1. Extensive infiltration of cancer from the pyriform sinus into the adjacent larynx. This pattern often resembles transglottic cancer, but usually remains submucosal for the main part. The lower border of the thyroid cartilage in this specimen has been invaded by the tumor. Note the tendency for the cancer to escape from the larynx through the cricothyroid membrane.

latter three patterns are usually associated with considerable invasion of the thyro-arytenoid muscle. Olofsson and vanNostrand have made similar observations.⁵

Larger growths may extend from the pyriform sinus on to the lateral or posterior walls of the hypopharynx or in the opposite direction across the upper postcricoid area to involve the opposite pyriform sinus.

Next in frequency to the pattern of spread into the adjacent supraglottic

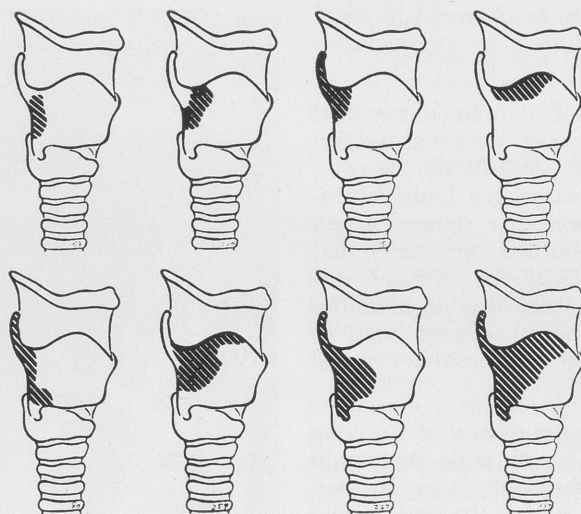


Fig. 2. Pattern of invasion by pyriform sinus cancer into the thyroid cartilage. Twenty specimens showed invasion of the thyroid and/or thyroid and cricoid cartilages.

larynx, and probably more ominous, is upward spread into the base of the tongue. Downward spread into the cervical esophagus has not been the pattern in this material. In three specimens showing involvement of this latter area, one was a postcricoid cancer, and the other two appeared to have arisen in the cervical esophagus and involved the pyriform sinus by upward extension.

In nine specimens the bulk of the neoplasm occupied mainly the medial wall of the pyriform sinus. Obviously none of these nine invaded the thyroid cartilage. Seven had been treated by preoperative irradiation, and growth patterns distorted. Three, however, showed no residual cancer. In four, small nests of "burned-out" tumor cells were seen. One nonirradiated specimen showed tumor cells close to the arytenoid cartilage and the other case recurred at the margin of resection after a partial laryngopharyngectomy.

By contrast, the 22 specimens which showed invasion or destruction of the thyroid or cricoid cartilage on serial section had all shown involvement of the lateral wall of the pyriform sinus at laryngoscopy and in the gross specimen.

Pyriform sinus cancer eroded the thy-

roid cartilage in 20 of 51 specimens, usually along the posterior edge, although the cricoid cartilage alone was invaded in two of 51 specimens. Cricoid invasion is usually observed as an extension of the same process in the thyroid ala. The risk of direct invasion of the superior lobe of the thyroid gland in these cases is obvious (Figs. 2, 3).

Preoperative irradiation appeared to have no destructive action on the laryngeal framework. Among 25 specimens which had been irradiated before operation, 13 showed dissolution limited to the postero-lateral portion of the thyroid ala or cricoid ring, the same pattern as seen in the nonirradiated cases (10/26), where the destruction was obviously caused by cancer. It would appear, then, that the portion of the thyroid ala or cricoid ring that had been invaded by cancer simply disappeared under radiation therapy.

The thyroid lobe on the involved side was usually not removed if it did not appear to be near tumor or if there was no induration palpable in the superior lobe. However, the pattern of erosion of the thyroid and cricoid cartilages indicates that this is not a safe practice, even when the superior lobe can be

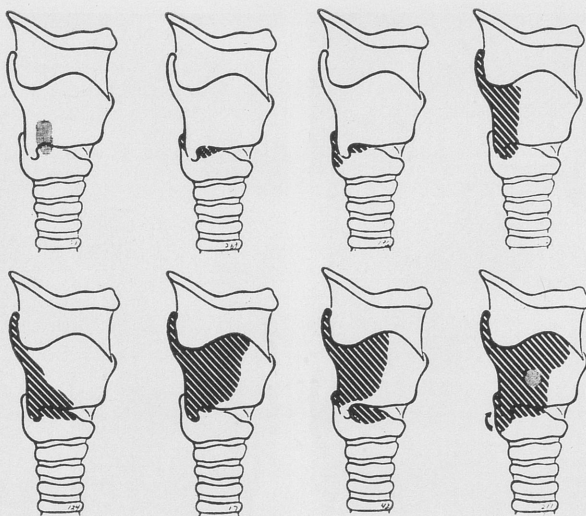


Fig. 3. Patterns of invasion in those specimens in which the cricoid cartilage was involved. Two specimens showed invasion limited to the cricoid cartilage. In one of the latter, both pyriform sinuses contained cancer. The specimen represented in the upper left corner diagram showed erosion only on the inner cortex of the thyroid and cricoid cartilages.

easily displaced off the larynx, and when there is no obvious involvement of the laryngeal framework by the growth.

Ogura observed that the gland may be invaded even if the cancer has not eroded through the thyroid cartilage. In addition to lymphatic tumor emboli, he demonstrated a case showing tumor within vascular channels of the gland.⁶ This would suggest that involvement of the thyroid gland or the adjacent paratracheal nodes may have been responsible for the 14 local and regional recurrences among the 22 cases with invasion of the laryngeal framework. The same could be true of the 13 recurrences among the remaining 29 uninvaded cases (Fig. 4).

Histological Differentiation. Of the 22 growths which invaded the laryngeal framework, the degree of differentiation was estimated at 17. Six were well differentiated, four moderately, and seven poorly.

Cervical Node Metastasis. In 38 of the 51 growths, the degree of differentiation was reported by the pathologist. Of 16

well differentiated primary growths, eight had proven metastasis. Of eight moderately well differentiated growths, six had proven metastasis. Of fourteen poorly differentiated growths, seven had proven metastasis.

The metastatic rate is probably higher than indicated by these figures since, in many of these cases, the neck had been included in the field of preoperative irradiation or radiotherapy.

Peripheral Growth Pattern. A pushing edge was seen in five of the 51 specimens. In four there was no invasion of the laryngeal framework. In the fifth, the cancer spilled over the top and presented as a palpable mass under the skin (Fig. 5). Further posteriorly, this tumor destroyed the thyroid cartilage (Fig. 6). Despite their relatively benign appearance on section, this feature did not insure a good prognosis. Two of the five patients died within two years with primary recurrence.

CONSERVATION SURGERY

Serial section studies indicate that pre-

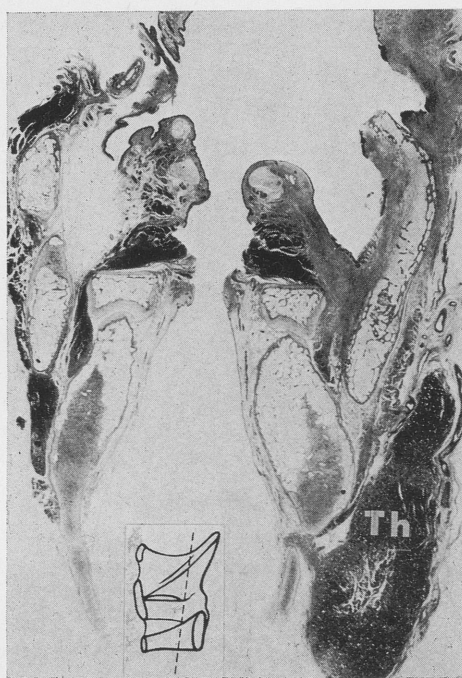

Fig. 4. Relation of superior lobe of thyroid gland to cricothyroid membrane. Cancer escaping from the lower larynx could invade the gland by direct extension. This specimen had been given 5,600 rads five weeks before laryngectomy.

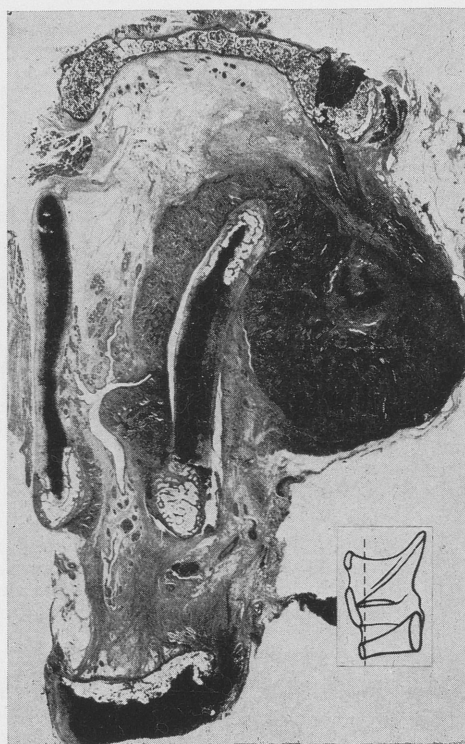


Fig. 5. This growth, characterized by a "pushing edge" escaped through the thyrohyoid membrane and presented as a mass under the skin of the neck. The pyriform sinus apex was clinically invaded by the tumor, and there was extensive destruction of the posterior portion of the thyroid cartilage, as shown in Figure 6.

operative irradiation disqualifies a pyriform sinus cancer for conservation surgery. This is not so much because of the healing problems caused by the scar tissue resulting from irradiation, but rather because of the unpredictable extent of invasion into the larynx and other surrounding structures. Surface presentation of a pyriform sinus cancer rarely reflects the exact extent of invasion even before irradiation. After treatment, not only is the tumor smaller, but also the surrounding normal tissues are shrunk and distorted so that the surgical procedure is hampered by unidentifiable margins. In this regard, Ogura's series of 28 pyriform sinus cancers treated by partial laryngopharyngectomy did not include any cases subjected to preoperative irradiation.⁷

In his 1960 report on partial laryngo-

pharyngectomy for pyriform sinus cancer, Ogura set forth certain criteria for selecting cases suitable for conservation surgery. These included the caution that there must be no involvement of the apex of the pyriform sinus and that the thyroid cartilage must be free of tumor.⁸ The present study confirms the validity of these criteria and illustrates their histological rationale.

Of the 40 growths which involved the lateral wall of the pyriform sinus on laryngoscopy or barium studies, 22 invaded the thyroid cartilage, cricoid ring, or both. The apex of the pyriform sinus was clinically involved by the growth in each of these 22 cases.

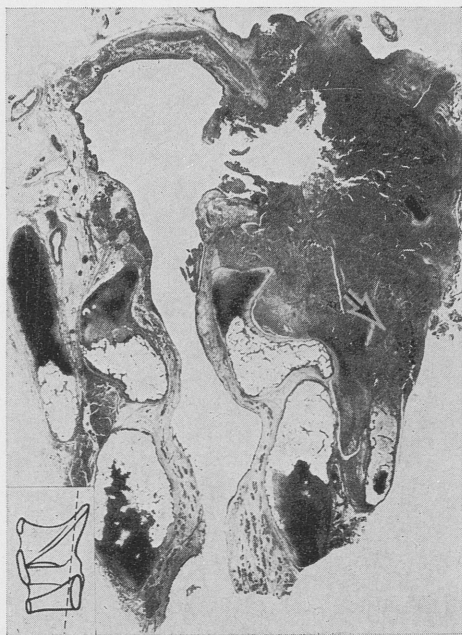

Fig. 6. Destruction of the upper two-thirds of the thyroid ala (arrow) by cancer invading from the pyriform sinus. The tumor was classified as "well differentiated," but the patient died six weeks after operation with pulmonary metastases.

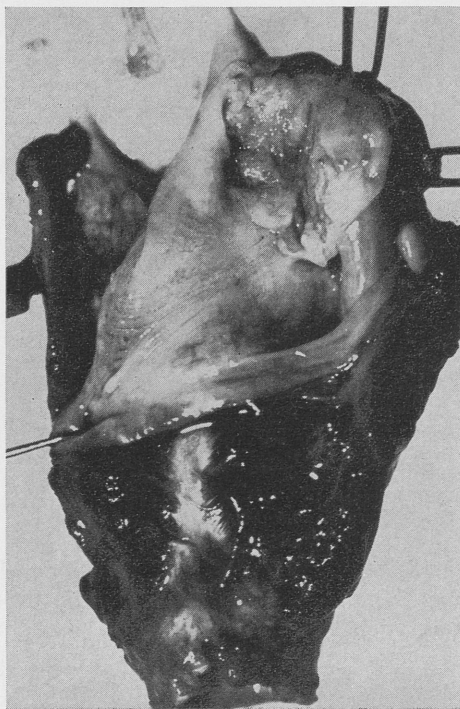


Fig. 7. Cancer of the upper portion of the pyriform sinus with no involvement of the apex. In serial section studies, growths of this type never invaded the thyroid cartilage. It was only among those growths showing clinical involvement of the lateral wall and apex that invasion of the laryngeal framework was frequently observed histologically.

In the remaining 18 cases there was no invasion of the thyroid or cricoid cartilage, and clinical involvement of the pyriform sinus apex was minimal or incidental (Fig. 7). It can be said of our material, then, that every case in which thyroid or cricoid cartilage invasion was found in serial sections had exhibited involvement of the pyriform sinus apex clinically (Table XVII).

TABLE XVII
LATERAL WALL INVOLVED
CLINICALLY (40)

↓ Framework Invaded (22)	↓ Framework Not Invaded (18)
↓ Pyriform Sinus Apex Involved	↓ Pyriform Sinus Apex Involved
 Always	 Rarely

Even though the destruction was usually confined to the posterior portion of the thyroid ala and the upper edge of the cricoid ring, this pattern varied considerably and the extent of invasion could not have been predicted on the basis of surface presentation. Conservation surgery, therefore, would have been entirely inappropriate in any one of these 40 cases with involvement of the lateral wall and apex of the pyriform sinus. In many of our specimens, the saw cut would have traversed cancer in the thyroid ala (Fig. 8).

Of the 47 T3 lesions sectioned, no other feature of the primary growth, such as histological differentiation, appeared to influence the tumor's tendency to in-

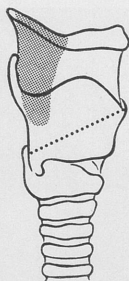


Fig. 8. Stippled area on diagram shows position of pyriform sinus. The dotted line shows the saw cut, usually employed in partial laryngopharyngectomy, which in most of our specimens would have passed through, or very close to the cancer. Clinical involvement of the apex of the pyriform sinus is therefore a contraindication to conservation surgery for cancer in this area.

vade the laryngeal framework. None of the T1 and T2 lesions invaded the thyroid or cricoid cartilages.

Small growths on the medial wall of the pyriform sinus that appeared to be possible candidates for conservation surgery appeared on histological examination to have responded well to irradiation. In the smallest lesion there was infiltration of the soft tissue around the arytenoid cartilage so that the manda-

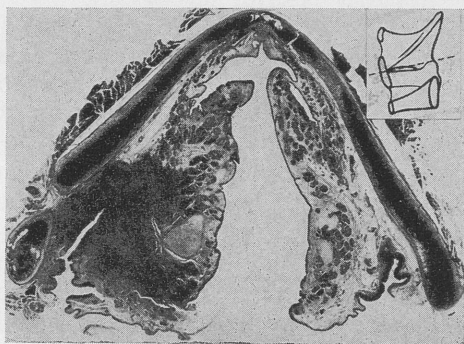


Fig. 9. Horizontal section of specimen in Figure 7 (right side of specimen is on left of picture). Cancer has partly surrounded the arytenoid cartilage and infiltrated the submucosal portion of the false cord.

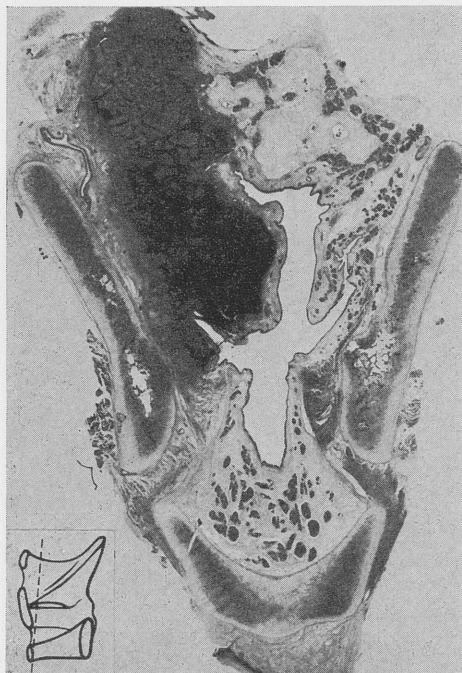


Fig. 10. Cancer invading the false cord and extending downward, lateral to the ventricle. Further extension of this type produces fixation of the true vocal cord, resembling a transglottic growth in this respect. Note the intact mucous membrane of the false cord.

tory arytenoidectomy would have been oncologically unsafe.

Larger growths on the medial and anterior walls showed a significant degree of deep infiltration by cancer cells into the supraglottic larynx (Fig. 9). Cancer invading this region does not follow the usual pattern of supraglottic cancer, but invades downward within the paraglottic space, extending below the level of the ventricle and resembling a transglottic growth in this respect (Fig. 10). It tends to escape from the larynx via the cricothyroid membrane where it may invade the lower border of the thyroid cartilage and the upper border of the cricoid.

REFERENCES

1. *U.I.C.C. and A.J.C. Supplement to TNM Classification of Malignant Tumors*. Geneva, G. de Buren S. A., rev. 1973
2. Harrison DFN: Pathology of hypopharyngeal cancer in relation to surgical management, *J Laryngol Otol* 84:349-367, 1970
3. Jacobsson F: Carcinoma of the hypopharynx, *Acta Radiol [Diagn]* (Stockh) 35: 1-21, 1951
4. Kirchner JA: One hundred laryngeal cancers studied by serial section. *Ann Otol Rhinol Laryngol* 78:689-709, 1969
5. Olofsson J, vanNostrand AWP: Growth and spread of laryngeal and hypopharyngeal carcinoma with reflections on the effect of preoperative irradiation: 139 cases studied by whole organ serial sectioning, *Acta Otolaryngol [Suppl]* (Stockh) 308:1-84, 1973
6. Ogura JH: Surgical pathology of cancer of the larynx. *Laryngoscope* 65:867-926, 1955
7. Ogura JH, Mallen RW: Partial laryngopharyngectomy for supraglottic and pharyngeal carcinoma. *Trans Am Acad Ophthalmol Otolaryngol* 69:832-845, 1965
8. Ogura JH, Jurema AA, Watson RK: Partial laryngopharyngectomy and neck dissection for pyriform sinus cancer: conservation surgery with immediate reconstruction, *Laryngoscope* 70:1399-1417, 1960

RADIATION FAILURES IN CANCER OF THE LARYNX

EMANUEL M. SKOLNIK, M.D.

LAWRENCE MARTIN, M.D.

KING F. YEE, M.D.

MICHAEL A. WHEATLEY, M.D.

CHICAGO, ILLINOIS

SUMMARY — Overwhelming statistics have been published regarding the success of radiation therapy in the management of laryngeal carcinoma. The fate of those patients whose cancers are not controlled by radiotherapy is often left to speculation. An analysis is made of 61 patients with early and advanced laryngeal cancer treated initially with radiation therapy and subsequently operated upon because of recurrent or persistent tumor. Frequently, diagnosis of recurrence is difficult or delayed. Preservation of voice can only be accomplished when recurrence of T₁ and T₂ lesions is detected early and strict criteria are followed. Conservation surgery is not feasible for early lesions which progress after radiation failure. Advanced T₃ and T₄ lesions which become radiation failures also require laryngectomy for salvage. In cancer of the larynx, there is a definite, identifiable group of patients in whom surgery would be advisable as the initial therapy.

Radiation therapy for cancer of the larynx, and especially the glottic region, is receiving increased emphasis today. Its contribution in the management of laryngeal cancer is well known. However, like its surgical counterpart, it is not without its share of failures. But, unlike its surgical counterpart, delay in diagnosis of recurrent tumor after radiation therapy failure is common.

In early vocal cord cancer, the cure rates have been reported to be 80-96%. In Till's report of larynx cancer end results (10,989 patients), presented at the Centennial Conference on Laryngeal Cancer, the initial treatment was radiation therapy for cure in the majority of cases.¹ However, the crude five-year survival for 3,296 T₁N₀ glottic patients was only 72%, and the same survival for 637 T₁N₀ supraglottic patients was only 55%. These crude five-year survival rates do not reveal the status or quality of the voice following therapy. Only cure is reported, and patient survival may not reflect the reliability of the primary

treatment method. Often salvage surgery is required after radiation therapy has failed. Survival, then, does not always correlate with voice preservation.

Both radiotherapists and surgeons would concur that the first opportunity is the best opportunity for cure in cancer of the larynx. The advantages of radiation therapy in preserving laryngeal function have been well outlined by Lederman² who has treated large numbers of patients with early and advanced lesions of the larynx. Unfortunately, the microscopic characteristics of a tumor from a biopsy specimen offer no prediction as to the response of the tumor to radiotherapy.

During the past twenty years, other laryngologists have advocated conservation surgery of the larynx while preserving laryngeal function. The voice in these partial procedures is certainly adequate, and the surgery is not incapacitating. There is a definite group of patients who are best advised to have sur-

From the Department of Otolaryngology, Abraham Lincoln School of Medicine, College of Medicine, University of Illinois at the Medical Center.

TABLE I
CRITERIA FOR PARTIAL
LARYNGECTOMY⁵ FOLLOWING
RADIATION FAILURE

1. The cancer must have been localized originally
2. Regional lymph node metastasis should not be a dominant feature of the disease
3. The original extent of the cancer should be circumscribed by the surgical procedure

gery as the initial therapy. These patients will be identified later. Lederer's classic article on laryngic descriptive discrepancy would support the advantage of having a surgical specimen to examine following initial therapy.³ The confusion and discrepancy of indirect and direct laryngoscopy by different examiners is solved when the entire specimen is in hand. Macroscopic and microscopic correlations can be made. Analysis of the

TABLE II
CRITERIA FOR HEMI-LARYNGECTOMY⁶
FOLLOWING RADIATION FAILURE

1. No opposite cord tumor except anterior commissure
2. No arytenoid involvement except vocal process
3. No subglottic extension >5 mm
4. No cartilage involvement
5. No cord fixation
6. Recurrence should correlate with original tumor

specimen offers prognostic information at once regarding the fate of the patient. This opportunity is lost when radiation therapy is used as the initial treatment.

Radiation failures of T₁ and T₂ laryngeal lesions can be treated by partial laryngectomy with voice preservation. In 1951, Som first reported four cases of radiation failure managed by partial laryngectomy.⁴ Other laryngologists have reported similar success, and Ballantyne and Fletcher (1966)⁵ and Biller, *et al* (1968)⁶ have outlined the criteria for partial procedures following radiation therapy (Tables I and II). However,

TABLE III
LOCATION BY TNM STAGING
SUPRAGLOTTIC (11 Pts.)

	N ₀	N ₁	N ₂	N ₃	Total
T ₁	2	0	0	0	2
T ₂	2	0	0	1	3
T ₃	2	1	0	0	3
T ₄	1	0	1	1	3

these early cord lesions can progress to large tumors when recurrence is not detected early, thus making conservation surgery impossible. For various reasons, T₃ and T₄ lesions best treated with surgery initially are occasionally given radiotherapy for cure. Only total laryngectomy can salvage these patients after radiation failure.

Ideally, the well-trained laryngologist would: a) avoid failure by choosing the

TABLE IV
LOCATION BY TNM STAGING GLOTTIC
(49 Pts.)

	N ₀	N ₁	N ₂	N ₃	Total
T ₁	15	2	0	0	17
T ₂	9	0	0	0	9
T ₃	15	2	0	0	17
T ₄	2	4	0	0	6

appropriate initial therapy, b) detect failure early, and c) manage and salvage these failures by using the appropriate surgical therapy.

METHODS AND MATERIALS

Sixty-three patients were evaluated by the otolaryngology staff as radiation failures of the larynx during 1955-1974. Two patients were excluded from the report because they developed epidermoid carcinoma in a different site at 84 months (supraglottic primary) and at 79 months (glottic primary) after initial radiation therapy. This development was considered to be evidence for a second primary carcinoma of the larynx. There were 11 supraglottic, 49 glottic, and 1 subglottic cases for analysis. The location by TNM staging is shown in Tables III and IV for the supraglottic and glottic groups, respectively. The lone sub-

TABLE V
STATUS OF SUPRAGLOTTIC RADIATION
FAILURES (11 Pts.)

<i>Patients</i>	<i>Status</i>
5	A \bar{s} D
0	A \bar{c} D
1	D \bar{s} D
5	D \bar{c} D
Average recurrence	5.3 Mo
Average survival	42 Mo
A \bar{s} D — Alive without disease.	
A \bar{c} D — Alive with disease.	
D \bar{s} D — Dead without disease.	
D \bar{c} D — Dead with disease.	

glottic carcinoma was staged T₄N₀. There were no glottic carcinoma *in situ* patients. There were 56 males and only five females in the series. Age range was from 39 to 80 years. A history of excessive tobacco and alcohol was elicited in more than 80% of the patients.

Reasons for radiation therapy as the initial treatment are not individualized. Patients with early, as well as advanced, lesions had refused surgery originally and were treated with radiotherapy for cure. Several patients were referred as radiation failures. Radiation therapy had been deemed the best treatment initially by the referring physician and/or radiotherapist. Diagnosis of recurrence was made and institution of surgical treatment was then done in our department. All patients were originally treated for cure by ⁶⁰Co (Cobalt) with at least 6,000 R over a 6 to 7 week period.

Detection of recurrence or persistent disease was usually made by direct laryngoscopy and biopsy. Laryngogram, x-roradiogram, and tomograms were helpful in assessing the extent of recurrence prior to endoscopy. Often, repeat biopsies were necessary to confirm the diagnosis. Occasionally, microscopic laryngoscopy with supravital staining was needed. Thyrotomy or laryngofissure was also used in order to obtain sufficient tumor for analysis.

On two occasions, patients presented with aspiration due to fixed vocal cords and pain due to perichondritis. In both instances, biopsies were insufficient for diagnosis of recurrence. In the first patient, tracheotomy had to be done prior to repeated endoscopy so as not to compromise the airway. Laryngectomy without positive biopsy was considered in the second patient until deeper sections of the first biopsy revealed cancer.

TABLE VI
SURGICAL PROCEDURES FOR
SUPRAGLOTTIC RADIATION FAILURE
(11 Pts.)

Supraglottic laryngectomy	1
Supraglottic laryngectomy RND	1
Laryngectomy	3
Laryngectomy RND	4
Laryngopharyngectomy and RND	1
Contralateral RND	1

RESULTS

Each of the three distinct regions of the larynx is analyzed separately.

Supraglottic. The status of the 11 radiation failures is shown in Table V. All failures occurred within nine months; the average recurrence was at 5.3 months, and the average survival after initial therapy was 42 months.

Table VI indicates the surgical procedures for the supraglottic patients. Ta-

TABLE VII
SUPRAGLOTTIC SALVAGE BY SITE AND
VOICE PRESERVATION

	<i>Pts.</i>	<i>Salvage</i>	<i>%</i>	<i>P.P.*</i>
T ₁	2	1/2	50	0
T ₂	3	2/3	67	1
T ₃	3	1/3	33	0
T ₄	3	2/3	67	2
	11	6/11	55	3

*P.P. — Partial procedure successful in preserving voice. (Patient had a contralateral neck dissection only.)

ble VII reveals salvage by initial site and if a partial procedure was successful in preserving the voice. Salvage by surgery overall was 6/11 (55%). Only two patients had partial procedures; the others required at least laryngectomy, except for one patient who underwent contralateral radical neck dissection only. The T₄N₀ patient remains free of disease seven years after supraglottic laryngectomy and radical neck dissection. Residual dis-

TABLE VIII

SUPRAGLOTTIC RADIATION FAILURES
(11 Pts.) COMPLICATIONS AFTER
SURGERY

	Pts.	%
Fistula	2	18
Carotid Blowout	2	18
Postop. bleeding	1	9
Wound infect./dehis.*	5	45

*Infection/dehiscence

ease was detected at three months after radiation therapy, however. The T₂N₀ (epiglottic) patient has required a permanent tracheotomy following supraglottic laryngectomy. She is 80 years old. The T₄N₃ patient has had a contralateral radical neck dissection after control of the primary lesion and ipsilateral neck with radiation therapy. Her follow-up is limited to 13 months.

TABLE IX

STATUS OF GLOTTIC RADIATION
FAILURES (49 Pts.)

Patients	Status
15	A \bar{s} D
0	A \bar{c} D
7	D \bar{s} D
25	D \bar{c} D
2	LTF

Average recurrence 13.5 Mo

Average survival 39.2 Mo

Complications for the supraglottic group are noted in Table VIII. Two patients expired with carotid artery blowout.

Glottic. The status of the 49 radiation failures is shown in Table IX. All failures occurred within 42 months; the average recurrence was 13.5 months, and the average survival after initial therapy was 39.2 months.

Table X indicates the surgical procedures for the glottic patients. Table XI reveals salvage by initial site and if

TABLE X

SURGICAL PROCEDURES FOR GLOTTIC
RADIATION FAILURES (49 Pts.)

Corpectomy	2
Hemilaryngect. (vert.)	4
Laser(s)	1
Laryngectomy	25
Laryngectomy and RND	16
Laryngopharyngectomy and RND	3
Contralateral RND	4

a partial procedure was successful in preserving the voice. Salvage by surgery, overall, was 22/49 (45%). Only five patients could be salvaged by partial laryngectomy. Two patients had successful corpectomies by thyrotomy. Four patients underwent (vertical) hemilaryngectomy for salvage, but one patient (T₂N₀) ultimately underwent laryngectomy and staged bilateral radical neck

TABLE XI

GLOTTIC SALVAGE BY SITE AND
VOICE PRESERVATION

	Pts.	Salv.	%	P.P.*
T ₁	17	8/17	47	5
T ₂	9	6/9	67	0
T ₃	17	7/17	41	0
T ₄	6	1/6	17	0
	49	22/49	45	5

*P.P. — Partial procedure successful in preserving voice. (Patient had a contralateral radical neck dissection only.)

dissection to control persistent disease. He remains free of disease at 54 months.

A 69-year-old male initially had radiotherapy for cure for an early cord lesion (T₂N₀). Recurrence developed at 16 months after several biopsies were taken on different occasions. Transoral laser surgery was utilized for the recurrence, but he ultimately required laryngectomy. He died at 22 months from pulmonary metastases due to bronchogenic carcinoma.

TABLE XII

GLOTTIC RADIATION FAILURES
(49 Pts.) COMPLICATIONS AFTER
SURGERY

	Pts.	%
Fistula	7	14
Carotid blowout	0	0
Postop. bleeding	2	4
Wound infec./dehis.	5	10
Slough	4	8
Stomal recurrence	4	8

Four patients had contralateral radical neck dissection for control of neck recurrence. The aforementioned first patient (T_2N_0) underwent (vertical) hemilaryngectomy for recurrence at 24 months; at 36 months he required laryngectomy and radical neck dissection; and at 48 months, he underwent contralateral radical neck dissection. He is free of disease at 54 months. The second patient (T_4N_0) is free of disease at 24 months after undergoing laryngectomy and staged bilateral radical neck dissection. The third patient (T_4N_1) required laryngopharyngectomy and staged bilateral radical neck dissection for recurrence at four months. Multiple reconstructions were necessary for partial neck flap slough before this patient expired after 24 months with disease. The fourth patient (T_1N_0) died with stomal disease at 53 months following laryngectomy and staged bilateral radical neck dissection for recurrence detected at 41 months.

Complications are noted in Table XII, including stomal disease. A total of four patients had stomal recurrence, and two of these patients had original T_1N_0 lesions. Five patients had partial neck flap slough requiring further surgery including the use of regional pedicle flaps.

Subglottic. The lone subglottic patient (T_3N_0) failed at ten months and died with disease after 24 months. Extensive recurrence was noted and the patient developed a fistula and a wound infection/dehiscence postoperatively.

DISCUSSION

Failure rates in carcinoma of the larynx vary with the extent of the tumor and the anatomical site of origin. Supraglottic cancer is less responsive to radiation and more apt to develop metastases than glottic cancer. Fifty-five percent of the supraglottic patients were salvaged by surgery, but only three patients have voice preservation. At least five patients had lesions amenable to supraglottic laryngectomy initially.

Salvage after radiation therapy is well documented for early glottic lesions. Excellent salvage with voice preservation for early glottic lesions (T_1 and T_2) has been reported by Biller, *et al*⁶ in 14 of 18 patients. Norris also reported similar results⁷ for ten of 12 comparable patients. These patients were obviously well followed and recurrence detected early. Biller, *et al* also advocate hemilaryngectomy as the treatment of choice for true vocal cord cancer extending beyond the confines of the membranous cord; they report a three-year tumor control rate of 77% with hemilaryngectomy when strict criteria are maintained.⁸

Only 14 of 26 T_1 and T_2 patients in the present series were salvaged by surgery, and the voice was preserved in only five of these patients. We can only speculate what the outcome for these patients with early cord lesions might have been had they not been given radiation therapy.

Salvage for advanced glottic radiation failures is not well documented. Only 8 of 23 T_3 and T_4 patients were salvaged in this series. Nineteen of these patients required radical neck dissection with laryngectomy. Four patients ultimately required contralateral radical neck dissection. Microscopic node metastases may occur during the course of radiation therapy, but clinical evidence may not become apparent until much later.

Early cord lesions are not commonly seen in our department. Most of the patients present with advanced laryngeal lesions. We are concerned about identifying the patients who are likely to become

radiation failures. This group can be selected for conservation or ablative laryngeal surgery. Many of our patients are from the lower socioeconomic class and have abusive tobacco and alcohol habits. It is difficult to explain to these patients the nature of their cancerous process and to turn them from their "suicidal habits." These same patients are unreliable in receiving radiation therapy and follow-up appointments. Relentlessly, they continue their habits during and even after treatment. Often, they present several months after receiving radiation therapy with fungating tumors, neck metastases, and complications such as fistula and aspiration pneumonia. True, frequently these patients initially refuse surgery and are given radiation therapy as an alternative. However, this group of patients and their families need to be informed and even strongly urged that surgery may be the best initial therapy.

Another group of patients, usually referred to a university hospital for laryngeal cancer, are mental patients and inmates of penal or correctional institutions. For security and other logistic reasons, these patients are best treated with conservation surgery for early lesions and laryngectomy for advanced lesions.

Financial assistance is often required for transportation and accommodation by patients undergoing six weeks of radiation therapy. State and national health coverage is not available in this country to provide these funds for transportation and accommodation. Frequently, the radiation center is miles from the patient's home. Often the cancer victim is the breadwinner of a large rural family, and the time and expense involved with daily therapy may be exorbitant. Definitive surgery for these patients may be the treatment of choice. The family is often relieved to know that the entire tumor was removed by surgery.

Elderly patients seem to do better with surgery as primary therapy for laryngeal cancer. Thirty-five of the patients in the series were 60 years of age or older. There were no operative deaths,

TABLE XIII
POSTRADIATION COMPLICATIONS¹⁰

1. Laryngeal edema
2. Perichondritis
3. Cartilage necrosis
4. Changes in irradiated skin

and two octogenarians are free of disease at 48 months and 53 months.

Regular follow-up at close intervals is mandatory for all patients who have undergone radiation therapy for laryngeal malignancy. Brewer has detailed the signs and symptoms of early laryngeal disease in a recent report.⁹ These subtle changes may be of aid in the diagnosis of recurrent cancer, and they should be investigated thoroughly when present.

The effects of radiation therapy may mask early recurrence and make diagnosis both difficult and delayed. Lederman noted four postradiation complications in 1970:¹⁰ 1) laryngeal edema, 2) perichondritis, 3) cartilage necrosis, and 4) changes in irradiated skin (Table XIII). Protracted postradiation edema is the most common factor responsible for the delay in diagnosis of recurrence. Ward, *et al*¹¹ found a high incidence of residual cancer in patients who had persistent edema six months after completion of radiotherapy. In their series of 43 cases who met this criteria, 23 patients had recurrent carcinoma. Many of these patients had original T₁ and T₂ lesions. Only six of these patients were salvaged, and no conservation procedures with voice preservation were done.

With this in mind, repeat biopsies at 6- to 8-week intervals are recommended when the index of suspicion for recurrence is high. Deep biopsy is usually required in the postradiation state for the mucous membrane overlying the residual tumor may be normal except for the edema. Multiple biopsies are usually necessary because the recurrence may be present in tiny nests of cells. Multiple biopsies are discouraged when evaluating a recurrence for possible conservation

surgery because the tumor margin may become indistinct.

At times we have had to resort to microlaryngoscopy with supravital staining under general anesthesia and thyrotomy for definitive diagnosis of recurrence. Toluidine blue will only identify residual surface cancer; however, tumor deep in the laryngeal musculature will not be stained. Thyrotomy or laryngofissure offers direct vision, and this technique can be a good diagnostic tool when recurrence is suspect. Frozen section can be obtained, and, if applicable, hemilaryngectomy can then be done. Consent should also be obtained for total laryngectomy when this procedure is considered.

On occasion, laryngectomy without a positive biopsy has been considered when the larynx becomes a functionless organ and is hazardous to the patient's health. Fixed cords causing aspiration and sepsis and occasionally perichondritis with actual cartilage necrosis may be enough evidence of recurrence to warrant laryngectomy. In these unfortunate patients, aspiration will not cease until the larynx is removed.

Late recurrence is not unusual in glottic carcinoma treated initially with radiation therapy. Four glottic failures in the series did not occur until 36 months or later. Follow-up every three months (or sooner if symptoms warrant) is recommended even three years after the initial therapy. Long term follow-up may reveal a second primary carcinoma of the larynx. Both patients excluded from the study because of the development of a new primary lesion continued to smoke and imbibe alcohol. The role of radiation therapy in this sequence is unknown.

Modern training in otolaryngology and facial plastic and reconstructive surgery includes the principles of regional pedicle flaps. Not infrequently, multiple flaps were used to reconstruct the hypopharynx, cervical esophagus, and cervi-

cal neck defects after radiation failure. Expertise in the use of these flaps in heavily radiated tissue is essential. If the radiotherapist and the laryngologist are not aware of the potential reconstructive problems, it may be wise to refer the patient where a definitive initial procedure may be done. Only a well-trained, creative surgeon utilizing pedicle flaps can reconstruct these patients.

CONCLUSIONS

From the findings and implications in this series of patients who have been radiation failures in cancer of the larynx, several points can be made.

Total patient consideration is necessary in planning the initial therapy. There is an identifiable group of patients who do better with conservative or ablative surgery of the larynx. Surgery offers a surgical specimen which can be analyzed to better evaluate a patient's prognosis.

Survival rates in cancer of the larynx following radiation therapy should not be interpreted to mean that the voice is always preserved. Close follow-up after radiation therapy is mandatory. Recurrence may not be evident until after 36 months. Laryngeal edema persisting longer than six months after the initial radiotherapy may indicate recurrent tumor. Repeat biopsies at 6- to 8-week intervals are necessary when recurrence or persistence of tumor is suspected. Deep biopsies are emphasized since tumor cell nests may be present in the submucosal tissue. Microlaryngoscopy and thyrotomy occasionally are necessary in order to diagnose recurrence.

Laryngectomy without positive biopsy is indicated when the larynx becomes a functionless, hazardous organ. The laryngologist must be willing to accept and undertake the reconstructive problems that arise in radiation failures of cancer of the larynx.

REFERENCES

1. Till JE, Bruce WR, Elwan MA, *et al*: A preliminary analysis of end results for cancer of the larynx. *Laryngoscope* 85:259-275, 1975
2. Lederman M: Radiotherapy of cancer of the larynx. *J Laryngol Otol* 84:867-896, 1970
3. Lederer FL: Laryngic descriptive discrepancy. *Ann Otol Rhinol Laryngol* 72:396-415, 1963
4. Som ML: Limited surgery after failure of radiotherapy in the treatment of carcinoma of the larynx. *Ann Otol Rhinol Laryngol* 60:695-703, 1951
5. Ballantyne AJ, Fletcher GH: Preservation of the larynx in the surgical treatment of cancer, recurrent after radiation therapy. *Am J Roentgenol Radium Ther Nucl Med* 99:336-339, 1967
6. Biller HF, Barnhill FR Jr, Ogura JH, *et al*: Hemilaryngectomy following radiation failure for carcinoma of the vocal cords. *Laryngoscope* 80:249-253, 1968
7. Norris CM, Peale AR: Partial laryngectomy for irradiation failure. *Arch Otolaryngol* 84:558-562, 1966
8. Biller HF, Ogura JH, Pratt LL: Hemilaryngectomy for T₂ glottic cancers. *Arch Otolaryngol* 93:238-243, 1971
9. Brewer DW Sr: Early diagnostic signs and symptoms of laryngeal disease. *Laryngoscope* 85:499-515, 1975
10. Lederman M: Radiotherapy of cancer of the larynx. *J Laryngol Otol* 84:867-896, 1970
11. Ward PH, Calcaterra TC, Kagan AR: The enigma of postradiation edema and recurrent or residual carcinoma of the larynx. *Laryngoscope* 85:522-529, 1975

DISCUSSION OF THE PREVIOUS THREE PAPERS

DANIEL MILLER, M.D. (Boston, Massachusetts): I have certainly enjoyed these brilliant papers. There is too much to swallow all at once, but I detect something going on here that caused me to get up to say a few words.

First, there appears to be a feeling of some sort for downgrading irradiation therapy in the management of cancer of the larynx.

In this surgical society he who speaks for radiotherapy sounds like heresy, but apropos of the report of Dr. Lawson and Dr. Som yesterday and of today's reports, I am a little concerned that these statistical surveys do not really tell the whole story.

We are all trying to preserve the larynx, to preserve the voice and get rid of the cancer and we do it with different techniques.

I really feel that no one can really state that a cancer, a second primary, is due to radiotherapy under an average of about ten years from previous statistics, however, this is always a moot point.

Second, on this most recent excellent paper, by Dr. Skolnik and Dr. Martin's group, it would appear that multiple biopsies of the edematous larynx are fraught with lots of troubles and one may find that the perichondritis produced by biopsy cannot be controlled and will necessitate an ablative laryngectomy; instead of being a little more cautious and using better clinical judgment in observing the patients before biopsy, which you recommend, of course.

Also, the use of thyrotomy in a radiated

larynx, in a full course irradiated larynx for biopsy, is fraught with lots of troubles and I must say a word of caution about the attempt to make the diagnosis of recurrent cancer in this fashion, or by a biopsy, every eight weeks.

On the other hand, the earlier the diagnosis of recurrent cancer, the better the prognosis.

Dr. Kirchner's brilliant paper as usual has helped us with prognosis, yet it is interesting, if my figures are correct, that 21 out of his 29 patients who had nodes that were still positive on postirradiation did not match our own report where we found that we had probably sterilized 18 out of 36, showing that radiation therapy does have a greater effect on nodes than had been thought. The important thing, however, is that when nodes are positive in the radical neck dissection in such patients with pyriform fossa lesions, this prognostically is a very bad sign for cure in our own report.

And, my final comment concerning the paper of Dr. Krause and his group in Iowa, I think this is a magnificent step forward. He has made a scratch on the surface of the tumor cell, but it has been a deep scratch, I think, in developing this technique of immuno-assay of the antigen for epidermoid carcinoma.

CHAIRMAN DOUGLAS P. BRYCE, M.D.: If I may be allowed to add a comment, I think the combination therapy, salvage conservation therapy following radiotherapy, is certainly a very desirable therapeutic procedure. But I agree with Dr. Miller that biopsy may not be very helpful. I think clinically the decision whether a surgical procedure will have to be

done or not must be made by the appearance as well as the history of the disease, rather than by the diagnosis.

MAX L. SOM, M.D. (New York, New York): I enjoyed these three papers immensely.

I would like to dwell upon the need for multiple biopsies following radiation therapy. I refer to cordal cancer treated by radiation.

I think the significance of the persistence of arytenoid edema is, of course, great, but I want to point out that unilateral edema, edema of the arytenoid on one side, usually on the side of the initial lesion, is much more significant as an indication of the persistence of tumor than bilateral edema incident to radiotherapy. This, of course, would be more of an indication for a biopsy than the bilateral edema.

The other point I would like to make is in cordal carcinoma, treated by radiotherapy where the voice has almost regained its original tone, that in the follow-up any occurrence of persistent hoarseness, not attributable to an intercurrent infection, or gripe, should be very, very significant of the recurrence or the persistence of the tumor.

In other words; in the patient who, six months, a year or two years, after radiotherapy for cordal carcinoma, has regained and stabilized his voice, if then there occurs a hoarseness not explicable on the basis of a recent upper respiratory condition, I would be more inclined to do a biopsy even in the absence of gross evidence of disease. In my experience, this has usually been associated with the occurrence of tumor following radiation.

JOSEPH H. OGURA, M.D. (St. Louis, Missouri): You do not mind if I step up and take this podium? I was going to refrain from comment. I think the first paper was magnificent.

I want to comment about the second paper, i.e., John Kirchner's, which I think was a splendid paper. I would like, however, to add one other thing to what he did say, "the apex must be free." I am sure there was a little omission. I suspect paraglottic space involvement when the cords are fixed. I look at the false cord area very carefully with pyriform fossa involvement and that is how I can pick this up under direct laryngoscopy.

With regard to the third paper of Dr. Skolnik, the radiation cases, I think their salvage rate is splendid when you consider that these were primarily cases from the lower socioeconomic groups. I think when you try to compare private cases with clinic cases you are always going to wind up with worse results. This is true in our series when we com-

pare our city hospital cases with our private cases. You just cannot achieve the same results.

I think their results are great considering the cases that they had to work with. The results were 50%, or close to it, by conservation surgery. I think they are to be congratulated.

J. RYAN CHANDLER, M.D. (Miami, Florida): There was indeed a great deal of meat in all of these three papers and I certainly intend to peruse them very carefully and critically when they appear in print.

I was struck by the frequency of associated neck dissections in the management of the radiation failures of glottic carcinomas as recorded by Dr. Martin in the last paper.

I have myself had the tendency to perform laryngectomies in practically all instances in patients with stage one and two carcinoma of the larynx who have had recurrent carcinoma after radiation failure. So I would appreciate some clarification as to the indications for the associated neck dissections in the material from Chicago.

EMANUEL M. SKOLNIK, M.D. (closing): Incidentally, Dr. Miller, we did not present this paper with the intention of incriminating radiotherapy as treatment and you will recognize that when you read the paper.

What we are trying to show is that in certain areas — I think Dr. Ogura pointed this out very clearly — not every patient can be treated with irradiation and not every patient can be treated with surgery. In our particular center where we are seeing a group of patients who are in the lower socioeconomic strata, they do better with surgery than with irradiation.

Another point is that many of the patients that we see are chronic alcoholics, many of them have debilitating diseases, and many of them are uncooperative, so that to subject each patient to extensive irradiation often times produces many complications, much more so than we would expect to find in private practice with our surgical patients.

As to the comment Dr. Chandler alluded to about neck dissections: 24 of these patients were T-3 and T-4 and these are almost always handled by larynx and neck, and as presented in the paper, many of these patients were treated with radiation only because they refused surgery as a primary attack to the problem. Even though we did not recommend irradiation, we did explain to the patient the advantages of surgery. Of course, with the failures, many of them did come to surgery.

REHABILITATION OF THE SHOULDER AFTER RADICAL NECK DISSECTION

W. H. SAUNDERS, M.D.

E. W. JOHNSON, M.D.

COLUMBUS, OHIO

SUMMARY — After classical radical neck dissection with removal of the sternocleidomastoid muscle and division of the spinal accessory nerve, there are certain disabling or disagreeable musculoskeletal defects. This paper describes the muscular deficiencies and gives a set of exercises which can be counted on to minimize the problems.

After classical radical neck dissection with excision of the sternocleidomastoid muscle and division of the spinal accessory nerve supplying the trapezius muscle, there is weakness and deformity, and often pain of the shoulder.

To avoid these postoperative difficulties, some surgeons have advocated grafting between the cut ends of the spinal accessory nerve using the greater auricular nerve. While not a common practice, this procedure does afford adequate neural supply to the trapezius muscle in most instances. Others have performed various types of modified neck dissections in which both the sternocleidomastoid muscle and the nerve supply to the trapezius are spared. Bocca* saves even the internal jugular vein, removing only the fascial compartments around muscles, vessels, and nerves.

Most surgeons still prefer the classical operation to the various modified or conservative procedures. Intent on removal of the patient's malignancy and with consideration for a reasonable cosmetic result, they are apt to ignore the functional deformity resulting from neck dissection. It is for these patients, some

with bilateral radical neck dissections, that we present the following rehabilitative program designed to relieve postoperative pain, early and late, and to restore as much function as possible to the shoulder.

The Normal Trapezius. The trapezius is an important stabilizer of the scapula. It has three parts, upper, middle, and lower, and is a large muscle, extending inferiorly farther than is commonly realized. It resembles a fan, attaching at one end to the vertebrae and at the other to the scapular spine. Its function includes hugging the scapula tightly to the posterior thoracic cage during movements of the arm, rotating the scapula upward and downward, and retracting it. Participating muscles which compensate for loss of the trapezius are the levator scapulae and the rhomboids (Figs. 1-2).

The usual test for trapezius function, having the patient shrug his shoulder against resistance, tests chiefly the upper trapezius. A better test, or an additional one, is to have him hold both arms in full abduction above his head while the examiner pulls each arm downward laterally against resistance (Fig. 3). The

*Bocca E: Personal communication.

From the Departments of Otolaryngology and Physical Medicine, The Ohio State University College of Medicine, Columbus, Ohio.

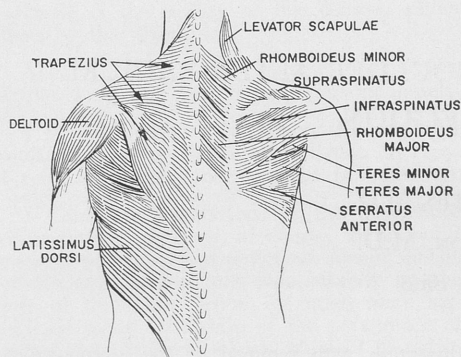
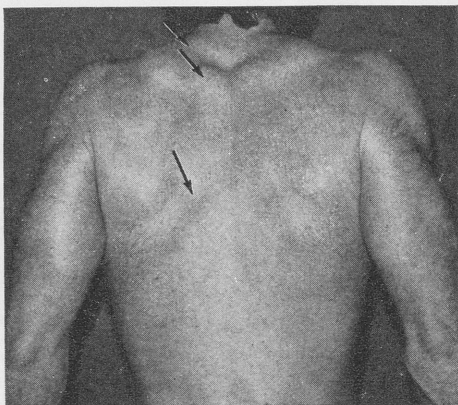


Fig. 1. Muscles of back.

Fig. 2. Trapezius, indicating its three parts.



weakened middle and lower trapezius muscles are demonstrated as one arm is brought down easily while the other is not. Even better testing for the middle and lower segments is done with the patient lying prone, arms outstretched laterally, and thumbs pointed upward in the "hitchhiking" position. Having him raise his arms in the direction of the upward extended thumbs brings these muscles into prominence.

Effects of Paralysis. The major antagonist of the trapezius may be considered to be the serratus anterior which moves the scapula forward and downward when the trapezius is paralyzed. In paralysis, the vertebral border of the scap-

ula becomes flared, particularly inferiorly and laterally (Fig. 4), and this flaring is accentuated when the arm is abducted from the side against resistance. Furthermore, since the scapula must be stabilized and synergistically moved in concert with the humerus (scapulohumeral joint), abduction of the shoulder is apt to be limited. In ten consecutive patients tested by electromyography, all three parts of the trapezius showed complete denervation. Patients with marked loss of shoulder abduction, 70° or less, characteristically try to compensate by contralateral flexion of the trunk (Fig. 5). Even though the trapezius is paralyzed, the shoulder forward flexors may elevate the arm




Fig. 3. Demonstration of how one arm can be pulled downward against resistance, while the other cannot. (Paralysis of the trapezius.)

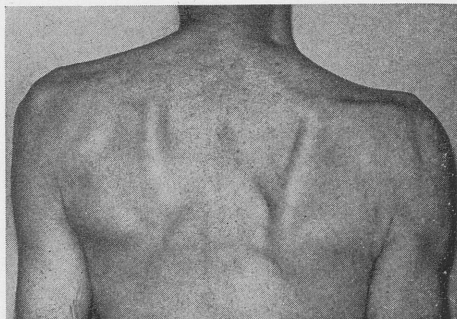

Fig. 4. Prominent vertebral border of scapula in patient with paralyzed trapezius. Also note atrophy of upper portion of the muscle.

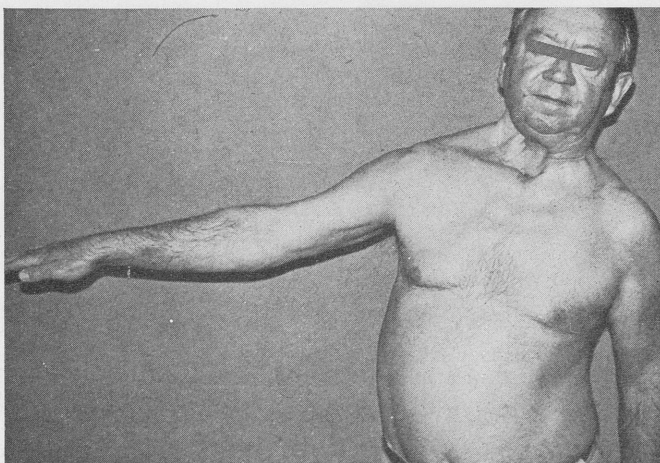


Fig. 5. Maximum abduction patient could achieve. Note compensatory contralateral flexion of trunk. (Compare to Fig. 6.)

180° since the serratus anterior can stabilize the scapula with the arm in forward flexed position (Fig. 6). Thus, it may appear that the patient is abducting the arm, while in reality he is using forward flexors to raise the arm above the head.

Since rotation of the shoulder joint




Fig. 6. Elevation 180° by use of serratus anterior (forward flexor). Failure to note this alternate mechanism for raising arm may confuse examiner regarding trapezius paralysis. (Compare to Fig. 5.)

must accompany abduction, the extremes of external rotation generally are lost because of disuse. Additionally, pain associated with the surgery, at least in the early postoperative weeks, may limit extremes of shoulder motion. The scapulohumeral joint tends to lose motion and in some cases develops a condition best described as periarthrititis or adhesive capsulitis of the shoulder. The characteristic postoperative position of the scapulohumeral complex is forward and downward (Fig. 7).

Functional limitations after neck dis-

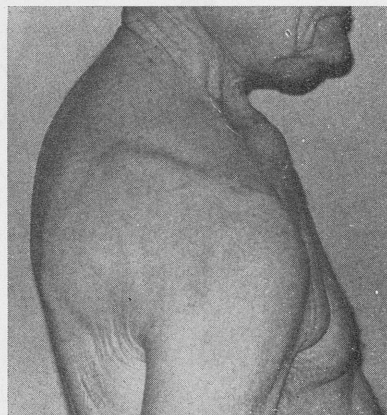


Fig. 7. Characteristic downward and forward position of shoulder complex after neck dissection.

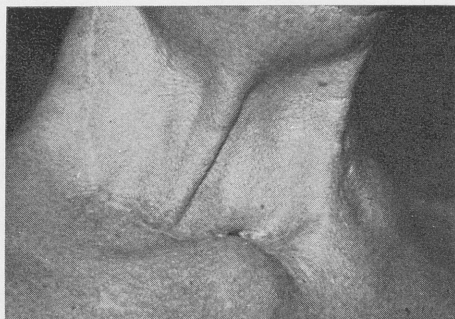
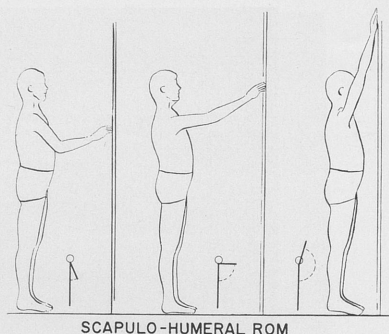


Fig. 8. Osteoarthritis of sternoclavicular joint, one cause of postoperative pain.

section are imposed by: 1) painful motion of the scapulohumeral joint (peri-arthritis), and 2) inability fully to abduct the shoulder because of loss of scapular stability.

Cosmetic considerations include the forward and downward displacement of the shoulder complex. Loss of the sternocleidomastoid muscle produces abnormal contour at the junction of the neck and shoulder as well as a flatness of one side of the neck. Atrophy of the trapezius is particularly evident in its upper portion.

Pain is imposed by stretching of the chief scapular retractor (rhomboids) and the elevator (levator scapulae), initiated by the now unbalanced pull of the

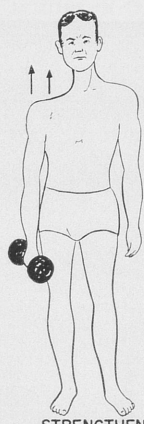


SCAPULO-HUMERAL ROM

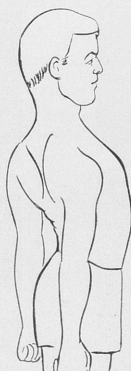Fig. 9. Exercises recommended for patients after radical neck dissection.

serratus anterior. Peri-arthritis of the scapulohumeral joint also is a factor in some patients. A relatively infrequent cause of pain is osteoarthritis of the sternoclavicular joint on the side of the paralysis (Fig. 8). This may occur as the result of long standing stress imposed by the unbalanced scapulohumeral complex.

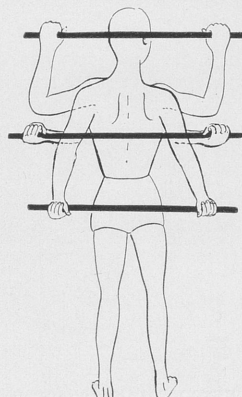
Physical treatment is directed at: 1) pain, using infrared luminous 250 watt lamp at home, 2) strengthening the scapular retractors and elevators, using regressive resistance technique: first ten repetitive exercises at maximum effort, then 8, and finally 5 (Fig. 9), 3) range of motion exercises to increase scapulohumeral joint motion (Fig. 10), and 4)



STRENGTHEN
ELEVATORS & RETRACTORS



PROTRACTORS



STRETCH PROTRACTORS

Figs. 10, 11, and 12. Exercises recommended for patients after radical neck dissection.

active stretch of the shortened scapular protractor (serratus anterior) (Figs. 11, 12).

The patient is instructed in two or three sessions by the physical therapist, then checked every three to four weeks to insure progress. 35 mm color photo-

graphs are useful to demonstrate cosmetic improvement, especially the position of the shoulder complex.

The usual result of treatment is relief of pain, then an improvement in posture, and finally functional improvement of the arm as shoulder motion increases.

Request for reprints should be sent to W. H. Saunders, M.D., Department of Otolaryngology, The Ohio State University College of Medicine, 456 Clinic Drive, Columbus, Ohio 43210.

CARCINOMA OF THE NASOPHARYNX IN CHILDREN

JAMES B. SNOW, JR., M.D.

PHILADELPHIA, PENNSYLVANIA

SUMMARY — Seven children with carcinoma of the nasopharynx have been treated and followed for five years. In this group of patients there were no cranial nerve palsies or radiographic evidence of destruction of the base of the skull. Four of the seven patients are living and well. The development of lymphoepithelioma in two siblings is of great interest from an environmental and genetic point of view. The older sibling developed the clinical manifestations of the tumor at 12 years of age and four years later the younger sibling developed them at 14 years of age. The possible etiologic relationship of carcinoma of the nasopharynx to the Epstein-Barr virus is discussed. The good survival rate in these patients under 21 years of age suggests that the prognosis in carcinoma of the nasopharynx is better in the younger age group than in adults. The management of these patients illustrates that carcinoma of the nasopharynx should be managed as a regional rather than a systemic disease. Systemic drug therapy is sometimes advocated because of confusion over the name lymphoepithelioma on the assumption that these tumors are more related to lymphomas and lymphosarcomas than carcinomas. It is clear that lymphoepitheliomas should be managed as carcinomas.

Carcinoma of the nasopharynx is more common in adults than in children. Seven patients under 21 years of age were treated for carcinoma of the nasopharynx at the University of Oklahoma Health Sciences Center during the ten-year period between 1962 and 1972.

In children, carcinoma of the nasopharynx is often composed of large epitheloid cells with characteristics of malignant cells and normal appearing lymphocytes and is often designated lymphoepithelioma although most authorities consider lymphoepitheliomas to be squamous cell carcinomas.

HISTORICAL ASPECTS

Skull lesions in an Egyptian mummy circa 3000 BC, an ancient Peruvian skeleton, and a medieval English skeleton indicate that carcinoma of the nasopharynx is a very old disease.¹ Bosworth, in 1889, reviewed the literature and added a sixth case of his own.² Durand-Fardel, in 1837, reported the first case.³ Jackson, in 1901, added eight

cases and condemned the use of surgery in the treatment of carcinoma of the nasopharynx.⁴

Dobson's 1924 letter to the editor of the *China Medical Journal* is a landmark in the history of thought regarding the etiology of carcinoma of the nasopharynx.⁵ In this letter he calls attention to the nasopharynx in cases of malignant enlargement of the cervical glands and suggests that the cause of these tumors is exposure to the smoke of candles, kerosene and peanut oil lamps, tobacco, and incense, as well as dry grass and poor quality wood cooking fires. Similar conditions were described by Clifford more recently in Kenya.⁶

INCIDENCE

The incidence of carcinoma of the nasopharynx is low in Caucasian populations and high among the Chinese. Carcinoma of the nasopharynx accounts for 18% of all malignant neoplasms in some reports from China.⁷ Nasopharyngeal cancer comprises 0.25% of all malignan-

From the Department of Otorhinolaryngology and Human Communication, University of Pennsylvania School of Medicine, 3400 Spruce Street, Philadelphia, Pennsylvania.

cies in Caucasian populations and has an incidence of 2 per 100,000 population per year.⁸ In nonwhite populations in the United States (90% Negro), the rates are slightly higher. In Caucasian populations 5.5% of cancers of the head and neck are primary in the nasopharynx, while in Chinese, 82% of the cancers of the head and neck are primary in the nasopharynx.⁹

In nearly every series of carcinoma of the nasopharynx, there are more males than females. The sex ratio is approximately two to one in all races.¹⁰

The clinical manifestations of carcinoma of the nasopharynx occurs at relatively young ages. In Caucasian populations 6% of nasopharyngeal carcinomas occur before the age of 30 years, and 30% occur before the age of 50 years.⁸ The youngest patient with carcinoma of the nasopharynx is a four-year-old girl reported by Lederman.¹⁰ Females contract the disease at an earlier age than males. Chinese patients tend to be younger than patients of other ethnic groups.

ETIOLOGIC FACTORS

The inhalation of known potent carcinogens such as 3, 4- benzpyrene contained in smoke and soot from poorly ventilated cooking fires, incense and tobacco, and the sniffing of snuff have long been considered possible etiologic factors.¹¹ Snuffing by the Bantu appears to increase the risk of carcinoma of the nose and paranasal sinuses but not of the nasopharynx.¹² Industrial exposure to nickel, chromium, arsenic, isopropyl alcohol, and radioactive dusts increase the risk of carcinoma of the nose and paranasal sinuses. The role of incense smoke may be very limited in view of Ho's report from Hong Kong that of 2,000 patients there were only one Taoist temple attendant and one Buddhist nun.¹³

The high incidence among the Chinese probably results from a combination of genetic and environmental factors. Zip-pin, *et al*, in 1962, reported a high incidence of carcinoma of the nasopharynx

in young immigrant Chinese males in the United States. The risk was somewhat less among older immigrant Chinese males and among Chinese males born in the United States.¹⁴ In Kenya, the incidence appears to relate to environmental factors and not to racial factors.

Herrold has induced in rodents squamous cell carcinomas from the nasal cavities to the bronchi experimentally with subcutaneously injected diethylnitrosamine.¹⁵ Dawe has induced nasopharyngeal neoplasms in mice with the polyoma virus, but these tumors are not lympho-epitheliomas or squamous cell carcinomas.¹⁶ Spontaneous neoplasms of the upper respiratory tract in wild and domestic animals occur occasionally in the nose and paranasal sinuses but only rarely in the nasopharynx.¹⁷ It is of interest that nasal carcinomas often occur endemically in horses, cattle, sheep, and pigs. Liang's serological study of carcinoma of the nasopharynx in Chinese suggests that infection with adenoviruses 7 and 12 may be significant.¹⁸

Immunologic similarities exist in patients with Burkitt's lymphoma, nasopharyngeal carcinoma, and infectious mononucleosis. The virus of infectious mononucleosis remained unclassified until recently but has now been placed in the Herpes virus group of the DNA viruses.¹⁹ The evidence that the Epstein-Barr virus (EBV) is the etiologic factor in infectious mononucleosis is that antibodies to the virus appear during the course of the illness, the virus can regularly be recovered from leukocyte cultures of patients with the illness, the heterophile antibody of infectious mononucleosis has been reproduced in monkeys inoculated with the EBV, and immunity to the illness is associated with the presence of the EBV antibodies.²⁰ In lower socioeconomic circumstances, primary EBV infections as evidenced by seroconversions occur earlier in childhood.²¹ The EBV transforms human and simian blood leukocytes into continuous cell lines.²⁰

The EBV is suspected to be etiologic in Burkitt's lymphoma and carcinoma of

the nasopharynx. The EBV was originally isolated from cultured cell lines from patients with Burkitt's lymphoma. Elevated titers of anti-EBV antibodies have been found in patients with Burkitt's lymphoma and nasopharyngeal carcinoma.²² Although significantly high antibody titers to EBV are present in only 45% of patients with Stage I carcinoma of the nasopharynx, the titers are elevated in 100% of patients with Stage V lesions.²³ Treated patients without evidence of recurrence have lower titers. Elevated titers occur in patients with squamous cell carcinoma and lymphoepithelioma.²⁴ The role of the EBV in the etiology of Burkitt's lymphoma and carcinoma of the nasopharynx is obscured by the fact the virus can persist in lymphoid tissue for long periods as a latent infection. Therefore, its presence in these diseases may be on the basis of a previous EBV infection. Although the EBV may not be the etiologic agent in Burkitt's lymphoma and carcinoma of the nasopharynx, it appears to be a necessary factor for Burkitt's lymphoma and carcinoma of the nasopharynx. There is apparently some other unidentified necessary factor.

PATHOLOGIC CHARACTERISTICS

Squamous cell carcinomas consist of epithelioid cells with pleomorphic and hyperchromatic nuclei, prominent nucleoli, and a relatively large cytoplasmic to nuclear ratio. Intercellular bridges, individual cell keratinization, and epithelial pearls are characteristics. In children and young adults, tumors lack these characteristics. The cells may be large with pale staining nuclei, prominent and multiple nucleoli, and poorly defined cytoplasm, and the stroma may contain numerous lymphocytes. Under these circumstances, the term lymphoepithelioma is appropriate.

Regaud introduced the term lymphoepithelioma in 1921 to describe highly radiosensitive tumors composed of a syncytium of anaplastic epithelial cells surrounded by lymphoid cells.²⁵ Schmincke described a similar tumor in the same year.²⁶ The possibility that the tumor

originates from lymphocytes as well as epithelial cells is still debated. The presence of lymphocytes in the metastases tends to support the concept of the mixed origin of the tumor. The presence of the lymphocytes in the primary and the metastases is probably evidence of the immunologic response of the host to the tumor.

CLINICAL MANIFESTATIONS

Carcinoma of the nasopharynx arises from the lateral wall in 37% of patients and from the roof in 32%.¹⁰ It arises from the posterior wall in only 15%. The fossa of Rosenmüller is the site of predilection in the lateral wall. Carcinoma may infiltrate rapidly into the parapharyngeal space, cranial cavity, and orbit.

Eustachian tube obstruction with serous otitis media and a conductive hearing loss was the presenting complaint in 17% of Lederman's patients, and nasal obstruction with rhinorrhea and epistaxis occurred in 38%. Cranial nerve paralysis and lymph node metastases are common presenting complaints. Trotter's triad of unilateral hearing loss, fixation of the soft palate, and neuralgia or anesthesia of the third division of the trigeminal nerve is occasionally seen as the presenting symptom complex. These findings can be explained by invasion of the prestyloid compartment of the parapharyngeal space through the anterior, inferior aspect of the fossa of Rosenmüller through the fascial space surrounding the levator veli palatini muscle.

Mechanism of Spread. The fossa of Rosenmüller is directly adjacent to the parapharyngeal space. It is separated from the parapharyngeal space by the internal lamina of the parapharyngeal fascia. The parapharyngeal space is divided into three compartments by the styloid process and its muscles and fascial attachments as well as the fascia of the carotid sheath: the prestyloid compartment, the retrostyloid compartment, and the retropharyngeal compartment. The prestyloid compartment has as its roof the greater wing of the sphenoid with its foramen spinosum and foramen ovale.

The retrostyloid compartment contains the carotid sheath, the cervical sympathetics, and cranial nerves IX, X, XI, and XII. The retropharyngeal compartment separates the nasopharyngeal mucous membrane and superior pharyngeal constrictor muscle from the prevertebral fascia and muscles, and it contains lymph nodes, in particular a laterally placed node known as the node of Rouviere.

Invasion of the prestyloid compartment of the parapharyngeal space may cause neuralgia, anesthesia, or paresthesia of the mandibular division of the trigeminal nerve and paralysis of the muscles of mastication. The pterygoid muscles may be invaded, and trismus may be produced. The tumor may extend as far as the stylomastoid foramen and cause paralysis of the VII cranial nerve.

Invasion of the retrostyloid compartment of the parapharyngeal space may cause paralysis of cranial nerves IX, X, XI, and XII and Horner's syndrome. From this compartment, tumor can follow the internal jugular vein through the jugular foramen and the internal carotid artery through the carotid canal to gain access to the parasellar area occupied by cranial nerves III, IV, and VI and the ophthalmic and maxillary divisions of the trigeminal nerve and to produce diplopia and neuralgia, anesthesia, and paresthesia of the trigeminal divisions.

Invasion of the cranial cavity through the foramen lacerum, foramen rotundum, and foramen ovale, though rare, may cause paralysis of cranial nerves II, III, IV, and VI (Jacod's syndrome). The VI cranial nerve is vulnerable because of its enclosure in Durello's canal which is relatively inflexible. Often the VI cranial nerve is involved first, then the III, V, IV, and II.¹⁰ In contrast to the situation with orbital invasion, there is no proptosis.

The V cranial nerve is most frequently involved (16%) according to Lederman, but others have found the VI to be most frequently involved. The nerves of the extraocular muscles and the trigeminal are most frequently affected as a

group, and the last four cranial nerves are next most frequently involved as a group. The olfactory nerve is least frequently involved, and the VII and VIII cranial nerves are rarely involved.¹⁰

Invasion of the pituitary fossa is rare and usually does not result in hypopituitarism. The tumor gains access to the pituitary fossa through the sphenoid sinus, and there is usually concurrent involvement of cranial nerves II, III, IV, and VI.

In order for the tumor to reach the orbit, it must invade the nasal cavity and then gain access to the orbit through the maxillary and ethmoid sinuses. This sequence of events is rare. When it occurs, proptosis and paralysis of the nerves of the extraocular muscles may be produced.

Metastases. Carcinoma of the nasopharynx metastasizes early to cervical lymph nodes. Eighteen percent of Lederman's series presented with lymph node enlargement.¹⁰ Clinically evident metastases to cervical lymph nodes were present in 70% of his patients and bilateral in 39%. Primary tumors arising in the roof of the nasopharynx tend to metastasize bilaterally. Males are more likely to present with cervical lymph node metastases than females, and cervical metastases are more likely to be present initially in children than in adults.¹⁰

Metastasis occurs more readily from the roof and lateral wall as compared with the posterior wall. Metastases are often bilateral because the tumor is centrally placed; but even if the primary is distinctly unilateral, the metastases may occur on the contralateral side as well as the ipsilateral side. The route of the cervical metastasis is to the lateral retropharyngeal nodes of Rouviere and then to the superior deep cervical nodes. The superior deep cervical nodes of the jugular chain lie deep to the superior portion of the sternocleidomastoid muscle and are usually the first to enlarge sufficiently to become clinically detectable in carcinoma of the nasopharynx. Metastasis to the node of Rouviere can be sus-

pected when there is paralysis of cranial nerves IX, X, XI, and XII.

In Lederman's series of those who had enlarged cervical nodes, 70% had jugulodigastric nodes, 66% had superior posterior cervical triangle nodes, 34% had jugulo-omohyoid nodes, 28% had spinal accessory nodes, and 20% had inferior cervical nodes.¹⁰ Submaxillary nodes are rarely involved and indicate spread of the tumor to the oropharynx, soft palate, or parapharyngeal space. Direct extension to the parotid compartment and the submaxillary triangle may occur from the prestyloid space.

It is to be emphasized that enlarged lymph nodes in the superior part of the posterior cervical triangle should raise suspicion that the primary site of the lesion is in the nasopharynx.

Metastases may appear in the viscera, skeleton, lung, and central nervous system (CNS). Lederman demonstrated distant metastases in 26 of 218 patients on initial evaluation. Nine were to the viscera, seven were to the skeleton, five were to the lung, two were to the CNS and three were to other sites.

Staging. The staging of carcinoma of the nasopharynx by the American Joint Committee for Cancer Staging and End Results Reporting is adopted from the TNM system of classification of the International Union Against Cancer.²⁷ The sites for the nasopharynx are the posterior superior wall (vault) and the lateral wall. The posterior superior wall extends from the superior border of the choanae to the level of the free border of the soft palate and is limited laterally by the groove between the lateral wall and the base of the skull. The lateral wall extends from the base of the skull to the level of the free border of the soft palate. The size and extent of the primary tumor is described by three "T" categories. The T₁ category describes tumor limited to one site in the nasopharynx. The T₂ category describes tumor extending into two sites in the nasopharynx. The T₃ category describes tumor extending beyond the nasopharynx into the nasal cavities or

oropharynx, into or through bone, to the brain, or into the pterygopalatine fossa.

The presence or absence of lymph node metastasis is described by three "N" categories. The N₀ category indicates no palpable cervical lymph nodes. The N₁ category describes clinically palpable cervical lymph node(s) that are not fixed in which metastasis to the node(s) is suspected. The N₂ category describes clinically palpable cervical lymph node(s) that are fixed in which metastasis to the node(s) is suspected.

The presence or absence of distant metastasis is described by two "M" categories. The M₀ category indicates no distant metastasis. The M₁ category describes clinical and/or radiographic evidence of metastasis other than to cervical lymph nodes. Radiographic evidence of bone erosion at the base of the skull or clinical signs of intracranial extension should be considered as evidence of distant metastasis (M₁).

Patients with carcinoma of the nasopharynx are designated as Stage I who are categorized as T₁ N₀ M₀. Stage II consists of those patients who are categorized as T₂ or T₃ N₀ M₀. Stage III consists of those patients who are categorized as T₁ or T₂ or T₃ N₁ M₀. Stage IV consists of those patients who are categorized as T₁ or T₂ or T₃ N₂ M₀ and T₁ or T₂ or T₃ N₀ or N₁ or N₂ M₁.

DIAGNOSTIC FEATURES

Clinical Evaluation. Carcinoma of the nasopharynx becomes clinically apparent in diverse ways and should be suspected in patients with serous otitis media, nasal obstruction, rhinorrhea, epistaxis, cervical lymphadenopathy (particularly in the superior part of the posterior cervical triangle), and any cranial nerve paralysis.

On physical examination, a granular mass or ulcer may be seen through the nasal cavity. The palate may be deformed by the bulk of the nasopharyngeal mass or its mobility may be limited by paralysis of the levator veli palatini. With visualization of the nasopharynx

by mirror or nasopharyngoscope, the carcinoma characteristically appears as a granular mass. It may be quite bulky or there may be an ulcer instead of a mass. The tumor may spread deep to the mucous membrane and appear as a slight fullness, while the mucous membrane may appear normal. Because of this tendency of carcinoma of the nasopharynx, biopsy through apparently normal mucous membrane is frequently diagnostic.

General anesthesia is necessary to palpate the extent of the primary lesion. The biopsy is also facilitated by general anesthesia. Carcinoma in the nasopharynx produces a firm mass which stands out from any remaining adenoid tissue. If there is no definite mass, the removal of the adenoid tissue in children as in an adenoidectomy is likely to provide the diagnosis.

Roentgenographic Evaluation. Roentgenographic evaluation ordinarily includes a lateral view of the nasopharynx, a submental-vertex view of the base of the skull and tomographs of the orbits, paranasal sinuses, and petrous pyramids. In the lateral view of the nasopharynx, soft tissue masses are contrasted with the air column of the nasopharynx. In children, a soft tissue density projecting from the posterior wall and the roof of the nasopharynx is normally produced by the adenoid tissue. A similar density in an adult raises the possibility of a neoplasm. Normally the air column of the nasopharynx has in the submental-vertex view bilateral convex lateral borders. In obese individuals these convexities disappear. In patients with nasopharyngeal tumors, the air column may become asymmetrical since the tumor may cause a loss of these convexities. The submental-vertex view also provides evidence of destruction of the base of the skull which can be demonstrated in approximately 30% of patients with carcinoma of the nasopharynx.¹⁰ The foramen lacerum, carotid canal, greater wing of the sphenoid bone, and hypophyseosphenoïdal area are particularly likely to be sites of bone destruction. The tumor may en-

ter the carotid canal and thereby the foramen lacerum. The tumor may reach the greater wing of the sphenoid bone intracranially but extradurally through the carotid canal or by direct invasion of the prestyloid compartment of the parapharyngeal space. The foramen ovale and foramen spinosum may become indistinct on the submental-vertex view as destruction of the greater wing of the sphenoid bone occurs. The tumor may destroy the tip of the petrous pyramid through the same intracranial but extradural route. This destruction can be demonstrated particularly well with tomographs of the petrous pyramids. In patients with carcinoma of the nasopharynx who have cranial nerve paralyses, destruction of the base of the skull occurs five times more frequently than in patients without cranial nerve paralyses.²⁸ Carcinoma tends to be more destructive of the base of the skull than are lymphomas and sarcomas.¹⁰

DIFFERENTIAL DIAGNOSIS

In children lymphomas and sarcomas are the lesions most likely to require differentiation from carcinoma. Other possibilities for differentiation include benign tumors such as the juvenile angiofibromas, cysts of the nasopharynx, and the infectious granulomata. The differential diagnosis is based on biopsy of the primary lesion. Neck masses should not be biopsied until the nasopharynx has been inspected and palpated and any suspicious lesion has been biopsied because biopsy of the metastases violates the integrity of the block of tissue that must be removed if radical neck dissection is required. A biopsy of the neck mass may result in implantation of the tumor in the skin and subcutaneous tissue. Even if a histologic diagnosis is obtained from biopsy of the cervical metastases, it is necessary to demonstrate the tumor in the nasopharynx by biopsy prior to the initiation of therapy.

TREATMENT

Radiation Therapy. Radiation therapy is the treatment of choice for carcinoma of the nasopharynx. The full extent of

the primary lesion must be determined as accurately as possible to include all areas involved with the tumor in the treatment fields. Such determinations ordinarily include careful physical examination, the outlined radiographic studies, and examination of the nasopharynx under anesthesia. The radiation should be delivered to all areas bearing the primary tumor and to both sides of the neck whether there is clinically evident metastasis or not. The therapy should be delivered from a supervoltage source and be fractionated at a rate of 150 to 200 rads per day for a total dose of 7,000 rads to the primary lesion and 5,000 rads to each side of the neck.

Surgery. Surgical therapy in the form of a radical neck dissection should be considered for patients in whom cervical metastases remain clinically palpable following radiation therapy. Likewise, patients who develop neck masses subsequent to radiation therapy should be considered for a radical neck dissection. As a general rule, radical neck dissection is indicated only if there is evidence that the primary lesion has been controlled. Clinical and radiographic evidence of control of the primary is usually all that is appropriate; however, if the nasopharynx has a suspicious appearance, biopsy of the nasopharynx should be repeated prior to the radical neck dissection.

Chemotherapy. Chemotherapy is of value in certain symptomatic patients in whom radiation therapy or surgery have failed to control the tumor. Since there is no specific and reliably effective agent for squamous cell carcinoma, chemotherapy is not ordinarily appropriate as the primary form of therapy. In investigative therapy, chemotherapeutic agents are in use in conjunction with radiation therapy and surgery. In patients experiencing pain or other distressing symptoms in which radiation therapy and appropriate surgery have been utilized, Methotrexate®,* blenomyacin, and Adriamycin®**

benefit a small percentage of such patients. Methotrexate appears to be the most reliable and has an acceptable ratio of benefits to complications.

Cryosurgery. Cryosurgery may occasionally be of benefit in the patient in which the primary lesion in the nasopharynx persists following radiation therapy, there is no evidence of local extension beyond the nasopharynx, and there is no evidence of uncontrolled local or distant metastases. In this situation, the persisting tumor may be frozen through a transpalatal approach. This rather aggressive form of treatment may result in palliation and an occasional cure. Relative contraindications to cryosurgery are radiographic evidence of destruction of the base of the skull, cranial nerve palsies, and trismus.

PROGNOSIS

The prognosis for patients with carcinoma of the nasopharynx is adversely affected by cranial nerve paralyzes and destruction of the base of the skull. The five-year survival rate for radiation therapy ranges from 76% for Stage I lesions of the vault to 17% for Stage IV lesions of the lateral wall.²⁹ Although Lederman reports an overall five-year survival rate of 13%, the generally accepted overall five-year survival is 35%.¹⁰ The outcome is very similar whether there are clinically evident cervical metastases or not, apparently because failure results from persistence of the primary tumor in both instances. Female patients have a higher survival rate than male patients. Younger patients have a higher survival rate than older patients. The survival rate according to the American Joint Commission is higher among patients with posterior superior wall lesions as compared to patients with lateral wall lesions.²⁷ The five-year survival rate of Lederman's patients with posterior wall lesions was 26%, while the patients with lateral wall lesions had a 12% five-year survival rate.

* Lederle Laboratories, Pearl River, New York.

** Adria Laboratories, Inc., Wilmington, Delaware.

CASE REPORTS

Seven patients under 21 years of age were treated for carcinoma of the nasopharynx at the University of Oklahoma Health Sciences Center between 1962 and 1972. These patients ranged in age, at the time of diagnosis, from nine to 17 years. Two of the patients were girls, and five were boys. Three of the patients were Negro and four were Caucasian. Four are living and free of disease, and three are dead. The five-year survival rate in this group of patients is 57%.

Case 1. A 12-year-old Caucasian male presented with a right cervical mass in September 1963. A right radical neck dissection was performed, and the histopathologic diagnosis of lymphoepithelioma was made. Subsequently the nasopharynx was biopsied, and the lymphoepithelioma was demonstrated again. He received radiation therapy to the nasopharynx and to both sides of the neck from September to November 1963. He is living and well 11 years after the diagnosis was made.

As a general rule in evaluating cervical masses, the primary lesion should be sought and biopsied rather than biopsying the metastasis.

Case 2. A 12-year-old Negro male presented in November 1963 with complaints of headache, epistaxis, and frequent tonsillitis for one year and with a 2 cm by 2 cm nontender node in the superior part of the right posterior cervical triangle. A tonsillectomy and adenoidectomy was performed in December 1963. The right cervical mass increased in size, and in February 1964 histopathologic reexamination of the adenoid tissue demonstrated a lymphoepithelioma. Radiation therapy to the nasopharynx and to both sides of the neck was carried out from March to May 1964. The patient is now living and well 11 years after the diagnosis was made.

This patient's history demonstrates the essentiality of careful histopathologic study of all tonsillar and adenoid tissue.

Case 3. A 14-year-old Negro male, the younger brother of Case 2, presented in July 1967 with bilateral posterior cervical triangle lymphadenopathy and a mass in the nasopharynx. The nasopharyngeal mass proved to be a lymphoepithelioma on biopsy. From August to October 1967 the patient received radiation therapy to the nasopharynx and to both sides of the neck. A right radical neck dissection was performed for a persistent right cervical mass in December 1967. The patient

developed a staphylococcal wound infection with massive necrosis of the cervical skin flaps and exsanguinated from carotid artery rupture. No tumor was found in the surgical specimen.

The development of the lymphoepithelioma in two siblings is of great interest from an environmental and genetic point of view. The older sibling developed the clinical manifestations of the tumor at 12 years of age, and four years later the younger sibling developed them at 14 years of age. None of the previously proposed environmental etiologic factors could be elicited in this family, and no new factors came to light.

Case 4. A 15-year-old Caucasian male presented with a large left cervical mass in September 1966. The mass in the left side of the neck was biopsied, but the biopsy was not diagnostic. A mass was found in the nasopharynx, and the nasopharyngeal biopsy demonstrated a lymphoepithelioma. Radiation therapy was given to the nasopharynx and to both sides of the neck from September to November 1966. A left radical neck dissection was performed for a persistent left cervical mass in January 1967. No tumor could be demonstrated in the surgical specimen. In March 1967 the proximal portion of the left fibula was resected because of pain in the leg and a radiolucent defect in the fibula. The tissue removed was similar to the primary tumor in the nasopharynx. He remained free of clinically apparent tumor for five years and died in February 1973 of carcinomatosis.

This patient demonstrates the exceptional circumstance in which surgical control of a distant metastasis proved to be beneficial.

Case 5. A 10-year-old Caucasian male presented with sore throat, bilateral lymphadenopathy, fever, and malaise in June 1967. The diagnosis of lymphopithelioma was established by biopsy of the nasopharynx. He was treated with intravenous Cytoxan®* with a good clinical response. Radiation therapy was given to the nasopharynx and to both sides of the neck from August to October 1967. A left radical neck dissection was performed for a persistent mass in the left side of the neck in December 1967. No tumor could be demonstrated in the surgical specimen. A right radical neck dissection was performed for a persistent right cervical mass in April 1968. No tumor could be demonstrated in the surgical specimen. On the third postoperative day, the patient developed sudden upper respiratory obstruction apparently due to edema of the hypopharynx and larynx and had a cardiac arrest. Following resuscitation there was persistent hypotension, and the patient died on the sixth postoperative day.

In spite of clear indications for the radical

* Mead Johnson Laboratories, Evansville, Indiana.

neck dissections, no tumor was found in the surgical specimens. Such aggressive management of carcinoma of the nasopharynx merits continued evaluation.

Case 6. A nine-year-old Caucasian female presented with bilateral cervical lymphadenopathy in April 1969. During the previous seven months, she had had multiple nondiagnostic biopsies of the cervical masses and multiple incisions and drainages of what were thought to be cervical abscesses. In June 1969 a cervical node biopsy demonstrated lymphoepithelioma. Examination of the nasopharynx, oropharynx, hypopharynx, and larynx under general anesthesia failed to demonstrate a primary lesion. The tonsils and adenoids were removed, but no tumor was demonstrated in the specimens. Nevertheless, it was elected to radiate the nasopharynx as well as both sides of the neck. She is now living and well six years after the diagnosis was made.

Case 7. A 17-year-old Negro female presented with a right cervical mass in June 1970. A biopsy of the nasopharynx demonstrated a lymphoepithelioma. The patient received radiation therapy to the nasopharynx and to both sides of the neck from June to August 1970. She is living and well five years after the diagnosis was made.

DISCUSSION

The five-year survival rate in this group of patients under 21 years is 57% and is very good compared to the more usual five-year survival rate of 35% for all age groups. The prognosis for patients with carcinoma of the nasopharynx appears to be better in the younger patient. None of these patients had cranial nerve palsies or roentgenographic evi-

dence of destruction of the base of the skull which have an adverse effect on prognosis.

The high survival rate in these patients illustrates that carcinoma of the nasopharynx in children should be managed as a regional disease rather than a systemic one. Systemic drug therapy is occasionally advocated rather than regional radiation therapy because of confusion over the name lymphoepithelioma. The assumption is sometimes made that these tumors are more related to lymphomas and lymphosarcomas than carcinomas.

No serious complication of radiation therapy has so far been encountered in this group of patients.

Five radical neck dissections (RND) were performed in four patients. One of these was performed prior to radiation therapy. Two mortalities in this group of young patients were directly related to RND. The RND's following radiation therapy were clearly indicated by the persistence of a cervical mass. The operative mortality of the RND's following radiation therapy was 50%. Although failure to demonstrate tumor in a surgical specimen does not exclude its existence, no tumor could be demonstrated in any of the postradiation neck dissection specimens. The value of RND in this age group following radiation therapy for carcinoma of the nasopharynx merits further critical review.

Request for reprints should be sent to James B. Snow, Jr., M.D., Department of Otorhinolaryngology and Human Communication, University of Pennsylvania School of Medicine, 3400 Spruce Street, Philadelphia, Pennsylvania 19104.

REFERENCES

1. Muir CS: Nasopharyngeal cancer — a historical vignette, in Muir CS, Shanmugaratnam K (eds): *Cancer of the Nasopharynx*. New York, Medical Examiners Publishing Co, 1967
2. Bosworth FH: *A Treatise on Diseases of the Nose and Throat*. New York, Wm Wood Co, 1889, vol 1, pp 612-616
3. Durand-Fardel J: Cancer de pharynx — ossification dans la substance musculaire du coeur. *Bull Soc Anat (Paris)* 12:73-80, 1837
4. Jackson C: Primary carcinoma of the nasopharynx: a table of cases. *JAMA* 37:371-377, 1901
5. Dobson WH: Cervical lymphosarcoma (letter to editor). *China Med J* 38:786-787, 1924
6. Clifford P: Malignant diseases of the nasopharynx and paranasal sinuses in Kenya, in Muir CS, Shanmugaratnam K (eds): *Cancer of the Nasopharynx*. New York, Medical Examiners Publishing Co, 1967
7. Digby KH, Fook WL, Che YT: Naso-

pharyngeal carcinoma. *Br J Surg* 28:517-537, 1941

8. Bailar JC: Nasopharyngeal cancer in white populations — a worldwide survey, in Muir CS, Shanmugaratnam K (eds): *Cancer of the Nasopharynx*. New York, Medical Examiners Publishing Co, 1967

9. Martin H, Quan S: The racial incidence (Chinese) of nasopharyngeal cancer. *Ann Otol Rhinol Laryngol* 60:168-194, 1951

10. Lederman M: *Cancer of the Nasopharynx — Its Natural History and Treatment*, Springfield, Charles C Thomas Publishing Co, 1961

11. Falk HL, Steiner PE: The identification of aromatic polycyclic hydrocarbons in carbon blacks. *Cancer Res* 12:30-39, 1952

12. Keen P, DeMoor NG, Shapiro MP, *et al*: The aetiology of respiratory tract cancer in South African Bantu. *Br J Cancer* 9:528-538, 1955

13. Ho HC: Nasopharyngeal carcinoma in Hong Kong, in Muir CS, Shanmugaratnam K (eds): *Cancer of the Nasopharynx*. New York, Medical Examiners Publishing Co, 1967

14. Zippin C, Tekawa IS, Bragg KU, *et al*: Studies on heredity and environment in cancer of the nasopharynx. *J Natl Cancer Inst* 29:483-490, 1962

15. Herrold KM: Induction of olfactory neuroepithelial tumors in Syrian hamsters by diethylnitrosamine. *Cancer* 17:114-121, 1964

16. Dawe CJ: Neoplasms induced by polyoma virus in the upper respiratory tracts of mice, in Muir CS, Shanmugaratnam K (eds): *Cancer of the Nasopharynx*, New York, Medical Examiners Publishing Co, 1967

17. Cotchin E: Spontaneous neoplasms of the upper respiratory tract in animals, in Muir CS, Shanmugaratnam K (eds): *Cancer of the Nasopharynx*, New York, Medical Examiners Publishing Co, 1967

18. Liang D: Virus as the cause of rhinopharyngeal carcinoma. *Acta Otolaryngol (Stockh)* 67:190-199, 1969

19. Snow JB: The classification of respiratory viruses and their clinical manifestations. *Laryngoscope* 79:1485-1493, 1969

20. Miller G, Niederman JC, Andrews LL: Prolonged oropharyngeal excretion of Epstein-Barr virus after infectious mononucleosis. *N Engl J Med* 288:229-232, 1973

21. Henle W, Henle G: Epstein-Barr virus and infectious mononucleosis. *N Engl J Med* 288:263-264, 1973

22. Klein G, Geering G, Old LJ, *et al*: Comparison of the anti-EBV titre and the EBV-associated membrane reactive and precipitating antibody levels in the sera of Burkitt lymphoma and nasopharyngeal carcinoma patients and controls. *Int J Cancer* 5:185-194, 1970

23. Henle W: Elevated antibody titers to Epstein-Barr virus in nasopharyngeal carcinoma, other head and neck neoplasms and control groups. *J Natl Cancer Inst* 44:225-231, 1970

24. Miller D, Goldman J, Goodman M: Etiologic study of nasopharyngeal cancer. *Arch Otolaryngol* 94:104-108, 1971

25. Regaud C: Discussion of paper by Reverchon L, Coutard H: Lymphoepitheliome de l'hypopharynx traite par le roentgentherapie. *Bull Soc franc, Oto-rhino-laryngol* 34:209-214, 1921

26. Schmincke A: Ueber lymphoepitheliale Geschwülste. *Beitr Pathol* 58:161-170, 1921

27. *Clinical Staging System for Carcinoma of the Pharynx (Nasopharynx, Oropharynx, and Hypopharynx)*, in American Joint Committee for Cancer Staging and End Results Reporting. American College of Surgeons, 1965

28. Godtfredsen E: Ophthalmologic and neurologic symptoms at malignant nasopharyngeal tumors. *Acta Psychiatr Scand (Suppl)* 34, 1944

29. Smith RR, Frazell EL, Caulk R, *et al*: The American Joint Committee's Proposed Method of Stage Classification and End Results Reporting applied to 1,320 pharynx cancers. *Cancer* 16:1505-1520, 1963

DISCUSSION OF THE PREVIOUS TWO PAPERS

EMANUEL SKOLNIK, M.D. (Chicago, Illinois): I want to thank both essayists for their excellent presentations but I would like to address myself to Dr. Saunders' paper.

I noticed his title was "Prevention and Correction of Shoulder Disability After RND" and this offered me an opportunity to make a plea for the surgical procedure that we have

been doing since 1960; that is, the preservation of the spinal accessory nerve.

The more surgery that I do through the years and the more opportunity I have of evaluating the data, the more I am convinced that the spinal accessory nerve can be saved far more frequently than we originally anticipated.

In the past we advocated preservation of the nerve in only those situations where there is no evidence of palpable nodes. However, now we have clinical and histopathological evidence that the nerve can be preserved in selected situations when the nodes are small, mobile and are involving the midjugular region or even in the subdiaphragmatic area. One can still preserve the spinal accessory nerve without jeopardizing the cure potential of the patient.

The two basic problems, when the nerve is sacrificed, are, as Dr. Saunders pointed out, pain and impaired mobility of the shoulder.

Many years ago, I tried the same rehabilitative exercises Dr. Saunders talked about. This worked quite well for some young patients, but older patients tend to do poorly. Most of these older patients complained bitterly of the pain, and the lack of function became worse with the passage of time because they were unable to use the shoulder.

Although we can correct and rehabilitate some of the shoulders where the nerve has been sacrificed, I would still make an urgent plea for the prevention of the painful shoulder disorders by preserving the spinal accessory nerve where indicated, in radical neck surgery.

HERBERT HARRIS, M.D. (Houston, Texas): I want to address myself to the paper of Dr. Saunders, chiefly because I proposed the graft of the spinal accessory with the great auricular ten years ago.

I notice that there has been little attention given to the nerve supply to the levator scapulae. This nerve, if you will recall, crosses from the brachial plexus over the posterior belly of the scalenus, dips underneath and enters the fibers of the levator. This muscle is very important for the function of a shoulder. Without nerve supply to the trapezius, without nerve supply to the levator, you have a very painful, useless shoulder.

I find that this nerve to the levator can be damaged or cut quite easily unless one is looking for it and trying to preserve it. It lies in the fascia and if one is a little vigorous in doing his neck dissection, he may lift the fascia off the posterior belly of the scalenus and take with it the nerve.

DANIEL MILLER, M.D. (Boston, Massachusetts): Pardon me for getting up here a second time, but I could not help but discuss Dr. Snow's paper. This is extremely well presented. He probably has the highest rate of cure for children's cancer of the nasopharynx that I have seen in print.

There was an article out of Michigan some years ago. I think only one child lived over five years out of a group of nine with naso-

pharyngeal carcinoma. He has brought to our attention that it can occur in children, that therefore we must have an index of suspicion for it.

There are a few comments that I would like to make regarding his paper.

First, regarding EB virus. We had 31 out of 39 patients in whom we did studies of the antibodies for the EB virus that were highly positive in cancer of the nasopharynx, and as he explained, the worse the stage, the higher the antibody titer. However, this is still in the early stage of study and his statement that a positive titer is normally present in children who have been exposed to the infection calls for explanation.

If one uses a titer of nothing less than one to 80 as a negative and those above one to 80 as positive you will find it will eliminate the so-called positive EB virus titer found in the general population of children.

Second, I noted in his neck dissections that he did a bilateral neck dissection in one youngster who expired and the question I raise is was the tracheostomy done after the first radical neck since the neck had been radiated?

What I am trying to point out is that when a neck is radiated and a radical neck dissection is to be done on either side, a tracheostomy is indicated before one embarks upon that procedure to avoid any possible troubles immediately postoperatively. I wonder how much of a part this played in the post-operative deaths.

If a patient, especially a child, is about to have the second neck dissection done, I wonder if it would not be better to do a Silverman needle biopsy of the node on the side to be done, in view of the hazards of a bilateral neck dissection in a child, to prove to yourself that you did have evident metastatic disease in the node to be removed.

JAMES B. SNOW, JR., M.D. (closing): Thank you, very much, Dr. Miller, for your comments.

Regarding the neck dissections in patient number five, the first neck dissection was performed in December of 1967 because of a persistent mass in the left side of the neck, which was two months following the completion of irradiation therapy. The second neck dissection was performed in April of 1968, six months following the irradiation therapy and four months following the radical neck dissection on the left side.

We did not do a tracheotomy with either radical neck dissection and the tracheotomy was done only after the patient had the respiratory and cardiac arrest, and I think

what Dr. Miller has pointed out is a very important point.

I must say I have not performed tracheotomies on every patient who has had a radical neck dissection following irradiation therapy, but perhaps I should and I certainly will take his advice in that matter very seriously. I think all of us can devote attention to it.

Regarding the use of the Silverman needle biopsy, this has the theoretical objection of seeding the skin and subcutaneous tissue with tumor, and I feel that one should make the decision on whether a radical neck dissection should be done under these circumstances of a proved primary and a persistent or developing mass in the neck on the basis of one's clinical judgment.

In a study that George Reed and Werner Muller and I did back in the late fifties, we were able to demonstrate that we were correct in our judgment as to whether or not there was metastasis present 80% of the time.

In other words, we were right four out of five times, wrong one out of five times.

It was our opinion at that time, and still my opinion, that it is best to make that judgment on a clinical basis, recognizing that you will be wrong in one out of five times.

However, it seems that there is a different situation, at least based on our experience with carcinoma of the nasopharynx in children. We were wrong 100% of the time in this group of youngsters and so I do not know that a persistent mass in the neck, following irradiation therapy in a child with carcinoma of the nasopharynx, means the same thing that it does in the adult. Although I cannot be very specific about this I certainly would tend to be more conservative in this group of patients than I would in other patients with head and neck malignant tumors.

Now, regarding the 7,000 rads. The radiation therapy was carried out in these children by two different radiation therapists, Robert Bogardis and Seymour Levitt, and they chose this dosage.

I think it is high, but I think it is appropriate. I do not know that I can really defend it though and I think that certainly one might go along with anything as low as 6,000 rads. Once one gets beyond 8,000 rads, then one gets into supralethal irradiation and runs into very severe problems.

In this particular group of patients, there were no complications with this 7,000 rads to the primary lesion.

OBSERVATIONS ON THE PRIMATE HYOEPIGLOTTIC COMPLEX

GABRIEL TUCKER, JR., M.D.

JOHN A. TUCKER, M.D.

PHILADELPHIA, PENNSYLVANIA

SUMMARY — In the species presented, the orifice to the subhyoid air sac is found at the tuberculum (when the epiglottis attaches at the level of the ventricle); here also is noted the presence of a cartilaginous island(s) just anterior to the duct. When seen in coronal section along the axis of the duct, the glandular elements cluster around the sac in the anterior supra-glottic subhyoid wedge, in preference to the area around the ventricles.

The analogy between laryngocele¹ in the human larynx and various primate ventricular air sacs² is indeed not new. Less frequently discussed are those air sacs termed "subhyoid" by Negus.³ The hyoid bone in such animals is found to be thin and concave. The concavity embraces the anterosuperior aspect of the thyroid ala and is separated from it by the neck of the air sac. Indeed Negus suggested that the concave hyoid "protected" the neck of the sac which in turn he postulated to be a secondary organ of respiration.

Negus schematized a number of subhyoid air sacs.³ Such schema nicely demonstrate the relationship between the hyoid bone, the anterior portion of the thyroid "notch" and the "subhyoid" air sac.

Nèmai⁴ (quoted by Kelemen⁵) schematized a sagittal section which suggested that the air sac in the cercopithecus monkey might have its orifice in the region of the epiglottic tuberculum.

LABORATORY STUDIES

In the spring of 1974, we were privi-

leged to review the primate laryngeal collection of Dr. George Kelemen. This collection, accumulated over at least four decades, was comprised of some 41 specimens representing 15 species. Most of the specimens had been split in the midsagittal plane before imbedding, thus making it possible to section the mirror halves of any one larynx in two different planes.

Dr. Kelemen's tracer series were studied in his laboratory at the Ear Research Institute. The unstained sections of 33 primate larynges were forwarded to the laboratory of the Institute of Laryngology and Human Communications at Hahnemann* for staining and further study. It is from this latter material that those sagittal sections published herein were obtained.

To Dr. Kelemen's material has been added coronal sections processed through the cooperation of the Armed Forces Institute of Pathology.** This material was prepared to complement the prior sections by providing coronal sections perpendicular to an intact midsagittal plane. Our current efforts are directed toward the processing of whole, unsplit,

*Hahnemann Medical School, Philadelphia, Pa.

**Vincent Hyams, M.D., Director of ENT Branch, A.F.I.P.

From the Department of Laryngology and Broncho-esophagology, Temple University Health Sciences Center, and the Institute of Laryngology and Human Communications, The Hahnemann Medical College, Philadelphia, Pa.

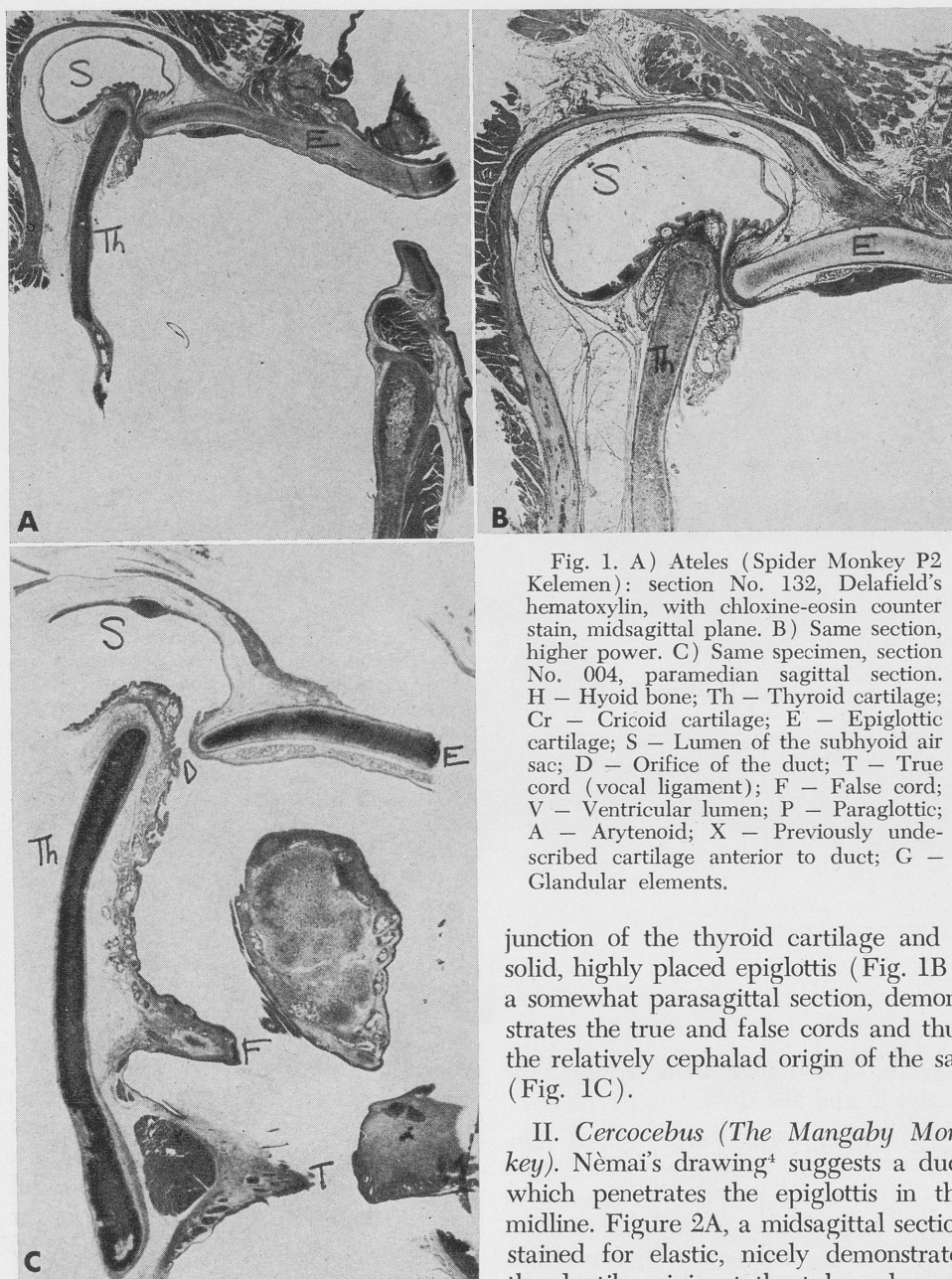


Fig. 1. A) *Ateles* (Spider Monkey P2 Kelemen): section No. 132, Delafield's hematoxylin, with chloxine-eosin counter stain, midsagittal plane. B) Same section, higher power. C) Same specimen, section No. 004, paramedian sagittal section. H - Hyoid bone; Th - Thyroid cartilage; Cr - Cricoid cartilage; E - Epiglottic cartilage; S - Lumen of the subhyoid air sac; D - Orifice of the duct; T - True cord (vocal ligament); F - False cord; V - Ventricular lumen; P - Paraglottic; A - Arytenoid; X - Previously undescribed cartilage anterior to duct; G - Glandular elements.

junction of the thyroid cartilage and a solid, highly placed epiglottis (Fig. 1B), a somewhat parasagittal section, demonstrates the true and false cords and thus the relatively cephalad origin of the sac (Fig. 1C).

II. *Cercocebus* (*The Mangaby Monkey*). Nèmai's drawing⁴ suggests a duct which penetrates the epiglottis in the midline. Figure 2A, a midsagittal section stained for elastic, nicely demonstrates the ductile origin at the tuberculum. It also demonstrates a separate previously undescribed cartilage (Fig. 2B, higher power) anterior to the duct. Also to be noted is the hyoepiglottic ligament extending from the trailing edge of the concave hyoid. Figure 2C, a paramedian sagittal section, demonstrates the inter-

primate larynges in all three planes of section.

OBSERVATIONS

I. *Ateles* (*The Spider Monkey*). Midsagittal section (Fig. 1A) demonstrating a subhyoid air sac; the orifice is at the

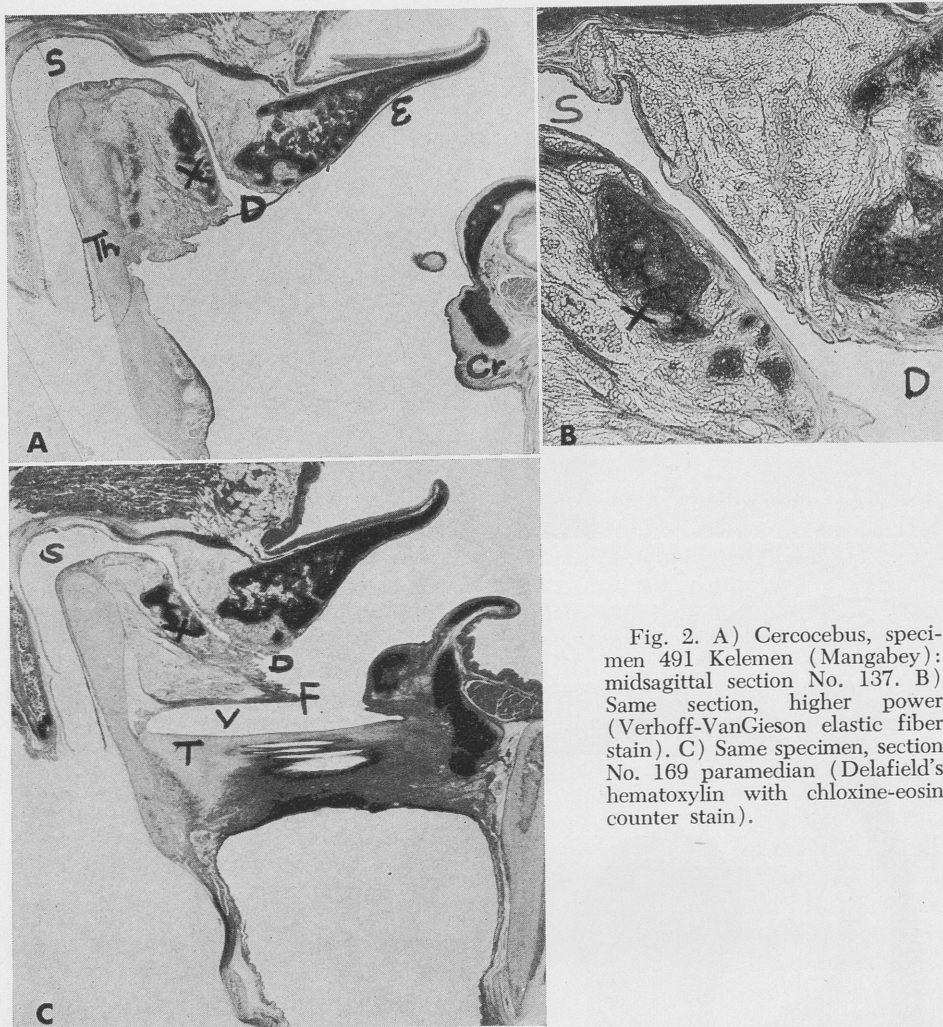


Fig. 2. A) *Cercopithecus*, specimen 491 Kelemen (Mangabey): mid-sagittal section No. 137. B) Same section, higher power (Verhoff-VanGieson elastic fiber stain). C) Same specimen, section No. 169 paramedian (Delafield's hematoxylin with chloxine-eosin counter stain).

position of the false cord between the ventricle and the duct.

III. *Lutong* (*The Purple Faced Langur*). Figure 3A demonstrates the larynx in which the proportions are somewhat varied (*i.e.*, the epiglottis is foreshortened, forward tipping of the arytenoid, *etc.*), yet there is the same basic pattern. Duct is better seen at higher power in Figure 3B.

IV. *Macaca Mulatta*. Similar pattern (Fig. 4) X indicates cartilage anterior to the duct.

V. *Baboon*. This specimen was pro-

cessed and photographed at the A.F.I.P. and is indeed similar to the human larynx. Close inspection reveals an orifice at the epiglottic tuberculum (Fig. 5). In the coronal section (Fig. 6), the lumen of the duct can be traced from the orifice at the epiglottic tuberculum up into the sac under the body of the hyoid.

DISCUSSION

The parallel between tumor spread from the tuberculum into the preepiglottic space⁶ is naturally intriguing. A firm conclusion in this regard would seem premature.

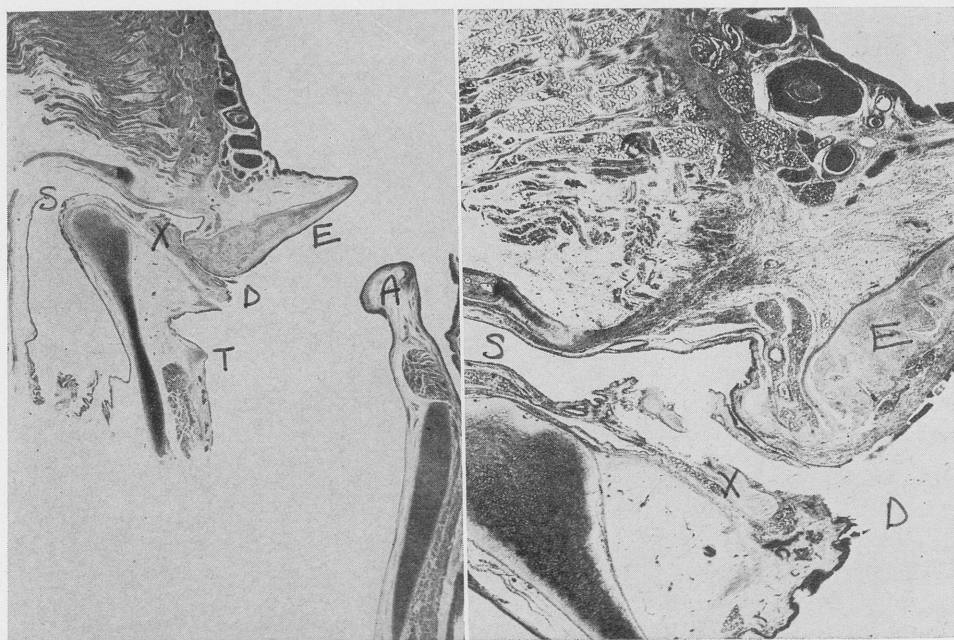


Fig. 3. A) Lutong P94A Kelemen (the purple faced Langur): section No. 316, midsagittal. B) Higher power, same section.

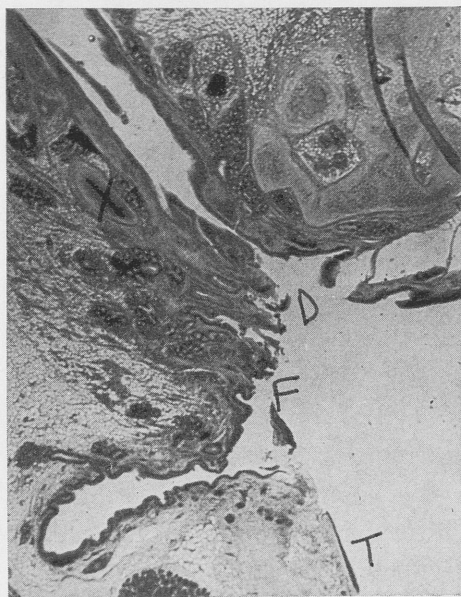


Fig. 4. *Macaca mulatta*, No. 2 Kelemen: section No. 53, midsagittal section, high power.

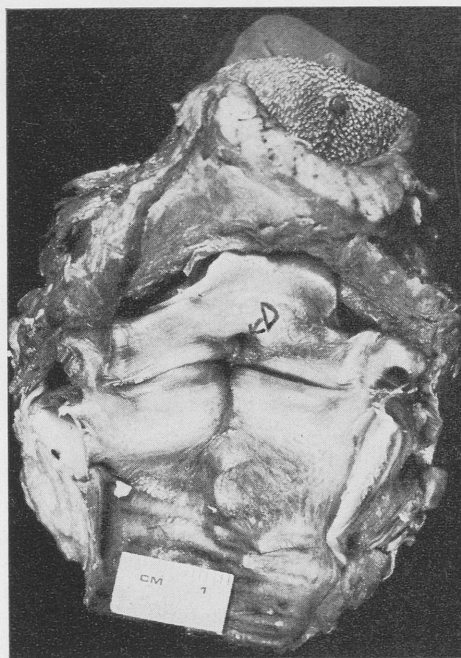


Fig. 5. Baboon (A.F.I.P.): specimen photographed conventional posterior split.

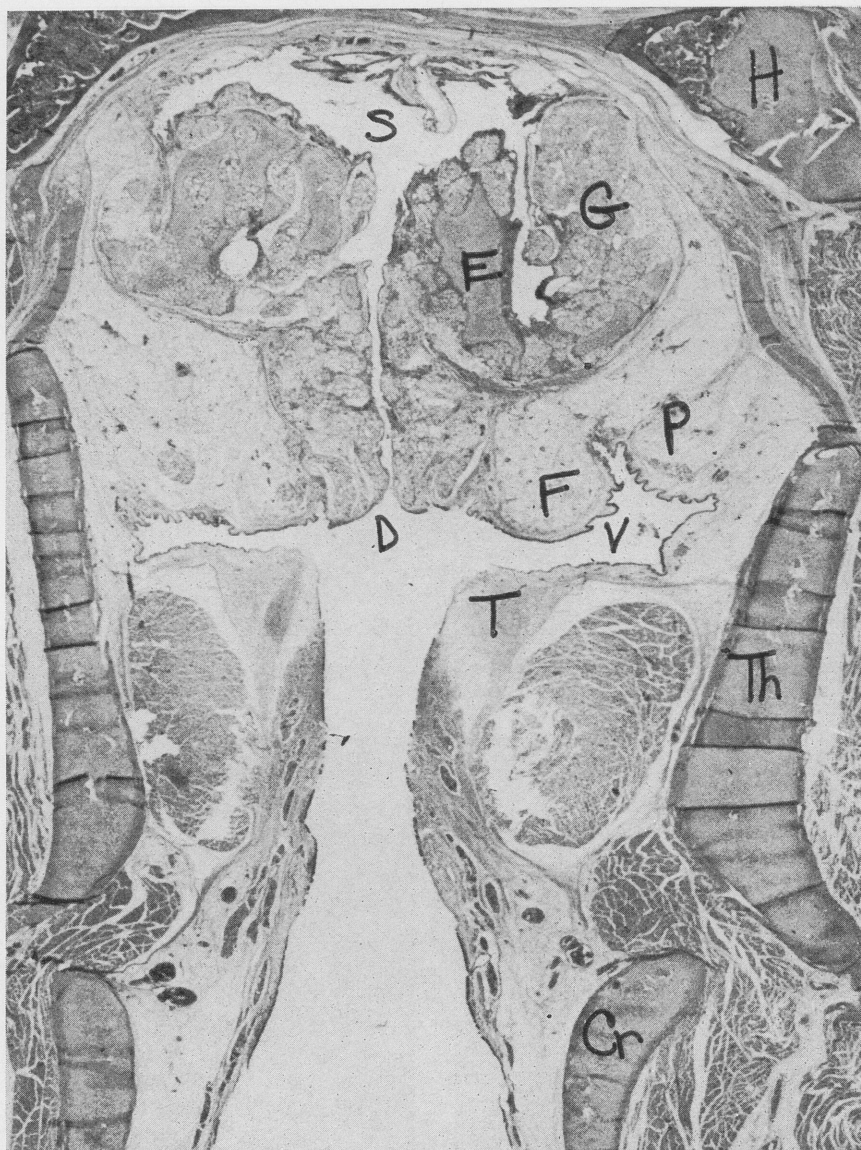


Fig. 6. Delafield's hematoxylin with chloxine-eosin counter stain. Coronal midcord section.

The preliminary studies reported herein suggest the possible value of comparative primate histologic studies in furthering our understanding of the human larynx.

The developmental sequence of air sac formation of the primate if similar to the human would approximate the later stages of the embryonic period and

during the early portion of the fetal development.⁷

CONCLUSION

The above studies suggest a more complex arrangement between the hyoid and the conventional "larynx" in other primates than is usually assumed for the human.

Such observations would tend to reinforce the suggestion that the hyoid be included in our conceptualization of the larynx rather than as a separate entity.

Request for reprints should be sent to Gabriel Tucker, Jr., M.D., Children's Memorial Hospital, 2300 Children's Plaza, Chicago, Ill. 60614.

ACKNOWLEDGEMENT — This study would have been impossible without the outstanding help and generosity of Dr. George Kelemen of the Los Angeles Foundation of Otolaryngology in giving to the authors precious unstained material collected over many years and in making available for study his stained tracer series of the same material. Mary Lou Gregory HT (ASCP), Research Assistant at the Institute of Laryngology, stained sections selected from the material donated by Dr. Kelemen. Frances Schoppy, from the laboratory of the ENT Branch of the A.F.I.P., prepared, sectioned, and stained the baboon larynx reported herein. Photography credits: Whole baboon specimen — A.F.I.P. Histologic sections: Hahnemann and Temple Medical Schools, Departments of Photography.

REFERENCES

1. Broyles EN: Anatomical observations concerning the laryngeal appendix. *Ann Otol Rhinol Laryngol* 68:461-470, 1959
2. Negus VE: *The Comparative Anatomy and Physiology of the Larynx*. New York, Grune and Stratton, 1949
3. Negus VE: *The Mechanism of the Larynx*. St. Louis, C. V. Mosby, 1929
4. Nèmai J: Das Stimmorgan der Primaten. *Z Anat Entwicklungs Gesch* 81:657-672, 1926
5. Kelemen G: Comparative anatomy and performance of the vocal organ in vertebrates, in Busnel RG (ed): *Acoustic Behavior of Animals*. New York, Elsevier Publ. Co., 1964, chap 18
6. Tucker GF: The anatomy of laryngeal cancer. *Can J Otolaryngol* 3:417-431, 1974
7. Tucker J, Tucker G: Some aspects of fetal laryngeal development. *Ann Otol Rhinol Laryngol* 84:49-55, 1975

INCIDENCE, PREDISPOSING FACTORS AND OUTCOME OF PHARYNGOCUTANEOUS FISTULAS COMPLICATING HEAD AND NECK CANCER SURGERY

DOUGLAS D. DEDO, M.D.

WILLIAM A. ALONSO, M.D.

JOSEPH H. OGURA, M.D.

ST. LOUIS, MISSOURI

SUMMARY — A major complication of head and neck cancer surgery following radiation and extensive resection is pharyngocutaneous fistula. A retrospective analysis of 36 fistula patients out of 376 major head and neck procedures between January 1971 and July 1973 revealed certain guidelines for improved clinical management. Since a large discrepancy existed in the incidence of fistulas between the different surgical procedures, each operative group was examined separately. The incidence, predisposing factors, and methods of treatment for this complication following composite jaw-neck resections and various laryngeal procedures are analyzed and discussed.

INTRODUCTION

Oro- and pharyngocutaneous fistulas complicating head and neck cancer surgery significantly increase patient morbidity and mortality. A retrospective study of this complication on the Head and Neck service from January 1971 to July 1973 was undertaken. The incidence, predisposing factors, and outcome of these fistulas were reviewed in order to establish criteria for improved management. The following guidelines were introduced: 1) preoperative identification of the high risk patient likely to develop a fistula; 2) prediction of spontaneous fistula closure or the need for surgical reconstruction; 3) alteration of the proposed surgical procedure to include primary reconstruction; and 4) prevention of future fistulas.

METHODS AND MATERIALS

Charts from January 1971 to July 1973 were reviewed of all major head and neck cancer patients whose courses were compli-

cated by the development of a fistula. As summarized in Table I, a total of 50 immediate and delayed fistulas complicated 376 primary resections for an incidence of 13.3%. Nine fistulas were created primarily at the time of resection and five developed spontaneously more than six weeks after surgery. Omission of these 14 cases reduces the incidence of fistulization to 9.6%. The major head and neck procedures under study included composite jaw-neck resections, partial laryngopharyngectomies (PLP), subtotal supraglottic laryngectomies (SSL), and total laryngectomies. It does not include hemilaryngectomies since none were complicated by a fistula. A significant difference in the incidence of fistulas was noted among the various surgical procedures (Table I). Each surgical category was analyzed separately to account for this discrepancy and to identify any factors that might be unique to each procedure.

RESULTS

One hundred twenty composite jaw-neck dissections were performed. Twelve patients (10%) developed a fistula. Three of the 12 cases developed late fistulas and all were related to persistent carcinoma. The site of the primary tumor

From the Department of Otolaryngology, Washington University School of Medicine, St. Louis, Missouri.

Supported in part by NIH Training Grant No. 5T01 NS0 5190-15 from NINDS.

TABLE I
INCIDENCE OF FISTULAS WITH RESPECT TO
SURGICAL TREATMENT OF PRIMARY TUMOR

	No. of Cases	Total No. Fistulas	No. Fistulas Complicating Surgery
Jaw neck dissection	120	12 (10 %)	9 (7.5%)
Partial laryngopharyngectomy (and radical neck dissection)	72	17 (23.6%)	15 (20.8%)
Subtotal supraglottic laryngectomy (and radical neck dissection)	60	5 (8.3%)	5 (8.3%)
Total laryngectomy	117	9 (7.6%)	7 (5.9%)
Total laryngopharyngectomy with surgical reconstruction	7	7 (100 %)	0 —
Totals	376	50 (13.3%)	36 (9.6%)

correlated with the location of the fistula in the remaining nine cases (7.5%). In seven of the nine patients the tumor involved the posterior oropharynx (base of tongue, tonsil, lateral pharyngeal wall, etc.). In all of these patients the fistula developed at the trifurcation in the skin, overlying the lateral pharyngeal suture line. In contrast, two patients with a floor of the mouth cancer developed fistulas in the submental triangle.

It is difficult to single out a specific etiology for each of the nine fistulas. Numerous factors influence the pharyngocutaneous breakdown (Table II). All

TABLE II
FACTORS CONTRIBUTING TO FISTULAS
FOLLOWING JAW NECK DISSECTION

Large T ₃ lesions*	9
Fluid accumulation under cervical flaps	7
Necrosis of cervical flaps	5
Dosage of preop irradiation >3,000 rads	4
Recurrent carcinoma	
Local	1
Distant	4
Systemic disease	3
Hemorrhage requiring reexploration	2
Osteomyelitis of mandible	2
Previous rhytidectomy	1

*Classification according to UICC.

nine patients had advanced T₃ lesions. Seven patients required counter drainage of their wounds after fluid accumulation under the flaps. Five of the nine patients had partial necrosis of their cervical flaps. Four of the patients with fistulas received more than the usual dose of 3,000 rads preoperatively. Five cases were subsequently treated for local persistence (1) or distant metastases (4). Two patients had diabetes mellitus and a third developed hepatic failure postoperatively. Two patients required reexploration of a wound hematoma. Osteomyelitis of the mandible developed at the margin of resection in two other cases. These were successfully treated with debridement. Another patient, with a rhytidectomy prior to composite jaw-neck resection, was treated with 5,000 rads preoperatively. Postoperatively the cervical flaps were noted to be very atrophic. High dose preoperative irradiation combined with the face lift played a major role in her wound dehiscence.

Analysis of these nine cases reveals certain predisposing factors which contributed to fistula formation. Four patients received high dose preoperative irradiation for large T₃ lesions, two involving the lateral pharyngeal wall. After resection with an adequate margin and primary closure, the hypopharyngeal suture line was under excessive tension. An irradiated suture line under tension is susceptible to ischemia, necro-

sis, and fistula formation. Disruption of the normal healing process by fluid, flap necrosis, or counter drainage in an irradiated neck further predisposes to fistula formation.

The five remaining patients received low dose preoperative irradiation. Their postoperative course was complicated by two or more local wound disruptions. This included reexploration for hemorrhage (2), flap necrosis (3), fluid accumulation (3), and osteomyelitis of the mandible (2). In addition, three patients had disabling systemic disease.

Preoperative identification of three of these high risk patients (high dose irradiation, pharyngeal wall involvement, alteration of cervical skin) might have decreased the incidence of spontaneous fistula by 33%. Subsequent alteration of the surgical procedure in these three patients to include immediate reconstruction or a controlled pharyngostome would have decreased morbidity.

Table III summarizes the outcome of these nine fistulas. Three small fistulas closed spontaneously after an average of 120 days (22-180) from the day of primary resection. They were treated conservatively with daily dressing changes. Two of the three were followed on an outpatient basis. Three moderately

sized fistulas also closed spontaneously after an average of 45 days (34-53). The principal difference between these two groups of patients is the fact that the latter three fistulas were debrided in the operating room and had a Bakamjian chest flap staged. The three largest fistulas required multiple surgical procedures for closure. One patient was successfully reconstructed by the 105th postoperative day. Another fistula remained open, and the patient died of distant metastases seven months following the primary resection. The third case had been draining for six months and was terminated by the end of the study.

The highest incidence of postoperative fistulas was seen after PLP. Seventeen patients (23.6%) developed fistulas out of a total of 72 PLP's. Two control fistulas were created at primary resection, reducing the postoperative incidence to 20.8%. The remaining 15 fistulas developed within six weeks of surgery and are considered a complication of a PLP.¹

Hypopharyngeal tumors involving the pyriform sinus, vallecula, or pharyngeal walls are treated with a PLP. Closure of the hypopharynx after a PLP is dependent upon the amount of mucosa remaining after primary tumor resection. When the lateral wall of the pyriform sinus is free of disease, closure of the neopharynx can be accomplished without difficulty. However, in large tumors extending to the lateral and/or posterior pharyngeal walls, the mucosal closure may be compromised. As a result, the approximation of perichondrium to mucosa may be placed under excessive tension. Necrosis and separation of the lateral pharyngeal suture line can occur. Sixteen of the 17 patients in this group had large T₃ or T₄ lesions. Fourteen of the 17 involved the pyriform fossa with extension to the lateral (9) and/or posterior pharyngeal walls (4).

Several factors involved in the development of these fistulas are summarized in Table IV. In seven patients split thickness skin grafts and Negus stents were used following resection to close the pharynxes. Six patients developed fluid

TABLE III
OUTCOME OF THE FISTULAS
COMPLICATING JAW AND NECK
DISSECTION

	No. of Cases	Avg. No. Days from 1° Resection to Closure
Closed spontaneously without any surgical manipulation	3	120 (22-180)
Closed spontaneously without surgical reconstruction	3	45.6 (34- 53)
Closed with surgical reconstruction	1	105
Never closed	2	7 mo 6 mo

TABLE IV
FACTORS RESPONSIBLE FOR
POST PLP FISTULAS

Large T ₃ or T ₄ lesions	16
Use of Negus stent and STSG for closure of neopharynx	7
Fluid accumulation	6
Necrosis of cervical flaps	4
Persistent carcinoma	
Local	1
Distant	3
Dosage of preop irradiation (>3,000 rads)	3
Suture abscess	2
Created surgically	2
Multiple operations for post PLP glottic insufficiency	1
Improper feeding	1
Omission of prophylactic antibiotics	1

under the flaps. Necrosis and partial slough of the cervical flaps occurred in four cases. One patient had residual tumor at the margin of the resection and three developed distant metastases during fistula treatment within a year of surgery. Three of the 17 patients received greater than 3,000 rads preoperatively. Four attempts were made on one patient with persistent aspiration to restore glottic competence. After the fourth open procedure, the patient developed a fistula which drained for two weeks. Against medical advice, one patient fed herself on the fourth postoperative day and resisted attempts to curtail her oral intake. One patient did not receive prophylactic antibiotics. Two patients developed fistulas on the 34th and 37th days postoperatively. Both had been decannulated and had good oral intake. Exploration revealed silk suture abscesses along the base of the tongue-perichondrial suture line.

The outcome in this group of 17 fistulas is summarized in Table V. Two were classified as small fistulas and closed spontaneously with conservative therapy after an average of 41.5 days (23-60). Three patients were prepared for surgical reconstruction with a staged Bakamjian chest flap, but the fistula

closed spontaneously after an average of 92 days (29-210). Eleven patients (including seven repaired with split thickness skin grafts and Negus stents, and two with controlled pharyngostomes) required surgical reconstruction for closure. An average of 3.9 months (23 days to 14 months) from the day of tumor resection to fistula repair was required. Two patients with a controlled pharyngostome were successfully closed 23 and 36 days following resection with return of the chest flaps. One patient died of a carotid artery rupture while being prepared for surgical reconstruction of the fistula.

Preoperative identification of the high risk patient likely to develop a fistula following a PLP is largely related to two factors. First, large T₃ or T₄ tumors of the pyriform sinus are associated with a high incidence of postoperative fistulas (16 of 17). Secondly, tumor involvement of the lateral or posterior pharyngeal wall markedly complicates suitable primary closure of the neopharynx following extensive resection (13 of 17).

An SSL was performed on 60 patients. Five patients in this series developed a pharyngocutaneous fistula for an incidence of 8.3%.

In all five cases fistulas were traced to a breakdown at the perichondrial-base of tongue suture line. Table VI summarizes the factors responsible for

TABLE V
RESOLUTION OF FISTULAS
FOLLOWING A PLP

	No. of Cases	Avg. No. Days from 1° Resection to Closure
Closed spontaneously without any surgical manipulation	2	41.5
Closed spontaneously without surgical reconstruction	3	92
Closed with surgical reconstruction	11	116
Never closed	1	

TABLE VI
FACTORS RESPONSIBLE FOR
POSTOPERATIVE SSL FISTULAS

Suture abscess	3
Necrotic thyroid cartilage	2
Liver failure	1

wound dehiscence in this group of patients. Three patients required incision and drainage (I and D) for localized abscesses. At the core of each abscess was a mass of silk suture. In two patients fragments of necrotic cartilage were debrided after the fistulas were exteriorized. Liver failure complicated wound healing in another patient.

Two of three fistulas discovered after I and D of a suture abscess closed spontaneously within 38 days of surgery (Table VII). The third case closed spon-

TABLE VII
OUTCOME OF THE POST SSL FISTULAS

	No. of Cases	Avg. Day Postop
Closed spontaneously without any surgical manipulation	2	38
Closed spontaneously without surgical reconstruction	1	51
Closed with surgical reconstruction	2	120

taneously 51 days after primary resection and staging of a Bakamjian chest flap. These three cases were staged as T₂ or T₃ lesions. By comparison, the two cases requiring surgical closure were T₄ lesions. Successful surgical rehabilitation required 90 days and five months, respectively.

The lowest incidence (7.6%, or nine out of 117 patients) of postoperative fistulas occurred after total laryngectomy. Two of the nine fistulas appeared two and five years following primary resection. The remaining seven or 5.9% represent the true incidence of fistula as a surgical complication.

TABLE VIII
FACTORS INVOLVED IN POST
TOTAL LARYNGECTOMY FISTULAS

High dose irradiation >3,000 rads	4
Persistent carcinoma (1 delayed)	3
Extension to posterior pharyngeal wall	3
Systemic disease	3
Foreign body granuloma, 1 delayed	2
Postsurgical persistence	2

The most frequent sites of fistula drainage were either through carcinoma (3), or adjacent to the tracheostoma. Table VIII summarizes the factors involved in the development of the seven fistulas. Four patients received 4,000-8,000 rads prior to surgery. Two were radiation failures. Three had tumor extending into the lateral and posterior pharyngeal walls. Two patients required excision of foreign body granulomas. (One granuloma developed more than five years postoperatively.) Two patients required a total laryngectomy for residual tumor after hemilaryngectomy and SSL, respectively. In three patients, systemic disease such as diabetes mellitus or chronic obstructive pulmonary disease (COPD) complicated their clinical course.

Patients with a high risk of fistula formation after total laryngectomy are those who are radiation or surgical failures. Cancer involvement of the lateral and posterior pharyngeal walls or serious systemic disease are additional factors which modify the clinical course. A controlled pharyngostome followed by secondary reconstruction should be considered in these cases.

Results of fistula repair and survival were poor in this group of patients. There were no spontaneous fistula closures (Table IX). One fistula closed after debridement 70 days after tumor resection. Another fistula was closed surgically following excision of a granuloma and fistula tract with primary closure of the defect. The remaining seven cases never closed. Six patients (66%) died within six months after recognition

TABLE IX
OUTCOME OF FISTULAS
COMPLICATING TOTAL
LARYNGECTOMIES

	No. of Cases	Avg. No. Days from 1° Resection to Closure
Closed spontaneously	0	—
Closed spontaneously after surgical manipulation	1	70
Surgical closure without reconstruction	1	21
Never closed	7	—

of a fistula. The causes of death were uncontrolled primary (3), bronchopneumonia (2), and severe COPD with multiple spontaneous pneumothoraces (1). Poor survival rates in this group of patients was in part related to the large size of the tumors. Chronic debilitation and poor nutrition also contributed to their demise despite vigorous supportive care.

For purposes of discussion, seven patients with primary chest flap reconstruction at the time of total laryngopharyngectomy will be analyzed. Four patients received 6,000 rads preoperatively and three received 3,000 rads. Three patients were treated for a post-surgical or postirradiation cancer persistence. Table X summarizes the outcome in these cases.

Four of five patients with unilateral chest flap reconstruction were successfully rehabilitated after an average of 50 days (28-90). Although the pedicle flaps were usually returned to the donor

site within 25 days of primary resection, drainage often continued for two additional months at the inferior suture line. Two patients requiring multiple flaps for reconstruction required seven months to close. Of seven patients, 50% developed a recurrence within six months of the original surgery.

DISCUSSION

The period January 1971 through July 1973 was chosen for study for two reasons. First, by reviewing relatively recent years, established techniques of primary resection and reconstruction could be analyzed and compared. Second, povidone-iodine ointment² was added to the regimen of local fistula care in November 1972. Our clinical impression was that the fistulas were healing more rapidly with povidone-iodine than with the other nonsurgical local treatments. In order to design a laboratory model and test the efficacy of this local wound management, accumulation of more clinical information about fistula formation was necessary.

The 9.6% total incidence of spontaneous fistulization compares favorably with other studies.³⁻⁶ Lavelle⁷ reported a 37% and Smits, *et al*⁸ a 36% incidence of fistulas following total laryngectomy. We have a 5.6% fistula rate for 117 total laryngectomies. The 20% rate of spontaneous fistulization following PLP will decrease as the Negus stent is being replaced by other modes of reconstruction. Recent use of controlled pharyngostomes in PLP's and other extensive resections to decompress the neopharyngeal suture line has been successful in reducing spontaneous, uncontrolled fistulas.

TABLE X
FOLLOW-UP OF SEVEN CASES OF TOTAL LARYNGOPHARYNGECTOMY

	No. of Cases	Avg. No. Days Before Closure	Recurrent Carcinoma
Reconstruction using a single chest flap	5	50* (28-90)	3
Reconstruction using more than 1 pedicle flap	2	7 mo (5-9)	1

*Does not include one patient cut off by end of study who had been draining for 77 days.

The combined incidence (15%) of fistulas following conservation laryngeal surgery is two and one-half times greater than the incidence for total laryngectomies. We consider this an acceptable risk in exchange for better patient function and quality of life.

Common predisposing factors to fistula formation among the various surgical procedures allows the preoperative identification of high risk patients. In general, patients with a systemic disease (diabetes mellitus, COPD, *etc.*) will have a complicated clinical course. Large T₃ and T₄ tumors requiring resection of large amounts of the lateral and posterior pharyngeal walls may be difficult to close primarily. Patients requiring large surgical resections for postirradiation or postsurgical tumor persistence may require staged reconstruction. While there is controversy regarding the dose of irradiation which significantly impairs wound healing, it is generally recognized⁸⁻¹¹ that as higher doses of irradiation (4,500-8,000 rads) are employed, neopharyngeal dehiscence is more likely to occur. Two or more of these common factors combined with local wound disruption will predispose the majority of patients to a cutaneous fistula.

Technical weaknesses inherent in each surgical procedure contribute to the development of a fistula. For example, in a composite jaw-neck resection, inadequate removal or cover of the resected mandible can result in osteomyelitis and drainage. When a PLP is utilized for large pyriform sinus tumors extending to the posterior pharyngeal wall, the neopharyngeal suture line can break down if not primarily reconstructed or decompressed with a controlled pharyngostome. Careful elevation of the perichondrial flap and gentle handling of the thyroid cartilage during the saw cuts are necessary to avoid cartilage necrosis and subsequent drainage in both SSL's and PLP's.

The pharyngeal mucosa was closed with silk sutures in all cases except after total laryngectomies. After 14 days, the silk suture acts as an impediment to

wound healing. This was amply demonstrated after exteriorizing the fistulas. A large number of silk sutures was always removed from the sloughed area of the pharyngeal or thyroid cartilage suture lines. Not only does the silk act as a nidus for infection, but its mucosal holding properties are dissipated within two weeks. A study is currently underway to compare the various suture materials for closure of the pharynx.

The results of the management of these 36 fistulas may be summarized as follows: seven (19.4%) closed spontaneously, eight (22.2%) required some form of surgical manipulation before closing spontaneously, 13 (36%) required surgical closure, and eight (22.2%) failed to close. Prediction of spontaneous or surgical fistula closure is largely related to the operation performed. Following a composite jaw-neck resection, debridement in the operating room within ten days of fistula development is recommended to decrease prolonged morbidity. Concomitant staging of the chest flap for future use during debridement will save time, especially if the size of the fistula is large. A PLP complicated by a fistula has an 80% probability of requiring surgical manipulation for closure. Therefore, shortly after the diagnosis of a fistula, debridement and staging of a chest flap should be completed. Fistulas developing after SSL's for small lesions will close spontaneously following removal of necrotic cartilage and silk sutures. A fistula following a total laryngectomy is an ominous sign. In addition to vigorous supportive care, debridement and staging of a chest flap for moderate to large fistulas will be necessary.

Preoperative planning of the surgical procedure to include staged reconstruction in the high risk patient should be considered to lessen patient morbidity and expensive postoperative stays. In two PLP's with primary chest flap reconstruction, wound closure was achieved an average of 29 days after resection. This is in marked contrast to an average of 3.9 months required for closure of the nine uncontrolled PLP fistulas. The five

cases of total laryngopharyngectomies with single chest flap reconstruction were closed an average of 50 days from the day of resection. The decrease in number of hospital days for those patients reconstructed at the time of initial tumor resection justifies a more frequent use of chest flaps and controlled pharyngostomes in head and neck extirpative surgery.

Over 70% of the fistulas reported were diagnosed within three weeks following surgery. Frequently, the patients were eating and decannulated when their wounds drained. Since an average wound does not reach its maximum breaking strength for six weeks,¹² an irradiated wound would be expected to be delayed even longer. Swallowing and coughing subject the neopharyngeal suture line to significant stress. To prevent fistulas and encourage wound healing, we delay decannulation and oral intake for three weeks in high risk patients. In addition, any patient who displays abnormal wound healing postoperatively (e.g., cellulitis, edema, fluid accumulation) is placed on high dose IV antibiotics until the complication is resolved. Decannulation and peroral feeding are similarly

delayed for three weeks to encourage further wound healing.

SUMMARY

A retrospective analysis of 36 fistulas which complicated 376 major head and neck resections between January 1971 and July 1973 was made to establish guidelines for improved clinical management and prevention of this complication.

Criteria for the preoperative identification of the high risk patient was based upon the predisposing factors and outcome of these 36 fistulas. In general, the size of the lesion, dosage of irradiation, presence of systemic disease, and failure of prior treatment modalities (surgery or irradiation) are the common factors which predispose the majority of patients to a cutaneous fistula. Prediction of spontaneous or surgical closure is dependent upon the tumor site and operation performed. Prevention of spontaneous fistulization postoperatively may be accomplished by delaying peroral feeding for at least three weeks in the high risk patient and/or a more frequent use of controlled pharyngostome to decompress the neopharyngeal suture line.

REFERENCES

1. Ogura JH, Mallen RW: Partial laryngopharyngectomy for supraglottic and pharyngeal carcinoma. *Trans Am Acad Ophthalmol Otolaryngol* 69:832-845, 1965
2. Connell JF, Rousselot LN: Povidone-iodine, extensive surgical evaluation of a new antiseptic agent. *Am J Surg* 108:849-851, 1964
3. Rolandez TL, Everts EC, Shumrick DA: Carcinoma of the tonsil: a planned combined therapy approach. *Laryngoscope* 81:1199-1207, 1971
4. Constable WC, Marks RD, Robbins JP, *et al*: High dose preoperative radiotherapy and surgery for cancer of the larynx. *Laryngoscope* 82:1861-1868, 1972
5. Goldman JL, Silverstone SM, Roffman JD, *et al*: High dosage preoperative radiation and surgery for carcinoma of the larynx and laryngopharynx — a 14 year program. *Laryngoscope* 82:1869-1882, 1972
6. Wang CC, Schulz MD, Miller D: Combined radiation therapy and surgery for carcinoma of the supraglottic and pyriform sinus. *Laryngoscope* 82:1883-1890, 1972
7. Lavelle RJ, Maw AR: The aetiology of post-laryngectomy pharyngocutaneous fistulae. *J Laryngol Otol* 86:785-793, 1972
8. Smits RG, Krause CJ, McCabe BF: Complications associated with combined therapy of oral and pharyngeal neoplasms. *Ann Otol Rhinol Laryngol* 81:496-500, 1972
9. Myers EN: The management of pharyngocutaneous fistula. *Arch Otolaryngol* 95:10-17, 1972
10. Peacock EE Jr, Van Winkle, W Jr: *Surgery and Biology of Wound Repair*. Philadelphia, Saunders, 1970
11. Dingman RO: Factors of clinical significance affecting wound healing. *Laryngoscope* 83:1540-1554, 1973
12. Levenson SM, Geever EF, Crowley LV, *et al*: The healing of rat skin wounds. *Ann Surg* 161:293-298, 1965

DISCUSSION OF THE PREVIOUS TWO PAPERS

JOHN A. KIRCHNER, M.D. (New Haven, Connecticut): Dr. Tucker is to be congratulated for this latest example of his meticulous observations in laryngeal anatomy. It is a scholarly presentation, and to my knowledge, something entirely new, at least to me.

I would like to ask him one question to see if we can get him to speculate. Do you think that the fenestrae in the human epiglottis from the laryngeal to the lingual surface that you see in the cartilage, are remnants of our evolutionary past, perhaps when man had a subhyoid air sac?

I would also like to clarify one thing in Dr. Dedo's presentation which was a very nice one. I am sure not only Dr. Ogura but Dr. Herbert Dedo must be very proud of the essayist here.

I wanted to be sure that I was clear that he said a fistula following total laryngectomy is an ominous sign and the patient will probably be dead within six months. I am not sure I understood this.

In our experience the fistulas that we have had following total laryngectomy have been due to wound separation inside, and I rather think that the fluid that accumulates under the flap very often is saliva that has simply escaped from a breakdown of the closure line internally, and that this is where the wound has to be reinforced with constrictor muscle or any available tissues.

JOHN CONLEY, M.D. (New York, New York): Dr. Tucker's paper was a really beautiful paper and I will not discuss that. I appreciate hearing it very much.

Dr. Dedo's paper, I think, has said it all. Perhaps just some condensation of what he said is important. What he has said is if you are getting too many fistulae you are doing something wrong. This equals a mistake in concept of management. The mistake in the concept of management is that you are trying to do too much at one time.

We have a saying that "Rome wasn't built in a day," and not every operation can be executed in a rigid framework of "cut it all out and build it all up" in one concept.

What he implied was in the high risk cases, and I think he listed four criteria which are fundamental and which are correct in my judgment, that in these cases, one should give consideration at the time of primary ablation to creating a controlled fistula or stoma and then repair that at a later date after the wound has healed.

I think he was fortunate in his series of 39 fistulae that he had only one carotid blow-out. If I am correct, because the gravity of a

fistula is not the fact that you have a hole or that you are losing spit, but that the carotid artery is in this wound and if it is an infected wound without covering and it is postirradiated — particularly with large doses of irradiation — you are, in my experience, threatened with carotid artery hemorrhage and this is the germane factor.

So, we do everything to pay respect to the carotid artery and the highest respect you can pay is to control the wound by negotiating a controlled fistula or stoma at the time of the primary resection.

I think if Dr. Dedo applied his own philosophy to the management of his own cases, he could reduce 9% incidence of fistula, which is an acceptable percentage, to half of that.

MAX L. SOM, M.D. (New York, New York): I enjoyed these two papers immensely. I would just like to make one comment with reference to the beautiful presentation by Dr. Dedo. And that is, when the fistula occurs, the risk there is to the carotid artery. When the fistula occurs and the carotid artery is endangered, and you raise the flap and cover the carotid artery, I would suggest that no attempt be made at that time to close the oropharyngeal fistula.

I think that the carotid artery should be covered immediately and then the fistula closed at a later date using a good healthy flap. If you close anything but a very small fistula after you have used a delta pectoral flap, then if you tried at the same time to close a larger fistula, I think you are endangering the flap and in most cases you will have a second fistula. I suggest you just take care of coverage of the carotid artery primarily and delay your fistula closure for a few weeks later. You probably will be ahead of the game.

CHAIRMAN BRYCE: Thank you, Dr. Som.

I think one point might be made which hasn't been made. I believe that in a heavily irradiated case where a laryngopharyngectomy and block dissection is necessary, the block dissection should be staged, if at all possible, and this will also help in the reduction.

GABRIEL F. TUCKER, JR., M.D. (closing): I neglected to mention the fact that my brother is my co-author and obviously the only reason he could do the pointing while I did all the reading was that he knew all the material as well as I did.

I want to thank Dr. Conley and Dr. Kirchner for their kind remarks. In reply to Dr. Kirchner's speculative question, I am afraid the answer is not going to be that simple. If we go through this material, and I am sorry we had to go through it as quickly as we did,

in the first monkey, the spider monkey, the epiglottis is a fairly solid, straight plate of cartilage.

As we get down into the mangaby we begin to see some variation. Actually, in the last case we showed (the baboon), the sections do show the elaboration and the piercing by glands that you would see in a human, in addition to the duct, so I think it is probably a little more complex. I do not think I can make that straight extrapolation.

JOSEPH H. OGURA, M.D. (closing): I think it is appropriate to say when the study was initiated it was primarily preoperatively oriented for the jaws and for the larynxes and so forth, and the bulk of the cases came up at the later part of the time when the radiation dose was much higher.

The fistula rate we recognized as increasing, and as Dr. Conley so appropriately put it, there is something wrong with the way we were doing it.

Now, today, what we do with these large lesions in the pharynx, as our dose of preoperative irradiation increases, is to prepare a medial based flap and intentionally do a diversionary fistula.

If the resection is carried out, the primary

objective is to cover the carotid artery. I intentionally create a large opening to a smaller opening using a medial based flap covering the artery, sealing that area off over a dermal graft and making an opening smaller.

In other words, it is now an anterior pharyngostome.

In this way, you decompress the pharynx and in this way you avoid the complications. You do have a fistula, though.

Now, if you have a delayed type of fistula, we immediately bring up a delta pectoral flap and we convert that fistula that is present to another smaller fistula.

If we have a large fistula, and into the neck, a primary concern is to seal off that carotid artery. When Max was here he mentioned something about changing the fistulas from a large fistula to a small fistula and the way is to bring up a delta pectoral flap and seal off the neck dissection side by bringing the apex up, closing and surrounding the carotid artery and leaving the middle part of the flap towards the anterior portion of the pharyngostome. Then this can be closed by a secondary procedure. In this way we have reduced our morbidity and our complications immensely.

Executive Sessions

FIRST EXECUTIVE SESSION

SUNDAY, APRIL 6, 1975

The first Executive Session of the Ninety-sixth Annual Meeting was convened at 8:15 A.M. in the Phoenix Ballroom of the Hyatt Regency Atlanta, Atlanta, Georgia, Joseph H. Ogura, M.D., President of the Association, presiding.

The two items on the agenda were the election and introduction of Fellows and the appointment of the Nominating Committee.

The following candidates, after recommendation by the Council, were unanimously elected:

For Active Fellowship:

Byron J. Bailey, M.D., Galveston, Texas.

Hugh F. Biller, M.D., New York, N. Y.

Roger Boles, M.D., San Francisco, Calif.

Fernando R. Kirchner, M.D., Kansas City, Kans.

Alan M. Nahum, M.D., San Diego, Calif.

Philip M. Sprinkle, M.D., Morgantown, W. Va.

M. Stuart Strong, M.D., Boston, Mass.

For Emeritus Fellowship:

John M. Converse, M.D., New York, N. Y.

Walter P. Work, M.D., Detroit, Mich.

For Honorary Fellowship:

Edwin N. Broyles, M.D., Baltimore, Md.

Anderson C. Hilding, M.D., Duluth, Minn.

Following their election the new Fellows were introduced to the Association by their respective sponsors, presented with certificates of Fellowship, and welcomed by President Ogura.

Dr. Arthur Cracovaner was elected Chairman of the Nominating Committee with Drs. Loring Pratt, William Saunders, Harold Tabb and Lup Pang to serve with him.

SECOND EXECUTIVE SESSION

MONDAY, APRIL 7, 1975

The second Executive Session was convened by President Ogura at 8:15 A.M. Annual reports of the officers of the Association were presented, and reports from committee chairmen were also heard.

REPORT OF THE SECRETARY

The membership as of the date of the Ninety-sixth Annual Meeting, April 6-7, 1975, is as follows:

Active	92
Emeritus	33
Honorary	10
Corresponding	15
<hr/>	
Total	150

Fourteen candidates were proposed for membership in 1975. All were excellent candidates, distinguished for character and achievement. Yesterday, you elected seven and warmly welcomed them into the Association. We are already enjoying the exhilaration of this fresh infusion among us. Our interest now turns to the others. Some were merely lacking in years of maturity that seems to bring to the fullness of development that indefinable charisma so notably present in the members of the ALA. Choosing candidates for the ALA is much like choosing among great wines; some reach their peak quickly and are ready, some need a year or two for full development, others mature slowly, but never cease to surprise us with their new achievements — they are the delight of our company. You have done well this year in proposing this fine group of men. The vitality of the Association depends on your continued effort to bring into the Association candidates whose character, talent and achievements are wedded to a congenial and kindred spirit. Only once, and for a very brief time of a few months, the Association reached its full membership of 100. May we hope that in the natural course of events, this may happen again.

The Secretary has had the pleasure of working with the Baker Family during this past year in setting up The Daniel C. Baker, Jr., Memorial Fund and Lectureship. They have been most generous in many ways, not the least of which is the amount of time and effort they expended in contacting friends and patients of Dr. Baker who have added generously to the Fund. The Lectureship in Laryngology will be an event of international importance. Your participation in the selection of a subject and speaker will be enlisted during the year. The Association, in the past, has frequently desired to bring to the Annual Meeting a speaker of international importance, but the funds to do so were not there. Now it can be done.

Though the time is out of joint for soliciting your generosity in building up the Research Fund, it is our hope that the members will plan to become Benefactors of the Association. Many of you have already made a start and we encourage you to become Benefactors of the Association. To this end, we have separated the listing of the Benefactors from The Memorial Funds, as it seemed more appropriate.

The 1976 Annual Meeting will be held in Palm Beach, Florida, at The Breakers Hotel. The two senior societies will hold their meetings at the beginning of the week. There are two arrangements which the members may consider: to meet Sunday and Monday, alternating the morning and afternoon sessions with the Otological Society and holding the banquets on Sunday and Monday evenings; this was the arrangement accepted in the first discussions of the Secretaries. The Otological won the toss and chose to have its banquet Sunday evening. Ours would then follow on Monday evening. However, there is another option which the Council recommends and would like you to consider. To wit, that the Laryngological meeting start on Saturday with our banquet on Saturday evening and the second scientific session to be held on Sunday morning. Members may find the pleasant ambience of Palm Beach sufficient inducement to leave home Friday night and have a pleasant weekend in the Florida sunshine.

Respectfully submitted,

John F. Daly, M.D.
Secretary

(This report was duly accepted by the Fellows.)

REPORT OF THE TREASURER

AMERICAN LARYNGOLOGICAL ASSOCIATION

GENERAL FUND

OPERATING STATEMENT AND FUND BALANCE —
FISCAL YEAR ENDING MARCH 31, 1975*Exhibit A**Income*

Dues (86 @ \$100.00; 5 new members @ \$150.00)	\$9,350.00	
Sale of Transactions	378.62	
Sale of Banquet Tickets	1,670.00	
Interest (Savings Acct. \$495.90; S&L \$1,389.07)	1,884.97	
Assessments re Centennial	2,250.00	
		<u>\$15,533.59</u>

Expenses

Annual Meeting 1974 (Palm Beach)

Reception and Banquet	\$2,063.99	
Reporting	558.98	
Projection	225.20	
Programs, inserts and Membership Certificates	1,003.89	
Guest of Honor	594.00	
Miscellaneous	79.25	
		<u>4,525.31</u>

Total Annual Meeting Expense	4,525.31	
Council Expense	1,360.47	
Transactions and Editorial Expense	5,123.73	

General Expense

Stationery, printing, postage	2,354.06	
Clerical Hire	700.00	
Auditing	175.00	
Treasurer's Bond	55.00	
Dues — Int. Fed. Otolaryngological Societies	100.00	
National Society of Medical Research	100.00	
American Council	150.00	
Miscellaneous	63.12	
		<u>3,697.18</u>

TOTAL GENERAL EXPENSE	3,697.18	
TOTAL EXPENSES		<u>14,706.69</u>

NET INCOME FOR YEAR (including \$2,250.00 Centennial Assessment)	826.90	
Fund Balance March 31, 1974	9,240.13	
Fund Balance March 31, 1975	10,067.03	
Less Escrow Centennial Assessment	2,250.00	
Fund Balance March 31, 1975 — excluding Centennial Assessment	7,817.03	

AMERICAN LARYNGOLOGICAL ASSOCIATION

TRUST FUND

OPERATING STATEMENT AND FUND BALANCE —
FISCAL YEAR ENDING MARCH 31, 1975*Exhibit B**Income*

Interest on U. S. Series H Bonds	\$ 389.68	
Dividends Common Stocks and Mutual Fund	1,610.58	
Daniel C. Baker, Jr., Memorial Fund:		
Family Gift	20,000.00	
Gifts of Others	7,965.00	
Gift of Edley Jones in Memory of Francis Weille	100.00	
		\$ 30,065.26

Expense

DeRoaldes Medal (Dr. Boies)	400.00
Net Income for Fiscal Year	29,665.26
Fund Balance March 31, 1974	81,410.22
Fund Balance March 31, 1975	111,075.48

TRUST FUND ASSETS

Cash	8,958.73
Savings Certificates (First Federal Savings and Loan Association of Philadelphia)	20,000.00
U. S. Treasury Bills — (\$25,000.00) at cost	24,612.50
Investments (Exhibit D)	
U. S. Bonds Series H at cost, par and maturity	\$ 6,500.00
Common Stocks	
Purchased (at cost)	11,617.52
Donated (market value at donation)	2,362.00
Mutual Fund (Mass. Inv. Trust) at cost	37,024.73
	57,504.25
Total Trust Fund Assets:	111,075.48

CASH SUMMARY

Cash in Commercial Account (Girard Bank — Philadelphia)	5,715.51
Cash in Savings Account (Girard Bank — Philadelphia)	13,310.25
	19,025.76

Allocation

General Fund (Exhibit A)	10,067.03
Trust Fund (above)	8,958.73
	19,025.76

AMERICAN LARYNGOLOGICAL ASSOCIATION
INDIVIDUAL TRUST FUNDS
MARCH 31, 1975

Exhibit C

	<i>Principal and Retained Earnings 3/31/74</i>	<i>Earnings*</i>	<i>Donations</i>	<i>Awards</i>	<i>Principal and Retained Earnings 3/31/75</i>
Daniel C. Baker, Jr., Memorial Fund			\$27,965.00		\$ 27,965.00
Casselberry	\$11,022.87	\$ 270.84			11,293.71
Johnston	10,436.61	256.43			10,693.04
DeRoaldes	6,950.01	170.76		\$400.00	6,720.77
Newcomb Trust	4,097.34	100.67			4,198.01
Newcomb Prize	956.32	23.50			979.82
Research	31,273.52	1,178.06			32,451.58
Memorial	16,673.55	0.00	100.00		16,773.55
	<u>81,410.22</u>	<u>2,000.26</u>	<u>28,065.00</u>	<u>400.00</u>	<u>111,075.48</u>

*Net income for the year is allocated to each fund in the ratio it bears to the total value of the trust funds at the beginning of the year, except that by action of the Council January 3, 1975, current income from the Memorial Fund is added to the Principal and Retained Earnings of the Research Fund.

AMERICAN LARYNGOLOGICAL ASSOCIATION
TRUST FUND INVESTMENTS
MARCH 31, 1975

Exhibit D

Savings Certificates (First Federal Savings and Loan of Philadelphia)			\$20,000.00	\$ 20,000.00
U. S. Government Bonds (6%)				
Six \$1,000.00 Series H Bonds (at cost)			6,000.00	
One \$500.00 Series H Bond (at cost)			500.00	
				6,500.00
U. S. Treasury Bills - (\$25,000 due 4/24/75) at cost ..				24,612.50
<i>Common Stocks</i>	<i>Shares</i>	<i>Cost</i>	<i>Market Value at Donation</i>	
American Telephone and Telegraph	200	\$10,790.16		
International Business Machines Corp.	1		517.00	
International Business Machines Corp. (1)	9	803.98		
McDonnell Douglas Corp. (2)	112		1,170.00	
McDonnell Douglas Corp. (3)	14	23.38		
McDonnell Douglas Corp. (4)	3			
McDonnell Douglas Corp. (5)	3			
McDonnell Douglas Corp. (6)	33			
McIntire Porcupine Mines, Ltd.	15		675.00	
		<u>11,617.52</u>	<u>2,362.00</u>	<u>13,979.52</u>
Mutual Fund (Mass. Investors Trust) at cost				37,024.73
				<u>102,116.75</u>
TOTAL TRUST FUND INVESTMENTS				

- Notes: (1) Includes 7¼ shares received in stock splits 1965, 1966, 1968, 1973.
 (2) Includes 86 shares received in stock dividends and splits 1964, 1965, 1966.
 (3) Includes 13.44 shares received in stock split 1967; rights exercised to purchase 0.56 share.
 (4) Shares received as stock dividend (3%) in 1972; fractional share sold.
 (5) Shares received as stock dividend (3%) in 1973; fractional share sold.
 (6) Shares received as 5 for 4 stock split 4/30/73.

Respectfully submitted,
Charles M. Norris, M.D., Treasurer

(This report was duly accepted by the Fellows.)

REPORT OF THE ACCOUNTANT

To the members of the American Laryngological Association

Gentlemen:

We have examined the statements of cash receipts and disbursements of THE AMERICAN LARYNGOLOGICAL ASSOCIATION, including Trust Funds, for the fiscal year ended March 31, 1975. Our examination was made in accordance with generally accepted auditing standards, and accordingly included such tests of the accounting records and such other auditing procedures as we considered necessary in the circumstance.

Cash receipts and disbursements were verified as recorded to date, and all securities were examined or accounted for as of this date.

In our opinion, the accompanying statements of cash receipts and disbursements present fairly the financial position of The American Laryngological Association and its Trust Funds at March 31, 1975, on a cash basis, and the results of its operations for the year then ended, in conformity with generally accepted accounting principles applied on a basis consistent with that of the preceding year.

Respectfully submitted,

Graham, Crossan, Horrocks & Company
Certified Public Accountants

April 1, 1975

(This report was duly accepted by the Fellows.)

REPORT OF THE LIBRARIAN, HISTORIAN AND EDITOR

The Ninety-fifth Annual Meeting of the American Laryngological Association was held at The Breakers, Palm Beach, Florida, on the mornings of Friday and Saturday, April 26 and 27, 1974. Seventy-eight Fellows (67 Active, 2 Honorary and 9 Emeritus) along with 108 guests were officially registered.

Most of the essayists were again cooperative in turning over their manuscripts for publication, either at the time of the reading of their paper, or, as is always earnestly requested, had already forwarded them directly to the publishers before the meeting. The remaining ones, with a single exception, were mailed to the ANNALS Publishing Company within the following twelve days.

Mrs. Edna Pollack of the Martin Johnson Agency of New York was again our official reporter, and with her usual efficiency returned the completed transcript of the entire meeting on May 28. Discussions for corrections were immediately mailed out, and with only a few exceptions promptly returned, so that the Editor had to correct personally, as well as he could, only two of them. Completed manuscript of the meeting was mailed from Boston on June 24, but galley proof was not returned until October 22, in keeping with the rotation policy of the ANNALS Publishing Company. This year we led off, with publication of our ALA papers in the July-August issue, so we were last to receive our TRANSACTIONS. They were finally mailed on February 3, 1975, 170 volumes in all. Ninety-two were mailed to Active members, 8 to Honorary members, 6 to families of the recently deceased, along with one to the Library of Congress, 51 on standing orders and 12 on single

orders. Purchase price to libraries and booksellers was \$15.00, and \$6.00 to those Emeritus members who had placed orders.

Total cost to the Association was \$4,906.13, reflecting not only increased publishing costs, but the fact that the 1974 volume contained the 10-year index, (16 extra pages) accounting for a larger issue with 195 pages, as against 158 for the 1973 volume. This year only 200 copies were ordered, rather than the customary 225, but this still gives us a surplus of 30 for future sale.

On January 7 the Editor sent letters to all essayists for our present meeting, enclosing copies of the ANNALS rules and regulations for publication of papers, with an urgent request to have copies in the ANNALS office prior to the meeting, and a copy here for the use of Mr. Alfred Walter of the Beaumont, Heller and Sperling Company, who is our liaison public relations man with the visiting editors of the various medical periodicals and the lay press. AudioDigest Foundation of Los Angeles again recorded the meeting for the use of their subscribers.

As Historian, I have the sad duty to record seven deaths since our 1974 meeting:

Active Members:

Daniel C. Baker, Jr.	June 2
James J. O'Neil	October 15
Francis L. Weille	November 10

Honorary Members:

Sir Victor E. Negus	July 24
Henry L. Williams, II	May 28

Emeritus Members:

Oliver E. van Alyea	May 10
Walter E. Theobald	December 15

We shall always remember them as honored colleagues and devoted Fellows of our Association.

Respectfully submitted,

Charles F. Ferguson, M.D.

Librarian, Historian and Editor

(This report was duly accepted by the Fellows.)

REPORT OF THE AMERICAN BOARD OF OTOLARYNGOLOGY

As representatives of the American Board of Otolaryngology to the American Laryngological Association, Inc., we are pleased to report to you on the activities of the American Board of Otolaryngology.

We have previously reported to you the changes in the format of the examination for certification. This format has been in effect for the last three examinations, and in general, has seemed to provide a satisfactory method of evaluating candidates for certification.

The examination for 1974 was held in the Palmer House, Chicago, Illinois, from November 4 through November 8, 1974. Three hundred eighty-one candidates were examined on this occasion. Of these, 275 were certified and 106 were not. Forty-two

of those who failed to qualify for certification had failed on at least one previous occasion also.

Respectfully submitted,

Frank D. Lathrop, M.D.

Paul H. Holinger, M.D.

Representatives to the
American Board of Otolaryngology

(This report was duly accepted by the Fellows.)

REPORT OF THE ALA REPRESENTATIVE TO THE AMERICAN COUNCIL OF OTOLARYNGOLOGY

The American Laryngological Association's Representative to the American Council of Otolaryngology is a member of the Board of Directors of the ACO. In that capacity I attended the Board Meeting on October 9, 1974. The membership of the ACO is 3,004. This represents an increase of 10% over the 1973 membership. The total number of otolaryngologists in active practice in the United States is over 5,000. Thus, the membership in the ACO represents about 2/3 of the total in active practice.

The ACO has a category for membership for residents; there are some 458 resident members of the ACO.

The Board of Directors is a rather large group of some 29 members, which includes the officers of the ACO, the Representatives from the House of Delegates, Representatives from the 14 sponsoring societies.

The ACO has a seven man Executive Committee which is responsible for carrying on the business when the Board of Directors is not in session.

The important feature of the structure of the ACO is the House of Delegates which provides broad representation on a state-by-state basis so that the ACO provides representation for the otolaryngologist in practice in all areas of the country. As you know, the American Council of Otolaryngology was formed so that our specialty would have a central unifying organization that could speak with a single voice when federal, state and other agencies looked for information and guidance and also in the opposite direction, that the average otolaryngologist could make his views known through a national organization.

The effectiveness of this organization has been attested by its activities in areas of manpower, professional liability, conservation of hearing and other national health problems and in providing a placement service for otolaryngologists.

The importance of this organization to otolaryngology would be impossible to overestimate. Its success was brought home recently to me when the members of the neurosurgical community came to see me to get information for setting up a similar organization to represent neurosurgery.

Where so many have contributed to the success of the ACO, it is hazardous and usually considered imprudent to single out any group of individuals for special mention. However, I think that everyone would agree that the first President, Jerry Hilger, and the First Executive Director, John Bordley, deserve in everyone's opinion special mention and our deep gratitude.

The organization has been most fortunate in having a successor to Dr. Bordley in the person of Ray Jordan and the present incumbent of that key job, Harry McCurdy.

The American Council of Otolaryngology is in sound financial position. It would be difficult to cover the wide range of reports that were made by Chairmen of the various Committees reporting at the Board of Directors Meeting. Almost every facet of the socio-economic and political aspects of otolaryngology practice are being actively investigated. If one were to select two items for special mention they would be: 1) the Manpower Study for Otolaryngology which the ACO undertook in collaboration with HEW. This study undoubtedly will furnish the data for manpower decisions that the government may be making in the future and it will be important in the recommendations that will emanate from otolaryngology itself; and 2) the second report is one that is far reaching, that is, the Future of Otolaryngology Committee, chaired by Dr. Joseph Goldman. This Committee report is an extremely important one in that it touches on the key issues affecting medicine and specifically, of course, otolaryngology, e.g., Continuing Education, the credentialling process, the structure of residency programs, the geographic distribution of otolaryngologists, the problem of multiple meetings and multiple societies in otolaryngology. The report points up areas that will involve a great deal of discussion in the coming years.

The American Laryngological Association makes a rather modest financial contribution to the American Council of Otolaryngology. It represents a token appreciation of the excellent and important work that this organization is doing for us.

Respectfully submitted,

John F. Daly, M.D.

Representative to the

American Council of Otolaryngology

(This report was duly accepted by the Fellows.)

REPORT FROM THE BOARD OF GOVERNORS AMERICAN COLLEGE OF SURGEONS

The Governors attended a preview of the SOSSUS material on October 19, 1974. The formal meeting of the Board took place October 20 and 23, 1974, in Miami Beach.

The meeting was convened by Robert C. Hickey, Chairman of the Board of Governors, who introduced Claude E. Welch, President of the College. Doctor Welch stated the College's second Surgical and Education and Self Assessment Program (SESAP II) had been prepared at an overall cost of one million dollars. He described the College's current position on PSRO as one in which individual Fellows who believe in the concept were encouraged to work with local organizations to develop the suggested surgical criteria. It was felt at this time PSRO was still much in the state of flux.

Doctor Frank E. Stinchfield, Chairman of the Board of Regents, discussed continuing education which he felt should be in the hands of surgical specialties and not determined by the AMA, the AAMC, or any governmental body. Toward this end he announced the College planned to establish a Department of Continuing Education, headed by a full-time director and staff. He announced a further

study was being made of measures by which clinical competence might properly be evaluated.

Dr. C. Rollins Hanlon, Director of the College, described the formation of a new Department of Surgical Practice, charged with a greater study of how socio-economics affect the quality of care. This new Department will analyze the implications of the SOSSUS Report as it is finally published.

Mr. Robert G. Happ, College Controller, was introduced and gave a detailed Financial Report which appears in the February, 1975, Bulletin. It should be noted the College plans to increase dues by small increments as necessary rather than by quantum jumps every few years.

Dr. Luis F. Sala, Secretary of the Board, reported membership at 189 with 61 Governors representing specialty societies in the United States and the remainder, Governors at large in the United States, Canada and Latin America.

Dr. Robert C. Hickey, Chairman, then gave his own report describing the increased utilization of Governors by placing them on more committees.

At the afternoon meeting the Governors were invited into discussion groups on PSRO, Professional Liability, Surgical Education, Re-Certification, Surgeons' Assistants, Financing Graduate Surgical Teaching, Surgical Care in Hospitals of Fifty Beds or Less, and Non-U.S. Governors. I was in the Professional Liability Group, which I must say proved disheartening. Since that date, the College has become much more active in professional liability matters with frequent mailings to keep the Governors up to date on its activities, especially in states where professional liability insurance has become a critical problem.

Reports from all the discussion groups were made and discussed at the adjourned meeting on October 23.

The Advisory Council for Otorhinolaryngology held its annual meeting on October 22 chaired by Dr. John T. Dickinson. The Governors were invited to this meeting, the highlight of which was our Regent, Dr. Loring Pratt's discussion of the current debate with the plastic surgical group which objected to the term "maxillofacial, plastic and reconstructive" appearing in the listed Essentials for otolaryngology. I would say in this critical fight our Regent, aided by the logic of our position and his own talent, maintained our position well.

This report, being made six months after the annual meeting, is always somewhat dated. Again, I would suggest you read the Bulletin of the American College as it appears and would welcome any input from the membership as would our Regent and the Advisory Council.

Respectfully submitted,

William M. Tribble, M.D., F.A.C.S.
Governor A.C.S.

(This report was duly accepted by the Fellows.)

REPORT OF NATIONAL SOCIETY FOR MEDICAL RESEARCH

Your representative attended the 28th National Council Meeting of the National Society for Medical Research held at the Palmer House in Chicago on February 1, 1975. About ninety individuals were in attendance. Because of a conflict with the Middle Section Meeting of the Triological Society, your representative found it necessary to leave during the sixth item of the Agenda.

The seriousness of this organization, in protecting the interests of research involving animals, is readily apparent. As such the organization is rendering a definite service to medicine and to our specialty.

Of special concern to many of those present was the Annual Animal Use Report Form for the United States Department of Agriculture. This was a new form, had headings that were not previously used, was issued with only two weeks to complete the form. It was obviously impossible for many of the institutions to abide by the deadline and considerable resentment was expressed. The Honorable Thomas S. Foley, Member of the House of Representatives from Spokane, Washington and Chairman of the Subcommittee on Livestock and Grains of the Committee on Agriculture, gave an address entitled, "Outlook for Animal Welfare Legislation in the 94th Congress." Representative Foley seemed to be sympathetic to the problems created by the Annual Report Form and indicated that he and his Committee would look into the matter very thoroughly.

Concern was expressed by the successes of the Antivivisectionists, particularly in New Jersey, where Governor Brendan T. Byrne signed a Bill into law banning the sale of impounded animals for medical research.

Another item along the same line of great concern was the film, "Primate." This was produced by Frederick Wiseman and called by the Public Broadcasting Services a documentary film. The film was made at the Yerkes Primate Research Center of Emory University in Atlanta. The film was anything but a documentary and pictured, in a glaring way, the so called "tortures" used for animals. The sound track was very skimpy and very little explanation was given and the explanations that could have been given would have explained what was being shown by the film. For example, cages were being shown wheeled into a large autoclave and wheeled out again steaming, the implication being that there were animals in the cages and no explanation was given that it was used for cleaning and sterilizing the cages. Geoffrey H. Bourne, director of Yerkes, allowed the film to be made there with the provision that Yerkes would have the privilege of seeing the film before it was displayed with the privilege of editing. This was not done. The furor caused by this film has been extensive and Dr. Bourne has filed a complaint with the Federal Communications Commission.

Albert H. Andrews, Jr., M.D.
Representative to N.S.M.R.

(This report was duly accepted by the Fellows.)

REPORT OF THE NOMINATING COMMITTEE

The Nominating Committee met yesterday and is happy to present the following slate for the Council for the year 1975-1976:

Stanton A. Friedberg, M.D.
John S. Lewis, M.D.
Edwin W. Cocke, Jr., M.D.
John F. Daly, M.D.
Charles M. Norris, M.D.

Charles F. Ferguson, M.D.
F. Johnson Putney, M.D.
Frank D. Lathrop, M.D.
G. Slaughter Fitz-Hugh, M.D.
Joseph H. Ogura, M.D.

Respectfully submitted,
Arthur J. Cracovaner, M.D., Chairman

(This report was duly accepted by the Fellows.)

After the scientific session of the morning, the Executive Session was reconvened by President Ogura at 11:45 A.M. The Board of Directors was elected as presented by the Nominating Committee earlier, and after a brief meeting announced the following officers for 1975-76:

President: Stanton A. Friedberg, M.D.

First Vice-President: John S. Lewis, M.D.

Second Vice-President: Edwin W. Cocke, Jr., M.D.

Secretary: John F. Daly, M.D.

Treasurer: Charles M. Norris, M.D.

Historian, Librarian and Editor: Charles F. Ferguson, M.D.

First Councilor: F. Johnson Putney, M.D.

Second Councilor: Frank D. Lathrop, M.D.

Third Councilor: G. Slaughter Fitz-Hugh, M.D.

Fourth Councilor: Joseph H. Ogura, M.D.

Following the election, President Friedberg expressed deep appreciation to Dr. Ogura for his devoted service and presented him with a pin. He also expressed humility and gratitude for his election and pledged a fruitful new year. Meeting was adjourned at 11:50 A.M.

Memorials

SIR VICTOR NEGUS, D.Sc.

1887 - 1974


The death of Sir Victor Negus on the fifteenth of July at the age of 87 marks the end of an era in international, as well as British Laryngology.

Born in February 1887, he was educated at King's College School and King's College in the Strand, London, before entering King's College Hospital in 1909. His initial medical qualification was the Conjoint Diploma which he gained in 1912. After house appointments at his Teaching hospital he acted as clinical assistant to Charles Hope and Lionel College at the Hospital for Diseases of the Throat in Golden Square, for already there was an interest in the field of laryngology. The outbreak of the First World War saw an end to this period of training for he joined the Royal Army Medical Corps and in 1914 sailed to France with the first expeditionary force.

On his return to London in 1919 he obtained the MB.BS degree, FRCS Diploma and joined the Junior Staff at "Golden Square." His interest in Laryngology led to study periods at Bordeaux with Moure and Portmann, with Chevalier Jackson at Philadelphia and finally joining St. Clair Thomson's Department at King's College Hospital as Clinical Assistant. At this time the Department of Otology and Laryngology were separate; and, though they joined later, Victor Negus never really developed an interest in Otology.

His experience in America had convinced him of the urgent need to introduce Chevalier Jackson's methods into Britain; and he designed the laryngoscopes, bronchoscopes and esophagoscopes which are still in use throughout the world. During this early part of his laryngological career he was carrying out the dissections of the larynx of animals at the Royal College of Surgeons, which later were to form the basis of his publication *The Mechanism of the Larynx* produced in 1929. The first part of this was submitted for the Master's Degree in Surgery (MS) of the University of London, gained with a gold medal in 1924. In the same year he was appointed Junior Surgeon in the ENT Department at King's. He was named Surgeon in 1931 and Senior Surgeon in 1940. On retirement in 1952 he became Consulting Surgeon, a position held until his recent death. At the Royal College of Surgeons, where he spent so much of his research time, he was an Arris Gale Lecturer in 1924, Hunterian Professor in 1925 and was awarded the John Hunter medal and triennial prize for 1925-27. He was President of the Listerian Society from 1939-41 being awarded the Lister medal in 1954. As a co-opted member of the Council of the College of Surgeons and an examiner for the Fellowship in Otolaryngology, he ensured that this specialty was not forgotten in the "corridors of surgical power."

In 1942 he was elected President of the British Association of Otolaryngologists. For 20 years he served as Honorary Treasurer of the Collegium Oto-Rhino-Laryngologicum Amicitiae Sacrum and was President at its meeting in London in 1954. His many other academic and professional achievements were rewarded in 1956 when he was knighted, an honor so richly deserved.



SIR VICTOR NEGUS, D.Sc.

Apart from his monograph on the *Mechanism of the Larynx*, he produced his *Comparative Anatomy and Physiology of the Nose and Paranasal Sinuses* in 1958 and in 1965, *Biology of Respiration*. Later in his life he became a trustee of the Hunterian Collection in the Royal College; and in 1967, while Chairman of the trustees, published his book *The Artistic Possessions at the Royal College of Surgeons of England*.

These are the mere bones of an exceptional man, possessing both ability and energy, being perhaps fortunate to be born at the time when a growing field of work was ripe for his particular attributes. Of Victor Negus it can well be said — Laryngology owed him much!

D. F. N. H.



JAMES JULIAN O'NEIL, M.D.

JAMES JULIAN O'NEIL, M.D.

1919 - 1974

James Julian O'Neil, a member of the American Laryngological Association since 1961, died unexpectedly October 15, 1974.

Jim O'Neil was born January 20, 1919, at Council Bluffs, Iowa. He was graduated from Creighton preparatory school and received his medical degree in 1943 from Creighton University School of Medicine. He served in the armed services from 1944-1946. Following this, he completed his graduate work at the University of Illinois and returned to Omaha to practice in 1949.

Doctor O'Neil continued to carry on an active participation in teaching and an active practice in Omaha up until the time of his demise. He was an active member of the Broncho-Esophagological Association, the American Society for Head and Neck Surgery, the Triological and the American College of Surgeons. He served on many committees in these organizations.

He is survived by his wife, Rosemary, two sons, James J., Jr., and Robert H., and two grandchildren.

Doctor O'Neil's untimely passing left incomplete much of his sharing program with his colleagues as he was an ardent student and a dignified, active member of our specialty.

The Members of the American Laryngological Association collectively extend our sympathy to Rosemary and his sons.

R. I. W.



WALTER HENRY THEOBALD, M.D.

WALTER HENRY THEOBALD, M.D.

1886 - 1974

Many eulogies have been written about this otolaryngologist long before and since his death in Bethesda, Maryland, at the age of 87 years. Few can compare with one written in 1959 by his life-long friend and colleague, Francis Lederer. Following are excerpts from his comments. He aptly described Dr. Theobald as "this wiry, dapper and energetic native of Oconomowoc, Wisconsin . . . who not only played piano at parties there with an orchestra but commanded an impressive position as traveling examiner for the Illinois Central Railroad following his internship at St. Luke's Hospital. A private car convinced Mildred Morkill, a St. Luke's nurse, that Walter was on his way, and more than 50 years of married life verified her confidence in his destiny.

"An early association with Norval Henry Pierce, but not at the prevailing financial remuneration commanded by our budding young men of the present era, (namely, \$50 per month), at least permitted Walter to eat, but more importantly, to meet one of the largest and most influential clienteles in Chicago. Many of these patients played roles in the success of Dr. Theobald as an otolaryngologist as well as a businessman associated with various endeavors, including the Champion Machinery Company, the Bannon Construction Company, not to disregard his four decades of activity in a pea canning factory in Oconomowoc. Not all of these were successful ventures, for as I understand it, when the sidewalks they made for Al Tierney's place caved in, so did the construction company. Nevertheless, success was his in a million dollar bid for McCormick road when his company didn't even have a shovel! Other areas of action were more rewarding. The large gates to Soldier Field hinge on a Theobald enterprise!

"Walter has had a following representing every section of society, from the highest to the lowest. His 'stock in trade' was the ability to listen and deftly handle instruments which permitted him to cannulate a middle meatus, an attic perforation, or a Eustachian orifice so skillfully as to be especially noted by his appreciative patients.

"Two societies, our own Chicago Laryngological and Otological, and the American Academy of Ophthalmology and Otolaryngology, have recognized Walter Theobald by bestowing their highest office upon him. His professorial climb began in 1915 at the University of Illinois until his retirement in 1954 as Clinical Professor Emeritus. These would attest to his otolaryngological competence at a local as well as at a national level, but even of greater magnitude is his contribution as Citizen Theobald. For many years Dr. Theobald was intimately associated with other prominent physicians who envisioned a great medical center for the area surrounding Cook County Hospital, Presbyterian Hospital, the University of Illinois and its Research and Educational Hospitals, and other medical and dental institutions in the immediate neighborhood. After many discouragements this dream became a reality by the establishment in 1941, through an Act of the Illinois Legislature, of the Medical Center District, comprising 305 acres. Dr. Theobald has been a member since the inception of the Medical Center Commission, and has served as its president continuously (from 1946 to 1972). Under his administration, large tracts of blighted areas in the district have been acquired and sites have been made ready for the construction of new hospitals, nursing schools and related institutions. Major

projects including two large hospitals representing an investment of \$20,000,000 have recently been completed and a third, to cost \$5,500,000, is under construction. These will account for an addition of approximately 1,500 beds to the hospital complement of the Medical Center District. Right now there is a total of six projects under construction at an estimated cost of \$19,000,000. The program for the five years ending in 1963 will cost about \$98,000,000.

"Ultimate plans developed under Dr. Theobald's administration call for an investment of more than \$300,000,000 in institutional buildings and in the construction of modern housing facilities and park areas — combining to make the Medical Center District a mecca for teaching, research and service to humanity.

"We admire the heritage left by a painter or a sculptor. Enduring is their art. Walter Theobald combines these talents and will leave behind him monumental enterprises which will continue to occupy sites in Chicago's skyline, but more importantly, herald discoveries which will relieve humanity's burdensome ills."

Dr. Theobald was born December 19, 1886 in Oconomowoc, Wisconsin, graduating from the University of Chicago as a Bachelor of Science in 1909 and a Doctor of Medicine from Rush Medical College in 1911. He joined the faculty of the University of Illinois College of Medicine in 1915 and was certified by the American Board of Otolaryngology in 1925, one year after its founding. In addition to many other offices, Dr. Theobald had been Chairman of the Board of the Institute of Medicine of Chicago.

Dr. Theobald is survived by a son, Pierce L. Theobald, M.D., of Chicago; a daughter, Mrs. Harriet Elwood; six grandchildren; and three great-grandchildren. His accomplishments through a knack of getting people to cooperate with him in great ventures to achieve his goals are indelibly engraved on Chicago, the State and the Nation.

P. H. H.

HENRY LANE WILLIAMS, JR., M.D.

1898 - 1974

Henry Lane "Bill" Williams, Jr., was born in 1898 in Philadelphia, Pennsylvania. In his youth he lived in Minneapolis where his father combined a medical practice with the position of head football coach at the University of Minnesota, a major football power of the time. He attended the University of Minnesota, transferring to Yale when his father became coach at that institution. Bill played football under his father's instruction and was granted the degree of A.B. in 1921. After receiving the degree of M.D. from the University of Pennsylvania in 1924 he interned for one year in Philadelphia, then returned to Minnesota where he lived until his death in 1974.


In 1925 he entered the Mayo Foundation as a Fellow in Otolaryngology and Rhinology, beginning a distinguished career in our specialty in which he combined the functions of thoughtful and innovative practitioner, inspiring teacher, and dedicated clinical researcher. At the completion of his training in 1928 he was appointed first assistant and in 1930 consulting physician in the department of Otolaryngology and Rhinology at the Mayo Clinic and instructor in the Mayo Foundation, Graduate School of Medicine, University of Minnesota.

He married Helen G. Craddock in 1930. The Williams lived in Rochester, Minnesota until 1963 with exception of a two-year period of practice in Minneapolis from 1932 to 1934. Their home was the scene of warm hospitality for many distinguished Otorhinolaryngologists who came to visit and to observe his work. The Williams have three children, Katherine, Henry Lane, III, and Elizabeth (Mrs. Roger Plunkett).

His professional interests were directed to Otology and Rhinology in keeping with the distribution of practice at the Mayo Clinic at the time. He forcefully advocated reorganization of the specialty within the institution and laid the groundwork for the eventual consolidation of the various subspecialties into a single department.

Bill's writings reveal his deep conviction that Oto-Rhino-Laryngology was as much a medical as a surgical specialty, as well as his intense interest in new developments in the field. His early papers were concerned with infections and their complications. Later he contributed to the development of modern surgery of the ear and finally his interests turned to the role of allergy, immunology and endocrinology in diseases of the ear and nose.

He was associated with graduate education throughout his career. At Mayo he was Professor of Otolaryngology and Rhinology and served as head of the department from 1951 to 1958. He was senior consultant from 1958 to 1963. Following retirement from Mayo Clinic he joined the faculty of the University of Minnesota and became director of Resident training at the Veterans Administration Hospital in Minneapolis. He continued as consultant at the V.A. Hospital until his death. His ideals are perpetuated by his many students.



HENRY LANE WILLIAMS, JR., M.D.

Bill was a member and took an active role in the affairs of many professional societies. These include: The American Academy of Ophthalmology and Otolaryngology, The American Laryngological, Rhinological and Otological Society, Inc., of which he was Vice President in 1952, The American Otological Society (President 1960-1961), The American Laryngological Association, the Otosclerosis Study Group (President 1951-1952), The American Rhinological Society (President 1968-1969), and the American Society for Facial Plastic and Reconstructive Surgery.

Henry Lane Williams, Jr., was associated with Oto-Rhino-Laryngology for nearly half a century. His was an era of rapid progress in medicine and in his chosen field. He leaves significant contributions to the progress of our specialty through his own untiring work and the continuing efforts of many of his students.

His was a job well done.

K. M. S.



OLIVER E. VAN ALYEA, M.D.

OLIVER E. VAN ALYEA, M.D.

1889 - 1974

Dr. Oliver E. Van Alyea was born in Princeville, a small town in central Illinois on February 9, 1889, but he became an outstanding leader in the field of Otolaryngology and was world renowned for his studies on the anatomy and physiology of the sinuses and the proper diagnosis and treatment of sinus disease.

Dr. Van Alyea found time for teaching and research in addition to a busy private practice in otolaryngology. He conducted courses for many years at the American Academy of Ophthalmology and Otolaryngology and was a faithful contributing member of the Chicago Laryngological and Otologic Society, the Triological Society and the American Laryngological Association. In 1964, he served as President of the Pan-American Society of Otorhinolaryngology and Bronchoesophagology.

He was chosen to be a Director and Examiner of the American Board of Otolaryngology and was recognized as a kind, thoughtful, and able examiner; he was a capable and dependable member of the Editorial Board of the *Annals Of Otology, Rhinology and Laryngology*.

Much of his academic life was centered in the College of Medicine at the University of Illinois. He became Professor Emeritus in 1957 but continued to come to the Eye and Ear Infirmary regularly to teach the residents until shortly before he suddenly died on May 10, 1974.

We have lost a great clinician, an able teacher, a conscientious, devoted investigator, and a kindly, thoughtful, considerate friend.

B. J. S.



FRANCIS LEE WEILLE, M.D.

FRANCIS LEE WEILLE, M.D.

1899-1974

Francis Lee Weille died quietly in his Needham, Massachusetts home on November 1, 1974. Dr. Weille will long be remembered in Boston and throughout the country as a fine gentleman who was completely devoted and dedicated to medicine.

Francis Weille was born in Brandon, Mississippi. He graduated from the University of Virginia in 1921 and Harvard Medical School in 1925. He served as an intern on the first surgical service at Boston City Hospital, 1925 to 1927, and trained as a Resident in Otolaryngology at the Massachusetts Eye and Ear Infirmary, 1927 to 1929. Thereafter he served as a member of the Staff at the Massachusetts Eye and Ear Infirmary continuously for 45 years.

His memberships in professional societies included the American College of Surgeons, American Laryngological Association, American Otological Society, American Triological Society, American Academy of Allergy, and many others. He was a member of the Phi Beta Kappa, Sigma Alpha Epsilon, Raven and Boylston Societies.

Doctor Weille's accomplishments in medicine were many. His greatest love in medicine was anatomy. For more than two decades he studied and taught in the Anatomy Department of Harvard Medical School. His interests were not only head and neck anatomy, but also neuro-anatomy.

In the mid-forties Dr. Weille was instrumental in bringing several basic science laboratories to the Massachusetts Eye and Ear Infirmary. Among these were the Virology Laboratory, Microcirculatory Laboratory, the D. Harold Walker Laboratory of Biochemistry, and the Eaton-Peabody Laboratory of Auditory Physiology.

In the early 1950's, Dr. Weille was a pioneer in the subspecialty now known as Head and Neck Surgery. He is credited with having performed the first radical neck dissection at the Massachusetts Eye and Ear Infirmary.

While the above achievements outline his academic successes, they reveal little about the warmth of this fine man. Dr. Weille not only loved the *science* of medicine, but also the *practice* of medicine. He was kind to, and loved by, his patients. Their loyalty and admiration for Dr. Weille was so great, it is difficult for those of us who remain to replace him as their physicians.

Many of us in Boston enjoy fond memories of spending weekends with Dr. and Mrs. Weille at their summer home in Dublin, New Hampshire. Sunday morning, while the rest of us relaxed reading the Sunday paper, Francis would invariably be reading a medical journal or studying a medical textbook. He was totally dedicated to medicine and never ceased to learn, to explore, to question.

Dr. Weille leaves his wife, Evelyn (Higginson). Francis and Evelyn worked closely together in medicine and he very much valued her assistance and encouragement. He also leaves a son, Francis Blair Weille of Brookline; a daughter, Mrs. Michael (Adeline) Maccoby of Washington, D. C.; and a sister, Mrs. Elizabeth Carmichael of Tuscumbia, Alabama.

With Dr. Weille's demise, Otolaryngologists everywhere lose a valuable colleague. Yet his enthusiastic approach to medicine, like his energetic attitude toward all of life, is especially missed by his many close friends.

W. W. M.

THE MEMORIAL FUND
LARYNGOLOGICAL RESEARCH FUND

The Council earnestly requests that Fellows of the Association give consideration to making a special bequest to these important funds, or to become a benefactor.

MEMORIAL FUND DONORS

DANIEL C. BAKER, JR.	FREDERICK T. HILL
JOHN F. BARNHILL	GEORGE E. HOURN
AUGUST L. BECK	SAMUEL JOHNSTON
GORDON BERRY	LILA FETTEROLF KENNEDY
WILLIAM E. CASSELBERRY	JAMES E. NEWCOMB
CORNELIUS G. COAKLEY	HENRY B. ORTON
LEE WALLACE DEAN	LYMAN G. RICHARDS
ARTHUR W. DEROALDES	BURT R. SHURLY
FRED W. DIXON	LESTER T. SUNDERLAND
WILLIAM E. GROVE	H. MARSHALL TAYLOR
GORDON F. HARKNESS	WALTER H. THEOBALD

BENEFACTORS

MRS. SALLY SAMPLE AALL	DR. AND MRS. FRANCIS W. DAVISON
MRS. DANIEL C. BAKER, JR.	MR. A. P. MARCHESSINI
DR. EDWIN N. BROYLES	DR. SAMUEL SALINGER
DR. LOUIS H. CLERF	DR. SAM H. SANDERS
DR. SEYMOUR R. COHEN	DR. HARRY P. SCHENCK
DR. JOHN J. CONLEY	DR. DEGRAAF WOODMAN

ZELDA RADOW WEINTRAUB CANCER FUND, INC.



Obverse of the deRoaldes medal

RECIPIENTS OF THE DEROALDES AWARD

- 1928. DR. CHEVALIER JACKSON
- 1931. DR. D. BRYSON DELAVAN
- 1934. DR. HARRIS P. MOSHER
- 1937. DR. LEE WALLACE DEAN
- 1943. DR. RALPH A. FENTON
- 1949. DR. GEORGE M. COATES
- 1951. DR. ARTHUR W. PROETZ
- 1954. DR. LOUIS H. CLERF
- 1959. DR. ALBERT C. FURSTENBERG
- 1960. DR. DEAN M. LIERLE
- 1961. DR. FREDERICK T. HILL
- 1966. DR. PAUL H. HOLINGER
- 1970. DR. FRANCIS E. LEJEUNE
- 1973. DR. LAWRENCE R. BOIES

RECIPIENTS OF THE CASSELBERRY AWARD

1923. DR. GEORGE FETTEROLF AND DR. HERBERT FOX
1928. DR. RALPH A. FENTON AND DR. O. LARSELL
1929. DR. RICHARD A. KERN AND DR. HARRY P. SCHENCK
1929. DR. EDWARD H. CAMPBELL
1931. DR. ARTHUR W. PROETZ
1934. DR. ANDERSON C. HILDING
1936. DR. FRANCIS E. LEJEUNE; DR. JOEL J. PRESSMAN
1939. DR. H. MARSHALL TAYLOR; DR. BRIEN T. KING
1940. DR. FRENCH K. HANSEL
1941. DR. NOAH D. FABRICANT
1946. DR. PAUL H. HOLINGER
1949. DR. HENRY B. ORTON
1962. DR. HANS VON LEDEN
1966. DR. JOHN A. KIRCHNER AND MR. BARRY D. WYKE
1968. DR. JOSEPH H. OGURA

RECIPIENTS OF THE NEWCOMB AWARD

- 1941. DR. BURT R. SHURLY
- 1942. DR. FRANCIS R. PACKARD
- 1943. DR. GEORGE M. COATES
- 1944. DR. CHARLES J. IMPERATORI
- 1947. DR. HARRIS P. MOSHER
- 1948. DR. GORDON BERRY
- 1949. DR. GORDON B. NEW
- 1950. DR. H. MARSHALL TAYLOR
- 1951. DR. JOHN D. KERNAN
- 1952. DR. WILLIAM J. McNALLY
- 1953. DR. FREDERICK T. HILL
- 1954. DR. HENRY B. ORTON
- 1955. DR. THOMAS C. GALLOWAY
- 1956. DR. DEAN M. LIERLE
- 1957. DR. GORDON F. HARKNESS
- 1958. DR. ALBERT C. FURSTENBERG
- 1959. DR. HARRY P. SCHENCK
- 1960. DR. JOEL J. PRESSMAN
- 1961. DR. CHEVALIER L. JACKSON
- 1962. DR. PAUL H. HOLINGER
- 1963. DR. FRANCIS E. LEJEUNE
- 1964. DR. FRED W. DIXON
- 1965. DR. EDWIN N. BROYLES
- 1966. DR. LYMAN G. RICHARDS
- 1967. DR. JOSEPH H. OGURA
- 1968. DR. WALTER P. WORK
- 1969. DR. JOHN A. KIRCHNER
- 1970. DR. LOUIS H. CLERF
- 1971. DR. DANIEL C. BAKER, JR.
- 1972. DR. ALDEN H. MILLER
- 1973. DR. DEGRAAF WOODMAN
- 1974. DR. JOHN J. CONLEY
- 1975. DR. FRANCIS W. DAVISON

Roster of Fellows

1975

LIST OF FELLOWS

Date Indicates Year Admitted to Active Fellowship

Attendance at meetings is shown by figures following each name.

Asterisk (*) indicates year paper was read.

Active Fellows

1962. ALEXANDER, FRED W., Falls Road, Chagrin Falls, Ohio 44022, 1962, '63*, '64, '66, '68, '69, '70, '71, '72, '75.
1974. ALFORD, BOBBY R., 1200 Moursund Ave., Houston, Texas 77025, 1974.
1969. ANDREWS, ALBERT H. JR., 122 S. Michigan Ave., Chicago, Ill., 60603, 1970, '71, '72, '73, '74*, '75.
1962. ARNOLD, GODFREY E., 2500 N. State St., Jackson, Mississippi 39216, 1962, '63*, '64*, '66, '69, '70, '72, '73, '75.
1969. AUSBAND, JOHN R., Bowman Gray School of Medicine, Winston-Salem, N. C. 27103, 1970, '71, '72, '73, '75.
1975. BAILEY, BYRON J., Dept. Otol., UTMB, Galveston, Texas 77550, 1975.
1970. BALLENGER, JOHN J., 723 Elm St., Winnetka, Ill. 60093, 1971, '72, '73, '74, '75.
1963. BAXTER, JAMES D., 687 Pine Ave. West, Montreal, 112, Quebec, Canada, 1963, '65*, '66, '67, '68, '69, '70, '71, '72, '73, '74.
1975. BILLER, HUGH F., Mt. Sinai Hosp., 100th St. & Fifth Ave., New York, N. Y., 1975.
1975. BOLES, ROGER, Dept. Otolaryng. Univ. of Cal., San Francisco, Cal., 1975.
1955. BORDLEY, JOHN E., Johns Hopkins Hospital, Baltimore, Maryland 21205, 1955, '56, '57, '59, '60, '62, '63, '64, '65, '66, '67, '69, '70, '71, '72, '73*, '74, '75.
1959. BREWER, DAVID W., 1100 E. Genesee St., Syracuse, N. Y. 13210, 1959, '60*, '61, '62*, '63*, '66, '70, '73, '74*.
1955. BROWN, LESTER ALEXANDER, 490 Peachtree Street, N.E., Atlanta, Georgia 30308, 1955, '56, '57, '58, '59, '61, '63, '65, '68, '69, '70, '71, '72, '73*, '74, '75.

1963. BRYCE, DOUGLAS P., O.P.D. Toronto General Hospital, Toronto, Ontario, Canada, 1963*, '64, '66*, '67*, '68*, '69, '70, '71, '72, '73, '74, '75.
1968. CHANDLER, J. RYAN, 1700 N.W. 10th Ave., Miami, Fla. 33136, 1968, '69*, '70, '71, '72, '73, '74, '75.
1967. COCKE, EDWIN W., JR., 899 Madison, Memphis, Tenn. 38102, 1967, '68, '69, '70, '72, '74, '75.
1964. CODY, CLAUDE C., III, 1600 Memorial Professional Building, Houston, Texas 77002, 1964, '65, '67, '69, '71, '73, '75.
1971. COHEN, SEYMOUR R., 6221 Wilshire Blvd., Los Angeles, Calif. 90048, 1971, '72*, '73*, '74, '75*.
1957. CONLEY, JOHN J., 211 Central Park West, New York, N. Y. 10024, 1958*, '60*, '61, '62*, '63*, '64, '65, '70, '72, '74*, '75*.
1959. CRACOVANER, ARTHUR J., 103 E. 78th St., New York, N. Y. 10021, 1959, '60, '61*, '62, '63, '65, '66, '67, '68, '69, '72, '74, '75.
1960. DALY, JOHN F., Faculty Practice Offices, 566 First Ave., New York, N. Y. 10016, 1960, '61*, '62, '63, '64, '65, '66, '67, '68, '69, '70, '71, '72, '73, '74, '75.
1951. DAVISON, FRANCIS W., Geisinger Medical Center, Danville, Pa. 17821, 1951, '52, '53*, '54, '55, '56, '57, '58, '59, '60, '61, '62, '63*, '64, '65, '66, '67*, '68, '69*, '70, '71, '72, '73*, '74, '75.
1973. DEDO, HERBERT H., University of California, S.F. School of Medicine, Rm. 495U, San Francisco, Calif. 94122, 1973*, '74, '75*.
1966. DEVINE, KENNETH D., Mayo Clinic, Rochester, Minn. 55901, 1966, '67, '68, '72*, '74*.
1968. DEWEESE, DAVID D., 3181 S.W. Sam Jackson Park Rd., Portland, Ore. 97202, 1968, '69*, '73, '74, '75.
1969. DICKINSON, JOHN T., 1501 Locust St., Pittsburgh, Pa. 15219, 1970, '71, '72, '73, '75.
1973. DUVALL, ARNDT J., III, University of Minn. Hospital, A-605 Mayo Memorial Bldg., Minneapolis, Minn. 55455, 1973*, '75.
1968. FARRIOR, RICHARD T., 509 Bay St., Tampa, Fla. 33606, 1968, '69, '70*, '72, '74.

1964. FEARON, BLAIR, 308 Medical Arts Building, Toronto 5, Ontario, Canada, 1964, '66, '67, '68, '69, '70, '71*, '72*, '73*, '74*, '75.
1963. FERGUSON, CHARLES F., P. O. Box 313, Osterville, Mass. 02655, 1963, '64*, '66, '67*, '68, '69*, '70, '71, '72, '73, '74*, '75.
1955. FITZ-HUGH, GLASSELL SLAUGHTER, P. O. Box 3698 University Station, Charlottesville, Virginia 22903, 1955, '57, '59, '60, '61, '62*, '64, '65, '66, '67*, '68, '69, '70, '71, '72, '73, '74, '75.
1970. FRAZER, JOHN P., 260 Crittenden Blvd., Rochester, N. Y. 14620, 1971, '72, '73, '74, '75.
1956. FRIEDBERG, STANTON A., 1725 West Harrison St., Chicago, Ill. 60612, 1956, '57*, '58, '59, '60, '61, '62, '63, '64, '65*, '67, '68, '69, '70, '71*, '72, '73, '74, '75.
1959. GOLDMAN, JOSEPH L., 1050 Park Ave., New York, N. Y. 10028, 1959, '60*, '61, '62, '63, '64, '65, '66, '67, '68, '69, '70, '71, '72*, '73, '74, '75.
1965. HANCKEL, RICHARD W., JR., 80 Barre St., Charleston, S. C. 29401, 1965, '66, '67, '69, '70, '71, '72, '73, '74.
1957. HARRILL, JAMES A., Bowman Gray School of Medicine, Winston-Salem, N. C. 27103, 1957, '58, '59, '61, '62, '63, '64, '66, '67, '68, '69, '71, '73, '75.
1960. HARRIS, HERBERT H., 907 Hermann Professional Building, Houston, Texas 77025, 1960, '61*, '62, '63, '64, '65*, '66, '67, '68, '69, '70, '71, '72, '73, '74, '75.
1959. HENRY, G. ARNOLD, 170 St. George St., Toronto, Canada, 1959, '61, '63, '66, '67, '69, '70, '73.
1955. HILGER, JEROME A., Suite 6A, 393 Dunlap St., St. Paul, Minnesota 55104, 1955, '56*, '57, '58, '59, '60, '62, '63, '64, '65, '66, '68, '69, '70, '71, '75.
1945. HOLINGER, PAUL H., 700 North Michigan Ave., Chicago, Illinois 60611, 1946, '47, '49, '50*, '51*, '52, '53, '54*, '55, '56, '57, '58*, '59, '60, '61*, '62*, '63, '64, '65, '66*, '68, '69*, '72*, '73*, '74.
1957. HOLMES, EDGAR M., 2000 Washington St., Newton, Mass. 02162, 1957, '59, '61, '63, '68, '70, '71, '72, '74, '75.
1974. HUDSON, WILLIAM R., Duke Univ. Med. Center, E.N.T., P.O.P., 3805, Durham, N. C. 27710, 1974, '75.

1961. JONES, EDLEY H., 1910 Mission 66 Avenue, Vicksburg, Miss. 39180, 1961, '62, '63*, '65, '66, '67, '68, '69, '70, '71, '72, '73, '74, '75.
1965. KING, JAMES T., Suite 206, W. Paces Ferry, Professional Building, 3250 Howell Mill Rd. N. W., Atlanta, Ga. 30327, 1965, '66, '67, '69, '70, '71, '73, '74, '75.
1975. KIRCHNER, FERNANDO R., U. of Kansas Med. Centr., Kansas City, Kansas 66103, 1975*.
1963. KIRCHNER, JOHN A., 333 Cedar St., New Haven, Conn. 06510, 1963, '65*, '67*, '68, '69*, '70, '71*, '72*, '73, '74, '75*.
1963. LATHROP, FRANK D., R.F.D. No. 1, Pittsford, Vt. 05763, 1963, '64*, '67*, '69, '70, '71, '72, '73, '74, '75.
1966. LEWIS, JOHN S., 3 East 71st Street, New York, N. Y. 10021, 1966, '67, '68, '69*, '70, '71, '72, '74, '75.
1961. LEWY, ROBERT B., 25 East Washington St., Chicago, Ill. 60602, 1961, '62*, '63, '65*, '67, '68, '69, '70, '71, '73, '74, '75.
1972. LILLIE, JOHN C., Mayo Clinic, Rochester, Minn. 55901, 1972, '75.
1973. LORE, JOHN M., JR., 100 High St., Buffalo, N. Y. 14203, 1974*.
1966. McCABE, BRIAN F., Dept. of Otolaryngology, University Hospitals, Iowa City, Iowa 52240, 1966, '69, '72*, '73, '75*.
1963. MCGOVERN, FRANCIS H., 139 South Main St., Danville, Virginia 24541, 1963, '64, '66, '68, '71, '72, '74, '75.
1952. MILLER, ALDEN H., 1407 N. Vermont Ave., Los Angeles, Calif. 90027, 1952, '53*, '55, '57, '58*, '61, '62, '64, '66, '67*, '68, '69, '70, '71, '72, '73*, '74*.
1965. MILLER, DANIEL, 110 Francis St., Boston, Mass. 02215, 1965, '66, '67, '68, '69*, '70, '71, '72, '73*, '74, '75.
1964. MONTGOMERY, WILLIAM W., 243 Charles St., Boston, Mass. 02114, 1964, '65*, '66*, '68*, '70, '71, '72, '74*, '75.
1972. MORSE, HARRY R., Tatakett Square, Teaticket, Mass. 02536, 1972, '75.
1957. MUNOZ-MACCORMICK, CARLOS EDUARDO, 71 Park Terrace, Santurce, Puerto Rico, 1957, '58, '59, '60, '61, '62, '63, '64, '65, '66, '67, '68, '69, '70, '71, '72, '73, '74, '75.
1975. NAHUM, ALAN M., 225 W. Dickinson, San Diego, Cal., 1975.

1956. NORRIS, CHARLES MORGAN, 3401 North Broad Street, Philadelphia, Pennsylvania 19140, 1956, '57, '58*, '59, '60, '61*, '62, '63, '64, '66, '67, '68*, '69, '70*, '71, '72, '73, '74, '75.
1961. OGURA, JOSEPH H., 517 S. Euclid Ave., St. Louis, Mo. 63110, 1961*, '62*, '63, '64*, '65, '66*, '67, '68*, '69, '70, '71*, '72, '73*, '74*, '75*.
1958. O'KEEFE, JOHN J., 130 S. Ninth St., Philadelphia, Pa. 19107, 1958, '59*, '60, '62, '64, '67, '71, '73, '74, '75.
1961. PANG, LUP Q., 1374 Nuuanu Ave., Honolulu, Hawaii 96817, 1961, '62*, '64, '66, '67, '70, '71, '72, '73, '75.
1961. PASTORE, PETER N., 5503 Riverside Drive, Richmond, Va. 23225, 1961, '62*, '64, '66, '67, '69, '71, '72, '73, '74, '75.
1972. PENNINGTON, CLAUDE L., JR., 800 First St., Macon, Ga. 31201, 1972, '73, '75.
1967. PRATT, LORING W., 325-B Kennedy Memorial Drive, Waterville, Maine 04901, 1967, '68, '69, '70, '71, '72, '73, '74, '75.
1951. PRIEST, ROBERT E., 79 S. Ninth St., Minneapolis, Minn. 55402, 1951, '53*, '54*, '56, '59, '60*, '61, '65, '67*, '68, '69, '70, '71, '72, '73, '75.
1951. PUTNEY, F. JOHNSON, 80 Barre St., Charleston, S. C. 29401, 1951, '52, '53*, '54, '55, '56, '58*, '59, '60, '61, '62, '63*, '64*, '65, '66, '67, '68*, '69*, '70*, '71, '72*, '74, '75.
1963. REED, GEORGE F., 750 E. Adams St., Syracuse, N. Y. 13210, 1963, '65*, '66, '68, '69*, '70, '71, '72, '73, '75.
1974. RITTER, FRANK N., 326 N. Ingalls, Ann Arbor, Mich. 48104, 1974, '75.
1959. SANDERS, SAM H., 1286 Peabody Ave., Memphis, Tenn. 38104, 1959, '60, '61, '62, '63, '65, '70, '71, '72, '73, '75.
1964. SAUNDERS, WILLIAM H., Ohio State Univ., Rm. 3110, 456 Clinic Dr., Columbus, Ohio 43210, 1964, '65, '66, '68*, '69, '70*, '71, '72*, '73, '74, '75*.
1959. SILCOX, LOUIS E., 33-34 Lankenau Med. Bldg., Philadelphia, Pa. 19151, 1959, '60, '61, '62, '63, '64, '65, '66, '67, '68, '69, '70, '71, '72, '73, '74, '75.
1958. SIMONTON, KINSEY M., Atlanta Ear, Nose and Throat Clinic, 960 Johnson Ferry Rd. N.E., Atlanta, Ga. 30342, 1958, '59*, '62, '64, '66, '67, '69, '72, '74, '75.

1962. SISSON, GEORGE A., Northwestern U. Medical School, 303 Chicago Ave., Chicago, Ill. 60611, 1962, '63*, '65, '66, '68, '69, '70, '71, '72, '73.
1964. SKOLNIK EMANUEL M., Abraham Lincoln School of Medicine, P. O. Box 6998, Chicago, Ill. 60680, 1964*, '65, '66*, '67, '68, '69, '70*, '71, '72, '73, '75*.
1974. SNOW, JAMES B., JR., 3400 Spruce St., Philadelphia, Pa. 19104, 1974, '75*.
1972. SOBOROFF, BURTON J., 307 N. Michigan Ave., Chicago, Ill. 60601, 1972, '73, '74, '75.
1973. SOM, MAX L., 121 East 60 Street, New York, N. Y. 10022, 1973, '74*, '75*.
1954. SOOY, FRANCIS A., University of California Hospital, 3rd and Parnassus Ave., San Francisco, Calif. 94122, 1954, '56*, '58, '60, '62, '63, '64, '65*, '67, '68*, '71.
1975. SPRINKLE, PHILIP M., W. Va. Univ. Med. Cent., Morgantown, W. Virginia, 1975.
1975. STRONG, M. STUART, 720 Harrison Ave., Boston, Mass. 02118, 1975.
1961. SUEHS, OLIVER W., 14 Medical Arts Square, Austin, Texas 78705, 1961, '62*, '63, '64, '66, '68, '69, '70, '71, '72, '74, '75.
1963. TABB, HAROLD G., 1430 Tulane Ave., New Orleans, La. 70112, 1963, '65, '66, '67, '69, '71, '72, '74, '75.
1954. THORNELL, WILLIAM C., 2340 Auburn Avenue, Cincinnati, Ohio 45219, 1955*, '57, '59, '60, '63, '68, '70, '72, '74.
1967. TRIBLE, WILLIAM MACL., 1234 19th St., N.W., Washington, D.C. 20036, 1967, '68, '69*, '70, '71, '72, '73, '74, '75.
1970. TUCKER, GABRIEL F., JR., 3401 North Broad St., Philadelphia, Pa. 19140, 1970*, '71, '72, '73*, '74*, '75*.
1973. TUCKER, JOHN A., Hahnemann Hospital, 230 N. Broad St., Philadelphia, Pa. 19102, 1973*, '74*, '75*.
1974. WARD, PAUL H., UCLA School of Medicine, Los Angeles, Calif. 90024, 1974*, '75.
1962. WEAVER, DELMAR F., Med. Profess. Bldg., Culpeper, Va. 22701, 1962, '63, '64*, '65, '67*, '69, '70, '72, '74.

1971. WILLIAMS, RUSSELL I., 1605 East 19th St., Cheyenne, Wyo. 82001, 1971, '72*, '73, '74.
1951. WOODMAN, DEGRAAF, P.O. Box 560, Easton, Md. 21601, 1951, '53, '54, '55*, '56, '58, '59, '60, '61, '62, '63, '64, '65, '66, '67, '68, '69, '70, '71, '72, '73, '74, '75.

Honorary Fellows

1968. (1946) ALONSO, REGULES JUSTO E., Mercedes 1233, Montivideo, Uruguay.
1975. (1940) BROYLES, EDWIN N., 11 E. Chase St., Baltimore, Md. 21202, 1940, '41*, '42, '46, '48*, '49, '50, '51*, '52, '53, '54, '55, '56, '58, '59*, '60, '61*, '63, '64, '65, '67, '71.
1957. (1925) CLERF, LOUIS H., 5575 Eighth Avenue, North, St. Petersburg, Florida 33710, 1957, '58, '59, '60, '61, '63, '64, '65, '66, '68, '69, '70, '71, '72*, '73, '74, '75.
1968. (1936) GALLOWAY, THOMAS C., 636 Church St., Evanston, Ill. 60201, 1969, '71, '75.
1975. (1943) HILDING, ANDERSON C., St. Luke's Hospital, Duluth, Minn. 55805, 1944*, '46, '47, '48*, '49, '50, '51, '53, '55, '56*, '57, '60, '62*, '63, '64*, '65, '66, '67, '68, '69, '70, '71, '72, '73, '74, '75.
1968. (1957) HUIZINGA, EELCO, Noorderhaven 7, Groningen, The Netherlands, 1957.
1967. (1933) LIERLE, DEAN M., University Hospitals, Iowa City, Iowa 52240, 1967, '68, '71, '74.
1966. (1957) ONO, JO, 6-13, 6-Chome, Roppongi, Minato-Ku, Tokyo, Japan, 1971.
1968. (1937) PORTMANN, PROF. DR. GEORGES, Clinique S, Augustin, 114, Avenue d'Ares, Bordeaux, France, 1947.
1968. (1957) RUEDI, PROF. DR. LUZIUS, Kurhausstrasse 50, Zurich, Switzerland, 1957.

Corresponding Fellows

1972. ARSLAN, PROF. MICHELE, Otorinolaringoiatrica dell' Universita de Padova, 37 Via Altinate, Padova, Italy, 1972.
1959. BARRETTO, PLINIO DE MATTOS, Rua Cons Torres, Homem 371, Sao Paulo, Brazil, 1960, '69, '73.

1959. BATEMAN, SIR GEOFFREY H., Beech Hill, E. Lavington, Petworth, Sussex, England.
1942. BATSON, OSCAR V., 3926 Pine St., Philadelphia, Pennsylvania 19104, 1942*, '54*.
1964. CLEVES, CARLOS, Apto 202, Carrera 14 No. 44-54, Bogota, Colombia, S. A., 1970.
1966. DOHLMAN, GOSTA, Dept. of Otolaryngology, University of Toronto, Toronto, Ontario, Canada, 1966.
1970. HALLIDAY, SIR GEORGE C., 143 Macquarrie St., Sydney, N.S.W. Australia.
1971. HARRISON, D. F. N., 330/332 Gray's Inn Road, London, W.C.1, England, 1971.
1970. HUTCHEON, JACK, Morris Towers, 149 Wickham Terrace, Brisbane, Australia, 1971.
1971. MACBETH, RONALD G., Radcliffe Infirmary, Oxford, England, 1971.
1968. NAKAMURA, FUMIO, Kyoto Prefectural U. Medicine, Kawara-Machi 1, Kamikyo-Ku, Kyoto, Japan.
1964. PEREZ, ALFREDO C., Instituto Celis Perez, Avenida Montes Deoca, Valencia, Venezuela, S. A., 1965.
1971. RETHI, AUREL, Liszt Str 10, Budapest 6, Hungary.
1952. TAPIA-ACUNA, RICARDO, Av. Insurgentes, Sur No. 300, Mexico 7 D.F., 1953, '57, '60*, '67, '73, '75.
1936. VIALLE, JACQUES, 27 Rue de France, Nice (Alpes Maritimes), France.

Emeritus Fellows

1973. (1944) BOIES, LAWRENCE R., Department of Otolaryngology, A-605, Mayo Memorial Bldg., Minneapolis, Minnesota 55455, 1944, '46, '47, '48*, '49, '50*, '51*, '53, '54, '55, '56, '57, '58, '59, '60, '61, '62, '63, '64, '65, '66, '67, '68*, '69, '71.
1966. (1945) CAMPBELL, PAUL A., 700 E. Hildebrand, Apt. 401, San Antonio, Texas 78212.
1965. (1942) CANFIELD, NORTON, P.O. Box 377, Stony Creek, Branford, Conn. 06405.

1969. (1959) CARDWELL, EDGAR P., P.O. Box 581, Shell Island, Wrightsville Beach, N. C. 28480.
1975. (1957) CONVERSE, JOHN MARQUIS, 722 Park Ave., New York, N. Y. 10021, 1960, '62*, '67.
1969. (1947) EAGLE, WATT W., Route 6, P. O. Box 339, New Bern, N. C. 28560.
1972. (1962) ERICH, JOHN B., Mayo Clinic, 102 Second Ave., Rochester, Minn. 55901.
1970. (1940) GOODALE, ROBERT L., 141 Argilla Rd., Ipswich, Mass. 01938, 1971, '74, '75.
1963. (1928) GOODYEAR, HENRY M., 2012 Edgecliff Point, Cincinnati, Ohio 45206.
1960. (1940) HANSEL, FRENCH K., 515 Timberwyck, St. Louis, Missouri 63131, 1962, '65, '73.
1968. (1942) HEATLEY, CLYDE A., 125 Douglas Rd., Rochester, N. Y. 14610, 1942, '46*, '49, '50, '52, '53*, '54, '55, '57, '58, '60, '61, '65.
1961. (1950) KLINE, ORAM R., 896 Lake Ave., Woodbury Heights, N. J. 08097, 1961, '63, '70, '72, '74.
1970. (1936) LEJEUNE, FRANCIS E., Ochsner Clinic Bldg., 1514 Jefferson Highway, New Orleans, La. 70121, 1971, '73, '74, '75*.
1967. (1949) LINDSAY, JOHN R., 950 E. 59th St., Chicago, Ill. 60621, 1967.
1954. (1927) LUKENS, ROBERT M., 141 West Heather Road, Wildwood Crest, N. J. 08260.
1964. (1952) MCCALL, JULIUS W., 22880 Canterbury Lane, Shaker Heights, Ohio 44122, 1964, '66, '68, '69, '70, '71, '72, '73, '75.
1974. (1951) MCHENRY, LAWRENCE C., 1607 Glenbrook Terrace, Oklahoma City, Okla. 73116, 1953*, '62, '63, '64, '65, '66, '68, '71.
1970. (1931) McNALLY, WILLIAM J., 1509 Sherbrooke St. West, Montreal, Quebec, Canada, 1972, '73, '74, '75.
1971. (1954) MOORE, PAUL M., 22520 Calverton Rd., Cleveland, Ohio 44122, 1954, '55*, '56, '57, '59, '60, '61, '62, '63, '64, '65, '66, '68, '70, '71, '74.

1971. (1953) MURTAGH, JOHN A., 1198 A1A Apt. 240, Hillsboro Beach, Pompano, Fla. 33062, 1953, '54, '55, '56*, '57, '58, '59, '61, '62, '63, '65, '66, '67, '69, '70, '72, '74.
1959. (1927) MYERSON, MERVIN C., 624 Mourning Dove Drive, Sarasota, Fla. 33577.
1957. (1948) Phelps, Kenneth A., 1788 Oak Creek Drive, Apt. 402, Palo Alto, Cal. 94304, 1971.
1969. (1951) RAWLINS, AUBREY G., 490 Post St., San Francisco, Calif. 94102, 1971.
1972. (1956) RICHARDSON, JOHN R., P.O. Box 52, Searsport, Maine 04974.
1958. (1938) SALINGER, SAMUEL, 1260 East Alejo Road, Palm Springs, Calif. 92262, 1958, '59, '61, '62, '63, '64, '65, '66, '67, '68, '69, '71.
1962. (1932) SCHALL, LEROY A., 121 Winfield Road, Princeton, N. J. 08540, 1964, '66, '68, '69, '72, '73, '74, '75.
1964. (1934) SCHENCK, HARRY P., 1235 Wyngate Rd., Wynnewood, Pa. 19096, 1964, '65*, '66, '68, '69, '70.
1965. (1939) SIMPSON, W. LIKELY, 606 E. 5th St., Des Moines, Iowa 50309, 1973.
1969. (1950) SMITH, AUSTIN T., 382 Lakeside Rd., Box 28, Wynnewood, Pa. 19096, 1970, '71, '72, '73, '74.
1973. (1963) TOLAN, JOHN F., 1118 Ninth Ave., Seattle, Washington 98101, 1963, '64, '65, '66, '67, '69, '71, '73.
1968. (1950) TREMBLE, G. EDWARD, 1374 Sherbrooke St. W., Montreal, Quebec, Canada, 1950, '51, '52, '53, '54, '55*, '56, '57, '58, '60, '61, '62, '63, '65, '66, '67*, '68, '69, '70, '71, '73, '74.
1961. (1941) VIOLE, PIERRE P., 241 South Windsor, Los Angeles, Calif. 90004, 1964.
- 1975 (1953) WORK, WALTER P., University Hospitals, 1405 E. Ann St., Ann Arbor, Michigan 48104, 1953, '54, '56, '58, '59*, '62, '63*, '65, '67, '68, '69, '72, '73, '75.

OFFICERS 1975-1976

* * * *

PRESIDENT

STANTON A. FRIEDBERG, M.D.

FIRST VICE-PRESIDENT

JOHN S. LEWIS, M.D.

SECOND VICE-PRESIDENT

EDWIN W. COCKE, JR., M.D.

SECRETARY

JOHN F. DALY, M.D.

TREASURER

CHARLES M. NORRIS, M.D.

LIBRARIAN, HISTORIAN AND EDITOR

CHARLES F. FERGUSON, M.D.

* * * *

COUNCIL

The above ex officio and

FIRST COUNCILOR

F. JOHNSON PUTNEY, M.D.

SECOND COUNCILOR

FRANK D. LATHROP, M.D.

THIRD COUNCILOR

G. SLAUGHTER FITZ-HUGH, M.D.

FOURTH COUNCILOR

JOSEPH H. OGURA, M.D.

INDEX

to the

TRANSACTIONS

of the

AMERICAN
LARYNGOLOGICAL ASSOCIATION

1975

AUTHORS INDEX

A		McCabe, Brian F., M.D. 79	
Alford, Bobby R., M.D.	25	McDonald, Thomas J., M.D.	38
Alonso, William A., M.D.	128	N	
B		Newton, Thomas H., M.D.	31
Batsakis, John G., M.D.	73	Norman, David, M.D.	31
C		Nysather, John, M.D.	79
Cohen, Seymour R., M.D.	53	O	
Conley, John J., M.D.	20	Ogura, Joseph H., M.D.	11, 13, 128
D		P	
Dedo, Douglas D., M.D.	128	Pletcher, James D., M.D.	31
Dedo, Herbert H., M.D.	31	R	
Devine, Kenneth D., M.D.	38	Roark, David T., M.D.	25
Djalilian, Mohsen, M.D.	38	S	
H		Saunders, William H., M.D.	105
Hengerer, Arthur S., M.D.	46	Sessions, Roy, M.D.	25
J		Skolnik, Emanuel M., M.D.	96
Jaffe, Burton F., M.D.	46	Snow, James B., Jr., M.D.	110
Johnson, Ernest, M.D.	105	Som, Max L., M.D.	63
K		Strome, Marshall, M.D.	46
Kirchner, Fernando, M.D.	68	T	
Kirchner, John A., M.D.	85	Tucker, Gabriel F., Jr., M.D.	122
Krause, Charles J., M.D.	79	Tucker, John A., M.D.	122
L		W	
Lawson, William, M.D.	63	Weiland, Louis H., M.D.	38
LeJeune, Francis E., M.D.	14	Wheatley, Michael A., M.D.	96
Lulenski, Gary C., M.D.	73	Y	
M		Yee, King F., M.D.	96
Martin, Lawrence O., M.D.	96		

SUBJECT INDEX

<p>A</p> <p>Address, Guest of Honor (LeJeune) 14</p> <p>Address, Presidential (Ogura) 11</p> <p>Angiofibromas of Nasopharynx, Preoperative Embolization of (Pletcher, Newton, Dedo H, and Norman) 31</p> <p>Antigen (Tumor) in Epidermoid Carcinoma, Characterization of (Krause, Nysather, and McCabe) 79</p> <p style="text-align: center;">B</p> <p>Baker Lecture. Some Reflections on Our Specialty (Conley) 18</p> <p style="text-align: center;">C</p> <p>Cancer of Larynx, Radiation Failures in (Skolnik, Martin, Yee, and Wheatley) 96</p> <p>Cancer of Larynx, Second Primary Cancer after Irradiation of (Lawson and Som) 63</p> <p>Cancer of Pyriform Sinus: A Clinical and Laboratory Study (Kirchner J) 85</p> <p>Cancer Surgery (Head and Neck), Pharyngocutaneous Fistulas Complicating (Dedo D, Alonso, and Ogura)128</p> <p>Carcinoma (Epidermoid), Characterization of Tumor Antigen in (Krause, Nysather, and McCabe) 79</p> <p>Carcinoma of Nasopharynx in Children (Snow)110</p> <p>Cleft Larynx (A Report of Seven Cases) (Cohen) 53</p> <p>Continuing Education: A Challenge and a Necessity (LeJeune) 14</p> <p style="text-align: center;">E</p> <p>Education, Continuing: A Challenge and a Necessity (LeJeune) 14</p> <p>Embolization (Preoperative) of Juvenile Angiofibromas of Nasopharynx (Pletcher, Newton, Dedo H, and Norman) 31</p> <p>Epidermoid Carcinoma, Tumor Antigen in (Krause, Nysather, and McCabe) 79</p>	<p>Executive Sessions 138</p> <p>Experimental Granuloma of Larynx (Kirchner F) 68</p> <p style="text-align: center;">F</p> <p>Failures of Radiation in Cancer of Larynx (Skolnik, Martin, Yee, and Wheatley) 96</p> <p>Fistulas (Pharyngocutaneous) Complicating Head and Neck Surgery (Cancer) (Dedo D, Alonso, and Ogura)128</p> <p>Frey's Syndrome, A Technical Remedy (Sessions, Roark, and Alford) 25</p> <p style="text-align: center;">G</p> <p>Granuloma (Experimental) of the Larynx (Kirchner F) 68</p> <p>Guest of Honor Address (LeJeune) 14</p> <p style="text-align: center;">H</p> <p>Head and Neck Cancer Surgery, Pharyngocutaneous Fistulas Complicating (Dedo D, Alonso, and Ogura)128</p> <p>Hyoepiglottic Complex, Observations on the Primate (Tucker G and Tucker J)122</p> <p style="text-align: center;">I</p> <p>Incision (Tracheal) as Contributing Factor to Tracheal Stenosis (Lulenski and Batsakis) 73</p> <p>Introduction of Guest of Honor (Ogura) 13</p> <p>Intubation (Endotracheal Tube) Suggested Modification (Hengerer, Strome, and Jaffe) 46</p> <p>Irradiation of Laryngeal Cancer, Second Primary Cancer After (Lawson and Som) 63</p> <p style="text-align: center;">J</p> <p>Juvenile Angiofibromas of Nasopharynx, Preoperative Embolization of (Pletcher, Newton, Dedo H, and Norman) 31</p>
---	---

L		Primary Cancer (Second) after Irradiation of Laryngeal Cancer (Lawson and Som)	63
Laryngeal Cancer, Second Primary Cancer After Irradiation (Lawson and Som)	63	Primate Hyoepiglottic Complex, Observations on the (Tucker G and Tucker J)	122
Larynx Cancer, Failures of Radiation in (Skolnik, Martin, Yee, and Wheatley)	96	Pyriform Sinus Cancer: A Clinical and Laboratory Study (Kirchner J)	85
Larynx, Cleft (in Seven Cases) (Cohen)	53	R	
Larynx, Experimental Granuloma of (Kirchner F)	68	Radiation Failures of Larynx Cancer (Skolnik, Martin, Yee, and Wheatley)	96
Larynx (Neonatal), Injuries to, From Long-term Endotracheal Tube Intubation (Hengerer, Strome, and Jaffe)	46	Radical Neck Dissection, Rehabilitation of the Shoulder After (Saunders and Johnson)	105
M		Reflections on Our Specialty (Conley)	20
Memorials	152	Rehabilitation of the Shoulder After Radical Neck Dissection (Saunders and Johnson)	105
N		S	
Nasopharynx, Carcinoma of, in Children (Snow)	110	Shoulder, Rehabilitation of, after Radical Neck Dissection (Saunders and Johnson)	105
Nasopharynx, Preoperative Embolization of Juvenile Angiofibromas of (Pletcher, Newton, Dedo H, and Norman)	31	Sinus (Pyriform) Cancer (Kirchner J)	85
Neonatal Larynx, Injuries to, From Long-term Endotracheal Tube Intubation (Hengerer, Strome, and Jaffe)	46	Specialty, Some Reflections on Our (Conley)	20
Nontraumatic, Nonneoplastic Subglottic Stenosis (Djalilian, McDonald, Devine, and Weiland)	38	Stenosis (Subglottic), Nontraumatic, Nonneoplastic (Djalilian, McDonald, Devine, and Weiland)	38
O		Stenosis (Tracheal), Tracheal Incision as a Contributing Factor to (Lulenski and Batsakis)	73
Observations on the Primate Hyoepiglottic Complex (Tucker G and Tucker J)	122	Surgery (Head and Neck Cancer), Pharyngocutaneous Fistulas Complicating (Dedo D, Alonso, and Ogura)	128
P		Syndromes (Frey's), A Technical Remedy (Sessions, Roark, and Alford)	25
Pharyngocutaneous Fistulas Complicating Head and Neck Cancer Surgery (Dedo D, Alonso, and Ogura)	128	T	
Preoperative Embolization of Juvenile Angiofibromas of Nasopharynx (Pletcher, Newton, Dedo H, and Norman)	31	Tracheal Stenosis, Tracheal Incision as Contributing Factor to (Lulenski and Batsakis)	73
Presidential Remarks (Ogura)	11	Tumor Antigen in Epidermoid Carcinoma, Characterization of (Krause, Nysather, and McCabe)	79

