TRANSACTIONS

American Laryngological Association

NINETY-SEVENTH VOLUME

1976

PUBLISHED BY THE ASSOCIATION
CHARLES FOSS FERGUSON, MD, Editor

"DOCENDO DISCIMUS"

TRANSACTIONS

OF THE

NINETY-SEVENTH ANNUAL MEETING

OF THE

American Laryngological Association

1976

HELD AT

The Bbeakers

Palm Beach, Florida

April 24 and 25, 1976

PUBLISHED BY THE ASSOCIATION

ST. LOUIS, MISSOURI

CHARLES FOSS FERGUSON, MD, Editor

1976

Contents.

PAGE

Officers for 1975-1976 7

Annual Photograph 8

Registration of Fellows for Annual Meeting 9

* * * *

Presidential Address, Stanton A. Friedberg, MD 11

Introduction of Guest of Honor, Thomas C. Galloway, MD,
by President Stanton A. Friedberg, MD 16

Address of Guest of Honor, Thomas C. Galloway, MD
The Domain of Otolaryngology 17

Second Daniel C. Baker, Jr. Lecture:
Progress of Otolaryngology in Head and Neck Surgery, Joseph H. Ogura, MD 21

* * * *

SCIENTIFIC SESSION

Etiology of Bilateral Abductor Vocal Cord Paralysis: A Review of 389 Cases.
Lauren D. Holinger, MD, Paul C. Holinger, MD, and Paul H. Holinger, MD 24

Bilateral Abductor Paralysis: 30 Years Experience with Arytenoidectomy.
DeGraaf Woodman, MD, and Claude L. Pennington, MD 33

Experience with Vocal Cord Injection.
Robert B. Lewy, MD 36

Recurrent Laryngeal Nerve Section for Spastic Dysphonia.
Herbert H. Dedo, MD 47

Discussion of previous four papers:

Walter P. Work, MD 55

Kenneth D. Devine, MD 56

John F. Daly, MD 56

Paul H. Holinger, MD 57

Alden H. Miller, MD 57

DeGraaf Woodman, MD (closing) 57

Robert B. Lewy, MD (closing) 57

Herbert H. Dedo, MD (closing) 58

CONTENTS

PAGE

Fiber Components of the Recurrent Laryngeal Nerve in the Cat.
Richard R. Gacek, MD, Michael J. Lyon, MA 59

An Implanted Electronic Laryngeal Prosthesis.
Byron J. Bailey, MD, Ceri M. Griffiths, MD, and Robert Everett, PhD 71

Otolaryngological Manifestations of Arthrogryposis Multiplex Congenita.
Seymour R. Cohen, MD, and Hart Isaacs, Jr., MD 83

Congenital Laryngeal Defects in the Adult.
William W. Montgomery, MD, and Stephen A. Smith, MD 90

Discussion of previous four papers:

John A. Tucker, MD 97

Douglas P. Bryce, MD 97

Robert B. Lewy, MD 97

William W. Montgomery, MD (closing) 97

Verrucous Carcinoma of the Larynx: Management by Radiotherapy and Surgery.
Hugh P. Burns, MB, A. W. Peter van Nostrand, MD, and Douglas P. Bryce, MD .. 98

Mucus Gland Tumors of the Larynx and Laryngopharynx.
Ronald H. Spiro, MD, John S. Lewis, MD, Steven I. Hajdu, MD, and Elliot W. Strong, MD 104

Granular Cell Tumors of the Larynx.
Harvey L. Coates, MB, Thomas J. McDonald, MD, Kenneth D. Devine, MD, and Louis H. Weiland, MD 110

Discussion of previous three papers:

John J. Conley, MD 114

Charles M. Norris, MD 115

Recurrent Respiratory Papillomatosis: Management with the CO_2 Laser.
M. Stuart Strong, MD, Charles W. Vaughan, MD, Sidney R. Cooperband, MD, Gerald B. Healy, MD, Manuel A. C. P. Clemente, MD 116

Dinitrochlorobenzene Skin Sensitization and Peripheral Lymphocyte Count: Predictors of Survival in Head and Neck Cancer.
Robert H. Maisel, MD, and Joseph H. Ogura, MD 125

Discussion of previous two papers:

Albert H. Andrews, Jr., MD 130

Osteoplastic Frontal Sinusotomy: An Analysis of 250 Operations.
James M. Hardy, MD, and William W. Montgomery, MD 131

Laryngeal Suspension and Epiglottic Flap in Laryngopharyngeal Trauma.
Nels R. Olson, MD 141

CONTENTS

PAGE

Discussion of previous two papers:

Douglas P. Bryce, MD 145

Robert L. Goodale, MD 145

John F. Daly, MD 145

William W. Montgomery, MD (closing) 145

Nels R. Olson, MD (closing) 146

Executive Sessions:

First Session (April 24) 148

Second Session (April 25) 149

Reports of:

Secretary, John F. Daly, MD 149

Treasurer, Charles M. Norris, MD 151

Accountant 154

Librarian, Historian and Editor, Charles F. Ferguson, MD 154

American Board of Otolaryngology, Frank D. Lathrop, MD 155

American Council of Otolaryngology, John F. Daly, MD 156

American College of Surgeons Governors, William M. Trible, MD 157

Nominating Committee, John E. Bordley, MD 158

Centennial Committee, Alden H. Miller, MD, Chairman 159

Action on Problem of Recertification in Otolaryngology 160

Memorials:

Justo M. Alonso, MD 162

Samuel Salinger, MD 164

W. Likely Simpson, MD 166

Memorial Fund; Laryngological Research Fund 169

Recipients of deRoaldes Award 170

Recipients of Casselberry Award 171

Recipients of Newcomb Award 172

Roster of Fellows 173

Officers, 1976-1977 184

Index:

Authors 186

Subjects 187

OFFICERS 1975-1976

* * * *

PRESIDENT

STANTON A. FRIEDBERG, MD

FIRST VICE-PRESIDENT

JOHN S. LEWIS, MD

SECOND VICE-PRESIDENT

EDWIN W. COCKE, JR., MD

SECRETARY

JOHN F. DALY, MD

TREASURER

CHARLES M. NORRIS, MD

LIBRARIAN, HISTORIAN AND EDITOR

CHARLES F. FERGUSON, MD

* * * *

COUNCIL

The above ex officio and

FIRST COUNCILOR

F. JOHNSON PUTNEY, MD

SECOND COUNCILOR

FRANK D. LATHROP, MD

THIRD COUNCILOR

G. SLAUGHTER FITZ-HUGH, MD

FOURTH COUNCILOR

JOSEPH H. OGURA, MD



FELLOWS IN ATTENDANCE AT THE NINETY-SEVENTH ANNUAL MEETING

First Row: Fitz-Hugh, Putney, Galloway, Friedberg, Lewis, Ferguson, Daly, Cocke, Norris, Lathrop. *Second Row:* Trible, Snow, Baxter, Strong, G. Tucker, J. Tucker, Chandler, Saunders, Lewy, King, Hilding, Fearon, Woodman, Pennington, Goodale, Cracovaner, LeJeune, Dedo, Goldman. *Third Row:* Bryce, Doyle, Briant, Dickinson, Farrior, A. Miller, Cantrell, Pratt, Jones, Sprinkle, Williams, Munoz-MacCormick, D. Miller, Miglets, Weaver, Sisson, Ogura, Andrews, Bailey, Montgomery, Hudson. *Fourth Row:* Biller, Holmes, Ballenger, Ward, Cohen, Boles, Devine, Skolnik, Holinger, Som, Frazer, Lingeman, Brown, Reed, Soboroff, Lore, Suehs, Clerf, Tremble, Duvall.

TRANSACTIONS OF THE
NINETY-SEVENTH ANNUAL MEETING

OF THE

American Laryngological Association

HELD AT

The Breakers

Palm Beach, Florida

April 24 and 25, 1976

* * * *

REGISTRATION OF FELLOWS

ACTIVE

Andrews, Albert H., Jr.
Bailey, Byron J.
Ballenger, John J.
Baxter, James D.
Biller, Hugh F.
Boles, Roger
Bordley, John E.
Briant, Thomas D. R.
Brown, Lester A.
Bryce, Douglas P.
Cantrell, Robert W.
Chandler, J. Ryan
Cocke, Edwin W., Jr.
Cohen, Seymour R.
Conley, John J.
Cracovaner, Arthur J.
Daly, John F.
Dedo, Herbert H.
Devine, Kenneth D.
DeWeese, David D.
Dickinson, John T.
Doyle, Patrick J.
Duvall, Arndt J. III
Farrior, Richard T.
Fearon, Blair

Ferguson, Charles F.
Fitz-Hugh, G. Slaughter
Frazer, John P.
Friedberg, Stanton A.
Goldman, Joseph L.
Harrill, James A.
Hilger, Jerome A.
Holinger, Paul H.
Holmes, Edgar M.
Hudson, William R.
Jones, Edley H.
King, James T.
Kirchner, Fernando
Lathrop, Frank D.
Lewis, John S.
Lewy, Robert B.
Lingeman, Raleigh E.
Lore, John M., Jr.
McCabe, Brian F.
Miglets, Andrew
Miller, Alden H.
Miller, Daniel
Montgomery, William W.
Munoz-MacCormick, Carlos E.
Nahum, Alan M.
Norris, Charles M.
Ogura, Joseph H.
Pastore, Peter N.
Pennington, Claude L.
Pratt, Loring W.
Putney, F. Johnson
Reed, George E.
Saunders, William H.
Sisson, George A.
Skolnik, Emanuel M.
Snow, James B., Jr.
Soboroff, Burton J.
Som, Max L.
Sprinkle, Philip M.
Strong, M. Stuart
Suehs, Oliver W.
Trible, William M.
Tucker, Gabriel F.
Tucker, John A.
Ward, Paul H.
Weaver, Delmar F.
Williams, Russell I.
Woodman, DeGraaf

EMERITUS

Goodale, Robert L.
LeJeune, Francis E.
Murtagh, John A.
Schall, LeRoy A.
Tremble, G. Edward
Work, Walter P.

HONORARY

Clerf, Louis E.
Galloway, Thomas C.
Hilding, Anderson C.

PRESIDENTIAL ADDRESS

DR. GURDON BUCK, JR., AND SURGERY OF THE LARYNX IN THE PRELARYNGOSCOPIC ERA

STANTON A. FRIEDBERG, MD



GURDON BUCK, JR., MD
(ca. 1850)

The first annual meeting of the American Medical Association was held in Baltimore in early May 1848. The President, Dr. Nathaniel Chapman of Pennsylvania, addressed the opening ceremony and had this to say about the public attitude toward doctors: "The profession to which we belong, once venerated on account of its antiquity — its various and profound science — its elegant literature — its polite accomplishments — its virtues — has become corrupt, and degenerate, to the forfeiture of its social position, and with it, of the homage it formerly received spontaneously and universally . . . complaints, at first heard only in the murmurs of discontent, are now so loud, distinct, and potential, as not to be disregarded or admit further postponement . . . From slumbers too long indulged, the profession has at length awoke, and shaking the poppies from its brows, is recalled to a sense of what is due to itself, and the obligations it owes to preserve its fair heritage, to be transmitted to posterity unsullied, and without detriment or loss . . . Confiding in our own resources, we shall through them maintain the struggle till conducted to victory and triumph."[1]

Of more interest to laryngologists, however, is the following article in the same volume and the first scientific paper to appear in what was then known as the *Transactions of the American Medical Association.* It was titled "Oedematous Laryngitis Successfully Treated by Scarifications of the Glottis and Epiglottis" by Gurdon Buck, Jr., MD. Surgeon to the New York Hospital.[2] Dr. Buck observed eight patients with edematous laryngitis in the winter of 1847-1848, a period characterized "by rainy wet weather and the prevalence of erysipelas and typhus fever." He felt that scarification of the edematous glottis and epiglottis might be employed for relief and that "the well-known fatal character of the disease warranted the trial of any new remedy that afforded a reasonable prospect of benefit."

At this point is is reasonable to assume that Dr. Buck was aware of the writings of Dr. Horace Green, whose text on *Diseases of the Air Passages* was the first book on Laryngology published in America (1846). The controversy surrounding Dr. Green reached its height in 1847, and revolved around his claims of being able to treat diseases of

the larynx by introducing medications therein solely by the sense of touch. However, no reference to Dr. Green's methods are to be found in Dr. Buck's first paper and the inference could be drawn that he might purposefully have avoided involvement in the stormy debate then surrounding Dr. Green's activities.

It is well to recall that although some claims of visualizing the interior of the larynx with mirrors and prisms had been made by Babington, Liston, Avery and others, we are discussing a period of seven or eight years prior to the introduction of the laryngoscope by Manuel Garcia and all laryngeal manipulation was done purely by the sense of touch. Dr. Buck wrote: "Though the oedematous swelling of one or both edges of the glottis is the cause of the dyspnoea, from the mechanical obstruction it presents to the entrance of air into the larynx, yet, as will hereafter appear, the epiglottis almost always participates in the swelling, and being within reach of the fore-finger passed into the mouth, it affords an invaluable means of diagnosis.

"The patient being seated on a chair, with his head thrown back, and supported by an assistant, he is directed to keep his mouth as wide open as possible; and if there be any difficulty in this respect, a piece of wood an inch and a quarter in width, and half an inch in thickness, is to be placed edgewise between the molar teeth of the left side. The fore-finger of the left hand is then to be introduced at the right angle of the mouth, and passed down over the tongue till it encounters the epiglottis.

"But little difficulty is generally experienced in carrying the end of the finger above and behind the epiglottis so as to overlap it and press it forwards towards the base of the tongue. In some individuals the finger may be made to overlap the epiglottis to the extent of three-fourths of an inch.

"Thus placed, the finger serves as a sure guide to the instrument to be used, which is represented accurately in the accompanying plate. The knife is then to be conducted with its concavity directed downwards, along the finger till its point reaches the fingernail. By elevating the handle so as to depress the blade an inch to an inch and a half farther, the cutting extremity is placed in the glottis between its edges; at this stage of the operation the knife is to be slightly rotated to one side and the other, giving it a cutting motion in the act of withdrawing it. This may be repeated without removing the finger, two or three times on either side. The margin of the epiglottis, and the swelling between it and the base of the tongue may be scarified still more easily with the same instrument, or scissors curved flatwise may be employed for these parts, guided in the same manner as the knife.

"Though a disagreeable sense of suffocation and choking is caused by the operation, the patient soon recovers from it, and submits to a repetition after a short interval. In every instance the operation has been performed twice, and in some three times."[2]

Dr. Buck's article describes the use of this scarification procedure in five patients. In one individual, tracheotomy was necessary, but the author minimized its importance because the patient was able to be decannulated in 48 hours and it was felt that the scarification had been the reason for the quick recovery. It should also be noted that venesection, leeches, emetics and mercury were used as adjuvants in two of the patients. Three other patients terminated fatally, without scarification.

As so frequently happens, the individual who claims priority for a procedure often discovers that someone preceded him to the starting gate. Such was the case when it was pointed out to Dr. Buck that one M. Lisfranc, writing in the Journal Gén. de Méd. in 1823 had described an identical scarification operation and had cured five of six patients thus treated.[3]

Dr. Buck's second contribution was entitled "On the Surgical Treatment of Morbid Growths within the Larynx"

and appeared in 1853, in Volume VI of the *Transactions of the American Medical Association.*[3] It described in great detail the clinical course of a 51-year-old female with hoarseness followed by complete loss of voice, dyspnea and stridor. "Exploration with the finger could detect no swelling or other morbid change at the orifice of the larynx. The patient has been previously subjected to applications of silver nitrate to the larynx and irritants to the front of the neck, but without benefit." Dr. Buck's differential diagnosis included chronic inflammatory states such as syphilis and tuberculosis, postpharyngeal abscess, aneurysm pressing on the trachea and the presence of a morbid growth within the larynx. He settled on the latter as the most likely diagnosis and proposed an operation to alleviate the dyspnea and spasmodic paroxysms which threatened suffocation. His account of the operation in May 1851, is as follows:

"The patient was seated before a window in a low armchair, with the head thrown back, and the front legs of the chair raised about three inches upon blocks. The neck being short and fleshy, the notch of the thyroid cartilage could only be obscurely distinguished by the touch. From this point an incision four inches in length was made, along the median line downwards, dividing the skin and subadjacent tissues, till the cartilages of the larynx and the three upper rings of the trachea were laid bare — the latter being effected partly by lacerating, and partly by pushing downwards the isthmus of the thyroid body with the handle of the scalpel. After the hemorrhage had entirely ceased, the crico-thyroid membrane was incised, and the incision continued upwards in the median line with the utmost precision through the whole extent of the thyroid cartilage: at the moment of penetrating the larynx, air rushed in with a whizzing sound, and the voice became extinct. The thyroid cartilage being ossified, the division was made with strong scissors, curved edgewise. The section was then continued downwards through the cricoid cartilage, and the exposed rings of the trachea. The sides of the larynx were stretched apart with retractors, and brought into view its cavity, lined by growths attached to its lateral walls.

"On the left side, two or three granules, half the size of grains of rice, hung pendulous from thread-like stalks. The remainder of the tumor was attached by a broad base, partly concealing the ventricle, and extending higher up upon the wall of the laryngeal cavity. The entire extent of the growth could not be traced, owing to the deep situation of the larynx, and the limited extent to which the sides could be separated from each other. Several portions of the tumour were snipped away, and, in cutting them, their substance appeared to be of a firm consistence, not unlike condylomata.

"The hemorrhage from these incisions was of short duration, and was mostly prevented from flowing into the trachea by stuffing pieces of sponge, held by the forceps, into the open larynx, and keeping them there for a short time. A good deal of time was necessarily consumed in accomplishing this partial removal of the tumour, and the patient was much fatigued by the coughing excited by the flow of blood into the trachea. The flattened form of the tumors, and the breadth of their attachment, together with the depth of their situation, and the narrowness of the space within which manipulations had to be performed, proved to be insurmountable difficulties, rendering the entire removal of the disease impracticable. It was therefore decided to suspend further attempts for the present. A portion of the two upper rings of the trachea was removed on either side, in order to lodge the trachea-tube, which was introduced and secured in place by a tape passed around the neck. By this arrangement, respiration was rendered perfectly easy and comfortable. The patient displayed the most remarkable courage and firmness throughout the whole of this very difficult and protracted operation. When visited the

same evening, considerable oozing of blood was found to have taken place from the lower angle of the wound, and the viscid secretion, expectorated through the tube, was also stained with blood. Her respiration continued easy."[4]

A repeat operation was performed the following day and an unsuccessful effort made to expose more of the larynx to remove the remainder of the tumor. Dr. Buck then performed a cadaver dissection and found that by splitting the epiglottis and hyoid he could obtain more exposure. He prepared for a third attempt in as many days but thought better of it and decided to await healing of the external wound. Swallowing became increasingly difficult and was thereupon forbidden, beef tea enemas being administered for nourishment.

Some months later in August, the symptoms of laryngeal obstruction returned and another operation was decided upon. This was done in September, the incision being extended to the level of the hyoid. Tumor was found within the larynx, narrowing the glottis and subglottic space. A paring piecemeal procedure was used to remove tumor before it was decided that total removal of the tumor would be impossible. In succeeding months there was tumor encroachment upon the tracheal tube and trachea, along with difficulty in swallowing. A fourth procedure was undertaken in order to reposition the tracheal tube at a lower level and this resulted in improved breathing. In March 1852, the patient began to expectorate necrotic tissue, there was a fetid odor to the wound and increasing difficulty with breathing. In August, her daughter, attempting to change the tracheal tube, failed in her effort to replace it and the patient expired. This occurred 16 months after the initial surgery.

An autopsy revealed extensive gangrene of the laryngeal interior with residual neoplasm. The microscopic examination describes a tumor which could be regarded as "non-malignant per sé and to belong to that class of morbid growths known as epithelial." Could this have represented papilloma of the larynx?

Dr. Buck collected a total of 42 examples of laryngeal lesions culled from the world literature. Some of these were undoubtedly carcinoma, others papillomas, polyps or tuberculosis. No attempt was made at classifying the pathology. All were designated simply as "morbid growths." He described in detail the symptomatology associated with laryngeal growths and recommended surgery as the only resource for the relief or cure of laryngeal disease. Dr. C. H. Ehrmann of Strasburg was credited by Dr. Buck with originating the thyrotomy procedure, having successfully removed a large polyp via this approach. It would seem, however, that Dr. Buck was the first to attempt to remove what was thought to be a malignant laryngeal growth via thyrotomy. Twelve to 15 years later, successful similar procedures were performed by Sands, Gibb, and Cohen.[4]

Various paternal titles have been accorded the hardy pioneers in the specialty of laryngology. Thus, Horace Green is often referred to as the Father of Laryngology, Gurdon Buck as the Father of Intralaryngeal Surgery and Manuel Garcia as the Father of Laryngoscopy.[5,6]

Gurdon Buck, Jr. was certainly one of the outstanding surgeons in America in the era before the discoveries of Lister. His name is identified with the treatment of fractures (Buck's extension) and a fascial layer of the genitourinary tract (Buck's fascia). He performed successful ligations of major blood vessels for wounds and aneurysms, and also improved the techniques of tracheotomy. Dr. Buck was perhaps best known for his contributions in the field of plastic and reparative surgery, in

which he published 21 articles and a book which was translated into three foreign languages.[7]

In the field of Laryngology, Dr. Buck richly merits our respect for his early efforts in laryngeal surgery at a time when nothing was known of the actual appearance of the larynx in the living human and very little of its pathologic processes.

REFERENCES

1. Minutes of the First Annual Meeting of The American Medical Association. Trans Am Med Assoc 1:7-9, May, 1848

2. Buck G Jr: Oedematous laryngitis successfully treated by scarification of the glottis and epiglottis. Trans Am Med Assoc 1:135-151, 1848

3. Buck G Jr: On the surgical treatment of morbid growths within the larynx. Trans Am Med Assoc 6:509-535, 1853

4. Alberti PW: The evolution of laryngology and laryngectomy in the mid-19th century. Laryngoscope 85:288-298, 1975

5. Delavan DB: Historical address. Trans Am Laryng Assoc pp 274-296, 1928

6. Bryan JH: The history of laryngology and rhinology and the influence of America in the development of this specialty. Ann Med Hist 5:151-170, 1933

7. Conway H, Stark RB: *Plastic Surgery at the New York Hospital One Hundred Years Ago.* New York, Paul B. Hoeber, Inc, 1953

———

REPRINTS—Stanton A. Friedberg, MD, 1725 West Harrison St., Chicago, IL 60612.

INTRODUCTION OF GUEST OF HONOR, THOMAS C. GALLOWAY, MD

STANTON A. FRIEDBERG, MD, PRESIDENT

It is a distinct privilege to present our Guest of Honor, Dr. Thomas C. Galloway and particularly heartwarming to report that he has recently celebrated his 90th birthday. Born in Boise, Idaho, on March 17, 1886, Dr. Galloway grew up in the days of the old West, which may indeed have been a factor in his long life of sturdy good health. He was graduated from the University of Idaho, (which later awarded him an honorary Doctor of Science degree) and subsequently attended the University of Chicago, where he obtained an MS, followed by an MD from its Rush Medical College in 1912. An internship at Cook County Hospital was followed by 3½ years in the U.S. Public Health Service and two years in World War I. After the war, he returned to Chicago as an assistant to Dr. Robert Sonnenschein who maintained a large practice in Otolaryngology and who, incidentally, was a Fellow of The American Laryngological Association. The salary he received in this position was $100 a month!

Dr. Galloway moved to Evanston, Illinois, and thereupon commenced a brilliant career in Otolaryngology. While Attending Surgeon at Cook County Hospital, he played an active role as a participant and teacher of residents in the period from 1927 through 1947, an era marked by the grim ravages and complications of infections and eventual conquest of these diseases through antibiotics.

Elected to Fellowship in The American Laryngological Association in 1936, Dr. Galloway's contributions were properly recognized by the Newcomb Award in 1955 and his elevation to Honorary Fellowship in 1968.

Dr. Galloway's career has been marked by a consuming intellectual curiosity and a broad range of accomplishment in all aspects of Otolaryngology. His surgical skill was equally evident in otology, head and neck surgery and endoscopy. By his example he proved that superspecialization was not a prerequisite to achievement. His knowledge of ophthalmology enabled him to more fully understand the orbital and intracranial complications which he encountered. He always felt that coagulation diathermy was not fully appreciated and his superb results with this modality were comparable to those now being obtained with cryosurgery.

Dr. Galloway's major contribution has been in the field of respiratory physiology and he is properly credited with establishing the role of tracheostomy in the management of airway problems in a wide variety of diseases.

As a physician, he was totally dedicated to his patients. His modesty caused him to disclaim the accolades accorded him, and when co-author of a paper, he always insisted that the younger man's name appear first. As a teacher of residents, his guidance was patient, firm and reinforcing. A truly gentle man, I cannot recall ever having heard him make a disparaging remark about another human being.

Among his many interests have been horses, golf, billiards and bridge. To these hobbies he brought the same degree of inquisitiveness and manual dexterity which characterized his professional career.

Who could more properly wear the mantle of Guest of Honor of The American Laryngological Association? I proudly introduce Dr. Thomas C. Galloway.

ADDRESS OF GUEST OF HONOR

THE DOMAIN OF OTOLARYNGOLOGY

THOMAS C. GALLOWAY, MD

When one has sat on the pinnacle of age and watched the splurge of progress go by, it is pleasant to march again in the parade, even as a minor historian. I just hope I do not stumble and fall flat on my face.

It is a great privilege for me to stand here today, for I have always felt that this is one of the great medical societies, and its leaders were my mentors. They were highly individual, self-made or educated in Europe or by preceptorship, which I found in my own case left gaping holes in the medical fabric. These men were mostly fine teachers and fruitful investigators, humanistic and anxious to help young men. If they were autocratic and even acrimonious at times, that was the spice that made medical meetings exciting.

In the early 20s, along with this outstanding group, there were so many poorly trained men professing to be specialists even after six week courses, that otolaryngology as a whole did not rate too high. Then under the American Boards and the special societies the profession policed itself, offered fine courses of instruction, histopathology and residencies, and turned out a solid body of well-trained and able men who inspired confidence and restored prestige both in and out of medicine. I was happy to find my teachers and my counselors and fine friends among them. Real threats to our specialty seem to have come from outside and there seem to be some rumblings of regimentation from Washington now. We have had some confrontations, but our cohorts by their zeal and skill have withstood most of these.

In microsurgery of the mastoid, ear, and petrous bone our domain seems secure, as it does in diseases of the nasal sinuses and the larynx. In surgery of the head and neck we seem to maintain a safe detente,[1] as we do in audiology and hearing and medical allergy, although it is sometimes hard to distinguish allies from opportunistic guerrilas.

In many areas of medicine, sway seems to be established by the right of discovery or innovation. Jackson, going to Europe by cattle boat, brought back ideas and instruments by which world leadership in endoscopy was established. Aiding considerably in this was a Chicago physician, Stanton A. Friedberg, Sr. The latter had great mechanical sense, was an able technician and inspiring teacher and clinician, as I can personally testify. To our great loss an intracranial otogenic infection cut short early what promised to be an outstanding career.

To justify our claim to the area of respiratory obstruction, I shall retell the experience with bulbar poliomyelitis. In the late 30s, perceptive laryngologists, including Richards,[2] the Jacksons,[1] Baum,[3] Gittins,[4] Davison[5] and others pointed out that the mortality of 50 to 70% from an epidemic of acute laryngotracheobronchitis was due not to overwhelming sepsis, but to respiratory obstruction and its secondary effects, including anoxia, cardiac failure, pulmonary edema, and exhaustion. If the patient lived long enough, atelectasis and pneumonitis were likely. When the pediatricians were persuaded of the urgency of the situation and brought to realize that tracheostomy in a failing patient might have to be done in three

to five minutes, the mortality of the disease was reduced from 60 or 70% to 2% or less. That was my experience at the Evanston Hospital. These experiences solidified our alliance with the pediatricians.

In 1942 an epidemic of poliomyelitis brought a good many patients with the bulbar form to the Evanston Hospital. Although I was there every day, I was never asked — almost not allowed — to see such a patient. A night charge nurse, Myrtle Brown, who had often assisted in the care of tracheobronchitis, came upon three interns desperately trying to save a man with bulbar polio. A forceps on his tongue was tied to the foot of his bed. He was unconscious, slate blue, his pulse was thready, his pupils dilated and he was apparently dying. She said, "That man is choking to death," and advised them to call me.

I was there in three minutes and found only a little air gurgling through thick secretion. Miss Brown and I were so ignorant of current concepts of polio as an overwhelming central nervous system infection with a virus, that we simply thought we saw a man drowning in his own secretions. It took only a few minutes to open the trachea, aspirate mucus and saliva and get air into the lungs. In 5 minutes he was in a respirator; in 30 he was rosy pink and conscious; in 45 he was demanding to be taken out of the "damned machine." In ten days he walked out of the hospital. This dramatic result at our hospital resulted in acceptance of this method of care for polio, with immediate tracheostomy when the patient's condition became serious, with signs of obstruction, failing heart, anoxic depression and exhaustion. A report of three cases — one fatal — was published in the J.A.M.A. in 1943.[6] Based on this, Priest *et al*[7] shortly after reported 75 cases treated with tracheostomy with greatly improved results. The procedure was generally accepted by laryngologists. Up to that time some three cases of tracheostomy for polio had been reported. In 1932 Wilson[8] had suggested the guarded use of tracheostomy for polio but had damned it as being "too dangerous for general use." I have never seen a patient die of tracheostomy *per se* in polio.

Perceptiveness is a valuable faculty in medical men — the ability to see the relevancy of cause and effect in spite of preconceived ideas, and to adopt decisive relief based on that relationship. It is usual in our specialty, due to good physiological training — in my case that of Professor A. J. Carlson of the University of Chicago. If it seems unimportant, consider the effect of "anti-perceptiveness," the resistance to the acceptance of new ideas in the treatment of bulbar polio. A year after our first paper at a one hour conference on bulbar polio in Chicago only two minutes were allowed to present tracheostomy. Four years later, although repeated favorable papers had been given, at a conference of the National Foundation I was given only ten minutes to explain physiopathology and none to describe its relief. The situation was saved however, when the censor, Professor Hoff, said his values from the conference had been in my remarks.

After we had secured 15 consecutive cures in bulbar polio at the Evanston Hospital, the charge was given over to a respiratory disease department which substituted intubation (with painful results), and our authority was soon restored. An outstanding specialist on contagious disease had for eight years written on polio charts "no tracheostomy unless in extremis," which, of course, was too late. During an adverse consultation we had to literally snatch the patient from dying, and the doctor was converted. Otolaryngologists easily saw the logic of the proposed treatment of polio and soon the principles advocated were generally adopted with marked reduction in mortality. The successful use of vaccines has nearly closed this chapter.

This physiopathology, including the danger and urgency of anoxia[9] presented about the same time, was accepted by surgeons and others in the relief of many related conditions.[10]

Thomas, Echols and others,[11] point out that this work has led to the widespread use of tracheostomy in many conditions with similar basic features. These include head injuries and postoperative damage, especially in neurosurgery; anesthetic and drugs, depressions; trauma, especially war wounds; vascular accidents; flame injuries; systemic disease involving the bulb; tetanus and botulism. Intubation may suffice in diphtheria and some other situations where obstruction is limited to one or two days.

Although these principles have been widely accepted, the full implications have not always been noted. For instance, in a recent J.A.M.A. article[12] an analysis of the treatment of tetanus concludes that antitoxin was of proven benefit, and that of human origin was of greater value. This analysis was relevant, but other factors were almost ignored, "although meticulous supportive therapy" is mentioned. An editorial[13] in the same issue stated that the effect of serotherapy does not seem very important. Statistics based on probably the least effective factors in treatment probably mean little.

Although Heurich *et al*[14] gave a good detailed regimen, the subject seems far from closed. In 1949 Turner and Galloway demonstrated that by invoking the principles already discussed here, the treatment of tetanus using tracheostomy and respirator might be as simple as that of a well-ordered case of bulbar polio.

Our outline of treatment was:

1. Sedation, short of dangerous depression.

2. Debridement with exposure to constant nascent O_2.

3. Curare or similar drug in the minimal dose to control spasm. More may damage muscle and lead to atonic shock.

4. Tracheostomy except in very mild cases to keep the airway open and permit use of mechanical respirator and suction.

5. O_2 if needed, parenteral fluids and gavage later.

6. Extreme gentleness.

The use of a steady supply in the wound of nascent O_2 from fresh heat-activated Zn_2 O_2,* retained by packs, repeated every 12 hours is suggested by its striking effect on anaerobic streptococci in cranial osteomyelitis, another situation where anaerobic infection is commonly combined with thrombophlebitis. Hydrogen peroxide is too evanescent to expect it to be effective. Tetanus is rare now, under 200 cases a year, but I would hope that nascent O_2 might have a striking effect, possibly on the toxins.

There is not time to discuss other related subjects, for instance, the allotment of training to various subspecialties. Shall we continue to expand or achieve more in narrower fields? Shall we discourage new recruits or assume that as always we find a chance to do what we can do better?

I hope that this report may help to consolidate our authority in the field of respiratory obstruction. In the field of the peripheral airway it seems to be sought less because we do not control the raw material, and our young men have not prepared themselves for such cases or made themselves available. In the field of medicine there should be no war rules so that the final defense will have to be our own trained readiness to meet any challenge.

REFERENCES

1. Jackson C, Jackson CL: Acute laryngotracheobronchitis. JAMA 107:929-933, 1936

2. Richards L: A further study of the pathology of acute laryngotracheobronchitis in children. Ann Otol Rhinol Laryngol 47:326-341, 1938

3. Baum HL: Acute laryngotracheobronchitis. JAMA 91:1097-1102, 1928

4. Gittins TR: Laryngitis and tracheobronchitis: Reference to nondiphtheritic infections. Ann Otol Rhinol Laryngol 45:1165-1174, 1936

5. Davison FW: Acute laryngotracheobron-

* E. I. Du Pont de Nemours and Co., Wilmington, DE.

chitis. Arch Otolaryngol 47:455-464, 1948

6. Galloway TC: Tracheotomy in bulbar poliomyelitis. JAMA 123:1096-1097, 1943

7. Priest RE, Boies LR, Goltz NF: Tracheostomy in bulbar poliomyelitis. Ann Otol Rhinol Laryngol 56:250-263,1947

8. Wilson JL: Acute anterior poliomyelitis. N Engl J Med 206:887-893, 1932

9. Galloway TC: The danger of unrecognized anoxia in laryngology. Ann Otol Rhinol Laryngol 55:508-518, 1946

10. Thomas GK: Tracheostomy in otolaryngology, in Paparella MM, Schumrick DA (eds): *Otolaryngology. Vol III, Head and Neck.* Philadelphia, WB Saunders and Co., 1973, pp 845-857

11. Echols DH, Llewellyn R, Kirgis HD, *et al*: Tracheostomy in the management of severe head injuries. Surgery 28:801-811, 1950

12. Blake PA, Feldman RA, Buchanan TM, *et al*: Serologic therapy of tetanus in the U.S. 1965-71. JAMA 235:42-44, 1975

13. Edsall GE: Editorial item. JAMA 235: 62, 1975

14. Heurich AE, Brust JC, Richter RW: Management of urban tetanus. Med Clin North Am 57:1373-1381, 1975

15. Turner VE, Galloway TC: Tetanus treated as a respiratory problem. Arch Surg 58:478-483, 1949

SECOND DANIEL C. BAKER, JR. LECTURE

PROGRESS OF OTOLARYNGOLOGY IN HEAD AND NECK SURGERY

JOSEPH H. OGURA, MD

ST. LOUIS, MISSOURI

Over 100 years ago the first laryngectomy for cancer was performed by C. Billroth, although he was a general surgeon. It was a historical event. The surgical mortality rate from this operation was high for years and its progress was slow. But in 1878, another historical event took place. Twenty men under the presidency of Dr. H. Elsberry held the first meeting in New York City of the American Laryngological Association. The title of his first lecture was "Laryngology in America." It was a long address of 56 pages with a 100 page bibliography. Today, we accept laryngology as something we have been doing for years, but in New York in 1879 it was only ten years old. The frequency of infection of the larynx leading to serious or fatal consequence with respiratory and deglutition difficulties and the development of the laryngoscope for recognition of these problems led to the establishment of many departments of laryngology.

There was a long period of void in the evolution of surgery in laryngology, from the laryngofissure by C. Jackson in 1904 until 1928 when Dr. G. B. New described the two stage laryngectomy because of infectious complications and fistulas.

From the narrow field laryngectomy in 1938 we entered a period of irradiation alone or radical surgery in the treatment of laryngeal cancers. Because it was known that the lymphatics were separate above and below the true vocal cords, the basis for conservation surgery was formed. We are all familiar with the development of the subtotal operation so this really needs no comment. J. Alonso and others in America (J. Ogura and M. Som) further refined this technique. Early laryngeal cancer operations and many early head and neck cancers are treated by irradiation. Larger lesions are treated by radical surgery or by the addition of pre- or postoperative irradiation.

In the late forties with the return of veterans from the war, there was a brief period of excess of residents. The training period for residents was lengthened to three years, but there was a shortage of qualified applicants. This was also the period of ascendancy for ear surgery, but despite this, otolaryngology was in a period of great difficulty and decline.

Some 26 years ago D. Lierle addressed this association on the training of the resident. At that time, things were very bright. Most of the institutions were teaching basic sciences, giving residents experience in head and neck surgery, and otology. The papers were mostly philosophical, personal attitudes of management, and documentation of case reports. This is understand-

From the Department of Otolaryngology, Washington University School of Medicine, St. Louis, Missouri.

able because sophisticated electronic or biochemical markers were not available. Clinical and basic research were minimal.

The advent of National Institutes of Health (NIH) training grants and research funds have increased and improved the research environment of many departments, thus improving greatly the clinical training available. You can see this today in the improved quality of our residents. Now it is not at all unusual that a candidate for Board certification has completed two years of general surgery and four years of otolaryngology. Better residents are making better young staff men and practitioners.

It is not possible for all residents to receive equal and uniform training, however, the American College of Surgeons in conjunction with the American Board of Otolaryngology and the Council of Medical Education of the AMA, has sponsored and passed the special Essentials of Otolaryngology. The Society of Head and Neck Surgeons and the American Society for Head and Neck Surgery have also been working to seek a solution to this problem for head and neck cancer. It is the hope to standardize training with options in providing training in head and neck surgery, plastic surgery of the head and neck, oncology, and immunology. However, it is likely that the number of head and neck surgeons to be certified as competent by certification will not be accomplished at this time.

Today's otolaryngologist has become an expert in the head and neck area. Because of this, the treatment of glomus vagale, carotid body, parotid, oral cavity, and esophageal tumors has often fallen his way. The use of flaps in reconstructive procedures has evolved into a great interest by many otolaryngologists in surgery of the head and neck. However, otology still has an active hold on others.

Finally, I would like to comment on the progress being made by the Head and Neck Cancer Cadre. This idea had its origin from the National Cancer Advisory Board of which I am its representative. To gain cooperation, confidence, assistance and security from the other disciplines, we made it purposely multidisciplinary over a few years. Through six subcommittees we have developed over the last two years a number of well-designed research protocols that can be implemented through a national program of treatment, cure, and control of cancers of the head and neck. However, it became evident last year that our basic science approach lacked a solid focus. A state of the art conference was suggested as the best forum for securing and disseminating the needed information and the National Cancer Institute (NCI) and the American Cancer Society agreed to cosponsor such a conference.

A steering committee that was selected from the Cadre membership and consultants drafted a conference goal and a program which would satisfy this goal.

The State of the Art Conference participants convened in New Orleans, February 16, 1976. This was of necessity a closed conference to get needed discussion from these experts. The conference consisted of five sections – Immunology; Pharmacology, Cell Kinetics and Radiation Biology; Epidemiology, Carcinogenesis and Virology; Natural History and Modification of Head and Neck Cancer; and Quality of Life. Clinical cooperation studies previously randomized were omitted.

Each of the five sections was chaired or guided by a steering committee member to insure achievement of the conference goal, with the participants of each section chosen for their competency in a given professional speciality.

The interdisciplinary cooperation and probing by the participants in their quest for the most interesting and demanding subjects for investigation gave us results beyond our expectations. Most of the presentations were varied and equally valuable.

The first morning was devoted to immunology. The afternoon section pro-

vided an overview for pharmacology, cell kinetics and radiation biology.

On the second morning, Section III, Epidemiology, Carcinogenesis and Virology met. Again, the examination of subject areas revealed many sources for future investigation. The Natural History and Modification of Head and Neck Cancer met that same afternoon. It was our heaviest scheduled section.

The last section on the third day was Quality of Life. This section brought within one spectrum medical professionals, paraprofessionals, and legal specialists needed to provide comprehensive and compassionate care prospectives.

This particular state of the art conference was a genuine success to all who attended and an overwhelming success as finally summarized by the NCI staff members, and from which a national program on head and neck cancer should evolve.

This I believe – the orderly, gradual development and evolution of laryngology is in head and neck surgery.

As I conclude this Daniel C. Baker Lecture, let me comment that it was indeed a great honor to deliver this lecture. To me, our growth has been spectacular, our future is secure, our platform very broad, firm, and indeed bright. If Dan Baker were here today I am sure he would be the first to agree with this.

SCIENTIFIC SESSIONS

The first Scientific Session of the Ninety-Seventh Annual Meeting, held in the Venetian Ballroom of The Breakers Hotel at Palm Beach, Florida, convened on Saturday April 24, 1976 at 8:30 A.M. The First Vice-President, John S. Lewis, MD, of New York, New York was in the Chair for the first session.

The second session on Sunday, April 25 at 1:30 P.M. was moderated by Edwin W. Cocke, Jr., MD, Second Vice-President of the Association.

ETIOLOGY OF BILATERAL ABDUCTOR VOCAL CORD PARALYSIS

A REVIEW OF 389 CASES

LAUREN D. HOLINGER, MD

PAUL C. HOLINGER, MD PAUL H. HOLINGER, MD

CHICAGO, ILLINOIS

SUMMARY – The etiology of 389 cases of partial or complete bilateral abductor vocal cord paralysis has been determined and classified. One hundred and forty-nine were infants and children 12 years of age and under; 240 were adults, age 13 and older. In the infants and children the paralyses were congenital in 82 cases, of which 43 were associated with other congenital anomalies, and 39 were without associated anomalies. Fifty-nine cases were considered acquired, most being secondary to underlying congenital anomalies, particularly the associated findings of meningomyelocele, Arnold-Chiari malformation, and hydrocephalus. Eight cases of paralysis in this age group were of undetermined etiology. Of the 240 adult cases of bilateral vocal cord paralysis, 138 followed thyroidectomy. Fifty-two cases were associated with various neurologic disorders, including poliomyelitis, Parkinson's disease, cerebrovascular accident, Guillain-Barré syndrome, multiple sclerosis, neoplasm, and other miscellaneous neurologic conditions. Sixteen cases were due to malignant neoplasms of the neck and mediastinum. The remaining 34 cases constitute a miscellaneous group which includes foreign bodies, bilateral neck dissection, infection, congenital lesions, trauma, and idiopathic paralyses. The characteristic symptoms of bilateral abductor vocal cord paralysis include normal or near normal phonation with inspiratory stridor which may progress to complete respiratory obstruction. These symptoms are due to the stationary but flaccid midline position of the vocal cords which places them in a phonating position, where they both obstruct the airway and produce a fairly clear voice or cry. This paradoxical combination of symptoms was frequently found to be responsible for a failure or delay in diagnosis.

Bilateral abductor vocal cord paralysis is a distressing condition, often life-threatening, and not infrequently a direct cause of asphyxial death. Yet many times it is unrecognized clinically because the voice or cry of the patient with bilateral paralysis is quite normal and invariably better than that of the patient with unilateral paralysis. This paradox is due to the fact that in bilateral paralysis both cords remain weakly adducted, in which position they vibrate during expiration or phonation, passively but equally. In unilateral paralysis, on the other hand, differences in tension between the normal and the

From the Department of Otolaryngology, Abraham Lincoln School of Medicine of the University of Illinois; the Department of Psychiatry, Psychosomatic and Psychiatric Institute, Michael Reese Hospital and Medical Center; the Department of Bronchology, The Children's Memorial Hospital; and the Department of Otolaryngology and Bronchoesophagology, Rush/Presbyterian-St. Luke's Medical Center, Chicago, Illinois.

TABLE I

ETIOLOGY OF BILATERAL ABDUCTOR VOCAL CORD PARALYSIS IN INFANTS AND CHILDREN

Congenital			
Without associated anomalies		39	
With associated anomalies			
Neurologic	21		
Laryngeal	10		
Cardiac	8		
Other	4		
		43	
Total Congenital			82 (55%)
Acquired			
Secondary to congenital anomalies			
Meningomyelocele, A-CM, hydrocephalus	24		
Hydrocephalus unrelated to A-CM	6		
Postoperative for congenital lesion	11		
		41	
Secondary to acquired conditions			
Infectious	7		
Neoplasm	7		
Birth trauma	2		
Guillain-Barré syndrome	2		
		18	
Total Acquired			59 (40%)
Undetermined		8	8 (5%)
	Total		149 (100%)

paralyzed cord result in a hoarse, aspirate voice. Patients with bilateral vocal cord paralysis have a limited airway and a persistent, soft, inspiratory stridor which may be barely audible or may increase to a loud, agonal, even terminal crow. Any additional edema of the cords results in extreme dyspnea, for which intubation or tracheotomy may become necessary. Failure to recognize the condition most often occurs in the thyroidectomized adult. Similarly, in the stridorous infant with a major central nervous system (CNS) defect, bilateral paralysis may remain undiagnosed because of a failure to examine the larynx routinely and without anesthesia.

METHODS AND MATERIALS

This study reviews the etiology of 389 cases of partial or complete bilateral abductor vocal cord paralysis in infants and children 12 years of age and under, and adults age 13 or older. Diagnosis in all cases was confirmed by mirror or endoscopic examination. In infants, the diagnosis can be established only by direct laryngoscopic examination without anesthesia.[1] The spatulous tip of a standard Jackson pediatric laryngoscope is placed in the vallecula to lift the base of the tongue and epiglottis to evaluate vocal cord mobility. Care must be taken to avoid contact with the vocal cords or arytenoids, which would alter cord mobility. Passive mobility should be evaluated by palpation to rule out midline vocal cord fixation.[2] In adults the examination is made with the laryngeal mirror, not only during the phonation of "e-e-e-e," but especially during inspiration as well.

RESULTS

The data derived from this study are most informative when infants and children are evaluated separately from adults. Bilateral paralysis in infants is largely congenital in origin, or secondary to congenital anomalies of the CNS. In adults the great majority of cases are acquired. Unfortunately, the leading cause is surgical injury to the recurrent laryngeal nerves at thyroidectomy. Neurologic lesions are the second most common cause of bilateral paralysis in adults. A classification based on the

TABLE II

ETIOLOGY OF BILATERAL ABDUCTOR VOCAL CORD PARALYSIS IN ADULTS

Thyroidectomy		138	(58%)
Neurologic			
Poliomyelitis	14		
Parkinson's disease	4		
Cerebrovascular accident	4		
Guillain-Barré syndrome	3		
Multiple sclerosis	3		
CNS neoplasm	3		
CNS infection	2		
Charcot-Marie-Tooth	2		
Other	17		
		52	(22%)
Malignancy of the neck		16	(6%)
Miscellaneous			
Foreign bodies	2		
Bilateral neck dissection	3		
Infection	3		
Congenital	3		
Trauma	2		
Substernal thyroid	2		
Idiopathic	8		
Other	3		
Undetermined	8		
		34	(14%)
Total		240	(100%)

two age groups is presented in Tables I and II.

Of the 389 cases, 149 (38%) were present in infants and children under 13 years of age; 240 (62%) were found in adults. There were 146 males and 243 females. Sex distribution was similar among the infants and children (80 males, 69 females), but among the adults there were 66 males and 174 females. This was due to a higher incidence of thyroid disease in females; of 138 cases of bilateral paralysis due to thyroidectomy, only 11 occurred in males. Tracheotomy was required at some time during the patient's course in 199 cases (51%); 71 cases were in infants and children and 128 in adults; 48% of the infants and children required tracheotomy, as did 53% of adults.

DISCUSSION

Stridor is the most prominent symptom of bilateral abductor vocal cord paralysis. It varies from a soft, high-pitched, inspiratory sound to an extremely loud, distressing crow. Adult patients' families volunteer that often it is easily heard throughout the room or ward and even by neighbors if the windows are open in the summertime. Snoring is especially pronounced when the patient is relaxed during sleep. The voice and speech are somewhat abnormal; a peculiar monotone with long, hurried sentences is interrupted by a stridorous, inspiratory pause as the patient attempts to fill his lungs for continuation of his comment. Laughter is consciously suppressed to avoid the air loss which must be followed by distressing inspiration. Cough is desperately suppressed for the same reason. In infants, while the cry may be clear, stridor is high-pitched and not necessarily accompanied by acute respiratory distress, although marked indrawing of the suprasternal notch and epigastrium is usually apparent. With prolonged obstruction, however, fatigue becomes the major factor precipitating either intubation or tracheotomy.

The degree of aspiration, especially of liquids, helps localize the site of the lesion superior or inferior to the origin of the superior laryngeal nerve. While this should be a fairly accurate diagnostic criterion, patients with aspiration due to superior laryngeal nerve involvement soon learn to control coughing and choking, and the clinical significance of this diagnostic point is lost.

The most serious symptom, of course, is respiratory obstruction, which is evidenced by stridor, dyspnea, retraction, and nasal flaring. Since the airway through the larynx is limited, the least effort, activity, inflammation or edema may result in increasing dyspnea, and even psychiatric symptoms in adults. As obstruction increases, restlessness, the use of the accessory respiratory musculature, and eventually cyanosis become apparent. If unrelieved, total asphyxia follows. Many patients tolerate their

condition for considerable lengths of time, remaining marginally compensated until a minimal change in their status renders the airway inadequate. Patients with postthyroidectomy bilateral paralysis usually adapt to a minimal airway over a period of years; yet eventually, even 10 to 20 years later, may require surgical intervention such as a tracheotomy or arytenoidectomy. This may be associated with myxedematous infiltration of the cords due to hypothyroidism or laryngeal spasm associated with the hypocalcemic tetany of hypoparathyroidism. Infants and children may remain stridorous but undiagnosed until an upper respiratory infection leads to obstruction, or a prolonged episode of croup, for which the child is ultimately referred for endoscopic evaluation. The importance of direct endoscopic examination of children with stridor or persistent episodes of croup cannot be overemphasized. In a recent review of subglottic stenosis in infants and children,[3] 34% of 115 cases of congenital subglottic stenosis presented with recurrent or persistent croup.

Infants and Children

Congenital Paralysis. Vocal cord paralysis represents approximately 10% of all congenital anomalies of the larynx.[4] It is the second most common laryngeal anomaly; only laryngomalacia is seen more often. In this series, 82 of the 149 infants and children had congenital bilateral paralysis.

In 39 of the 82 congenital cases the paralysis was without associated anomalies, most of which tended to resolve spontaneously over a period of weeks or months; a closer study of this group is now under way to more accurately determine the outcome. In some of these infants, the arytenoids were observed to move in the absence of any mobility of the vocal cords, which were immobile in the median position. Palpation demonstrated the arytenoids could be moved with forceps.

Forty-three infants and children had other congenital anomalies associated with congenital bilateral paralysis. Twenty-one had associated neurologic lesions. The association between the paralysis and the neurologic disorders had greater etiologic significance in some cases than in others. Congenital bilateral paralysis was seen in six infants with cerebral agenesis, four infants with congenital cranial nerve palsies including X, and one infant with congenital nuclear hypoplasias including X. In these 11 cases the congenital bilateral vocal cord paralysis was apparently secondary to the neurologic lesions. In the remaining ten cases the relationship between the vocal cord paralysis and the neurologic disorder was less well defined. Three of these ten had benign congenital hypotonia, one had Werdnig-Hoffmann disease, another had leukodystrophy (Alexander's disease), and there was one child with scapuloperoneal muscular dystrophy. The exact nature of the neurologic lesion remained obscure in three cases. Congenital bilateral paralysis was found in one patient with Charcot-Marie-Tooth disease; the occurrence of congenital bilateral vocal cord paralysis in families has been documented and is discussed elsewhere.[5-8]

Ten infants and children had other laryngeal anomalies associated with their congenital bilateral vocal cord paralysis; subglottic stenosis was present in six; laryngomalacia in three and laryngocele in one. One of the infants with laryngomalacia had other congenital anomalies, including hypospadias and bilateral dysplasia of the hips; a chromosomal abnormality was documented with karyotype interpretation 46, XY, one of D chromosomes having a short arm.

A wide variety of cardiac anomalies occurred in eight infants and children with congenital bilateral paralysis; these included ventricular septal defect, three; coarctation of the aorta, two; transposition of the great vessels, two; and atrial septal defect, one. Two of these patients also had Down's syndrome.

A miscellaneous group of congenital

anomalies comprised the other four cases associated with congenital bilateral paralysis. These included spontaneous pneumothorax, muscular hypertonia and tracheomalacia with a narrow right main bronchus.

Acquired Paralysis. In this series, 59 of the 149 infants and children had acquired bilateral paralysis. In 41, the acquired paralysis occurred secondary to underlying congenital anomalies or was secondary to the surgical treatment of such anomalies. Of these 41, 24 involved infants born with meningomyelocele.

The association of meningomyelocele with paralysis of the vocal cords was noted in 1932,[9] 1939,[10] 1941[11] and again 15 years later.[12,13] Investigators later identified the relationship in more extensive case reports,[14-17] and others have recently probed the pathogenesis of bilateral vocal cord paralysis when related to meningomyelocele.[18-22] Associated meningomyelocele, Arnold-Chiari malformation, and hydrocephalus, as well as the neurosurgical efforts to repair these abnormalities, may result in increased intracranial pressure with subsequent airway obstruction due to bilateral vocal cord paralysis. Arnold-Chiari malformation (Chiari II), documented in 9 of the 24 cases with meningomyelocele, is probably present to some degree in all of these cases.[23] It is a developmental disorder characterized particularly by varying degrees of herniation of the cerebellum and kinking of the medulla oblongata, the causes of which are debated, but for which there may be a genetic background.[24]

In this series, neurosurgical repair of the meningomyelocele was usually accomplished shortly after birth; increased intracranial pressure and hydrocephalus occurred at varying lengths of time thereafter. Shunting procedures were instituted to control the hydrocephalus. The increased intracranial pressure which preceded signs and symptoms of airway obstruction was most frequently associated with malfunctioning or infected shunts. Less frequently, the bilateral paralysis occurred following repair of the meningomyelocele but before a diagnosis of hydrocephalus was made. Some children were later readmitted when the stridor of bilateral paralysis developed as the first sign of increased intracranial pressure due to a malfunctioning or infected shunt. The clinical course and pathophysiology seen in these are reviewed in greater detail elsewhere.[22]

Six cases of infants with bilateral paralyses were seen with hydrocephalus secondary to tumor, meningitis, and other underlying conditions, but without meningomyelocele.

Signs and symptoms of increased intracranial pressure, particularly increased head size, bulging fontanelle, and vomiting, usually preceded evidence of airway obstruction. Stridor and respiratory distress were prominent among the signs and symptoms of the ensuing bilateral paralysis. While associated with increased intracranial pressure, the precise etiology of the bilateral vocal cord paralysis in these cases is uncertain and discussed in detail elsewhere.[21,22] Among the possible hypotheses are brain stem dysgenesis, mechanical compression of the vagus nerve by the herniated posterior fossa contents, stretching of the vagus nerve rootlets during herniation with resulting neuronal degeneration, and circulatory impairment of the brain stem.

Although the etiology of the bilateral vocal cord paralysis in these cases is uncertain, the resulting airway obstruction can be life-threatening, and an airway must be promptly secured by intubation. Subsequent direct laryngoscopy discloses the median or paramedian position of the cords; tracheotomy is frequently necessitated when extubation attempts are unsuccessful. At The Children's Memorial Hospital in Chicago, where nearly all of the infants and children were seen, the neurosurgical service has been acutely aware of the relationship between bilateral vocal cord paralysis and increased intracranial pressure for many years. When stridor develops in a child known to have a potential for increased

intracranial pressure, *e.g.*, those with hydrocephalus and meningomyelocele, they are assumed to have bilateral paralysis on the basis of increasing pressure. An endotracheal tube is placed, the cause of the increased pressure treated (it is most often related to an infected or malfunctioning shunt) and the child extubated.

Eleven instances of acquired bilateral paralysis followed surgical repair of congenital lesions which were not related to the CNS. Six became apparent after repair of tracheoesophageal fistula, three following surgery for congenital heart disease. One was diagnosed following the excision of a congenital bronchial cyst and one following craniotomy for craniostenosis.

Eighteen of the 59 children with acquired bilateral paralysis had no associated congenital anomaly. Seven were due to infectious disease: meningitis, encephalitis and poliomyelitis. Neoplasms of the CNS caused the paralysis in six; a seventh patient had Hodgkin's disease of the mediastinum and suffered bilateral paralysis following radiation therapy. Birth trauma was implicated in two cases and Guillain-Barré syndrome in two.

Undetermined Paralysis. The etiology of bilateral abductor vocal cord paralysis was undetermined in 8 of the 149 infants and children.

ADULTS

Two hundred and forty of the patients with bilateral abductor vocal cord paralysis were adults 13 years of age and older. Unlike the infants and children, the overwhelming majority of adults had acquired paralyses. Only three were considered to have congenital paralyses, these on the basis of a history of stridor since infancy. None had ever been examined directly or indirectly until seen at ages 33, 59, and 70, when their obstruction became severe enough to necessitate investigation.

Postthyroidectomy. One hundred and thirty-eight of the acquired adult cases followed thyroidectomy. Many of these had no symptoms of upper airway obstruction until after their second or even third thyroidectomy, although they generally gave a history of voice change following the original operation. In addition to respiratory obstruction, many had signs and findings of hypothyroidism and hypoparathyroidism. The number of cases observed increased during the period of time a total thyroidectomy was recommended for certain cardiac conditions. Psychiatric symptoms associated with hypothyroidism and hypoparathyroidism were freqeunt in this group of 138, and included depression, psychomotor retardation, irritability, and other personality changes.

Hoarseness following thyroidectomy is most often the result of paralysis of one vocal cord, due to trauma to a recurrent laryngeal nerve. The voice is weak and breathy; aspiration is frequent. However, when both nerves are involved, the voice, which may be temporarily affected, soon returns to almost normal, punctuated only by varying degrees of stridor. On examination with a laryngeal mirror during the phonation of "e-e-e-e," the larynx appears quite normal. However, the patient is usually so dyspneic that attempts to watch for the separation of the cords during inspiration are often abandoned.

In a review of 63 cases of bilateral vocal cord paralysis following thyroidectomy reported in 1955,[25] 40% were found to be hypothyroid while 21% were hypoparathyroid. The symptoms are generally manifested by the progressive limitation of the individual's activity, resulting from pulmonary and circulatory involvement as well as the increasing airway obstruction. Bouts of acute respiratory obstruction may be noted after an episode of emotional stress or in association with respiratory tract infections to which these patients are particularly susceptible. When the obstruction becomes sufficiently severe, intubation or tracheotomy must be undertaken to relieve the hypoxia and to protect the circulation: anoxia with its depressant effect on the myocardium can create a circulatory crisis to the

extent of precipitating congestive heart failure.

The signs and symptoms of hypothyroidism are readily recognized. The complacent attitude, slowness of response, dull facies, dry skin, marked pallor, coarse hair, and poor tolerance to cold are characteristic. These findings are emphasized to stress their significance in patients who have post-thyroidectomy respiratory obstruction from bilateral vocal cord paralysis. The myxedema of hypothyroidism includes the vocal cords and the supporting tissues of the larynx, and thus increases the degree of obstruction. The correction of the laryngeal myxedema with proper thyroid replacement therapy is necessary before surgical intervention is considered, and may obviate the need for surgery.

The symptoms due to hypoparathyroidism may be masked by those of hypothyroidism, and the diagnosis overlooked for this reason. When symptoms of fatigue, muscular weakness, tetany and paresthesias are present in the thyroidectomized patient, hypoparathyroidism should be suspected. Depending upon the degree of hypocalcemia, there may be cramps of the extremities, carpopedal as well as laryngeal spasm; even generalized convulsions may occur. Not uncommonly, these symptoms may be misdiagnosed as psychogenic. Cardiac conduction disturbances relating to calcium metabolism may also be present.

Paralysis Associated with Other Neurological Disorders. The commonest neurologic disorder associated with bilateral paralysis in adults was found to be poliomyelitis. The frequency with which bilateral laryngeal paralysis was caused by bulbar polio has been well documented by Galloway and Seifert.[26] Their description of the life-threatening and fatal complications of not only respiratory obstruction but aspiration of pharyngeal secretions is classic. Similar concepts of management were employed by Ibsen during the great Copenhagen polio epidemic of 1952, through the use of cuffed endotracheal tube and positive pressure ventilation.[27] Our experience in the acute phase[28] is not as extensive as that of Galloway and Ibsen. The 14 cases recorded in this series were encountered during a later stage when the respiratory obstruction of bilatral paralysis was complicated by the atelectasis associated with diaphragmatic and intercostal paralysis. Pharyngeal and laryngeal sensory involvement was thought to complicate the motor paralysis contributing to patients' aspiration of food and fluids, thus increasing the respiratory embarrassment. The resulting respiratory difficulties became extreme and tracheotomy was urgently needed. Yet many physicians who treated poliomyelitis were apparently unaware of the fact that the patient with bilateral vocal cord paralysis is able to phonate without difficulty, although the airway may have been so obstructed that he lapsed into unconsciousness.

In addition to the 14 cases of polio, several other acquired neurologic disorders have been found complicated by bilateral vocal cord paralysis, most with dyspnea so severe that they required tracheotomy. These cases include Parkinson's disease (four), cerebrovascular accident (four), Guillain-Barré syndrome (three), multiple sclerosis (three), CNS tumors (three), encephalitis and meningitis (two), and others (bulbar and pseudobulbar palsies, 17). Also, two patients with Charcot-Marie-Tooth disease, a mother and her son, were both found to have an associated bilateral vocal cord paralysis.

Paralysis Associated with Malignancy of the Neck. Sixteen cases of malignant neoplasms of the thyroid, cervical esophagus, subglottic larynx, neck and upper mediastinum were found to be responsible for bilateral abductor paralysis by pressure or invasion of the vagus or its recurrent branches. Usually one side was affected first; later the dyspnea of bilateral involvement became unmistakable. Mirror laryngoscopy or x-ray studies of the larynx and trachea are necessary to distinguish this

symptom from tracheal compression or invasion by the neoplasm.

Miscellaneous Etiology. The 34 remaining patients with bilateral paralysis were found to have a variety of disorders. Foreign bodies in the esophagus were responsible for two cases of bilateral paralysis of the larynx. One was a 2-year-old child who was admitted to the hospital with severe dysphagia and dyspnea. Roentgen studies revealed a large, nonopaque button in the cervical esophagus which the mother was able to identify as having been swallowed nine months previously. Following tracheotomy the button was removed from a bed of scar, granulation tissue, and pus. Laryngoscopy demonstrated the bilateral midline position of the vocal cords. Extensive ulceration of the esophageal walls with periesophageal inflammation, induration, and abscess accounted for the paralysis.[13] The paralysis was permanent and eventually required arytenoidectomy. The second case was an adult who had an extensive cervical mediastinitis following esophageal perforation by a chicken bone.

In three cases in the miscellaneous group the paralysis followed bilateral neck dissection. Three others developed their paralysis following respiratory tract infections. In another three cases discussed previously, the etiology was considered congenital. Two patients had bilateral paralysis due to cervical trauma, and in two others, substernal thyroids involved both recurrent nerves. There was one case each of arthritis, leukemia, and a lesion of the cervical esophagus.

Eight cases in this group of miscellaneous paralyses were seen once in consultation for verification of the diagnosis only, and the etiology was not determined.

Eight adult patients were studied extensively but the etiology of their bilateral vocal cord paralyses was not discovered; these are considered idiopathic. Diagnostic evaluation began with a thorough history, which in many instances led directly to the etiology. Patients were questioned specifically about trauma, previous surgery, the degree and onset of hoarseness, dysphagia, aspiration, stridor and pain. A history of infection or recent upper respiratory infection was sought. Others had had thyroidectomies decades previously with symptoms beginning only weeks or months prior to evaluation; many of these were found to be hypothyroid or hypoparathyroid.

Remaining patients had medical and neurologic evaluations and laboratory studies which usually consisted of CBC, urinalysis, fasting and two-hour postprandial blood glucose, serologic tests for syphilis (VDRL, FTA-abs), erythrocyte sedimentation rate, PBI, T3 and T4. When the etiology remained obscure, thorough head and neck physical examination was extended to include endoscopic evaluation of larynx, trachea, and cervical esophagus. When indicated, these were preceded by special roentgenographic examinations, such as tomography and contrast studies (barium esophagram). Further specialized tests were employed to define associated neurologic lesions.

CONCLUSIONS

The etiology of 389 cases of partial or complete bilateral abductor vocal cord paralysis has been analyzed. There were 149 cases of infants and children 12 years of age and under: in 82, the lesions were congenital in origin, in 59, the etiology was acquired, and in 8, the etiology was undetermined. Two hundred and forty of the patients were adults 13 years of age and older; in all but three the condition was acquired. One hundred and thirty-eight followed thyroidectomy, 52 were neurologic, 16 were due to malignancies of the neck, and 34 were miscellaneous, eight of which were considered idiopathic.

The diagnosis of bilateral vocal cord paralysis is obscured by the paradoxical association of a relatively clear voice or cry with varying degrees of respiratory obstruction. The diagnosis may be overlooked in stridorous infants and children with meningomyelocele, Arnold-

Chiari malformation and hydrocephalus, because the larynx is not examined without anesthesia; in such infants the onset of stridor is most often due to bilateral cord paralysis precipitated by increasing intracranial pressure. In adults, mirror examination of the larynx must be made during both phonation and inspiration. While some thyroidectomized adults adapt to the compromised airway of bilateral paralysis, the additional insult of hypothyroid myxedema or hypoparathyroid tetany may upset their compensated state. Conservative management involves correction of the underlying metabolic abnormality before any surgical intervention is undertaken.

REFERENCES

1. Holinger PH: Clinical aspects of congenital anomalies of the larynx, trachea, bronchi and oesophagus. J Laryngol Otol 75:1-44, 1961

2. Cox DJ, Simmons FB: Midline vocal cord fixation in the newborn. Arch Otolaryngol 100:219, 1974

3. Holinger PH, Kutnick SL, Schild JA, *et al*: Subglottic stenosis in infants and children. Ann Otol Rhinol Laryngol, to be published.

4. Holinger PH, Brown WT: Congenital webs, cysts, laryngoceles and other congenital anomalies of the larynx. Ann Otol Rhinol Laryngol 76:744-752, 1967

5. Platt D: Congenital laryngeal – abductor paralysis due to nucleus ambiguus dysgenesis in three brothers. N Engl J Med 271: 593-597, 1964

6. Watters GV, Fitch N: Familial laryngeal abductor paralysis and psychomotor retardation. Clin Genet 4:429-433, 1973

7. Gacek RR: Hereditary abductor vocal cord paralysis. Ann Otol Rhinol Laryngol 85: 90-93, 1976

8. Holinger PC, Holinger LD, Vuckovich MD, *et al*: Familial bilateral abductor vocal cord paralysis in Charcot-Marie-Tooth disease, to be published.

9. New GB, Childrey JH: Paralysis of the vocal cords. Arch Otolaryngol 16:143-159, 1932

10. Heatly CA: The larynx in infancy: A study of chronic stridor. Arch Otolaryngol 29: 90-103, 1939

11. Work WP: Paralysis and paresis of the vocal cords: A statistical review. Arch Otolaryngol 34:267-280, 1941

12. Bigler JA, Holinger PH, Johnston KC, *et al*: Tracheotomy in infancy. Pediatrics 13: 476-486, 1954

13. Holinger PH, Johnston KC: Bilateral recurrent laryngeal nerve paralysis; medical and surgical aspects. Eye Digest 38-45, June 1956

14. Cavanagh F: Vocal cord palsies in children. J Laryngol Otol 69:399-418, 1955

15. Rullan A: Associated laryngeal paralysis. Arch Otolaryngol 64:207-212, 1956

16. Smith MEN: The association of laryngeal stridor with meningomyelocele. J Laryngol Otol 73:188-190, 1959

17. Graham MD: Bilateral vocal cord paralysis associated with meningomyelocele and the Arnold-Chiari malformation. Laryngoscope 73:85-92, 1963

18. Snow JB, Rogers KA Jr: Bilateral abductor paralysis of the vocal cords secondary to the Arnold-Chiari malformation and its management. Laryngoscope 75:316-321, 1965

19. Kirsch WM, Duncan BR, Black FO, *et al*: Laryngeal palsy in association with meningomyelocele, hydrocephalus, and the Arnold-Chiari malformation. J Neurosurg 218: 207-214, 1968

20. Sieben RL, Hamida MB, Shulman K: Multiple cranial nerve deficits associated with the Arnold-Chiari malformation. Neurology 21:673-680, 1971

21. Bluestone LD, Delerme HN, Samuelson GM: Airway obstruction due to vocal cord paralysis in infants with meningomyelocele and hydrocephalus. Ann Otol Rhinol Laryngol 81:778-783, 1972

22. Reichert TJ, Schild JA, Holinger PH: Respiratory obstruction in infants with meningomyelocele and hydrocephalus. Presented at the Third Annual Meeting of Society for Ear Nose and Throat Advances in Children, Mexico City, Mexico, November 8, 1975

23. Emery JL, MacKenzie N: Medullocervical dislocation deformity (Chiari II deformity) related to neurospinal dysraphism (meningomyelocele). Brain 96:155-162, 1973

24. Gardner E, O'Rahilly R, Prolo D: The Dandy-Walker and Arnold-Chiari malformations. Arch Neurol 32:393-407, 1975

25. Ranke EJ, Holinger PH: Paralysis of the vocal cords following thyroidectomy. JAMA 158:543-547, 1955

26. Galloway TC, Seifert MH: Bulbar poliomyelitis. Ann Otol Rhinol Laryngol 56:250-263, 1947

27. Ibsen B: Anesthetists' viewpoint on treatment of respiratory complications in poliomyelitis during the epidemic in Copenhagen in 1952. Proc R Soc Med 47:72-74, 1954

28. Holinger PH, Johnston KC: Tracheotomy in acute tracheobronchitis and poliomyelitis. Prog Ophthalmol Otolaryngol 1:590-597, 1952

REPRINTS—Lauren D. Holinger, MD, 700 N. Michigan Avenue, Chicago, IL 60611.

BILATERAL ABDUCTOR PARALYSIS

30 YEARS EXPERIENCE WITH ARYTENOIDECTOMY

DeGraaf Woodman, MD

Easton, Maryland

Claude L. Pennington, MD

Macon, Georgia

SUMMARY – Modifications of the technique originally reported in 1946 are presented, which may help in improving the percentage of successful decannulations. The importance of a change in the level of the vocal cord by this procedure is emphasized. The ten cautions to be followed are reviewed in doing this procedure.

An excellent and detailed paper on arytenoidectomy was presented in 1975 by Newman and Work[1] in which successful decannulations were reported in 75% of the 23 cases. In 1953, we reported 521 cases by 90 different surgeons, with a better than 90% success rate of decannulation, when the operations were done on patients with no previous history of attempts at lateralizing surgery.[2]

We will now describe some of the modifications that have been done to the original method, some of which may help raise the success level.[3,4] One step in particular has been completely eliminated – that of placing a traction ligature around the arytenoid cartilage to aid in this dissection. We found this to be a handicap. The placement of the endotracheal tube holds the cartilage rather firmly, making the dissection of the attached muscles possible with the aid of a small suction tube. The tissues are then dissected free of the cartilage with a Freer septum knife (Fig. 1). When all muscular attachments are freed with particular attention to the interarytenoid muscle fibers, the arytenoid is removed by cutting across and leaving a sufficient nubbin of cartilage intimately associated with the vocal process around which the lateralizing sutures can be placed. Then, two single zero atraumatic sutures are used to include the vocal process and pass laterally, so as to include some of the vocalis and thyroarytenoideus muscle, and brought out laterally anterior to the inferior thyroid cornu. The second suture is placed just anterior to the first (Fig. 2).

Before tying either of these sutures around the inferior cornu, their traction ability is observed through the laryngoscope. Once assured of the lateralizing effect, they are tied. A second inspection is then made by the laryngoscope.

We have come to feel that it is a distinct advantage to have some change in the level of the lateralized cord. The tendency for retraction to occur later will still permit adequate airway due to the change of the level of the cord. We have examined many postoperative cases and wondered why there was sufficient airway. This is due to the fact that while the cords may appear in the midline, there is a change in the level permitting adequate airway (Fig. 3).

We also believe that if the cautions previously noted in our summary of 521 cases reported in 1953[2] are carefully observed and followed, the results today should be as good as those reported then by 90 different surgeons.

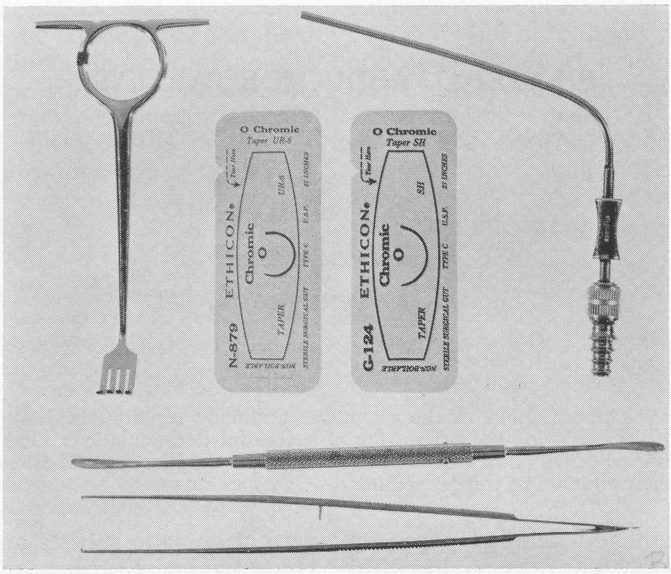

Fig. 1. Instrumentation which facilitates accurate dissection of the arytenoid and placement of the lateralizing suture. Left - Thyroid ala retractor. Right - No. 8 Frazier suction. Center - Lateralizing sutures. Below - Freer septum knife, Cushing forceps with teeth.

These cautions are:

1. In the selection of cases it is well to eliminate those in which there is localized laryngeal tuberculosis or cancer, or in which considerable irradiation has been given to laryngeal tissues. While ankylosis of the arytenoid is relatively rare, it should be thought of and checked as it makes a successful lateralization difficult.

2. A careful medical workup is essential, the serum calcium and phosphorus levels being noted. One should have the patient well stabilized as to the thyroid and parathyroid metabolic balance. In some of the hypoparathyroid patients, tetany and psychotic symptoms develop.

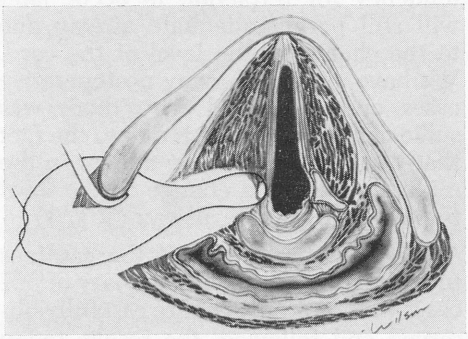

Fig. 2. A coronal section showing passage of the lateralizing suture around the nubbin of vocal process cartilage to include some of the vocalis and thyroarytenoideus muscles.

3. While many of these patients come to the surgeon with tracheotomy tube already placed, if a primary tracheotomy is to be done, it is better that it be done a week or ten days prior to any plastic operation, for the cough which accompanies the placement of a tube during the first week may help to dislodge the lateralized cord or loosen the lateralizing suture.

4. An endotracheal tube of medium size should always be placed down between the cords even though there is a tracheotomy tube in place. This procedure helps to hold the arytenoid in the field and offers some support for its dissection. Be sure to cut all interarytenoid fibers. The surgeon should also be sure to remove the endotracheal tube before placing the lateralizing sutures.

5. Exposure of the arytenoid can often be improved by cutting across the

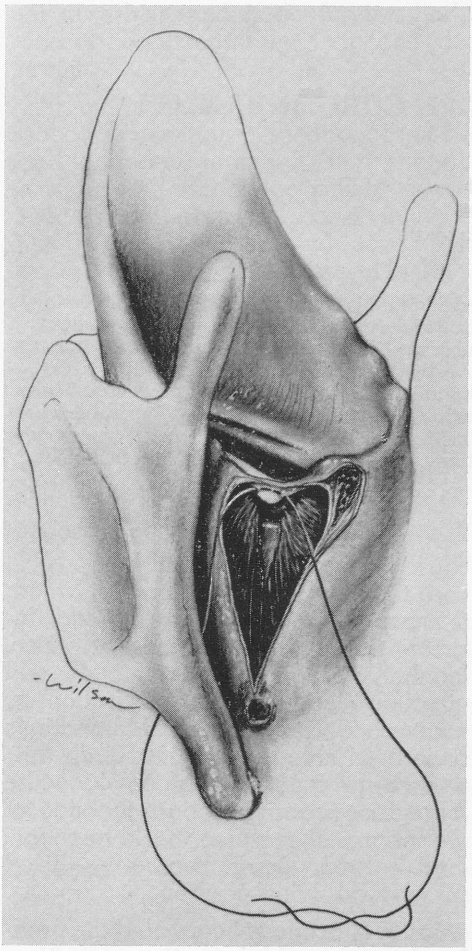

Fig. 3. An artist's concept of completed surgical procedure, showing the change in level on the vocal cord by the suture, as well as correct placement of the suture around the cartilaginous nubbin of the vocal process. The suture is secured around the inferior thyroid cornu.

superior cornu of the thyroid cartilage, thus giving greater mobility to the thyroid ala, permitting better rotation of the cartilage and increasing the size of the operated field.

6. As an extra assurance, two lateralizing sutures should be used. We prefer an atraumatic curved sharp needle with Single zero chromic suture.

7. Inspection should always be made by the laryngoscope after the sutures are placed but before they are anchored. This permits one to know that the suture has a hold on the vocal process and gives some idea as to how much lateralization tension is needed to obtain the desired glottic space. It is well to err by producing a wider space than needed as the tendency is towards later retraction.

8. The surgeon should never fail to leave in a drain for two or three days. This prevents the formation of any organized hematoma.

9. If we must operate on a patient who has had previous lateralization surgery without sufficient airway, it is recommended that one operate on the same side by a laryngofissure approach.[5] It is better not to operate on the other side if an operation can possibly be avoided, in order to preserve the full adductor powers of the other cord. These will be very helpful in stronger voice rehabilitation.

10. Finally, if speech therapy is available, it should be utilized. We have found marked improvement in the voices of all patients who have had the advantage of such training.

REFERENCES

1. Newman MH, Work WP: Arytenoidectomy revisited, presented April 8, 1975 at the national meeting of the Triological Society, Atlanta, Georgia. (To be published in Transactions of Triological, American Laryngological, Rhinological and Otological Society, Inc.)

2. Woodman D: Bilateral abductor paralysis: a survey of 521 cases of arytenoidectomy via the open approach as reported by ninety surgeons. Arch Otolaryngol 58:150-153, 1953

3. Woodman D: A modification of the extralaryngeal approach to arytenoidectomy for bilateral abductor paralysis. Arch Otolaryngol 43:63-65, 1946

4. Woodman D: The open approach to arytenoidectomy for bilateral abductor paralysis, with a report of twenty-three cases. Ann Otol Rhinol Laryngol 57:695, 1948

5. Woodman D: Laryngeal stenosis. Laryngoscope 63:714-720, 1953

REPRINTS—DeGraaf Woodman, MD, P.O. Box 560, Easton, MD 21601 and Claude L. Pennington, Jr., MD, 800 First St., Macon, GA 31201.

EXPERIENCE WITH VOCAL CORD INJECTION

ROBERT B. LEWY, MD

CHICAGO, ILLINOIS

SUMMARY — For 14 years investigators accredited by the FDA have been injecting a Teflon® — glycerin mixture into lateral-lying, paralyzed vocal cords. This paper represents a summary of the work of this author, including successes, failures, and complications; it is the largest reported series, plus that of accredited investigators. The method described is exceptionally useful; it has restored voices, laughter, the ability to strain, and has prevented aspiration. A new surgical technique involving the injection of sterile glycerin into comparable vocal cords in acute new situations is also described. This is done by direct or indirect laryngoscopy, and has been used to eliminate some tracheotomy surgery by virtue of the immediately improved cough effectiveness.

The larynx should be regarded as a physiological valve that functions to make the process of breathing effective and efficient. If the glottis leaks, air cannot be held in the alveoli long enough for a sufficient oxygen interchange.

If one vocal cord is fixed and not in the midline, the voice loses its timbre and becomes hoarse and breathy. The valve closure function of the larynx also permits, by voluntary control, sudden explosive releases which permit the clearing of the lungs, a protection against pneumonia, foreign body, and irritants. Similarly, closure of the larynx acts to permit increased intraabdominal pressure for lifting and for straining. In a corresponding fashion, it functions to permit the greatest of human expressions, laughter.

With appropriate laryngeal function, there is obviously a greater efficiency of oxygen exchange at the alveolar interfaces and, therefore, better oxygenation of all body tissues. This permits more effective cardiac function, relieving the symptoms of the failing heart of angina pectoris (with oxygen deprivation to the myocardium).

Anything, therefore, which would cause a paralyzed lateral-lying vocal cord to be brought to the midline where it can work with its fellow, would improve the glottic functions of voice, laughter, straining ability, cough and offer protection against aspiration as well as better oxygenation. Many things have been noted in the past to do this; twisted positions of the neck, acute laryngitis, pressure against the side of the larynx, all of which would force one cord inward when it is otherwise fixed in a lateral, lying position.

In 1911, Brunings[1] corrected the problem by a peroral laryngoscopy injection, vocal cord augmentation technique. He used paraffn as the implant. His colleague, Killian, criticized the implant material, suggesting the risk of paraffinoma formation.

The method lingered within the scientific memory, but largely disappeared from view. Subsequent reports on occasional cases by various investigators suggested the use of plastics, cartilage, and a variety of other implant materials for this purpose. These usually required a laryngofissure approach to secure them into the vocal cord. If they were

From the Department of Otolaryngology, University of Illinois at the Medical Center. This study was supported by research grant R01 NS 09891-01A1 CMS from the Department of Health, Education and Welfare.

not absorbed, and if no foreign body reaction occurred, they benefited the patient.

Arnold,[2-4] Brunings' student, re-established the injection procedure. First he used ground-up tantalum, then went on to use ground particulate Teflon® mixed with equal parts of glycerin, injected into the vocal cord through a laryngoscope with a needle combined with a pistol type syringe. The process varied a little from Brunings' treatment in that though the technique was similar, the implant substance was different.

An early objective was to find a satisfactory substance which tissues would tolerate and with which there would be a minimal amount of foreign body response or rejection and maximum of safety and healing. This proved to be Teflon®.

Teflon®, itself, is a tradename for a polymer of tetrafluoroethylene. This substance was discovered by serendipity, a fortuitous accident and intelligent observation by a chemist working for the Manhattan Project for the Atomic Energy Commission. It was immediately recognized that the substance was most inert, and therefore it was used in the work on the atomic project.

Prior to its laryngeal application, it was determined that this substance would be well tolerated in human tissue. It had been used in thousands of cases to replace the stapes in a middle ear condition of deafness (otosclerosis). It had been used often as an artery substitute. It was not rejected by the host tissue and caused minimal foreign body response. Arnold[4] earlier, and Kirchner *et al*[5] later, did animal tissue tolerance tests and found minimal reaction.

In 1973, Dedo[6] made a report before the American Laryngological Association of a successful series of 135 patients. Rubin,[7] in 1975, reported an occasional mild misadventure with misplaced Teflon®. He also reported high speed photographic studies of the vocal cord after Teflon® injection.

Our series includes principally Teflon®. Tantalum was used only in the first two cases of the series. Tantalum, incidentally, while found to be effective and nonreactive, was difficult to work with. It was very hard, and therefore its granules tended to freeze the glass syringes that were used at that time. Fresh sterile preparations had to be made for each individual case.

PURPOSE

The purpose of this retrospective study as stated in the request for the grant from the Department of Health, Education and Welfare, which made this study possible, follows:

> "To establish the clinical usefulness, the safety and evaluation of the results of the injection of a Teflon®* glycerin mixture into the lateral, lying paralyzed vocal cord. The objective is to offer substantive proof of both the long term and short term value of the injection of the Teflon®-glycerin mixture."

This investigator has published five articles relating to this problem.[8-12] These articles describe the instruments that have been developed for the procedure and the technique involved. They cover as well the etiology of vocal cord paralysis and the changes in the larynx before and after the procedure. They also describe the absence of migration of the foreign material and suggest the reasons for this.

All observations, across a period of 13 years, indicate a remarkable degree of success; therefore, it was considered highly desirable to evaluate long-term data. If favorable, the procedure could develop from a somewhat experimental technique to that of an accepted procedure for all appropriately trained laryngologists.

The central core of information in this paper is drawn from two sources. The first represents a statistical evaluation of the returns of 144 patients obtained from 218 cases who had Teflon® injection of the vocal cord performed by

---

* Mentor Division, Codman and Shurtleff, Inc., Randolph, MA.

TABLE I

SUMMARY OF RESEARCH DATA
(Author's Series of Patients from 1962-1974)

Male/Female ratio	Males	101
	Females	43
Age at time of injection	Youngest	9
	Oldest	83
	Median	55
Duration of laryngeal dysfunction	Minimum	5 wk
	Maximum	35 yr
	Median	1 yr
Primary presenting complaints	Yes	143
Hoarse weak voice?	No	1
Type of anesthesia	Local	132
	General	3
	Intravenous	4
Immediate results (24-hour impression of voice as determined by author)	Excellent	15
	Good	42
	Fair	1
	Poor	3
Second injection required?	Yes	18
	No	126
Current status	Living	118
	Deceased	26
Causes of death (when known)	Pneumonia	1
	Pulmonary embolus	1
	Stroke	1
	Congestive heart failure	2
	Carcinoma of lung	12
	Carcinoma of esophagus	4

this investigator (Table I). The second includes information from 38 accredited investigators throughout the country who performed 1139 procedures (Table II).

They reported the type of anesthesia used: local, general, or intravenous (combined with local), immediate complications within the first 48 hours, delayed complications, and success rate based upon the improvement of voice quality.

Corresponding studies are drawn from the questionnaires and voice tapes returned by those patients contacted.

The voice tapes form a permanent record, invaluable in evaluating results for legal protection and persuasion. Tapes however, have a disadvantage: they are not objective. Expert judges would vary in the interpretations of changes of voice quality.

The sonagram offers an excellent evaluation from visual record of voice quality. This has been used by von Leden *et al*,[13] as well as this author.[10] The visual record is persuasive and specific. Spectrographic studies obtained from voice tapes showing varied results are illustrated in this paper (Figs. 1-4).

Spectrography has been of value in voice studies and research in the physiology of the cough mechanism. Rontal *et al*[14] refer to three characteristics which can be recognized in the voice spectrograph. Excessive breathiness

TABLE II

QUESTIONNAIRE SUBMITTED TO THE INVESTIGATOR*

Where procedure was performed:		
Private office	0	0.0%
Hospital	1139	100.0%
Type of anesthesia:		
Local anesthesia	835	73.3%
General anesthesia	178	15.6%
Intravenous anesthesia	161	14.1%
Immediate complications:		
Severe edema	13	1.1%
Respiratory obstruction	13	1.1%
Drift or misplacement of Teflon®	22	1.9%
Excessive injection	65	5.7%
Other	17	1.4%
Long-term complications:		
Carcinoma of the vocal cord	1	<0.1%
Granuloma of the vocal cord	4	0.3%
Failure to improve voice	46	4.0%
Other	1	<0.1%
Success rate (indicated by no. of patients)		
Poor voice quality	39	3.4%
Fair voice quality	89	7.8%
Good voice quality	246	21.5%
Excellent voice quality	389	34.1%

* Note that not all questions were answered by the investigators.

(air wastage), aperiodicity of vocal cord movement, and poor formant structure. Our observations agree. We add an illustration of a cough sonagram before and after glycerin was injected to improve cough effectiveness (Figs. 5, 6).

Our data presents:

1. Male/female ratio
2. Age at time of injection
3. Duration of laryngeal dysfunction
4. Primary presenting complaints
5. Type of anesthesia
6. Immediate results (24-hour impression of voice)
7. Second injection required
8. Current status
9. Causes of death (when known)

We, therefore, offer a source of information which can be used as a reference background for the future of many workers in this vineyard, including those who may wish to modify or improve this procedure. It would be of value as a source of information to determine the appropriate expectations within a given case. The information acquired therefore becomes a substitute for experience to a new operator in this field.

RESEARCH DATA

Similarities and differences between the author's series and those of other investigators are of interest. Some can be accounted for by differences in the patient population group. An example is illustrative. In the author's series, 63 cases of a total of 218 were done at a veterans' hospital. This population is predominantly male, more elderly, heavy smoking, and therefore would have an expected higher incidence of carcinoma of the lung. Such indeed is

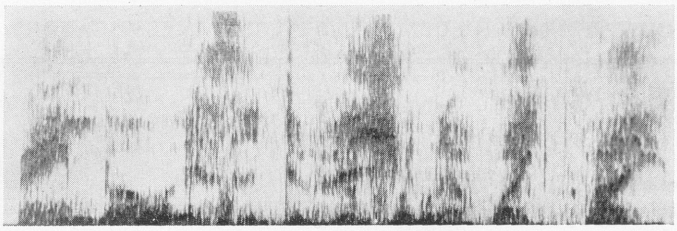

Fig. 1. Sonagram failure – postoperative.



Fig. 2. Sonagram success – postoperative.



Fig. 3. Preoperative recording, wide band "takes the shape of a long, round arch." Note the lack of individual clarity of vibrations, formants and harmonics.



Fig. 4. Postoperative recording, wide band. "Takes the shape of a long, round arch." Note individual clarity of vibrations, formants and harmonics.

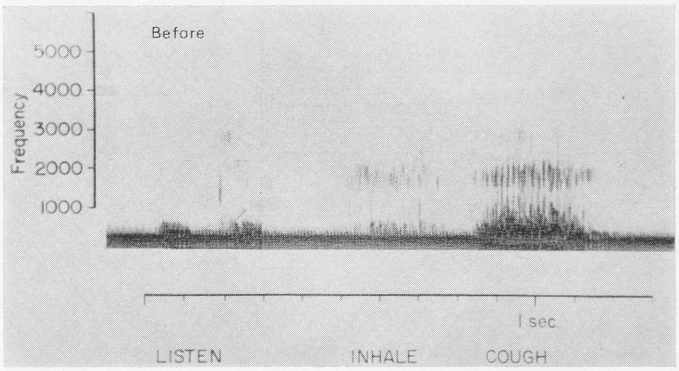

Fig. 5. Time measurement of cough *before* injection.

the case, 16.3% (author's series) as compared with 6.9% (other investigators' series). In idiopathic causes (viral?): the author's series led the list at 16.7%, other workers', 13.6%.

In both series, the commonest causes of the paralysis were the same: idiopathic, carcinoma of the lung, and thyroid surgery, with thyroid surgery as the commonest cause of recurrent laryngeal nerve paralysis in other investigators' series (Table III).

Of considerable interest are newer surgical procedures and diagnostic techniques, represented in incidence of mediastinal surgery, cardiac surgery and pacemaker implant procedures as causes.

The combined statistics disclose a total of 18 cases associated with mediastinal surgery, therefore, this is a standard risk of this procedure. The association with metastasis of carcinoma of the breast should be noted. Also noteworthy is the risk in surgery of diverticulum of the esophagus by transcervical approach (nine cases).

The risk to the recurrent laryngeal nerve (eight cases) in thoracic aortic aneurysm surgery is also very real. Thus, it is evident that some modern surgical procedures can contribute to the problem.

In the author's research, most of the figures speak for themselves and only an occasional comment seems in order. Male/female ratio was greater than two to one. This was perhaps because of higher incidence of carcinoma of the lung in the male. Age at time of injection varied from age 9 to 83. This is a tribute to the easy applicability of the procedure. Maximum duration of paralysis was 35 years, yet with excellent voice result.

The most frequent indication for in-

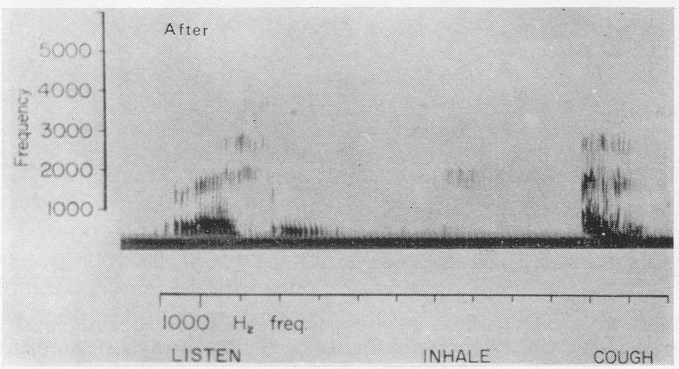

Fig. 6. Time measurement of cough *after* injection.

TABLE III

CAUSES OF VOCAL CORD DYSFUNCTION

Causes	*Author*		*Other Investigators*	
Head:				
Brain injury	4	2.1%	15	1.3%
Vascular accident	2	1.1%	9	0.7%
Neck:				
Thyroid surgery	24	13.0%	254	22.3%
Radical neck surgery	6	3.0%	23	2.0%
Diverticulum of esophagus surgery	2	1.1%	7	0.6%
Bowed cords (congenital or acquired)	8	4.1%	21	1.8%
Cordectomy	12	5.6%	34	1.8%
Gun-shot wound	1	0.5%	11	0.9%
Auto accident	10	5.4%	13	1.1%
Thyroid tumors	2	1.1%	6	0.5%
Neck trauma	4	2.2%	13	1.1%
Deformed cord	4	2.2%	7	0.6%
Carcinoma of esophagus	2	1.1%	7	0.6%
Chemodectoma	4	2.2%	4	0.3%
Carcinoma of vocal cord	4	2.2%	31	2.7%
Neurilemoma	2	1.1%	10	0.8%
Foreign body in larynx	1	0.5%	1	<0.1%
Chest:				
Mediastinal pathology	1	0.5%	6	0.5%
Sarcoidosis	2	1.1%	5	0.4%
Tuberculosis	1	0.5%	8	0.7%
Mediastinal surgery	2	1.1%	16	1.4%
Carcinoma of lung	30	16.3%	79	6.9%
Enlarged heart	2	1.1%	2	0.1%
Aortic aneurysm	3	1.6%	5	0.4%
Carcinoma of breast	4	2.2%	6	0.5%
Pneumonia	2	1.1%	0	0.0%
Lipoma of bronchus	3	1.6%	0	0.0%
Cardiac arrest and surgery	2	1.1%	5	0.4%
Chest crush	2	1.1%	0	0.0%
Pacemaker implant	2	1.1%	0	0.0%
Neurological:				
Poliomyelitis	2	1.1%	2	0.3%
Parkinson's disease	2	1.1%	0	0.0%
Meningitis	1	0.5%	1	<0.1%
Other Causes:				
Idiopathic	31	17.3%	156	13.6%

jection (143 cases to 1) was the hoarse, weak, breathy voice.

The anesthesia used is of note with the exception of one child and two other especially difficult cases. One hundred and thirty-two patients were operated upon, using a topical, local anesthesia, with Innovar®*, deliberately maintaining the patient's consciousness. This proved safe. The phonatory cooperation of the patient was invaluable in controlling the amount of injected

* McNeil Laboratories, Inc., Fort Washington, PA.

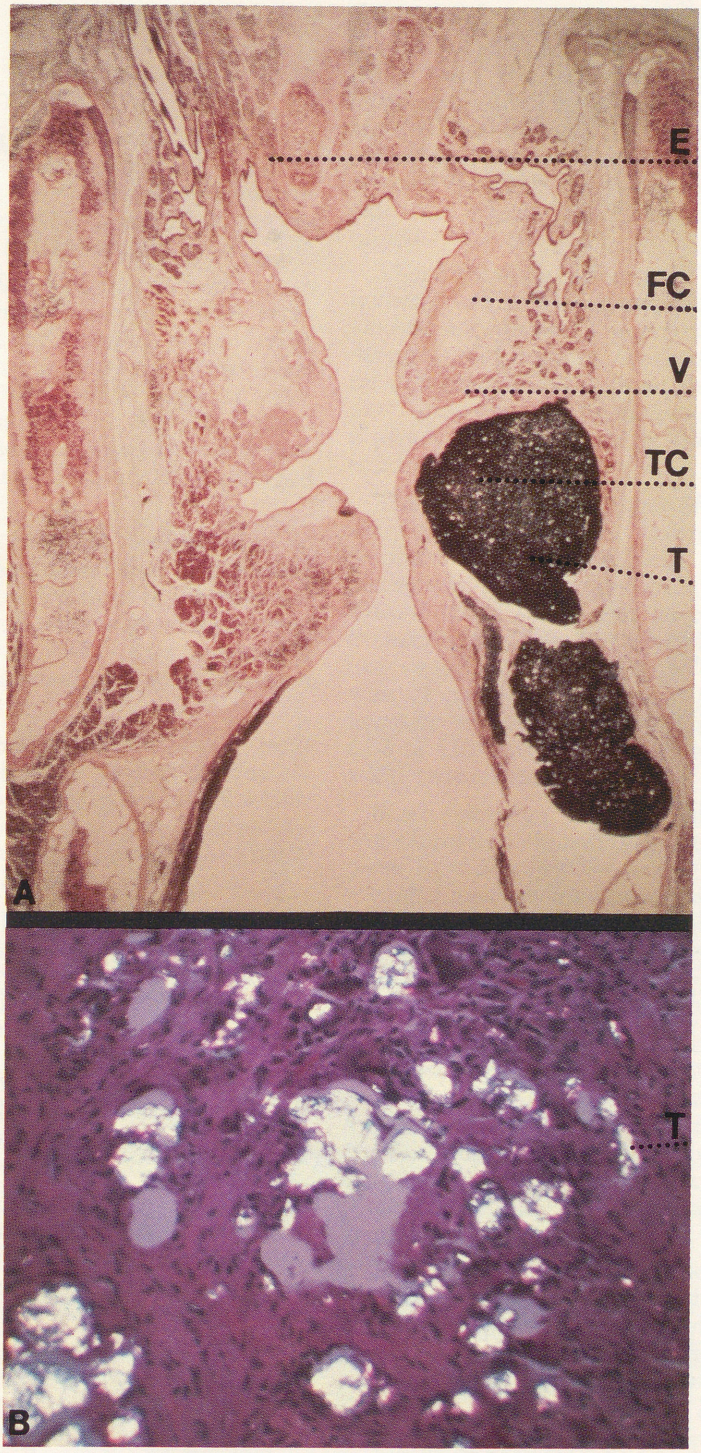

Fig. 7. A) Coronal section of larynx showing Teflon® *in situ*. E - Epiglottis. TC - True cord. FC - False cord. V - Ventricle. T - Teflon®. B) Teflon® granuloma under polarized light; bright particles are Teflon® granules.

substance as well as the location of implant of the material.

Absolute precision was not always possible. This accounted for a series of 18 failures and subsequent second injections. However, a stabilized laryngoscope was used routinely.

All procedures of the author's series and the other investigators' series were performed in the hospital. Considering that direct laryngoscopy was the usual approach (Dedo's work[6] was the principal exception to this), this was logical. It was an essential safety factor in protecting against edema which challenged the airway.

The most frequent complication in the author's series and that of the other investigators was failure to improve the voice. In both, however, the success rate was above 90%. Any reasonable voice improvement was considered a success.

As for immediate results, the 24-hour impression of voice by author was excellent in 15 cases, good in 42 cases, fair in one case and poor in 3 cases. An occasional immediate result was almost perfect and lasted.

Within 24 hours, there was usually edema of the vocal cord, aryepiglottic fold, and the arytenoid on the injected side of the larynx. Therefore, it was impossible to make a prognosis on the basis of the immediate result. It was five days, on the average, before the edema subsided and the expected result could be evaluated. Infrequently, a longer wait was required.

Atrophy of the vocal cord, far-lateral position of the vocal cord, small larynx, marked hypertrophy of the false cords, were contributing factors of that group in which a second injection was required.

It could be fairly stated that the procedure shortened the life of no one and improved the life of more than 90%. It is believed that the patients' lives were lengthened, breathing efficiency was improved, and aspiration was prevented.

One of the excellent aspects of this study was the cooperation received from accredited investigators throughout the United States. There was a high correspondence in the results. It increased by 1139 cases, the number of cases in which information was obtained.

There are some differences. The other investigators had a higher percentage of general anesthesia. There is a frequent disagreement among otolaryngologists on this issue. The opinion depends in part upon the circumstances in which a physician was originally trained and conditioned.

The incidence and types of immediate complications, *i.e.*, severe edema, respiratory obstruction, drift, and misplacement, corresponded in both series. This author's series had no reports of excessive injection, but other investigators reported 65 cases, or 5.7%. There was, of course, a substantial failure to improve voice in 46 cases. This is only 4.0% of 1139 cases, therefore represents a 96% success rate.

Some patients reported that they were forced to change occupations temporarily; a teacher became a librarian, a cantor gave up his singing, a minister gave up his pulpit. All these and others returned to their previous occupations after augmentation therapy.

The most prominent of all symptoms was the inability to talk with ease. This had the corresponding difficulty of inability to be well heard and well understood. Outstanding too, was the inability to strain, inefficiency of breathing, inability to laugh, problems with swallowing food, including aspiration and cough.

The test of voice improvement is the accuracy of pronunciation of phrases and of sentences as a result of the implant. Using these criteria, a large group of tapes were studied by two research associates. Eighty-two before and after injection procedure voice tapes were evaluated. These were classified success, intermediate, or failure. This subjective analysis resulted in a 69% success rate.

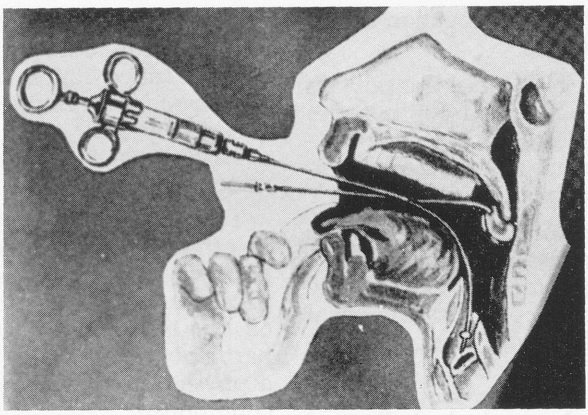

Fig. 8. Sagittal section indicating indirect method glycerin vocal cord injection.

COMPLICATIONS

One of the gratifying elements of this study was the low incidence of complications. The term, complications, requires some definition. We define complications as events that developed which required additional actions.

There were two immediate complications in our own series of 218 cases in which we found excessive swelling requiring a tracheotomy. There were two improper placements of material.

In the reports of the other investigators, there was one of carcinoma of the vocal cord, 22 cases of the Teflon® being misplaced, and 13 cases of respiratory obstruction.

There were no fatalities. The end results were excellent. All other problems were corrected by repeat procedure or by removal of granulations or the Teflon® granuloma palpable under the skin.

Of special note is the one reported carcinoma. It is clearly established that the patient had carcinoma of the larynx. There is substantial doubt that the carcinoma had any relationship to the Teflon®, itself, except that it occurred after the Teflon® injection. The patient was a heavy smoker and contrary to doctor's advice, continued to smoke. The carcinoma was found some distance from the Teflon® location. Progressive histopathologic tissue changes were evident on microscopic study but distant from the location of the implant material.

In another study, published by this author,[11] coronal sections were taken of a larynx in which Teflon® had been implanted 14 months earlier. The larynx was removed postmortem and studied by four pathologists whose opinions agreed. The tissues showed no signs of carcinogenesis. A healed, mild, inflammatory process, a very thin, marginal capsule, and a few giant cells in the substance of the vocalis muscle tissue plus the granular Teflon® could be observed (Fig. 7).

Of all cases reported, therefore, only one could be interpreted as having any neoplastic relationship to the result of the Teflon®.

Work,[15] in a statistical review of paralysis and paresis of the vocal cord, refers to three cases of unusual causation. One of the three cases was pneumonectomy because of a diagnosis of neoplasm of the lung. At the present time, pneumonectomy, partial pneumonectomy, or carcinoma of the lung, have become common causes of recurrent laryngeal nerve paralysis, the first two because of the great progress in thoracic surgery, the last because of tragedies subsequent to tobacco smoking and perhaps environmental pollution.

EXTENSION AND NEW IDEAS

With needle implantation of the Teflon®-glycerin mixture into the vocal

cord as a basis, three additional useful procedures have developed (Fig. 8). Two are mentioned in passing. The first is the closure of the velopalatine gap in which there is air escapage. This is far simpler than pharyngeal surgery and it is equally or more effective.

The second procedure[16] is often helpful in Teflon®injection of the tubotubarious area for the problems associated with chronic, excessive patency of the Eustachian tube opening.

The third procedure reported by Lewy and Mathews[10] is the injection of sterile glycerin of a newly paralyzed vocal cord where the recurrent laryngeal nerve was sacrificed in chest surgery. This has, therefore, reduced the need for a protective cleansing type of tracheotomy. Occasionally, the paralyzed vocal cord has remained in the midline as a result of glycerin injection, and no further Teflon® implantation has been required.

This can be a bedside or a clinic procedure with a curved needle and indirect laryngoscopy. It can, when necessary, be done via the direct laryngoscopy. A three-ringed glass syringe is used, to give a good grip and to avoid glycerin leakage. Because of the lower viscosity of glycerin, the Brunings' syringe (pistol grip) is not desirable.

CONCLUSIONS

1. The combination of particulate Teflon® (tetrafluoroethylene polymer) and glycerin as an augmentation implant seems well established.

2. The procedure is usually not difficult. It is well tolerated by patients of any age, via direct laryngoscopy.

3. There is limited immediate foreign body tissue reaction.

4. Continuing long term residence of the implant *in situ* without cancerogenic responses is the rule.

5. There are minimal manageable complications on immediate or long-term basis.

6. Re-establishment of impaired voice quality and the other physiological functions of the laryngeal valve occurs in a very high percentage of cases.

7. Pulmonary protection from aspiration and improved oxygen utilization is the rule.

8. These statements are supported by statistical analysis of long-term patient reports and the parallel evaluation of results of other investigators.

REFERENCES

1. Brünings W: Über eine neue Behandlungsmethode der Rekurrenslähmung. Verhandl Ver Dtsch Laryngol 18:93-151, 1911

2. Arnold GE: Vocal rehabilitation of paralytic dysphonia. IX Technique of intrachordal injection. Arch Otolaryngol 76:358-368, 1962

3. Arnold GE: Vocal rehabilitation of paralytic dysphonia. X Functional results of intrachordal injection. Arch Otolaryngol 78: 179-186, 1963

4. Arnold GE: Alleviation of aphonia or dysphonia through intrachordal injection of teflon paste. Ann Otol Rhinol Laryngol 72: 384-395, 1963

5. Kirchner FR, Toledo PS, Svoboda DJ: Studies of the larynx after teflon injection. Arch Otolaryngol 83:350-354, 1966

6. Dedo HH, Urrea RD, Lawson L: Intrachordal injection of Teflon® in the treatment of 135 patients with dysphonia. Ann Otol Rhinol Laryngol 82:661-667, 1973

7. Rubin HJ: Misadventures with injectable polytef (teflon). Arch Otolaryngol 101: 114-116, 1975

8. Lewy RB: Glottic rehabilitation with teflon injection — the return of voice, cough and laughter. Acta Otolaryngol (Stockh) 58: 214-220, 1964

9. Lewy RB: Glottic reformation with voice rehabilitation in vocal cord paralysis: the injection of teflon and tantalum. Laryngoscope 73:547-555, 1963

10. Lewy RB, Mathews R: Immediate temporary restoration of glottic valve function. Laryngoscope 75:1348-1351, 1965

11. Lewy RB: Responses of laryngeal tissue to granular teflon in situ. Arch Otolaryngol 83:355-359, 1966

12. Lewy RB: Tracheotomy avoidance: glycerine vocal cord injection. Arch Otolaryngol 92:502-504, 1970

13. von Leden H, Yanagihara N, Werner-Kukuk E: Teflon in unilateral vocal cord paralysis: preoperative and postoperative function studies. Arch Otolaryngol 85:666-674, 1967

14. Rontal E, Rontal M, Rolnick MI: The use of spectrograms in the evaluation of vocal cord injection. Laryngoscope 85:47-56, 1975

15. Work WP: Paralysis and paresis of the vocal cords. Arch Otolaryngol 34:267-280, 1941

16. Pulec JL: Abnormally patent eustachian tubes: treatment with injection of polytetrafluoroethylene (teflon) paste. Laryngoscope 77:1543-1554, 1967

———

ACKNOWLEDGMENT—The author would like to thank Dr. A. J. Derbyshire, Gayle Burgess, Lee Hamilton, Charles Gerlach and Audio-visual Services, Department of Otolaryngology for their assistance in various aspects of this project.

REPRINTS—Robert B. Lewy, MD, 25 East Washington St., Chicago, IL 60602.

RECURRENT LARYNGEAL NERVE SECTION FOR SPASTIC DYSPHONIA

HERBERT H. DEDO, MD

SAN FRANCISCO, CALIFORNIA

SUMMARY – Spastic dysphonia is a severe vocal disability in which a person speaks with excessively adducted vocal cords. The resulting weak phonation sounds tight, as if he were being strangled, and has also been described as laryngeal stutter. It is often accompanied by face and neck grimaces. In the past it has been regarded as psychoneurotic in origin and treated with speech therapy and psychotherapy with disappointing results. Because of laboratory and clinical observation that recurrent nerve paralysis retracts the involved vocal cord from the midline, it was proposed that deliberate section of the recurrent nerve would improve the vocal quality of patients with spastic dysphonia. In 34 patients the recurrent nerve was sectioned after Xylocaine® temporary paralysis showed significant improvement in vocal quality. Several patients have been advised against this operation because of the type of voice they developed with one vocal cord temporarily paralyzed. With nerve section plus postoperative speech therapy, approximately half of the patients have returned close to a "normal" but soft phonatory voice. The rest had varying degrees of improvement, but all, so far, have been pleased with the improvement in ease and quality of phonation and reduction or elimination of face and neck grimaces. Two men have a breathy component in their phonatory voices, and one woman has variable pitch.

The first description of a spastic form of psychogenic hoarseness was made by Traube[1] in 1871. Four years later the Viennese laryngologist, Schnitzler,[2] provided a detailed description of spastic dysphonia and coined the diagnostic term. Berendes[3] defined spastic dysphonia as a disorder of phonation which is characterized by a strained, creaking, and choked vocal attack, a tense and squeezed voice sound which is accompanied by extreme tension of the entire phonatory system. He noted that the stressed vowels may be broken into two portions and that the disorder disturbs primarily the communicative function of speech with variations in intensity. Often the patient can speak to himself, whisper, laugh, achieve a falsetto singing tone and sometimes phonate isolated vowels or whole sentences with a normal phonatory voice. During indirect laryngoscopy, the structure of the larynx and vocal cords appears normal. While silent respiration is normal, the frustrated vocal effort causes severe obstruction to expiration of air from the lungs causing aching fatigue of the upper anterior chest muscles.

Spastic dysphonia has been repeatedly described as "stuttering with vocal cords."[3] It is often accompanied by associated spastic or grimacing type contractions of the neck and facial muscles, causing complete closing of the eyes at times. In some people there is superimposed stuttering of the lips and tongue and palate as an extreme form of an already serious disability. It ordinarily starts in people over the age of 40 years, but one patient in our series had the onset in her 20s.

Virtually all of the contributors to this subject in the last hundred years have stated that spastic dysphonia is an expression of psychoneurosis. According to the early psychiatric teaching, such conditions were regarded as hysterical.[1] In a most exhaustive review by Ber-

From the Department of Otolaryngology, University of California, San Francisco, San Francisco, California.

endes in 1939, spastic dysphonia was regarded as a typical neurosis without hysterical traits.[3] Robe *et al*[4] and Aronson *et al*[5,6] were among the exceptional authors who suggested that spastic dysphonia is due to some organic pathology of the nervous system, rather than hysteria or psychogenic disorder or reaction to stress. These investigators also were among the few who admitted the singular ineffectiveness of voice therapy and psychotherapy in spastic dysphonia.

Multiple treatments have been tried without achieving consistent permanent cure of vocal spasticity. Brodnitz comments that psychotherapy has not been too helpful.[7] It may help the patient to gain better insight into his psychological background but he still will exhibit a marked degree of dysphonia; only one of his patients improved "significantly." He adds that it is one of the characteristics of the disorder that many of the patients react violently to the suggestion of psychiatric counseling. One only has to give such advice to lose the patient immediately. Brodnitz further states that voice training alone has proved to be of only very limited value. Cooper reported that of 41 patients, 22 entered speech therapy and only 6 of them completed therapy with results described as excellent — one; good — three; and fair — one.[8] Even this much improvement required a minimum of 1½ years. Boone comments that with speech therapy "progress has been erratic and limited, with no one patient experiencing a permanent restoration of normal voice. The problem of spastic dysphonia still remains both a diagnostic and etiologic unknown, which, of course, makes the development of an effective therapeutic approach impossible."[9]

In the spring of 1975 I was asked to see M.Y. in consultation. I feel that because of the special nature of her problem, including the tenacity with which she continued to seek help after 17 years of disappointment, and her willingness to knowingly undergo experimental procedures, she and her husband deserve credit for participating in the discoveries which were made. She had treatment by more than 29 doctors, including laryngologists, speech therapists, psychiatrists, and hypnotists in the United States. She continued to be disabled by severe dysphonia which was accompanied by marked associated grimaces of the face and neck during her attempts to talk. Speech therapists confirmed that their modality could not offer her the chance to return to normal. Because of the disruption of her life caused by her being a vocal cripple, there was considerable encouragement to develop a new approach to help her. I proposed that we again try temporary topical and local paralysis of the internal branch of the superior laryngeal nerve which had earlier given her only partial, temporary relief and if this failed, to test the effects of paralysis of the recurrent nerve. Diligent review of the literature did not provide any support for such a proposal. In fact, the only report of surgery for this disorder was that of Rethi,[10] in which he reported some success in one patient with dividing the stylopharyngeus muscle, which is considerably different than deliberately paralyzing the recurrent laryngeal nerve (RLN).

RATIONALE

Laryngeal research in dogs and humans with electromyography and still and motion pictures has confirmed that paralysis of one recurrent laryngeal nerve in the normal individual not only paralyzes the vocal cord but sets it in the paramedian position so that the normal (unparalyzed) cord fails to reach it as firmly as usual, causing a breathy but often phonatory soft voice.[11] It has long been recognized that the voice can sound nearly normal, although soft in some persons, if the normal vocal cord can compensate by crossing the midline to reach a paralyzed vocal cord. In patients with Teflon®* injections of paralyzed vocal cords, many had a brief period of spas-

* Polytef paste for injection; Mentor Division, Codman & Shurtleff, Inc., Randolph, MA.

tic or tight phonation for a few moments after the injection before the mobile vocal cord quit compensating across the midline. It seemed possible that if a recurrent laryngeal nerve were paralyzed in a patient with spastic dysphonia, the other vocal cord might prove to be "precompensated" so that its excessively strong adduction would carry it across the midline to the deliberately paralyzed cord, giving a relatively normal phonation. After describing the above hypothesis, it was proposed to M.Y. that one recurrent laryngeal nerve be paralyzed temporarily with lidocaine since paralysis of the superior laryngeal nerve had temporarily improved her voice by only 10% or 15%. She and her husband agreed, and to our amazement and delight, once the recurrent nerve had been thoroughly paralyzed by the injection of 1% lidocaine, she was able to talk with a phonatory voice without vocal spasticity. Furthermore, as soon as she found she had a consistent phonatory sound, she was able to stop the neck and facial grimaces and special respiratory efforts. Although her voice at this point had a raspy or husky sound, Dr. Lucie Lawson, speech therapist, was rapidly able to help her raise the pitch and bring the sound "up in the front of her mouth," largely clearing the huskiness. Unfortunately, as soon as the lidocaine wore off, the spasticity of voice and face and neck returned. When this had been repeated four more times with identical results, she and her husband agreed to surgical section of the recurrent nerve to try to make the vocal improvement permanent, even though there was no guarantee what would happen to her voice or psyche. Although she did not appear hysterical or psychoneurotic when her vocal cord was temporarily paralyzed and she was able to phonate properly, there was some trepidation about whether she would develop hysterical phenomena such as paralysis or numbness of a limb, since the literature had stressed the psychiatric etiology of this disease for over a hundred years. However, when the right recurrent nerve was sectioned on September 9, 1975, she had an uneventful convalescence. Her speech and facial movements were dramatically better on awakening from the anesthetic. With speech therapy she regained an essentially normal voice within weeks, and she was able to stop the associated movements of her face or neck. She has now even resumed her political, radio, and television career after an 18-year hiatus.

TREATMENT TECHNIQUE

Diagnosis. There are several different types of spastic dysphonic speech. The basic type has a constant, very tight, hoarse, soft, barely phonatory sound which may vary slightly with fatigue and stress. Several have resorted to a stage whisper voice, inspiratory speech, or even the small buzzer* used by laryngectomees to talk, and when requested to phonate they can only produce a soft, harsh, tight sound low in the back of the throat. A second type has frequent breaks in the tight sound caused by momentary vocal cord abductions which produce a quavering, spastic dysphonic sound low in the back of the throat. Considerable variation in the spasticity can occur in one patient. Some are able to achieve a clear, normal phonatory voice with occasional single words, phrases or sentences. In one patient, within one sentence the voice went from a whisper through clear phonatory, to spastic phonatory, back through clear phonatory to a whisper. (Her spastic dysphonia had been present less than two years, and in the majority of patients who had had the disorder longer than this, the voice did not have such remarkable variability.) There is often throat clearing or groaning phonations made between words in an attempt to obtain a clear phonatory sound. Many of these patients can laugh and sing a falsetto musical note or phonate some vowels such as "e" and "o" with a clear phonatory sound. There is considerable variation between patients on the amount of associated grimacing

* Western Electric buzzer available through local telephone company.

movements of the face and neck and oral tics which they have, similar to that of a severe oral stutterer. Indirect laryngoscopy ordinarily shows that there are no lesions on the vocal cords. Naturally it is essential to rule out benign or malignant tumors of the vocal cords and unilateral or bilateral voice cord paralysis by indirect laryngoscopy before proceeding.

Two patients were noted to have mobile vocal cords which were bowed during phonation but created a spastic type of phonation. Although the initial reaction was that Teflon® injection was indicated as with previous patients with bowed mobile vocal cords and breathy voices,[12] it was found that paralysis of one recurrent laryngeal nerve with lidocaine dramatically improved the voice by clearing the spasticity. However, this made the voice worse in one patient with bowed mobile cords during phonation and a breathy voice. Therefore, it appears that patients with spastic dysphonia *and* bowed mobile vocal cords during phonation actually have adopted the technique of cricothyroid relaxation in their attempts to achieve a nonspastic voice. They can benefit by recurrent nerve section if indicated by lidocaine test paralysis. Teflon® injection of *one* vocal cord should be reserved for bowed mobile vocal cord with *breathy* phonation.[12]

Preoperative Evaluation. The voice is tape-recorded and evaluated by a speech therapist and the surgeon. Temporary paralysis is then achieved by injecting 1% lidocaine, 3-6 ml adjacent to the cricothyroid joint. Paralysis is then confirmed after two to four minutes by repeat indirect laryngoscopy. The risks of this lidocaine, of course, are explained to the patient. Although they are unlikely, they include the possibility of severing the nerve with the needle, entering the carotid artery or jugular vein or the trachea. The temporary paralysis wears off in 7 to 30 minutes, sometimes before the patient can break through the old speech therapy relaxation training and hear and feel the improvement.

The patient must be prepared to accept this voice as the minimum achievable voice after surgery in case speech therapy does not achieve maximum potential improvement. As soon as the recurrent nerve has been temporarily paralyzed, the voice is tape-recorded again and the speech therapist, the surgeon and the patient decide whether enough improvement has been obtained to justify permanent section of the recurrent laryngeal nerve. Ordinarily these procedures are performed on the right side because the laryngeal nerves and vocal cords are symmetrical and it is technically preferable on the right. Several patients have been refused recurrent nerve section because they or the surgeon were not satisfied they had achieved the typical and proper change in their voice. The voice change during lidocaine paralysis differs somewhat from that obtained after permanent recurrent nerve paralysis. This is because the adjacent external branch of the superior laryngeal nerve and therefore the right cricothyroid muscle is often paralyzed by the lidocaine but not the surgery. (This is shown by posterior rotation of the larynx to the left.) They often have a temporary Horner's syndrome and a "lump" sensation in the throat during lidocaine paralysis which disconcerts them during the usual 10 to 15 minutes they have to determine whether the recurrent laryngeal nerve paralysis should be made permanent. Thus, the temporary lidocaine paralysis only approximates the vocal improvement which can be obtained by recurrent nerve section. However, even though this has usually been exceeded by surgical division of one recurrent nerve, especially when supplemented by speech therapy, it is emphasized that the voice, while likely to be improved, will not necessarily be completely normal after permanent section.

Surgical Technique. Under general anesthesia a collar incision is made one finger-breadth below the cricoid cartilage. Dissection is carried down to the anterior surface of the trachea and around its right side to the tracheoesophageal groove. The recurrent nerve

is identified ordinarily at the level of the inferior pole of the right thyroid gland 1 cm lateral to the trachea. It is sometimes necessary for adequate exposure to divide the isthmus and resect the upper portion of the thyroid gland off of the trachea with resultant extra bleeding. Direct laryngoscopy is then performed so that the right vocal cord can be observed while an assistant crushes the presumed recurrent nerve with a hemostat. If the vocal cord contracts abruptly at the instant of crushing, the structure is presumed to be the whole recurrent nerve and is ligated with a 2-0 silk ligature. A 1 cm segment is then removed adjacent to the inferior pole of the thyroid gland about 3 - 4 cm below the cricoid. Care needs to be taken to avoid injury to the trachea, thyroid gland, parathyroid glands, carotid artery, cervical esophagus, cervical sympathetics and, especially to the recurrent nerve on the other side. (It is possible to dissect through the party wall between the trachea and esophagus and reach the left recurrent laryngeal nerve.) It is *not* necessary or desirable to section both recurrent nerves. Care must also be taken to avoid injury to the innominate artery and vein which are nearby in the upper mediastinum in some patients.

The incision is closed with gut subcutaneous sutures and Steri-strips®* to the skin with a drain in place. A pressure dressing is installed. When the endotracheal tube is removed and the patient awakens, it is usually possible to hear marked improvement in the voice, even in the recovery room. One exception was a patient in whom a small amount of arytenoid and vocal cord edema resulted from the intubation or direct laryngoscopy so that an injection of cortisone was necessary, and improvement was delayed for several days.

RESULTS

We have now temporarily paralyzed the right recurrent laryngeal nerve in 41 patients and have surgically sectioned 34 recurrent laryngeal nerves. All of these patients have been pleased with the improvement (loss of spasticity) in their voices and decrease or clearance of associated tics and grimaces. However, several of the patients have spoken with a mild residual hoarseness (huskiness or raspiness or a soft low pitch), and one has had some intermittent mild spastic phonation and pitch variability after surgery. Two have breathy but phonatory voices when tired or they have to push their voices in a noisy environment. Although clarity of tone, good pitch control and elimination of associated face, neck and chest movements (grimaces, tics, oral stuttering, and chest muscle fatigue) have been achieved by some patients spontaneously after surgery, most have benefited by speech therapy varying from a few days to several weeks. So far there has been no reversion to the severe preoperative spastic dysphonia and no hysterical conversions. Three patients had been receiving psychotherapy, including one who had a complete nervous breakdown five months before surgery and two who had attempted suicide. They are reported by their psychiatrists as doing much better because the disability of spastic dysphonia had been causing or increasing their emotional disturbances, rather than the reverse situation which has generally been the one described in the literature.

DISCUSSION

Etiology. If the etiology for a disorder is unknown, it is ordinarily blamed on psychoneurotic reaction to stress, or on viruses, or on allergy. In the past, most authors stated that spastic dysphonia was caused by emotional stress.[13] This just increased the patient's problems and resentments because psychotherapy has been singularly ineffective in treating this disorder. Psychotherapy should be used, if necessary, for other emotional problems which may be present, but not in an attempt to treat the spastic dysphonic since it has not been useful in the past. It just adds to these patients' problems by suggesting they are benefiting from their terrible speech dis-

* 3M, Minnesota Mining and Manufacturing Co., St. Paul, MN.

ability and they can talk normally if they just will try.

The fanciful psychodynamics in the psychiatric reports sent with these patients is incredible. It is interesting that when Aronson[5,6] used the Minnesota Multiphasic Personality Test (MMPT) to evaluate patients with spastic dysphonia, he found a lower incidence of repressed anger and compulsive personality traits than were present in the general medical population at Mayo Clinic. This whole concept that spastic dysphonia was due to hysteria or psychoneurosis apparently was based on the clinical observation that even though these patients could get a clear phonatory sound with singing and laughing, they spoke with spastic dysphonia when required to talk "with emotional content."[1] Furthermore, the spasticity was variable and, in some, increased with stress or fatigue or seemed to start originally after some special stress. Therefore, it was assumed that this was a conscious attempt to penalize family members or coworkers and that all that was necessary was to trick or analyze the patient out of the problem. This was reinforced by occasional observations that spastic dysphonic patients could speak with a clear, phonatory voice while awakening from general anesthesia or if they were plied with enough alcohol to make them drunk. None of these are useful observations since it is not possible to remain in a drunken or drugged state from alcohol or general anesthetic agents and to continue to function with full effectiveness. In fact, in discussions with psychiatrists who were seeing three of these patients, they readily agreed that the spastic dysphonia had increased the emotional problems rather than the emotional problems being the cause of the spastic dysphonia.

Only a few authors have suggested that spastic dysphonia was caused by organic disorder of the neuromuscular system. Moore and his coworkers[4] found that 10 of 14 patients with spastic dysphonia had abnormal electroencephalograms. Aronson *et al*[5,6] then exhaustively reviewed 31 spastic dysphonia patients seen at Mayo Clinic. Of 27 patients given neurologic examinations, 20 had one or more neurologic signs, including tremor, hyperreflexia, reduced alternate motion rate and faciolingual asymmetries. (Only one of our patients has had organic neurologic defects elsewhere, and her spinocerebellar degeneration was far advanced before spastic dysphonia appeared.) These signs occurred with greater frequency than would be expected in normal population. They hypothesized that spastic dysphonia has a neurologic substrate and may be related to the essential tremor syndrome. Of the 29 patients given psychiatric interviews, 18 were judged to have some emotional problems, and 11 did not. Although as a group they gave the impression of being compulsive, of overcontrolling their anger, and of being quite unaggressive verbally, it is suggested that these traits are not exclusively characteristic of spastic dysphonia. It should be remembered that these traits are present in a vast number of people who show no signs of spastic dysphonia.

I would now like to suggest that this disease is caused by a disturbance in the proprioceptive control of the vocal cords. Specifically, it is proposed that neurotropic viral infection damages the a & c fibers either peripherally or in the central nervous system while sparing the larger diameter motor nerve fibers to the intrinsic laryngeal muscles. Neurotropic viral injury of the large motor nerve fibers is invoked for many cases of paralysis of the facial nerve causing Bell's palsy. Viral damage of the large motor nerve fibers unilaterally or bilaterally is given as the present best explanation of spontaneous recurrent laryngeal nerve paralysis. Proprioceptive control of the vocal cord muscles is poorly understood because even with electroneurophysiology techniques now available, it is difficult to study in the normal human and dog. Furthermore, there is no good animal model for spastic dysphonia. It is interesting that over half of these patients had a clinically apparent viral illness of the respiratory

or gastrointestinal system at, or shortly before, the onset of spastic dysphonia. In fact, it was easier to elicit this than a history of specific stress at or about the time of onset. One patient had poliomyelitis some time before, and one had a temporary partial paralysis of the right facial nerve which started at the same time as the spastic dysphonia. An advantage of using this hypothesis is that there is no specific treatment for viral infection so the patient's money is not wasted on psychotherapy.

It is striking that these patients do not appear hysterical or emotionally disturbed after the recurrent laryngeal nerve has been cut and they are able to resume reasonably normal phonation. In every patient a control injection to test the Psychoneurotic Etiology Hypothesis was performed by injecting Xylocaine®* subcutaneously and beside the cricoid cartilage or for two to four minutes after placing it on the nerve sheath. There was no change in the voice even though the patient was unable to see precisely where the Xylocaine® was being placed. The spasticity left the voice only when the recurrent laryngeal nerve became fully paralyzed by the lidocaine, as confirmed by indirect laryngoscopy. Furthermore, the spasticity returned as soon as the lidocaine began to wear off, in spite of the fact that these patients did not know exactly how long the lidocaine effect would last. If their spastic dysphonia were on a voluntary or hysterical basis, at least some of them would have cleared with the combination of suggestion, and an injection of a powerful medicine in the neck or the improvement should have lasted after the lidocaine wore off. Only one patient has had an hysterical manifestation elsewhere in the body (a brief glove anesthesia of one hand one month before surgery). None have had postoperative hysterical conversion reactions or increase in emotional problems. In fact, there has been a striking decrease in manifestation of emotional disorders after their voices have returned to normal or to even near-normal status. Intensive speech therapy during temporary lidocaine paralysis of the vocal cord did not achieve permanent resolution of the spastic dysphonia in a single patient. Associated movements of the face, neck and throat, clearing of the throat, whisper voice, bowed mobile vocal cords during phonation, and even use of a W.E. Buzzer to achieve phonation were all caused by conscious attempts to achieve phonatory sound. When consistent, reliable glottic phonation became possible and apparent to these patients after lidocaine injections and later when recurrent laryngeal nerve section had repositioned the cord, these associated problems usually cleared rapidly. If the patient had really been trying to use the disease for psychological or social reasons, these voluntary manifestations would be expected to continue or to increase. Usually after section of the recurrent laryngeal nerve, the pitch is low "in the back of the throat," showing they were trying to relax the vocal cords before the paralysis.

There is no reliable clinical or experimental evidence for classifying spastic dysphonia as a psychoneurotic or hysterical disease. In fact, it just causes time and money to be wasted on psychotherapy, at least for the vocal disorder itself, and it increases the patient's guilt and emotional stress. Proprioceptive disturbance by neurotropic viral infection has as solid a theoretical and clinical basis as psychoneurosis and causes less expense (for ineffective psychotherapy) and less social opprobrium.

Treatment. Psychotherapy, allergy treatment, hypnosis, acupuncture, special diets, vitamins, cortisone and tranquilizers had all been tried repeatedly on these patients and have no place in the treatment of spastic dysphonia. Speech therapy before recurrent laryngeal nerve section had only helped *some* patients *partially* and then it took 1½ years or more at considerable cost and constant deliberate effort which always continued to be necessary.

---

* Astra Pharmaceutical Products, Inc., Worcester, MA.

The speech therapists who have seen this group of patients have now agreed that speech therapy is not useful or effective if spastic dysphonia has been present three months or more. In fact, we are still looking for an established spastic dysphonic who has been returned to a normal voice by speech therapy. Therefore, patients in whom spastic dysphonia has been present more than three months are advised to have the lidocaine paralysis test of the RLN, and if there is the typical improvement in the voice, a RLN section. The advantage of this approach is that the RLN can be paralyzed temporarily with lidocaine before the surgery so the patient and family can determine whether they wish to make it permanent. This kind of inexpensive diagnostic test is not possible with any of the other modalities, such as speech therapy alone, psychotherapy, hypnosis, acupuncture, special diets, tranquilizers, allergy treatment and cortisone shots. The surgery is a low risk, general anesthetic procedure and is rapidly effective in one or two hours, instead of one or more years. Postoperative speech therapy is provided when the patient is not able to spontaneously return to a relatively normal, clear, soft phonatory voice. The chest muscle fatigue (from pushing against the tightly closed glottis during phonation) is eliminated. Most importantly, these persons are able to stop being vocal cripples and even to forget about their voices and just proceed to talk. It is not necessary for them to make an enormous effort to learn to speak in an unnatural way. In fact, the biggest problem in resuming "normal" phonatory speech so far has been in the patients who have had the most effective preoperative speech therapy or who have developed a lot of associated movements in their desperate attempt to speak. Even the worst of these, however, were dramatically better within minutes after the lidocaine injection and within an hour after surgery (*i.e.*, as soon as they were awake enough to talk in the recovery room).

Theoretically, a vocal cord could also be repositioned slightly away from the midline and preserve the recurrent nerve by placing a silk suture between the arytenoid and the thyroid ala. Since there is a limit to how far the mobile cord can adduct, this would tie it back so the mobile one could just reach it at the end of its excursion, preventing the overtight closure and vocal spasticity. However, it is more difficult to reposition a cord in the ideal paramedian position with a tie-back suture than by sectioning a recurrent nerve. Furthermore, the suture would soon cut through the cartilage because of the strong persistent adduction, which is not present in the patients who require Woodman operations for bilateral recurrent nerve paralysis. Speech therapy has then improved the voice further when necessary. It is designed to get the patient to do three things:

1. Raise the pitch from the back of the throat ideally to a clear phonatory level (which may well not equal the prespastic dysphonic "normal"). This pitch adjustment is sometimes necessary to minimize or eliminate diplophonia, which is present in some of these patients postoperatively because of the slightly different vocal cord tension on the two sides. (The diplophonia can be minimized or eliminated by matching the mobile vocal cord frequency to that of the paralyzed vocal cord.)

2. Resume normal volume and pressure of air flow through the larynx.

3. Eliminate the associated face and neck movements and throat clearing, which all the patients so far have been able to do rapidly once they were able to achieve reliable, easy laryngeal phonation.

If the vocal cord were to atrophy and move too far from the midline, Teflon® injection could be used to reposition it. If the cord did not end up far enough lateral from the midline to prevent the other vocal cord from reaching it too tightly, a direct laryngoscopy and excision of some of the free edge of the vocal cord could be performed. So far neither of these secondary procedures has been necessary.

The main problem now is getting used to the idea of sectioning a recurrent nerve for a disease widely considered to be psychoneurotic. However, severing the facial nerve for blepharospasm must have been just as shocking initially.

Many of these people have had difficulty retaining jobs and friends and some have become recluses. The satisfying part of this surgical procedure, which has been as dramatic as with many patients after repair of severe hearing loss by stapedectomy, is seeing these patients resume normal, happy lives. Just as stapedectomy can provide a dramatic improvement in hearing and be successful without return to "normal" (0 dB), recurrent nerve section can dramatically improve a spastic dysphonic voice even when it does not return completely to "normal." However, deliberate surgical section to achieve permanent unilateral recurrent nerve paralysis is not yet standard treatment for even as disabling a disease as spastic dysphonia; it should not be done without careful preparation and evaluation.

REFERENCES

1. Traube, cited by Arnold GE: Spastic dysphonia: I. Changing interpretations of a persistent affliction. Logos 2:3-14, 1959

2. Schnitzler, cited by Arnold GE: Spastic dysphonia: I. Changing interpretations of a persistent affliction. Logos 2:3-14, 1959

3. Berendes, cited by Arnold GE: Spastic dysphonia: I. Changing interpretations of a persistent affliction. Logos 2.3-14, 1959

4. Robe E, Brumlik J, Moore P: A study of spastic dysphonia. Neurologic and electroencephalographic abnormalities. Laryngoscope 79:219-245, 1960

5. Aronson AW, Brown JR, Litin EM, *et al*: Spastic dysphonia. I. Voice, neurologic, and psychiatric aspects. J Speech Hear Dis 33:203-218, 1968

6. Aronson AW, Brown JR, Litin EM, *et al*: Spastic dysphonia. II. Comparison with essential (voice) tremor and other neurologic and psychogenic dysphonias. J Speech Hear Dis 33:219-231, 1968

7. Brodnitz FS: Spastic dysphonia. Ann Otol Rhinol Laryngol 85:210-214, 1976

8. Cooper M: *Modern Techniques of Vocal Rehabilitation*, ed 2. Springfield, Ill., Charles C. Thomas, 1974

9. Boone DR: *The Voice and Voice Therapy*. Englewood Cliffs, N.J., Prentice-Hall, Inc., 1971

10. Rethi A: Role des stylopharyngealen muskelsystems im Krankheitsbild der Taschenbandstimme und der dysphonia spastica. Folia Phoniatr (Basel) 4:201-216, 1952

11. Dedo HH: The paralyzed larynx: An electromyographic study in dogs and humans. Laryngoscope 80:1455-1517, 1970

12. Dedo HH, Urrea RD, Lawson L: Intracordal injection of Teflon® in the treatment of 135 patients with dysphonia. Ann Otol Rhinol Laryngol 82:661-667, 1973

13. Bloch P: Neuro-psychiatric aspects of spastic dysphonia. Folia Phoniatr (Basel) 17: 301-364, 1965

ACKNOWLEDGMENTS—The author wishes to express appreciation to Francis A Sooy, MD, Joseph H. Ogura, MD, Roger Boles, MD, and the Nationl Institutes of Health for providing the training, support, and milieu which made this work possible.

REPRINTS—Herbert H. Dedo, MD, Department of Otolaryngology, University of California, 400 Parnassus Ave., San Francisco, CA 94143.

DISCUSSION

WALTER P. WORK, MD (Ann Arbor, Michigan): I wish to limit discussion to the paper on arytenoidectomy. Last year we presented our experience at the University of Michigan before the Triological Society. There were 75% successful results as to establishing an airway and preserving voice.

In the previous years, the Thornell procedure has been done with success.

Ideally for rehabilitation in patients with bilateral abductor paralysis, one should strive to obtain recurrent nerve function. Recurrent nerve suture or graft or nerve substitution does not produce satisfactory results in animals or humans.

The substitution for nerve repair is the widening of the airway mechanically. In this day and age, I think a word of caution is apropos concerning "Informed Consent" for the patient. The patient must be informed that the operation may fail as to airway and voice. The choice must be left to the patient; the use of Teflon®, *etc.*

I remember the first muscle transplant in 1937, or thereabout, published in the AMA Journal, where Dr. King, a general surgeon in Seattle, tried to establish function of the paralyzed side of the larynx by transferring the omohyoid muscle belly.

Next was the submucous cordectomy by the French. Too much airway was obtained in this instance. The voice was entirely lost.

I cannot sit down unitl I give Dr. Clerf credit. Early in the 1940s, before this society he discussed his operation of moving the arytenoid laterally. Later, the work of Dr. Woodman and Dr. Kelly came along. I want to conclude by saying nerve muscle transplant is now back with us. The operation is being introduced again by Dr. Harvey Tucker.

Surgeons are still plagued with bilateral abductor paralysis in patients undergoing thyroid surgery. The number of cases has lessened. A certain number of these patients have permanent palsies and need rehabilitation through surgical methods.

Again, Drs. Woodman and Pennington, I would like to thank you for reopening this subject. It is a pleasure to be here and discuss it.

KENNETH D. DEVINE, MD (Rochester, Minnesota): I am here as a substitute for Dr. Bill Thornell, who was unable to come. He described his technique for transoral removal of the arytenoid cartilage using suspension laryngoscopy in 1948 in the *Archives of Otolaryngology.* The title of his paper was, "Intra-Laryngeal Approach for Arytenoidectomy in Bilateral Abductor Vocal Cord Paralysis." The technique which he described in 1948 has become known as the Thornell arytenoidectomy.

In 1972, we published in the *Laryngoscope* the long-term results of Thornell arytenoidectomy in 147 patients with bilateral abductor vocal cord paralysis. The average length of follow-up was 11 years. Bilateral paralysis occurred after thyroidectomy in the majority of patients and the classic history was one of immediate aphonia following thyroidectomy (with recovery of the voice) and ensuing dyspnea six months postoperatively. However, in this series there were 13 patients who had a tracheotomy immediately postoperatively.

Twenty-eight patients had their air hunger for 20 to 30 years and four went more than 45 years before they submitted to an arytenoidectomy.

One hundred forty-seven patients had Thornell arytenoidectomy as their initial procedure. A satisfactory result was obtained in 120 (or 82%). In 21 patients the glottic opening was not enlarged and 16 of these had a contralateral arytenoidectomy and results were satisfactory in nine of these.

Therefore, out of 147 patients followed on an average of 11 years, 135 had a satisfactory result (or 92%). The voice was considered satisfactory in all but six patients (4%) and not one of them had aphonia. The chief complaint in these six people was inadequate volume.

I think that we will continue to use the Thornell arytenoidectomy because of these figures. I would suggest to you that if you do an arytenoidectomy you suggest to the patient that he or she stop smoking because we have had several of them come back later with myxomatous polypoid thickening of the opposite cord or both cords, thus reducing the airway in sufficient amount to require removal to improve the airway.

JOHN F. DALY, MD (New York, New York): I would like to add an interesting anecdote to the history of the arytenoidectomy operation. My association with Dr. Joseph D. Kelly in New York brought this problem very acutely to us and it was shortly after Dr. King of Seattle, whom Dr. Work has mentioned, published his article in the JAMA.

Dr. Kelly had a patient referred to him who was about to sue following a thyroidectomy, because of a bilateral abductor paralysis. The general surgeon asked Dr. Kelly to help this patient. The publication of Dr. King's article in the JAMA in 1939 opened up a new posterior approach to the larynx. It was interesting that laryngologists traditionally used the anterior approach, opening the larynx in the midline and widening it by one method or another. But Dr. King, being a general surgeon, was not restrained by his training; he employed the orthopedic principle of transposition of a nonparalyzed muscle for a paralyzed one. Looking for a viable muscle to take over the function of the abductor, he found the omohyoid, an accessory muscle of respiration.

Dr. Kelly thought that the transposition of the omohyoid had little to do with the success of the procedures that Dr. King reported. Dr. Kelly's thesis was that removal of the arytenoid alone was responsible for improvement in the airway.

Dr. Kelly wrote to Dr. King and Dr. King very obligingly sent a complete report of all of his cases and in one patient he explained that in placing the suture around the arytenoid, the cartilage split. The cartilage was removed; yet, the patient had a good result. And Joe Kelly said, "This is it." Dr. Kelly made the approach more direct to the arytenoid by creating a window in the thyroid cartilage. It was the first fenestration operation, I guess, that was done by a laryngologist. He also gave the name to the operation, "arytenoidectomy."

I can recall too, the great skepticism that greeted this operation, but "nothing succeeds like success!"

This era of a mechanical approach to this problem is closing. Dr. Millesi of Austria has done some interesting microsurgery of the peripheral nerves. Perhaps his technique will supply the answer to reconstructing the recurrent laryngeal nerve.

PAUL H. HOLINGER, MD (Chicago, Illinois): We spend all of our lives trying to correct paralysis of the recurrent laryngeal nerve and now we find that by *paralyzing* the nerve, patients who are in great distress obtain relief!

This is a milestone. We would be very remiss in our recognition of this if we did not commend Dr. Dedo for a very marvelous presentation and addition to the concept of the patients suffering with spastic dysphonia. The distress and the relief that was obtained was shown by the pictures and by the movie. We have heard one of the most original contributions to our specialty that has been given in a long time.

I wonder, Dr. Dedo, whether it is possible to consider another part of the situation of the patient with spastic dysphonia: namely, the complete fixation of the diaphragm and the effort to force air through the spastic larynx with the accessory muscles of respiration. Would not a phrenic nerve paralysis, preferably on the right side which is rather an innocuous procedure, be of help to these patients by eliminating the complete fixation of the diaphragm?

But, I certainly do not believe one could get the same improvement that you demonstrated that followed the sectioning of the recurrent laryngeal nerve.

The phrenic operation is relatively simple. It has been done many, many hundreds of times in patients with tuberculosis. Since the spastic diaphragm is part of the picture I wonder whether this has been considered in the management of these patients?

I certainly want to congratulate Dr. Dedo in contributing something original in our field of laryngology.

ALDEN H. MILLER, MD (Los Angeles, California): First of all, I congratulate Dr. Dedo on this exhilarating, fascinating but still to me a little mystifying paper that he has just given us. The reason I rise is not because I think I have the answer to what causes spastic dysphonia, or that I have known what to do about it. Rather, I rise to tell you, that I saw this patient about 13 years ago, and to me she had the absolutely typical picture of spasmodic dysphonia. She had the voice that Dr. Dedo has described. Second, she had a larynx that was completely normal in appearance and in movement. The diagnosis was spasmodic dysphonia. Speech therapy and the hint to her husband of psychotherapy were advised; but she had already had both of these.

I did not see her again until just a few months ago, some six months postoperative, and maybe you would be interested as I was to see what her larynx looked like.

The right true cord was completely paralyzed, just at the midline or just barely off it. There was a less than 1 mm chink just for a millimeter or two in front of, and a millimeter or two in back of the vocal process. Neither cord was in spasm. The left cord, for some reason or other, looked a tiny bit thin but was not flaccid. Her voice was completely normal as you heard it, the low pitched woman's voice (of those who have a low pitched voice). She could count beautifully in falsetto; she stated that her voice as a teenager was always considered to be low pitched. There were a few tiny movements of the arytenoids while she was speaking. She had excellent range, pitch and color to her voice. She sang, "Home On The Range," in almost a contralto; clear and musical and pleasant. So to me there is just no argument that this is a fabulous result in this patient, in clearing up what was a most distressing condition.

Now, what could some guesses be?

I talked with my research speech pathologist and I asked, "With your sonograms, with your tracings, is there somthing characteristic about the voice of the spastic dysphonia?"

And, he said, "Oh, yes! We describe it as — there seems to be a bit of a 'quiver'!"

Of course, he may have been making that fit his theory that the vocal cords are in tension; that they are in too much spasm; are too tight; that they are "quivering."

Therefore, on the basis of what Dr. Dedo has shown us, if they are "quivering," I have an hypotheis. There were a few times that I thought a quiver seemed a little consistent in some of my patients but after coming together the cords would then fall apart a bit posteriorly.

I could never really convince myself that I was seeing much spasm. But if there is, certainly Dr. Dedo's operation stops the spasm and the quivering of the cord on which he has cut the nerve. Second, his explanation of the overcompensating of the other cord might be stopping the quivering in that cord, so I would guess just trying to use what I have heard that maybe this is what happened. I surely wish to thank Dr. Dedo for giving me something I hope to be able to offer these patients.

DE GRAAF WOODMAN, MD (closing): There are several ways of skinning this cat and the results depend on in whose hands and how deft they are in doing a job.

I agree with Dr. Work's suggestion that further work should be done along the lines of nerve implantation. I think this is a very worthwhile laboratory procedure.

I do question, however, how practical this would be when one is handicapped by stepping into a scarred neck attendant with muscle atrophy. I doubt the success rate would be any better than that already attained by the present method.

ROBERT B. LEWY, MD (closing): I have but two things to add.

One is, that it should be mentioned that the work which we summarized was done on government grant.

The second was my hope and my expectation even before we started this project, that it would prove that Teflon® vocal cord injection had reached maturity. Today this went unchallenged.

HERBERT H. DEDO, MD (closing): I appreciate the discussants' comments.

In answer to Dr. Holinger's question about the phrenic nerve. I have not found it to be necessary, but one of the intriguing things about this procedure has been that when these patients can start getting a consistent and reliable sound from the larynx, even if it is vocal fry in the back of the throat, they stop the spasms of the forehead, the grimacing of the eyes, the stuttering of the tongue and lips and the palate, the spasms of the neck muscles, the spasms of the chest muscles and the diaphragm.

It is too good to be true and all I can say is you have to see one of these patients to believe it. As you know, it is quite variable. Some of them have only plain spastic dysphonia, but the people with these other things (most of the patients) say that one of the things they appreciate most about it is they are able to talk without this terrible tight feeling in the chest. After they have talked for about an hour they have extreme fatigue and aching of the chest muscles and the diaphragm. Therefore, so far we have not found it necessary.

We have had a few of them who required a little speech therapy to get the breathing straightened out because they have breathed abnormally for so long.

That lady in the movie had had the speech problem for 21 years and had lost her job with the telephone company as a result.

And, Dr. Alden Miller's comments: I have noticed the same thing, these larynges appear the same. The letters that have come from the laryngologists have said the same thing. They have looked in the larynx and have seen no visible pathology. I would like to compliment them; I feel they are more honest than the psychiatrists who send you reports that would make you blush about all the real and imagined psychopathology that is present. It is tragic, really, but they do look like they are trying to promote this or to gain some benefit from misusing their voice like this, but when they are able to talk normally, they do not look abnormal anymore.

There are several varieties of spastic dysphonia. Several were talking in just a stage whisper because that is the only consistent sound they can get. Two have arrived with Western Electric buzzers because their speech was so bad they were unintelligible otherwise.

Quaver has been present in maybe 15 or 20% where they speak like — (demonstrating the voice) — and I think what is happening is they are putting the cords together and get the terrible sound, then they pull them apart a little bit and release it and they overshoot and then they get a break in the voice and the cords. You can see them actually grossly coming together and going apart about once or twice a second.

FIBER COMPONENTS OF THE RECURRENT LARYNGEAL NERVE IN THE CAT

RICHARD R. GACEK, MD

MICHAEL J. LYON, MA

WORCESTER, MASSACHUSETTS

SUMMARY – Experimental neuroanatomical methods were employed in 21 adult cats to determine 1) the number and size of myelinated motor and sensory fibers in the recurrent laryngeal nerve (RLN), and 2) the fiber components originating in the nucleus ambiguus (NA) and retrofacial nucleus (RFN) of the brain stem. Intracranial transection of the X and XI cranial nerves and selective destruction of the NA or RFN were the experimental lesions inflicted in order to obtain the following results. About 55% (312) of the right RLN (565 fibers) is composed of myelinated motor nerve fibers which measure 4 μ - 9 μ in diameter. Nine percent come from the RFN and are smaller (4-6 μ) than the 46% which emanate from the NA and measure 6-9 μ in diameter. The remaining 45% of the RLN is made up of sensory neurons which can be divided into three groups. 1)The largest numerical group (32%) is very small in caliber (1-3 μ) and supplies extralaryngeal regions (trachea, esophagus). 2) The intermediate size fiber group (4-9 μ) comprises 11% of the RLN and probably supplies the subglottic mucosa. 3) The smallest group (2%) of sensory fibers is the largest in diameter (10-15 μ) and may represent either the innervation of muscle spindles or afferents from the superior laryngeal nerve coursing down into the chest.

A need for morphological data on the fiber components of the recurrent laryngeal nerve (RLN) is indicated by the recent physiological[1] and anatomical[2] demonstrations of different types of motor units supplying intrinsic laryngeal muscles in the cat. Accurate description of the size and number of fibers associated with the functions served by the RLN is necessary before the physiology of laryngeal function can be fully understood. The ultimate purpose of such knowledge is its application in the understanding and treatment of disorders affecting the human larynx.

The present study represents an experimental anatomical demonstration of the motor and sensory fiber components of the cat's RLN. Major contributions of this report are: 1) the identification of the nerve fibers emanating from each of two brain stem nuclei (retrofacial nucleus [RFN] and nucleus ambiguus [NA]) responsible for laryngeal motor innervation, and 2) division of the myelinated fibers in the RLN into three categories according to diameter and functional components.

METHODS AND MATERIALS

Twenty-one adult cats were used in this study. Adult cats rather than kittens were chosen because the myelinization of nerve fibers is more complete in adult animals. This difference permits more accurate data on fiber sizes and also allows for a clear distinction between myelinated and unmyelinated fibers. Furthermore, since adult animals are the choice of many neurophysiological investigations, this anatomical information can be more directly related to physiological data. These animals were anesthetized with intraperitoneal sodium pentobarbital* (30 mg per kg of body weight) and the back of the head and neck were shaved and prepared for surgery. After a posterior fossa craniotomy was carried out, the cerebellopontine angle and the brain stem on the right side was carefully exposed. This

---

* Pentosol® 65 mg/ml. Burns-Biotec Lab., Inc., Oakland, CA.

From the Department of Otolaryngology, University of Massachusetts Medical School, Worcester, Massachusetts. This study was supported by Grant No. NS08451 NINCS. NIH, Bethesda, MD.

exposure permitted a view of the cochlear nucleus and the IX, X, and XI nerve rootlets.

Two types of intracranial lesions were carried out. 1) Transection of the rootlets of the X and XI nerves between the brain stem and the base of the skull. This lesion was produced in order to determine the total number of motor and sensory fibers in the RLN. Since the ganglion cells of the sensory neurons are located extracranially, this intracranial transection of the nerve rootlets would cause wallerian degeneration of only the motor neurons whose cell bodies are located within the brain stem. 2) The second type of lesion was electrolytic destruction of each of the two brain stem nuclei (retrofacial nucleus and nucleus ambiguus) concerned with laryngeal motor innervation. The RFN was approached by inserting an electrode through the dorsal surface of the restiform body in the caudal brain stem. After the electrode was inserted in a vertical direction to a predetermined depth, a current of 20 ma was applied for five seconds. Location of the electrode within the retrofacial nucleus was monitored by the observation of facial muscle twitching from stimulation of the nearby facial nucleus. In order to produce a lesion in the NA, the electrode was moved progressively more caudally from the facial nucleus to a premeasured location and 20-50 ma of current were applied for ten seconds. The electrode was again moved progressively in a caudal direction and the current injury applied two additional times in order to destroy this extensive nucleus. The posterior cervical muscles and the skin incision were approximated with interrupted sutures. The postoperative course was usually benign in these animals; those animals with intracranial transection of the X and XI nerves and those with NA destruction were treated prophylactically with tracheostomy because of the possibility of airway obstruction from the complete unilateral vocal cord paralysis.

All the animals were allowed to survive a two-week period in order to allow sufficient time for complete wallerian degeneration of the transected axons. This interval was short enough to minimize the possibility of retrograde degeneration in sensory neurons in the RLN. Animals were sacrificed by first producing anesthesia with intraperitoneal sodium pentobarbital. Intracardiac perfusion was used to first infuse Ringer's solution, then the fixative solution. In those animals where the preparation of the RLN was to be carried out with the Sudan Black B stain, 10% buffered formalin was used as the fixative. Where electron microscopic evaluation was to be carried out on the RLN, the animals were perfused with a 2% glutaraldehyde and 2.5% paraformaldehyde solution as the fixative.

After a 24-hour period of immersion in the respective fixative solution, the brain stems were carefully removed from the cranial cavity and both RLN's were carefully dissected out under the operating microscope.* They were then placed separately in labeled bottles containing fixative. A 2 cm length of the RLN just proximal to its entrance inferior to the thyroid lamina was removed in each instance.

The RLN's were prepared in two ways: 1) Those nerves fixed in 10% formalin were stained by immersing them in 70% alcohol solution of Sudan Black B and then embedded in 15% gelatin solution. After this embedding medium had hardened in the refrigerator, frozen sections were cut at 10 μ. These sections were collected and mounted in glycerine on slides. Photographs were taken of the nerves and enlarged to a known magnification before constructing a montage about one-third of a meter in diameter. The fibers were then carefully counted and measured according to a previously determined scale which depended on the magnification used in the photography. 2) Those nerves which were immersed in the glutaraldehyde-paraformaldehyde fixative were stained with osmium and embedded in Epon 812®** for electron microscopic sectioning. Thin sections were cut on an ultra microtome*** and prepared for study under the electron microscope. Photographs were taken of the entire nerve cross-section through the transmission electron microscope and enlarged to a magnification of about 4,500 X. A montage was then constructed of these component photographs which usually extended about two-thirds of a meter in diameter. The nerve fibers were measured according to a predetermined scale and counted. Both myelinated and unmyelinated fibers were counted in nerves prepared in this manner.

The brain stems of all animals in which electrolytic lesions had been produced were blocked so that sections could be taken of the caudal brain stem. Horizontal sections were cut at 25 μ thickness and collected serially. These were stained with 1% cresyl violet to display neurons and mounted on slides. The brain stem sections were carefully evaluated under the light microscope and were reconstructed after projecting outline drawings of the lesions in these sections.

Those animals in which the electrolytic lesion intended for the RFN was not located in the nucleus were used as control animals. In almost all of these animals the lesion was placed in the facial nerve nucleus or its perimeter.

RESULTS

Control Nerves. A careful survey of the cat's RLN revealed that three major

---

* Carl Zeiss, Inc., N.Y., NY.
** Shell Chemical Co., N.Y., NY.
*** Sorvall MT2-B, Ivan Sorvall, Inc., Newtown, CT.

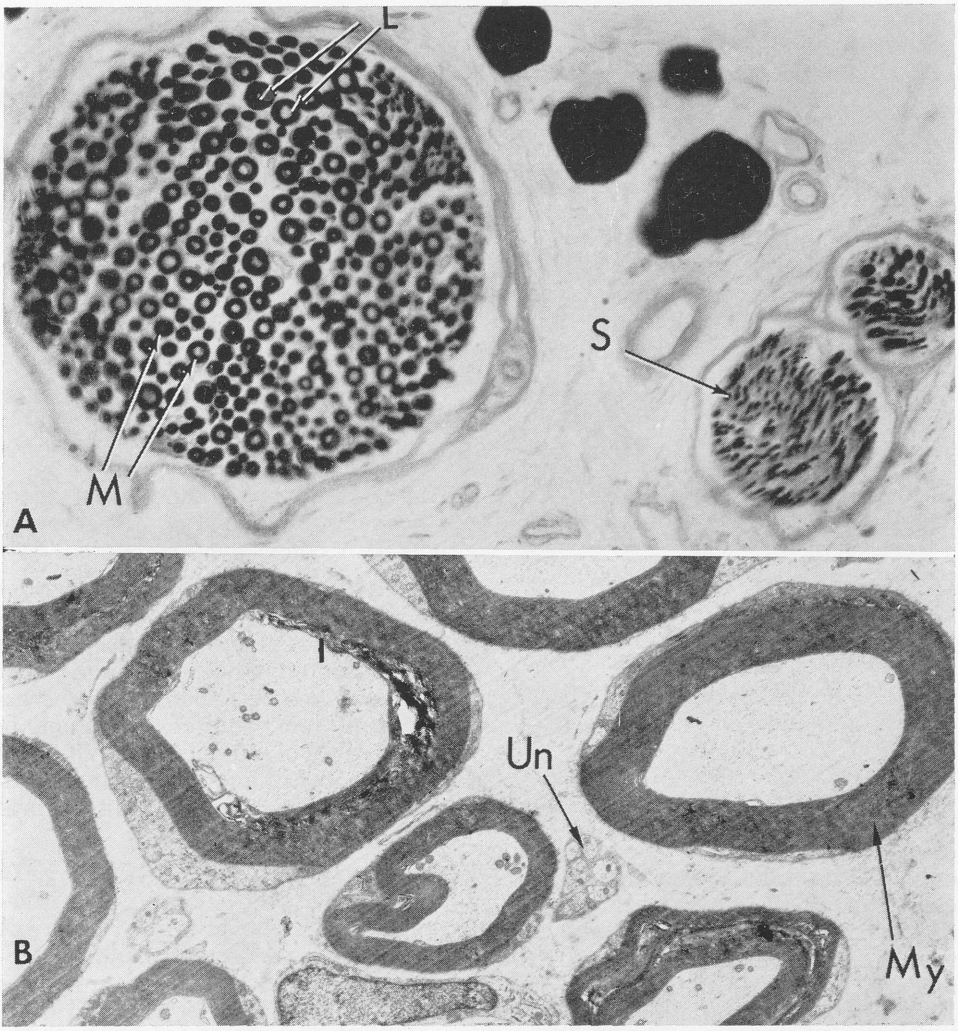

Fig. 1. A) Normal cat RLN stained with Sudan Black demonstrating small (S), medium (M), and large (L) myelinated fibers (X110). B) Electron micrograph of normal cat RLN showing myelinated (My) and unmyelinated fibers (Un). I - Irregularity due to fixation. (X5780).

groups of myelinated fiber sizes could be distinguished (Fig. 1). There are numerous small fibers 3.0 μ or less in diameter which either are grouped together within the main trunk of the RLN or comprise a separate small nerve bundle which accompanies the RLN. A second category of very large fibers measuring 10 μ - 15 μ in diameter which are few in number, are found scattered throughout the RLN. The third and most numerous group of fibers have diameters intermediate in size measuring 4 - 9 μ. Subsequent experimental animals indicated that all myelinated motor (efferent) fibers are contained in this intermediate fiber group.

Table I summarizes the results of nerve fiber counts and measurements in the right and left RLN of animals used as controls. This group of ten animals represents those in which attempted electrolytic destruction of the RFN was unsuccessful and resulted in a lesion which did not involve this nucleus.

Although in two animals, 7 and 8,

TABLE I

ANALYSIS OF MYELINATED FIBERS IN THE NORMAL RLN

Animal No.		Total Fibers	Small (1-3 μ)	Medium (4-9 μ)	Large (10-15 μ)
1	R	422	110	304	8
	L	539	199	318	22
2	R	568	165	386	17
	L	512	215	276	21
3	R	584	208	363	13
	L	421	75	339	7
4	R	470	128	329	13
	L	447	101	334	12
5	R	773	338	427	8
	L	671	244	418	9
6*	R	487	120	361	6
	L	460	118	335	7
7	R	728	349	357	22
	L	—	—	—	—
8*	R	580	167	407	6
	L	—	—	—	—
9	R	528	184	338	6
	L	499	176	314	9
10*	R	514	176	327	11
	L	306	15	287	4
Avg. N=10	R	565	195	360	11
N= 8	L	482	143	330	11

* Electron microscope evaluation

only the right RLN was counted because the left RLN was lost in preparation or removal, the nerves of both sides were analyzed in the remaining eight animals. In seven of these, the right RLN contained more fibers than the left RLN. The average total fiber count in ten right RLNs was 565 compared to 482 fibers in eight left RLNs. The number of left RLN fibers was not greatly changed when ten additional normal left RLNs from the experimental animals were also included in the averaging; the overall average fiber count in left RLNs from both the control and experimental animals was 499. Since all the experimental lesions were inflicted on the right side, separate analysis of the right and left RLN was important in order to determine a valid standard for numerical comparison of results in experimental animals. Therefore, the significantly higher figures of the right RLN were chosen as the normal standard against which the experimental right RLN counts were compared.

TABLE II

MYELINATED FIBER COUNTS IN RLN FOLLOWING TRANSECTION OF RIGHT X AND XI CRANIAL NERVES

Animal No.		Total Fibers	Small (1-3 μ)	Medium (4-9 μ)	Large (10-15 μ)
11	R	385	319	47	19
	L	448	137	293	18
12	R	218	184	25	9
	L	475	112	335	28
13*	R	426	346	74	6
	L	405	89	311	5
Avg.	R	342	283	48	11

* Electron microscope evaluation

Analysis of the three fiber categories indicated considerable numerical variation in the small and large fiber groups while the intermediate (medium) fiber group was relatively constant. The exceptionally low count of small fibers in the left RLN of animals 3 and 10 could be due to loss of an unrecognized small accessory nerve bundle during removal of the RLN.

Transection of X and XI Nerves. In three animals, 11, 12 and 13, intracranial transection of cranial nerves X and XI was performed, causing wallerian degeneration of all motor axons in the RLN (Fig. 2). Table II summarizes the results in these animals. Loss of fibers occurred in only the medium fiber group, demonstrating that the small and large fiber groups contain sensory nerve fibers only. However, 47, 25, and 74 fibers in the medium sized group were not degenerated in these three animals, indicating that a small portion of this group contains sensory neurons. Subtraction of the average number of intact fibers (48) in the medium category following this lesion from those in the control right RLN (360), indicates that there are about 312 motor nerve fibers in the right RLN.

In two animals which are not in-

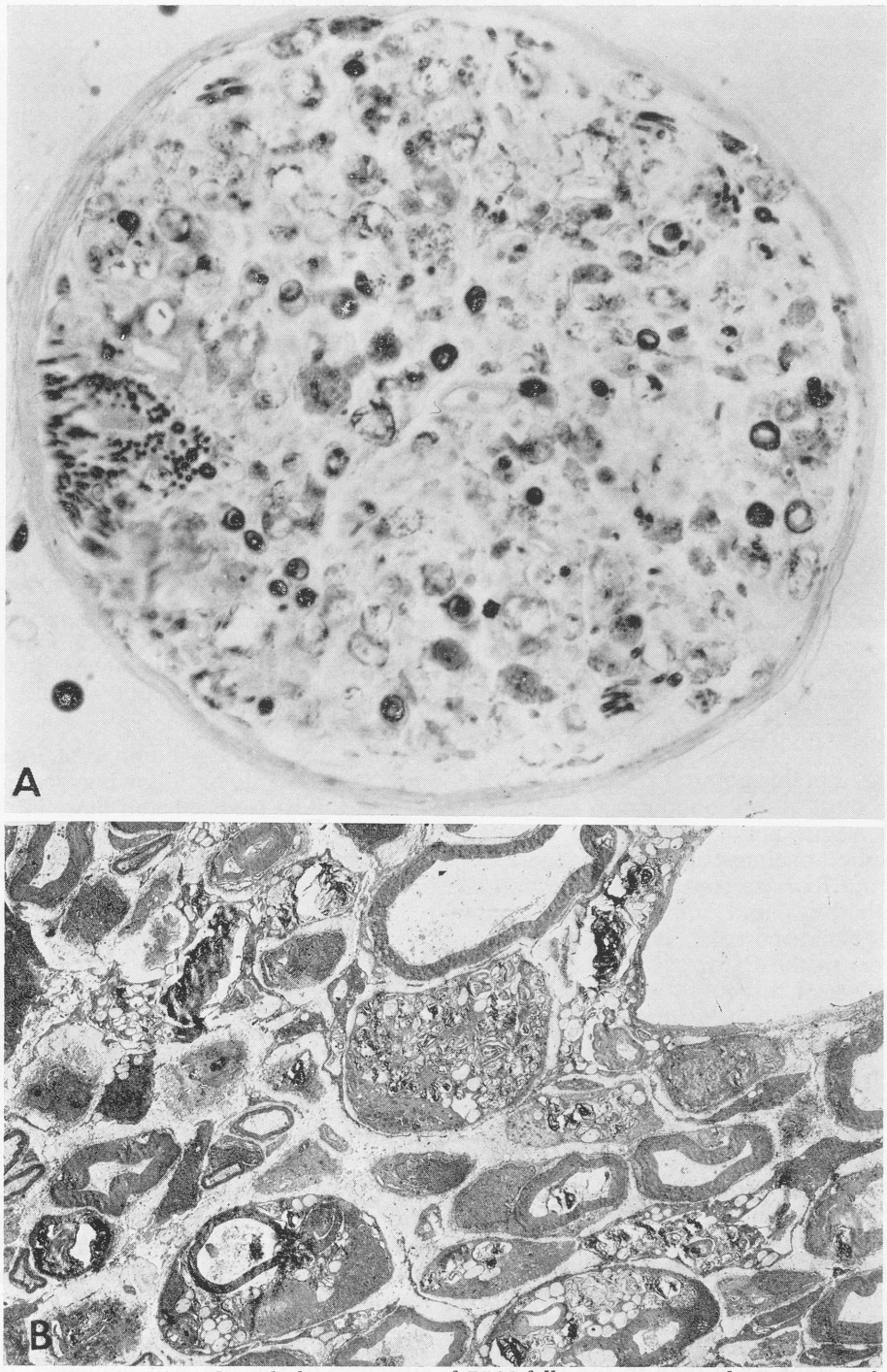

Fig. 2. A) Sudan Black preparation of RLN following intracranial transection of nerves X and XI in 12. Some large, medium, and small fibers remain intact although most of the nerve is degenerated. A separate bundle of intact small fibers has been omitted from the photograph. (X110) B) Electron micrograph of RLN from 13 also shows intact large, medium, and small fibers and various stages in degeneration of motor fibers in the nerve (X2030).

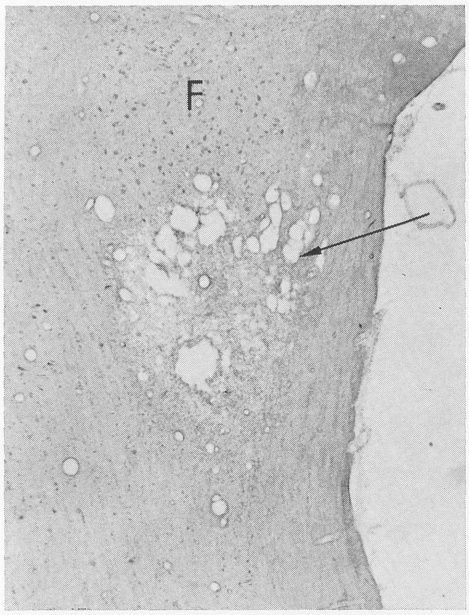

Fig.3. Horizontal brain stem section from animal 16 illustrating the selective destruction (arrow) of the RFN just caudal to the facial nerve nucleus (F) (X6).

cluded in this report, transection of only the most rostral one or two rootlets of the vagus nerve was carried out and resulted in almost as much degeneration in the RLN as complete transection of both the X and XI nerves. This indicates that most, if not all of the motor fibers to the RLN, travel in the rostral rootlets of the vagus nerve and the XI nerve contributes little to this fiber component.

Selective Destruction of RFN. In six animals successful selective destruction of only the RFN was accomplished (Fig. 3). The RLNs in three of these were evaluated by light microscopy while those in the other three were examined under the electron microscope. Although the decrease of fibers in the nerves evaluated by light microscopy was not great (Fig. 4A), a consistent pattern of fewer medium sized fibers in the right RLN than in the left RLN was seen (Table III). This suggestion of fiber loss was strengthened by the electron microscopical observation of numerous degenerating myelinated fibers measuring 4 - 6 μ in diameter in the right RLN of animals 16, 18 and 19 (Fig. 4B).

TABLE III

MYELINATED FIBER COUNTS IN RLN FOLLOWING DESTRUCTION OF RIGHT RETROFACIAL NUCLEUS

Animal No.		*Total Fibers*	*Small (1-3 μ)*	*Medium (4-9 μ)*	*Large (10-15 μ)*
14	R	469	172	269	28
	L	438	116	314	8
15	R	576	236	317	23
	L	652	255	390	7
16*	R	549	180	350	19
	L	679	293	369	17
17	R	549	256	282	11
	L	—	—	—	—
18*	R	438	156	271	11
	L	481	221	252	8
19*	R	526	153	367	6
	L	392	41	336	15
Avg.	R	518	193	309	16

* Electron microscope evaluation

Since the average number of intact medium sized fibers following destruction of the RFN is 309, and those in the control right RLN is 360, the estimate of fibers arising from the RFN is 51 fibers.

Partial Destruction of NA. In two animals partial destruction of the NA was produced, one of these also extending to involve the RFN (Table IV). In four other animals an attempt was made to completely destroy the NA with extensive electrolytic means. However, these animals failed to survive, all of them expiring within the first 24 to 48 hours. Since no evidence of intracranial bleeding or respiratory tract obstruction was present, it is probable that extensive destruction in this part of the brain stem also injures the nearby respiratory center.

In both animals in which partial destruction of the NA was achieved, the fiber degeneration was also restricted to the medium size fiber category. The greater decrease of fibers in animal 20 was commensurate with the larger le-

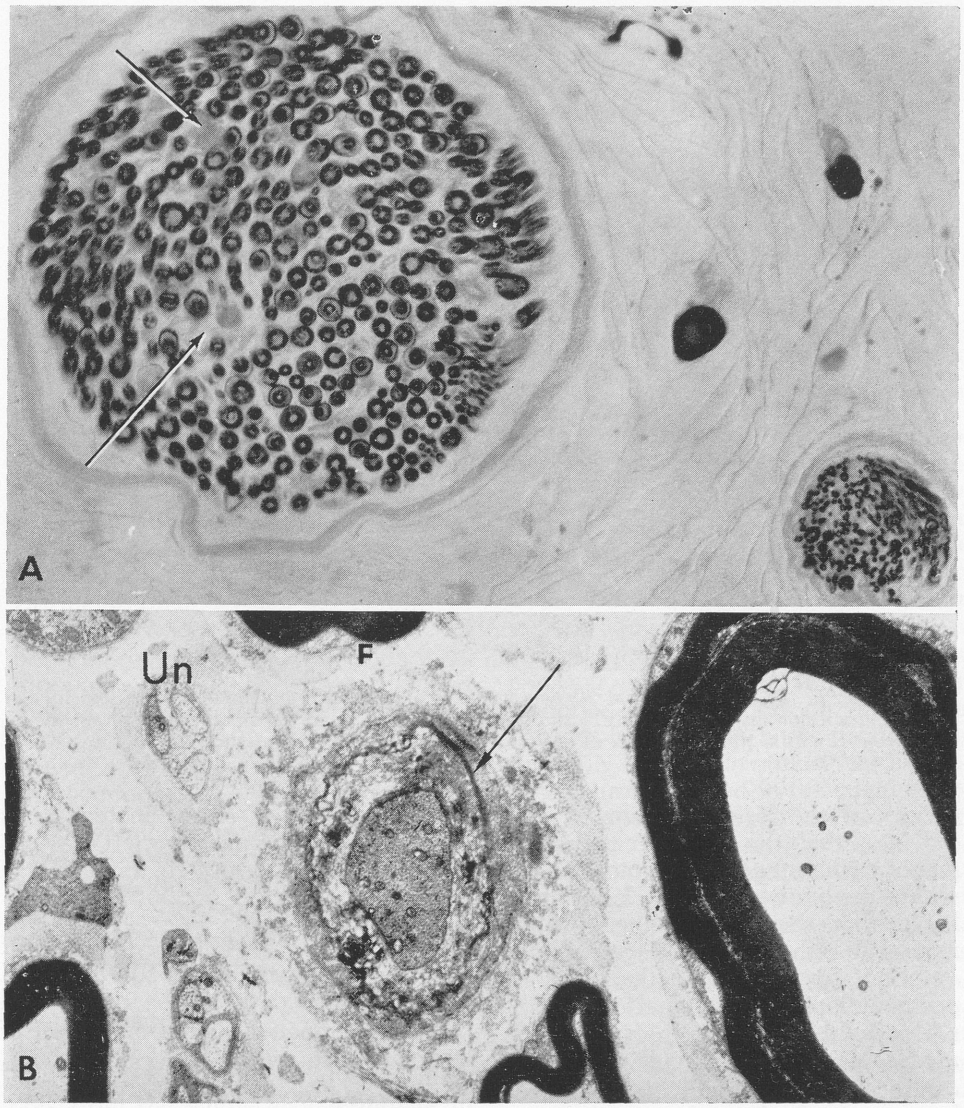

Fig. 4. A) Sudan Black preparation of RLN from animal 15 indicates a slight fiber loss (arrows) following selective lesion of RFN (X110). B) Electron micrograph of RLN in animal 16 where RFN was injured selectively. A degenerating myelinated fiber (arrow) is shown in the center of the field. Un-Unmyelinated fibers. (X8500)

sion which involved the RFN and about one-third of the NA (Fig. 5). In animal 21 only a small portion of the NA was destroyed by a small electrolytic lesion, resulting in less fiber degeneration in the medium size group.

Unmyelinated Fibers in the RLN. An analysis of unmyelinated fibers was performed in those nerves examined by electron microscopy. These nerves were taken from animals in the control, transection of nerves X and XI, and the RFN lesion groups. Table V summarizes the counts of unmyelinated fibers in each of these animals. Although the total unmyelinated fiber count varied greatly, from 399 in the left RLN of animal 13 to 1256 fibers in the right RLN of animal 16, there was no unmyelinated fiber loss in the right RLNs

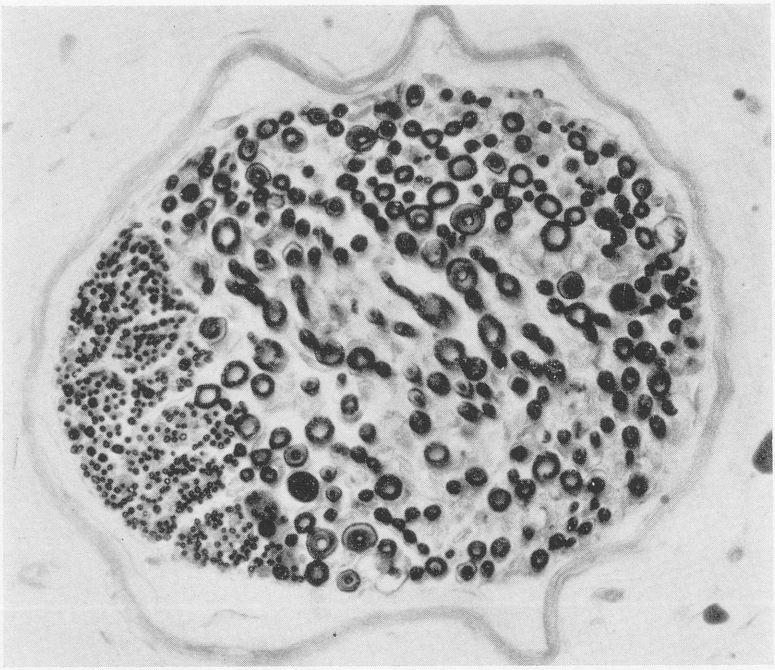

Fig. 5. RLN from animal 20 demonstrates a noticeable myelinated fiber loss following a lesion involving the RFN and part of NA. Note that the small fiber component is located within the main RLN rather than in a separate bundle as shown in Figures 1A and 4A. (X110)

in any of the lesioned animals. This indicates that the unmyelinated fibers do not represent axons of motor neurons within the brain stem. Instead, it seems likely that these unmyelinated fibers represent either cervical sympathetics entering the RLN in the neck or postganglionic parasympathetic fibers whose cell bodies lie in the vagus nerve near the base of the skull. A distinct preponderance of unmyelinated fibers in the right RLN over the left was observed in this series of six animals.

DISCUSSION

Control Nerves. The evaluation of this series of normal cat RLNs should provide valid data on the myelinated and unmyelinated fiber composition of this nerve since these nerves were eval-

TABLE IV

MYELINATED FIBER COUNTS IN RLN FOLLOWING PARTIAL DESTRUCTION OF RIGHT NUCLEUS AMBIGUUS

Lesion	*Animal No.*	*Total Fibers*	*Small (1-3 μ)*	*Medium (4-9 μ)*	*Large (10-15 μ)*
RFN and part of NA	20	R 620 L 612	438 179	156 425	26 8
Small part of NA	21	R 403 L 592	161 217	234 364	8 11
	Avg.	R 511	299	195	17

RFN - Retrofacial nucleus
NA - Nucleus ambiguus

TABLE V

UNMYELINATED FIBERS IN RLN

Animal No.	*Lesion*	*Fiber Counts* R	L
6	Control	565	645
10	Control	867	488
13	Transection X & XI	652	399
16	RFN	1256	1022
18	RFN	951	837
19	RFN	673	693
	Avg.	827	680

uated by both light microscopy and electron microscopy. The average total number of 565 fibers in the cat's right RLN and 482 in the left RLN compare well with total counts by Murray[3] (400-600 fibers in six nerves) and by Abo-El-Enein[4] (545 to 962 fibers in four nerves). However, Murtagh and Campbell[5] reported 1026 to 1456 fibers in three cat RLNs. The fiber diameter spectra found in this study also compare favorably with those found by Murray, Abo-El-Enein, and Murtagh and Campbell.

The tendency for the right RLN to have a significantly larger number of fibers than the left RLN was also reported by Abo-El Enein,[4] who analyzed two pairs of nerves. The present study demonstrates that this is true for both myelinated and unmyelinated fibers. An explanation for part of this difference may lie in the fact that the left RLN descends into the chest and some afferents from the vagus may terminate in the chest, whereas on the right side they continue on with the RLN into the regions of the larynx, trachea, and esophagus. Since the difference in number of medium sized fibers of the right and left RLN could be in the afferent component, it is not possible to say that there is a significant difference in the efferent component also. The answer to that question must come from degeneration studies of the left RLN.

The determination of the motor or efferent fibers in the RLN rests upon transection of the motor axons at a point proximal and far removed from the sensory neurons, which are contained in the nodose and jugular ganglia at the base of the skull. Intracranial transection of all of the rootlets of the X and XI cranial nerves at their emergence from the brain stem and before penetration of the dura at the jugular foramen was the point selected for carrying out this lesion. In this manner, wallerian degeneration of the motor neurons in the vagus nerve destined for the RLN will occur rapidly, while sensory neurons located in the vagal ganglia at the base of the skull remain intact. A two-week survival period was selected to allow sufficient time for complete wallerian degeneration, yet not long enough to permit significant retrograde degeneration of sensory neurons in the vagal ganglia. All rootlets of the X and XI cranial nerves were transected because of the possibility that motor neurons to the laryngeal muscles may be contributed by both cranial nerves exiting from the brain stem almost the entire length of the NA.

The results of the intracranial transection experiment indicate that all motor fibers are contained in the medium size fiber group (measuring 4 - 9 μ) which comprises more than one-half of the total fiber population of the RLN at a point approximately 2 cm below the thyroid cartilage. However, at this point the RLN also contains a numerous small fiber component which has been shown to contain afferents to the trachea and esophagus.[6] If one discounts

this small fiber group as containing nonlaryngeal afferent fibers, the motor fibers could be regarded as making up over 80% of the RLN just prior to its entering the intrinsic larynx.

These motor nerve fibers represent the axons of neurons in the RFN and the NA located in the caudal brain stem. According to numerical estimates made from retrograde tracer studies in the kitten,[2] there are approximately 100 neurons in the RFN and about 285 neurons in the NA which project into the RLN. The total number of motor axons determined by the present experimental study is about 312 fibers. While this number is lower than the cell counts arrived at in the kitten, it should be noted that these RLN fiber counts were performed in adult cats so that neuron loss from aging could account for some, if not all, of the numerical difference. In addition, since these figures can only be regarded as estimates, this approximation may be considered to be in agreement.

Selective destruction of the RFN in six animals indicated that the myelinated fibers projecting from this nucleus are smaller than those from the NA. RFN axons measure 4 - 6 μ in diameter while those from the NA range from 6 - 9 μ in diameter. This difference in fiber size is not surprising since it is in keeping with the difference in neuron size, the retrofacial neurons being decidedly smaller than the large multipolar neurons which comprise the NA.[2] An estimate of the RFN fiber component in the RLN was 51 myelinated axons.

Although complete destruction of the NA was not possible because of the frequent involvement of the nearby respiratory centers, it is reasonable to assume that the remaining motor axons in the RLN belong to the NA motor neurons. This assumption rests upon retrograde tracer studies which show that only the NA and the RFN are responsible for the motor supply in the RLN.[2] Furthermore, the agreement of numerical estimates of the combined RFN and NA cell counts in the kitten and the RLN motor fiber counts in the adult cat supports this statement.

The demonstration of two separate motor neurons to intrinsic laryngeal muscles invites speculation on their respective roles. It has been shown[7-9] in other animals where there are two distinct groups of motor nerve fibers to skeletal muscles, that stimulation of small diameter (5 μ) myelinated nerve fibers causes slow, graded muscular contractions resulting in low amplitude muscle potentials of long duration. Stimulation of large myelinated nerve fibers (10 - 12 μ) produces fast motor unit twitches with rapidly propagated muscle potentials of short duration. The small motor nerves have been regarded as part of a neuromuscular system with a tonic function.

Since different motor units have been demonstrated physiologically in the posterior cricoarytenoid (PCA) muscle of the cat,[1] and the dual innervation from the RFN and NA are associated with the PCA and cricothyroid (CT) muscles,[2] a hypothesis of the role of these motor neurons could involve these muscles.

Morphologically, the smaller size of the retrofacial motor neuron could qualify it as the unit which produces a slow contraction of long duration. The larger motor neurons of the NA could then be responsible for the rapid contraction short-acting kinetic muscle activity in these laryngeal muscles. Such different roles for these two neural units might fit in with the dual actions of the PCA and CT muscles in both inspiration and phonation. For example, while the PCA muscle contracts rapidly in inspiration to abduct the vocal cords, the CT muscle also tenses and exerts a tonic pull on the cords to increase the anterior-posterior glottic dimension.[10] Conversely, while the CT muscle contracts to produce strong adduction of the vocal cords in phonation, the PCA muscle also is responsible for a steady tonic counterpull on the arytenoid to result in more effective adduction.

Another possible role for the dual in-

nervation of these laryngeal muscles is to result in a smooth, coordinated and more effective muscle contraction. Such a contraction could represent the additive effect of neuromuscular units having long, short, and intermediate contraction times as demonstrated in the PCA muscle by Kirchner and his coworkers.[1]

The afferent myelinated fibers occupy all three of the fiber categories recognized in the RLN of the cat. The small fiber group (1 - 3 μ) is the most numerous (32% of RLN). These afferents have been shown by both morphological[3] and physiological[6] studies to supply the tracheal and esophageal mucosa. In a sense, these fibers may not be considered as truly laryngeal. The largest sensory fibers in the RLN are those measuring 10 - 15 μ in diameter and represent only 2% of the RLN. Since the sparse presence of muscle spindles and spiral receptors has been demonstrated within the intrinsic laryngeal muscles of animals[4] and the human,[11-14] it is possible that these fibers provide innervation to such structures.[15-17] Large size myelinated fibers are known to innervate spindles in other muscles of the body.[18] It is also possible however, that these large afferent fibers merely represent the extension of afferents from the superior laryngeal nerve through the ramus communicans into the RLN where they extend in a retrograde fashion into the thoracic cavity to innervate baroreceptors.[3] The medium sized fiber group also contains a variable number of afferent fibers which average approximately 48 fibers per nerve in the cat. These afferent fibers representing 11% of the RLN presumably supply the mucosa of the subglottic region.

Unmyelinated fibers in the RLN have not previously been carefully counted, primarily because the RLN has not been studied extensively under the electron microscope. Murray[3] counted 48 to 81 unmyelinated fibers in the cat RLN using a light microscopic technique. He also found that these did not diminish following transection of the vagus nerve high in the neck. Abo-El-Enein[4] and Murtagh and Campbell[5] did not evaluate unmyelinated fibers in the cat RLN. The present study shows that the RLN actually contains more unmyelinated than myelinated fibers. The tendency for the right RLN (average 827 fibers) to possess more unmyelinated fibers than the left RLN (average 680 fibers) parallels this relationship with regard to myelinated fibers. The number of unmyelinated fibers in the RLN was not diminished following destruction of the intracranial nuclei or nerve rootlets which contribute to the RLN. The logical conclusion is that the unmyelinated fiber component either represents sympathetic fibers from the cervical sympathetic chain which enter the RLN in the neck or that they represent postganglionic parasympathetic fibers whose cell bodies are located near the base of the skull. It seems likely that these autonomic nerve fibers travel along the RLN to enter the larynx where they provide the innervation for blood vessels and glandular structures in this region.

REFERENCES

1. Suzuki M, Kirchner JA: The posterior cricoarytenoid as an inspiratory muscle. Ann Otol Rhinol Laryngol 78:849-864, 1969

2. Gacek RR: Localization of laryngeal motor neurons in the kitten. Laryngoscope 85:1841-1861, 1975

3. Murray JG: Innervation of the intrinsic muscles of the cat's larynx by the recurrent laryngeal nerve: A unimodal nerve. J Physiol (Lond) 135:206-212, 1957

4. Abo-El-Enein: *Functional Anatomy of the Larynx*, Ph.D. thesis. University of London. Quoted by Bowden REM in, Wyke B (ed): *Ventilating and Phonatory Control Systems*. London, Oxford Univ Press, 1974, chap 22

5. Murtagh JA, Campbell CJ: The respiratory function of the larynx. III. The relation of fiber size to function in the recurrent larvngeal nerve. Laryngoscope 61:581-590, 1951

6. Suzuki M, Kirchner JA: Sensory fibers in the recurrent laryngeal nerve. Ann Otol Rhinol Laryngol 78:21-31, 1969

7. Kuffler SW, Hunt CC, Quilliam JP: Function of medullated small nerve fibers in mammalian ventral roots: efferent muscle spindle innervation. J Neurophysiol 14:29-54, 1951

8. Kuffler SW, Vaughan-Williams EM: Small-nerve junctional potentials. The distribution of small motor nerves to frog skeletal muscle, and the membrane characteristics of the fibers they innervate. J Physiol 121:289-317, 1953

9. Hunt CC, Kuffler SW: Motor innervation of skeletal muscle: Multiple innervation of individual muscle fibers and motor unit function. J Physiol 126:293-303, 1954

10. Suzuki M, Kirchner JA, Murakami Y: The cricothyroid as a respiratory muscle. Ann Otol Rhinol Laryngol 79:976-983, 1970

11. Goerttler R: Die anordnung, histologie und histogenese der quergestreiften muskulatur im meuschlichen stimmband. Z Anat Entwicklungesch 115:352-401, 1950

12. Paulsen R: Untersachungen uber das vorkommen und zahl von muskelspindeln im M. vocalis des menschen. Z Zellforsch Mikrosk Anat 47:363-366, 1958

13. Keene MF: Muscle spindles in human laryngeal muscles. J Anat 95:25-29, 1961

14. Bowden REM: Muscle spindles in the human foetus. Acta Biologica Med Ger 9 (fasc 1-4):35-59, 1963

15. Hunt CC: Relation of function to diameter in afferent fibers of muscle nerves. J Gen Physiol 38:117-131, 1954

16. Scheur JL: Fiber size frequency distribution in normal human laryngeal nerves. J Anat 98:99-104, 1964

17. Bowden REM: Innervation of intrinsic laryngeal muscles, in Wyke B (ed): *Ventilatory and Phonatory Control Systems.* London, Oxford Univ Press, 1974, chap 22

18. Barker D: The innervation of the muscle spindle. Q J Microsc Sci 89:143-186, 1948

———

REPRINTS—Richard R. Gacek, MD, Dept. of Otolaryngology, University of Massachusetts Medical School, 55 Lake Ave., North, Worcester, MA 01605.

AN IMPLANTED ELECTRONIC LARYNGEAL PROSTHESIS

BYRON J. BAILEY, MD
GALVESTON, TEXAS

CERI M. GRIFFITHS, MD
GALVESTON, TEXAS

ROBERT EVERETT, PHD
HOUSTON, TEXAS

SUMMARY — The authors present a preliminary progress report on their investigations dealing with the development of an implanted electronic laryngeal prosthesis system. Their initial observations indicate success in the design and fabrication of the implantable, retropharyngeal transducer and secondary induction coil elements. The surgical procedure for implantation is described, and the complications encountered during the first thirteen procedures are reported. These complications included five seromas, one postoperative abscess, one partial wound breakdown secondary to animal-inflicted trauma, and two anesthetic deaths at the time of follow-up radiographic procedures. Additional observations are presented regarding the acoustical output of the transducer in air and after implantation. Projections are made concerning the use of this laryngeal prosthesis system in human patients for vocal rehabilitation after total laryngectomy.

Since the first report of esophageal speech by Reynaud in 1841,[1] physicians have been searching for better solutions to the problem of vocal rehabilitation of the patient whose voice has been lost through accident or surgery. The social, economic and psychological impact of laryngectomy has been observed on numerous occasions by almost all head and neck surgeons. Conversely, measures which can restore effective communication to these patients are of immeasurable value to the victim and his family.

The purposes of this paper are to review significant developments in this field, and to report our preliminary investigational observations regarding an implantable electronic laryngeal prosthesis.

HISTORICAL REVIEW

The period from 1859 to 1942 was characterized by a number of highly innovative attempts to develop procedures and devices which would assist the laryngectomized patient (Table I).[1-23] Limitations of surgical and mechanical technology were such that these efforts were only partially successful and were attempted in only a small number of patients.

The work of Briani between 1942 and 1952 ushered in the modern era of surgical procedures and prosthetic devices with which we are dealing today. This innovative Italian surgeon developed a functional external air bypass prosthesis which is fitted into a surgically-created, skin-lined, cervical-esophageal fistula. Working independently in this country, Conley reported his experiences with external and internal tracheopharyngeal shunts in 1958 and 1959. These reports were followed by important contributions from various head and neck surgeons in North America and England. The most widely accepted and utilized procedures have been those described by Asai, Montgomery, Calcaterra, Shedd, Komorn, Edwards, Taub, and Sisson and McConnel.

While most of the publications on

From the University of Texas Medical Branch, Galveston, Texas, and the University of Houston, Houston, Texas. This work was supported in part by NIH Research Grant CA 17961-01 from the NCI.

TABLE I

SPEECH REHABILITATION AFTER TOTAL LARYNGECTOMY
CHRONOLOGY OF DEVELOPMENTS

Date	*Scientist Development*
1841	Reynaud[1] described esophageal speech. Followed by reports by Bourquet (1856), Sawyer (1856) and Bose (1865).
1859	Czermak[1-3] developed a reed-containing tube which passed externally from the trachea to the mouth.
1861	Bruns[1-3] a flexible metal tube (containing a rubber band) which was placed externally between the trachea and mouth.
1874	Gussenbauer[1-3] a tracheopharyngeal air bypass prosthesis with a reed required a pharyngeal fistula.
1887	Stoerk[1-3] devised a tracheooral tube with a whistle held between the teeth. Later modified to be powered by a hand-held bellows.
1925	Brown[4] reported the use of a pitch whistle and ear speculum inserted into a small pharyngeal fistula.
1927	Beck[2,5] presented a patient who had created a tracheopharyngeal fistula with an ice pick and had developed speech.
1928	Scuri[3] described a patient with speech after the spontaneous development of a tracheopharyngeal fistula.
1935	Guttman[3] reported three patients who had been able to speak following a tracheopharyngeal fistula created by a diathermy knife.
1942-1958	Briani[6] developed and reported speech rehabilitation employing a skin-lined cervical-esophageal fistula and an external air bypass prosthesis.
1958-1959	Conley[5,7] developed external and internal tracheoesophageal fistula techniques.
1962	Ogura, *et al*[8] described an experimental technique (in dogs) for creation of a tracheopharyngeal fistula.
1965	Asai[9] described a staged technique for creation of a tracheopharyngeal internal voice tunnel.
1965	Barton[10] reported a tracheooral speech tunnel technique.
1968	Montgomery and Toohill[10,11] developed tracheoesophageal and tracheopharyngeal fistula techniques.
1969	Goode[12] published his work on an external electronic laryngeal prosthesis which utilizes a pharyngeal fistula.
1970-1971	McGrail and Oldfield[13] reported the use of a deltopectoral flap to create a tracheopharyngeal fistula for speech.
1970	Kitamura[14] described a tracheopharyngeal fistula for speech rehabilitation.
1971	Calcaterra[8] reported his findings involving a tracheoesophageal fistula for speech.
1972	Shedd[15] developed an external reed-fistula prosthesis which utilizes a pharyngocutaneous fistula.
1973	Komorn[16,17] published his experience with a tracheoesophageal fistula technique.
1973	Edwards[18] described another form of tracheopharyngeal shunt using an air bypass prosthesis.
1973	Taub[19,20] reported his work with an esophageal fistula and an external air bypass prosthesis.
1974	Shedd[21] developed a second air bypass prosthesis which employs a higher pharyngeal fistula.
1975	Sisson and McConnel[22] published their technique which uses an external air bypass prosthesis and a pharyngeal fistula.
1975	Rogers, Frederickson and Bryce[23] described an implanted electronic laryngeal prosthesis which had been studied experimentally in dogs.

TABLE II

NONINVASIVE AIR-POWERED METHODS OF VOCAL REHABILITATION

	Air Source	*Vibrator*
Esophageal speech[1]	Esophageal reservoir	Pharyngeal mucosa
Czermak's device[1]	Pulmonary air	Rubber band
Bruns' device[3]	Pulmonary air	Rubber band
Stoerk's device[1]	Mechanical bellows	Whistle
Tokyo device[24]	Pulmonary air	Rubber band

vocal rehabilitation after total laryngectomy provide some historical material, two of the most comprehensive reviews on this subject are found in the articles by Hanson[2] and Arnold.[1]

CLASSIFICATION OF PROCEDURES AND DEVICES

The diversity of the theoretical, mechanical and surgical approaches which have been taken to this problem creates a need for an attempt at classification (Tables II,[1,3,24] III,[1,3-10,13-22,25] IV).[1,12,23,26,27]

Table II lists the major types of noninvasive, air-powered methods of vocal rehabilitation after total laryngectomy. These range from conventional esophageal speech to a recently reported modification of the Japanese (Tokyo) pneumatic speech aid. These rehabili-

TABLE III

INVASIVE PROCEDURES FOR PULMONARY AIR-POWERED VOCAL REHABILITATION

	Prosthesis Required	*External Fistula/ Internal Shunt*	*Fistula/ Shunt Location*	*Presumed Vibrator Sound Source*
Conley-I[5,7]	No	I	T-E	M & T
Conley-II[5,7]	Yes	E	T-E	M & T
Montgomery-I[10]	Yes	E	T-E	M & T
Calcaterra[8]	No	I	T-E	M & T
Komorn[16,17]	No	I	T-E	M & T
Taub[19,20]	Yes	E	T-E (? low pharyngeal)	M
Gussenbauer[1]	Yes	E	T-P (H)	Reed
Brown[4]	Yes	E	T-P (L)	Pitch Whistle
Guttman[3]	No	I	T-P (L)	M & T
Briani[6]	Yes	E	T-P (H)	M
Asai[25,9]	No	I	T-P (H)	T
Montgomery-II[10]	Yes/No	E	T-P (L)	M
McGrail[13]	Yes	I	T-P (H)	T
Kitamura[14]	No	I	T-P (H)	T
Shedd-I[15]	Yes	E	T-P (L)	Reed
Shedd-II[21]	Yes	E	T-P (H)	M
Edwards[18]	Yes	E	T-P (H)	T
Sisson[22]	Yes	E	T-P (H)	T O
Barton[10]	Yes	I	T-Oral	T O

E - External. I - Internal. T-E - Tracheoesophageal. T-P - Tracheopharyngeal. (H) - High. (L) - Low. M - Mucosa. T - Tunnel. T O - Tunnel Opening.

TABLE IV

ELECTRONIC POWERED DEVICES FOR VOCAL REHABILITATION

	Varieties of Devices
External transoral[1,26]	(Cooper-Rand, Tait, Ticchioni pipe)
External transcervical[1,26]	(Aurex, Kett, Electro-larynx)
Goode[12]	External sound source — Pharyngocutaneous fistula
Pichler[12]	Intraoral (dental) transducer with wireless transduction
Frederickson[23]	Implanted pharyngeal transducer with wireless transduction
Bailey[27]	Implanted pharyngeal transducer with wireless transduction

tative methods require no surgical procedures. The air source and vibrator mechanism for each of these methods are indicated.

The most extensive variety of vocal rehabilitative procedures are those which require an operative procedure (invasive techniques) and utilize expired pulmonary air for their power source.

Table III lists the invasive procedures for pulmonary air-powered vocal rehabilitation which are of historical relevance and current interest. Table III indicates whether it is necessary to employ a prosthetic device in conjunction with the surgical procedure, differentiates between those surgical procedures which employ the creation of an external fistula with a prosthetic device and those which consist of the construction of an internal (subdermal) air shunt, describes the anatomic location of the external fistula/internal shunt, and designates the presumed vibrating source which produces the air column necessary for speech.

More recently, efforts have been made to develop an electronic sound source for speech. Table IV lists the different varieties of electronic devices, and includes both noninvasive (external and nonsurgical) devices, and those which must be implanted behind the pharyngeal wall. Currently, the latter group are experimental but may become available for use in patients within the next two years.

Numerous studies from various major institutions presumed to have excellent speech pathology support indicate that one-third of the patients who undergo total laryngectomy do not develop satisfactory esophageal speech.[28] In patients over 60 years of age, approximately 50% may fail to develop adequate communicative ability with this method. It is estimated that 25,000 patients living in the United States have undergone total laryngectomy. Therefore, it is possible that from 8,000 to 10,000 patients in this country would benefit from the development of a satisfactory laryngeal prosthesis for speech.

The Western Electric Electro-larynx®* is the most popular device for solving this problem. Despite its usefulness in many patients, it has certain serious disadvantages, including monotonous speech, high noise to signal ratio and limited effectiveness in some patients.

Many of the surgical techniques listed in Table III are associated with technical problems and postoperative complications when employed in patients whose treatment has included irradiation therapy.

The prosthetic devices shown in Tables III and IV have several disadvantages. In some instances, they are not commercially available for widespread use. In other instances, they are extremely expensive. Most are quite visible, and, therefore, objectionable to the patient. Others restrict the patient's activity, limiting free use of both hands.

* Western Electric, New York, NY.

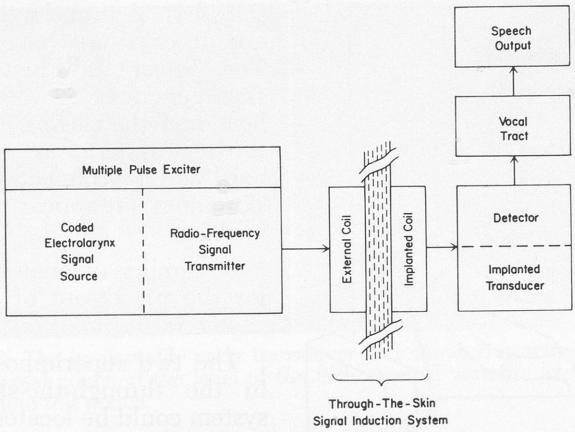

Fig. 1. Diagrammatic representation of the electronic laryngeal prosthesis system.

In addition, they require varying degrees of cleaning, maintenance and replacement.

Recent advances in electronic technology provide the opportunity to explore the possible development of a lightweight, durable, implanted electronic laryngeal voice prosthesis.

OBJECTIVES

The three specific objectives of our approach are: 1) To design and fabricate an electronic laryngeal prosthesis. This prosthesis will be implanted between the posterior pharyngeal wall and the cervical spine and will be a passive-type sound generator, deriving its power from an external signal source via transdermal transduction. 2) To evaluate the tissue acceptance, durability and sound generating capability of this device on the basis of careful animal experiments. 3) Ultimately, to evaluate the usefulness of an implantable electronic laryngeal prosthesis as a voice-producing mechanism for patients who have undergone laryngectomy.

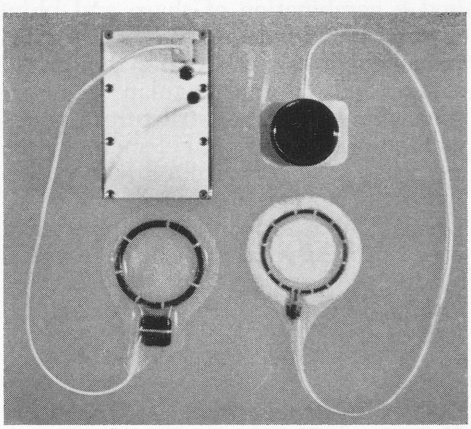

Fig. 2. The prosthetic system currently being investigated. The transducer and secondary induction coil are implanted, and the power supply/signal transmitter and primary coil are worn outside the animal.

DEVELOPMENTAL APPROACH AND PROGRESS

The focus of our experiments has been on the development and investigation of a two-part electronic laryngeal prosthesis system. The basic elements of this system and their relationship to the speech output are shown in Figure 1.

The external portion of the system, consisting of a multiple pulse exciter unit and power supply, will generate a radio frequency power source which drives an induction coil on the external body surface. This external induction coil creates a large magnetic field, inducing a voltage in a secondary coil which is implanted appropriately just under the surface of the skin. The purpose of this dual coil system is to eliminate the need for wired electrical connections through the skin. The implanted coil will be connected by a small coaxial cable to the electro-me-

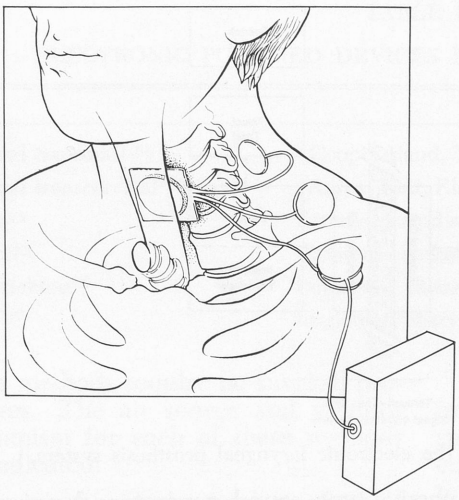

Fig. 3. Location for implantation of the transducer element and the various options available for placement of the subdermal secondary coil.

chanical transducer which has been implanted just behind the pharyngeal wall at the level of the fifth cervical vertebra. The inward and outward movements of the transducer diaphragm produce a moving column of pharyngeal air which is then formed and articulated into the vowels and consonants essential for intelligible speech.

The elements of this system which have been developed to date are shown in Figure 2.

The electro-mechanical transducer unit is the element which is central to all of our efforts and has received most of our initial attention. Factors relating to case design and biocompatibility have been studied. We have determined that adequate sound pressure levels can be generated by a transducer unit of stainless steel which houses all of the necessary standard electronic components and measures approximately 4.0 cm in diameter by 0.9 cm in thickness.

In our initial studies with dogs, we used a system which employs a hard-wired connection between the transducer and the pulse generator/power supply through the skin of the upper back of the dog. We are currently developing the two-coil, through-the-skin transdermal transduction element, and our observations have been favorable. The power transduction through-the-skin generates no excessive levels of heat and the power loss of this transduction system, as compared to the hard-wired connection through-the-skin, does not appear to be a significant problem.

A number of anatomic options exist for the placement of the two coils as shown in Figure 3.

The two superimposed coils utilized in the through-the-skin transduction system could be located in the posterior cervical area, the supraclavicular portion of the lateral neck or the lateral deltopectoral area (a common place for the implantation of subdermal cardiac pacemakers). The external coil would be housed in a lightweight plastic sheath which could be attached to the skin with adhesive paste. This coil would connect with the power supply/multiple pulse exciter unit which could be worn in a comfortable, lightweight chest halter.

The surgical procedure for implantation of the transducer unit is quite simple in the dog experiments and is within the technical ability of any head and neck surgeon. A lateral cervical incision, measuring approximately 8 cm, is made, and a combination of sharp and blunt dissection is used to develop a surgical plane which begins lateral to the carotid artery and internal jugular vein and passes deep to these structures and all of the significant neural elements of the midneck. The prevertebral fascia overlying the fifth cervical vertebra is exposed. The transducer unit is positioned exactly in the midline in this area and sutured to the fascia. The surgical steps for transducer implantation are shown in Figure 4B.

EXPERIMENTAL OBSERVATIONS

The Electro-mechanical Transducer Unit. Our initial objective was to design and build an electro-mechanical transducer which would meet the criteria of being a) biocompatible, b) of a size suitable for implantation in the retro-

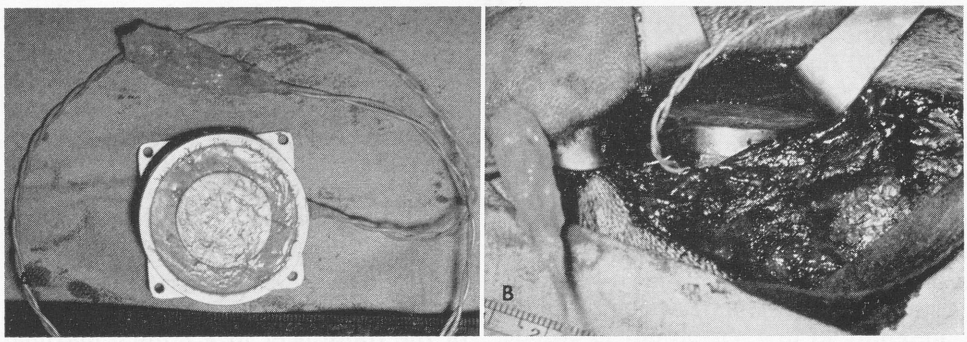

Fig. 4. A) The implantable early transducer and connecting wire. B) Creation of the retropharyngeal pouch at the level of the fifth cervical vertebra and implantation of the transducer into this pouch.

pharyngeal space, c) capable of producing sound pressure levels in excess of 85 dB, and d) capable of producing a periodic signal in the vocal tract which has the harmonic structure similar to that of the signal produced by the action of the vocal folds.

Our initial approach was to design a transducer which uses the principle of magnetic circuits. This is a transducer comprised of a magnetic circuit with a steady magnetic field bias derived from a permanent magnet, a magnetic field source comprised of a coil set for introducing control signals and a mobile diaphragm which would induce motion of the posterior pharyngeal wall. The principle of operation of this type of transducer is based on the fact that the steady field of the permanent magnetic field attraction on the diaphragm is against its spring action. Mechanical action is produced by the additive and subtractive magnetic field produced by currents in the coils of the magnetic circuit. During the early phase of our studies, we identified fourteen factors which required separate analysis. These were:

1. Transducer migration
2. Factors related to midline versus lateral placement
3. Performance factors related to the level of placement
4. Complications related to the surgical implantation procedure
5. Factors related to transducer size
6. Factors related to transducer weight
7. Transducer case design and fabrication
8. Diaphragm design and fabrication
9. Transducer magnets
10. Transducer electronic circuitry
11. Transducer backplate design
12. Transducer case-diaphragm seal
13. Transducer acoustical output tuning factors
14. Transducer-secondary coil connection

Though the limitations of space prohibit a detailed discussion of each of these areas, some summary statements are appropriate.

Transducer migration does not appear to be a significant problem with the perforated metal backplate, the stainless steel mesh backplate or the Dacron®* felt/Silastic®** sheeting backplate, because the transducer is anchored by local tissue ingrowth fairly soon after implantation.

Transducer acoustical output is maximal with midline placement of the

* E. I. DuPont de Nemours & Co., Inc., Wilmington, DE.
** Shell Chemical Co., N.Y., NY.

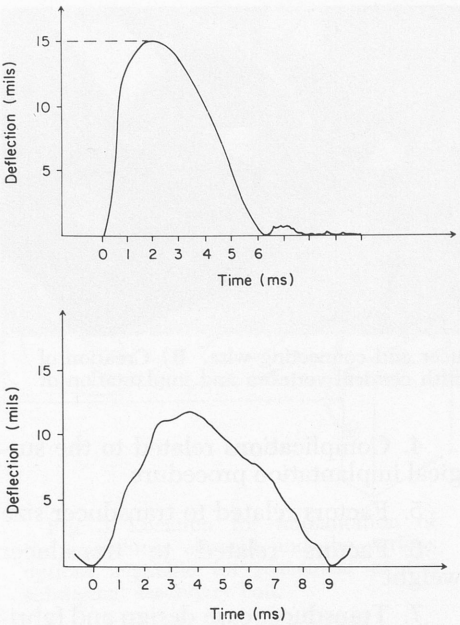

Fig. 5. A) Unloaded wave shape of the transducer diaphragm output. B) The deflection response of the loaded transducer.

transducer unit, but declines rather sharply if the transducer is implanted off-center or migrates laterally.

Our hypothesis is that the quality of the speech output will be superior when the transducer is located toward the inferior limit of the pharyngeal funnel. Extra-oral sound pressure level recordings have shown that acceptable sound pressure levels can be recorded at one meter from the dog's mouth, and it is presumed that this level of placement will maximize the ability of a patient to form and articulate the vibrating column of air into intelligible speech.

The size and weight of the transducer are of concern in terms of comfort when the electronic laryngeal prosthesis system is employed in patients. It is our impression that the transducer size (4.0 cm in diameter and 0.9 cm in thickness) which we have developed has been maximally miniaturized consistent with the desired levels of sound pressure output and the utilization of standard electronic components. We feel that this size and weight is consistent with general patient comfort and minimal impairment of swallowing.

The transducer units are bench-tested extensively in air and in a liquid medium with diaphragm loading to simulate the performance of the unit in the retropharyngeal space. The pulses generated by our latest series of transducers have the unloaded wave shape shown in Figure 5A.

This deflection pulse is the response of the transducer to a 2 msec maximal pulse. The small pulses of latency more than 6 msec are the result of the diaphragm bounding on a mechanical stop.

The tissue loading effects were simulated by placing the transducer unit in a bath of water and attaching a heavy viscous mass with properties similar to the pharyngeal tissues on the diaphragm. The measured pulse deflection under repetitious 100 pulses/sec excitation is shown in Figure 5B.

As shown, the principal effects of transducer loading are to diminish the amplitude response and to lengthen or smear out the unloaded response. The transducer diaphragm is acting as a ballistic device. An excitation pulse releases it, and the stored energy in the diaphragm pushes out the diaphragm and the associated tissue mass. When the pulse is discontinued, the magnetic force commences to pull the diaphragm in again. However, the diaphragm is only responding to determinate forces which have little to do with the exact excitation pulse.

The small irregularities on the pulse wave are mechanical oscillations induced by the loading mass and the spring constant of the diaphragm. The appearance of such oscillations introduces no particular difficulty.

Each transducer is individually fabricated to produce its optimal wave shape. This optimal wave shape corresponds closely with maximal sound pressure level output of the device. The sound pressure level output of the first two series of transducers which were produced is shown in Figure 6.

Sound transmitted from the open and

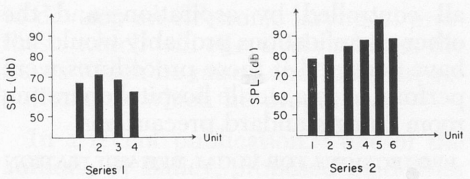

Fig. 6. Sound pressure level output from the transducer units. The transducers in Series 1 had a diaphragm diameter of approximately 28 mls, while those in Series 2 have a diaphragm of approximately 41 mls.

unobstructed oral cavity and pharynx of the dogs was measured after transducer implantation and excitation. Typical levels of such signals were 60 to 70 dB at a distance of one meter. Attenuation by the tissue of the pharyngeal wall and the vocal tract was calculated by subtracting the vocal tract transmitted sound pressure level from the free space radiated sound pressure level. We find that when the transducer remains centered over the midline of the posterior pharyngeal wall, the typical attenuations are only 3 to 5 dB. The best unit which we encountered had an original versus transmitted wave shape displayed in Figure 7.

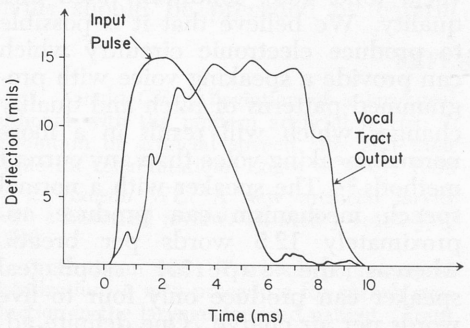

Fig. 7. Comparison of the free space displacement waveshape and the waveshape transmitted by the vocal tract with the implanted transducer.

The effect of the tissue loading and the vocal tract on the original displacement wave shape shows the expected broadening of the impulse. An unexpected feature of the transmitted signal was the rapidly falling trailing edge of the pressure wave.

When we have approximated typical glottal wave shapes with our transducer when it is *in situ*, if we find that tissue loading effects change with passage of time, the only way that we can effect the proper wave shape corrections is to modify the electronic drive currents. As it is, the standard transducer response that we use is the result of a short (1-2 ms) current pulse. For current pulses less than maximal and for current pulses longer than the standard period, the response of the device will be different.

In order to conserve driving power, both in the electronic system and in the transducer, it is desirable to use only rectangular pulses for excitation purposes. In the experiments carried out to date, with the transducer *in situ* or in free space conditions, it has been simple to observe the acoustical output wave shape of the transducer while varying the number, amplitudes and latencies of the driving pulse train so as to arrive at excellent approximations of the appropriate wave shape. For our device, in which care is taken to arrive at a reasonable approximation of the proper wave with a single pulse, any subsequent pulses introduce only minor modifications in the trajectory of the diaphragm and involve little expenditure of power.

Surgical Observations and Complications. The surgical procedure for implantation of the electro-mechanical transducer has been described. The first critical step in the procedure is to accomplish the dissection without injuring the important neurovascular structures of the upper and midneck. The second critical step is to accomplish the placement of the transducer element in the midline immediately over the fifth cervical vertebra. Our studies regarding transducer migration have been promising, particularly with the currently favored model in which the transducer unit is attached to a Dacron® felt/Silastic® sheeting backplate.

During the coming months, we will focus our attention on the local tissue response to the transducer unit. Our primary concern will be the biocompatibility between the transducer and the

surrounding tissue in terms of the formation of both granulation tissue and a seroma around the foreign body. We will study this reaction with weighted "dummy" units and with chronically excited units. We anticipate more problems with the excited units in view of the effect of the acoustical energy of the transducer on the surrounding tissue.

As the sound pressure level output of our newer models will be above 90 dB, we will also include careful studies of the temporal bones in order to be certain that these units do not induce cochlear damage as a result of the sound pressure levels which will be generated.

In our first 13 experiments, we encountered difficulty with postoperative seroma in five dogs. These seromas responded to periodic aspiration when the swelling was visible, and they are probably to be expected in a situation where a large pocket is made and a nonconforming foreign body is introduced. It is technically impossible to close all of the dead space around the transducer unit. Though this complication has produced no serious problems, we are in the process of designing a tapered Silastic® transducer holder to be studied in future experiments.

Anesthetic deaths occurred in two instances during the early phase of our project when animals were anesthesized for routine radiographic studies. In the last six months, there have been no anesthetic deaths.

A postoperative wound abscess developed in one dog. This abscess responded to antibiotics, incision, and drainage without rejection or loss of the transducer unit.

We observed a partial breakdown of the healing surgical incision in one dog. This may have been related to trauma inflicted by the animal during the postoperative period and did not result in loss of the prosthesis or any other complications.

Analysis of our postoperative complications reveals no serious problems in terms of extrapolation of this procedure to the human patient. The seromas were all controlled by aspiration, and the other complications probably would not have occurred if these procedures were performed in a sterile hospital operating room using standard precautions.

PROJECTIONS FOR VOCAL REHABILITATION

We are cognizant of the giant step between the development of sophisticated, prosthetic hardware and the practical rehabilitation of the laryngectomized patient.

Putney[28] reviewed and analyzed 440 patients who had undergone total laryngectomy at Jefferson Hospital. He noted that 38% of these patients were unable to develop any esophageal speech. A small percentage of this group was satisfied to communicate with the Western Electric Electro-larynx®, but many of the patients failed to achieve any means of verbal communication.

In his excellent monograph on the scientific foundations for voice restoration, Snidecor[29] discusses several of the parameters which must be considered in the process of speech rehabilitation. During the design and early fabrication stage, we are addressing the issues of vocal tone, rate, loudness, pitch and quality. We believe that it is possible to produce electronic circuitry which can provide a speaking voice with programmed patterns of pitch and quality changes which will result in a more normal speaking voice than any current methods.[30] The speaker with a normal speech mechanism can produce approximately 12.5 words per breath, whereas the superior esophageal speaker can produce only four to five words per air charge. One definite advantage of the electronic laryngeal prosthesis is its capacity for prolonged speech without interruption.

At the Centennial Conference on Laryngeal Cancer in Toronto in May of 1974, Murry[31] reviewed the basic biophysical requirements for new and projected procedures and devices for voice rehabilitation after total laryngectomy. We were impressed by his distinction between speech intelligibility and speech acceptability. It is our objective

to develop an electronic laryngeal prosthesis which will effectively address the issues which he raised and fulfill the requirements which he proposed.

In a recent publication,[27] one of the authors, BJ Bailey, proposed guidelines for the further progress of vocal rehabilitation after total laryngectomy. Any new procedure or device should meet the following criteria:

1. Use of newer procedures/devices should not compromise any phase of tumor management for cure.

2. Patients should first be encouraged to develop satisfactory esophageal or external electro-laryngeal voice.

3. Patients should decide if their communication ability is adequate to meet their personal needs.

4. *Informed consent* is essential if new procedures are to be employed. Patients must be aware of *all* risks and complications.

5. Patients should be offered several options and alternatives for vocal rehabilitation.

6. The use of new techniques in patients should be preceded by careful animal experimentation.

7. External prosthetic devices should be small, simple, durable and reasonably priced.

8. The ideal prosthetic voice device should leave both hands free and not require frequent adjustment in order to breathe, phonate or cough.

9. The ideal fistula should be placed so that it opposes salivary leakage, avoids major neck vessels, can be employed after irradiation therapy, and can be accomplished in one or two stages.

10. Patients must be selected carefully in terms of intellect, motivation, and freedom from the likelihood of cancer.

Our research plan is to pursue our objectives within the framework of the ten guidelines presented in the preceding paragraph. We hope that our initial progress will stimulate others to work in this important field, so that we may hasten the day when patients will be able to select from a variety of successful procedures and devices which can provide successful vocal rehabilitation after total laryngectomy.

REFERENCES

1. Arnold GE: Alleviation of a laryngeal aphonia with the modern artificial larynx: I. Evolution of artificial speech aids and their value for rehabilitation. Logos 3:55-67, 1960

2. Hanson WL: A new artificial larynx with a historical review. Ill Med J 7:483-486, 1940

3. Guttman MR: Tracheohypopharyngeal fistulization: a new procedure for speech production in the laryngectomized patient. Trans Am Laryngol Rhinol Otol Soc Inc, 1935, pp 219-226

4. Brown RG: A simple but effective artificial larynx. J Laryngol Otol 40:793-797, 1925

5. Conley JJ, DeAmesti F, Pierce MK: A new surgical technique for the vocal rehabilitation of the laryngectomized patient. Ann Otol Rhinol Laryngol 67:655-664, 1958

6. Briani AA: Riabilitazione fonetica di laringectomizzati a mezzo della corrente aerea espiratoria polmonare. Arch Ital Otol 63:469-475, 1952

7. Conley J: Surgical techniques for the vocal rehabilitation of the postlaryngectomized patient. Trans Am Acad Ophthalmol Otolaryngol 73:288-299, 1969

8. Calcaterra TC, Jafek BW: Tracheoesophageal shunt for speech rehabilitation after total laryngectomy. Arch Otolaryngol 94:124-128, 1971

9. Asai R: Laryngoplasty after total laryngectomy. Arch Otolaryngol 95:114-119, 1972

10. Montgomery WW, Toohill RJ: Voice rehabilitation after laryngectomy. Arch Otolaryngol 88:499-506, 1968

11. Montgomery WW: Postlaryngectomy vocal rehabilitation. Arch Otolaryngol 95:76-83, 1972

12. Goode RL: The development of an improved artificial larynx. Trans Am Acad Ophthalmol Otolaryngol 73:279-287, 1969

13. McGrail JS, Oldfield DL: One-stage operation for vocal rehabilitation at laryngectomy. Trans Am Acad Ophthalmol Otolaryngol 75:510-512, 1971

14. Kitamura T, Kaneko T, Togawa K, *et al*: Supracricoid laryngectomy. A new technique for vocal rehabilitation. Laryngoscope 80:300-308, 1970

15. Shedd D, Bakamjian V, Sako K, *et al*:

Further appraisal of reed-fistula speech following pharyngolaryngectomy. Can J Otolaryngol 4:583-587, 1975

16. Komorn RM, Weycer JS, Sessions RB, *et al*: Vocal rehabilitation with a tracheoesophageal shunt. Arch Otolaryngol 97:303-305, 1973

17. Komorn RM: Vocal rehabilitation in the laryngectomized patient with a tracheoesophageal shunt. Ann Otol Rhinol Laryngol 83:445-451, 1974

18. Edwards N: Post-laryngectomy vocal rehabilitation using expired air and an external fistula method. Laryngoscope 85:690-699, 1975

19. Taub S, Bergner LH: Air bypass voice prosthesis for vocal rehabilitation of laryngectomees. Am J Surg 125:748-756, 1973

20. Taub S: Voice prosthesis for speech restoration laryngectomees. Trans Am Acad Ophthalmol Otolaryngol 78:287-288, 1974

21. Shedd DP, Bakamjian VY, Sako K, *et al*: Post-laryngectomy speech rehabilitation by a simplified, single-stage surgical method. Am J Surg 128:505-511, 1974

22. Sisson GA, McConnel FMS, Logemann JA, *et al*: Voice rehabilitation after laryngectomy: results with the use of a hypopharyngeal prosthesis. Arch Otolaryngol 101:178-181, 1975

23. Rodgers JH, Fredrickson JM, Bryce DP: New techniques for vocal rehabilitation. Can J Otolaryngol 4:595-604, 1975

24. Nelson IW, Parkin JL, Potter JF: The modified Tokyo larynx: an improved pneumatic speech aid. Arch Otolaryngol 101:107-108, 1975

25. Miller AH: Four years experience with the Asai technique for vocal rehabilitation for the laryngectomized patient. J Laryngol Otol 85:567-576, 1971

26. Goode RL: Artificial laryngeal devices in post-laryngectomy rehabilitation. Laryngoscope 85:677-689, 1975

27. Bailey BJ, Goode RL: New and projected procedures and devices for voice rehabilitation after total laryngectomy. Can J Otolaryngol 4:605-609, 1975

28. Putney FJ: Rehabilitation of the post-laryngectomized patient: specific discussion of failures, advanced and difficult technical problems. Ann Otol Rhinol Laryngol 69:544-549, 1958

29. Snidecor JC: Some scientific foundations for voice restoration. Laryngoscope 85: 640-648, 1975

30. Everett RL, Mitchell C, Yanowitz A: An electronic laryngeal prosthesis for the production of natural sounding speech, in *Proceedings of the 28th Annual Conference on Engineering in Medicine and Biology.* Chevy Chase, Md., Alliance for Engineering in Medicine and Biology, 1975, vol 17, p 202

31. Murry T: Biophysical requirements for new and projected procedures and devices for voice rehabilitation after total laryngectomy. Can J Otolaryngol 4:571-578, 1975

REPRINTS: Byron J. Bailey, MD, University of Texas Medical Branch, Galveston, TX 77550.

OTOLARYNGOLOGICAL MANIFESTATIONS OF ARTHROGRYPOSIS MULTIPLEX CONGENITA

SEYMOUR R. COHEN, MD

HART ISAACS JR., MD

LOS ANGELES, CALIFORNIA

SUMMARY – The important otolaryngological manifestations of arthrogryposis multiplex congenita (AMC), which heretofore have not been described in otolaryngological and other specialty journals, are reviewed. Thirty-seven patients with AMC were studied. Nine of these patients with neurogenic AMC, had otolaryngological manifestations. Six of these had Pierre Robin-like syndromes. Seven patients had severe dysphagia and aspiration pneumonitis. Five patients had voice changes, and three of these required tracheotomy to relieve laryngeal obstruction and prevent aspiration. Two of these patients were aphonic and had laryngeal paralysis. Three of the nine patients who had laryngeal examination showed supraglottic narrowing similar to laryngomalacia. Six patients with otolaryngological problems were autopsied, and two had pharyngeal biopsies. The histological examination demonstrated normal laryngeal and pharyngeal musculature. The cricoarytenoid joints were found normal in all the larynges examined. Central nervous system dysfunction rather than simple muscle weakness, caused the dysphagia and respiratory difficulties in patients with neurogenic AMC. Dysphagia with aspiration was the single most important cause of death in approximately 20% of patients with AMC. A tracheotomy and feeding gastrostomy appears essential for successful management of the otolaryngological complications of AMC.

The important otolaryngological manifestations of arthrogryposis multiplex congenita (AMC) have heretofore not been described in the otolaryngological literature, and are rarely mentioned in other specialty journals. AMC is an uncommon congenital, and sometimes familial disorder, characterized by multiple fixed joint deformities, involving the upper and the lower extremities, and, less commonly, the spine and mandible. It may be associated with other congenital defects.

The purpose of this paper is to acquaint the otolaryngologist with the laryngeal and pharyngeal problems associated with this entity. Severe aspiration pneumonia and airway difficulties are frequently present. While the disease is well known to pediatricians, neurologists and orthopedic surgeons, the otolaryngologist is less frequently involved in the care of these patients.

REVIEW OF THE LITERATURE

AMC was originally described by Otto[1] in 1841. The patient he reported had rigidity of the limbs, which were fixed in bizarre positions. Since then, hundreds of cases have been described in the literature. Rosenkranz[2] in 1905, first applied the term "arthrogryposis," meaning curved joints, to this disease. Stern,[3] in 1923, named the syndrome arthrogryposis multiplex congenita. While Otto described this entity as a congenital myodystrophy, arthrogryposis now is generally considered a syndrome with several causes rather than a single disease. The orthopedic problems are characterized by club feet (equinovarus) deformity, torticollis, hip dislocations and vertebral joint involve-

From the Departments of Surgery (Division of Otolaryngology) and Pathology, Childrens Hospital of Los Angeles, and University of Southern California School of Medicine, Los Angeles, California.

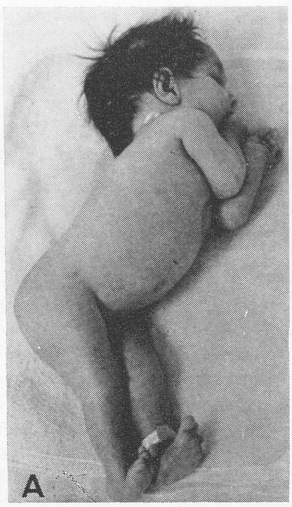

Fig. 1. A) Flexion contractures of arms, club hands, rocker bottom feet. B) Expressionless face, open mouth, flexion contractures of hand; tracheotomy to overcome obstruction.

ment. The wrist, hand and finger contractures (club hand) are either flexion or extension deformities.[4] The frequency of joint involvement increases from proximal to distal, and is more frequent in the lower than in the upper extremity. Temporomandibular joint involvement produces varying degrees of trismus. Facial diplegia (Möbius syndrome) occurs not infrequently. Pearson and Fowler[5] reported a 10-year-old boy with slurred speech, mushy voice, trismus, deformed tongue with inability to protrude it, and inability to whistle. Temporary marked difficulty in swallowing was noted at age three months. The patient's sister, also an arthrogrypotic, had only curling of the tongue, but none of the other ear, nose or throat anomalies. Sandbank and Cohen[6] report a case of tuberous sclerosis with AMC in a patient who had dysphagia, inspiratory stridor, costal retractions, and subsequently died of airway obstruction. No mention is made of laryngeal examination, and the tongue was not examined.

ETIOLOGY

Many causes of AMC have been proposed. Intrauterine problems, such as increased pressure on, or malposition and inactivity of the fetus, have been considered as mechanical etiologic factors. Arthrogryposis has been produced in animals by curarization of the fetus.[7] Central nervous system (CNS) abnormalities have been described, including dysplasia and/or degeneration of the anterior horn cells, meningoceles or myeloceles, involvement of the nuclei of the V and VII cranial nerves (Möbius syndrome), cortical atrophy, microgyria, and varying degrees of hydrocephalus. While most authorities question the role of heredity in this disorder, the myopathic type can clearly show an autosomal recessive genetic pattern.[8] AMC has occurred in twins, but in other instances, one twin was free of the disease. The condition also occurs in families with no previous family history of the disease, and other causes postulated include embryonic muscle abnormalities, abnormal tendon attachments, connective tissue abnormalities, prenatal viral disease, or intrauterine periarthritis.[9] An analysis of pathologic studies from muscle biopsies and autopsy material suggests there are at least two fundamental mechanisms for AMC: neurogenic and myogenic.[5]

CASE REPORTS

Case 1. C.B., a Caucasian female, was born February 11, 1967, and admitted to the Childrens Hospital of Los Angeles, at age 36 days. The purpose of her admission was for casting of her feet. This infant was the product of a traumatic birth, with leg fractures. She had had five episodes of apnea since birth. Arthrogryposis with a muscular disorder was the diagnosis (Figs. 1A, B). Examination revealed an infant in distress, cyanotic at room

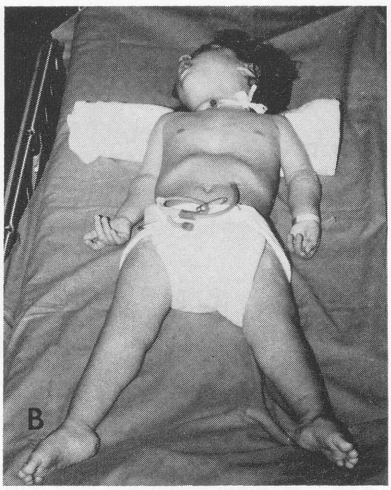

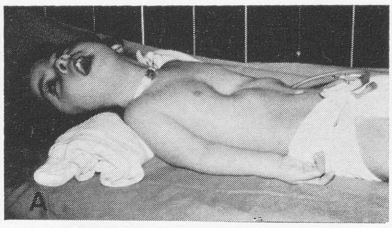

Fig. 2. A) Extensor contraction both feet and flexing contractions of both hands, pectus excavation, a feeding gastrostomy and tracheotomy. B) Hypoplastic mandible, expressionless facies, high arched palate.

air, but pink in oxygen, with an extremely weak voice. Retraction at the xiphoid with loud inspiratory stridor and pooling of saliva in the oropharynx and mouth were noted. The suck reflex was poor, and, because of severe dysphagia, gavage feedings were necessary. Respiratory distress progressed, and on March 21, 1967 laryngoscopy, bronchoscopy, and tracheotomy were performed. The sternocleidomastoid muscle was hypertrophied on the right, and almost absent on the left. The larynx was seen to be inflamed, with marked redundancy of all the superglottic structures. The pharynx was flat, and did not constrict with stimulation. The gag reflex was absent. Pooling of saliva was seen. Whereas the left vocal cord remained in the midline, the right vocal cord abducted 1 mm from the midline. Purulent secretion was seen in the tracheobronchial tree. With the tracheotomy in place she continued to require constant care. On April 10, 1967 biopsy of pharyngeal musculature showed a slight, focal increase in interstitial fibrous tissue, without evidence of either dystrophy or denervation atrophy. On May 17, 1967 direct laryngoscopy again showed superglottic collapse similar to laryngomalacia, the vocal cords were the same, and esophagoscopy revealed hypertrophy of the cricopharyngeus and upper esophagus. The lower esophagus was normal. On March 11, 1968 laryngoscopy again showed retention of saliva in the pharynx, with spilling into the larynx, plus superglottic collapse due to widespread relaxation of the musculature and loss of tone. The vocal cords moved poorly, with loss of tension, and poor adduction. Spasmodic closure of the larynx was absent, accounting for aspiration. The child expired on January 2, 1969 following a rapidly spreading pulmonary infection and *Salmonella gastroenteritis*. An autopsy was not permitted.

Case 2. J.D.G. was admitted to the hospital age 10 hours, because of multiple congenital anomalies. This child was the product of a 30-year-old mother with two healthy children. Presentation and delivery were double footling breech. The mother had a respiratory infection during the first trimester of pregnancy. The child was born at full term. Examination showed multiple joint contractures, a high arched palate, and severe arthrogrypotic involvement of the mandible, which hampered examination of the mouth and throat. The jaw was ankylosed and hypoplastic (micrognathia). The course in the hospital was one of serious feeding difficulty, with resultant aspiration bronchopneumonia. The child was gavage fed, but gradually the course was downhill, and the child died one month after admission. Postmortem examination revealed focal cortical neurone deficiency and heterotopic grey matter nodules in the arachnoid. Skeletal muscle fibers were uniformly small, but showed no other abnormality.

Case 3. B.B.T., a 3-hour-old Caucasian male, was admitted to the hospital on May 11, 1967 in moderately severe distress, cyanotic, and unresponsive. The product of a pregnancy of unknown gestational period, the child required immediate resuscitation at birth. Multiple congenital anomalies were noted. A cleft palate, single umbilical artery, rudimentary left thumb, omphalocele and contractures of the feet bilaterally were noted. The suck reflex was poor. Moro and grasp reflexes were depressed. A spinal tap was normal. The patient was intubated after a cardiorespiratory arrest, but could not be resuscitated. Death occurred three hours after admission. At autopsy esophageal, diaphragm, intercostal, psoas and cervical muscle fibers were uniformly small in diameter. Other than immaturity, the brain and spinal cord were not remarkable.

Case 4. B.G.P., a female Caucasian infant, was admitted to the hospital on February 1, 1964, immediately after her birth. She was

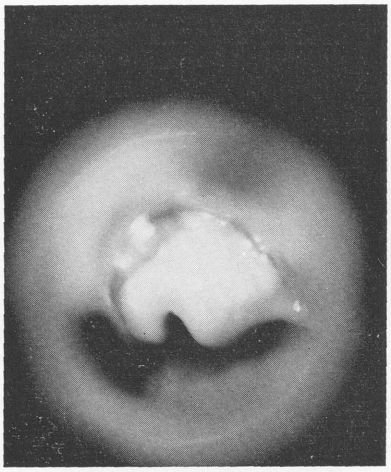

Fig. 3. Marked enlarged thickened, inflamed, and swollen epiglottis and aryepiglottic folds.

three weeks premature. Her mother had "flu" in the first trimester of pregnancy. Delivery was normal. The child was noted to be asphyxiated at birth, required oxygen, and was transferred to the hospital with a diagnosis of tracheoesophageal fistula. The infant was severely depressed, with pooling of saliva in the mouth. In addition, she had severe aspiration pneumonitis, a ureteral vaginal fistula, pectus carinatum, and Potter's facies. In spite of therapy for severe pneumonitis, the patient expired on the ninth hospital day. At autopsy, laryngeal and cervical skeletal muscle fibers were uniformly small in diameter, but otherwise unremarkable. Central nervous system exhibited no diagnostic abnormality.

Case 5. D.W., a Caucasian female, born June 5, 1973, was admitted to the hospital on September 5, 1973. The child was transferred

Fig. 4. Swollen displaced right arytenoid and swollen short aryepiglottic folds.

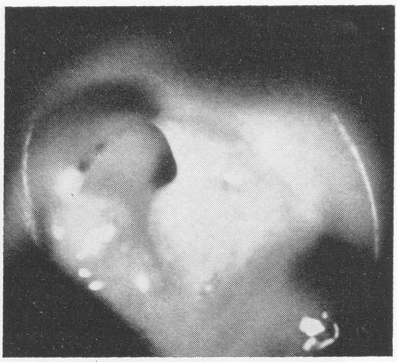

Fig. 5. Bulbous arytenoids, anterior and medial displaced right arytenoid, poor closure mechanism.

from another hospital with a diagnosis of AMC, multiple anomalies and pneumonitis. Born by frank breech presentation, she required continued hospitalization because of severe apneic spells. Recurrent pulmonary problems persisted, necessitating continuous oxygen and suctioning. She could not take oral feedings and required intravenous fluids. Examination revealed a Caucasian female with multiple orthopedic anomalies (Figs. 2A, B), severe pallor with periods of cyanosis, and irregular respirations. Both upper and lower extremities were involved by contractures. X-ray of the chest showed bilateral pulmonary infiltrates. An esophogram with an indwelling tube showed the esophagus to be normal. She required resuscitation with respirator aid during severe periods of respiratory difficulty, and was transferred to the hospital at age three months. On admission to the hospital, she was taken to the operating room where direct laryngoscopy, bronchoscopy and a tracheotomy were performed. The findings were those of severe micrognathia, glossoptosis, and a high arched palate without a cleft. The pharynx was filled with secretions. The cough reflex was intact, and purulent secretion filled the tracheobronchial tree. The larynx was difficult to visualize because of the small hypopharynx. The supraglottic structures were inflamed and hypertrophic (Fig. 3). The right vocal cord remained in the midline, with the right arytenoid anteriorly and medially displaced (Fig. 4). The left vocal cord moved only into the paramedian position. Spasmodic closure was faulty (Fig. 4). Neither a cleft of the larynx, nor a tracheoesophageal fistula were found. Bronchoscopy showed the tracheobronchial tree to be normal, but flooded with secretions. A tracheotomy was performed. The infant continued to aspirate secretions and required constant tracheal suctioning. A feeding gastrostomy was performed. During the next two-and-a-half years, the patient had numerous admissions to the hospital, for splinting and casting of her extremities, and repeated

Fig. 6. Faulty adductor spasmodic closure; right vocal cord in paramedian position.

laryngeal examinations showed persistent, poor spasmodic closure of the vocal cords, but abduction of vocal cords has improved. On July 14, 1975 and on subsequent examinations, the epiglottis was extremely thickened (Fig. 3) and diffusely inflamed. The arytenoids were bulbous and the right was anteriorly and medially displaced (Fig. 5). The vocal cords appeared to abduct normally but adduction was faulty (Fig. 6). The pharynx was filled with secretion. Esophagoscopy showed the cricopharyngeus to be hypertrophic with folds which filled the esophageal lumen. The lower portion of the esophagus was not examined. On December 29, 1975 a hypopharyngeal muscle biopsy was performed, but showed no diagnostic abnormality. Only mild focal fibrosis was seen. However, sections of gastrocnemius, and quadriceps femoris skeletal muscle biopsies, on the other hand, revealed muscle atrophy consistent with late denervation atrophy. The child as of this date is still tracheotomized, and requires gastrostomy feedings. Her face remains expressionless and drooling persists (Fig. 7).

Fig. 7. Typical facies, expressionless drooling, curled tongue, and slightly hypoplastic mandible.

Case 6. M.W., a Caucasian male infant, was admitted to the hospital at age four months on April 7, 1958. He was a full term infant, the product of an uncomplicated pregnancy and normal delivery. A sibling died at age four months of congenital heart disease. The mother and grandfather had club feet. His admitting diagnosis was multiple congenital anomalies—micrognathia, glossoptosis, and bilateral club feet. His course in the hospital was one of failure to gain weight, poor suck reflex, constant aspiration and pneumonitis. It was impossible to maintain his airway. The child expired on July 27, 1958. Autopsy revealed a Pierre Robin-like syndrome without cleft palate. Significant findings included cerebral hypoplasia, flooded tracheobronchial secretions and pneumonitis, AMC, and congenital absence of the right kidney. Histologically, the tongue and skeletal muscles demonstrated uniformly small fibers. In addition, the tongue showed a hyperkeratotic epithelial surface which cascaded upon itself. Spinal cord anterior horn cells were reduced in number. The brain was histologically immature.

Case 7. F.R., a four-month-old Caucasian male, was admitted to the hospital on June 17, 1972 with severe respiratory distress, fever and dysphagia. A diagnosis of Werdnig-Hoffmann disease with arthrogryposis had been made one month prior to admission. The infant was floppy, drooled and was unable to handle excessive saliva. Physical examination showed absent deep tendon reflexes, and Moro reflexes were absent. The patient responded to pain. The course was rapidly downhill and he expired on June 19, 1972. Postmortem findings included neurogenic muscular atrophy involving most skeletal muscles. The musculature of the tongue, esophagus and diaphragm were spared. Anterior horn cells of spinal cord and XI and XII cranial nerve nuclei showed neuronal "ballooning degeneration" and nerve cell loss.

Case 8. H.H., a female Caucasian infant, was admitted to the hospital at age 17 days because of "failure to thrive" and excessive salivation. The infant had been born prematurely during the 35th week of gestation and weighed 2 kg. She was the product of a breech delivery following eight hours of labor. The patient was apparently doing well until age three days when she developed fever and was found to have pneumonia. She was treated for a week with antibiotics and apparently recovered from the pneumonia. However, from that time the infant progressively lost weight, and on admission to the hospital weighed only 1.6 kg. Physical examination on admission revealed a poorly developed infant with multiple skeletal anomalies and stigmata of the Pierre Robin syndrome. She had a small mouth and a high arched palate. There were

flexion contractures of the wrists and fingers with hypermobility of both wrists. The fingers as well as the toes were elongated. She had bilateral congenital dislocations of the hips and genu valgus deformities of both knees. A mass was palpable in the right flank which was thought to be the right kidney. The heart and lungs were clear. While in the hospital, the patient was gavage fed. It was felt that some congenital anomaly of her genitourinary system was present as well as multiple musculo-skeletal abnormalities (AMC). She was doing relatively well until the day prior to death when she developed marked respiratory distress. Physical examination was suggestive of a high airway obstruction. She was taken to surgery for a tracheotomy, at which time direct laryngoscopy and bronchoscopy revealed laryngomalacia (supraglottic collapse). Following the tracheotomy, she improved somewhat, but expired the following day. Postmortem examination showed early bronchopneumonia and right hydronephrosis with double collecting systems. The CNS exhibited no diagnostic abnormality other than immaturity. Skeletal muscle fibers were uniformly small in diameter, but not otherwise remarkable.

Case 9. C.O., a Caucasian female infant, was admitted to the hospital at four days of age on January 31, 1963 with inability to feed. Mother's pregnancy was uncomplicated. The infant was born by breech delivery and was noted to have only a squeaky cry, a weak suck reflex and a hypoplastic mandible facies. Acrocyanosis was observed with a slow respiratory rate and paroxysmal abdominal movements. A tensilon test and lumbar puncture were normal. Because of aspiration of feedings, she was gavage fed. A muscle biopsy showed uniformly small fibers. Neither dystrophic nor inflammatory changes were evident. Histology was consistent with disuse atrophy. Clinical diagnosis was AMC with spinal cord lesion other than Werdnig-Hoffmann disease. Her second admission was on March 5, 1963 for treatment of pneumonia. Chest x-ray revealed a right upper and right lower lobe pneumonia. Her ability to feed improved, and she was followed until 1968. Her mental development was normal and her dysphagia subsided. While diabetes mellitus developed, the patient at present is living and well.

PATHOLOGY

Postmortem and biopsy material of nine infants and children with AMC were reviewed. The larynx, pharynx, esophagus, skeletal muscles and CNS were studied. Two patients had pharyngeal biopsies and two extremity muscle biopsies (D.W. and C.O.).

One infant (F.R.) had AMC associated with Werdnig-Hoffman disease. Most of the skeletal muscles showed severe neuromuscular atrophy, but the diaphragm, larynx and tongue musculature were spared. The spinal cord and caudal medulla exhibited nerve cell loss and "balloon cell" degeneration.

In the other five autopsied patients, skeletal muscles, including the larynx, showed no diagnostic abnormality. In addition to H. and E., trichrome and PTAH stains were used to study skeletal muscle morphology. Skeletal muscles were essentially normal except that the muscle fibers tended to be uniformly small in diameter in all muscle groups sampled. In one patient (M.W.), a decreased number of anterior motor neurons was noted in the cervical spinal cord, but neuromuscular atrophy was not observed. Microscopic examination of the CNS of the other four patients showed immaturity without other abnormalities.

A three-year-old girl (D.W.), one of the two presently living children with laryngeal problems, had biopsies of pharyngeal, gastrocnemius and quadriceps femoris muscles. Pharyngeal biopsy showed normal muscle fibers with mild focal interstitial fibrosis, but the extremity muscles exhibited striking changes consistent with late denervation atrophy.

The pharyngeal muscle biopsy of the other surgical patient (C.B.) revealed essentially normal fibers with mild focal interstitial fibrosis.

SUMMARY AND CONCLUSIONS

The clinical courses of 37 patients (20 male, 17 female) with arthrogryposis multiplex congenita (AMC) were reviewed. Nine patients, all with neurogenic AMC, had otolaryngological manifestations. Six of these had Pierre-Robin syndrome (or a similar disorder with two of the three criteria for this entity). Seven of the nine patients had severe dysphagia and aspiration pneumonitis. One patient, with hypoplastic mandible and severe dysphagia, had temporomandibular joint disease with trismus severe enough to prevent ade-

quate examination of the oropharynx. Five of the patients, all of whom had severe aspiration problems, had voice changes; three of these required tracheotomy to relieve laryngeal obstruction and prevent aspiration.

Two patients had expressionless facies, pharyngeal paralysis, and absent gag reflexes. They could not protrude the tongue, were aphonic, and had laryngeal paralysis with displaced bulky arytenoids. At first these two patients had midline vocal cord paralysis, but later developed defective adductor closure mechanisms. The supraglottic structures were thickened and inflamed. Only three of the nine patients had laryngeal examination, each showing supraglottic narrowing similar to that of "laryngomalacia." In two patients esophagoscopy revealed marked hypertrophy of the cricopharyngeus and upper one-third of the esophagus.

Of the nine patients with otolaryngological problems only two are alive, and one of these has severe CNS disease. Six of these patients with otolaryngological problems were autopsied, and two had pharyngeal muscle biopsies. Autopsy and muscle biopsies demonstrated normal laryngeal and pharyngeal musculature even in one infant with advanced Werdnig-Hoffmann disease and AMC. In all larynges studied, the cricoarytenoid joints were normal.

Central nervous system dysfunction rather than simple muscle weakness thus appears to be an important cause of dysphagia and respiratory difficulty in patients with neurologic AMC, as a result of dysfunction of pharynx, palate, tongue and larynx. Since the resultant severe dysphagia with aspiration pneumonitis can be fatal, a tracheotomy and feeding gastrostomy appear essential for successful management of the otolaryngological complications of AMC.

Although otolaryngologic difficulties caused the death of approximately 20% of patients with AMC in this study, and were the single most important cause of death in these patients, other significant lesions may also reduce survival in AMC. Additional disorders present in patients in this series included optic atrophy, imperforate anus, cryptorchidism, genitourinary system anomalies, cardiomyopathy, and congenital heart disease.

REFERENCES

1. Otto AW: Monstrorum sexcentorum descriptio anatomica in Uratislaviae Museum. *Anatomico-Pathologicum Vratislaviaevise*: 1841

2. Rosenkranz E: Uber Kongenitale Kontrakturen der oberen Extremital. Z Orthop Chir 14:52-93, 1905

3. Stern WG: Arthrogryposis multiplex congenita. JAMA 81:1507-1510, 1923

4. Swinyard CA: Congenital contractures (arthrogryposis), Nature of the syndrome and hereditary considerations. Neurology 15:1397-1398, 1974

5. Pearson CM, Fowler WG Jr: Hereditary non-progressive muscular atrophy inducing arthrogryposis syndrome. Brain 86:75-88, 1974

6. Sandbank V, Cohen L: Arthrogryposis multiplex congenita associated with tuberous sclerosis. Pediat 64:571-574, 1964

7. Drachman DB, Coulombre AJ: Experimental clubfoot and arthrogryposis multiplex congenita. Lancet 2:523-526, 1962

8. Lebenthal E, Schochet SB, Adam A, *et al*: Arthrogryposis multiplex congenita 23 cases in an Arab kindred. Pediat 46:191-199, 1970

9. Friedlander HL, Westin GW, Wood WL Jr: Arthrogryposis multiplex congenita. J Bone J Surg 50:89-112, 1968

ACKNOWLEDGMENTS—The authors are grateful to Benjamin H. Landing, MD, Chairman of the Department of Pathology, Childrens Hospital of Los Angeles, and Professor of Pathology and Pediatrics at the University of Southern California School of Medicine, for his help with the final review of the paper.

REPRINTS—S. R. Cohen, MD, 1300 North Vermont Avenue, Los Angeles, CA 90027.

CONGENITAL LARYNGEAL DEFECTS IN THE ADULT

WILLIAM W. MONTGOMERY, MD

STEPHEN A. SMITH, MD

BOSTON, MASSACHUSETTS

SUMMARY – Two types of congenital laryngeal defects in the adult are presented. The first case is a patient with a laryngeal cleft who became symptomatic at 42 years of age. Dysphagia, dyspnea, hoarseness and aspiration progressed in severity until surgery was necessary at the age of 48 years. The second case presented is a 21-year-old male with nonfusion of the thyroid laminae. He was asymptomatic except for persistence of a high-pitched voice after puberty. The case histories and radiographic studies are reviewed, emphasizing that the diagnosis of these defects was more difficult than their management. The surgical repair is described and illustrated. Briefly, this involved repair of the laryngeal cleft using techniques similar to those of a herniorrhaphy. The nonfusion of the thyroid laminae and resultant defective anterior glottis was repaired using bipedicled muscle flaps and a silicone keel.

Congenital laryngeal defects in the newborn and infant are rarely encountered. Congenital laryngeal defects which clinically manifest for the first time in adulthood are even more rare. Two such defects are the subject of this paper. The first is a posterior laryngeal cleft and the second is an anterior nonfusion of the thyroid cartilages.

Posterior laryngeal cleft in the newborn should be suspected when the symptoms of dysphagia, aspiration, abnormal cry, and respiratory distress are present. The primary diagnostic examination is fluoroscopy. Contrast material is introduced through a catheter which is gradually withdrawn from the stomach and esophagus to search for a tracheoesophageal fistula. Following this, a swallowing cine-esophagram with thin contrast material is carefully performed, with attention focused on the hypopharynx and larynx. The congenital defect is then confirmed by endoscopy. Several excellent reviews of the congenital posterior laryngeal cleft in the neonatal and pediatric age groups have been published.[1-20]

Dysphagia, aspiration, hoarseness, and dyspnea can also be symptoms of posterior laryngeal cleft in the adult. To make the diagnosis prior to endoscopy or exploratory surgery is a noteworthy accomplishment.

CASE REPORTS

Case 1. Posterior Laryngeal Cleft. A 48-year-old white woman presented with a history of six years of progressive dysphagia and one year of slowly progressive hoarseness and dyspnea. A complete review of her medical history revealed that she was the product of an uncomplicated pregnancy and delivery. Birth weight was 3.6 kg and there were no neonatal respiratory or feeding difficulties. However, she had three episodes of pneumonia between the ages of 1 and 15 years, and two more as an adult. The family history was unremarkable.

At the age of 42, she was admitted to the hospital for removal of a foreign body in the esophagus. No abnormalities of the larynx or esophagus were noted at esophagoscopy.

Five years later she was evaluated by the same otolaryngologist with complaints of increasing dyspnea on exertion, progressive hoarseness, and aspira-

From the Massachusetts Eye and Ear Infirmary, Boston, Massachusetts.

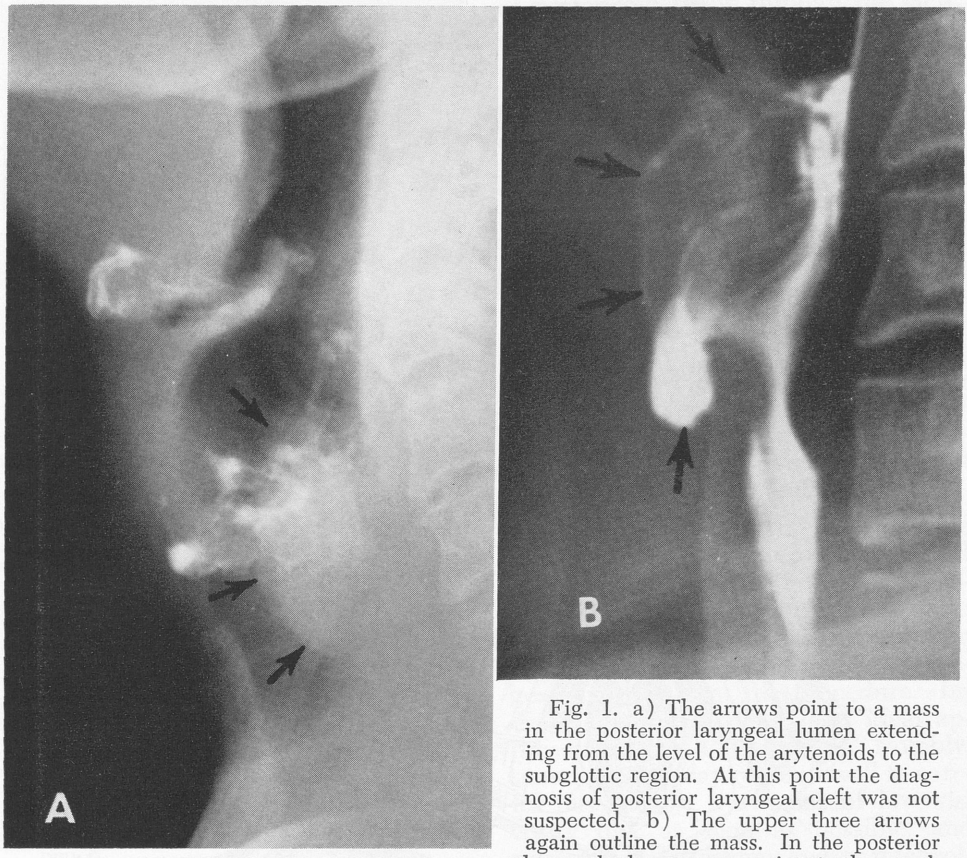

Fig. 1. a) The arrows point to a mass in the posterior laryngeal lumen extending from the level of the arytenoids to the subglottic region. At this point the diagnosis of posterior laryngeal cleft was not suspected. b) The upper three arrows again outline the mass. In the posterior larynx the lower arrow points to the pouch of the cervical esophagus which herniates into the subglottic lumen. The diagnosis of posterior laryngeal cleft was added to the differential diagnosis.

tion with cough. Direct laryngoscopy at that time revealed a large "mass" involving the posterior larynx, and biopsy of this mass demonstrated "normal epithelium."

At the Infirmary, indirect laryngoscopy revealed a large "tumor" mass involving the posterior commissure and projecting anteriorly into the glottic and subglottic regions. The glottic airway was limited to a narrow passage anteriorly. Both arytenoids appeared to function normally; the true vocal cords were obscured posteriorly and were normal anteriorly.

Plane films demonstrated a large mass involving the posterior larynx and extending 2 cm below the glottis. Barium swallow (Fig. 1) revealed a pouch extending into the glottic and subglottic lumen from the postcricoid region.

Direct laryngoscopy under general anesthesia revealed a "floppy" soft tissue mass in the interarytenoid space, extending well into the glottic and subglottic spaces. The mass was easily compressible, unlike a tumor. The esophageal inlet appeared normal, and the esophagus was easily entered. No defect in the posterior cricoid lamina was detected.

Following endoscopy, the larynx was exposed by way of an anterior thyrotomy. The defect in the posterior cricoid lamina became immediately apparent, the "tumor" mass representing esophageal herniation anteriorly into

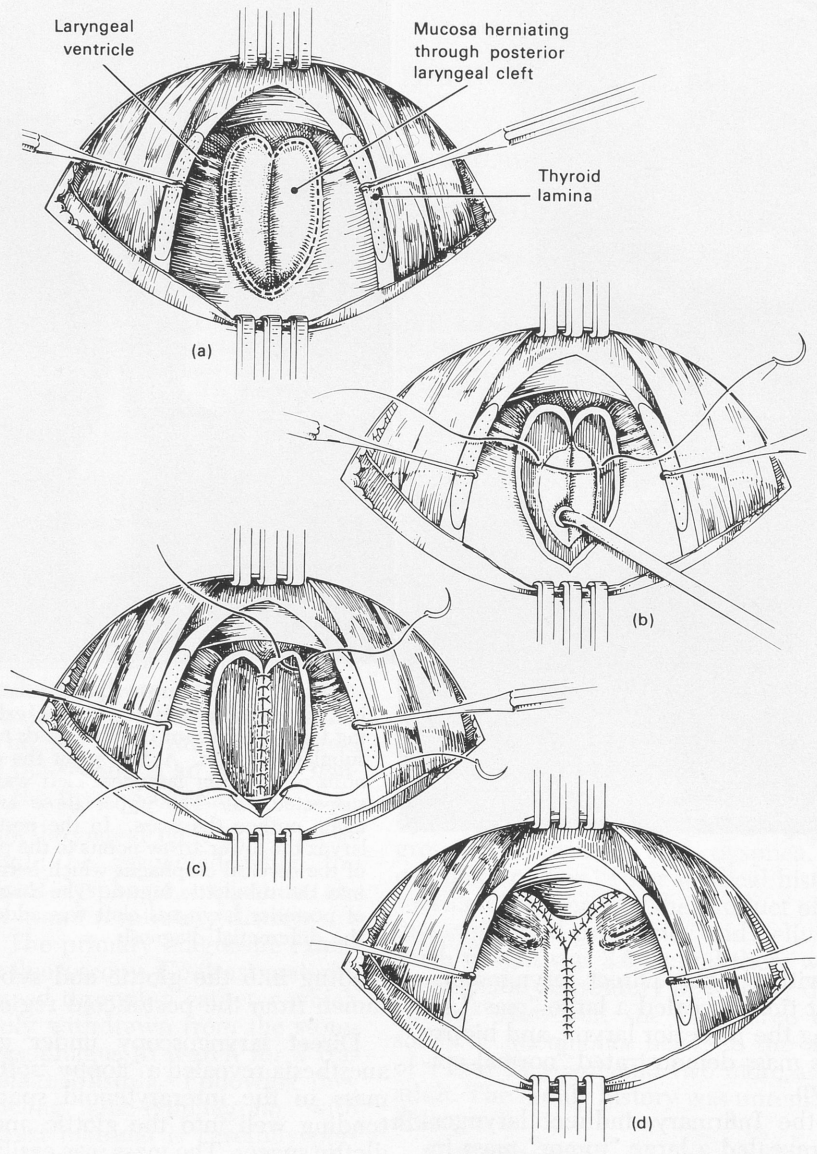

Fig. 2. a) An incision is made in the mucous membrane around the periphery of the mass, which has herniated into the laryngeal region through the posterior laryngeal cleft. Sufficient mucous membrane must remain on each side so that the medial margins can be approximated in the midline. b) Mucous membrane has been carefully dissected from the anterior aspect of the mass, which herniated from the esophagus through the posterior laryngeal cleft. The defect in the postcricoid region is repaired with 3-0 chromic catgut suture material. The herniating esophageal mucous membrane must be pushed posteriorly as this repair is accomplished. c) The first layer of closure has been accomplished. Two sutures have been applied to the postcricoid mucous membrane, which is also repaired using interrupted 3-0 chromic catgut sutures. d) The closure is complete. The normal structures of the larynx can be much more readily visualized. The thyrotomy is closed in the usual fashion. No stent or keel is necessary.

Fig. 3. A postoperative x-ray demonstrating the absence of the mass and pouch.

the larynx and subglottic region. The diagnosis of congenital laryngeal cleft was confirmed and the defect was repaired as illustrated in Figure 2.

A postoperative x-ray (Fig. 3) demonstrates the absence of the mass which was previously present in the larynx and the subglottic regions. The tracheotomy tube was removed two weeks following the surgery. The patient has had no difficulty with deglutition, and her voice and airway are normal three years postoperatively.

Comments. We assume that this patient's recurrent pneumonias were early evidence of this malformation, and that the cleft facilitated the lodging of a foreign body in the cervical esophagus.

It was only in the patient's fourth decade that soft tissue support bolstering the cleft became sufficiently weakened to permit progressive herniation of postcricoid tissue through the cleft. Symptoms referable to this herniation ultimately led her to seek relief.

If the diagnosis is considered during endoscopy, the cleft can be explored with a laryngeal spatula. The large mass of herniated tissue in the present case would have made this difficult, however.

The embryology of this malformation is well-described in the literature.[3-5,9-11] Over 40 cases have been reported to date, many with multiple anomalies. The rate at which new cases are published is accelerating. Unlike tracheoesophageal fistula and esophageal atresia, a familial tendency has been documented in this condition.[1,7,18,21]

In the past, successful repairs have been effected in children via lateral pharyngotomy.[4,12,13,15,16,19,20] Haguenauer's[16] excellent experiences with three thyrotracheotomies in children refute the theoretical concerns of laryngeal damage from the procedure. Indeed, this was a direct and ideal approach for our adult patient. Notably, some patients may respond well to careful observation, avoidance of low viscosity diet as soon as possible, and supportive gastrostomy and/or tracheotomy.[20] How many patients managed this way will become symptomatic as adults, like our patient, is a question for the future.

Case 2. Anterior Laryngeal Defect. A normal appearing 17-year-old boy first consulted an otolaryngologist in 1970 complaining of a high-pitched voice. Short, but normally functioning vocal cords were noted during indirect laryngoscopy (Fig. 4a). Flattening and widening of the larynx were reported as part of the neck examination. The patient was referred to a second otolaryngologist who advised vocal therapy. There was no improvement. Endocrine evaluation was normal at that time.

At the age of 21, the patient was first examined at the Infirmary. By external palpation it was apparent that the thyroid notch was absent and the larynx

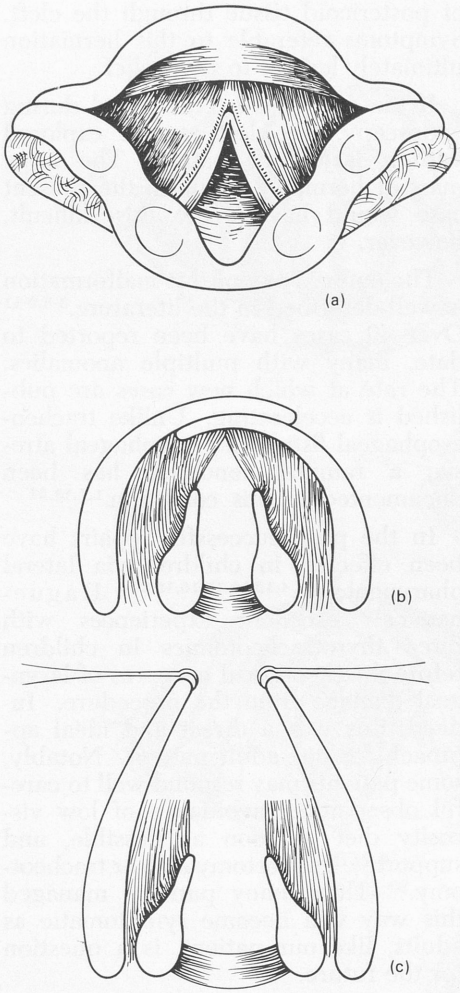

Fig. 4. a) A sketch of the mirror view showing a shortening of the anteroposterior dimension in Case 2. b) A horizontal sketch through the larynx showing nonfusion and overlapping of the anterior thyroid laminae which resulted in shortening of the vocal cords. c) The thyroid laminae have been dissected free and retracted laterally. The anterior half of the true and false vocal cords along with the immediate supraglottic regions are absent.

was flat and wide. It was thus suspected that the thyroid laminae were not fused anteriorly. The vocal cords functioned normally, but were quite short and produced a feminine-type voice.

X-ray evaluation added nothing to establish a positive clinical diagnosis

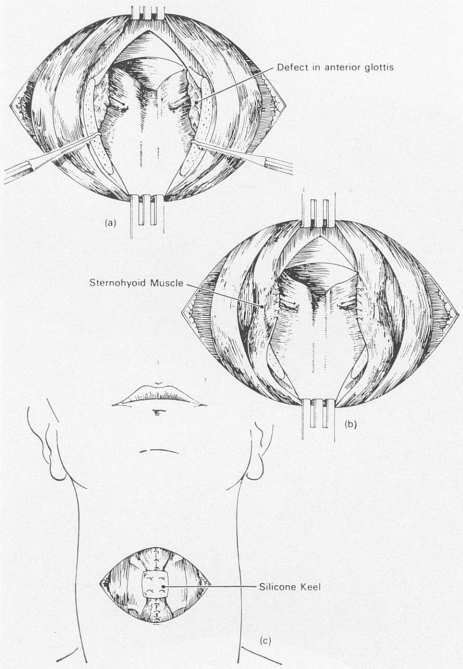

Fig. 5. a) The defect in the anterior glottis is illustrated. b) The sternohyoid muscles and fascia are used as bipedicled flaps to repair the defect of the anterior larynx. c) A silicone keel is sutured in place between the sternohyoid muscles and thyroid laminae.

other than confirmation of the short antero-posterior dimension of the larynx.

In November, 1974, the larynx was exposed by way of a horizontal anterior cervical skin incision at the midlaryngeal level. After performing a tracheotomy, the thyroid laminae were exposed and found not to be fused anteriorly, but were more curved than usual and overlapped to produce the flattening and widening of the larynx as well as the shortening of the vocal cords (Fig. 4b).

The thyroid laminae were separated from one another and retracted laterally with a resultant defect of the anterior half of the glottis (Figs. 4c, 5a). In other words, the soft tissues of the anterior half of the vocal cords and immediate supraglottic and subglottic regions were absent. It was necessary to score the thyroid laminae vertically in order to break the spring of their ab-

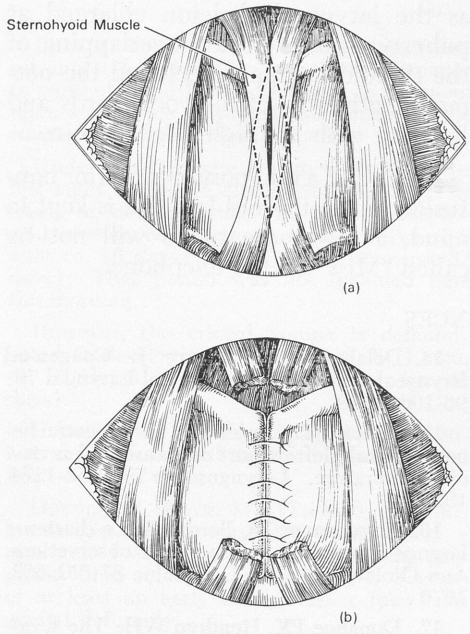

Fig. 6. a) The silicone keel has been removed. The superior and inferior portions of the sternohyoid muscles not used for the repair are transected (broken line) so that the newly constructed anterior commissure can be closed. b) The thyroid laminae have been approximated anteriorly.

normal curvature and retract them laterally.

The sternohyoid muscles with their fascia were carefully dissected so that they could be reflected into the larynx in order to supply tissue for the anterior half of each side of the glottis (Fig. 5b). This repair was accomplished using 4-0 catgut suture material.

A silicone keel[22] was inserted between the sternohyoid muscles inside the larynx and sutured in place with 3-0 polyethylene suture material (Fig. 5c). Three weeks postoperatively the silicone keel was removed as an office procedure. The tracheotomy tube was removed one week later.

After two months his voice was definitely at a lower pitch, but not satisfactory to either the patient or surgeon. It became apparent that the thyroid laminae had not united because of the presence of the laryngeal keel.

Ten months postoperatively the thyroid laminae were again exposed. The superior and inferior portions of the sternohyoid muscle, which were external to the laryngeal lumen and not used as part of the repair, were incised so that the anterior margin of each thyroid lamina could be visualized (Fig. 6a). The thyroid laminae were carefully approximated in the midline with nonabsorbable suture material (Fig. 6b). The airway was not entered, and no tracheotomy was necessary. The result was excellent. Shortly thereafter he enjoyed a normal airway and the voice of a normal adult male.

Comments. In this case the second stage operation was clearly necessary, but possibly could have been performed at the time the keel was removed. Perhaps the thyroid laminae could have been more securely approximated anteriorly above and below the silicone keel at the first operation, making the second operation unnecessary.

Polytomography of the larynx in a vertical plane was not done. This would have demonstrated the overlapping of the nonfused thyroid laminae. Had the thyroid laminae been ossified, the reconstruction would have been much more difficult.

Interestingly, we have found no reported significant anomalies of the thyroid cartilage compatible with life. From an evolutionary standpoint, the thyroid cartilage is the newest feature of the laryngeal skeleton.[23,24] It is peculiar to placental mammals, the more primitive hyobranchial apparatus of vertebrates consisting primarily of a hyoid-cricoid framework.

The thyroid cartilage is represented in the embryo, at the end of the fourth week, as a cell mass situated immediately anterior to the fourth arch and cleft. The thyroid mass is continuous with the primordium of the greater cornu of the hyoid bone in the 9.5 mm embryo, sixth week. A week later, chrondrification is underway; the alae are markedly convex and widely separated superiorly. The inferior cornu be-

gins to develop, and in the middle of the third month (the 35 mm embryo) the inferior cornu makes contact with the thyroid cartilage. The thyroid alae join ventrally first at the lower ends.[25]

During puberty in boys, as the larynx grows rapidly, the vocal cords normally become about 1 cm longer, contributing to the normal lowering of pitch which occurs at this time.[26] In our patient, as the laryngeal skeleton enlarged at puberty, nonfusion and overlapping of the thyroid laminae precluded the normal lengthening of the vocal cords and left him with his high-pitched voice.

Possibly if a diagnosis of anterior nonfusion of the thyroid laminae is kept in mind, a few more males will not be called "Miss" on the telephone.

REFERENCES

1. Finlay HVL: Familial congenital stridor. Arch Dis Child 24:219-233, 1949

2. Palmer HD: Clinicopathologic conference: congenital cricoid cartilage defect. Q Med Bull Children's Hosp, Denver, 3:168-181, 1951

3. Holinger PH, Brown WT: Congenital webs, cysts, laryngoceles and other anomalies of the larynx. Ann Otol Rhinol Laryngol 76: 744-752, 1967

4. Pettersson G: Inhibited separation of the larynx and the upper part of the trachea from esophagus in a newborn. Acta Chem Scand 110:250-254, 1955

5. Triboletti E: Unusual congenital anomaly involving the larynx, trachea, and esophagus. N Engl J Med 258:1002-1003, 1958

6. Fisher JH: Extensive tracheoesophageal communication. Bronches 19:105-109, 1961

7. Zachary RB, Emery JL: Failure of separation of larynx and trachea from esophagus: persistent esophagotrachea. Surgery 49: 525-529, 1961

8. Cameron AH, Williams TC: Cleft larynx: a cause of laryngeal obstruction and incompetence. J Laryngol Otol 76:381-387, 1962

9. Blumberg JB, Stevenson JK, Lemire RJ, *et al*: Laryngotracheoesophageal cleft, the embryologic implications: review of the literature. Surgery 57:559-566, 1965

10. Harrison HS, Fuqua EB, Griffin RB: Congenital laryngeal cleft: report of a case. Am J Dis Child 110:556-558, 1965

11. Griscom NT: Persistent esophagotrachea, the most severe degree of laryngotracheoesophageal cleft. Amer J Roentgenol Radium Ther Nucl Med 97:211-215, 1966

12. Shapiro MJ, Falla A: Congenital posterior cleft larynx (laryngotracheoesophageal cleft): report of a case. Ann Otol Rhinol Laryngol 75:961-967, 1966

13. Jahrsdoerfer RA, Kirchner JA, Thaler SU: Cleft larynx. Arch Otolaryngol 86:108-113, 1967

14. Delahunty JE, Cherry J: Congenital laryngeal cleft. Ann Otol Rhinol Laryngol 78: 96-106, 1969

15. Imbrie JD, Doyle PJ: Laryngotracheoesophageal cleft: report of a case and review of the literature. Laryngoscope 79:1252-1274, 1969

16. Haguenauer JP, Berdal P: Le diasteure larynge congenital: a propos de 6 observations. Ann Otolaryngol Chir Cervicofac 87:651-662, 1970

17. Donahoe PK, Hendren WH: The surgical management of laryngotracheoesophageal cleft with tracheoesophageal fistula and esophageal atresia. Surgery 71:363-368, 1972

18. Phelan PD, Stocks JG, Williams HE, *et al*: Familial occurrence of congenital laryngeal clefts. Arch Dis Child 48:275-278, 1973

19. Pracy R, Stell PM: Laryngeal cleft: diagnosis and management. J Laryngol Otol 88:483-486, 1974

20. Cohen SR: Cleft larynx: a report of seven cases. Ann Otol Rhinol Laryngol 84: 747-756, 1975

21. Crooks J: Noninflammatory laryngeal stridor in infancy. Arch Dis Child 29:381, 1954

22. Montgomery WW: *Surgery of the Upper Respiratory System.* Philadelphia, Lea & Febiger, 1973, vol 2, chap 8, p 570

23. Goodrich ES: *Studies on the Structure and Development of Vertebrates.* New York, Dover, 1958

24. Hyman LH: *Comparative Vertebrate Anatomy.* Chicago, University of Chicago Press, 1942

25. Myerson MC: *The Human Larynx.* Baltimore, CC Thomas, 1964

26. Pressman JJ, Keleman G: Kirchner JA (rev): *Physiology of the Larynx. Continuing Education Manual.* Rochester, Am Acad Ophthalmol Otolaryngol, 1970

———

REPRINTS—William W. Montgomery, MD, Massachusetts Eye and Ear Infirmary, 243 Charles Street, Boston, MA 02114.

DISCUSSION

JOHN A. TUCKER, MD (Philadelphia, Pennsylvania): I enjoyed Dr. Montgomery's paper in particular and I would just like to comment upon a sequence of staging, a comment on the staging sequence of development.

Under the Carnegie system of staging, the first eight weeks are divided into 23 stages or levels of development. The tracheal-esophageal septum occurs from stages 12 (ca. 3-5 mm; ca. 26 days) to 14 (ca. 5-7 mm; ca. 32 days). That period was not included here this morning.

However, the cricoid lamina is definitely noted to develop in stages 16 (ca. 8-11 mm; ca. 37 days) to 19 (ca. 16-18 mm; ca. 48 days).

However, the laminae of the thyroid cartilage do not fuse until the third month of fetal life.

DOUGLAS P. BRYCE, MD (Toronto, Canada): I was just going to ask Dr. Montgomery a question. I wonder whether there is any possibility that this was evidence of a fracture or at least an early injury, rather than congenital deformity

And, second, I was not clear and perhaps others were not, as to how the voice was improved by the second procedure?

ROBERT B. LEWY, MD: I would like to argue in the direction of simplicity. Some months ago, I wrote John a letter because I suggested instead of splitting a larynx and tying the vocal cords together on people who aspirated, he might have filled up both vocal cords with Teflon® and closed that larynx off, perhaps accomplishing the same thing with a much simpler type of procedure.

I am wondering on the last case which he presented, whether increasing the bulk of the vocal cords by adding some Teflon®, a normal laryngoscopic procedure, might not have accomplished the same voice purpose. It could be put in a position where it would not necessarily challenge the airway.

WILLIAM W. MONTGOMERY, MD (closing): Dr. Bryce's questions are well taken. The photographs do, however, demonstrate that the anterior aspect of both thyroid laminae were completely symmetrical, smooth and rounded. There is no way that this could have been due to trauma in early life.

The voice was lowered by lengthening the vocal cords. The larynx originally appeared similar to a female larynx with short vocal cords. His voice was lowered by doubling the length of each vocal cord. The second operation was necessary because the thyroid laminae did not remain fused anteriorly after the keel was removed.

Dr. Lewy, a Teflon® injection might possibly have jeopardized the airway in this case. It seems to me that such an injection would tend to raise the voice rather than lower it.

VERRUCOUS CARCINOMA OF THE LARYNX
MANAGEMENT BY RADIOTHERAPY AND SURGERY

HUGH P. BURNS, MB

A. W. PETER VAN NOSTRAND, MD DOUGLAS P. BRYCE, MD

TORONTO, CANADA

SUMMARY — Verrucous carcinoma is an unusual and distinct variant of well differentiated squamous cell carcinoma, and accounts for approximately 1 to 2% of all primary squamous cell carcinomas of the larynx. There has been considerable controversy regarding the role of radiotherapy in the management of these tumors, as they are said to be radioresistant, and in a number of instances "anaplastic transformation" has apparently occurred following such therapy. We have reviewed 18 patients with verrucous carcinoma of the larynx in which eight received surgical therapy alone, eight received radiotherapy alone, and two received combined therapy. We conclude that radiotherapy and surgery are equally effective in eradicating the disease. "Anaplastic transformation" of these tumors represents a small but nevertheless real risk following radiotherapy. Accordingly, our current therapeutic policy is to treat by surgical excision those smaller tumors which can be removed by conservation laryngectomy procedures, reserving radiotherapy for those large tumors which would require total laryngectomy if treated surgically.

Verrucous carcinoma is a distinct variant of well differentiated squamous cell carcinoma. Ackerman[1] first coined the term "verrucous carcinoma" in 1948, and delineated the interesting and peculiar, clinical and pathological characteristics of this group of neoplasms.

Ackerman emphasized the following features: Most lesions occur in elderly men, usually on the buccal mucosa and lower gingiva. Tobacco chewing may be of etiologic significance. The lesions have a warty, papillomatous appearance, tend to grow slowly, but may be very extensive and tend to invade local structures, for example, bone structures. With coexisting infection, the regional lymph nodes are often enlarged and tender, but metastasis to local lymph nodes is very unusual, and distant metastasis has not been documented. Microscopically, these lesions are extremely well differentiated, and have papillary surface projections and downgrowth of club-shaped, finger-like processes of squamous epithelium. Hyperkeratosis is a prominent feature. The advancing margin of the tumor has pushing borders associated with a prominent chronic inflammatory infiltrate.

The oral cavity is the most common site. Other sites include the larynx, external genitalia, nasal fossa, and esophagus. Verrucous carcinoma may account for up to 10% of all squamous cell carcinomas of the buccal mucosa. One to 2% of all squamous cell carcinomas of the larynx are of the verrucous variety.[2]

There has been considerable controversy regarding the role of radiotherapy in the management of these tumors, as they are said to be radioresistant, and in a number of instances, "anaplastic transformation" has apparently occurred following such therapy. In their review of 105 cases, Kraus and Perez-Mesa[3] indicated that radiotherapy was employed in 17 patients, and failed to control the lesion in all instances. In 4 of the 17 patients a sudden alteration in the character of the lesion to an anaplastic pattern occurred. These lesions

From the Departments of Otolaryngology and Pathology, University of Toronto, and Toronto General Hospital, Toronto, Canada. This work has been supported in part by the Charlie Conacher Cancer Research Fund.

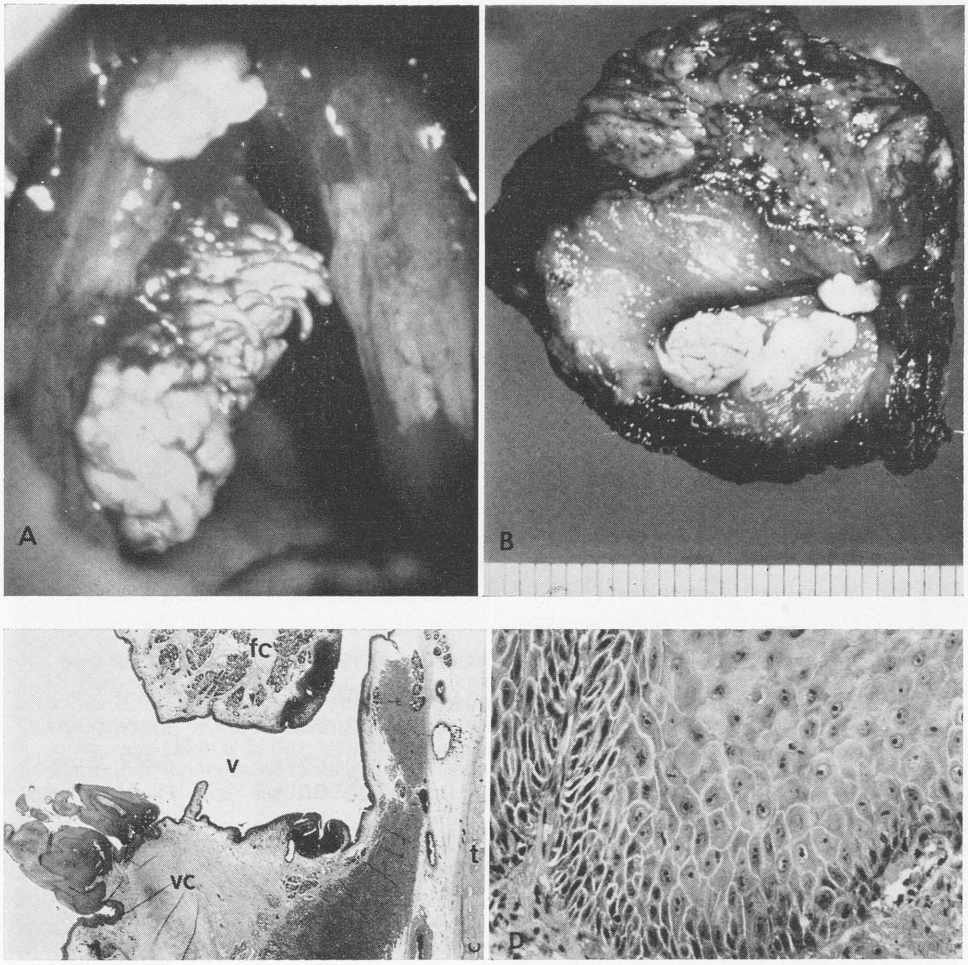

Fig. 1. (Case 6) A) Endoscopic view of a multifocal papillary lesion confined to the left vocal cord of a 53-year-old male. B) Gross photograph of the left vertical hemilaryngectomy specimen illustrating the multifocal nature of the lesions and emphasizing the white warty appearance. C) Low power photomicrograph of the hemilaryngectomy specimen. The papillary verrucous tumor is confined to the mucosa and submucosa of the free margin of the vocal cord (vc) (H & E X 15). fc - False vocal cord. t - Thyroid ala. v - Laryngeal ventricle. D) Photomicrograph of the advancing margin of the tumor. The "pushing" border and well differentiated nature of the neoplasm are clearly shown (H & E X 375).

grew rapidly, with distant metastases, and death attributable to the tumor rapidly followed in three patients.[3,4] Five additional cases having similar transformation have been reported.[2,5,6]

The purpose of this paper is to review the results of therapy in 18 patients with verrucous carcinoma of the larynx. We are currently conducting a similar study of 36 cases of verrucous carcinoma originating in the oral cavity.[7]

METHODS AND MATERIALS

In the Toronto area, virtually all new patients with head and neck carcinoma are referred to the Princess Margaret Hospital (a radiotherapy center) for assessment prior to therapy. In the 15 year period 1960 - 1975, of a total of approximately 1,300 cases of laryngeal carcinoma seen, 18 new cases (1.4%) of verrucous carcinoma of the larynx were diagnosed.

The clinical charts, x-rays, photographs, pathological reports and microscopic slides were examined in all instances. We adhered

TABLE I

VERRUCOUS CARCINOMA OF THE LARYNX
RESULTS OF THERAPY

Case	*Age/Sex*	*Site*	*Treatment*	*Follow-up*
1	61 M	T_{1A} G	VH	A & W 6 yr
2	77 F	T_{1B} SG	Horiz. SG. Later, TL for aspiration	A & W 1 yr
3	65 M	T_{1A} G	Cordectomy	A & W 4 yr
4	39 M	T_{1B} G	TL	A & W 13 yr
5	61 M	T_2 G	TL	A & W 14 yr
6	53 M	T_{1A} G	VH	A & W 1 yr
7	61 M	T_2 G	VH	A & W 9 mo
8	58 M	T_2 G	VH	Died with multiple separate primaries (larynx clear) - 2 yr later
9	52 F	T_3 G	Co60 5500 R/5 wk	A & W 6 yr
10	58 M	T_2 SG	Co60 4500 R/3 wk	A & W 4 yr
11	66 F	T_{1B} SG	Co60 5500 R/5 wk	A & W 2 yr
12	77 M	T_2 G	Co60 5500 R/5 wk	A & W 5 yr
13	34 F	T_2 G	Co60 5500 R/6 wk	A & W 9 yr
14	83 M	T_2 SG	Co60 5500 R/5 wk	A & W 9 mo
15	76 M	T_2 SG	Betatron 5000 R/3 wk	Died unrelated causes - 5 yr later
16	69 F	R. Ary. Ep. fold	Co60 5500 R/7 wk	Died with disseminated malignancy ("anaplastic transformation") 10 mo later
17	58 M	T_2 G	Co60 5500 R/5 wk Pos. biopsy 6/52 later TL specimen negative	A & W 7 yr
18	65 M	T_{1B} G	Co60 5500 R/5 wk for SCC - developed verrucous ca 3½ yr later, treated by TL	A & W 9 yr

G - Glottic; SG - Supra-glottic; R. Ary. Ep. - Right aryepiglottic; VH - Vertical hemilaryngectomy; TL - Total laryngectomy; Co60 - Cobalt-60; A & W - Alive and well.

to the diagnostic criteria laid down by Ackerman,[1] and amplified by Kraus and Perez-Mesa,[4] and others.[2]

The details of the clinical features, treatment and follow-up of the 18 laryngeal cases are provided in Table I. Twelve of the 18 laryngeal cases were of glottic origin, and presented with voice disturbance. The remaining six cases were of supraglottic origin and presented with dysphagia, discomfort in the throat and/or sore throat. The average age was 62 years, with a range of from 34 to 85 years.

RESULTS

Of the 18 patients, 8 were treated by surgery alone. Six patients had a partial laryngectomy performed (Fig. 1) and two patients had a total laryngectomy. Follow-up revealed seven patients to be alive and well from nine

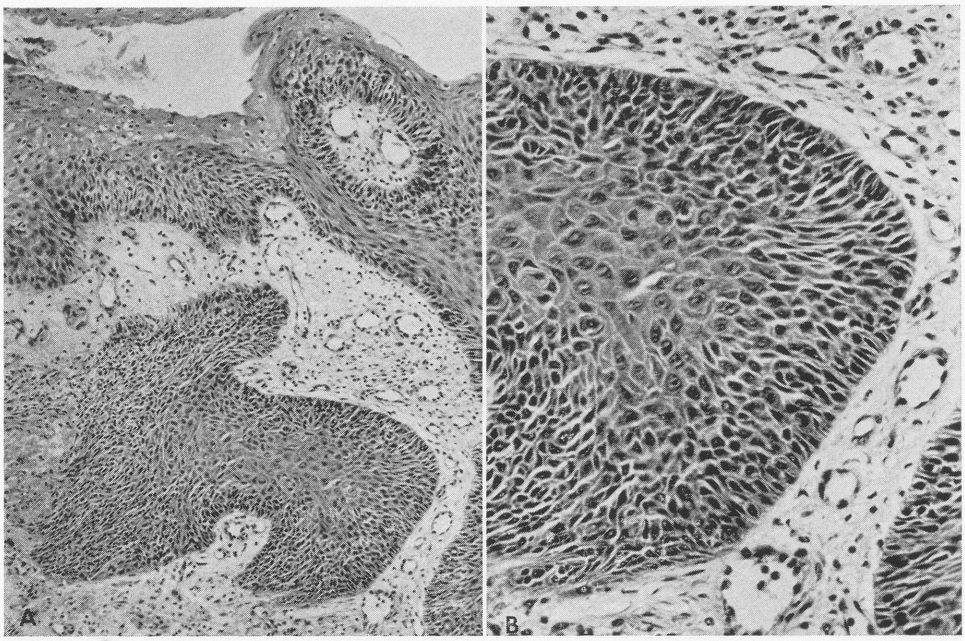

Fig. 2. (Case 10) Photomicrographs of the laryngeal biopsy specimen from a 58-year-old male with a T_2 supraglottic tumor. This patient received radiotherapy and is free of disease four years following treatment. A) A low power view illustrating the keratinization of the surface of the lesion (top) and the islands of tumor in the vascular submucosa (H & E X 60). B) The same field under greater magnification. The normal maturation sequence of the squamous cells and the well defined margins of the tumor are readily evident (H & E X 375).

months to 14 years following treatment. One patient died two years later of multiple, separate primaries (stomach, lung, thyroid) without evidence of recurrent or residual disease in the larynx.

Eight patients were treated with radiotherapy alone (Figs. 2, 3). Cobalt-60, 4500 - 5000 rads was administered over a three to seven week period. Follow-up reveals six patients to be alive and well from nine months to eight years following completion of therapy. One patient died five years later from unrelated disease (ischemic heart disease). One patient died ten months later of "anaplastic change" resulting in widespread distant metastases.

Two patients received combined therapy. Both deserve special mention. The first patient had a T_2 glottic lesion treated with cobalt-60, 5500 rads over five weeks, with a positive biopsy some six weeks later. A total laryngectomy was performed 12 weeks after completion of the course of radiotherapy, and the laryngectomy specimen was negative for tumor. This patient is alive and well seven years following treatment. The second patient had a squamous cell carcinoma of the larynx, staged as T_{1B} glottic, treated with cobalt-60, 5500 rads over five weeks. The lesion regressed, but 3½ years later, at the same site, another tumor arose which had the typical gross and microscopic features of a verrucous carcinoma. This man was treated by total laryngectomy, and is alive and well nine years later.

CONCLUSIONS

Contrary to previous reviews, verrucous carcinoma, at least when it occurs in the larynx, can be successfully treated by radiotherapy alone. In our material, the results of treatment by radiotherapy alone are equally as good as by surgery alone.

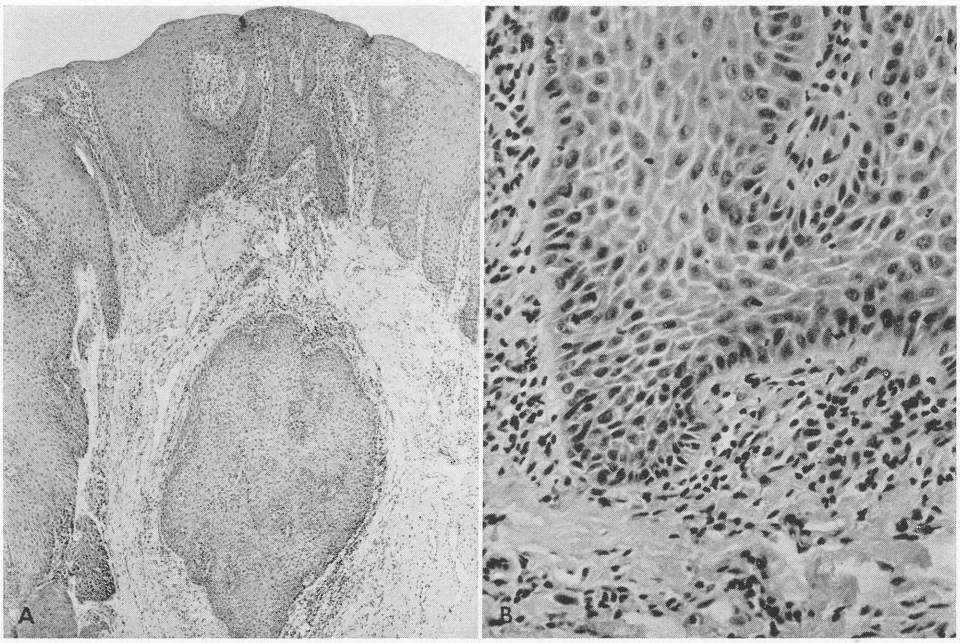

Fig. 3. (Case 11) Photomicrographs of the laryngeal biopsy specimen from a 66-year-old female with a T_{1B} supraglottic tumor. This patient received radiotherapy and is free of disease two years following treatment. A) Low power view showing the well differentiated nature of the lesion and prominent inflammatory halo adjacent to the advancing margin of the tumor (H & E X 60). B) Another portion of the same biopsy specimen under higher magnification. The halo of lymphocytes is clearly seen in the submucosa adjacent to the tumor. Close cooperation between the clinician and the pathologist is essential in order to establish the diagnosis in such cases (H & E X 375).

"Anaplastic transformation" occurred in one of our ten cases of verrucous carcinoma treated by radiotherapy. This patient received 5500 rads of cobalt-60 over seven weeks for a "supraglottic" tumor, occupying the right aryepiglottic fold; this had the typical gross and microscopic appearance of a verrucous carcinoma. Less than five months later the tumor had enlarged, and a biopsy showed anaplastic tumor. This lady died ten months after radiotherapy, with a clinical diagnosis of disseminated malignancy, although permission for autopsy could not be obtained. While the interval between the completion of radiotherapy and the appearance of the anaplastic tumor would appear to be rather short (five months), this interval is similar to that recorded in the eight cases previously reported in the literature (two to seven months).[3-6] The risk of such transformation occurring is difficult to assess, but does appear to be a real one. We have not encountered a similar transformation in 30 cases of oral cavity lesions receiving radiotherapy.[7]

It is from an analysis of these results that our current therapeutic policy has evolved. At the present time, surgery alone is used on those tumors that are small enough and localized enough to be removed by "voice conserving" partial laryngectomy procedures. Radiotherapy alone is used for those tumors sufficiently large to require a total laryngectomy, if treated surgically.

REFERENCES

1. Ackerman LV: Verrucous carcinoma of the oral cavity. Surgery 23:670-678, 1948

2. van Nostrand AWP, Olofsson J: Verrucous carcinoma of the larynx. A clinical and pathologic study of 10 cases. Cancer 30:691-702, 1972

3. Kraus FT, Perez-Mesa C: Verrucous carcinoma. Clinical and pathologic study of

105 cases involving oral cavity, larynx and genitalia. Cancer 19:26-38, 1966

4. Perez CA, Kraus FT, Evans JC, *et al*: Anaplastic transformation in verrucous carcinoma of the oral cavity after radiation therapy. Radiology 86:108-115, 1966

5. Fonts EA, Greenlaw RH, Rush BF, *et al*: Verrucous squamous cell carcinoma of the oral cavity. Cancer 23:152-160, 1969

6. Proffit SD, Spooner TR, Kosek JC: Origin of undifferentiated neoplasm from verrucous epidermal carcinoma of oral cavity following irradiation. Cancer 26:389-393, 1970

7. Burns HP, van Nostrand AWP, Palmer J: Verrucous carcinoma of the oral cavity. Management by radiotherapy and surgery, to be published.

———

ACKNOWLEDGMENTS—The laryngeal sectioning was performed by Kenneth Ekem and Janice Etty. Jean Cetkovski typed the manuscript.

REPRINTS—A. W. Peter van Nostrand, MD, Department of Pathology, Banting Institute, 100 College Street, Toronto, Canada, M5G IL5.

MUCUS GLAND TUMORS OF THE LARYNX AND LARYNGOPHARYNX

RONALD H. SPIRO, MD
JOHN S. LEWIS, MD
STEVEN I. HAJDU, MD
ELLIOT W. STRONG, MD

NEW YORK, NEW YORK

SUMMARY — During the 30-year period from 1939 through 1968, 20 patients were seen who had "minor salivary" tumors arising in the mucus glands of the larynx or laryngopharynx. This group comprised about 3% of more than 600 patients with mucus gland tumors of the upper aerodigestive tract treated at Memorial Sloan-Kettering Cancer Center during the same interval. In each instance the tumor was malignant, and all but three of these patients were men. Location and histology of these uncommon tumors is described. Only 2 of 18 treated cases were "cured." Uncontrolled cervical lymph node involvement or distant metastasis was more often the reason for treatment failure, rather than local recurrence at the primary site.

It is well known that mucus glands beneath the epithelium of the upper respiratory and digestive tract may occasionally give rise to tumors histologically identical to those occurring in the major, or paired salivary glands. In most instances, these so-called minor salivary neoplasms are found in the mouth, usually in the palate. At times, the nasal cavity or paranasal sinuses may be involved. In this report we direct attention to the larynx and laryngopharynx as a most unusual site for salivary type neoplasms.

During the years 1939 through 1968, 21 patients who had a salivary neoplasm arising in the larynx or laryngopharynx were seen at Memorial Sloan-Kettering Cancer Center. This group comprised only 3% of more than 600 patients with minor salivary gland tumors, or 0.8% of 2,793 patients with cancer of the larynx seen during the same 30-year interval.[1] As reported previously from our hospital, most nonepidermoid carcinomas of the larynx proved to be of mucus gland origin.[2]

HISTOPATHOLOGY

All of the patients in this series had malignant tumors, but other reports suggest that any type of salivary neoplasms, whether benign or malignant, may occur in the larynx or laryngopharynx.[3-8] One exception seems to be acinic cell carcinoma, which only rarely occurs in mucus glands.[1] No histologic material is available in one patient who was treated elsewhere, and this case has been excluded.

Using a classification which is a modification of that originally proposed by Foote and Frazell,[9] the tumor proved to be an adenocarcinoma in 13 patients. Most of these were of the solid variety and showed a striking resemblance to mammary carcinoma in some instances. These tumors infiltrated the submucosal connective tissue in cell cords and clusters; a minimal connective tissue stroma was present between the tumor cells. Reactive histiocytes and lymphocytes were seen in many tissues sections, but necrosis of the tumor was rare (Fig. 1). Others showed a small cell pattern with features suggestive of carcinoid tumors. Mucus production was conspicuous in one patient who had an adenocarcinoma, and another had a most unusual tumor with Pagetoid changes in the overlying mucous membrane (Fig. 2).

From the Head and Neck Service, Department of Surgery, and the Department of Pathology, Memorial Sloan-Kettering Cancer Center, New York, New York.

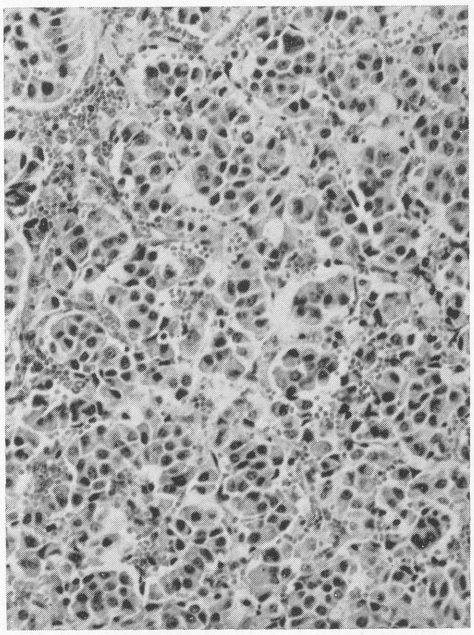

Fig. 1. Adenocarcinoma of solid duct cell type (H & E X170).

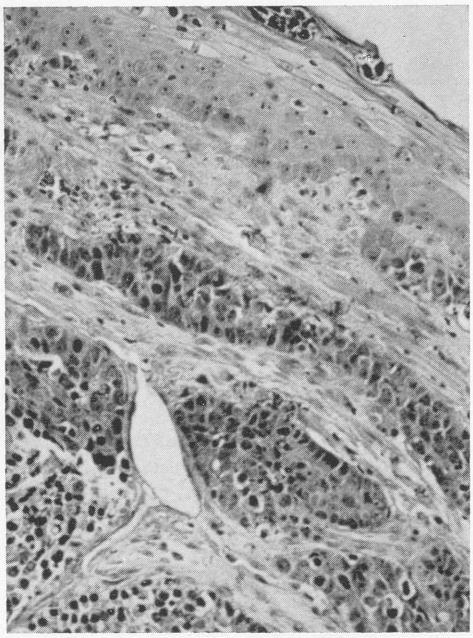

Fig. 2. Adenocarcinoma in the submucosa and areas of Pagetoid change in the surface mucosa (H & E X170).

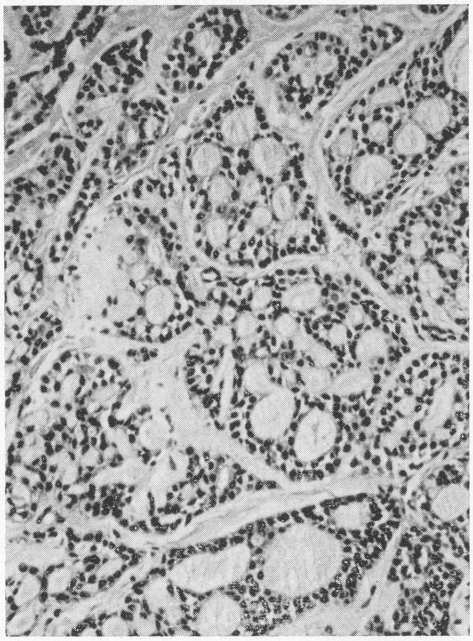

Fig. 3. Adenoid cystic carcinoma. Note transition from a low grade, glandular appearance on the right, to cord-like structures suggestive of a higher grade tumor on the left (H & E X170).

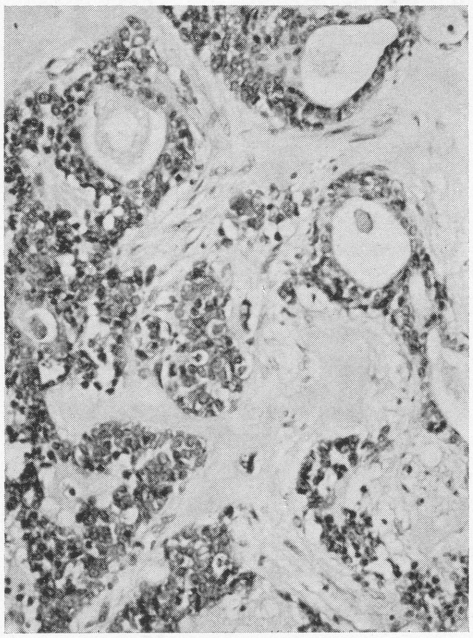

Fig. 4. Mucoepidermoid carcinoma, histologic Stage II (H & E X170).

TABLE I

HISTOPATHOLOGY AS RELATED TO SITE OF ORIGIN

	Adeno-carcinoma	*Adenoid Cystic Carcinoma*	*Muco-epidermoid Carcinoma*	*Anaplastic Carcinoma (oat cell)*	*Total*
Glottic	2	1	1	—	4
Supraglottic					
Epiglottis	2	2	1	1	6
Ventricular band	4	—	—	—	4
Aryepiglottic fold	4	—	1	—	5
Pyriform	1	—	—	—	1
Total	13	3	3	1	20

Adenoid cystic carcinoma was the diagnosis in three patients whose tumors showed features ranging from glandular arrangement to cell clusters or cell cord formation (Fig. 3). Gland formation with mucinous material in the lumen and areas composed of poorly differentiated cells helped to identify the tumor as mucoepidermoid carcinoma in three others (Fig. 4). One patient had an anaplastic carcinoma which closely resembled oat cell carcinoma of the lung.[10] Distribution of the various histologic types according to the site of origin is given in Table I.

OBSERVATIONS

The patients ranged in age from 38 through 79 years (median 59 years) and all but three were men. Symptoms varied in duration from one month to four years and hoarseness was the usual presenting complaint (12 patients). Sore throat (five patients), dysphagia (four patients), cough (three patients), and the sensation of a foreign body in the throat (three patients) were also noted. In three instances, a lump in the neck was the main reason the patient sought medical attention. Treatment had previously been given elsewhere in four patients.

TABLE II

CLINICAL STAGE ACCORDING TO SITE IN 16 PREVIOUSLY UNTREATED PATIENTS

	Stage I	*Stage II*	*Stage III*	*Stage IV*
Glottis	1	1	1	1
Epiglottis	—	2	3	—
Ventricular band	—	—	3	—
Aryepiglottic fold	—	—	3	—
Pyriform fossa	1	—	—	—
Total	2	3	10	1

The tumor involved the supraglottic larynx in 15 patients, 6 of whom had lesions in the epiglottis. Aryepiglottic folds or ventricular bands were the site of origin in five and four instances, respectively. The lesion involved the glottic larynx in four patients and one had a tumor located in the pyriform fossa.

With few exceptions, these patients had sizeable exophytic or ulcerated growths which were thought to be epidermoid carcinoma. The examining physician suspected that the tumor was unusual in one patient who had intact mucous membrane over a swelling involving a ventricular band, and in two others who had a pedunculated lesion on the medial wall of the pyriform fossa and aryepiglottic fold, respectively.

Most had tumors which were locally advanced by the time they were first seen. Moreover, cervical lymph nodes were initially involved in seven instances, including one patient who had bilateral metastases. According to the criteria proposed by the American Joint Committee on Staging,[11] 10 of 16 previously untreated patients had Stage III lesions, whereas three had Stage II, two

TABLE III

RESULTS IN 18 TREATED PATIENTS

Age Sex	*Primary Histology Clinical Stage*	*Iniitial Treatment*	*Result*	*Comment*
50 M	Glottic Adenocarcinoma Stage IV	Laryngectomy	DOD 1 yr, 3 mo	Lung and visceral metastases
53 M	Glottic Adenocarcinoma Stage III	Laryngectomy	DOC 1 yr	Neck recurrence
57 M	Glottic Adenoid cystic Stage II	Laryngectomy	DOD 2 yr	Carcinomatosis
55 M	Glottic Mucoepidermoid Stage I	Laryngectomy	NED 10 yr	Small commissure lesion
59 M	Epiglottis Mucoepidermoid Stage III	Laryngectomy and neck dissection	DOD 7 mo	Neck recurrence and bone metastases
70 F	Epiglottis Adenoid cystic Stage III	External irradiation	DOD 6 yr, 5 mo	Local recurrence
38 M	Epiglottis Adenoid cystic Stage II	External irradiation	DOC 6 mo	Hemorrhage due to radionecrosis
79 M	Epiglottis Anaplastic Stage III	Epiglottectomy and neck dissection	DOD 6 mo	Carcinomatosis
51 F	Epiglottis Adenocarcinoma (Prev. treated)	Chemotherapy	DOD 3 mo	Metastases present initially
64 M	Ventricular band Adenocarcinoma Stage III	Laryngectomy	DOC 9 mo	Tumor incompletely excised
70 M	Ventricular band Adenocarcinoma Stage III	Laryngectomy and neck dissection	DOD 5 mo	Neck recurrence
65 M	Ventricular band Adenocarcinoma (Prev. treated)	Laryngectomy, bilateral neck dissection	Postoperative death	Cerebrovascular accident
77 M	Ventricular band Adenocarcinoma Stage III	Laryngectomy	DOC 4 yr, 3 mo	Neck recurrence and distant metastases
41 M	Aryepiglottic fold Adenocarcinoma (Prev. treated)	Laryngectomy and neck dissection	DOD 4 yr	Neck recurrence lung metastases
70 M	Aryepiglottic fold Adenocarcinoma Stage III	Laryngectomy	DOD 1 yr, 6 mo	Local and neck recurrence and bone metastases
50 F	Aryepiglottic fold Adenocarcinoma Stage III	Laryngofissure excision and radical neck	DOD 3 yr, 7 mo	Local and neck recurrence
72 M	Aryepiglottic fold Adenocarcinoma (Prev. treated)	Laryngectomy and neck dissection	DOD 5 yr, 9 mo	Lung and brain metastases
57 M	Pyriform fossa Adenocarcinoma Stage I	Laryngectomy and neck dissection	NED 11 yr	Small pedunculated lesion

DOD - Died of disease; DOC - Died of other causes; NED - No evidence of disease

TABLE IV

CERVICAL LYMPH NODE INVOLVEMENT IN 18 TREATED PATIENTS

	No. of Patients	*Involved Initially*	*Involved Subsequently*	*Never Involved*
Adenocarcinoma	12	5*	4	3
Adenoidcystic carcinoma	3	—	1	2
Mucoepidermoid carcinoma	2	1	—	1
Anaplastic carcinoma	1	1	—	—
Total	18	7	5	6

* Bilateral involvement in one patient.

had Stage I and one had Stage IV disease, respectively (Table II).

TREATMENT AND RESULTS

No treatment was given in one patient who had an extensive primary, as well as a synchronous adenocarcinoma of the prostate, and another who refused laryngectomy and went elsewhere. Of the remaining 18 patients, irradiation was the only treatment in 2, both of whom were seen in the early years of this study. Laryngectomy was required in 13 patients, one had an epiglottectomy and another had local excision of a recurrence through a laryngofissure approach. Radical neck dissection was performed initially in nine patients, seven of whom had clinical evidence of cervical lymph node involvement. Chemotherapy alone was the treatment in one patient who presented with disseminated metastatic disease after irradiation elsewhere.

Postoperative death occurred in the one patient who had simultaneous bilateral radical neck dissection. In 11 patients, uncontrolled or metastatic mucus gland carcinoma was directly responsible for death, with survival ranging from seven months to 6½ years. One other patient died elsewhere within six months and is presumed to have been a treatment failure. Death due to other causes was recorded within nine months to four years in three additional patients who also had evidence of tumor recurrence. One patient who had a small, pedunculated adenocarcinoma in the pyriform fossa remains alive and well 14 years after total laryngectomy and radical neck dissection. Another remained free of disease ten years after laryngectomy for a small, glottic mucoepidermoid carcinoma and was then lost to follow-up (Table III).

Information about treatment failure was available in 14 of the 15 patients who survived initial treatment and subsequently died of or with disease. Local recurrence was documented in only four patients, one of whom had incomplete excision of an extensive primary tumor at the time of laryngectomy. Failure to control cervical lymph node metastasis, noted in nine instances, was a more frequent problem. In all, 12 of the 18 treated patients had evidence of cervical lymph node involvement at some time during the course of the disease (Table IV).

Including one patient who died postoperatively and was found to have unsuspected disseminated metastases on postmortem examination, a total of nine treated patients had distant metastasis (50%). This propensity for distant dissemination was evident for each histologic variety of tumor, and multiple sites were usually involved.

SUMMARY AND CONCLUSIONS

On rare occasion, mucus glands of the larynx and laryngopharynx may give rise to typical salivary type neoplasms. Twenty such cases are reported which comprise about 3% of our total minor salivary gland tumor experience during a 30-year period. The neoplasm in each instance was malignant and was usually extensive when most of these

patients were initially examined. The preferred treatment was surgical, but only 2 of 18 treated patients were long term "cures." Uncontrolled cervical node metastasis or distant dissemination of tumor was more often the reason for treatment failure than local recurrence. Our experience suggests that the results might possibly have been improved if regional lymph nodes had been treated more aggressively, either by more liberal use of elective radical neck dissection or by combinations of radiation therapy and surgery.

REFERENCES

1. Spiro RH, Koss LG, Hajdu SI, *et al*: Tumors of minor salivary origin, a clinicopathologic study of 492 cases. Cancer 31:117-129, 1973

2. Cady B, Rippey JH, Frazell EL: Nonepidermoid cancer of the larynx. Ann Surg 167:116-120, 1968

3. Ahued SV: Cylindroma of the epiglottis. Arch Otolaryngol 63:366-371, 1956

4. Donald PJ, Krause CJ: Papillary cystadenoma of the larynx. Laryngoscope 83:2024-2028, 1973

5. Jokinen K, Seppala A, Palva A: Laryngeal pleomorphic adenoma. J Laryngol Otol 88:1131-1134, 1974

6. New GB, Erich JB: Adenocarcinoma of the larynx. Ann Otol Rhinol Laryngol 50:706-712, 1941

7. Olofsson J, van Nostrand AWP: Anaplastic small cell carcinoma of the larynx. Ann Otol Rhinol Laryngol 81:284-287, 1967

8. Sabri JA, Hajjar MA: Malignant mixed tumor of the vocal cord. Arch Otolaryngol 85:118-120, 1967

9. Foote FW Jr, Frazell EL: Tumors of the major salivary glands. Cancer 6:1065-1133, 1953

10. Koss LG, Spiro RH, Hajdu SI: Small cell (oat cell) carcinoma of minor salivary gland origin. Cancer 30:737-741, 1972

11. *Clinical Staging System for Carcinoma of the Larynx, Revision.* Chicago, American Joint Committee for Cancer Staging and End Results Reporting, 1972, pp 1-16

REPRINTS—Ronald H. Spiro, MD, Memorial Sloan-Kettering Cancer Center, 1275 York Ave., New York, NY 10021.

GRANULAR CELL TUMORS OF THE LARYNX

HARVEY L. COATES, MB THOMAS J. MCDONALD, MD
KENNETH D. DEVINE, MD LOUIS H. WEILAND, MD
ROCHESTER, MINNESOTA

SUMMARY — Granular cell tumors of the larynx are relatively uncommon, always benign, and most commonly located in the posterior portion of the larynx. They are easily identified and should be differentiated from other lesions. A possible problem in the differential diagnosis is the presence of pseudoepitheliomatous hyperplasia, which overlies the granular cell tumor and which may mimic squamous cell carcinoma. Careful histopathologic differentiation is important because the laryngeal granular cell lesion should be managed conservatively, with transoral local excision usually being adequate. The histogenesis of these lesions remains in doubt, with a neural or epithelial derivation being the most likely possibility.

Granular cell tumors are uncommon benign lesions distributed mainly in mucous membranes of the head and neck.* Differentiation from squamous cell carcinoma is important because granular cell tumors are treated conservatively. Confusion and inappropriate treatment occur when pseudoepitheliomatous hyperplasia, which frequently overlies granular cell tumors, is misinterpreted as squamous cell carcinoma.

We present 12 new cases to stress the clinical and histopathologic features that differentiate these lesions from others occurring in the larynx, especially squamous cell cancers. In addition, current concepts on the histogenesis of this lesion are reviewed.

OBSERVATIONS

Clinical Features. The series included 12 patients with histologically proved granular cell tumors. Eight were men and four were women; at the time of diagnosis, their ages ranged from 23 to 64 years (Table 1). All patients had smoked the equivalent of one or more packages of cigarettes daily. Five of the patients had their lesions noted on routine indirect laryngoscopy, and five others had their lesions noted during examination for hoarseness and throat discomfort.

One unexpected finding was that 2 of the 12 patients had coexisting squamous cell carcinoma and presented with symptoms — pain and hemoptysis — caused by their cancers. In one of the patients, the preoperatively noted granular cell tumor was situated on the posterior portion of the true vocal cord, separate from the coexisting supraglottic squamous cell carcinoma. In the other patient, a large squamous cell cancer involved the base of the epiglottis, anterior commissure, and false cords. In this patient, the previously unsuspected granular cell lesion was situated on the left side of the laryngeal surface of the epiglottis, apart from the squamous cell cancer. In 11 of 12 cases, the granular cell tumors occurred in the posterior portion of the vocal cord in the region of the arytenoid process.

Morphologic Features. The tumors are usually described as small (0.2 to 0.8 cm), gray to yellow, and subepithelial. All had an intact but distinctly attached overlying epithelial layer. One of the tumors was pedunculated. Microscopically, the tumors feature cells that have given rise to their descriptive name

* Weiland LH, Ryan RE Jr, McDonald TJ: Unpublished data.

From the Mayo Clinic and Mayo Foundation, Rochester, Minnesota.

TABLE I

CLINICAL FEATURES OF 12 PATIENTS WITH GRANULAR CELL TUMORS OF THE LARYNX

Case	Sex and age, yr	Symptoms	Site	Characteristics	Diameter of tumor (cm)	Treatment	Other
1	M 58	Sore throat, hemoptysis	Post V.C.†	Gray lesion	10 x 2 x 2	Removed in laryng.	1½ PPD
2	F 45	Hoarseness	Interaryt. region	Granulomatous mass	8	Laryngofissure	1 PPD
3	F 49	None, routine exam	Aryt. region	Gray lesion	6	T.e.	1 PPD; SCC biopsied
4	M 39	None, routine exam	Aryt. region	Pink matchhead appearance	2	T.e.	2 PPD; Also SCC of lip
5	M 36	Hoarseness	Post. V.C.	White-gray cyst	5	T.e.	2 PPD
6	M 51	None, routine exam	Post. V.C.	White-yellow tumor	3	T.e.	1 PPD
7	M 23	None, routine exam	Post. V.C.	Pedunculated lesion	4	T.e.	1 PPD
8	M 45	None, routine exam	Post. V.C.	Not mentioned	Not mentioned	T.e.	1 PPD
9	F 32	Sore throat	Aryt. region	Gritty gray appearance	4	T.e.	1 PPD; SCC diagnosed
10	F 42	Soreness	Interaryt. region	Yellow lesion	5	T.e.	1 PPD
11	M 64	Hoarseness	Aryt. region	Firm mass	6	T.e.	1 PPD
12	M 57	Dysphagia, otalgia	Epiglottis‡	Not mentioned	Not mentioned	Laryng.	2 PPD

Post. V.C. - Posterior vocal cord. † - Associated with supraglottic and laryngeal squamous cell carcinoma. Interaryt. - Interarytenoid. Aryt. - Arytenoid. ‡ - Associated with squamous cell carcinoma of the base of the epiglottis, anterior commissure, and false cords. Laryng. - Laryngectomy. T.e. - Transoral excision. PPD - Packages of cigarettes smoked per day. SCC - Squamous cell carcinoma.

(Fig. 1). The cells are large, have abundant granular eosinophilic cytoplasm, and have relatively small and inconspicuous nuclei. Because cytoplasmic borders are indistinct, there is a resulting syncytium of cells without any semblance of encapsulation. The cells do not have malignant features, but the closely adjacent squamous epithelium may undergo hyperplasia. With inadequate biopsy and lack of awareness, this may lead to an erroneous diagnosis of carcinoma.

Treatment. The two patients with coexisting squamous cell cancers underwent laryngectomy. One patient underwent laryngofissure for removal of the tumor; the remaining nine patients had transoral excision of the lesion. There were no recurrences.

DISCUSSION

The term "granular cell myoblastoma" was coined by Abrikossoff[1] in 1926.

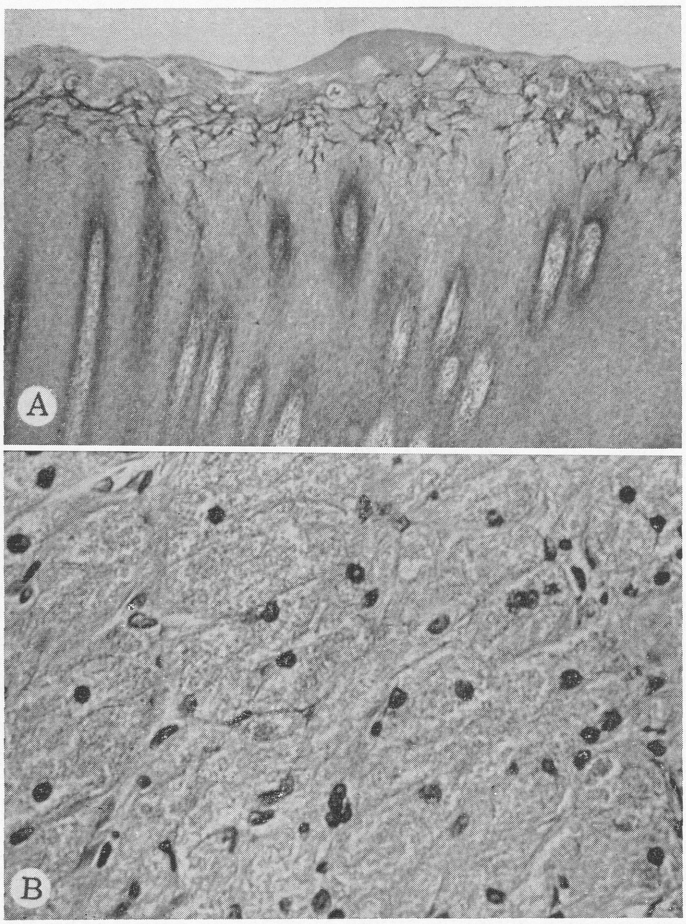

Fig. 1. Granular cell tumor. A) Pseudoepitheliomatous hyperplasia (H&E X50). B) Showing typical appearance (H&E X500).

Several reports before his had described an identical lesion.[2] The choice of this term was based on the theory that the granular cells which typified these tumors were derived from striated cells of embryonic muscle, the myoblasts. Numerous isolated reports and small reviews on the subject have followed.[3-5] In addition to the skeletal muscle cell as the possible cell of origin, the derivation of the granular cell also has been ascribed to histiocytes,[6] fibroblasts,[7] nerve sheath cells,[8] and mesenchymal cells.[9] Current studies strongly support a neurogenic origin, whereas some believe cells of diverse origin can become granular cells.

Granular cell tumors have been frequently noted in the head and neck region[4,5] and are especially common on the tongue.[9] In 1970, Booth and Osborn[10] reviewed 69 cases of laryngeal granular cell tumors. Our review of the literature includes 15 additional cases.[11-14] With the present 12 cases, the total number of cases involving granular cell tumors of the larynx is now 96.

The characteristics of the laryngeal lesions in the present 12 cases are similar to those reported by others.[4,5,10] A possible problem in the differential diagnosis concerns pseudoepitheliomatous hyperplasia and squamous cell carcinoma. The need for a close working relationship between the pathologist and the clinician is obvious. We have found that frozen-section diagnosis in

granular cell tumors is both reliable and convenient.

Granular cell tumors of the larynx are "silent" lesions. The patient is usually seen by the otolaryngologist not because of complaints relative to the lesion but because of symptoms due to other causes, such as smoking. The granular cell tumor is usually detected incidentally. Relatively few patients present with hoarseness, perhaps because of the posterior location of the tumors on the vocal cord and the absence of ulceration. Chronic irritation has been indicated by some authors as a possible cause and may explain the interarytenoid location.[5]

In 1949, Fust and Custer[8] suggested a neural origin. This was later supported by Fisher and Wechsler[3] in 1962. More recently, Frable and Fischer[5] reported results of ultrastructure study of a congenital myoblastoma from a 1-hour-old female patient. They found no neural elements, but they noted junctional complexes between the granular cells, which suggested to them an epithelial origin.

The 12 cases of laryngeal granular cell tumors in the present series are part of approximately 90 cases, the total number of granular cell tumors in the Mayo Clinic files. None of the 90 lesions showed malignant change. Review of the lesions designated as malignant indicated that placement into one of the known categories of soft-tissue malignancies would have been more accurate.

The coexistence of the granular cell lesion with squamous cell carcinoma in two cases in our series was most unusual; this association has been reported only once before.[12] The obvious importance of this association is that the presence of one does not exclude the concomitant presence of the other.

Our study of these 12 laryngeal lesions and the 90 patients from which this series was extracted supports the concept that the embryonal muscle cell is not necessarily the cell of origin for this tumor. Until further work delineates the exact cell of origin, the term "granular cell tumor" is preferable to the probably erroneous term "granular cell myoblastoma."

REFERENCES

1. Abrikossoff A: Über Myome, ausgehend von der quergestreiften willkürlichen Muskulatur. Virchows Arch Pathol Anat Physiol 260:215-233, 1926

2. Murphy GH, Dockerty MB, Broders AC: Myoblastoma. Am J Pathol 25:1157-1181, 1949

3. Fisher ER, Wechsler H: Granular cell myoblastoma — a misnomer: electron microscopic and histochemical evidence concerning its Schwann cell derivation and nature (granular cell schwannoma). Cancer 15:936-954, 1962

4. Canalis RF, Cohn AM: Granular cell myoblastoma of the larynx. Arch Otolaryngol 91:125-127, 1970

5. Frable MA, Fischer RA: Granular cell myoblastomas. Laryngoscope 86:36-42, 1976

6. Whitten JB: The fine structure of an intraoral granular-cell myoblastoma. Oral Surg 26:202-213, 1968

7. Pearse AGE: The histogenesis of granular-cell myoblastoma (? granular-cell perineural fibroblastoma). J Pathol Bacteriol 62: 351-362, 1950

8. Fust JA, Custer RP: On the neurogenesis of so-called granular cell myoblastoma. Am J Clin Pathol 19:522-535, 1949

9. Aparicio SR, Lumsden CE: Light- and electron-microscope studies on the granular cell myoblastoma of the tongue. J Pathol 97: 339-355, 1969

10. Booth JB, Osborn DA: Granular cell myoblastoma of the larynx. Acta Otolaryngol (Stockh) 70:279-293, 1970

11. Bhatnagar HN, Schwarz HJ: Granular cell myoblastoma of larynx with papillary adenocarcinoma of thyroid. Arch Otolaryngol 90:156-158, 1969

12. Goldstein A, Thaler S, Rozycki D: Granular cell myoblastoma and carcinoma of the larynx. Arch Otolaryngol 94:366-368, 1971

13. Miglets AW, Gebhart DE, Gregg LO: Airway obstruction due to a large laryngeal granular cell myoblastoma. Laryngoscope 81: 971-978, 1971

14. Thawley SE, Ogura JH: Granular cell myoblastoma of the head and neck. South Med J 67:1020-1024, 1974

———

REPRINTS—Section of Publications, Mayo Clinic, Rochester, MN 55901.

DISCUSSION

JOHN J. CONLEY, MD (New York, New York): It is not an easy assignment to discuss these papers and I think I would like to start with the last one first, the paper by Dr. Coates, coauthored by McDonald, Weiland and Devine of the Mayo Clinic.

I think to have 12 granular cell tumors in the larynx is quite an unusual collection and to me, what they highlight is the rarity of this tumor, the fact that it is practically asymptomatic in the beginning; the fact that it is most likely, in their series, to be associated with smokers, and that it is a submucosal bulge. It does not metastasize.

It is a relatively innocuous situation over a period of years with very slow growth. They do not metastasize and the important thing, I think, for the clinician is to make a microscopic diagnosis. We are all aware of that.

Over the decades, the pathologist has had a considerable amount of difficulty trying to decide what this tumor was. The fact that two of their cases were associated with squamous cell cancer, I think, is again quite unusual and not to be expected. One of the enigmatic factors about this and a misleading factor is the pseudoepitheliomatous hyperplasia that is often associated with it.

I do think, however, that this particular tumor is now an easily diagnosable tumor by the pathologist and that it is becoming more and more accepted. It is not a tumor as mysterious as it used to be. It is considered to be a tumor of neurogenic origin. You notice there were six or seven possible origins for this tumor at one time, but they have been more or less set aside in favor of the neurogenic origin.

The treatment for it is conservative local resection. There is not anything in the book that indicates that you have to treat this tumor radically.

I would like to go to another interesting and rather rare tumor in the larynx, the paper by Drs. Bryce *et al.* Up until a pathologist in St. Louis, Dr. Ackerman specifically, identified this tumor, nobody knew that it really existed as a specific entity and this is certainly a great step forward because this tumor is a unique type of squamous cell neoplasm. The clinician looks at it and says, "This is a cancer!" and he biopsies it and gives it to the pathologist and the pathologist will not admit that it is cancer and he calls it verrucal, with atypia and hyperplasia and papillary changes, *etc.* He usually asks for another biopsy and he gets another biopsy. The clinician knows that it is a cancer and, again, he is refuted on this by the pathologist. About this time the pathologist and the clinician get together and they agree that with the clinical presentation and with this microscopic appearance that Dr. Van Nostrand demonstrated so beautifully, they decide on the basis of these two phenemona that this is low grade squamous cancer. I thing it was stated that these tumors did not respond to radiotherapy, but there is information coming from several centers now, in addition to Dr. Bryce's center, that these tumors do respond to radiotherapy almost equally as well as to surgery. This is a new development. I think here there is an analogy between the low grade squamous cancer which does not respond to small doses of radiotherapy, but if you hit a low grade squamous cell cancer with enough rads you have a very good chance of curing it, too. You have to give an adequate dose. I was a little bit surprised that in some of these cases, these tumors melted away with relatively smaller doses than 6,000 rads in a few instances that Dr. Bryce demonstrated.

Of course, the other side of the coin is that all you have to do to cure these tumors is to totally remove them. All you need is an adequate margin and you do not have to plan an elective neck dissection because they rarely metastasize when they are in the category of a verrucal cancer.

The big point here is the resolution of the controversy from the laboratory. The pathologist is inclined not to call this a cancer or malignant tumor, and the clinician is; and there has to be a coming together in this particular arena. The only way that this will be resolved is by additional stains or some other type of classification from the pathology department, which is more than just looking at these relatively benign-looking cells under the microscope. However, with the combination of the information of the surgeon, the laryngologist and the pathologist, they can be treated.

I would like to say a word about the Spiro *et al* paper. This is indeed a rare bird. Twenty cases from the Memorial series is something less than 1% of all the salivary gland tumors and is a type of indoctrination not to be aware of this entity. When you look at the larynx, you never think of the tumor of the benign or malignant salivary gland system. These all arise from the minor salivary gland system, the mucous system, and because of its rarity, you are seduced away from this possibility.

I think the other thing that is a little bit seductive in this area, or in any other area of the head and neck, is the only thing you see is the little bulge underneath the smooth mucosal pattern and this could be an adenoma, a cyst or almost anything else. So, you are looking at a bulge in the mucosa and this bulge is not apparent until it gets big enough for you to see it; so you can imagine many of these tumors are fairly well developed — I think Dr. Spiro pointed this out — by the time you have the opportunity to diagnose it.

They may become ulcerated after they have gotten so large that the mucous membrane is destroyed, but ordinarily they are not.

Therefore, you are looking at a bulge and the only thing I can say here is that with every bulge that you see in the supraglottis or subglottis or glottis, you have to do a biopsy on it to find out what it is.

These tumors are exceptionally pernicious and I think in Dr. Spiro's presentation, the "free of disease" in the long overlook was only two out of sixteen cases. Let us say about 13 or 14%, and that 66% of them presented with surgical metastases; 40% on the first examination and about another 26% as the historical development went on. So here, we have had an illumination that these very pernicious tumors have to be treated aggressively once you get the diagnosis and there is very little room for conservative treatment in these instances.

The thing that usually defeats the management program is about 50% of these tumors have distant metastases within a relatively short period of time. The reason these tumors are so difficult to conquer is that, number one, they are very small in themselves and their size immediately so permits the development of a malignant neoplastic process inside this little pinhead that it is immediately out in your body. But even though it is out in your body you do not know that it is there until you get a mass underneath the smooth mucosal surface that is big enough to call it to your attention. By that time, the tumor is far advanced.

CHARLES M. NORRIS, MD (Philadelphia, Pennsylvania): I would like to discuss briefly the paper of Drs. Lewis, *et al.* Their experience is large, considering the uncommon nature of laryngeal tumors of salivary gland origin.

I was able to find six cylindromas in the records of the Jackson Clinic going back some 30 years, excluding those which were thought to be other types of adenocarcinoma.

The experience with these does correspond quite closely with that related by Dr. Spiro. Of the six cylindromas, five were treated surgically, two by rather limited types of partial laryngectomy because they were small lesions and these two were apparently cured after 7 and 17 years respectively.

These were the only two, however, in which treatment was curative. One supraglottic case treated by supraglottic partial laryngectomy had no local recurrence, but after 8 years developed pulmonary nodules, then bone metastases, survived for another 4 years with palliative radiation (still with no local recurrence) and died after 12 years.

The two laryngectomies died also of pulmonary and bone metastases without cervical nodes, one of them in less than a year. The sixth case was offered the option of irradiation, responded well and survived 15 years. This was a lesion which involved larynx, upper trachea and esophagus, and did show an unusually good response to irradiation. Death ultimately occurred as a result of obstruction due to mediastinal involvement.

With respect to cylindromas, everyone would agree, I think, that five year cures are less significant, because patients have lived with disease far beyond this time. Certainly, the greater propensity for hematogenous metastasis has been evident, as compared with the squamous cell carcinomas, with spread to the lung, the bones and in one of our cases, the brain.

One item which Dr. Spiro did not deal with particularly was the use of irradiation, which in the cylindroma has been quite useful, not as the primary method of treatment with curative intent, but as a means of palliation. These are basically, of course, adenocarcinomas, which would not be expected to respond to radiation and yet they do seem to show regression over relatively long periods of time.

I would like to show three slides if I may. (Slide) This shows a lesion which has no particularly distinctive gross features but it was a cylindroma in which there was no local recurrence, but after 8 years metastasis to lung, bone and mediastinum. The total survival time was 12 years.

(Slide) This is an endoscopic view of the subglottic and upper tracheal lesion in which irradiation was given as an option. I think now we would not perhaps give a patient with this lesion much choice and would feel that radical surgery would be preferable. But this is the one which unexpectedly responded very well to radiation with a 15 year survival.

(Slide) And, finally, this is one I show partly because it is a nice illustration of a tracheal cylindroma, which is somewhat pedunculated, allowing resection by an external approach, repair by pedicled skin flap, with a resulting good lumen and an 8½ year survival up to this point.

This is a fine review which Drs. Lewis *et al* have given, and I am grateful for a chance to discuss it.

RECURRENT RESPIRATORY PAPILLOMATOSIS

MANAGEMENT WITH THE CO_2 LASER

M. Stuart Strong, MD

Charles W. Vaughan, MD — Gerald B. Healy, MD

Sidney R. Cooperband, MD — Manuel A. C. P. Clemente, MD

Boston, Massachusetts

SUMMARY — Recurrent respiratory papillomatosis is most common in childhood but it affects all age groups; it represents a diathesis of the aerodigestive tract so that lesions may develop at various sites — the nares, lips, pharynx, nasopharynx, larynx, tracheobronchial tree, and the lungs. Ablation of all visible papillomas with the surgical laser achieved remissions in approximately one-third of patients for one year or more; since relapses may occasionally occur 2 to 20 years later, cure can never be assumed. At the present time, management is directed towards total ablation of all visible papilloma consistent with preservation of the airway and voice; reduction of the tumor burden to minimal proportions is thought to allow the maximum opportunity for remission. As the host-papilloma relationship is unraveled, it may be possible in the future to provoke an immune response so that remissions can be predicted and produced consistently.

Recurrent papillomas, occurring in the larynx and related areas, have been a vexing problem for many decades in the United States and elsewhere. One hundred years ago, MacKenzie[1] found papillomas to be the most common benign tumor of the larynx. The myriad of treatments that have been used attest to the frustration of generations of otolaryngologists throughout the world.

When the CO_2 surgical laser became available for clinical usage in 1971, it was natural that it should be given a trial in the management of recurrent papillomas. The precision of laser surgery and the lack of bleeding occurring during laser dissection suggested that the laser might be an ideal instrument for ablation of laryngeal papillomas; the technique would provide for removal of all visible lesions and allow for preservation of important structures, such as laryngeal cartilage, vocalis muscle, and uninvolved mucosa.

During the years 1972 to 1975, 110 patients with recurrent papillomas were examined and operated upon with the surgical laser at the University Hospital and the Boston Veterans Administration Hospital. This experience has made it possible to draw conclusions regarding the complex nature of the disease, the role of the CO_2 laser in the management of recurrent papillomas and the need for investigation of the papilloma-host relationship. It appears that something more than total ablation under microscopic control will be needed before papillomas can be eradicated consistently and permanently.

METHODS AND MATERIALS

The CO_2 surgical lasers used in this study were standard 50 watt and 80 watt prototype instruments designed by American Optical Corporation. For the treatment of papillomas the laser was coupled to the Zeiss operating microscope and controlled with the micromanipulator.[2] All patients were operated upon under general anesthesia using a small bore endotracheal tube protected with aluminum tape; in the event that exposure of the interarytenoid space was inadequate (especially in children), the endotracheal tube was withdrawn and the patient was then ventilated using a Venturi system. Various combinations

of nonflammable anesthetic gasses, sedatives, narcotics and muscle relaxants were used, most often nitrous oxide, oxygen, halothane or enflurane and succinyl choline. In patients with tracheobronchial disease, the laser was coupled to a standard ventilating bronchoscope via the laser endoscopic attachment.[3]

One hundred and two patients were treated at University Hospital and eight at the Boston Veterans Administration Hospital; a few patients came from the Boston area, but many came from other parts of Massachusetts and the United States. Five patients came from overseas.

The patients were admitted to the hospital the day before operation, and almost invariably were discharged the day after surgery. No restrictions were imposed with regard to diet or talking after surgery except that patients with laryngeal disease were advised to talk softly. During the operation, patients requiring prolonged intralaryngeal manipulation were administered 40 mg of methylprednisolone intravenously. Although the interaction between the laser and soft tissue is not associated with visible postoperative edema, extensive manipulation with probes, suction tips, retractors and the laryngoscope tip may produce postoperative swelling; this sequela can be minimized by intravenous administration of steroids.

The larynx was most often exposed with a Jako-Pilling wide bore laryngoscope of appropriate size, but occasionally a difficult patient required the use of the Dedo-Pilling anterior commissure laryngoscope.

After the distribution of the papillomas had been determined, a biopsy was taken for light microscopy; 20 patients had biopsies taken of papillomas and adjacent mucosa for electron microscopy. The lesions were then ablated, often exposing submucosa, perichondrium or muscle of various parts of the larynx. If papillomas involved the anterior commissure, a fragment of papilloma was purposely left on one cord to discourage web formation; in favorable situations this residual fragment was excised at an operation four to six weeks later. After initial laser excision, patients were usually reoperated upon promptly in four to six weeks in order to reduce the tumor burden to nonvisible proportions, so that the patient would have the maximum opportunity for remission. In the event of recurrence reoperation was advised at sufficient intervals to avoid the need for tracheostomy.

Patients with tracheobronchial disease were examined with a ventilating bronchoscope and the papillomas were destroyed with the laser directed through the bronchoscope. Bronchoscopy and laser destruction were repeated often enough to preserve the lower airway if two excisions did not suggest the possibility of early remission. In some patients with massive recurrences in the larynx, attention was concentrated on preserving the patency of the tracheobronchial tree only.

Lesions in the nares, oral cavity, or nasopharynx were excised using suitable retractors or gags; to reach the vault of the nasopharynx or dorsum of the soft palate, stainless steel mirrors were used to view the lesions and reflect the laser beam onto them.

After laser surgery patients were followed as their symptoms demanded. If symptom free they were followed in the office every four months; children who could not be examined with a mirror had direct microscopic laryngoscopy under anesthesia at 6 and 12 months after the last recurrence before it was assumed that they had gone into remission.

In addition to the usual history and physical examination in the office and in the hospital prior to operation, 25 patients were tested for evidence of a cutaneous delayed hypersensitivity reaction to tuberculin, candida, streptokinase, streptodornase and trichophyton; these tests were performed at least two weeks before or two weeks after a general anesthetic and operation. The standard intradermal injections were made into the volar aspects of each forearm, two on each side, and the results were read 48 hours later.

TABLE I

AREAS OF RESPIRATORY TRACT INVOLVED IN 110 PATIENTS

Nasal vestibule	2
Lips	2
Gingiva	1
Palate	13
Nasopharynx	3
Larynx	103
Tracheobronchial tree	22
Lungs	3

RESULTS

General Features of the Disease

Study of these 64 male and 46 female patients quickly revealed that recurrent papillomatosis has a predilection for a wide variety of sites within the oral cavity and the respiratory tract (Table I); the larynx was by far the predominant site (103 patients) but the tracheobronchial tree and the palate were involved in 22 and 13 instances respectively. In the nasal vestibules the lesions were found to be growing on the mucosa near the mucocutaneous junction. One patient presented with multiple recurrent papillomas of the lips, the upper

and lower gingivae, the palate, tonsil fossa, nasopharynx, larynx and tracheobronchial tree! A history of skin warts was present in 4 out of 53 patients under the age of 16, and in 19 out of 57 patients over the age of 16 years, including 4 patients with perineal warts. In several patients, during the course of managing their respiratory tract papillomas, their cutaneous warts disappeared spontaneously. This, however, was not correlated with a similar disappearance of the mucosal lesions.

It was apparent that the disease has a worldwide distribution; patients came from Iran, Italy, East Africa, the Caribbean, Canada and all regions of the United States. From this experience it does not appear that the disease is significantly more common in warm climates than cold, although it would appear from the origin of many of these patients that the disease is particularly prevalent in Kentucky, Tennessee, Georgia and the Carolinas.

The influence of *socioeconomic status* was not apparent in the study; the patients were from all levels of society. It was noted, however, that 9 of 36 children below the age of five years had been adopted by their parents; a history of the circumstances of their births was therefore not available. Some of the patients showed evidence of poor personal hygiene and neglect while others showed no such traits.

Antigen responses were studied in 24 patients with severe recurrent disease. Eleven out of 24 patients when tested produced no response to intradermal injections of tuberculin, candida, streptokinase, streptodornase or trichophyton, 48 hours after injection; all but one of the 11 have continued to produce recurrences of papilloma relentlessly. Two patients who did react to one or more of the antigens, however, presented with the most advanced stage of the disease, namely, involvement of the lung parenchyma.

The *histology* of all these lesions was one of benign squamous papilloma; in a few specimens varying degrees of cellular atypia were noted but in no instance was malignancy suspected. None of these multiple recurrent lesions was seen to be keratinizing so that there was no confusion with solitary papillary keratoses occurring in older patients or with verrucous carcinoma. Scanning and transmission electron microscopy was carried out on 20 specimens by Incze *et al*,[4] whose findings are being reported in detail elsewhere. Papova-like virus particles were seen in 20% of cases. It was also noted that papilloma cells have an abnormal number of microvilli and desmosomes upon their surface; similarly, the surface epithelial cells of mucosa taken from an area immediately adjacent to papilloma presented with an abnormal number of microvilli and desmosomes. This finding suggests a gross abnormality of the microstructure of epithelial cells covering apparently normal appearing mucosa adjacent to a papilloma.

The *reservoir of recurrent respiratory papillomatosis appears to be condylomata acuminata.* Of 36 patients under the age of five years, 18 or 50% were born of mothers who had vaginal warts at the time of delivery; if a history could have been obtained from the natural mothers of nine adopted children, the proportion might have been higher. Four patients who acquired their disease after the age of 20 years volunteered a history of oral-genital contact with an infected partner; a history of such contact was solicited from only a few of the remaining 33 patients whose age of onset was 16 to 50 years (Fig. 1).

Natural History of the Disease

Age of Onset. In children this information was obtained from the parents and probably is accurate, even though nine children were adopted. In adults it was often difficult for the patients to recall exactly when the diagnosis was first made, but they were certain as to whether it was in childhood or adult life. While the disease was most commonly diagnosed before the age of five years (66%), it was apparent that there is another important age of onset be-

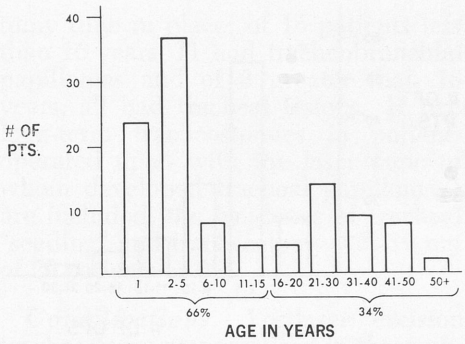

Fig. 1. Age of onset of papillomata. While the greatest number of patients dated the onset in childhood, one-third had no symptoms until age 16 years or older.

tween 16 and 50 years (34%) (Fig. 1). One patient developed hoarseness due to papilloma at the age of 68!

Age at Presentation. It was a surprise to find that more than 50% of patients who presented for further treatment were 16 years of age or older (Fig. 2). Referred patients of course are highly selected; those patients with refractory disease tended to be referred because of the long duration of their condition.

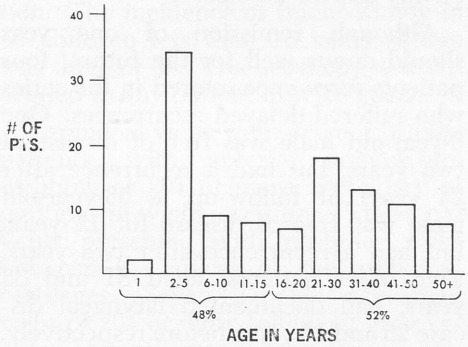

Fig. 2. Age at presentation. The higher proportion of patients aged 16 years or more reflects the referral of some patients who had their disease for many years and had not responded to other forms of treatment.

Prior Treatment. The number of procedures that patients had prior to undergoing laser excision varied greatly (Fig. 3). Sixteen patients had a simple biopsy or excisional biopsy and one patient had a history of 137 operations.

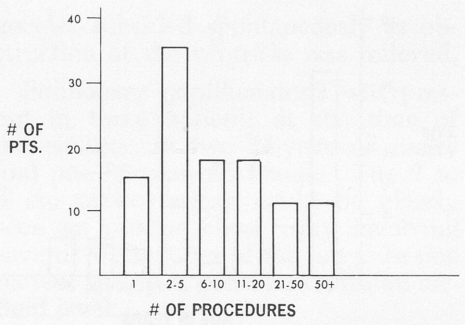

Fig. 3. The number of prior procedures indicate the refractory nature of the disease.

Several patients had lost count after 100 operations!

In addition to surgical excision, five patients had been treated with cryosurgery, two of them on seven occasions. Two patients had surgical excision combined with ultrasound irradiation, one of them on 15 occasions. Three patients had received autogenous vaccine prior to being treated by laser excision.

Remissions. It was impossible to predict when the disease might become arrested. On some occasions the amount of recurrent disease that was excised was very small and yet in six months another recurrence appeared at the same or a different site. On other occasions, after many rapid recurrences of bulky lesions, quite unexpectedly the recurrence rate slowed down and the disease vanished after one or two more excisions.

In this series of 110 patients, 11 patients were lost to follow-up; no answer could be elicited from their last known address. Of the remaining 99 patients, 76 had been in this study for a year or more and hence were at risk of undergoing remission. Remission was defined as no evidence of visible disease for one year or more by mirror examination in older children and adults or by direct microlaryngoscopy in small children. There were 47 patients less than 16 years of age and 29 patients greater than 16 years of age who were followed for one year or more (Fig. 4).

Of the 76 patients under follow-up

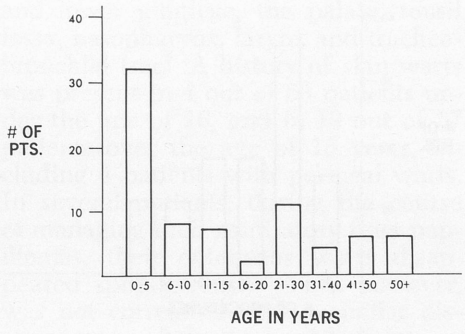

Fig. 4. Age of 76 patients in follow-up for one year or more. In addition to the group of children under 5 years of age, an opportunity for remission was present in 29 patients over 16 years of age.

for one year or more, 26 patients stayed in remission for one year or more (34%). Figure 5 shows the age of patients when remission was achieved. The table indicates that remission can occur at any time, but is most predictable after age 40 years. By referring to Figures 4 and 5 it can be seen that of 47 patients less than 16 years of age, 12 patients underwent remission (25%) and of 29 patients 16 years of age and over, 14 underwent remission (50%). This suggests that the change of remission occurring increases slightly with age, but is lowest between the ages of 16 and 40 years — 3 out of 17 patients. There were 18 patients with laryngeal and tracheobronchial disease; only three of these achieved total remission after multiple laser excisions.

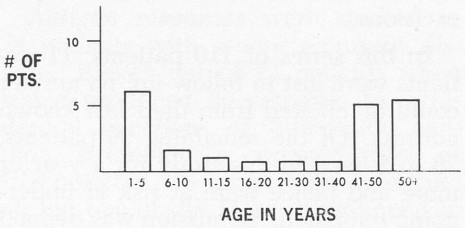

Fig. 5. Age of onset of remission in 26 patients. The paucity of remissions between age 11 and 40 years is very striking.

The number of prior procedures was not related to the possibility of laser excision promoting a remission; some of the patients who had more than 50 previous operations went into remission as some of those did who had only one

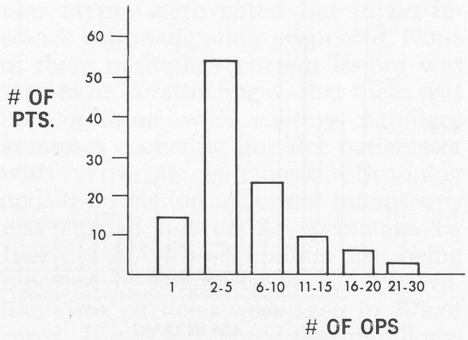

Fig. 6. Number of laser excisions. Most of the patients requiring more than 15 operations have tracheobronchial papillomas.

or two procedures. Only two of the five patients previously treated by cryosurgery went into remission and none of those who had received ultrasound irradiation or autogenous vaccine responded to laser excision.

The number of laser excisions performed is shown in Figure 6 and although 18 patients have undergone more than 11 laser operations, no remission was encountered if more than 10 operations were required. Operations in excess of ten served to maintain the airway and/or a voice.

Although remission of one year should augur well for the future, four patients were encountered in the series who suffered delayed recurrences. One 8-year-old male was free of disease at two years, but had a recurrence after 2½ years of follow-up; a 58-year-old male was free of disease for 1½ years but had a recurrence after two years. Two other patients, aged 31 and 32 years, had documented laryngeal disease 25 and 19 years before respectively. These patients illustrate the tenuous nature of remission and that recurrence may occasionally appear even decades later.

Incidence of Tracheobronchial Disease and Tracheostomy. In nine patients over 16 years of age who presented with a history of having had a previous tracheostomy and since removed, four had residual papillomas in the trachea and five had no tracheal disease. Eighteen patients presented with a tracheos-

tomy tube in place; of 15 patients less than 16 years, 11 had tracheobronchial papillomas and of 3 greater than 16 years, all had tracheal lesions. If two long-term tracheostomies in patients operated upon with the laser (one of whom developed tracheal papillomas) are included, the incidence of tracheal "seeding" and tracheostomy was 19 out of 29 patients or 65%.

Complications. Postlaser excision tracheostomy was required in three patients. In one 3-year-old patient, the rate of recurrence of papillomas in the larynx was so great that it became impractical to remove the lesions as frequently as every ten days; to preserve the airway a tracheostomy was done. Within a month there was extensive involvement of the trachea with papillomas requiring bronchoscopic removal every two months. A second 2-year-old male had a tracheostomy because the mother had become pregnant and felt she would not be able to bring the child back for several months. A third 4-year-old boy required tracheostomy for three days because of edema secondary to excessive intralaryngeal manipulation. The incidence of tracheostomy in 53 children less than 16 years of age was three or 6%. Tracheostomy was not needed in any patient over 16 years.

Laryngeal webs were present in nine patients, with anterior commissure webbing of 20% or more, secondary to multiple previous excisions. Three patients presented with posterior webs between the apices of the arytenoid cartilages. Seven patients developed webs of 20% or more following laser excision of papillomas in the anterior commissure; three of these were severe and involved 50% of the membranous portion of the cords. These patients were treated early in this series before it was realized that excision, even with a laser, must not be carried out simultaneously on each cord in the area of the anterior commissure.

Laryngoceles developed in two patients with extensive involvement of the false cords and ventricle. After laser excisions on several occasions, the laryngoceles subsided spontaneously as obstruction of the ventricle was relieved.

Pulmonary papillomatosis was present in three patients at the time of presentation in two 14-year-old males and one 26-year-old female. The 2 to 3 cm cystic lesions could be clearly seen on routine chest x-ray involving several of the lobes of the lung. In one patient the cysts presented with an air-fluid level.

Malignant degeneration was encountered in only one patient who presented as a laryngectomee. She had received x-radiation at the age of 12 for laryngeal papillomas and developed cancer of the larynx at age 31. Following laryngectomy the patient continued to produce obstructive masses of papillomas in the lower trachea and bronchi.

Near asphyxiation developed in a 5-year-old girl who had a tracheostomy since two years of age. Her tracheobronchial tree had cleared following laser excision, but the larynx required operation every four months to maintain a voice; she was found unconscious with cardiopulmonary arrest at school due to obstruction of the inner cannula of her tracheostomy tube by inspissated mucus. Resuscitation was accomplished by the rescue squad but the child did not regain consciousness. Repeat bronchoscopy revealed no tracheobronchial papillomas but the child has remained in coma.

DISCUSSION

The nomenclature of this disease has been a source of confusion in the past. There appears to be no difference in the microstructure or biologic behavior of papillomas that occur in the nares or the larynx, or in those that occur in children or adults.[5] Papillomas may first appear in any area of the aerodigestive tract and at any age; the lesions are both multiple and recurrent. This being the case, the qualifying prefixes "juvenile" and "laryngeal" are redundant when describing recurring papillomas. It appears that the solitary, pedunculated papilloma commonly seen on the uvula or tonsil pillars may be a different disease; although they have a

similar histologic appearance, they do not tend to recur. Solitary papillary lesions occurring in the adult larynx most often present a degree of keratinization which distinguishes them from recurrent respiratory papillomatosis. A keratinizing papillary lesion of the larynx or oral cavity may, of course, represent an early stage of verrucous carcinoma.

Evidence that recurrent respiratory papillomatosis is of viral origin is convincing although proof is not as yet available. Papova-like viruses were seen in this study[4] and in others.[6] It is presumed that the particles are visible only in a small proportion of cells because the remainder of the cells are in the transformed state. Solisch *et al*[7] not only saw papovavirus particles in some specimens but were able to culture viruses from many specimens. The clinical behavior of the disease, its transmission, remissions and recurrences, are certainly compatible with a disease of viral origin. It is most probable that the reservoir of recurrent respiratory papillomatosis is genital warts;[8] the concept was reinforced by this series. Transmission to the child during passage through the birth canal is most likely. Appearance of the disease for the first time in an adult is more difficult to explain; either the disease was transmitted at birth and lay dormant until later years or it was acquired secondarily during the years of sexual activity. The prevalence of oral-genital practices and the documentation of incidents where patients had contact with infected partners, are most suggestive that this is an alternate method of transmission. We have no idea as to the infectivity of the disease, but it is probably low. We know of no siblings with the disease, and mothers who have recovered from condyloma have had further children without problems. However, we would advise an infected mother to be delivered by cesarean section. The incidence of this disease is not known. It has been suggested that it is on the increase in certain areas.[9] Since there has been an explosive increase in the incidence of condylomata acuminata, especially among young adults, it is quite possible that there will be an increase in the incidence of respiratory tract papillomatosis.

The disease appears to have sites of predeliction but how and why it appears at more than one site is a mystery. The frequent "spread" of papillomas from the larynx to the tracheobronchial tree after tracheostomy suggests seeding onto the traumatized area of mucosa. However, multiple papillomas have been encountered in the tracheobronchial tree in the absence of laryngeal disease[10] so it is possible that the cells of tracheal epithelium have already been infected, and the trauma of the tracheostomy tube merely activates the dormant viral infection resulting in the production of a papilloma. Invasion of the lung parenchyma defies explanation;[11] it has been encountered only in patients with laryngeal disease requiring tracheostomy.

The occurrence of disease at extralaryngeal sites — the nares, lips, gums, and nasopharynx is interesting; these are sites of airway constriction (as well as the larynx) where air flow rates and consequent cooling from evaporation are high. It is known that cell mediated immune response can be temperature related;[12] perhaps both local cooling and the trauma associated with drying and crusting play a role in the development of papillomas in these sites of predeliction. Perhaps the beneficial effect, if any, of ultrasound (which is known to raise the tissue temperatures 1.1 C) is related to elevation of the cell mediated immune response.[13]

The significance of cellular immunity in respiratory papillomatosis is not known; the finding of 11 out of 24 patients with severe disease to be nonreactive to any of four common skin antigens suggests an anergic background. As this part of the study progresses, it will be possible to determine whether or not there is any correlation between the presence or absence of anergy and the occurrence of remission.

Remission in respiratory papillomatosis is most unpredictable. So far it

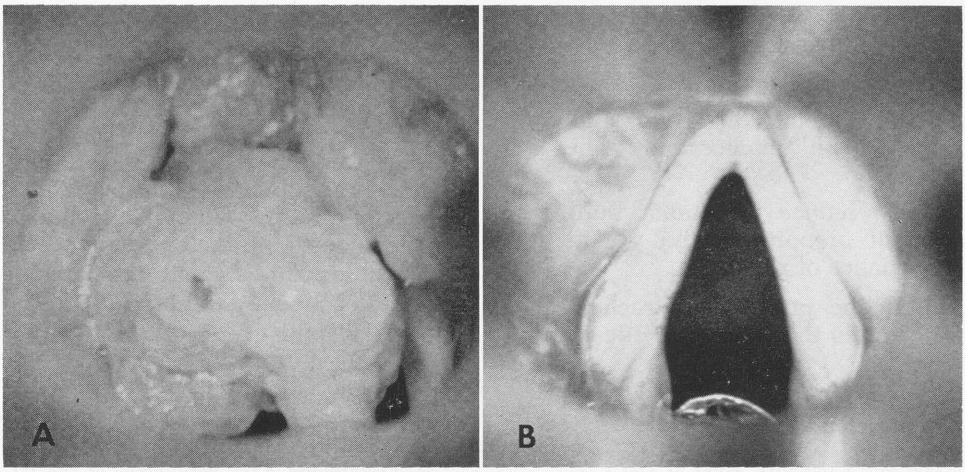

Fig. 7. A) Multiple papillomas in the larynx of an 11-year-old girl requiring excision twice a year. B) The larynx as seen in A after two laser excisions. Note the healthy mucosa and absence of visible scarring.

has not been possible to predict when it is going to occur or how long it will last. It is highest below 10 years of age[14] and lowest between 20 to 40 years of age as seen in this series. The onset of puberty did not appear to have an influence on the age of remission in this series. While a remission of one year bodes well for the future, there is no assurance that the remission will be maintained. Since recurrences can occur years later,[15] it is probable that we cannot speak of "cure" in this disease any more than we can speak of cure in herpes labialis; because relapses are not unusual one and two years later, only three-year remissions should be considered when comparing the efficacy of various methods of management.

The *origin of the recurrence* remains a mystery. After laser excision of a localized papilloma of the vocal cord down to the underlying muscle and including a margin of surrounding mucosa, the lesion may vanish and not recur, or in three months a papilloma may reform just as if the lesion had never been removed! Were the "seeds" of a new papilloma within the muscle or were fragments of papilloma seeded into the wound? Neither possibility is likely. A more plausible suggestion is that the origin of the new papilloma is in the cells of the surrounding normal appearing mucosa; the surrounding margin of epithelium may contain transformed cells which, when stimulated to regenerate a new epithelial covering of the wound, may be stimulated into producing a new papilloma. This may explain the apparent success of decortication of the vocal cord and resurfacing with vein graft after excision of vocal cord papilloma. The vein graft survives as a viable graft so that epithelial migration does not occur.[16] Electron microscopy studies of the epithelium surrounding a papilloma support this concept. Unfortunately, total excision of all the laryngeal epithelium and replacement with a new covering is not a practical consideration.

Total ablation of all visible papilloma reduces the tumor burden to invisible proportions; the best that can be hoped for is that the immune response of the host will be sufficient to contend with the invisible residue and promote a remission. There is no question that the surgical laser is the optimal method of papilloma removal; all visible papilloma can be removed at the expense of minimal damage to supporting structures such as the vocal cords, *etc* (Fig. 7 A, B). However, at the present time no method of tissue destruction by surgical removal, cautery, ultrasound irradiation, cryosurgery or laser, can be ex-

pected on its own to promote permanent remissions consistently.

The *present goals* of management are:

1. To maintain the airway and voice and to avoid tracheostomy whenever possible.

2. To reduce the tumor burden to minimal proportions and provide the best chance of remission.

3. In the presence of tracheostomy, to maintain the patency of the tracheobronchial airway by bronchoscopy and to use the shortest tracheostomy tube possible.

Future goals do not call for a method of papilloma removal more ideal than the surgical laser; they do call for elucidation of the subtleties of the papilloma-host relationship. When this relationship is understood, then perhaps it will be possible to manipulate the immune response of the host and produce remissions in all patients.

REFERENCES

1. MacKenzie M: *Diseases of the Pharynx, Larynx and Trachea.* New York, William Wood and Company, 1880, p 226

2. Strong MS, Vaughan CW, Polanyi TG, *et al*: Laser surgery in the aero-digestive tract. Am J Surg 126:529-533, 1973

3. Strong MS, Vaughan CW, Polanyi TG, *et al*: Bronchoscopic CO_2 laser surgery. Ann Otol Rhinol Laryngol 83:769-776, 1974

4. Incze JS, Lui PS, Strong MS, *et al*: The morphology of human papillomas of the upper respiratory tract. To be published

5. Kleinsasser O, Oliviera EG: Juvenile and adult laryngeal papillomas. HNO 21:97-100, 1973

6. Boyle WF, Riggs JL, Oshiro LS, *et al*: Electron microscopic identification of papova virus in laryngeal papilloma. Laryngoscope 83:1102-1107, 1973

7. Solisch T, Hannefeld H, Brandt RH: Zur papova virus ëtiology des menschlicken laryngopapilloma. Z Erkr Atmungsorgane 138: 379-384, 1973

8. Cook TA, Cohn AM, Brunschwig PS, *et al*: Laryngeal papillomas: etiologic and therapeutic considerations. Ann Otol Rhinol Laryngol 82:649-655, 1973

9. Dekelboum AM: Papillomas of the larynx. Arch Otolaryngol 81:390-397, 1965

10. Al-Saleem T, Peale AR, Norris CN: Multiple papillomatosis of the lower respiratory tract. Cancer 22:1173-1184, 1968

11. Smith L, Gooding C: Pulmonary involvement in laryngeal papillomatosis. Pediatr Radiology 2:161-164, 1974

12. Portilo DT, Walsh GP, Storrs EE, *et al*: The impact of cool temperature on transformation of human and armadillo lymphocytes as related to leprosy. Nature 248:450-452, 1974

13. Birck HG, Manhart HE: Ultrasound for juvenile laryngeal papillomatosis. Arch Otolaryngol 77:603-608, 1963

14. Majoras M, Parkhill EM, DeVine KD: Papilloma of the larynx in children. Am J Surg 108:470-475, 1964

15. Klos J: Clinical course of laryngeal papillomatosis in children. Ann Otol Rhinol Laryngol 79:1132-1138, 1970

16. Tabb HG, Kirk RL: Vein grafts in the management of laryngeal papillomas. Laryngoscope 72:1228-1238, 1962

———

REPRINTS—M. Stuart Strong, MD, 75 E. Newton St., Boston, MA 02118.

DINITROCHLOROBENZENE SKIN SENSITIZATION AND PERIPHERAL LYMPHOCYTE COUNT: PREDICTORS OF SURVIVAL IN HEAD AND NECK CANCER

ROBERT H. MAISEL, MD

MINNEAPOLIS, MINNESOTA

JOSEPH H. OGURA, MD

ST. LOUIS, MISSOURI

SUMMARY — Dinitrochlorobenzene (DNCB) is a simple chemical useful to evaluate both afferent (sensitizing) and efferent (reacting) limbs of the delayed, cell-mediated immune system. This system invokes the small lymphocyte (T cell) and is apparently part of the host defense against cancer. Seventy-two patients with new primary squamous cell carcinomas of the larynx, hypopharynx and oropharynx were sensitized to DNCB by contact application, and delayed cutaneous hypersensitivity tested. The T cells were also assessed in this study by lymphocyte count. All patients were treated for cure. Ninety-one percent of DNCB reactors were alive and tumor-free at two years. Forty-five percent of negative reactors had recurrent tumor and died of carcinoma. Cases grouped by site among glottic, supraglottic and inferior hypopharynx showed identical results. Lymphocyte counts showed a trend in the same direction. On statistical analysis, all differences were significant. Eighty-five percent of recurrent tumors occurred in patients who were nonresponders. The present data suggest DNCB reactivity is helpful in predicting outcome after surgery, or combined radiation and surgery, for mucosal squamous carcinoma of the head and neck.

Malignant epithelial tumors of the head and neck are amenable to careful mapping by tumor site and size because these tumors are palpable, visible, and relatively easily accessible. Analysis of treatment regimens based on tumor size and precise location has been done for many years.[1-3] Patients with carcinoma have been suspected of being immune deficient. Recently, studies on host response to the tumors have begun. Eilber and Morton,[4] Eilber *et al*[5] and Morton *et al*[6] were among the first to evaluate prognostically the immune system in clinical neoplasia, and others have followed their lead.[7] Many of these studies are based on large tumor clinic populations where the head and neck sample is small and poorly defined. These patients often are evaluated after primary cancer therapy is accomplished and recurrent or progressive disease is evident.[8]

The host response to foreign protein is a precisely tailored mechanism which protects against bacteria, virus, and neoplasia. In humans the system is mediated through a B cell line which comprises stationary immune cells including plasma cells. This humoral system functions via circulating immunoglobulins or antibodies which interact with antigens or foreign protein to effect their destruction, removal and dispersal.

The T cell or thymus derived system is manifest as small circulating lymphocytes. These are in deep cortical areas of the lymph node and in the spleen from where they can enter the blood stream.

All recent evidence suggests the small

From the Department of Otolaryngology, University of Minnesota Medical School, Minneapolis, Minnesota, and the Department of Otolaryngology, Washington University, St. Louis, Missouri. This study was supported in part by NIH Grant 5 T01 NSO 5190.

lymphocyte is integral in delayed hypersensitivity, protects the internal environment from fungal infection, inhibits homograft transplant, and performs the immune surveillance which seeks and destroys the multiple neoplastic cells hypothesized to be created daily within all living vertebrates.[9] Using this information, many students of cancer and immunology have assessed delayed hypersensitivity reactions looking for group differences between normal and tumor populations.

One nitro 2-4 dichlorobenzene (DNCB) is a simple compound with disinfectant properties which until recently had a limited industrial application. (More recently, this chemical has been used in swimming pool cleansers in Europe). Thus in the past, few people have had exposure to this chemical, which like several other chemicals (including Dinitroflorobenzene), acts as a hapten by forming covalent bonds with lysine in skin proteins.[10,11] The complex interacts with the defense mechanism to sensitize a lymphocyte population which develops a "memory" for the complex. This event occurs in regional nodes and utilizes the small (T) lymphocytes.[12,13] Such lymphocytes, once sensitized, react at any subsequent encounter in a hypersensitive manner, thus demonstrating an intact immune arc. Sensitization requires 7 to 21 days and is a delayed cutaneous hypersensitivity reaction (DCH). This is distinguised by the time sequence from the initial irritative reaction of sensitization which occurs in the first 24 to 72 hours after application, and by histologic characteristics of delayed hypersensitivity.

This clinical test of immune competence used in humans for over 20 years is more valuable than introducing bacterial or fungal antigens, since it assesses the afferent (sensitizing) and efferent (hyperreacting) loops of the system.

If immune deficiency in the cancer patient is due to failure of sensitization of the small lymphocyte to the malignant cell, as well as failure to sensitize to any other "foreign" protein (DNCB plus skin hapten), the DNCB test will be unreactive and will discover this failure. Stimulating a new response to previously unencountered protein requires the entire system to be functional. This will be perceived when testing this delayed cutaneous response. Unlike tuberculosis antigens (PPD), this test makes no presumption of previous antigen contact. Clinical work suggesting the preservation of the efferent loop in the cancer patient furthers the importance of assessing the complete circuit *in vivo* by DNCB.

Since the small lymphocyte is felt to be integral to the delayed hypersensitivity reaction, several investigations of cancer immunology have assayed this cell. Many methods of DNCB testing and interpretation have been used. Eilber and Morton[4] described a simple repeatable method which we have followed.

Other investigators have felt that the cancer patient has a loss of ability to mount a histamine response. They have measured response to croton oil (an irritant), and have found patients unresponsive to this are often also DNCB negative.[14] Roth *et al*[15] recently have refuted the purported value of croton oil irritation. Dermatologists have biopsied the sensitization and challenge sites and have described histologic characteristics of DCH.[13] Despite these sophistications the method we follow continues to be widely used clinically.[14,16]

Our sample was selected on a consecutive basis among new untreated patients clinically diagnosed to have squamous carcinoma of the oral cavity, larynx, or pharynx. All patients were evaluated on their first office visit and as part of the examination had a DNCB sensitization dose of 2000 μg applied to the left volar antebrachium. A 100 μg dose was applied to the right arm in an identical location to insure no previous sensitivity was operant. A decision at the first office visit was made that these patients were amenable to primary therapy either via surgery alone or preoperative irradiation in combina-

TABLE I

PERCENTAGE OF DNCB REACTORS IN CONTROL AND CANCER PATIENTS

	DNCB +	*DNCB −*	*% Reactors*
Control	26	5	84
Cancer Patients	32	40	44

tion with surgery. All patients were tested before institution of radiotherapy, and no patients had received chemotherapy. No patients had undergone surgery in the two weeks prior to testing. Several patients did have a short surgical procedure (biopsy) within a week subsequent to application of the DNCB. Fourteen to 21 days after the sensitizing test, a test dose of 100 μg DNCB was applied to the left arm 3 inches distal to the original 2000 μg dose. Complete blood cell count and differential was obtained at the first office visit or on hospital admission.

Our hypothesis was that cancer patients would have a lower incidence of reactivity to DNCB and would have a lower absolute lymphocyte count than age-matched controls. We further predicted that the subgroup who survived the usual treatment protocol tumor-free would contain more positive skin reactors regardless of stage or site of tumor than the treatment failure group.

RESULTS

We have completed all studies on 72 patients with squamous cell carcinoma and have followed all patients 24 months or longer. Twelve patients who entered the study were disqualified, because despite a clinical presentation compatible with squamous cell carcinoma, their biopsy revealed other malignant histology (lymphoma, adenocarcinoma). Three patients were dropped from the series because of early postoperative death. All 72 patients had the prescribed DNCB and lymphocyte count. Many of them had mumps antigen and PPD application. Our control population was drawn from the orthopedic ward and included patients 40 to 70 years old, none with a history of previous carcinoma. Eighty-four percent of these controls were DNCB reactors while 44% of the cancer patients reacted (Table I).

TABLE II

PERCENTAGE OF DNCB REACTORS AMONG TUMOR FREE PATIENTS COMPARED TO PATIENTS WITH RECURRENT CARCINOMA

	DNCB +	*DNCB −*
Tumor Free	29	22
Recurrent	3	18
	91%	55%

Increased tumor-free survival of positive reactors. T test significant statistically. $P<0.01$.

We have described the results in Table II. Ninety-one percent of positive DNCB reactors survived greater than two years tumor free. Twenty-two of 40 patients (55%) who were nonresponders were tumor free at two years. This group difference is statistically significant at the 0.01 level.

Table III divides the patients into groups by two measures of delayed hypersensitivity. Fifteen of 24 patients with lymphocytopenia (<1500 (lymphocytes/cm^3) survived tumor free two years, as did 36 of 48 patients with normal lymphocyte counts. This shows a trend to decreased survival with lymphocytopenia, but it is not statistically significant. Table IV shows that 20 of 21 patients (95%) with both normal DNCB reaction and normal lymphocyte counts were free of disease at two years. Analysis of the data shows this is significant to the 0.01 level.

The cancers were divided by location into four groups to assess the validity of the DNCB test in different regions and sites in the head and neck (Table

TABLE III

RELATIVE LYMPHOCYTOPENIA AND ITS RELATION TO RECURRENT TUMOR

	WBC >1500	*WBC <1500*
No Recurrence	36	15
Recurrent Tumor	12	9

TABLE IV

DINITROCHLOROBENZENE SKIN REACTIVITY AND LYMPHOCYTOPENIA RELATIONSHIP TO RECURRENT TUMOR

	DNCB +		*DNCB −*	
	WBC > 1500	< 1500	WBC > 1500	< 1500
No Recurrence	20	9	16	6
Recurrent Tumor	1	2	11	7

Absolute lymphocyte count and DNCB reactivity. Statistical significance 0.01; $P < 0.01$.

V). Bulky laryngeal lesions are classified by considering the center of the tumor mass the named site of origin. Fifty-two percent of the patients with glottic lesions reacted to the DNCB. This group included large T_4 lesions as well as small lesions amenable to vertical hemilaryngectomy. Twelve of 17 supraglottic lesions were in people who were skin test positive (71%). Thirteen patients with pyriform sinus lesions were studied and four were DNCB positive (30%). The other 17 lesions included several anatomic areas (tongue base, tonsil, floor of mouth) and these are not included in Table V.

As noted in Table V, for laryngeal and pyriform lesions 27 of 29 patients (93%) who manifested DCH survived. The nonresponders showed a 39% recurrence rate.

DISCUSSION

Our results show DNCB reactors almost unfailingly (91%) survived two years. This two-year result agrees with the short-term follow-up of Morton *et al*,[6] and confirms our previous work.[17] In view of the conclusions of Session[18] and Fletcher,[19] that 85 to 90% of recurrences occur within two years, our results suggest the long-term prognosis for DNCB reactors is excellent.

DNCB skin testing can predict, at a statistically significant level, the outcome for patients with squamous cell carcinoma primary to the head and neck. Lymphocytopenia dims the prognosis, but not to a statistically significant degree.

DNCB skin testing is now a well-accepted part of the evaluation of a new patient in a major cancer treatment center. Its importance and value to planning cancer therapy is not yet clear. This series of 72 patients with regional cancer of the head and neck is the first to admit only patients whose tumor and general health uniformly

TABLE V

DINITROCHLOROBENZENE SKIN REACTIVITY GROUPED BY ANATOMIC LOCATION OF THE PRIMARY CARCINOMA

	Recurrence	*DNCB +*	*DNCB −*	*Total*
Glottic	No	13	9	25
	Yes	–	3	
Supraglottic	No	11	3	17
	Yes	1	2	
Pyriform sinus Extrinsic larynx	No	3	4	13
	Yes	1	5	
	2 yr tumor free	27/29	16/26	

Positive reactors with fewer recurrences than negative DNCB reactors.

allows a planned curative treatment program. All patients were treated for cure, and none received chemotherapy. The DNCB test is a valuable adjunct in an initial evaluation of the patient with cancer. Small vocal cord cancers will almost uniformly respond to treatment.[2] Three of 25 in this subseries suffered recurrence (one salvaged by laryngectomy). All three were nonresponders. The same holds in larger and more dangerous tumors of the pharynx and oral cavity. Of 21 recurrent tumors in this series, only three had normal skin reactivity (15%).

We feel DNCB testing holds an advantage over *in vitro* tests as a functional measure of delayed hypersensitivity. This simply performed, easily interpreted clinical measure is a valid predictor of survival from squamous carcinoma of the head and neck. It holds true for two-year survival which is sufficient time under good clinical follow-up for tumor regrowth to occur and be discovered. In our series, it differentiates with reliability, and to a statistically significant level, the patients whose tumor will recur from those in whom the usual therapy will be successful.

From our data, failure of patients to respond, implies about a 45% chance of recurrent tumor, with the likelihood of dying from the cancer. The DNCB test does not differentiate potential failures but does forecast an excellent incidence of tumor cure when positive.

For laryngeal and inferior hypopharyngeal lesions, 27 or 29 DNCB positive reactors survived two years (93%). Sixteen of 26 nonresponders were tumor-free after two years (61%). This further shows the sharp predictive value of *in vivo* double-limbed (afferent and efferent) DCH measure. The results are similar for each site, but statistical analysis was not performed because of the scarcity of cases within each site in the oral cavity and superior hypopharynx.

We have evaluated this test only once on each patient. We intend to expand our study, to measure as Krant[16] did, if recurrent tumor can convert a responder to negative, and we plan to elucidate the gross parameters which associate with failure of immune surveillance. Our present study comprises a two-year clinical follow-up at several institutions and includes other noninvasive measures of delayed hypersensitivity (keyhole lampert cyanin, phytohemagglutinin, and T cell rosette) as well as histologic exam of neck lymph nodes from patients operated by radical neck dissection for lymphocyte depletion pattern.

The clinical application of the DNCB test as a predictor in survival remains in the large tumor which, by location and size alone (T_3T_4), offers a poor survival prospect. A positive skin test in such a lesion suggests a favorable outcome and implies aggressive therapy to irradicate these tumors is advisable. Contrarily, a negative test implies a generally less favorable prognosis despite clear surgical margins. It may mean adjunctive immuno-and chemotherapy has merit in such a patient. It may also suggest that aggressive surgical radiotherapeutic measures are not advisable since the chances for a successful outcome are dim, and palliative therapy may be the recommended method of treatment. This information is not yet forthcoming.

REFERENCES

1. Ogura JH, Biller HF: Conservation surgery in cancer of the head and neck. Otolaryngol Clin North Am 3:641-665, 1969

2. Biller HF, Ogura JH, Pratt LL: Hemilaryngectomy for T_2 glottic carcinoma. Arch Otolaryngol 93:238-243, 1971

3. Krause CJ, Lee JG, McCabe BJ: Carcinoma of the oral cavity. Arch Otolaryngol 97:354-358, 1973

4. Eilber FR, Morton DL: Impaired immunologic reactivity and recurrence following cancer surgery. Cancer 25:362-367, 1970

5. Eilber FR, Nizze JA, Morton DL: Sequential evaluation of general immune competence in cancer patients: correlation of clinical course. Cancer 35:660-665, 1975

6. Morton DL, Holmes EC, Eilber FR, *et al*: Immunological aspects of neoplasia: a

rational basis for immunotherapy. Ann Intern Med 74:587-604, 1971

7. Mandel MA, Kiehn CL: The prognostic significance of delayed cutaneous reactivity in head and neck cancer patients. Plast Reconst Surg 53:72-76, 1974

8. Parker R, Alexander S, Shaheen OH, *et al*: On the immunology of head and neck cancer — prognostic index. Preliminary communication. J Otol Laryngol 89:687-695, 1975

9. Craddock CG, Longmire R, McMillan R: Lymphocytes and immune response. N Engl J Med 285:324-331, 1971

10. Eisen HN, Orris L, Belman S: Excitation of delayed allergic skin reactions with haptens: the dependence of elicitation of hapten combination with protein. J Exp Med 95: 473-487, 1952

11. Eisen HN, Tabachnick M: Elicitation of allergic contact dermatitis in the guinea pig: the distribution of bound dinitrobenzene groups within the skin and quantitative determination of the extent of combination of 2, 4 dinitrochlorobenzene with epidermal protein *in vivo*. J Exp Med 108:773-796, 1958

12. Catalona WJ, Cretien PB: Abnormalities of quantitative dinitrochlorobenzene sensitization in cancer patients: correlation with tumor stage and histology. Cancer 31:353-356, 1971

13. Catalona WJ, Taylor PT, Rabson AS, *et al*: A method for dinitrochlorobenzene contact sensitization. A clinicopathological study. N Engl J Med 286:399-402, 1972

14. Johnson NW, Mailback HI, Salmon SE: Skin reactivity in patients with cancer. Impaired delayed hypersensitivity or faulty inflammatory response. N Engl J Med 284: 1255-1257, 1971

15. Roth JA, Eilber FR, Nizze JA *et al*: Skin reactivity to DNCB and croton oil in patients with cancer. N Engl J Med 293:388-389, 1975

16. Krant MJ, Manekopf G, Brandrup CS, *et al*: Immunologic alterations in bronchogenic cancer. Cancer 21:623-631, 1968

17. Maisel RH, Ogura JH: Abnormal dinitrochlorobenzene skin sensitization: a prognostic sign of survival in head and neck squamous cell carcinoma. Laryngoscope 83:2012-2019, 1973

18. Sessions DB: Cancer of the head and neck. Laryngoscope 85:1960-1976, 1975

19. Fletcher GH, Lindberg RD, Hamberger A, *et al*: Reasons for radiation failure in squamous cell carcinoma of the larynx. Laryngoscope 85:987-1003, 1975

———

Acknowledgments—Ms Caroline Bradley, Registrar of the Washington University ENT Cancer Registry, was instrumental in obtaining data on the patients studied. The help of Ms. Toy Lin Lee, Otolaryngology Department Secretary, Hennepin County Medical Center, is gratefully acknowledged.

Reprints—Robert H. Maisel, MD, Hennepin County Medical Center, 701 Park Avenue, Minneapolis, MN 55415.

DISCUSSION

Albert H. Andrews, Jr., MD (Chicago, Illinois): I have had the opportunity of working with a carbon dioxide laser for a little over three years. I have been quite impressed with our response in terms of remission of papilloma, mostly of the larynx, some in the treachea.

The most impressive part of it, however, has been the accuracy of the destruction and particularly the preservation of the normal architecture of the larynx.

If the remission results were the same with conventional surgery as they are with the laser, I still feel the laser would have the advantage by the preservation of the normal tissue.

We have seen a number of patients who have had synechia resulting from previous removals, both in my hands and in other hands and these have actually improved during the laser therapy. So, we feel it is a distinct addition to the armamentarium.

We wish to congratulate Dr. Strong upon an excellent presentation. I believe he has made a definite contribution to our specialty.

OSTEOPLASTIC FRONTAL SINUSOTOMY

AN ANALYSIS OF 250 OPERATIONS

JAMES M. HARDY, MD

WILLIAM W. MONTGOMERY, MD

BOSTON, MASSACHUSETTS

SUMMARY — The operative approach and findings of 250 osteoplastic frontal sinusotomy operations performed from 1956 through 1972 at the Massachusetts Eye and Ear Infirmary are reviewed. Indications for surgery were symptomatic and/or complicated disease of the frontal sinus, including primary chronic sinusitis and osteoma or trauma with or without associated infection. Immediate postoperative complications were minor. Follow-up of at least three years was obtained in 83% of the patients, and 93% of these have no significant symptoms to date. A distressing problem of persistent postoperative frontal pain is discussed in detail. Revision surgery has been performed in 6% of patients due to recurrent frontal sinus infection. The reasons for failure are analyzed, and recommendations are made to minimize the possibility of recurrence.

June 19, 1976 marks the 20th anniversary of the first osteoplastic frontal sinusotomy done at the Massachusetts Eye and Ear Infirmary. On that date this method was used to revise a patient who had a mucocele recur one year after a Lynch frontoethmoidectomy. In spite of admonitions that such radical surgery would never be as successful, nor would it ever replace the Lynch sinusotomy, the osteoplastic operation soon became the standard procedure at this institution for all chronic symptomatic diseases of the frontal sinus except malignant disease.* Since the first 100 operations were reported in 1966,[1] considerably more experience has been accumulated. It is the purpose of this paper to review 250 patients treated by this method with attention to operative indications, findings at surgery, and postoperative results including revision surgery.

Two hundred and fifty-five consecutive osteoplastic frontal sinusotomy operations performed from 1956 through 1972 were identified. Five hospital charts were lost, thus 250 records were reviewed. Sixty-five procedures were performed by residents and 185 by 29 members of the Attending Staff. Follow-up was obtained on 208 patients (83%), 129 by examination, and 79 by questionnaire. Median follow-up was 8 years, but ranged from 3 to 19 years. Eighty-four patients were followed for more than ten years.

The etiologies of frontal sinus disease leading to surgery are broken down into four categories: chronic infection, osteoma, trauma, and miscellaneous (Table I).

One hundred and ninety patients (76%) had chronic infection as the etiology for surgery. Of these patients, 61% had mucoceles or pyoceles, and 39% had chronic infection without mucocele or pyocele. Sixty percent had unilateral disease.

Twenty-five patients (10%) were operated on for osteoma or its related complications. Thirteen of these patients had secondary chronic infection

---

* Goodale, RL. Personal communication.

From the Department of Otolaryngology, Harvard Medical School, and the Massachusetts Eye and Ear Infirmary, Boston, Massachusetts.

TABLE I

OSTEOPLASTIC FRONTAL SINUSOTOMY

Etiologies		*No. Patients*	*%*
Chronic infection		190	76
Osteoma			
with infection	13		
without infection	12		
Total		25	10
Trauma			
with infection	15		
acute without infection	10		
Total		25	10
Miscellaneous		10	4
Total		250	100%

with or without mucocele or pyocele. Unilateral osteomata were present in 19 patients.

Twenty-five patients (10%) had surgery due to trauma or its sequelae in the frontal sinus. In 15 of these patients there was associated chronic sinusitis, which generally followed from violation of the sinus or its nasofrontal duct by fracture, or by foreign body secondary to trauma or neurosurgery. Acute trauma was present in ten patients. Three patients had cerebrospinal fluid (CSF) leak, two with secondary meningitis. The CSF leaks had been present for 16 days, one month and 16 years respectively.

Ten patients (4%) had miscellaneous indications for sinusotomy. Eight were related to neoplastic disease including three with mucoceles secondary to nasal inverted papilloma, two with mucoceles associated with fibrous dysplasia of the sinus, one with meningioma invading the sinus, one with reticulum cell sarcoma, and one with Wegener's granulomatosis.

ANALYSIS

Of the 250 total patients, 154 (62%) were male and 96 (38%) were female. The youngest was age 10 years and the oldest 84 (Table II). Sixty-four percent of the patients were between the ages of 31 and 60. The median postoperative hospitalization was six days, with a range of 2 to 40 days.

TABLE II

OSTEOPLASTIC FRONTAL SINUSOTOMY

1956-1972	*250 Consecutive Operations*	
62% M	Age	83% Follow-up
38% F	10-84	(from 3 to 19 yr)

Allergy

Respiratory tract allergy was present in 59 (24%) of 250 patients. Chronic infection was the only primary etiology leading to sinusotomy in which allergy may have played a role since 28% of these patients had associated allergy.

Previous Surgery

One hundred and four of 250 patients (42%) had previous frontal surgery: 46 Lynch operations, 37 trephines, eight duct probings, six Riedel procedures, five osteoplastic sinusotomies performed at other institutions, and two operations of unknown type. Several patients had histories of multiple frontal procedures. These operations were performed from four days to 43 years prior to definitive sinusotomy, the median time being eight years. Seventy-four patients (30%) had 145 previous nasal and sinus procedures other than on the frontal sinus.

Presenting Signs and Symptoms

Frontal pain or headache was the chief complaint in 61% of all patients, forehead or periorbital swelling in 27%, draining fistulae in 5%, diplopia in 4%, and miscellaneous in 3%. Symptom duration ranged from one day to 40 years. In 40% of patients, symptoms were present for more than one year (average 7.7 years).

Seventy-eight patients (27%) had normal physical examination except for decreased or absent transillumination. Forty-five had proptosis, 43 had masses in the superior medial canthal region, 42 had frontal or lid edema, 31 had tenderness, 16 had purulent rhinorrhea, 13 had depression of the frontal bone due to previous trauma or surgery, 10 had "Pott's Puffy Tumor" associated with chronic disease, and 6 demonstrated decreased extraocular motion.

Of special interest are 23 patients (11%) who had painless swelling of the forehead or upper lid region, or had painless proptosis as their only presenting symptom. Swelling had been present for a median of six months duration. Examination revealed proptosis and/or nontender mass of the supraorbital area or superior medial canthal region. This group included patients with chronic infection alone, osteoma with or without infection, trauma with infection fibrous dysplasia with mucoceles and reticulum cell sarcoma. All patients but two with osteoma had erosion of the bony walls of the sinus, including six patients with erosion of the posterior wall with exposed dura. Thus, these patients had rather frighteningly extensive disease in light of the paucity of symptoms.

Regional Complications

Thirty-one patients (12%) presented with regional complications of frontal sinusitis, the primary etiologies being chronic infection alone or chronic infection associated with osteoma or trauma. Four patients had meningitis; six, brain abscess; nine, periorbital cellulitis; four, periorbital abscess; and, eight, osteomyelitis of the frontal bone. All but one of the nine patients with central nervous system (CNS) complications of meningitis or brain abscess had erosion of the posterior wall of the sinus with exposed dura.

Patients with regional complications rarely had a past history of symptoms compatible with frontal sinus disease. In about 80% of CNS and orbital complications, the presenting picture was that of the complication rather than of the primary chronic frontal sinus disease.

The brain and the periorbital abscesses were drained four to six weeks before the sinusotomy. *Staphylococcus aureus* was cultured in the majority of cases. There were no ophthalmologic sequelae. Eight of ten patients with CNS complications had no sequelae.

All patients with osteomyelitis of the frontal bone had significant residual deformity due to erosion of bone or debridement. This deformity was unrelated to the osteoplastic operation. Several subsequently have had cranioplasty to correct the defect.

Incision

One hundred and eighty-seven patients (75%) had brow incisions, 60% being unilateral. Sixty had coronal incisions, and 3 had incisions via previous scar. Average blood loss was 250 cc for unilateral brow incision, 350 cc for bilateral incision, and 650 cc for coronal incision.

TABLE III

OSTEOPLASTIC BONE FLAP

Operation	*Patients*
Unilateral flap	124
Bilateral flap	126
32 unilateral disease	
94 bilateral disease	

Bone Flaps

One hundred and twenty-four patients (50%) had unilateral bone flaps for approach to unilateral sinus disease, 32 (13%) had bilateral bone flaps for approach to unilateral disease, and 94 (37%) had bilateral bone flaps for approach to bilateral disease (Table III). In eight patients, the bone cuts were inadvertently made outside the confines of the frontal sinus. Seven of these eight had exposure of dura, and three had dural lacerations which were small, easily controlled, and without sequelae. One flap was inadvertently fractured into three pieces during elevation. The periosteum was kept intact between the pieces and the final cosmesis was good. There were no instances of necrosis or osteomyelitis of a bone flap.

Wall Erosion

Bony wall erosion occurred in 118 patients (47%). Seventy patients had exposed periorbita, 51 had exposed dura (8 with CNS complications), 20 had interfrontal septum erosion, and 12 had front wall erosion. Several had erosion of more than one wall. Thirty-

two of the 70 patients with exposed periorbita had proptosis (46%). Twenty-seven had a palpable mass in the superior medial canthal region. Only three had periorbital cellulitis or abscess. Eight of the 51 patients with exposed dura (16%) had history of meningitis or frontal lobe abscess.

Culture

One hundred and eighty-four culture reports were available for analysis. Of these, 75 showed no growth and 38 grew only *Staphylococcus albus.* These reports were obtained from patients who were on preoperative antibiotics, or from cases with no associated infection. Seventy-one patients had pathogens isolated. There were 61 Gram positive organisms including 46 with *S. aureus,* six pneumococci, five alpha streptococci, and four beta streptococci. There were ten Gram negatives including four *Escherichia coli,* two Proteus, two Pseudomonas, one Klebsiella and one Bacteroides.

Fat Obliteration

Eighty-three percent of the osteoplastic frontal sinusotomies (208 patients) were obliterated with fat after meticulous removal of all mucous membrane and the inner cortical lining of the sinus. Seventeen percent (42 patients) did not have fat obliteration.

The median follow-up of those with no obliteration is 12 years, indicating that most were done in the early years of experience with this procedure. Ten percent of the patients who did not have fat obliteration required revision surgery because of recurrent frontal sinus infection. Likewise, 4% of those who had fat obliteration were revised.

Supraorbital Ethmoid

Supraorbital ethmoid cells located between the floor of the frontal sinus and the roof of the orbit were recognized in 29 patients (12%). Twenty-two were obliterated with fat after converting them into a common cavity with the frontal sinus, and none required revision. In seven patients the supraorbital ethmoid was not obliterated. In one of these, an unrecognized pyocele led to revision surgery two months later.

Deep Posterior Extension of the Frontal Sinus

This condition was present in 11 patients and often extended as a slit-like pseudopod for two or more centimeters posteriorly between the roof of the orbit and the anterior cranial fossa. Nine were obliterated with fat and remain uncomplicated. There has been one revision of the two cases not obliterated.

TABLE IV

OPERATIVE AND POSTOPERATIVE COMPLICATIONS

47 of 250 Patients (18%)	
Abdominal wound	13
Frontal wound	14
6 hematoma or seroma	
8 abscess (6 required revision)	
Bone cuts outside confines of sinus	8
Dural laceration	7
Miscellaneous	5

Operative Complications

Forty-seven patients (18%) had complications related to the frontal sinus surgery (Table IV).

Abdominal Wound. Thirteen patients had abdominal wound complications. There were 11 hematoma or seroma, and two abscesses, one due to *S. aureus* and one to *E. coli.* All were drained appropriately and added little to the morbidity or duration of hospitalization.

Frontal Wound. Six patients were complicated by uninfected hematoma or seroma, which were drained by removing a few sutures, inserting a rubber drain and applying a pressure dressing. Eight additional patients had abscess of the frontal wound, (five *S. aureus,* one *E. coli,* and two nonpathogens). In six of these, revision surgery was necessary.

Osteoplastic Flap Made Outside the Confines of the Frontal Sinus. Seven patients had exposure of dura, of which three had small dural lacerations. In one patient the bone cut extended into

the opposite normal sinus without consequence.

Dura Laceration. Seven patients had inadvertent dura lacerations. Three were due to bone cuts outside the frontal sinus, and four occurred while stripping mucous membrane from dura exposed by disease. Five of these lacerations were small and were controlled by the adipose obliteration. Two lacerations were large. One was an avulsion which required fascia for repair, and one was repaired with silk sutures. There were no CNS sequelae, and all of these patients remain asymptomatic.

Nasal Skin Necrosis. This complication occurred in two patients secondary to the pressure dressing. In each there was a 2 cm depressed linear scar on the dorsum of the nose. One patient has had revision of the scar.

Other. Three patients had other complications:

1. total anosmia.
2. temporary ptosis which resolved in two months.
3. temporary loss of unilateral frontalis muscle function which resolved in six months.

TABLE V

FOLLOW-UP SYMPTOMS

(208 Patients)

No significant symptoms	93%
Persistent postoperative pain	6%
Persistent neuralgia	1%

FOLLOW-UP SYMPTOMS

No Significant Symptoms. Of the 208 patients with follow-up (Table V), 193 (93%) have no significant symptoms with median follow-up of eight years. This includes those patients now asymptomatic after revision surgery.

Severe Persistent Frontal Pain or Headache. Twelve of the 208 patients with follow-up (6%) have persistent moderate or severe frontal pain or headache, 3 to 13 years postoperatively. This pain or headache does not have the characteristics of neuralgia. There is no relation to allergy, type of incision, fat obliteration or lack of, bony wall erosion, previous frontal surgery, presence or absence of infection at the sinusotomy or to the primary etiologies leading to surgery.

There does seem to be a significant relationship to the existence of chronic moderate or severe preoperative pain or headache. Eleven of these 12 patients had such preoperative symptoms, and in 8, the symptoms had been present for more than two years preoperatively.

Eleven of the 12 patients have no evidence of frontal sinus disease on examination or serial x-ray. Most have had antibiotic treatment in an effort to prove or disprove recurrent infection. All have had extensive negative neurological examination and laboratory studies. Four patients had revision osteoplastic sinusotomies, and no evidence of frontal sinus disease was found at surgery. One patient has had a recommendation for revision surgery at another institution.

Seven of these 12 patients have x-ray evidence of chronic sinusitis in sinuses other than the frontal sinus. One patient is to undergo surgery for an ethmoid mucocele. Five, by x-ray, had no evidence of disease in other sinuses.

Two patients have had neurectomies without relief of symptoms. One had a supraorbital nerve neurectomy, and one a sphenopalatine ganglionectomy. Two patients had a history of psychiatric disorder. One had a history of conversion reaction, and the other, drug addiction.

Neuralgia. Three of 208 patients with follow-up have had persistent frontal neuralgia for up to ten years postoperatively. These patients had brow incisions with the necessary severance of the supraorbital nerves, which probably is causative. They have been treated with repeated local anesthetic and alcohol injections of the supraorbital nerves without permanent relief. An additional patient had severe neuralgia completely relieved after alcohol injec-

tions six months postoperatively. Several other patients with brow incisions had temporary neuralgia in the first few months after surgery.

Persistent Abnormal Forehead Sensation. Almost 100% of patients with brow incisions, and the majority with coronal incisions, had temporary distorted forehead sensation described as numbness, pruritis, tightness, crawling paresthesias, and pins and needles paresthesias. In 65% of these patients, symptoms disappeared in six to twelve months. However, in 35% the abnormal sensation is persistent, though no patient described the symptoms as more than a minor annoyance. There was no significant difference in the percentage of patients who had brow or coronal incisions when considering the persistent anesthesia and paresthesias. However, those with brow incisions generally stated that the symptoms were more annoying.

TABLE VI

COSMESIS

Scar		
Good or excellent		88%
Fair or poor		12%
Bony forehead contour		
Good or excellent		79%
Fair or poor		21%
Defect existed preoperatively	75%	
Elevated or depressed bone flap	25%*	

* 6% of all patients

Cosmesis

Evaluation of cosmetic result was divided into appearance of the scar, and appearance of the bony forehead contour (Table VI). These observations were the subjective opinion of the examining physician.

Scars. Eighty-eight percent of all scars, brow and coronal, were considered good or excellent. Fair or poor coronal scars were due to exposure of the scar by natural balding in two males. Fair or poor brow scars resulted when the incision was made too high above the brow, when incisions from previous surgery were reincised, or when the incision between the brows did not extend to the deepest recess of the glabella.

Bony Contour. Seventy-nine percent of all forehead contour cosmesis was considered excellent or good (89% of coronal, 74% of brow). In three-fourths of those with fair or poor forehead contour, the deformity was secondary to a previous surgical defect, or to anterior sinus wall erosion due to disease. Thus in 6% of all patients was the bone flap cosmesis considered fair or poor, secondary to depression or elevation of the flap. Relatively more of these were associated with brow incisions rather than coronal, particularly unilateral brow incisions. This may be due to the more difficult exposure with the unilateral brow incision which can produce difficulty in beveling the superior bone cuts. There were no permanent floating osteoplastic flaps due to nonunion.

Twelve patients had surgery to correct cosmetic defects. Two patients had scar revision, and ten had cranioplasty or bone grafting to correct the bony depressions. Nine of these defects were due to previous surgery or anterior wall erosion by disease. One was related to a depressed flap following osteoplastic operation.

X-ray

Initial x-ray evaluation was extremely accurate in predicting the extent and etiology of disease even in the prepolytomography era. The most frequent error of omission, without polytomography, was not being able to predict wall erosion. With polytomography, the surgeon can accurately be advised as to wall erosion and the presence of supraorbital ethmoid cells, or deep posterior extensions of the frontal sinuses.

Serial postoperative x-rays of the frontals have been of great value in determining whether or not recurrent infection of the sinus is present. In three instances, such serial radiographs ruled out recurrent mucoceles which were thought to be present on initial postoperative x-rays. Subsequent films have shown no change in the lucencies

TABLE VII

REVISION FRONTAL SURGERY

20 of 208 Patients with Follow-up		*Patients*
Short-term revisions		6
Acute wound infection and fat necrosis	5	
Acute wound infection due to unrecognized supraorbital ethmoid pyocele	1	
Long-term revisions		14
Negative exploration for persistent pain	4	
Osteomyelitis outside normal sinus	2	
Recurrent chronic sinus infection	7	
Recurrent fibrous dysplasia with infection	1	
	Total	20

after several years. In one patient, serial studies revealed an expanding mucocele in an otherwise asymptomatic patient.

Initial x-rays in 115 of 190 patients with chronic infection (61%) indicated involvement of other sinuses in addition to the frontals. Ethmoid involvement was more common than antral or sphenoid. Only 17% of patients with osteoma, trauma, and miscellaneous etiologies showed sinusitis in other than the frontals, and all of these had secondary chronic infection of the frontals. Thirty-five percent of those patients with evidence of ethmoid, sphenoid or maxillary sinusitis on preoperative x-ray had complete clearing of the sinuses on follow-up radiography. Conversely, 10% of those with no evidence of disease in other sinuses preoperatively did have such sinusitis on follow-up films.

REVISION FRONTAL SURGERY

Twenty patients of 208 with follow-up (9.5%) have had revision frontal surgery from four days to 14 years (median two years) following the initial procedure (Table VII). Four of these cases were performed initially on the Resident Service (6.5% of 61 cases with follow-up). Sixteen of the revisions were initially done by nine members of the Attending Staff (11% of 147 cases with follow-up).

Short-Term Revisions

Six revisions were done in the first few days or months after the original surgery because of persistent purulent drainage via a fistula following acute wound infection. All had fat obliteration at the first sinusotomy, and the operative findings in each, at revision, was acute infection with fat necrosis. However, in one of these the initial procedure failed because a supraorbital ethmoid pyocele was unrecognized. These six patients represent 3% of all those who had fat obliteration at the first operation.

At revision two patients had fresh fat obliteration, the wounds were closed primarily, and specific antibiotics instituted. Four did not have obliteration; two had Riedel procedures, one had the wound packed open due to allergy to appropriate antibiotics, and in the fourth, no reason was given for not reobliterating. The last patient developed another wound infection, and was reexplored a second time. The other five patients are asymptomatic to date.

Long-Term Revisions

Fourteen patients had revision a median of five years after the original surgery; the longest interval was after fourteen years. Eight of the patients were found to have recurrent infection in the frontal sinus, whereas six were found to have no infection in the sinus. Of the latter, four had negative reexplorations for persistent postoperative pain, and two developed frontal bone osteomyelitis at sites of previous trauma outside the sinus.

Of the eight patients with recurrent

chronic infection within the frontal sinus, all but one presented with acute gross findings of complicated chronic disease: swelling, proptosis, forehead abscess, fistulae or tenderness. The other patient had evidence of enlarging mucocele on serial radiographs, though his examination was unremarkable. This is in contrast to no evidence of recurrent disease on exam or x-ray in the four reexplored for persistent pain.

The reasons for failure in the eight patients with recurrent chronic sinus infection were evident in all but one:

1. Three did not have removal of all mucous membrane at the first operation according to the operative records. Two of these had fat obliteration.
2. Three were not obliterated with fat, possibly allowing regrowth of mucous membrane from the nasal cavity.
3. One patient had recurrent fibrous dysplasia plus chronic infection.

Excluding the patient with fibrous dysplasia, seven patients, or 3% of 208 with follow-up, had long-term failure with recurrent chronic frontal sinus infection.

TABLE VIII

REVISION DUE TO RECURRENT SINUS INFECTION

Of 208 Patients with Follow-up	
Acute infection	6 (3%)
Chronic infection	7 (3%)
Total	13 (6%)

Discussion of Revisions with Recurrent Infection

Thirteen patients, or 6% of 208 with follow-up, had revision due to acute infection or recurrent chronic infection within the frontal sinus (Table VIII). There was an equal revision rate for each initial etiology. Fifty-four percent had associated allergy (versus 24% of all patients). Seventy percent had bony wall erosion by the original disease (versus 47% of all patients). Four percent (9 of 208) who had original fat obliteration were later revised, whereas 10% (4 of 42) of those who did not have fat obliteration, had revision. In comparison to the total patient population, there was no correlation of the revision surgery in reference to types of incisions used at initial surgery, whether the initial disease was unilateral or bilateral, culture at original sinusotomy, presence of associated systemic disease, or history of frontal sinus surgery prior to the initial osteoplastic procedure.

It should be mentioned that 13 patients had fat obliteration at revision surgery, and none have evidence of disease to date. Conversely, four of seven patients with no fat obliteration subsequently had a second revision.

Conclusions

1. The osteoplastic frontal sinusotomy is the procedure of choice for treating all chronic complicated diseases of the frontal sinus except malignant disease. Adipose obliteration should be accomplished in all cases, regardless of etiology, unless unsuspected malignant disease is encountered.

2. Subcutaneous fat should be obtained with atraumatic technique just before insertion into the prepared sinus. Two patients with acute postoperative wound infection and fat necrosis had fat obtained at the beginning of the procedure, possibly allowing drying and necrosis before insertion into the sinus.

3. Specific antibiotic therapy should be instituted preoperatively in all cases associated with chronic infection. Until culture and sensitivity reports are available, coverage for *S. aureus* is recommended.

4. The patient should be crossmatched for blood replacement.

5. The coronal incision is ideal for females, and also for males who have demonstrated no tendency for balding. It offers better cosmesis and exposure than the brow incision at the expense of increased blood loss. No patient with the coronal incision had postoperative neuralgia.

6. Bilateral bone flap approach for unilateral disease can be technically easier, and can offer better exposure than a unilateral flap.

7. Supraorbital ethmoid cells should be converted into a common cavity with the frontal sinuses, and obliterated. Likewise, deep posterior extensions of the frontal sinus sould be included with fat obliteration. Removal of the inner cortical lining often requires the smallest diamond burr, and an operating microscope may be necessary.

8. Treatment of osteomyelitis associated with chronic frontal sinus disease should include preoperative antibiotics, surgery with a combination of osteoplastic adipose obliteration and debridement of necrotic bone, and postoperative antibiotics for six weeks. Most cases of osteomyelitis associated with an initial acute frontal sinusitis will respond to antibiotic treatment only. Occasionally, trephination can be used in addition to antibiotics.

9. Operative complications have generally been minor and of no permanent consequence. There have been no operative deaths, nor CNS or ophthalmologic complications.

10. Thirteen patients had revision due to recurrent frontal sinus infection. This is a 6% failure rate. Six patients (3%) had short-term revisions due to acute postoperative wound infection and fat necrosis. One of these had an unrecognized supraorbital ethmoid pyocele. Postoperative frontal wound infections should be treated aggressively with specific antibiotics and drainage. If infection persists, the sinus should be reexplored, the necrotic fat removed, and fresh fat obliteration accomplished. Seven patients (3%) had long-term revisions due to recurrent chronic infection. All had gross physical or x-ray findings of recurrent disease. All patients who came to revision, except one with osteoma, had chronic infection evident at the first operation. Associated allergy and bony wall erosion was significantly higher in patients who had revision.

11. After discharge from the hospital, postoperative follow-up care, patient inconvenience, and discomfort are usually minimal. This is in contrast with most other radical frontal sinus procedures. The patient should have postoperative x-rays three weeks after surgery, after one year, and serially thereafter if symptomatic.

12. Six percent of patients have moderate to severe persistent frontal pain or headache postoperatively with no evidence of recurrent disease. Those with chronic severe preoperative pain or headache seem most likely to develop this distressing symptom. Reexploration is rarely indicated if extensive otolaryngologic, neurologic, and serial radiologic work-up is negative in these patients.

13. Thirty-five percent of all patients have persistent anesthesia or paresthesia of the forehead after surgery.

14. Though cosmesis after the osteoplastic procedure is generally far superior to other radical frontal operations, unpleasant results can occur. Properly placed incisions and meticulous closure can minimize scar deformity. Beveled bone incisions and meticulous closure of periosteum can avoid osteoplastic flap elevation or depression. If there is any question concerning the stability of the bone flap, drill holes and wiring are indicated.

15. While it is believed that the osteoplastic sinusotomy with fat obliteration is far superior to other frontal operations in regards to disease eradication, cosmesis, minimal postoperative care, and patient discomfort, it must be reiterated that frontal sinus disease can be insidious. Follow-up in this study is nineteen years, whereas recurrent disease has become evident up to forty-three years after other types of frontal surgery.

REFERENCES

1. Zonis RD, Montgomery WW, Goodale RL: Frontal sinus disease: 100 cases treated by osteoplastic operation. Laryngoscope 56: 1816-1825, 1966

ACKNOWLEDGMENTS—The authors thank the members of the Massachusetts Eye and Ear Infirmary Staff for allowing use to include their patients in this study. We particularly thank Robert L. Goodale, MD, for his kind advice. Follow-up radiology was interpreted by Alfred L. Weber, MD. Special acknowledgment is due Mary Ellen Doyle, Patricia Egan and Pauline Hardy for their technical assistance.

REPRINTS—James M. Hardy, MD, 1127 North Boulevard, East, Leesburg, FL 32748.

LARYNGEAL SUSPENSION AND EPIGLOTTIC FLAP IN LARYNGOPHARYNGEAL TRAUMA

NELS R. OLSON, MD

ANN ARBOR, MICHIGAN

SUMMARY – Physicians treating laryngeal trauma are still looking for ways to improve results. Severe disruption of the supporting structures between hyoid and trachea may allow stretching and narrowing of the laryngeal lumen during the healing period. This can easily be prevented by placing wires across the disrupted zone. In addition, loss of the epithelial lining of the larynx is a serious cause of stenosis. By dissecting out the epiglottic cartilage, one can create a sizeable, useful flap of mucous membrane based in the vallecula to use in relining of the anterior larynx.

The search continues for the best ways to prevent stenosis in repair of blunt laryngeal injuries. In two recent cases I have treated, I have utilized two techniques which have not been reported previously, to my knowledge. One of these techniques I call laryngeal suspension. It involves wiring between the hyoid and the larynx to support structural weakness and prevent stretching and narrowing of the lumen. The other is the use of a flap of mucosa developed by dissecting out the epiglottis to help reline the larynx, thereby promoting primary healing.

CASE REPORTS

Case 1. A male, aged 25, struck his neck on the steering wheel of his car in an accident on February 26, 1974. Soon thereafter, he underwent open reduction, suture of mucosal lacerations and placement of a silicone stent (Montgomery's type). Two weeks later the repair had broken down and the stent was exposed anteriorly and surrounded by granulation tissue. The wound was reopened, using a "T" incision. Granulation tissue was excised from the larynx. A vallecula-based flap was developed by dissecting out the epiglottic cartilage. The larynx was stented with a skin graft sutured raw side out around a sponge covered with finger cots. The epiglottic flap was placed in the anterior larynx where mucosa had been lost. Wires were then placed between

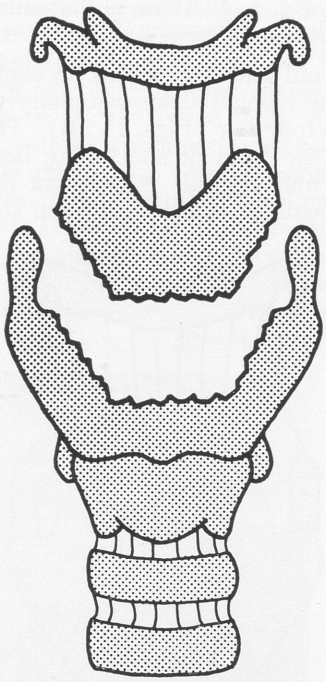

Fig. 1. (Case 1) Separation of a large fragment of thyroid cartilage. The lumen is narrowed by the resulting stretching and elongation.

From the University of Michigan Medical School and Ann Arbor Veterans Administration Hospital, Ann Arbor, Michigan.

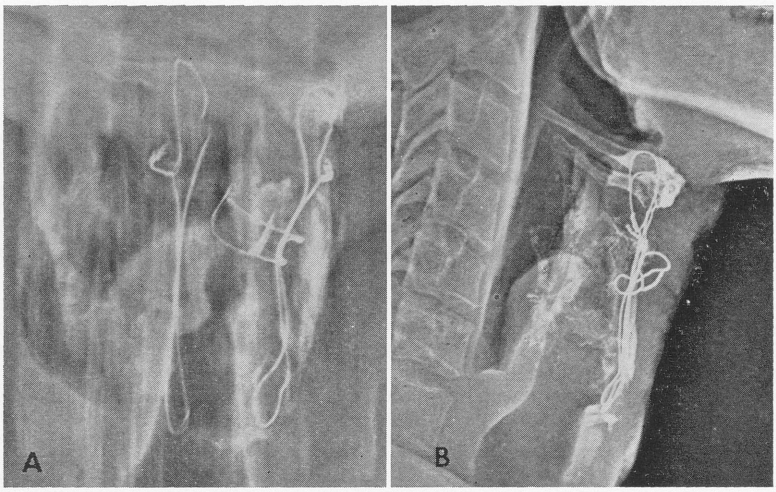

Fig. 2. A) (Case 1) Suspension wires placed from hyoid to cricoid. Direct wiring of the loose fragment of thyroid cartilage. B) (Case 1) Lateral view of repair.

the hyoid and the cricoid on each side and the elongated laryngopharynx was drawn together (Figs. 1 - 2B). This resulted in 2 cm of shortening between hyoid and cricoid. A segment of thyroid cartilage which had been severed in the original injury was wired into place. Eighteen days later the sponge stent was removed. At this time healing was by primary intention and no granulation was seen in the larynx. Two months after that, the tracheotomy tube was removed. The patient had a breathy voice because of an abducted, immobile right vocal cord and in March of 1975, about one year after his initial injury, he had a Teflon® paste injection of the right vocal cord to improve the voice quality. Currently, he has some dyspnea on exertion and a fair voice. He is working full time.

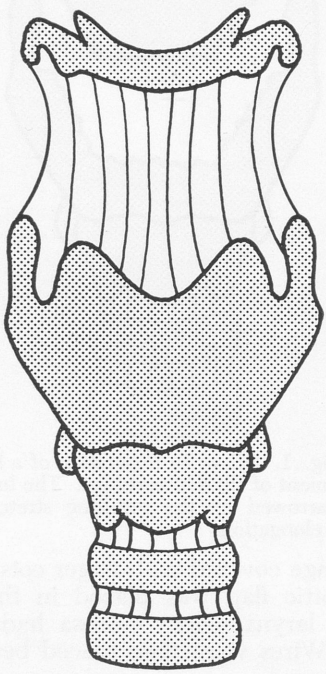

Fig. 3. (Case 2) Scarf injury has destroyed support between hyoid bone and thyroid cartilage, resulting in elongation and narrowing of the lumen.

Case 2. On March 18, 1972, this 9-year-old boy backed into a lathe, catching both ends of a scarf he was wearing in the turning machinery. Fortunately, the machine was stopped quickly. He was hospitalized with stiff neck, skin abrasions, subcutaneous emphysema and dysphagia. There was no airway problem at first. Initial treatment consisted of antibiotics, steam, steroids, bedrest, voice rest, oxygen. Thirteen days later he was still unable to swallow and a direct laryngoscopy was done. Circular granulations were seen just above the true cords and extending around the entire pharyngeal wall. He was discharged on tube feedings. Gradually, airway obstruction developed and on April 12, 1972, 26 days after injury,

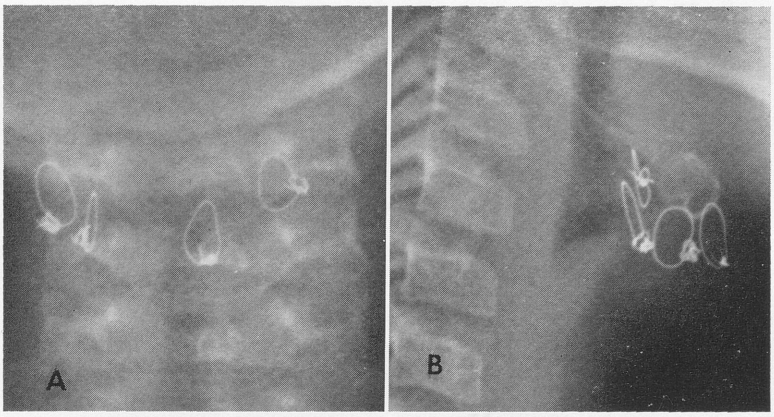

Fig. 4. A) (Case 2) Suspension wires placed between hyoid bone and thyroid cartilage. B) (Case 2) Lateral view of repair.

a tracheotomy was performed. Shortly thereafter the area of injury closed completely except for the feeding tube.

On June 16, 1972 he underwent pharyngotomy, excision of some scar tissue, and skin grafting of the pharynx. This operation succeeded to the extent that he could swallow liquids and some soft solids, but he still had to wear his tracheotomy tube.

Three years later, on June 19, 1975 he underwent another procedure. This time he had circumferential resection of scar tissue, sparing the mucosa. Additional mucosa was obtained by dissecting out the epiglottic cartilage. The gap between the hyoid bone and thyroid cartilage which had been produced by the injury was closed, using wires to draw these structures together (Figs. 3 - 4B). Placement of the wires resulted in 2 cm of shortening between hyoid bone and thyroid cartilage. The mucosa was carefully sutured. No stent was used. Two months later, he was eating

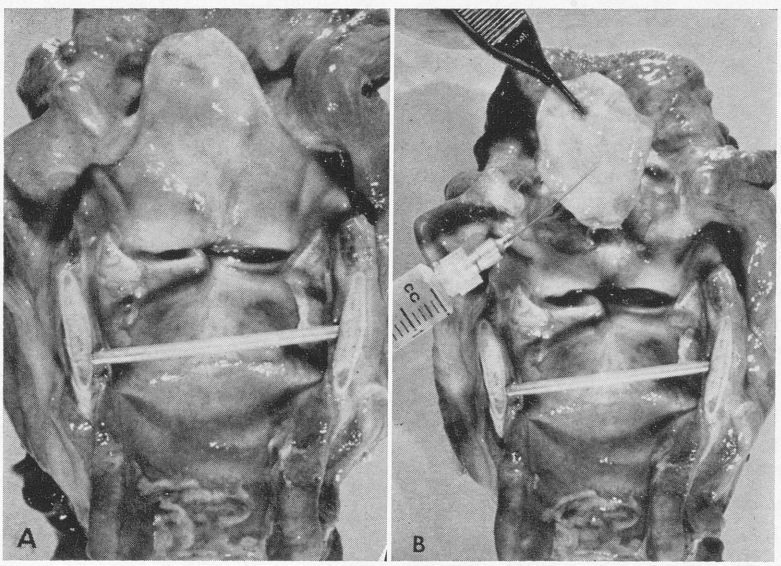

Fig. 5. A) Fresh laryngeal specimen, posterior-anterior view of epiglottis. B) Incision from vallecula through aryepiglottic fold around petiolus of epiglottis, through contralateral aryepiglottic fold and ending in contralateral vallecula. Injection of saline beneath mucosa aids elevation.

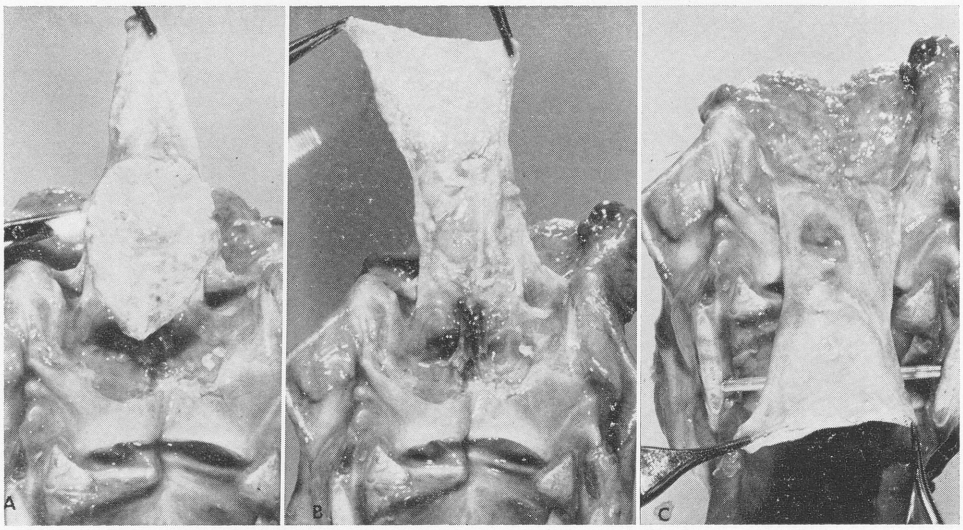

Fig. 6. A) Laryngeal surface of epiglottis dissected completely. B) Epiglottic cartilage removed. C) Flap easily reaches from vallecula to upper trachea.

with ease, gaining weight and could be decannulated. He has functioned normally since.

DISCUSSION

Laryngeal Suspension. With each swallow, there is forcible elevation of the hyoid bone, larynx, and trachea by contraction of the mylohyoid muscle. The supporting elements which transmit this force through the larynx to the treachea are the thyroid cartilage, thyrohyoid muscle, thyrohyoid membrane and associated ligaments. With crushing or disruption of some of these structures, the upward pull of the mylohyoid will stretch and elongate the soft tissues in the area of injury. This will lead to narrowing analagous to the drawing out of a heated glass tube.

Wiring across the area of injury ("laryngeal suspension") has these advantages:

1. The wiring of weakened structure prevents elongation and narrowing of the lumen.

2. By drawing the wires quite snug one can overcorrect slightly, hoping thereby to widen the lumen of the larynx or pharynx a little.

3. The wiring eliminates all motion between the wired parts, putting the unit at rest and promoting healing. This is especially important when a flap or graft has been placed in the lumen or the mucosa has been sutured.

Epiglottic Flap. One of the important principles in repair of the crushed larynx is to create conditions which will result in primary healing. The goal is to prevent granulation and fibrosis. I have used a skin graft in the lumen whenever there has been disruption of the mucosa, as added insurance against granulation and fibrosis in case sutured mucosal lacerations break down.

In Case 1, the epiglottis and part of the thyroid cartilage were separated from the rest of the larynx. There was considerable loss of anterior laryngeal mucosa. It was therefore decided that the epiglottis should be dissected out in such a way that a flap of mucosa based in the vallecula would be formed (Figs. 5, 6). It appears that such a flap will be useful in many cases of laryngeal injury because of the high priority of the anterior commissure region and the ease with which this area can be reepithelialized by this method.

SUMMARY

I have described two adjuncts to treatment of laryngopharyngeal injuries.

One, laryngeal suspension, is designed to prevent or correct elongation and narrowing of the lumen by upward motion of the hyoid with swallowing. The other, the epiglottic flap, is a way of providing epithelial lining for the anterior part of the larynx when necessary.

REPRINTS—Nels R. Olson, MD, University of Michigan Medical Center, Ann Arbor, MI 48104.

DISCUSSION

DOUGLAS BRYCE, MD: I wanted to comment on Dr. Olson's paper. It leaves me somewhat confused. The first case looked to me like a supraglottic laryngeal fracture with posterior displacement of the epiglottis, preepiglottic space, and some portions of the thyroid ala.

Why is it not proper to do a supraglottic laryngectomy rather than trying to replace the epiglottis and the displaced structures? It may be that there was more damage to the larynx than was described.

The second point with regard to the wiring of the hyoid to the thyroid again confuses me a little bit because again when we do laryngeal drop, this is exactly the procedure we carry out. And, we don't seem to have very much trouble with swallowing or airway following this particular procedure.

So, I would like to ask Dr. Olson if he would care to comment on these two suggestions.

ROBERT L. GOODALE, MD (Ipswich, Massachusetts): I want to comment on the osteoplastic frontal sinusotomy operation. Thirty-six of these cases were my own. I performed the first operation in this country in 1956 after I had been to Puerto Rico and heard a paper by Dr. Beraglio of Buenos Aires and had corresponded with Drs. Tato and Bergara of Buenos Aires and also with Mr. Macbeth of England.

We had rather poor results from transorbital radical surgery, and it seemed that this might help in some of our difficult patients. Both Dr. Montgomery and I worked on these cases together and we reported many times the results and described our technique.

I would like to make one comment about the rationale of the fat implant. In South America, they used what Bergara called "boiled fat." This was fat that had been autoclaved, sterilized and presumably was nonviable. It acted somewhat as a foreign body. His theory was that the cellular framework of the implant would be replaced by osteogenesis or fibrosis from the frontal sinus so that the cavity would gradually be filled with solid tissue.

It seemed to us that we could use live fat in our cases. In other words, we would take the fat from the abdominal wall and place it in the cavity as a living fat graft. Now Mr. Macbeth does not do that. He told me he considers the frontal sinusotomy somewhat analogous to the Caldwell-Luc operation on the maxillary sinus. He would take no fat. He would just remove all the mucosa from the sinus and the nasofrontal duct and rely on the osteogenesis from the bare bone to obliterate the cavity. The success of the fat implant, I believe, depends entirely on the meticulous removal of all infected mucosa and very careful bacteriological check-up and analysis of the pathogenic organisms involved and proper control with antibiotics. The follow-up is terribly important.

I wish to congratulate the essayists for a very thorough analysis and a very honest report of our results.

JOHN F. DALY, MD: I would like to comment on Dr. Olson's experience with the epiglottic flap. About ten years ago I had occasion to use the epiglottis as a flap in a patient who attempted to commit suicide with a carving knife. The initial repair was done in a hospital emergency room near her home. Complete stenosis developed in the pharynx. In other words, she succeeded in cutting right through to the posterior wall of the pharynx. Several months later in reconstructing the pharynx, I was looking for mucosal lining to cover the defect left by removal of scar tissue. The epiglottis was handy. I kept the cartilage attached to the mucosa and split the epiglottis in the midline. The two halves lined by mucosa and attached to the base of the tongue could be rotated to either side of the larynx and pharynx for reconstruction.

The cartilage acts as a batten, proving support. Thus, you have mucosal lining on the pharyngeal side and the cartilage, besides giving support, also prevents further contraction.

WILLIAM W. MONTGOMERY, MD (closing): Before Dr. Olson gets up here, I would like to congratulate him on a very fine paper. I think it takes an innovative and aggressive surgeon to treat this type of lesion.

I would, however, like to ask him a couple of questions. What size laryngeal stent was used in the first case? It seemed to me that it might have been a little large. There are three sizes of the silicone conforming laryngeal stent. I would be inclined to agree with Dr. Bryce that these injuries represent a laryngeal inlet type of stenosis. The procedure which we have described and is quite similar

to that mentioned by Dr. Daly, is quite useful in treating this type of injury.

I again compliment him on a fine presentation and also I would like to compliment our senior resident, Dr. Hardy, on a wonderful presentation.

NELS R. OLSON, MD (closing): I do not feel positive about using supraglottic laryngectomy to treat supraglottic stenosis. It strikes me as a destructive method and creates new wounds in the area. Another concern is that one may cause sensory denervation of the larynx by this operation.

The primary guiding principle in treatment of laryngeal injuries for me has been to attempt to obtain primary healing. Rather than remove elements of the larynx which have been injured, I would prefer to reposition and repair them. The epiglottis, when dissected out, provides a large piece of mucosa local to the area which provides additional epithelial cover and is a real advantage in repair of these injuries. I have never been satisfied with the method of repair which requires re-epithelialization over an indwelling stent.

Dr. Bryce mentioned that the operation to drop the larynx down for repair of tracheal injuries does not cause stenosis by elongation of the lumen. I believe this is because the injury here is a controlled one without damage to cartilage or mucosa. When this procedure is done, it is usually done by sectioning the tissues between thyroid and hyoid or by releasing the hyoid. In either of these areas, some narrowing can be tolerated.

I appreciated Dr. Daly's remarks about his previous use of an epiglottic flap. I am suspicious that others have used the epiglottic mucosa before. I simply have never run across an organized presentation of the epiglottic flap and the way to do it. It is an excellent flap of mucosa which is readily available and of a type natural to the local area. Since the epiglottis serves no purpose, the cartilage can be removed without hesitation. The mucosa which is so badly needed to promote primary healing of the laryngeal injury, is readily available.

Skin grafting of the larynx is not the best method to use, although it is very utilitarian. Some of them build up epithelial debris which must be coughed out from time to time.

Dr. Montgomery states that the laryngeal stent used in Case 1 may have been too large. I am not certain whether it was a proper size or not since I did not place it in the first place.

Executive Sessions

FIRST EXECUTIVE SESSION

April 24, 1976

The first Executive Session of the Ninety-Seventh Annual Meeting was convened at 8:10 A.M. in the Venetian Ballroom of The Breakers Hotel, Palm Beach, Florida, Stanton A. Friedberg, MD of Chicago, Illinois, President of the Association, presiding.

The two items on the agenda were the election and presentation of the new Fellows and the appointment of the Nominating Committee.

The following candidates, having been recommended for Fellowship by the Council, were unanimously elected:

To Active Fellowship:

Thomas D. R. Briant, MD, Toronto, Ontario, Canada

Robert W. Cantrell, MD, San Diego, California

Patrick J. Doyle, MD, Vancouver, British Columbia, Canada

Raleigh E. Lingeman, MD, Indianapolis, Indiana

Andrew W. Miglets, Jr., MD, Columbus, Ohio

To Emeritus Fellowship:

Robert E. Priest, MD, Minneapolis, Minnesota

Following their election the new Fellows were introduced to the Association by their respective sponsors, presented with certificates of Fellowship and welcomed by President Friedberg.

The following Fellows were elected as members of this year's Nominating Committee:

John E. Bordley, MD, Chairman

John J. Ballenger, MD

David D. DeWeese, MD

Joseph L. Goldman, MD

Jerome A. Hilger, MD

SECOND EXECUTIVE SESSION

April 25, 1976

The second Executive Session was convened by President Friedberg at 8:12 A.M. Annual Reports of the Officers were presented, followed by reports of committee chairmen or representatives to other organizations.

REPORT OF THE SECRETARY

I. *Membership:* The current membership of the Association is:

Active	96
Emeritus	32
Honorary	9
Corresponding	15
Total	152

The Secretary recommended that the constitutional limit of 100 Active members should be the goal for the Hundredth Anniversary celebration in 1978. This can be attained by electing eight new members in 1977 and eight new members in 1978.

There are ten candidates under review at the present time and the Secretary urged that additional proposals for membership should be made in the coming months.

II. *ALA Funds:* During the past year, efforts have been made to stimulate contributions to The Memorial Fund and enrollment of Benefactors. A goal of $100,000 should be set for the next ten years as reasonable. It was felt that through even modest bequests from the members and special fund raising efforts, this goal could be easily attained. This would make it possible to make meaningful funds available to support young investigators in Laryngology and Rhinology.

III. *Council Meeting Reports:* The Council held its Annual Meeting in Washington, D. C. on January 3, 1976 and its Second Council Meeting on April 23, 1976 in Palm Beach. The actions taken by the Council are included in the agenda of the Annual Business Meeting.

IV. The Second Daniel C. Baker, Jr. Lecture will be given at this meeting. We solicited contributions to the Baker Memorial Fund this year too, and are pleased with the response. Our Fund at the present time is somewhat close to $29,000 and we hope to reach $30,000 in the next year.

Next year's meeting will be held on May 8 and 9, 1977 at the Sheraton Boston Hotel in Boston, Massachusetts.

In 1978 our Centennial celebration will be held in New York. You will hear a great deal more about this at the Business Meeting when the reports are made by the Chairman of the Centennial celebration, Dr. Alden Miller, and also from

Dr. John Lewis, Chairman of the Subcommittee on Local Arrangements. Dr. Lewis and his Committee have selected the Waldorf-Astoria for the meeting.

In 1978 our meeting will be held from May 19 to May 21 in New York, preceding the Spring Meetings at The Breakers.

For future meetings, Vancouver is being considered as a meeting site for 1981 and after that, Phoenix, San Diego and New Orleans.

Respectfully submitted,
John F. Daly, MD
Secretary

(This report was duly accepted by the Fellows.)

REPORT OF THE TREASURER

Exhibit A

AMERICAN LARYNGOLOGICAL ASSOCIATION
GENERAL FUND
OPERATING STATEMENT AND FUND BALANCE
FISCAL YEAR ENDING MARCH 31, 1976

Income			
Dues (6 @ $150 – 82 @ $100)		$9,100.00	
Sales of Transactions		1,440.00	
Sales of Banquet Tickets		3,990.00	
Interest (Savings Acct. 349.06; S & L 1,872.67)		2,221.73	
Assessments re Centennial		2,225.00	
			$18,976.73
Expenses			
Annual Meeting 1975 (Atlanta)			
Reception and Banquet	$3,880.63		
Reporting	429.45		
Projection	540.41		
Programs, inserts and Membership Certificates	628.00		
Guest of Honor	97.76		
Secretarial Help	47.00		
Miscellaneous	40.32		
Total Annual Meeting Expense		5,663.57	
Council Expense		1,905.48	
Transactions and Editorial Expense		4,458.33	
General Expense			
Stationery, printing, postage	775.18		
Clerical Hire	900.00		
Auditing	175.00		
Treasurer's Bond	55.00		
Dues-Int. Fed. Otolaryngological Societies	202.50		
National Society of Medical Research	100.00		
American Council Otolaryngology	150.00		
Miscellaneous	15.47		
Total General Expense		2,373.15	
TOTAL EXPENSES			$14,400.53
NET INCOME FOR YEAR (including $2,225 Centennial Assessment)			4,576.20
Fund Balance March 31, 1975			10,067.03
Fund Balance March 31, 1976			14,643.23
Less Escrow Centennial Assessments ('74-75 and '75-76)			4,475.00
Fund Balance March 31, 1976 (excluding Centennial Assessments)			10,168.23

Exhibit B

AMERICAN LARYNGOLOGICAL ASSOCIATION
TRUST FUND
OPERATING STATEMENT AND FUND BALANCE
FISCAL YEAR ENDING MARCH 31, 1976

Income			
Interest on U. S. Series H Bonds	$ 396.88		
Interest on Income Bond	151.48		
Interest on Treasury Bills	1,467.00		
Dividends Common Stocks and Mutual Fund	1,925.42	$ 3,940.78	
Donations:			
Baker Fund	1,215.00		
Memorial Fund			
Edley Jones $ 400 (additional)			
Robert Goodale 550 (in Memory of Joseph L. Goodale)			
Joseph Goldman 100			
F. H. Mc Govern 1,000			
John F. Daly 100			
Sam H. Sanders 100	2,250.00	3,465.00	$ 7,405.78
Expense			
Baker Fund (brochures, reprints, etc.)	1,397.24		
Research grants Dr. Edwin Everts	1,000.00		
Dr. Marcello Obando	1,520.00		3,917.24
Net Income for Fiscal Year			3,488.54
Fund Balance March 31, 1975			111,075.48
Fund Balance March 31, 1976			114,564.02

TRUST FUND ASSETS

Cash			$ 2,059.77
Savings Certificates (1st Federal S & L Assn. (of Phila.)			30,000.00
Income Bond (Girard Bank – Phila.)			25,000.00
Investments (Exhibit D)			
U. S. Bonds Series H at cost, par and maturity		$ 6,500.00	
Common Stocks			
Purchased (at cost)	$11,617.52		
Donated (market value at donation)	2,362.00	13,979.52	
Mutual Fund (Mass. Inv. Trust) at cost		37,024.73	
			57,504.25
Total Trust Fund Assets:			114,564.02

CASH SUMMARY

Cash in Commercial Account (Girard Bank – Phila.)		13,043.69
Cash in Savings Account (Girard Bank – Phila.)		3,659.31
		16,703.00
Allocation		
General Fund (Exhibit A)		$14,643.23
Trust Fund (above)		2,059.77
		16,703.00

Exhibit C

AMERICAN LARYNGOLOGICAL ASSOCIATION
INDIVIDUAL TRUST FUNDS
MARCH 31, 1976

	Principal and Retained Earnings 3/31/75	*Earnings**	*Donations - Additions*	*Awards - Expenses*	*Principal and Retained Earnings 3/31/76*
Daniel C. Baker, Jr., Memorial Fund	$ 27,965.00	$ 992.15	$1,215.00	$1,397.24	$ 28,774.91
Casselberry	11,293.71	400.68			11,694.39
Johnston	10,693.04	379.37			11,072.41
DeRoaldes	6,720.77	238.44			6,959.21
Newcomb Trust	4,198.01	148.93			4,346.94
Newcomb Prize	979.82	34.76			1,014.58
Research	32,451.58	1,746.45	2,500.00(1)	2,520.00	34,178.03
Memorial	16,773.55		2,250.00	(2,500.00)(1)	16,523.55
	111,075.48	3,940.78	5,965.00	1,417.24	114,564.02

*Net income for the year is allocated to each fund in the ratio it bears to the total value of the trust funds at the beginning of the year, except that by action of the Council, January 3, 1976, current income from the Memorial Fund is added to the Principal and Retained Earnings of the Research Fund.

(1)Transfer from unused income of Memorial Fund to Research Fund. (Council action 4/5/75)

Exhibit D

AMERICAN LARYNGOLOGICAL ASSOCIATION
TRUST FUND INVESTMENTS
MARCH 31, 1976

Savings Certificates (First Fed. S & L of Phila.)			$30,000.00	$ 30,000.00
U. S. Government Bonds				
Six $1,000 Series H Bonds (now mature)			6,000.00	
One $500 Series H Bond (now mature)			500.00	
				6,500.00
Girard Bank 7.5% Income Bond Purchased 2/6/76				25,000.00
Common Stock	*Shares*	*Cost*	*Market Value at Donation*	
American Telephone and Telegraph	200	$10,790.16		
International Business Machines Corp.	1		517.00	
International Business Machines Corp. (1)	9	803.98		
McDonnell Douglas Corp. (2)	112		1,170.00	
McDonnell Douglas Corp. (3)	14	23.28		
McDonnell Douglas Corp. (4)	3			
McDonnell Douglas Corp. (5)	3			
McDonnell Douglas Corp. (6)	33			
McIntire Porcupine Mines, Ltd.	15		675.00	
		11,617.52	2,362.00	13,979.52
Mutual Fund (Mass. Investors Trust) at cost				37,024.73
TOTAL TRUST FUND INVESTMENTS				112,504.25

Notes: (1) Includes 7¼ shares received in stock splits 1965, 1966, 1968, 1973.
(2) Includes 86 shares received in stock dividends and splits 1964, 1965, 1966.
(3) Includes 13.44 shares received in stock split 1967; rights exercised to purchase 0.56 share.
(4) Shares received as stock dividend (3%) in 1972; fractional share sold.
(5) Shares received as stock dividend (3%) in 1973; fractional share sold.
(6) Shares received as 5 for 4 stock split 4/30/73.

Respectfully submitted,
Charles M. Norris, MD, Treasurer

(This report was duly accepted by the Fellows.)

REPORT OF THE ACCOUNTANT

To the members of the American Laryngological Association
Gentlemen:

We have examined the statements of cash receipts and disbursements of *The American Laryngological Association*, including Trust Funds, for the fiscal year ended March 31, 1976. Our examination was made in accordance with generally accepted auditing standards, and accordingly included such tests of the accounting records and such other auditing procedures as we considered necessary in the circumstance.

Cash receipts and disbursements were verified as recorded to date, and all securities were examined or accounted for as of this date.

In our opinion, the accompanying statements of cash receipts and disbursements present fairly the financial position of The American Laryngological Association and its Trust Funds at March 31, 1976, on a cash basis, and the results of its operations for the year then ended, in conformity with generally accepted accounting principles applied on a basis consistent with that of the preceding year.

Respectfully submitted,

Graham, Crossan, Horrocks & Company
Certified Public Accountants

April 8, 1976

(This report was duly accepted by the Fellows.)

REPORT OF THE LIBRARIAN, HISTORIAN AND EDITOR

The Ninety-sixth Annual Meeting of the American Laryngological Association was held at the Hyatt Regency in Atlanta, Georgia on the mornings of April 6 and 7, 1975. Eighty-seven Fellows (77 Active, 3 Honorary, 6 Emeritus and 1 Corresponding) along with 275 guests were officially registered. After the remarks of President Joseph H. Ogura and the address of the Guest of Honor, Francis E. LeJeune, 15 scientific papers were presented. The highlight of the meeting this year was the first Daniel C. Baker, Jr. Memorial Lecture given most eloquently by John J. Conley, entitled "Some Reflections on Our Specialty." Dr. Baker's family was well represented and they were entertained at luncheon by the officers. The papers presented this year were published in the November-December issue of the *Annals of Otology, Rhinology and Otolaryngology.*

Mrs. Edna Pollack of the Martin Johnson Agency was again our reporter and had the completed transcript of the entire two-day procedure in the hands of the Editor on April 23, 16 days after adjournment. Discussions were sent out for correction on the following day, and for the most part promptly returned. Twelve manuscripts were in the hands of the Editor of the *Annals* by the close of the meeting, as requested by letters to all of the essayists, and the last of the three delinquent manuscripts was obtained on May 20. Completed copy for the 1975 *Transactions* was mailed to the *Annals* office in St. Louis on June 2 and galley proof returned on August 22. This year we were able to establish a record of some sort by having the 160 copies in the mail on October 24. In keeping with the rotation policy of the *Annals,* our *Transactions* were published first and our papers last.

Ninety-two copies were mailed to the Active members, ten to the Honorary and seven to the families of the deceased whose obituaries appeared this year. There were 48 standing orders from libraries, booksellers and Emeritus members, two single orders, and one volume sent as usual to the Library of Congress. Since then eight more orders have been filled. Purchase price to libraries and booksellers, by vote of Council, remained at $15.00 and the three Emeritus members who have placed standing orders are charged $6.00.

Following instruction by the Council last year we did not publish the lists of deceased members and previous officers, thereby saving 15 pages. Because of the greater number of papers and discussions however, we ran 187 pages as against 195 in 1974 (the year of the 10-year Index). The net reduction, therefore, was only eight pages but we did save money, as this year's cost was only $4260.72 as against $4906.13 last year. So far we have collected $807 for the sale of 1975 *Transactions*. Two hundred copies were again ordered, as in the past two years, and this number has proved adequate.

As Historian I have the sad duty to report three deaths since our 1975 Annual Meeting:

Samuel Salinger (Emeritus) August 11, 1975. Fellow since 1938.

Justo M. Alonso (Honorary) October 22, 1974. Fellow since 1946.

W. Likely Simpson (Emeritus) March 1976. Fellow since 1939.

Respectfully submitted,

Charles F. Ferguson, MD

Librarian, Historian and Editor

(This report was duly accepted by the Fellows.)

REPORT OF THE AMERICAN BOARD OF OTOLARYNGOLOGY

Three hundred and seventy-seven candidates took the examination and 282 candidates successfully passed the November 1975 certifying examination. Ninety-five candidates failed, for a failure rate of 25.2%. Of the 377 candidates who took the examination 101 were foreign medical school graduates. Forty-five of the 282 candidates who were successfully certified were foreign graduates.

Some revisions have been made in the new booklet of information. For example: State licensure is now a prerequisite for eligibility for applying for certifying examination. Code board eligibility status has been changed to one three-year period only. A candidate who does not pass an examination may reapply any number of times. This does convey eligibility to sit for that particular examination, but does not reinstate board eligibility after the one three-year period.

Upon request from the Program Director, the American Board of Otolaryngology can furnish information as to the "pass-fail" rate of your particular training program. One can write to the American Board of Otolaryngology for this information.

The revised essentials have been accepted by the American Board of Otolaryngology, the AMA, the American College of Surgeons, and the Liaison Committee for Graduate Medical Education and will be published in the next Directory of Approved Residencies, which is the Green Book.

The American Board of Otolaryngology has been vitally interested in recertification, but at the present time, the American Board favors voluntary recertification. It does not recommend any firm target date, nor does it recommend any particular format for this evaluation process. Input regarding this matter will be appreciated by the Board.

Respectfully submitted,

Frank D. Lathrop, MD

Representative to the American Board

(This report was duly accepted by the Fellows.)

REPORT OF THE ALA REPRESENTATIVE TO THE AMERICAN COUNCIL OF OTOLARYNGOLOGY

The American Council of Otolaryngology is now in its eighth year and, as a relatively young organization, it is doing a singularly effective job representing otolaryngologists in a complex of the socioeconomic and political aspects of the practice of the specialty.

In 1976 the ACO, in collaboration with HEW, completed a four-year Manpower Study of the specialty. The results of this Manpower Study have been submitted to the Government Printing Office and will be available for general distribution in the Spring and Summer of 1976. This is the first detailed study of the specialty ever undertaken.

The ACO has been engaged during the past year in discussion at the National level concerning Hearing Aid Delivery Systems in the United States. This places the ACO in the middle of conflicting interests of audiologists, hearing aid dealers, consumer groups, the hearing aid industry and otolaryngologists. A definite position is still to be developed for the specialty in regard to Hearing Aid Delivery Systems. To accomplish this a Committee, headed by Dr. Lindsay Pratt, is now working on developing information upon which such a position can be established. This is important for representatives of the specialty appearing before Government committees and agencies.

An increasing number of issues of national importance involve the ACO in the socioeconomic aspects of otolaryngological practice. Because of this trend, the ACO is reviewing its present status as an educational and scientific organization. As demands increase for the ACO to actively represent the specialty before regulatory and legislative branches, it begins to appear that the original concept of the educational and scientific nature of its activities is changing and it may be more desirable to accept the status of a professional society representing the interests of its members to the general public. This would provide for freedom of activities that are now constrained by its present designation.

Respectfully submitted,

John F. Daly, MD

Secretary

(This report was duly accepted by the Fellows.)

REPORT OF THE AMERICAN COLLEGE OF SURGEONS, BOARD OF GOVERNORS

The Annual meeting of the Board of Governors of the College took place in San Francisco on October 12 and 15, 1975 at the Hilton Hotel.

The meeting was convened by David Sebaston, Chairman of the Board of Governors, who introduced Charles W. McLaughlin Jr., President of the College. Special reports followed from the officers, but the bulk of the morning meeting was the discussion of the limitation of the Board of Governors. A Committee proposal had been made limiting the size of the Board of Governors markedly, cutting speciality Governors to 50, as well as the general Governors. The reason for limitation was that an increasing number of Governors each year would allow no decent deliberations and in fact would make it difficult to control an adequate meeting. After much deliberation and voting it was finally concluded to continue the numbers and terms of the Board of Governors as they are at present. A new society applying for a Governor should have at least 200 member doctors, half of which are members of the American College. Granting a Governorship is by no means pro forma, as it must be then discussed by the Executive Committee of the Board of Governors, who will make a recommendation. It should be noted that at no point in this discussion was there any question of removing governorships from those organizations, such as our own, which have less than 200 active members. The entire thrust of the discussion was toward the future and new Governors.

The afternoon session was filled by a most interesting panel on Professional Liability. This included Dexter Ball, Chairman of the Governors Committee on Professional Liability; Dr. Hanlon, Director of the College; Paul Gebhard, Esq., College legal counsel; Lester Rawls, Insurance Commissioner of the state of Oregon; William V. Nick, JD, MD, College consultant; and last, Jeffrey O'Connell, Professor of Law, University of Illinois. This last speaker made the most profound impression discussing "no fault" as applied to medical liability. He expressed having a sensation of *deja vu* regarding professional liability. He states the same actions occurred at the turn of the century with Workmen's Compensation and are presently occurring with auto insurance. He feels sure the near term solution will be a "no fault" solution, perhaps varying from state to state. A very lively question and answer period followed the speakers with most interest in the remarks of Mr. Rawls and Mr. O'Connell. Some discussion was also made as to why the American College of Surgeons liability fund never "got off the ground." All Fellows who contributed $1000 had their money returned in full.

The adjourned meeting of the Board of Governors was held October 15th with little activity other than nomination of officers and speeches by the retiring Governors.

The Advisory Council for Otorhinolaryngology met October 14, 1975, again chaired by Dr. John T. Dickinson. Dr. Loring Pratt discussed the Regents meeting, and on-going difficulties with surgery by non-MDs, such as oral surgeons. The program for the 1976 Clinical Congress was discussed and the panel moderators approved.

The increasing attendance at this meeting by Otolaryngologists was noted, as well as the increasing membership in the College. At least two more Otolaryngology organizations have applied for Governorships for later action. Again, any suggestions to our Regent, Dr. Pratt, or any of the Governors or the Advisory Council would be welcomed.

Respectfully submitted,
William M. Trible, MD, F.A.C.S.
Governor A.C.S.

(This report was duly accepted by the Fellows.)

REPORT OF THE NOMINATING COMMITTEE

The Nominating Committee met yesterday and has made its recommendations. It presents the following slate for members of the Council for the year 1976-1977:

Charles M. Norris, MD
Emanuel M. Skolnik, MD
John T. Dickinson, MD
John F. Daly, MD
Harold G. Tabb, MD
Charles F. Ferguson, MD
Frank D. Lathrop, MD
G. Slaughter Fitz-Hugh, MD
Joseph H. Ogura, MD
Stanton A. Friedberg, MD

Respectfully submitted,
John E. Bordley, MD, Chairman

(This report was duly accepted by the Fellows.)

After the Scientific Session, the Executive Session was reconvened by President Friedberg. The Council was elected as presented on the above slate. After a brief organizational meeting the following officers for 1976-77 were announced:

President: Charles M. Norris, MD

First Vice-President: Emanuel M. Skolnik, MD

Second Vice-President: John T. Dickinson, MD

Secretary: John F. Daly, MD

Treasurer: Harold G. Tabb, MD

Historian, Librarian and Editor: Charles F. Ferguson, MD

First Councilor: Frank D. Lathrop, MD

Second Councilor: G. Slaughter Fitz-Hugh, MD

Third Councilor: Joseph H. Ogura, MD

Fourth Councilor: Stanton A. Friedberg, MD

Following election of the new officers, President Norris presented the pin to retiring President Friedberg who thanked the Association and all who had helped make the year and the program of the Annual Meeting successful. President Norris expressed his thanks for his election and his hopes for a good year.

REPORT OF THE CENTENNIAL COMMITTEE

ALDEN MILLER, MD: I am very pleased with our plans so far. Without a doubt we are going to have a *souvenir,* and I think a suitable one. It looks like we are going to have a very fascinating *exhibit* of old instruments.

The big problem, of course, is the writing of the *history,* and there we need and want your help – I have prepared a format of what the history would do and I will quickly show three slides to see if any of you want to volunteer.

(Slide) Here, very quickly, is the format as to the *span of years* that we are going to try to cover.

(Slide) Next, we are going to try to do it on a *geographical basis* and here we listed the geographic areas for you. I would tell you that we have set up an editorial board which very much fits this. The boss for the Northeast will be John Daly. He is hoping, and we are, that he will get some help from Charles Norris and Charles Ferguson.

For the *Middle Atlantic* states "Put" Putney, and we hope he will get some help from Dr. Trible, Dr. Bordley and Dr. Fitz-Hugh for the Washington, D.C. area, Maryland and Virginia.

For the *South,* Dr. Clerf is already off to a real good start and he will get a lot of help from Francis LeJeune.

Stan Friedberg has said he will do the *Midwest* and I will try and cover what is left of the United States that's good! (*West*)

(Slide) Here are the things we want. Just quickly take a look at those and let me tell you that I have prepared some forms that have these three slides listed on them. If you feel that you have anything in those *five categories* that would help us, please get one of these forms from me and volunteer.

The meeting will be held in New York, and you will now hear from John Lewis as to the local plans.

JOHN LEWIS, MD: I just want to tell you the local arrangements committee is off and running. The members of the local committee are Drs. Cracovaner, Miller, Daly, Goldman, Som, John Conley and myself as Chairman, and we have already had our first meeting.

We are planning to have headquarters for the meeting at the Waldorf-Astoria. There will be a package for everyone.

We hope to have a *cocktail reception* at the United Nations or the Metropolitan Opera. There will also be the Centennial banquet at the Waldorf-Astoria. It should be very, very interesting and worthwhile.

ACTION ON RECERTIFICATION IN OTOLARYNGOLOGY

SECRETARY DALY: The Council approved the following resolution for its submission to the membership for approval or disapproval:

1. That the ALA supports in principle the process of recertification.

2. That the American Board of Otolaryngology is the proper organization to recertify in Otolaryngology.

3. That certification should be on a voluntary basis.

4. That the process of certification is separate and distinct from licensure.

5. That the target date of 1980 seems reasonable.

Mr. President, those were the five elements in the resolution that the Council approved for submission to the membership.

PRESIDENT FRIEDBERG: I call for a motion whether or not to accept the Council's recommendation.

DR. LATHROP: So moved.

DR. BLAIR FEARON: Second.

It is moved and seconded that the Council's recommendation on recertification insofar as this organization is concerned be accepted by the membership. The motion is passed. This, then, will be forwarded to the Secretary of the American Board.

Memorials

JUSTO M. ALONSO, MD

JUSTO M. ALONSO, MD

1886 - 1974

Justo M. Alonso, MD, of Montevideo, Uruguay, who was considered to be the leader of the South American specialists in the fight against cancer of the larynx and whose brilliant practice lasted for over half a century, passed way on October 22, 1974, at the age of 88.

Two years after graduating from Montevideo University, and already associate professor of clinical ORL, Dr. Alonso travelled to Europe for further study in Basel, Switzerland, and in Vienna, Austria. In 1927, he became head of the ORL Department at Montevideo University, a position he held until his retirement in 1951 at the age of 65. Dr. Alonso continued to teach, practice and even to operate until he was 85, after which he dedicated himself entirely to preparation of the third edition of his *Treatise on Otorhinolaryngology.*

Early in his career Dr. Alonso worked principally on ear surgery, but became more and more interested in the problems of laryngeal cancer, the field to which he ultimately dedicated his greatest efforts. In 1944, with experience in 800 cases of cancer of the larynx, he presented a memorable paper at the Second South American Congress of ORL in which he outlined his bases for surgical treatment: to try to save the lives of patients and to preserve totally or partially, whenever possible, the fundamental functions of the larynx. His extensive contribution to the progress of surgery of cancer of the larynx was analyzed on the occasion of the Centennial Conference on Laryngeal Cancer held in Toronto in 1975.

From the time the Latin American Committee for the Study of Laryngeal Cancer was created, Dr. Alonso was chosen to preside over it. With incomparable persistency he worked to expand the Committee's activities throughout Latin America. Later he succeeded in organizing the International Committee, of which he was also the president until his death. In Montevideo he founded a model center for aid to the laryngectomee, and when called to fill an important political position in his country, this great humanitarian continued to help those with laryngeal problems by working to have a bill passed, which became the Alonso Law, benefiting them. He was the founder and President of the Uruguayan ORL Society; corresponding member of the Medical Academy of Paris; honorary member of the American Academy of Ophthalmology and Otolaryngology and the American Laryngological Association; honorary member of the American College of Surgeons; and honorary member of various other Latin American and European societies of otorhinolaryngology.

Dr. Alonso actively participated in nearly all of the international, Latin American and Panamerican ORL conferences and gave many postgraduate courses in his own country and in Argentina, Brazil, Chile, Colombia, Spain, and Venezuela. In 1957 he was awarded the Eliseo V. Segura prize granted by the Latin American Confederation of ORL Societies.

His disciples recognized that the success of his leadership was based on his enormous experience and on his goodness, humility and concern, so that his pupils never felt humiliated by their ignorance. His humility showed itself in all of his knowledge, never complaining when others presented his ideas as their own contributions.

In Uruguay, Brazil and many other countries Dr. Alonso maintained a wide circle of acquaintances by whom he was profoundly respected and esteemed.

P. de M. B.

SAMUEL SALINGER, MD

1885 - 1975

Samuel Salinger was born in Cleveland, Ohio on January 3, 1885 and died on August 11, 1975 at the age of ninety.

His father, Dr. Simon Salinger, also lived into his nineties. He had been both a Rabbi and an esteemed family physician, stimulating his eldest son to become a physician and subsequently a specialist in a day when training opportunities were rare.

The young Salinger lived in many parts of the country, moving with his father and family from one pulpit to another until the father settled in Chicago for medical practice. He graduated from the Male High School of Louisville, Kentucky at the turn of the century. Included in his graduating class of twelve young men were people who would become famous as physicians, lawyers and a Supreme Court justice. He attended college in Louisville – graduating from the Hospital College of Medicine of the University of Louisville in 1905, receiving his M.D. degree from the College of Medicine and Surgery of the University of Chicago in 1906. After a brief internship, he entered the private practice of medicine.

The next period of his education took place in Vienna, Austria where, in 1913, he enrolled at the University of Vienna to be trained in Otolaryngology at the old Allgemeine Krankenhaus where he was exposed to some of the great teachers of the world. He frequently told stories of his pleasant relationship with such men as Alexander, Neumann, Rutin and Jaques Joseph. The latter had a profound effect upon him since he was the father of nasal plastic surgery.

World War I interrupted Dr. Salinger's training. He returned to Chicago where be became an assistant to Dr. Otto Freer. He then furthered his career in E.N.T. and plastic surgery of the head and neck as an attending physician at Cook County Hospital from 1920 to 1932 and at the Illinois Charitable Eye and Ear Infirmary from 1933 to 1946. His next appointment carried him to Loyola University Medical School where he became Professor and Chairman of the Ear, Nose and Throat Department. His Michael Reese Hospital service began in 1926 where he served as Chairman of the Division of Otolaryngology from 1951 through 1954.

Dr. Salinger retired from Chicago and moved to Palm Springs, California in July 1955. He "moved" to practice his specialty in Palm Springs continuously until 1970. He trained young surgeons in bronchoscopy and nasal emergencies so that this resort town could have proper coverage when he was not available. He left active practice in 1970 at the age of 85 as one of the early victims of the inpact of the problem of Malpractice Insurance coverage. He then occupied his time professionally writing an annual review of the world's sinus literature, a document that was published in several of the specialty journals and treasured by all of his colleagues. He also organized and directed the medical library at the Palm Springs Desert Hospital on whose staff he served from 1955 until his death.

Dr. Salinger lived in an interesting time in medicine, one that saw the change to the scientific antibiotic era. Among his noted contemporaries and personal friends in Chicago were Otto Freer, Norval Pierce, Joseph Beck, Robert Sonnenschein, and Alfred Lewy.

His legacy exists in his many articles (over 100 published); numerous professional societies, many of which elected him as president; documented surgical innovations and new instruments bearing his name; the departments he chaired; the many students he trained; and the honors he received in his lifetime. Of the latter, he was the designated honoree of the year, receiving the Stritch Medal of Honor at the Loyola University in 1967, and the honoree of the year at the Western Section of the American Laryngological, Rhinological and Otological Society in 1971. He also served as a Regent of the American College of Surgeons for a great many years. His writings extended into the nonmedical area, exhibiting a family talent shared with his nephew, the noted author, J. D. Salinger.

A visit to his office attested to his numerous close friends in the literary and theatrical world. His walls were covered with autographed photographs of the world's most noted writers and actors — Groucho Marx was a boyhood friend, and they continued an intimate relationship up to the doctor's death.

Dr. Salinger is survived by his wife Dorothy (néé Holtz), his two sisters and numerous nieces and nephews.

R. B. L.



W. LIKELY SIMPSON, MD

W. LIKELY SIMPSON, MD

1878 - 1976

Except for a few nonincapacitating infirmities of old age, Dr. W. Likely Simpson was alert and well until six weeks prior to his death, when he developed chronic myocardial failure. He died in Diagonal, Iowa a few months prior to his 98th birthday, of acute myocardial infarction.

Dr. Simpson developed a memorable reputation as a churchman, physician, author, student, teacher and golfer. He was praised by his students and residents as a dedicated otolaryngologist of unequaled talents, especially in the field of paranasal sinus and temporal bone surgery. No doubt his motivation was influenced by his close association with outstanding teachers in this country and abroad.

As a student, he visited Vienna, Austria and England on four occasions from 1908 to 1912. He studied under the masters of the art — Drs. Hajek, Politzer, Fuchs, Barany, Hasslinger and Killian. He received a degree from the University of Vienna in Ophthalmology and Otolaryngology, and a degree in Ophthalmology from Oxford University in England.

Dr. Simpson was born in Goshen (now Diagonal), Iowa on July 15, 1878. His father was Eleazor Lloyd Simpson and his mother Agnes Jane Likely Simpson. He married Miss Lenora Balderston of Mt. Ayr, Iowa, on October 29, 1909. Although he had no children, he was a very devoted and attentive husband. His wife preceded him in death. His nephew, Lyle L. Simpson of 218 Sixth Avenue, Des Moines, Iowa, survives him.

His church and his faith in God were of primary interest and importance to him. This was emphasized during his life by his election in 1916 as an elder in the Second Presbyterian Church of Memphis. He became a charter member of the Independent Presbyterian Church of Memphis in 1965. He encouraged and supported its growth with his very generous gifts.

Dr. Simpson attended the Lincoln Township School in Ringgold County, Iowa and Knowlton Iowa High School from 1895 to 1896. He received a BD degree from Highland Park College in Des Moines, Iowa in 1899. In 1904, he graduated from the University of Illinois College of Medicine, and he completed a residency in ophthalmology and otolaryngology at the Illinois Eye and Ear Infirmary in 1905. From 1905 to 1911 he was associated with Dr. E. C. Ellett of Memphis, Tennessee. His private practice of otolaryngology was interrupted by his studies abroad and in 1918 by a tour of duty as Captain in the Army Medical Corps in World War I. He retired from private practice in 1964.

He was an enthusiastic Chairman and Head of the Department of Otolaryngology at the University of Tennessee College of Medicine from 1938 to 1948, although he had served on the teaching staff since 1910. His students and residents recognized him as a dedicated teacher, student and author. More than one private patient was asked to rearrange an appointment so that he might assist an anxious resident in the operating room. He wrote with authority on many subjects and imparted his knowledge to scores of his colleagues as a speaker at numerous national, state, and local medical meetings. He stimulated those around him to emulate his admirable qualities.

He was a member and held many official titles in numerous medical societies. These included the Memphis and Shelby County Medical Society; the Memphis and Shelby County Otolaryngology Society; the Memphis Academy of Otolaryngology; the Tennessee Medical Association; the Tennessee Society of Otolaryngology; the American Medical Association and its Otolaryngology Section; the Southern Medical Association and its section of Otolaryngology; the American Laryngological, Rhinological and Otological Society, the American Academy of Ophthalmology and Otolaryngology; the American Broncho-Esophagological Association and the American Laryngological Association.

Dr. Simpson's recognition as an authority in the field of otolaryngology and his participation as an active national figure culminated in his selection as guest of honor of the American Broncho-Esophagological Association at its annual meeting in Lake Placid, New York in 1963. In the same year, he received a Doctor of Humanities degree from Southwestern University in Memphis, Tennessee. He also accepted an invitation to join the Omicron Delta Kappa Fraternity at Southwestern.

Dr. Simpson was guest of honor of the Section of Otolaryngology of the Southern Medical Association at its annual meeting in Washington, D. C. in 1966. His remarks in this, his last presentation as a scientific speaker, typified his dedication and confidence in the specialty of otolaryngology. "When I survey the field of medical science to which most of us devote our lives, I am amazed but not surprised at the competence and dedication of those who employ, as a matter of routine, techniques and instrumentation and scientific procedures involving tremendously complicated devices which were unknown a few years ago. As an 'old timer' who has watched so many of the 'younger men' extend their knowledge in our fields to unprecedented achievements, serving people with ever increasing skill, I salute you all and feel the most complete confidence in your continued high service to mankind."

Dr. Simpson was a man of distinction and dedication. He will be missed, but his contribution and influence in otolaryngology will continue for many years to come.

E. W. C.

THE MEMORIAL FUND
LARYNGOLOGICAL RESEARCH FUND

The Council earnestly requests that Fellows of the Association give consideration to making a special bequest to these important funds, or to become a Benefactor.

MEMORIAL FUND DONORS

Daniel C. Baker, Jr.
John F. Barnhill
August L. Beck
Gordon Berry
William E. Casselberry
Cornelius G. Coakley
Lee Wallace Dean
Arthur W. deRoaldes
Fred W. Dixon
George Fetterolf
Joseph L. Goodale
William E. Grove
Gordon F. Harkness
Frederick T. Hill
George E. Hourn
Samuel Johnston
James E. Newcomb
Henry B. Orton
Lyman G. Richards
Burt R. Shurly
Lester T. Sunderland
H. Marshall Taylor
Walter H. Theobald
Francis L. Weille

BENEFACTORS

Mrs. Sally Sample Aall
Mrs. Daniel C. Baker, Jr.
Dr. Edwin N. Broyles
Dr. Louis H. Clerf
Dr. Seymour R. Cohen
Dr. John J. Conley
Dr. and Mrs. Francis W. Davison
Dr. Robert L. Goodale
Dr. Edley H. Jones
Mr. A. P. Marchessini
Dr. Francis H. McGovern
Dr. Samuel Salinger
Dr. Sam H. Sanders
Dr. Harry P. Schenck
Dr. DeGraaf Woodman

Zelda Radow Weintraub Cancer Fund, Inc.

Obverse of the deRoaldes medal

RECIPIENTS OF THE deROALDES AWARD

1928. Dr. Chevalier Jackson
1931. Dr. D. Bryson Delavan
1934. Dr. Harris P. Mosher
1937. Dr. Lee Wallace Dean
1943. Dr. Ralph A. Fenton
1949. Dr. George M. Coates
1951. Dr. Arthur W. Proetz
1954. Dr. Louis H. Clerf
1959. Dr. Albert C. Furstenberg
1960. Dr. Dean M. Lierle
1961. Dr. Frederick T. Hill
1966. Dr. Paul H. Holinger
1970. Dr. Francis E. LeJeune
1973. Dr. Lawrence R. Boies
1976. Dr. Anderson C. Hilding

RECIPIENTS OF THE CASSELBERRY AWARD

1923. Dr. George Fetterolf and Dr. Herbert Fox
1928. Dr. Ralph A. Fenton and Dr. O. Larsell
1929. Dr. Richard A. Kern and Dr. Harry P. Schenck
1929. Dr. Edward H. Campbell
1931. Dr. Arthur W. Proetz
1934. Dr. Anderson C. Hilding
1936. Dr. Francis E. LeJeune: Dr. Joel J. Pressman
1939. Dr. H. Marshall Taylor: Dr. Brien T. King
1940. Dr. French K. Hansel
1941. Dr. Noah D. Fabricant
1946. Dr. Paul H. Holinger
1949. Dr. Henry B. Orton
1962. Dr. Hans von Leden
1966. Dr. John A. Kirchner and Mr. Barry D. Wyke
1968. Dr. Joseph H. Ogura

RECIPIENTS OF THE NEWCOMB AWARD

1941. Dr. Burt R. Shurly
1942. Dr. Francis R. Packard
1943. Dr. George M. Coates
1944. Dr. Charles J. Imperatori
1947. Dr. Harris P. Mosher
1948. Dr. Gordon Berry
1949. Dr. Gordon B. New
1950. Dr. H. Marshall Taylor
1951. Dr. John D. Kernan
1952. Dr. William J. McNally
1953. Dr. Frederick T. Hill
1954. Dr. Henry B. Orton
1955. Dr. Thomas C. Galloway
1956. Dr. Dean M. Lierle
1957. Dr. Gordon F. Harkness
1958. Dr. Albert C. Furstenberg
1959. Dr. Harry P. Schenck
1960. Dr. Joel J. Pressman
1961. Dr. Chevalier L. Jackson
1962. Dr. Paul H. Holinger
1963. Dr. Francis E. LeJeune
1964. Dr. Fred W. Dixon
1965. Dr. Edwin N. Broyles
1966. Dr. Lyman G. Richards
1967. Dr. Joseph H. Ogura
1968. Dr. Walter P. Work
1969. Dr. John A. Kirchner
1970. Dr. Louis H. Clerf
1971. Dr. Daniel C. Baker, Jr.
1972. Dr. Alden H. Miller
1973. Dr. DeGraaf Woodman
1974. Dr. John J. Conley
1975. Dr. Francis W. Davison
1976. Dr. Joseph L. Goldman

Roster of Fellows

1976

LIST OF FELLOWS

Date Indicates Year Admitted to Active Fellowship

Attendance at meetings is shown by figures following each name.
Asterisk (*) indicates year paper was read.

Active Fellows — 96

1962. ALEXANDER, FRED W., Falls Road, Chagrin Falls, Ohio 44022, 1962, '63*, '64, '66, '68, '69, '70, '71, '72, '75.

1974. ALFORD, BOBBY R., 1200 Moursund Ave., Houston, Texas 77025, 1974.

1969. ANDREWS, ALBERT H. JR., 122 S. Michigan Ave., Chicago, Ill., 60603, 1970, '71, '72, '73, '74*, '75, '76.

1962. ARNOLD, GODFREY E., 2500 N. State St., Jackson, Mississippi 39216, 1962, '63*, '64*, '66, '69, '70, '72, '73, '75.

1969. AUSBAND, JOHN R., P.O. Box 6125, Hilton Head, So. Carolina 29928, 1970, '71, '72, '73, '75.

1975. BAILEY, BYRON J., Dept. Otol., UTMB, Galveston, Texas 77550, 1975, '76*.

1970. BALLENGER, JOHN J., 723 Elm St., Winnetka, Ill. 60093, 1971, '72, '73, '74, '75, '76.

1963. BAXTER, JAMES D., 687 Pine Ave. West, Montreal, 112, Quebec, Canada, 1963, '65*, '66, '67, '68, '69, '70, '71, '72, '73, '74, '76.

1975. BILLER, HUGH F., Mt. Sinai Hosp., 100th St. & Fifth Ave., New York, N. Y., 1975, '76.

1975. BOLES, ROGER, Dept. Otolaryng. Univ. of Cal., San Francisco, Cal., 1975, '76.

1955. BORDLEY, JOHN E., Johns Hopkins Hospital, Baltimore, Maryland 21205, 1955, '56, '57, '59, '60, '62, '63, '64, '65, '66, '67, '69, '70, '71, '72, '73*, '74, '75, '76.

1959. BREWER, DAVID W., 1100 E. Genesee St., Syracuse, N. Y. 13210, 1959, '60*, '61, '62*, '63*, '66, '70, '73, '74*.

1976. BRIANT, THOMAS D. R., 170 St. George Street, Toronto, Ontario, Canada, 1976.

1955. BROWN, LESTER ALEXANDER, 490 Peachtree Street, N.E., Atlanta, Georgia 30308, 1955, '56, '57, '58, '59, '61, '63, '65, '68, '69, '70, '71, '72, '73*, '74, '75, '76.

1963. BRYCE, DOUGLAS P., O.P.D. Toronto General Hospital, Toronto, Ontario, Canada, 1963*, '64, '66*, '67*, '68*, '69, '70, '71, '72, '73, '74, '75, '76*.

1976. CANTRELL, ROBERT W., Naval Regional Medical Center, San Diego, Cal. 92134, 1976.

1968. CHANDLER, J. RYAN, 1700 N.W. 10th Ave., Miami, Fla. 33136, 1968, '69*, '70, '71, '72, '73, '74, '75, '76.

1967. COCKE, EDWIN W., JR., 920 Madison, Memphis, Tenn. 38103, 1967, '68, '69, '70, '72, '74, '75, '76.

1964. CODY, CLAUDE C., III, 1600 Memorial Professional Building, Houston, Texas 77002, 1964, '65, '67, '69, '71, '73, '75.

1971. COHEN, SEYMOUR R., 1300 N. Vermont Ave., Los Angeles, Calif. 90027, 1971, '72*, '73*, '74, '75*, '76*.

1957. CONLEY, JOHN J., 211 Central Park West, New York, N. Y. 10024, 1958*, '60*, '61, '62*, '63*, '64, '65, '70, '72, '74*, '75*, '76.

1959. CRACOVANER, ARTHUR J., 3509-A Bahia Blanca West, Laguna Beach, Cal. 92653, 1959, '60, '61*, '62, '63, '65, '66, '67, '68, '69, '72, '74, '75, '76.

1960. DALY, JOHN F., Faculty Practice Offices, 566 First Ave., New York, N. Y. 10016, 1960, '61*, '62, '63, '64, '65, '66, '67, '68, '69, '70, '71, '72, '73, '74, '75, '76.

1951. DAVISON, FRANCIS W., Geisinger Medical Center, Danville, Pa. 17821, 1951, '52, '53*, '54, '55, '56, '57, '58, '59, '60, '61, '62, '63*, '64, '65, '66, '67*, '68, '69*, '70, '71, '72, '73*, '74, '75.

1973. DEDO, HERBERT H., University of California, S.F. School of Medicine, Rm. 495U, San Francisco, Calif. 94122, 1973*, '74, '75*, '76*.

1966. DEVINE, KENNETH D., Mayo Clinic, Rochester, Minn. 55901, 1966, '67, '68, '72*, '74*, '76*.

1968. DEWEESE, DAVID D., 3181 S.W. Sam Jackson Park Rd., Portland, Ore. 97202, 1968, '69*, '73, '74, '75, '76.

1969. DICKINSON, JOHN T., 1501 Locust St., Pittsburgh, Pa. 15219, 1970, '71, '72, '73, '75, '76.

1976. DOYLE, PATRICK J., 865 W. 10th Ave., Vancouver, British Columbia, Canada, 1976.

1973. DUVALL, ARNDT J., III, University of Minn. Hospital, A-605 Mayo Memorial Bldg., Minneapolis, Minn. 55455, 1973*, '75, '76.

1968. FARRIOR, RICHARD T., 509 Bay St., Tampa, Fla. 33606, 1968, '69, '70*, '72, '74, '76.

1964. FEARON, BLAIR, 308 Medical Arts Building, Toronto 5, Ontario, Canada, 1964, '66, '67, '68, '69, '70, '71*, '72*, '73*, '74*, '75, '76.

1963. FERGUSON, CHARLES F., P. O. Box 313, Osterville, Mass. 02655, 1963, '64*, '66, '67*, '68, '69*, '70, '71, '72, '73, '74*, '75, '76.

1955. FITZ-HUGH, GLASSELL SLAUGHTER, P. O. Box 3698 University Station, Charlottesville, Virginia 22903, 1955, '57, '59, '60, '61, '62*, '64, '65, '66, '67*, '68, '69, '70, '71, '72, '73, '74, '75, '76.

1970. FRAZER, JOHN P., 260 Crittenden Blvd., Rochester, N. Y. 14620, 1971, '72, '73, '74, '75, '76.

1956. FRIEDBERG, STANTON A., 1725 West Harrison St., Chicago, Ill. 60612, 1956, '57*, '58, '59, '60, '61, '62, '63, '64, '65*, '67, '68, '69, '70, '71*, '72, '73, '74, '75, '76*.

1959. GOLDMAN, JOSEPH L., 55 E. 87th St., New York, N. Y. 10028, 1959, '60*, '61, '62, '63, '64, '65, '66, '67, '68, '69, '70, '71, '72*, '73, '74, '75, '76.

1965. HANCKEL, RICHARD W., JR., 80 Barre St., Charleston, S. C. 29401, 1965, '66, '67, '69, '70, '71, '72, '73, '74.

1957. HARRILL, JAMES A., Bowman Gray School of Medicine, Winston-Salem, N. C. 27103, 1957, '58, '59, '61, '62, '63, '64, '66, '67, '68, '69, '71, '73, '75, '76.

1960. HARRIS, HERBERT H., 907 Hermann Professional Building, Houston, Texas 77025, 1960, '61*, '62, '63, '64, '65*, '66, '67, '68, '69, '70, '71, '72, '73, '74, '75.

1959. HENRY, G. ARNOLD, 170 St. George St., Toronto, Canada, 1959, '61, '63, '66, '67, '69, '70, '73.

1955. HILGER, JEROME A., Suite 6A, 393 Dunlap St., St. Paul, Minnesota 55104, 1955, '56*, '57, '58, '59, '60, '62, '63, '64, '65, '66, '68, '69, '70, '71, '75, '76.

1945. HOLINGER, PAUL H., 700 North Michigan Ave., Chicago, Illinois 60611, 1946, '47, '49, '50*, '51*, '52, '53, '54*, '55, '56, '57, '58*, '59, '60, '61*, '62*, '63, '64, '65, '66*, '68, '69*, '72*, '73*, '74, '76*.

1957. HOLMES, EDGAR M., 2000 Washington St., Newton, Mass. 02162, 1957, '59, '61, '63, '68, '70, '71, '72, '74, '75, '76.

1974. HUDSON, WILLIAM R., Duke Univ. Med. Center, E.N.T., P.O.P., 3805, Durham, N. C. 27710, 1974, '75, '76.

1961. JONES, EDLEY H., 1901 Mission 66 Avenue, Vicksburg, Miss. 39180, 1961, '62, '63*, '65, '66, '67, '68, '69, '70, '71, '72, '73, '74, '75, '76.

1965. KING, JAMES T., Suite 206, W. Paces Ferry, Professional Building, 3250 Howell Mill Rd. N. W., Atlanta, Ga. 30327, 1965, '66, '67, '69, '70, '71, '73, '74, '75, '76.

1975. KIRCHNER, FERNANDO R., U. of Kansas Med. Centr., Kansas City, Kansas 66103, 1975*, '76.

1963. KIRCHNER, JOHN A., 333 Cedar St., New Haven, Conn. 06510, 1963, '65*, '67*, '68, '69*, '70, '71*, '72*, '73, '74, '75*.

1963. LATHROP, FRANK D., R.F.D. No. 1, Pittsford, Vt. 05763, 1963, '64*, '67*, '69, '70, '71, '72, '73, '74, '75, '76.

1966. LEWIS, JOHN S., 3 East 71st Street, New York, N. Y. 10021, 1966, '67, '68, '69*, '70, '71, '72, '74, '75, '76*.

1961. LEWY, ROBERT B., 25 East Washington St., Chicago, Ill. 60602, 1961, '62*, '63, '65*, '67, '68, '69, '70, '71, '73, '74, '75, '76*.

1972. LILLIE, JOHN C., Mayo Clinic, Rochester, Minn. 55901, 1972, '75.

1976. LINGEMAN, RALEIGH E., 1100 W. Michigan St., Indianapolis, Ind. 46202, 1976.

1973. LORE, JOHN M., JR., 100 High St., Buffalo, N. Y. 14203, 1974*, '76.

1966. MCCABE, BRIAN F., Dept. of Otolaryngology, University Hospitals, Iowa City, Iowa 52240, 1966, '69, '72*, '73, '75*, '76.

1963. MCGOVERN, FRANCIS H., 139 South Main St., Danville, Virginia 24541, 1963, '64, '66, '68, '71, '72, '74, '75.

1976. MIGLETS, ANDREW, 456 Clinic Drive, Rm. 4118, Columbus, Ohio 43210, 1976.

1952. MILLER, ALDEN H., 1407 N. Vermont Ave., Los Angeles, Calif. 90027, 1952, '53*, '55, '57, '58*, '61, '62, '64, '66, '67*, '68, '69, '70, '71, '72, '73*, '74*, '76.

1965. MILLER, DANIEL, 110 Francis St., Boston, Mass. 02215, 1965, '66, '67, '68, '69*, '70, '71, '72, '73*, '74, '75, '76.

1964. MONTGOMERY, WILLIAM W., 243 Charles St., Boston, Mass. 02114, 1964, '65*, '66*, '68*, '70, '71, '72, '74*, '75, '76*.

1972. MORSE, HARRY R., Tataket Square, Teaticket, Mass. 02536, 1972, '75.

1957. MUNOZ-MACCORMICK, CARLOS EDUARDO, 71 Park Terrace, Santurce, Puerto Rico, 1957, '58, '59, '60, '61, '62, '63, '64, '65, '66, '67, '68, '69, '70, '71, '72, '73, '74, '75, '76.

1975. NAHUM, ALAN M., 225 W. Dickinson, San Diego, Cal., 1975, '76.

1956. NORRIS, CHARLES MORGAN, 3401 North Broad Street, Philadelphia, Pennsylvania 19140, 1956, '57, '58*, '59, '60, '61*, '62, '63, '64, '66, '67, '68*, '69, '70*, '71, '72, '73, '74, '75, '76.

1961. OGURA, JOSEPH H., 517 S. Euclid Ave., St. Louis, Mo. 63110, 1961*, '62*, '63, '64*, '65, '66*, '67, '68*, '69, '70, '71*, '72, '73*, '74*, '75*, '76*.

1958. O'KEEFE, JOHN J., 130 S. Ninth St., Philadelphia, Pa. 19107, 1958, '59*, '60, '62, '64, '67, '71, '73, '74, '75.

1961. PANG, LUP Q., 1374 Nuuanu Ave., Honolulu, Hawaii 96817, 1961, '62*, '64, '66, '67, '70, '71, '72, '73, '75.

1961. PASTORE, PETER N., 5503 Riverside Drive, Richmond, Va. 23225, 1961, '62*, '64, '66, '67, '69, '71, '72, '73, '74, '75, '76.

1972. PENNINGTON, CLAUDE L., JR., 800 First St., Macon, Ga. 31201, 1972, '73, '75, '76*.

1967. PRATT, LORING W., 325-B Kennedy Memorial Drive, Waterville, Maine 04901, 1967, '68, '69, '70, '71, '72, '73, '74, '75, '76.

1951. PUTNEY, F. JOHNSON, 80 Barre St., Charleston, S. C. 29401, 1951, '52, '53*, '54, '55, '56, '58*, '59, '60, '61, '62, '63*, '64*, '65, '66, '67, '68*, '69*, '70*, '71, '72*, '74, '75, '76.

1963. REED, GEORGE F., 750 E. Adams St., Syracuse, N. Y. 13210, 1963, '65*, '66, '68, '69*, '70, '71, '72, '73, '75, '76.

1974. RITTER, FRANK N., 326 N. Ingalls, Ann Arbor, Mich. 48104, 1974, '75.

1959. SANDERS, SAM H., 1286 Peabody Ave., Memphis, Tenn. 38104, 1959, '60, '61, '62, '63, '65, '70, '71, '72, '73, '75.

1964. SAUNDERS, WILLIAM H., Ohio State Univ., Rm. 3110, 456 Clinic Dr., Columbus, Ohio 43210, 1964, '65, '66, '68*, '69, '70*, '71, '72*, '73, '74, 75*, '76.

1959. SILCOX, LOUIS E., 33-34 Lankenau Med. Bldg., Philadelphia, Pa. 19151, 1959, '60, '61, '62, '63, '64, '65, '66, '67, '68, '69, '70, '71, '72, '73, '74, '75.

1958. SIMONTON, KINSEY M., Khalili Hospital, E.N.T. Dept., Shiraz, Iran, 1958, '59*, '62, '64, '66, '67, '69, '72, '74, '75.

1962. Sisson, George A., Northwestern U. Medical School, 303 Chicago Ave., Chicago, Ill. 60611, 1962, '63*, '65, '66, '68, '69, '70, '71, '72, '73, '76.

1964. Skolnik, Emanuel M., Abraham Lincoln School of Medicine, P. O. Box 6998, Chicago, Ill. 60680, 1964*, '65, '66*, '67, '68, '69, '70*, '71, '72, '73, '75*, '76.

1974. Snow, James B., Jr., 3400 Spruce St., Philadelphia, Pa. 19104, 1974, '75*, '76.

1972. Soboroff, Burton J., 307 N. Michigan Ave., Chicago, Ill. 60601, 1972, '73, '74, '75, '76.

1973. Som, Max L., 121 East 60 Street, New York, N. Y. 10022, 1973, '74*, '75*, '76.

1954. Sooy, Francis A., University of California Hospital, 3rd and Parnassus Ave., San Francisco, Calif. 94122, 1954, '56*, '58, '60, '62, '63, '64, '65*, '67, '68*, '71.

1975. Sprinkle, Philip M., W. Va. Univ. Med. Cent., Morgantown, W. Virginia, 1975, '76.

1975. Strong, M. Stuart, 720 Harrison Ave., Boston, Mass. 02118, 1975, '76*.

1961. Suehs, Oliver W., 14 Medical Arts Square, Austin, Texas 78705, 1961, '62*, '63, '64, '66, '68, '69, '70, '71, '72, '74, '75, '76.

1963. Tabb, Harold G., 1430 Tulane Ave., New Orleans, La. 70112, 1963, '65, '66, '67, '69, '71, '72, '74, '75.

1954. Thornell, William C., 2340 Auburn Avenue, Cincinnati, Ohio 45219, 1955*, '57, '59, '60, '63, '68, '70, '72, '74.

1967. Trible, William MacL., 1234 19th St., N.W., Washington, D.C. 20036, 1967, '68, '69*, '70, '71, '72, '73, '74, '75, '76.

1970. Tucker, Gabriel F., Jr., The Children's Memorial Hospital, 2300 Children's Plaza, Chicago, Ill. 60614, 1970*, '71, '72, '73*, '74*, '75*, '76.

1973. Tucker, John A., Hahnemann Hospital, 230 N. Broad St., Philadelphia, Pa. 19102, 1973*, '74*, '75*, '76.

1974. Ward, Paul H., UCLA School of Medicine, Los Angeles, Calif. 90024, 1974*, '75, '76.

1962. Weaver, Delmar F., Med. Profess. Bldg., Culpeper, Va. 22701, 1962, '63, '64*, '65, '67*, '69, '70, '72, '74, '76.

1971. WILLIAMS, RUSSELL I., 1605 East 19th St., Cheyenne, Wyo. 82001, 1971, '72*, '73, '74, '76.

1951. WOODMAN, DEGRAAF, P.O. Box 560, Easton, Md. 21601, 1951, '53, '54, '55*, '56, '58, '59, '60, '61, '62, '63, '64, '65, '66, '67, '68, '69, '70, '71, '72, '73, '74, '75, '76*.

Honorary Fellows — 9

1975. (1940) BROYLES, EDWIN N., 11 E. Chase St., Baltimore, Md. 21202, 1940, '41*, '42, '46, '48*, '49, '50, '51*, '52, '53, '54, '55, '56, '58, '59*, '60, '61*, '63, '64, '65, '67, '71.

1957. (1925) CLERF, LOUIS H., 5575 Eighth Avenue, North, St. Petersburg, Florida 33710, 1957, '58, '59, '60, '61, '63, '64, '65, '66, '68, '69, '70, '71, '72*, '73, '74, '75, '76.

1968. (1936) GALLOWAY, THOMAS C., 1625 Hinman Avenue, Evanston, Ill. 60201, 1969, '71, '75, '76*.

1975. (1943) HILDING, ANDERSON C., St. Luke's Hospital, Duluth, Minn. 55805, 1944*, '46, '47, '48*, '49, '50, '51, '53, '55, '56*, '57, '60, '62*, '63, '64*, '65, '66, '67, '68, '69, '70, '71, '72, '73, '74, '75, '76.

1968. (1957) HUIZINGA, EELCO, Noorderhaven 7, Groningen, The Netherlands, 1957.

1967. (1933) LIERLE, DEAN M., University Hospitals, Iowa City, Iowa 52240, 1967, '68, '71, '74.

1966. (1957) ONO, JO, 6-13, 6-Chome, Roppongi, Minato-Ku, Tokyo, Japan, 1971.

1968. (1937) PORTMANN, PROF. DR. GEORGES, Clinique S, Augustin, 114, Avenue d'Ares, Bordeaux, France, 1947.

1968. (1957) RUEDI, PROF. DR. LUZIUS, Kurhausstrasse 50, Zurich, Switzerland, 1957.

Corresponding Fellows — 15

1972. ARSLAN, PROF. MICHELE, Otorinolaringoiatrica dell' Universita de Padova, 37 Via Altinate, Padova, Italy, 1972.

1959. BARRETTO, PLINIO DE MATTOS, Rua Cons Torres, Homem 371, Sao Paulo, Brazil, 1960, '69, '73.

1959. BATEMAN, SIR GEOFFREY H., Beech Hill, E. Lavington, Petworth, Sussex, England.

1942. BATSON, OSCAR V., 3926 Pine St., Philadelphia, Pennsylvania 19104, 1942*, '54*.

1964. CLEVES, CARLOS, Apto 202, Carrera 14 No. 44-54, Bogota, Colombia, S. A., 1970.

1966. DOHLMAN, GOSTA, Dept. of Otolaryngology, University of Toronto, Toronto, Ontario, Canada, 1966.

1970. HALLIDAY, SIR GEORGE C., 143 Macquarrie St., Sydney, N.S.W. Australia.

1971. HARRISON, D. F. N., 330/332 Gray's Inn Road, London, W.C.1, England, 1971.

1970. HUTCHEON, JACK, Morris Towers, 149 Wickham Terrace, Brisbane, Australia, 1971.

1971. MACBETH, RONALD G., Radcliffe Infirmary, Oxford, England, 1971.

1968. NAKAMURA, FUMIO, Kyoto Prefectural U. Medicine, Kawara-Mach 1, Kamikyo-Ku, Kyoto, Japan.

1964. PEREZ, ALFREDO C., Institito Celis Perez, Avenida Montes Deoca, Valencia, Venezuela, S. A., 1965.

1952. TAPIA-ACUNA, RICARDO, Av. Insurgentes, Sur No. 300, Mexico 7 D.F., 1953, '57, '60*, '67, '73, '75.

1936. VIALLE, JACQUES, 27 Rue de France, Nice (Alpes Maritimes), France.

Emeritus Fellows — 32

1973. (1944) BOIES, LAWRENCE R., Department of Otolaryngology, A-605, Mayo Memorial Bldg., Minneapolis, Minnesota 55455, 1944, '46, '47, '48*, '49, '50*, '51*, '53, '54, '55, '56, '57, '58, '59, '60, '61, '62, '63, '64, '65, '66, '67, '68*, '69, '71.

1966. (1945) CAMPBELL, PAUL A., 700 E. Hildebrand, Apt. 401, San Antonio, Texas 78212.

1965. (1942) CANFIELD, NORTON, P.O. Box 377, Stony Creek, Branford, Conn. 06405.

1969. (1959) CARDWELL, EDGAR P., P.O. Box 581, Shell Island, Wrightsville Beach, N. C. 28480.

1975. (1957) CONVERSE, JOHN MARQUIS, 722 Park Ave., New York, N. Y. 10021, 1960, '62*, '67.

1969. (1947) EAGLE, WATT W., Route 6, P. O. Box 339, New Bern, N. C. 28560.

1972. (1962) ERICH, JOHN B., Mayo Clinic, 102 Second Ave., Rochester, Minn. 55901.

1970. (1940) GOODALE, ROBERT L., 141 Argilla Rd., Ipswich, Mass. 01938, 1971, '74, '75, '76.

1963. (1928) GOODYEAR, HENRY M., 2012 Edgecliff Point, Cincinnati, Ohio 45206.

1960. (1940) HANSEL, FRENCH K., 515 Timberwyck, St. Louis, Missouri 63131, 1962, '65, '73.

1968. (1942) HEATLEY, CLYDE A., 125 Douglas Rd., Rochester, N. Y. 14610, 1942, '46*, '49, '50, '52, '53*, '54, '55, '57, '58, '60, '61, '65.

1961. (1950) KLINE, ORAM R., 896 Lake Ave., Woodbury Heights, N. J. 08097, 1961, '63, '70, '72, '74.

1970. (1936) LEJEUNE, FRANCIS E., Ochsner Clinic Bldg., 1514 Jefferson Highway, New Orleans, La. 70121, 1971, '73, '74, '75*, '76.

1967. (1949) LINDSAY, JOHN R., 950 E. 59th St., Chicago, Ill. 60621, 1967.

1954. (1927) LUKENS, ROBERT M., 141 West Heather Road, Wildwood Crest, N. J. 08260.

1964. (1952) MCCALL, JULIUS W., 22880 Canterbury Lane, Shaker Heights, Ohio 44122, 1964, '66, '68, '69, '70, '71, '72, '73, '75, '76.

1974. (1951) MCHENRY, LAWRENCE C., 1607 Glenbrook Terrace, Oklahoma City, Okla. 73116, 1953*, '62, '63, '64, '65, '66, '68, '71.

1970. (1931) MCNALLY, WILLIAM J., 1509 Sherbrooke St. West, Montreal, Quebec, Canada, 1972, '73, '74, '75.

1971. (1954) MOORE, PAUL M., 22520 Calverton Rd., Cleveland, Ohio 44122, 1954, '55*, '56, '57, '59, '60, '61, '62, '63, '64, '65, '66, '68, '70, '71, '74.

1971. (1953) MURTAGH, JOHN A., 1198 A1A Apt. 240, Hillsboro Beach, Pompano, Fla. 33062, 1953, '54, '55, '56*, '57, '58, '59, '61, '62, '63, '65, '66, '67, '69, '70, '72, '74, '76.

1959. (1927) MYERSON, MERVIN C., The Hyde Park, 25 East 77th St., New York, N. Y. 10021.

1957. (1948) PHELPS, KENNETH A., 1788 Oak Creek Drive, Apt. 402, Palo Alto, Cal. 94304, 1971.

1976. (1951) PRIEST, ROBERT E., 322 Medical Arts Building, Minneapolis, Minn. 55402.

1969. (1951) RAWLINS, AUBREY G., 490 Post St., San Francisco, Calif. 94102, 1971.

1972. (1956) RICHARDSON, JOHN R., P.O. Box 52, Searsport, Maine 04974.

1962. (1932) SCHALL, LEROY A., 121 Winfield Road, Princeton, N. J. 08540, 1964, '66, '68, '69, '72, '73, '74, '75, '76.

1964. (1934) SCHENCK, HARRY P., 1235 Wyngate Rd., Wynnewood, Pa. 19096, 1964, '65*, '66, '68, '69, '70.

1969. (1950) SMITH, AUSTIN T., 382 Lakeside Rd., Box 28, Wynnewood, Pa. 19096, 1970, '71, '72, '73, '74.

1973. (1963) TOLAN, JOHN F., 1118 Ninth Ave., Seattle, Washington 98101, 1963, '64, '65, '66, '67, '69, '71, '73.

1968. (1950) TREMBLE, G. EDWARD, 1374 Sherbrooke St. W., Montreal, Quebec, Canada, 1950, '51, '52, '53, '54, '55*, '56, '57, '58, '60, '61, '62, '63, '65, '66, '67*, '68, '69, '70, '71, '73, '74, '76.

1961. (1941) VIOLE, PIERRE P., 241 South Windsor, Los Angeles, Calif. 90004, 1964.

1975 (1953) WORK, WALTER P., University Hospitals, 1405 E. Ann St., Ann Arbor, Michigan 48104, 1953, '54, '56, '58, '59*, '62, '63*, '65, '67, '68, '69, '72, '73, '75, '76.

OFFICERS 1976-1977

* * * *

PRESIDENT

CHARLES M. NORRIS, MD

FIRST VICE-PRESIDENT

EMANUEL M. SKOLNIK, MD

SECOND VICE-PRESIDENT

JOHN T. DICKINSON, MD

SECRETARY

JOHN F. DALY, MD

TREASURER

HAROLD G. TABB, MD

LIBRARIAN, HISTORIAN AND EDITOR

CHARLES F. FERGUSON, MD

* * * *

COUNCIL

The above ex officio and

FIRST COUNCILOR

FRANK D. LATHROP, MD

SECOND COUNCILOR

G. SLAUGHTER FITZ-HUGH, MD

THIRD COUNCILOR

JOSEPH H. OGURA, MD

FOURTH COUNCILOR

STANTON A. FRIEDBERG, MD

INDEX

to the

TRANSACTIONS

of the

AMERICAN
LARYNGOLOGICAL ASSOCIATION

1976

AUTHORS INDEX

B

Bailey, Byron J., MD 71

Bryce, Douglas P, MD 98

Burns, Hugh P., MB 98

C

Clemente, Manuel A. C. P., MD 116

Coates, Harvey L., MB 110

Cohen, Seymour R., MD 83

Cooperband, Sidney R., MD 116

D

Dedo, Herbert H., MD 47

Devine, Kenneth D., MD 110

E

Everett, Robert L., PhD 71

F

Friedberg, Stanton A., MD 11, 16

G

Gacek, Richard R., MD 59

Galloway, Thomas C., MD 17

Griffiths, Ceri M., MD 71

H

Hadju, Steven I., MD 104

Hardy, James M., MD 131

Healy, Gerald B., MD 116

Holinger, Lauren D., MD 24

Holinger, Paul C., MD 24

Holinger, Paul H., MD 24

I

Isaacs, Hart, Jr., MD 83

L

Lewis, John S., MD 104

Lewy, Robert B., MD 36

Lyon, Michael J., MA 59

M

Maisel, Robert H., MD 125

McDonald, Thomas J., MD 110

Montgomery, William W., MD 90, 131

O

Ogura, Joseph H., MD 21, 125

Olson, Nels R., MD 141

P

Pennington, Claude L., MD 33

S

Smith, Stephen A., MD 90

Spiro, Ronald H., MD 104

Strong, Elliott W., MD 104

Strong, M. Stuart, MD 116

V

van Nostrand, A. W. P., MD 98

Vaughan, Charles W., MD 116

W

Weiland, Louis H., MD 110

Woodman, DeGraaf, MD 33

SUBJECT INDEX

A

Abductor Paralysis, Bilateral: 30 Years Experience with Arytenoidectomy (Woodman and Pennington) 33

Abductor Vocal Cord Paralysis, Bilateral, Etiology of (Holinger LD, Holinger PC, and Holinger PH) 24

Address, Guest of Honor (Galloway) 17

Address, Presidential (Friedberg) 11

Adult, Congenital Laryngeal Defects in the (Montgomery and Smith) 90

Arthrogryposis Multiplex Congenita, Otolaryngological Manifestations of (Cohen and Isaacs) 83

Arytenoidectomy in Bilateral Abductor Paralysis (Woodman and Pennington) 33

B

Baker Memorial Lecture (Ogura) 21

Bilateral Abductor Paralysis (Woodman and Pennington) 33

Bilateral Abductor Vocal Cord Paralysis, Etiology of (Holinger LD, Holinger PC, and Holinger PH) 24

C

Cancer of Head and Neck, Predictors of Survival in (Maisel and Ogura) 125

Carcinoma, Verrucous, of the Larynx (Burns, van Nostrand, and Bryce) 98

Congenital Laryngeal Defects in the Adult (Montgomery and Smith) 90

D

Dinitrochlorobenzene Skin Sensitization in Prediction of Survival in Head and Neck Cancer (Maisel and Ogura) 125

Dysphonia (Spastic), Recurrent Laryngeal Nerve Section for (Dedo) 47

E

Electronic Laryngeal Prosthesis, Implanted (Bailey, Griffiths, and Everett) 71

Epiglottic Flap in Repair of Laryngopharyngeal Trauma (Olson) 141

F

Fiber Components of the Recurrent Laryngeal Nerve in the Cat (Gacek and Lyon) 59

Frontal Sinusotomy, Osteoplastic: An Analysis of 250 Operations (Hardy and Montgomery) 131

G

Granular Cell Tumors of the Larynx (Coates, McDonald, Devine, and Weiland) 110

Guest of Honor Address (Galloway) 17

H

Head and Neck Cancer, Survival in: Predictors (Maisel and Ogura) 125

Head and Neck Surgery, Progress of Otolaryngology in (Ogura) 21

I

Implanted Electronic Laryngeal Prosthesis (Bailey, Griffiths, and Everett) 71

Injection, Experience with Vocal Cord (Lewy) 36

Introduction of Guest of Honor (Friedberg) 16

L

Laryngopharyngeal Trauma, Laryngeal Suspension and Epiglottic Flap in (Olson) 141

Larynx, Congenital Defects in the Adult (Montgomery and Smith) 90

Larynx, Granular Cell Tumors of (Coates, McDonald, Devine, and Weiland) 110

Larynx, Malignant Minor Salivary Gland Tumors of (Spiro, Lewis, Hadju, and Strong EW) 104

Larynx, Nerve Section, Recurrent for Spastic Dyphonia (Dedo) 47

Larynx, Nerve, Recurrent, Fiber Components of, in the Cat (Gacek and Lyon) 59

Larynx, Prosthesis, Implanted (Bailey, Griffiths and Everett) 71

Larynx, Suspension: Epiglottic Flap in Laryngopharyngeal Trauma (Olson) 141
Larynx, Verrucous Carcinoma of (Burns, van Nostrand and Bryce) 98
Laser, CO_2 Management in Recurrent Respiratory Papillomatosis (Strong MS, Vaughan, Cooperband, Healy, and Clemente) 116
Lymphocyte Count (Peripheral): Predictors of Survival in Head and Neck Cancer (Maisel and Ogura) 125

M

Malignant Minor Salivary Gland Tumors of Larynx (Spiro, Lewis, Hadju, and Strong EW) 104
Memorials 162

N

Nerve, Recurrent Laryngeal Paralysis (Holinger LD, Holinger PC, and Holinger PH) 24
Nerve, Section, for Spastic Dysphonia (Dedo) 47
Nerve, Recurrent Laryngeal in Cat, Fiber Components of (Gacek and Lyon) 59

O

Osteoplastic Frontal Sinusotomy (Hardy and Montgomery) 131
Otolaryngological Manifestations of Arthrogryposis Multiplex Congenita (Cohen and Isaacs) 83

P

Papillomatosis, Respiratory, Recurrent, Management with the CO_2 Laser (Strong MS, Vaughan, Cooperband, Healy, and Clemente) 116
Paralysis, Abductor, Bilateral: 30 Years Experience with Arytenoidectomy (Woodman and Pennington) 33
Paralysis, Bilateral, Etiology of Abductor Vocal Cord (Holinger LD, Holinger PC, and Holinger PH) 24
Peripheral Lymphocyte Count as Predictor of Survival in Head and Neck Cancer (Maisel and Ogura) 125
Presidential Address (Friedberg) 11
Progress of Otolaryngology in Head and Neck Surgery (Ogura) 21
Prosthesis, Laryngeal, An Implanted Electronic (Bailey, Griffiths, and Everett) 71

R

Recurrent Laryngeal Nerve in Cat, Fiber Components of (Gacek and Lyon) 59
Recurrent Laryngeal Nerve Section for Spastic Dysphonia (Dedo) 47
Respiratory Papillomatosis, Recurrent: Management with the CO_2 Laser (Strong MS, Vaughan, Cooperband, Healy, and Clemente) 116

S

Salivary Gland (Minor) Tumors of Larynx, Malignant (Spiro, Lewis, Hadju, and Strong EW) 104
Section, Nerve, Recurrent Laryngeal, for Spastic Dysphonia (Dedo) 47
Sinusotomy, Frontal, Osteoplastic (Hardy and Montgomery) 131
Skin Sensitization (Dinitrochlorobenzene) and Peripheral Lymphocyte Count: Predictors of Survival in Head and Neck Cancer (Maisel and Ogura) 125
Spastic Dysphonia, Recurrent Laryngeal Nerve Section for (Dedo) 47
Surgery of Head and Neck, Progress of Otolaryngology in (Ogura) 21
Survival in Head and Neck Cancer, Predictors in (Maisel and Ogura) 125
Suspension, Laryngeal, in Laryngopharyngeal Trauma (Olson) 141

T

Trauma, Laryngopharyngeal; Laryngeal Suspension and Epiglottic Flap in (Olson) 141
Tumors of Larynx, Granular Cell (Coates, McDonald, Devine, and Weiland) 110
Tumors, of Larynx, and Laryngopharynx, Mucus Gland (Spiro, Lewis, Hadju, and Strong EW) 104

V

Verruccus Carcinoma of Larynx: Management by Radiotherapy and Surgery (Burns, van Nostrand, and Bryce) 98
Vocal Cord Injection, Experience with (Lewy) 36
Vocal Cord Paralysis, Etiology of Bilateral Abductor: A Review of 389 Cases (Holinger LD, Holinger PC, and Holinger PH) 24