

TRANSACTIONS

American Laryngological Association

≈

ONE HUNDREDTH VOLUME


1979

PUBLISHED BY THE ASSOCIATION
GABRIEL FREDERICK TUCKER, JR., MD, Editor





"DOCENDO DISCIMUS"




TRANSACTIONS
OF THE
ONE HUNDREDTH ANNUAL MEETING
OF THE
**American
Laryngological Association**
1979

HELD AT
THE CENTURY PLAZA
LOS ANGELES, CALIFORNIA
APRIL 1 AND 2, 1979

≈

PUBLISHED BY THE ASSOCIATION
ST. LOUIS, MISSOURI
GABRIEL FREDERICK TUCKER, JR., MD, Editor

1979



Contents

	PAGE
Officers for 1978-79	7
Annual Photograph	8
Registration of Fellows for Annual Meeting	9
Presidential Address, John F. Daly, MD, Otolaryngology at the Crossroads	11
Introduction of Guest of Honor, F. Johnson Putney, MD, by President John F. Daly, MD ..	14
Address of the Guest of Honor, F. Johnson Putney, MD, Docendo Discimus	15



SCIENTIFIC SESSION

Evaluation of Computerized Tomography, Cinelaryngoscopy, and Laryngography in Determining the Extent of Laryngeal Disease.	
Paul H. Ward, MD, William Hanaffee, MD, Anthony Mancuso, MD, Joel Shallit, MD, George Berci, MD	17
Discussion of Previous Paper	25
Leiomyosarcoma of the Cervical Trachea. Report of a Case with Reconstruction Using a Latissimus Dorsi Island Flap.	
John M. Fredrickson, MD, Anthony Jahn, MD, Douglas P. Bryce, MD	27
Endoscopic Teflon® Keel for Anterior Glottic Web.	
Herbert H. Dedo, MD	31
Discussion of Previous Two Papers	37
Fifth Daniel C. Baker, Jr. Lecture: Resident Education: Past, Present, and To Where.	
Walter P. Work, MD	39
Benign Tumors and Lesions of the Larynx in Children: Surgical Excision by CO ₂ Laser.	
George T. Simpson, MD, Gerald B. Healy, MD, Trevor McGill, MD, M. Stuart Strong, MD	44
Discussion of Previous Paper	50
Clinical Course of Unusual Malignant Sarcomas of Head and Neck.	
Michael Setzen, MD, Steven Sobel, MD, James M. Toomey, MD, DMD	52
Enteral and Parenteral Nutrition in Patients with Head and Neck Cancer.	
Steven Sobel, MD, Michael Conoyer, MD, Donald G. Sessions, MD	61
Discussion of Previous Two Papers	68
Effects of Irradiation on Cervical Lymph Nodes.	
Louis W. Welsh, MD, Frank Campellone, MS	70
Radiation Fibrosis and Necrosis of the Larynx.	
James R. Chandler, MD	77
Bilateral Hypoglossal Nerve Paralysis after Irradiation Therapy.	
William H. Saunders, MD, Sheila Hodgson, MD	83
Discussion of Previous Three Papers	86

CONTENTS

	PAGE
Cholesteatoma of the Frontal and Ethmoid Areas.	
Ruth S. Campanella, MD, David D. Caldarelli, MD, Stanton Friedberg, MD	88
Discussion of Previous Paper	93
The Problem of the Collapsing Upper Lateral Cartilage.	
Brian F. McCabe, MD	95
Discussion of Previous Paper	98
Laryngeal Dysfunction Following Prolonged Intubation.	
Robert E. Whited, MD	99
Discussion of Previous Paper	103
Recurrent Laryngeal Nerve Section for Spasmodic Dysphonia.	
Howard L. Levine, MD, Benjamin G. Wood, MD, Eugene Batza, PhD, Melinda Rusnov, MA, Harvey M. Tucker, MD	104
Laryngeal Nerve Crush for Spastic Dysphonia.	
Hugh F. Biller, MD, Max L. Som, MD, William Lawson, MD	108
Discussion of Previous Two Papers	109
Executive Sessions:	
First Session	112
Second Session	113
Reports of:	
Secretary, William M. Tribble, MD	114
Treasurer: Harold G. Tabb, MD	114
Accountant	120
Librarian, Historian and Editor, Gabriel F. Tucker, Jr., MD	120
Nominating Committee	121
American College of Surgeons, Governors, William M. Tribble, MD, FACS	121
Memorials:	
John T. Dickenson, MD, DSc	124
Robert McDowell Lukens, MD	127
Mervin C. Myerson, MD	131
Harry P. Schenck, MD	128
Memorial Fund: Laryngological Research Fund	132
Recipients of deRoaldes Award	133
Recipients of Casselberry Award	134
Recipients of Newcomb Award	135
Officers 1879-1978	138
Roster of Past Fellows	143
Roster of Fellows	154
Officers 1979-1980	162
Index 1979	
Subjects	164
Authors	166
Index 1975-1979	
Subjects	168
Authors	174

OFFICERS 1978-1979



PRESIDENT

JOHN F. DALY, MD

FIRST VICE-PRESIDENT

JOHN E. BORDLEY, MD

SECOND VICE-PRESIDENT

LESTER A. BROWN, MD

SECRETARY

WILLIAM M. TRIBLE, MD

TREASURER

HAROLD G. TABB, MD

LIBRARIAN, HISTORIAN AND EDITOR

GABRIEL F. TUCKER, JR., MD



COUNCIL

The above ex officio and

FIRST COUNCILOR

JOSEPH H. OGURA, MD

SECOND COUNCILOR

STANTON A. FRIEDBERG, MD

THIRD COUNCILOR

CHARLES M. NORRIS, MD

FOURTH COUNCILOR

CHARLES F. FERGUSON, MD



FELLOWS IN ATTENDANCE AT THE ONE HUNDREDTH ANNUAL MEETING

First Row: Cantrell, Friedberg, Ferguson, G. Tucker, Tabb, Tribble, Putney, Daly, Bordley, Brown, Ogura, Norris, Woodman. *Second Row:* Harris, Sooy, McCabe, Ballenger, Fearon, Sisson, Goldman, Bryce, Skolnik, Davison. *Third Row:* Pastore, Miller, Sessions, DeWeese, Soboroff, Reed, A. Miller, Priest, Cody, Andrews, Morse, Pang, McGovern. *Fourth Row:* Dedo, Kirchner, Cracovaner, Work, Lewy, Som, H. Tucker, Shapiro, Munoz-MacCormick, Chandler, Boles, Farrior, Tardy. *Fifth Row:* Baxter, LeJeune, Hanckel, Blaugrund, Toomey, Hudson, Fredrickson, Lewis, Lingeman, Frazier.

TRANSACTIONS OF THE
ONE HUNDREDTH ANNUAL MEETING
OF THE
American Laryngological Association


HELD AT
THE CENTURY PLAZA
LOS ANGELES, CALIFORNIA
APRIL 1 AND 2, 1979

≈

REGISTRATION OF FELLOWS

ACTIVE

ANDREWS, ALBERT H., JR.	CODY, CLAUDE C.
ARNOLD, GODFREY E.	DALY, JOHN F.
BALLENGER, JOHN J.	DEDO, HERBERT H.
BAXTER, JAMES D.	DEWEESE, DAVID D.
BILLER, HUGH F.	FARRIOR, RICHARD T.
BLAUGRUND, STANLEY M.	FEARON, BLAIR
BOLES, ROGER	FERGUSON, CHARLES F.
BORDLEY, JOHN E.	FRAZER, JOHN P.
BROWN, LESTER A.	FREDRICKSON, JOHN M.
BRYCE, DOUGLAS P.	FRIEDBERG, STANTON
CALCATERRA, THOMAS C.	GACEK, RICHARD R.
CANTRELL, ROBERT W.	GOLDMAN, JOSEPH L.
CHANDLER, J. RYAN	HANCKEL, RICHARD W., JR.
	HARRILL, JAMES A.



KIRCHNER, FERNANDO R.
KRAUSE, CHARLES J.
LEJEUNE, FRANCIS E., JR.
LEWIS, JOHN S.
LEWY, ROBERT B.
LINGEMAN, RALEIGH E.
LYONS, GEORGE D.
McCABE, BRIAN F.
McGOVERN, FRANCIS H.
MILLER, ALDEN H.
MILLER, DANIEL
MORSE, HARRY R.
MYERS, EUGENE M.
NAHUM, ALAN M.
NORRIS, CHARLES M.
OGURA, JOSEPH H.
PANG, LUP Q.
PASTORE, PETER N.
PRATT, LORING W.
PUTNEY, F. JOHNSON
REED, GEORGE E.
RITTER, FRANK N.
SAUNDERS, WILLIAM H.
SESSIONS, DONALD G.
SHAPIRO, MYRON J.
SISSON, GEORGE A.

SKOLNIK, EMANUEL M.
SNOW, JAMES B., JR.
SOBOROFF, BURTON J.
SOM, MAX L.
SOOY, FRANCIS A.
SPECTOR, GERSHON J.
SPRINKLE, PHILIP M.
STRONG, M. STUART
TABB, HAROLD G.
TARDY, M. EUGENE, JR.
TOOMEY, JAMES M.
TRIBLE, WILLIAM M.
TUCKER, GABRIEL F., JR.
TUCKER, HARVEY M.
WARD, PAUL H.
WOODMAN, DeGRAAF

EMERITUS

CRACOVANER, ARTHUR J.
DAVISON, FRANCIS W.
HARRIS, HERBERT
MUNOZ-MACCORMICK, CARLOS
MURTACH, JOHN A.
PRIEST, ROBERT E.
WORK, WALTER P.



PRESIDENTIAL ADDRESS

JOHN F. DALY, MD

OTOLARYNGOLOGY AT THE CROSSROADS

As president it is a great and singular privilege to call into session the Hundredth Annual Scientific Meeting of the American Laryngological Association. Last year we celebrated the 100th Anniversary of the founding of this Association, the first national organization in this country, and indeed in the world, dedicated to the promotion of knowledge of diseases of the upper air passages. With the founding of this Association and the American Otological Society some eleven years before, the young specialty of Otolaryngology had achieved national standing in American Medicine.

The first Annual Meeting of the Association was held in New York City on June 10, 11 and 12, 1879 at Delmonico's. Sixteen members, numerous guests and visitors attended. The program consisted of 13 papers and the long Address by first President, Louis Elsberg, which occupies 48 pages of the first volume of our Transactions. The annual meetings have been held since that time without interruption, even in the years when our country was involved in two World Wars.

I am very grateful for the honor and privilege of serving as President of this now venerable and most prestigious society in our specialty and indeed in American Medicine. I lack the eloquence of my predecessors to express my appreciation adequately. Perhaps no one expressed it more strikingly than President Elsberg. He said, "I would rather hold this office than the Presidency of the American Medical Association. Indeed I would rather be President of the American Laryngological Association than hold the political office which I look upon as a higher position than any monarch or potentate on earth, namely that of the President of the

United States." On first reading this, I thought that Dr. Elsberg had let himself be carried away by the emotion of the moment of his election; but having observed our President Carter during this past year, I too say, I would rather be President of the American Laryngological Association and wonder whether there have been moments when President Jimmy Carter would agree.

It is a hallowed ritual for Presidents of the Association to seek inspiration and guidance in the Addresses of their illustrious predecessors. Wishing to preserve this tradition, I went to The New York Academy of Medicine on a hot July day, and requested the first five volumes of the Association's Transactions. The clerk was quick to see through my plan and determined he would have no part in it and set about discouraging the project. No one is more resourceful in the ways of discouragement than a library clerk on a hot summer's afternoon in a library without air conditioning. This called for a change in strategy; I settled for the 1928 volume of the Transactions—the year of the 50th Anniversary. This was a stroke of luck. For here was D. Bryson Delavan, the only member of the Association ever to hold the Presidency twice, commenting on Presidential Addresses. Obviously delighting in the opportunity of quoting from his first Presidential Address, he told the audience that his remarks were as true as when he first delivered them 35 years before. "Some," he said, "have held the value of a Presidential Address in question." (Parenthetically I might add that this includes anyone who has not given one.) Delavan speaking again, said "I believe that it should be considered in like manner with our Annual Dinner, a very desirable, if not indispensable part of each yearly gathering, affording an opportunity to call attention

to ideas and suggestions of timely interest which could hardly otherwise be presented."

Presidential Addresses he thought should have three elements: something historical, a comment on the present, and a look to the future. Last year we paid respect to the past by the publication of the handsomely bound and illustrated volume *Centennial History*. We are grateful to Alden Miller and his committee for making this possible.

The past is prologue. Our comprehension of the future depends on how well we understand the present. Although our generation is constantly bombarded through the mass media with the complexities of the international scene and their influence on our daily lives, over these we have little influence. At the national level we are experiencing the tightening grip of the government as it seeks to control medicine through its bureaucratic regulations. The danger of increasing federal control was pointed out by Dr. Woodman and Dr. Ferguson in their Presidential Addresses.

Our immediate concerns and responsibility involve our field of Otolaryngology. Our specialty has undergone 30 years of progress and expansion of such a dimension that it really is a new specialty. From the simple specialty involved with the management of life-threatening complications of infections of the ear, nose and throat, it has expanded into the broad fields of head and neck surgery and plastic and reconstructive surgery. There have been amazing advances in functional ear surgery. Allergy and immunology, communication sciences and their application to hearing and speech disorders, and pediatric otolaryngology have further widened the scope of Otolaryngology. As each new area opened, organizations were formed to satisfy the needs for exchange of information. This was a period of exciting progress that attracted young talented men into the field. Otolaryngology has become a multidisciplinary regional specialty committed to provide qualified, competent practitioners to serve as generalists in the head and neck area and further committed to provide competent practitioners in its highly technical subspecialties.

Progress is not without its problems. Increasing concern has been expressed about the identity of the specialty and the difficulties in training in this broadly expanded field. The question is asked, does "Otolaryngology" adequately convey the extent of the field as it is practiced today? Evidently not. Several academic departments have attempted to resolve this problem by adopting such titles as Otolaryngology and Maxillo-Facial Surgery, Otolaryngology and Communication Disorders, Otolaryngology and Head and Neck Surgery. Some have even advocated dropping the term Otolaryngology and substituting the title "Medicine and Surgery of the Head and Neck."

The second problem concerns the resources for training otolaryngologists. This problem takes two forms. First, do the training programs have the resources to provide the background and experience necessary for competence in all phases of this broadened field? Second, is it realistic to attempt to train every resident to be competent in all aspects of Otolaryngology. Dr. Ogura, in his Presidential Address, stated, "The pressing problem of training young men in the broad field of head and neck surgery seems insurmountable. There is just not enough clinical material to equally train every resident." Dr. Schuknecht, in an editorial in the February 1979 issue of the *Archives of Otolaryngology*, expressed concern about "the increasing difficulty of training residents in stapes surgery because of the decline in patients available for surgery."

Furthermore the individual otolaryngologist, no matter how well and broadly trained in his residency, eventually either develops as a generalist in the field or by further training, preference and opportunity, limits himself to a highly technical subspecialty of Otolaryngology. The attempt to train every resident for competency in every phase of Otolaryngology seems unrealistic as well as a waste of effort and resources.

Program directors ask whether our training programs should be restructured or should a laissez-faire attitude prevail and let the specialty evolve, hoping "that we can instill in our trainees a sufficiently keen sense of profes-

sional self-assessment to insure that the welfare of their patients will never be impugned."

Two recent developments seem to indicate the direction in which the training of otolaryngologists is moving:

1. The Residency Review Committee and The American Board of Otolaryngology have recommended an increase in the period of training from four to five years.

2. An increasing number of trainees are seeking additional training in fellowships following their residency in order to develop competency in special areas.

It is quite possible in the near future that hospital-based peer review committees will define and limit the privileges of otolaryngologists based on training and qualifications beyond the general Otolaryngology residency program. The danger here is that the future of the specialty would be determined by groups outside the specialty.

In the First Daniel Baker Lecture, Dr. Conley warned, "There is no overall plan for projecting into the next five years. This exposes Otolaryngology to a potentially diminishing role in this area in the future and even the possibility of being finessed out of important aspects of head and neck surgery by more astute planners." Dr. Schuknecht also warned of the danger of separating otology and head and neck surgery in the training program. Head and neck surgery might then drift off and become a subspecialty of general surgery. The

reality of these dangers is made more convincing when we realize that the council of our American Society for Head and Neck Surgery voted to amalgamate with the American Society of Head and Neck Surgeons, an organization composed mainly of general surgeons and plastic surgeons. If such a move were consummated, Otolaryngology would be deprived of its base in head and neck oncology.

These are major issues that vitally affect the specialty as a whole. They must not be confused with minor concerns about the proliferation of organizations within Otolaryngology. The solutions are not to be found in solving the logistics of arrangements for meetings or in providing administrative services to otological organizations. What is needed urgently is a commission or panel of leaders in Otolaryngology to study these problems in a comprehensive way and recommend a plan for the future of Otolaryngology.

The American Laryngological Association as a senior organization can and should, through its representatives, act in concert with its sister organizations to bring such a commission into being. The time gap between the statement of the issues and the development of programs to deal with them is widening with the passing of each day. It is now four years since Dr. Conley called for the comprehensive and coordinated plan for the next five or ten years for our specialty.

The time for action is now. The American Laryngological Association, as it begins its next hundred years, can and should provide the leadership.

INTRODUCTION OF GUEST OF HONOR,
FLOYD JOHNSON PUTNEY, MD

JOHN F. DALY, MD, PRESIDENT

When we survey the long history of our Association, we are struck by the dedication and quality of its leadership. On the occasion of this 100th Anniversary of the Association, it is altogether fitting that we should recognize and honor a colleague who has served the Association according to this great tradition.

Elected to the Fellowship in 1951, he has been a consistent contributor to its scientific sessions. He served as Editor, Librarian and Historian of the Association from 1964-70. He was a member of the Council for over 10 years. He was elected to the Presidency in 1970. He received the Newcomb Award in recognition of many contributions to laryngology and head and neck surgery and his long services to the Association.

He was born in Easton, Maryland, of a family that had its roots in Virginia. His father was a clergyman and his mother a charming southern lady. He matriculated at Washington and Lee University in Lexington. When his father became a Trustee of Furman University of South Carolina, he transferred to Furman and graduated with a B.S. degree in 1930. Although his father had hopes that his son might follow in his footsteps, he was not displeased when young Putney chose medicine as a career of service to humanity.

His acceptance at Jefferson Medical School brought him to Philadelphia. This was to have a great influence on his medical career. Philadelphia was the world center of laryngology and bronchoesophagology. The clinics of Jackson, Clerf and Tucker attracted students from all over the world. So as a student, and later as an intern and then as a resident in pathology at Jefferson, it was inevitable that he would be drawn to this exciting field of laryngology, and to the Professor of Bronchoesophagology at

Jefferson, Dr. Louis Clerf. The meeting with Dr. Clerf was to be the second great influence in his formative years. He became Dr. Clerf's associate when he finished his residency in pathology. The personalities of these two men had much in common. Both had a refreshing clarity and simplicity of style in their approach to complex medical problems; a quality and style stemming undoubtedly from Dr. Clerf's midwestern and Dr. Putney's southern backgrounds.

In 1939 I first met Dr. Putney as we suffered under that benign tyrant Harris P. Mosher in his course on the ethmoidal labyrinth at the Massachusetts Eye and Ear Infirmary. In 1940 Dr. Putney started his residency in Otolaryngology at the Manhattan Eye, Ear and Throat Hospital and here again our friendship was renewed. He returned to the Jefferson faculty and resumed his association with Dr. Clerf, ascending the ladder of academic promotions to become Associate Clinical Professor at that institution.

In 1967 he was invited to join the Faculty of the Medical University of South Carolina as Professor of Otolaryngology. It was the South calling one of her successful sons to return and he answered the call.

Dr. Putney has contributed generously to the literature on laryngology, head and neck surgery and bronchoscopy. His articles are models of scientific exposition. They have the strength derived from clarity and simplicity—a Hemingway quality.

It is with sincere personal pleasure that I call on Dr. Putney, our Guest of Honor, on this 100th Annual Meeting of our Association: a scholar, a gentleman, a laryngologist of excellence, a loyal friend and a tower of strength in our Association—Dr. Floyd Johnson Putney, to address this 100th Anniversary of our Association.

ADDRESS OF GUEST OF HONOR

DOCENDO DISCIMUS

F. JOHNSON PUTNEY, MD

CHARLESTON, SOUTH CAROLINA

Twenty-eight years ago I received the exciting news of my election to this impressive association, and I can honestly say that the annual meetings have constituted some of the most enjoyable experiences of my life. When Dr. Daly casually asked me at dinner one night to be the guest of honor my first reaction was, could he really mean it, for I had never dreamed of receiving such distinction. The list of my predecessors beginning in 1961 with Dr. Clerf is outstanding and brings an additional awareness of one's own shortcomings. I should like to express my very great appreciation of the honor bestowed upon me.

Founded on the motto, "docendo discimus" (by teaching let us learn), the past accomplishments of this association have made the present possible. Learning must be ceaseless, for one cannot understand even the fundamentals of an important subject without knowing its higher levels, at least not well enough to teach it. Every day mistakes are made by teachers who promote a figment of their imagination, say a half-truth, or pronounce as gospel conjecture once uttered by an authority they admired. Learning refers to growth in self-insight and increased awareness of what has taken place through personal development.

One reward of teaching is happiness, of creating something, molding a mind or stimulating a person. Many of the presentations made before this society have described major advances in medical science and their application to laryngology. These are historic contributions. In our own way we have served as agents for change and created a forum to preserve the standards of quality. This great heritage dedicated to the academic and scientific aspect of laryngology cannot be smug or stifled.

As soon as respect for tradition shrinks to nothing more than dutiful imitation, it becomes a deadening weight. As long as tradition provides a desire for strong, constant and varied creative activity, it is a healthy stimulus and a wise guide. Today with a government grown preoccupied with a maximum return on the health dollar, we must carry tradition with us or something of great importance will have been lost forever.

Our specialty has been judged too limited to function usefully in the health care system of the future. Primary care and family medicine have become rallying cries for this criticism which has assumed the dimension of a national campaign. Currently, we seem to be scurrying to redefine ourselves into respectability.

There are some among us who consider the usefulness of the A.L.A. as a scientific and teaching organization ineffective and would relegate the association simply to that of a social club. While we may regret how slow our group has come to understand the forces of change and how late has been our participation in the process, our association has stoutly resisted change for change's sake and rather prides itself that it usually manages to do so. In the aging process a venerable association such as the A.L.A. becomes slow to accept new truths, and the safeguard against stagnation is to live in company with younger, more receptive and progressive minds. At the two hundredth annual meeting the unquestioned facts we talk about today will be obsolete.

With computerized medicine and the persistent beeper only the beginning, the role of the A.L.A. in the future may well be that of guidance relative to the quality and value of the forthcoming science.

tific and technical changes. Our motto, the combination of teaching/learning, when directed by thinking, remains constant.

The most dangerous foe we have to fight is apathy from whatever cause, not from lack of knowledge but from care-

lessness born of self-satisfaction. This senior society's long established custom of electing the most capable teachers and clinicians in North America has contributed much to the growth of laryngology, and this vital role will continue to provide inspiration, direction and leadership to our specialty.

EVALUATION OF COMPUTERIZED TOMOGRAPHY, CINELARYNGOSCOPY, AND LARYNGOGRAPHY IN DETERMINING THE EXTENT OF LARYNGEAL DISEASE

PAUL H. WARD, MD

WILLIAM HANAFEE, MD

ANTHONY MANCUSO, MD

JOEL SHALLIT, MD

GEORGE BERCI, MD

LOS ANGELES, CALIFORNIA

A prospective study of over 100 cases comparing computerized tomography (CT) and correlating these studies with photographic motion picture studies of the larynx, conventional tomography and contrast laryngography has been performed. The authors give illustrative examples of cases in which the CT scan has been documented as providing equal and oftentimes greater information concerning not only tumors, but also cystic lesions and traumatic lesions. With the newer technology, the reduced radiation (which is less than one half that of conventional tomography), and the decreased expense (now comparable to that of laryngography alone), eliminates the need for conventional laryngography and tomography examinations. The incorporation of motion picture documentation of the lesions allowing future comparative studies between the original lesion and the CT are recommended for a more accurate retrospective classification and assessment of therapeutic results.

Computed tomography (CT) of the extracranial head and neck structures has generated great interest, curiosity, and enthusiasm as a potentially valuable diagnostic tool.¹⁻⁴ Clearly, its value in the diagnosis of intracranial lesions has surpassed all expectations and has been called the most important contribution to medical diagnostic techniques since the discovery of x-ray by Roentgen in 1875. Because of the initial expense of the procedure, many third party medical insurance companies have withheld approval of payment for its use for extracranial head and neck diagnostic evaluation. The limited attention given to the value of CT in the diagnosis of the extent of laryngeal pathology resulted in a prospective study which began in 1975,⁵ now includes over 100 cases, and has led to some conclusive evidence which is presented in this article.

This study has been expanded to include color motion picture photography, conventional tomography, and cine- and conventional laryngography. The laryngeal photography was obtained through the Berci-Ward telescope (Karl

Storz Endoscopy, Los Angeles, CA). The value and importance of permanent still and motion picture photography has long been recognized and has been previously described.⁶⁻⁸ The ultimate position of importance that CT of the larynx should achieve has not been clearly defined in the literature. Clinicians, particularly those concerned with determining the extent of malignant lesions of the larynx so that conservation surgery and reconstruction of the larynx can be performed, have often questioned which tests to order preoperatively; a number of them may be ordered in an effort to glean all possible information as to the extent of the lesion. Of equal importance is the availability of this type of information to the radiotherapist in planning his treatment portals.⁹ It is believed that this study has helped to clarify and answer some of these perplexing problems.

The markedly improved technology in each generation of new CT scanners has removed the majority of features which were previously considered negative. The increase in usage has diminished the unit test cost, improved tech-

From the Departments of Surgery/Head and Neck Surgery (Otolaryngology), and Radiology, UCLA School of Medicine, Los Angeles, California.

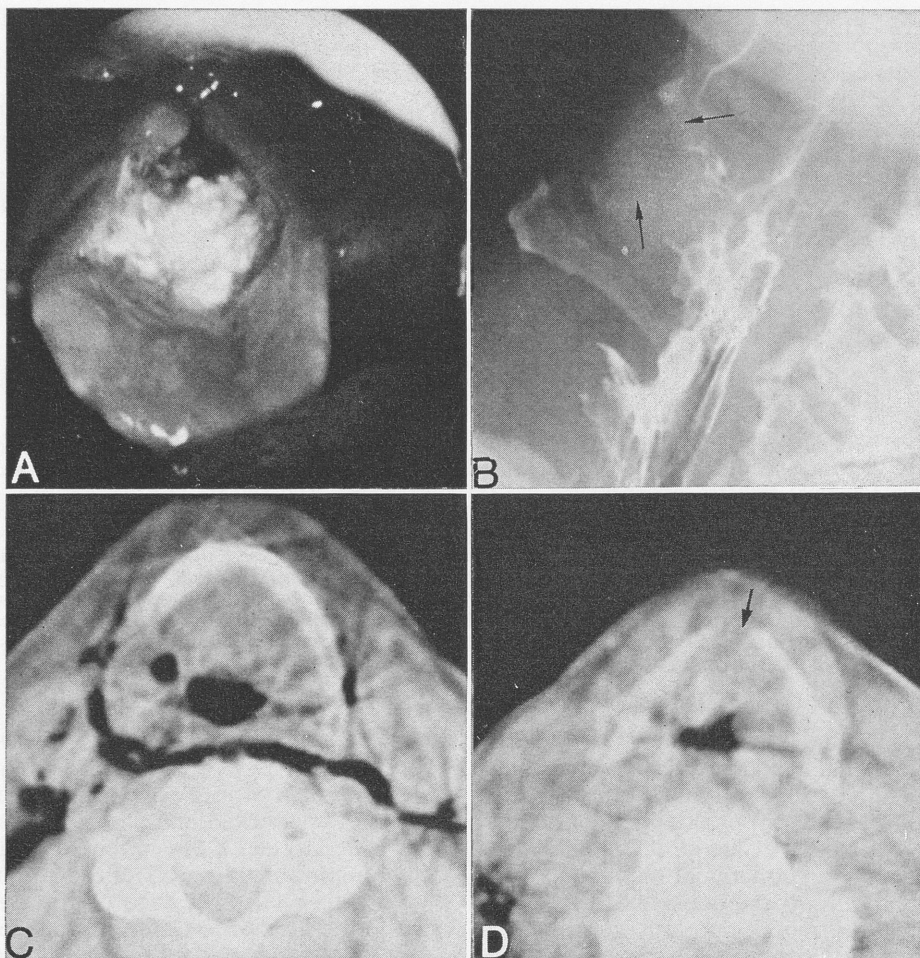


Fig. 1. (Case 1) A) Indirect telescopic photograph taken from a 16 mm movie film of the larynx showing the large epiglottic carcinoma almost occluding the larynx and extending onto the aryepiglottic folds. B) Conventional contrast laryngogram shows the massive transglottic nature of the tumor with infiltration below the level of the cords into the preepiglottic space and into the cartilage (arrows) with posterior displacement of the valleculae. C) CT scan at the level of the hyoid bone shows the infiltration into the preepiglottic space. D) At the level of the false cords, the involvement of both sides and invasion of the thyroid cartilage on the right (arrow) is clearly delineated.

nology has decreased the exposure to radioactivity, and the lamination can now be conducted so that even small lesions can be clearly defined. The single most important feature of CT over all other radiographic techniques is the imagery of soft tissue. This quality helps define tumor margins and offers promise in providing new information about cystic, traumatic, and other laryngeal lesions.

METHODS AND MATERIALS

High-quality scans are obtained with relative facility and comfort to the patient. The patient is placed in the supine position with

the head hyperextended, mouth opened, and tongue slightly protruded. Because of the increased rapidity of acquiring each section, respiration is suspended for several seconds. Even quiet respiration does not significantly degrade the image. Scans are made at 0.5 cm intervals beginning 1 cm below the cricoid cartilage and proceeding cephalad to 1 cm or more above the thyroid notch. The computed images are taped and can be recalled upon the image console where hard copies are obtained as desired. The early CT models required 20 seconds to obtain each section; this has been reduced to two seconds per section and the new General Electric scanner permits six section scans per second. The techniques of conventional tomography and contrast laryngography were utilized for comparison.

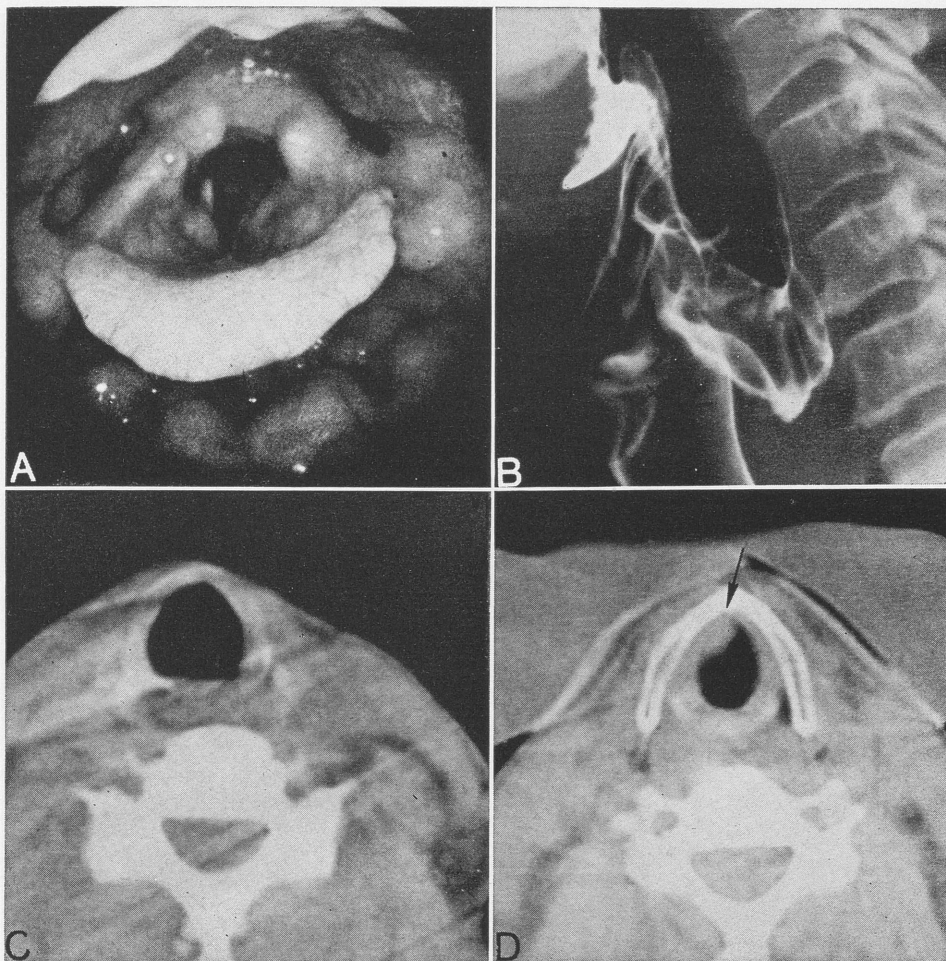


Fig. 2. (Case 2) A) Photograph of larynx showing lesion of the left vocal cord extending from the anterior commissure to the arytenoid. B) Lateral laryngogram shows involvement of the undersurface of the vocal fold (arrow) with the bulk of the left tumor mass abutting against and distorting the normal right cord. The normal sacculus of the laryngeal ventricle is demonstrated (crossed arrow). C) CT scan at the level of the cricoid cartilage shows the normal structures well preserved without evidence of tumor. D) At a higher level just beneath the vocal folds, the CT shows the tumor extending subglottically (arrow) from the left cord.

The following brief case reports exemplify the merits and superiority of CT for the evaluation of laryngeal pathology.

CASE REPORTS

CASE 1

The patient was a healthy 69-year-old complaining only of increasing hoarseness and progressive shortness of breath of three months' duration. Examination of the head and neck area was normal except for the larynx which demonstrated a large epiglottic mass, almost occluding the larynx and extending onto the aryepiglottic folds (Fig. 1A). Laryn-

gograms are usually not performed in this type of case for fear of inducing respiratory obstruction. Because of the patient's good general condition, a laryngogram was performed and showed the large transglottic nature of the lesion with tumor destroying the thyroid cartilage anteriorly and extending below the level of the true vocal cord (Fig. 1B). The CT scan at the level of the hyoid bone clearly demonstrated the infiltration of the preepiglottic space by the tumor (Fig. 1C). Slightly higher, at the level of the false cords, the tumor mass involved the false cords, crossed the mid-

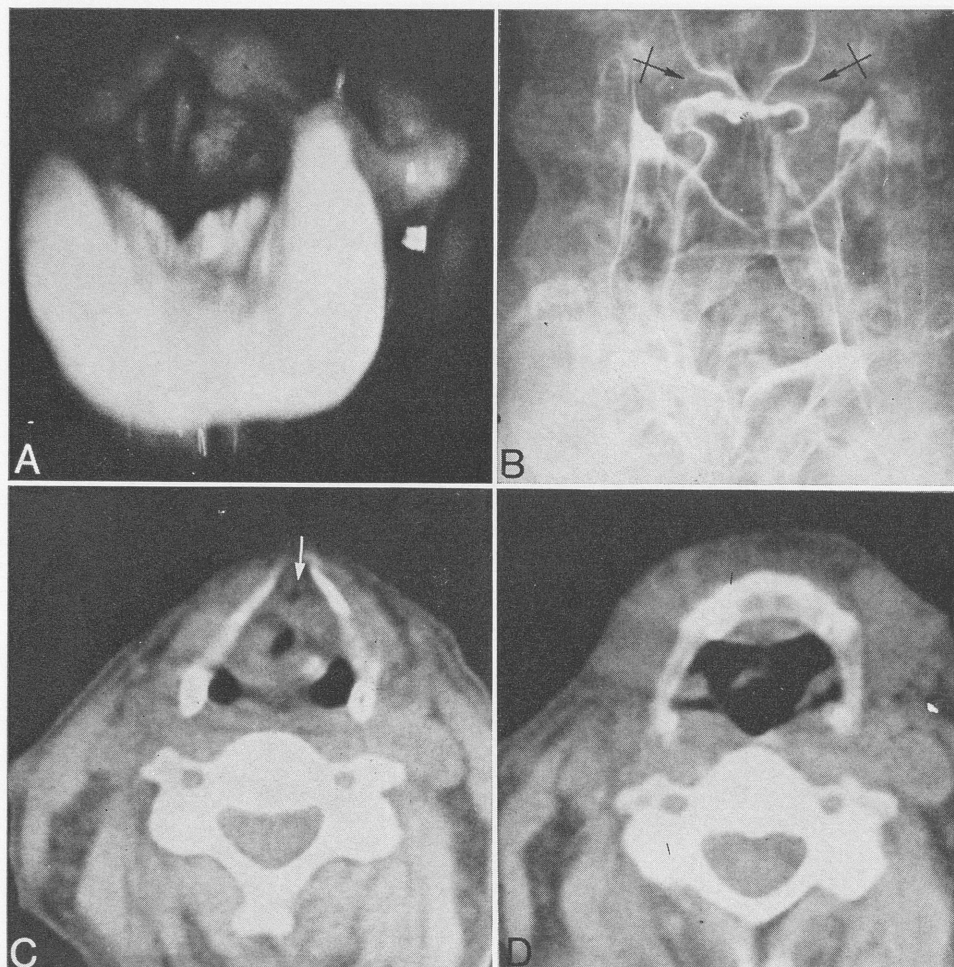


Fig. 3. (Case 3) A) Indirect telescopic photograph of the larynx showing a bulky epiglottic carcinoma of the epiglottis with a normal appearing anterior commissure. B) AP laryngograms show the normal filling of the ventricles (crossed arrows) and normal glottic structures. C) CT scan at the level of the false cords shows residual epiglottic tumor mass, but the area immediately above the anterior commissure (arrow) is free of tumor. D) At the level of the hyoid bone, the base of the tongue and valleculae are normal.

line, and invaded the thyroid cartilage (Fig. 1D).

Comment. In patients with large neglected lesions similar to this case, all diagnostic procedures, including direct laryngoscopy and contrast laryngography, are of some risk. Many of these patients have a tracheostomy and then laryngoscopy and biopsy in order to obtain a histological diagnosis. At times, a frozen section is performed, followed by an emergency laryngectomy. Even in moribund cases with pending airway obstruction, a CT scan can be safely performed and valuable information obtained con-

cerning the extent of the lesion (ie, subglottic and submucosal) as well as possible evidence of enlarged nonpalpable lymph nodes.

CASE 2

The patient was a 57-year-old Caucasian male executive who caught a cold while visiting England a number of months previously. His chief complaint was intermittent fluctuating hoarseness of nine months' duration. On examination, the lesion of the left vocal cord extended from the anterior commissure to the arytenoid (Fig. 2A). Lateral laryn-

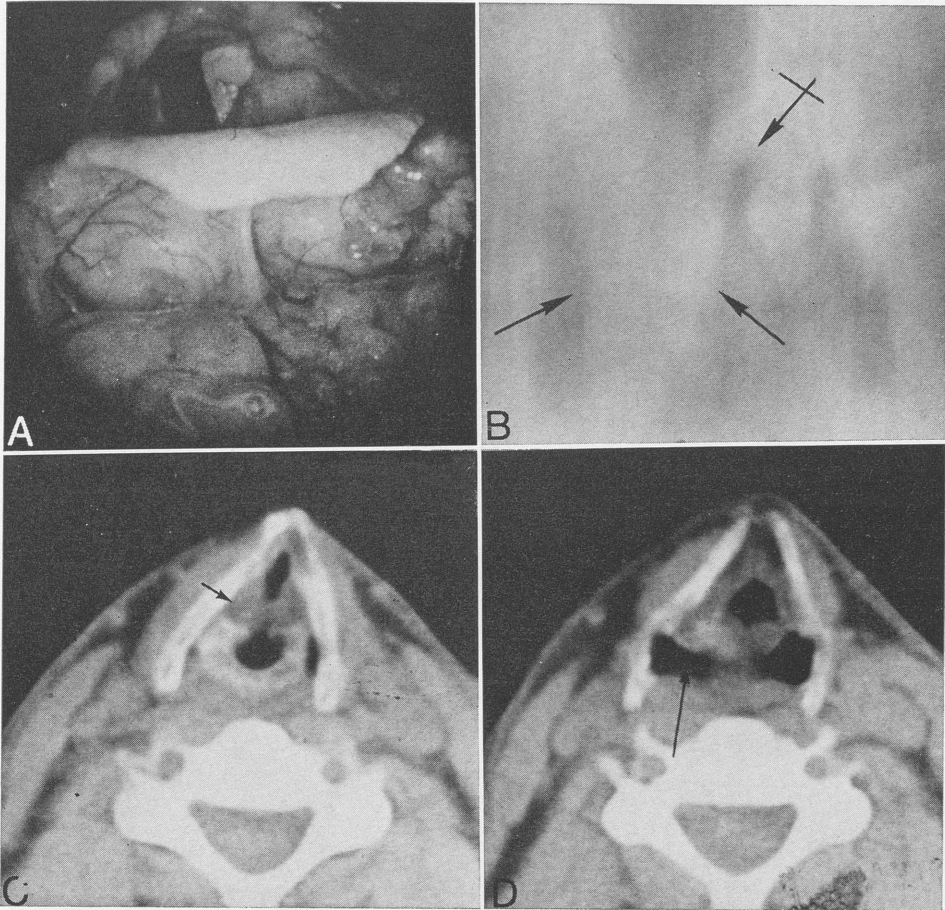


Fig. 4. (Case 4) A) Indirect telescopic photograph of the larynx showing a large hyperkeratotic lesion of the left arytenoid and posterior cordal area. B) Conventional tomography in the AP view shows marked swelling and increased thickness of the periglottic space with obliteration of the ventricle (arrows) on the pathological side. The normal ventricle is demonstrated on the right side (crossed arrow). C) CT scan at the level of the false cords (arrow) and D) at the level of the true cords shows with remarkable clarity the density changes in the paracordal area and around the arytenoid (arrow).

gogram demonstrated the distortion of the normal right cord by the mass involving the left cord extending subglottically and abutting against and distorting the normal cord (Fig. 2B). The CT scan at the level of the cricoid showed it to be free of tumor (Fig. 2C). At a slightly higher level just below the level of the cord, the CT scan showed the involvement of the left cord with some subglottic extension (Fig. 2D).

Comment. While both the laryngogram and the CT scan demonstrated the extent of the lesion of the left vocal cord, the CT scan demonstrated more clearly the level of the subglottic extension and

the absence of involvement of the lesion at the level of the cricoid. This information was extremely helpful to the surgeon in the preoperative planning of a partial laryngectomy with imbrication reconstruction.

CASE 3

The patient was a 63-year-old male who complained of fullness in the throat of six months' duration. Recently he had noted the onset of pain and sore throat. Examination of the larynx showed a large bulky lesion of the epiglottis. The cords were freely mobile. The anterior commissure could not be visualized by

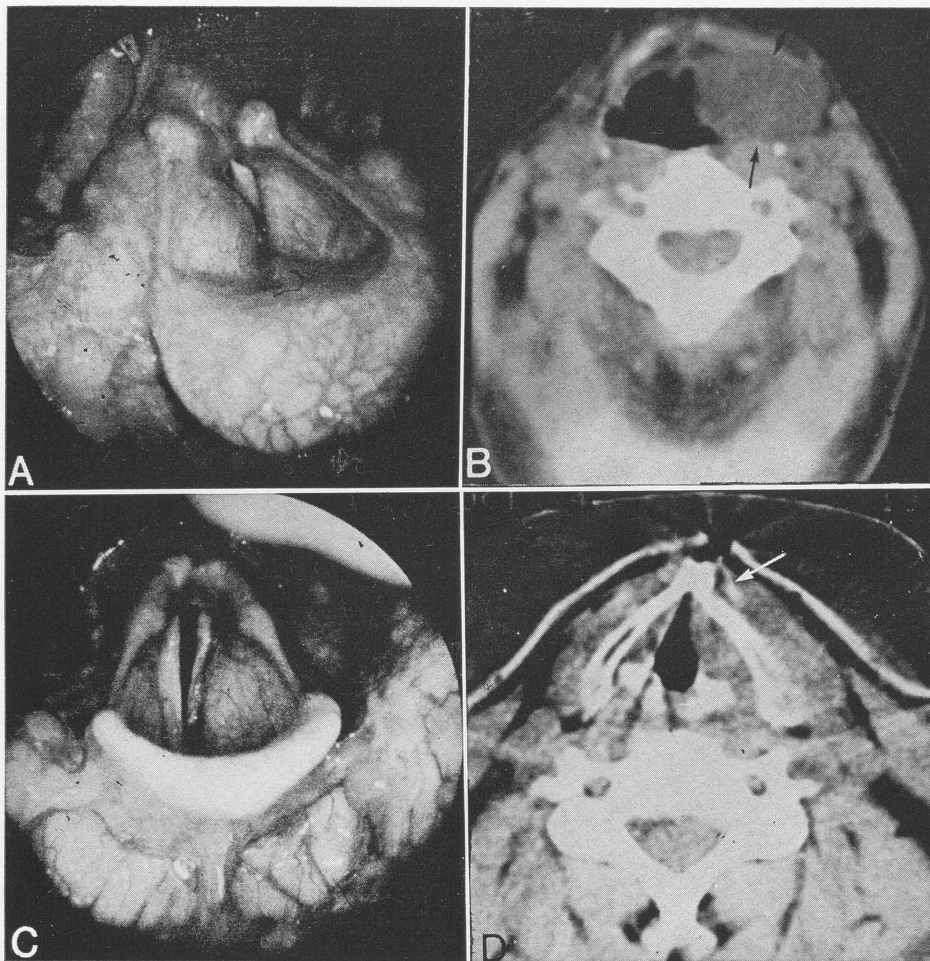


Fig. 5. A) Indirect telescopic photograph of the larynx of Case 5 showing fullness of the right aryepiglottic area, obliterating view of the true cord, accompanied by bulging into the pyriform sinus. B) CT scan shows a large lesion filling out the aryepiglottic fold (arrows) extending into the pyriform sinus with a scan density indicating the lesion was fluid filled. C) Indirect telescopic photograph of Case 6 showing a large hematoma of the right aryepiglottic fold. D) CT scan at the level of the true cord shows the buckling fracture (arrow) of the thyroid cartilage.

mirror examination, and it was only by indirect laryngoscopy with a telescope that it was possible to demonstrate freedom of the anterior commissure area of tumor (Fig. 3A). Direct laryngoscopy and biopsy confirmed the diagnosis of epidermoid carcinoma. The anterior-posterior (AP) laryngogram demonstrated filling of the ventricles and a fairly bulky lesion of the epiglottis that was seen better on lateral view (Fig. 3B). Computerized tomography scan at a level just slightly above the cords showed residual epiglottic tumor mass but more important was the normal appearance of the

area just above the anterior commissure (Fig. 3C). The CT scan at the level of the hyoid bone showed the preepiglottic space in valleculae to be clear of tumor metastasis (Fig. 3D).

Comment. The information from the laryngogram and direct laryngoscopy as well as the CT scan were helpful in determining preoperatively that a supraglottic laryngectomy would be feasible in this patient. Subsequently, this surgery was successfully conducted with maintenance of excellent voice and filling him in with primary glottic closure.

The information obtained from the CT scan was of equal if not even greater value for this patient in that it gave information concerning the soft tissue structures of the paracordal and preepiglottic spaces. These being clear and no nodes being seen in the other portions of the neck, a supraglottic laryngectomy alone appeared adequate.

CASE 4

The patient was a 40-year-old male who had complained of hoarseness of over two years' duration. He had a total of six previous biopsy excisions of large hyperkeratotic lesions of the left vocal cord. Each stripping was accompanied by rapid recurrence. The previous histologic slides were reviewed, and confirmed the impression that this was a granuloma, although because of the size of the lesion, the rapid recurrence and the appearance on indirect laryngoscopy and telescopic examination, suspicion of a carcinoma was entertained (Fig. 4A). Conventional tomography showed the marked increase in thickness of the periglottic area with obliteration of the ventricle on the pathological left side (Fig. 4B). Contrast laryngogram showed swelling of the false cord extending into the laryngeal vestibule and pushing up out into the piriform sinus. The apex of the piriform sinus was normal, however, as was the opposite piriform sinus. The CT scan at the level of the true cords (Fig. 4D), false cords (Fig. 4C), and even higher showed an increase in bulk and density in the paracordal area. Particularly noticeable were the density changes around the arytenoid.

Comment. In this particular case, the CT scan demonstrated one of the major attributes of computerized tomography; its ability to distinguish and ascertain the involvement of soft tissue changes in the paracordal area.

CASE 5

The patient was a 40-year-old Negro female with a one-month history of pain in the throat and mild swelling in the neck with minimal hoarseness. Indirect laryngoscopy revealed a fullness in the larynx involving the aryepiglottic fold and obliterating the view of the true cord accompanied by bulging out into the piriform sinus (Fig. 5A). The CT

scan showed a large cystic lesion filling the right aryepiglottic fold extending into the piriform sinus (Fig. 5B). The CT scan indicated the difference in the tissue density, the Delta factor, which indicated that the mass was cystic and filled with fluid.

Comment. Because of marked limitation of movement of the vocal cord, the differential diagnosis was either laryngocele or malignancy. The CT scan in this situation was essentially pathognomonic of a laryngocele and the approach to informing the patient was much easier in terms of helping to determine the surgical approach.

CASE 6

The patient was a 34-year-old Caucasian male who came into the emergency room because of hoarseness after having been struck in the neck with a fist. Indirect laryngoscopy revealed a large hematoma of the right aryepiglottic fold (Fig. 5C). There was limited motion of the right vocal cord and there was a shift of the larynx somewhat to the right with some evidence of paresis of the external branch of the superior laryngeal nerve that could be determined by the examination of motion picture study of the larynx. The CT scan at the level of the true cord showed the buckling fracture of the thyroid cartilage (Fig. 5D). The arytenoids, however, were not dislodged and the large hematoma involved in the aryepiglottic fold on the right side involving the cord could be seen extending into the piriform sinus.

Comment. Noninvasive methods of evaluating trauma to the larynx now are available. The risk in cases where there has been neck injury, lacerations of the pharynx with blood in the pharynx and where the airway is not compromised, can now provide information that allows us to follow the patient more safely without exploration, even though this patient had a nondisplaced fracture of the larynx. The absence of lacerations and the presence of an adequate airway with determination of the extent of the hematoma allowed the observation and eventual restoration of the patient's voice to normal without operative intervention.

DISCUSSION

The development of CT and the nu-

merous recent improvements and technological advancements in the procedure now make this a feasible diagnostic technique for studying numerous lesions involving the larynx including tumors, benign and malignant, cystic lesions and traumatic lesions of the larynx. The rapid progress in medicine and the development of laryngography, cinelaryngography, and conventional tomography as well as CT, have markedly increased the cost, particularly if all of these tests are needed. After a careful study of over 100 cases, the radiological colleagues and surgical author of this paper are convinced that valuable information can be obtained from each of the prediagnostic studies of various lesions of the larynx. This study had led to the conclusion that in cases of tumor, trauma, and cystic lesions of the larynx adequate evaluation needs to include only cinematographic documentation of the lesion accompanied by CT of the larynx. It is the feeling of the group that conventional tomography and contrast laryngography are now obsolete and no longer need to be ordered, providing good CT scanning is available. Many attributes of CT including increased comfort for the patient, noninvasiveness of the procedure with absence of need to inject any material that may cause a reaction or airway obstruction, and the much enhanced detail of the newer CT machines, all contribute to the unequivocal success of this procedure. Most important of all is the ability to assess the volume of tissue masses and the density factors which assist in differential diagnosis. In addition to providing better assessment of the paracordal and pararytenoidal involvement, it also allows better assessment of the preepiglottic space. The newer technology has now reduced the period of performing the procedures to several minutes. The initial scan section required 20 seconds each. The current scanning techniques allow each section to be scanned within a two-second period, eliminating respiration as a problem in increasing the definition of the lesion.

The newer General Electric scanner is capable of performing six scans per second, which will reduce the total time of examination to several minutes. It is primarily because of this extensive prospective study that third party payers have recognized the value of the procedure and are now paying for laryngeal CT scanning whenever there is a question of tumor involvement. It is hoped that their policy will be expanded to include approval for evaluation of extracranial areas other than the larynx where CT scanning may prove of value. The amount of radiation exposure with the new technology has been reduced to less than one half of the radiation exposure of the conventional tomography. Through more extensive use, the cost has been reduced to a level similar to that of conventional tomography, and thus acceptable to third party payers.

Perhaps the greatest drawback of this procedure is the requirement that the clinician exert the effort to develop the capability of reading these new scans, as was previously required to develop ability in reading the conventional tomography and laryngography. This is easily achieved by clinical consultation with the radiologist performing the tomography, who always is interested in clinical correlation similar to those achieved in this study. It is further encouraged that expansion of the use of the indirect telescope not only for examination but for photographic documentation be performed since the era of drawing pictures is nearing an end and photographic documentation, particularly in the form of motion pictures, allows evaluation and reassessment, as well as restaging, any time in the future that retrospective studies of therapeutic results are desired. The authors are currently involved, as are others, in extensive evaluation of photographic and tomographic correlative studies in other areas of the head and neck that may be proved of value in the use of this new tool in our continued advancement in medicine.

REFERENCES

1. Gould L, Cummings C, Rabuzzi D, et al: Use of computerized axial tomography of the head and neck region. *Laryngoscope* 87: 1270-1276, 1977
2. Pullen F: The use of computerized tomography in otolaryngology. *Trans Am Acad Ophthalmol Otolaryngol* 84:622-627, 1977
3. Thawley S, Gado M, Fuller T: Com-

puterized tomography in the evaluation of head and neck lesions. *Laryngoscope* 88:451-459, 1978

4. Wortzman G, Holgate RC: Computerized tomography (CT) in otolaryngology. *Laryngoscope* 86:1552-1562, 1976

5. Mancusco A, Hanafee W, Juillard G, et al: The role of computed tomography in the management of cancer of the larynx. *Radiology* 124:243-244, 1977

6. Ward PH, Berci G, Calcaterra T: Advances in endoscopic examination of the re-

spiratory system. *Ann Otol Rhinol Laryngol* 83:754-764, 1974

7. Ward PH, Berci G, Calcaterra T: The larynx and the pharynx — what the endoscope can show you, live on film. *Resid Staff Phys* 80:19-26, 1976

8. Ward PH, Berci G, Calcaterra T: Superior laryngeal nerve paralysis, an often overlooked entity. *Trans Am Acad Ophthalmol Otolaryngol* 84:78-87, 1976

9. Jelden GL, Chernak ES, Rodriquez AA, et al: Further progress in CT scanning and computed radiation therapy treatment planning. *Am J Roentgenol* 127:179-185, 1976

REPRINTS — Paul H. Ward, MD, Department of Head and Neck Surgery, UCLA School of Medicine, Los Angeles, CA 90024.

DISCUSSION

CHARLES NORRIS, MD (Philadelphia, Pennsylvania): I think this has been a rather convincing demonstration of what CT can do. We all, of course, have a common goal of precision in diagnosis in a quantitative and not just a qualitative sense and anything which contributes to this is worthwhile. Precision is the key to selection of treatment and is the key to successful treatment.

Ordinarily, our judgement is based on a synthesis of findings of various methods of examination, mucosal changes, thickening, asymmetries, and changes in mobility which can be determined on the basis of the variety of studies which Dr. Ward has shown. The particular contribution of the CT seems to be its enhancement of alterations in soft tissue density, particularly cartilage destruction and this can be valuable in determining indications for radiation versus conservation surgery or perhaps conservation surgery versus more radical surgery.

I do not feel that the CT is going to supplant the more often used laryngogram and conventional tomograms. The laryngogram to me seems to complement the CT done in the transaxial plane, since the laryngogram provides an image in the coronal as well as in the sagittal plane. It may be found that the laryngogram gives the most useful information with respect to the intrinsic laryngeal structures despite the possibilities of CT in demonstrating adjacent soft tissue abnormalities.

In the manuscript, Dr. Ward mentions the possible value of CT in detecting subclinical lymph nodes, and I would like to ask him to elaborate further on this.

J. RYAN CHANDLER, MD (Miami, Florida): It is always a pleasure to see new advances in diagnosis which help us in the study and the pathogenesis of disease. However, we must be careful in translating these studies which elucidate those sorts of things, into the clinical management of the patient. While I greatly admire the work that Dr. Ward has done I'd like to hear him comment in regard to what way those studies contributed to the decision-

making process in the management of those patients.

PAUL WARD, MD (closing): I particularly want to thank Dr. Norris and Dr. Chandler for their comments. In response to their questions, in the manuscript we have described, discussed and studied extensively over 100 cases. This was a study done with some grant funds to help determine third party payments as to whether they would be made or not; and the answer is yes, Dr. Norris, we do think that CT scan will supplant laryngography and tomography, that likewise with the increase in usage the third party payers have now agreed to pay, in the cases of tumors, the cost that's approximately the same as that of a laryngogram. The amount of radiation that is produced in the newer scanners which now take as many as six sections per second (versus the old 20-second scanner) has reduced the radiation to less than half of a regular tomogram. In terms of determination of nodes, these can certainly be seen many, many times when they are subclinical in size. However, one cannot differentiate between tumor invasion versus reactive hyperplasia except those cases where there has been extension out into the tissues per se. I want to emphasize the importance of documentation because the days are over when we have to draw pictures. Particularly moving picture photographic documentation will allow the reclassification, reevaluation, and staging in the future when people want to go back and combine these things and restudy lesions that they had previously, because color, appearance, and mobility, plus the information of the CT scanner are invaluable. I felt like all of you that it's hard to give up laryngography and tomography but Dr. Hanafee and Dr. Mancuso have made a believer of me. I would advise and ask all of you to spend a lot of time with your radiologists and they will help you learn to read these as I am learning to read them. You can get all the information plus from this one test that will cost less or the same, that will give you more information and will give the patient less radiation. I would emphasize to Dr. Chandler that the example of the case of the large lesion (where

one cannot actually see the lower extent of it) is not one that you would like to do laryngography on, particularly with the use of contrast material. Easy assessment of the lesion can be done with the CT scanner without any unpleasantness or risk to the patient, with relative comfort, and the extent of the lesion can be easily determined. Likewise, the paracordal

invasion, invasion of cartilage, and change in denseness of these structures is very, very helpful in determining the extent of the lesion, and offers the opportunity to present to the patient what probable type of surgery one will do. I think this is a great advance and I am very much indebted to my colleagues who have taught me.

LEIOMYOSARCOMA OF THE CERVICAL TRACHEA

REPORT OF A CASE WITH RECONSTRUCTION USING A LATISSIMUS DORSI ISLAND FLAP

J. M. FREDRICKSON, MD

A. F. JAHN, MD

D. P. BRYCE, MD

TORONTO, ONTARIO, CANADA

A case of leiomyosarcoma of the cervical trachea is described, detailing clinical presentation, pathologic diagnosis and surgical management. The rarity of this tumor in this location accounted for difficulties in clinical diagnosis and pathologic classification. Surgical treatment involved resection of two thirds of the circumference of the infracricoid trachea, with partial resection of the cricoid cartilage and thyroid gland. The defect was reconstructed using bilateral "butterfly" advancement flaps and a latissimus dorsi myocutaneous island flap. The technique and advantages of the latissimus dorsi flap are briefly described.

Leiomyosarcoma is a mesenchymal malignancy which very rarely involves the trachea. A recent case which was treated by primary resection provided an opportunity to review the clinical and pathologic features of this tumor and to describe a novel way of performing part of the tracheal reconstruction.

CASE REPORT

Mr. P. R., a 22-year-old university student, presented with a two-month history of "asthma" which had grown progressively worse in spite of medical therapy. An athlete, he initially noted minor difficulty on deep inspiration. After the first month this progressed to frank wheezing on exertion. Chest roentgenograms were normal. He was referred for bronchoscopy. During anesthetic induction, the patient's airway became acutely obstructed, necessitating emergency tracheostomy. Following tracheostomy, endoscopic examination of the trachea revealed a pedunculated mucoid, yellowish-pink tumor attached to the anterior and right lateral wall of the trachea, about 4 cm below the cricoid. The mass was removed piecemeal, and the pathologic diagnosis was inflammatory pseudotumor. Only one of ten pathologists disagreed, wondering whether it might represent a low grade sarcoma.

Six months after initial removal, he developed an upper respiratory tract infection followed by persistent cough and

wheezing, suggestive of a recurrence. He was then referred to us. Xerogram of the trachea revealed a large pedunculated mass arising from the anterior wall of the trachea (Fig. 1). He was readmitted for bronchoscopy. During induction the patient's airway again occluded. The previous stoma was reopened, and, with the airway secure, numerous biopsies were taken. Sarcoma of uncertain morphology was diagnosed. Subsequent search for distant metastases was negative.

Four weeks following this diagnostic procedure, definitive resection of the tumor was carried out. The 5 cm mass arose from a 2 cm stalk on the anterior and right lateral walls of the trachea. Approximately 8 cm of the anterior and right lateral trachea was resected including the tracheostomy site with partial removal of the cricoid anteriorly in continuity with the right thyroid lobe. Care was taken during surgery to identify and preserve both recurrent laryngeal nerves. A thorough search of the neck revealed no spread, and representative paratracheal neck nodes were biopsy negative. Anterior chest flaps were elevated bilaterally and rotated medially. Their medial edges were sutured to the edges of the tracheal defect to construct an open tracheal trough (Fig. 2). Post-operatively the vocal cords functioned normally.

Six weeks following resection, the second stage of reconstruction was un-

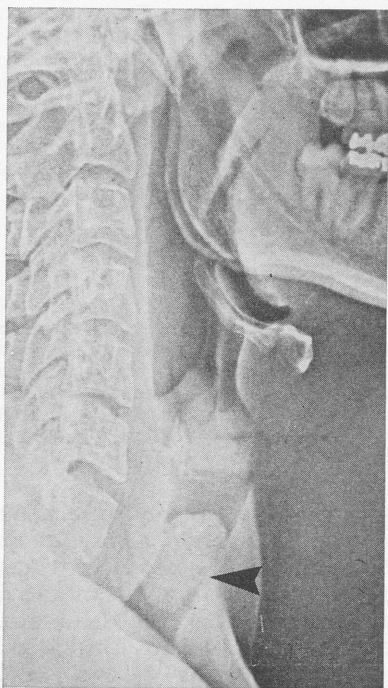


Fig. 1. Lateral xerogram demonstrating a mass arising from a pedicle attached to the anterior wall of the trachea (arrow).

dertaken. The open trough and adjacent margin of skin were circumcised, the skin margin undermined and folded over to close the tracheal trough. Previous use of the "butterfly" chest flap (Fig. 2) precluded the use of other convenient chest flaps (eg, deltopectoral or pectoralis major myocutaneous) to cover the resulting sizeable cervical skin defect. Cover was obtained using a right latissimus dorsi myocutaneous flap. The flap was pedicled on the thoracodorsal vessels, and brought up in an undelayed fashion under the skin of the anterior

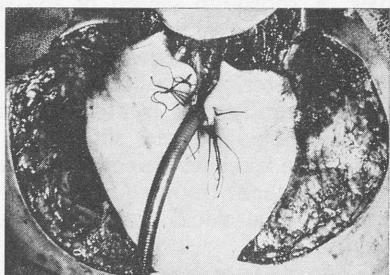


Fig. 2. Photograph demonstrates advancement of "butterfly" chest flaps. These were sutured to the resected margins of the trachea to form an open tracheal trough.

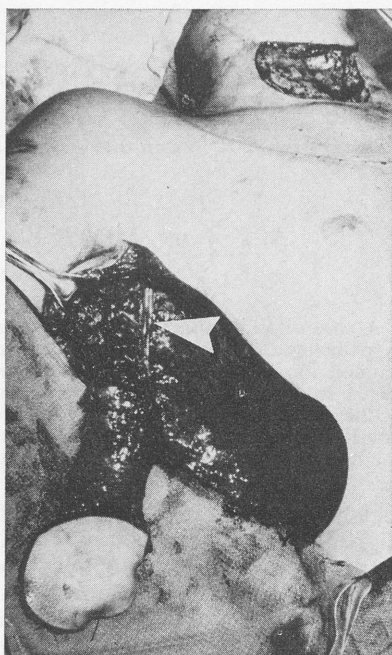


Fig. 3. Photograph of the right latissimus dorsi myocutaneous flap developed to close the obvious cervical skin defect. The thoracodorsal vessels (arrow) supply the muscle and overlying skin. The flap was transferred to the cervical defect by undermining the adjacent skin. The donor site was closed primarily.

chest wall to fill the midline skin defect (Fig. 3). The donor site was closed primarily.

Postoperatively the flap maintained good color, and the patient's airway remained uncompromised. Some difficulty with extubation produced a coughing paroxysm and the patient developed subcutaneous emphysema under the flap with a subsequent small air leak at the flap margin which lasted six weeks. Despite this the flap remained viable.

At present the patient has a good voice and an ample airway by radiologic and bronchoscopic evaluation. He is an ambidextrous squash player and weight lifter, and muscular function of the right arm and shoulder girdle have not been impaired by partial resection of the latissimus dorsi (Fig. 4).

DISCUSSION

This case merits discussion clinically, pathologically and surgically. The clinical presentation of tracheal sarcomas differs from carcinomas in three ways. There are no predisposing historic fea-

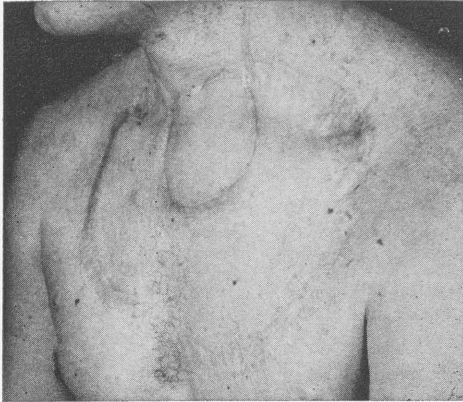


Fig. 4. Appearance of patient's chest six months postoperatively. He has a normal voice and an excellent airway.

tures such as age or smoking. There are no areas of predilection within the trachea, and sarcomas may develop in a random distribution from the cricoid to the carina. Thirdly, since sarcomas tend to remain subepithelial, hemoptysis (an important sign of tracheal carcinomas) is not seen.

Sarcomas of the trachea are rare, but the rarity of tracheal carcinomas in infants makes tracheal sarcomas the most common tumor in this age group.¹ Ninety percent of tracheal malignancies are squamous or adenoid cystic carcinoma.²⁻⁴ In a representative 30-year survey from the Mayo Clinic, Houston et al⁴ found only 5 of 53 cancers (or 11.4%) to be mesenchymal in origin. Most of tracheal sarcoma are descriptions of single cases.⁵⁻⁸ A survey of the English literature has disclosed only five previous reports of tracheal leiomyosarcoma,^{4,8,9} although it is likely that early reports included leiomyosarcomata that where histologically unrecognized.¹⁰

Histologic identification and grading of this tracheal tumor is important in planning treatment and predicting the results of therapy. Since reports of tracheal leiomyosarcoma are statistically insignificant in number, the histologic features of prognostic importance have been inferred from studies of leiomyosarcoma in other locations. Studies of leiomyosarcoma of lung,⁸ uterus,¹¹ and superficial soft tissues¹² are relevant. Poor prognostic features are; large lesions, anaplasia, and numerous mitoses. In Stout and Hill's¹²

series of superficial soft tissue tumors, leiomyosarcomas measuring greater than 5 cm in diameter had a poor prognosis, while tumors under 2.5 cm were curable. In tumors between 2.5 and 5 cm, the prognosis was variable. Suit,¹³ in an overview of soft tissue sarcomas also considers tumors over 5 cm to be prognostically poor. Only where a tumor over 5 cm demonstrates a very low histopathological grade does he feel somewhat optimistic about curative surgical resection. Although anaplasia and the presence of bizarre cells is generally felt to be indicative of a tumor's malignant potential, Wheelock and Warren,¹⁴ in a study of uterine leiomyosarcoma, caution against overestimating this index of malignancy.

The number of mitotic figures per high power field is helpful when the distinction between leiomyoma and leiomyosarcoma is unclear,¹² but the exact number of mitotic figures required to diagnose a highly malignant tumor versus one of low malignant potential is a subject of debate.^{11,12}

In extrapolating the above pathologic evidence to the cervical trachea, certain concessions must be made to local anatomy and physiology. Endotracheal tumors present earlier than tumors in lung or other soft tissues, and thus are of smaller size when treated. Another advantageous factor is the segmental blood supply,¹⁵ and lymphatic supply of the trachea¹⁶ which slow the systemic spread of tracheal tumors and facilitate local resection even when extension beyond the actual tracheal wall has occurred.

In the present case, the tumor was localized to the trachea, and had a low mitotic index. Although it had a 5 cm diameter, it arose from a 2 cm pedicle. In the absence of obvious extension the prognostic features appear most favorable.

Surgical resection of tumors of the cervical trachea pose reconstructive problems. The surgeon must create a laterally rigid tube which is fully epithelium-lined, airtight, constructed of the patient's own tissues and a tube which heals promptly with minimal stenosis.¹⁵ Earlier efforts using synthetic material grafts¹⁷ have given way to circumferen-

tial resection with end-to-end anastomosis.¹³ Mediastinal mobilization¹⁵ combined with laryngeal release,¹⁹ has permitted approximation of proximal and distal tracheal stumps over distances up to 10 cm. Laryngeal release alone provides approximately 7 cm of bridging. Where the tracheal segment was excised completely, reconstruction using interposed skin flaps has been unsuccessful, since the rigidity of the interposed segment is unpredictable.¹⁵

In the present case, complete tracheal resection with laryngeal release and end-to-end anastomosis was considered. However, an 8 cm segment of trachea had to be resected in order to excise the tumor radically including the tracheostomy site. This amount of tracheal loss was considered too risky to bridge. Since the posterior and left lateral tracheal supporting walls could be spared without compromising resection, a two-stage "trough" technique was chosen for reconstruction. After bilateral "butterfly" flaps were advanced to the edges of the resected trachea, the problem of cervical skin cover at the second stage arose (Fig. 2). The "butterfly" flaps compro-

mised the blood supply to both deltopectoral flaps, and therefore rectangular horizontal advancement flaps would have been preferable in the first stage. Given this problem, the latissimus dorsi myocutaneous flap offered a novel solution to the surgeon's dilemma.

The latissimus dorsi myocutaneous flap is an arterial island flap based on the thoracodorsal branch of the artery with its accompanying vein. The vascular pedicle has a point of rotation high in the axilla, giving the flap considerable reach, and permitting its utilization over the sacrum, anterior chest wall, or neck.^{20,21} The flap has been used to cover the buccal and mandibular area.²¹

The latissimus dorsi myocutaneous flap has advantages for the head and neck cancer surgeon; there is little donor site deformity and no functional loss;^{20,21} it brings fresh tissue to an area that may have been irradiated; and it can be transferred in one stage. For the surgeon not conversant with microvascular techniques, this flap offers many of the advantages of a free flap without the problems of microvascular anastomosis for revascularization.

REFERENCES

1. Gilbert JG, Mazzarella LA, Feit LJ: Primary tracheal tumours in infants and children. *Arch Otolaryngol* 58:1-9, 1953
2. Hajdu SI, Huvos AG, Goodner JT, et al: Carcinoma of the trachea. *Cancer* 25: 1448-1456, 1970
3. Bennetts F: Tracheal tumors. *Postgrad Med J* 45:446-454, 1969
4. Houston HE, Payne S, Harrison EG, et al: Primary cancers of the trachea. *Arch Surg* 99:132-140, 1969
5. Daniels AC, Conner GH, Straus FH: Primary chondrosarcoma of the tracheobronchial tree. *Arch Pathol* 84:615-624, 1967
6. Roncoroni AJ, Puy RJM, Goldman E, et al: Fibrosarcoma of the trachea with severe tracheal obstruction. *Thorax* 28:777-781, 1973
7. Richards LG, Dietrich HF: Fibrosarcoma of the trachea. *Ann Otol Rhinol Laryngol* 43:892-905, 1934
8. Fleetham JA, Lynn RB, Hunt PW: Tracheal leiomyosarcoma: A unique cause of stridor. *Am Rev Respir Dis* 116:1109-1112, 1977
9. Holinger PH, Slaughter DP, Novak FJ: Unusual tumors obstructing the lower respiratory tract of infants and children. *Trans Am Acad Ophthalmol Otolaryngol* 54:223-234, 1950
10. D'Aunoy R, Zoeller A: Primary tumours of the trachea. *Arch Pathol* 11:589-600, 1931
11. Anderson WAD, Kissane JM: *Pathology*. St. Louis, CV Mosby Co, 1977
12. Stout AP, Hill WT: Leiomyosarcoma of the superficial soft tissues. *Cancer* 11:844-854, 1958
13. Suit HD: Sarcoma of soft tissue. *Cancer* 28:284-295, 1978
14. Wheelock MC, Warren S: Leiomyosarcoma of the uterus. *Ann Surg* 116:882-890, 1942
15. Grillo HC: Management of cervical and mediastinal lesions of the trachea. *JAMA* 197:137-142, 1966
16. Strauss JF: The intimate lymphatics of the trachea. *Ann Otol Rhinol Laryngol* 31: 715-726, 1922
17. Pearson FG, Henderson RD, Gross AE, et al: The reconstruction of circumferential tracheal defects with a porous prosthesis. *J Thorac Cardiovasc Surg* 55:605-616, 1968
18. Grillo HC: Surgery of the trachea. *Curr Probl Surg*, July 1970, pp 3-59
19. Dedo HH, Fishman NH: Laryngeal release and sleeve resection for tracheal stenosis. *Ann Otol Rhinol Laryngol* 78:285-296, 1969
20. McCraw JB, Penix JO, Baker JW: Repair of major defects of the chest wall and spine with the latissimus dorsi myocutaneous flap. *Proc R Soc Med* 62:197-206, 1978
21. Quillen CC, Shearin C, Georgiade NG: Use of the latissimus dorsi myocutaneous island flap for reconstruction in the head and neck area. *Proc R Soc Med* 62:113-117, 1978

REPRINTS — John M. Fredrickson, MD, Department of Otolaryngology, Medical Sciences Bldg., Room 7310, University of Toronto, Toronto, Ontario, Canada M5S 1A8.

ENDOSCOPIC TEFLON® KEEL FOR ANTERIOR GLOTTIC WEB

HERBERT H. DEDO, MD

SAN FRANCISCO, CALIFORNIA

Anterior glottic webs are generally repaired with a McNaught keel placed and removed by laryngofissure. Attempts have been made since 1922 to repair these webs endoscopically. An endoscopic technique using a Teflon keel which has been successful in properly selected cases is presented.

An anterior glottic scar or web can be congenital or develop as a result of trauma. External injury can cause anterior larynx fracture which tears the mucosa, or there can be surgical removal of mucosa from the anterior edges of both vocal cords. When the raw anterior vocal cord edges heal together, the resulting scar or web can cause voice abnormalities (higher pitch or hoarseness) if it extends more than 3 to 4 mm back along the cord edges. If it reaches back to the vocal processes of the arytenoids, it will cause a whisper voice and moderate to severe airway obstruction. In severe cases total glottic stenosis can occur, stopping the voice and laryngeal breathing, and requiring a tracheotomy.

Treatment has gone through several phases in the past. First, attempts were made to dilate or cut the web. This usually has not worked because it simply duplicates the mechanism of the original injury in which raw surfaces are created on the anterior free edges of both vocal cords and allowed to become adherent to each other. Recently, attempts have been made to use a new modality, the CO₂ laser, to divide webs in the hope they would not re-form because of the relatively rapid healing and minimum scarring after laser incision or excision of mucosa. Perhaps this approach will occasionally work in very thin mucosal adhesions or webs involving most of the membranous cord. However, in my experience this approach has not provided reliable results, probably because the webs are not thin through to the anterior commissure.

Another type of treatment used was

Haslinger's endoscopically placed stent or plate of metal folded in half and held in place with a wire passing out through the thyrohyoid membrane and cricothyroid membrane to buttons.¹ This metal plate was supposed to hold the raw surfaces apart while they epithelialized (Fig. 1); it was abandoned because it was not consistently successful. In retrospect, it and other endoscopic keels²⁻⁴ may not have been successful because to get these stents to reach into the anterior commissure is difficult since the anterior or leading edge is a straight line, while the epiglottis and anterior wall of the trachea make approximately a 120° to 125° angle. Thus the metal plate would not stay in the anterior commissure unless the upper corner of it was just at or above the anterior commissure. This is hard to maintain when the upper wire comes out through the thyrohyoid membrane and tends to cause granulations immediately at or above the anterior commissure.

Another approach designed to avoid the problems of the Haslinger keel was provided by McNaught.⁵ His keel, made of metal with tabs alternating to the right and left side, was installed via laryngofissure after separating the web (Fig. 2). This meant that the metal plate extended not only through the anterior commissure, but even anterior to that through the thyroid cartilage. Thus it was able to prevent the anterior edges of the vocal cords from again becoming attached to each other. The disadvantage was that it required an external incision with an open operation twice, once to divide the web and install the keel, and once to remove it. Also, it re-

From the Department of Otolaryngology, University of California, School of Medicine, San Francisco, California.

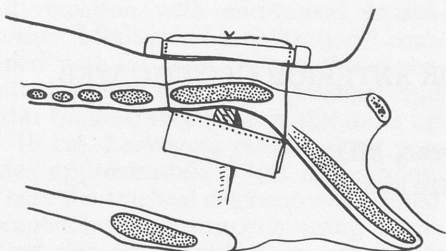


Fig. 1. Haslinger type of keel in place with a *straight* anterior edge.

quired a tracheotomy and tended to cause granulation tissue polyps to form along the anterior thyrotomy line requiring a direct laryngoscopy and removal two or three months later. These were ordinarily not a problem because the cords were epithelialized almost to the anterior commissure on each side so that the polypoid granuloma was attached over a thin vertical pedicle, allowing easy removal. There has been a high success rate in our hands using the McNaught keel, although it ordinarily leaves a small, approximately 2 to 3 mm anterior web when healing is complete. I find it the most satisfactory technique for thick anterior glottic stenosis, ie, those extending more than 5 to 8 mm below the superior free edge of the vocal cord, particularly when the stenosis extends into the cricothyroid membrane and the cricoid area (Fig. 2).

For total glottic stenosis, various techniques have been described using hard or soft, round stents, with or without skin grafts, left in place for a week or for months. In my experience, these have not proved reliable and effective. In these patients I prefer to use the mucosal advancement flap from the false cord and aryepiglottic fold to reestablish epithelialization in the posterior

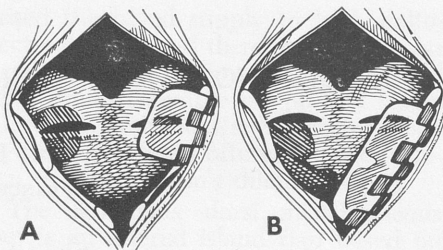


Fig. 2. A) McNaught keel in place for anterior false and/or true cord web. B) McNaught keel being used for vertically thick glottic and subglottic stenosis. Note posterior commissure mucosa must be intact for this technique to be used alone.

larynx on one side,⁶ combined with submucosal resection of scar and, if necessary, a McNaught keel. The mucosal advancement flap, by epithelializing one half of the posterior larynx, prevents the other side from adhesion to it, and the McNaught keel then is used to keep the anterior raw surfaces apart while they epithelialize at the supraglottic, glottic and cricoid levels, if necessary.

Because of the disadvantages of the McNaught keel, I started nine years ago trying to correct the thinner anterior glottic webs or stenoses with an endoscopic keel. I have now used an endoscopically placed, triangular-shaped flat plate or keel fashioned from a sheet of the Teflon plastic,* commonly used in nasal surgery as an anterior septal stent, in six patients. The patients have been followed for six months to seven years and now five or six have only 1 to 3 mm webs with good to normal voices.

TECHNIQUE

Direct laryngoscopy is performed to evaluate the extent of the stenosis, both in an anterior/posterior dimension and in a vertical or superior/inferior dimension. There should be intact mucosa in the posterior commissure,

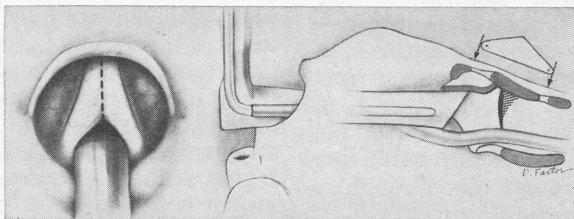


Fig. 3. Glottic stenosis divided. Teflon keel cut so its length equals distance between hyoid and cricoid, and width is same or less than distance from anterior commissure to vocal processes.

*V. Mueller, Chicago, IL.

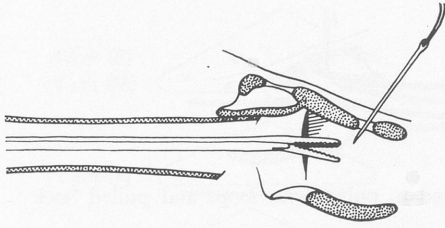


Fig. 4. Needle with 26 gauge stainless "puller" wire is inserted through cricothyroid membrane and grasped with alligator clamp and pulled to proximal end of laryngoscope.

and the web should be thin to use this keel. The Teflon keel has been successful with stenoses extending from the anterior commissure to the anterior edge of the vocal process since this left intact mucosa in the posterior commissure (Fig. 3). It has been used successfully in a newborn baby and an elderly adult. The length of the stenosis is determined via direct laryngoscopy, and the inferior extent is determined by passing a blunt 90° hook below the stenosis and palpating to determine how thick it is as it goes anteriorly. The self-retaining arm and the photography model of my laryngoscope¹⁸ are used so the microscope and a camera can be utilized. The patient's permission has been obtained to permit placement of an endoscopic keel, and if it is not deemed feasible, authorization has also been obtained to proceed with a tracheotomy and a McNaught keel so that an extra anesthetic can be avoided. If it is thin and there is a normal posterior commissure, the stenosis is divided with a laryngoscopy knife. If, when the web has been divided to the anterior commissure it is confirmed that it does not go below the bottom edge of the true cord, then a keel is fashioned from the sheet of Teflon plastic used for nasal surgery. This is used instead of metal so that it will not cut into the thyroid cartilage during larynx elevation with swallowing while in place. The keel is designed so that the overall length extends approximately from the midpoint of the hyoid bone to the superior edge of the cricoid cartilage, or to the midpoint of the cricoid cartilage.

The three key dimensions are as follows (Fig. 3):

1. The length needs to be sufficient so that the distance between the two needle holes approximately equals the distance between the thyrohyoid and cricothyroid membranes.

2. The anterior edge of the keel should make an angle of 120° since the angle of the epiglottis with the anterior tracheal wall is between 120° and 125°.

3. The width should be such that when the V of the leading edge of the keel is in the anterior commissure, the back edge of the keel is approximately at the anterior end of the vocal processes. If the width is too great and the keel rests on the posterior commissure, it will cause scarring and webbing between the arytenoids pulling them together postoperatively and interfering with the airway. If the keel is so narrow that it does not separate the raw edges of the cords, there is a danger that scar tissue could bridge across between the cords behind it.

A straight needle at the middle of a 60 cm length of 26 gauge stainless steel wire, the "puller wire," is inserted through the cricothyroid membrane, grasped with an alligator forceps through the laryngoscope, and the needle is pulled to the proximal end of the laryngoscope (Fig. 4). A Kelly clamp is placed on the two free ends of the wire adjacent to the skin overlying the thyrohyoid membrane and the needle is broken off the loop end of the wire. Then the thyrohyoid membrane puller wire is inserted in the same fashion (Fig. 5). After the Teflon keel has been cut to the right size, a straight needle is used to pull separate pieces of 60 cm long 26 gauge stainless steel wire through a hole in each end to the midpoint of the wire, and the needle is then removed (Fig. 5). The ends of each of these two wires are bent back into short hooks to be fitted into the puller wires. The hook ends of the upper and lower fixation wires on the keel are then placed in the loops of the thyrohyoid and cricothyroid membrane puller wires respectively (Fig. 6). Then the puller wires are used to pull the Teflon keel fixation wires out through the thyrohyoid membrane and cricothyroid membrane while the surgeon guides the Teflon keel into position with an alligator forceps (Fig. 6). The upper and lower Teflon keel fixation wires are then tied over buttons with 2.5 cm diameter Teflon washers under each button (Fig. 7) to prevent skin erosion as the larynx is

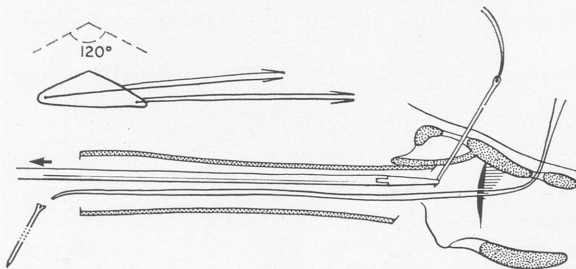


Fig. 5. Thyrohyoid membrane puller wire is inserted. Needles are broken off both puller wires. Keel is prepared with two fixation No. 26 stainless steel wires.

*The Narco Pilling Company, Fort Washington, PA.

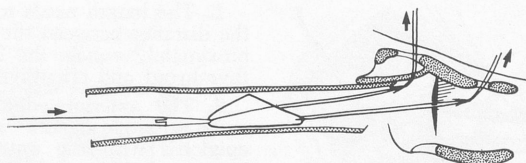


Fig. 6. Teflon keel fixation wires are hooked in puller wire loops and pulled back through skin while keel is guided into place.

elevated with each swallow. Number 1 or 2 nylon fixation sutures can be used in place of the 26 gauge stainless steel wires if desired.

The Teflon keel has been left in place three to four weeks in adults, but with thin webs it only needs to be left in place two weeks. In a newborn infant it was found that leaving the keel in place only one week was sufficient to provide time for epithelialization of both anterior vocal cords.

Figure 8 shows some Teflon keel suggested dimensions. Figure 9 shows a 60% congenital web in an adult female which had redeveloped after lysis elsewhere. The web was divided and a Teflon keel installed for four weeks. Now, ten months later, she has a clear, normal phonatory voice, feminine pitch, and a 2-3 mm anterior web (Fig. 9B).

RESULTS

Five of six patients in whom the Teflon keel has been used have had a good result with marked decrease or elimination of the anterior commissure web. In the first patient in which it was used, a newborn baby, two alternative fixation systems were used before reverting to the double button and wire system similar to that used by Haslinger and others in the past. First the keel was sutured to the side of the endotracheal tube. This was a mistake because each time the baby swallowed, the endotracheal tube was caused to knuckle at the base of the tongue since it could not slide through the vocal cords into the trachea as the larynx elevated. As a result, approximately 12 hours after surgery, the endotracheal tube had weakened and started

to kink at the base of the tongue and collect dried secretions at this point and had to be removed, along with the stent.

The keel was then replaced and held in position with a wire to a single button over the cricothyroid membrane. It was left in place one week curing the web so that seven years later there is a sharp anterior commissure. However, the anterior thrust on the keel to keep it in the anterior commissure was achieved by having the keel rest on the posterior commissure. This was a mistake because it caused a vertical scar in the posterior commissure which pulled the arytenoids together and necessitated leaving a tracheotomy tube in place until the age of six. Then at age six a laryngofissure was performed, the adhesion in the posterior commissure was divided, and the arytenoids were retracted laterally, gently but easily, with a Kelly clamp. A mucosal advancement flap was created from the mucosa of the interarytenoid notch to epithelialize the raw surface and prevent re-formation of the posterior web. He subsequently did well; the tracheotomy tube has been removed, and he has an excellent airway and voice. The posterior web has been avoided since the two-button and two-wire support system has been used to hold the Teflon keel into the anterior commissure so that it does not touch the posterior commissure.

Another small child in whom the Tef-

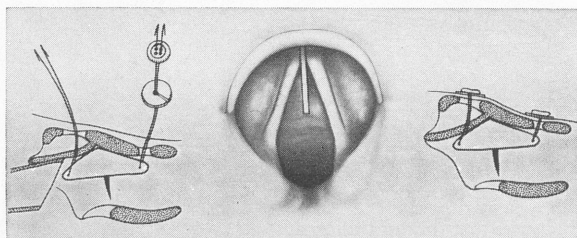


Fig. 7. Keel fixation wires tied over buttons with Teflon washers to protect skin. Teflon keel in place as seen via laryngoscope.

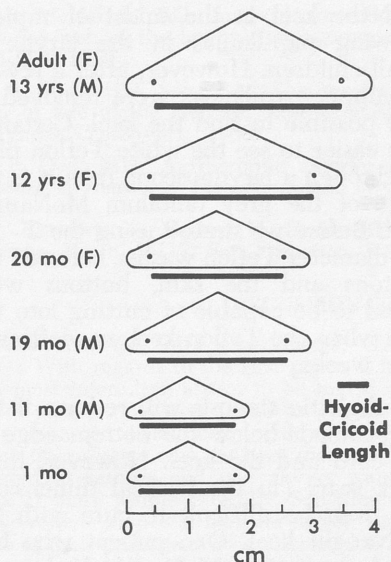


Fig. 8. Estimates of sizes of keels for different ages.

lon keel was used for two weeks to cure an anterior glottic stenosis later developed a nearly total glottic stenosis from rapid growth of papillomas and granulation tissue at the glottic level. Thus, although the Teflon keel was technically successful, we were subsequently overwhelmed by rapidly growing papillomas and posterior granulations, so it is being counted as the one failure.

DISCUSSION

It used to be accepted that any an-

terior commissure web caused hoarseness. In recent years we have become aware that a 2 mm, and sometimes even a 3 mm web, can be present in an adult larynx without materially affecting the voice. Of course, it is best to prevent web formation, and this is best done by preserving mucosa on the anterior 3 mm of one or the other cord when mucosa, papillomas or other growths are being removed. Thus, membrane can be removed if necessary from the top and under surface of one whole vocal cord and the posterior one half, or even up to two thirds of the other membranous vocal cord. This is true not only of the true cords but of the false cords.

Unfortunately, supraglottic and glottic webs can develop which cover enough of the anterior entrance to the larynx or the glottis respectively to interfere with airway and/or voice. The advantages of using a keel placed endoscopically are that two open neck operations are avoided, and in adults, tracheotomies are often unnecessary. This results in less scar, less time spent in the hospital, less cost, and less formation of granulation tissue in the anterior commissure, especially if the Teflon keel is left in place one to three weeks. Unlike a McNaught keel, it does not cut the cartilage and expose it to salivary contamination and chondritis.

In infants and small children it is safest to use an endotracheal tube, if it is

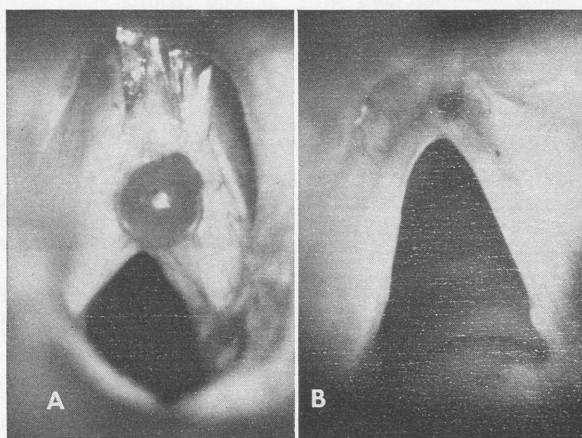


Fig. 9. Middle aged female with 60% anterior congenital web and granuloma which immediately redeveloped after simply cutting it. A) A No. 24 French endotracheal tube completely filled the glottic opening so it was removed to take the photograph. B) Tiny anterior web after lysis and endoscopic Teflon keel for four weeks, ten months before. Voice is virtually normal and a No. 24 French endotracheal tube could now be left in place while making the photograph.

tolerated, alongside the stent; or if necessary, to perform a tracheotomy. However, the adult larynx is large enough so that a tracheotomy is ordinarily unnecessary. This is one of the advantages of this keel over round stents⁸ which obstruct the airway, don't reach into the anterior commissure, and can cause ulceration and granulations.⁹

Reasons for Details of Technique. Buttons are used instead of tying the wire through a catheter left on the anterior neck skin because a catheter can cut into, and even through, the skin in less than three weeks. It is desirable to twist the 26 gauge fixation wires over the buttons loosely enough so that the tip of a Kelly clamp can be inserted between the Teflon washer and the skin. Every time the patient swallows, the larynx pulls upward against the buttons and washers so that the Teflon keel is continually being pulled into the anterior commissure. In one instance it was not possible to find the airway passing a needle through the anterior neck skin, so a straight needle was bent slightly, threaded through the hooks on the end of the fixation wires, and passed through the laryngoscope and out through the cricothyroid membrane by grasping the needle with a specially designed needle holder. The upper wire was similarly passed out through the thyrohyoid membrane. However, in general I have found it easier to use the puller wires as described above. To minimize granuloma formation it is important that the keel be left in the minimum length of time, rather than the one to six months often advocated in the past in the literature. It is possible that this keel would work successfully with more extensive stenoses, and we are now investigating this. However, now it is a minimum condition that there be good intact mucosa in the posterior commissure if an endoscopic Teflon keel or a McNaught keel is to be used.

On two occasions it has been hard to

find the keel in the midst of rapidly growing papillomas in the larynx in small children. However, after a few of the upper papillomas were removed, it was possible to find the keel. Certainly it is easier to see the white Teflon plastic through a laryngoscope than it is the edge of the grey tantalum McNaught keel. Before we started using the 2 - 2.5 cm diameter Teflon washer between the buttons and the skin, buttons were found to be capable of cutting into the skin when the Teflon keel was left even four weeks.

Subglottic stenosis will re-form if the scar extends below the bottom edge of the cord and the keel. However, these thick scars (in the vertical dimension) can even be difficult to cure with the McNaught keel. One patient who had had four previous McNaught keels, each left in for several months, restenosed after we placed a McNaught keel for four weeks. If anterior commissure granulation tissue polyps form with a narrow pedicle base after the Teflon keel, which has not been a problem for us so far, they can be readily removed two months later via laryngoscope with cup forceps. If one is available, the CO₂ laser is an even better technique for removing the granulation polyps. If stenosis were to re-form, it is still possible to do a McNaught keel.

CONCLUSION

The results with the endoscopic Teflon keel have been gratifying because it is easier on the patient, less expensive, requires less operating room time and hospital time, and the voice can be returned to a clear phonatory ("normal") type if the web was just an adhesion of the mucosal edges of the anterior membranous cords. This is because in these patients there is no significant scar and stiffening in the cord substance (the thyroarytenoid muscle) itself to interfere with vibration after the cords are freed from each other.

REFERENCES

1. Pennington CL: The treatment of anterior glottic webs: A re-evaluation of Haslinger's technique. *Laryngoscope* 78:728-741, 1968
2. Birk HG: Endoscopic repair of laryngeal stenosis. *Trans Am Acad Ophthalmol Otolaryngol* 74:140-143, 1970
3. Alonso JM, Regules JE: Treatment of membranes and synechiae of the anterior part of the glottis. *Arch Otolaryngol* 65:111-113, 1957
4. Devgan BK, Lampros WP, Leach W: Endolaryngeal surgery for anterior glottic stenosis. *Ear Nose Throat J* 55:377-381, 1976

5. McNaught RC: Surgical correction of anterior web of the larynx. *Laryngoscope* 60: 264-272, 1950

6. Dedo HH, Sooy FA: The surgical repair of late glottic stenosis. *Ann Otol Rhinol Laryngol* 77:435-441, 1968

7. Dedo HH: A fiberoptic anterior commissure laryngoscope for microscopic laryngo-

scopy. *Trans Am Acad Ophthalmol Otolaryngol* 182:91-92, 1976

8. Cohn AM, Larson DL: Laryngeal injury. A critical review. *Arch Otolaryngol* 102: 166-170, 1976

9. Thomas GK, Stevens MH: Stenting in experimental laryngeal injuries. *Arch Otolaryngol* 101:217-221, 1975

REPRINTS — Herbert H. Dedo, MD, Associate Professor, Otolaryngology, 400 Parnassus Avenue, Room A-717, San Francisco, CA 94143.

DISCUSSION OF PREVIOUS TWO PAPERS

ALAN NAHUM, MD (San Diego, California): With regards to the first paper, I found the most interesting aspect to be that diagnosis of asthma. We have found on our medical service an occasional person with upper respiratory tract disease who has been diagnosed and treated as asthma and one always wants to look at those people carefully. Sometimes the flow volume loop will indicate to you the nature of their problem. I'd be interested to have a comment on the problem with the first pathologic diagnosis and perhaps some thoughts about why it became evident on the second biopsy, ie, whether the nature of the lesion had changed or they feel it was a problem with a pathologic diagnosis. The result is certainly delightful and hardly to be faulted. There is no question that the myocutaneous flap is coming of age in plastic and reconstructive surgery and if one merely glances at the literature both in otolaryngology and plastic surgery, one can see the great push in this direction. I note on the program later this week, I think it's going to be discussed several times. With regards to the second paper, Dr. Dedo always has the ability to focus upon clinical problems and think about them, and obviously the external placement of a keel is always a troubling situation particularly in the infant and child, where one wonders whether one, two or three operations are worth the trouble. So this appears to be a very useful and innovative technique. I would ask him to comment perhaps on how he combines this with tracheostomy when he feels it's a necessary adjuvant and if so how long he keeps them in position during the course of the therapy.

RICHARD T. FARRIOR, MD (Tampa, Florida): I want to compliment Dr. Dedo particularly for the contribution of the 120° angle. I had the privilege of discussing Mercer Lynch's last paper in New Orleans on this subject. He was using the South American literature using a polyethylene tube or proposing a keel to be used to prevent the second operation for the posterior web, and with that proceeded to use first folded Tanalium® and then the polyethylene tube. What I'd like to suggest to Dr. Dedo is that perhaps a wider keel in it's posterior dimension where you can pass a longitudinal wire, instead of your two separate wires from each end which I could visualize creating some rocking. This is what we do and with polyethylene you can pass a needle through the thicker portion of the keel.

I'd like to also encourage the principle we use in maxillofacial surgery in which you can pass a large caliber needle through the cricothyroid membrane and pass your wire through this, eliminating the need to break your needle via a needle. By passing the wires through the large caliber needle you can just withdraw the large calibration going around the mandible or whatever, and with that you can use a single wire, see that you pull the long wire through your original inferior incision so you have a wire going superiorly, put it through your keel and then put it through the second wire to pull it out through the cricothyroid membrane. We've used this for many years.

WILLARD FEE, MD (Stanford, California): I'd like to compliment Herb on his paper. I have 13 patients that we've used on endoscopic keel no longer than 1 cm, using reinforced Silastic® and woven nylon suture rather than wire. I don't think it's necessary to place these stents any longer than 1 cm. At least in the 13 cases none of the patients have had recurrence of the web. It obviates the 120° angle problem that Herb has talked about, and secondly, I place the woven nylon subcutaneously and tied over knots so that I eliminate the button problem. It prevents such things as wires breaking in two or three weeks and sometimes the tube scars that result from placing a button and stitching it up to the skin. None of the patients have required tracheostomy and all the keels are removed in 2 to 3 weeks.

ALBERT H. ANDREWS, MD (Chicago, Illinois): I wish to compliment the authors of both papers. In regards to the first paper, I believe that during the next year we'll see an increased use of the bronchoscopic adapters for the carbon dioxide laser and I think a note of caution should be mentioned here. We have used this quite extensively for palliation of the endotracheal masses but it certainly is not indicated for the actual treatment of a sarcoma or even a carcinoma of the trachea. One must admire Dr. Dedo's ingenuity, ability and his attack on these problems. We have been interested in these webs and have found them to be amenable to the carbon dioxide laser. We have had several of these patients and have had excellent results. Some of them have had keel operations of different types and we've been able to open up the anterior commissure. The lazing should not be done when the size of the burned area is greater than the distance between the two cords because then the cords

themselves will be burned. To get around this we have made slotted blanks to confine the laser beam to just a thin line that can go up to the anterior commissure. It is interesting that Dr. Coerba of Sao Palos, Brazil in the presentation of his work yesterday at the international laser symposium, presented a number of cases of anterior webs. His attitude is somewhat different than mine. He likes to do them in several stages. Another advantage to this procedure is, you do the patient today, you send them home tomorrow and prolonged hospitalization is not required. Again my compliments to both speakers.

HERBERT H. DEDO, MD (San Francisco, California): I just would like to comment about the first paper that this certainly was an ingenious and extensive way to take of the tumor in the trachea, but I think that it would have been possible to have resected this and repaired it primarily with a segmental resection of trachea-larynx release and a mediastinal mobilization. We've done over 3 dozen of these now and although our earlier paper described the removing of stenosis of the trachea up to 3.5 or 4 cm vertical dimension of the trachea, we've now done a 6.5 cm and a 7 cm segmental resection of the trachea, releasing it above the hyoid bone. (All of you who have done laryngectomy know how much this releases the larynx and allows us to go inferiorly.) I think it would have been nice to have gone ahead and just done a primary resection of the trachea and a primary reconstruction and not to have done all the other surgical procedures.

JOHN M. FREDERICKSON, MD (closing): I want to thank Dr. Nahum for his comments. The tumor was originally removed by a gentleman who referred the case to us so that the diagnosis of pseudotumor was made after having sent the tissue after endoscopic removal to 10 pathologists including AFIP, and one gentleman suggested that perhaps this represented a low grade sarcoma. We then saw the case later and carried out the resection. On biopsy before that resection, a diagnosis of low grade leiomyosarcoma was made. With regards to

Dr. Dedo's comments, indeed we did consider a resection and laryngeal drop, but I feel that the general principle of preservation of tissue without compromising resection was a reasonable one in this case and Dr. Bryce has had much experience with the resection of trachea and laryngeal drop. He and I together operating on this case felt that it would be more reasonable, since so much of the trachea could be preserved and since the tumor was pedunculated, to carry out the sort of procedure that we did. But certainly, I think a resection and laryngeal drop would have been a reasonable thing to do as well.

HERBERT H. DEDO, MD (closing): Dr. Nahum's comments and other comments are appreciated. The presentation, of course, is condensed in the paper and Dr. Nahum's point is a key. I have used tracheotomy in children or, in infants, but in older children and adults, I have felt we could get along without the tracheotomy because the size of the airway is so much larger that the relative space taken up by the keel is small. I am of course not suggesting that using an endoscopic keel is innovative but this is simply an attempt to share with you my current feelings that having a 120° angle on the anterior edge of the keel is helpful in keeping it in the anterior commissure and getting a better result. I'm using two wires rather than one in the anterior commissure because I like to avoid any granulation tissue right there at the anterior commissure that would tend to cause more web reformation. Dr. Andrews as usual has come up with another innovative idea: the slotted blank to keep the laser beam very narrow where it's working between the anterior cords. In my hands, the carbon dioxide laser has been useful with a posterior commissure web and has been useful at the false cord level, but I have been disappointed and I'm going to need to have Dr. Andrews teach me how, with the carbon dioxide laser, I can cure anterior commissure webs at the vocal cord level because in my hands (and I know other people using the carbon dioxide laser) I made the observation that it's possible to create a 1 or 2 mm web there at the anterior commissure web.

FIFTH DANIEL C. BAKER, JR.

MEMORIAL LECTURE

RESIDENT EDUCATION: PAST, PRESENT AND TO WHERE

WALTER P. WORK, MD

GREEN VALLEY, ARIZONA

The specialties in medicine and surgery developed slowly during the later 19th century and the early decades of this century. The American boards were the focal points for sponsoring specialty societies through which these developments occurred. The resident review committees have also played an important role. Otolaryngology resident education has developed into a progressively structured educational experience so that presently otolaryngology resident education is a broad experience in head and neck oncology, plastic and reconstructive surgery, otology, laryngology, rhinology, allergy and immunology, bronchoesophagology, teaching and research. Resident education is not static. The year of 1978 can be noted as the year of change, for the Resident Review Committee in Otolaryngology recommended that resident education be of five years in duration, one year being in surgery, three years in otolaryngology and one year being elective as to content. Such programming can be highly structured to meet a candidate's present and future needs in manpower, superspecialization and general otolaryngology. In this system superspecialization can and will be recognized and awarded through channels already established in otolaryngology. Manpower and general otolaryngology will also profit.

In 1968, Dr. Dean M. Lierle¹ stated, "During the last three years, as Educational Director of the Society of University Otolaryngologists, I have visited about 90 residency training centers in the United States. Dr. Lawrence R. Boies, Dr. Daniel Baker and Dr. George Sisson have accompanied me on many of these visits . . ."

Even though this quotation was delivered 11 years ago, it points out one of Dr. Baker's early activities. Thus, because of Dr. Baker's sincere interest and the timeliness of this subject, it appeared that a discussion of resident education might be of interest and at the same time pay tribute to the man we honor.

The data and discussion presented here represent my own thoughts, interpretations and conclusions, and do not in any way represent universities, specialty societies, government agencies, corporations, or groups of "policy planners" with whom I may have been or am now associated.

PAST

In 1924, five otolaryngologic societies² joined and pooled their resources in the

common cause of quality patient care. In November of that year, a meeting was held in Chicago which was attended by two representatives from each of the following societies: Section of Laryngology, Rhinology and Otology of the American Medical Association, J. C. Beck and R. C. Lynch; American Academy of Ophthalmology and Otolaryngology, W. P. Wherry and T. E. Carmody; American Otological Society, H. W. Loeb and T. H. Halsted; American Laryngological Association, H. P. Mosher and R. H. Skillern; and American Laryngological, Rhinological and Otological Society, B. R. Shurly and F. R. Spencer. Dr. George Shambaugh, Sr., chaired this meeting. The framework of the American Board of Otolaryngology (ABO) was finalized. The Board received its certificate of incorporation from the state of Missouri, January 6, 1925.

During the next three decades the ABO was the focal point through which the five sponsoring societies shaped the future development of this specialty. In addition to its primary duties of evaluation and certification of candidates who

From the Section of Otolaryngology, Department of Surgery, University of Arizona Medical School, Tucson, Arizona.

applied voluntarily, the ABO accredited the existing and the newly formed residency education programs. The American Medical Association and the American College of Surgeons became interested in accreditation so that in 1952 the Resident Review Committee in Otolaryngology (Tripartite Committee: American Medical Association, American College of Surgeons, ABO) became a reality. This committee has served otolaryngology extremely well over the years.

In the 19th and early 20th centuries ophthalmology and otolaryngology were often practiced by the same individual. Derick T. Vail, MD, who was Guest of Honor for Ophthalmology at the 74th annual session of the American Academy of Ophthalmology and Otolaryngology in Chicago, October 12-16, 1969, gave a graphic description of the era and the vicissitudes of practice, and the difficulties in dual resident education.³ Historically it was not until the third, fourth and fifth decades that the two specialties programmed resident education separately. Since medical and surgical specialties were slowly changing, it was quite natural that the development of resident education programs in the United States evolved slowly also. Otolaryngology was no exception. Individuals were practicing otolaryngology in spite of the scarcity of resident education programs. These persons were largely trained by the preceptorship method here and in Europe. The newly formed Board recognized many by certifying them as specialists through the so-called "Formal Method" by issuing a certificate without examination and by "passing them on their record."

Hospital based programs in resident education in otolaryngology occurred mostly in universities and were sporadic in their development. The internship year was looked upon with favor as a training experience for young candidates particularly if there were sufficient otolaryngologic patients and a trained staff. The specialty societies soon joined in support of structured resident education which included basic science courses and research endeavors. The general internship developed and replaced the internship as a specialty year.

In the 1940s a candidate who desired training in otolaryngology had to be a graduate of an approved medical school and have served a general internship in an approved program. He was then required to complete a basic science course and serve two years of resident education in otolaryngology. Even at this time the number of years an individual practiced the specialty helped to qualify him/her for eligibility for certification either with or without examination. Credit was also allowed some for experience in the Medical Corps of the Armed Services provided the experience was in otolaryngology and of high quality. Three years of training could still qualify some to be candidates for certification in both ophthalmology and otolaryngology.

The 1950s were difficult years for otolaryngology; the specialty was in a struggle for survival as a result of the use of antibiotics and chemotherapeutic agents and its character had changed. This set of circumstances had a deleterious effect on the specialty as a whole and on the number of applicants for residency.

A three-year requirement for resident education in otolaryngology was introduced in the early 1950s. Four years were required for ophthalmologic-otolaryngologic training. In this latter instance, if the candidate had served *the* year of general internship and one year of internal medicine or one year of surgery or a second year of general internship, only three years of ophthalmology and otolaryngology were required. All resident training years were followed by one year of practice before final specialty certification could be pursued.

These requirements held throughout the 1950s. The establishment of the previously described Resident Review Committee in Otolaryngology did much to validate and help guide the course of resident education in these and in subsequent years.

PRESENT

Present education requirements in otolaryngology date from 1959 forward. In 1960 resident education in otolaryngology required that a candidate be a graduate of an approved medical school and that one year of general internship be served; in addition, one year of gen-

eral surgery as well as three years of otolaryngology was required. All years had to be served in approved programs either in the United States or Canada. Structured basic science and research programs were included along with the regular resident education. In 1969 the preceptorship method of training was discontinued. Two years of general surgical training were considered as a requisite, but by 1973 this was completely abandoned because of lack of support by surgeons and otolaryngologists alike. Other important changes have been discontinuation of the internship and the approval for resident education of osteopathic physicians who meet standards required of doctors of medicine.

The present resident education requirements have been in effect for 18 years with the various modifications mentioned. Programs have been strengthened and broadened to include training in head and neck oncology, otology, allergy, rhinology, laryngology, plastic and reconstructive surgery and bronchoesophagology.

Basic science and research programs have been markedly strengthened. U.S. Department of Health, Education and Welfare grants have benefited all medical and surgical specialties by fiscal support during these years, and otolaryngology has benefited appreciably. Directors in otolaryngology have participated in all these worthwhile efforts. The specialty societies have been vitally interested and have given their full support. It is apparent that resident education programs cannot include all areas of teaching in a given specialty. To date, the medical and surgical specialties have recognized this and have allowed for such differences through their accreditation processes by the resident review committees. In all specialties resident education is more comprehensive today than it has been in previous years. This is as it should be and leads us to the discussion of the future.

TO WHERE

The year of 1978 can be considered a year of change in otolaryngology for it was in March that the Resident Review Committee suggested that an extra year of training be added to resident educa-

tion. The impact of this extra year, since it is of extreme flexibility, can be far reaching to influence further specialization within our ranks. Superspecialization, some say, leads to fragmentation and is self-defeating; others say that superspecialization leads to better and higher quality of patient care. It is believed that this extra year of resident education will allow the trainee, program director and administrator to plan resident education according to an individual's needs. Also, resident education can be so structured during the five years that it will allow otolaryngologists to meet needs in patient care, teaching and research. This will tend to do away with a fellowship pathway leading to superspecialization as now structured in obstetrics and gynecology, internal medicine, pediatrics, and other specialties. Up to now the programs in the fellowship years are not accredited along conventional resident review committee channels. This dichotomy will probably soon be remedied through corrective efforts of the primary specialty boards. A very distinct advantage will accrue for otolaryngology's plan since all years of resident education will have only one accrediting body, namely, the Resident Review Committee in Otolaryngology. This accrediting process for programs will lead to highly qualified specialists whose numbers can be monitored on an ongoing basis. Up to now superspecialization has been unstructured. The recognition and award (certificate of competency) will now follow established channels.

On the other hand, surgery and pediatrics have cooperated to produce the pediatric surgeon through regular resident programs which are accredited by the Resident Review in Surgery. The pediatric surgeon is then awarded a certificate of designation by the American Board of Surgery. Such certificates are widely recognized throughout the United States and the world. In a like manner, in the future, resident education in otolaryngology will meet its needs in head and neck oncology, allergy, otology, plastic and reconstructive surgery, rhinology, laryngology and bronchoesophagology under established accrediting and award mechanisms. We are in an environment where organized

medicine must continue to accept high quality patient care. Alford⁴ and Schuknecht⁵ have recently written editorials which bear on these problems, and it is suggested that they be read by every otolaryngologist who desires to preserve and enhance our diversified specialty. In the first year programs the numbers of superspecialists will become balanced as to public needs, teaching and research. General otolaryngologists will be trained to meet general otolaryngology needs also. If such are otolaryngology's goals and objectives, and I believe they are, then pursuit and accomplishment are paramount.

I have not dealt with details of resident education's future in otolaryngology since there has been great individuality of expression in each program. Directors are in an important position to preserve these features and at the same time meet expectations of the resident program, the institution and community. Specifically, also, more attention must be given to the development and education of future program directors themselves, accomplished through workshops, conferences, lectures, demonstrations, classes and simulation techniques. As a former chairman responsible for resident education, I wished on many occasions that I had had more formal background in the fields of basic finance, ambassadorship, group and university organization, telecommunication, grants and donations, and administration in general.

Resident education as a whole is being studied from the standpoint of institutional responsibility in many parts of the country. If this is realized there will be more administrative control of budget, physical space, research and teaching, and patient care placed upon the respective specialties. Already the medical and surgical specialties are functioning in a hierarchy represented chiefly by the American Board of Medical Specialties. Otolaryngology's future then lies not only within its own ranks but within the province of the institutional (medical school and hospital) community, organized medicine, and state and federal governments. Otolaryngology is well represented through its specialty societies, councils, resident review committees and American Board to voice its objectives and goals. A warning is

sounded to the effect that the promulgation of too many rules and regulations by possessive administration can and will destroy spontaneity, ambitions, creativity, enthusiasm and motivation within the individual director and trainee. Mediocrity must be avoided.

The costs of resident education in otolaryngology will increase with the introduction of the required fifth year. Even though four years are now obligatory (one year surgery and three years otolaryngology), my own estimate is that slightly over 50% of the programs now in the United States have five or six years. Hence no fiscal changes would be noted in these programs. Administrators would be concerned with changing four-year to five-year programs. When the clear-cut benefits to the trainee, hospital, medical school and to other community specialists are noted, the longer program in otolaryngology resident education would no doubt meet with approval by all. This is predicted to happen in spite of the fact that most hospital and universities are budget-conscious to a high degree and curtailments rather than increased expenditures are mottos of respectability and practicality. The important question is whether increased revenues from supervised medical and surgical resident patient services would offset the cost of resident education. In active programs it is believed they would.

It is emphasized again that an extra year of resident education in otolaryngology can be a tremendous stimulus to the future development of this specialty since flexibility will be the key for the resident in the planning and realization of his future needs. The flexibility allowed in a five-year program will tend to eliminate training redundant to the trainees' future practice. In other words, programs of the future will be geared to earlier career selection, and will allow directors to develop those which will meet needs of all residents within a given program.

Many configurations of resident education will be possible for the potential primary, secondary and tertiary physician specialist. For example, a year of allergy resident education in an established allergy program could appeal to

some candidates while others may opt for a research year, or an extra year of surgery, pediatrics, etc. In other instances, the year could be served in otology, head and neck oncology, facial plastic and reconstructive surgery, laryngology, rhinology or bronchoesophagology. Resident education programs of the future will be structured to conserve resources.

In conclusion, otolaryngology is in the early dawn of exciting times preparing for the future in resident education. Program directors and specialty and society leaders working in cooperation with organized medicine, and backed by the community are in a position to speak out and become leaders for our younger men and women in the future.

REFERENCES

1. Lierle DM: Undergraduate and graduate education in otolaryngology. *Ann Otol Rhinol Laryngol* 77:1001-1004, 1968
2. Minutes of meeting of delegates to form American Board of Otolaryngology. Chicago, University Club, November 10, 1924
3. Vail DT: The rise and fall of EENT.

Trans Am Acad Ophthalmol Otolaryngol 74: 11-17, 1970

4. Alford BR: Editorial comment. *Arch Otolaryngol* 104:725, 1978

5. Schuknecht HF: Training in otolaryngology, editorial. *Arch Otolaryngol* 105:57, 1979

REPRINTS — Walter P. Work, MD, Section of Otolaryngology, Dept. of Surgery, University of Arizona Medical School, Tucson, AZ 85724.

BENIGN TUMORS AND LESIONS OF THE LARYNX IN CHILDREN

SURGICAL EXCISION BY CO₂ LASER

GEORGE T. SIMPSON, MD

GERALD B. HEALY, MD

TREVOR MCGILL, MD

M. STUART STRONG, MD

BOSTON, MASSACHUSETTS

Benign lesions of the airway in infants and children may endanger the airway and compromise laryngeal function. The CO₂ laser provides an elegant method of transoral surgical excision without compromising laryngeal function or airway competence. It avoids the risks of such other treatment modalities as external surgical approaches, prolonged steroid therapy, and radiation. It is applicable to a wide variety of lesions without the necessity of tracheotomy. Hospitalization is minimized. Ten cases are presented to show the wide applicability of this technique. Gross pathology and pre- and postoperative findings are demonstrated and discussed, as is the safety and efficacy of the laser soft-tissue interaction.

The cardinal principles of pediatric airway management include thorough assessment, accurate diagnosis, and appropriate selection of a therapeutic modality. The appropriate treatment must incorporate the principles of safety and efficacy. A therapeutic method, though dramatically effective, may be unacceptable if the hazards and complications are significant.

Any new form of treatment must meet the challenge of these principles. The carbon dioxide laser, in animal studies^{1,2} and extensive clinical use,^{3,4} has shown itself to be a unique surgical tool with clinical application in the management of benign and malignant lesions of the upper aerodigestive tract. Over 130 cases of laryngeal airway lesions have been treated with the laser at Children's Hospital Medical Center, Boston. We have selected ten cases of benign neoplasms or acquired pathology to illustrate the value of the CO₂ laser in the surgical management of a variety of pediatric airway problems. These cases illustrate the ease, safety, efficacy and applicability of microendoscopy and microsurgery in pediatric patients of all ages including neonates.

METHODS AND MATERIALS

Patients with benign soft tissue lesions of the larynx which had been identified by en-

doscopy and biopsy were selected for treatment (Table 1). Ages ranged from six weeks to 12 years. Carbon dioxide laser surgery was performed with the American Optical A-100 50 W surgical laser coupled to a Zeiss binocular operating microscope. Laser energy used varied between 10 and 25 W as selected by the surgeon.

All surgery was performed under general inhalation anesthesia delivered by small endotracheal tube wrapped with aluminum tape for protection, metal tracheotomy tube, or, if necessary for intralaryngeal or subglottic visualization, Venturi injection ventilation through the laryngoscope. Muscle relaxants were used as necessary for Venturi ventilation and to prevent laryngeal movement during laser applications.

No visible postoperative edema has been noted from laser interaction with soft tissue alone.^{3,5} However, to minimize postoperative laryngeal edema from laryngeal manipulation with probes, suction tips, endotracheal tubes and laryngoscope tips, all patients received dexamethasone 1 to 2 mg/kg to a maximum dose of 12 mg.

A Jako-Pilling wide-bore laryngoscope with the Lewy holder supported on a Mayo stand, provided good visualization of the larynx. Operating room personnel wore glasses or plastic goggles to protect against laser beam reflection.

The patient's eyes were protected with saline moistened cotton sponges secured with adhesive tape. Precautions were taken to prevent movement of the patient and table while the laser was in use. As needed, saline moistened neurosurgical cottonoids were placed within the trachea to protect it from laser energy. The cottonoids were frequently moistened to prevent ignition by laser energy.

From the Department of Otolaryngology, Children's Hospital Medical Center, Harvard Medical School, and Boston University School of Medicine, Boston, Massachusetts.

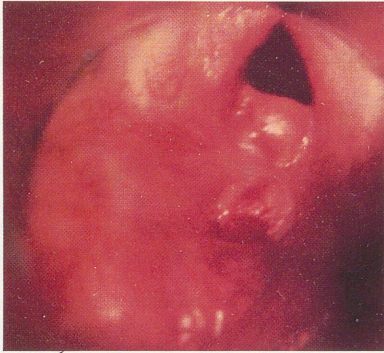


Fig. 1. (Case 9) Glottic web and granulomas, postintubation preoperative.

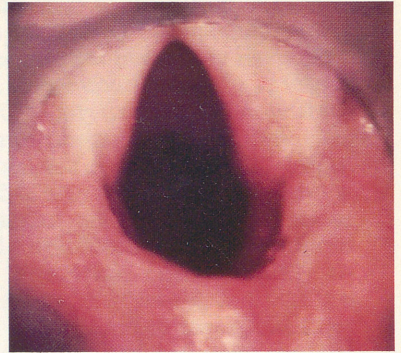


Fig. 2. (Case 9) Glottic web and granuloma three weeks postlaser excision.

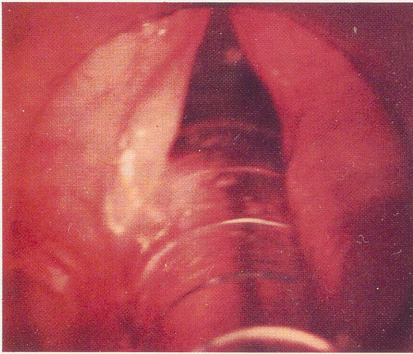


Fig. 3. (Case 1) Neurofibroma of right larynx and neck preoperative. Note mass over right true vocal cord.

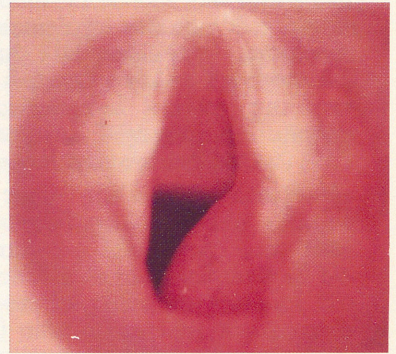


Fig. 4. (Case 3) Subglottic hemangioma preoperative.

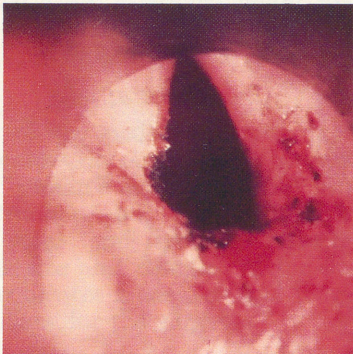


Fig. 5. (Case 3) Appearance of larynx immediately after excision of subglottic hemangioma by CO₂ laser.

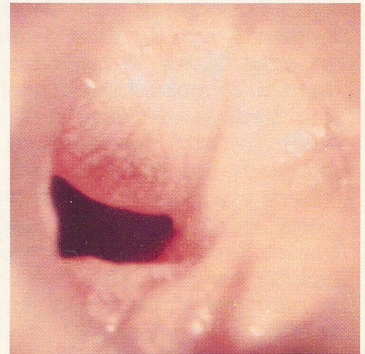

Fig. 7. (Case 6) Anterior subglottic cyst.

TABLE 1. SOFT TISSUE LESIONS OF LARYNX SELECTED FOR TREATMENT

Case No.	Lesion
1	Neurofibroma
2	Lymphangioma
3	Hemangioma (subglottic)
4	Chondroma (subglottic)
5	Polypoid fibroma (subglottic, congenital)
6	Mucosal cyst (subglottic)
7	Supraglottic lymphedema (congenital)
8	Subglottic stenosis and granuloma (traumatic dog bite)
9	Postintubation glottic web and granulomas
10	Subglottic stenosis (congenital) with ? hemangioma and granuloma

RESULTS

Cases are summarized in Table 2. Patients tolerated the procedure well. There were no intraoperative anesthetic or surgical complications. No stents were used. In general, patients were discharged on the morning of the first postoperative day. No patient required postoperative intubation or tracheotomy. Four patients had preoperative tracheotomies for airway obstruction. Of these, one was decannulated within one week of surgery, another within two weeks. The other two patients retain plugged tracheotomy tubes as a precaution while undergoing further staged treatment, but vocalize satisfactorily. Discrete intrinsic laryngeal lesions required only one or two laser excisions, while extrinsic or systemic conditions necessitated multiple procedures.

DISCUSSION

Lesions of the pediatric larynx present a therapeutic challenge. Not only may they produce life-threatening airway obstruction, but also frequently produce voice and feeding disturbances. The size and delicacy of the infant larynx creates immediate and long-term problems for the surgeon.

Surgical treatment of laryngeal lesions may require tracheotomy, multiple procedures, and general anesthetics, with prolonged hospitalizations. Severe acquired subglottic stenoses and granulomas such as cases 8, 9, 10 (Figs. 1 and 2), are especially troublesome in this regard. Stenosis tends to recur and does

not respond well to dilatation. External surgical approaches, tracheotomies and stenting techniques frequently have been necessary. Other conditions of the intrinsic or extrinsic larynx such as neurofibromata, lymphangiomas, hemangiomas, and lymphedema (cases 1, 2, 3, 7) (Figs. 3, 4, and 5), may persist or recur necessitating similar surgical approaches or prolonged tracheotomy and steroid therapy. Subglottic chondromas, fibromas, and cysts (cases 4, 5, 6) (Figs. 6 and 7), do not tend to recur, but their location, also, has dictated open surgical management.

Residual functional laryngeal problems may follow surgery, trauma, inflammatory reaction and laryngeal nerve injury. Wound infections and sepsis can occur. Hemorrhage can complicate other surgical and respiratory problems. Cosmetic deformity varies. Psychosocial, communication and learning problems may accompany laryngeal dysfunction and prolonged tracheal intubation.

While these are readily acceptable hazards in malignancy where ablative surgery may be life-saving, such risks are less tenable in the treatment of benign lesions. In pediatric patients, the safest and most efficacious treatment is sought by the responsible surgeon.

Endoscopic laser surgery provides an attractive alternative surgical technique. Each of our ten selected cases had laryngeal lesions of the type or degree which previously could have been managed effectively only by external surgical approaches with all the attendant problems and risks, or would have required prolonged tracheotomies or stenting. While four patients required preoperative tracheotomy, two of these were soon decannulated and the other two patients have precautionary tracheotomies while undergoing staged treatment or observation. The laser excised each lesion effectively, whether cartilaginous, fibrous, neoplastic, edematous, or angiodysplastic. Satisfactory airways were established without residual functional disturbances. No prolonged steroids or radiation were necessary. Case 1 (neurofibroma) and case 2 (lymphangioma) will require more extensive surgery of their extrinsic laryngeal lesions, but the laser has been effective in maintaining an intrinsic airway.

TABLE 2. SUMMARY OF CLINICAL DATA AND SURGICAL PROCEDURES.

Case No.	Lesion	Sites Other Than Larynx	Tracheotomy		Decannulate	No. of Procedures		Age†
			Preop	Postop		Laser	Endo. Total**	
1	Neurofibroma	Skull base Pharynx Mediastinum	No	No	N/A	5	(7)	10 yr
2	Lymphangioma	Bilateral neck	Yes	Yes	No Plugged*	3	(7)	4 wk-2 yr
3	Hemangioma (subglottic)	O	No	No	N/A	1	(1)	6 wk
4	Chondroma (congenital subglottic)	O	Yes	Yes	No Plugged*	1	(3)	3-6 wk
5	Polypoid fibroma (congenital subglottic)	O	Yes	Yes	Yes, 1 wk Postop	3	(5)	2 yr
6	Mucosal cyst (subglottic)	O	No	No	N/A	1	(1)	8 wk
7	Lymphedema (congenital systemic)	Entire body	No	No	N/A	2	(3)	12 yr
8	Subglottic stenosis + granuloma posttrauma (dog bite)	O	Yes	Yes	Yes, 2 wk Postop	1	(2)	8 yr
9	Glottic web + granulomas (postintubat.)	O	No	No	N/A	1	(2)	2 yr
10	Subglottic stenosis (congenital) granuloma ? hemangioma	O	No	No	N/A	2	(2)	16 mo

*Not decannulated, tracheotomy tube is electively plugged.

**Total number of endoscopic procedures performed including laser excisions.

†Age at treatment. Case 2, laser treatments were performed over age range indicated. Case 4, initial evaluation at three weeks of age; laser treatment performed at six weeks of age.

The special applicability of the CO₂ laser to pediatric laryngeal lesions, as well as its efficacy and safety, are a direct result of the unique characteristics of laser energy. The interaction of this energy with biological tissue is specific.

A delivery system is available which allows the laser to be applied to living tissue in precise increments. Laser energy has the specific characteristics of temporal and spatial coherence^{2,6} (Fig. 8). Temporal coherence means that the energy delivered is at a specific wavelength. It is monochromatic. This determines the characteristic type of energy (ie, infrared heat, or visible light, etc) delivered. Spatial coherence describes

the narrow bundle of propagated radiation, in parallel beams, which allows all the energy to be delivered in a small area. The spatial coherence is most important for surgical applications as this coherence allows the high energy of the laser beam to be applied to the focal point of a lens and in turn, be directed to a small specific point of tissue without significant scattering of the energy (Fig. 9).

The carbon dioxide laser at a wavelength of 10.6 μ in the infrared spectrum, provides purely heat energy which is almost completely absorbed by all biological tissues. Most living tissue is composed predominantly of water. If

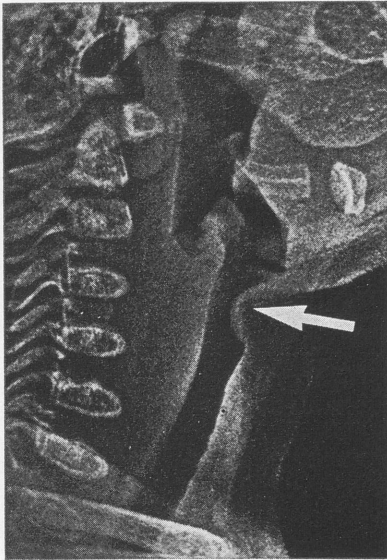


Fig. 6. (Case 6) Xeroradiogram of anterior subglottic cyst (arrow).

2.5 joules of energy are applied with a beam power of 25 W for 0.1 second, 1 cu mm of water (or soft tissue) at 37 C will be vaporized as steam at 100 C.² Water has an extinction coefficient or length of 0.3 mm for a wavelength of 10.6μ .² This means that at the wavelength of the CO₂ laser, 90% of the heat energy delivered should be absorbed within 0.3 mm thickness from the delivery site. The shorter the extinction coefficient the more sharply localized the area of tissue destruction, and the less the surrounding tissue is effected. Heat is conducted away to surrounding tissue, however, and if energy is continually supplied to the same area, heat conduction to the surrounding tissue increases with resultant tissue coagulation.

Thermal processes induced by CO₂ laser irradiation produce tissue destruction in two ways: the physiomechanical factor from the expansion effects of rapid water vaporization; and the physiochemical factor with thermal denaturation of tissue proteins.⁷ The first factor

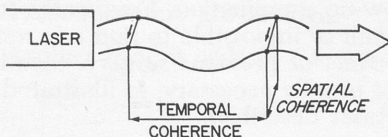


Fig. 8. Temporal and spatial coherence of laser radiation.

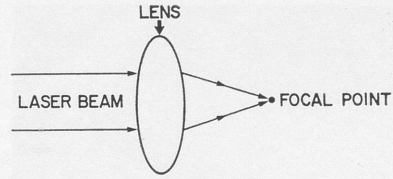


Fig. 9. Spatial coherence allows laser beam to be optically focused for maximum concentration of laser energy.

is the primary one in tissue ablation. The second factor is present in surrounding tissue damage.

In brief applications (less than one second), tissue destruction and damage decreases rapidly to zero within 1-2 mm of the wound edge (Figs. 10 and 11). This is because the thermal gradient in the tissue rapidly falls with distance (700 μ m from the wound edge the maximum temperature rise is 9 C, and 2 mm from the edge the temperature rise is 5 C, etc). No detectable histologic changes can be seen beyond 500 to 600 μ m from the wound edge.⁸ By delivering higher energy to the same tissue volume in a shorter time period, a similar volume of tissue can be destroyed with less heat conduction to surrounding tissue. In this way, destruction of contiguous tissue can be limited to a layer five to ten cells thick.^{3,7,8}

Instantaneous hemostasis is a fortuitous result of the thin layer of coagulation necrosis around the vaporization cavity.⁹ The physiochemical factor of laser soft tissue interaction produces protein denaturation within a few cell layers. This effect seals small vessel wall defects and instantaneously coagulates

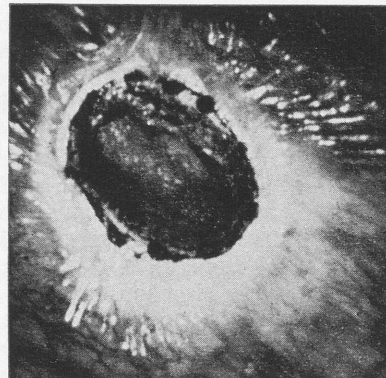


Fig. 10. CO₂ laser beam vaporizing mucosal tissue. Ulcer diameter - 1 mm.

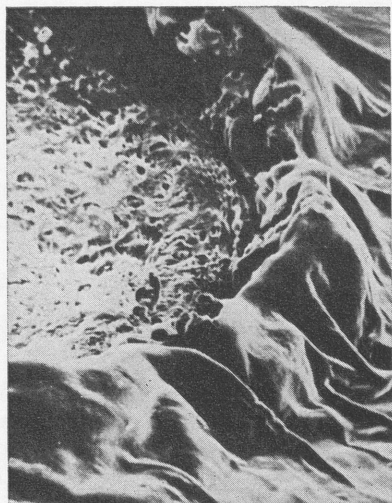

Fig. 11. Scanning electromicrograph of CO₂ laser ulcer in mucosa. (Reproduced by permission of New York Academy of Sciences.⁷)

blood. Bleeding vessels of 0.2 to 0.5 mm diameter can be immediately cauterized.^{2,9} Microsurgery with the laser provides a bloodless field with excellent vision and enhances assessment of remaining tissue for preservation of normal anatomy (Fig. 3). This is especially helpful with capillary hemangiomas and recurrent papillomas. Cavernous hemangiomas however, ooze blood too rapidly from the large vascular spaces, and are not treated effectively with the laser.

The limitation of coagulation necrosis to a thin layer of cells, in turn protects surrounding tissue. There is no edema as vascular permeability is not increased, and capillary flow and cell processes continue unaffected.³

This is in sharp contrast to wounds produced by electrocautery¹⁰ and cryosurgery.¹¹ Electrocautery, whether direct current, alternating current or radio-frequency powered is associated with high voltage, deep penetration, an unpredictable level of penetration and a predilection for electrical flow along vessels and nerves. Bipolar cauterization does not completely solve these problems. Cryosurgery has been noted by all who use it, including ourselves, to produce lesions of unpredictable depth. This is not crucial within the oral cavity and many other anatomic sites, but within the delicate anatomy of the pediatric

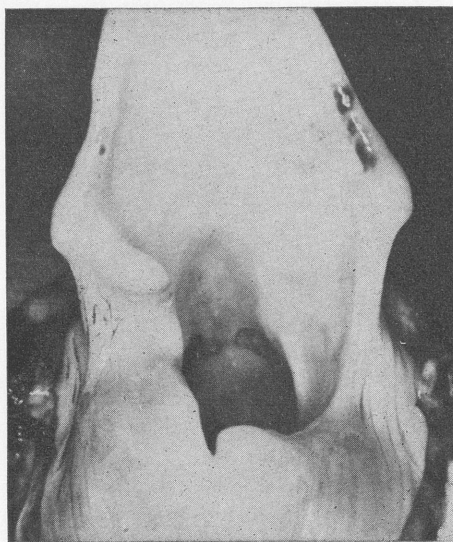


Fig. 12. Canine larynx postlaser excision of right false and true cord showing excellent healing. (Courtesy of Charles W. Vaughn, MD, Department of Otolaryngology, Boston University School of Medicine.)

larynx, cryosurgery can produce unpredictable and unacceptable amounts of tissue and cartilage injury and necrosis with resultant scarring and dysfunction. The laser has shown itself superior to both techniques within the larynx. Lack of edema precludes the necessity of tracheotomy for airway preservation, in most instances.

Laser wounds, in all tissue except skin, where healing may be retarded,¹² have been noted to heal rapidly.¹⁻³ Epithelial migration into the wound cavity is rapid, so that epithelialization is prompt and complete within three weeks.^{3,7} Scar contracture is minimal.^{3,4,7} Excellent healing is probably a result of the minimal injury to surrounding tissues (Fig. 12). Preservation of normal tissue and structural anatomy, when combined with rapid complete healing, have meant that many of our patients have normal appearing and functioning larynges and airways on follow-up examination. Frequently, it is difficult or impossible to find any residual effect of previous surgery. Stenting is not usually necessary, as illustrated in the cases described.

A major factor in the precision and safety of laser surgery in the larynx is

the delivery system. The coupling of the laser to the binocular operating microscope has been described elsewhere in detail, as have the techniques of its use.^{1-5,13} We would emphasize, however, that the micromanipulator with its sensitive "joystick" control, aiming guidelight, choice of burst or continuous firing, and visual magnification to 16x or 25x, allows extraordinarily precise control. For this reason, the surgeon rapidly becomes habituated to the use of the laser in preference to many other microsurgical techniques for laryngeal surgery. Any visible lesion except those containing large vascular spaces, ie, cavernous hemangioma, can be extirpated as desired.

As our experience with the laser has increased, we have been impressed, also, with the exceptional applicability of microendoscopy and microsurgical techniques in managing pediatric airway problems. The superb visibility provided not only assists in the application of more precise surgical techniques, but more importantly, allows more definitive determinations of pathological states thereby improving diagnosis and therapeutic planning. Microendoscopy and microsurgery using suspension laryngoscopes have been well tolerated by pediatric patients of all ages including neonates.

The safety of microscopic laser surgery in pediatric patients is best illustrated by its complete lack of complications in our institution. No patient has experienced a significant complication or required surgical intervention such as tracheotomy or intubation following laser excision. Some patients had required tracheotomy or intubation for airway management preoperatively. Preoperative tracheotomies were not routinely discontinued after surgery, but even these were frequently unnecessary. Patient risk from repeated and prolonged general anesthesia is minimized. In addition, the hazards of radiation,¹⁴⁻¹⁶ prolonged steroid therapy,¹⁷ cryosurgery, and electrocautery are avoided.

Another benefit of laser microsurgery

is its cost effectiveness. Hospitalization is minimized. Frequently, pediatric patients undergoing laser excisions are only in the hospital for 24 to 36 hours. Seventy-two hours is the usual maximum hospitalization except for social reasons which may necessitate longer periods for patient protection, or in cases requiring more extensive evaluation or management of unrelated anomalies or illnesses. The decreased requirements for tracheotomy also assist in shortened hospitalizations as well as improved rehabilitation. Shortened and less frequent hospitalizations lessen exposure to nosocomial infections. Microsurgery eliminates the risk of wound infections associated occasionally with external surgical approaches. All these features promote maximum cost effectiveness by minimizing complications and hospitalizations.

Microsurgery and the CO₂ laser have established their efficacy and safety in the management of benign lesions of the pediatric larynx and airway.

SUMMARY

The carbon dioxide laser coupled with microlaryngoscopy provides an exceptionally safe and efficacious technique for the treatment of benign laryngeal tumors and lesions in pediatric patients of all ages including neonates.

The specific advantages of CO₂ laser surgery in children include:

- 1) precise control; 2) protection of surrounding structures with preservation of anatomy and function; 3) airway preservation without tracheotomy; 4) hemostasis; 5) rapid excellent healing without stricture formation or functional disturbance; 6) possibility of repeated surgery without trauma, cosmetic defect or danger of wound infection; 7) lessened anesthesia risk; 8) possibility of cost effectiveness superior to other methods; and 9) avoidance of potential hazards of radiation and steroids.

The carbon dioxide laser offers a superior method of managing many benign tumors and lesions of the pediatric larynx.

REFERENCES

1. Jako GJ: Laser surgery of the vocal cords. *Laryngoscope* 82:2204-2216, 1972
2. Stellar S, Polanyi TG, Bredemeier HC: Lasers in surgery, in Wolbarsht ML (ed):

Laser Applications in Medicine and Biology, vol 2. New York, Plenum Publishing Corp, 1973, pp 241-293

3. Strong MS, Jako GJ: Laser surgery in the larynx: Early clinical experience with continuous CO₂ laser. *Ann Otol Rhinol Laryngol* 81:791-800, 1972

4. Strong MS, Jako GJ, Polanyi T, et al: Laser surgery in the aerodigestive tract. *Am J Surg* 126:529-533, 1974

5. Strong MS, Vaughan CW, Healy GB, et al: Recurrent respiratory papillomatosis: Management with the CO₂ laser. *Ann Otol Rhinol Laryngol* 85:508-517, 1976

6. Goldman L, Rockwell RJ: *Lasers in Medicine*. New York, Gordon and Breach Science Publishers Inc, 1971, pp 90-92

7. Mihashi S, Jako GJ, Incze J, et al: Laser surgery in otolaryngology: Interaction of CO₂ laser and soft tissue. *Ann N Y Acad Sci* 268:263-294, 1976

8. Ver Schueren RCJ, Koudstaal J, Oldhoff J: The carbon dioxide laser; some possibilities in surgery. *Acta Chir Belg* 74:197-204, 1975

9. Polanyi TG, Bredemeier HC, Davis

TW: A CO₂ laser for surgical research. *Med Biol Eng* 8:541-548, 1970

10. Greenwood J: Electrocoagulation in neurosurgery. *Surg Neurol* 2:4, 1974

11. Hong SW, Silverstein H, Sadegh S: The effect of cryosurgery on the canine and human larynx. *Laryngoscope* 87:1079-1085, 1977

12. Hall RR: The healing of tissues incised by a carbon dioxide laser. *Br J Surg* 58:222-225, 1971

13. Andrews AH, Moss HW: Experiences with the carbon dioxide laser in the larynx. *Ann Otol Rhinol Laryngol* 83:462-471, 1974

14. Wilson GM: Thyroid neoplasms following irradiation. *Br Med J* 2:929-934, 1958

15. Winship T: Carcinoma of the thyroid in children. *J Am Goiter Assoc* 3:64, 1951

16. Wilson EH, Asper SP: The role of x-ray therapy to the neck region in the production of thyroid cancer in young people: A report of 37 cases. *Arch Intern Med* 105:244, 1960

17. Schecter G, Biller H: The limitations of cortico-steroids and cryotherapy for subglottic hemangioma. *Trans Am Acad Ophthalmol Otolaryngol* 76:1360-1362, 1972

ACKNOWLEDGMENT — Publication of the color illustrations was made possible by the Pilling Company, Fort Washington, Pennsylvania.

REPRINTS — George T. Simpson, MD, Department of Otolaryngology, Boston University School of Medicine, 720 Harrison Ave., Boston, MA 02118.

DISCUSSION

GEORGE LYONS, MD (New Orleans, Louisiana): I enjoyed Drs. Simpson's and Strong's paper very much and do appreciate the opportunity to discuss their work. Laser surgery in our hands has been somewhat straightforward on destruction of specific lesions and corresponds closely to their work. In one area our experience has differed and that is in the management of laryngeal stenosis. It is here that I would like to present our experience.

Eight patients ranging from 3 to 67 years of age were treated for acquired laryngeal stenosis. Five of these patients were considered failures from conventional surgical techniques including multiple open endolaryngeal procedures and repeated dilatations. Using the CO₂ laser the various obstructing lesions were excised microendoscopically and injected with interstitial steroid. After one to six procedures all of these patients are now successfully managed with adequate airways and serviceable voices.

GERALD B. HEALY, MD (Boston, Massachusetts): First, I'd just like to make a slight correction in the presentation. The patient with the chondroma was actually a 3-week-old and not a 3-year-old child. Second, I am obviously a great advocate of this form of surgery but I think we should be realists and realize that it is not the be-all and end-all and I'm sure there are many people in this room who have years of experiences with other ways of managing these problems. I would just like to point

out that we feel this is another tool in the armamentarium of the laryngologist and if it can be put to use in specific cases then it should be. But I don't think we should throw out the lessons learned by our predecessors and I think we should just add this tool to the means that are available in treating some of these troublesome lesions.

ALBERT H. ANDREWS, MD (Chicago, Illinois): I wish to complement the presentors on their work. There are three questions that I have. In regard to that cyst I have two questions. First, how did he prevent the contents of the cyst from being aspirated and second, did he resect the cyst completely, or did he marsupialize the cyst? The third question has to do with the cartilage. After exposing cartilage was there further resorption of the cartilage and is there good regrowth of the mucosa over the cartilage?

BRIAN McCABE, MD (Iowa City, Iowa): I'd like to ask you a question about the endotracheal tube. It seems such an improvisation wrapping the tube with aluminum tape. It's a messy thing, it's time consuming. Does the essayist or the discussor or anyone indeed have a better method, a good tube. There must be a better way.

GEORGE T. SIMPSON, MD (closing): I'll answer the last question first. In answer to Dr. McCabe, the reason we use the aluminum tape wrapped tube is that we've not had a small enough size available to use in the earli-

est ages, ie, in the very smallest patients; it's been better to use a small tube that's wrapped in tape in our experience. There are metal flexible tubes which have been developed and are available. I want to thank Dr. Healy for his slight correction and his additional comments. I want to thank Dr. Lyons for his excellent report. I think that we are basically in agreement and I think that steroid injections are certainly an interesting topic which we can explore at much greater length in the future and may offer us help in some of our more difficult patients.

In answer to Dr. Andrews' question, the cyst contents were removed with suction. The cyst was basically excised in its entirety but in essence this is a marsupialization because the anterior wall of the cyst which remained after the rest was excised would technically qualify it as a marsupialization. In regards to the cartilage itself, the one removed with the chondroma, there appeared to be excellent growth of the mucosa over the area which was excised. We will have to follow the patient further to see if stenosis develops further down the line.

CLINICAL COURSE OF UNUSUAL MALIGNANT SARCOMAS OF HEAD AND NECK

MICHAEL SETZEN, MD

STEVEN SOBOL, MD

JAMES M. TOOMEY, MD, DMD

ST. LOUIS, MISSOURI

The clinical manifestations of 29 recently encountered sarcomas of the head and neck were analyzed in an attempt to define more accurately the diagnostic characteristics and therapeutic responses of these unusual tumors. The host factors of age, sex distribution, race, habits and associated features differ sufficiently to distinguish the sarcoma from the carcinoma population. In addition, the clinical course of sarcoma patients as monitored by mode of presentation, site of involvement, tumor histology, diagnostic features and certain elements of management and outcome, further indicates that these tumors can be defined and managed as a distinct group of lesions. A review of the recent literature supports the major conclusions of this study.

Nonepithelial malignancies of the head and neck are distinctly unusual and, in consequence, most clinicians have a somewhat unclear and incomplete concept of the mode of presentation and the biologic behavior of such lesions. As noted recently by Westbury, "Rare cancers tend to be misdiagnosed, badly treated and unreasonably feared. This is certainly true for the (soft tissue) sarcomas."¹

In an attempt to resolve some of the confusion we have reviewed our recent experience with a series of head and neck sarcomas. Emphasis has been placed upon an analysis of those clinical characteristics of such tumors which, while not pathognomonic, are of use in distinguishing sarcomas from the more common carcinomas of the region on the one hand, and from benign mesenchymal lesions on the other hand. Although it is recognized that such a study cannot provide absolute guidelines for diagnosis and therapy, it is felt that helpful insights can be provided.

METHODS AND MATERIALS

The hospital records of 29 consecutive patients admitted to the otolaryngology service with a diagnosis of sarcoma of the head and neck between January 1, 1973 and December 31, 1978 were reviewed. All relevant clinical data were analyzed and follow-up information was obtained from the tumor registry. The host factors examined were age, sex, race, habits, and associated features. The

clinical course of each patient was studied with particular emphasis on the mode of presentation, site of involvement, pathology, therapy and the status of the patient one year following definitive therapy.

RESULTS

HOST FACTORS

Age. The age range was from six months to 83 years with a mean age of 49 years (Table 1).

Sex. The sex distribution was 18 males and 11 females or a male to female ratio of 1.6:1.

Race. There were 26 Caucasian and three Negro patients.

Habits. Fifteen patients (52%) were moderate to heavy smokers and six patients (21%) were moderate drinkers.

Associated Features. One patient had received radiation therapy to the head and neck region as a child. The patient with a leiomyosarcoma was known to have had an antecedent leiomyoma in the same location.

CLINICAL COURSE

Mode of Presentation (Table 2). Eighteen of the 29 patients presented initially with a regional mass. Eight of the ten patients with laryngeal lesions first complained of hoarseness, but all ten admitted to the presence of dysphonia on further questioning. One patient each

From the Department of Otolaryngology, Washington University School of Medicine, St. Louis, Missouri.

TABLE 1. GENERAL CHARACTERISTICS OF 29 PATIENTS WITH HEAD AND NECK SARCOMA

No. of Patients	Sex Ratio (M:F) Age Range (yr)	Histology	Ratio of Well to Poorly Diff. Tumors	Anatomical Location	Treatment	Patient Status Post-treatment
5	2:3/28-76	XanthoS.	4:1	Neck 3 Trachea 2	WE 4 Unresect. 1	NED 3 Mets 1 Death 1
5	4:1/57-83	ChondroS.	5:0	Larynx 5	WE 5	NED 5
4	2:2/53-74	AngioS.	4:0	Scalp 2 Cheek 1 Larynx 1	WE 3 Unresect. 1	Rec. 2 Death 1
4	4:0/43-67	LipoS.	3:1	Neck 3 Larynx 1	WE 4	NED 3. Lost to FU 1
4	2:2/0.5-41	FibroS.	3:1	Neck 2 Oral 1 Larynx 1	WE 4 + Rad. 3	NED 2 Local rec. 2 Death 1
2	1:1/13-61	RhabdomyoS.	0:2	Neck 1 Oral 1	WE 2 + Rad. Chem. Rx 1	NED 1 Rec. 1
2	1:1/11-22	OsteoS.	2:1	Mandible 2	WE 2	NED 2
1	M/27	LeiomyoS.	0:1	Neck	WE	Rec.
1	M/25	Synovial S.	1:0	Oral	WE + Rad.	NED
1	F/67	Malignant hemangiopericytoma	0:1	Neck	WE + Rad.	Rec.

Diff. - Differentiated; S. - Sarcoma; WE - Wide excision; Unresect. - Unresectable; Rad. - Radiation; Chem. - Chemotherapy; NED - No evidence of disease; Mets - Metastasis; FU - Follow-up; Rec. - Recurrence.

initially noted stridor and dyspnea, local pain, and hemoptysis.

Site of Involvement (Table 3). Ten of the tumors occurred in the soft tissues of the neck, two in the scalp and one in the cheek. Visceral sites of involvement included the larynx in ten cases, the oral cavity in three, the mandible in two and the paranasal sinuses in one.

Histology (Table 4). The histological types of sarcoma encountered most commonly were malignant fibrous histiocytoma and its variants, and chondrosarcoma in five cases each. Angiosarcoma,

liposarcoma and fibrosarcoma were seen in four cases apiece. Two cases of rhabdomyosarcoma and osteosarcoma were treated along with one case each of leiomyosarcoma, synovial sarcoma and malignant hemangiopericytoma. Twenty-two of the tumors were well-differentiated (76%) while the remaining seven lesions were poorly differentiated.

The ten laryngeal sarcomas (Table 5) consisted of five chondrosarcomas, two xanthosarcomas, one angiosarcoma, one liposarcoma, and one fibrosarcoma. One

TABLE 2. PRESENTING SIGNS AND SYMPTOMS IN 29 HEAD AND NECK SARCOMAS

Signs and Symptoms	No. of Patients
Regional mass	18
Hoarseness	8
Stridor and dyspnea	1
Local pain	1
Hemoptysis	1

TABLE 3. SITE OF PRESENTATION OF 29 HEAD AND NECK SARCOMAS

Anatomical Sites	No. of Patients
Soft tissues	
Neck	10
Scalp	2
Cheek	1
Larynx, cervical trachea	10
Oral cavity	3
Mandible	2
Paranasal sinuses	1

TABLE 4. HISTOLOGICAL TYPES OF 29 HEAD AND NECK SARCOMAS

<i>Histological Type</i>	<i>No. of Patients</i>
Malignant fibrous histiocytoma (Xanthosarcoma)	5
Chondrosarcoma	5
Angiosarcoma	4
Liposarcoma	4
Fibrosarcoma	4
Rhabdomyosarcoma	2
Osteosarcoma	2
Leiomyosarcoma	1
Synovial sarcoma	1
Malignant hemangiopericytoma	1

of the xanthosarcomas and the liposarcoma were poorly differentiated; the eight other lesions were well-differentiated. At the time of endoscopy five of the laryngeal tumors were described as smooth and mucosa-covered while two appeared to be fungating and ulcerated.

Diagnosis. Three of 29 patients (10%) required more than one biopsy before a definitive diagnosis could be made. Originally one of the lesions was diagnosed as benign.

Special studies employed included xerograms of the neck and larynx (Fig. 1), CT scans of these areas, tomography of the larynx, and laryngograms.

The mean delay between the time of onset of symptoms and the confirmation of the diagnosis was 9.7 months. The longest delay was seen with chondrosarcomas with a mean of 29.8 months. By contrast the shortest interval occurred with fibrosarcomas (4.25 months).

Management and Outcome. Twenty-seven of the 29 patients underwent wide surgical excision as their definitive therapy with ten of these patients receiving

TABLE 5. HISTOLOGICAL TYPES OF LARYNGEAL SARCOMAS

<i>Histology</i>	<i>No. of Patients</i>
Chondrosarcoma	5
Xanthosarcoma	2
Angiosarcoma	1
Liposarcoma	1
Fibrosarcoma	1

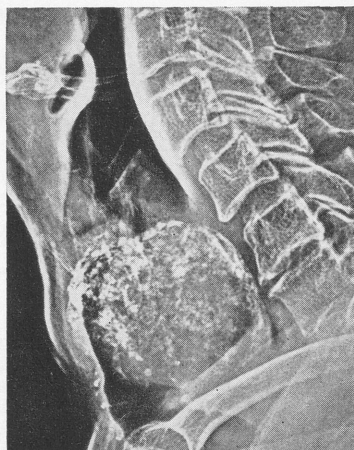


Fig. 1. Lateral xerogram of neck demonstrating intralesional calcification in a laryngeal chondrosarcoma.

pre- or postoperative irradiation. One patient was found to be unresectable and was treated with radiation and chemotherapy while another patient received chemotherapy alone.

Our conscious selection of a group of recent patients for clinical analysis obviously precludes any meaningful assessment of end results. The short term incidence of local recurrences and metastases is presented in Table 6 in relation to the variables of site, tumor grade, histology and patient age. The data suggest that cervical location, poor differen-

TABLE 6. FREQUENCY OF LOCAL RECURRENCE AND METASTASES WITHIN ONE YEAR OF TREATMENT

<i>Variables</i>	<i>Recurrence/ Metastases</i>
Site	
Larynx	1/9
Neck	6/12
Oral cavity	1/3
Paranasal sinuses	1/1
Mandible	0/2
Tumor grade	
Well-differentiated	8/22
Poorly differentiated	6/7
Histology	
Chondrosarcoma	0/5
Fibrosarcoma	2/4
Xanthosarcoma	2/5
Rhabdomyosarcoma	1/2
Patient age	
<50 years	3/13
>50 years	8/10

tiation or advanced patient age may be unfavorable factors.

DISCUSSION

Mesenchymal tumors of the head and neck comprise less than 10% of all malignancies in this region. When encountered, they pose difficult diagnostic and therapeutic problems. Mesenchymal malignancies, ie, sarcomas, possess an entirely different clinical course and therapeutic outcome than the more commonly encountered carcinomas. Rarely can one group of surgeons in one institution accumulate a sufficient spectrum of experience within a short time span to feel comfortable in diagnosing and treating these lesions. This study of 29 patients with varying sarcomas of the head and neck within a recent five-year period has provided us with several observations of their clinical behavior.

The presenting signs and symptoms of patients with sarcomas of the head and neck seem most dependent on their location. Since the vast majority occur in the soft tissues of the neck, the most common presenting complaint is of a neck mass. In our series, 13 of 29 patients (45%) had a neck mass as their chief complaint.

Unfortunately, the presence of a mass in the neck does not lead a priori to the diagnosis of a mesenchymal neoplasm. The question as to whether certain features of these neck masses suggest the diagnosis of sarcoma has not been satisfactorily answered. Ketcham et al² suggested that rapidly enlarging, deeply situated masses which disturb the normal face or neck contour should be suspect of sarcoma. Although pain is infrequent, rhabdomyosarcomas have been associated with sufficient surrounding inflammation to be confused with infectious processes.³ Rapid enlargement with fixation of adjacent soft tissue and muscle dysfunction has been reportedly associated with these tumors. Size per se is rarely diagnostic, although lesions measuring less than 5 cm are the exception.⁴

Although location in a particular region in the neck is not specific for mesenchymal malignancies, the vast majority of sarcomas presenting as neck masses have this as the sole evidence of their presence in this region. Since any

deeply infiltrating mass in the neck is considered malignant until proven otherwise, the diagnosis of sarcoma must be entertained, particularly in those cases without evidence of an upper aerodigestive tract primary lesion.

There is roughly an equal distribution of head and neck sarcomas between men and women, and although they tend to occur in a younger age group than carcinomas, neither of these features is of significant help in making a diagnosis.⁴

In our series, sarcomas occurring in the larynx were next in frequency to those in the cervical soft tissues. Most were chondrosarcomas. According to Friedmann,⁵ of the approximately 150 laryngeal sarcomas reported, more than 50% were fibrosarcomas followed in frequency by chondrosarcomas, rhabdomyosarcomas, lymphosarcomas, and more rare forms including osteosarcomas and liposarcomas. Most commonly, hoarseness is the presenting symptom, although occasionally dyspnea and hemoptysis occur. In our series, hoarseness was noted in eight of ten patients (80%), dyspnea in one (10%), and hemoptysis in one (10%).

Although laryngeal sarcomas occur only once to every 100 cases of carcinoma,⁵ selected features should make one suspect of the diagnosis. Laryngeal sarcomas are found within the vocal cord, ventricular and aryepiglottic folds and the cricoid cartilage. Laryngoscopically, their appearance is quite different from corresponding epidermoid cancers; usually a pink, fleshy, sessile or polypoid mass will be seen submucosally, partially occluding or prolapsing into the laryngeal lumen. While ulceration occurs, it is seen much less frequently than in carcinomas. Certain sarcomas, particularly chondrosarcomas, are palpable as midline or paramedian masses intimately associated with the larynx. This feature of apparent extralaryngeal extension only occurs with extremely large squamous cancers which have infiltrated the thyroid cartilage or thyrohyoid membrane.

Ketcham et al² suggested that since the endoscopic appearance of sarcomas of the larynx is somewhat characteristic, biopsy can and should be deferred by

the referring physician. This will provide the treating physician an opportunity to visualize the tumor prior to biopsy, and will not falsely alter the necessary radiographic studies. While laryngograms are rarely diagnostic, xeroradiograms and CAT scans of the larynx may reveal the typical calcified, stippled appearance of chondrosarcomas and osteosarcomas (Fig. 1).

Epidemiologically, sarcomas of the larynx are more common in males but the preponderance is less impressive than with squamous carcinoma.⁶ In our series, eight of ten patients were males; four of the five chondrosarcomas occurred in males. The age range of patients is most frequently 40 to 60, however, Rigby and Hollinger,⁷ Glick⁸ and others have reported fibrosarcomas and rhabdomyosarcomas in infants. The age range in our series was from six months to 83 years.

The frequency of sarcomas occurring in sites other than the soft tissues of the neck and larynx in our series was limited (6/29). This does not reflect the general pattern reported in the literature. Dito and Batsakis³ reported the nose, nasopharynx and paranasal sinuses as second in frequency only to the orbit in 170 rhabdomyosarcomas. Of the approximately 100 chondrosarcomas of the head and neck reported, 27 occurred in these same sites. Bankaci et al⁹ recently reviewed 14 cases of angiosarcoma of the nose, nasopharynx and paranasal sinuses and estimated them to be about one eighth as common as those occurring in the skin and soft tissue. Fu and Perzin¹⁰ estimated that malignant nonepithelial tumors comprise only 10% of malignancies in this region.

Clinically, sarcomas involving the nose, nasopharynx and paranasal sinuses present with nasal obstruction, epistaxis, signs of ostia obstruction (acute or subacute sinusitis) and otitis media, secondary to eustachian tube obstruction. Visualization and palpation is limited by the bony confines. Ancillary evaluative studies, notably tomograms, CAT scans and arteriograms will make recognition and therapy more simple.

Intraoral sarcomas, not unlike those occurring in the larynx, may have a characteristic gross appearance. A smooth-

surfaced, coarsely lobulated submucosal mass should lead the clinician to be suspicious of the diagnosis even before the biopsy diagnosis is obtained.

Sarcomas of the mandible, particularly osteosarcomas, are frequently diagnosed by their characteristic x-ray appearance.

Caron et al¹¹ suggested that alkaline phosphatase, calcium and phosphorus determinations might aid in differentiating osteosarcoma from other mandibular lesions.

Unlike the highly significant correlation between tobacco and alcohol abuse and carcinoma of the head and neck, sarcomas have not been associated with chronic mucosal irritation. Rather, a history of antecedent radiation and trauma has been correlated with the development of sarcoma. DeLathouwer and Brocheriou¹² reviewed the literature and found 43 patients with head and neck sarcomas who had previously received 3000 to 6000 rads. They estimated that 10% of all mandibular sarcomas arose in previously irradiated bone. Interestingly, of these, 46% were irradiated for fibrous dysplasia, also implicated etiologically in the development of sarcomas. Similarly, Skolnick et al¹³ reported an interesting case of osteosarcoma of the skull following irradiation. Mindell et al¹⁴ claimed that osteosarcoma and fibrosarcoma were the most common sarcomas to occur following radiation therapy.

Meyerding¹⁵ stated that 11% of soft tissue fibrosarcomas were associated with previous injury and scar. Others have not substantiated this, particularly in the head and neck. Lynch et al¹⁶ suggested that sarcomas appear to be associated with a variety of distinct genotypical hereditary cancer syndromes including the multiple nevoid basal cell carcinoma syndrome, von Recklinghausen's neurofibromatosis, tuberous sclerosis, Werner's syndrome and the polyposis syndromes of Turcot and Gardner. Hasson et al¹⁷ have implicated Thorotrast® in the etiology of extraskeletal osteosarcomas in the head and neck. In our series, none of the above etiologic associations were noted.

Biopsy ultimately provides the definitive diagnosis of sarcomas of the head

and neck. Unfortunately, establishing the histopathologic diagnosis of a specific sarcoma may be confounded by strikingly similar histologic features shared with other mesenchymal tumors.¹⁸ Moreover, incorrectly diagnosing certain well-differentiated sarcomas as their benign counterparts may occur in up to 40% of cases initially; the correct diagnosis only becoming apparent following disease recurrence.

Sarcomas arise from relatively undifferentiated mesenchymal cells. Histologically, they recapitulate in a neoplastic fashion their own cellular embryogenesis. Although established histopathologic guidelines for differentiating the various benign and malignant mesenchymal tumors have been set up by experienced pathologists,¹⁸ sufficient confusion still exists to require multiple biopsies in many cases. In our series, 13% of the tumors required more than one biopsy to establish a diagnosis, and in two patients the tumor was initially misdiagnosed as its benign counterpart. Conley et al¹⁹ noted an 85% accuracy of the original diagnosis in his series of 84 fibrosarcomas. In contrast, Moore and Grossi²⁰ reported that the correct diagnosis was made initially in only 4 of 37 rhabdomyosarcomas.

These different experiences presumably relate to the experience and judgment of the pathologists involved. Improvement may be possible if the surgeon informs the pathologist of his clinical assessment. The importance of pursuing the diagnosis of a lesion suspected of being a sarcoma cannot be overemphasized. Meticulous review of microscopic material and intensive follow-up is mandatory if these tumors are to be diagnosed and treated early.

Wide local excision is generally accepted as the primary mode of therapy for most sarcomas of the head and neck, regardless of histologic type. Finger-like extensions, satellite foci and the tendency to spread along muscle bundles and fascial planes should deter the surgeon from attempting enucleation procedures, which in the past have been associated with high rates of local recurrence. With respect to sarcoma, wide local excision implies an en bloc resection of the tumor including a broad

margin of adjacent normal tissue encompassing the next deepest uninvolved musculofacial plane.²¹ In the neck, this concept is easy to implement. Applied to maxillofacial sarcomas, limited, or at times extensive, adjacent bony resections will be necessary to achieve satisfactory margins. Laryngeal sarcomas have been treated successfully with both total laryngectomy and partial laryngectomy in carefully selected cases.^{5,6}

Not unlike squamous carcinomas of the head and neck, conservative procedures resulting in positive margins will almost invariably result in local disease recurrence. Fu and Perzin,²² for instance, reported four patients with chondrosarcomas of the paranasal sinuses who, following resections with positive margins, developed uncontrolled local recurrence with destruction of the base of the skull.

Although somewhat dependent on histologic type and degree of differentiation, it is generally agreed that recurrence tends to develop more rapidly with sarcomas than with carcinomas. The literature is not entirely supportive of this concept. Farr²³ claimed that 50% of sarcomas that recurred locally did so within one year, and 89% did so within two years. Caron et al¹¹ showed that 60% of osteosarcomas recurred within an average of 8.5 months. Swain et al²⁴ found that the average time for recurrence of fibrosarcoma was 1.9 years, while some did not occur for upward of five years. Recent data⁴ suggest that even ten years may not be sufficient time to identify all disease recurrence in some of the less aggressive sarcomas.

Inadequate excision of sarcomas may result in hematogenous dissemination to lung, bone and brain. Distant metastases are a well-known feature of sarcomas and have been reported in up to 50% of the more aggressive forms.³ Fortunately, with some sarcomas, such as chondrosarcomas and liposarcomas, this occurs relatively late, affording the surgeon a second attempt at local resection.

In our series, 17 of 29 patients (93%) were treated by wide local excision. Seven patients (26%) developed local recurrence and three patients (11%) developed within one year. Of Conley et al's 84 patients with fibrosarcoma, only

36% were cured by a single operative procedure.¹⁹ Cade²⁵ recorded prolonged survival in 50% of soft tissue sarcomas as a whole when given adequate local treatment. In Farr's review,²³ 30% of patients with soft tissue sarcomas of the head and neck, treated primarily by wide resection survived without recurrence for five years.

In his study of laryngeal sarcomas, Krajina⁶ treated 20 patients primarily with total laryngectomy resulting in an overall disease-free five-year survival rate of only 20%. Conversely, Weber et al²⁶ believed that the rate of local recurrence would remain relatively low with adequate laryngeal resection. Flanagan et al²⁷ reported that 21 of 29 patients with fibrosarcomas of the larynx survived an average of 4.9 years without recurrence.

With the exception of rhabdomyosarcomas and fibrous histiocytomas, radical neck dissection is not routinely performed for sarcomas of the head and neck. In their series of rhabdomyosarcomas, Mason and Soule²⁸ noted a 30-50% incidence of metastases to cervical nodes and suggested that neck dissection is indicated. Although the percent of fibrous histiocytomas metastasizing to nodes is not known, most such tumors reported have risen in the neck and are felt to merit neck dissection on that basis. With these exceptions, neck dissection is employed only in order to encompass the primary tumor en bloc or in cases with clinically suspicious adenopathy. In our series, two patients underwent radical neck dissection and nodal metastases were found microscopically in one.

The value of radiation as either a primary or adjunctive mode of therapy remains unproven for most sarcomas. Lindberg,²⁹ in a review of soft tissue sarcomas in adults, showed a local failure rate of 66% when treated by radiation therapy alone. More favorable results have been reported in selected tumors treated with combined therapy. Goepfert et al³⁰ reported an overall survival rate free of disease of 56% in 23 patients with soft tissue sarcomas of the head and neck treated by combined surgery and irradiation.

In recent years, studies have shown a

significant improvement in control of some sarcomas by the use of combination surgery, irradiation and chemotherapy. This is most notable for rhabdomyosarcomas in children. In 1973, Donaldson et al³¹ reported a two-year survival of 74% and local control of 89% in 19 patients with rhabdomyosarcoma of the head and neck. Sessions et al³² reported significantly improved disease control using surgery, irradiation and triple drug chemotherapy (actinomycin D, vincristine, Cytosan[®]) in a group of patients with embryonal rhabdomyosarcoma.

Relatively few of our patients were treated using these combined modalities, therefore our own data do not relate to these concepts.

Although the heterogeneity of sarcomas of the head and neck precludes general statements concerning survival; several clinical and histopathological features correlate prognostically. Different histologic types and subtypes exhibit different biologic behavior and thus carry varying prognoses. It is beyond the scope of this paper to review the differential recurrence and survival rates for each tumor type.

As with squamous carcinomas, both tumor size and location correlate with overall prognosis. Since both of these factors determine the ease of complete en bloc resection, the prognosis of any given histologic type will vary with them. In our series, the difference between soft tissue neck sarcomas and laryngeal sarcomas in terms of recurrent local or disseminated disease within one year was significant (9/13 vs 1/9). From the literature, it appears that sarcomas of the larynx are more easily controlled than sarcomas in the soft tissues of the neck, maxillofacial area or oral cavity.

Tumor grade or degree of differentiation can play a significant role in predicting local or systemic recurrence. Goepfert et al³⁰ reported 0%, 33%, and 63% local recurrence rates for grades 1, 2 and 3 respectively, in a series of assorted sarcomas of the head and neck. Similarly, survival rates of 100%, 66% and 13% occurred respectively in their series. Conley et al¹⁹ reported a 79% tumor control rate for well-differentiated versus 33% for undifferentiated fibrosarcomas. In our series, reappearance of disease

locally or systemically within one year occurred in 8 of 22 patients (36%) with well-differentiated sarcomas and in 6 of 7 patients (86%) with poorly differentiated lesions.

Until recently, the multitude of reports and the inconsistencies in classification and reporting of results precluded a meaningful comparative analysis of survival figures. In a large cooperative clinicopathologic study through the AJCC,⁴ 1,215 soft tissue sarcomas (177 in the head and neck) were staged according to tumor size, histologic grade, and nodal and systemic metastases (TNMG). Stage and grade clearly cor-

related with overall disease recurrence and survival. The respective five year survival rates for stages I - IV were 75%, 55%, 29% and 7%. It therefore would appear to be highly desirable to begin staging sarcomas of the head and neck so that more meaningful data regarding the appropriateness of therapy can be generated.

In conclusion, it would appear that awareness of the combined host and clinical factors studies should provide the physician with increased diagnostic acumen and therapeutic expertise in dealing with sarcomas of the head and neck.

REFERENCES

1. Westbury G: Sarcomas of soft tissue. *Clin Oncol* 4:109-111, 1978
2. Ketcham AS, Chretien PB, Pilch YH: Sarcomas of the head and neck, in Gaisford JE (ed): *Symposium on Cancer of the Head and Neck*, vol 2. St. Louis, C. V. Mosby Co, 1969, p 337
3. Dito WR, Batsakis JG: Rhabdomyosarcoma of the head and neck: An appraisal of the biologic behavior in 170 cases. *Arch Surg* 84:582-585, 1962
4. Russell WO, Cohen J, Enzinger F, et al: A clinical and pathological staging system for soft tissue sarcomas. *Cancer* 40:1562-1570, 1977
5. Friedmann I: Sarcomas of the larynx. *Can J Otol* 4:297-302, 1975
6. Krajina Z: Laryngeal sarcoma. *Can J Otol* 4:303-306, 1975
7. Rigby RC, Hollinger PA: Fibrosarcoma of the larynx in an infant. *Arch Otolaryngol* 37:421-424, 1943
8. Glick HN: An unusual neoplasm in the larynx of a child: Rhabdomyosarcoma. *Ann Otol Rhinol Laryngol* 53:699-704, 1944
9. Bankaci M, Myers EN, Barnes L, et al: Angiosarcoma of the maxillary sinus: Literature review and case report. *Head Neck Surg* 1:274-280, 1979
10. Fu Y-S, Perzin KH: Non-epithelial tumors of the nasal cavity, paranasal sinuses, and nasopharynx: A clinicopathologic study. I. General features and vascular tumors. *Cancer* 33:1275-1288, 1974
11. Caron AS, Hajdu SI, Strong EW: Osteogenic sarcoma of the facial and cranial bones. *Am J Surg* 122:719-725, 1971
12. DeLathouwer C, Brocheriou C: Sarcoma arising in irradiated jawbones. Possible relationship with previous non-malignant bone lesions. *J Maxillofac Surg* 4:8-20, 1976
13. Skolnik EM, Fornatto EJ, Heydemann J: Osteogenic sarcoma of the skull following irradiation. *Ann Otol Rhinol Laryngol* 65:915-936, 1956
14. Mindell ER, Shah NK, Webster JH: Postradiation sarcoma of bone and soft tissue. *Orthop Clin North Am* 8:821-834, 1977
15. Meyerding HW: Clinical aspects of fibrosarcoma of the soft tissue. *Surg Gynecol Obstet* 62:1010-1019, 1936
16. Lynch HT, Krush AJ, Harlan WH, et al: Association of soft tissue sarcoma, leukemia and brain tumors in families affected with breast cancer. *Am Surg* 39:199-206, 1973
17. Hasson J, Hartman KS, Milikov E, et al: Thorotrast-induced extraskelatal osteosarcoma of the cervical region. *Cancer* 36:1827-1833, 1975
18. Batsakis JG: *Tumors of the Head and Neck*. Baltimore, Williams and Wilkins Co, 1974, p 178
19. Conley J, Stout AP, Healey MV: Clinicopathologic analysis of eighty-four patients with an original diagnosis of fibrosarcoma of the head and neck. *Am J Surg* 114:564-569, 1967
20. Moore O, Grossi C: Embryonal rhabdomyosarcoma of the head and neck. *Cancer* 12:69-73, 1959
21. Fortner JG: Operative management of soft tissue sarcomas, in Najarian JS, Delaney JP (eds): *Advances in Cancer Surgery*. New York, Stratton Intercontinental Medical Book Co, 1976, p 394
22. Fu Y-S, Perzin KH: Non-epithelial tumors of the nasal cavity, paranasal sinuses and nasopharynx. III. Cartilaginous tumors. *Cancer* 34:453-463, 1974
23. Farr HW: Soft part sarcomas of the head and neck. *Am J Surg* 122:714-718, 1971
24. Swain RE, Sessions DG, Ogura JH: Fibrosarcoma of the head and neck: A clinical analysis of forty cases. *Ann Otol Rhinol Laryngol* 83:439-444, 1974
25. Cade S: Soft tissue tumors: Their na-

tural history and treatment. Proc R Soc Med 44:19-36, 1951

26. Weber AL, Shortsleeve M, Goodman M, et al: Cartilaginous tumors of the larynx and trachea. Radiol Clin North Am 16:261-271, 1978

27. Flanagan P, Cross R McP, Libcke JH: Fibrosarcoma of the larynx. J Laryngol Otol 79:1049-1056, 1965

28. Masson JK, Soule EH: Embryonal rhabdomyosarcoma of the head and neck. Report of eighty-eight cases. Am J Surg 110:585-586, 1965

29. Lindberg RD: The management of soft tissue sarcomas in adults: Surgery and post-operative radiotherapy, in Najarian JS, De-

laney JP (eds): *Advances in Cancer Surgery*. New York, Stratton Intercontinental Medical Book Co, 1976, p 401

30. Goepfert H, Lindberg RD, Sinkovics JG, et al: Soft-tissue sarcoma of the head and neck after puberty. Arch Otolaryngol 103:365-368, 1977

31. Donaldson SS, Castro JR, Wilbur JR, et al: Rhabdomyosarcoma of head and neck in children: Combination treatment by surgery, irradiation and chemotherapy. Cancer 31:26-35, 1973

32. Sessions DG, Ragab AH, Vietti TJ, et al: Embryonal rhabdomyosarcoma of the head and neck in children. Laryngoscope 83:890-897, 1973

REPRINTS — Michael Setzen, MD, Department of Otolaryngology, Washington University School of Medicine, 517 S. Euclid, St. Louis, MO 63110.

ENTERAL AND PARENTERAL NUTRITION IN PATIENTS WITH HEAD AND NECK CANCER

STEVEN M. SOBOL, MD

J. MICHAEL CONOYER, MD

DONALD G. SESSIONS, MD

ST. LOUIS, MISSOURI

Head and neck cancer patients present with special problems in nutritional homeostasis because of local pharyngeal discomfort and obstruction and difficulty with deglutition due to either the neoplasm or the surgical alterations in the upper aerodigestive tract. Pretreatment malnutrition and vitamin deficiency are only compounded by the nutritional stress imposed by radiation and surgery. Reduced wound complications occur if the patients are nutritionally replenished before treatment. While nasogastric feedings will suffice in many patients, rapid nutritional restoration by this method is limited, and positive nitrogen balance may be difficult to achieve in the severely malnourished patient. Intravenous hyperalimentation offers a rapid and efficacious alternative in selected cases. The case histories of two patients are presented to illustrate these concepts.

In recent years, nutritional therapy has been recognized as an increasingly important adjunct in the management of patients with cancer. The treatment modalities of surgery, radiation and chemotherapy are often limited by the nutritional status of the host. Nutritionally depleted patients may not heal satisfactorily and have a marked reduction in immune resistance. Nutritional support is thus mandatory for the successful treatment of cancer.

Patients with head and neck cancer face problems with protein-calorie malnutrition. It is generally agreed that the presence of malnutrition adversely affects the hospital course of these patients by creating unacceptable morbidity and mortality. Prompt recognition and treatment is essential to reduce this morbidity and mortality to acceptable levels.

Although enteral alimentation is the preferred method of nutritional support in patients with head and neck cancer, it is not always successful in achieving positive nitrogen balance. Intravenous hyperalimentation provides rapid nutritional restoration and may be a necessary alternative in selected patients.

This report discusses two patients with head and neck cancer who illustrate the devastating nature of host malnutrition and the necessity of selecting the proper method of nutritional support. The mechanisms behind malnutrition are presented and the rationale for its management is discussed.

CASE REPORTS

Case 1. W. B. was a 66-year-old Caucasian male admitted to Barnes Hospital, St. Louis, Missouri, in February 1967, with a three-month history of a left neck mass. The mass was 3 x 5 cm and located in the jugulodigastric area. Routine head and neck examination revealed no primary lesion. Chest x-ray and barium swallow with upper gastrointestinal series were normal. Laryngoscopy, esophagoscopy, bronchoscopy with washings and nasopharyngoscopy with blind biopsy were all negative. Open biopsy of the left neck mass revealed epidermoid carcinoma. The patient was discharged to receive outpatient radiotherapy. The patient's weight during this admission was 61 kg (135 lb). Hemoglobin was 13.5 gm%, BUN 22 mg%, creatinine 0.7%, albumin 3.4 gm% with a total protein of 6.8 gm%.

After 3000 rads to the neck and a four-week rest period, the patient was readmitted. The left neck mass was 2 cm in size. The patient weighed 60.3 kg (134 lb) with a hemoglobin of 12.1 gm%, creatinine 0.9 mg%, BUN 15 mg% and albumin 3.0 gm% with total protein 6.3 gm%. Repeat panendoscopy was again unre-

From the Department of Otolaryngology, Washington University School of Medicine, St. Louis, Missouri.

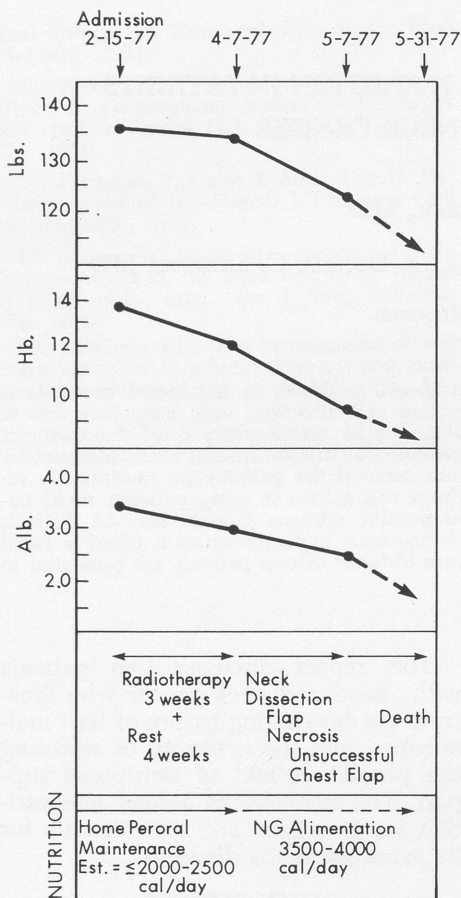


Fig. 1. (Case 1) Metastatic carcinoma to the left neck from an unknown primary. Gradual and progressive nutritional depletion despite forced enteral hyperalimentation.

vealing for the primary lesion. The patient underwent a routine left neck dissection. Postoperatively, massive flap necrosis with carotid exposure occurred. A left thoracoacromial flap was staged. Two weeks after staging, the chest flap was elevated but was returned to the donor site because of inadequate marginal circulation. The edges of the flap subsequently necrosed. Despite tolerating 4000 calories/day via nasogastric feeding, the patient's weight fell to 56 kg (124 lb) with a hemoglobin of 9.8 gm%, creatinine 0.8 mg%, BUN 30 mg%, albumin 2.8 gm% with total protein 7.7 gm%. He suffered carotid rupture with exsanguination nine weeks after the neck dissection. A graphic illustration is presented in Figure 1.

Case 2. J. Y. was a 76-year-old Caucasian male with a 60-year history of cigarette and alcohol abuse who presented to Barnes Hospital in April 1976, with a three-month history of hoarseness, dysphagia, odynophagia and an 18 kg (40 lb) weight loss. Laryngoscopy with biopsy revealed an epidermoid carcinoma in-

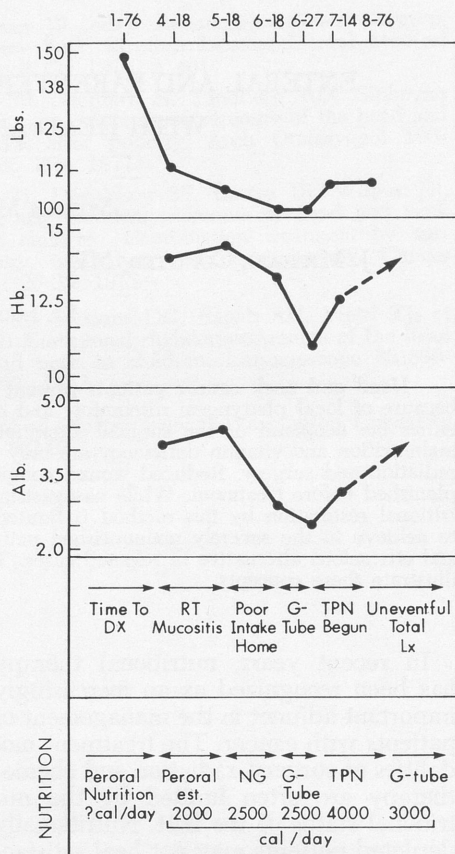


Fig. 2. (Case 2) T_4 carcinoma of the larynx. Insufficient nutritional gain via the enteral route necessitated intravenous hyperalimentation. Note nutritional restoration within weeks after IVH begun.

volving the left aryepiglottic fold, false vocal cord, anterior true vocal cord and epiglottis. Radiographic evaluation suggested thyroid cartilage invasion. No neck nodes or other evidence of metastases were present. The patient weighed 51 kg (113 lb) with a hemoglobin of 14 gm%, creatinine 0.8 mg%, BUN 9 mg%, and albumin 4.1 gm% with total protein 7.4 gm% and cholesterol 161 mg%.

The patient was discharged to receive outpatient radiation therapy, but was readmitted one month later with severe mucositis. His weight was 48 kg (106 lb) with a hemoglobin of 14.5 gm%, creatinine 1.4 mg%, BUN 25 mg%, albumin 4.4 gm% with total protein 7.9 gm% and cholesterol 203 mg%. He was given 2500 calories/day via nasogastric feeding, allowing the completion of 400 rads preoperative therapy. He was discharged on nasogastric feedings.

One month later the patient was again admitted for nutritional support because of mucositis and intolerance of nasogastric feedings. His weight on admission was 45.4 kg (101 lb) with a hemoglobin of 13 gm%, creatinine

0.7 mg%, BUN 16 mg%, albumin 2.8 gm% with total protein 5.8 gm% and cholesterol 136 mg%. A gastrostomy was performed and feedings of 2500 calories/day were tolerated for one week without weight gain. The hemoglobin was 11 gm%, creatinine 0.8 mg%, BUN 15 mg%, albumin 2.6 gm% with total protein 5.4 gm%, and cholesterol 122 mg%.

Central venous hyperalimentation with 8.5% FreamineTM was instituted, yielding an intake of 4000 calories/day. The patient gained 4 kg (8 lb) in three weeks. The hemoglobin was 12.5 gm%, creatinine 0.7 mg%, BUN 21 mg%, albumin 3.1 gm% with total protein 6.2 gm% and cholesterol 157 mg%.

The patient underwent an uneventful total laryngectomy with a controlled pharyngostome. Central venous hyperalimentation was continued one week postoperatively and gastrostomy feedings were resumed. Three thousand calories/day were tolerated without weight loss or change in laboratory parameters. The patient was discharged with gastrostomy feedings. Subsequent closure of the pharyngostome using the deltopectoral flap was uneventful. A graphic illustration is presented in Figure 2.

DISCUSSION

Head and neck cancer patients present with nutritional problems not unlike other cancer patients, but also possess special problems of alimentation of their own. Most of these patients are elderly and may have long histories of tobacco and alcohol abuse. Difficulties with deglutition resulting from pain, edema, ulceration and bleeding are common and preclude adequate peroral nutrition, even before any treatment has begun.

A state of relative starvation is not uncommon for patients with head and neck cancer. Under normal circumstances, starvation involves a biphasic metabolic process;¹ the first phase involves increased gluconeogenesis at the expense of fat and skeletal muscle protein and the second phase involves alterations which reduce the obligatory breakdown of protein. The net effect of the process is protein sparing at the expense of fat. In patients with malignancy, these normal adaptive metabolic mechanisms fail and the result is cachexia.

Cachexia is a poorly understood syndrome, resulting from complex organic and biochemical interactions, characterized by weakness, muscle wasting, anorexia and profound nutritional depletion.² Although speculative, the "cachectic syndrome" has been predominantly attributed to reduced food intake,

rather than selective and preferential consumption of vital nutrients by the neoplasm.^{2,3} While overall tumor burden undoubtedly plays a role, no linear relationship exists between tumor size and degree of cachexia.^{3,4} The point at which food intake drops sufficiently to produce a net host metabolic deficit is dependent on unpredictable host-tumor interactions.⁴

These pretreatment nutritional deficits are made worse by the addition of radiation, chemotherapy or surgery. The effects of head and neck radiation on nutrition may be devastating. Progressive mucositis, xerostomia and altered dental hygiene create local oropharyngeal discomfort, dysphagia, and odynophagia contributing significantly to generalized host malnutrition. Altered taste, anorexia, nausea and vomiting only worsen this problem. Moreover, many of these malnutritive effects of radiation therapy persist for weeks or even months after the treatment has ceased.

Surgery is a well-known cause of nutritional stress. Generalized catabolism follows surgery, in which fat and skeletal muscle protein reserves are mobilized, effectively creating a state of negative nitrogen balance.¹ The severity of the surgical stress combined with the preoperative nutritional deficits will determine the number of days or weeks required for the body to convert itself into a metabolic schema favoring positive nitrogen balance. This time course may be modified by appropriate attention to pre- and postoperative nutritional maintenance.

The nutritional status of head and neck cancer patients will profoundly alter their course and prognosis. Weight loss itself has been shown to correlate with mortality. Mortality rates as high as 30% exist in patients who have lost 20% of their body weight, and rates close to 100% exist for patients with a loss of 50% of their body weight.⁵

Host protein-calorie malnutrition creates unacceptable morbidity in several ways. Reduced immune competence and resistance to infection are exaggerated by nutritional depletion.^{6,7} Patients with head and neck cancer, however, demonstrate variable degrees of immune in-

TABLE 1. NUTRITIONAL ASSESSMENT

Patient Name _____		Date _____		No. _____	
Primary Dx _____					
Parameters	Value	Deficit			
		Severe	Moderate	Minimal	
Weight/height					
Brachial circumference					
Triceps skinfold					
Albumin					
Serum transferrin					
Total lymphocyte count					
Cell mediated immunity					
(mumps, SK/SD)					
(Candida)					
Creatinine/height index					
Urinary urea nitrogen					
Nitrogen balance					
(Total protein intake/6.25) - (urinary urea N. + 4)					
Standards		Severe	Moderate	Minimal	
Weight	}	>30%	>15-30%	>5-15%	
Anthropometrics					
Albumin		<2.5 gm%	<3.0-2.5 gm%	<3.5-3.0 gm%	
Transferrin		<160 mg%	<180-160 mg%	<200-180 mg%	
Lymphocyte count		<900	<1500-900	<1800-1500	
Skin tests		<5.0	<10-5	<15-10	
(Adapted from Blackburn and Bistrian ²¹)					

(Adapted from Blackburn and Bistrian²¹)

competence regardless of nutritional status. It is estimated that 65 to 75% of patients with head and neck cancer are incapable of mounting a normal cell-mediated immune response.⁸ Copeland et al⁹ believe that malnutrition accounts for about one half of these anergic responses. Meakins et al¹⁰ demonstrated that reduced immune competence increases morbidity and mortality.

Similarly wound healing is affected adversely by malnutrition. The deleterious effects of hypoproteinemic malnutrition on gastrointestinal anastomoses are well documented.¹¹ A similar effect on surgical wound closure in the upper aerodigestive tract is to be expected. Fistula, wound breakdown, flap necrosis and slough account for a large percentage of the morbidity following head and neck cancer surgery.¹² High protein-calorie nutritional support is necessary to alter favorably both the incidence and treatment of these problems.

Nutritional assessment is the first step in the rehabilitation of the malnourished patient. While several factors can be measured, no single assessment parameter can fully characterize the nutritional status. The concept of a complete comprehensive metabolic profile, most recently popularized by Blackburn et al,¹³ is necessary to follow and predict response to therapy and survival. Included are serial measurements of body weight, lean body mass, serum and urinary creatinine and urea nitrogen, serum albumin and transferrin and tests of cell-mediated immune function (Table 1). Body weight and anthropometric measurements are expressed as a percent of ideal. Serum protein studies reflect the status of the visceral protein compartment. Total lymphocyte count and delayed hypersensitivity skin tests reveal the immune status of the host. Nitrogen balance can be estimated from measurements of urinary urea. Adherence to a schedule of measuring these parameters

TABLE 2. CHARACTERISTICS OF AN IDEAL TUBE FEEDING

Bacteriologic safety
Acceptable osmolality
Caloric density \approx 1-1.5 calorie/cc
Contains proper porportion of readily absorbable nutrients
Contains mineral and vitamin supplements
Ease of handling and administration
Affordable
(Modified from Gormican and Liddy. ¹⁹)

is mandatory if the effects of nutritional therapy are to be confirmed with accuracy.

Using nutritional assessment profiles, previous hospital-wide studies have estimated the high prevalence (50%) of malnutrition.^{14,15} In an attempt to answer the important question of which specific nutritional assessment parameters are sufficiently accurate and sensitive to identify the subpopulation of malnourished patients at greatest risk of less than optimal clinical outcome, Mulen et al¹⁶ studied 64 elective surgical patients. Although these authors noted a 97% incidence of abnormality in at least one nutritional assessment parameter, only serum albumin, transferrin and delayed hypersensitivity tests were predictive of suboptimal clinical outcome. They noted that albumin levels less than 3.0 gm%, transferrin levels less than 220 mg%, and anergic responses to skin test antigens were associated with a two to four-fold increase in primarily septic complications. This supports the view that the visceral protein compartment is critical in maintaining the integrity of the host defense system and further emphasizes the need for prompt recognition and treatment.

Since the gastrointestinal tract is the ideal system for digestion, absorption and assimilation of nutrients, and since it is normal in most head and neck cancer patients, the enteral route is generally chosen for nutritional support. Peroral intake is often limited or impossible during the preoperative period for the reasons already discussed. Postoperatively, resumption of oral intake may take several days or weeks and is usually associated with deglutition problems resulting from the surgical alterations in the upper aerodigestive tract.

Nasogastric intubation, esophagostomy or gastrostomy are the most frequently selected routes for enteral alimentation. Although complications, including benign esophageal stricture,¹⁷ reflux esophagitis,¹⁸ mucosal erosion and leakage of gastric contents have been reported with each of these techniques, they are generally well tolerated by most. Selecting a proper tube feeding diet involves careful attention to the overall state of nitrogen balance, digestive and absorptive capacity, anticipated electrolyte and fluid imbalance, underlying systemic disorders and patient tolerance.^{19,20} The characteristics of an ideal tube feeding diet as delineated by Gormican and Liddy are listed in Table 2.

Protein-calorie requirements are determined by nutritional status and degree of catabolism. Blackburn and Bistrian²¹ estimate that a 30-35 kcal/kg/day with a nitrogen: calorie ratio of 1:300 is sufficient for maintenance in the noncatabolic state; 40-45 kcal/kg/day with proportionally more protein is necessary for severely depleted or catabolic patients. While administration of 2000-2500 kcal/day is sufficient for maintenance in most adults, 3000-4000 kcal/day are necessary to achieve positive nitrogen balance in the depleted state.^{19,21,22} Since head and neck cancer patients are usually depleted preoperatively, a two to three week period of extraoral enteral alimentation prior to surgery might serve to reduce potential postoperative morbidity.²³

As some patients are unable to tolerate the commonly used bolus schedule of feeding, a continuous drip form of enteral hyperalimentation has been recommended by Kaminski.²⁴ With this technique, a soft, small caliber Silastic® indwelling nasogastric tube is left attached to a tube-feeding pump which is regulated to deliver up to 125 cc per hour (3000 calories/day).

With all tube feeding methods, several problems exist which may preclude adequate enteral nutrition. Diarrhea, bloating, abdominal distension, regurgitation, tube feeding intolerance and food allergies occur frequently in tube-fed patients.^{16,19,21} Resultant interruptions in the enteral feeding schedule

are nutritionally costly. Moreover, studies suggest that severely malnourished patients cannot absorb nutrients normally, making forced enteral alimentation relatively inefficient. Adibi and Allen²⁵ showed a reduced jejunal absorption of various amino acids associated with alterations in villous architecture within the gut lumen in malnourished patients. Dey and Romalingaswami²⁶ demonstrated experimentally that malnutrition impedes the replication of intestinal villous cells. Thus, assimilation of nutrients via the gastrointestinal tract is reduced in clinically malnourished patients, with much of the administered meal being lost in the stool. As long as three months may be required to reverse the nutritionally depleted state using the enteral route.²⁷

Intravenous hyperalimentation provides a rapid, relatively safe and efficacious method of nutritional restoration.²⁸ Studies at the M. D. Anderson Hospital, Houston, Texas,^{2,29} indicate that intravenous hyperalimentation can favorably alter the nutritional status of head and neck cancer patients within 14 to 21 days. The authors suggested that total parenteral nutrition reduced the rate of pharyngocutaneous fistula and increased flap viability and the healing of grafts over radiated tissue. Schwartz et al³⁰ and others^{31,32} have shown that parenteral hyperalimentation may improve response rates to chemotherapy and allow patients to tolerate more treatment. Copeland et al³³ and Copeland³⁴ believe that intravenous hyperalimentation likewise improves patient tolerance, and thus responsiveness to radiotherapy, and reduces the incidence of radiation stomatitis. Improvement in cell mediated immune function, as measured by delayed hypersensitivity skin tests is similarly found in cancer patients following intravenous hyperalimentation.⁹

The principles and techniques involved in total parenteral nutrition have been described elsewhere.²⁷ Catheter-related sepsis, although an infrequent but accepted complication of intravenous nutrition, poses a potentially greater threat in head and neck patients. Secretions from pharyngostomes, fistulas, and tracheostomies frequently contaminate nearby dressings. Careful

attention to aseptic technique during daily dressing changes and the use of adherent plastic sheets may keep this problem to a minimum.

The concept that enteral alimentation may not always provide adequate nutritional restoration despite a relatively normal gastrointestinal tract is supported by our selected cases. In our first patient, despite sufficient protein-calorie enteral intake, progressive wound breakdown, flap death and malnutrition ultimately led to the patient's demise. The second patient illustrates the nutritional problems encountered preoperatively by head and neck cancer patients. However, recognition that enteral alimentation was not improving the nutritional status prompted the use of parenteral nutrition. Within three weeks, the patient demonstrated progressive nutritional restoration, and was able to return to enteral feedings within a reasonably short time postoperatively.

While intravenous hyperalimentation has had limited use to date in head and neck cancer patients who are able to tolerate tube feedings, its more widespread use as both an adjuvant and complete caloric source seems warranted.

CONCLUSION

It appears that nutrition provides a major adjuvant modality in head and neck cancer therapy. Although a malignant lesion in the head and neck may be anatomically resectable and potentially curable, negative nitrogen balance, cachexia, and impaired wound healing may eliminate these patients as viable candidates for surgical or radiation therapy. Nutritional assessment must include serial measurements throughout the hospital course. Precise nutritional rehabilitative strategy must be planned and the results carefully followed. Enteral alimentation may not always meet the nutritional demands incumbent upon the depleted head and neck cancer patient. Intravenous hyperalimentation offers a viable and necessary alternative in selected cases. The empirical and physiological basis of such treatment deserves the same fundamental scientific evaluation as that given to all therapeutic modalities employed for head and neck cancer.

REFERENCES

1. Moore FD: *Metabolic Care of the Surgical Patient*. Philadelphia, WB Saunders, 1959
2. Schein P, MacDonald J, Waters C, et al: Nutritional complications of cancer and its treatment. *Semin Oncol* 2:337-345, 1975
3. Corta G: Cachexia; the metabolic component of neoplastic disease. *Cancer Res* 37: 2327-2335, 1977
4. Dewys WD: Systemic effects of cancer: Cachexia-anorexia, abstracted. XI Int Cancer Congress 1:145, 1974
5. Dudrick SJ, Wilmore DW, Voss HM, et al: Long-term total parenteral nutrition with growth, development and positive nitrogen balance. *Surgery* 64:134-145, 1968
6. Law DK, Dudrick SJ, Abdou NI: Immunocompetence of patients with protein-calorie malnutrition. The effects of nutritional repletion. *Ann Intern Med* 79:545, 1973
7. Cannon PR: The importance of proteins in resistance to infection. *JAMA* 128:360-363, 1945
8. Olivari A, Piadier R, Fierstein J, et al: Cell mediated immune response in head and neck cancer patients. *J Surg Oncol* 8:287-294, 1976
9. Copeland EM, MacFadden BV, Dudrick SJ: Effect of intravenous hyperalimentation on established delayed hypersensitivity in the cancer patient. *Ann Surg* 184:60-64, 1976
10. Meakins JL, Patsch JB, Babernick O, et al: Delayed hypersensitivity: Indicator of acquired failure of host defenses in sepsis and trauma. *Ann Surg* 186:241-247, 1977
11. Thompson W, Ravdin I, Frank I: Effect of hypoproteinemia on wound disruption. *Arch Surg* 36:500-508, 1938
12. Gall A, Sessions DG, Ogura JH: Complications following surgery for cancer of the larynx and hypolarynx. *Cancer* 39:624-631, 1977
13. Blackburn GL, Bistrian BR, Maini BS, et al: Nutritional and metabolic assessment of the hospitalized patient. *J Parent Ent Nutr* 1:11-22, 1977
14. Bistrian BR, Blackburn GL, Vitale J, et al: Prevalence of malnutrition in general medical patients. *JAMA* 235:1567-1570, 1976
15. Wilcutts HD: Nutritional assessment of 1,000 surgical patients in an affluent suburban community hospital. *J Parent Ent Nutr* 1:25-30, 1977
16. Mullen J, Gertner M, Buzby G, et al: Implications of malnutrition in the surgical patient. *Arch Surg* 114:121-125, 1979
17. Banfield WT: Esophageal stricture associated with nasogastric intubation. *Arch Intern Med* 134:1083-1086, 1974
18. Nagler R, Spiro HM: Persistent gastro-esophageal reflex induced during prolonged gastric intubation. *N Engl J Med* 269:495-497, 1963
19. Gormican A, Liddy E: Nasogastric tube feedings. Practical considerations in preservation and evaluation. *Postgrad Med* 53:71-76, 1973
20. Sobol SM, Conoyer JM, Zill R, et al: Nutritional concepts in the management of head and neck cancer, pt. I & II. *Laryngoscope*, in press
21. Blackburn G, Bistrian BR: Nutritional care of the injured and/or septic patient. *Surg Clin North Am* 56:1195-1224, 1976
22. Gormican A: Nutritional status of patients after extended tube feedings. *J Am Diet Assoc* 63:247-253, 1973
23. Allendyce DB: A comparison of nutritional gains resulting from intravenous and enteral feedings. *Surg Gynecol Obstet* 139:179-184, 1974
24. Kaminski M: Enteral hyperalimentation. *Surg Gynecol Obstet* 143:12-77, 1976
25. Adibi SA, Allen RE: Impaired jejunal absorption rates of essential amino acids induced by either dietary, calorie or protein deprivation in man. *Gastroenterology* 59:404-413, 1970
26. Dey MG, Romalingaswami V: Reaction of the small intestine to induced protein malnutrition in rhesus monkeys: A study of population kinetics in the jejunum. *Gastroenterology* 49:150-157, 1965
27. Tandon B, Magrota M, Saraya A, et al: Small intestine in protein malnutrition. *Am J Clin Nutr* 21:813-819, 1968
28. Dudrick SJ, Rubey RL: Principles and practice of parenteral nutrition. *Gastroenterology* 61:901-910, 1971
29. Copeland E, MacFadyen B, MacComb WS, et al: Intravenous hyperalimentation in patients with head and neck cancer. *Cancer* 35:606-611, 1975
30. Schwartz G, Green H, Bendon M, et al: Combined parenteral hyperalimentation and chemotherapy in the treatment of disseminated solid tumors. *Am J Surg* 121:169-173, 1971
31. Copeland EM, MacFadyen BV, Lanxotti VJ, et al: Intravenous hyperalimentation as an adjunct to cancer chemotherapy. *Am J Surg* 129:167-173, 1975
32. Steiger E, Oram-Smith J, Miller E, et al: Effects of nutrition on tumor growth and tolerance to chemotherapy. *J Surg Res* 18:455-461, 1975
33. Copeland E, Souchon E, MacFayden B, et al: Intravenous hyperalimentation as an adjunct to radiation therapy. *Cancer* 39:609-616, 1977
34. Copeland EM: Intravenous hyperalimentation as an adjunct to cancer patient management. *CA* 28:322-330, 1978

REPRINTS — Steven M. Sobol, MD, Dept. of Otolaryngology, Washington University School of Medicine, 517 South Euclid, St. Louis, MO 63110.

DISCUSSION OF PREVIOUS TWO PAPERS

GEORGE A. SISSON, MD (Chicago, Illinois): It's often acknowledged by eminent histopathologists that even though 90% of all the head and neck cancers are squamous cell derivatives, more time, effort and concern is spent on diagnosing and confirming the remaining 10%. In addition, the number game comes into this. These cases are few and far between. While they are the elusive, difficult, confusing and often frustrating group, this 10% of head and neck tumors becomes the most challenging, interesting, curious and often satisfying, once experience is gained by either the pathologist or the clinician. I sincerely believe that the authors enjoy pulling out these pathological hors d'oeuvres from the records of the Washington University School of Medicine. Papers such as this first paper are certainly important and I complement the authors in the orderly manner in which they presented these 29 rare birds. The bibliography is in itself a reference library with the most current and appropriate articles. One must read the article to garner all the nuances and subtleties when early diagnosis and treatment are discussed. Multiple biopsies for confirmation, a nine-month mean delay in diagnosis, the dilemma as to surgery — radiation combination, all represent realistic frustrations encountered when one manages these unusual cases. There are six important points made which are shared by me: 1) Most of these cases present as neck masses. 2) Chondrosarcomas of the larynx or sinuses (and these are the most common areas) present finally after inordinate delays. In the cases they presented here it was up to 3 years 29 months. 3) Surgery is the preferred treatment. 4) If sarcoma is suspected clinically one must persevere until diagnosis is confirmed. 5) More progress seems to have been made with rhabdomyosarcoma than any of the others and that's interesting. It's probably due to the tremendous success with triple therapy, chemotherapy particularly and one wonders why isn't this added to some of the other sarcomas. At least in our institution this has not happened as yet. 6) Laryngeal sarcomas are the easier ones to manage; particularly easier than the paranasal sinuses and the soft tissue primaries. And finally I share the author's frustration in comparing literature reports to determine which treatment or combination really is the best. Perhaps the use of the new TNM system will help us as more people report papers such as we just heard.

In the second paper, these two cases are very dramatic and impressive. They represent the two extremes. However, as my grandfather said, you know two swallows don't really make the summer. For the past seven years at Northwestern we've had a dedicated unit who have dedicated up to four beds in our general cancer unit for hyperalimentation. While busy at first, presently there's been no real rush by the surgeons (including the head and neck surgeons) to admit to these special units. An occasional case is managed on our service and it's usually managed by our own attendings

and the medical men. Perhaps the advantages exist mostly for the head and neck and that may account for it as was intimated by the authors. However, for years I've looked for the scapegoat to explain why cases go bad. In the community hospital where the surgeon may be an occasional operator we blame that. In the medical center we blame the chief resident or the lack of nurses. Lack of the levator or the dermal graph, breakdown in technique, suture material, these have all been singled out as the villains when cases go bad. Now impending catabolism or negative nitrogen balance is perhaps the fall guy. I mention this to bring this argument, perhaps, into perspective. Nobody ever objects when we say we prefer to operate on well developed and well nourished bodies. Realistically this is the exception in head and neck cancer. Further too many wrecks that we've operated on have made it, sometimes defying all the laws of sound science and medical practice. I submit that this is an important paper but where are the criteria and the guidelines as to where we will apply this modality? Have we carefully studied the numbers at this point so we can make a judgement as to where it should be applied? Certainly in the era of cost containment and governmental watch-dogging, we must determine precisely the time and place when we add two weeks of expensive hospitalization. I believe that perhaps the RFP or the NIH has issued studies and hopefully, collaborative studies may bring this into focus and help us to determine when we can add this modality. I'm sure the authors have other cases and I guess they did intimate that and I would like to ask two questions. What are their numbers to date? (I realize there are probably not too many.) And the other is, have they really thought this out as to what cases will they apply this costly modality?

DOUGLAS P. BRYCE, MD (Toronto, Canada): I also have been very interested in the problem of nutrition in head and neck cases and as George suggests we tend to look for some reason for some of them breaking down so badly. We, however, were unable to develop an appropriate protocol to determine whether such alimentation really makes the difference. In other words, you can, of course, give them alimentation one way or the other but you will never really know whether that's helping you. At least it will be very difficult to do so unless you can develop the protocol by which, under controlled circumstances, you will determine whether this actually does help. So I would like to ask the authors, have they got such a protocol whereby they can, in a period of time, compare their results after using hyperalimentation with the results they had before? This is a very difficult thing and perhaps they have the answer and if so I'd like to know it. We have great difficulty in using the intravenous hyperalimentation because of its cost. As Dr. Sisson has said it takes at least two weeks to turn the picture around and that's only before you operate. We

even occasionally have complications after we operate and have to keep this alimentation going on for another two, three or four weeks. This adds tremendously to the cost. I guess in

summing up what I am saying, I'd like to know whether the authors have some way of evaluating the results of this assistance to our treatment of the patients.

EFFECTS OF IRRADIATION ON CERVICAL LYMPH NODES

LOUIS W. WELSH, MD

FRANK CAMPELLONE, MS

JENKINTOWN, PENNSYLVANIA

The effects of irradiation upon the functional integrity of lymph nodes were studied in the isolated cervical region of the dog. After 6000 rads were applied in one dose plan, the measure of lymph flow was determined by the migration of radiogold from the larynx to the associated primary lymphatic terminals at intervals of 2, 4, and 12 weeks, and six months post-irradiation. Interference with lymph flow was identified by radionuclide stasis in the injection depot; alteration in the direction of flow was identified by relative concentration of the tracer item in the associated nodal terminals. The lymph flow was minimally distorted by irradiation in the test period unless secondary damage to the associated lymphatic channels intervened. The relative migration was consistent with the normal data in 52%, depressed in 13% and increased in 35% of the cases studied. Major obstruction and rerouting of lymph flow contralaterally was evident in 19% of the subjects due to fibrosis secondary to local infection.

In this investigation the authors discuss the effects of irradiation on the isolated cervical lymph node of the dog and measure the functional abnormalities due to the ionizing energy. How these data and conclusions apply to human cancer treatment are the topics of this paper.

The goals of this research may be considered by four questions: 1) Is there a difference in the lymph flow through an irradiated regional lymph node? 2) What are the quantitative alterations from the normal lymph flow due to the application of external irradiation? 3) What are the effects of time following irradiation upon the lymph flow? 4) What other experimental factors relate to this problem which modify the alterations due to irradiation?

There is a considerable volume of research literature from 1938 until the present which identifies the morphologic alterations and modifications in lymphatic function secondary to irradiation.¹ Many of the studies are based upon regional or isolated lymph nodes of the lower extremities in animals. Those investigations in humans are concerned with tissue undergoing radiotherapy for malignant disease.

For the purpose of discussion, it is practical to arbitrarily isolate the lymph

vessels from the lymph nodes and to evaluate each on the basis of functional integrity, viz, lymph flow and filtration or barrier effect.

The earliest data of Ariel et al² taken from investigation on the rabbit ear lymphatics pointed to the low sensitivity of the lymphatic vessels to irradiation. Subsequent investigations by Van den Brenk³ who utilized 4000 rads applied in a single dose, indicated no change in the structure and endothelial lining nor was there any obstruction in the lymphatic vessels. When doses in excess of 5000 rads were applied, endothelial swelling and rupture of the lymphatic vessels ensued. Lenzi and Bassani⁴ by contrast with the earlier data, observed that a dosage of 6000 rads was the threshold level for considerable change in the irradiated lymphatic vessel in rabbit uteri. With this dosage and the higher 8000 rads while the lymph vessels appeared tortuous and rigid, the continuity of the lymph vessels was not impaired.

From a functional aspect, the patency of the lymphatic channels can be measured by lymphangiography. Animal programs which irradiated the hind limbs of rats, laryngeal and tracheal lymphatics in the cat, and the pelvic limb of dogs did not identify disturbances in lymph flow. Dosage range

from 2000 to 8000 rads did not impair the continuity of the lymph vessels. Lymphangiographic studies in rats up to one year postirradiation of 3000 rads did not reveal disturbances in lymph flow.⁵ Thereafter, the lymph flow was not obstructed but appeared deviated from the previous course due to adjacent fibrosis.⁵

In the human, the effects of irradiation paralleled those of animals. Cancericidal doses in uterine carcinoma up to 15,000 rads do not alter the lymphatic flow; while doses of about 20,000 rads produce regions of necrosis with consequent interruption of lymphatic flow.⁴ In other human pelvic irradiation studies,⁶ variation from the normal flow patterns are altered by collateral lymphatic circulation and extravasation of contrast. Ariel et al² studied ten patients who had been irradiated with doses of 2000 to 4000 rads in 10 or 23 days from a cobalt-60 source or 2 million volt generator, and noted that while the lymph nodes were greatly destroyed, Ethiodol® passed with a free flow through the pelvis and abdominal regions.

Barrier effects⁷ may be identified by the passage of cells or particles through the lymph node. Among others, human and toad erythrocytes, colloidal gold particles (¹⁹⁸Au), and V₂ tumor cells are used as measures of nodal function. The data on animal nodes as barriers may reflect the agent, tumor cells, or particle size chosen for the study. In the rat, a 3000 rad dose gradually reduced the barrier effect measured by human and toad erythrocytes until one year at which point shunts by-passed the irradiated node.⁵ Two thousand rads applied to the popliteal node in dogs do not alter the barrier function for colloidal gold particles. In this study the authors suggested that a single dose of 6000 rads might be the threshold beyond which the barrier effect is suppressed by radiation treatment.

V₂ tumor cells are effectively trapped in the popliteal lymph nodes of rabbits for at least a two-week period. Following irradiation of 1000 or 3000 rads in two equal portions with a one-week interval, the flow of V₂ cells appears to be modified with distant tumor growth sig-

nificantly increased.⁸ Fischer and Fischer⁹ disputed these data and in their experiment found that irradiation reduced the barrier function of the node for erythrocytes but failed to modify the barrier function for V₂ cells.

In humans, the barrier effects are less well known due to the difficulty in measuring the *in vivo* state. In our studies¹⁰ employing radiogold postirradiation and by body scanning, we identified localization of the tracer item to the injection site (endolarynx) and within the primary lymph node at the superior thyroid neurovascular bundle. Other nodes inferiorly located within the jugular chain failed to be identified by this technique. We have assumed this limitation of flow to be a combined effect of irradiation, but more importantly, secondary to surgery in this region which produced fibrosis and lymphatic obstruction.

Other studies by Fisch¹¹ on the barrier effect of extirpated cervical lymph nodes of humans removed by radical neck dissection, suggest that function may be influenced by preoperative irradiation. By comparison of nodes, one receiving more than 6000 rads and another undergoing 2000 rads less barrier effect was found in the node undergoing higher levels as measured by avian erythrocytes. The time interval also was significant in that there was a tendency to less effective filtration in the 6000-7000 rad levels applied three or more months prior to surgery.

The authors refer the reader to a splendid review by Jovanovic¹ which summarizes much of the historical and current concepts of the influence of irradiation on blood vessels and circulation.

TECHNIQUES, METHODS AND MATERIALS

Several approaches are available which outline lymphatic channels and lymph nodes. The earliest method was by an injection of blue dye into a specific target organ, and by visual inspection identification of the related lymph terminals.¹² This modality provides a qualitative study, and in our earlier research, we observed that a relatively small number of lymph terminals could be identified by the presence of pigment. Other nodal targets in the regional network were not stained by the extreme dilution of the vital dyes. A further

deficiency in this method is that concentration of the dye agent and relative flows to individual target areas could not be computed.

Later, direct infusion of the radiopaque agent within afferent lymphatic channels (lymphangiography) or into regional lymph nodes (lymphadenography) presented the network of the associated lymphatic structures more clearly by radiologic visualization. This study is more appropriate for the paraortic nodes which are otherwise more difficult to appraise than those of the cervical region. Furthermore, by palpation, the status of enlargement, nodularity, and fixation of the cervical lymphatics can be determined without dye infusion. Finally, precise measurement of flow to individual terminals is not possible by this method.

Advances in radioisotopes and application of these tracer items to lymphatic research have simplified the investigation of lymphatic flows and terminals. Quantitative flow patterns have been mapped in the animal¹³ and in normal¹⁰⁻¹⁴ and pathologic¹⁵ states in the human. Total recall of the injection bolus and identification of the deposit areas are possible by this technology. We have employed colloidal radiogold (¹⁹⁸Au) as the isotope of choice due to the favorable characteristics of particulate matter, phagocytosis by the reticuloendothelial system, minimal local reaction, and relatively short half-life (4.5 days).

An analogy could be drawn between the behavior of radiogold particles and metastatic tumor cells in the regional lymphatic system. This model cannot be applied to the activity of malignant cells. The biologic reactivity and immunologic capacity of the normal human and the animal is not compromised in the current study, as may exist in the tumor-bearing individual. The functional competence of the regional lymph nodes is normal in the healthy animals as opposed to the cancer patient where metastatic nodules alter the flow pattern via obstruction or interruption. Finally, there is a great disparity in size between the radiogold particle and the malignant cell. Nonetheless, with awareness of these differences, the gold particle does define the relationship of the endolarynx and the associated cervical lymphatics.

Animals. The dogs weighed from 9-18 kg (20-40 lb).

Surgical Exposure. Under barbiturate anesthesia, the neck was prepared, a midline vertical incision was carried through to the superficial layer of the deep cervical fascia. By blunt dissection and elevation, the single right-sided cervical lymph node, approximately 2-3 cm in diameter, was identified in close proximity to the carotid system. The node was left in place with minimal disturbance of the adjacent connective tissue. A prepared lead shield contoured to expose the lymph node and adapted closely to the margin of the gland was applied and irradiation begun. At the completion of the 6000 rad exposure, the operative field was closed.

Radiation. The animals received 6000 rads at one exposure from a 100 kvp source, 20

mamp, 50 cm distance, with a quality of radiation half value layer 0.5 mm aluminum.

Injection. A specially designed 25 gauge needle, 25 cm long, was adapted to a shielded syringe calibrated in 1/100 ml. The volume of injection of radiogold was 0.02 ml. A standard laryngoscope was inserted and the supraglottic larynx visualized; the instillation of the agent was submucosal and readily became apparent as a blue-gray stain in the tissue. The radius of injection was approximately 2-3 mm and clearly was limited to the intended area, ie, right false cord midposition between the arytenoid cartilage posteriorly and the anterior commissure. The particle size of the radioactive gold was approximately 3 m μ in diameter, the range of activity being from 100 to 400 μ Ci.

Time Flow Studies. The normative data¹³ were derived previously and compared to studies of lymphodynamics at intervals of 2, 4, 6, 12 weeks, and six months following irradiation.

Measurements. This test was designed to measure migration of radiogold from the injection site to the regional lymphatics. We determined previously that the migration would be complete by 48 hours after injection and, therefore, the animals were sacrificed at that time. The cervical nodes were dissected individually, marked as to laterality, and the larynx removed in toto. The animal was scanned for residual activity. None was found in these experiments beyond the cervical region. The nodes and larynx were separately measured in a well-type scintillation counter, Nuclear Chicago, Model 1620C. A numerical value for the total of radiogold was computed and the percentage of material remaining within the larynx was calculated; the quantity in the lymph nodes reflected lymph flow, and the relative concentration of material in right and left nodes indicated the stream pattern. Variation from the standards of right-left flow suggested modification by the irradiation.

DATA

We shall present the results of two experiments at differing intervals postirradiation to illustrate the method of presentation of data and, thereafter, the composite data for the complete series.

The first specimen displayed an extralaryngeal flow of 35% of the radionuclide with the residual of 65% of the total mass located in the depot site of injection. These data for isotope migration fall within the control range of 30 to 50%.

In Figure 1 we note that the nodal concentration is 76% right and 24% left which exceeds the normal distribution, ie, 10% or less crossing contralaterally.

The second specimen suggests 44% of the injection located in the target area

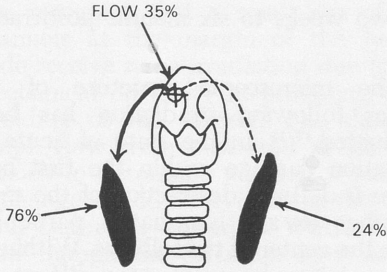


Fig. 1. The flow of radiogold via the lymphatics is measured from the injection site and represents 35% of the total; 76% stream along the ipsilateral channels and 24% contralaterally.

of the larynx and a stream of 56% to the related lymph nodes.

Figure 2 shows that the direction of lymph flow is altered from the standard functional pattern with the preponderance of radionuclide terminating in the contralateral node. This is statistically evident as 25% measured in the ipsilateral node with a disproportionate concentration of 75% in the contralateral cervical gland.

We shall now view the composite data for the studies on 25 irradiated animals and ten unchallenged dogs as controls. The first parameter of this investigation is the percentage of lymphatic spread from the larynx computed by the concentration of radionuclide in the regional cervical lymph nodes. We find a normal appearance of the irradiated node, although shrunken in comparison with the control nodes, cervical contents, and larynx when there is no secondary disturbance due to the trauma of surgery or infection. There is evidence at second-

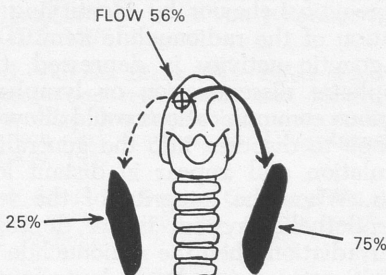


Fig. 2. The majority (56%) of the tracer material migrates from the larynx. An obstructive phenomenon of contralateral flow (75%) is evident with 25% terminating in the ipsilateral cervical node.

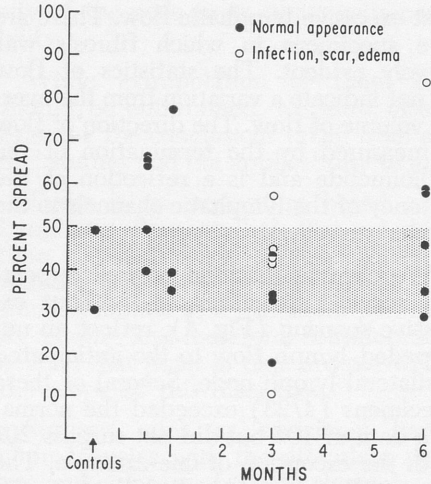


Fig. 3. Lymphatic spread. The composite data of 23 studies indicate 12 are within control data, 8 suggest greater tracer spread, and 3 depressed migration.

dary surgery of mild adhesions of the skin flaps to the superficial surface of the lymph node and a severe dipylatory effect beneath the irradiated node corresponding exactly to the portal field. Infection, excessive scar, and edema are clinical findings which are secondary to the regional infection introduced at the time of the primary surgery.

As indicated in Figure 3, there were 23 subjects and 12 fell within the normally expected range (30-50%). Three were noteworthy in that the flow was substandard, and the residual eight sug-

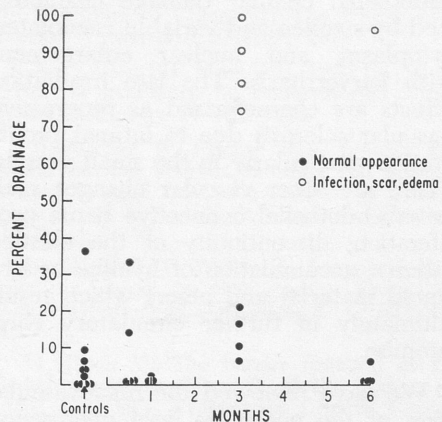


Fig. 4. Crossed lymph drainage suggests obstruction to normal lymphatic channels. Five studies deviate widely from control data due to lymphatic scarring.

gest excessive lymphatic flow. There are five specimens in which fibrosis was grossly evident. The statistics of flow do not indicate a variation from the overall volume of flow. The direction of flow is measured by the termination of the radionuclide and is a reflection of the patency of the lymphatic channels to the normal terminals.

We observe that the normal appearing cervical structures, ie, without excessive scarring (Fig. 4), reflect an unimpeded lymph flow to the anticipated ipsilateral lymph node. Several of these specimens (4/23) exceeded the normative data of 10% but did not surpass 20% with the exception of one example. The abnormally scarred studies illustrate the extensive interruption of flow with the lymph-borne isotope terminating contralaterally between 75 and 100%.

This study would be incomplete without histologic analysis of the irradiated lymph node. The tissues were stained by standard hematoxylin and eosin and Masson's trichrome techniques to define the cellular morphology and presence of fibrous tissue.

We shall consider the changes observed in the vascular structures, lymph nodules, and the medullary region of the nodes. The effects should be viewed on a temporal basis; that is, early and late changes.¹⁶

The early vascular changes involve primarily the microvasculature with endothelial cellular damage characterized by swollen and variably vacuolated cytoplasm, and nuclear enlargement with karyorrhexis. The late irradiation effects are characterized as progressive vascular sclerosis due to intimal proliferation particularly in the small vessels. There are other vascular changes such as subendothelial connective tissue proliferation, discontinuity of the elastica interna, accumulation of hyaline or fibrinoid material and others which result ultimately in further circulatory compromise.

We have reviewed the microvasculature of the nodes by light microscopy and find the vessels to be fully patent, without evidence of endothelial damage, or perivascular fibrosis, and consistent with the control nodes within the period

of two weeks to six months postirradiation.

The microscopic structure of the nodes following irradiation has been evaluated.¹⁷⁻¹⁸ In the state of acute irradiation damage within the first hour there is definite destruction of the small lymphocytes and lymphatics, particularly in the center of the follicles. Within six hours, injury becomes more diffuse, involving the entire lymph node with depletion of the lymphocytes. There is destruction of the cells in the center of the follicle which gradually extends into the margin, and at three days a scant number of lymphocytes remain superimposed upon a structure of reticular cells and a few plasma cells. As recovery takes place, a return to the former normal architectural and cellular design develops.

In this study the analysis of the architecture at two weeks and six months postirradiation reveals no significant differences in the large lymphatic nodules. The structure of the medullary area differs over the time base, namely, the two-week study reflects a very cellular infiltrate in the sinusoidal areas. In the latter period there is edema and widening of the sinusoids without the cellular density of the earlier area.

DISCUSSION

The functional capacity of a lymph node may be measured by cell perfusion or by particles which pass through the afferent lymphatic channels; and into the lymph nodes for filtration or phagocytosis. For quantitative purposes the authors have selected radiogold because exact measurements can be made of phagocytic behavior by identifying the location of the radionuclide item. If the phagocytic activity is depressed, then lymphatic dissemination or lymphaticovenous communications could allow the isotope to disperse into the generalized circulation and appear in distant locations. When the integrity of the reticuloendothelial system is not depressed by irradiation, then the radionuclide and its ultimate course should be consistent with the normative data.

The experimental plan was designed to irradiate selectively the lymph node while sparing the lymphatic channels.

We recognize that a small rim of the channels at the margin of the lymph node receive some irradiation due to the mechanical difficulty in providing total shielding of the vessels. The data of lymph flow were measured at selected periods to determine whether a pattern of change would be evident as the temporal basis was extended. We find that even though the direction may be severely reversed, there is little evident obstruction to lymph flow from the larynx. This is due to the fact that collateral channels are utilized and that alternative directions of flow exist.

The main factor of damage to the lymphatic channels brings about flow disturbances through collateral or alternative streams rather than damage to the functional integrity of the node. Damage in this series is a consequence of infection and subsequent scarring.

The morphology of the lymph nodes is not greatly modified from the normal. We note little if any difference in the composition of the germinal centers and lymph nodules. Sinusoidal hyperplasia with dilatation of the sinusoid is apparent with a marked plasmacytosis in this region in the six-month studies; the more recent postirradiation nodes suggest increased cellularity and less change in the sinusoidal configuration. In spite of these morphologic differences, there is no difference in the functional capa-

city of the node in its phagocytic capability.

While extrapolation of these data should be entertained, we must closely examine the conclusions taken from animal studies and the applicability to man.

There is no suggestion based upon lymphatic flow studies that an ideal time for definitive surgery following radiotherapy can be identified. The study is limited to a maximum period of six months, and therefore, considerations beyond that point in time are not within the scope of this discussion.

Surgery, such as excisional lymph node biopsies with the attendant damage and stricture of lymph channels, can modify the metastatic behavior of cancer cells from the primary location. As a consequence, secondary deposits of tumor may locate in less surgically accessible areas such as the most cephalic deep cervical lymph nodes adjacent to the jugular foramen, or descend into the mediastinum. From a clinical aspect surgical interference which transects lymph channels should be avoided until the definitive procedure is undertaken. There is no evidence from this study that a "sealing-off" of lymphatics would develop when radiotherapy is selected as the primary modality of care and the regional lymphatic field is widely covered by irradiation to control micro-metastasis.

REFERENCES

1. Jovanovic D: The influence of radiation on blood vessels and circulation. *Curr Top Radiat Res* 10:85-97, 1974
2. Ariel IM, Resnick MI, Oropeza R: The effects of irradiation (external and internal) on lymphatic dynamics. *Am J Roentgenol* 99: 404-415, 1967
3. Van den Brenk HAS: Effect of ionizing radiations on regeneration and behavior of mammalian lymphatics: In vivo studies in sandison clark chamber. *Am J Roentgenol* 78: 837-849, 1957
4. Lenzi M, Bassani G: The effect of radiation on the lymph and on the lymph vessels. *Radiology* 8:814-817, 1963
5. Engeset A: *Irradiation of Lymph Nodes and Vessels*. Universitets for Laget, Oslo, 1964
6. Markovits P, Blache R, Gasquet C, et al: Les images radiologiques des lymphographies faites apres irradiation. *Ann Radiol* 12: 835-847, 1969
7. Rubin P: Comment: The lymph node barrier. *JAMA* 213:104-107, 1970
8. O'Brien PH, Moss WH, Ujiki GT, et al: Effect of irradiation on tumor-infused lymph nodes. *Radiology* 94:407, 1970
9. Fischer B, Fischer ER: Lymph and blood vascular systems in tumor cell dissemination, in Ariel IM (ed): *Progress in Clinical Cancer*, vol 4. New York, Grune and Stratton, 1970, pp 84-97
10. Welsh LW, Welsh JJ: Laryngeal lymphatics, human in vivo studies. *Trans Am Acad Ophthalmol Otolaryngol* 67:524-530, 1963
11. Fisch V: The barrier function of the lymph nodes in the neck of the human, in Ariel IM (ed): *Progress in Clinical Cancer*, vol 4. New York, Grune and Stratton, 1970, pp 97-108
12. Rouviere H: *Anatomy of the Human Lymphatic System*. Ann Arbor, Mich, Edwards Brothers Inc, 1938

13. Welsh LW, Welsh JJ, Behlke FM: Surgical alterations of the laryngeal lymphatics. *Ann Otol Rhinol Laryngol* 70:52-56, 1961
14. Welsh LW: The normal human laryngeal lymphatics. *Ann Otol Rhinol Laryngol* 73:569-584, 1964
15. Welsh LW, Welsh JJ: Cervical lymphatics: Pathologic condition. *Ann Otol Rhinol Laryngol* 75:176-193, 1966
16. White DC: The histopathologic basis for functional decrement in late radiation injury in diverse organs. *Cancer* 37:1126-1144, 1976
17. Krayevskii NA: *Studies in the Pathology of Radiation Disease*. New York, Pergamon Press, 1965
18. Rubin P, Casarett GU: *Clinical Radiation Pathology*. Philadelphia, WB Saunders, 1968

ACKNOWLEDGMENT — The authors are indebted to George C. Henny, MD, Professor of Radiation Physics, Temple University Medical Center, and Dean M. Lierle, MD, for his support in the early stages of this research.

REPRINTS — Louis W. Welsh, MD, 179 Washington Lane, Jenkintown, PA 19046.

RADIATION FIBROSIS AND NECROSIS OF THE LARYNX

JAMES R. CHANDLER, MD

MIAMI, FLORIDA

The deleterious effects of ionizing radiation upon the normal tissues of the larynx, even when it is not the specific target of the radiation therapist, are always apparent to the observant and experienced laryngologist. On occasions they are so marked as to obscure the diagnosis of concomitant persistent or recurrent cancer. There is a direct relationship between the number of rads delivered and the severity of the subsequent radiation reaction. A system of classifying such reactions is proposed. Grade 0 is normal. Grades I and II are expected. Grades III and IV may be considered complications and require specific and even energetic treatment. In grade IV reactions, which require operative intervention, laryngectomy may be the treatment of choice.

Therapeutic radiation therapy for epidermoid carcinoma of the larynx invariably results in some degree of reaction in the normal tissues immediately adjacent to the tumor. In fact, whenever treatment is given in sufficient doses to destroy cancer, all normal tissues in the path of the beam will be permanently damaged.¹ This includes skin and all deep tissues. There is increased vascularity, redness and local tenderness. There is local discomfort and during the administration of the radiation therapy, there is increasing local edema, hyperemia, and inflammatory changes within the mucosa and in the laryngeal structures themselves. These changes are due to an inflammatory reaction characterized by infiltration of polymorphonuclear leucocytes, vascular thromboses, and obliteration of lymphatic channels. Late changes consist of telangiectases of the skin, alopecia, loss of subcutaneous fat, degenerative changes in the connective tissues, and marked endarteritis of smaller blood vessels. The extent of all of these changes depend upon the amount of radiation therapy delivered, the field sizes, and the time interval. Higher doses, shorter time periods, and larger portals lead to progressively greater soft tissue reaction and more marked late changes. While megavoltage radiation therapy spares the skin somewhat, the deeper structures of the neck and larynx itself are not spared. The relationship be-

tween the amounts of radiation therapy delivered and the likelihood of permanent significant damage to the surrounding normal tissues is shown in Figure 1.

These changes result in local discomfort and hoarseness as well as dryness, dysphagia, and the sensation of a lump in the throat. Upon the completion of radiation therapy, most or all of these symptoms may gradually subside with the passage of time. Most commonly, some hyperemia and edema of both true vocal cords and surrounding tissues remain and are accompanied by some hoarseness.

When the radiation therapy includes the larynx as it is administered to full neck fields, the hypopharynx or to the base of the tongue, the same reactions and symptoms result.² In some instances, these reactions subside gradually only to undergo exacerbations as long as 25 years following its completion.

Clinical Features. The patient undergoing radiation therapy which includes the larynx, usually experiences no symptoms until he has been treated five to ten days. About then, he develops the sensation of a lump in his throat and some local tenderness which is accentuated on swallowing and prolonged use of the voice. Examination reveals slight hyperemia and edema of the mucosa and of the larynx and skin of the neck. These symptoms and signs grad-

From the Department of Otolaryngology, University of Miami School of Medicine and Jackson Memorial Hospital, Miami, Florida.

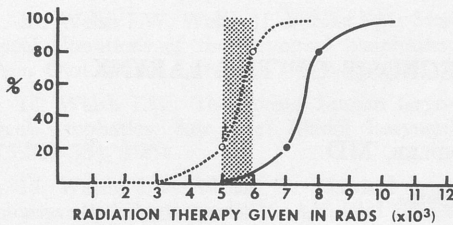


Fig. 1. The dotted line indicates the local control (cure) rate; the solid line, incidence of significant damage to normal tissues (necrosis); the shaded area, the therapeutic range of radiation therapy wherein a cure rate of 80% incurs a reasonable complication rate of about 12%. Attempts to increase the cure rate result in a sharp increase in the complication rate and incidence of frank necrosis.

usually progress as radiation therapy is continued and usually reach their peak about the conclusion of therapy. At this time, there is marked redness, edema, and loss of hair from the skin over the larynx. There is tenderness on palpation. There is edema and redness of all mucosa of the larynx. There may be, and usually is, some impairment of motion of the larynx with some decrease in airway. There is usually a fibrinous exudate with a patchy distribution over the endolarynx and hypopharynx. These changes are always more intense in the area of the tumor itself and are aptly described as "tumoritis." Symptoms are usually exacerbated by continued smoking and may lead to a significant loss of weight.

Symptoms and signs gradually subside over the succeeding two to six weeks when some hyperemia of the mucosa and slight edema of the structures of the larynx may remain, along with some slight subsiding redness of the skin. The soreness and difficulty on swallowing usually subside by this time. If the treatment has included only the larynx, symptoms referable to swallowing are usually minimal. Larger fields result in atrophy of the parotid and other salivary glands and lead to xerostomia and resultant dysphagia.

Signs and symptoms continue to subside over the succeeding months and years, and in some patients, particularly those with glottic tumors, disappear completely. Examination of the larynx reveals perfectly normal structures. The skin of the neck itself may appear to be

perfectly normal although a slight edema of the subcutaneous tissues usually betrays previous radiation therapy.

Edema persists to a variable degree in a significant number of patients. Larger tumors which require larger treatment fields will be associated with more persistent changes. Infiltration of the cartilage by tumor or previous surgical trauma contributes to these changes.³ Webs may develop in the anterior commissure as a result of the denuding effect of therapy. Limitation of cord motion may be the result. Edema is by far the most common manifestation of persistent radiation damage.⁴ It is due to the factors described previously. Progressive endarteritis of small arteries and veins leads to fibrosis of the subcutaneous tissues and muscles of the larynx as well as overlying mucosa. Atrophy of the cords may result. Telangiectases and hyperemia of one or both vocal cords is common.

More severe changes relate to the resultant ischemia of tissues. With upper respiratory tract infections, with or without surgical trauma of the laryngeal structures, infection can enter the soft tissues and lead to progressive necrosis and slough of soft tissues and cartilage. This results in an exacerbation of all symptoms and particularly the appearance of marked fetor oris. If not treated properly, these lead to progressive loss of weight, loss of the protective function of the larynx with aspiration and pneumonia, progressive inanition and death.

Diagnosis. The diagnosis of radiation fibrosis and necrosis of the larynx is not usually a problem. However, the determination of whether or not underlying residual or recurrent carcinoma, which may be masked by the edema and other changes described previously, constitutes a real enigma and diagnostic problem. It requires a very astute and alert clinician to make this determination. The height of the radiation reaction usually coincides with the end of radiation therapy and begins to subside rapidly thereafter. In most cases, the marked mucosal reactions gradually subside so that the larynx becomes near normal. The larynx should be observed carefully at frequent intervals in order to de-

termine that the changes induced in the larynx as a result of radiation therapy do subside as the normal tissues heal. A certain amount of residual changes, consisting of some hyperemia and slight edema, is to be expected. Monthly observation of such patients will demonstrate that in the majority of them, such changes gradually subside and improve steadily with the passage of time. It has been my observation that when the neoplasm has been eradicated and remains eradicated, the laryngeal structures and laryngeal function return to normal or near normal. Some larger lesions, and those which involve transglottic structures as well as the hypopharynx, are more likely to result in permanent distortion and impairment of mobility as well as persistent edema. Reappearance or increase in edema or any of the signs and symptoms discussed herein should be considered as possible and probable recurrence of the neoplasm rather than radiation-induced changes alone. The dilemma of the laryngologist is that persistent or recurrent carcinoma may exist hand in hand with the radiation necrosis. The proving of recurrent carcinoma in such instances is frequently a difficult and frustrating task. Furthermore, repeated diagnostic intralaryngeal forays may result in converting edema and ischemic fibrosis into frank necrosis.

Incidence. It is very difficult to determine the true incidence of radiation necrosis of the larynx owing to the above described factors. The presence of persistent or recurrent carcinoma in a radiated larynx leads to necrosis of the tumor itself as well as adjacent radiated tissues as the tumor infiltrates them. Even the skilled laryngologist has difficulty in such instances in determining the optimum site of biopsy for histologic diagnosis of suspected tumor. Because severe edema has been described as a complication of radiation therapy and has been included in some figures with actual necrosis of tissues as well as recurrent and persistent tumor,^{5,6} no true incidence of this complication can really be established. At the University of Miami School of Medicine and Jackson Memorial Hospital Medical Center, we have experienced approximately 12% serious reactions sec-

TABLE 1. SEVERE RADIATION REACTIONS OF THE LARYNX IN UNSELECTED SERIES OF PATIENTS TREATED FOR CARCINOMA OF LARYNX AND HYPOPHARYNX

Number of patients treated	122
Grade III reactions	13
Grade IV reactions	2
Deaths	1
Incidence of complications	12%

ondary to radiation therapy. Some of these were associated with recurrent and persistent tumor (Table 1).

Classification and Grading System. Most of the acute side effects and reactions of the normal tissues subside within three months following conclusion of therapy. In the event that the tumor has not disappeared by six weeks, or significant residual abnormality of the larynx remains, then persistent tumor should be suspected and proven by histologic examination of appropriate biopsy specimens, and appropriate surgical therapy instituted promptly. In most instances, this would consist of a total laryngectomy. If the neoplasm has disappeared, a similarly careful assessment of what might be called the post-radiation therapy state of the larynx should be determined. Depending upon the size of the original lesion, the amount of radiation therapy delivered, and size of fields, one can expect a variable number of residual changes and symptoms. I propose that these be graded by a system of Roman numerals, I through IV reserving 0 for the normal appearing larynx with no symptoms (Table 2). The postradiation therapy state should be assessed at regular intervals thereafter and assignment to various grades made accordingly.

In grades I and II would be those patients with slight to moderate symptoms and changes on clinical examination of the larynx. They would be the expected side effects of the radiation therapy and are due to the permanent damaging effects of the ionizing radiation therapy on normal tissues. No treatment is indicated. Patients with more extensive changes are assigned to grades III and IV. These are considered complications of radiation therapy. Assignment of any

TABLE 2. GRADING SYSTEM FOR RADIATION REACTIONS OCCURRING IN THE LARYNX AND LARYNGOPHARYNX

<i>Grade*</i>	<i>Symptoms</i>	<i>Sign</i>	<i>Treatment</i>
0	None	None	None
I	Slight hoarseness; slight dryness	Slight edema; telangiectasis	None
II	Moderate hoarseness; moderate dryness	Slight impairment of cord mobility, moderate edema and erythema	None
III	Severe hoarseness with dyspnea; moderate odynophagia and dysphagia	Severe impairment or fixation of at least one vocal cord, marked edema, skin changes	Steam; antibiotics
IV	Respiratory distress; severe pain; severe odynophagia; weight loss; dehydration; fever	Fistula, fetor oris, fixation of skin to the larynx, laryngeal obstruction, edema occludes the airway, toxicity	Tracheotomy and/or laryngectomy

*Grades I and II are expected side effects of radiation therapy delivered in therapeutic amounts to this region whether or not it is the site of the lesion receiving treatment. Grades III and IV are complications.

patient to a higher group with the passage of time suggests progressive radiation damage and/or recurrence of the neoplasm. These should be considered complications of therapy. They consist mostly of edema and fibrotic changes in the less severe reactions and of frank necrosis in the more severe.

I have found this grading system to be practicable and have employed it with success for the past two years in this medical center. Classifying in a retrospective fashion an unselected group of patients with carcinoma of the larynx and hypopharynx treated for cure in the past eight years, we have experienced a total of 13 grade III reactions and 2 grade IV reactions. One of the latter died as a result of extensive uncontrolled necrosis involving all tissues of the neck including the vertebrae and carotid arteries following laryngectomy (Table 1).

Treatment. No treatment at all is required or suggested for grades 0, I and II. Those patients with grade III reactions should be treated with humidity and steam inhalations, culture and sensitivity studies, appropriate antibiotics, steroids in the absence of frank infection or necrosis, and in general, with supportive and expectant therapy. Hyperbaric oxygen therapy may reverse a progressive change in the absence of neoplasm.^{7,8}

Those patients who develop frank necrosis require aggressive surgical therapy including tracheotomy. Because of the difficulty in proving or disproving

the presence of carcinoma, total laryngectomy with or without histologic proof, is frequently indicated. In this group of patients, the larynx frequently becomes totally useless and incompetent. A tracheotomy is necessary with its resulting problems of hygiene. Aspiration through an incompetent glottis may lead to pneumonitis, fever, inanition and debility. Marked pain interferes with nutrition and uncontrolled necrosis of tissues invites extension into adjacent tissues, including great vessels. Useful speech is lost in such patients as total glottic obstruction frequently results from marked edema of surrounding tissues. In addition, the necessity of a cuffed tracheotomy tube to decrease the hazards of aspiration also impedes useful phonation.

DISCUSSION

The laryngologist is devoted to preserving the larynx and its function. Consequently, the concept of extirpating the human larynx in the absence of definite histologic proof of cancer is anathema. In the absence of such proof, conservative treatment of radiation fibrosis and even early necrosis is suggested. Voice rest, steam, increase in humidity, application of local heat, culture and sensitivity studies with specific antibiotic therapy if possible, and even steroids have been reported as being beneficial. There seems to be a place for hyperbaric oxygen therapy although its general unavailability limits its usefulness. Conservative operative procedures consisting of removal of the necrotic cartilage and

other tissues has been advocated.⁹ Occasionally, the necrotic tissues slough and the process is self-limited. One instance in which this occurred resulted in a laryngocutaneous fistula. The fistula was subsequently repaired by local rotation flaps with preservation of laryngeal function.* Inasmuch as frank necrosis is precipitated by bacterial infection in traumatized tissue with greatly reduced healing powers, one should not lightly undertake vigorous surgical manipulations of nonulcerated, heavily irradiated tissues.⁶ However, in spite of this, it has been advocated that earlier and frequent biopsies be performed because of the high incidence of residual carcinoma in such patients.³ Multiple biopsies are advocated by others.⁴ The frequent presence of recurrent carcinoma with, or masqueraded by, radiation necrosis has been emphasized.⁴ Delay in diagnosis results in a poor prognosis for these patients.

I recall a 72-year-old male who had been treated three years previously with cobalt teletherapy for a right glottic lesion. He did well for two years, then developed progressive hoarseness, odynophagia, 9.10 kg weight loss, local pain and finally a laryngeal fistula and a malodorous, objectionable, purulent discharge. Three previous laryngoscopic procedures and biopsies had failed to confirm the presence of recurrent neoplasm. Progressive dyspnea and the advice of yet another laryngoscopy, biopsy and tracheotomy prompted consultation. In lieu of tracheotomy, etc, I advised a total laryngectomy which was performed forthwith. Convalescence was prompt and a grateful patient was the result. Histologic examination of the surgical specimen revealed extensive radiation necrosis of soft tissues and cartilage but no residual tumor.

Another example is that of a 17-year-old male who was seen in consultation 1½ years following radiation therapy for a carcinoma of his left vocal cord. After one year of doing relatively well, he developed local pain and tenderness, increasing hoarseness, odynophagia and dysphagia. Two previous attempts at biopsy and confirmation of recurrent tumor had resulted only in reports of ne-

crotic tissue. Examination of his larynx revealed marked distortion of all structures, a marked fetor oris, and a marginal airway. There was redness and fixation of the skin over the larynx, and marked tenderness on motion of all laryngeal structures. Because of his age, confirmation of the diagnosis of recurrent carcinoma was suggested. Again this was unsuccessful. A tracheotomy had been necessary and laryngectomy was then advised. The patient and his parents refused and sought additional consultation. Another biopsy elsewhere was positive only for necrotic tissue. A laryngeal fistula appeared and the patient sustained a weight loss of 6.85 kg. A very difficult operative procedure was then performed at which time the larynx and adjacent tissues in the left side of his neck were removed. A control fistula failed to avoid subsequent necrosis of soft tissues and a carotid blowout. He survived this and the half-dozen surgical procedures necessary to restore continuity of his pharyngoesophageal tract and remains well, free of disease ten years after his surgery.

Two other patients in my own experience with the past 18 years have died as the result of extensive necrosis of cartilage, bone and soft tissues of the larynx. Neither had carcinoma and both died as a result of carotid blowouts following a complicated postlaryngectomy surgical course.

Delay in diagnosis of recurrent carcinoma following radiation therapy may decrease the otherwise excellent chance of surgical salvage. Prompt recognition is important in maximizing the salvage rate. Furthermore, it may provide the opportunity for conservation surgery in selected instances. The changes secondary to radiation fibrosis may obscure recurrent carcinoma for a while. Frank necrosis renders the diagnosis of recurrent carcinoma even more difficult. The changes of radiation fibrosis are permanent. Occasional exacerbations of the signs and symptoms of radiation fibrosis precipitated by upper respiratory tract infections or local trauma may be reversed by appropriate conservative therapy as discussed previously. On the other hand, when frank necrosis has occur-

*Richardson R: Personal communication.

red, return of laryngeal function is not likely. In addition, local pain and tenderness interfere greatly with the patient's quality of life. Progressive laryngeal obstruction may require a tracheotomy. Pain on swallowing leads to weight loss and inanition. Local discomfort becomes progressively more severe. Progressive changes interfere with phonation. Because of loss of laryngeal function in protecting the lower airway, a cuffed tracheotomy tube is frequently necessary to avoid aspiration and in itself prevents the use of the voice. To delay extirpation of an irreversibly crippled larynx until histologic proof of cancer has been secured allows progression of necrosis and infection and invites disaster. In addition, it permits unchecked growth of the concomitant neoplasm, if present, and may result in uncontrollable distant metastases. For all of these reasons, I suggest that a laryngectomy is the treatment of choice. This will eliminate all of the above symptoms and at the same time remove any carcinoma present. It is appropriate and definitive treatment and can result in the saving of much human misery.

SUMMARY

Therapeutic radiation therapy for carcinoma of the larynx always results in some damage to the normal tissues. This damage may be slight and inconsequential. More extensive damage results in hyperemia and edema of laryngeal structures. Severe damage is manifested by more edema, limitation of laryngeal function and respiratory obstruction. Frank necrosis of cartilage and soft tissues supervenes with added infection or with more extensive damage. Severe reactions obscure the diagnosis of concomitant persistent or recurrent tumor.

A system of classifying such radiation therapy damage and reactions of the larynx is proposed wherein grade 0 is considered normal. Minor and intermediate changes are classified in grades I and II. Grade III consists of fibrotic changes and requires specific conservative treatment. Grade IV requires surgical management. Because of the frequent concomitant presence of recurrent carcinoma, positive histologic proof is not necessary prior to the indicated procedure of total laryngectomy.

REFERENCES

1. Deland EM: Radiation damage to tissue and its repair. *Surg Gynecol Obstet* 72: 372-383, 1941
2. Morrison R: Review article-Radiation therapy in diseases of the larynx. *Br J Radiol* 44:489-504, 1971
3. Calcaterra TC, Stern F, Ward PH: Dilemma of delayed radiation injury of the larynx. *Ann Otol Rhinol Laryngol* 81:501-507, 1972
4. Ward PH, Calcaterra TC, Kagan AR: The enigma of post-radiation edema and recurrent or residual carcinoma of the larynx. *Laryngoscope* 85:522-529, 1975
5. Fletcher GH, Klein R: Dose-time-volume relationship in squamous-cell carcinoma of the larynx. *Radiology* 82:1032-1042, 1963
6. Goodrich WA, Lenz M: Laryngeal chondronecrosis following roentgen therapy. *Am J Roentgenol Radium Ther Nuclear Med* 60:22-28, 1948
7. Farmer JC Jr, Shelton DL, Bennett PD, et al: Treatment of radiation-induced tissue injury by hyperbaric oxygen. *Ann Otol Rhinol Laryngol* 87:707-715, 1978
8. Davis JC, Dunn JM, Gates GA, et al: Hyperbaric oxygen: A new adjunct in the management of radiation necrosis. *Arch Otolaryngol* 105:58-61, 1979
9. Litton WB: Preservation of a radionecrotic larynx by excision of thyroid cartilage with flap coverage. *Laryngoscope* 88:1947-1949, 1978

REPRINTS — James R. Chandler, MD, Department of Otolaryngology, Miami School of Medicine and Jackson Memorial Hospital, Miami, FL 33136.

BILATERAL HYPOGLOSSAL NERVE PARALYSIS AFTER IRRADIATION THERAPY

WILLIAM H. SAUNDERS, MD

SHEILA E. HODGSON, MD

COLUMBUS, OHIO

Cancericidal doses of irradiation therapy to the head and neck may be followed by paralysis of cranial nerves due to fibrosis of tissue about the nerves and infiltration of the nerves with fibrous tissue. The hypoglossal nerve is particularly prone to this delayed effect of irradiation therapy and a case is presented here in which there was bilateral hypoglossal paresis appearing three years after therapy.

Patients with malignant disease of the head and neck, especially the nasopharynx, who are treated with irradiation therapy and then later develop a cranial nerve palsy usually prove to have recurrence of their malignancy, and die of that disease. Although peripheral and cranial nerves are generally considered to be relatively radioresistant and are not commonly injured even when large doses of radiation are delivered, neural injury may be produced by cancericidal doses of irradiation. Thus it is necessary to distinguish between these two causes of cranial nerve palsy after treatment of malignant lesions of the head and neck by radiotherapy.

Necrosis of the brain due to radiation therapy and radiation myelopathy of the spinal cord have been reported sporadically for several decades.^{1,2} In addition to the spectacular and irreversible transverse lesions of the spinal cord, fortunately uncommon, milder symptoms such as paresthesia and weakness of the extremities are common, though they often go unnoticed because of concomitant and more taxing symptoms. Taken together one author gives a total incidence of 2.4% for spinal cord injuries in patients subjected to intense irradiation. In the milder reversible cases, symptoms usually appear three to six months after completion of irradiation. They tend to be aggravated by flexion of the neck (Lhermitte's sign) which may produce

an electric shock-like paresthesia in the extremities.

The following report describes a patient who, 3½ years after completing irradiation therapy, developed bilateral hypoglossal nerve paresis, the first report of a bilateral instance.

In 1974, a 26-year-old Caucasian male discovered a mass in his upper neck which was biopsied and reported as undifferentiated squamous carcinoma. Later, nasopharyngeal examination showed a primary lesion predominantly on the left side. Another biopsy here was reported as lymphoepithelioma. There were no cranial nerve palsies and, other than the large neck mass and two smaller adjacent masses, there was no evidence of regional or distant metastatic disease.

The patient was entered in a national clinical trial to investigate the value of split-course radiation versus continuous-course radiation. His case was randomized to receive the split course. This regimen was planned to deliver a tumor dose of 6000 rads in 20 fractions, with a three-week break after the first ten fractions. Overall treatment time was to be 49 days. The patient was treated from February 14 to April 12, 1974, and received a midplane tumor dose of 6000 rads in 56 elapsed days (1,925 rets). A 4 meV linear accelerator was used with equally loaded parallel opposed fields.

From the Departments of Otolaryngology and Radiology, The Ohio State University, Columbus, Ohio.

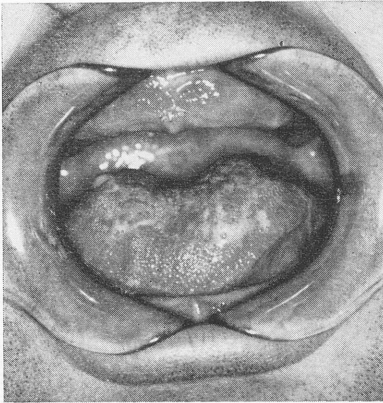


Fig. 1. Maximum protrusion of tongue. Tip barely reaches lower gingiva.

Fields 12x20 cm were used, covering the nasopharynx and cervical region. The fields were reduced to 6x11 cm after ten treatments to avoid the spinal cord, and a single anterior field was added to treat the lower neck and supraclavicular area, using a midline shield for the spinal cord. The patient had a severe mucosal reaction after ten treatments, which subsided during the three-week break. After five treatments of the second series, treatment was again discontinued for ten days because of mucosal reaction, severe difficulty in swallowing and weight loss of 6.8 kg. The patient lost a total of 10.4 kg during the entire treatment course. Immediately following the radiation, he had severe xerostomia and loss of taste, but after one year these symptoms were gradually improving.

After his irradiation therapy the patient did well and worked full-time until September 1977, a period of 3½ years. Then he began to complain of severe right-sided neck, jaw and ear pain requiring codeine for relief. The pain lasted two months, then cleared completely, but was followed in December 1977 by fasciculation and weakness of the side of the tongue. The patient complained he no longer could whistle. Three months later *both* sides of the tongue were paretic.

The patient was readmitted to the hospital for thorough neurological and diagnostic radiologic examination. All was clear except for the clinical finding of bilateral hypoglossal paresis which

was confirmed by an electromyographic examination showing "bilateral severe paralysis of tongue. Our diagnosis was bilateral hypoglossal nerve atrophy after irradiation therapy (Fig. 1).

Various writers attribute nerve palsies after irradiation to perineural fibrosis rather than to any direct effect on the nerve itself. Thus, consideration was given to decompression of one or both hypoglossal nerves which, we assumed, were imbedded in and infiltrated with scar tissue. No surgery was done and the patient was treated instead with a two-week course of prednisone which did not help. The tissue of the neck remained firmer than normal but never was "woody" or stiff. The patient has continued to work and hold his weight and has no evidence of local or metastatic disease more than five years after his course of irradiation therapy. He speaks reasonably distinctly but does have trouble with mastication and swallowing of solids.

DISCUSSION

The hypoglossal appears to be the most frequently affected of the cranial nerves after exposure of the neck to irradiation therapy. Bataini et al reported the first instance of injury to the hypoglossal nerve in 1974,³ followed by four case reports of unilateral paralysis by Cheng and Schultz in 1975.⁴ An additional 16 unilateral isolated hypoglossal nerve paralyses were reported by Berger and Bataini⁵ who also reported 3 others (making a total of 19 hypoglossal paralyses), in which paralysis of the hypoglossal nerve was associated with 10th, or 10th and 11th nerve paralysis. In their patients irradiation dosage to the nerve varied from 6,250 rads in 41 days to 10,000 rads in 43 days. The interval between irradiation therapy and onset of paralysis in their cases tended to be significantly greater than in our case, and ranged from 3 years to as long as 12 years. The authors note, however, that the exact time of onset of the paralyses often was unknown. In the report by Cheng and Schultz⁴ the interval between therapy and paralysis (four patients) was from six to nine years. Thus it seems unlikely for cranial nerve palsy resulting from irradiation therapy to appear in less than three years.

Paralysis or injury of other cranial nerves is reported much less frequently than hypoglossal injury. Optic nerve damage is reported four times,^{5,6} abducens damage once,⁷ eighth nerve damage as manifested by sensorineural hearing loss in 11 cases,⁸⁻¹⁰ vagus nerve alone in 3 cases,⁵ and in a combination with nerves XI and XII in six cases.⁵ Speiss¹¹ described an instance of 11th and 12th nerve palsies.

Laurent¹² described four cases of femoral nerve compression with paresis of the quadriceps muscle caused by radiotherapy. Earlier, similar lesions in the upper extremities had been described

and attributed to compression of the brachial plexus after irradiation therapy for cancer of the breast.¹³⁻¹⁶ Laurent's report also is of interest because he describes pain as the first symptom followed by loss of quadriceps strength some months later. This also was the sequence in our case of bilateral hypoglossal nerve paresis in which pain was the most dramatic symptom until it resolved spontaneously after two months. In one of Laurent's cases a decompression of the femoral nerve was performed and the nerve found to be compressed by scar tissue. The operation did not improve the paresis but did relieve the pain.

REFERENCES

1. Baekmark UB: Neurologic complications after irradiation of the cervical spinal cord for malignant tumour of the head and neck. *Acta Radiol [Ther]* (Stockh) 14:33-41, 1975
2. Godwin-Austen RB, Howell DA, Worthington B: Observations of radiation myelopathy. *Brain* 98:557-568, 1975
3. Bataini JP, Ennuyer A, Poncet P, et al: Treatment of supraglottic cancer by radical high dose radiotherapy. *Cancer* 33:1253-1262, 1974
4. Cheng VST, Schultz MD: Unilateral hypoglossal nerve atrophy as a late complication of radiation therapy of head and neck carcinoma: A report of four cases and a review of the literature on peripheral and cranial nerve damages after radiation therapy. *Cancer* 35:1537-1544, 1975
5. Berger PS, Bataini JP: Radiation-induced cranial nerve palsy. *Cancer* 40:152-155, 1977
6. Shukovsky LJ, Fletcher GH: Retinal and optic nerve complications in a high dose irradiation technique of ethmoid sinus and nasal cavity. *Radiology* 104:629-634, 1972
7. Rider WD: Radiation damage to the brain — A new syndrome. *J Can Assoc Radiol* 14:67-69, 1963
8. Borsanyi S, Blanchard CL, Thorne B: Effect of ionizing radiation on the ear. *Ann Otol Rhinol Laryngol* 70:255-262, 1962
9. Leach W: Irradiation of the ear. *J Laryngol Otol* 79:870-873, 1965
10. Moretti JA: Sensori-neural hearing loss following radiotherapy to the nasopharynx. *Laryngoscope* 86:598-602, 1976
11. Spiess H: Die Schädigung des Nervensystems durch ionisierende strahlen. *Ther Umsch* 72:379-386, 1970
12. Laurent LE: Femoral nerve compression syndrome with paresis of the quadriceps muscle caused by radiotherapy of malignant tumours: A report of four cases. *Acta Orthop Scand* 46:804-808, 1975
13. Westling P, Svensson H, Hele P: Cervical plexus lesions following postoperative radiation therapy of mammary carcinoma. *Acta Radiol* 11:209-212, 1972
14. Mementhaler M: Armplexusparesen in Anschluss an Röntgenstrahlen. *Schweiz Med Wochenschr* 94:1069-1073, 1964
15. Stoll BA, Andrews JT: Radiation-induced peripheral neuropathy. *Br Med J* 1: 834-837, 1966
16. Notter G, Hallberg O, Vikterlof KJ: Strahlenschaden am Plexus Brachialis bei Patienten mit Mammakarzinom. *Strahlentherapie* 139:538, 1970

REPRINTS — William H. Saunders, MD, Dept. of Otolaryngology, The Ohio State University, Columbus, Ohio 43210.

DISCUSSION OF PREVIOUS THREE PAPERS

DOUGLAS BRYCE, MD (Toronto, Ontario): Malignancies of the head and neck are uniquely situated for the direct observation of the effect of therapy whether by surgery or by radiotherapy. Of all the areas in the body, except for the skin, malignancies of the head and neck respond most favorably to radiation and that type of therapy, therefore, will continue to be used in these areas and will probably find a greater role as time goes on. Because of this, it is essential that head and neck surgeons should be familiar with not only the nature and techniques of radiotherapy but also the effects of radiotherapy upon the tissues. It is, therefore, very appropriate that these three papers should have been given before this Society discussing the effect of radiation upon the lymphatic system, cranial nerves and the cartilaginous structure of the larynx.

I would like to commend Dr. Welsh for this very interesting piece of research into the effect of radiation upon the lymphatics. It would appear, as he has demonstrated, that the lymph nodes and lymphatics have a great ability to repair, and a great resistance to radiotherapy even in the doses that they are using, and I believe this has been the experience of others and is also our clinical impression. The effect of radiation on lymphatics is, of course, clinically important as knowledge of this will help us to determine the patterns of spread of head and neck malignancies to cervical lymph nodes during and subsequent to radiotherapy. So far, it would appear that associated surgical trauma and infection have a great deal more influence on the unusual spread of malignant cells than does radiotherapy alone.

Radiotherapy in appropriate doses expertly given at the present time very rarely results in significant radiation necrosis. The effects of radiation are long-term, however, and we are still seeing cases improperly treated or those in which some form of error in the administration of the radiation produces at a later date severe changes in skin cartilage and only very rarely in cranial nerves. The case of Dr. Saunders was of interest because of its rarity and undoubtedly should be recorded.

I have shared with Dr. Chandler the experience of dealing with advanced radionecrosis in the laryngeal area involving skin and cartilage and the vascular tissues. The irradiation effects as a result of overdose or improper administration of this mode of treatment affects all the tissues but has particular effect upon the blood vessels. The result here is a destruction of the elastic tissue of the arteries, thickening and degeneration of the intima, and a sclerosing narrowing of the vessels. This may apply not only to the small vessels but to the larger vessels in the body. The importance of this, clinically, is that such poor blood supply results in a fibrosis and sometimes ulceration and tissue necrosis. When surgery is used to remove the necrotic tissue, this further insult very often results in an increase in the spread of necrosis and with disastrous results often

related to the carotid artery rupture. I would agree with the management that Dr. Chandler is suggesting, except that I am very reluctant to operate at all in these areas, unless absolutely necessary. My experience has been that surgery itself accentuates the problem and often results disastrously. However, on occasion we are forced to carry out laryngectomies either because of the extensive necrosis in the absence of tumor, or because the presence of a recurrent tumor is highly suspected.

I hope that this subject will form part of the program of the Society in subsequent years and I would suggest that it would be of value to have as part of the program a radiotherapist and a pathologist both of whom would add to the interest of the discussion very greatly.

WILLIAM HANAFEE, MD (Los Angeles, California): I would like to ask Dr. Chandler or any of the other essayists for the mechanism of the changes we see in the cartilage and their deformity, and whether this is due to a muscular pull or whether it's due to a venturi effect of breathing.

EMANUEL M. SKOLNIK, MD (Chicago, Illinois): I'd like to ask Dr. Chandler whether he has correlated any of the systemic disease problems relative to the radionecrosis. Some years ago, I had occasion to review a series of our patients who had radionecrosis and most of them seemed to fall into this chronic constitutional disease relative to diabetes or severe vasculitis and also the severe alcoholics and, of course, with more sophistication of radiotherapy today and with our more careful evaluation of the patient and his systemic disease, we have found fewer and fewer of the problems that have been mentioned today, although we do see them.

JOHN S. LEWIS, (New York, New York): In the days when orthovoltage was used in radiation therapy both of the larynx and nasopharynx, we did see many cases of radiation necrosis of the larynx in which the only treatment (once it was ulcerated and cartilage exposed) was total laryngectomy. Also we have many cases of paralysis of the 10th and 12th nerves. But since the introduction of supervoltage this has been a rarity and I'd like to ask Dr. Chandler and perhaps Dr. Saunders to tell us what quality of radiation, was this just orthovoltage radiation that produces complication or was this supervoltage?

JOHN F. DALY, MD (New York, New York): What has been mentioned by Dr. Lewis is quite true that in the time of orthovoltage a hot point used to develop the anterior commissure and the cartilage would be destroyed at that point. (That's the thyroid cartilage.) And at that time, during that period we used to do, and I've done it and it worked very well, remove the cartilage the thyroid ala and there is enough support to maintain an airway and the edema has subsided not completely but the airway and the voice were preserved. More recently we don't see this com-

plication as often, but we have had a few cases and instead of going to the laryngectomy first if you have enough evidence from laminography and from your computer studies that it's just the thyroid cartilage that's involved, I wonder Dr. Chandler whether you would consider just removing the thyroid ala, the diseased tissue and then waiting. I don't see that there is any jeopardy in doing this. The other point is that there are national studies now being conducted by the radiotherapists in which patients that are getting — in addition to radiation to the organ in the head and neck (whether it's nasopharynx or hypopharynx or larynx) bilateral full neck radiation and the effects here are beginning to show up. None of these have gone on to actual necrosis but most of them would fall into your grouping of either one or two, mostly two. This has been a very disturbing thing to see the radiotherapists doing this because there are cases in which there is no reason to suspect clinically that there is lymph node metastasis. Is there any basis for it on the basis of statistics?

STEVEN SCHAFER, MD (Dallas, Texas): We are involved in a platinum study using combined therapy of radiation platinum for people with stage 4 carcinoma. My question is to Dr. Chandler. We observe in patients undergoing this type of intense therapy that if we can avoid any sort of tracheostomy (even the patient which is questionable in airway) and also the placement of an NG tube, by going to a gastrostomy that we are able to avoid the complication. I'd like to ask Dr. Chandler, does he think that by some of these patients he showed where they have the ulcers, that if the NG tube was removed and a gastrostomy was instilled and if a tracheostomy at all could have been avoided, could some of these complications also have been avoided?

JAMES R. CHANDLER, MD (closing): To answer the last question first, I'm sure all of you have seen the patients that have been operated on for persistent carcinoma after radiation therapy where there is an ulcer on the postcricoid-hypopharynx where the indwelling nasogastric tube has ulcerated the mucosa and certainly this occurs in these patients because these tissues are radiation damaged tissues. Dr. Schafer is absolutely correct that one should avoid any trauma to tissues which has the potential capacity for reversing the damage. I have tried to observe that in the past but I can't give any figures. I certainly do feel the same as he does and it's the same thing about biopsying edematous areas in the larynx which really have very little chance of demonstrating recurrent tumor. Firm submucosal dense tissues, of course, in the presence of a progressive change from one grade to the next, for example from grade 2 to grade 3 do warrant an aggressive surgical approach because that's potentially reversible, but at the same time the patient may have persistent carcinoma. For Dr. Bryce's question and Dr. Lewis' regarding quality of radiation therapy, they are absolutely correct, of course. Ionizing ra-

diation affects tissues no matter what the type of the source. Megavoltage and supervoltage spares the skin but they affect a deeper structure quite as much as the orthovoltage. I think we ought to ascribe a great deal of our improved results of radiation therapy, and the decrease of the complications as cited by our President, to the increasing expertise and skill of our radiation therapist colleagues rather than to the type of source of radiation therapy employed. I didn't mean to suggest that surgical extirpation of the radiation necrotic larynx would prevent the inexorable progress of progressive radiation necrosis which will affect the spinal column, the vertebrae, the soft tissues and the arteries of the neck. Dr. Bryce is absolutely correct in that point of view. But on the other hand, if one allows a progressive necrosis of the cartilage and the soft tissues to progress, the patient might very well die of inanition, pulmonary infection, or lung abscess, before one can salvage the patient by the required surgical procedure. It is very interesting to see the computerized scans of this distorted laryngeal cartilages shown by Dr. Hanaffee. I have no idea, of course, but he didn't tell us whether or not he said they had edema. We don't know, of course, whether they had actual necrosis of the cartilage which caused their disolution and disappearance or an in-pulling, as I would suspect that it was probably a combination of both and the scarring of the tissues was due to a loss of blood supply actually distorted them as he demonstrated. In response to Dr. Skolnik, I've not correlated any systemic factors or other generalized disorders. I feel that it is a matter of nutrition and primarily the quality, time, duration, and the field sizes of the radiation therapy. Radiation therapists do object to treating the individual who continues to abuse himself with smoking and alcohol. Our radiation therapists feel that this very definitely contributes to the possibility of radiation necrosis and/or other complications. And to our President who suggested the conservative treatment of radiation necrosis I would agree with him only to the point that he was absolutely certain that the necrosis was not obscuring the possible concomitant, persistent, recurrent tumor. I think this is really my message, and in the patient, for example, who has had radiation therapy for carcinoma of the larynx or base of the tongue and who six or seven years later develops classic signs of radiation fibrosis and necrosis, one can relax somewhat concerning the likelihood of persistent tumor. Then one is certainly justified in conservative procedures such as he suggested and such as have been reported just very recently by Dr. Lytton.

WILLIAM H. SAUNDERS, MD (closing): While treated with orthovoltage this patient was treated on the linear accelerator with megavoltage. The other patients that I looked up in the literature and reported have been reported recently so that I would think they also received some form of megavoltage.

CHOLESTEATOMA OF THE FRONTAL AND ETHMOID AREAS

RUTH S. CAMPANELLA, MD

DAVID D. CALDARELLI, MD

STANTON A. FRIEDBERG, MD

CHICAGO, ILLINOIS

Cholesteatomas of the frontoethmoid region must always be considered in the differential diagnosis of a mass in the frontoethmoid region. A painless, slow-growing mass, often accompanied by proptosis and diplopia, but without history of trauma or infection, should make one suspect of this pathologic entity. Although histologically a benign lesion, the keratinizing squamous epithelial lining will continue to desquamate and expand, leading to erosion of surrounding structures which could be life-threatening. In order to prevent recurrence, complete removal of the cyst lining is mandatory. Cosmetic reconstruction, often requiring obliteration of the surgical cavity, should be delayed for one year to insure against recurrence of the covering of active squamous tissue adjacent to dura, cribriform plate or ocular structures.

Whereas cholesteatomas in the temporal bone are well known to otolaryngologists, the world literature reports only 23 cases involving the frontal and ethmoid regions. We report four additional cases histologically documented in the past nine years at Rush-Presbyterian-St. Luke's Medical Center. Two of these involved the frontal sinuses, one the frontal bone alone, and one the ethmoid sinus with extension into the nasal cavity and sphenoid sinus.

HISTORIC ASPECTS

In addition to involving the temporal bone and frontoethmoid area, cholesteatomas may occur in the cranium, skin, breast, kidney and central nervous system. First described by Cruveilhier in 1829¹ as a "pearly tumor" by virtue of its highly refractive and nodular surface, the actual term *cholesteatoma* was introduced by Müller in 1833² because of the presence of cholesterol crystals.³ Critchley and Ferguson proposed that the term "epidermoid" more suitably conveyed the epithelial character of the growth.⁴

In 1916 Haeggstrom first reported a frontal sinus cholesteatoma which produced proptosis and diplopia.⁵ Spencer, in 1930, described a slowly growing epidermoid of 20 years' duration involving

the right frontal sinus, ethmoid and orbit. This lesion recurred eight years following surgery, and squamous cell carcinoma was found at the second operation.⁶ Coates, in 1937, presented a single case report with an addendum by F. Woodward.⁷ Recent literature contains isolated case reports by Calcaterra and Schwartz⁸ and Holt et al.⁹ Involvement of the frontal bone associated with intracranial and intradiploic epidermoids is described in some neurosurgical literature.

PATHOGENESIS

Four basic theories of pathogenesis may explain the development of these slow-growing lesions. The most acceptable is that of congenital origin from epithelial remnants detaching from the neural groove closure during the fifth embryonic week. Cholesteatomas often develop where two ectodermal surfaces fuse together, when an ectodermal implant which may proliferate is retained deep to the surface. Remak in 1854,¹⁰ and Bucy in 1935,¹¹ proposed that epidermoids are probably neural ectodermal remnants which incompletely separated from the surface ectoderm. When these remnants are deposited between two ectodermal structures such as the brain and the skin, epidural, intradiploic, and epicranial tumors are formed.

Secondary vesicles, particularly the op-

From the Department of Otolaryngology and Bronchoesophagology, Rush-Presbyterian-St. Luke's Medical Center, Chicago, Illinois.

tic and otic vesicles, develop at about the fifth week of embryonic life, and it is possible that misplaced cell nests are related to the laterally located epidermoid tumor. The orbital region is a common site for cholesteatoma. Inclusion of epithelial remnants at the time of development of the optic vesicle constitutes a likely explanation of the origin. The frontal sinus develops within the diploic space, and hence alterations in the pneumatization process or retention of displaced epithelial nests in the frontal sinus may explain the development of intrasinal cholesteatomas. Rand and Reeves¹² felt that, depending on the depth of the layer or the age of the embryo at the time of inclusion, an epidermoid or a dermoid might develop. An epidermoid arises if only the squamous epithelium is included in the inclusion. However, when the fetal inclusion contains ectodermal epithelium in addition to mesodermal corium with its connective tissue, fat cells, sebaceous glands and hair follicles, a dermoid cyst occurs.

The second theory, that of implantation as proposed by Ewing,¹³ states that a cholesteatoma arises secondarily to direct entry of epithelium at the time of trauma. Cholesteatomas have been reported at the site of previous injury or following nasal or sinus surgery. The epithelium, if viable, will continue to desquamate and form an expanding, destructive cyst. The observation that intraspinal cholesteatomas have developed incidental to introduction of skin from repeated intrathecal injections of streptomycin for meningeal tuberculosis supports the theory.

Habberman, in 1888,¹⁴ postulated the "immigration theory," stating that a cholesteatoma may form in the ingrowth of keratinizing epithelium from the surface. This is most likely in tympanomastoid cholesteatomas, but in the frontal and ethmoid sinus the epithelium would have to migrate from the nasal vestibule, resulting in an intranasal tract of epidermis.

The metaplasia theory that respiratory epithelium changes to squamous epithelium in response to chronic infection with suppuration has been demonstrated. Most instances of cholesteatoma report-

ed in this region, however, do not exhibit a history of infection or sinusitis.

PATHOLOGY

An epidermoid has a white glistening capsule which may be very thin and friable. Histologically, the capsule has three normal layers of epidermis: the strata germinativum, granulosum, and corneum. The epithelial layer, in turn, overlies a layer of connective tissue which may contain portions of the mucosa and inflammatory cells.¹⁵ This basal layer also may be vascular and adherent to the dura.

Desquamation accounts for the lamellar structure, and expansive growth of the cyst. Degenerating epithelium within the cyst initiates a foreign body reaction characterized by the presence of giant cells, fatty degeneration, hemosiderin, cholesterol crystal formation and fibrosis. Bone erosion accompanying this tumor is consequent upon expansive pressure and enzymatic digestive activity in the connective tissue base.

Epidermoids are slow-growing asymptomatic lesions. Patients seek medical advice because of facial deformity produced by enlargement of the mass and its extension to adjacent structures. Frontal, nasal, and/or orbital rim swelling are the usual presenting symptoms. Often proptosis secondary to downward pressure by the cyst, prompts the patient to seek medical attention. As the globe is depressed there may be limitation of upward gaze, followed by diplopia and eventual reduction of visual acuity.³ Facial pain, frontal headache, and central nervous system symptoms of increased intracranial pressure are infrequent, since the cyst tends to expand outward. A history of frontoethmoid trauma, surgery or infection should be sought in the attempt to eliminate more frequent lesions, such as mucocèles or neoplasms.

CASE REPORTS

Case 1. A 65-year-old Caucasian male presented in February 1969 complaining of proptosis of the left eye, of ten years' duration. It had progressed to where he now complained of diplopia. There was no history of trauma or surgery to the area. There was a 2.5 cm firm swelling overlying the left lateral orbital rim, which was intact to palpation. Radio-

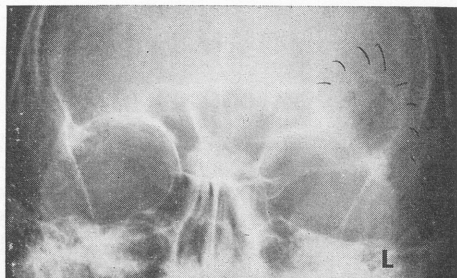


Fig. 1. (Case 1) Lytic lesion with sclerotic margins involving left supraorbital region which proved to be a cholesteatoma communicating with the frontal sinus.

graphs revealed a mass in the left frontal sinus with smooth margins extending beyond the lateral margin of the sinus (Fig. 1). The tentative diagnosis was a frontal sinus mucocele.

He underwent a left sinus and supraorbital exploration via a brow incision with planned osteoplastic flap. On elevating the skin and periosteum, a 2 cm white cystic mass was encountered. This connected directly with the frontal sinus through a bony defect in the anterior wall, and eroded the superior orbital rim contacting the periorbital fat. The sac contents were drained of thick brown fluid and cheesy white material.

The entire sac lining and osteitic bone involving the lateral edge and anterior wall of the left frontal sinus were removed. No attempt at bony reconstruction or obliteration of the left frontal sinus was performed. Postoperatively, vision and eye mobility were within normal limits, and there was no proptosis. At present there is a slight bony defect in the

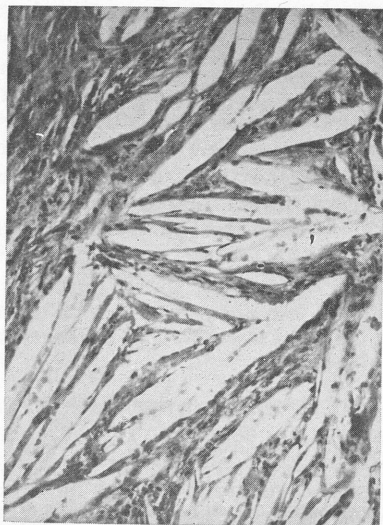


Fig. 2. (Case 1) Surgical specimen showing cholesterol crystals with keratin debris.

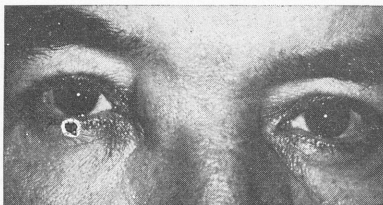

Fig. 3. (Case 2) Soft swelling involving inner canthus of right eye and extending to nasal bridge.

left lateral supraorbital rim which is of insufficient deformity to warrant further surgery. There has been no evidence of recurrence over the past ten years.

A cholesteatoma marked by cholesterol crystals, keratin debris and a lining of keratinizing squamous epithelium with a connective tissue base, was seen histologically (Fig. 2).

Case 2. A 48-year-old Caucasian male presented in June 1972 because of an enlarging, painless swelling of three months' progression, over the medial aspect of the right eye. There was no prior trauma or inflammation in the area, but there had been intranasal surgery at age 25 for nasal obstruction. The operative report was unavailable.

On physical examination there was a 1 x 1 cm painless swelling with an area of central fluctuance between the inner canthus of the right eye and the nasal bridge (Fig. 3). The orbital rim and frontal bone were intact to palpation. Intranasal examination revealed a right superior cartilaginous septal deviation. Sinus tomography revealed a destructive lesion in the right ethmoid with smooth edges and possible erosion of the cribriform plate. A dacryocystogram was within normal limits. Aspiration of the mass prior to admission was noncontributory to diagnosis.

In May 1972 the area was explored via a right lateral rhinotomy. On elevating the periosteum over the right nasal bone and ethmoid, a green fluid-filled mass was encountered extending from the ethmoid sinus and lamina papyracea into the nasal cavity with destruction of the right lateral nasal wall. This mass also invaded the nasal septum and spread into the left nasal cavity. It extended posteriorly, partially destroying the anterior wall of the sphenoid sinus and extended to but not through the cribriform plate. The mass was decompressed and removed, along with its lining membrane. Histologic diagnosis was cholesteatoma with a keratinizing squamous epithelial lining, marked foreign body reaction, and cholesterol granulomas. Routine follow-up examinations have revealed no evidence of recurrence.

Case 3. A 46-year-old Caucasian male was admitted for evaluation of back pain and intermittent frontal headache. Skull radiographs revealed a lytic lesion in the right frontal sinus. The possibility of metastatic hypernephroma was ruled out.

Examination showed mild asymmetry of the right forehead, with a firm protuberance above

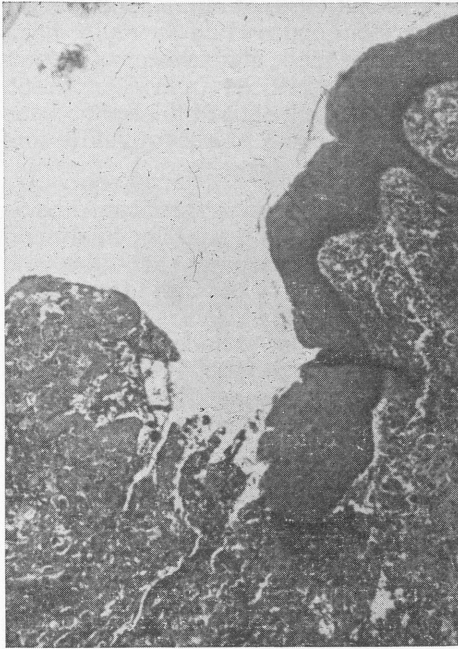

Fig. 4. (Case 3) Sac wall composed of keratinizing squamous epithelium and marked foreign body reaction.

the right eyebrow. There was no history of sinusitis, frontal trauma or ocular disturbance.

Exploration of the right frontal sinus via a right osteoplastic flap was contemplated. However, elevation of the periosteum from the anterior sinus wall revealed the bone to be extremely thin. Inferiorly there was erosion of the roof of the right orbit. Upon removal of this osteitic bone, a large mass containing caseous material was uncovered. This lesion was excised together with the mucosal lining of the right frontal sinus. The nasofrontal duct was uninvolved and patent. The sinus was packed with Gelfoam® and the bony defect not repaired. Histologic diagnosis was a keratin-filled cholesteatoma (Fig. 4).

Case 4. A 36-year-old male was first seen in consultation by the ophthalmologists in August 1978. In November 1977 a mass had been removed from the right orbital rim after radiographs revealed a dense mass in the right frontal bone. Vision at that time was 20/400 without correction.

The patient had complained of swelling in the area for many months prior to his first operation but did not pursue the matter until October 1977 after he had been struck in the right eye. At the time of his original surgery there was marked ecchymosis over the upper eyelid. The initial impression was an orbital tumor radiographically consistent with eosinophilic granuloma. Following exploration via a superior eyelid incision, a cavity was found, filled with chocolate-colored fluid, representing old hematoma. The tissue lining was not removed. Histologically there were cholesterol

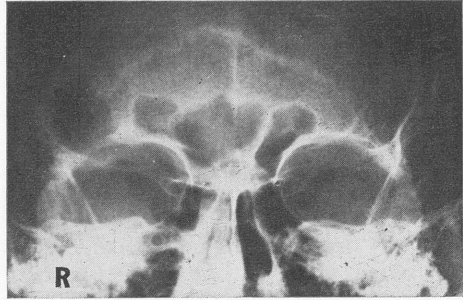


Fig. 5. (Case 4) Plain x-ray of osteolytic lesion with right orbital rim erosion.

granulomas, an old hematoma, and a giant cell reaction. Since surgery, he had complained of periodic drainage from the incision line with a slight increase in proptosis.

Examination revealed a 1 x 1 cm fistula just beneath the right eyebrow in the midline, with a sequestrum of bone protruding through the right upper lid laterally. Intranasal, nasopharyngeal, and oral cavity examinations were within normal limits. There was no diplopia, and visual acuity remained at 20/400. Sinus tomography revealed a well-defined osteolytic lesion with a sclerotic border involving the right supraorbital area, with destruction of the orbital rim and extension through the roof of the orbit (Fig. 5). A small bony density protruded into the cystic area and was thought to represent a sequestrum. Culture of the drainage revealed a coagulase-positive staphylococci. Cephalosporin therapy resulted in cessation of the drainage but the proptosis remained unchanged.

On August 28, 1978 an exploration of the right frontal bone and right orbit revealed a dense mass containing an old ophthalmologic sponge. On elevation of the periosteum over the superior orbital rim a bony defect was discovered which extended approximately 2 cm superiorly, with surrounding osteitic bone. A cystic mass beneath the bony defect contained caseous material. A further defect in the inferior margin revealed orbital fat and muscles. Removal of the sac showed that the posterior

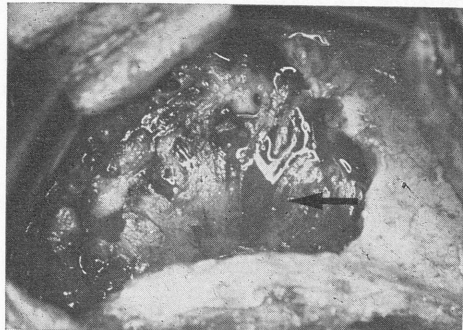


Fig. 6. (Case 4) Exposed dura (arrow) resulting from erosion of right frontal bone by cholesteatoma.

wall of the frontal bone had been eroded, and there was a 2 x 2 cm area of exposed dura (Fig. 6). The sac was totally stripped from this area, and the remaining osteitic bone curetted. There was no evidence of a spinal fluid leak. Gelfoam placed in the cavity covered the dura and orbital defect.

Histologically there was a foreign body reaction within a keratinizing squamous cell lined cyst, plus extensive scarring and granulation tissue. The postoperative course was unremarkable.

Since the bony defect was cosmetically unacceptable, subsequent reconstruction was planned in one year, barring recurrence. Unfortunately, the patient was killed in an automobile accident in December 1978. Examination immediately prior to his accident revealed no evidence of infection or fistula.

DISCUSSION

Case reports 1 and 3 seem to support the theory of congenital origin of cholesteatoma when there is no prior history of trauma, surgery, or infection. In case 2 there was nasal surgery 20 years prior to the diagnosis of cholesteatoma, with the nature of the procedure unknown. Either the implantation theory or the congenital theory could be implicated.

Case 4 is confusing as to pathogenesis. Historically, a mass increased in size following trauma and subsequent surgery, with infection and foreign body reaction. All four theories of pathogenesis might apply to the size and destruction produced by this cholesteatoma.

Diagnosis. The diagnosis of frontal or ethmoid cholesteatoma should be considered in the presence of any painless soft swelling presenting in this area, with or without orbital displacement or ocular dysfunction. Radiographic characteristics are osseous destruction with increased density of the smooth surrounding margins. At times the bony margin may be irregular and more scalloped due to slow erosion of the bone. Intradiploic lesions may destroy the outer and inner tables of the frontal bone producing a sequestrum-like or honeycombed appearance.¹⁵

Other slow-growing lesions in the frontal and ethmoid regions must be considered in the differential diagnosis. The most common painless growth which will produce bone erosion and orbital proptosis is the mucocele. Char-

acteristically the radiograph will demonstrate sinus mucosal hypertrophy adjacent to the mass, and a history of sinusitis is often elicited from the patient. Chronic osteomyelitis of the frontal bone with a fistula may present a picture similar to cholesteatoma.

Sebaceous cysts are the most common skin lesions causing swelling in this region. Bony erosion is absent in this condition. A lipoma is less firm to palpation. An organized hematoma with fibrosis usually can be excluded by history. Osteomas are differentiated by dense calcification on x-ray. Fibromas in this region are rare, and surgery is needed to establish their presence. Dermoids will give identical presentations, and unless teeth or other mesodermal or ectodermal derivatives are seen on radiographs, pathologic diagnosis provides the differentiation. Vascular abnormalities tend to be pulsatile and change dimension with head position. A lacrimal sac tumor can be differentiated by a dacrocystogram.

Malignant tumors in this area tend to grow more rapidly and often are associated with pain. Rapid recurrence of an excised cholesteatoma must alert one to the possibility of an underlying malignancy.

Multiple systemic conditions may present as a frontal mass or as exophthalmus. Thyrotoxicosis, pseudotumor of the orbit, leukemic infiltration, lymphosarcoma, and diffuse neurofibromatosis must be considered in the differential diagnosis. Syphilis can produce gumma formation involving the orbital apex or superior wall of the orbit.³

Treatment. The appropriate treatment of cholesteatoma is surgery. As emphasized, it is important that the wall of the cyst, which is the only living, growing portion of the mass, be completely removed. This must be done to prevent recurrence; simple evacuation will not suffice, as seen in case 4.

Cosmesis should be taken into consideration in the original surgical incision. A planned osteoplastic flap via a brow or coronal incision should be used in frontal bone or frontal sinus surgery. The ethmoid and intranasal area can be approached by a lateral rhinotomy. Ade-

quate visualization to insure complete removal is needed. If a bony deformity results, reconstruction should be postponed until recurrence has been excluded and there is less possibility of rejection of any prosthetic material.

In cases presented, complete removal or normal sinus mucosa with sinus obliteration was not employed nor deemed necessary, due to the well-formed nature of the cysts and normal-appearing adjacent mucosa and patent frontal sinus ducts. Lack of infection in the three cases involving the frontal and ethmoid sinus was the factor recommending this nonobliterative approach. If the dura is involved, it should be repaired primarily or with a fascia graft.

CONCLUSION

Although literature on the subject is

sparse, cholesteatomas must always be considered in the differential diagnosis of a mass in the frontoethmoid region. A painless, slow-growing mass, often accompanied by proptosis and diplopia, but without history of trauma or infection should make one suspect of this pathologic entity. Although histologically a benign lesion, the keratinizing squamous epithelial lining will continue to desquamate and expand, leading to erosion of the surrounding structures which could be life-threatening. In order to prevent recurrence, complete removal of the cyst lining is mandatory. Cosmetic reconstruction, often requiring obliteration of the surgical cavity, should be delayed for one year to insure against recurrence or the covering of active squamous tissue adjacent to dura, cribriform plate or ocular structures.

REFERENCES

1. Cruveilhier J: *Anatomie Pathologique du Corps Humain*, vol 1. Paris, J B Bailliere, 1829, p 341
2. Müller J: *Veber den Feinern Bau und die Formen der Krankhafter Geschwulste*, vol 1. Berlin, G Reimer, 1838, p 50
3. Thacker EA: Epidermoid tumors of the frontal bone, sinus and orbit. *Arch Otolaryngol* 51:400-413, 1950
4. Critchley M, Ferguson FR: The cerebrospinal epidermoids (cholesteatomata). *Brain* 51:334-341, 1928
5. Haeggstrom AA: Cholesteatoma removed from the frontal sinus. *Hygiea* 78:1122, 1916
6. Spencer FR: Primary cholesteatoma of the sinus and orbit: Report of a case followed by carcinoma and death. *Arch Otolaryngol* 12:44-46, 1930
7. Coates GM: Cholesteatoma of the frontal sinus. *Arch Otolaryngol* 26:29-37, 1937
8. Calcaterra TC, Schwartz HE: Cholesteatoma of the frontal sinus. *Trans Am Acad Ophthalmol Otolaryngol* 82:579-581, 1976
9. Holt RC, Holt JE, David WE: Late recurrence of frontal sinus cholesteatoma. *Ann Otol Rhinol Laryngol* 86:852-855, 1977
10. Remak R: Ein Beitrag zur Entwicklungsgeschichte der Krebshafter Geschwulste. *Arch Klin Med* 6:170, 1854
11. Bucy PC: Intradiploic epidermoid (cholesteatoma) of the skull. *Arch Surg* 31:190-197, 1935
12. Rand CW, Reeves DL: Dermoid and epidermoid tumors (cholesteatomas) of the central nervous system: Report of twenty-three cases. *Arch Surg* 46:350-376, 1943
13. Ewing J: *A Treatise on Tumors*. Philadelphia, W B Saunders Co, 1928
14. Habermann J: Zur Entleerung des cholesteatomas der mittelohrs. *Arch Klin Exp Ohren Nasen Kehlkopfheilkd* 27:42, 1888
15. Nager GT: Epidermoids involving the temporal bone: Clinical, radiological and pathological aspects. *Laryngoscope* 85(Suppl 12: 1-22) 1975

REPRINTS — Ruth S. Campanella, MD, Department of Otolaryngology & Bronchoesophagology, Rush-Presbyterian-St. Luke's Medical Center, 1753 West Congress Parkway, Chicago, IL 60612.

DISCUSSION

BURTON J. SOBOROFF, MD (Chicago, Illinois): I'm pleased to be able to discuss an excellent paper presenting four cases of a relatively rare clinical entity. Drs. Campanella, Calderelli and Friedberg have been kind enough to provide a copy in advance so that I was able to see it well ahead of time.

Cholesteatoma of the head and neck area, other than those occurring in the middle ear secondary to infection, marginal perforation or atelectasis, are unusual and rare tumors of squamous epithelium. One or two cases make up most reports even in the neurosurgical literature. Our experience has been limited to

two such cases in the sinus area and two others in the cranium. In the sinus area one of them occurred in the frontal region, presented much like a mucocoele seen in the differential diagnosis presented here and was treated surgically. It had a lining of squamous epithelium producing a cavity filled with thick pasty material. In days gone by such pathological findings were often present in chronic infection with the cholesterol clefts in a granuloma but without a true squamous lining indicating almost a tumor-like mass originating from the squamous epithelium. The presence of cholesterol crystals, however, is not particularly diagnostic. The diagnostic feature is that lining of squamous epithelium. The second patient had such a tumor mass arising in the ethmoid area extending into the antrum and likewise was treated surgically, without other extension into the surrounding structures. It was filled with a thick pasty debris and recurred after the primary removal because the entire lining had not been removed. Two other cases, however, with white cholesteatomatous debris have been seen and represent the classic appearance of such a cholesteatomatous tumor.

The first patient is shown in a series of slides illustrating the clinical swelling seen in the parietal region of the skull. Following slides show successive surgical steps in ex-

posing the shiny white cholesteatoma beneath the thin overlying bone and the erosion of bone by the tumor exposing the intact dura. One of our major concerns with such tumors of the sinuses and cranium is erosion of bone and potential involvement of important structures within the dura and intracranial cavity.

The second patient was admitted because of cerebral spinal rhinorrhea but his skull x-rays showed large bony defects on each side of the occiput. Surgical exploration revealed a huge cholesteatoma (with classic white shiny appearance) on each side of the skull, extending to the dura in the region of the sigmoid and transverse sinuses. Exploration in this patient was carried out by neurosurgeons because of the extensive cranial involvement.

Some cholesteatomas may present as intracranial masses and have been reported as such in the neurosurgical literature; at times they may present as an angle tumor and clinically resemble an acoustic neuroma. CT scan or ultrasound are diagnostic procedures that may be helpful.

Most important, these authors have reminded us of the possibility of cholesteatoma in this differential diagnosis and it is significant that such tumors may erode bone, expose dura and involve intracranial structures.

THE PROBLEM OF THE COLLAPSING UPPER LATERAL CARTILAGE

BRIAN F. McCABE, MD

IOWA CITY, IOWA

The collapsing upper lateral cartilage is an airway problem that admits to no ready solution, such as the deviated nasal septum or deflected columella. It is my understanding from experienced nasal surgeons that an attack directly on the upper lateral cartilage has not provided a solution, but in general makes the problem worse. A look at the nasal septal base by simultaneous viewing of both nasal chambers may reveal a dimension of 1 cm or more. In that event, a fairly radical narrowing of the septal base in the plane of the pyriform crest by a subperiosteal and subperichondrial approach with well-placed transfixion sutures can increase the airflow across that plane. It has done so in eight patients. This operation is for the experienced nasal surgeon, or the otolaryngologist who has prepared himself by careful cadaver preexperience.

Patients with the complaint of an inadequate nasal airway which is restored to them are among the most grateful patients in otolaryngic practice. The submucous resection (SMR) of the nasal septum, coupled with SMR of the inferior turbinate of one or both sides where indicated, is a very rewarding operation. It is relatively simple in execution when properly done after adequate training, requiring not a great deal in terms of expense, discomfort, and hospitalization on the part of the patient. The claim to such greater well-being on the part of the patient has a much more scientific basis today than the simple patient observation of a free nasal airway. It has been demonstrated that when nasal breathing is severely impaired, the PO_2 nocturnally is significantly dropped and the PCO_2 rises. It cannot be otherwise that the nocturnally hypoxxygenated organism functions less efficiently, in carrying out the demands of daytime living, whether they are physical or mental, than the euoxxygenated organism.

Patients with midnasal or posterior nasal obstruction have been well served by a variety of operations of established worth. Indeed, these operations are proven to the degree that they are among the earliest to be placed in the armamentarium of our trainees in otolaryngology. Far anterior obstruction however is quite a different problem. I was taught early by my professors that the

inhalation — especially forced inhalation — type of obstruction is one that is not solved by septal or turbinate surgery. This type, immediately relieved by placement and opening of the Vienna nasal speculum, is familiar to all otolaryngologists. In that maneuver, the observation may be made whether the improved airway is by virtue of elevation of the inferior or upper lateral cartilage. It is the upper that is virtually always at fault. This has been termed the "nasal valve" by rhinologists. It seems to me most reasonable that patients with nocturnal hypoxemia due to upper lateral cartilage collapse with inability to compensate simultaneously for this by mouth breathing, would be less than optimally productive during waking hours. Attributing the upper lateral cartilages to any greater crime than this however seems indefensible.

The beach is littered with the wrecks of operations for correction of upper lateral cartilage collapse. Usually (but not invariably) the cartilage on visual inspection appears to be rotated with its caudal and cephalic edges extending dependently into the airstream, clearing the nasal septum by 1-2 mm. On seeing this, the surgeon is strongly tempted to solve the situation by trimming the edge to shorten the cartilage away from its proximity to the septum. Upon inquiry I was admonished by Jack Anderson and other rhinologic surgeons however, that this is exactly the wrong thing to do; one

From the Department of Otolaryngology and Maxillofacial Surgery, University of Iowa Hospitals and Clinics, Iowa City, Iowa.

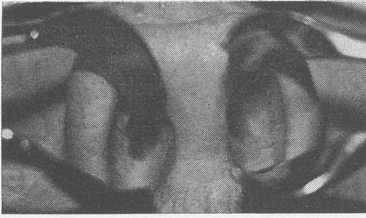


Fig. 1. The examiner seldom examines both nasal chambers simultaneously; doing so reveals the sometimes surprisingly wide anterior septal base.

is never to touch the upper lateral cartilage in this disease or the situation will only be made worse. Anderson stated that his best course of action was to resort to what he called a "cheater" operation, that is, to divert the airstream along the floor of the nose rather than over the vault by cutting laterally the pyriform crest in the lower third and placing canoe-shaped full thickness skin grafts into the gap of the vertical incisions. I did this and these patients claimed definite improvement. They received enough improvement that they asked what could be done to receive any additional improvement.

The problem seemed to rest in how further air could be admitted past the plane of the pyriform crest into the nasal chamber. One solution would be to lower the inferior edge of the pyriform crest to the nasal floor. Another would be to narrow the anterior base of the nasal septum, if more space is achievable in this way.

We seldom if ever examine *both* nasal chambers in the same view. If one does, however, using a speculum in each hand, the examiner may be impressed by how wide the nasal septum is at its anterior base (Fig. 1). It is not uncommonly

only a centimeter or more in width. This may be simply measured. One blade of the speculum is placed in one nasal aperture and the other in the opposite, the speculum vertically held. The speculum is closed gently until the blades rest on each side (Fig. 2A), then is pulled out without altering the dimension between the two handles. The distance between the blade tips (Fig. 2B) is measured and this is the width of the septal base.

The operation selected for these patients was one to narrow maximally this dimension without losing nasal dorsum support. It is an entirely extranasal procedure, through a sublabial incision, skeletalizing the inferior pyriform crest, nasal spine, anterior maxillary crest, and columella under local anesthesia (Fig. 3A). The entire anterior nasal base including all these structures is then narrowed with a rotating burr to a width of 1-2 mm (Fig. 3B). Then three inferiorly placed transfixion sutures are placed in the septal base (Fig. 4) and the sublabial incision closed. Packing is not used. It may be indicated to place the transfixion sutures over heavy stents of Silastic® on each side. The airway (Fig. 5A, B) continues to improve for up to six months as scar tissue contracts.

RESULTS

Eight patients have received the operation. All expressed satisfaction with the result in terms of being significantly relieved of nasal obstruction. Four were nocturnal snorers; two related relief of this, two were about the same. Each claimed an improved feeling of well being from the operation, presumably because of improved oxygenation. Two claimed moderate but unenthusiastic im-

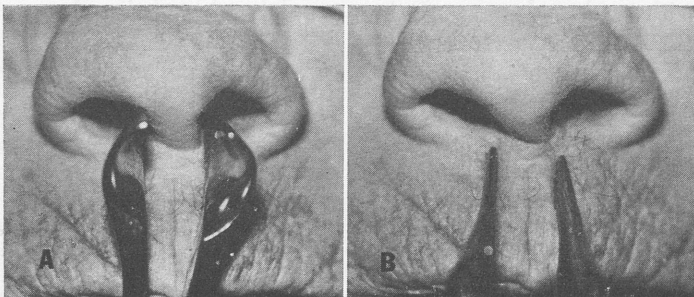


Fig. 2. A, B) The width of the septal base can be measured with the nasal speculum.

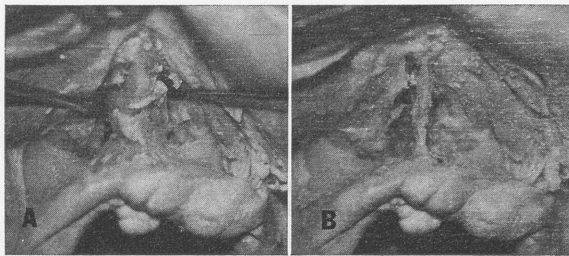


Fig. 3. A) Through a sublabial incision the entire anterior septal base is skeletonized extranasally, including the inferior pyriform crest region. B) With a rotating burr the septum is thinned to 1-2 mm.

provement. We think their improvement was more from desire to please their surgeon than anything else, or perhaps an endogenous steroid outpouring effect from operational stress.

An attempt was made to quantify the postoperative improvement in airway by

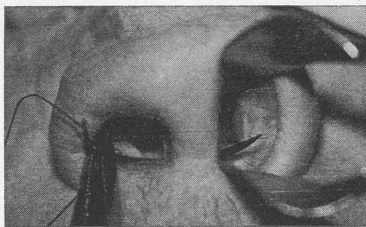

Fig. 4. Several transfixion sutures are placed.

measuring the distance between the upper lateral cartilage and the corresponding lateral nasal wall at a fixed point above the nasal floor. This proved to be a rather ephemeral effort because the nasal floor was shifted by the operation. We thus can report no significant data in this regard. One wonders about the

significance of such data in any event, since all the factors that effect tissue turgor (hormonal cycle, diurnal factors, hydration, postural fluid shifts, etc) may significantly change the diameters of body apertures from one time to another. A 1-2 mm change in nasal aperture may be reflected in a 20%-40% change in airflow. Mere physical measurements made at the coronal plane of the nasal aperture would not be expected to reflect the true median airflow. Rhinomanometry is not suitable for judging the results of operations in this region because the olive tip alters the position of the alae. Thus, we have as postoperative data only the septal base width and subjective responses. Criticism may be applied to the operation in this regard, and it is valid.

Complications consisted in the main of denervation of the upper medial teeth and lip. Tooth reinervation did not occur, but lip reinervation did, at a maximum time of about three months. No other complications occurred in this small group of patients.

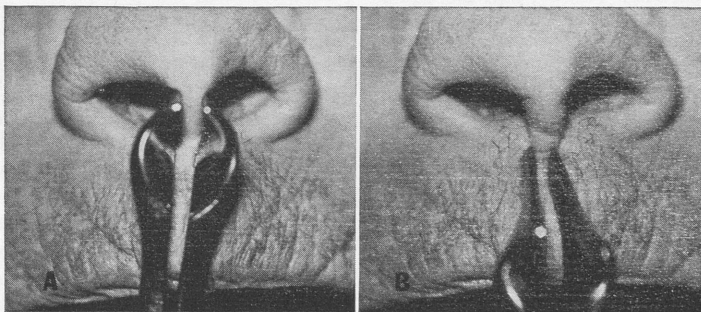


Fig. 5. A, B) The new width of the septal base.

References upon request.

REPRINTS — Brian F. McCabe, MD, Department of Otolaryngology and Maxillofacial Surgery, University of Iowa Hospitals, Iowa City, IA 52242.

DISCUSSION

RICHARD FARRIOR, MD (Tampa, Florida): Dr. McCabe has brought to us a unique solution to a unique entity. There are many factors which contribute to collapse of the cartilaginous nasal vault, some reflecting the changes of aging with loss of the elasticity of the cartilage itself and, perhaps more important, loss of fibrous tissue support. These changes are often overlooked by the rhinologist. I find myself fascinated as much by the conditions he describes as the surgery. The entity of collapse with loss of attachment or support at the cephalic edge (slide)* of the upper lateral cartilage, or at its attachment to the nasal bones, is a new observation to me for the unoperated patient or when not resulting from injury. I am interested that he has found eight patients to operate (slide). Each anatomic unit is interrelated. The more caudal structures, including the lower lateral cartilage, influence the more cephalic cartilaginous structures. The resilience of the upper lateral cartilage at its union with the nasal septum may change, increasing the angle at this junction.

The rhinoplastic surgeon sees far too many cases of collapse resulting from overvigorous surgery to the lateral nasal cartilages. I concur in "acquired" collapse that no additional excision of cartilage should be done. The inexperienced surgeon frequently overoperates the upper lateral cartilages along the nasal dorsum where they may be detached from the septum or may, in out-fracture or in other maneuvers, actually tear the cephalic fibrous union from the undersurface of the nasal bones (slide). Trauma may avulse the cartilage from its syndesmotic relation beneath the bone. At the anterior valve area (slide), about the level of the limen vestibule, both the lower lateral cartilage itself and the return or scroll of both the upper and lower lateral cartilages act as a buttress to maintain the upper lateral cartilages in a normal lateral position influencing the position of the more cephalic cartilage. The scroll (slide) which has some of the extra rigidity of a tube or cylinder is often not considered for this influence on support. The scroll, the cephalic border of the lower lateral cartilage (slide), and the caudal border of the upper lateral cartilage (slide) are often too enthusiastically attacked leading to collapse. Each of these factors contribute to conditions for which Dr. McCabe's operation might be beneficial (slide).

At the junction (slide) or blending of the upper lateral cartilage with the septum, the

angle may be increased or more acute simply by the cartilage losing its starch.

The operation itself is simple and one we should consider for offering the patient relief especially when the usual procedures have failed.

A number of authors, more recently Patterson,¹ have emphasized the loss of support in the aging nose. But both in his writing and personal communication Dr. Patterson does not describe separation or weakening at the junction with the nasal bones. Relaxation at this more firm fibrous attachment could occur I presume. Cottle² described in detail the importance of the nasal vestibule on air flow (slide). The door sill or window sill is eluded to and this operation would seem to be attacking that problem, increasing the aperture here rather than the point of altered air current higher up. This then becomes a by-pass operation, not attacking the deficiency itself. The operation does reduce negative pressure alleviating pull on the collapsible cartilage.

The objective and chief question is: Does the operation provide relief and more comfortable breathing for the patient? The results are subjective. The next question might be: Should the operation be attempted before more conventional procedures such as septal reconstruction, turbinate surgery, direct surgery at the valve area such as cartilage implants or composite implants of cartilage and skin (slide), tip elevation, columella struts (slide), and narrowing the columella base (slide).

I will be on the lookout for these cases and the opportunity to try the procedure. Technically it could be accomplished either through the intraoral approach as described or through a modified transfixion incision (slide). In rhinoplasty we often try not to narrow the airway excessively by preserving a triangle of bone at the lateral inferior pyriform rim. It is conceivable then, that widening could be accomplished by removing the bone in this area effecting lateral displacement. Hodges** has augmented this further by actually excising external skin to this and then after removing bone suturing the periosteum.

I congratulate Dr. McCabe for this original thinking.

Dr. Daly, I'm pleased there is a paper on rhinology on the program. I would refresh the memory of the Laryngological members by noting that the coveted Casselberry Award is in laryngology and rhinology.

REFERENCES

1. Patterson C: *Surgery of the Aging Nose, Plastic and Reconstructive Surgery of the Face and Neck: Proceedings of the Second International Symposium*. Grune and Stratton, New York, vol 1, pp 20-28, 1977
2. Cottle MH: The structure and function of nasal vestibule. *Arch Otolaryngol* 62:173-181, 1955

*Slides were shown to demonstrate the anatomy and interrelationship of all anatomic structures, particularly at the junction and overlap of the upper lateral cartilages beneath the caudal margin of the nasal bones and pyriform rim, the relationship and return of the upper and lower lateral cartilages together, the junction of the upper lateral cartilage with the nasal septum along the dorsum, and details of the lateral inferior bony pyriform rim.

**Hodges JM: Personal communication.

LARYNGEAL DYSFUNCTION FOLLOWING PROLONGED INTUBATION

ROBERT E. WHITED, MD

CINCINNATI, OHIO

Prolonged endotracheal intubation in the adult is becoming more popular with the advent of "soft" tubes and cuffs. The many deleterious effects of such long-term intubation on the laryngotrachea have been extensively discussed in the literature. However, only sporadic attention has been given to vocal cord paresis or paralysis. The University of Cincinnati Medical Center experience with postintubation patients has shown that cord mobility disturbances are relatively common. Sixteen patients are presented who have had similar clinical findings and course following extubation. The clinical picture is that of a symmetrical vocal cord paresis or paralysis associated with arytenoid and posterior commissure edema and erythema. Vocal cord position is most often median or paramedian. A spontaneous recovery over days to weeks is the usual course. During the recovery phase cord movement most often remains symmetrical; however, full motion may occur in one cord before the other. In all patients abduction was most limited and slowest to return. In this series the most significant effect has been aspiration. Two patients developed a posterior commissure stenosis. This entity is believed to be due to inflammation initiated by the tube and its movement against the posterior half of the endolarynx. In particular, inflammatory involvement of the cricoarytenoid joints and interarytenoid region best explain the clinical course. When mucosal ulcerations and granulation tissue are superimposed on the immobilized cords interarytenoid scarring may lead to chronic stenosis.

That long-term intubation in the adult may result in significant laryngeal injury has been well-defined in the otolaryngology literature. These problems most commonly relate to granulomas or stenosis.^{1,2} Direct injuries from introduction of the tube has been reported as well.³ Additionally, several patients have been reported to have developed unilateral or bilateral vocal cord paralysis following extubation.^{4,5} This paralysis, whether permanent or transitory has been presumed to be due to the recurrent nerve pressure injury by the inflated cuff in the subglottic area.⁶

Despite extensive evidence that laryngeal injury may occur in the context of prolonged intubation, a frequent conclusion is that significant injury is extremely unusual.⁷ Further, many of the deleterious effects on the trachea have been dealt with by advances in cuff design and care. These factors combine to encourage increasing lengths of intubation time. Consistent with this viewpoint, the otolaryngologist now often serves as a consultant for tracheotomy or for those patients who have either persisting or delayed problems following extubation.

The present report is from the Otolaryngology Consultation Service at the University of Cincinnati Medical Center. The active and ongoing involvement in care, once referral has been made, has led to a new appreciation of the laryngeal functional derangements which not uncommonly follow early in the postextubation phase. A recurring clinical picture is presented which underscores the need for otolaryngologic contribution to these patients' care.

METHODS AND MATERIALS

From June 1977 through December 1978, there were 76 adult patients referred for evaluation of regional problems related to intubation. From this population 16 patients were selected using the following predetermined criteria:

1. Vocal cord paralysis or paresis following extubation.
2. Intubation time of five days or longer.
3. Absence of known, preexisting laryngotracheal abnormalities.
4. Minimum postextubation patient survival of six months.

Additional patients were excluded because of associated severe head and neck trauma; inhalation; or caustic ingestion.

The patients in this series were studied in depth beginning with the point of referral.

TABLE 1. PRIMARY PROBLEM LEADING TO INTUBATION

<i>Problem</i>	<i>No. Patients</i>
Cardiac failure	4
Pulmonary failure	5
Drug overdose	5
Abdominal-pelvic trauma	2

Serial examinations by mirror and fiberoptic laryngoscopy were done at set intervals. In patients with tracheotomies, motion assessment was done both with the tube plugged and unplugged, and during coughing, swallowing and phonatory effort. Radiographic evaluation was obtained when allowed by the general status of the patient. When feasible, patient questionnaires provided supplementary information.

PATIENT POPULATION

This series is comprised of ten males and six females with an age range of 24 to 68 years. The median age is 54 years. The initial otolaryngology evaluation was begun while the patient was in either the medical or surgical intensive care unit (ICU). Table 1 outlines the primary problems which led to the initial requirement for respiratory support.

As in any ICU setting, the number of variables involved per patient was great. All patients were cared for by multiple physicians. For each patient there was a primary system failure, as well as associated medical and surgical complications which led to the prolonged intubation. Each patient in this series had assisted ventilation and nasogastric tubes as part of the care requirements for the majority of time that the endotracheal tube was in place. All tubes were orotracheal and met accepted standards for construction, size, and care. Table 2 outlines the length of time

TABLE 2. LENGTH OF INTUBATION TIME

<i>No. Days</i>	<i>No. Patients</i>
8-9	2
9-10	3
10-11	4
11-12	3
12-16	4
11.2 Median	

TABLE 3. REASON FOR OTOLARYNGOLOGIC CONSULTATION

<i>Reason</i>	<i>No. Patients</i>
Request for tracheotomy	10
Aspiration	1
Airway compromise postextubation	3
Inability to "plug" tracheotomy	2

that the endotracheal tube was continuously in place. The otolaryngology consultation was obtained initially by the primary service for the reasons outlined in Table 3.

INITIAL LARYNGEAL FINDINGS

There were ten patients referred for tracheotomy after prolonged intubation had occurred. This surgery was completed in the operating room with the endotracheal tube being removed at that time. Direct examination of the larynx uniformly showed good cord motion. In two patients there was incomplete closure of the posterior glottic chink with a persisting deficit estimated to be 2 to 3 mm.

Within 24 hours after tracheotomy, re-examination of the larynx revealed a recurring picture of marked inflammatory edema of the arytenoids, associated with vocal cord paralysis. There was likewise, a marked inflammatory response in the posterior aryepiglottic folds and posterior false vocal cords. In each patient the findings were symmetrical. The true vocal cord position was in adduction in eight of these patients with two having essentially paramedian positions and open glottic chinks.

Three patients had elective removal of the endotracheal tube in the ICU by the primary service. Initially they had good airways, but they became progressively obstructed within hours. Crash reintubation was done in each case, with the Department of Otolaryngology consulted for tracheotomy thereafter. The initial laryngeal findings in these patients corresponded to those described in the preceding paragraph who had been extubated for several hours. In the elective-removal group, cord position was essentially midline with a persisting incomplete closure of the posterior glottis.

TABLE 4. LARYNGEAL RECOVERY TIME FOLLOWING EXTUBATION

<i>Time (wks)</i>	<i>No. Patients</i>
0-1	10
1-2	3
1-4	2
1-16	1

A laryngeal evaluation on the remaining three patients was delayed several days after the endotracheal tube had been removed. In all of these there was a significant but milder degree of inflammatory arytenoid edema than the patients evaluated earlier in their course. Nevertheless, cord paralysis of a symmetrical nature was noted in all three. On initial evaluation in each instance, the true vocal cords were in an essentially paramedian position with only partial and incomplete adducting movements.

LARYNGEAL RESOLUTION

The initial symmetrical vocal cord paralysis or paresis with arytenoid inflammatory edema resolved in all patients. The time required for a spontaneous resolution was measured from the point of extubation and is given in Table 4. The pattern for resolution was similar in all patients. There was progression from paralysis to paresis to full recovery; however, the degree of movement varied on a day-to-day basis. The earliest movements to recovery in each instance were those of adduction, with a slower but progressive recovery toward full abduction. Complete adducting closure of the posterior glottis closely paralleled the recovery of full abduction. Fourteen of the 16 patients maintained symmetrical recovery of movement between the two vocal cords. In two patients, one cord recovered completely several weeks prior to the opposite cord.

The inflammatory soft tissue laryngeal findings roughly subsided as motion returned to normal. The aryepiglottic fold and false cord inflammatory changes subsided earliest. Resolution of arytenoid edema took longer, but was complete by the time full cord motion returned in all patients.

ADDITIONAL FINDINGS

The regional symptoms elicited from the patients in this series were surprisingly few. Of course, during the early phases the patients were acutely and severely ill which would tend to override any but the most severe discomfort. Throat pain was invariably present, and swallowing made the discomfort worse in each instance. Two patients initially complained of odynophagia; however, this symptom cleared early in the course of resolution. Six patients had initial tenderness to palpation of the thyroid cartilage which rapidly subsided.

Three patients had endoscopy during the early postextubation phases. These studies confirmed the mirror and fiberoptic findings. All three had marked "stiffness" of direct arytenoid rotation.

Fifteen of the 16 patients in this series had tracheotomy tubes in place during laryngeal resolution which makes documentation of aspiration less meaningful. Each of these patients had serial methylene blue swallows which showed free aspiration of the dye into the trachea. Radiographic contrast study was done in two patients, and likewise demonstrated free aspiration.

CLINICAL SIGNIFICANCE OF LARYNGEAL DYSFUNCTION

Even though resolution of laryngeal immobility spontaneously occurred in all patients, the clinical importance of this dysfunction should be stressed. For this series, two patients developed laryngeal sequelae. Both developed the clinical findings which were described following extubation, with spontaneous resolution to a point of normal adduction and nearly complete return of abducting movements at 10 and 16 days. At that point, both patients were discharged to be followed by their primary physicians. At two and four months respectively they returned with a several-week history of progressive airway obstruction. Subsequently, both patients progressed to a midline fixed vocal cord on the basis of posterior commissure stenosis which was confirmed and corrected surgically in each instance. It is believed that the early immobility allowed organization

of posterior commissure fibrosis which achieved clinical significance as the scar contracted during the healing phase.

Fourteen of the 16 patients developed or experienced worsening of pneumonitis within 48 hours of extubation. Clinically, this event was accompanied by acute hypoxia, fever and radiographic findings of new lower lobe infiltrates suggestive of aspiration. One patient was started on oral liquids by the primary service and subsequently developed a lung abscess. During this period, the laryngeal examinations on all patients showed incomplete glottic closure. Despite other possible explanations for pneumonitis in these ICU patients, the laryngeal dysfunction is felt to play a significant contributing role.

Three patients developed unexpected upper airway obstruction following extubation which required crash reintubation and an emergency tracheotomy. In each of these instances the only point of airway obstruction was at the glottic level. Three additional patients had delay in tracheotomy decannulation because of slow resolution of the cord paralysis. One patient showed no truly significant effects from the laryngeal findings which resolved rapidly.

DISCUSSION

A recurring clinical picture of laryngeal dysfunction following prolonged intubation in the adult has been presented. The incidence of occurrence is not known for this type of patient population, however it is felt not to be uncommon. It is believed that these laryngeal effects are brought about by the mechanical trauma of the tube as it rides within the posterior endolarynx. This traumatizing force is constant and ongoing, related to tube movement, reflex, and laryngeal movements against the tube. When extubation occurs, a return of full arytenoid motion initiates what clinically appears to be a traumatic

cricoarytenoid arthritis as a fundamental element. Montgomery's studies of acute cricoarytenoid arthritis in other patient populations show remarkable similarities to the events in these patients.⁶ Additional factors which may play a role include the mechanical effects of edema, inflammatory involvement of intrinsic laryngeal musculature and perhaps motor nerves as well. Resolution of this process occurs spontaneously following extubation, with the majority of patients returning to normal laryngeal mobility rapidly.

The clinical significance of even transient laryngeal dysfunction is evident to the otolaryngologist and reinforced from the examples given. Perhaps most importantly, the loss of laryngeal sphincteric function allows aspiration with deleterious pulmonary effects. It should be noted that in addition to vocal cord paralysis with the usual finding of incomplete posterior glottic closure, there is inflammatory edema of the aryepiglottic folds, false cords and arytenoids as well. All of these effects combine to cause transient loss in the three-tier laryngeal closure mechanism. The resultant aspiration that occurs may be catastrophic for an already acutely and chronically ill patient with minimal reserves. Morbidity and mortality may occur without recognition of the primary organ failure, which is the larynx.

A reassessment of laryngeal tolerance to prolonged intubation is needed. Emphasis on the early functional derangements which occur must supplement the well appreciated long-term sequelae. Prevention of the problems presented in this series remains the best approach. This can only be achieved by continued efforts to minimize the quantity of trauma with tube design and tube care. Further, the duration of unpreventable trauma delivered to the endolarynx must be reduced by earlier tracheotomy in these patients.

REFERENCES

1. Hawkins DB: Glottic and subglottic stenosis from endotracheal intubation. *Laryngoscope* 87:339-346, 1977
2. Schlorf RA, Duvall AJ III: Post-intubation granuloma of the larynx. *Minn Med* 52: 717-720, 1969
3. Prasertwanitch Y, Schwarz JJ, Vandam LD: Arytenoid cartilage dislocation following prolonged endotracheal intubation. *Anesthesiology* 41:516-517, 1974
4. Holley SH, Gildea JE: Vocal cord paralysis after tracheal intubation. *JAMA* 215: 281-284, 1971

5. Hahn FW, Martin JT, Lillie JC: Vocal cord paralysis with endotracheal intubation. *Arch Otolaryngol* 92:226-229, 1970

6. Ellis PD, Pallister WK: Recurrent laryngeal nerve palsy and endotracheal intubation. *J Laryngol Otol* 89:823-826, 1975

7. Bryce DP, Briant TD, Pearson FG: Laryngeal and tracheal complications of intubation. *Ann Otol Rhinol Laryngol* 77:442-461, 1968

8. Montgomery WW: Cricoarytenoid arthritis. *Laryngoscope* 73:801-836, 1963

REPRINTS — Robert E. Whited, MD, Department of Otolaryngology and Maxillofacial Surgery, University of Cincinnati Medical Center, 231 Bethesda Ave., Cincinnati, OH 45267.

DISCUSSION

ROBERT E. WHITED, MD (closing): The point about the posterior commissure stenosis is that in patients who develop this early transitory paralysis or immobilities, presumably do so on the basis of a traumatic cricoarytenoid arthritis. When followed prospectively this early immobility in these two patients lasting in one instance 10 days and in the other instance 16 days, they were discharged from the hospital with a return of motion and over the next several months gradually came in less and less abduction so that they eventually resulted in midline fixed cords on the basis of what was surgically confirmed and surgically corrected as a submucosal posterior commissure stenosis. So it is presumed that this early

immobility did allow deposition of scar tissue such that as that scar tissue matured over the next two to three months, they developed this progressive midline fixation of the cord.

GABRIEL F. TUCKER, MD (Chicago, Illinois): I feel I must make one further comment on Dr. Whited's paper. I appreciate his use of the term immobility or dysfunction but I am seriously concerned that this paper will be indexed in the literature as using the term paralysis. I think paralysis means a very specific neuromuscular dysfunction and I don't think he has shown us any reason to use this term. I would hope that in the final paper the word paralysis will not be used.

RECURRENT LARYNGEAL NERVE SECTION FOR SPASMODIC DYSPHONIA

HOWARD L. LEVINE, MD

BENJAMIN G. WOOD, MD

EUGENE BATZA, PhD

MELINDA RUSNOV, MA

HARVEY M. TUCKER, MD

CLEVELAND, OHIO

Spasmodic dysphonia is a severe disorder of phonation accompanied by extreme tension of the entire phonatory system. The expressive functions of speech such as laughter, singing, and whispering are much less affected if at all. Psychotherapy, speech therapy, stimulant and psychotropic drugs, hypnotism and acupuncture have all been tried as treatment without success. In 1976, Dedo reported 34 patients who were managed with recurrent laryngeal nerve section for spasmodic dysphonia. All of these patients had marked improvement in voice with relief of spasticity. Twenty-two patients with documented spasmodic dysphonia present for at least one year have been managed at the Cleveland Clinic since Dedo's report. None of them had any improvement with conventional voice therapy and were subjected, therefore, to recurrent laryngeal nerve section.

Spasmodic dysphonia is a rare disease of phonation characterized "by a strained, creaking, and choked vocal attack, a tense and squeezed voice sound that is accompanied by extreme tension of the entire phonatory system."¹ The expressive functions of speech such as laughter, singing, and whispering are much less affected, if at all.

In 1976, Dedo² reported 34 patients who underwent recurrent laryngeal nerve section for this condition and obtained marked improvement in voice with relief of spasticity. Because of those results, recurrent laryngeal nerve lysis was performed on 22 patients with spasmodic dysphonia at the Cleveland Clinic. This paper reports the results obtained in these patients.

METHODS AND MATERIALS

Thirty-five patients with diagnosis of spasmodic dysphonia are currently being followed at The Cleveland Clinic Foundation. Those patients who had undergone at least one year of speech therapy without significant improvement were considered potential candidates for recurrent laryngeal nerve lysis. Twenty-nine of these patients underwent preoperative evaluation of potential voice improvement by injecting 5-10 cc of Xylocaine® 1% into the area of the point of entry of the recurrent laryngeal nerve into the larynx to create a temporary nerve block. This was accomplished by

preparing the neck and turning the head to the opposite side. A small weal was raised at approximately the level of the cricothyroid membrane just anterior to the sternocleidomastoid muscle. Using a long spinal needle, the injection was then achieved by directing the needle at the palpated point representing the inferior cornu of the thyroid cartilage. Approximately 1 cc of Xylocaine was then injected incrementally in this area until repeated phonation by the patient showed a clinical improvement. At this point the needle was withdrawn and the patient examined by mirror laryngoscopy. When this study confirmed that unilateral cord paralysis had been achieved, postinjection voice recordings were obtained. Fourteen of the patients underwent bilateral injection in this fashion, the individual procedures being separated by several days' time. In those cases in which both sides were injected and recorded, the tapes were played back and the patient, the speech pathologist and the otolaryngologist jointly decided which side gave the better voice result. Twenty-two of the 29 patients subsequently underwent recurrent laryngeal nerve lysis. In five patients, in whose cases initial successful results later deteriorated, subsequent ipsilateral superior laryngeal nerve lysis was also carried out. All patients in the series have been followed postoperatively by the laryngologist and speech pathologist with sequential voice recordings. The length of follow-up has varied from a minimum of six months to a maximum of three years.

SURGICAL TECHNIQUE

Recurrent Laryngeal Nerve Lysis.
The head is rotated to the side opposite

From the Department of Otolaryngology and Communicative Disorders, The Cleveland Clinic Foundation, Cleveland, Ohio.

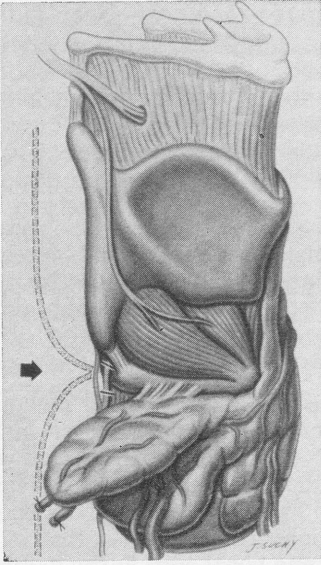


Fig. 1. Mobilization of the superior pole of the thyroid gland and identification of the recurrent laryngeal nerve at the cricothyroid joint (arrow).

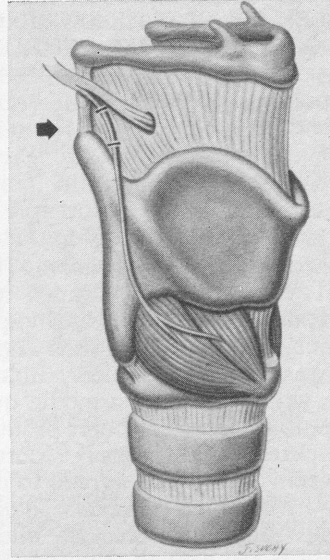


Fig. 2. Identification (arrow) of the external branch of the superior laryngeal nerve by retrograde dissection from internal branch.

that to be operated upon. A horizontal incision is made in a skin crease at the level of the cricothyroid membrane. The strap muscles are identified after elevation of superior and inferior flaps and they are separated in the midline. Having been mobilized in this fashion, the strap muscles are retracted laterally and the cricoid cartilage identified. If necessary, the superior pole of the thyroid gland is mobilized at the same time. Dissection in this area allows an approach to the cricothyroid joint (Fig. 1). The nerve is consistently identified inferior to this point in the tracheoesophageal groove. After identification of the nerve, a 1-2 cm segment is carefully exposed and without applying any traction, excised cleanly for subsequent studies. A small drain is placed and the wound closed in layers in the usual fashion.

Superior Laryngeal Nerve Lysis. Incision is made in a skin crease just below the upper border of the thyroid cartilage. The incision is then carried through skin, superficial fascia and platysma to expose the greater cornu of the thyroid cartilage. Dissection in this area will identify the neurovascular bundle and retrograde dissection from this point allows identification of the external branch of the superior laryngeal nerve which is

then traced downward to its point of entry into the cricothyroid muscle (Fig. 2). Following positive identification, a 1-2 cm segment of the nerve is excised for later studies. The wound is closed in layers with a small drain.

RESULTS

Of the 29 patients who underwent temporary vocal cord paralysis by Xylocaine injection, all but one exhibited marked improvement in voice quality with relief of spasm and facial grimacing. All of the 14 patients who were subjected to bilateral sequential recurrent laryngeal nerve injection performed on separate days exhibited a distinct difference in the quality of improvement obtained from one side or the other. When the postinjection recordings were compared, the three decision-making observers agreed unanimously that one side provided a better voice quality with less spasticity, less breathiness and greater ease of sound production. In each such case it was this "better" side that was chosen for subsequent nerve lysis.

Of the 22 patients who underwent recurrent laryngeal nerve lysis, 13 had the procedure performed on the right recurrent laryngeal nerve and nine on the

TABLE 1. RESULTS OF RECURRENT LARYNGEAL NERVE SECTION

Total patients		22
Right	13	
Left	9	
Initial improvement		22
Late recurrence		5

left recurrent laryngeal nerve (Table 1). All patients operated upon in this manner demonstrated distinct improvement in symptomatology. Such improvement was defined as clear, unhalting speech with relief of spasmodic quality and improved ease of sound production as compared to presurgical recordings. Such improvement was agreed to unanimously by all three observers (otolaryngologist, speech pathologist and patient) in every case.

Five patients ultimately developed some recurrence of spasmodic dysphonia: one 4 months, one 7 months, one 8 months, one 11 months, and one 22 months following surgery (Table 2). All of these patients underwent subsequent ipsilateral superior laryngeal nerve lysis. Two of them achieved either complete or significant improvement in voice with loss of the spasmodic quality as a result of this surgery. The remaining patients who underwent superior laryngeal nerve lysis gained no improvement and are considered complete failures. Several of the 22 patients undergoing recurrent laryngeal nerve lysis exhibited an initial breathiness in addition to the loss of the spasmodic quality of voice. All but one of these recovered to what were considered good levels without further intervention within a matter of several days to a maximum of three weeks. In one case the persistent breathiness was of such severity that a Teflon® injection was performed nine months after surgery. This gave a very good voice result and this improvement has been maintained without evidence of recurrence of spasmodic dysphonia.

DISCUSSION

In 1938, Berendes¹ described spasmodic dysphonia as a typical neurosis. Robe et al³ were the first to consider it an organic disorder of the central nervous system. Ninety percent of their patients had abnormal electroencephalo-

TABLE 2. RECURRENT PLUS IPSILATERAL SUPERIOR LARYNGEAL NERVE SECTION

Total patients		5
Initial improvement	2	
Failure	3	

grams and 83% had other pyramidal tract signs. Aronson et al⁴ agreed that spasmodic dysphonia might have an organic etiology. They found abnormal neurologic examinations in 20 of the 27 patients they reported.

In 1976, Dedo² reported sectioning of the recurrent laryngeal nerve in 34 patients. All of his patients were pleased with their resulting voices. However, several had mild residual hoarseness and breathiness. He theorized that by paralyzing one vocal cord in the paramedian position, the contralateral cord could be considered "precompensated," due to its preexistent ability to adduct across the midline.

From a histologic standpoint, study of the sections of recurrent laryngeal nerve removed at surgery has tended to confirm the organic basis for this disease process. Dedo² found nerve bundle groups that did not stain for either myelin or axones by light microscopy. He found no active breakdown of myelin by macrophages, however. These findings seemed consistent with a demyelinating process in 30% of the patients examined.

Bocchino and Tucker⁵ studied electron microscopic histology in recurrent laryngeal nerves removed for spasmodic dysphonia. They found segmental demyelination in all cases examined. Control cases did not show any of these changes. The axones were noted to be normal except for occasional secondary changes resulting from extensive demyelination. It was their opinion that spasmodic dysphonia, whatever its ultimate cause, resulted in peripheral demyelination and that the disease might be related to other cranial nerve syndromes in which similar histopathologic findings have been reported.

It is noteworthy that all patients in whom bilateral preoperative recurrent laryngeal nerve injections were under-

taken demonstrated a significant difference in voice quality from one side to the other. Since the better voice result was chosen for laryngeal nerve section and since demyelination was identified in essentially every case by electron microscopy, some evidence has been produced to suggest that the disease process is, indeed, a bilateral one. This conclusion is based on the fact that the better voice result should be obtained when the less active cord is paralyzed, leaving the more abnormal (thus more strongly adducting) cord intact. If, under those circumstances, pathologic changes have been identified in every nerve removed, it would seem that the disease process involved both nerves.

CONCLUSION

Surgical lysis of the recurrent laryn-

geal nerve may be regarded as an acceptable approach to patients with spasmodic dysphonia, in those cases in which conventional therapy has failed. While not every patient will have persistently successful results from this operation, subsequent lysis of the ipsilateral superior laryngeal nerve can give a good long-term result in nearly every case. Further long-term experience with recurrent laryngeal nerve lysis for spasmodic dysphonia is needed before this procedure can be presumed to be permanently effective.

Continued experience both clinically and with histopathologic examination of excised recurrent laryngeal nerves continues to support the view that spasmodic dysphonia is an organic disease process rather than one of purely psychological origin.

REFERENCES

1. Berendes J: Zur Entstehung und Behandlung der Dysphonia Spastica. *Z Hals Nasen Ohrenheilkd* 44:78, 1938
2. Dedo HH: Recurrent laryngeal nerve section for spastic dysphonia. *Ann Otol Rhinol Laryngol* 85:451-459, 1976
3. Robe E, Brumlik J, Moore P: A study of spastic dysphonia, neurologic and electroencephalographic abnormalities. *Laryngoscope* 79:219-245, 1960
4. Aronson AE, Brown JR, Litin EM: Spastic dysphonia: Neurological and psychiatric aspects. *J Speech Hear Disord* 33:203-218, 1968
5. Bocchino JV, Tucker HM: Recurrent laryngeal nerve pathology in spasmodic dysphonia. *Laryngoscope* 88:1274-1280, 1978

REPRINTS — Howard Levine, MD, Department of Otolaryngology and Communicative Disorders, The Cleveland Clinic Foundation, 9500 Euclid Ave., Cleveland, OH 44106.

LARYNGEAL NERVE CRUSH FOR SPASTIC DYSPHONIA

HUGH F. BILLER, MD

MAX L. SOM, MD

WILLIAM LAWSON, MD

NEW YORK, NEW YORK

Four patients with spastic dysphonia refractory to speech and psychiatric therapy were treated by crushing the recurrent laryngeal nerve. Vocal cord paralysis was produced in all patients. Vocal spasticity subsided in all patients. Vocal cord motion returned in four to six months. Three of four patients remained free of spasticity for a minimum of 24 months.

In 1976 Dr. H. Dedo presented to the American Laryngological Association the sectioning of the recurrent laryngeal nerve for the treatment of spastic dysphonia.¹ This was a radical treatment approach for a disease which was thought, by most, to be psychogenic in origin. Dr. Dedo was courageous and deserves great credit for reawakening the interest in this disease by laryngologists, speech therapists and psychiatrists. He is responsible for the recent clinical investigative climate and above all the grateful patients, who prior to this surgical approach were relegated to a life with significant disability.

Even though the success of recurrent laryngeal nerve sectioning is unchallenged, there has been reluctance by some laryngologists to permanently paralyze the recurrent laryngeal nerve. Som and Biller in a letter to the editors in 1977 described the successful treatment in a patient with spastic dysphonia by crushing the recurrent laryngeal nerve.²

The purpose of this paper is to describe the long-term results in a small number of patients who were treated by recurrent laryngeal nerve crush.

METHODS AND MATERIALS

Four patients (two females and two males) with a clinical diagnosis of spastic dysphonia were treated by crushing the left recurrent laryngeal nerve (Table 1). The duration of the disease prior to surgery varied from 2 to 20 years. The initiating factors were thought to be, by the patients, emotional strain in one and upper respiratory infection in three.

The four patients at various times during the disease had received both speech and psychiatric therapy. One patient considered speech therapy to have improved the voice minimally. All patients had clinical relief of their vocal spasticity following paralysis of the vocal cord by Xylocaine® injection of the left recurrent laryngeal nerve. Voice recordings were obtained prior to surgery. The procedure of recurrent laryngeal nerve crush was performed under general anesthesia. Following mobilization of the thyroid lobe, the left recurrent laryngeal nerve was isolated and crushed with a hemostat.

RESULTS

There were no complications relating to the surgery (Table 2). Postoperatively, the left vocal cord was paralyzed in all patients and there was complete resolution of the vocal spasticity as judged clinically and by comparison of pre- and postoperative recordings. Three of the four patients had slight huskiness of their voices which subsided within seven days. Three of four patients continued to have the typical breathing pattern which was present prior to surgery. The abnormal breathing pattern returned to normal following one or two sessions with the speech therapist. The patients were followed at monthly intervals postoperatively. The left vocal cord motion returned in four to six months. Three patients were followed 20, 29 and 30 months respectively and remained free of dysphonia. One patient with return of vocal cord motion at four months experienced a return of spastic dysphonia, although of less severity than before surgery.

DISCUSSION

Although the results of recurrent laryn-

From the Mount Sinai Medical Center, New York, New York.

TABLE 1. MATERIAL

Pt.	Sex	Age	"Cause" of Dysphonia	Psychiatric & Speech Therapy	Improvement With Therapy
H.D.	M	46	URI	Yes	None
E.K.	F	51	URI	Yes	None
R.G.	M	42	Emotional Stress	Yes	Slight
H.S.	F	58	URI	Yes	None

URI - Upper respiratory infection.

geal nerve section have been excellent, the fact remains that an important motor nerve is sacrificed. The permanent loss of function of the recurrent laryngeal nerve may have deleterious effects on the patient in the future. Involvement of the contralateral recurrent laryngeal nerve by viral infections, diabetic or other neuropathies, cerebral vascular disease, intrathoracic or mediastinal disease, thyroid disease, external trauma or intubation may result in a patient with a bilateral vocal cord paralysis. Similarly, the paralyzed vocal cord frequently is an early diagnostic sign of treatable disease. Also to be considered is the possibility of subsequent vocal cord atrophy resulting in a lateralized cord and a breathy voice. For these reasons some laryngologists are hesitant to sever electively the recurrent laryngeal nerve.

TABLE 2. RESULTS OF NERVE CRUSH

Pt.	Return of VC Motion (mo)	Follow-Up (mo)	Results
H.D.	6	30	S
B.K.	6	29	S
R.G.	5	20	S
H.S.	4	6	F

VC - Vocal cord ; S - Success ; F - Failure.

Crushing the recurrent laryngeal nerve is an alternative procedure which produces successful results with ultimate preservation of vocal cord motion.

Dedo postulates that spastic dysphonia is related to a disturbance of the proprioceptive control of the vocal cord. The cause, most likely viral, affects the sensory fibers with preservation of the larger motor fibers. The success of the nerve crush may be related to the permanent damage of the proprioceptive fibers while the motor fibers are capable of regeneration.

Two years after the nerve crush, three of the four patients are without evidence of dysphonia. Indirect view of the larynx shows normal cord motion. The single failure developed return of vocal cord mobility at four months along with spasticity. The early return of mobility may reflect insufficient crushing injury at the time of surgery. The authors are satisfied with the results of the nerve crush and will continue to use this method in the treatment of spastic dysphonia. The early results indicate that crushing of the laryngeal nerve, rather than laryngeal nerve section, may be the preferred treatment.

REFERENCES

1. Dedo HH: Recurrent laryngeal nerve section for spastic dysphonia. *Ann Otol Rhinol Laryngol* 85:451-459, 1976
2. Som ML, Biller HF: Letter to the editor. *Ann Otol Rhinol Laryngol* 86:411, 1977

Reprints — Hugh F. Biller, MD, Department of Otolaryngology, Mount Sinai School of Medicine, 5th Ave. and 100th St., New York, NY 10029.

DISCUSSION OF PREVIOUS TWO PAPERS

HERBERT H. DEDO, MD (San Francisco, California): It is very nice to have other people find spastic dysphonia interesting and feel that recurrent nerve section does have a place in treatment of this disorder. I stopped doing lidocaine block after the first 100 or so, because by then I was satisfied that I could di-

agnose the disorder more reliably with my ear, and because that needle does hurt. Also, in the gross cases of spastic dysphonia, you really don't need to do the lidocaine injection to make the decision whether or not to do the surgery and in the mild forms of spastic dysphonia it was possible to be misled by the re-

sult, because of the initial breathiness. The other misleading effect is that it is difficult to paralyze the recurrent nerve at the inferior cornu of the thyroid cartilage without having some of the Xylocaine® drift up and paralyze the external branch of the superior laryngeal nerve. The key to diagnosis is the need to listen with the ear.

I am worried that somebody is going to section a recurrent nerve in the wrong type of patient. The most common mistake in diagnosis, in my experience, is that I've been sent patients who have what I call whisper dysphonia. To me, spastic dysphonia means the vocal cords are too tight together during phonation. Ordinarily a spastic dysphonic can laugh and sing clearly and yet have this tightness in the voice in running speech.

I've had equal results with nerve block on each side and with surgery on each side. I now do the recurrent laryngeal nerve section on the left because of the greater theoretical risk of later spontaneous paralysis on the left.

I understand the reluctance to section this nerve by Drs. Som and Biller, and their preference for crushing it or the superior laryngeal nerve. In my experience the superior laryngeal nerve block just gives a very minor reduction

of spasticity and thus is insufficient as the primary procedure. As far as crushing the nerve is concerned, I have done this in three patients and when the mobility of the cord returned after three to six months, the spasticity simultaneously returned. The disadvantage of the nerve crush is that if the spasticity does come back, a second operation is necessary and it is harder to find the nerve when there is scar from a prior operation.

In the 3-5% where the voice is still too breathy or weak one year postoperatively I do a Teflon® injection but underinject or the spastic dysphonia will return. I know a patient where it was done at four months and he redeveloped spasticity because the larynx had not fully stabilized. If they get some spasticity back, as we have seen happen in about 3-5% of over 210 of these patients, and if it's mild you can section the superior laryngeal nerve because recurrent nerve paralysis puts the cord in the paramedial position while recurrent plus superior nerve paralysis puts it in the intermediate position. If marked spasticity comes back, superior laryngeal nerve section will be insufficient so we now do a vocal cord thinning operation, such as I described at the Western Section of the Triological Society, when we find a convex vocal cord after Teflon injection.

Executive Sessions

FIRST EXECUTIVE SESSION

April 1, 1979

The first Executive Session of the One Hundredth Annual Meeting was convened at 8:00 A.M. in the Ballroom of the Century Plaza, Los Angeles, California, John F. Daly, MD of New York City, New York presiding.

The following candidates, having been recommended for Fellowship by the Council were unanimously elected:

To Active Fellowship:

Thomas C. Calcaterra, MD, Los Angeles, California
Charles J. Krause, MD, Ann Arbor, Michigan
Francis E. LeJeune, Jr., MD, New Orleans, Louisiana
Eugene M. Myers, MD, Pittsburgh, Pennsylvania
Myron J. Shapiro, MD, Livingston, New Jersey
Gershon J. Spector, MD, St. Louis, Missouri
M. Eugene Tardy, Jr., MD, Chicago, Illinois
Harvey M. Tucker, MD, Cleveland, Ohio

To Emeritus Fellowship:

G. Slaughter Fitz-Hugh, MD, Charlottesville, Virginia

Following their election the new Active Fellows were introduced to the Association by their respective sponsors, presented with certificates of Fellowship and welcomed by President Daly.

The following Fellows were elected as members of this year's Nominating Committee:

DeGraff Woodman, MD, Chairman
F. W. Davison, MD
Johnson Putney, MD
Alden H. Miller, MD
Joseph L. Goldman, MD

The following Officer's reports were submitted and duly accepted:

Report of the Secretary

Report of the Treasurer

Having heard the Treasurer's Report it was duly moved, seconded, and passed that there be a dues increase to \$150.00 per year; the initiation fee is increased to \$200.00.

SECOND EXECUTIVE SESSION

April 2, 1979

The second Executive Session was opened by President Daly at 8:30 A.M. Annual Reports of the following Officer and Representative to another organization were received.

Report of the Librarian, Historian and Editor

Report of the Representative to the American College of Surgeons

President Daly and Secretary Tribble then explained to the Society the process whereby a review of our tax status had brought to light the fact that we had been dropped as a corporation by the State of New York in 1953. Our legal counsel has advised reincorporation in the District of Columbia. This is now in process. We already have verbal assurance from the Internal Revenue Service of our tax exempt status. At this moment there are actually two corporations; the old one founded in New York and the new, based in Washington. As the reorganization proceeds, the assets and the membership will be voted into the new corporation.

After the Scientific Session, the Executive Session was reconvened by President Daly who prefaced the Report of the Nominating Committee with a statement as to Dr. John Conley's inability to accept nomination to the Council because of ill health. Dr. Woodman then presented the Report of the Nominating Committee. After a brief organizational meeting the directors announced their organization for the year 1979-80 as follows:

President: John A. Kirchner, MD

First Vice-President: Albert H. Andrews, MD

Second Vice-President: Seymour R. Cohen, MD

Secretary: William M. Tribble, MD

Treasurer: Harold G. Tabb, MD

Historian, Librarian and Editor: Gabriel F. Tucker, Jr., MD

First Councilor: Stanton A. Friedberg, MD

Second Councilor: Charles M. Norris, MD

Third Councilor: Charles F. Ferguson, MD

Fourth Councilor: John F. Daly, MD

Following the election of the new officers, First Vice-President Andrews presented the pin to retiring President Daly who thanked the Association and all who had helped make the year and the program of the Annual Meeting successful. First Vice-President Andrews then adjourned the meeting.

REPORT OF THE SECRETARY

The membership at the present time is 7 Honorary, 34 Emeritus, 96 Active, 14 Corresponding, for a total of 151. This represents a loss of 2 Emeritus and 2 Corresponding but 6 more Active members than last year. The Honorary status remains unchanged.

Much thanks for the success of our local meeting should go to Dr. Alden Miller who again has given yeoman's service to this Association.

Our banquet tonight will be at the Beverly Hills Hotel. The reception starts at 6:30 p.m. This is an estimated 5-minute taxi ride.

We have available centennial plates and centennial histories for sale for those who wish an extra copy. If anyone failed to receive theirs last year, please let me know.

Our 1980 meeting will be April 14-15 at The Breakers in Palm Beach, Florida. We have advanced our position one day to accommodate a switch with the American Broncho-Esophagological whose meeting will adjoin an International Broncho-Esophagological meeting at The Breakers the preceding week. The 1981 meeting will be May 3-4 at the Bayshore Inn in Vancouver, B.C. The 1982 meeting will again be at The Breakers. I might mention parenthetically that the COSM group has options on The Breakers every even year through the year 2000.

In conclusion I wish to thank the Council for their help, especially President Daly and Treasurer Tabb.

Respectfully submitted,
William M. Trible, MD
Secretary

REPORT OF THE TREASURER

AMERICAN LARYNGOLOGICAL ASSOCIATION
STATEMENT OF ASSETS AND FUND BALANCES

MARCH 15, 1979

ASSETS

GENERAL FUND

Cash	\$ 1,816
------------	----------

TRUST FUND

Current Assets:

Cash - overdraft - due from General Fund	\$(1,364)
Savings Certificate - First Federal Savings and Loan	10,000
Savings Bond - Girard Bank	25,000
U. S. Series H Bonds	6,500
7½% Treasury Notes	29,955
Treasury Bill	9,072
Deposit	600
Total	<u>79,763</u>

Investments (Note 2):

Common stocks	13,980
Mutual fund	37,025
Total	<u>51,005</u>

TOTAL ASSETS	<u>\$132,584</u>
--------------------	------------------

FUND BALANCES

GENERAL FUND	\$ 1,816
TRUST FUNDS	130,768
TOTAL FUND BALANCES	<u>\$132,584</u>

See accompanying notes to financial statements

AMERICAN LARYNGOLOGICAL ASSOCIATION
STATEMENT OF EXCESS DISBURSEMENTS OVER RECEIPTS
GENERAL FUND
FOR THE PERIOD APRIL 1, 1978 THROUGH MARCH 15, 1979

RECEIPTS:

Dues	\$ 8,600
Centennial assessments	600
Sale of banquet tickets	4,690
Sale of transactions	3,750
Council dinner	82
Centennial plates and books	1,388
Interest income (Note 2):	
Savings account	\$ 62
Savings certificate - First Federal Savings and Loan	576
7% Treasury note	1,678
Total	<u>2,316</u>
Total	<u>21,426</u>

DISBURSEMENTS:

Expenses of annual meeting — 1978	
Reception and banquet	7,972
Programs, inserts and certificates	864
Guest of honor - hotel and travel	976
Miscellaneous	38
Total	<u>9,850</u>
Transactions and editorial expense	6,544
Council expenses	4,097
Commemorative books and plates	8,541
General expenses:	
Legal expense	2,305
Stationery, printing and postage	2,169
Officer honorariums	1,200
Accounting	600
Clerical	242
Miscellaneous	26
Foreign exchange expense	8
Total	<u>6,550</u>
Total	<u>35,582</u>

EXCESS DISBURSEMENTS OVER RECEIPTS	<u>(14,156)</u>
FUND BALANCE, April 1, 1978	15,972
FUND BALANCE, March 15, 1979	<u>\$ 1,816</u>

See accompanying notes to financial statements

AMERICAN LARYNGOLOGICAL ASSOCIATION
STATEMENT OF EXCESS RECEIPTS OVER DISBURSEMENTS
TRUST FUNDS
FOR THE PERIOD APRIL 1, 1978 THROUGH MARCH 15, 1979

RECEIPTS:

Interest income (Note 2):	
Savings bond - Girard Bank	\$1,907
U. S. Series H Bonds	472
Total	<u>\$ 2,379</u>
Dividends on common stocks and mutual funds (Note 2)	2,358
Total	<u>4,737</u>
Donations:	
Baker fund	236
Memorial fund	2,000
Total	<u>2,236</u>
Total	<u>6,973</u>

DISBURSEMENTS:

Baker fund:	
Honorarium - Dr. Raymond Fink - Baker memorial lecture	500
Brochures - Valley Press	214
Brochures - Annals Publishing Co.	586
Total	<u>1,300</u>

EXCESS RECEIPTS OVER DISBURSEMENTS	<u>5,673</u>
FUND BALANCE, April 1, 1978	125,095
FUND BALANCE, March 15, 1979	<u>\$130,768</u>

See accompanying notes to financial statements

AMERICAN LARYNGOLOGICAL ASSOCIATION
STATEMENT OF INDIVIDUAL TRUST FUNDS
MARCH 15, 1979

	<i>Fund Balance 4/1/78</i>	<i>Receipts</i>	<i>Transfers</i>	<i>Donations</i>	<i>Disburse- ments</i>	<i>Fund Balance 3/15/79</i>
Daniel C. Baker, Jr. Memorial Fund	\$ 30,483	\$1,154		\$ 236	\$1,300	\$ 30,573
Casselberry Fund	12,609	478				13,087
Johnston Fund	11,941	452				12,393
DeRoaldes Fund	7,137	270				7,407
Newcomb Trust Fund ..	4,687	178				4,865
Newcomb Prize Fund ..	1,095	41				1,136
Research Fund	38,184	1,446	\$ 718			40,348
Memorial Fund	18,959	718	(718)	2,000		20,959
Total	<u>\$125,095</u>	<u>\$4,737</u>	<u>\$</u>	<u>\$2,236</u>	<u>\$1,300</u>	<u>\$130,768</u>

See accompanying notes to financial statements

AMERICAN LARYNGOLOGICAL ASSOCIATION
STATEMENT OF CHANGES IN FUND BALANCES
FOR THE PERIOD APRIL 1, 1978 THROUGH MARCH 15, 1979

FUND PROVIDED BY:

Excess receipts over disbursements - Trust Fund\$ 5,673

FUND APPLIED TO:

Excess disbursements over receipts - General Fund 14,156
Purchase of Treasury Bill 9,072
Deposit 600
Total 23,828

NET DECREASE IN FUNDS \$(18,155)

CHANGES IN FUND COMPONENTS:

Increase (decrease) in fund accounts:

Cash - General Fund\$(14,156)
Cash - Trust Funds (3,999)

DECREASE IN FUNDS \$(18,155)

See accompanying notes to financial statements

AMERICAN LARYNGOLOGICAL ASSOCIATION
NOTES TO FINANCIAL STATEMENTS

1. Summary of Significant Accounting Policies

The organization uses the cash basis method of accounting and is a nonprofit entity exempt from Federal and State income taxes.

Excess cash over anticipated disbursements is transferred from the checking account to the savings account to earn interest.

2. Allocation of Investment Income

Interest on Series H government bonds, Girard Bank savings bond and dividends on common stock and the mutual fund are credited as income to the Trust Fund.

Interest on the savings and loan certificates, on the savings account, and on the 7½% Treasury notes is credited to the General Fund.

Trust Fund income is further allocated to each fund in the ratio the fund bears to the total value of the trust funds at the beginning of the year, except that by action of the Council, January 3, 1976, current income from the Memorial Fund is transferred to the Principal and Retained Earnings of the Research Fund.

3. Centennial Assessments

The following information is provided in regard to the centennial meeting held in Palm Beach, Florida in April, 1978.

The General Fund balance includes a centennial assessment of \$100 per member assessed four years ago and collected over that period of time, plus a banquet surcharge of \$35 per member assessed for current period. As of March 15, 1979 a total of \$14,435 has been collected. The receipts and disbursements span more than the current fiscal period, therefore comparability is impaired.

REVENUES:

Centennial assessment	\$9,775	
Banquet surcharge	<u>4,660</u>	
Total Assessments		\$14,435
Sale of books and plates		<u>1,423</u>
Total Revenues		<u>15,858</u>

EXPENSES:

Annual Meeting:

Dinner, gratuity and tax	\$4,023	
Cocktails	1,373	
Speaker - travel and hotel	976	
Programs	864	
Coasters	741	
Orchestra	655	
Coffee and cokes	448	
Menus	359	
Photographs	43	
Engraving	38	
Registrar	26	
Tickets	<u>20</u>	9,566

Books:

History	2,250	
Printing and binding	3,919	
Art work and typing	793	
Shipping and handling	<u>739</u>	7,701

Plates:

Wilton Armetale	1,992	
Art work	400	
Shipping and handling	<u>739</u>	3,131
Total Expenses		<u>20,398</u>

EXCESS OF DISBURSEMENTS OVER RECEIPTS \$(4,540)

4. Due to cumulative donations to the Memorial Fund totaling \$500 each, three members have reached benefactor status this year, they are:

John F. Daly
Joseph L. Goldman
Charles M. Norris

AMERICAN LARYNGOLOGICAL ASSOCIATION
GENERAL FUND — RESUME

	For the Year Ended March 31,							April 1, 1978 Through March 15, 1979
	1971	1972	1973	1974	1975	1976	1977	1978
EXPENSES:								
Annual meeting	\$ 3,254	\$ 4,746	\$ 3,899	\$ 5,204	\$ 4,525	\$ 5,664	\$ 3,615	\$ 6,930
Council	2,396	3,168	1,447	1,800	1,360	1,906	2,042	3,348
Transactions	3,221	3,654	3,477	2,833	5,124	4,458	4,824	4,124
General	<u>1,934</u>	<u>2,021</u>	<u>940</u>	<u>3,279</u>	<u>3,697</u>	<u>2,373</u>	<u>4,585</u>	<u>5,512</u>
Totals	10,805	13,589	9,763	13,116	14,706	14,401	15,066	19,914
INCOME	<u>9,021</u>	<u>13,179</u>	<u>12,411</u>	<u>14,723</u>	<u>13,284*</u>	<u>16,752*</u>	<u>16,621*</u>	<u>14,788*</u>
GAIN (LOSS)	<u>\$(1,784)</u>	<u>\$ (410)</u>	<u>\$ 2,648</u>	<u>\$ 1,607</u>	<u>\$(1,422)</u>	<u>\$ 2,351</u>	<u>\$ 1,555</u>	<u>\$(5,126)</u>
								<u>\$ (14,156)</u>

*Excluding Centennial Assessments.

AMERICAN LARYNGOLOGICAL ASSOCIATION
TRUST FUND INVESTMENTS

MARCH 15, 1979

		April 1, 1978 Through March 15, 1979			Share Value	Market Value
	Cost	High	Low	3/15/79	Shares	3/15/79
STOCK PORTFOLIO:						
COMMON STOCKS:						
American Telephone and Telegraph	\$10,790	61%	61%	61%	200	\$12,275
International Business Machines	1,321	308%	305½	306%	10	3,069
McDonnell-Douglas Corp.	1,194	31½	30½	30%	165	5,053
McIntyre Porcupine	675	<u>30</u>	<u>29</u>	<u>29½</u>	<u>15</u>	<u>439</u>
	<u>\$13,980</u>					<u>\$20,836</u>

MUTUAL FUND:

Massachusetts Investors Trust	<u>\$37,025*</u>		<u>10.81</u>	<u>2,071</u>	<u>\$22,388</u>
		March 15, 1979	March 31, 1978		
Common stocks (at cost)	\$13,980	\$13,980			
Mutual fund (at cost)	<u>37,025</u>	<u>37,025</u>			
Total		51,005	51,005		
Market value		<u>43,224</u>	<u>38,907</u>		
Cost in Excess of Market		<u>\$ 7,781</u>	<u>\$12,098</u>		
Dow Jones Industrials - March 31, 1978				757.36	
Dow Jones Industrials - March 15, 1979				847.02	

*Including initial sales charge and dividends reinvested by purchase of additional shares.

AMERICAN LARYNGOLOGICAL ASSOCIATION
FUND BALANCES

March 31,	General Fund	Trust Fund
1970	\$ 7,178	\$ 65,143
1971	5,394	71,750
1972	4,985	77,374
1973	7,634	79,224
1974	9,240	81,410
1975 (excluding centennial assessments)	7,817	111,075
1976 (excluding centennial assessments)	10,168	114,564
1977 (excluding centennial assessments)	11,723	119,548
1978 (excluding centennial assessments)	6,597	125,095
March 15, 1979	1,816	130,768

Respectfully submitted,
Harold G. Tabb, MD

REPORT OF THE ACCOUNTANT

To the Members of the American Laryngological Association

We have examined the statement of assets and fund balances resulting from cash transactions of the general and trust funds of the American Laryngological Association, at March 15, 1979 and the accompanying statements of excess receipts and disbursements, fund balances, and changes in fund balances for the period April 1, 1978 through March 15, 1979. Our examination was made in accordance with generally accepted auditing standards, and accordingly included such tests of the accounting records and such other auditing procedures as we considered necessary in the circumstances.

In our opinion, such financial statements present fairly the assets and fund balances of the American Laryngological Association at March 15, 1979 arising from cash transactions and the recorded receipts and disbursements and changes in the fund balances for the period April 1, 1978 through March 15, 1979 applied on a basis consistent with that of the preceding year.

Respectfully submitted,
Pechon, Thorpe, Robbert & Favaloro
A Corporation of Certified Public Accountants

March 20, 1979

REPORT OF LIBRARIAN, HISTORIAN AND EDITOR

The 99th Annual Meeting of the American Laryngological Association was held at The Breakers, Palm Beach, Florida, on Saturday, April 22 and Sunday, April 23, 1978. The total attendance recorded was 435 — 86 Fellows (77 Active, 7 Emeritus, 1 Honorary and 1 Corresponding) and 349 guests. The first session of the meeting was a historical session at the end of which President Ferguson introduced Raymond B. Fink, MD, the fourth Daniel C. Baker, Jr. lecturer who spoke on "Energy and the Larynx." This presentation was then followed by two scientific sessions. The proceedings of the scientific sessions were published in the September-October issue of the Annals of Otology, Rhinology and Laryngology; the historical sessions were edited for Annals publication in a form somewhat briefer than that for our Transactions and appeared as part of the January-February issue of the Annals of Otology, Rhinology and Laryngology.

The tapes obtained for Audio-Digest were transcribed in the Editor's office to supply us with working drafts of the discussions and committee reports. These, in turn, were circulated to the pertinent individuals and forwarded to St. Louis in mid-Summer. Galley proof was returned to the Annals editor in mid-Fall and the usual order for 200 copies was placed with the publisher. In order to avoid the Christmas mailing confusion, the bound Transactions were actually mailed early in January. 91 copies were mailed to active members, 7 to honorary members, 7 complimentary copies, including the Library of Congress and the widows of deceased members whose obituaries appeared in this volume of Transactions. Six standing orders are to senior members. 38 standing orders to libraries and book sellers. The price for libraries and book sellers has been increased to \$20.00 but maintained at \$6.00 for those emeritus members who have placed standing orders. Total cost this year was \$6,544.00 as compared to \$4,260.00 last year; this represents a 54% increase in cost. However, with the addition of a historical section to our Transactions, the volume itself is actually 60% longer and thus the price per page is slightly less than last year.

As Historian I have the sad duty to report four deaths since our meeting a year ago:

ACTIVE: Dr. John E. Dickinson, Active '69. Died October 17, 1978.

EMERITUS: Dr. Robert Lukens, Active '27. Emeritus '54. Died June 24, 1978.

Dr. Mervin C. Myerson, Active '27. Emeritus '59. Died August 18, 1978.

Dr. Harry P. Schenck, Active '34. Emeritus '64. Died November 11, 1978.

Respectfully submitted,
Gabriel F. Tucker, Jr., MD
Librarian, Historian, and Editor

REPORT OF THE NOMINATING COMMITTEE

The Nominating Committee after due deliberation came up unanimously with the following slate for members of the Council for the year 1979-1980:

John A. Kirchner, MD

Gabriel F. Tucker, Jr., MD

Albert H. Andrews, Jr., MD

Stanton A. Friedberg, MD

Seymour R. Cohen, MD

Charles M. Norris, MD

William M. Tribble, MD

Charles F. Ferguson, MD

Harold G. Tabb, MD

John F. Daly, MD

Respectfully submitted,
DeGraff Woodman, MD
Chairman

REPORT OF THE AMERICAN COLLEGE OF SURGEONS, BOARD OF GOVERNORS

The meeting was convened by Dr. Oliver H. Beahrs, Chairman of the Board of Governors.

Dr. William H. Muller, Jr., Chairman of the Board of Regents, spoke on the increasingly important role of young surgeons in the College. He also emphasized that the Board of Regents is exploring the need for the College to become actively represented in Washington, DC by the establishment of an office, to obtain first-hand information regarding legislative measures affecting surgery and to relate effectively to government agencies and the Congress.

Dr. Frank E. Stinchfield, President of the College, told the Governors the new summary report of the Governors' recommendations was one of the most important documents reviewed by the Board during their meeting. He pointed out the College has never opposed second surgical opinions and has always spoken strongly against unnecessary surgery. He warned, however, that the national toll-free hotline of HEW makes one wonder if their concern is to provide good care for the surgical patient or to impress the current administration in Washington, DC. He also felt that should the ACS become stronger nationally, it is still necessary that chapters become strong within their local medical and lay communities.

Dr. C. Rollins Hanlon, Director of the College, discussed the chiropractic issue and challenged the authority of the AMA to enter into its recent settlement agreement which is contrary to AMA's principles of medical ethics. He felt the AMA settlement compromises the principle of medical ethics that reads: "A physician

should practice a method of healing founded on scientific basis, and he should not voluntarily associate with anyone who violates this principle."


Dr. Frank C. Spencer, Chairman of the Committee on Professional Liability, indicated that reports reflect the leveling off of the professional liability problem across the country. The frequency of suits and premiums are not rising as rapidly as previously, but striking inequities continue. Medical liability experience in California has a five- to tenfold difference in rates than Massachusetts. There is no data reflecting any true decrease in hospital injuries. There is surprising viability in the physician liability companies which flourish in at least 18 states. A study in Orange County, California, has shown no solid information on any relationship between litigation and lack of professional liability coverage.

Dr. Homer E. Smith, Chairman of the Governors' Committee to Study the Fiscal Affairs of the College, reported that there was a potential budget surplus of \$957,300 for 1979, of which \$500,000 will be placed in the building fund and the remainder in the contingency fund. The dues increased from \$160 to \$175 as recommended.

In conclusion, I have enjoyed greatly my six-year tenure as your Governor to the American College of Surgeons. I am pleased to state the College has selected as my successor Dr. Gabriel F. Tucker, Jr.

Respectfully submitted,
William M. Tribble, MD, FACS
Former Governor,
American College of Surgeons

Memorials



JOHN T. DICKINSON

JOHN T. DICKINSON

1918-1979

John T. Dickinson, MD, DSc, one of the leaders in the field of otolaryngology, died on October 17, 1978, at the age of 60.

He was born in Pittsburgh, Pennsylvania on April 9, 1918, the son of a physician. He graduated from Peabody High School in 1936, where he had been an outstanding football player, as well as class president and valedictorian. For the next four years he attended the University of Pittsburgh, where he was an outstanding end who averaged a blocked punt per game for the great football teams under Dr. Jock Sutherland. He received an offer to play professional football for the Chicago Bears, but declined in favor of attending medical school. Years later, in 1964, he was remembered for his accomplishments on the football field by the Sports Illustrated Magazine, where he received a Silver Anniversary All-American Award. In 1969 he was inducted into the National Football Foundation Hall of Fame, Pittsburgh Chapter.

In 1943, he received his MD from the University of Pittsburgh School of Medicine, where, in addition to completing his medical studies, he also found time to become class president and was assistant football coach under Sutherland from 1940-1943. He then interned at the Mercy Hospital of Pittsburgh and attended the Graduate School for otolaryngology at the University of Pennsylvania from 1944-1945.

Dr. Dean Lierle came into Dr. Dickinson's life to play an important role as both teacher and life-long friend, when Dr. Dickinson was a resident in otolaryngology at the University of Iowa from 1945-1947, and as a fellow from 1947-1948. Under Dr. Lierle's influence Dr. Dickinson developed a great interest in two areas that were to hold his attention for the rest of his life: maxillofacial trauma, and fresh water fishing. After receiving certification by the American Board of Otolaryngology in 1947, he returned to the Graduate School of the University of Pennsylvania between 1950-1952, where he received the Degree of Master of Medical Science and Doctor of Medical Science.

On returning to Pittsburgh, Dr. Dickinson was extremely active in local medical affairs. He was Chief of the Division of Otolaryngology and Maxillofacial Surgery, and Program Director of the Division of Otolaryngology and Residency Training Program at Mercy Hospital in Pittsburgh until he retired from this position in 1976. During those years he also continued as an active member of the Senior Medical Staff at Eye and Ear Hospital of Pittsburgh, and was a Clinical Associate Professor of Otolaryngology in the University of Pittsburgh School of Medicine.

After his retirement from Mercy Hospital, Dr. Dickinson turned his attention in teaching to the Department of Otolaryngology, University of Pittsburgh. He also relocated the American Academy of Facial Plastic and Reconstructive Surgery Audio-Visual Library to the Eye and Ear Hospital and was its Director. The library has now been named the "John T. Dickinson Memorial Audio-Visual Library." From 1974 until the time of his death, he served as Clinical Professor of Otolaryngology at the West Virginia University School of Medicine, where he was active in the teaching program. He was also active in the Pittsburgh Otological Society, and the Pennsylvania Academy of Ophthalmology and Otolaryngology, and had served as President of both Societies.

He contributed tremendously to virtually all of the national organizations related to our specialty. Dr. Dickinson became a member of the American Laryn-

gological Society in 1969. He was on the Board of Directors of the American Board of Otolaryngology from 1973-1978, and served for many years on the Residency Review Committee. He was a member of the Advisory Council for Otolaryngology of the American College of Surgeons, the American Medical Association, the American Academy of Facial Plastic and Reconstructive Surgery (President, 1965), the American Academy of Ophthalmology and Otolaryngology (Chairman of the Plastic and Reconstructive Committee), the American Laryngologic, Rhinologic and Otologic Society (Vice-President of the Eastern Section), the American Cleft Palate Association, the American Society for Head and Neck Surgery (Committee for Surgical Training), the International College of Surgeons, The Society of University Otolaryngologists, and the Pan-American Association of Otorhinolaryngology and Bronchoesophagology.

Numerous honors were bestowed upon Dr. Dickinson, including a special award for outstanding service in Plastic and Reconstructive Surgery given by the American Academy of Facial Plastic and Reconstructive Surgery in 1966. He was a recipient of the Honor Award of Merit in 1969. He received the Distinguished Service Honor Award of Merit from the American Academy of Ophthalmology and Otolaryngology, and the Distinguished Service Honor Award from the Pennsylvania Academy of Ophthalmology and Otolaryngology, both in 1967. In 1971, he received the Herbert Birkett Memorial Lectureship Award as an outstanding leader in Otolaryngology by the Montreal Med-Chi Society.

A steady contributor to the literature in our field, Dr. Dickinson was the author of 34 articles and three book chapters. He was coeditor of a two volume book entitled *Plastic and Reconstructive Surgery of the Head and Neck*, coedited with his life-long friend, John Conley, MD. He also served on the Editorial Board of *The Laryngoscope*, *Otolaryngology Digest*, and the *Study of Reconstructive and Facial Plastic Surgery*, the international microfilm journal.

John Dickinson and Jean Daker were married in 1941, and took great pride and satisfaction in their family of three children, Jody Dickinson, Barbara Jones, and Pamela Finsness. His daughter, Pam, caught some of John's interest in our field, and was very active as an audiologist in John's practice. He also had a granddaughter, in whom he took great pride.

John Dickinson was a man dedicated to his profession, his family, and his friends. He leaves us with a great heritage of honesty, integrity and intensity of purpose. These qualities made him a terrific negotiator in the difficult days when our specialty was not well accepted by colleagues in other fields. He was the idol of those students and residents whom he helped to train, and he was a wise counselor for those colleagues who sought him out. He even demonstrated equanimity and understanding toward those who sought to destroy him.

John will be sadly missed and long remembered by his friends and colleagues.

E.N.M.

ROBERT McDOWELL LUKENS

1888-1978

Robert McDowell Lukens, an Emeritus Fellow of the American Laryngological Association, elected to Fellowship in 1927, died on June 24, 1978 at his home in Wildwood Crest, New Jersey, at the age of 90.

A native Philadelphian, Dr. Lukens received his medical degree from the Jefferson Medical College in 1912. After a rotating internship of 26 months at the Jefferson Hospital he entered the office of Dr. D. Braden Kyle, Professor of Laryngology at Jefferson. This Association was interrupted by World War I in 1917 when Dr. Lukens joined the U. S. Army Medical Service. He was sent overseas and assigned to a Scottish regiment on the Ypres front. He later was transferred to the American War Theatre and served at the American Hospital at Neuilly, France. At war's end, he returned unscathed to Philadelphia and resumed the practice of Laryngology.

Dr. Lukens joined the Department of Laryngology at Jefferson and was placed in charge of the clinic at the Department of Diseases of the Chest. He soon became an authority in the treatment of laryngeal tuberculosis. He demonstrated that chaulmoogra oil, used in the treatment of leprosy in the Far East, was useful in laryngeal tuberculosis.

In 1922, he joined the Chevalier Jackson Bronchoscopic Clinic at Jefferson and was assigned to the Department of Diseases of the Chest to study bronchoscopically chronic broncho-pulmonary diseases. In cooperation with Dr. Aaronson of The Phipps Institute, who was interested in producing tuberculosis by direct implants in laboratory animals, he made many observations which were helpful in determining indications for bronchoscopy in tuberculous patients. Dr. Lukens was on the staffs of the Jewish and Rush hospitals and a consultant at several sanatoriums. He was truly a pioneer in the early development of bronchoscopy in the diagnosis and treatment of chronic broncho-pulmonary disease and made many contributions to the early medical literature. He retired in 1961 and was elected Honorary Clinical Professor of Laryngology and Broncho-Esophagology at Jefferson College.


In 1971, he was awarded the Chevalier Jackson Award by the American Broncho-Esophagological Association of which he was President in 1946. He also was a member of the Triological Society and the American Academy of Ophthalmology and Otolaryngology.

As avocations, Dr. Lukens enjoyed boating and fishing and was an accomplished cellist and painter. His skills with oils won him awards at the A.M.A. Physician Art exhibits. His outstanding canvass, a portrait of Chevalier Jackson hangs in the halls of Jefferson.

He is survived by his wife, Irene, who now resides in Horsham, Pennsylvania.

A truly gentle man, which was evident in his disposition as well as his manual dexterity, he thoroughly enjoyed his clinical practice and shared his avocations with his friends.

L.H.C.



HARRY PAUL SCHENCK

HARRY PAUL SCHENCK

1894-1978

Dr. Harry Paul Schenck was a distinguished otolaryngologist who had a major influence on the thinking and teaching of our specialty during his lifetime.

He was born in Philadelphia to James Buchanan and Savilla Schenck on January 6, 1894. Dr. Schenck received his Bachelor of Science degree from Haverford College in 1917 and was graduated from the University of Pennsylvania School of Medicine in 1923 with the degree of Doctor of Medicine. His post-doctoral education included the graduate school of medicine in the University of Pennsylvania as well as residencies in otolaryngology and pathology at the Hospital of the University of Pennsylvania. He was also a research fellow in allergy.

In 1924 Dr. Schenck married Edna Leinbach who was an inspiration to him in his many scientific achievements.

He was certified by the American Board of Otolaryngology in 1932 and began his outstanding career in private practice in Philadelphia. His strong influence in teaching medical students, residents and graduate students at the University of Pennsylvania led to his appointment as Professor and Chairman of the Department of Otolaryngology which position he held from 1939 to 1959. Other academic positions he held were Assistant Professor of Pathology at the University of Pennsylvania Dental School and Professor of Otolaryngology at the graduate school of medicine.

Dr. Schenck was elected to Fellowship in the American Laryngological Association in 1934 and served as Librarian, Historian and Editor from 1947 to 1952, Secretary from 1952 to 1957 and was elected to the Presidency in 1957. He was the recipient of the Casselberry Award with Dr. Richard A. Kern in 1929 and the Newcomb Award in 1959.

Dr. Schenck had the distinction of serving in the armed forces in two World Wars. He was a private in the U.S. Army with active duty in France in 1918 and served as Captain in the Medical Corps on the Hospital Ship U.S.S. Solace with the University of Pennsylvania Naval Medical Specialist Unit from 1941 to 1943. He was Executive Officer of the U.S. Naval Hospital at Oceanside, California from 1943 to 1946.

The author of over 80 published scientific articles he was also Editor-in-Chief of the five-volume *Encyclopedia of Otolaryngology*. Dr. Schenck had a profound influence on his specialty locally as well as nationally. He was president of the Philadelphia Laryngological Society and Curator of the famous Mutter Museum of the College of Physicians of Philadelphia. He served as Chairman of the Residency Review Committee for Otolaryngology from 1956 to 1961, and was on the executive committee of the Board of Governors of the American College of Surgeons from 1956 to 1964. He actively participated by presenting papers or offering stimulating discussions in the scientific programs of the following societies of which he was a member: The American Otological Society, The American Rhinological, Otological, and Laryngological Society, The American Academy of Ophthalmology and Otolaryngology, The Philadelphia Allergy Society, The Association of Military Surgeons, the New York Academy of Sciences, as well as the prestigious International Collegium Oto-Rhino Laryngologicum Amicitiae Sacrum, being president of the latter organization in 1967. He was a director of the American Board of Otolaryngology from 1951 to 1968 and consultant to the Veterans Administration and the National Research Council. Dr. Schenck was a member of Nu Sigma Nu,

Phi Beta Kappa and Sigma Xi. His hobbies were reading, writing, and collecting rare books and his membership in the Philobiblon Club of Philadelphia furthered these pursuits.

His special ability and interest in research was an inspiration to many of the younger otolaryngologists who came under his influence. His dedication to the national otolaryngologic societies encouraged the busy Philadelphia specialists to attend the meetings of these societies to further their education long before "continuing medical education" became the theme. It was at these meetings that Dr. Schenck proved himself a titan in his field by graciously introducing his young followers to the great men in the field of otolaryngology.

He will long be remembered and revered for his leadership, generosity and inspiration to all who knew him.

L.E.S.

MERVIN C. MYERSON

1892-1978

Dr. Mervin C. Myerson died August 18, 1978 following a myocardial infarction at the age of 86.

Dr. Myerson was born in New York City and was educated in the city's school system. He received his medical degree from The Long Island College Hospital Medical School now known as the Downstate Medical School of The University of The State of New York. He served as Chief of Otolaryngology at Kings County Hospital, Brooklyn, NY from 1930 to 1946 and was Associate Attending Otolaryngologist at The Mount Sinai Hospital, New York, NY, from 1925 to 1932. In 1947 Dr. Myerson left New York for Los Angeles where he practiced his specialty until 1973. While in Los Angeles he was on the staffs of Los Angeles General Hospital and University of California at Los Angeles Hospital. After retirement he moved to Palm Springs for several years and then returned to the east coast.

Dr. Myerson was a dynamic personality, always showing an avid interest in his chosen field. He made many contributions to the otolaryngologic literature. He was the author of two books, *Tuberculosis of The Ear, Nose and Throat* in 1944 and *The Human Larynx* in 1964. He also published 138 papers.

He was a Fellow of both the American Laryngological Association and the American Broncho-Esophagological Association.

Dr. Myerson is survived by his wife Ruth, two daughters from a previous marriage, Mrs. Marvin Tableman and Mrs. Amy Barkshire, and a stepson, Dr. Robert Glass.

J.L.G.

THE MEMORIAL FUND
LARYNGOLOGICAL RESEARCH FUND

The Council earnestly requests that Fellows of the Association give consideration to making a special bequest to these important funds, or to become a Benefactor.

MEMORIAL FUND DONORS

DANIEL C. BAKER, JR.

JOHN F. BARNHILL

AUGUST L. BECK

GORDON BERRY

WILLIAM E. CASSELBERRY

CORNELIUS G. COAKLEY

LEE WALLACE DEAN

ARTHUR W. DEROALDES

FRED W. DIXON

GEORGE FETTEROLF

JOSEPH L. GOODALE

WILLIAM E. GROVE

GORDON F. HARKNESS

FREDERICK T. HILL

GEORGE E. HOURN

SAMUEL JOHNSTON

JAMES E. NEWCOMB

HENRY B. ORTON

LYMAN G. RICHARDS

BURT R. SHURLY

LESTER T. SUNDERLAND

H. MARSHALL TAYLOR

WALTER H. THEOBALD

FRANCIS L. WEILLE

BENEFACTORS

MRS. SALLY SAMPLE AALL

MRS. DANIEL C. BAKER, JR.

DR. EDWIN N. BROYLES

DR. LOUIS H. CLERF

DR. SEYMOUR R. COHEN

DR. JOHN J. CONLEY

DR. AND MRS. FRANCIS W. DAVISON

DR. STANTON A. FRIEDBERG

DR. THOMAS C. GALLOWAY

DR. JOSEPH L. GOLDMAN

DR. ROBERT L. GOODALE

DR. EDLEY H. JONES

MR. A. P. MARCHESSINI

DR. FRANCIS H. MCGOVERN

DR. SAMUEL SALINGER

DR. SAM H. SANDERS

DR. HARRY P. SCHENCK

DR. DEGRAAF WOODMAN

ZELDA RADOW WEINTRAUB CANCER FUND, INC.



Obverse of the deRoaldes medal

RECIPIENTS OF THE DEROALDES AWARD

- 1928. DR. CHEVALIER JACKSON
- 1931. DR. D. BRYSON DELAVAN
- 1934. DR. HARRIS P. MOSHER
- 1937. DR. LEE WALLACE DEAN
- 1943. DR. RALPH A. FENTON
- 1949. DR. GEORGE M. COATES
- 1951. DR. ARTHUR W. PROETZ
- 1954. DR. LOUIS H. CLERF
- 1959. DR. ALBERT C. FURSTENBERG
- 1960. DR. DEAN M. LIERLE
- 1961. DR. FREDERICK T. HILL
- 1966. DR. PAUL H. HOLINGER
- 1970. DR. FRANCIS E. LEJEUNE
- 1973. DR. LAWRENCE R. BOIES
- 1976. DR. ANDERSON C. HILDING
- 1979. DR. JOSEPH H. OGURA

RECIPIENTS OF THE CASSELBERRY AWARD

1923. DR. GEORGE FETTEROLF AND DR. HERBERT FOX
1928. DR. RALPH A. FENTON AND DR. O. LARSELL
1929. DR. RICHARD A. KERN AND DR. HARRY P. SCHENCK
1929. DR. EDWARD H. CAMPBELL
1931. DR. ARTHUR W. PROETZ
1934. DR. ANDERSON C. HILDING
1936. DR. FRANCIS E. LEJEUNE: DR. JOEL J. PRESSMAN
1939. DR. H. MARSHALL TAYLOR: DR. BRIEN T. KING
1940. DR. FRENCH K. HANSEL
1941. DR. NOAH D. FABRICANT
1946. DR. PAUL H. HOLINGER
1949. DR. HENRY B. ORTON
1962. DR. HANS VON LEDEN
1966. DR. JOHN A. KIRCHNER AND MR. BARRY D. WYKE
1968. DR. JOSEPH H. OGURA

RECIPIENTS OF THE NEWCOMB AWARD

- 1941. DR. BURT R. SHURLY
- 1942. DR. FRANCIS R. PACKARD
- 1943. DR. GEORGE M. COATES
- 1944. DR. CHARLES J. IMPERATORI
- 1947. DR. HARRIS P. MOSHER
- 1948. DR. GORDON BERRY
- 1949. DR. GORDON B. NEW
- 1950. DR. H. MARSHALL TAYLOR
- 1951. DR. JOHN D. KERNAN
- 1952. DR. WILLIAM J. McNALLY
- 1953. DR. FREDERICK T. HILL
- 1954. DR. HENRY B. ORTON
- 1955. DR. THOMAS C. GALLOWAY
- 1956. DR. DEAN M. LIERLE
- 1957. DR. GORDON F. HARKNESS
- 1958. DR. ALBERT C. FURSTENBERG
- 1959. DR. HARRY P. SCHENCK
- 1960. DR. JOEL J. PRESSMAN
- 1961. DR. CHEVALIER L. JACKSON
- 1962. DR. PAUL H. HOLINGER
- 1963. DR. FRANCIS E. LEJEUNE
- 1964. DR. FRED W. DIXON
- 1965. DR. EDWIN N. BROYLES
- 1966. DR. LYMAN G. RICHARDS
- 1967. DR. JOSEPH H. OGURA
- 1968. DR. WALTER P. WORK
- 1969. DR. JOHN A. KIRCHNER
- 1970. DR. LOUIS H. CLERF
- 1971. DR. DANIEL C. BAKER, JR.
- 1972. DR. ALDEN H. MILLER
- 1973. DR. DeGRAAF WOODMAN
- 1974. DR. JOHN J. CONLEY
- 1975. DR. FRANCIS W. DAVISON
- 1976. DR. JOSEPH L. GOLDMAN
- 1977. DR. F. JOHNSON PUTNEY
- 1978. DR. JOHN F. DALY
- 1979. DR. CHARLES F. FERGUSON

List of Fellows

PAST OFFICERS

Presidents

(Year of Election)

1879. Louis Elsberg	1909. J. E. Logan
1880. J. Solis-Cohen	1910. D. Braden Kyle
1881. F. I. Knight	1911. James E. Newcomb
1882. G. M. Lefferts	1912. George A. Leland
1883. F. H. Bosworth	1913. Thomas Hubbard
1884. E. L. Shurly	1914. Alexander W. MacCoy
1885. Harrison Allen	1915. G. Hudson Makuen
1886. E. Fletcher Ingals	1916. Joseph L. Goodale
1887. R. P. Lincoln	1917. Thomas H. Halstead
1888. E. C. Morgan	1918. Cornelius G. Coakley
1889. J. N. Mackenzie	1919. Norval H. Pierce
1890. W. C. Glasgow	1920. Harris P. Mosher
1891. S. W. Langmaid	1921. Harmon Smith
1892. M. J. Asch	1922. Emil Mayer
1893. D. Bryson Delavan	1923. J. Payson Clark
1894. J. O. Roe	1924. Lee Wallace Dean
1895. W. H. Daly	1925. Greenfield Sluder
1896. C. H. Knight	1926. Chevalier Jackson
1897. T. R. French	1927. D. Bryson Delavan
1898. W. E. Casselberry	1928. Charles W. Richardson
1899. Samuel Johnston	1929. Lewis A. Coffin
1900. H. L. Swain	1930. Francis R. Packard
1901. J. W. Farlow	1931. George E. Shambaugh
1902. J. H. Bryan	1932. George Fetterolf
1903. J. H. Hartman	1933. George M. Coates
1904. C. C. Rice	1934. Dunbar Roy
1905. J. W. Gleitsman	1935. Burt R. Shurly
1906. A. W. deRoaldes	1936. William B. Chamberlain
1907. H. S. Birkett	1937. John F. Barnhill
1908. A. Coolidge, Jr.	1938. George B. Wood

1939. James A. Babbitt	1961. Dean M. Lierle
1940. Gordon Berry	1962. Francis E. LeJeune
1941. Thomas E. Carmody	1963. Anderson C. Hilding
1942-3. Charles J. Imperatori	1964. Albert C. Furstenberg
1944-5. Harold I. Lillie	1965. Paul H. Holinger
1946. Frank R. Spencer	1966. Joel J. Pressman
1947. Arthur W. Proetz	1967. Lawrence R. Boies
1948. Frederick T. Hill	1968. Francis W. Davison
1949. Ralph A. Fenton	1969. Alden H. Miller
1950. Gordon B. New	1970. DeGraaf Woodman
1951. H. Marshall Taylor	1971. F. Johnson Putney
1952. Louis H. Clerf	1972. Frank D. Lathrop
1953. Gordon F. Harkness	1973. G. Slaughter Fitz-Hugh
1954. Henry B. Orton	1974. Daniel C. Baker
1955. Bernard J. McMahon	1974. Joseph H. Ogura
1956. LeRoy A. Schall	1975. Stanton A. Friedberg
1957. Harry P. Schenck	1976. Charles M. Norris
1958. Fred W. Dixon	1977. Charles F. Ferguson
1959. William J. McNally	1978. John F. Daly
1960. Edwin N. Broyles	<i>Kirchwer miller</i>

Vice-Presidents

1879. F. H. Davis	J. O. Roe
1880. W. C. Glasgow	W. Porter
1881. E. L. Shurly	E. F. Ingals
1882. C. Seiler	S. Johnston
1883. S. W. Langmaid	W. H. Daly
1884. J. H. Hartman	G. W. Major
1885. H. A. Johnson	J. N. Mackenzie
1886. E. C. Morgan	S. W. Langmaid
1887. J. N. Mackenzie	C. E. DeM. Sajous
1888. W. C. Glasgow	C. E. Bean
1889. F. Holden	J. H. Hartman
1890. J. O. Roe	S. Johnston
1891. M. J. Asch	J. C. Mulhall
1892. S. Johnston	W. E. Casselberry
1893. J. C. Mulhall	

1894. C. C. Rice	S. H. Chapman
1895. J. Wright	A. W. deRoaldes
1896. T. M. Murray	D. N. Rankin
1897. A. W. MacCoy	H. S. Birkett
1898. J. W. Farlow	F. W. Hinkel
1899. T. A. DeBlois	M. R. Brown
1900. H. L. Wagner	A. A. Bliss
1901. J. W. Gleitsmann	D. Braden Kyle
1902. G. A. Leland	T. Melville Hardie
1903. J. H. Lowman	W. Peyre Porcher
1904. Thomas Hubbard	W. J. Freeman
1905. J. L. Goodale	C. W. Richardson
1906. G. H. Makuen	A. R. Thrasher
1907. J. P. Clark	J. E. Rhodes
1908. E. Mayer	F. R. Packard
1909. C. G. Coakley	H. P. Mosher
1910. Robert C. Myles	J. M. Ingersoll
1911. F. C. Cobb	B. R. Shurly
1912. A. W. Watson	W. Scott Renner
1913. F. E. Hopkins	Geo. F. Shambaugh
1914. Clement T. Theisen	Lewis A. Coffin
1915. J. Gordon Wilson	Christian R. Holmes
1916. Thomas H. Halsted	Greenfield Sluder
1917. John Edwin Rhodes	D. Crosby Greene
1918. G. E. Shambaugh	John R. Winslow
1919. Francis R. Packard	Harmon Smith
1920. Harmon Smith	W. B. Chamberlin
1921. Dunbar Roy	Robert C. Lynch
1922. George Fetterolf	Lorenzo B. Lockard
1923. Hubert Arrowsmith	Joseph B. Greene
1924. Ross H. Skillern	Gordon Berry
1925. John E. Mackenty	Robert Levy
1926. Lewis A. Coffin	William V. Mullin
1927. Charles W. Richardson	Hill Hastings
1928. Robert Clyde Lunch	Francis P. Emerson
1929. William B. Chamberlin	Ralph Albert Fenton
1930. Harris P. Mosher	James A. Babbitt

1931. Joseph B. Greene	E. Ross Faulkner
1932. Gordon Berry	Frank A. Spencer
1933. E. Ross Faulkner	Thomas S. Carmody
1934. Gordon B. New	Samuel McCullagh
1935. Edward C. Sewall	H. Marshall Taylor
1936. William P. Wherry	Harold I. Lillie
1937. Frank R. Spencer	Bernard J. McMahon
1938. Ralph A. Fenton	Frederick T. Hill
1939. John H. Foster	Thomas R. Gittins
1940. Charles H. Porter	Gordon F. Harkness
1941. Arthur W. Proetz	Henry B. Orton
1942-3 Harold I. Lillie	Dean M. Lierle
1944-5. John J. Shea	Thomas C. Galloway
1946. H. Marshall Taylor	C. Stewart Nash
1947. John J. Shea	Frederick A. Figi
1948. Henry B. Orton	Anderson C. Hilding
1949. LeRoy A. Schall	Fletcher D. Woodward
1950. W. Likely Simpson	Lyman G. Richards
1951. Wm. J. McNally	Thomas C. Galloway
1952. J. Mackenzie Brown	Edwin N. Broyles
1953. Claude C. Cody	Daniel S. Cuning
1954. James H. Maxwell	Clyde A. Heatly
1955. Robert L. Goodale	Paul H. Holinger
1956. Henry M. Goodyear	Robert E. Priest
1957. Francis E. LeJeune	Pierre P. Viole
1958. Charles Blassingame	Chevalier L. Jackson
1959. James Maxwell	Oliver Van Alyea
1960. Walter Theobald	Anderson Hilding
1961. Julius W. McCall	P. E. Ireland
1962. Paul M. Moore	Jerome A. Hilger
1963. Paul M. Holinger	Lester A. Brown
1964. G. Slaughter Fitz-Hugh	Daniel C. Baker
1965. C. E. Munoz-MacCormick	Arthur J. Cracovaner
1966. Lawrence R. Boies	G. Edward Tremble
1967. John F. Daly	Stanton A. Friedberg
1968. DeGraaf Woodman	John Murtagh
1969. Joseph P. Atkins	Stanton A. Friedberg
1970. Robert B. Lewy	Oliver W. Suehs
1971. James A. Harrill	James D. Baxter
1972. Francis L. Weille	Sam H. Sanders
1973. William H. Saunders	Blair Fearon

PAST OFFICERS

- | | |
|--------------------------|---------------------|
| 1974. Joseph H. Ogura | Douglas P. Bryce |
| John A. Kirchner | |
| 1975. John S. Lewis | Edwin W. Cocke, Jr. |
| 1976. Emanuel M. Skolnik | John T. Dickinson |
| 1977. J. Ryan Chandler | Herbert H. Dedo |
| 1978. John E. Bordley | Lester A. Brown |

79
80

*Andrew
D. Haze*

Secretaries and Treasurers *Coker*
Sisson

- | | |
|-------------------------|---------------------|
| 1879. G. M. Lefferts | 1895. H. L. Swain |
| 1882. D. Bryson Delavan | 1900. P. E. Newcomb |
| 1889. C. H. Knight | 1911. Harmon Smith |

Secretaries

- | | |
|-----------------------------|-------------------------|
| 1912. Harmon Smith | 1942. Arthur W. Proetz |
| 1918. D. Bryson Delavan | 1947. Louis H. Clerf |
| 1919. J. M. Ingersoll | 1952. Harry P. Schenck |
| 1920. George M. Coates | 1957. James H. Maxwell |
| 1933. William V. Mullin | 1959. Lyman G. Richards |
| 1935. James A. Babbitt | 1968. Frank D. Lathrop |
| 1939. Charles J. Imperatori | 1972. John F. Daly |
| 1977. William MacL. Tribble | |

Treasurers

- | | |
|-----------------------------|--------------------------|
| 1912. J. Payson Clark | 1948. Gordon F. Harkness |
| 1923. George Fetterolf | 1953. Fred W. Dixon |
| 1932. William V. Mullin | 1958. Francis E. LeJeune |
| 1933. James A. Babbitt | 1962. Alden H. Miller |
| 1935. Charles J. Imperatori | 1969. Charles M. Norris |
| 1939. Frederick T. Hill | 1976. Harold G. Tabb |

Librarians

- | | |
|----------------------|------------------------|
| 1879. F. H. Bosworth | 1930. John F. Barnhill |
| 1883. T. R. French | 1934. Burt R. Shurly |
| 1903. J. H. Bryan | 1935. George M. Coates |

Librarian and Historian

- | | |
|------------------------|----------------------|
| 1936. George M. Coates | 1944. Louis H. Clerf |
|------------------------|----------------------|

Librarian, Historian and Editor

- | | |
|------------------------------|---------------------------|
| 1947. Harry P. Schenck | 1960. Francis W. Davison |
| 1952. Bernard J. McMahon | 1964. F. Johnson Putney |
| 1955. Edwin N. Broyles | 1971. Charles F. Ferguson |
| 1977. Gabriel F. Tucker, Jr. | |

PAST FELLOWS

Dates indicate original election to the Association

**Deceased*

Honorary Fellows

- *1946. Alonso, Justo M., Montevideo, Uruguay.
- *1908. Barnhill, John F., Miami Beach, Florida.
- *1893. Birkett, Herbert S., Montreal, Canada.
- *1878. Bosworth, Francke H., New York, N. Y.
- *1940. Broyles, Edwin N., Baltimore, Maryland.
- *1917. Coates, George M., Philadelphia, Pa.
- *1918. Dean, Lee Wallace, St. Louis, Mo.
- *1881. Delavan, D. Bryson, New York, N. Y.
- *1893. deRoaldes, Arthur W., New Orleans, La.
- *1890. De La Sota Y. Lastra, Ramon, Seville, Spain.
- *1923. Fenton, Ralph A., Portland, Oregon.
- *1879. French, Thomas R., Brooklyn, N. Y.
- *1936. Galloway, Thomas C., Evanston, Illinois.
- *1880. Garcia, Senior Manuel, London, England.
- *1903. Harris, Thos. J., New York, N. Y.
- *1943. Hilding, Anderson C., Duluth, Minnesota.
- *1928. Hill, Frederick T., Waterville, Me.
- *1945. Holinger, Paul H., Chicago, Illinois.
- *1957. Huizinga, Eelco, Groningen, The Netherlands.
- *1907. Jackson, Chevalier, Schwenksville, Pa.
- *1878. Johnston, Samuel, Baltimore, Md.
- *1878. Lefferts, George Morewood, Katonah, N. Y.
- *1914. Levy, Robert, Denver, Colo.
- *1918. Lewis, Fielding O., Media, Pa.
- *1933. Lierle, Dean M., Iowa City, Iowa.
- *1883. Mackenzie, John N., Baltimore, Md.
- *1881. Mackenzie, Sir Morel, London, England.
- *1910. Masser, Ferdinand, Naples, Italy.
- *1904. Mosher, Harris P., Marblehead, Mass.
- *1910. Moure, J. J. E., Bordeaux, France.
- *1937. Nager, F. R., Zurich, Switzerland.

- *1930. Negus, Sir Victor E., London, England.
- *1918. Oliver, H. K., Boston, Mass.
- *1906. Pierce, Norval Harvey, San Diego, Calif.
- *1924. Proetz, Arthur C., St. Louis, Mo.
- *1909. Semon, Sir Felix, Great Missenden, England.
- *1878. Solis-Cohen, J., Philadelphia, Pa.
- *1889. Swain, Henry L., New Haven, Conn.
- *1914. Thomson, Sir St. Clair, London, England.
- *1903. Tilley, Herbert, London, England.
- *1914. Wagner, Clinton, New York, N. Y.
- *1948. Williams, Henry L., Rochester, Minnesota.
- *1890. Wright, Jonathan, Pleasantville, N. Y.

Corresponding Fellows

- *1892. Browne, Lennox, London, England.
- *1938. Blair, Vilray P., St. Louis, Missouri.
- *1968. Cawthorne, Sir Terence, London, England.
- *1940. Colledge, Lionel, London, England.
- *1901. Collier, Mayo, Kearsney, Abbey, Kent, England.
- *1893. Desvernine, Carlos M., Havana, Cuba.
- *1930. Emerson, Francis P., Franklin, Mass.
- *1943. Eggston, Andrew A., New York, N. Y.
- *1961. Faaborg-Anderson, Kund, Nykobing, Denmark.
- *1936. Fraser, John S., Edinburgh, Scotland.
- *1901. Grant, Sir James Dundas, London, England.
- *1887. Cougenheim, A., Paris, France.
- *1894. Holden, Edgar, Newark, N. J.
- *1919. Kelly, Adam Brown, Helensburgh, Scotland.
- *1881. Labus, Carlo, Milan, Italy.
- *1950. Larsell, Olof, Portland, Oregon.
- *1931. LaSagna, Francesco, Parma, Italy.
- *1926. Law, Frederick M., New York, N. Y.
- *1921. LeMaitre, Ferdinand, Paris, France.
- *1902. Lermoyez, Marcel, Paris, France.
- *1897. Luc, H., Paris, France.
- *1896. MacDonald, Greville, Haslemere, Surrey, England.
- *1894. MacIntyre, John, Glasgow, Scotland.

- *1903. McBride, P., York, England.
- *1920. McKenzie, Dan, London, England.
- *1919. McKernon, James F., New Canaan, Conn.
- *1880. Meyer, Wilhelm, Copenhagen, Denmark.
- *1910. Moure, J. J. E., Bordeaux, France.
- *1896. Mygind, Holger, Copenhagen, Denmark.
- *1950. Neil, James Hardie, Auckland, New Zealand.
- *1919. Paterson, Donald Rose, Cardiff, Wales.
- *1941. Patterson, Norman, Herts, England.
- *19 . Rethi, Aurelius, Budapest, Hungary.
- *1919. Rogers, John, Jr., New York, N. Y.
- *1894. Sajous, C. E. DeM., Philadelphia, Pa.
- *1924. Schaefer, J. Parson, Philadelphia, Pa.
- *1896. Schmiegelow, Ernst, Copenhagen, Denmark.
- *1946. Segura, Eliseo, Buenos Aires, Argentina.
- *1940. Soto, E. Fernandez, Havana, Cuba.
- *1881. Thornton, Pugin, London, England.
- *1913. Turner, A. Logan, Edinburgh, Scotland.
- *1880. Whistler, W. McNeil, London, England.
- *1901. Wingrave, Wyatt, Lyme Regis, Dorset, England.
- *1894. Wolfenden, R. Norric, Kent, England.

Emeritus Fellows

- *1936. Ballenger, Howard C., Winnetka, Ill.
- *1923. Barlow, Roy A., Nova Scotia, Canada.
- *1915. Barnes, Harry Aldrich, Kingston, Mass.
- *1944. Beatty, Hugh G., Columbus, Ohio.
- *1928. Beck, Joseph C., Chicago, Illinois.
- *1921. Berry, Gordon, Worcester, Mass.
- *1941. Bowers, Wesley C., New York, N. Y.
- *1901. Brown, J. Price, Toronto, Canada.
- *1891. Bryan, Joseph H., Washington, D. C.
- *1913. Butler, Ralph, Philadelphia, Pa.
- *1930. Campbell, Edward H., Philadelphia, Pa.
- *1959. Cardwell, Edgar P., Newark, New Jersey.
- *1897. Clark, J. Payson, Boston, Mass.
- *1899. Cobb, Frederick C., Bradenton, Florida.

- *1939. Cody, Claude C., Jr., Houston, Texas.
- *1905. Coffin, Lewis A., New York, N. Y.
- *1893. Coolidge, Algernon, Boston, Mass.
- *1937. Crowe, Samuel J., Baltimore, Maryland.
- *1941. Cunning, Daniel S., New York, N. Y.
- *1913. Dabney, Virginia, Washington, D. C.
- *1882. De Blois, Thomas Amory, Boston, Mass.
- *1941. Dixon, Fred W., Shaker Heights, Ohio.
- *1892. Farlow, John W., Boston, Mass.
- *1930. Figi, Frederick A., Rochester, Minn.
- *1922. Forbes, Henry H., New York, N. Y.
- *1933. Foster, John H., Houston, Texas.
- *1905. Freer, Otto T., Chicago, Ill.
- *1932. Furstenberg, Albert C., Ann Arbor, Mich.
- *1940. Gatewood, E. Tribble, Richmond, Va.
- *1928. Gittins, Thomas R., Sioux City, Iowa.
- *1880. Gleitsmann, Joseph W., New York, N. Y.
- *1922. Goldsmith, Perry G., Toronto, Canada.
- *1898. Goodale, Joseph L., Ipswich, Mass.
- *1932. Graham, Harrington B., San Francisco, California.
- *1906. Greene, D. Crosby, Jr., Boston, Mass.
- *1917. Greene, Joseph B., Asheville, N. C.
- *1950. Hall, Colby, Encino, Calif.
- *1905. Halsted, Thomas H., Los Angeles, Calif.
- *1896. Hardie, Thomas Melville, Chicago, Ill.
- *1959. Hart, Verling K., Charlotte, N. C.
- *1915. Hastings, Hill, Los Angeles, Calif.
- *1944. Havens, Fred Z., Rochester, Minn.
- *1888. Hinkel, Frank Whitehill, Buffalo, New York.
- *1944. Hoople, Gordon D., Syracuse, N. Y.
- *1895. Hopkins, Frederick E., Springfield, Mass.
- *1930. Houser, Karl M., Ardmore, Pa.
- *1927. Hubbard, Thomas, Toledo, Ohio.
- *1919. Hurd, Lee Maidment, Rowayton, Conn.
- *1920. Imperatori, Charles J., Essex, N. Y.
- *1904. Ingersoll, John Marvin, Miami, Fla.
- *1952. Ireland, Percy E., Toronto, Canada.

- *1928. Jarvis, DeForest C., Barre, Vt.
- *1939. Johnston, William H., Santa Barbara, Calif.
- *1942. Kelly, Joseph D., New York, N. Y.
- *1918. Kenyon, Elmer L., Chicago, Ill.
- *1921. Kernan, John D., New York, N. Y.
- *1929. Kistner, Frank B., Portland, Oregon.
- *1885. Knight, Charles H., New York, N. Y.
- *1939. Large, Secord H., Cleveland, Ohio.
- *1939. LeJeune, Francis E., New Orleans, La.
- *1894. Leland, George A., Boston, Mass.
- *1922. Lillie, Harold I., Rochester, Minn.
- *1943. Lincoln, William R., Cleveland, Ohio.
- *1927. Lukens, Robert M., Wildwood Crest, New Jersey.
- *1928. Lyman, Harry Webster, St. Louis, Mo.
- *1886. MacCoy, Alexander W., Philadelphia, Pa.
- *1941. Martin, Robert C., San Francisco, Calif.
- *1896. Mayer, Emil, New York, N. Y.
- *1951. McCart, Howard W. D., Toronto, Canada.
- *1939. McCaskey, Carl H., Indianapolis, Indiana.
- *1943. McCullagh, Samuel, New York, N. Y.
- *1923. McKinney, Richmond, Memphis, Tenn.
- *1933. McMahon, Bernard J., St. Louis, Mo.
- *1928. MacPherson, Duncan, New York, N. Y.
- *1939. Myers, John L., Kansas City, Mo.
- *1927. Myerson, Mervin C., New York, N. Y.
- *1901. Myles, Robert C., New York, N. Y.
- *1937. Nash, C. Stewart, Rochester, N. Y.
- *1922. New, Gordon B., Rochester, Minn.
- *1923. Newhart, Horace, Minneapolis, Minn.
- *1903. Packard, Francis R., Philadelphia, Pa.
- *1878. Porter, William, Ocean Springs, Mass.
- *1942. Potts, John B., Omaha, Nebr.
- *1951. Rawlins, Aubrey G., San Francisco, Calif.
- *1903. Renner, W. Scott, Buffalo, N. Y.
- *1897. Rhodes, John Edwin, Chicago, Ill.
- *1884. Rice, Clarence C., New York, N. Y.
- *1905. Richards, George L., South Yarmouth, Mass.

- *1878. Robinson, Beverly, New York, N. Y.
- *1938. Salinger, Samuel, Palm Springs, Calif.
- *1921. Sauer, William E., St. Louis, Mo.
- *1934. Schenk, Harry P., Philadelphia, Pa.
- *1923. Sewall, Edward C., Palo Alto, Calif.
- *1930. Seydell, Ernest M., Wichita, Kansas.
- *1907. Shambaugh, George E., Chicago, Ill.
- *1939. Simpson, W. Likely, Memphis, Tennessee.
- *1908. Smith, Harmon, New York, N. Y.
- *1923. Spencer, Frank R., Boulder, Colo.
- *1947. Theobald, Walter H., Chicago, Illinois.
- *1927. Tobey, Harold G., Boston, Mass.
- *1950. Tremble, G. Edward, Montreal, Quebec, Canada.
- *1925. Tucker, Gabriel, Haverford, Pa.
- *1943. Van Alyea, Oliver E., Chicago, Illinois.
- *1892. Wagner, Henry L., San Francisco, Calif.
- *1892. Watson, Arthur W., Philadelphia, Pa.
- *1948. Whalen, Edward J., Hartford, Conn.
- *1922. White, Francis W., New York, N. Y.
- *1939. Wilson, J. Gordon, Old Bennington, Vt.
- *1905. Wood, George B., Wynnewood, Pa.
- *1935. Woodward, Fletcher D., Charlottesville, Va.

Active Fellows

- *1958. Alfaro, Victor R., Washington, D. C.
- *1880. Allen, Harrison, Philadelphia, Pa.
- *1917. Arrowsmith, Hubert, Brooklyn, N. Y.
- *1879. Asch, Morris J., New York, N. Y.
- *1942. Ashley, Rae E., San Francisco, Calif.
- *1958. Atkins, Joseph P., Philadelphia, Pa.
- *1923. Babbitt, James A., Philadelphia, Pa.
- *1906. Ballenger, William L., Chicago, Ill.
- *1880. Bean, C. E., St. Paul, Minn.
- *1949. Beck, August L., New Rochelle, N. Y.
- *1904. Berens, T. Passmore, New York, N. Y.
- *1924. Bigelow, Nolton, Providence, R. I.
- *1938. Blassingame, Charles D., Memphis, Tenn.

- *1893. Bliss, Arthur Ames, Philadelphia, Pa.
- *1951. Boyden, Guy L., Portland, Oregon.
- *1895. Boylan, J. E., Cincinnati, Ohio.
- *1932. Brown, John Mackenzie, Los Angeles, Calif.
- *1892. Brown, Moreau R., Chicago, Ill.
- *1933. Buckley, Robert E., New York, N. Y.
- *1915. Canfield, R. Bishop, Ann Arbor, Mich.
- *1934. Carmack, John Walter, Indianapolis, Ind.
- *1924. Carmody, Thomas E., Denver, Colo.
- *1889. Casselberry, William E., Chicago, Ill.
- *1883. Chamberlain, C. W., Hartford, Conn.
- *1917. Chamberlin, William B., Cleveland, Ohio.
- *1896. Chappell, W. F., New York, N. Y.
- *1882. Chapman, S. Hartwell, New Haven, Conn.
- *1902. Coakley, Cornelius G., New York, N. Y.
- *1913. Coffin, Rockwell C., Boston, Mass.
- *1918. Cox, Gerald H., New York, N. Y.
- *1880. Cushing, E. W., Boston, Mass.
- *1878. Cutter, Ephraim, West Falmouth, Mass.
- *1880. Daly, W. H., Pittsburgh, Pa.
- *1878. Davis, F. H., Chicago, Ill.
- *1941. Davis, Warren B., Philadelphia, Pa.
- *1926. Dennis, Frank Lownes, Colorado, Springs, Colo.
- *1901. Dickerman, E. T., Chicago, Ill.
- *1969. Dickinson, John T., Pittsburgh, Pa.
- *1878. Donaldson, Frank, Baltimore, Md.
- *1954. Equen, Murdock S., Atlanta, Ga.
- *1935. Eves, Curtis C., Philadelphia, Pa.
- *1919. Faulkner, E. Ross, New York, N. Y.
- *1914. Fetterolf, George, Philadelphia, Pa.
- *1901. Freeman, Walter J., Philadelphia, Pa.
- *1917. Friedberg, Stanton A., Chicago, Ill.
- *1940. Fuchs, Valentine H., New Orleans, La.
- *1897. Frothingham, Richard, New York, N. Y.
- *1909. Getchell, Albert C., Worcester, Mass.
- *1907. Gibb, Joseph S., Philadelphia, Pa.
- *1940. Gill, William D., San Antonio, Texas.

- *1878. Glasgow, William Carr, St. Louis, Mo.
- *1913. Goldstein, Max A., St. Louis, Mo.
- *1905. Grayson, Charles P., Philadelphia, Pa.
- *1934. Grove, William E., Milwaukee, Wisconsin.
- *1933. Harkness, Gordon F., Davenport, Iowa.
- *1878. Hartman, J. H., Baltimore, Md.
- *1945. Hickey, Harold L., Denver, Colo.
- *1879. Holden, Edgar, Newark, N. J.
- *1907. Holmes, Christian R., Cincinnati, Ohio.
- *1882. Hooper, Franklin H., Boston, Mass.
- *1893. Hope, George B., New York, N. Y.
- *1938. Hourn, George E., St. Louis, Mo.
- *1939. Hunt, Westley Marshall, New York, N. Y.
- *1901. Hyatt, Frank, Washington, D. C.
- *1925. Iglauer, Samuel, Cincinnati, Ohio.
- *1878. Ingals, E. Fletcher, Chicago, Ill.
- *1882. Ives, Frank L., New York, N. Y.
- *1938. Jackson, Chevalier L., Philadelphia, Pa.
- *1880. Jarvis, William C., New York, N. Y.
- *1878. Johnson, Hosmer A., Chicago, Ill.
- *1879. Johnson, Woolsey, New York, N. Y.
- *1960. Johnston, Kenneth C., Chicago, Ill.
- *1944. Jones, Marvin F., New York, N. Y.
- *1879. Kealhofer, R. H., St. Louis, Mo.
- *1964. Keim, W. Franklin, Montclair, N. J.
- *1942. King, Edward D., North Hollywood, Calif.
- *1901. King, Gordon, New Orleans, La.
- *1878. Knight, Frederick Irving, Boston, Mass.
- *1965. Knight, John S., Kansas City, Mo.
- *1898. Kyle, D. Braden, Philadelphia, Pa.
- *1880. Langmaid, Samuel W., Boston, Mass.
- *1953. Lederer, Francis L., Chicago, Ill.
- *1878. Lincoln, Rufus P., New York, N. Y.
- *1911. Lockard, Lorenzo B., Denver, Colo.
- *1913. Loeb, Hanau W., St. Louis, Mo.
- *1897. Logan, James E., Kansas City, Mo.
- *1935. Looper, Edward A., Baltimore, Md.

- *1888. Lowman, John H., Cleveland, Ohio.
- *1919. Lynah, Henry L., New York, N. Y.
- *1952. Lynch, Mercer G., New Orleans, La.
- *1915. Lynch, Robert Clyde, New Orleans, La.
- *1879. McBurney, Charles, New York, N. Y.
- *1927. McGinnis, Edwin, Chicago, Ill.
- 1936. McGregor, Gregor, Toronto, Canada.
- *1913. McKimmie, O. A., Washington, D. C.
- *1945. McLaurin, John G., Dallas, Texas.
- *1885. McSherry, II. Clinton, Baltimore, Md.
- *1914. Mackenty, John E., New York, N. Y.
- *1898. Makuen, G. Hudson, Philadelphia, Pa.
- *1881. Major, G. W., Montreal, Canada.
- *1948. Maxwell, James H., Ann Arbor, Mich.
- *1954. Meltzer, Philip E., Boston, Mass.
- 1958. Montreuil, Fernand, Montreal, Canada.
- *1881. Morgan, E. C., Washington, D. C.
- *1950. Morrison, Lewis F., San Francisco, Calif.
- *1940. Morrison, William W., New York, N. Y.
- *1886. Mulhall, J. C., St. Louis, Mo.
- *1925. Mullin, William V., Cleveland, Ohio.
- *1914. Munger, Carl E., Waterbury, Conn.
- *1892. Murray, T. Morris, Washington, D. C.
- *1881. Mynter, H., Buffalo, N. Y.
- *1893. Newcomb, James E., New York, N. Y.
- *1895. Nichols, J. E. H., New York, N. Y.
- *1927. Orton, Henry B., Newark, N. J.
- *1894. Park, William H., New York, N. Y.
- *1892. Porcher, W. Peyre, Charleston, S. C.
- *1927. Porter, Charles T., Boston, Mass.
- *1954. Pressman, Joel J., Los Angeles, Calif.
- *1908. Randall, B. Alexander, Philadelphia, Pa.
- *1882. Rankin, D. N., Allegheny, Pa.
- *1934. Richards, Lyman G., Wellesley Hills, Mass.
- *1902. Richardson, Charles W., Washington, D. C.
- *1930. Ridpath, Robert E., Philadelphia, Pa.
- *1879. Roe, John O., Rochester, N. Y.

- *1945. Robb, James M., Detroit, Michigan.
- *1953. Roberts, Sam E., Kansas City, Mo.
- *1881. Robertson, J. M., Detroit, Mich.
- *1913. Roy, Dunbar, Atlanta, Ga.
- *1878. Rumbold, T. F., St. Louis, Mo.
- *1879. Seiler, Carl, Philadelphia, Pa.
- *1928. Shea, John Joseph, Memphis, Tennessee.
- *1893. Shields, Charles M., Richmond, Pa.
- *1909. Shurly, Burt R., Detroit, Mich.
- *1878. Shurly, E. L., Detroit, Mich.
- *1892. Simpson, William Kelly, New York, N. Y.
- *1919. Skillern, Ross H., Philadelphia, Pa.
- *1909. Sluder, Greenfield, St. Louis, Mo.
- *1879. Smith, Andrew H., Geneva, N. Y.
- *1932. Smyth, Duncan Campbell, Boston, Mass.
- *1928. Sonnenschein, Robert, Chicago, Ill.
- *1924. Stein, Otto J., Chicago, Ill.
- 1934. Stevenson, Walter, Quincy, Ill.
- *1911. Staut, George C., Philadelphia, Pa.
- *1879. Tauber, Bernhard, Cincinnati, Ohio.
- *1924. Taylor, Hermon Marshall, Jacksonville, Fla.
- *1903. Theisen, Clement F., Albany, N. Y.
- *1899. Thorner, Max, Cincinnati, Ohio.
- *1892. Thrasher, Allen B., Cincinnati, Ohio.
- *1937. Tobey, George L., Jr., Boston, Mass.
- *1888. Van der Poel, S. O., New York, N. Y.
- *1938. Vail, Harris H., Cincinnati, Ohio.
- *1936. Voislowsky, Antonie P., New York, N. Y.
- *1954. Walsh, Theodore E., St. Louis, Mo.
- *1933. Wanamaker, Allison T., Seattle, Wash.
- *1896. Ward, Marshall R., Pittsburgh, Pa.
- *1879. Ward, Whitfield, New York, N. Y.
- *1886. Westbrook, Benjamin F., Brooklyn, N. Y.
- *1924. Wherry, William P., Omaha, Neb.
- *1924. White, Leon E., Boston, Mass.
- *1939. Williams, Horace J., Philadelphia, Pa.
- *1942. Wishart, D. E. Staunton, Toronto, Canada.
- *1922. Wishart, David J. G., Toronto, Canada.
- *1940. Wood, V. Visscher, St. Louis, Mo.
- *1896. Wollen, Green V., Indianapolis, Ind.
- *1953. Wilkerson, William W., Nashville, Tenn.

Roster of Fellows

1979

LIST OF FELLOWS

Date Indicates Year Admitted to Active Fellowship

Attendance at meetings is shown by figures following each name.

Asterisk (*) indicates year paper was read.

Active Fellows — 96

- 1974. ALFORD, BOBBY R., 1200 Moursund Ave., Houston, Texas 77025, 1974, '78.
- 1969. ANDREWS, ALBERT H. JR., 122 S. Michigan Ave., Chicago, Ill., 60603, 1970, '71, '72, '73, '74*, '75, '76, '77, '78, '79.
- 1962. ARNOLD, GODFREY E., 2500 N. State St., Jackson, Mississippi 39216, 1962, '63*, '64*, '66, '69, '70, '72, '73, '75, '77, '79.
- 1969. AUSBAND, JOHN R., LaMotte Clinic, P.A. P.O. Box 1126, Hilton Head Island, So. Carolina 29928, 1970, '71, '72, '73, '75, '78.
- 1975. BAILEY, BYRON J., Dept. Otol., UTMB, Galveston, Texas 77550, 1975, '76*, '77, '78.
- 1970. BALLENGER, JOHN J., 723 Elm St., Winnetka, Ill. 60093, 1971, '72, '73, '74, '75, '76, '77, '78, '79.
- 1963. BAXTER, JAMES D., 687 Pine Ave. West, Montreal, 112, Quebec, Canada, 1963, '65*, '66, '67, '68, '69, '70, '71, '72, '73, '74, '76, '77, '78, '79.
- 1975. BILLER, HUGH F., Mt. Sinai Hosp., 100th St. & Fifth Ave., New York, N. Y., 1975, '76, '77*, '78*, '79*.
- 1977. BLAUGRUND, STANLEY M., 115 E. 61st St., New York, N. Y. 10021, 1977, '78, '79.
- 1975. BOLES, ROGER, Dept. Otolaryng. Univ. of Cal., San Francisco, Cal. 94122, 1975, '76, '77, '78, '79.
- 1955. BORDLEY, JOHN E., Johns Hopkins Hospital, Baltimore, Maryland 21205, 1955, '56, '57, '59, '60, '62, '63, '64, '65, '66, '67, '69, '70, '71, '72, '73*, '74, '75, '76, '77, '78, '79.
- 1959. BREWER, DAVID W., 1100 E. Genesee St., Syracuse, N. Y. 13210, 1959, '60*, '61, '62*, '63, '66, '70, '73, '74*, '77.
- 1976. BRIANT, THOMAS D. R., St. Michael's Hospital, 30 Bond Street, 4B Wing, Toronto, M5B1W8 Ontario, Canada, 1976, '77, '78.
- 1955. BROWN, LESTER ALEXANDER, 490 Peachtree Street, N.E., Atlanta, Georgia 30308, 1955, '56, '57, '58, '59, '61, '63, '65, '68, '69, '70, '71, '72, '73*, '74, '75, '76, '77, '78, '79.
- 1963. BRYCE, DOUGLAS P., O.P.D. Toronto General Hospital, Toronto, Ontario, Canada, 1963*, '64, '66*, '67*, '68*, '69, '70, '71, '72, '73, '74, '75, '76*, '77, '78, '79.*
- 1979. CALCATERRA, THOMAS C., UCLA Medical Center, Los Angeles, Ca. 90224, 1979.
- 1976. CANTRELL, ROBERT W., University of Virginia Medical Center, Charlottesville, Virginia 22901, 1976, '77*, '78, '79.

1968. CHANDLER, J. RYAN, 1700 N.W. 10th Ave., Miami, Fla. 33136, 1968, '69*, '70, '71, '72, '73, '74, '75, '76, '77, '78, '79.*
1967. COCKE, EDWIN W., JR., 920 Madison, Memphis, Tenn. 38103, 1967, '68, '69, '70, '72, '74, '75, '76, '77, '78.
1964. CODY, CLAUDE C., III, 777 Southwest Freeway, Houston, Texas 77074, 1964, '65, '67, '69, '71, '73, '77, '78, '79.
1971. COHEN, SEYMOUR R., 1300 N. Vermont Ave., Los Angeles, Calif. 90027, 1971, '72*, '73*, '74, '75*, '76*, '77, '78*.
1957. CONLEY, JOHN J., 211 Central Park West, New York, N. Y. 10024, 1958*, '60*, '61, '62*, '63*, '64, '65, '70, '72, '74*, '75*, '76, '77, '78.
1960. DALY, JOHN F., Faculty Practice Offices, 566 First Ave., New York, N. Y. 10016, 1960, '61*, '62, '63, '64, '65, '66, '67, '68, '69, '70, '71, '72, '73, '74, '75, '76, '77, '78*, '79.*
1973. DEDO, HERBERT H., University of California, S.F. School of Medicine, Rm. 495U, San Francisco, Calif. 94122, 1973*, '74, '75*, '76*, '77, '78, '79.*
1966. DEVINE, KENNETH D., Mayo Clinic, Rochester, Minn. 55901, 1966, '67, '68, '72*, '74*, '76*.
1968. DEWEESE, DAVID D., 3181 S.W. Sam Jackson Park Rd., Portland, Ore. 97202, 1968, '69*, '73, '74, '75, '76, '77, '78, '79.
1976. DOYLE, PATRICK J., 865 W. 10th Ave., Vancouver 9, British Columbia, Canada, 1976, '77*.
1973. DUVALL, ARNDT, J., III, University of Minn. Hospital, A-605 Mayo Memorial Bldg., Minneapolis, Minn. 55455, 1973*, '75, '76, '77, '78.
1968. FARRIOR, RICHARD T., 509 Bay St., Tampa, Fla. 33606, 1968, '69, '70*, '72, '74, '76, '77, '78, '79.
1964. FEARON, BLAIR, 308 Medical Arts Building, Toronto 5, Ontario, Canada, 1964, '66, '67, '68, '69, '70, '71*, '72*, '73*, '74*, '75, '76, '77, '78*, '79.
1963. FERGUSON, CHARLES F., P. O. Box 313, Osterville, Mass. 02655, 1963, '64*, '66, '67*, '68, '69*, '70, '71, '72, '73, '74*, '75, '76, '77, '78*, '79.
1970. FRAZER, JOHN P., 601 Elmwood Ave., Rochester, N. Y. 14642, 1971, '72, '73, '74, '75, '76, '77, '78, '79.
1977. FREDRICKSON, JOHN M., Med. Sciences Bldg., Room 7310, University of Toronto, Toronto, Ontario, Canada, 1977, '78, '79.*
1956. FRIEDBERG, STANTON A., 1725 West Harrison St., Chicago, Ill. 60612, 1956, '57*, '58, '59, '60, '61, '62, '63, '64, '65*, '67, '68, '69, '70, '71*, '72, '73, '74, '75, '76*, '78*, '79.*
1977. GACEK, RICHARD R., State Univ. Hosp. of the Upstate Medical Center, 750 E. Adams St., Syracuse, N. Y. 13210, 1977*, '78, '79.
1959. GOLDMAN, JOSEPH L., 55 E. 87th St., New York, N. Y. 10028, 1959, '60*, '61, '62, '63, '64, '65, '66, '67, '68, '69, '70, '71, '72*, '73, '74, '75, '76, '77, '78*, '79.
1965. HANCKEL, RICHARD W., JR., 9 Valley Forge Dr., Nashville, Tenn. 37205, 1965, '66, '67, '69, '70, '71, '72, '73, '74, '77, '78, '79.
1957. HARRILL, JAMES A., Bowman Gray School of Medicine, Winston-Salem, N. C. 27103, 1957, '58, '59, '61, '62, '63, '64, '66, '67, '68, '69, '71, '73, '75, '76, '77, '79.

1955. HILGER, JEROME A., Suite 6A, 393 Dunlap St., St. Paul, Minnesota 55104, 1955, '56*, '57, '58, '59, '60, '62, '63, '64, '65, '66, '68, '69, '70, '71, '75, '76, '77, '78.
1974. HUDSON, WILLIAM R., Duke Univ. Med. Center, E.N.T., P.O.P., 3805, Durham, N. C. 27710, 1974, '75, '76, '77, '78*.
1961. JONES, EDLEY H., 1901 Mission 66 Avenue, Vicksburg, Miss. 39180, 1961, '62, '63*, '65, '66, '67, '68, '69, '70, '71, '72, '73, '74, '75, '76, '77, '78.
1965. KING, JAMES T., 1890 W. Paces Ferry Road, N.W., Atlanta, Ga. 30327, 1965, '66, '67, '69, '70, '71, '73, '74, '75, '76.
1975. KIRCHNER, FERNANDO R., U. of Kansas Med. Centr., Kansas City, Kansas 66103, 1975*, '76, '77, '79.
1963. KIRCHNER, JOHN A., 333 Cedar St., New Haven, Conn. 06510, 1963, '65*, '67*, '68, '69*, '70, '71*, '72*, '73, '74, '75*, '77, '78.
1979. KRAUSE, CHARLES J., University Hospital, Ann Arbor, Michigan, 1979.
1979. LE JEUNE, FRANCIS E., JR., 1514 Jefferson Highway, New Orleans, Louisiana 70121, 1979.
1966. LEWIS, JOHN S., 3 East 71st Street, New York, N. Y. 10021, 1966, '67, '68, '69*, '70, '71, '72, '74, '75, '76*, '78, '79.
1961. LEWY, ROBERT B., 25 East Washington St., Chicago, Ill. 60602, 1961, '62*, '63, '65*, '67, '68, '69, '70, '71, '73, '74, '75, '76*, '77, '78, '79.
1976. LINGEMAN, RALEIGH E., 1100 W. Michigan St., Indianapolis, Ind. 46202, 1976, '77*, '78, '79.
1973. LORE, JOHN M., JR., 2121 Main St., Buffalo, N. Y. 14214, 1974*, '76, '77*, '78*.
1978. LYONS, GEORGE D., 120 N. Jefferson Davis Pkwy., New Orleans, La. 70119, 1978, '79.
1966. McCABE, BRIAN F., Dept. of Otolaryngology, University Hospitals, Iowa City, Iowa 52240, 1966, '69, '72*, '73, '75*, '76, '79*.
1963. MCGOVERN, FRANCIS H., 139 South Main St., Danville, Virginia 24541, 1963, '64, '66, '68, '71, '72, '74, '75, '77, '79.
1976. MIGLETS, ANDREW, 456 Clinic Drive, Rm. 4118, Columbus, Ohio 43210, 1976, '77, '78*.
1952. MILLER, ALDEN H., 1407 N. Vermont Ave., Los Angeles, Calif. 90027, 1952, '53*, '55, '57, '58*, '61, '62, '64, '66, '67*, '68, '69, '70, '71, '72, '73*, '74*, '76, '77, '78*, '79.
1965. MILLER, DANIEL, 110 Francis St., Boston, Mass. 02215, 1965, '66, '67, '68, '69*, '70, '71, '72, '73*, '74, '75, '76, '77*, '78, '79.
1964. MONTGOMERY, WILLIAM W., 243 Charles St., Boston, Mass. 02114, 1964, '65*, '66*, '68*, '70, '71, '72, '74*, '75, '76*, '77, '78.
1972. MORSE, HARRY R., USAF Hospital, Bitburg, Germany Apony 09132, 1972, '75, '77, '79.
1979. MYERS, EUGENE N., Dept. of Otolaryngology, 230 Lathrop Street, Pittsburgh, Pa. 15213, 1979.
1975. NAHUM, ALAN, M., 225 W. Dickinson, San Diego, Cal. 92103, 1975, '76, '79.

1956. NORRIS, CHARLES MORGAN, 3401 North Broad Street, Philadelphia, Pennsylvania 19140, 1956, '57, '58*, '59, '60, '61*, '62, '63, '64, '66, '67, '68*, '69, '70*, '71, '72, '73, '74, '75, '76, '77, '78*, '79.
1961. OGURA, JOSEPH H., 517 S. Euclid Ave., St. Louis, Mo. 63110, 1961*, '62*, '63, '64*, '65, '66*, '67, '68*, '69, '70, '71*, '72, '73*, '74*, '75*, '76*, '77, '78*, '79.
1958. O'KEEFE, JOHN J., 130 S. Ninth St., Philadelphia, Pa. 19107, 1958, '59*, '60, '62, '64, '67, '71, '73, '74, '75, '78.
1961. PANG, LUP Q., 1374 Nuuanu Ave., Honolulu, Hawaii 96817, 1961, '62*, '64, '66, '67, '70, '71, '72, '73, '75, '77, '79.
1961. PASTORE, PETER N., 5503 Riverside Drive, Richmond, Va. 23225, 1961, '62*, '64, '66, '67, '69, '71, '72, '73, '74, '75, '76, '78, '79.
1972. PENNINGTON, CLAUDE L., JR., 800 First St., Macon, Ga. 31201, 1972, '73, '75, '76*, '78.
1967. PRATT, LORING W., 325-B Kennedy Memorial Drive, Waterville, Maine 04901, 1967, '68, '69, '70, '71, '72, '73, '74, '75, '76, '77, '78, '79.
1951. PUTNEY, F. JOHNSON, 80 Barre St., Charleston, S. C. 29401, 1951, '52, '53*, '54, '55, '56, '58*, '59, '60, '61, '62, '63*, '64*, '65, '66, '67, '68*, '69*, '70*, '71, '72*, '74, '75, '76, '77, '78*, '79.*
1963. REED, GEORGE F., 750 E. Adams St., Syracuse, N. Y., 13210, 1963, '65*, '66, '68, '69*, '70, '71, '72, '73, '75, '76, '77, '78, '79.
1974. RITTER, FRANK N., 326 N. Ingalls, Ann Arbor, Mich. 48104, 1974, '75, '77, '78, '79.
1959. SANDERS, SAM H., 1286 Peabody Ave., Memphis, Tenn. 38104, 1959, '60, '61, '62, '63, '65, '70, '71, '72, '73, '75, '78.
1964. SAUNDERS, WILLIAM H., Ohio State Univ., Rm. 3110, 456 Clinic Dr., Columbus, Ohio 43210, 1964, '65, '66, '68*, '69, '70*, '71, '72*, '73, '74, '75*, '76, '77, '78, '79.*
1978. SESSIONS, DONALD G., 1924 Breezeridge Dr., Des Peres, Mo. 63131, '79.*
1979. SHAPIRO, MYRON, J., 349 East Northfield Road, Livingston, New Jersey, 07039, 1979.
1959. SILCOX, LOUIS E., 115 Crescent Drive, Punta Gorda, Florida 33950, 1959, '60, '61, '62, '63, '64, '65, '66, '67, '68, '69, '70, '71, '72, '73, '74, '75, '77, '78.
1962. SISSON, GEORGE A., Northwestern U. Medical School, 303 E. Chicago Ave., Chicago, Ill. 60611, 1962, '63*, '65, '66, '68, '69, '70, '71, '72, '73, '76, '77, '78, '79.
1964. SKOLNIK, EMANUEL M., 1855 W. Taylor Street, Abraham Lincoln School of Medicine, Chicago, Ill. 60612, 1964*, '65, '66*, '67, '68, '69, '70*, '71, '72, '73, '75*, '76, '77, '78, '79.
1974. SNOW, JAMES B., JR., 3400 Spruce St., Philadelphia, Pa. 19104, 1974, '75*, '76, '77, '78*, '79.
1972. SOBOROFF, BURTON J., 307 N. Michigan Ave., Chicago, Ill. 60601, 1972, '73, '74, '75, '76, '77, '79.
1973. SOM, MAX L., 121 East 60 Street, New York, N. Y. 10022, 1973, '74*, '75*, '76, '77, '78*, '79.*

1954. SOOY, FRANCIS A., University of California Hospital, 3rd and Parnassus Ave., San Francisco, Calif. 94122, 1954, '56*, '58, '60, '62, '63, '64, '65*, '67, '68*, '71, '78, '79.
1979. SPECTOR, GERSHON J., Dept. of Otolaryngology, 517 South Euclid, St. Louis, Missouri 63110, 1979.
1975. SPRINKLE, PHILIP M., W. Va. Univ Med. Cent., Morgantown, W. Virginia, 26505, 1975, '76, '77, '78*, '79.
1975. STRONG, M. STUART, 720 Harrison Ave., Boston, Mass. 02118, 1975, '76*, '77, '78*, '79.*
1961. SUEHS, OLIVER W., 14 Medical Arts Square, Austin, Texas 78705, 1961, '62*, '63, '64, '66, '68, '69, '70, '71, '72, '74, '75, '76, '78.
1963. TABB, HAROLD G., Dept of Otolaryngology, Tulane Medical School, New Orleans, La. 70112, 1963, '65, '66, '67, '69, '71, '72, '74, '77, '78, '79.
1979. TARDY, M. EUGENE, 2013 Commonwealth, No. 430, Chicago, Illinois, 60657, 1979.
1954. THORNELL, WILLIAM C., 2340 Auburn Avenue, Cincinnati, Ohio 45219, 1955*, '57, '59, '60, '63, '68, '70, '72, '74, '77, '78.
1978. TOOMEY, JAMES M., Dept. of Otolaryngology, Washington University School of Medicine, 517 S. Euclid Ave., St. Louis, Mo. 63110, '79.*
1967. TRIBLE, WILLIAM MACL., 1234 19th St., N.W., Washington, D.C. 20036, 1967, '68, '69*, '71, '72, '73, '74, '75, '76, '77, '78, '79.
1970. TUCKER, GABRIEL F., JR., The Children's Memorial Hospital, 2300 Children's Plaza, Chicago, Ill. 60614, 1970*, '71, '72, '73*, '74*, '75*, '76, '77*, '78*, '79.
1979. TUCKER, HARVEY M., Dept. of Otolaryngology, Cleveland Clinic, Cleveland, Ohio 44106, 1979.
1973. TUCKER, JOHN A., Hahnemann Hospital, 230 N. Broad St., Philadelphia, Pa. 19102, 1973*, '74*, '75*, '76, '77*, '78*.
1974. WARD, PAUL H., UCLA School of Medicine, Los Angeles, Calif. 90024, 1974*, '75, '76, '77*, '78*, '79.*
1971. WILLIAMS, RUSSELL I., 414 East 23rd Street, Cheyenne, Wyo. 82001, 1971, '72*, '73, '74, '76, '77, '78*.
1951. WOODMAN, DEGRAAF, P.O. Box 560, Easton, Md., 21601, 1951, '53, '54, '55*, '56, '58, '59, '60, '61, '62, '63, '64, '65, '66, '67, '68, '69, '70, '71, '72, '73, '74, '75, '76*, '77, '78, '79.

Honorary Fellows — 7

1978. (1959) BARRETTO, PLINIO DE MATTOS, Rua Cons Torres, Homen 371, Sao Paulo, Brazil, 1960, '69, '73.
1957. (1925) CLERF, LOUIS H., 5575 Eighth Avenue, North, St. Petersburg, Florida 33710, 1957, '58, '59, '60, '61, '63, '64, '65, '66, '68, '69, '70, '71, '72*, '73, '74, '75, '76, '77, '78*.
1978. (1971) HARRISON, D. F. N., 330/332 Gray's Inn Road, London, W.C.I., England, 1971, '77.
1966. (1957) ONO, JO, 6-13, 6-Chome, Roppongi, Minato-Ku, Tokyo, Japan, 1971.

1968. (1937) PORTMANN, PROF. DR. GEORGES, Clinique S, Augustin, 114, Avenue d'Ares, Bordeaux, France, 1947.
1968. (1957) RUEDI, PROF. DR. LUZIUS, Kurhausstrasse 50, Zurich, Switzerland, 1957.
1962. (1932) SCHALL, LeROY A., P.O. Box 136, Barnstable, Mass. 02630, 1964, '66, '68, '69, '72, '73, '74, '75, '76, '77.

Corresponding Fellows — 14

1978. ARAUZ, JUAN CARLOS, 2150 Cangallo, Buenos Aires, Argentina.
1972. ARSLAN, PROF. MICHELE, Otorinolaringoiatrica dell' Universita da Padova, 37 Via Altinate, Padova, Italy, 1972.
1959. BATEMAN, SIR GEOFFREY H., Beech Hill, E. Lavington, Petworth, Sussex, England.
1942. BATSON, OSCAR V., 3926 Pine St., Philadelphia, Pennsylvania 19104, 1942*, '54*.
1964. CLEVES, CARLOS, Apto 202, Carrera 14 No. 44-54, Bogota, Columbia, S. A., 1970.
1966. DOHLMAN, GOSTA, Dept. of Otolaryngology, University of Toronto, Toronto, Ontario, Canada, 1966.
1970. HALLIDAY, SIR GEORGE C., 143 Macquarrie St., Sydney, N.S.W. Australia.
1970. HUTCHEON, JACK, Morris Towers, 149 Wickham Terrace, Brisbane, Australia, 1971, '78.
1978. KLEINSASSER, OSKAR, Univ ENT Clinic, 355 Marburg (Lahn), Cologne, West Germany.
1971. MACBETH, RONALD G., Meadow Close Church Hanborough of Lord, England.
1968. NAKAMURA, FUMIO, Kyoto Prefectural U. Medicine, Kawara-Mach 1, Kamikyo-Ku, Kyoto, Japan.
1964. PEREZ, ALFREDO C., Instituto Celis Perez, Avenida Montes Deoca, Valencia, Venezuela, S. A., 1965.
1952. TAPIA-ACUNA, RICARDO, Av. Insurgentes, Sur No. 300, Mexico 7 D.F., 1953, '57, '60*, '67, '73, '75.
1936. VIALLE, JACQUES, 27 Rue de France, Nice (Alpes Maritimes), France.

Emeritus Fellows — 34

1973. (1944) BOIES, LAWRENCE R., Department of Otolaryngology, A-605, Mayo Memorial Bldg., Minneapolis, Minnesota 55455, 1944, '46, '47, '48*, '49, '50*, '51*, '53, '54, '55, '56, '57, '58, '59, '60, '61, '62, '63, '64, '65, '66, '67, '68*, '69, '71.
1966. (1945) CAMPBELL, PAUL A., 700 E. Hildebrand, Apt. 401, San Antonio, Texas 78212.
1965. (1942) CANFIELD, NORTON, 59 Whitfield St., Guilford, Conn. 06437.
1975. (1957) CONVERSE, JOHN MARQUIS, 722 Park Ave., New York, N. Y. 10021, 1960, '62*, '67.

1978. (1959) CRACOVANER, ARTHUR J., 255 South Barrington Ave., Los Angeles, Calif. 90049, 1959, '60, '61*, '62, '63, '65, '66, '67, '68, '69, '72, '74, '75, '76, '78, '79.
1977. (1951) DAVISON, FRANCIS W., P.O. Box 135, Danville, Pa. 17821, 1951, '52, '53*, '54, '55, '56, '57, '58, '59, '60, '61, '62, '63*, '64, '65, '66, '67*, '68, '69*, '70, '71, '72, '73*, '74, '75, '77, '78*, '79.
1969. (1947) EAGLE, WATT W., 1891 Hoods Creer Dr., New Bern, N. C. 28566.
1972. (1962) ERICH, JOHN B., Mayo Clinic, 102 Second Ave., Rochester, Minn. 55901.
1955. (1979) FITZ-HUGH, GLASSELL SLAUGHTER, P. O. Box 3698 University Station, Charlottesville, Virginia 22903, 1955, '57, '59, '60, '61, '62*, '64, '65, '66, '67*, '68, '69, '70, '71, '72, '73, '74, '75, '76, '77*, '78.
1970. (1940) GOODALE, ROBERT L., 141 Argilla Rd., Ipswich, Mass. 01938, 1971, '74, '75, '76.
1963. (1928) GOODYEAR, HENRY M., 2012 Edgecliff Point, Cincinnati, Ohio 45206.
1960. (1940) HANSEL, FRENCH K., 515 Timberwyck, St. Louis, Missouri 63131, 1962, '65, '73.
1978. (1960) HARRIS, HERBERT H., 3457 Meadow Lake Lane, Houston, Texas 77027, 1960, '61*, '62, '63, '64, '65*, '66, '67, '68, '69, '70, '71, '72, '73, '74, '75, '77, '78, '79.
1968. (1942) HEATLEY, CLYDE A., 125 Douglas Rd., Rochester, N. Y. 14610, 1942, '46*, '49, '50, '52, '53*, '54, '55, '57, '58, '60, '61, '65.
1978. (1959) HENRY, G. ARNOLD, Suite #2, Group Box 24, Lagoon City, RR #1, Brechin, Ontario, LOKIBO, Canada, 1959, '61, '63, '66, '67, '69, '70, '73.
1977. (1957) HOLMES, EDGAR M., 15 Graydale Circle, Auburndale, Mass. 02166, 1957, '59, '61, '63, '68, '70, '71, '72, '74, '75, '76.
1961. (1950) KLINE, ORAM R., 896 Lake Ave., Woodbury Heights, N. J. 08097, 1961, '63, '70, '72, '74.
1977. (1963) LATHROP, FRANK D., R.D.1, Pittsford, Vt. 05763, 1963, '64*, '67*, '69, '70, '71, '72, '73, '74, '75, '76, '77, '78.
1967. (1949) LINDSAY, JOHN R., 3217 Otto Lane, Evanston, Ill. 60201.
1964. (1952) MCCALL, JULIUS W., 22880 Canterbury Lane, Shaker Heights, Ohio 44122, 1964, '66, '68, '69, '70, '71, '72, '73, '75, '76, '77, '78.
1974. (1951) MCHENRY, LAWRENCE C., 1607 Glenbrook Terrace, Oklahoma City, Okla. 73116, 1953*, '62, '63, '64, '65, '66, '68, '71.
1970. (1931) McNALLY, WILLIAM J., 1509 Sherbrooke St. West, Montreal, Quebec, Canada, 1972, '73, '74, '75.
1971. (1954) MOORE, PAUL M., 555 Southeast Sixth Ave., The Barrton Apts., No. 4 G, Delray Beach, Fla. 33444, 1954, '55*, '56, '57, '59, '60, '61, '62, '63, '64, '65, '66, '68, '70, '71, '74, '78.
1978. (1957) MUNOZ-MACORMICK, CARLOS EDUARDO, 71 de Diego, Santurce, Puerto Rico 00911, 1957, '58, '59, '60, '61, '62, '63, '64, '65, '66, '67, '68, '69, '70, '71, '72, '73, '74, '75, '76, '77, '78, '79.

1971. (1953) MURTAGH, JOHN A., 1198 A1A Apt. 240, Hillsboro Beach, Pompano, Fla. 33062, 1953, '54, '55, '56*, '57, '58, '59, '61, '62, '63, '65, '66, '67, '69, '70, '72, '74, '76, '78, '79.
1957. (1948) PHELPS, KENNETH A., The Brittany, 706 Hoffman Hill Rd., 4C, Burlington, N. C. 27215, 1971.
1976. (1951) PRIEST, ROBERT E., 322 Medical Arts Bldg., Minneapolis, Minn. 55402, 1977, '78, '79.
1972. (1956) RICHARDSON, JOHN R., P.O. Box 52, Searsport, Maine 04974.
1977. (1958) SIMONTON, KINSEY M., % Foster Daxbury, MA 02332, 1958, '59*, '62, '64, '66, '67, '69, '72, '74, '75, '78.
1969. (1950) SMITH, AUSTIN T., 382 Lakeside Rd., Box 28, Wynnewood, Pa. 19096, 1970, '71, '72, '73, '74.
1973. (1963) TOLAN, JOHN F., 3419 47th Avenue, N.E., Seattle, Washington 98105, 1963, '64, '65, '66, '67, '69, '71, '73.
1961. (1941) VIOLE, PIERRE P., 241 South Windsor, Los Angeles, Calif. 90004, 1964.
1977. (1962) WEAVER, DELMAR F., Med. Profess. Bldg., Culpeper, Va. 22701, 1962, '63, '64*, '65, '67*, '69, '70, '72, '74, '76.
1975. (1953) WORK, WALTER P., 172 East Paseo de Golf, Green Valley, Ariz. 85614, 1953, '54, '56, '58, '59*, '62, '63*, '65, '67, '68, '69, '72, '73, '75, '76, '78*, '79.*

OFFICERS 1979-1980

≈

PRESIDENT

JOHN A. KIRCHNER, MD

FIRST VICE-PRESIDENT

ALBERT H. ANDREWS, JR., MD

SECOND VICE-PRESIDENT

SEYMOUR R. COHEN, MD

SECRETARY

WILLIAM M. TRIBLE, MD

TREASURER

HAROLD G. TABB, MD

LIBRARIAN, HISTORIAN AND EDITOR

GABRIEL F. TUCKER, JR., MD

≈

COUNCIL

The above ex officio and

FIRST COUNCILOR

STANTON A. FRIEDBERG, MD

SECOND COUNCILOR

CHARLES M. NORRIS, MD

THIRD COUNCILOR

CHARLES F. FERGUSON, MD

FOURTH COUNCILOR

JOHN F. DALY, MD

INDEX

to the

TRANSACTIONS

of the

AMERICAN

LARYNGOLOGICAL ASSOCIATION

1979

SUBJECT INDEX

- A**
- Address, Guest of Honor (Putney) 15
 Address, Presidential (Daly) 11
- B**
- Baker Memorial Lecture (Work) 39
 Benign Tumors and Lesions of the Larynx
 in Children: Surgical Excision by CO₂
 Laser (Simpson, Healy, McGill and
 Strong) 44
 Bilateral Hypoglossal Nerve Paralysis
 after Irradiation Therapy (Saunders
 and Hodgson) 83
- C**
- Cancer, Head and Neck, Enteral and
 Parenteral Nutrition in Patients with
 (Sobel, Conoyer and Sessions) 61
 Cartilage, Upper Lateral, Collapsing,
 The Problem of the (McCabe) 95
 Cholesteatoma of the Frontal and Ethmoid
 Areas (Campanella, Caldarelli and
 Friedberg) 88
 Clinical Course of Unusual Malignant
 Sarcomas of Head and Neck (Setzen,
 Sobel and Toomey) 52
- D**
- Docendo Discimus (Putney) 15
 Dysphonia, Spasmodic, Recurrent
 Laryngeal Nerve Section for (Levine,
 Wood, Batza, Rusnov and Tucker H) ..104
 Dysphonia, Spastic, Laryngeal Nerve
 Crush for (Biller, Som and Lawson) ..108
- E**
- Education, Resident: Past, Present and To
 Where (Work) 39
 Effects of Irradiation on Cervical Lymph
 Nodes (Welsh and Campellone) 70
 Endoscopic Teflon Keel for Anterior
 Glottic Web (Dedo) 31
 Enteral and Parenteral Nutrition in
 Patients with Head and Neck Cancer
 (Sobel, Conoyer and Sessions) 61
 Evaluation of Computerized Tomography,
 Cinelaryngoscopy, and Laryngography
 in Determining the Extent of Laryngeal
 Disease (Ward, Hanafee, Mancuso,
 Shallit and Berci) 17
 Executive Sessions
 First112
 Second113
- F**
- Fellows, Registration of, for Annual
 Meeting 9
 Fellows, Roster of154
 Fellows, Roster of Past143
- G**
- Glottic Web, Anterior, Endoscopic Teflon
 Keel for (Dedo) 31
 Guest of Honor Address (Putney) 15
 Guest of Honor Introduction (Daly) 14
- H**
- Head and Neck Cancer, Enteral and
 Parenteral Nutrition in Patients with
 (Sobel, Conoyer and Sessions) 61
 Head and Neck, Clinical Course of
 Unusual Malignant Sarcomas of
 (Setzen, Sobel and Toomey) 52
 Hypoglossal Nerve, Bilateral, Paralysis of,
 after Irradiation Therapy (Saunders
 and Hodgson) 83
- I**
- Irradiation, Effects of, on Cervical Lymph
 Nodes (Welsh and Campellone) 70
 Irradiation Therapy, Bilateral Hypoglossal
 Nerve Paralysis after (Saunders and
 Hodgson) 83
- L**
- Laryngeal Disease, Evaluation of
 Computerized Tomography,
 Cinelaryngoscopy, and Laryngography
 in Determining the Extent of (Ward,
 Hanafee, Mancuso, Shallit and Berci) 17
 Laryngeal Dysfunction Following
 Prolonged Intubation (Whited) 99
 Laryngeal Nerve Crush for Spastic
 Dysphonia (Biller, Som and Lawson) ..108
 Laryngeal Nerve, Recurrent, Section, for
 Spasmodic Dysphonia (Levine, Wood,
 Batza, Rusnov and Tucker)104
 Larynx, Benign Tumors and Lesions of,
 in Children: Surgical Excision by CO₂
 Laser (Simpson, Healy, McGill and
 Strong) 44
 Leiomyosarcoma of the Cervical Trachea.
 Report of a Case with Reconstruction
 Using a Latissimus Dorsi Island Flap
 (Fredrickson, Jahn and Bryce) 27
 Lymph Nodes, Cervical, Effects of
 Irradiation on (Welsh and Campellone) 70
- M**
- Memorials:
 Dickenson, John T.124
 Lukens, Robert McDowell127
 Myerson, Mervin C.131
 Schenck, Harry P.128
 Memorial Fund: Laryngological
 Research Fund132
- N**
- Nerve Crush, Laryngeal, for Spastic
 Dysphonia (Biller, Som and Lawson) ..108

- Nerve Paralysis, Bilateral Hypoglossal,
after Irradiation Therapy (Saunders
and Hodgson) 83
- Nerve, Recurrent, Section for Spasmodic
Dysphonia (Levine, Wood, Batza,
Rusnov and Tucker)104
- Nutrition, Enteral and Parenteral, in
Patients with Head and Neck Cancer
(Sobel, Conoyer and Sessions) 61

O

- Officers 1879-1978 7
- Officers 1979-1980162
- Otolaryngology at the Crossroads (Daly) 11

P

- Paralysis, Bilateral Hypoglossal Nerve,
after Irradiation Therapy (Saunders
and Hodgson) 83
- Presidential Address (Daly) 11
- Problem of the Collapsing Upper Lateral
Cartilage, The (McCabe) 95

R

- Recurrent Laryngeal Nerve Section for
Spasmodic Dysphonia (Levine, Wood,
Batza, Rusnov and Tucker)104
- Recipients of Awards
Casselberry Award134
deRoaldes Award133
Newcomb Award135
- Registration of Fellows for Annual
Meeting 9

Reports

- Accountant120
- American College of Surgeons121
- Librarian, Historian and Editor120
- Nominating Committee121
- Secretary114
- Treasurer114
- Resident Education: Past, Present, and To
Where (Work) 39
- Roster of Fellows154
- Roster of Past Fellows143

S

- Sarcomas of Head and Neck, Unusual,
Clinical Course of (Setzen, Sobel and
Toomey) 52
- Surgical Excision by CO₂ Laser, of
Benign Tumors and Lesions in Children
(Simpson, Healy, McGill and Strong) 44

T

- Trachea, Cervical, Leiomyosarcoma of.
Report of a Case with Reconstruction
Using a Latissimus Dorsi Island Flap
(Fredrickson, Jahn and Bryce) 27
- Tumors and Lesions, Benign, of the Larynx
in Children: Surgical Excision by CO₂
Laser (Simpson, Healy, McGill and
Strong) 44

U

- Upper Lateral Cartilage, Collapsing, The
Problem of the (McCabe) 95

AUTHORS INDEX

B		M	
Batza, Eugene, PhD	104	Mancuso, Anthony, MD	17
Berci, George, MD	17	McCabe, Brian, MD	95
Biller, Hugh F., MD	108	McGill, Trevor, MD	44
Bryce, Douglas P., MD	27		
C		P	
Caldarelli, David D., MD	88	Putney, Floyd J., MD	15
Campellone, Frank, MS	70		
Campanella, Ruth S., MD	88	R	
Chandler, James R., MD	77	Rusnov, Melinda, MA	104
Conoyer, Michael, MD	61		
D		S	
Daly, John F., MD	11, 14	Saunders, William H., MD	83
Dedo, Herbert H., MD	31	Sessions, Donald G., MD	61
F		Setzen, Michael, MD	52
Fredrickson, John M., MD	27	Shallit, Joel, MD	17
Friedberg, Stanton, MD	88	Simpson, George T., MD	44
H		Sobel, Steven, MD	52, 61
Hanafee, William, MD	17	Som, Max L., MD	108
Healy, Gerald B., MD	44	Strong, M. Stuart, MD	44
Hodgson, Sheila, MD	83		
J		T	
Jahn, Anthony, MD	27	Toomey, James M., MD, DMD	52
L		Tucker, Harvey M., MD	104
Lawson, William, MD	108		
Levine, Howard L., MD	104	W	
		Ward, Paul H., MD	17
		Welsh, Louis W., MD	70
		Whited, Robert E., MD	99
		Work, Walter P., MD	39
		Wood, Benjamin G., MD	104

INDEX

to the

TRANSACTIONS

of the

AMERICAN
LARYNGOLOGICAL ASSOCIATION

Volumes 96-100

1975-1979

Volume 96-100 Inclusive

1975-1979

SUBJECT INDEX

A

Abductor Paralysis, Bilateral: 30 Years' Experience with Arytenoidectomy (Woodman and Pennington) 1976, 33.

Abductor Vocal Cord Paralysis, Bilateral, Etiology of (Holinger LD, Holinger PC and Holinger PH) 1976, 24.

Acute Laryngeal Obstruction in Children: Fifty Year Review (Davison) 1978, 25.

Address:

(Guest of Honor)

Davison, Francis W., 1978, 25.

Galloway, Thomas C, 1976, 17.

Holinger, Paul H., 1977, 15.

LeJeune, Francis E., Sr., 1975, 14.

Putney, Floyd J., 1979, 15.

(Honorary President)

Clerf, Louis H., 1978, 21.

(Presidential)

Daly, John F., 1979, 11.

Ferguson, Charles F., 1978, 11.

Friedberg, Stanton A., 1976, 11.

Norris, Charles M., 1977, 11.

Ogura, Joseph H., 1975, 11.

Adenocarcinoma, Papillary, of Thyroid, Invading Upper Air Passages (Lawson, Som and Biller) 1977, 63.

Anatomy and Development of Cricoid: Serial-Section Whole Organ Study of Perinatal Larynges (Tucker G, Tucker J and Vidić) 1977, 82.

Angiofibroma, Nasopharyngeal, Juvenile (Biller) 1978, 88.

Angiofibromas, Juvenile, of Nasopharynx, Pre-operative Embolization of (Pletcher, Newton, Dedo H and Norman) 1975, 31.

Anomalies of Supraglottic Larynx, Clinical Correlation of, with Staged Sequence of Normal Human Laryngeal Development (Tucker J, Tucker G and Vidić) 1978, 94.

Antigen, Tumor, Characterization of in Epidermoid Carcinoma (Krause, Nysather and McCabe) 1975, 79.

Arthrogryposis Multiplex Congenita, Otolaryngological Manifestations of (Cohen and Isaacs) 1976, 83.

Arytenoidectomy, 30 Years' Experience with, in Bilateral Abductor Paralysis (Woodman and Pennington) 1976, 33.

Aspiration, Postoperative, New Insights into Causes of, Following Conservation Surgery of the Larynx (Ward, Berci and Calcatera) 1977, 34.

Atresia, Choanal, Management with Carbon Dioxide Laser (Healy, McGill, Jako, Strong MS and Vaughan) 1978, 117.

B

Baker Memorial Lectures

Conley, John J., 1975, 18.

Fink, B. Raymond, 1978, 61.

Ogura, Joseph H., 1976, 21.

Thomas, Lewis, 1977, 18.

Work, Walter P., 1979, 39.

Benign Tumors and Lesions of the Larynx in Children: Surgical Excision by Carbon Dioxide Laser (Simpson, Healy, McGill and Strong MS) 1979, 44.

Bilateral Abductor Paralysis: 30 Years' Experience with Arytenoidectomy (Woodman and Pennington) 1976, 33.

Bilateral Hypoglossal Nerve Paralysis after Irradiation Therapy (Saunders and Hodgson) 1979, 83.

C

Cancer:

Head and Neck, Enteral and Parenteral Nutrition in Patients with (Sobel, Conoyer and Sessions D) 1979, 61.

Head and Neck, Management of Dying Patient with (Miller D) 1977, 119.

Head and Neck, Predictors of Survival in (Maisel and Ogura) 1976, 125.

Laryngeal, Second Primary Cancer after Irradiation of (Lawson and Som) 1975, 63.

Larynx, Radiation Failures in (Skolnik, Martin, Yee and Wheatley) 1975, 96.

Pyiform Sinus: Clinical and Laboratory Study (Kirchner J) 1975, 85.

Surgery, Head and Neck, Incidence, Predisposing Factors and Outcome of Pharyngocutaneous Fistulas Complicating (Dedo D, Alonso and Ogura) 1975, 128.

Carcinoma:

Epidermoid, Characterization of Tumor Antigen in (Krause, Nysather and McCabe) 1975, 79.

Glottic, with Posterior Subglottic Extension, Vertical Partial Laryngectomy for (Biller and Som) 1977, 25.

Head and Neck, Immune Monitoring Protocol for Patients with (Veltri, Sprinkle, Maxim, Theofilopoulos, Rodman and Kinney) 1978, 151.

Squamous Cell (T₂), Glottic: Retrospective Study (Doyle, Flores and Bell) 1977, 29.

- Supraglottic, Evaluation of Randomized Preoperative and Postoperative Radiation Therapy for (Snow, Gelber, Kramer, Davis, Marcial and Lowry) 1978, 145.
- Verrucous, of Larynx: Management by Radiotherapy and Surgery (Burns, van Nstrand and Bryce) 1976, 98.
- Of Nasopharynx in Children (Snow) 1975, 110.
- Carotid Body Tumors, Diagnosis and Treatment of (Ward, Jenkins and Hanafée) 1978, 73.
- Cartilage, Upper Lateral, Collapsing, Problem of (McCabe) 1979, 95.
- Characterization of Tumor Antigen in Epidermoid Carcinoma (Krause, Nysather and McCabe) 1975, 79.
- Cholesteatoma of Frontal and Ethmoid Areas (Campanella, Caldarelli and Friedberg) 1979, 88.
- Cleft Larynx: Report of Seven Cases (Cohen) 1975, 53.
- Clinical Correlation of Anomalies of Supraglottic Larynx with Staged Sequence of Normal Laryngeal Development (Tucker J, Tucker G, Vidić) 1978, 94.
- Clinical Course of Unusual Malignant Sarcomas of Head and Neck (Setzen, Sobel and Toomey) 1979, 52.
- Compendium of Rare Diseases of Larynx in Pediatric Age Group (Cohen et al) 1978, 116.
- Complications of Laryngectomy and Neck Dissection Following Planned Preoperative Radiotherapy (Cummings, Johnson, Chung and Sagerman) 1977, 57.
- Congenital Laryngeal Defects in the Adult (Montgomery and Smith) 1976, 90.
- Continuing Education: A Challenge and a Necessity (LeJeune) 1975, 14.
- Contributions of Philadelphia to Early Laryngology (Norris) 1978, 39.
- Cricoid, Anatomy and Development of: Serial-Section Whole Organ Study of Perinatal Larynges (Tucker G, Tucker J and Vidić) 1977, 82.
- Cyclic Pharyngeal Lymphoiditis (Goldman) 1978, 122.
- Cysts, Saccular, and Laryngocele (Holinger LD, Barnes, Smid and Holinger PH) 1978, 134.
- D**
- Diagnosis and Treatment of Carotid Body Tumors (Ward, Jenkins and Hanafée) 1978, 73.
- Dinitrochlorobenzene Skin Sensitization and Peripheral Lymphocyte Count: Predictors of Survival in Head and Neck Cancer (Maisei and Ogura) 1976, 125.
- Docendo Discimus (Putney) 1979, 15.
- Dysphonia:
- Spasmodic, Recurrent Laryngeal Nerve Section for (Levine, Wood, Batza, Rusnov and Tucker H) 1979, 104.
 - Spastic, Laryngeal Nerve Crush for (Biller, Som and Lawson) 1979, 108.
 - Spastic, Recurrent Laryngeal Nerve Section for (Dedo H) 1976, 47.
- E**
- Early Laryngology in the South (Putney) 1978, 43.
- Education, Continuing: A Challenge and a Necessity (LeJeune) 1975, 14.
- Education, Resident: Past, Present and To Where (Work) 1979, 39.
- Effects of Irradiation on Cervical Lymph Nodes (Welsh and Campellone) 1979, 70.
- Embolization of Juvenile Angiofibromas of Nasopharynx, Preoperative (Pletcher, Newton, Dedo H and Norman) 1975, 31.
- Endoscopic Teflon Keel for Anterior Glottic Web (Dedo H) 1979, 31.
- Energy and the Larynx (Fink) 1978, 61.
- Enteral and Parenteral Nutrition in Patients with Head and Neck Cancer (Sobel, Connoyer and Sessions D) 1979, 61.
- Epidermoid Carcinoma, Characterization of Tumor Antigen in (Krause, Nysather and McCabe) 1975, 79.
- Epiglottic Flap and Laryngeal Suspension in Laryngopharyngeal Trauma (Olson) 1976, 141.
- Esthesioneuroblastoma: Diagnosis and Treatment (Cantrell, Ghorayeb and Fitz-Hugh) 1977, 117.
- Etiology of Bilateral Abductor Vocal Cord Paralysis: Review of 389 Cases (Holinger LD, Holinger PC, and Holinger PH) 1976, 24.
- Evaluation of Computerized Tomography, Cinelaryngoscopy and Laryngography in Determining the Extent of Laryngeal Disease (Ward, Hanafée, Mancuso, Shallit and Ber-ci) 1979, 17.
- Evaluation of Randomized Preoperative and Postoperative Radiation Therapy for Supraglottic Carcinoma (Snow, Gelber, Kramer, Davis, Marcial and Lowry) 1978, 145.
- Experience with Vocal Cord Injection (Lewy) 1976, 36.
- Experimental Granuloma of Larynx (Kirchner F) 1975, 68.
- F**
- Fiber Components of Recurrent Laryngeal Nerve in Cat (Gacek and Lyon) 1976, 59.
- Fibrous Histiocytoma of Trachea (Cohen, Landing and Isaacs) 1978, 116.
- Fifty Years Ago (Clerf) 1978, 21.
- Fistulas, Pharyngocutaneous, Complicating Head and Neck Cancer Surgery, Incidence, Predisposing Factors and Outcome of (Dedo D, Alonso and Ogura) 1975, 128.
- Focusing Magnifying Laryngoscope (Robbett) 1977, 117.
- Frey's Syndrome. A Technical Remedy (Sessions R, Roark and Alford) 1975, 25.
- Frontal Sinusotomy, Osteoplastic: Analysis of 250 Operations (Hardy and Montgomery) 1976, 131.

G

- Glomus Jugulare and Vagale (Ogura, Spector and Gado) 1978, 80.
- Glottic Squamous Cell Carcinoma (T₂): Retrospective Study (Doyle, Flores and Bell) 1977, 29.
- Glottic Web, Anterior, Endoscopic Teflon Keel for (Dedo H) 1979, 31.
- Granular Cell Tumors of Larynx (Coates, McDonald, Devine and Weiland) 1976, 110.
- Granuloma of the Larynx, Experimental (Kirchner F) 1975, 68.
- Granulomatosis, Lymphomatoid, in a Child with Acute Lymphatic Leukemia in Remission (Cohen, Landing, Siegel, Shen, Heuser and Isaacs) 1978, 116.
- Granulomatosis, Wegener's, Causing Laryngeal and Tracheobronchial Obstruction in an Adolescent Girl (Cohen, Landing, King and Isaacs) 1978, 116.

H

Head and Neck:

- Cancer, Enteral and Parenteral Nutrition in Patients with (Sobel, Conoyer and Sessions D) 1979, 61.
- Cancer, Predictors of Survival in: Dinitrochlorobenzene Skin Sensitization and Peripheral Lymphocyte Count (Maisel and Ogura) 1976, 125.
- Cancer Surgery, Incidence, Predisposing Factors and Outcome of Pharyngocutaneous Fistulas Complicating (Dedo D, Alonso and Ogura) 1975, 128.
- Clinical Course of Unusual Malignant Sarcomas of (Setzen, Sobel and Toomey) 1979, 52.
- Hemangiomas of (Work) 1978, 91.
- Surgery, Progress of Otolaryngology in (Ogura) 1976, 21.
- Hemangiomas of Head and Neck (Work) 1978, 91.
- Histiocytoma, Fibrous, of Trachea (Cohen, Landing and Isaacs) 1978, 116.
- History of Laryngology in Early Chicago and Rush Medical College (Friedberg) 1978, 48.
- Hypersensitivity Problems in Otorhinolaryngology (Williams) 1978, 129.
- Hypoglossal Nerve, Bilateral, Paralysis of, after Irradiation Therapy (Saunders and Hodgson) 1979, 83.

I

- Immune Monitoring Protocol for Patients with Carcinoma of Head and Neck (Veltri, Sprinkle, Maxim, Theofilopoulos, Rodman and Kinney) 1978, 151.
- Implanted Electronic Laryngeal Prosthesis (Bailey, Griffiths and Everett) 1976, 71.
- Incidence, Predisposing Factors and Outcome of Pharyngocutaneous Fistulas Complicating Head and Neck Cancer Surgery (Dedo D, Alonso and Ogura) 1975, 128.

- Injuries to Neonatal Larynx from Long-Term Endotracheal Tube Intubation and Suggested Tube Modification for Prevention (Hengerer, Strome and Jaffe) 1975, 46.

Irradiation:

- Effects of, on Cervical Lymph Nodes (Welsh and Campellone) 1979, 70.
- Therapy, Bilateral Hypoglossal Nerve Paralysis after (Saunders and Hodgson) 1979, 83.
- of Laryngeal Cancer, Second Primary Cancer after (Lawson and Som) 1975, 63.

J

- Juvenile Nasopharyngeal Angiofibroma (Biller) 1978, 88.

L

Laryngeal:

- Cancer, Second Primary Cancer after Irradiation of (Lawson and Som) 1975, 63.
- Disease, Evaluation of Computerized Tomography, Cinelaryngoscopy, and Laryngography in Determining the Extent of (Ward, Hanafee, Mancuso, Shallit and Berci) 1979, 17.
- Defects, Congenital, in Adult (Montgomery and Smith) 1976, 90.
- Dysfunction Following Prolonged Intubation (Whited) 1979, 99.
- Nerve Crush for Spastic Dysphonia (Biller, Som and Lawson) 1979, 108.
- Nerve Section for Spasmodic Dysphonia, Recurrent (Levine, Wood, Batza, Rusnov and Tucker H) 1979, 104.
- Nerves, Preservation of During Total Thyroid Lobectomy (Lore, Kim and Elias) 1977, 93.
- Prosthesis, Electronic, Implanted (Bailey, Griffiths and Everett) 1976, 71.
- Suspension and Epiglottic Flap in Laryngopharyngeal Trauma (Olson) 1976, 141.
- Laryngectomy and Neck Dissection, Complications of, Following Planned Preoperative Radiotherapy (Cummings, Johnson, Chung and Sagerman) 1977, 57.
- Laryngectomy, Vertical Partial, for Glottic Carcinoma with Posterior Subglottic Extension (Biller and Som) 1977, 25.
- Laryngitis, Acute, Obstructive, in Children: Fifty Year Review (Davison) 1978, 25.
- Laryngocele and Saccular Cysts (Holinger LD, Barnes, Smid and Holinger PH) 1978, 134.
- Laryngology:
- Early, Contributions of Philadelphia to (Norris) 1978, 39.
 - Early, in the South (Putney) 1978, 43.
 - In the Far West (Miller A) 1978, 54.
 - History of, in Early Chicago and Rush Medical College (Friedberg) 1978, 48.
- Laryngopharyngeal Trauma, Laryngeal Suspension and Epiglottic Flap in (Olson) 1976, 141.
- Laryngoscopy, Focusing Magnifying (Robbett) 1977, 117.

Larynx:

- Cleft. Report of Seven Cases (Cohen) 1975, 53.
- Conservation Surgery of, New Insights into Causes of Postoperative Aspiration Following (Ward, Berci and Calcaterra) 1977, 34.
- Experimental Granuloma of (Kirchner F) 1975, 68.
- Granular Cell Tumors of (Coates, McDonald, Devine and Weiland) 1976, 110.
- Localization of Adductor and Abductor Motor Nerve Fibers to (Gacek, Malmgren and Lyon) 1977, 86.
- Neonatal, Injuries to, from Long-Term Endotracheal Tube Intubation and Suggested Tube Modification for Prevention (Hengerer, Strome and Jaffe) 1975, 46.
- Neurofibroma of, in a Child (Cohen, Landing and Isaacs) 1978, 116.
- Paralyzed Unilaterally, Reinnervation of (Tucker H) 1977, 105.
- Primary Lymphosarcoma of, in a Child (Cohen, Landing, Byrne, Feig and Isaacs) 1978, 116.
- Supraglottic, Clinical Correlation of Anomalies, with Staged Sequence of Normal Human Development (Tucker J, Tucker G and Vidić) 1978, 94.
- Suspension: Epiglottic Flap in Laryngopharyngeal Trauma (Olson) 1976, 141.
- Verrucous Carcinoma of: Management of Radiotherapy and Surgery (Burns, van Nostrand and Bryce) 1976, 98.
- and Energy (Fink) 1978, 61.
- and Laryngopharynx, Mucus Gland Tumors of (Spiro, Lewis, Hadju and Strong EW) 1976, 104.
- in Infancy and Childhood, Subglottic Stenosis of (Cotton) 1978, 107.
- in the Infant and Child, Subglottic Stenosis of (Fearon, Crysdael and Bird) 1978, 103.
- Laser, Carbon Dioxide:
- Management of Choanal Atresia with (Healy, McGill, Jako, Strong MS and Vaughan) 1978, 117.
 - Management with, in Recurrent Respiratory Papillomatosis (Strong MS, Vaughan, Cooperband, Healy and Clemente) 1976, 116.
 - Surgical Excision of Benign Tumors and Lesions of Larynx in Children (Simpson, Healy, McGill and Strong MS) 1979, 44.
- Lateral Rhinotomy: A Neglected Operation (Harrison) 1977, 70.
- Leiomyosarcoma of the Cervical Trachea. Report of a Case with Reconstruction Using a Latissimus Dorsi Island Flap (Fredrickson, Jahn and Bryce) 1979, 27.
- Leukemia, Acute Lymphatic, in Remission, Lymphomatoid Granulomatosis in a Child with (Cohen, Landing, Siegel, Shen, Heuser and Isaacs) 1978, 116.
- Localization of Adductor and Abductor Motor Nerve Fibers to Larynx (Gacek, Malmgren and Lyon) 1977, 86.
- Long-Term Stenting in Treatment of Subglottic Stenosis (Goode and Shinn) 1977, 113.
- Lupus Erythematosus, Systemic, Associated with Solitary Plasmacytoma of Larynx and Upper Trachea (Cohen, Landing, Isaacs, King and Hanson) 1978, 116.
- Lymphocyte Count, Peripheral, and Dinitrochlorobenzene Skin Test: Predictors of Survival in Head and Neck Cancer (Maisel and Ogura) 1976, 125.
- Lymph Nodes, Cervical, Effects of Irradiation on (Welsh and Campellone) 1979, 70.
- Lymphoiditis, Cyclic Pharyngeal (Goldman) 1978, 122.
- Lymphomatoid Granulomatosis in a Child with Acute Lymphatic Leukemia in Remission (Cohen, Landing, Siegel, Shen, Heuser and Isaacs) 1978, 116.
- Lymphosarcoma, Primary, of Larynx, in a Child (Cohen, Landing, Byrne, Feig and Isaacs) 1976, 116.

M

- Management of Dying Patient with Head and Neck Cancer (Miller D) 1977, 119.
- Management of Choanal Atresia with the Carbon Dioxide Laser (Healy, McGill, Jako, Strong MS and Vaughan) 1978, 117.
- Marks of Self (Thomas) 1977, 18.
- Memorials:
- Alexander, Fred W., 1977, 139.
 - Alonso, Justo M., 1976, 163.
 - Bryoles, Edwin N., 1978, 205.
 - Cardwell, Edgar P., 1978, 207.
 - Dickenson, John T., 1979, 124.
 - Galloway, Thomas C., 1977, 147.
 - Hilding, Anderson C., 1978, 208.
 - Holinger, Paul H., 1978, 216.
 - Huizinga, Eelco, 1977, 141.
 - LeJeune, Francis E., 1978, 211.
 - Lierle, Dean M., 1977, 143.
 - Lukens, Robert M., 1979, 127.
 - Myerson, Mervin C., 1979, 131.
 - Negus, Victor, 1975, 153.
 - O'Neil, James J., 1975, 157.
 - Rawlins, Aubrey G., 1977, 145.
 - Rethi, Aurelius, 1978, 213.
 - Salinger, Samuel, 1976, 164.
 - Schenck, Harry P., 1979, 128.
 - Simpson, W. Likely, 1976, 167.
 - Theobald, Walter H., 1975, 159.
 - Tremble, George E., 1978, 214.
 - Van Alyea, Oliver E., 1975, 165.
 - Weille, Francis L., 1975, 167.
 - Williams, Henry L., Jr., 1975, 161.
- Men and Institutions—New York 1878 (Daly) 1978, 33.
- Mucus Gland Tumors of the Larynx and Laryngopharynx (Spiro, Lewis, Hajdu and Strong EW) 1976, 104.
- Myasthenia Gravis of Larynx, Voice Spectrography in Evaluation of (Rontal M, Rontal E, Leuchter and Rolnick) 1978, 181.

N

- Nasopharynx, Carcinoma of, in Children (Snow) 1975, 110.
- Neck Dissection: Radical or Conservative (Lingeman, Helmus, Stephens and Ulm) 1977, 49.
- Neonatal Larynx, Injuries to, from Long-Term Endotracheal Tube Intubation and Suggested Modification for Prevention (Hengerer, Strome and Jaffe) 1975, 46.
- Neurofibroma of Larynx in a Child (Cohen, Landing and Isaacs) 1978, 116.
- New Insights into Causes of Postoperative Aspiration Following Conservation Surgery of Larynx (Ward, Berci and Calcaterra) 1977, 34.
- Nontraumatic, Nonneoplastic Subglottic Stenosis (Djalilian, McDonald, Devine and Weiland) 1975, 38.
- Nutrition, Enteral and Parenteral, in Patients with Head and Neck Cancer (Sobel, Conoyer and Sessions D) 1979, 61.

O

- Observations on Primate Hyoepiglottic Complex (Tucker G and Tucker J) 1975, 122.
- Osteoplastic Frontal Sinusotomy: Analysis of 250 Operations (Hardy and Montgomery) 1976, 131.
- Otolaryngological Manifestations of Arthrogryposis Multiplex Congenita (Cohen and Isaacs) 1976, 83.
- Otolaryngology at the Crossroads (Daly) 1979, 11.
- Otolaryngology, Progress of, in Head and Neck Surgery (Ogura) 1976, 21.

P

- Papillomatosis, Recurrent Respiratory, Management with the CO₂ Laser (Strong MS, Vaughan, Cooperband, Healy and Clemente) 1976, 116.
- Papillary Adenocarcinoma of Thyroid Invading Upper Air Passages (Lawson, Som and Biller) 1977, 63.
- Pharyngocutaneous Fistulas Complicating Head and Neck Cancer Surgery (Dedo D, Alonso and Ogura) 1975, 128.
- Plasmacytoma, Solitary, of the Larynx and Trachea, Associated with Systemic Lupus Erythematosus (Cohen, Landing, Isaacs, King and Hanson) 1978, 116.
- Preoperative Embolization of Juvenile Angiofibromas of Nasopharynx (Pletcher, Newton, Dedo H and Norman) 1975, 31.
- Preservation of Laryngeal Nerves During Total Thyroid Lobectomy (Loré, Kim and Elias) 1977, 93.
- Primary Lymphosarcoma of Larynx in a Child (Cohen, Landing, Byrne, Feig and Isaacs) 1978, 116.
- Primate Hyoepiglottic Complex, Observations on (Tucker G and Tucker J) 1975, 122.
- Problem of Collapsing Upper Lateral Cartilage (McCabe) 1979, 95.

- Progress of Otolaryngology in Head and Neck Surgery (Ogura) 1976, 21.
- Pyriform Sinus Cancer: A Clinical and Laboratory Study (Kirchner J) 1975, 85.

R

- Radiation Failures in Cancer of Larynx (Skolnik, Martin, Yee and Wheatley) 1975, 96.
- Radiation Fibrosis and Necrosis of the Larynx. 1979, 77.
- Radiation-Induced Tissue Injury, Treatment by Hyperbaric Oxygen (Farmer, Shelton, Angelillo, Bennett and Hudson) 1978, 116.
- Radiation Therapy, Randomized Preoperative and Postoperative for Supraglottic Carcinoma, Evaluation of (Snow, Gelber, Kramer, Davis, Marcial and Lowry) 1978, 145.
- Radiotherapy, Planned Preoperative, Complications of Laryngectomy and Neck Dissection Following (Cummings, Johnson, Chung and Sagerman) 1977, 57.
- Recurrent Laryngeal Nerve in Cat, Fiber Components of (Gacek and Lyon) 1976, 59.
- Recurrent Laryngeal Nerve Section for Spasmodic Dysphonia (Levine, Wood, Batza, Rusnov and Tucker H) 1979, 104.
- Recurrent Laryngeal Nerve Section for Spastic Dysphonia (Dedo H) 1976, 47.
- Recurrent Respiratory Papillomatosis: Management with Carbon Dioxide Laser (Strong MS, Vaughan, Cooperband, Healy, Clement) 1976, 116.
- Rehabilitation of Shoulder after Radical Dissection (Saunders and Johnson) 1975, 105.
- Reinnervation of the Unilaterally Paralyzed Larynx (Tucker H) 1977, 105.
- Resident Education: Past, Present, and To Where (Work) 1979, 39.
- Rhinotomy, Lateral: A Neglected Operation (Harrison) 1977, 70.

S

- Sarcomas of Head and Neck, Unusual, Clinical Course of (Setzen, Sobel and Toomey) 1979, 52.
- Second Primary Cancer After Irradiation of Laryngeal Cancer (Lawson and Som) 1975, 63.
- Shoulder, Rehabilitation of, after Radical Neck Dissection (Saunders and Johnson) 1975, 105.
- Sinusotomy, Osteoplastic, Frontal: Analysis of (Hardy and Montgomery) 1976, 131.
- Solitary Plasmacytoma of Larynx and Upper Trachea Associated with Systemic Lupus Erythematosus (Cohen, Landing, Isaacs, King and Hanson) 1978, 116.
- Some Reflections on Our Specialty (Conley) 1975, 20.
- Spectrography, Voice, in the Evaluation of Myasthenia Gravis of Larynx (Rontal E, Rontal M, Leuchter and Rolnick) 1978, 181.
- Stenosis:
- Laryngeal, Associated with Epidermolysis Bullosa (Cohen, Landing and Isaacs) 1978, 116.

- Subglottic, Long-Term Stenting in Treatment of (Goode and Shinn) 1977, 113.
- Subglottic, Nontraumatic, Nonneoplastic (Djalilian, McDonald, Devine and Weiland) 1975, 38.
- Subglottic, Management in Infancy and Childhood (Cotton) 1978, 107.
- Subglottic, of the Larynx, in Infant and Child (Fearon, Crysdale and Bird) 1978, 103.
- Tracheal, Tracheal Incision as a Contributing Factor to, Experimental Study (Lulenski and Batsakis) 1975, 73.
- Stenting, Long-Term, in Treatment of Subglottic Stenosis (Goode and Shinn) 1977, 113.
- Subglottic Stenosis in Infancy and Childhood, Management of (Cotton) 1978, 107.
- Subglottic Stenosis of Larynx in Infant and Child (Fearon, Crysdale and Bird) 1978, 103.
- Surgical Excision by Carbon Dioxide Laser, of Benign Tumors and Lesions in Children (Simpson, Healy, McGill and Strong MS) 1979, 44.
- Surgical Treatment of Acute, Blunt, Laryngeal Injuries (Olson) 1978, 175.
- T**
- Thorotrast Induced Pharyngeal Necrosis (Miglets, Letson and Speigel) 1978, 160.
- Thyroid Lobectomy, Total, Preservation of Laryngeal Nerves During (Lore, Kim and Elias) 1977, 93.
- Thyroid, Papillary Adenocarcinoma of, Invading Upper Air Passages (Lawson, Som and Biller) 1977, 63.
- Trachea, Cervical, Leiomyosarcoma of, Report of a Case with Reconstruction Using a Latissimus Dorsi Island Flap (Fredrickson, Jahn and Bryce) 1979, 27.
- Trachea, Fibrous Histiocytoma of (Cohen, Landing and Isaacs) 1978, 116.
- Tracheal Incision as Contributing Factor to Tracheal Stenosis: Experimental Study (Lulenski and Batsakis) 1975, 73.
- Trauma, Laryngopharyngeal: Laryngeal Suspension and Epiglottic Flap in (Olson) 1976, 141.
- Treatment of Radiation Induced Tissue Injury by Hyperbaric Oxygen (Farmer, Shelton, Angelillo, Bennett and Hudson) 1978, 166.
- Tumor Antigen, Characterization of, in Epidermoid Carcinoma (Krause, Nysather and McCabe) 1975, 79.
- Tumors:
- Carotid Body, Diagnosis and Treatment of (Ward, Jenkins and Hanafée) 1978, 73.
- Granular Cell, of Larynx (Coates, McDonald, Devine and Weiland) 1976, 110.
- Mucus Gland, of Larynx and Laryngopharynx (Spiro, Lewis, Hadju and Strong EW) 1976, 104.
- and Lesions, Benign, of the Larynx in Children: Surgical Excision by Carbon Dioxide Laser (Simpson, Healy, McGill and Strong MS) 1979, 44.
- V**
- Verrucous Carcinoma of Larynx: Management by Radiotherapy and Surgery (Burns, van Nostrand and Bryce) 1976, 98.
- Vertical Partial Laryngectomy for Glottic Carcinoma with Posterior Subglottic Extension (Biller and Som) 1977, 25.
- Vocal Cord Injection, Experience with (Lewy) 1976, 36.
- Vocal Cord Paralysis, Bilateral Abductor, Etiology of: A Review of 389 Cases (Holinger LD, Holinger PC and Holinger PH) 1976, 24.
- Voice Spectrography in Evaluation of Myasthenia Gravis of Larynx (Rontal M, Rontal E, Leuchter and Rolnick) 1978, 181.
- W**
- Wegener's Granulomatosis Causing Laryngeal and Tracheobronchial Obstruction in an Adolescent Girl (Cohen, Landing, King and Isaacs) 1978, 116.

Volume 96-100 Inclusive

1975-1979

AUTHORS INDEX

A

Alford, Bobby R., 1975, 25.
Alonso, William A., 1975, 128.
Angelillo, J. D., 1978, 166.

B

Bailey, Byron J., 1976, 71.
Barnes, David R., 1978, 134.
Batsakis, John G., 1975, 73.
Batza, Eugene, 1979, 104.
Bell, Desmond R., 1977, 29.
Bennett, P. D., 1978, 166.
Berci, George, 1977, 34; 1979, 17.
Biller, Hugh F., 1977, 25 & 63; 1978, 88; 1979, 108.
Bird, Russell, 1978, 103.
Bryce, Douglas P., 1976, 98; 1979, 27.
Burns, Hugh P., 1976, 98.
Byrne, William J., 1978, 116.

C

Calcaterra, Thomas C., 1977, 34.
Caldarelli, David D., 1979, 88.
Campellone, Frank, 1979, 70.
Campanella, Ruth S., 1979, 88.
Cantrell, Robert W., 1977, 57.
Chandler, James R., 1979, 77.
Chung, Chung K., 1977, 57.
Clemente, Manuel, 1976, 116.
Clerf, Louis H., 1978, 21.
Coates, Harvey L., 1976, 110.
Cohen, Seymour R., 1975, 53; 1976, 83; 1978, 116.
Conley, John J., 1975, 20.
Conoyer, Michael, 1979, 61.
Cooperband, Sidney R., 1976, 116.
Cotton, Robin, 1978, 107.
Crysdale, William S., 1978, 103.
Cummings, Charles, 1977, 57.

D

Daly, John F., 1978, 33; 1979, 11 & 14.
Davis, Lawrence W., 1978, 145.
Davison, Francis W., 1978, 25.
Dedo, Douglas D., 1975, 128.
Dedo, Herbert H., 1975, 31; 1976, 47; 1979, 31.
Devine, Kenneth D., 1975, 38; 1976, 110.

Djalilian, Mohsen, 1975, 38.
Doyle, Patrick, 1977, 29.

E

Elias, Samir, 1977, 93.
Everett, Robert L., 1976, 71.

F

Farmer, Joseph C., Jr., 1978, 166.
Fearon, Blair, 1978, 103.
Fee, Willard E., Jr., 1978, 159.
Feig, Stephen, 1978, 116.
Ferguson, Charles F., 1978, 11, 20, 24 & 60.
Fink, B. Raymond, 1978, 61.
Fitz-Hugh, G. Slaughter, 1977, 74.
Flores, A., 1977, 29.
Frederickson, John M., 1979, 27.
Friedberg, Stanton, 1976, 11 & 16; 1978, 48; 1979, 88.

G

Gacek, Richard R., 1976, 59; 1977, 86.
Gado, Mokhtar, 1978, 80.
Galloway, Thomas C., 1976, 17.
Gelber, Richard D., 1978, 145.
Ghorayeb, Bechara, 1977, 74.
Goldman, Joseph L., 1978, 122.
Goode, Richard L., 1977, 113.
Griffiths, Ceri M., 1976, 71.

H

Hadju, Steven I., 1976, 104.
Hanafee, William, 1978, 73; 1979, 17.
Hanson, Virgil, 1978, 116.
Hardy, James M., 1976, 131.
Harrison, Donald F. N., 1977, 70.
Healy, Gerald B., 1976, 116; 1978, 117; 1979, 44.
Helmus, Christian, 1977, 49.
Hengerer, Arthur S., 1975, 46.
Heuser, Eva, 1978, 116.
Hodgson, Sheila, 1979, 83.
Holinger, Lauren D., 1976, 24; 1978, 134.
Holinger, Paul C., 1976, 24.
Holinger, Paul H., 1976, 24; 1977, 15; 1978, 134.
Hudson, W. R., 1978, 166 & 187.

I

Isaacs, Hart, 1976, 83; 1978, 116.

J

- Jaffe, Burton F., 1975, 46.
 Jahn, Anthony, 1979, 27.
 Jako, Geza J., 1978, 117.
 Jenkins, Herman A., 1978, 73.
 Johnson, Ernest, 1975, 105.
 Johnson, Jonas, 1977, 57.
 Jones, Edley H., 1978, 159.

K

- Kim, Duck J., 1977, 93.
 King, Karen K., 1978, 116.
 Kinney, C. L., 1978, 151.
 Kirchner, Fernando, 1975, 68.
 Kirchner, John A., 1975, 85.
 Kramer, Simon, 1978, 145.
 Krause, Charles J., 1975, 79.

L

- Landing, Benjamin H., 1978, 116.
 Lawson, William, 1975, 63; 1977, 63; 1979, 108.
 LeJeune, Francis E., 1975, 14.
 Letson, James A., 1978, 160.
 Leuchter, William, 1978, 181.
 Levine, Howard L., 1979, 104.
 Lewis, John S., 1976, 104.
 Lewy, Robert B., 1976, 36; 1978, 187.
 Lingeman, Raleigh, 1977, 49.
 Lore, John M., Jr., 1976, 93; 1978, 72.
 Lowry, Lewis, D., 1978, 145.
 Lulenski, Gary C., 1975, 73.
 Lyon, Michael J., 1976, 59; 1977, 86.

M

- Maisel, Robert H., 1976, 125.
 Malmgren, Leslie T., 1977, 86.
 Mancuso, Anthony, 1979, 17.
 Marcial, Victor A., 1978, 145.
 Martin, Lawrence O., 1975, 96.
 Maxim, P. E., 1978, 151.
 McCabe, Brian F., 1975, 79; 1979, 95.
 McDonald, Thomas J., 1975, 38; 1976, 110.
 McGill, Trevor, 1978, 117; 1979, 44.
 Miglets, Andrew W., 1978, 160.
 Miller, Alden H., 1978, 54.
 Miller, Daniel, 1977, 119.
 Montgomery, William W., 1976, 90 & 131.

N

- Newton, Thomas H., 1975, 31.
 Norman, David, 1975, 31.
 Norris, Charles M., 1977, 11, 14 & 17, 1978, 39.
 Nysather, John, 1975, 79.

O

- Ogura, Joseph H., 1975, 11, 13 & 128; 1976, 21 & 125; 1978, 80.
 Olson, Nels R., 1976, 141; 1978, 175.

P

- Pennington, Claude L., 1976, 33.
 Pletcher, James D., 1975, 31.
 Putney, Floyd J., 1978, 43; 1979, 15.

R

- Roark, David T., 1975, 25.
 Robbette, William F., 1977, 117.
 Rodman, S. R., 1978, 151.
 Rolnick, Michael, 1978, 181.
 Rontal, Eugene, 1978, 181.
 Rontal, Michael, 1978, 181.
 Rusnov, Melinda, 1979, 104.

S

- Sadek, Hilal, 1978, 72.
 Sagerman, Robert, 1977, 57.
 Saunders, William H., 1975, 105; 1979, 83.
 Sessions, Donald G., 1979, 61.
 Sessions, Roy, 1975, 25.
 Setzen, Michael, 1979, 52.
 Shallit, Joel, 1979, 17.
 Shelton, D. L., 1978, 166.
 Shen, Susan, 1978, 116.
 Shinn, John B., 1977, 113.
 Siegel, Stuart, 1978, 116.
 Simpson, George, 1979, 44.
 Skolnik, Emanuel M., 1975, 96.
 Smid, Lijze, 1978, 134.
 Smith, Steven A., 1976, 90.
 Snow, James B., Jr., 1975, 110; 1978, 145 & 159.
 Sobel, Steven, 1979, 52 & 61.
 Som, Max L., 1975, 63; 1977, 25 & 63; 1978, 72; 1979, 108.
 Spector, Gershon J., 1978, 80.
 Spiegel, Jerome C., 1978, 160.
 Spiro, Ronald H., 1976, 104.
 Sprinkle, P. M., 1978, 151.
 Stephens, Robert, 1977, 49.
 Strome, Marshall, 1975, 46.
 Strong, Elliot, 1976, 104.
 Strong, M. Stuart, 1976, 116; 1978, 117; 1979, 44.

T

- Theofilopoulos, A. N., 1978, 151.
 Thomas, Lewis, 1977, 18.
 Toomey, James M., 1979, 52.
 Tucker, Gabriel F., 1975, 122; 1977, 82; 1978, 94.
 Tucker, Harvey M., 1977, 105; 1979, 104.
 Tucker, John A., 1975, 122; 1977, 82; 1978, 94.

U

Ulm, James, 1977, 49.

V

van Nostrand, A. W. P., 1976, 98.

Vaughan, Charles W., 1976, 116; 1978, 117.

Veltri, R. W., 1978, 151.

Vidić, Branislav, 1977, 82; 1978, 94.

W

Ward, Paul H., 1977, 34; 1978, 73; 1979, 17.

Weiland, Louis H., 1975, 38; 1976, 110.

Welsh, Louis W., 1979, 70.

Wheatley, Michael A., 1976, 96.

Whited, Robert E., 1979, 99.

Williams, Russel I., 1978, 129.

Wood, Benjamin G., 1979, 104.

Woodman, DeGraaf, 1976, 33.

Work, Walter P., 1978, 91; 1979, 39.

Y

Yee, King F., 1975, 96.

Yoder, Milton G., 1978, 187.

