TRANSACTIONS

AMERICAN LARYNGOLOGICAL ASSOCIATION

1982

VOLUME ONE HUNDRED THREE

"DOCENDO DISCIMUS"

≈

ONE HUNDRED THIRD ANNUAL MEETING

THE BREAKERS

PALM BEACH, FLORIDA

MAY 1 AND 2, 1982

≈

PUBLISHED BY THE ASSOCIATION
ST. LOUIS, MISSOURI
GABRIEL FREDERICK TUCKER, JR, MD, Editor

CONTENTS

Officers for 1981-1982 4

Registration of Fellows 5

Annual Photograph 6

Minutes of Executive Sessions 7

Reports:
- Secretary, W. M. Trible, MD 8
- Historian-Editor, G. F. Tucker, Jr, MD 8
- Nominating Committee, S. A. Friedberg, MD 8
- Governor, American College of Surgeons, G. F. Tucker, Jr, MD 8
- Accountant 9
- Treasurer 9

The Memorial Fund and the Laryngological Research Fund 11

Recipients of De Roaldes, Casselberry and Newcomb Awards 12

Presidential Address. H. G. Tabb, MD 13

Introduction of Guest of Honor James W. McLaurin, MD. H. G. Tabb, MD 14

Guest of Honor Address. J. W. McLaurin, MD 14

SCIENTIFIC SESSIONS

Introduction of Daniel C. Baker, Jr, Memorial Lecturer George F. Reed, MD. H. G. Tabb, MD 15

Eighth Daniel C. Baker, Jr, Memorial Lecture. Subcertification: A Dilemma for Otolaryngology-Head and Neck Surgery. G. F. Reed, MD 16

Office Telescopic Photography of the Larynx. E. Yanagisawa, MD, FACS 18

Laryngeal Sarcoidosis: Report of 13 Patients. H. B. Neel III, MD, PhD; T. J. McDonald, MD 23

Laryngotracheal Invasion by Thyroid Carcinoma. M. Friedman, MD; V. K. Shelton, MD; E. M. Skolnik, MD; F. G. Berlinger, MD; M. Arab, MD 27

Age-Related Changes in the Epithelium of the Monkey Larynx. M. P. Stearns, FRCS; C. W. Cummings, MD, FACS 34

Classification and Approach to Patients with Functional Voice Disorders. J. A. Koufman, MD; P. D. Blalock, MA 36

Pathogenesis of Vocal Cord Polyps. O. Kleinsasser, MD 42

Endoscopic Rehabilitation of the Airway in Laryngeal Paralysis. F. R. Kirchner, MD, FACS 46

Predictive Factors of Success or Failure in the Endoscopic Management of Laryngeal and Tracheal Stenosis. G. T. Simpson, MD, MPH; M. S. Strong, MD; G. B. Healy, MD; S. M. Shapshay, MD; C. W. Vaughan, MD 48

Diagnosis and Conservative Surgical Management of Chondrosarcoma of the Larynx. J. N. Hicks, MD; E. E. Walker, MD; E. E. Moor, MD 53

Chondrosarcoma of the Larynx: Excision of Massive Recurrence. F. E. LeJeune, Jr, MD, FACS; H. W. Van Horn III, MD; G. H. Farr, MD 56

Extended Transantral Approach to Pterygomaxillary Tumors. C. J. Krause, MD; S. R. Baker, MD 59

Primary Management of Laryngeal Trauma. S. D. Schaefer, MD 63

Assessment of Intubation in Croup and Epiglottitis. J. J. Zulliger, MD; D. E. Schuller, MD; T. P. Beach, MD; J. P. Garvin, MD; H. G. Birck, MD; J. E. Frank 67

Treatment of Severe Subglottic Stenosis Without Tracheotomy: A Preliminary Report. L. D. Holinger, MD 71

Infant Tracheotomy. C. R. Gerson, MD; G. F. Tucker, Jr, MD 77

Laryngeal Paralysis in Children: A Long-Term Retrospective Study. S. R. Cohen, MD; K. A. Geller, MD; J. W. Birns, MD; J. W. Thompson, MD 81

Laryngeal Papilloma: Results of Treatment with the CO_2 Laser and Podophyllum. H. H. Dedo, MD; R. K. Jackler, MD 89

Leukocyte Interferon in Patients with Juvenile Laryngeal Papillomatosis. H. Goepfert, MD; R. B. Sessions, MD; J. U. Gutterman, MD; A. Cangir, MD; W. J. Dichtel, MD; M. Sulek, MD 95

Cricothyroidotomy: The Impact of Antecedent Endotracheal Intubation. E. A. Weymuller, Jr, MD; C. W. Cummings, MD 101

Nerve-Muscle Pedicle Reinnervation of the Larynx: Avoiding Pitfalls and Complications. H. M. Tucker, MD 104

Surgery of the Inferior Nasal Turbinates. W. H. Saunders, MD 109

Correction of Posterior Glottic Incompetence Following Horizontal Partial Laryngectomy. H. F. Biller, MD; W. Lawson, MD, DDS; S. Sacks, MD 112

Tracheostomal Stenosis Following Total Laryngectomy. E. N. Myers, MD, FACS; L. J. Gallia, DDS, MD 114

Predicting Esophageal Speech. G. A. Gates, MD; E. M. Hearne III, PhD 118

Primary Vocal Rehabilitation Using the Blom-Singer and Panje Voice Prostheses. M. D. Maves, MD; R. E. Lingeman, MD 122

Chemical Modulation of the Hypoxic Fraction in the Treatment of Head and Neck Cancer. R. R. Weichselbaum, MD; T. J. Ervin, MD; D. Miller, MD 125

Single-Stage Correction of the Twisted Nose (abstract). M. E. Tardy, MD; T. Lawrence, MD 128

Discussions 129

≈

Memorials:

Paul A. Campbell 137

French K. Hansel 138

James A. Harrill 139

John R. Lindsay 140

Kenneth A. Phelps 141

Roster of Fellows 142

Officers 1982-1983 145

Index 146

OFFICERS 1981-1982

≈

PRESIDENT
HAROLD G. TABB, MD

VICE-PRESIDENT (PRESIDENT-ELECT)
M. STUART STRONG, MD

SECRETARY
WILLIAM M. TRIBLE, MD

TREASURER
LORING W. PRATT, MD

HISTORIAN-EDITOR
GABRIEL F. TUCKER, JR, MD

≈

COUNCIL

FIRST COUNCILOR
JOHN F. DALY, MD

SECOND COUNCILOR
JOHN A. KIRCHNER, MD

THIRD COUNCILOR
DANIEL MILLER, MD

COUNCILORS-AT-LARGE
RALEIGH E. LINGEMAN, MD
CHARLES F. FERGUSON, MD

REGISTRATION OF FELLOWS

ACTIVE

ALFORD, BOBBY R.
ANDREWS, ALBERT H., JR
BAILEY, BYRON J.
BALLENGER, JOHN J.
BAXTER, JAMES D.
BILLER, HUGH F.
BLAUGRUND, STANLEY M.
BOLES, ROGER
BORDLEY, JOHN E.
BRIANT, THOMAS D. R.
BROWN, LESTER A.
CANTRELL, ROBERT W.
CHANDLER, J. RYAN
COCKE, EDWIN W., JR
COHEN, SEYMOUR R.
CONLEY, JOHN J.
CUMMINGS, CHARLES W.
DEDO, HERBERT H.
DEWEESE, DAVID D.
FEARON, BLAIR
FEE, WILLARD
FERGUSON, CHARLES F.
FRAZER, JOHN P.
FRIEDBERG, STANTON A.
GACEK, RICHARD R.
GATES, GEORGE
GOLDMAN, JOSEPH L.
HILGER, JEROME A.
HUDSON, WILLIAM R.
KIRCHNER, FERNANDO R.
KIRCHNER, JOHN A.
KRAUSE, CHARLES J.
LAWSON, WILLIAM
LEJEUNE, FRANCIS E., JR
LEWIS, JOHN S.
LEWY, ROBERT B.
LINGEMAN, RALEIGH E.
LYONS, GEORGE D
MCGOVERN, FRANCIS H.
MIGLETS, ANDREW W., JR
MILLER, DANIEL
MONTGOMERY, WILLIAM W.
MYERS, EUGENE N.
NEEL, H. BRYAN III
NORRIS, CHARLES M.
OGURA, JOSEPH H.
OLSON, NELS
PANG, LUP Q.
PASTORE, PETER N.
PENNINGTON, CLAUDE L.
PRATT, LORING W.
PUTNEY, F. JOHNSON
REED, GEORGE F.
RITTER, FRANK N.
RONTAL, EUGENE
SAUNDERS, WILLIAM H.
SISSON, GEORGE A.
SKOLNIK, EMANUEL M.
SNOW, JAMES B., JR
SOBOROFF, BURTON J.
SOM, MAX L.
SPECTOR, GERSHON J.
SPRINKLE, PHILIP M.
STRONG, M. STUART
TABB, HAROLD G.
TARDY, M. EUGENE
THAWLEY, STANLEY
TRIBLE, WILLIAM M.
TUCKER, GABRIEL F., JR
TUCKER, HARVEY M.
TUCKER, JOHN A.
WARD, PAUL H.
WOODMAN, DEGRAAF
YANAGISAWA, EIJI

EMERITUS

CANFIELD, NORTON
HARRIS, HERBERT
LATHROP, FRANK D.
MUNOZ-MACCORMICK, CARLOS
MURTAGH, JOHN A.
SIMONTON, KINSEY M.
WORK, WALTER P.

CORRESPONDING

KLEINSASSER, OSKAR

FELLOWS IN ATTENDANCE AT THE ONE HUNDRED THIRD ANNUAL MEETING

First Row: Brown, Trible, Kirchner, Pratt, Lingeman, Miller, Tabb, Strong, Ferguson, G. Tucker.
Second Row: Hudson, Briant, Som, LeJeune, Yanagisawa, Andrews, Woodman, Ritter.
Third Row: Murtagh, Dedo, Pastore, Gacek, Goldman, Lathrop, Putney, Skolnik, Cohen, Myers, Pennington, Snow.
Fourth Row: Kleinsasser, Frazer, Soboroff, Reed, Lewis, Harris, Ogura, Fee, Lewy, Canfield, Munoz-MacCormick, Boles, Blaugrund.
Fifth Row: Hilger, Miglets, Pang, Friedberg, Fearon, Gates, Neel, Cocke, Olson, Montgomery, Cummings, Chandler, Saunders, Lyons, Norris, Baxter, Ward.

MINUTES OF THE EXECUTIVE SESSIONS

First Session — May 1, 1982

The first Executive Session of the One Hundred Third Annual Meeting was convened at 8:15 AM in the Venetian Room of The Breakers, Palm Beach, Florida, Harold G. Tabb, MD, New Orleans, presiding. The following candidates, having been recommended for Fellowship by the Council, were unanimously elected:

To Active Fellowship:

Willard E. Fee, Jr, MD, Stanford, California
Nels R. Olson, MD, Ann Arbor, Michigan
Eugene Rontal, MD, Bloomfield Hills, Michigan
Stanley Earl Thawley, MD, St. Louis, Missouri

To Emeritus Fellowship:

John Daly, MD, New York, New York
Charles F. Ferguson, MD, Osterville, Maine

Following their election the new Active Fellows were introduced to the Association by their respective sponsors, presented with Certificates of Fellowship and welcomed by President Tabb.

The following Fellows were elected as members of this year's Nominating Committee:

Stanton A. Friedberg, MD, Chairman
DeGraaf Woodman, MD
William Hudson, MD
Charles Norris, MD

The following Officers' reports were submitted and duly accepted:

Report of the Secretary
Report of the Historian-Editor

Second Session — May 2, 1982

The second Executive Session was opened by Secretary Trible at 1:15 PM. Dr. Pratt gave the Treasurer's report. This concluded with a motion that the dues be raised by $25.00 for the coming year. This motion was seconded and passed. The Nominating Committee report was received, and the report from the American College of Surgeons was given by Dr. Gabriel F. Tucker, Jr.

The meeting was then adjourned until the end of the Scientific Session.

At the close of the Scientific Session the Executive Session was reconvened by President Tabb. After a brief organizational meeting, the Directors announced that their organization for the year 1982-83 is as follows:

President: M. Stuart Strong, MD
Vice-President (President-Elect): John Lewis, MD
Secretary: Eugene N. Myers, MD
Treasurer: Loring Pratt, MD
Historian-Editor: Gabriel F. Tucker, Jr, MD
Councilor at Large: Herbert N. Dedo, MD
Councilor at Large: Claude L. Pennington, MD
First Councilor: John Kirchner, MD
Second Councilor: Daniel Miller, MD
Third Councilor: Harold Tabb, MD

Following the organization of the Directors, incoming President Strong presented the pin to retiring President Tabb who thanked the Association and all who helped to make the year and the program of the Annual Meeting successful. President Strong adjourned the meeting.

REPORTS

REPORT OF THE SECRETARY

The membership at the present time is 7 Honorary, 37 Emeritus, 93 Active, and 14 Corresponding, for a total of 151. I regret to inform you we have lost three Emeritus members to death in the past year — Drs. French Hansel, John Lindsay and James Harrill. Dr. Paul Campbell (Emeritus) resigned.

Our banquet tonight will be in the Beach Club with the reception starting at 7:00 PM and the dinner at 8:00 PM. Once again this year we would like to have the banquet tickets signed before they are picked up as this cross-check proves most valuable in the proper billing of the membership. Should someone have a different name than their host, please have "Guest of _____" written on it.

Next year we meet at the Fairmont Hotel in New Orleans on April 9 and 10, 1983.

In conclusion I wish to thank the council for their help this year, especially President Tabb, and the councils of the past five years which steered me through my tenure as secretary. It has been a great pleasure to work with these fine councilors, and next year it will be a greater pleasure to sit with you and listen to these reports.

Respectfully submitted,
William M. Trible, MD
Secretary

REPORT OF HISTORIAN-EDITOR

As Historian, I have the sad duty to report the deaths of four Emeritus Fellows:

French Hansel (elected to Active Fellowship 1940 and to Emeritus Fellowship 1960) died August 29, 1981; James A. Harrill (elected to Active Fellowship 1957 and to Emeritus Fellowship 1980) died March 16, 1982; John R. Lindsay (elected to Active Fellowship 1949 and to Emeritus Fellowship 1967) died December 21, 1981; Kenneth A. Phelps (elected to Active Fellowship 1948 and to Emeritus Fellowship 1957) died September 9, 1980.

As Editor: the usual 200 bound copies of the *Transactions* were printed at a cost of $6,500. Of the 160 pages, 101 (22 papers) had previously been printed in the September-October *Annals*. For comparison one might note that the 1980 *Transactions* cost $5,635 and contained 125 pages of which 91 (14 papers and 7 case reports) were reprinted from the November-December 1980 *Annals*. In an effort to keep publishing costs at a minimum, the discussions rather than being interwoven were "at the end of the *Annals* block." The publishers insist that to have interwoven these discussions as presented would have cost us another $1,000.

As we approach publication of the proceedings of this meeting, it should be noted that there were originally 28 scheduled papers. In addition to the increased length of the volume, the *Annals* has now expressed concern that our *Transactions* may increase the cost of the issue in which they are published. We are working closely with the *Annals* exploring various alternatives to minimize the expense of next year's *Transactions*.

Respectfully submitted,
Gabriel F. Tucker, Jr, MD
Historian-Editor

REPORT OF THE NOMINATING COMMITTEE

Mr. President, Fellows, on behalf of the Nominating Committee, I would like to propose the following Council members for the year 1982-83:

M. Stuart Strong, MD
John S. Lewis, MD
Eugene N. Myers, MD
Loring W. Pratt, MD
Gabriel F. Tucker, Jr, MD
John A. Kirchner, MD
Daniel Miller, MD
Harold G. Tabb, MD
Herbert H. Dedo, MD
Claude L. Pennington, MD

Respectfully submitted,
Stanton Friedberg, MD
Chairman

REPORT OF THE AMERICAN LARYNGOLOGICAL ASSOCIATION GOVERNOR OF THE AMERICAN COLLEGE OF SURGEONS

As your representative I attended the Board of Governors' meeting at the 1981 convocation of the College in San Francisco; I was at that time elected to serve another 3-year term as your representative. The American College of Surgeons continues its vigorous activity; their 1982 budget is almost $12,000,000. Of their current membership of 44,847, otolaryngologists make up 2,776 (6.19%). The College continues its activity regarding such timely subjects as professional liability, accreditation of graduate medical education programs, cost containment (including a recent article by our treasurer, Loring W. Pratt, on the patient's role in cost containment). Regarding Second Surgical Opinion Programs, the American College of Surgeons is opposed to these mandatory programs, but does not oppose voluntary programs that are well planned and thoughtfully implemented. As this society's representative on the Board of Governors, I would welcome instruction from the membership and the Council as to any matters which they wish me to present to that Board of Governors.

Respectfully submitted,
Gabriel F. Tucker, Jr, MD
Governor, American College of Surgeons

REPORT OF THE ACCOUNTANT

To the Officers and Directors of
American Laryngological Association

The accompanying balance sheets of the general fund and trust funds of the American Laryngological Association as of March 31, 1982, and the related statements of income and retained earnings have been compiled by us. This compilation is limited to presenting, in the form of financial statements, information that is the representation of management.

We have examined and verified the underlying data. The reports are on the cash basis method of accounting, and accordingly, an unqualified opinion cannot be expressed. The method of accounting is consistent with that of prior years.

Emil N. Northup
Certified Public Accountant, PA

April 26, 1982

REPORT OF THE TREASURER
AMERICAN LARYNGOLOGICAL ASSOCIATION

STATEMENT OF ASSETS, LIABILITIES AND FUND BALANCES — MARCH 31, 1982

ASSETS

General Fund:		
Cash (deficit)	$(2,899)	
Trust Fund:		
Current Assets:		
Cash due from General Fund	$ 1,307	
8⅞% Treasury note due 5/30/83	20,060	
11⅞% Treasury note due 8/15/83	14,981	
Certificates of deposit due 4/26/82 - 9/18/82	99,768	
Common stocks	13,980	
Total Assets		$147,197

LIABILITIES

None

FUND BALANCES

General Fund	$(2,899)	
Trust Funds	150,096	
Total Fund Balances		$147,197

See accountant's letter and notes to financial statements.

STATEMENT OF RECEIPTS AND EXPENSES — GENERAL FUND FOR THE FISCAL YEAR ENDED MARCH 31, 1982

Receipts:		
Dues	$13,500	
Initiation fees	500	
Banquet	6,278	
Nonmember attendance	6,100	
Sale of *Transactions*	2,154	
Centennial books	25	
Miscellaneous	46	
Total		$28,603
Disbursements:		
Expenses of annual meeting — 1981 & 1982		
Banquet	3,346	
Programs, inserts and certificates	3,783	
Kanata Conference consultants	6,959	
Miscellaneous	1,221	
Council travel and expense		3,176
Administrative expenses		886
Transactions expense 1980 & 1981		12,112
General expenses:		
Printing, postage and supplies	4,811	
Professional fees	1,155	
Honorarium	2,100	
Contribution	100	
Bond	40	
Total		39,689
Net Income (Loss)		(11,086)
General Fund Balance		
Beginning of year, April 1, 1981		8,187
End of year, March 31, 1982		$(2,899)

See accountant's letter and notes to financial statements.

STATEMENT OF INDIVIDUAL TRUST FUNDS, MARCH 31, 1982

	Fund Balance 4/1/81	*Receipts*			*Disbursements*	*Transfers*	*Fund Balance 3/31/82*
		Total	*Donations*	*Investment Income*			
Daniel C. Baker, Jr, Memorial Fund	$ 29,820	$ 2,274	$ 50	$2,324	$2,703		$ 29,441
Casselberry Fund	13,244	936		936			14,180
Johnston Fund	12,549	888		888			13,437
DeRoaldes Fund	7,502	535		535			8,037
Newcomb Trust Fund	4,925	352		352			5,277
Newcomb Prize Fund	1,149	73		73			1,222
Research Fund	42,596	2,893		2,893		$4,207	49,696
Memorial Fund	28,806	4,207		4,207		(4,207)	28,806
Total	$140,591	$12,158	$ 50	$12,208	$2,703	$	$150,096

See accountant's letter and notes to financial statements.

GENERAL FUND — RESUME

	For the Year Ended March 31,						April 1, 1978, Through March 15,			
	1973	*1974*	*1975*	*1976*	*1977*	*1978*	*1979*	*1980*	*1981*	*1982*
EXPENSES										
Annual meeting	$ 3,899	$ 5,204	$ 4,525	$ 5,664	$ 3,615	$ 6,930	$ 18,391	$ 9,033	$ 8,051	$ 16,195
Council	1,447	1,800	1,360	1,906	2,042	3,348	4,097	3,972	4,163	3,176
Transactions	3,477	2,833	5,124	4,458	4,824	4,124	6,544	5,358	----	12,112
General	940	3,279	3,697	2,373	4,585	5,512	6,550	7,434	6,339	8,206
Totals	9,763	13,116	14,706	14,401	15,066	19,914	35,582	25,797	18,553	39,689
INCOME	12,411	14,723	13,284*	16,752*	16,621*	14,788*	21,426	27,257	23,271	28,603
GAIN (LOSS)	$ 2,648	$ 1,607	$(1,422)	$ 2,351	$ 1,555	$(5,126)	$(14,156)	$ 1,460	$ 4,718	$(11,086)

*Excluding centennial assessments.

See accountant's letter and notes to financial statements.

STATEMENT OF TRUST FUNDS FOR THE YEAR ENDED MARCH 31, 1982

Receipts:		
Interest income (Note 2):		
US Treasury notes and bills	$7,277	
Certificates of deposit — banks	3,768	
Bank interest	339	
		$ 11,384
Dividends on common stocks		774
		12,158
Donation:		
Baker fund	50	
		12,208
Disbursements:		
Baker fund:		
Administrative expenses	505	
Speaker's expenses	2,198	
		2,703
Net Income		9,505
Fund Balance, April 1, 1981		140,591
March 31, 1982		$150,096

*See accountant's letter and notes to financial statements.

FUND BALANCES

	General Fund	*Trust Fund*
MARCH 31,		
1972	$ 4,985	$ 77,374
1973	7,634	79,224
1974	9,240	81,410
1975*	7,817	111,075
1976*	10,168	114,564
1977*	11,723	119,548
1978*	6,597	125,095
MARCH 15, 1979	1,816	130,768
1980	3,469	130,783
1981	8,187	140,591
1982	(2,899)	150,096

*Excluding centennial assessments.

TRUST FUND INVESTMENTS, MARCH 31, 1982

	Cost	*March 31, 1982 High*	*Low*	*Share Value 3/31/82*	*Shares*	*Market Value 3/31/82*
STOCK PORTFOLIO						
Common Stocks						
American Telephone and Telegraph	$10,790	56 3/4	56 1/8	56 1/4	200	$11,250
International Business Machines	1,321	60 5/8	59 5/8	59 3/4	40	2,390
McDonnell-Douglas Corp	1,194	34 3/8	34 1/8	34 1/8	165	5,631
McIntyre Porcupine	675	25 5/8	25 5/8	25 5/8	15	385
	$13,980					$19,656

	March 31, 1981	*March 31, 1982*
Common stocks (at cost)	$13,980	$13,980
Market value	19,137	19,656
Market in excess of cost	5,157	5,676

Dow Jones Industrials — March 31, 1981 ..... 1003.87
March 31, 1982 ..... 822.77

See accountant's letter and notes to financial statements.

NOTES TO FINANCIAL STATEMENTS

1. Accounting Policies

The organization uses the cash basis method of accounting and is a nonprofit entity exempt from Federal and State income taxes.

2. Allocation of Investment Income

Interest on US Treasury Bills and Notes, as well as dividends on common stock are credited as income to the Trust Fund.

Trust Fund income is further allocated to each fund in the ratio the fund bears to the total value of the trust funds at the beginning of the year, except that by action of the Council, January 3, 1976, current income from the Memorial Fund is transferred to the principal and retained earnings of the Research Fund.

Respectfully submitted,
Loring W. Pratt, MD
Treasurer

THE MEMORIAL FUND

and

THE LARYNGOLOGICAL RESEARCH FUND

The Council earnestly requests that Fellows of the Association give consideration to making a special bequest to these important funds, or to become a Benefactor.

MEMORIAL FUND DONORS

Dr. Daniel C. Baker, Jr
Dr. John F. Barnhill
Dr. August L. Beck
Dr. Gordon Berry
Dr. William E. Casselberry
Dr. Cornelius G. Coakley
Dr. Lee Wallace Dean
Dr. Arthur W. deRoaldes
Dr. Fred W. Dixon
Dr. George Fetterolf
Dr. Joseph L. Goodale
Dr. William E. Grove
Dr. Gordon F. Harkness
Dr. Frederick T. Hill
Dr. George E. Hourn
Dr. Samuel Johnston
Dr. James E. Newcomb
Dr. Henry B. Orton
Dr. Lyman G. Richards
Dr. Burt R. Shurly
Dr. Lester T. Sunderland
Dr. H. Marshall Taylor
Dr. Walter H. Theobald
Dr. Francis L. Weille

BENEFACTORS

Mrs. Sally Sample-Aall
Mrs. Daniel C. Baker, Jr
Dr. Edwin N. Broyles
Dr. Louis H. Clerf
Dr. Seymour R. Cohen
Dr. John J. Conley
Dr. John F. Daly
Dr. and Mrs. Francis W. Davison
Dr. Stanton A. Friedberg
Dr. Thomas C. Galloway
Dr. Joseph L. Goldman
Dr. Robert L. Goodale
Dr. Edley H. Jones
Zelda Radow Weintraub Cancer Fund, Inc.
Mr. A. P. Marchessini
Dr. Francis H. McGovern
Dr. Charles M. Norris
Dr. Samuel Salinger
Dr. Sam H. Sanders
Dr. Harry P. Schenck
Dr. William M. Trible
Dr. DeGraaf Woodman

Obverse of the de Roaldes medal

RECIPIENTS OF THE DE ROALDES AWARD

1928 Dr. Chevalier Jackson
1931 Dr. D. Bryson Delavan
1934 Dr. Harris P. Mosher
1937 Dr. Lee Wallace Dean
1943 Dr. Ralph A. Fenton
1949 Dr. George M. Coates
1951 Dr. Arthur W. Proetz
1954 Dr. Louis H. Clerf
1959 Dr. Albert C. Furstenberg
1960 Dr. Dean M. Lierle
1961 Dr. Frederick T. Hill
1966 Dr. Paul H. Holinger
1970 Dr. Francis E. LeJeune
1973 Dr. Lawrence R. Boies
1976 Dr. Anderson E. Hilding
1979 Dr. Joseph H. Ogura
1982 Dr. John J. Conley

RECIPIENTS OF THE CASSELBERRY AWARD

1923 Dr. George Fetterolf and Dr. Herbert Fox
1928 Dr. Ralph A. Fenton and Dr. O. Larsell
1929 Dr. Richard A. Kern and Dr. Harry P. Schenck
1929 Dr. Edward H. Campbell
1931 Dr. Arthur W. Proetz
1934 Dr. Anderson C. Hilding
1936 Dr. Francis E. LeJeune and Dr. Joel J. Pressman
1939 Dr. H. Marshall Taylor and Dr. Brien T. King
1940 Dr. French K. Hansel
1941 Dr. Noah D. Fabricant
1946 Dr. Paul H. Holinger
1949 Dr. Henry B. Orton
1962 Dr. Hans von Leden
1966 Dr. John A. Kirchner and Mr. Barry D. Wyke
1968 Dr. Joseph H. Ogura

RECIPIENTS OF THE NEWCOMB AWARD

1941 Dr. Burt R. Shurly
1942 Dr. Francis R. Packard
1943 Dr. George M. Coates
1944 Dr. Charles J. Imperatori
1947 Dr. Harris P. Mosher
1948 Dr. Gordon Berry
1949 Dr. Gordon B. New
1950 Dr. H. Marshall Taylor
1951 Dr. John D. Kernan
1952 Dr. William J. McNally
1953 Dr. Frederick T. Hill
1954 Dr. Henry B. Orton
1955 Dr. Thomas C. Galloway
1956 Dr. Dean M. Lierle
1957 Dr. Gordon F. Harkness
1958 Dr. Albert C. Furstenberg
1959 Dr. Harry P. Schenck
1960 Dr. Joel J. Pressman
1961 Dr. Chevalier L. Jackson
1962 Dr. Paul H. Holinger
1963 Dr. Francis E. LeJeune
1964 Dr. Fred W. Dixon
1965 Dr. Edwin N. Broyles
1966 Dr. Lyman G. Richards
1967 Dr. Joseph H. Ogura
1968 Dr. Walter P. Work
1969 Dr. John A. Kirchner
1970 Dr. Louis H. Clerf
1971 Dr. Daniel C. Baker, Jr
1972 Dr. Alden H. Miller
1973 Dr. DeGraaf Woodman
1974 Dr. John J. Conley
1975 Dr. Francis W. Davison
1976 Dr. Joseph L. Goldman
1977 Dr. F. Johnson Putney
1978 Dr. John F. Daly
1979 Dr. Charles F. Ferguson
1980 Dr. Charles M. Norris
1981 Dr. Stanton A. Friedberg
1982 Dr. William M. Trible

PRESIDENTIAL ADDRESS

HAROLD G. TABB, MD

It is a pleasure for me, as your president, to open this 103rd annual meeting of the American Laryngological Association. The Laryngological Association is the second oldest society in our specialty, preceded only by the Otological Society. It is the senior society for the head and neck surgeon and has provided direction and leadership in our specialty for over 100 years. I am honored and deeply grateful to serve as your president.

I came into this distinguished society 19 years ago and have served on the council as your treasurer for the past 5 years. Through the years I have been impressed with the people in this society, the quiet dignity which has prevailed, the adherence to tradition, and the preservation of excellence in the scientific programs. I hope we can maintain this heritage in this and in the meetings to follow.

There are problems in otolaryngology as Dr. Daly so eloquently pointed out three years ago in his presidential address. We are wrestling with a name change. We are training two classes of otolaryngologists — the generalist and the superspecialist. We are losing otolaryngologists to other specialties where they seek supposedly more prestigious credentials. We are facing an era of declining surgery available for teaching residents. We are agonizing over subcertification. We are seeing a change in otolaryngology from an organal specialty to a multidisciplined regional specialty. We are seeing more hospital regulations and government intrusion in our specialty with an overall decline in the image of medicine.

These problems are being addressed by ALA members along with others sitting on various boards and councils of our organizations. Progress is being made according to these recent developments. Otolaryngologists from around the country have voted overwhelmingly to change our name to Otolaryngology — Head and Neck Surgery, to better represent the specialty. The Academy and the Council of Otolaryngology have merged into a strong educational and political body for our specialty with a governing board representing all the otolaryngological societies. The American Board of Otolaryngology has increased the period of training in our specialty from four to five years and has broadened the scope of their examination. The Board has also taken a strong position asserting its support of our members performing facial plastic surgery in the field of otolaryngology. The Board is seriously deliberating the question of subcertification, a subject you will hear discussed later in the program by Dr. Reed.

Members of the Laryngological Association are playing a vital role in solving these problems. As these men of honesty, integrity, with intensity of purpose, step forward to assume leadership, I have no doubts that these problems will be solved. Let us move forward as Drs. Conley and Daly have suggested and develop a plan for the future for our specialty.

For our program I have solicited papers from the newer members of our society. We have had a tremendous response, and with the help of the Council, we have developed a program that I hope you will enjoy.

In closing I want to thank the membership for the high privilege of serving as your president. I want to express my gratitude to the Council for their assistance and guidance, and especially to Dr. William Trible, who has made my short term a very pleasant one.

INTRODUCTION OF GUEST OF HONOR, JAMES W. McLAURIN, MD

HAROLD G. TABB, MD, PRESIDENT

My guest of honor for this meeting is James W. McLaurin, whom I have known and admired for many years, and who has greatly influenced my academic career in otolaryngology.

Jim McLaurin grew up in Mississippi, attended Washington and Lee, and graduated from medicine at the University of Arkansas. He received his otolaryngology training at the University of Southern California under Dr. J. McKenzie Brown. Upon completion of his residency he entered private practice in Baton Rouge, Louisiana, with a teaching appointment at LSU Medical School.

In 1949 he was appointed Professor and Chairman of the Department of Otolaryngology at Tulane University School of Medicine, a position he held for the next ten years. The unusual thing about this appointment was that he ran the department from Baton Rouge, 70 miles away. He would arise at 4:00 AM and drive to New Orleans in time to supervise the residents in surgery, administer the affairs in the department at the medical school, and return to Baton Rouge in the afternoon to begin his office practice. This was done three days a week for almost ten years.

During this time he developed a strong academic department at Tulane. He organized the first speech and hearing center in the mid-South, training many of the early audiologists. He developed the first hearing conservation program in the South. His interests were primarily in otology, but he made contributions to the literature both in laryngology and otology. He has served on the council of the Otological Society and was chairman of the trustees of its research fund.

Jim is partially retired now and has sufficient time to pursue his avid sport — bird hunting. He has hunted grouse in Scotland, the red partridge in Spain, and turkeys in South Alabama.

Jim is a shy, unassuming person, who has shown unselfish devotion to teaching in otolaryngology. He has made significant contributions in our specialty. He has given me continued support in my academic career, and I am happy to honor him today. He is just an all-around great guy, and when you know him, you will like him. My guest of honor, James W. McLaurin.

GUEST OF HONOR ADDRESS

JAMES W. McLAURIN, MD

I thank you for the privilege of being your Guest of Honor. I do not have the words to tell you how much I appreciate it, but I am humbly grateful and deeply touched.

What I have to say would probably best be said at a Teachers' Section of the Academy, but knowing that most of you are teachers, I cannot resist the opportunity to tell you my observation of the otolaryngologists who are completing their residencies and beginning practice. They are all excellent surgeons, and I am sure most of them could cut your head off and put it back with good results. Many of them, however, know very little about the practice of medicine.

This is a very stressful world we live in, and they should know that stress causes many ear, nose, and throat complaints. Probably the most common is bruxism with temporomandibular joint symptoms and headache. They should also know that although Americans have access to more and better food than the people in most other countries, many of our patients are on an inadequate or improper diet. This faulty nutrition often results in electrolyte and blood chemistry changes which cause ear, nose, and throat complaints. Moreover, in spite of the popularity of walking, jogging, tennis playing, and other sports today, many older patients do not take any exercise. Lack of exercise can result in a lack of oxygen to cells and tissue and can produce ear, nose and throat symptoms.

We can make a much longer list of conditions that do not require surgery, but my plea to you is to continue to teach residents to be great surgeons and to teach them also to treat the whole patient.

I thank you again for allowing me to be your Guest of Honor. This recognition by my peers I shall always cherish.

SCIENTIFIC SESSIONS*

INTRODUCTION OF DANIEL C. BAKER, JR, MEMORIAL LECTURER GEORGE F. REED, MD

HAROLD G. TABB, MD, PRESIDENT

It is my privilege to introduce the eighth annual Daniel C. Baker, Jr, Memorial Lecturer. We are honored to have a member of our own society present the Baker Lecture today, a man who was a colleague of Dan Baker on the American Board of Otolaryngology and many other societies.

Dr. George Reed is the past-president of the American Board of Otolaryngology and is now executive secretary-treasurer. He is eminently qualified to speak on the subject of subcertification, having served on the Board of the Academy of Otolaryngology as secretary for continuing education and as a representative to the American Board of Medical Specialties. He is a past chairman of the Department of Otolaryngology, and now Dean of the College of Medicine and Vice-President of the Medical Center, State University of New York, Upstate Medical Center, Syracuse, New York.

It is an honor for me to present my good friend, Dr. George Reed, who will deliver the Baker Lecture.

---

*Papers published in the *Annals of Otology, Rhinology & Laryngology* are on pages 16-128. Discussions not previously published are on pages 129-136.

EIGHTH DANIEL C. BAKER, JR, MEMORIAL LECTURE

SUBCERTIFICATION: A DILEMMA FOR OTOLARYNGOLOGY—HEAD AND NECK SURGERY

GEORGE F. REED, MD

SYRACUSE, NEW YORK

The issue of subspecialization and subcertification has been one of great concern for many years and has recently received increased attention, especially in our specialty of Otolaryngology—Head and Neck Surgery. The problem being faced by the various specialties and their boards is not so much that of subspecialization, since this has definitely occurred in most of the specialties and today is an accepted fact. More specifically, the problem is that of subcertification, or some form of recognition of the subspecialist's advanced training, knowledge and expertise. This matter is indeed creating a serious dilemma, not only for Otolaryngology—Head and Neck Surgery but for most of the specialties. On the one hand, the specialists are concerned about fragmentation of the parent specialty while, on the other hand, there is a growing demand for recognition by those individuals who feel that they have acquired special competence in their areas of subspecialization.

My main purpose in this presentation is to express some personal thoughts on the subject of subcertification. Before doing so, however, I would like to review some of the common arguments for and against subcertification.

On the positive side, a number of points can be considered. As in all aspects of medical education, research, and patient care, the ultimate consideration must be that of improved patient care. In this regard, if one accepts the fact that specialization has improved patient care, then certainly subspecialization can be expected to do likewise. If this be the case, such subspecialization should be recognized by some form of subcertification to protect the public interest. It can be well argued that passage of time inevitably produces new knowledge and new technologies in various areas of our presently accepted specialties. It can also be argued therefore that those who concentrate their activities in these fields should have some form of recognition or subcertification by the nationally accepted certifying bodies — namely, the Boards. Another point on the positive side is that, since many fields of subspecialization cross specialty lines, subcertification provides the opportunity for diplomates of one specialty board to compete with the diplomates of competing boards in the delineation of hospital privileges and in the third party reimbursement process. There is also concern that, if subcertification is not provided by the Boards in the American Board system, certification might be provided by other organizations with lesser standards than those presently utilized. This would certainly be to the detriment of the public interest.

Now, what of the arguments against subcertification? It can be argued that increasing subspecialization will increase the cost of medical care. This has generally been the case in the past, wherein specialists usually expect higher fees than generalists. It can be assumed that subspecialization will produce the same phenomenon of increased fees. However, the mere fact of recognition of subspecialities by subcertification should not by itself have any significant impact upon increasing the cost of care by virtue of increased fees.

The cost of care probably would be increased by virtue of the fact that subspecialization, spurred by subcertification, usually results in increased training requirements, increased cost to the institution providing the training and to the physician involved by decreased income during training. Ultimately these costs are passed on to the patient. Another argument frequently given by the presently recognized parent specialties is that of fragmentation with resultant erosion of the status of the parent specialties and their specialty boards. It is felt by many that this could result in a diminution of the status of the individual who possesses certification from the general discipline but does not possess subcertification in the subspecialty area. Indeed, it is this subtraction from the globality of the general or parent discipline which gives rise to the greatest fears of subcertification — that lack of a certificate in a discipline's subspecialty might deny one the privilege of practicing that subdiscipline by restriction of hospital privileges to only those possessing

---

Dr. Reed is currently Secretary-Treasurer of the American Board of Otolaryngology.

Presented at the meeting of the American Laryngological Association, Palm Beach, Florida, May 1-2, 1982.

REPRINTS — George F. Reed, MD, 750 E. Adams Street, Syracuse, NY 13210.

such subcertification. There are also fears that the possession, or lack thereof, of a certificate of special competence might influence the amount of reimbursement by third party payers and also increase the risk of malpractice judgments to those who do not possess the special certificate.

Thus, in reviewing the pros and cons of subcertification, we find many valid reasons favoring some form of certification of special expertise. In contrast, the main fears appear to be those of fragmentation on the part of organized medicine, and those of potential restriction of hospital privileges and the increased threat of malpractice susceptibility on the part of individuals.

Now I would like to exercise the privilege, which is inherent in a lecture of this type, of expressing some of my personal thoughts regarding subcertification. I have given a great deal of thought to this subject over the past few years — frequently with mixed emotions. I now definitely believe that the arguments in favor of subcertification outweigh those against it.

As far as fragmentation is concerned, I really consider this to be a nonproblem. Fragmentation in the specialties has already occurred in the form of subspecialization and certainly this will not be compounded by the recognition of subspecialists by some form of certifying process. I think we must recognize that what we are experiencing at present is merely an extension of that which occurred when the present specialties and Specialty Boards were initiated a number of years ago. We are merely undergoing a further evolution of that specialization process in the form of subspecialization, with the need for accompanying subcertification. We should accept this evolutionary process rather than fight it. We must accept the fact that the need to recognize special knowledge, special training, special expertise, and extra achievements by some form of certification process is pervasive, inexorable, and unavoidable.

At the present time, the 23 Specialty Boards which operate under the umbrella of the American Board of Medical Specialties do issue some 25 special certificates in various subspecialties, either through the mechanism of conjoint boards, subboards, or certificates of special competence. In my opinion, the best mechanism is that of the primary board issuing certificates of special qualifications to individuals who can demonstrate possession of such special qualifications in subspecialty areas within the domain of their primary board. It is time for this process to be expanded. Indeed, the American Boards have a responsibility to recognize special knowledge and expertise if they are to continue to fulfill their role of serving and protecting the public.

OFFICE TELESCOPIC PHOTOGRAPHY OF THE LARYNX

EIJI YANAGISAWA, MD, FACS

NEW HAVEN, CONNECTICUT

After testing many different procedures for photographing the larynx in the office, the author found that telescopic photography is a most effective and reliable method. Four currently available right-angle laryngeal telescopes were reviewed and are discussed with regard to their results, along with the author's method of office telescopic photography.

Accurate photographic documentation of the larynx is of considerable value for teaching, permanent records, proper diagnosis and management of various laryngeal disorders. Yet there is no single reliable method of still photography of the larynx which laryngologists can easily employ at the office.

Ever since the first documentation of the successful office laryngeal photography by Thomas French of Brooklyn, New York, in 1882, many different methods of laryngeal photography have been described. They include 1) indirect laryngoscopic photography,[1-3] 2) direct laryngoscopic photography,[4-7] 3) microscopic photography,[8-15] 4) telescopic photography[16-21] and 5) fiberscopic photography.[22,23]

The purpose of this paper is twofold: first, to review four currently available right-angle laryngeal telescopes of different makes with regard to their results and, second, to present the author's method of office telescopic photography of the larynx which has proven to be satisfactory.

EQUIPMENT

RIGHT-ANGLE (LATERAL) TELESCOPES

Berci-Ward Indirect Laryngopharyngoscope with Hopkins Telescope (8702D, Karl Storz Endoscopy-America, Inc). This endoscope (Fig. 1-a) consists of two parts, a telescope and a light-conducting tube, which can be locked together with a bayonet socket. The telescope contains a series of fixed glass cylinders replacing the interspace between the lenses in the more conventional endoscopes and producing a set of small air-lenses between them. This construction is reported to bring about a wider view angle in relation to the diameter of the optics.[18,19]

The telescope measures 28.3 cm in length and 4.5 mm in diameter. Its front lens diameter is 2.2 mm (Fig. 2A-a). The rectangular outlets, one on each side of the lens, measure 1 mm x 3 mm (Fig. 2B-a)

There are two different sizes of light-conducting tubes, one of a smaller diameter for visual examination and flash photography only, and one of a larger diameter intended for cinephotography but also useful when the available light source is insufficient. The larger light-conducting tube has two connections for the fiber light cables so that either two separate cables or the two distal ends of a Y-shaped cable can be attached. In both tubes the light outlet is shaped into two rectangular areas on each side of the front lens.[19] In this study only the smaller tube (outer diameter 8.5 mm) was used.

The instrument has an antifog airflow system by means of a small air channel made by a groove along the inner aspect of the light-conducting tube and the telescope.

Laryngoscope with Hopkins Telescope (8704D, Karl Storz). This instrument (Fig. 1-b) is quite similar to KS 8702D but has a built-in focusing capability and the entire larynx can be seen within one single viewing field in 4x magnification. One can focus the larynx at different distances like a telephoto lens and can photograph the magnified view of the larynx to fill the entire slide.

The instrument measures 24.4 cm in length and 7.6 mm in outer diameter. Its front lens diameter is 3 mm (Fig. 2A-b). The rectangular light outlet on each side of the lens measures 1 mm x 7 mm (Fig. 2B-b). It also has an antifog device.

Stuckrad Magnifying Laryngoepipharyngoscope (Richard Wolf Medical Instruments Corp). This instrument (Fig. 1-c) consists of a telescope, a light-transmission system and an antifog device, but they cannot be taken apart.[19]

A fiberoptic cable, which also includes an air tube for the antifog device, is fixed to the instrument. Connections for changing the fiberoptic cables (and air tubes) are available. The instrument includes a plastic handle. The telescope has a relatively low weight as it contains groups of lenses in-

---

From the Section of Otolaryngology, Department of Surgery, Yale University School of Medicine, and the Section of Otolaryngology, Department of Surgery, Hospital of St. Raphael, New Haven, Connecticut.

Presented at the meeting of the American Laryngological Association, Palm Beach, Florida, May 1-2, 1982.

REPRINTS — Eiji Yanagisawa, MD, 98 York Street, New Haven, CT 06511.



Fig. 1. Four right-angle laryngeal telescopes. a) Berci-Ward Hopkins telescope (Karl Storz 8702D), b) Hopkins magnifying telescope (Karl Storz 8704D), c) Stuckrad magnifying laryngoepipharyngoscope (Wolf), and d) Nagashima SFT-1 laryngoscope, Note that Berci-Ward telescope is longest while other three are about same length. Also note that Stuckard and Nagashima telescopes have integrated light cable which would prevent loss of light transmission at connection.



Fig. 2. A) Close-up view of tip of each telescope. B) Tips showing light-transmission outlets. a - Hopkins telescope 8702D, b - Hopkins telescope 8704D, c - Stuckrad telescope, and d - Nagashima SFT-1 laryngoscope. Note difference in sizes of lens openings and light-transmission outlets.

stead of glass rods. With the aid of a knob, it is possible to change the relationship of these lenses to each other, which results in a change of magnification and focus of the object under observation. This construction should not be confused with a zoom lens, which can change the angle of view continuously and without influencing the focus,[19] but it does have a zoom lens effect.

The light transmission opens at two rectangular outlets on each side of the front lens of the telescope (Fig. 2A-c, B-c). It measures approximately 1 mm x 8 mm. The length of the telescope is 24.3 cm and its outer diameter is 9-10 mm. The antifog device consists of an air-conducting narrow metal tube, permanently fixed to the instrument and opening immediately behind the front lens.[19]

Laryngoscope (SFT-1, Nagashima Medical Instrument Co, Tokyo). This laryngoscope is a single integrated unit composed of a telescope and a light-transmission system (Fig. 1-d). It measures 24.5 cm in length and 9 mm in outer diameter. The angle of the prism at the tip of the laryngoscope is 70°, providing a right-angled view of the larynx. The rectangular outlets on each side of the lens offer well-balanced illumination of the viewing field (Fig. 2B-d). Each measures approximately 2 mm x 4 mm. The front lens diameter measures 4 mm x 3 mm[22] (Fig. 2A-d).

The telescope is connected to the 100-mm attachment lens on the SLR camera (Fig. 3B) and its fiber-optic light cable to a xenon light source.

Light transmission of the Nagashima laryngoscope was excellent and provided brighter definition of the image than other endoscopes we tried. The reasons for this appeared to be the wide diameter of the telescope, the newer optical lens system it employed, integration of the light cable into the telescope without a connecting joint and a higher number of fibers in the light-transmission system. The laryngoscope requires no additional light cable nor a special photographic sheath.[20] The Nagashima telescope has been found to be very effective for video-recording of laryngeal disorders.[20]

CAMERA

Olympus OM2 SLR camera with a 1-9 focusing screen and autowinder was used (Fig. 3B). For the Nagashima telescope, a Nagashima 100-mm attachment lens was used (Fig. 3B-b). This produced a photographic image 13 mm in diameter on the finished slide. Since the image was rather small for viewing, a 2X teleconverter (Fig. 3B-c) was placed between the 100-mm attachment lens and the camera body to produce a finished image size of 28 mm in diameter. For the Hopkins and Stuckrad telescopes, a 100-mm Zuiko lens and the quick-connect camera adapter (Fig. 3B-a) were used. Ektachrome ASA 400 color film was chosen after trying many different films.

LIGHT SOURCES

Xenon Cold Light Fountain (487C, Karl Storz). This xenon illuminator (Fig. 4), which produces approximately 6000 K ("instant sunlight"), 300 W, was used for all four telescopes with special adapters.

Dual Mode Flash and Examining Light System (maximum output 100 W-seconds with three-power steps 110/240 V AC; Karl Storz, KSFG). This light source was used for Hopkins telescopes only because the Y-shaped light cable for the dual flash and examining light system was not available for Nagashima and Stuckrad telescopes with integrated light cables.

Fiber Light Flash Generator (proximal type, 5005, R. Wolf, WFG). This fiber light projector

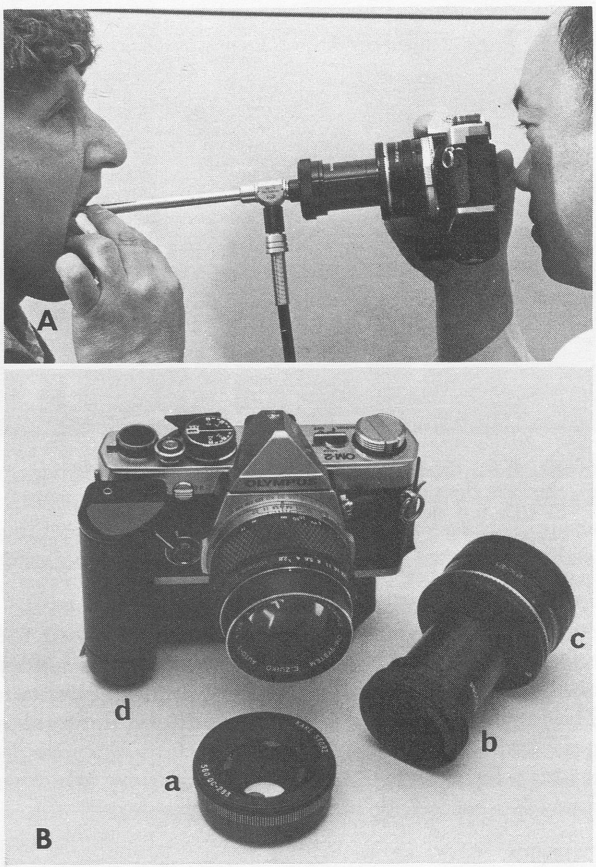

Fig. 3. Still telescopic photography. A) Nagashima telescope is connected to attachment lens for SLR camera. Examiner holds camera in one hand and inserts scope into mouth while holding patient's tongue with other hand. Larynx is centered on camera screen and picture is taken. B) Olympus OM2 SLR camera with autowinder, 1-9 focusing screen (not shown) and 100-mm Zuiko lens. a - Karl Storz quick-connect camera adapter, b - Nagashima 100-mm attachment lens, c - Vivitar 2X teleconverter, d - Autowinder.

and photographic light source combined in one unit was used for all four telescopes. The system of transmitting the light for observation as well as the electronic flash through the one cable makes it possible to take photographs with the small telescopes as well. The second light outlet permits simultaneous lighting of another instrument. Both diagnostic lights have a variable intensity control. The proximal flash has a 3-stage intensity control for photographic applications.

METHOD

The Olympus OM2 camera equipped with a 1-9 focusing screen, 100-mm Zuiko lens, automatic winder and Ektachrome ASA 400 color film is set at automatic mode with the aperture wide open (f 2.8) and the lens distance at infinity.

The patient and examiner sit facing each other. The soft palate and the posterior half of the tongue are topically anesthetized with 2% tetracaine hydrochloride (Pontocaine) solution. The telescope is connected to the camera via the adapter (the quick-connect adapter for KS 8702D, KS 8704D and Stuckrad telescopes and the Nagashima 100-mm attachment lens for the Nagashima telescope).

Fig. 4. Xenon cold light fountain (Karl Storz 487C).

The fiberoptic light cable of the telescope is connected to the xenon illuminator. The tip of the telescope is dipped in warm water and dried to prevent fogging of the lens during the photography. The xenon illuminator is turned on and set in the high filming mode (22A).

The examiner holds the camera in one hand and inserts the telescope into the mouth while holding the patient's tongue with the other hand. When the laryngeal image is viewed and centered on the focusing screen, a series of photographs of the larynx both on phonation and at rest are taken in rapid succession using the autowinder of the camera.

To find out if there are any differences between those pictures taken with the xenon light source and those taken with the electronic flash, laryngeal pictures were also taken using 1) the Karl Storz dual mode flash generator 558, and 2) the Wolf fiber light flash generator.

RESULTS

More than 1000 laryngeal photographs were taken using four different telescopes and three different light sources. Representative pictures of various laryngeal conditions taken with different methods are shown in Figure 5. Ektachrome ASA 400 color film was used for all the pictures shown.

The Berci-Ward Hopkins 8702D laryngoscope (Karl Storz) was very easy to use. The image was in focus from 4.5 cm to infinity. With the xenon illuminator at 22A, pictures were in focus in most cases. The final picture was 2.6 mm in diameter and ready for projection. Approximately 80% of the pictures taken were of satisfactory quality.

The Karl Storz Hopkins 8704D laryngoscope was difficult to focus during photography and required a great deal of cooperation on the part of the patients and skill on the part of the examiner. Since the operator had to hold the camera with one hand and manipulate the focusing knob of the telescope with the other hand, it was necessary for the patient to hold the tongue him- or herself. However, when adequately taken, picture quality was excellent and the enlarged view of the larynx filled the entire frame of the slide. Satisfactory results were obtained in approximately 40% of pictures taken.

The Stuckrad laryngoscope (Wolf) was also difficult to focus and required skill and practice on the part of the examiner and cooperation on the part of the patient. It was possible to change the magnification during examination and a detailed excellent view of the larynx could be obtained. The picture filled the entire frame of the slide. Satisfactory

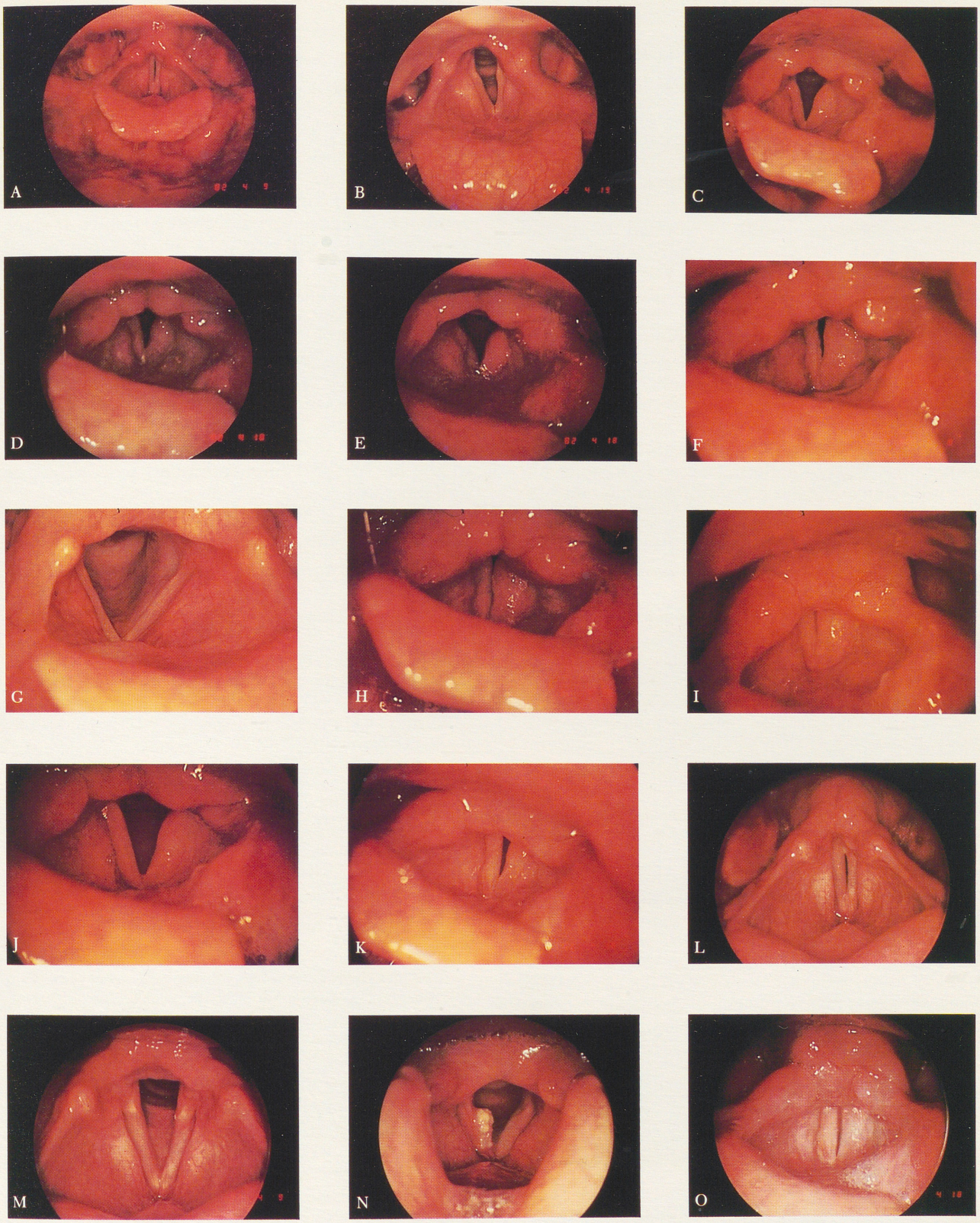

Fig. 5. Photographs of various laryngeal conditions taken with four different telescopes and three different light sources. A) Normal larynx on phonation (KS 8702D, Xenon f 2.8). B) Normal larynx on respiration (KS 8702D, Xenon f 2.8). C) Cancer of larynx after radiotherapy (KS 8702D, Xenon f 2.8). D) Cancer of larynx after radiotherapy (KS 8702D, KSFG f 2.8). E) Cancer of larynx after radiotherapy (KS 8702D, WFG f 2.8). F) Cancer of larynx after radiotherapy (KS 8704D, Xenon f 2.8). G) Normal larynx at rest (KS 8704D, KSFG f 2.8). H) Cancer of larynx after radiotherapy (KS 8704D, WFG f 2.8). I) Cancer of larynx after radiotherapy on phonation (Stuckrad, Xenon f 2.8). J) Cancer of larynx after radiotherapy on respiration (Stuckrad, Xenon f 2.8). K) Cancer of larynx after radiotherapy (Stuckrad, WFG f 2.8). L) Normal larynx on phonation (Nagashima, Xenon). M) Normal larynx on respiration (Nagashima, Xenon). N) Cancer of larynx (Nagashima, Xenon). O) Cancer of larynx after radiotherapy (Nagashima, WFG).

results were obtained in approximately 40% of the pictures taken.

The Nagashima SFT-1 laryngoscope was the easiest laryngoscope to manipulate because of its fixed focus. The size of the picture on a final slide when the 2X teleconverter was used was 28 mm in diameter. To visualize the anterior commissure, the tip of the laryngoscope had to be inserted deeply and tilted toward the examiner. Satisfactory results were obtained in approximately 80% of pictures taken.

When the flash generator — either Karl Storz or Wolf — was used, sharpness and color quality somewhat improved. However, recycling time was slow (4-5 seconds) and it took a much longer time to photograph the larynx. Repeated reinsertion of the telescope was necessary to take an adequate number of pictures. Use of the flash generator did not significantly change the success rate of each method.

CONCLUSIONS

1. The Berci-Ward 8702D telescope (Karl Storz) was the most satisfactory of those telescopes tested by the author when used with the xenon illuminator and Ektachrome ASA 400 film. It is recommended for general still photography of the larynx in the office.
2. The Nagashima SFT-1 telescope was the easiest to use and gave very satisfactory results. It is recommended for still and video photography of the larynx because of its excellent light transmission.
3. The Karl Storz 8704D telescope and the Stuckrad were difficult to use for photography, but were very useful for obtaining detailed enlarged views of the larynx. They are recommended for those otolaryngologists who are photographically oriented.
4. Use of the Olympus OM2 camera with a 1-9 focusing screen and automatic winder and xenon illuminator will make office telescopic photography of the larynx less complicated and more effective and pleasant.

REFERENCES

1. French TR. On photographing the larynx. Trans Am Laryngol Assn 1882; 4:32-5.

2. French TR. On a perfected method of photographing the larynx. NY Med J 1884; 4:655-6.

3. Padovan IF, Christman NT, Hamilton LH, Darling RJ. Indirect microlaryngoscopy. Laryngoscope 1973; 83:2035-41.

4. Holinger PA. Photography of the larynx, trachea, bronchi and esophagus. Trans Am Acad Ophthalmol Otolaryngol 1942; 46: 153-6.

5. Ferguson GB, Crowder WJ. A simple method of laryngeal and other cavity photography. Arch Otolaryngol 1970; 92:201-3.

6. Rosnagle R, Smith HW. Hand-held fundus camera for endoscopic photography. Trans Am Acad Ophthalmol Otolaryngol 1972; 76:1024-5.

7. Holinger PA, Brubaker JD, Brubaker JE. Open tube, proximal illumination mirror and direct laryngeal photography. Can J Otolaryngol 1975; 4:781-5.

8. Kleinsasser O. Microlaryngoscopy and endolaryngeal microsurgery. Philadelphia: WB Saunders Co, 1968.

9. Tardy ME, Tenta LT. Laryngeal photography and television. Otolaryngol Clin North Am 1970; 3:483-92.

10. Jako GJ, Strong S. Laryngeal photography. Arch Otolaryngol 1972; 96:268-71.

11. Alberti PW. Still photography of the larynx — an overview. Can J Otolaryngol 1975; 4:759-65.

12. Olofsson J, Ohlsson T. Techniques in microlaryngoscopic photography. Can J Otolaryngol 1975; 4:770-80.

13. Strong MS. Laryngeal photography. Can J Otolaryngol 1975; 4:766-9.

14. Hirano M. Phonosurgery, basic and clinical investigations. Otologia (Fukuoka) 1975; 21 Suppl 1:239-440.

15. Yanagisawa E, Eibling DE, Suzuki M. A simple method of laryngeal photography through the operating microscope. "Macrolens technique". Ann Otol Rhinol Laryngol 1980; 89: 547-50.

16. Gould WJ. The Gould laryngoscope. Trans Am Acad Ophthalmol Otolaryngol 1973; 77:139-41.

17. Ward PH, Berci G, Calcaterra TC. Advances in endoscopic examination of the respiratory system. Ann Otol Rhinol Laryngol 1974; 83:754-60.

18. Berci G, Calcaterra T, Ward PH. Advances in endoscopic techniques for examination of the larynx and nasopharynx. Can J Otolaryngol 1975; 4:786-92.

19. Hahn C, Kitzing P. Indirect endoscopic photography of the larynx — a comparison between two newly constructed laryngoscopes. J Audio V Media Med 1978; 1:121-30.

20. Yanagisawa E, Casuccio JR, Suzuki M. Video laryngoscopy using a rigid telescope and video home system (VHS) color camera. Ann Otol Rhinol Laryngol 1981; 90:346-50.

21. Saito S, Isogai Y, Fukuda H, et al. A newly developed curved laryngoscope. J Jpn Bronchoesophagol Soc 1981; 32:328-31.

22. Sawashima M, Hirose H. New laryngoscopic technique by use of fiber optics. J Acoust Soc Am 1968; 43:168-9.

23. Brewer DW, McCall G. Visible laryngeal changes during voice study. Ann Otol Rhinol Laryngol 1974; 83:423-7.

LARYNGEAL SARCOIDOSIS
REPORT OF 13 PATIENTS

H. BRYAN NEEL III, MD, PHD THOMAS J. MCDONALD, MD

ROCHESTER, MINNESOTA

Of 220 patients with sarcoidosis of the head and neck region, representing 9% of 2,319 patients with sarcoidosis seen at the Mayo Clinic from 1950 through 1981, we identified 13 who had laryngeal sarcoidosis. Edematous, pale, diffuse enlargement of the supraglottic structures was the most common laryngeal manifestation. The diagnosis is made by a group of clinical, radiologic, and laboratory findings, confirmed by the finding of noncaseating granuloma on biopsy. Sarcoidosis is a disease with frequent remissions and exacerbations and generally burns itself out; glucocorticoids may be indicated in particularly severe disease. When laryngeal sarcoidosis is suspected, the laryngologist should collaborate with other clinicians in a thorough evaluation of the patient.

Sarcoidosis is a chronic idiopathic granulomatous disease which may involve one or more of any number of organs, including those in the head and neck region.[1-6] Symptoms are generally mild in spite of extensive tissue involvement. The disease tends to progress slowly and is characterized by many relapses and remissions; ultimately, after years, the disease "burns out."

Epidemiologic studies have given no clues about the cause or pathogenesis of the disease, but it appears to be a host response to an unknown stimulus, possibly an infectious agent; an autoimmune disease or one of abnormal immunoregulation; or a response to chemical factors, such as zirconium and beryllium.[5,7] Many patients are not able to develop and maintain delayed-type hypersensitivity, have reduced lymphocyte blastogenesis, possess circulating immune complexes, and have a variety of other immunologic perturbations. The immunologic perturbations may be prerequisites to the development of the disease, but they are more likely a secondary rather than a primary phenomenon. In short, cell-mediated immunity is diminished and humoral immunity is heightened.

Microscopically, the granulomas are composed principally of epithelioid cells; occasionally there are a few giant cells and varying numbers of lymphocytes and plasma cells. There is no necrosis, that is, no caseation. The microscopic morphology becomes more fibrous and more hyalinization is seen in the late stages of the disease. The diagnosis is established by the exclusion of a variety of other disorders. Special staining techniques are required to exclude the presence of tubercle bacilli and fungi, and tissue should be cultured to substantiate this. The diagnosis is finally established by the consolidation of information derived from a thorough history, a physical examination, various laboratory tests, and interpretation of microscopic and culture examinations of tissue.

MATERIALS AND METHODS

From 1950 through 1981, 2,319 patients with sarcoidosis were seen at the Mayo Clinic. In this group 220 patients (9%) had clinically apparent manifestations in a variety of sites in the head and neck region. The anatomic locations of disease in the head and neck (and the approximate incidence in percent) were as follows: eye/lacrimal glands (40%), skin (26%), nose (13%), central or peripheral nervous system (6%), larynx (6%), salivary glands (4%), neck nodes (4%), and middle ear (1%). Thirteen patients with laryngeal involvement were identified, and one of these patients was seen before 1950. Most of the patients were from the north central part of the United States. There were ten females and three males. Their ages ranged from 12 to 67 years, with a mean of 40 years and a median of 47 years. Detailed case reports of 6 of these 13 patients were published previously.[8]

FINDINGS

Symptoms and Signs. Some combination of hoarseness, dysphagia, and dyspnea was quite common (table). The symptoms were as follows: hoarseness (9 patients), dysphagia (7), dyspnea (7), stridor (1), weak voice (1), sensation of a lump in the throat (1), and mild pain in the throat (1). In one patient, no symptoms related to the head and neck were noted, and sarcoidosis in the larynx was an incidental finding at bronchoscopy.

Appearance and Location in the Larynx. Sarcoidosis was found only in the supraglottic larynx in 11 patients and only in the subglottic larynx in 2. The true vocal cords were normally mobile in all except one patient, who had unilateral vocal cord paralysis following thyroid surgery several years before the diagnosis of sarcoidosis of the larynx was made.

The appearance of the larynx was strikingly characteristic in all of the patients with supraglottic involvement. The supraglottic larynx was chronically edematous and pale pink, and there was diffuse en-

From the Department of Otorhinolaryngology, Mayo Clinic and Mayo Foundation, Rochester, Minnesota.

Presented at the meeting of the American Laryngological Association, Palm Beach, Florida, May 1-2, 1982.

REPRINTS — H. B. Neel III, MD, Mayo Clinic, Rochester, MN 55905.

SUMMARY OF FINDINGS IN PATIENTS WITH LARYNGEAL SARCOIDOSIS (N = 13)

Age	Sex	Laryngeal Disease* Symptoms	Site	Clinical or Microscopic Evidence of Disease in Other Sites	Sequential Treatment and Response	Years Observ.
20	F	Hoarseness Dyspnea	Supraglottic	Migratory polyarthritis, relapsing fever, erythema nodosum	Tracheotomy for 3 yr; spontaneous remission and decannulation	1941-62
33	F	Hoarseness Dyspnea Dysphagia	Supraglottic	Recurring erythema nodosum; angioedema of hands, feet, and lips; edematous, granular posterior pharyngeal wall, biopsy positive; central nervous system; peripheral neuritis of upper extremity	Tracheotomy for 2 yr; spontaneous remission and decannulation. Tracheotomy, removal of polypoid tissue, irradiation; decannulation 5 yr later and normal larynx. Tracheotomy for 3 mo for polypoid swelling; spontaneous remission and decannulation	1921-45
43	F	Dyspnea Hoarseness Dysphagia	Supraglottic	None (transient Horner's syndrome of questionable significance)	Injection of hydrocortisone acetate into larynx, tracheotomy; normal 1 mo later and decannulation	1955-63
47	F	Dysphagia Dyspnea	Supraglottic	None	None	1958-60
50*	F	Dysphagia	Supraglottic	Skin rash of arms, biopsy positive; nasal crusting and obstruction; hilar nodes; extensive pulmonary fibrosis	Systemic ACTH; some improvement. Subsequently died from complications of pulmonary sarcoidosis (no autopsy)	1944-56
56	M	Dyspnea Stridor	Subglottic	None	Tracheotomy. Laryngofissure — excision of thickened subglottic tissue, skin grafting; excellent airway and decannulation. Died from cancer of kidney	1955-58
12	M	Hoarseness Nocturnal dyspnea	Supraglottic	Relapsing fever; malaise; nasal obstruction; arthritis; splenomegaly; right sudden (cochlear) hearing loss; facial skin rash, biopsy positive; pale edema of uvula, pharyngeal pillars, and posterior pharyngeal wall	No change in larynx. Prednisone given in 1975 and larynx cleared	1966-75
39	F	Hoarseness	Supraglottic	None	Oral prednisone intermittently; improvement. Injection of Kenalog into larynx 1981; further improvement	1980-81
19	M	Hoarseness Dysphagia	Supraglottic	None	Tracheotomy for more edema after biopsies. Hydrocortisone acetate (x1) and Depo-Medrol (x6) injected into larynx; no change	1974-77
67	F	Hoarseness Sensation of lump and mild pain in throat	Supraglottic	None	Depo-Medrol injected into larynx; no change	1961-66
54	F	Hoarseness	Subglottic	Cough, relapsing fever, hilar nodes, and lung parenchyma; mediastinoscopy positive	Prednisone; no effect on larynx	1974-82
47*	F	None	Supraglottic	Relapsing fever; bloody rhinorrhea and septal perforation, nasal biopsy positive; marked pale thickening of mucosa of trachea and throughout bronchi, biopsy positive	Prednisone; no change. Irradiation of toe and trachea; marked improvement	1963-73
38	F	Hoarseness Weak voice Dyspnea Dysphagia	Supraglottic	None (scalene node biopsy positive, but chest roentgenograms negative)	Tracheotomy. Hydrocortisone acetate injected into larynx; shrinkage and decannulation	1963-76

*All patients had laryngeal biopsies except the two indicated by asterisks.

largement of the supraglottic structures (figure). This appearance is pathognomonic of supraglottic laryngeal sarcoidosis. The rim of the epiglottis was full and rounded, and it had a turban-like thickening. There occasionally were either reddened or granular areas, and this was the characteristic appearance of the subglottic region in the patients with subglottic laryngeal sarcoidosis. It should be emphasized that the true cords appeared normal in all cases except one; and indeed, even in that patient, the upper edges of the true cords were normal, but there was reddened thickening of the anterior-inferior portions of the true vocal cords, reflecting more extensive subglottic disease. This did not impair vocal cord mobility but caused severe hoarseness.

We want to emphasize too that the edematous, pale, diffuse enlargement of the supraglottic structures was the most common laryngeal manifestation of sarcoidosis, and, in fact, is considered pathogno-

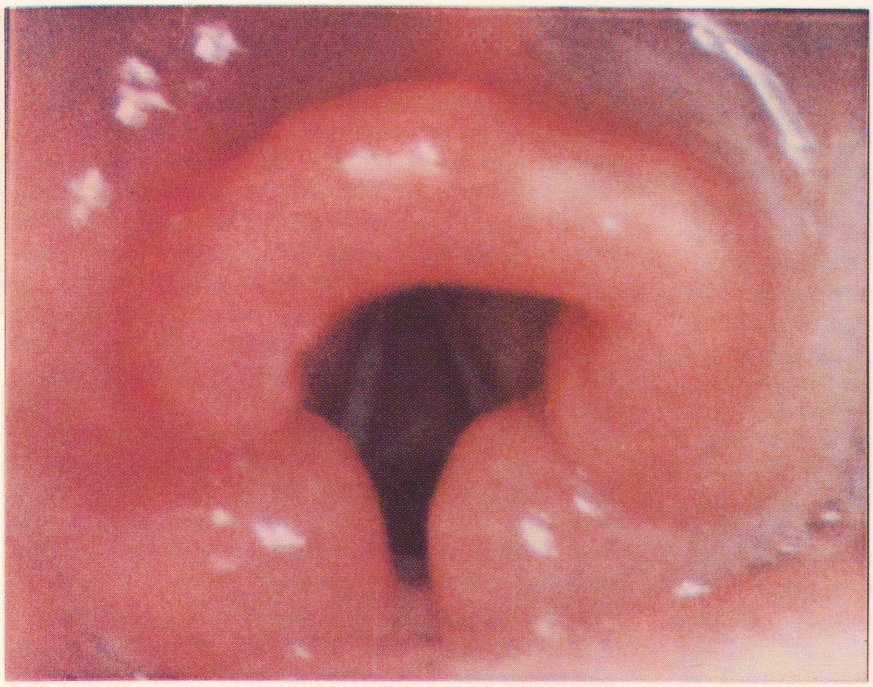

Typical appearance of laryngeal sarcoidosis. Supraglottic structures are edematous, pale pink, and diffusely enlarged, epiglottis is turban-like, and true cords are normal.

monic of sarcoidosis of the larynx (figure).

Biopsy. Biopsy of the larynx was carried out in 11 of the patients, and noncaseating granulomas were identified in all. Two patients who did not have laryngeal biopsies had the typical supraglottic appearance found in all of the patients with supraglottic sarcoidosis. One of these patients had a skin rash on the arms, and biopsy showed noncaseating granulomas. This patient also had nasal crusting and obstruction, the typical hilar nodes seen in sarcoidosis, and pulmonary fibrosis. The other patient had relapsing fever, bloody rhinorrhea, a septal perforation, a nasal biopsy that contained noncaseating granulomas, and marked, pale thickening of the mucosa of the trachea and bronchi, which also contained noncaseating granulomas. The diagnosis of systemic sarcoidosis was secure in both of these patients.

Several of the patients had biopsies of other organs, the results of which are described in the table.

Isolated Laryngeal Sarcoidosis. Of 6 patients with no obvious evidence of systemic sarcoidosis, 5 had the typical supraglottic appearance of sarcoidosis and biopsies that showed noncaseating granulomas; 1 patient had subglottic involvement and biopsies that revealed noncaseating granulomas. One other patient had no clinical evidence of systemic sarcoidosis, but a random scalene node biopsy showed noncaseating granulomas, although the chest roentgenograms were negative.

We feel comfortable with the diagnosis of isolated laryngeal sarcoidosis if the patient has had a careful history, thorough physical examination, laboratory tests, roentgenograms, biopsies of the larynx which show noncaseating granulomas in combination with the typical laryngeal appearance, and a long period of observation.

Laryngeal Sarcoidosis and Systemic Disease. In seven patients there were definite systemic manifestations as well as evidence of laryngeal sarcoidosis. These manifestations were skin involvement (5 patients), relapsing fever (4), migratory polyarthritis (2), pale edema and thickening of pharyngeal mucosa (2), granular nasal membranes and crusting (2), and central nervous system involvement (1). Three of these patients also had evidence of lung changes on roentgenograms, and two had obvious hilar nodes.

Duration of Observation. Six patients were observed for 9 to 24 years, three for 5 to 8 years, two for 3 to 4 years, and one for 1 to 2 years.

Sequential Treatment and Response. An outline of the sequence of treatment and response is shown in the table. Four patients had systemic cortisone; 4 patients had laryngeal injections of cortisone; 1 patient had both systemic and laryngeal cortisone; 1 patient had a laryngofissure, excision of the sarcoid tissue, and subglottic skin grafting; 1 patient had external radiation; and 2 patients had no treatment at all.

Tracheotomies for airway obstruction were necessary in six patients. Five patients had one tracheotomy, and one patient had three tracheotomies because of intermittent exacerbations of the laryngeal disease.

DISCUSSION

The diagnosis of sarcoidosis is made by assembling a constellation of clinical, radiologic, and laboratory findings (DeRemee RA, Zinsmeister AR, unpublished material).[5,7-10] The diagnosis is confirmed by the finding of noncaseating granulomas

in biopsy material. Antigen of reliable consistency for Kveim testing is difficult to procure, and so this test is of more theoretic than practical importance.[5]

About 9% of our patients with sarcoidosis had fairly striking clinical manifestations in the head and neck region. Because the manifestations of the disease are so protean, patients initially seek consultation from a variety of specialists; however, a large proportion of the presenting manifestations can involve structures in the head and neck region. The generalist may see the patient because of dyspnea, lymphadenopathy, or rash; the neurologist, because of nerve palsy (eg, VII), encephalopathy, seizures, or meningitis; the ophthalmologist, because of red eye (uveitis), dry eye (lacrimal), or blurred vision; the dermatologist, because of erythema nodosum, rash, or lesions in scars; and the otorhinolaryngologist, because of hoarseness, dysphagia, or dyspnea. When the diagnosis of sarcoidosis is suspected, the laryngologist should collaborate with other clinicians to do a thorough physical examination as well as pulmonary, ocular, and dermatologic evaluations. Basic laboratory studies usually consist of serum calcium levels, protein electrophoresis, electrocardiogram, chest roentgenogram, pulmonary function tests, serum angiotensin-converting enzyme determination, and perhaps in some instances gallium scans. Levels of angiotensin-converting enzyme often parallel the clinical course, and increases often antedate exacerbations of the disease.[9] The diagnosis is confirmed by biopsies of one or more diseased organs, namely, skin, eyes, lymph nodes, lung, salivary glands, larynx, liver, or bone marrow, and by culture of the biopsy material to exclude the presence of tuberculosis or fungal infections.

When the laryngologist is confronted with a patient who has typical laryngeal appearance of sarcoidosis, he or she must rule out lymphoma and other malignant neoplasms, cartilaginous tumors, benign myomatous polypoid thickening of the larynx due to smoking, and specific infections such as tuberculosis, syphilis, histoplasmosis, coccidioidomycosis, blastomycosis, and actinomycosis, along with such entities as amyloidosis and lipoid proteinosis. Myxedema, previous irradiation to the neck, and a variety of systemic connective tissue diseases should also be excluded. In the very rare patient with subglottic sarcoidosis, the causes of nontraumatic nonneoplastic subglottic stenosis should be excluded, namely, relapsing polychondritis, amyloidosis, and Wegener's granulomatosis.[11]

Laryngeal sarcoidosis can occur as an isolated phenomenon. As stated by Devine,[8] "a careful history may reveal evidence that the disease is or has been systemic, has involved other organs in the past, may do so in the future, and often requires long-term follow-up to reveal its true, chronic relapsing systemic nature." Gallium-67 citrate scans may help define clinically inapparent granulomatous inflammation in other organs, such as the lacrimal and salivary glands.[12]

It is difficult to recommend any specific treatment. The indications for the use of systemic glucocorticoids are controversial, and their effects are difficult to assess because, by nature, sarcoidosis is a disease with frequent spontaneous remissions and exacerbations. In general, systemic glucocorticoids are recommended for the treatment of active ocular disease, persistent hypercalcemia and nephrocalcinosis, central nervous system disease, myocardial involvement, chronic skin lesions, progressive pulmonary disease, and certainly impending laryngeal obstruction (DeRemee RA, Zinsmeister AR, unpublished material).[5,7,10] In this series of patients, cortisone was injected into the larynx on one or more occasions in 4 patients and led to improvement of the appearance of the larynx in 2 and no change in 2 others. In one patient, subglottic skin grafting led to a favorable outcome and an excellent airway. A recent report described a successful outcome after supraglottic laryngectomy for supraglottic sarcoidosis in one patient, who has remained free of symptoms for 20 months after surgery.[13]

REFERENCES

1. Weisman RA, Canalis RF, Powell WJ. Laryngeal sarcoidosis with airway obstruction. Ann Otol Rhinol Laryngol 1980; 89:58-61.

2. Weiss JA. Sarcoidosis in otolaryngology: report of eleven cases. Evaluation of blind biopsy as a diagnostic aid. Laryngoscope 1960; 70:1351-98.

3. Carasso B. Sarcoidosis of the larynx causing airway obstruction. Chest 1974; 65:693-5.

4. Miglets AW, Viall JH, Kataria YP. Sarcoidosis of the head and neck. Laryngoscope 1977; 87:2038-48.

5. Hanno R, Callen JP. Sarcoidosis: a disorder with prominent cutaneous features and their interrelationship with systemic disease. Med Clin North Am Sept 1980; 64:847-66.

6. Trible WM. Sarcoidosis of the larynx. Arch Otolaryngol 1958; 68:382-3.

7. Mitchell DN, Scadding JG. Sarcoidosis. Am Rev Respir Dis 1974; 110:774-802.

8. Devine KD. Sarcoidosis and sarcoidosis of the larynx. Laryngoscope 1965; 75:533-69.

9. DeRemee RA, Rohrbach MS. Techniques in the evaluation of sarcoidosis. Semin Respir Med 1981; 3:54-6.

10. Bower JS, Belen JE, Weg JG, Dantzker DR. Manifestations and treatment of laryngeal sarcoidosis. Am Rev Respir Dis 1980; 122:325-32.

11. Djalilian M, McDonald TJ, Devine KD, Weiland LH. Nontraumatic, nonneoplastic subglottic stenosis. Ann Otol Rhinol Laryngol 1975; 84:757-63.

12. Lauver JW, Gooneratne NS. Lacrimal, parotid and mediastinal uptake of gallium 67 in sarcoidosis. Br J Radiol 1979; 52:582-4.

13. Haar JG, Chaudhry AP, Kaplan HM, Milley PS. Granulomatous laryngitis of unknown etiology. Laryngoscope 1980; 90: 1225-9.

LARYNGOTRACHEAL INVASION BY THYROID CARCINOMA

MICHAEL FRIEDMAN, MD
VICKI K. SHELTON, MD
EMANUEL M. SKOLNIK, MD
FREDERICK G. BERLINGER, MD
MOHAMMAD ARAB, MD
CHICAGO, ILLINOIS

Laryngotracheal invasion by well-differentiated thyroid carcinoma is an uncommon occurrence. Recommendations for therapy have primarily included total laryngectomy or shaving of the tumor from laryngeal or tracheal cartilages. Clear guidelines have not been established for the applicability of partial laryngeal resections. In a retrospective analysis of patients with thyroid carcinoma, 13 patients had airway invasion. Of the five patients with laryngeal involvement, three were treated by a partial laryngeal resection. An experimental study was undertaken to determine more precisely the amount of cricoid cartilage which could be resected without reconstruction. Varying amounts of cricoid cartilage were resected. The results indicate that 25% of the cricoid cartilage may be resected without appreciable airway narrowing. On the basis of the retrospective analysis and experimental study, we feel a partial laryngeal resection is possible in most cases of airway invasion by thyroid carcinoma.

INTRODUCTION

Laryngotracheal invasion by well-differentiated thyroid carcinoma is an uncommon occurrence. Reports in the literature vary from 1% to approximately 13%.[1-5] However, of those patients who eventually succumb to thyroid carcinoma, local recurrence is the most common postmortem finding.[6] Residual tumor involving either the laryngeal or tracheal cartilages results in a high incidence of local recurrence and potential for airway invasion.[7]

Surgical management of patients with thyroid cancer invading the airway has primarily been total laryngectomy. Clark et al,[8] in an analysis of 218 patients, noted that laryngectomy had been required in 5. He felt that if the larynx or trachea were invaded, these structures should be removed. Schindel[4] performed a total laryngectomy in 8 of 225 patients with thyroid carcinoma. Djalilian et al,[2] in a review of 2000 cases, found seven patients had undergone a total laryngectomy while two other patients underwent a partial laryngeal resection. Lawson et al,[9] on the other hand, reported on 6 patients with airway invasion, 5 of whom had local control of their disease with conservation surgery. It was his feeling that if the lesion was surgically amenable to a conservation procedure, this should be performed.

Although partial laryngeal resections for patients with thyroid carcinoma invading the larynx have been used successfully, clear guidelines have not been established. The indications for partial laryngectomy, both with intraluminal invasion as well as minimal cartilage destruction, have not been elucidated. Through a retrospective study of thyroid carcinoma treated at the University of Illinois and affiliated hospitals and an experimental animal study, an attempt is made to clarify the criteria for partial laryngeal resection.

RETROSPECTIVE STUDY

A total of 190 patients with thyroid carcinoma were treated at the University of Illinois and affiliated hospitals between 1950 and 1980. Thirteen patients with well-differentiated tumors had airway invasion, an incidence of 6.8%. Five of these patients had extension of the thyroid neoplasm into the larynx or subglottic space, while the remainder had varying degrees of tracheal invasion.

Surgical therapy used in treating these five patients included one total laryngectomy and three partial laryngectomies. One patient, whose lesion was thought to be amenable to a partial laryngeal resection, refused surgery. Patients with tracheal invasion were treated with various procedures (Table 1). One patient's tumor was deemed unresectable due to massive tracheal, mediastinal, and esophageal invasion and was treated with radiation therapy. Two patients required anterior resection of five and six tracheal rings. These tracheal defects were reconstructed with bilateral sternocleidomastoid flaps. A tracheostomy, performed at the lower margin of the reconstruction, was removed in less than two weeks in both patients. Neither patient developed notable tracheal stenosis over extended follow-up periods (16 and 18 years).

Of these 13 patients, 8 are alive with no evidence of disease; 5 have either died or are alive with disease present (Table 2). Although a 15-year follow-up period is not available for all 13 patients with

From the Departments of Otolaryngology-Head and Neck Surgery (Friedman, Shelton, Skolnik and Arab) and Medicine (Berlinger), University of Illinois College of Medicine and University of Illinois Hospital, and the Departments of Otolaryngology (Friedman) and Medicine (Berlinger), Illinois Masonic Medical Center, Chicago.

Presented at the meeting of the American Laryngological Association, Palm Beach, Florida, May 1-2, 1982.

REPRINTS — Michael Friedman, MD, Department of Otolaryngology-Head and Neck Surgery, 1855 W. Taylor St., Chicago, IL 60612.

TABLE 1. TREATMENT OF TRACHEAL INVASION

Treatment	*No. Patients*
Window resection	3
Resection with reconstruction	3
Tracheal resection, partial esophagectomy	1
Radiation*	1

*Massive tracheal, mediastinal, esophageal invasion.

airway invasion, it is apparent that the type of surgical procedure performed had a marked effect on the survival rate. In those patients where a wide excision of tumor was accomplished, survival was increased. Inadequate surgical resection in our series resulted in uncontrolled disease in 100% of patients.

CASE REPORTS

Case 1. A 63-year-old male had a 1.5 x 2-cm mass in the left lobe of the thyroid fixed to the larynx. Direct laryngoscopy and bronchoscopy showed no mucosal abnormality. He underwent left thyroid lobectomy and isthmusectomy, at which time the mass was found to be adherent to the cricoid. Tumor was shaved off the cricoid, leaving residual disease on the cartilage. The pathologic diagnosis was mixed papillary follicular carcinoma.

Two years postoperatively, the patient returned with a recurrent neck mass fixed to the larynx, again with no intraluminal signs or symptoms.

On radioactive iodine (^{131}I) scanning the tumor displayed no uptake. The surgical service treated the mass with external radiation, which resulted in moderate shrinkage of the tumor mass.

Six years postoperatively, the patient was again admitted with an increase in size of the neck mass. The patient also complained of hemoptysis but had no hoarseness. Several enlarged neck nodes were present, in addition to the mass adherent to the larynx. The surgical service performed a radical neck dissection and partial removal of the mass adherent to the cricoid.

Eight years after initial presentation, the patient returned with massive hemoptysis. His voice remained normal. Bronchoscopy revealed an intraluminal subglottic tumor, following which a total laryngectomy was performed.

He was subsequently evaluated by one of us (MF) for voice rehabilitation. Twelve years after initial presentation (four years after laryngectomy), he is free of disease.

COMMENT. The pathologic specimen (Fig. 1A) revealed, both grossly and microscopically, that approximately 25% of the anterolateral aspect of the cricoid cartilage was involved with tumor.

Case 2. A 60-year-old female had a thyroid nodule. She underwent a thyroid lobectomy and isthmusectomy at which time tumor was noted to be adherent to the cricoid and was not completely removed. On referral to another institution, she underwent a second neck exploration. Additional tumor was removed, but residual tumor remained adherent to the cricoid. Pathologic diagnosis was mixed papillary follicular carcinoma.

She was rehospitalized seven years after initial presentation with a large anterior neck mass and hoarseness. Partial removal of the tumor was again performed, and she subsequently was treated with ^{131}I.

One year later she returned with an extensive neck mass. The CT scan showed invasion of the cricoid and thyroid (Fig. 2A-C). The patient was then referred to one of us (MF). The patient underwent a partial subglottic resection, removing approximately 25% of the lateral aspect of the cricoid and thyroid cartilages. The recurrent laryngeal nerve was resected since it was involved with tumor.

TABLE 2. SURVIVAL STATUS FOR 13 PATIENTS

Interval Since Diagnosis	*NED*	*AWD*	*DOD*
< 5 years			2
< 10 years	2	1	1
< 15 years	3		
> 15 years	3	1	

NED - No evidence of disease; AWD - Alive with disease; DOD - Dead of disease.

COMMENT. Reconstruction involved soft tissue closure of the defect. In view of the numerous previous surgical explorations and the postradiation treatment, reconstruction with cartilage, bone graft, or flap was not considered advisable.

Postoperatively, the patient was decannulated in ten days. She healed with minimal subglottic narrowing. She has a cord paralysis but an adequate airway. She is active without any shortness of breath, and she is currently free of disease two years after surgery.

Case 3. A 50-year-old female had a thyroid nodule, treated with a thyroid lobectomy and isthmusectomy. The diagnosis was a mixed papillary follicular carcinoma. Six years postoperatively, she presented with right cervical adenopathy, at which time she underwent a right radical neck dissection. Ten years postoperatively the patient presented with left cervical adenopathy, and underwent a left radical neck dissection. Twelve years after the first surgery, she had extensive recurrent neck disease and pulmonary metastasis. The recurrent neck disease was excised and she was treated with ^{131}I.

Subsequently, she had progressive enlargement of a neck mass adherent to the thyrohyoid membrane. Twenty years after initial presentation, she was admitted with airway obstruction and severe dysphagia. Examination revealed an extensive supraglottic mass obstructing the airway and requiring emergency tracheotomy. She underwent a supraglottic laryngectomy and partial pharyngectomy. Decannulation was accomplished seven days postoperatively. At present she eats normally and has a normal airway.

COMMENT. Although any treatment in a patient with pulmonary metastasis is palliative, this can be long-term. Removal of the local disease causing severe airway obstruction with a partial laryngectomy as opposed to a total laryngectomy is certainly optimum palliation.

EXPERIMENTAL STUDY

Review of the literature and analysis of our cases illustrate the need for several questions to be answered. In cases of minimal laryngeal involvement, how much can be removed without sacrificing function? In cases of more massive involvement, at what point of resection is some method of reconstruction essential?

An experimental model was designed to mimic possible areas of subglottic laryngeal involvement with thyroid carcinoma. Since other sites of laryngeal involvement fit into standard categories of partial laryngectomy, these were not studied.

Six mongrel dogs underwent preoperative soft tissue neck x-ray studies to establish the presence of a normal subglottic airway. The six dogs then had partial subglottic laryngectomies with varying amounts of resection. The amounts of resection ranged from a minimum of 25% cricoid resection (Fig. 3A,B) with preservation of the recurrent laryngeal nerve to a maximum resection of 50% of

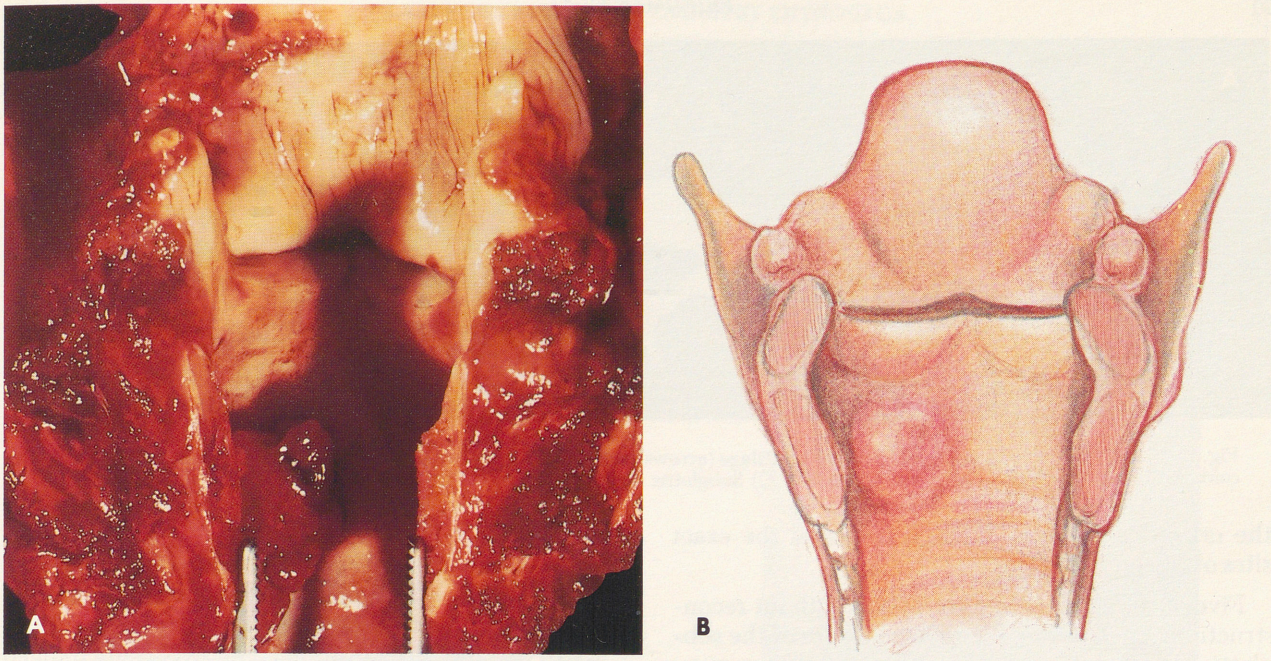

Fig. 1. (Case 1) A) Pathologic specimen showing intraluminal subglottic involvement by tumor. B) Sketch illustrating area of involvement found in pathologic specimen.

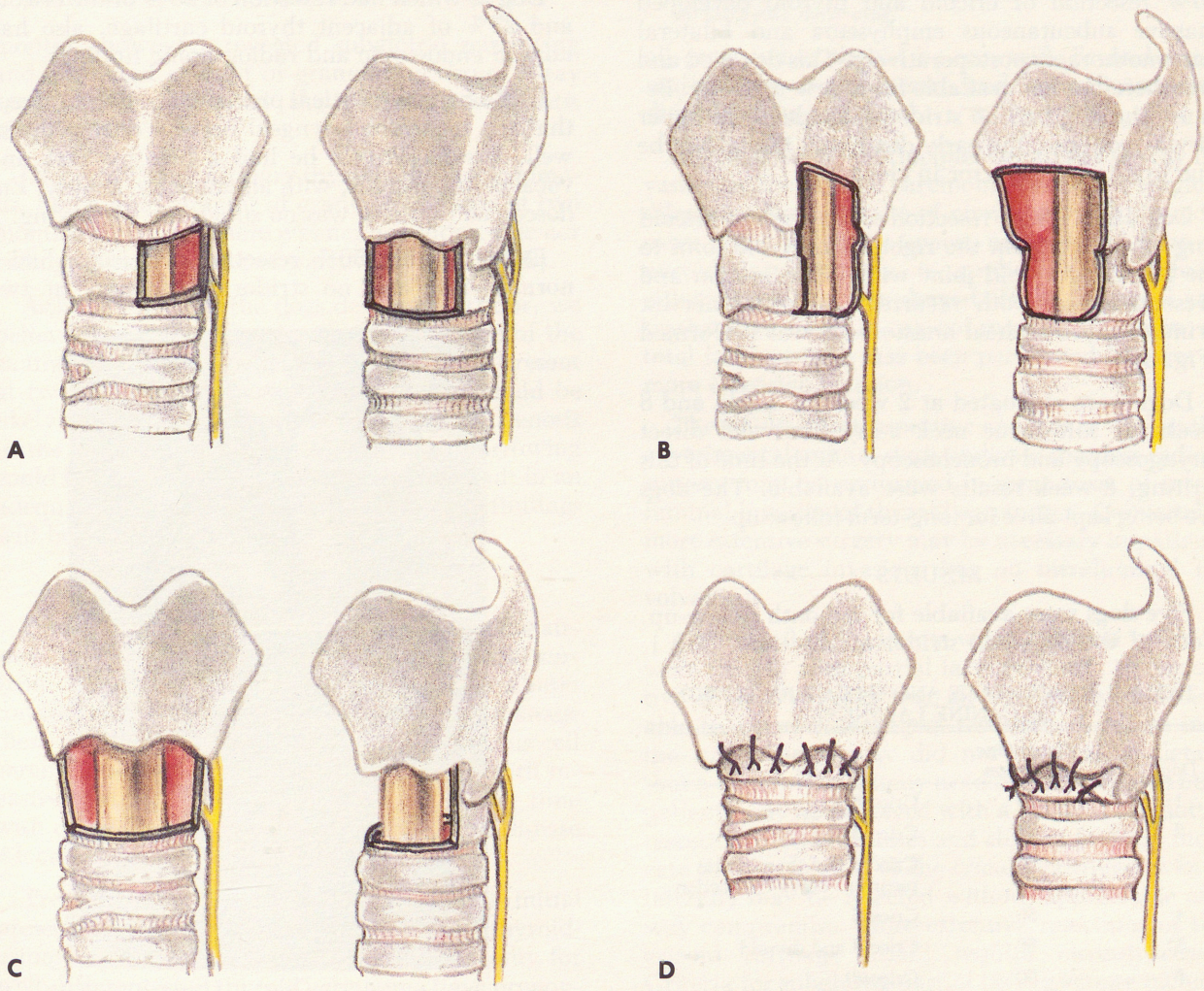

Fig. 3. Anterior and lateral views of reconstructions following partial subglottic laryngectomies. A) (Dog 1) Cricoid resection, 25%. B) (Dog 2) Cricoid and thyroid resection, 25%. C) (Dog 4) Cricoid resection, 50%. D) (Dog 6) Thyrotracheal anastomosis.

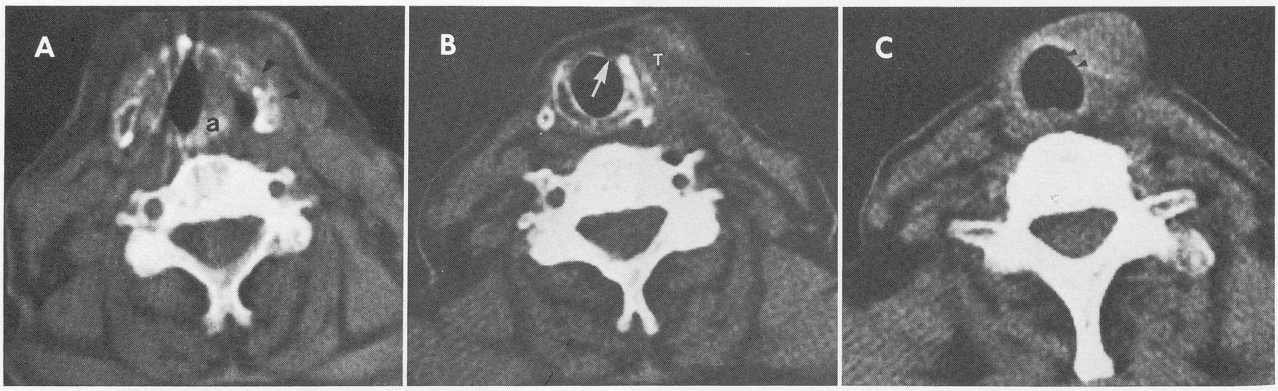

Fig. 2. (Case 2) A) Tumor eroding right thyroid cartilage (arrows) and extending onto aryepiglottic fold (a). B) Deformity of the cricoid cartilage (arrow) adjacent to the tumor (T). C) Subglottic airway invasion by the tumor (arrows).

the cricoid (Fig. 3C). Table 3 indicates the exact sites of resection.

Five of the six dogs had resections without reconstruction. Each of these dogs had closure of the subglottic defect with available soft tissue (strap muscles). None of the dogs had tracheotomies performed at the time of surgery. One of the dogs with 50% resection of cricoid and thyroid developed massive subcutaneous emphysema and bilateral pneumothoraces postoperatively. This dog died and was therefore not available for follow-up study. Because the dog had no stridor or evidence of upper airway collapse, the early death was thought to be due to a technical error in closure.

Dog 6 had a 50% resection of the anterior cricoid ring extending from the right cricothyroid joint to the left cricothyroid joint with identification and preservation of both recurrent laryngeal nerves. Primary thyrotracheal anastomosis was performed (Fig. 3D).

Dogs were evaluated at 2 weeks, 4 weeks and 8 weeks by soft tissue neck x-ray films and direct laryngoscopy and bronchoscopy. At the time of this writing, 8-week results were available. The dogs are being kept alive for long-term follow-up.

RESULTS

Five dogs were available for 2-month follow-up. None of the dogs had stridor at any time. Dog 1, which had a 25% resection of the cricoid, had a normal bark and normal endoscopic findings at two months. No narrowing, granulation tissue or scarring was detected. Soft tissue x-ray views (Fig. 4A,B) of the subglottic airway were unchanged compared to the preoperative x-ray views.

TABLE 3. PERCENTAGE AND SITE OF RESECTION OF CANINE LARYNGES

Dog	*Percentage Resection*	*Site*
1	25	Cricoid
2	25	Cricoid and thyroid
3	25	Cricoid and thyroid plus recurrent nerve transection
4	50	Cricoid
5*	50	Cricoid and thyroid
6	50	Cricoid†

*Dog 5 died in early postoperative course due to technical errors.

†With primary thyrotracheal anastomosis.

Dog 2, which had resection of 25% of the cricoid and 25% of adjacent thyroid cartilage, also had normal endoscopic and radiographic findings.

Dog 3 had an identical procedure to dog 2, except that the recurrent laryngeal nerve was resected as well. Postoperatively he had a breathy bark and vocal cord paralysis, with an adequate airway. Endoscopically, there was no subglottic narrowing.

Dog 4, with a 50% resection of cricoid, had a normal bark and no stridor. Endoscopy at two

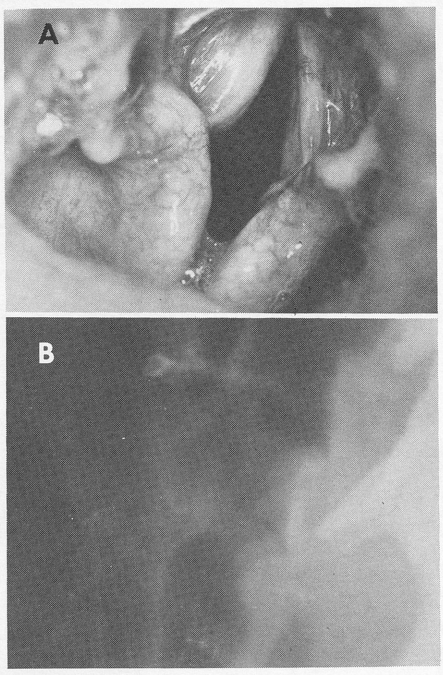

Fig. 4. (Dog 1) A) Postoperative endoscopic view showing normal subglottic larynx. B) Postoperative lateral neck x-ray film showing normal subglottic larynx.

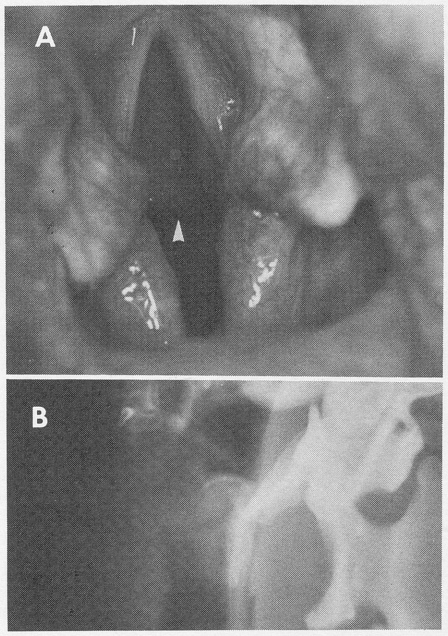

Fig. 5. (Dog 4) A) Postoperative endoscopic view showing enhanced subglottic narrowing (arrow). B) Postoperative lateral x-ray film confirming subglottic narrowing.

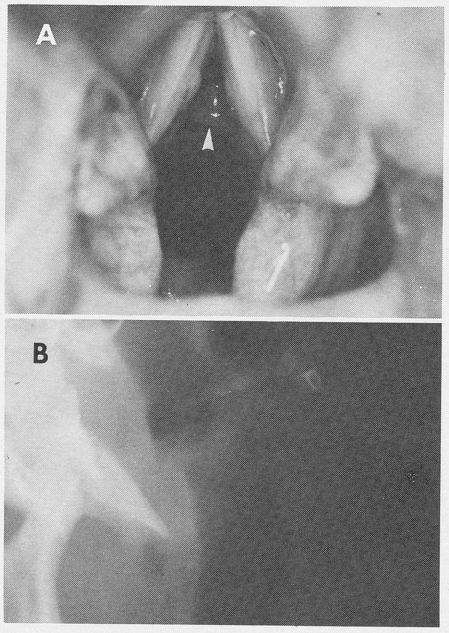

Fig. 6. (Dog 6) A) Postoperative endoscopic view showing mild moderate granulation tissue (arrow) without scar tissue formation. B) Postoperative lateral x-ray film showing no subglottic narrowing.

months, however, revealed subglottic narrowing and a marked amount of granulation tissue. X-ray examination confirmed the narrowed subglottis (Fig. 5A,B).

Dog 6, with the primary thyrotracheal anastomosis, had a mild amount of granulation tissue at two months. However, there was neither endoscopic nor radiographic evidence of narrowing (Fig. 6A,B).

Although none of the dogs developed stridor, we believe this is partially due to the large size of the canine larynx. Any evidence of narrowing present at two months in the experimental dog would be likely to suggest development of significant stenosis in the human. Procedures in which no narrowing could be detected at two months should result in an adequate postoperative airway. Long-term findings will be studied.

DISCUSSION

Patients with thyroid carcinoma invading the airway present difficult problems to the thyroid surgeon. The nature of the disease itself contributes considerably to the quandary of how to manage these patients. Unlike patients with squamous cell carcinoma of the head and neck, patients with invasive thyroid carcinoma can survive a long time with clinically evident disease, whether the disease is local or metastatic.

Treatment of thyroid carcinoma at the initial presentation remains controversial. Total thyroidectomy or total lobectomy and isthmusectomy for well-differentiated thyroid carcinoma have proponents. Universally accepted, however, are two basic principles of surgery for thyroid carcinoma. First, all gross tumor should be removed. Second, wide margins are not necessary and normal structures should not be sacrificed.

Adhering to these principles in cases of airway invasion by the thyroid carcinoma presents a surgical dilemma. Since the site of airway invasion in most cases is the subglottic space, no standard form of partial laryngectomy is applicable. Therefore, either tumor has been shaved off the laryngeal and tracheal cartilages in cases of marginal invasion, or total laryngectomy has been performed in cases of more extensive invasion.

The results of retrospective analysis as well as the experimental animal study indicate that less radical surgery may be performed in some cases of intraluminal invasion of thyroid carcinoma. Conversely, more extensive surgery may be necessary in patients with cartilage invasion, but no intraluminal involvement.

Although 3 of 5 patients with laryngeal invasion were treated with partial laryngectomy, retrospective analysis suggests that all 5 lesions were amenable to a partial laryngeal resection. Invasion into the subglottic airway did not necessarily dictate that a total laryngectomy need be performed. These patients may be managed with a subtotal subglottic resection. Animal studies and clinical findings indicate that up to 25% of the cricoid cartilage anterolaterally may be resected without appreciable airway compromise. More extensive resections of the cricoid cartilage would require reconstruction. Criteria for subglottic partial laryngectomy include adequate removal of disease, minimal functional change, and an acceptable risk of complications.

In those patients with cartilage involvement not extending intraluminally, a more extensive resection than shaving the cartilage is required. Removal of the involved cartilage should be performed. Resection of the cricoid cartilage can be treated as outlined. In cases of tracheal invasion, it is possible in many cases to resect portions of the tracheal rings without reconstruction. In those patients with minimal resections, closure of the defect with soft tissue is adequate.

Patients with extensive subglottic involvement may require resection of the entire anterior arch of the cricoid. In those patients, a primary thyrotracheal anastomosis is the preferable method of treatment. Gerwat and Bryce[10] and Pearson et al[11] have described the operative technique. Preservation of the cricothyroid joint stabilizes the larynx and protects the recurrent laryngeal nerves (if they are not involved with tumor).

Many techniques for reconstruction of tracheal and laryngeal cartilages have been used. These include the hyoid flap or graft,[12,13] rib graft,[14,15] and septal cartilage graft.[16,17] Circumferential tracheal resection has also been well described.[18-20] Primarily, these techniques have evolved from treatment of subglottic stenosis and traumatic airway injuries but are applicable in the treatment of airway invasion secondary to thyroid carcinoma.

Patients with thyroid carcinoma have unique limitations in reconstruction. Previous surgery, devascularized strap muscles and supporting structures and irradiation all tend to decrease the chance for successful graft or flap reconstruction. For these reasons, we strongly consider two alternatives. In minimal resections, reconstruction with soft tissue has been shown to be adequate. In extensive resections, primary anastomosis is the preferable method of treatment.

Our series reconfirms the importance of removal of gross disease. In those patients in whom an inadequate surgical resection was performed, 100% had uncontrollable disease and eventually died from their thyroid carcinoma. Residual disease predisposes the patient to local recurrence with airway invasion, possibly requiring extensive surgery.

CONCLUSIONS

On the basis of these observations we have reached the following conclusions.

1. Thyroid carcinoma invading the airway can usually be treated by partial laryngeal or tracheal resection.
2. Total laryngectomy may be required in cases of massive involvement.
3. Up to 25% of the cricoid cartilage may be resected without reconstruction.
4. Resection of a portion of the thyroid cartilage does not seem to alter the subglottic airway.
5. Primary thyrotracheal anastomosis is useful for reconstruction of patients requiring resection of the entire anterior cricoid arch.
6. Partial laryngeal or tracheal resection should be considered even in cases with no intraluminal involvement when the cartilage is involved. Gross tumor should not be left behind.

ACKNOWLEDGMENT — Mary McEnery, RN, assisted in this study.

REFERENCES

1. Cody H, Shah J. Locally invasive, well-differentiated thyroid carcinoma: 22 years' experience at Memorial Sloan-Kettering Cancer Center. Am J Surg 1981; 142:480-3.

2. Djalilian M, Beahrs O, Devine K, Weiland L, DeSanto L. Intraluminal involvement of the larynx and trachea by thyroid cancer. Am J Surg 1974; 128:500-4.

3. Frazell E, Foote FW. Papillary cancer of the thyroid: a review of 25 years of experience. Cancer 1958; 11:895-921.

4. Schindel J. Surgery of malignant tumors of the thyroid gland: a review of 15 years' experience with 225 cases. Ann Otol Rhinol Laryngol 1971; 80:61-6.

5. Breaux E, Guillamondegui O. Treatment of locally invasive carcinoma of the thyroid: how radical? Am J Surg 1980; 140: 514-7.

6. Silverberg S, Hutter R, Foote F. Fatal carcinoma of the thyroid: histology, metastases, and causes of death. Cancer 1970; 25:792-802.

7. Friedman M, Skolnik E, Baim H, Becker S, Katz A, Mantravadi R. Thyroid carcinoma. Laryngoscope 1980; 90: 1991-2003.

8. Clark RL, Ibanez M, White E. What constitutes an adequate operation for carcinoma of the thyroid? Arch Surg 1966; 92:23-6.

9. Lawson W, Som ML, Biller HF. Papillary adenocarcinoma of the thyroid invading the upper air passages. Ann Otol Rhinol Laryngol 1977; 86:751-5.

10. Gerwat J, Bryce DP. The management of subglottic laryngeal stenosis by resection and direct anastomosis. Laryngoscope 1974; 84:940-57.

11. Pearson FG, Cooper JD, Nelems JM, VanNostrand AWP. Primary tracheal anastomosis after resection of the cricoid cartilage with preservation of recurrent laryngeal nerves. J Thorac Cardiovasc Surg 1975; 70:806-16.

12. Alonso W, Druck N, Griffith C, Sumner H, Ogura J. Cricoid arch replacement in dogs: further studies. Arch Otolaryngol 1975; 101:42-5.

13. Alonso W, Druck N, Ogura J. Clinical experiences in hyoid arch transposition. Laryngoscope 1976; 86:617-24.

14. Cotton R. Management of subglottic stenosis in infancy and childhood. Ann Otol Rhinol Laryngol 1978; 87:649-57.

15. Cotton R, Evans J. Laryngotracheal reconstruction in children. Ann Otol Rhinol Laryngol 1981; 90:516-20.

16. Toohill R. Autogenous graft reconstruction of the larynx and upper trachea. Otolaryngol Clin North Am 1979; 12:909-17.

17. Toohill R. Panel discussion: the management of advanced laryngotracheal stenosis: composite nasal septal graft in the management of advanced laryngotracheal stenosis. Laryngoscope 1981; 91:233-7.

18. Grillo H. Tracheal reconstruction: indications and techniques. Arch Otolaryngol 1972; 96:31-9.

19. Dedo H, Fishman N. Laryngeal release and sleeve resection for tracheal stenosis. Ann Otol Rhinol Laryngol 1969; 78: 285-96.

20. Montgomery W. Suprahyoid release for tracheal anastomosis. Arch Otolaryngol 1974; 99:255-60.

AGE-RELATED CHANGES IN THE EPITHELIUM OF THE MONKEY LARYNX

M. P. STEARNS, FRCS
LONDON, ENGLAND

C. W. CUMMINGS, MD, FACS
SEATTLE, WASHINGTON

An experiment was designed to measure the area of subglottic squamous epithelium in a group of 14 adult monkeys. The animals were much older than any so far available for medical research. The larynges were strained using pyronin Y, which stains respiratory epithelium magenta and squamous epithelium pale pink. The areas of squamous epithelium inferior to the free margin of the vocal cord were measured. The results showed that the subglottic epithelium increased with age ($r = +0.61$, $p = <0.05$). This finding may have importance in the staging of laryngeal carcinoma.

INTRODUCTION

The first mention of the epithelium of the larynx in the scientific literature was by Galen[1] in the second century AD. In the late 19th century there was much controversy over the origins of the various types of epithelium in the larynx. This followed Tourneux's[2] writing that the free margin of the vocal cords was covered with stratified squamous epithelium and the adjacent areas with ciliated epithelium. The argument was whether the squamous epithelium was derived from physiological or pathological metaplasia. Kanthack[3] supported the physiological mechanism and Heymann[4] argued the case for pathological metaplasia.

A search of the literature fails to reveal the transition point from squamous to respiratory epithelium in the subglottic region. This area may have some importance in the staging and pathogenesis of laryngeal cancer as respiratory epithelium in the larynx has a rich lymphatic, whereas squamous epithelium does not. It is noteworthy that the UICC TNM[5] classification divides laryngeal carcinomas into supraglottic, glottic and subglottic, but does not specify where lies the division between the lower two regions. Stell et al[6] suggested that the division between glottis and subglottis should be the dividing line between squamous and respiratory epithelium. Kirchner and Som[7] suggested the upper border of the cricoid, and Ogura and Mallen,[8] a line 1 cm below the free edge of the cord.

A measure of the size of the squamous-lined subglottis and the area of transition therefore may be of importance. The purpose of this study was to try to establish whether the area of the squamous epithelium inferior to the free margin of the vocal cord was constant or whether it varied with age. The study was carried out on a group of rhesus monkeys.

MATERIALS AND METHOD

A group of 14 rhesus monkeys was used for the study. This was from one of the oldest primate colonies of experimental animals. Their age range was from 4 to 31 years (mean 15 years). The group included two 24-year-olds and three 31-year-olds. These latter animals might be expected to show some of the age changes seen in centenarian humans.

The larynges were removed, washed and subsequently fixed in 10% formol saline.

The epithelium of the larynges was stained using pyronin Y (Kodak). This dye stains ribonucleic acid.[9] After washing each larynx, it was suspended in a 4% aqueous solution of pyronin Y for one minute. The specimen was then washed to remove excess dye. Pyronin Y stains respiratory epithelium magenta and the squamous epithelium is left a pale pink color. This was confirmed histologically.

The specimens were split sagitally into two equal parts. They were then placed between two sheets of clear plastic (Perspex). The outline of the hemilarynx was then traced onto cellophane paper using a felt tip indelible marking pen. The areas of squamous and respiratory epithelium were recorded. These techniques have been fully described by Stell et al.[10]

The tracings of the larynges thus obtained were transferred to graph paper. This enabled the areas under study to be measured. These results were recorded and correlated with the animal's age.

RESULTS

It was found that the area of squamous epithelium inferior to the free margin of the vocal cord edge increased with age (table). Using the method of least squares, an r value for squamous epithelium in relation to age was obtained ($r = +0.61$, $p = <0.05$). No islands of squamous epithelium were seen in the respiratory epithelium-lined subglottic area.

CONCLUSIONS

The results show that in the group of animals studied, the area of squamous epithelium increases in size with advancing age. This appears to con-

From the ENT Department, Guy's Hospital, London, and the Department of Otolaryngology-Head and Neck Surgery, University of Washington, Seattle.
Presented at the meeting of the American Laryngological Association, Palm Beach, Florida, May 1-2, 1982.

AGE, SEX, AND SUBGLOTTIC SQUAMOUS EPITHELIALIZED AREA FOR EACH ANIMAL

Age (yr)	*Sex*	*Area of Subglottic Squamous Epithelium (sq mm)*
4	M	10
4	M	17
4	M	10
8	F	23
8	F	30
8	F	21
13	F	8
13	F	26
13	F	13
24	M	22
24	M	32
31	F	22
31	F	27
31	F	50

n = 14, r = +0.61, p = <0.05.

tinue even after skeletal growth has ceased. It is interesting to note that Pautow[11] in 1934 in a descriptive histological study stated that the laryngeal squamous epithelium increased with age, but did not support his statement with any data.

These animals were free of many of the factors that might be expected to contribute to pathological metaplasia such as tobacco smoke or air pollution, although local factors such as local and pulmonary infection could not be excluded. The results tend to support, therefore, Kanthack's[3] suggestion that a physiological metaplasia is involved. Hopp[12] in 1955 stated that occasional islands of squamous epithelium are seen in the subglottic region in the adult human larynx, but that these were rare and due to pathological change. We did not note any islands of squamous epithelium in our specimens. This may have been due to a lack of a pathological stimulus.

If one is able to draw any parallel with the human larynx, then the finding that the area of squamous epithelium beneath the free edge of the vocal cord increases in proportion to age may have importance in the staging of laryngeal tumors. These findings support Stell et al's[6] contention that for staging purposes the glottis should include the area of squamous epithelium below the vocal cords.

ACKNOWLEDGMENTS — I wish to thank Professor Josef Miller for his help with obtaining specimens and with the histology. I would also like to thank Dr. Roger Davies of Washington State University, Pullman, who made the specimens available.

REFERENCES

1. Galen. Opera omnia. Vol. 3. Kühn KG, ed. Leipzig: Cnobloch 1821-33. 1823:525, 551, 555, 586.

2. Tourneux MF. Sur le developpement de l'epithelium et des glands du larynx et de la trachee chez l'homme. Seances Soc Biol Paris 1885; 2:250-2.

3. Kanthack AA. Studien uber die Histologie der Larynxschleimhaut. Arch Pathol Anat Berlin 1889; 118:137-47, 273-94, 326-42.

4. Heymann R. Beitrag zur Kenntniss des Epithels und der Drüsen des menschliches Kehlkopfes im gesunden und kranken Zusande. Virchows Arch 1889; 118:320-48.

5. Union international contre le cancer. TNM classification of malignant tumours. Geneva, 1978.

6. Stell PM, Gregory I, Watt J. Morphometry of the epithelial lining of the human larynx. I. The glottis. Clin Otolaryngol 1980; 5:389-95.

7. Kirchner JA, Som ML. Clinical significance of a fixed vocal cord. Laryngoscope 1971; 81:1029-44.

8. Ogura JH, Mallen RW. Carcinoma of the larynx: diagnosis and treatment. Postgrad Med 1963; 34:493-8.

9. Brachet J. La localisation des acides pentasenucléiques dans les tissus animaux et les oeufs d'amphibiens en voie de développement. Arch Biol 1942; 53:207-57.

10. Stell PM, Gregory I, Watt J. Techniques for demonstrating the epithelial lining of the larynx. J Laryngol Otol 1972; 86: 589-94.

11. Pautow NA. Histologische Altersveranderungen an der Schleimhaut der Kehlkopfes. Z Hals Nasen Ohrenheilk. 1934; 37: 77-86.

12. Hoppe ES. The development of the epithelium of the larynx. Laryngoscope 1955; 65:475-99.

CLASSIFICATION AND APPROACH TO PATIENTS WITH FUNCTIONAL VOICE DISORDERS

JAMES A. KOUFMAN, MD P. DAVID BLALOCK, MA

WINSTON-SALEM, NORTH CAROLINA

Functional voice disorders result from vocal misuse or abuse; they are more easily recognized than other psychosomatic disorders because the clinician is able to visualize the laryngeal structure and function. If those structures appear normal, then an aberration of voice quality can be assumed to be functional. Functional dysphonia with prolonged aberrant vocal usage may lead to development of secondary pathological lesions of the larynx, which, although true pathological entities, must be recognized as resulting from the underlying and preceding functional disorder. In this report, we present a classification of and an approach to the diagnosis and treatment of functional voice disorders. On the basis of our clinical experience with 52 patients, we distinguished five types of functional voice disorders: type 1, hysterical aphonia/dysphonia; type 2, habituated hoarseness; type 3, falsetto voice; type 4, vocal abuse; and type 5, postoperative dysphonia. Forty-eight of the 52 patients (92%) were followed for a median period of 16 months (range 2-51 months). Therapy yielded excellent results in patients with types 1, 2 and 3; good results with types 4 and 5.

INTRODUCTION

A voice disorder is termed "functional" when it is primarily due to abuse or misuse of the anatomically and physiologically intact vocal apparatus. The underlying cause may be obscure or obvious, but prolonged abuse may result in the development of nodules, polyps, ulcers, or granulomas of the vocal cords.

The purpose of this paper is to present a classification and approach to treatment of functional voice disorders. The proposed system abandons the use of terms such as hypokinetic and hyperkinetic and focuses on the underlying mechanism and the clinical presentation. Although we present five clinically discrete groups (types), we have only limited data on some of the types and may not have identified other types or subtypes of voice disorders that can be termed truly functional.

MATERIAL AND METHODS

The medical records of 52 patients with a diagnosis of functional voice disorder were reviewed and yielded the data for this report. All patients were private patients seen by the senior author (JAK) from July 1978 through December 1981.

There were 39 female and 13 male patients (female to male ratio, 3:1). Their median age was 42 years (range: 6-76 years); seven patients were younger than 16 years. The median duration of symptoms before the patients were seen was 7 months (range 1-216 months); twelve patients (23%) had had a preceding bout of viral laryngitis.

To have been diagnosed as having a functional voice disorder, a patient had to have had a poor voice and a normal mirror laryngoscopy or had to have demonstrated patterns of vocal abuse with associated *secondary* pathological lesions. Patients with unilateral lesions or a lesion attributed to smoking, or with altered laryngeal physiology due to trauma or systemic illness (specifically, reflux esophagitis, thyroid disease, postinflammatory polyps, and spastic dysphonia) were specifically excluded from the study group. The voice problems were classified into one of five types by the senior author (Table 1). The criteria for each classification were as follows:

Type 1. Hysterical Aphonia/Dysphonia

1. Onset: sudden.
2. Indirect laryngoscopy: normal.
3. Often associated with a discrete precipitating event.
4. No history of prior laryngitis.
5. Associated symptoms: none.
6. Voice quality:
   a. Aphonia or whisper.
   b. Pitch-locked (if any voice present).
   c. Stable dysfunction (not intermittent or fluctuant).

Type 2. Habituated Hoarseness

1. Onset: persistence of hoarseness (for months or years) usually following an acute episode of laryngitis.
2. Indirect laryngoscopy; normal (except for occasional plica ventricularis).
3. Associated symptoms: none.
4. Not associated with a discrete precipitating event but frequently associated with "secondary gain."
5. Voice quality:
   a. Breathy, raspy, diplophonia, plica ventricularis (or a combination).
   b. Pitch-locked.
   c. Stable dysfunction (not intermittent or fluctuant).

Type 3. Falsetto

1. Onset: developmental or sudden.
2. Indirect laryngoscopy: normal.
3. Associated symptoms: none.
4. Voice quality:
   a. Abnormally high-pitched.
   b. Pitch-locked.
   c. Stable dysfunction (not intermittent or fluctuant).

Type 4. Voice Abuse

1. Onset: usually long-standing, intermittent or fluctuant dysphonia.

From the Section on Otolaryngology, Department of Surgery, Bowman Gray School of Medicine of Wake Forest University, Winston-Salem, North Carolina.

Presented at the meeting of the American Laryngological Association, Palm Beach, Florida, May 1-2, 1982.

REPRINTS — James A. Koufman, MD, Section on Otolaryngology, Bowman Gray School of Medicine, 300 S. Hawthorne Rd, Winston-Salem, NC 27103.

2. Vocal abuse resulting from:
   a. Overuse.
   b. Pitching the voice abnormally low.
   c. Abnormal muscular tension in the larynx and neck muscles.
   d. Any combination thereof.
3. Indirect laryngoscopy: normal or associated with "secondary" vocal nodules, polyps, ulcers, or granulomas.
4. Associated symptoms: throat pain coincident with the dysphonia (worse after voice strain).
5. Voice quality:
   a. Variable dysphonia.
   b. Hard glottal attack.
   c. Not pitch-locked.
   d. Intermittent and/or fluctuant dysfunction.

Type 5. Postoperative Dysphonia

1. Onset: severe dysphonia secondary to vocal abuse after operation.
2. Indirect laryngoscopy: normal or plica ventricularis, ulcers, or granulomas.
3. Associated symptoms: throat pain coincident with dysphonia (worse after voice strain).
4. Voice quality:
   a. Variable dysphonia.
   b. Hard glottal attack.
   c. Not pitch-locked.
   d. Frequent plica ventricularis.

All patients had undergone a complete otolaryngological examination and 40 patients had been evaluated by a speech pathologist. Eight of the patients underwent a neuropsychological evaluation which included an interview with a trained psychologist and a Minnesota Multiphasic Personality Inventory (MMPI). A neuropsychological evaluation was carried out in selected cases, both for research as well as for clinical purposes. (Such an evaluation may not be necessary for most patients with functional voice disorders; rather, referral to a psychologist or psychiatrist may suffice when referral is indicated.)

Treatment consisted of voice therapy alone in 67% of patients, voice therapy and operation in 17%, and voice therapy and psychiatric therapy in 6%. Five patients (10%) had been counseled but had received no formal therapy; it had not been recommended for 2 patients, and had been refused by 3 patients. The therapeutic procedures employed are discussed later.

Follow-up examinations of all 52 patients were carried out by the authors. "Late" follow-up (in March 1982) was also obtained by telephone interviews with 48 of the patients (92%). The results were judged by the authors as follows: *excellent* — voice normal without recurrent episodes of aphonia or dysphonia during the follow-up period; *good* — voice usually normal, but relapse occurred at least once during the follow-up period; *poor* — voice unimproved or improved but still poor.

Statistics. Due to the small sample size, medians and ranges rather than means were used. Statistical significance of the observed differences in the results of treatment in patients with type 1, 2, 4 and 5 disorders and type 4 subgroups was computed using the chi-square and ANOVA methods.

RESULTS

Hysterical aphonia/dysphonia (Type 1). Four female patients and one male patient (10%) had exhibited hysterical conversion reactions. Each presented with a sudden loss of voice: two were aphonic and three whispered softly. In all, the vocal loss was stable and not fluctuant, and the dysphonia (if a voice was present) was "pitch-locked." The median duration of symptoms before presentation was two months (range: 0.5-17 months).

Complete voice restoration was accomplished with voice therapy during the initial visit in four patients, and after two therapy sessions in the fifth patient. Neuropsychiatric evaluation including MMPI was recommended to each of these patients, but only one patient agreed to be tested (a 45-year-old male with multiple somatic complaints and severe dysphonia; MMPI results showed elevated scales 1, 3, and 8 consistent with the diagnosis of hysteria).

TABLE 1. CLASSIFICATION OF FUNCTIONAL VOICE DISORDERS

Type	*Disorder*	*% of Patients (n = 52)*
1	Hysterical aphonia/dysphonia	10
2	Habituated hoarseness	28
3	Falsetto voice	2
4	Vocal abuse*	52
5	Postoperative dysphonia*	8

*Only type 4 and 5 disorders are associated with pathological abnormalities of the larynx. Lesions were present in 60% of the type 4 patients (nodules — 13, polyps — 3, granulomas — 1) and lesions (nodules) were present in one type 5 patient (20%). These 18 cases represented 35% of the 52 patients.

The four female patients have remained asymptomatic with normal voices (median follow-up period: 16 months; range: 3-34 months). The male patient continues to have occasional relapses, and psychiatric therapy is in progress.

Habituated Hoarseness (Type 2). Thirteen female and two male patients (28%) were classified as having habituated hoarseness. The female to male ratio in this group was twice that of the overall group (6.5:1). The median age was 38.7 years (range: 14-76 years); the median duration of symptoms at presentation was 11 months (range: 2-24 months). In 12 of the 15 patients (80%), the dysphonia had begun with a bout of viral laryngitis. Three patients who denied having had laryngitis were included in this group because of the chronicity of their hoarseness and because, in all other respects, they resembled type 2 patients.

Indirect laryngoscopy had yielded normal findings in 10 patients; 3 patients had had false vocal cord voice and 2 had had mild Renke's edema.

Voice therapy and counseling were the only forms of therapy employed in this group. All 15 patients regained a completely normal voice, 12 (80%) doing so on the initial visit. Neuropsychological evaluation with counseling was suggested for three patients; however, only one patient was actually evaluated. Only 1 of the 15 patients has had recurrence of her hoarseness (median follow-up period: 16 months; range: 1-50 months).

Falsetto Voice (Type 3). Only one patient fell into this category, a 53-year-old female who had suddenly developed an abnormally high voice one year before we saw her. Her voice was restored with voice therapy, and she was referred for psychological evaluation and counseling because the neuro-

TABLE 2. TYPE 4 RESULTS OF TREATMENT ACCORDING TO SUBTYPE AND SEX

	Results		
	Excellent	*Good*	*Poor*
TFS			
M	3/7 (44%)	2/7 (28%)	2/7 (28%)
F	4/5 (80%)	1/5 (20%)	—
Nodules			
M	1/2 (50%)	—	1/2 (50%)
F	5/10 (50%)	3/10(30%)	2/10 (20%)
Polyps			
F	1/3 (33%)	2/3 (67%)	—
Granuloma			
M	1/1 (100%)	—	—

TFS - Tension-fatigue syndrome.

psychological evaluation had revealed a high psychosomatic score and possible impending psychological decompensation. Her voice is normal at 5-months follow-up.

Voice Abuse (Type 4). Of the 52 patients, 27 (52%) were classified as vocal abusers. The female to male ratio was 1.7:1. Sixteen (60%) had developed vocal nodules, polyps, or granulomas, and the remaining 11 (40%), who had had normal mirror laryngoscopic examinations, were classified as having musculoskeletal tension disorders, hereafter referred to as "tension fatigue syndrome." All nine of the patients in the entire study group who used their voices professionally were in this type 4 group. The median duration of symptoms for these 27 patients was 18 months (range: 2-216 months).

The results of treatment according to subclass and sex are shown in Table 2. Follow-up ranged from 1 to 38 months (median: 17 months). The best results were obtained in women with tension fatigue syndrome; the worst results in men with tension fatigue syndrome. However, the 5 patients with poor results had received no treatment (2 males with tension fatigue syndrome and 1 female with nodules had refused therapy, and no therapy was recommended for 2 children with nodules).

A chi-square test of the differences observed in results between male and female patients as well as between the subclasses revealed that none was statistically significant.

The nine patients in the entire series who were treated surgically all had type 4 disorders. All were women, three of whom had polyps and six of whom had nodules. The final results of operation were excellent in six patients (67%) and good in three patients (33%). (Of the 9 patients treated surgically by one of the authors, 3 developed transient postoperative plica ventricularis, which was responsive to voice therapy in every case).

The overall results for type 4 subjects were: excellent — 56%; good — 26%; and poor — 18%.

Postoperative Dysphonia (Type 5). Four patients had presented with severe dysphonia following operations at other institutions: bilateral vocal cord stripping in three patients, unilateral vocal cord stripping in one patient. One of the 4 had had severe dysphonia of the tension fatigue syndrome type; 1, a child, had developed recurrent nodules within six months of operation; and the other 2 patients employed a false vocal cord voice. The median duration of symptoms before presentation was three months (range: 1-6 months). Combining these four patients who had presented with type 5 disorders with the four type 4 patients who had developed type 5 disorders after operative treatment provided a group comprising 15% of the study population.

In this group, 5 of the 8 patients (63%) employed false vocal cord voices postoperatively. Late follow-up of those eight patients showed 50% with excellent results, 25% with good results, and 25% with poor results. The median follow-up period was 12 months (range: 6-28 months). These results are similar to the results observed in type 4 dysphonias.

Neuropsychological Evaluation. Four patients from group 4 and one patient each from the other groups had neuropsychological evaluations. The MMPI was interpreted as "psychosomatic" (classic conversion "V"; elevated 1, 3 scales) for 6 of the 8 patients, while two of the scores were normal. Evaluations suggested psychiatric disturbances in three patients (for which psychiatric referral was made); none of the patients were psychotic.

The neuropsychological evaluations were recommended for the few patients (15%) who were felt to be unresponsive to voice therapy due to psychological factors and for patients who seemed to display obvious psychopathological behavior. Further study is needed to clarify the contributing psychological factors in order to achieve a better understanding of the most effective therapeutic approach.

Comparative Results of Treatment: Types 1-5. The results of treatment for each type suggest that the overall prognosis in the functional voice disorders is dependent upon the presence or absence of pathological lesions of the larynx (Table 3). A statistical analysis of the differences in results of the individual types was not possible due to the small numbers in some of the groups. However, when the "non-lesion types" (types 1, 2, and 3) were grouped and compared with the grouped "lesion types" (types 4 and 5), the difference in the results of therapy was significant at a $p < .01$ level.

DISCUSSION

Arnold and Pinto,[1] Arnold[2,3] and Aronson[4] have contributed toward the classification of functional voice disorders; however, no unifying classification has been presented in the medical literature, despite the available data on many such disorders. Hysterical mutism, aphonia and dysphonia, for example,

TABLE 3. FUNCTIONAL VOICE DISORDERS: RESULTS BY TYPES (1-5)

Type	Results		
	Excellent (%)	Good (%)	Poor (%)
1	4/5 (80%)	1/5 (20%)	—
2	12/13 (92%)	1/13 (8%)	—
3	1/1 (100%)	—	—
4	15/27 (56%)	7/27 (26%)	5/27 (18%)
5	1/4 (25%)	1/4 (25%)	2/4 (50%)
	*4/8 (50%)	*2/8 (25%)	*2/8 (25%)

*Type 5 results including four type 4 patients who also had developed postoperative dysphonia.

are well-described[3-7] and are easily recognized, but are considered to be clinically discrete disorders. Polyps, nodules, contact ulcers, and granulomas, all well-known sequelae of vocal abuse, tend to be reported as separate entities rather than together as a single group.[8-10] Indeed, all the components of the classification presented here are well-known, but are seldom considered in the context of a common etiology.

Hysterical Aphonia/Dysphonia (Type 1). Carter[5] studied 100 cases of hysterical conversion reaction, excluding cases with diffuse or complicated symptoms, and noted that aphonia was, indeed, the most common conversion symptom (29%). In his series, 70% of patients were females, and while initial therapy successfully restored the voice in 100% of patients, follow-up of 27 patients 4 to 6 years later showed that only 68% had maintained a restored voice; 28% were improved; and 4% were unimproved. However, Carter concluded that "hysterical aphonia by itself is a symptom of only mild mental disassociation and has a very good prognosis."[5]

Habituated Hoarseness (Type 2). In Carter's series of patients with hysterical conversion reactions, many had aphonia following viral laryngitis.[5] Aronson has also suggested that "conversion aphonias and dysphonias are often triggered by cold or flu and associated laryngitis."[4] However, it is useful to separate the true hysterical conversion reaction from postviral chronic hoarseness: first, because more significant psychopathology may be associated with the true conversion reactions; second, because the long-term prognosis is probably better for the patient with postviral chronic hoarseness; and third, because the underlying cause is different for each group. In conversion reactions, the hysterical symptom (aphonia) is unconsciously selected and is usually of symbolic significance.[4-7] In postviral habituated hoarseness, on the other hand, the patient has simply made a chronic adaptation to an acute dysfunction, usually with some secondary gain.

Falsetto Voice (Type 3). Falsetto voice is uncommon, but is easily recognized. The larynx appears normal but the voice is disproportionately and inappropriately high-pitched. Correction is almost uniformly achieved by suggestion and reassurance.

It is likely that patients with falsetto voice can be divided into two subcategories. The first includes adolescents with preadolescent voices (mutational falsetto), and the second includes adults with acute onset falsetto (probably representing hysterical conversion reactions).

Vocal Abuse (Type 4). Unlike the first three types discussed which are associated with vocal misuse, this type is associated with functional abuse. Type 4 patients are prone to developing vocal nodules, polyps, ulcers, granulomas and lesions unassociated with the other functional types.

Other vocal abusers experience intermittent tension, fatigue, hoarseness and throat pain (the tension fatigue syndrome) without producing histopathological changes in the larynx. Patients in this group seem to be exclusively adult and are predominantly male. They are frequently ambitious, aggressive, hard-driving persons, and some are overly masculine, employing a fundamental voice pitch that is excessively low.[4] Our data and that in the literature suggest that tension-fatigue syndrome is the only functional voice disorder other than screamer's nodules that is more common in male patients. While type 4 females may develop tension-fatigue syndrome, they seem more prone to developing nodules or polyps. Children who abuse their voices are most prone to develop nodules.

Postoperative Dysphonia (Type 5). Some patients who undergo an endolaryngeal operation return to the surgeon's office for follow-up with severe dysphonia. These patients demonstrate a violent glottal attack, which represents a vain attempt to produce a normal voice. Some may speak with a false vocal cord voice or may even have developed postoperative ulcers or granulomas of the vocal cords. (We do not consider false vocal cord voice a distinct disorder type, even though 8 of the 52 patients (15%) in this series presented with or developed false vocal cord voice. Five of the 8 patients had developed postoperative plica ventricularis and 3 had had postviral laryngitis. Arnold[1] suggested that false vocal cord voice was a secondary form of "laryngitis" resulting from a primary vocal disorder. The data from this study also suggest that false vocal cord voice may simply be a compensatory mechanism associated with painful speaking, and that habituation is common. False vocal cord voice may, therefore, represent a symptom only and not a disorder entity.)

Postoperative dysphonia seems to occur in patients who either are not adequately prepared preoperatively or are noncompliant with postoperative voice conservation measures. Thus we believe that the incidence of postoperative dysphonias may be reduced by preoperative vocal reeducation of certain surgical patients.

Approach to Patients with Functional Voice Disorders. In laryngology, when the voice is disproportionately poor compared to the laryngeal findings, a functional voice disorder should be suspected. Since prompt voice restoration is the best confirmation of the diagnosis, the clinician should proceed with therapy as soon as the diagnosis is made, and avoid labeling the patient as psychosomatic, even though that may be the case. Since most patients seem to accept the concept that dysfunction may be the result of stress, the clinician should suggest it. Such an explanation serves three purposes: First, the patient is reassured that many normal persons have functional problems; second, the clinician suggests that he or she is willing to help; and third, the clinician implies that the patient will have a role in the therapeutic process.

Prompt vocal restoration may be achieved through techniques that encourage the patient to use any other voice, eg, falsetto; the clinician then works with the patient to extend incrementally the phonatory signal until a normal voice is achieved (asking the patient to cough, to clear his or her throat, or to meow like a kitten are effective maneuvers). If the clinician is successful in reestablishing the patient's voice, he or she should still refer the patient to a speech pathologist, who can reinforce the initial success. When the clinician is unsuccessful, he or she must be careful not to risk alienating the patient by expressing displeasure in the patient's response.

The speech pathologist employs relaxation techniques such as deep abdominal breathing, and repeats those methods already tried by the otolaryngologist. Biofeedback is another useful tool in the treatment of functional voice disorders, and a Vocal-2 Visible Training System or Fundamental Frequency Indicator may be employed. In resistant cases, a portable audiometer can be used to produce white noise masking.

Type 4 patients vary widely in terms of age, occupation, duration of symptoms, and motivation. Voice therapy remains the cornerstone of treatment, but the proportion of noncompliant patients resistant to such therapy is notably higher in this group than in the others.

Voice therapy techniques for type 4 patients are similar to those used in type 1, type 2, and type 3 patients, with the exception that the primary focus is on reducing or eliminating vocal abuse. Techniques toward this end include charting vocal behavior on a daily basis and voice taping for playback purposes, which are important because they reinforce the patient's awareness of normal versus abusive vocal patterns. Relaxation exercises and efficient use of the breath stream are also emphasized.

Postoperative dysphonia (type 5) patients may represent a special variety of type 4 patients. Postoperative dysphonia patients tend to be hostile and are poorly motivated. They are inclined to blame the surgeon for the poor result if not preoperatively counseled, and they may be resistant to therapy.

Routine preoperative voice therapy may be indicated for every vocal abuse patient with a surgical lesion. The patient should be forewarned that a hard glottal attack or any vocal abuse in the postoperative period may result in severe dysphonia and possibly even lead to the development of new lesions.

Patient motivation is the key to a successful therapeutic outcome in the functional voice disorders, and some patients with functional voice disorders may actually prefer dysphonia to a normal voice. This preference is especially common in those who use their voices professionally. Some use a "character" voice; in others (the late Louis Armstrong, for example), vocal abuse had led to the development of a uniquely individual voice quality. Patient motivation should therefore be evaluated in each case before formulation of a treatment plan.

Neither our experience nor that reported in the medical literature suggests the need for routine psychiatric therapy in patients with functional voice disorders. Such referral should be made whenever failure of treatment is thought to be due to psychological factors, or whenever a significant psychopathological condition is suspected.

CONCLUSIONS

1. A functional voice disorder should be suspected whenever a patient's dysphonia seems out of proportion to the laryngeal findings.
2. Chronic (habituated) hoarseness resulting from an acute viral laryngitis may be a discrete functional syndrome with an excellent prognosis.
3. Hysterical aphonia, habituated hoarseness and falsetto voice are more easily treated than the vocal abuse and postoperative dysphonia syndromes.
4. Voice therapy is essential for patients with functional voice disorders and particularly preoperatively for vocal abusers with surgical lesions.

REFERENCES

1. Arnold GE, Pinto S. Ventricular dysphonia: new interpretation of an old observation. Laryngoscope 1960; 70:1608-27.

2. Arnold GE. Vocal nodules and polyps: laryngeal tissue reaction to habitual hyperkinetic dysphonia. J Speech Hear Dis 1962; 27:205-17.

3. Arnold GE. Disorders of laryngeal function. In: Paparella MM and Shumrick DA, eds. Otolaryngology. Vol 3. Philadelphia: W. B. Saunders Co, 1980:2470-88.

4. Aronson AE. Psychogenic voice disorders. In: Aronson, AE. Clinical voice disorders: an interdisciplinary approach. New York: Decker, 1980:127-54.

5. Carter AB. The prognosis of certain hysterical symptoms.

Br Med J 1949; 1:1076-9.

6. Heaver L. Psychiatric observations on the personality structure of patients with habitual dysphonia. Logos 1958; 1:21-6.

7. Ljungberg L. Hysteria: a clinical, prognostic and genetic study. Acta Psychiatr Neurol Scand 1957; Suppl 112.

8. Harma R, Sonninen A, Vartiainen E, Haveri P, Vaisanen A. Vocal polyps and nodules. Folia Phoniatr 1975; 27:19-25.

9. Fitz-Hugh GS, Smith DE, Chiong AT. Pathology of three hundred clinically benign lesions of the vocal cords. Laryngoscope 1958; 68:855-75.

10. Preacher GM. Vocal therapy for contact ulcers of the larynx. A follow-up of 70 patients. Laryngoscope 1961; 71:37-47.

PATHOGENESIS OF VOCAL CORD POLYPS

OSKAR KLEINSASSER, MD

MARBURG, WEST GERMANY

Polyps of the vocal cords are a separate entity occurring nowhere else in the larynx or in the human body. Gelatinous and telangiectatic, but mainly transitional types of polyps can be discriminated. Histological, histochemical and electron microscopic investigations on a series of polyps show that an alteration of the permeability of blood vessels may be of importance, allowing the extravasation of edema fluid, fibrin or erythrocytes. Following this, reactive processes develop with the formation of labyrinthine vascular spaces. This process is very similar to the organization of a thrombus. Since polyps occur mainly in people who use their voices very intensively, and develop at the site of maximum muscular and aerodynamic forces exerted during phonation, vocal cord polyps are considered a sequela of a phonotrauma.

Polyps of the vocal cords are by far the most common benign lesions of the larynx. Polyps are a separate entity which can be discriminated easily from other forms of so-called laryngeal nodules; for instance, the true singer's nodules occurring in women only, the screamer's nodules in children of both sexes, and the polypoid corditis or Reinke edema. True polyps arise only on the vocal cords and in no other part of the larynx. Neither can polyps or analogous or even similar lesions be found anywhere else in the human body.

In a series of 900 vocal cord polyps which were removed by endolaryngeal microsurgery at the Clinic of Otolaryngology and Head and Neck Surgery of the University of Marburg 76% of the patients were males and 24% females. Most of the patients were between 30 and 50 years of age — the men averaged 40, the women 38 years; none of the patients were younger than 20 years of age. Of all these patients, 80-90% were smokers. Many of them reported that they had used or abused their voices professionally or habitually. Ten percent of the polyps were multiple and bilateral; 5% were multiple and unilateral.

Microlaryngoscopically two extreme types can be recognized: one of these is the glassy translucent gelatinous form; the second is the telangiectatic polyp. In some early lesions of the telangiectatic type a blister or convolute of capillaries can be seen. In more advanced forms there appear grape- or even raspberry-like convolutes of blood vessels which become more and more pedunculated. But most common are transitional forms with a nucleus of tortuous vessels embedded in a gelatinous substance covered by squamous epithelium.

Polyps have been called products of inflammation, allergic or immunologic processes or the results of trauma. Since none of these theories appeared plausible, we performed histological and histochemical investigations on a series of 100 consecutive vocal cord polyps. In addition, with the assistance of Professors H. Frenzel and W. Hort (Institute of Pathology, University of Düsseldorf), ten additional polyps were examined by electron microscopy.[1]

In the polyps which appear gelatinous macroscopically and histologically the stroma is very loose and edematous (Fig. 1A). Between the sparse collagen fibers lie blood vessels which have mostly a narrow lumen and relatively thick walls. Often cell-free sinus-like spaces lined with endothelial cells develop; in other areas within the stroma lake-like areas filled with a slightly basophilic fluid appear (Fig. 2 A), condensating sometimes to plaques of an eosinophilic material (Fig. 2B).

Some of the telangiectatic polyps are tightly filled with a dense nearly homogenous eosinophilic material around irregularly arranged vascular spaces. Most common are mixed forms consisting of a vascular nucleus surrounded by loose fluid-rich tissue (Fig. 1C).

Going further into the details of this vascular nucleus we find the deposits of the eosinophilic materials primarily around the walls of the vascular spaces, arranged either in larger or multiple small plaques. These eosinophilic deposits sometimes appear to be penetrated or organized by newly developing vascular sinuses. In this way some pictures remind one of a vascular labyrinth or even a renal glomerulus (Fig. 3A, B). These vascular labyrinths are lined with endothelial cells. In some cases bud-like endothelial proliferations and newly formed vessels show that the organization of these deposits is a very active process (Fig. 4A, B).

By histochemistry and electronmicroscopy we could identify these deposits as fibrin.[1] We were

---

From the Clinic of Otolaryngology, Head and Neck Surgery, Philipps-University, Marburg (Lahn), West Germany.

Presented at the meeting of the American Laryngological Association, Palm Beach, Florida, May 1-2, 1982.

REPRINTS — Prof. Dr. O. Kleinsasser, Univ-ENT-Clinic, Deutschhausstr 3, D-3550 Marburg (Lahn), West Germany.

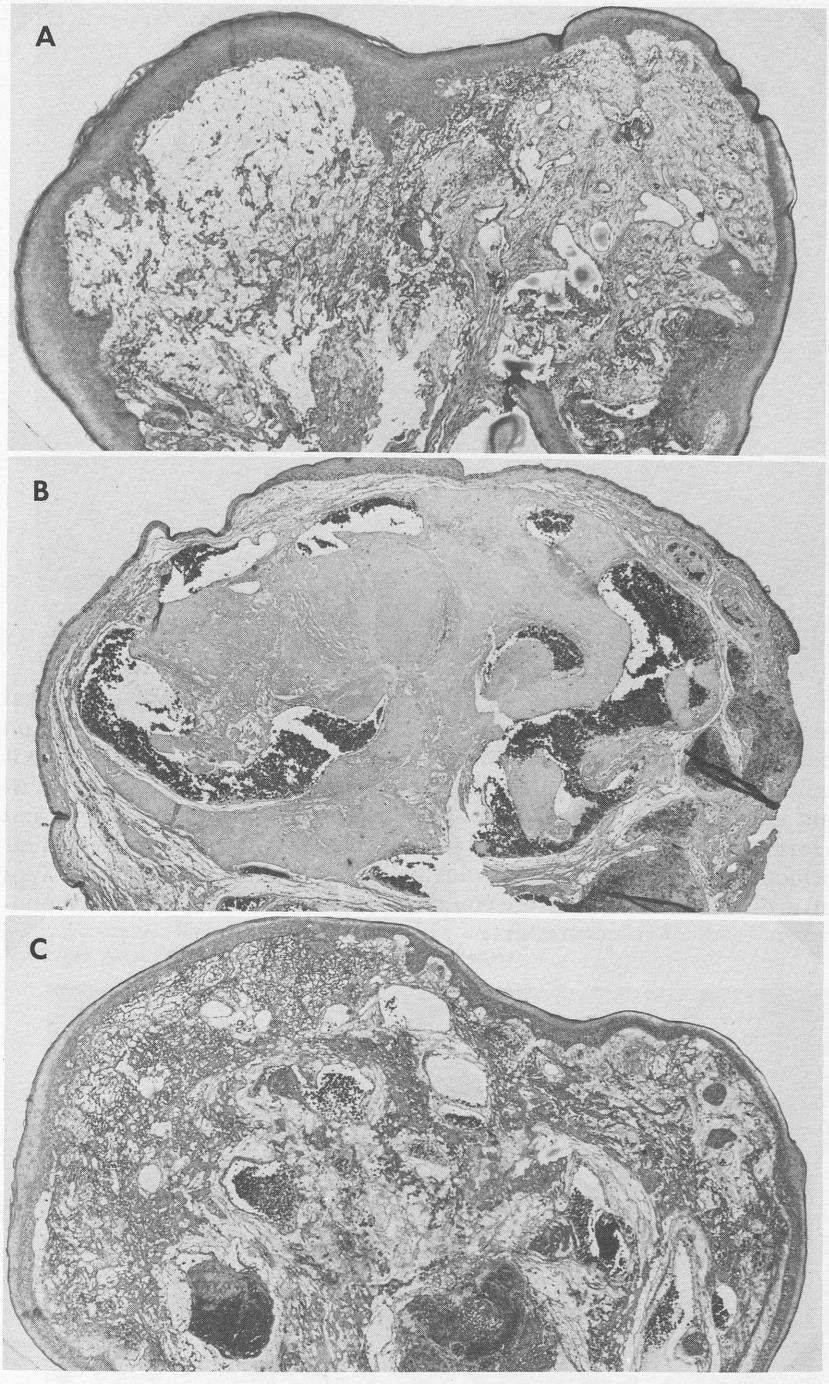

Fig. 1. A) Gelatinous type of vocal cord polyp. Polyp is filled with edema fluid in loose stroma, with several dilated vessels in right part. B) "Nucleus" of these telangiectatic polyps consisting of dense eosinophilic material and dilated vascular spaces. C) Most common "mixed type" vocal cord polyp containing vascular spaces of different configuration, deposits of dense eosinophilic material with edema. (x25)

especially interested in the vascular walls. In the gelatinous polyps the blood vessels were largely identical to the blood vessels of the normal vocal cords. Only seldom could a small gap be found between neighboring endothelial cells. The outer layers of the basal membrane were irregular and often incomplete, and mixed with the delicate collagen fibers of the loose stroma. Thereby the impression is given of a relatively thick vessel wall. In the telangiectatic parts of a polyp we often found gaps in the vascular walls permitting the extravasation of erythrocytes.

Summarizing the results of the morphological investigations our interpretation of the pathogenesis of vocal cord polyps is as follows. In the beginning of the process damage to the walls of the submucous capillaries of the vocal cords takes place. Coiled vessels and sinusoid vessels can appear. Depending on the extent of the damage an increased permeability of the vascular walls develops. Either a thin fluid permeates or a compact fibrin insudation emerges.

The reaction of this fibrin precipitation on the neighboring blood vessels and the connective tissue leads finally to a vascularization of the fissures between the fibers of the fibrin deposits. These pic-

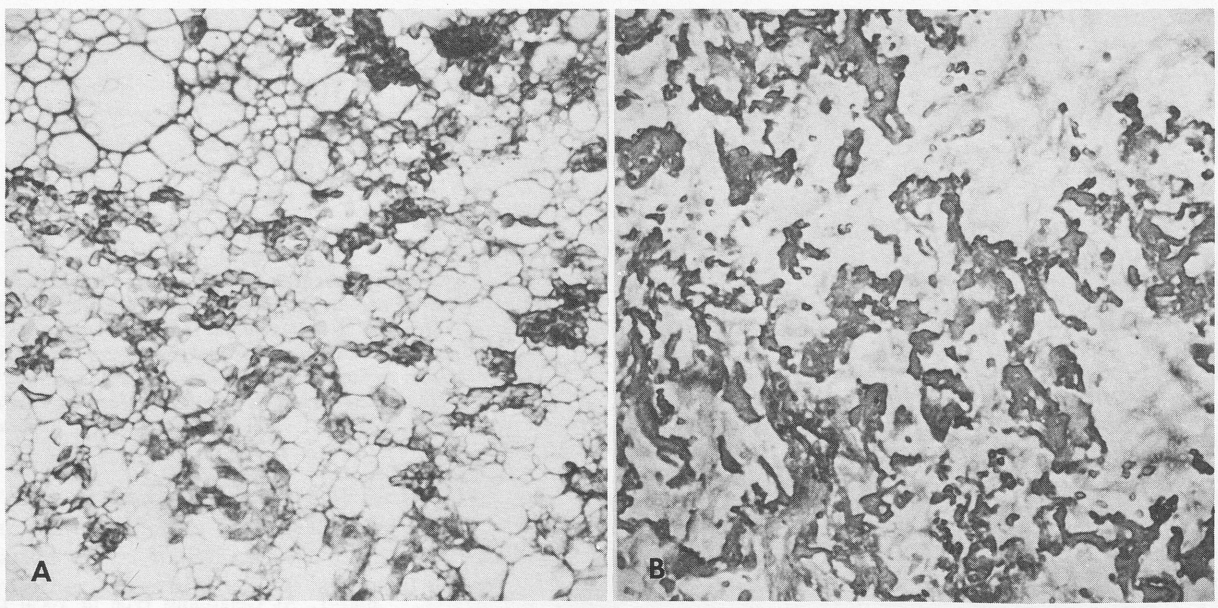

Fig. 2. A) Exudation of a thin fluid in a gelatinous polyp. B) In another case within the mucoid material more dense eosinophilic deposits appear which could be identified as fibrin. (x100)

tures are very similar to the organization of a thrombus. Gaps in the endothelial-lined sinus-like blood vessels cause the further efflux and the deposition of more blood constituents, and allow the increase in size of a polyp. Gelatinous and telangiectatic polyps have presumably the same formal genesis, since the slimy edema and the fibrinous secretions obviously are only expressions of a different permeability of the vascular walls.

Coming back from histopathogenesis to clinical observations: polyps develop with few exceptions on the middle of the surface of the vocal muscle. This is the place where the maximal aerodynamic and muscular forces hit one another during phonation, and most of our patients report an intensive use of their voices. Etiologically the human vocal cord polyps therefore could be considered as the results of a phonotrauma.

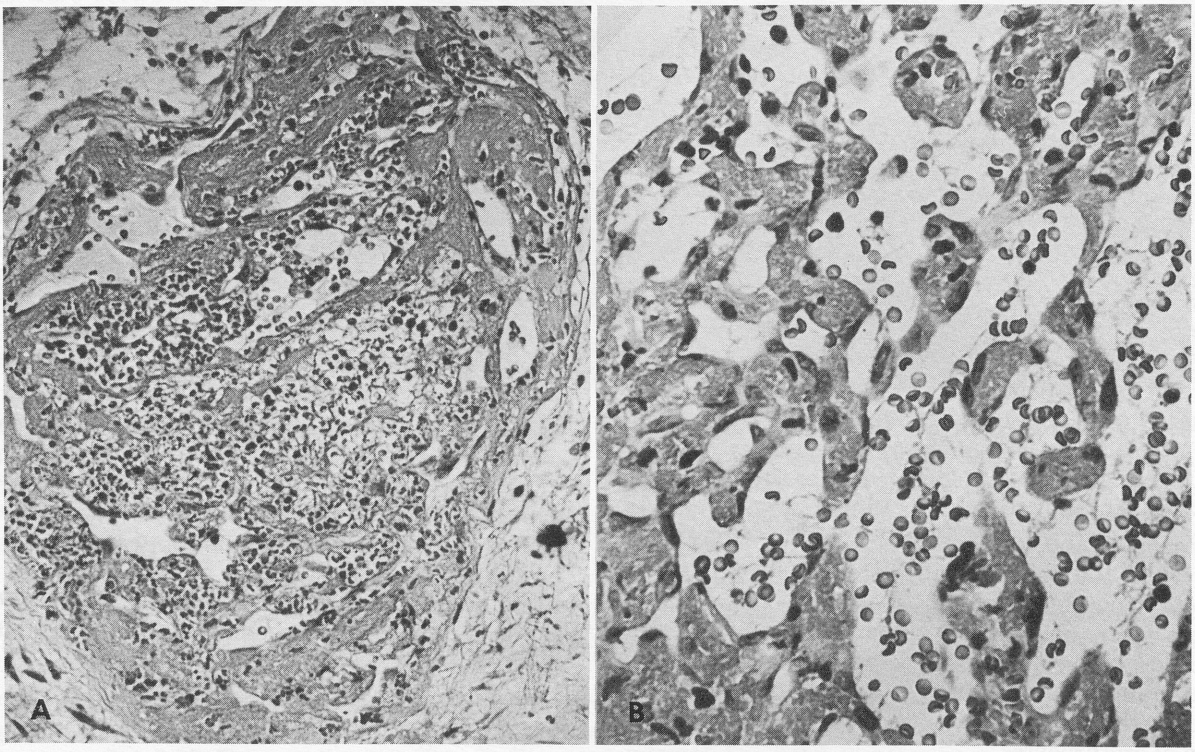

Fig. 3. A) Glomerulus-like labyrinth which develops during organization of a fibrin deposit (x80). B) Sponge-like labyrinth of vascular spaces lined with endothelial cells in the process of organization of a fibrin deposit (x400).

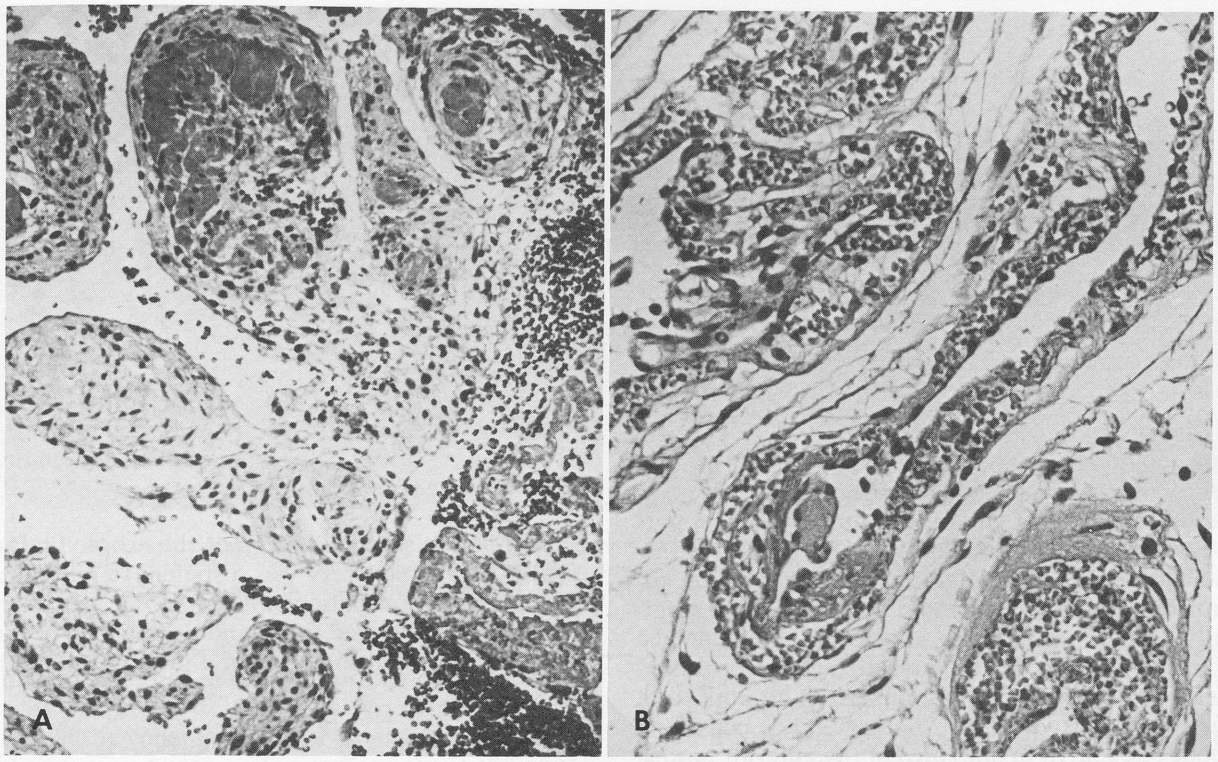

Fig. 4. A) Bud-like endothelial proliferations as a part of the organization process (x100). B) Newly formed vascular spaces in a mainly gelatinous polyp (x200).

REFERENCES

1. Frenzel H, Kleinsasser O, Hort W. Licht- und elektronenmikroskopische Untersuchungen am Stimmlippenpolypen des Menschen. Virchows Arch Pathol Anat Histol 1980; 389:189-204.

ENDOSCOPIC REHABILITATION OF THE AIRWAY IN LARYNGEAL PARALYSIS

FERNANDO R. KIRCHNER, MD, FACS

KANSAS CITY, KANSAS

This paper deals with the three most commonly encountered laryngeal problems that are related directly or indirectly to laryngeal paralysis. These problems are compromised airway secondary to excessive injection of Teflon paste, abductor paralysis of the vocal cords and posterior commissure laryngeal webs.

The dissecting microscope plus the use of focal heat, whether applied by the microcautery[1-5] or the laser beam, for surgical purposes has greatly expanded the field of endoscopic surgery. This report is based on two observations previously reported by the author. 1) The anatomical compartment occupied by the thyroarytenoid muscles may be surgically used to enlarge the airway by removing the fibers of this muscle and lateralizing the vocal ligament. 2) The posterior commissure is an important part of the airway since the arytenoids constitute about one fourth to one third of the anterior posterior diameter of the glottic aperture.

The purpose of this presentation is to describe three simple endoscopic techniques that have been used and the results that have been obtained in the rehabilitation of the airway in patients with 1) unilateral adductor paralysis with compromised airways secondary to excessive injections of Teflon; 2) bilateral abductor paralysis of the vocal cords; 3) revision surgery after arytenoidectomies that fail to produce adequate airway because of the formation of posterior commissure web.

EXCESSIVE INJECTION OF TEFLON

Teflon particles suspended in glycerin when injected in adequate amount into the thyroarytenoid muscle produce an indolent and stable granuloma.[6] This technique has been widely used as an augmentation procedure to accomplish the medial displacement of a laterally paralyzed vocal cord to improve voice and cough. Variable degrees of airway obstruction ensue, however, when the amount of Teflon is grossly increased and the site of injection improperly selected.

In the past several years 11 patients with airway obstruction after Teflon injection, including 2 with indwelling tracheostomies, have been successfully rehabilitated using the microcautery and simple endoscopic approaches. The anatomical distortion encountered in most of them has been either exophytic bulges or large intramural distortion producing imbrication of one cord upon the other or a combination of these two forms.

While the simple excision of the exophytic bulge with the microcautery was sufficient to rehabilitate the first group of patients, it required the excision of a block of infiltrated tissue and drainage to produce the improvement in the second group of patients.

LATERALIZATION OF VOCAL CORDS

The technique of lateralization of vocal cords has been used in 22 patients with bilateral abductor cord paralysis. All of these procedures were carried out with the aid of the microcautery, using routine endoscopic approaches.

The treatment consisted in the segmental removal of the thyroarytenoid muscle fibers adjacent to vocal ligament down to the conus elasticus medially and the thyroid cartilage laterally (Fig. 1A, B). This surgical excision is easily carried out with microcautery. The resultant surgical defect is then closed after lateralizing the vocal cord by means of two sutures of No. 2 Prolene that are introduced into the endolarynx above and below the vocal ligament through the lumen of two hypodermic needles (Fig. 1C). The splicing of these two sutures is always performed on the outside after extracting them from the endolarynx through the laryngoscope with the aid of a laryngeal alligator forceps. Adequate tension adjustments of these sutures on the surface of the neck are very important to prevent the sutures from injuring the laterally displaced vocal ligament. This adjustment and permanent fixation is easily accomplished by crimping lead sinkers around these sutures upon a padded button. Occasionally it is necessary to resect with a cup forceps an outstanding vocal process when this portion of the arytenoids protrudes into the airway after the vocal ligament has been lateralized. Three weeks later the stitch is removed via direct laryngoscopy.

Presented at the meeting of the American Laryngological Association, Palm Beach, Florida, May 1-2, 1982.

REPRINTS — Fernando R. Kirchner, MD, 155 South Street, Suite 270, Kansas City, KS 66102.

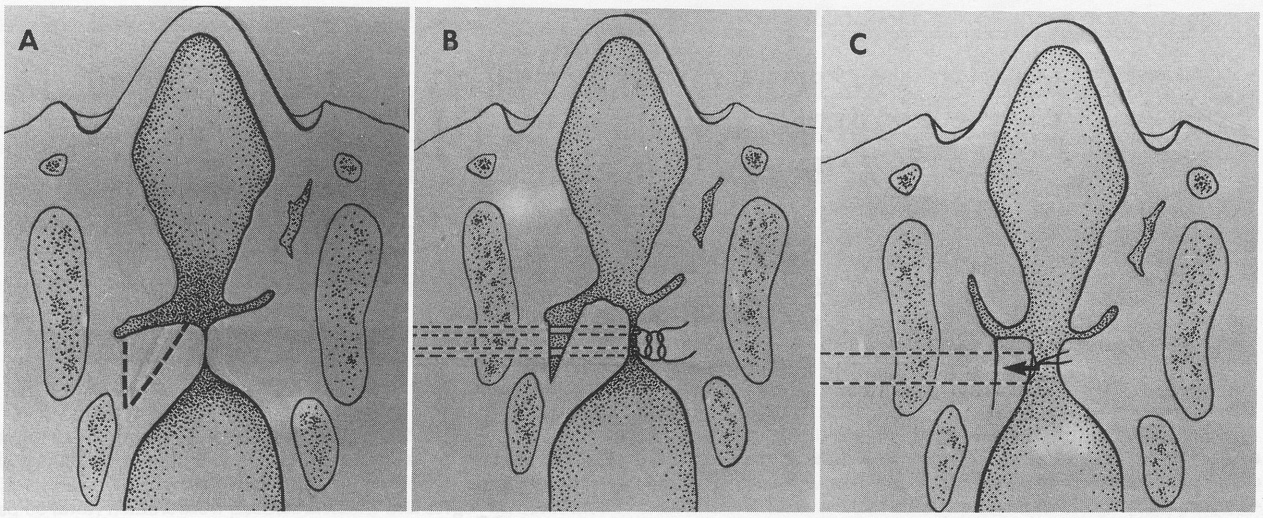

Fig. 1. A) Longitudinal section of larynx demonstrating the compartment occupied by the thyroarytenoid muscle. B) In the lateralization of the vocal ligament a wedge of thyroarytenoid muscle is removed with the microcautery. C) Closure of the defect produced is accomplished with two sutures introduced into the larynx through lumen of hypodermic needles.

Experience gained with these 22 patients has demonstrated that in order to produce a functional airway two requisites are necessary: first, lateralization of the vocal ligament of at least 5 mm, and in addition an anterior posterior diameter of the glottic opening, in the adult, of no less than 22-27 mm in length.

It is important to mention that the voice quality of these 22 patients changed to a more whispery coarse type after the lateralization of the vocal ligament was achieved. All of them, however, preferred this change rather than the alternative of chronic glottic obstruction or the inconveniences of wearing a tracheostomy tube.

REVISION SURGERY AFTER ARYTENOIDECTOMY

The following revision procedures have been successfully used in six patients whose airways remained impaired in spite of arytenoidectomies. The cause of failure of these initial procedures was found to be produced by a posterior cicatricial web that reduced by about one third the anterior posterior diameter of the airway in spite of an apparent adequate lateralization of the vocal cord. In three of these patients the reconstitution of the posterior commissure was accomplished in a rather simple fashion since the web obliteration yielded to a linear incision with minimal epithelial denudation. To avoid reformation of the web, however, a piece of reinforced Silastic sheeting was inserted into the surgical crevice and held in place by two parallel sutures, introduced into the larynx by two transfixion sutures using Keith needles from the right surface of the neck to the left surface with endoscopic guidance and visualization.

In the remaining three patients the scarred tissue was found to be broader and thicker in nature and, therefore, a wider incision became mandatory. A split-thickness skin graft was coadapted to the Silastic sheeting in order to provide the necessary epithelial coverage because of the extension of the epithelial denudation, which, when measuring the two surfaces, amounted to more than one square centimeter. The sutures and Silastic sheeting were removed six weeks later.

REFERENCES

1. Kirchner FR, Toledo PS. Microcauterization in otolaryngology. Arch Otolaryngol 1974; 99:198-202.

2. Kirchner FR, Duff WE. Treatment of laryngeal and ear strictures by microcauterization. Laryngoscope 1974; 84:1326-31.

3. Kirchner FR. Microcauterization in pediatric patients. Trans Am Acad Ophthalmol Otolaryngol 1975; 80:325-55.

4. Kirchner FR. Endoscopic lateralization of the vocal cords in abductor paralysis of the larynx. Laryngoscope 1979; 89;1779-83.

5. Kirchner FR. Suturing techniques in endolaryngeal surgery. Laryngoscope 1981; 91:1860-4.

6. Kirchner FR, Toledo PS, Svoboda DJ. Studies of the larynx after Teflon injection. Arch Otolaryngol 1966; 83:350-4.

PREDICTIVE FACTORS OF SUCCESS OR FAILURE IN THE ENDOSCOPIC MANAGEMENT OF LARYNGEAL AND TRACHEAL STENOSIS

GEORGE T. SIMPSON, MD, MPH
M. STUART STRONG, MD
GERALD B. HEALY, MD
STANLEY M. SHAPSHAY, MD
CHARLES W. VAUGHAN, MD
BOSTON, MASSACHUSETTS

Stenosis of the larynx and/or trachea presents perplexing problems. No one technique has proved totally satisfactory in the management of all varieties of stenosis. Recent reports have described the successful use of the CO_2 laser in the endoscopic management of stenosis of the larynx and trachea. Failures of this technique need emphasis to assure appropriate selection of therapeutic method. Retrospectively, 49 cases of laryngeal stenosis, 6 cases of tracheal stenosis and 5 cases of combined laryngeal and tracheal stenosis were studied (total 60 patients) following treatment at the Boston University Affiliated Hospitals. Follow-up ranged from 1 to 8 years. Multiple procedures were required in 35 laryngeal patients. Of the laryngeal patients 39 were successfully managed (average number of procedures in successful cases 2.18). Of 11 tracheal patients with combined laryngeal and tracheal procedures, 3 were successfully managed (average number of procedures in successful cases 6). Failures in laryngeal stenosis included four patients in whom an adequate airway was not established though voice was present while maintaining tracheostomies. Thirteen patients failing endoscopic management required open surgery with good result. Factors associated with poor result or failure include circumferential scarring with cicatricial contracture, scarring wider than 1 cm in vertical dimension, tracheomalacia and loss of cartilage, previous history of severe bacterial infection associated with tracheostomy, and posterior laryngeal inlet scarring with arytenoid fixation. In these circumstances, multiple procedures, more extensive alternative open surgical techniques, or maintenance of tracheostomy were necessary. In successful cases only three or fewer procedures on average were required. The factors associated with failure or success of endoscopic methods in the management of laryngotracheal stenosis, including use of the CO_2 laser and soft Silastic stents, are analyzed.

INTRODUCTION

Stenosis of the larynx and trachea can present perplexing problems. While not new, these clinical entities now most often result from different causes than previously. Caustic ingestions are far less frequent, and the infectious diseases associated with stenosis are now infrequent. New knowledge of physiology and advances in applied technology have allowed prolonged life-support efforts with artificial ventilatory support mechanisms. These methods, unfortunately, are sometimes associated with subsequent laryngeal and tracheal stenosis following airway trauma. High speed motor vehicle accidents produce crushing injuries to airway structures. New surgical techniques, such as cryosurgery and the laser, if used inappropriately, without adequate skill or precautions, may severely injure airway structures.

Whatever the cause, the clinical problems are the same. The surgeon facing them must select the most effective method, but on what factors should he base his decision?

The methods available for the surgeon's selection are of two general categories. Endoscopic methods include traditional dilatation and newer techniques utilizing stents and laser excision of stenotic areas, all having the advantage of lessened morbidity and hospitalization. Open surgical methods involve excision of stenotic lesions followed by reconstruction, but require perhaps greater costs in time and resources, with greater potential morbidity. Both methods can be effective if used properly.

In an effort to understand what factors may be associated with the successful use of endoscopic methods in the management of laryngeal and tracheal stenosis, we undertook a study of a series of cases managed endoscopically. Specifically, the factors which appeared associated with failure were sought.

MATERIALS AND METHODS

Sixty patients undergoing endoscopic treatment for laryngeal, tracheal or combined laryngotracheal stenosis between 1974 and 1981 at Boston University Affiliated Hospitals and whose records were available for review were subjected to retrospective analysis. Follow-up was from 1 to 8 years. The patients' ages ranged from two months to 72 years. The series included 49 cases of laryngeal stenosis, 6 cases of tracheal stenosis and 5 cases of combined laryngeal and tracheal stenosis. Laryngeal stenosis cases were further classified into supraglottic (6 cases), glottic (12 cases), and subglottic stenosis (31 cases) for analysis.

Of the 6 supraglottic stenosis patients, 4 followed supraglottic laryngectomy, 1 developed with Crohn's disease, and 1 followed blunt trauma.

Glottic stenosis was present in 12 patients and resulted from endolaryngeal intubation in 5. Congenital webs were present in two

From the Department of Otolaryngology, Boston University School of Medicine.
Presented at the meeting of the American Laryngological Association, Palm Beach, Florida, May 1-2, 1982.
REPRINTS — George T. Simpson, MD, Department of Otolaryngology, Boston University School of Medicine, 720 Harrison Avenue, Boston, MA 02118.

SUCCESSES AND FAILURES IN ENDOSCOPIC MANAGEMENT

	No. of Cases	*Successes* No. %	*Average No. of Endoscopic Procedures to Success*	*Failures* No. %	*Failures Successfully Treated with Open Surgery*	*Failures with Good Voice but Tracheostomy*
Laryngeal						
Supraglottic	6	4 (66.7)	1.25	2 (33.3)	1*	1
Glottic	12	9 (75.0)	1.66	3 (25.0)	2	1
Subglottic	31	25 (80.6)	2.44	6 (19.4)	4	2
Subtotal	49	38 (77.5)	2.11	11 (22.4)	6	4
Tracheal	6	2 (33.3)	6.0	4 (66.7)	3	1
Laryngeal & tracheal	5	1 (20.0)	1.0	4 (80.0)	4	2
Total	60	41 (68.3)		19 (31.7)	13 (21.7)	7 (11.7)

*Deceased.

patients. Postsurgical webbing, partial laryngectomy (vertical hemilaryngectomy), rheumatoid arthritic cricoarytenoid joint fixation, ideopathic cricoarytenoid joint ankylosis, and posttraumatic arytenoid fixation each produced one case of glottic stenosis.

Thirty-one patients had subglottic stenosis; 25 of these were secondary to endotracheal intubation. High tracheotomy produced two cases and two followed blunt trauma. Median thyrotomy for endolaryngeal surgery resulted in one case of subglottic stenosis. One patient had ideopathic subglottic stenosis for which no etiology could be identified.

All six cases of tracheal stenosis followed prolonged intubation and tracheotomy for respiratory assistance, as did all five cases of combined laryngeal and tracheal stenosis.

Florid bacterial infection associated with tracheotomy was identified as a precipitating factor in four patients with combined stenosis and one patient with subglottic stenosis.

One patient with combined stenosis and one with subglottic stenosis were each found to have retained nonabsorbable suture fragments from previous open surgeries present in the stenotic area.

Forty-five patients had tracheotomies present at the time of initial presentation: 4 with supraglottic stenosis, 3 with glottic stenosis, 29 with subglottic stenosis, 5 with tracheal stenosis, and 4 patients with combined laryngeal and tracheal stenosis.

All patients underwent endoscopic examination and treatment under inhalation general anesthesia provided via tracheostomy tube, when present, venturi ventilation, or ventilating bronchoscope, as necessary. Laryngeal exposure was provided by using Jako-Pilling laryngoscopes suspended by the Boston University-Pilling gallows or the Lewy suspension apparatus. Carbon dioxide surgical lasers (25-50W) coupled to Zeiss operating microscopes were employed to vaporize scar or granulation tissue, divide fibrotic bands, or excise redundant supraglottic tissue, this being sent for histologic examination.

Silastic stents were employed in 39 patients. One supraglottic stenosis patient had a solid Silastic stent suspended by a single transfixation wire for six weeks. A single sheet of reinforced Silastic was secured between the vocal folds of two glottic stenosis patients with webs (one anterior, the other posterior), suspended by wire in the Kleinsasser method.[1]

Of the 31 cases of subglottic stenosis 27 (87.1%) had soft Silastic roll stents secured in the subglottic area by the Evans method,[2] remaining from 2 to 6 weeks. Similar type roll stents were used in four cases of tracheal stenosis and four cases of combined laryngeal and tracheal stenosis.

Dilatation was employed in four cases each of tracheal and combined laryngeal and tracheal stenosis. No laryngeal stenosis patients underwent dilatation.

For purposes of analysis, successful patients were defined as those with good airway and voice and without tracheostomy, and not requiring further endoscopic manipulation of their airway either by laser excision or ablation, or by dilatation. Cases were classified as failures of endoscopic management if open surgical procedures were necessary, if continued tracheostomy was required for airway maintenance even with a good voice, or if recurrent endoscopic procedures were necessary to maintain voice or airway.

In successful cases, the numbers of endoscopic procedures required to produce the desired result were studied. All failures were then analyzed to determine pre-existing or concurrent factors which seemed contributory to the failure.

RESULTS

Forty-one cases (68.3%) of laryngeal, tracheal, or combined laryngeal and tracheal stenosis were successfully managed by endoscopic techniques (table). Nineteen cases (31.7% of the total) were classified as failures. Eleven laryngeal stenosis cases (22.4%), 4 tracheal stenosis cases (66.7%) and 4 with combined stenoses (80%) resulted in failure. A total of 13 cases (21.7%) required open surgery: 6 laryngeal (12.2%), 3 tracheal (50%) and 4 combined stenosis (80%). The remainder of the failures maintained tracheostomies with good voices.

Supraglottic Stenosis. Of 6 patients with supraglottic stenosis, 4 (66.7%) were managed endoscopically with success. The average number of endoscopic procedures required for a successful result was 1.25.

The two failures both had recurrent stenosis. One died of metastatic cancer, probably from the original supraglottic primary, but autopsy could not be obtained to confirm this. The other patient retained a tracheotomy with good voice. Both failures had reformation of cicatricial scarring in the supraglottic area. Both had tracheostomies present and one had five endoscopic procedures without success. Both were adults. No infection was associated with their endoscopic or previous (supraglottic laryngectomy) surgery. No stents had been employed in either failure.

Glottic Stenosis. Among 12 patients with glottic stenosis 9 (75%) achieved a successful result. This required an average of 1.66 endoscopic procedures. Three of the 9 had glottic webs, 3 had fibrotic bands between the vocal processes (postintubation),

2 had cricoarytenoid ankylosis and 1 had had a previous vertical hemilaryngectomy.

Three cases (25%) were failures, 2 requiring open surgery and 1 with good voice but maintaining a plugged tracheostomy and not desiring decannulation (but listed as a failure). Two of the failures had posterior fibrotic webbing resulting from prolonged endotracheal intubation in one patient and a traumatic intubation in the other. This webbing reformed after removal reproducing arytenoid fixation. The third failure occurred in the patient with arytenoid fixation following blunt trauma who underwent unsuccessful arytenoidectomy, but required a subsequent open procedure. In contrast, both patients with arytenoid fixation from rheumatoid arthritis and from idiopathic cause underwent successful arytenoidectomies using the laser. All three failures had tracheostomies as opposed to none of the successful cases. None of the glottic stenosis patients had a bacterial infection, scars that were circumferential or wider than 1 cm in depth, or history of cryosurgery. All failures were adults. None of the failures had had a stent.

Subglottic Stenosis. Thirty-one patients presented with subglottic stenosis; of these, 25 (80.6%) were managed endoscopically with a successful result, requiring an average of 2.44 endoscopic procedures. In 21 of these 25 cases (84%), soft Silastic stents were employed. Twenty of the successfully managed cases of subglottic stenosis followed endotracheal intubation (80.6%), while 2 had resulted from blunt trauma and 2 from high tracheotomy. One followed tracheotomy and median thyrotomy for a benign laryngeal lesion.

Six cases of subglottic stenosis (19.4%) were failures to endoscopic management methods. Four required open surgical procedures with successful result. One continues with plugged tracheostomy awaiting growth and one continues with functioning tracheostomy with a good voice.

Five of the 6 cases of failure (83.3%) had a tracheostomy on initial presentation but 29 of the total 31 cases of subglottic stenosis (93.5%) had tracheostomies similarly present. Five of the six cases of failure (83.3%) had presented following endotracheal intubation. Four of the cases (66.7%) resulting in failure had circumferential cicatricial scarring as opposed to 17 of the 31 total cases of subglottic stenosis (54.8%) and 12 of 25 successful cases (48%). Subglottic stenosis wider than 1 cm in vertical dimension was present in 3 cases of failure (50%), 15 of the total cases (48.4%) and 13 (52%) of the successfully managed cases. The incidence of preceding infection could not be adequately assessed to allow analysis. All cases resulting in failure had employed a stent (100%) while 21 of the 31 total cases of subglottic stenosis (71%) used stents. No prior cryosurgery was recorded at presentation in the 31 subglottic stenosis cases. No age relationship was evident as 5 of the failures (83.3%) and 22 of the successes (88%) were below 6 years of age.

Tracheal Stenosis. Two of the six cases of tracheal stenosis (33.3%) were successfully managed endoscopically. These two required an average of six endoscopic procedures to obtain a successful result. Both successful patients developed tracheal stenosis following intubation. One had undergone 4 previous operations elsewhere including tracheal resection of a 2 cm-wide stenotic ring with end-to-end anastomosis and 3 dilatations and required 4 further procedures: 2 laser excisions and 2 dilatations. The other patient had previously undergone 5 dilatations performed elsewhere and required 1 laser excision and 2 dilatations for a successful result. Neither case presented with tracheostomy and no stents were used. Both had narrow shelf-like noncircumferential stenosis.

Four of the six cases of tracheal stenosis (66.7%) resulted in failure. All 4 (100% of failures) had circumferential scarring wider than 1 cm, loss of tracheal cartilage and tracheomalacia, and tracheostomy present. Three of the failures (75%) had bacterial tracheal infection associated with tracheotomy prior to presentation. Three of the 4 failures were less than 6 years of age, while both successes were adults, and 3 of the total 6 (50%) were less than 6 years of age. Cryosurgery had been employed in one of the six total cases (16.7%) and this was a failure (25% of failures). Stents had been employed in all cases resulting in failure. Three failure patients were treated successfully with tracheal resection and end-to-end anastomosis. The other patient has a good voice with tracheostomy.

Combined Laryngeal and Tracheal Stenosis. Only one of the five patients having combined stenosis (20%) was treated successfully with endoscopic methods. This 2-year-old patient developed multiple fibrous bands in the larynx and proximal trachea after being intubated for croup. The bands were lysed with the laser and only one endoscopic procedure was necessary.

The remaining four cases of combined stenosis (80%) were failures. All had circumferential cicatricial scarring wider than 1 cm, significant loss of cricoid and tracheal cartilage and had preceding bacterial infections associated with their tracheostomies. One patient had elsewhere undergone more than 12 previous endoscopic surgeries including 6 cryosurgical applications. This patient was under ten years of age and represents 20% of the total number of combined stenosis patients and 25% of the failures. All four failures had stents employed.

DISCUSSION

Endoscopic management of laryngeal stenosis at all levels seems readily justified when the results are analyzed. Of all laryngeal stenosis cases 77.6%

were managed successfully, though 71.4% required multiple endoscopic procedures. Successful endoscopic management was possible in all parts of the larynx as shown by the success rates of 66.7% for supraglottic stenosis, 75% for glottic stenosis, and 80.6% for subglottic stenosis. These results also support the use of the carbon dioxide laser as a surgical instrument, as the laser was employed in all cases, whether or not a successful result ensued.

It is clearly apparent that purely endoscopic techniques are unsuccessful in most cases of severe tracheal stenosis and combined laryngeal and tracheal stenosis especially if the stenotic areas are wide, are circumferential, or if they are accompanied by significant loss of cartilage in the cricoid or trachea. Successfully managed cases in tracheal or combined stenosis showed more limited discrete lesions. Therefore, open operations should be employed in cases of extensive tracheal and combined stenosis. Endoscopic methods, however, may be justified in the initial management, if only to establish a lumen which later may be of help at open operations.

A major cause of failure at all levels was the reformation of the scar tissue following its excision. Abundant scar tissue of over 1 cm of vertical dimension, and/or if circumferential, was present in all failures at all levels except subglottic, where it was in the majority. Of special note is the observation that 2 cases of glottic stenosis involving fibrotic scar tissue in the interarytenoid area of the posterior commissure were failures to endoscopic management. This type of glottic stenosis seems best considered from the beginning for open surgical correction.

It would seem obvious that excessive application of laser energy should produce unnecessary necrosis in nearby tissue with resultant undesired scar-tissue formation. Such a factor in any failure proved difficult to analyze in this series as the cases resulting in failure did not seem to receive greater amounts of laser energy or longer periods of its application than did similar cases managed successfully. Experience with stenosis following widespread prolonged application of the laser, however, demands prudent caution. Extensive excision of severe subglottic stenosis proved successful if performed with brief (0.1 to 0.5 seconds), interrupted bursts of laser energy.

Superficially, tracheostomy would seem to be associated with failure, as a tracheostomy was present prior to endoscopic management attempts in all cases resulting in failure. It must be remembered, however, that tracheostomies existed in 75% of the total group on initial presentation, and were always necessary in the most severe cases of stenosis at any level. Furthermore, 93.5% of subglottic stenosis patients had tracheostomies present initially, yet 80.6% were successfully managed by endoscopic techniques alone, and 96% of the successful cases had tracheostomies.

A more significant factor in failure, and one associated with tracheostomy, is bacterial infection. While infection had not occurred in supraglottic and glottic stenosis cases, and could not be determined accurately in cases of subglottic stenosis, it represents a major pre-existent or predisposing factor in tracheal and combined stenosis. At these levels 87.5% of failures had sustained a severe bacterial infection of the trachea following tracheostomy and prior to any endoscopic management by our group. Such a history may predict the necessity of open surgery for management of tracheal stenosis alone or combined with other stenosis. The possibility of recurrent infection during endoscopic management with potential sequelae and failure may urge the endoscopic surgeon to employ antibiotics. Further data on patients in this series, now undergoing analysis, may support the use of prophylactic antibiotics in the endoscopic management of stenosis.

Of failing cases, 73.3% had a history of intubation prior to the diagnosis of stenosis, compared with 66.7% of the total series. A similar history was found in 72.5% of the cases managed endoscopically with success.

Soft Silastic stents were employed in all cases resulting in failure in subglottic, tracheal, and combined stenosis, but were associated with success in all cases where used in the supraglottis or glottis. Soft Silastic stents were used in 84% of the successful subglottic stenosis cases. As stents are obviously of benefit, especially in severe stenosis, and were so used, it appears that their use is not a factor in failure. Rather, the use of stents is associated with the most severe degrees of stenosis as it is here that they are most helpful.

Patient age was not associated with failure for endoscopic methods in any type of stenosis. In fact, in subglottic stenosis, 88% of the successful patients were less than 6 years of age, while 77.1% of all subglottic stenosis patients were in this age group. While three of the four failures in tracheal stenosis were patients under 6 years of age, they also were the patients with the most severe stenosis.

Cryosurgery had been previously employed elsewhere in one patient each with tracheal and combined stenosis who failed endoscopic management. Its prior use cannot be specifically indicted, however, as the relationship of the cryosurgery and the severe stenosis cannot be accurately determined. A history of previous cryosurgical techniques in a patient with severe stenosis may warn of future difficulties for endoscopic management methods.

Dilatation was not required at any time in virtually any patient in this series. It did prove helpful, however, in two patients with tracheal stenosis successfully managed endoscopically.

SUMMARY

Endoscopic management methods, including, as required, CO_2 laser excision, soft Silastic stents, and dilatations, are successful in most cases of laryngeal stenosis at all levels and of all etiologies. Endoscopic methods are successful only infrequently in major stenosis involving the trachea, either alone or in combination with laryngeal stenosis. To be managed endoscopically with success, stenosis involving the trachea must be limited in extent and without significant associated loss of cartilage, circumferential cicatricial stenosis or scarring wider than 1 cm in vertical width.

Major factors associated with failure of endoscopic management of stenosis at all levels of the larynx and trachea include preceding severe bacterial infection associated with tracheostomy, circumferential cicatricial scarring, scar tissue wider than 1 cm in vertical dimension and fibrotic scarring of the posterior laryngeal inlet with arytenoid fixation. Endoscopic management techniques should be considered with caution in the presence of a history of cryosurgery in the prior treatment of airway stenosis.

With consideration of these factors, the surgeon may choose either to proceed directly to open surgical methods, or to manage laryngeal and tracheal stenosis endoscopically with the expectation of a high likelihood of success.

ACKNOWLEDGMENT — We wish to express our gratitude to Mrs. Edna Joyner for the preparation of the manuscript.

REFERENCES

1. Kleinsasser O. Microlaryngoscopy and endolaryngeal microsurgery. Stuttgart: Schattauer-Verlag, 1976:156.

2. Evans JNG, Todd GB. Laryngotracheoplasty. J Laryngol Otol 1974; 88:589-97.

DIAGNOSIS AND CONSERVATIVE SURGICAL MANAGEMENT OF CHONDROSARCOMA OF THE LARYNX

JULIUS N. HICKS, MD
E. EARL WALKER, MD
E. EUGENE MOOR, MD
BIRMINGHAM, ALABAMA

Tumors of cartilage rarely occur in the larynx. Most laryngologists see no more than one of these tumors. Therefore, information about the general knowledge, early diagnosis, and surgical treatment of these tumors accumulates slowly. In this paper we will discuss one type of cartilaginous tumor: chondrosarcoma of the cricoid cartilage. We will review general diagnostic information about this tumor, present a case report, and describe a method of conservative surgical excision.

INTRODUCTION

Cartilaginous tumors of the larynx occur as isolated cases in the practice of laryngology. Travers reported a case to the Medico-Chirurgical Society of London in 1816.[1]

Chondrosarcoma of the larynx is usually of low-grade malignancy and does not respond to treatment with irradiation and chemotherapy. Treatment is limited to surgical excision. The exact surgical procedure will vary from simple excision for a neoplasm of limited size and low-grade malignancy to total laryngectomy for a tumor of extensive size or high-grade malignancy.

Chondrosarcoma of the larynx is reviewed, with diagnostic factors outlined; the surgical treatment described; and a case reported. A conservative method of surgical excision of a chondrosarcoma arising in the cricoid region is described.

REVIEW

Incidence. The case reports of approximately 200 cartilaginous tumors of the larynx from 1816 to 1979 indicate 20% to be chondrosarcomas.[2] A review of 58 cases of chondrosarcoma of the larynx during a recent period of 80 years reveals an average patient age of 58 years, and there were 43 males and 15 females.[3]

Clinical Findings. The symptoms of chondroma of the larynx are those of any mass growing slowly inside the lumen of the larynx: hoarseness, dyspnea, and dysphagia. These symptoms are related to the location and size of the tumor. A lesion of the cricoid extending into the laryngeal lumen can cause decreased air flow and vocal cord mobility. Growth of a cricoid lesion posteriorly and laterally into the hypopharynx can cause dysphagia.

Location of Tumor in Larynx. Laryngeal chondrosarcomas usually arise from hyaline cartilage and show no evidence of elastic tissue. There is a striking predilection for the tumor to form in the region of the cricoid cartilage. A review of chondrosarcoma of the larynx has been done at the Armed Forces Institute of Pathology (AFIP).[4] This AFIP series notes 16 cases from 1929 to 1969 and shows that 11 (68%) of these tumors occurred in the cricoid region.

Etiology. The etiology of chondrosarcoma is unknown. Virchow wrote in 1863 that these tumors originate from the connective tissue stroma of the normal perichondrium, the body of the cartilaginous tissue, or the cartilaginous cell nests which serve as a matrix and then undergo ossification.[5] No scientist has offered a better explanation for the etiology of chondrosarcomas.

Clinical Diagnosis. The clinical diagnosis of chondrosarcoma is made on the basis of the history, physical examination, radiologic findings, and histopathologic findings. The patient presents with a history of hoarseness, dyspnea or dysphagia. Indirect laryngoscopy can reveal a smooth, rounded mass below the true vocal cords. Soft tissue x-ray films or xeroradiograms of the larynx can demonstrate the tumor. Mottled calcification is seen within the tumor in up to 75% of the soft tissue x-ray studies.[6] Planigrams can outline the tumor, but the CT scan can demonstrate the exact origin of the tumor.

The definitive diagnosis is made in the operating room with direct laryngoscopy and biopsy. Histopathological criteria which indicate a chondrosarcoma have been established by Lichtenstein and Jaffe:[7] 1) irregularity in the size of the cells and their nuclei; 2) increased numbers of cells; 3) hyper-

From the Division of Otolaryngology and Head and Neck Surgery, Department of Surgery, University of Alabama Hospitals and Clinics, Birmingham.
Presented at the meeting of the American Laryngological Association, Palm Beach, Florida, May 1-2, 1982.
REPRINTS — Julius N. Hicks, MD, Division of Otolaryngology and Head and Neck Surgery, Department of Surgery, University of Alabama in Birmingham Medical Center, University Station, Birmingham, AL 35294.

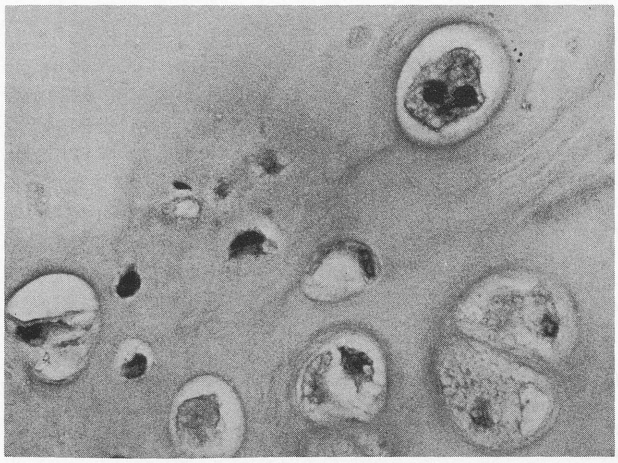

Fig. 1. Section of tumor showing at top a large binucleated cartilage cell which contributes to diagnosis of chondrosarcoma (H & E x600).

chromatic nuclei; 4) giant cartilage cells with single or multiple nuclei. These giant cartilage cells may be binucleated (Fig. 1).

Surgical Treatment. In most cases with significant airway obstruction a tracheotomy secures the airway and allows a direct laryngoscopy and biopsy to be done to establish the diagnosis. After the diagnosis is made, the grade of malignancy must be determined.

Since recurrences occur late and metastases are rare, surgical treatment should be as conservative as possible. Total laryngectomy may be required for a high-grade malignant tumor, a recurrent tumor, or a tumor which cannot be totally removed by a conservative surgical procedure. Adequate excision requires removal of the tumor with a margin of normal tissue. This can usually be done conservatively with a laryngofissure, thyrotomy, or partial laryngectomy. If adequate excision of the tumor requires removal of more than one half of the cricoid cartilage, a laryngectomy must be performed to avoid debilitating laryngeal and tracheal stenosis. In older patients the surgeon can sometimes remove the tumor with a curette and leave an adequate support of cricoid cartilage — the technique that was used in the case report following.

Since nodal metastases to the neck are rare, elective neck dissections are not indicated.

Although the tumor often recurs after conservative surgical treatment, most surgeons prefer laryngofissure exposure and total local excision, since the tumors recur many years later, grow slowly, and permit treatment by additional conservative surgical procedures.

CASE REPORT

A 67-year-old white female was referred to the University of Alabama in Birmingham Medical Center for definitive treatment. She had already been evaluated for periods of episodic shortness of breath. These episodes occurred at any time and had increased in frequency over the past year. A previous bronchoscopy revealed a subglottic mass. Her dyspnea increased and an emergency tracheotomy was performed on June 22, 1981, prior to transfer to the University of Alabama in Birmingham Medical Center for definitive treatment. At the time of the tracheotomy a biopsy was performed, and slides of the tissue were sent to the Armed Forces Institute of Pathology. The histopathological report by the AFIP revealed chondrosarcoma. Our pathology department confirmed this tissue diagnosis.

The patient's past history revealed that a surgeon performed a partial thyroidectomy in 1948, 31 years previously. An internist had ordered thyroid scans yearly for the previous five years.

Physical examination revealed an alert and cooperative female. The examination of the larynx revealed good true vocal cord movement. There was a large mass in the right subglottic region which completely filled the subglottic area except for a 1- to 2-mm space on the left side. The neck was supple, and the tracheostomy tube was in place. There was a 6-cm x 3-cm x 3-cm mass in the right thyroid lobe region. Admission laboratory studies revealed a normal hemogram, urinalysis, EKG and chest x-ray film. The electrolytes were normal. The GTT and alkaline phosphatase were slightly elevated.

A thyroid scan indicated an enlarged thyroid gland with increased uptake activity in the right upper lobe, consistent with multinodular goiter. The CT scan of the neck showed the large thyroid mass in the right neck and the smaller laryngeal mass in the lumen of the larynx and trachea. The laryngeal mass was attached to the right posterior lateral wall of the cricoid cartilage.

After completing the preoperative evaluation, the patient was taken to the operating room where laryngeal surgery was performed. The patient was given endotracheal anesthesia through the tracheotomy opening. The anatomic landmarks of the neck were identified. A skin mark was made with a marking pen for the horizontal skin incision over the midregion of the thyroid cartilage. The vertical limb of the incision was made through the previous vertical tracheotomy scar. After elevation of the skin flap, dissection was carried out to expose the thyroid cartilages. An incision was made through the midline and the superior margins of the perichondrium of the thyroid cartilages. Lateral extensions of the incisions on the superior margin were made to points medial to the superior laryngeal nerves and vessels.

The perichondrium was elevated on each side of all incisions. The larynx was transected in the midline of the thyroid cartrilages with scissors for a laryngofissure incisional approach. The lumen of the cricoid region was viewed by retracting each

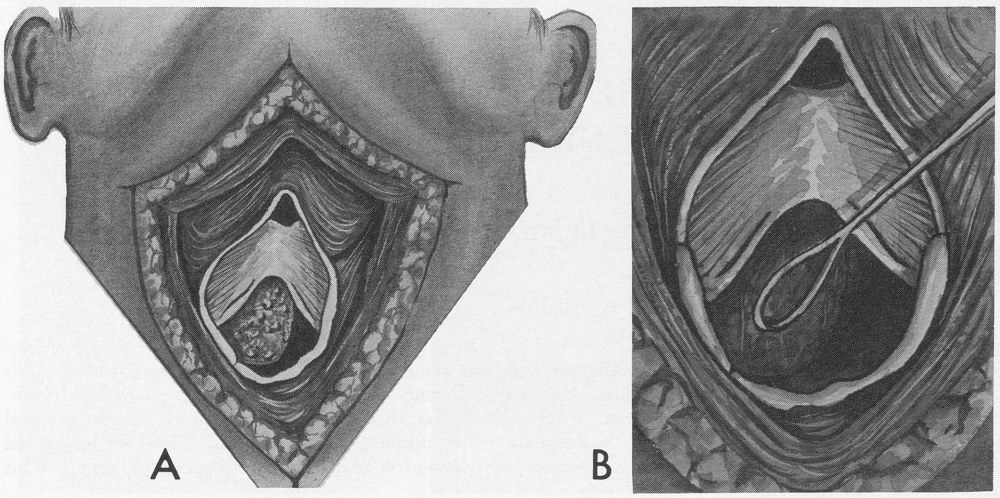

Fig. 2. Drawing showing A) subglottic mass and B) curette placed in raw surface after removal of tumor.

side of the thyroid cartilage with a skin hook. This maneuver exposed the site of attachment of the mass (Fig. 2A). The exact location of the attachment was determined by palpation with a small curette. The mucous membrane was incised so that there was a wide margin of normal mucous membrane around the mass. The mass was removed by curettage at its origin from the cricoid cartilage (Fig. 2B). The mass had a distinct difference in tissue density relative to normal cricoid cartilage. This tissue density could be appreciated during curettage and allowed complete excision of the tumor without taking an excessive amount of normal cricoid cartilage. The cricoid ring was not cut through and the integrity of the laryngeal airway was maintained.

The wound was irrigated with saline. The mucous membrane was cut so it would lie in the defect without tension. At this time the patient appeared to have a very satisfactory operative result.

The perichondrium was closed with 4-0 chromic catgut. A rubber drain was inserted. The muscles were approximated with 3-0 Vicryl sutures. Skin closure was performed with 5-0 nylon vertical mattress interrupted sutures. After the patient was breathing spontaneously, the Anode tube was removed and a No. 6 cuffed Shiley tracheostomy tube was inserted. The patient was awakened and taken to the recovery room in good condition.

The patient's postoperative course was uncomplicated. She was discharged on the third postoperative day to be followed by her referring physician. He decannulated her four weeks after her surgical procedure. It has been over nine months since excision of her tumor and there is no evidence of recurrence.

SUMMARY

The incidence, clinical findings, location, etiology, clinical diagnosis, and surgical treatment of chondrosarcoma of the larynx are discussed. Important features in the diagnosis and treatment of a chondrosarcomatous tumor of the larynx are demonstrated in a case report.

The patient's chief complaint was episodic shortness of breath occurring with increasing frequency over a period of 12 months. Her dyspnea progressed in severity until an emergency tracheotomy was required for airway control.

CT scan documented the attachment of the tumor to the right posterior lateral wall of the cricoid cartilage. Direct laryngoscopy and biopsy were done to obtain tissue for diagnosis. The histopathological examination revealed low-grade chondrosarcoma.

The tumor was removed totally with a wide-margin mucous membrane incision and careful curettement. A definite difference in the consistency of the tumor compared to normal cartilage allowed complete excision of the tumor with minimal sacrifice of healthy cricoid cartilage. This presentation emphasizes the conservative surgical removal of these tumors and notes how a curette can be used for this removal.

REFERENCES

1. Travers F. A case of ossification and bony growth of the cartilages of the larynx. Med Chir Trans 1816; 7:150.

2. Hellquist H, Olofsson J, Grontof T. Chondrosarcoma of the larynx. J Laryngol Otol 1979; 93:1037-47.

3. Cantrell RW, Jahrsdoerfer RA, Reibel JF, Johns ME. Conservative surgical treatment of chondrosarcoma of the larynx. Ann Otol Rhinol Laryngol 1980; 89:567-71.

4. Hyams VJ, Robuzzi DD. Cartilaginous tumors of the larynx. Laryngoscope 1970; 80:755-67.

5. Virchow R. Die Krankhaften Geschwulste. Vol. 1. Berlin: August Hirschwald Verlag 1863:442.

6. Zigmor J, Noyek AM, Lecois JS. Radiologic diagnosis of chondroma and chondrosarcoma of the larynx. Arch Otolaryngol 1975; 101:232-4.

7. Lichtenstein L, Jaffe H. Chondrosarcoma of bone. Am J Pathol 1943; 19:553-74.

CHONDROSARCOMA OF THE LARYNX: EXCISION OF MASSIVE RECURRENCE

FRANCIS E. LEJEUNE, JR, MD, FACS
HERBERT W. VAN HORN III, MD GIST H. FARR, MD
NEW ORLEANS, LOUISIANA

Chondrosarcoma of the larynx is an uncommon, slow-growing malignant tumor of the larynx which tends to metastasize late. This paper adds to the literature a case which was followed for 18 years. During the first three years is was thought to be a benign chondroma. Conservative management by limiting surgical resection, at the patient's direction, allowed observation of the disease for this unusual length of time. Massive enlargement finally necessitated laryngectomy. The lesion, though unquestionably malignant, had not infiltrated adjacent neck structures and appears to have been totally excised, with the patient now being free of disease six months after surgery. This supports the view of conservative surgical management.

INTRODUCTION

Only approximately 200 cases of cartilaginous tumors of the larynx have been reported in the medical literature since 1822. Of these, approximately 20% have been malignant. In Cantrell et al's review,[1] 78% of the tumors arose from the cricoid, usually in the posterior or posterolateral areas. Another 15% arose from the thyroid cartilage. Males outnumbered females approximately 3 to 1. The ages of patients ranged from 33 to 91 years with the average being 58 years. No cases of documented chondroma transforming to malignant tumor have been reported, though one case was suspected.[2] In Ollier's disease, a familial syndrome characterized by multiple chondromatoses, approximately 10% of the cartilaginous tumors may be malignant.

CASE REPORT

In August 1981, a 72-year-old female with a tracheotomy was referred because of a large neck mass and purulent drainage (Fig. 1A). The history revealed that in 1963, at age 54, she had been evaluated by an otolaryngologist because of progressive dyspnea, hoarseness, and a slowly enlarging neck mass. A subglottic mass was noted and a biopsy indicated chondroma. In August 1966, progressive airway obstruction necessitated a tracheotomy. Biopsy again confirmed diagnosis of chondroma. She refused surgery at this time, electing to wear a tracheotomy tube for the next 12 years.

In 1978, she sought medical attention for progressive dysphagia and enlargement of the neck mass (Fig. 1B). In February 1979, she underwent a laryngofissure and partial excision of the mass. Pathologic diagnosis was chondrosarcoma. She refused definitive surgery but she changed her mind after noting drainage of purulent material from the large neck mass. In September 1981 a wide field laryngectomy was performed which appeared to completely excise all tumor. Healing was uneventful. The patient is now six months postsurgical treatment and is without evidence of disease (Fig. 1 C).

HISTOPATHOLOGY

Gross and Microscopic. The surgical specimen measured 12.5 x 9 x 8.5 cm. The cephalic aspect contained the epiglottis and the lower pharyngeal mucosa stretched over the submucosal tumor (Fig. 2 A, B). The caudal aspect of the specimen included the upper trachea, tracheostomy wound and surrounding skin. The anterior aspect of the specimen included portions of the thyroid gland and lymph nodes. The mass was unyielding to firm compression and a band saw was necessary to section the tumor. Contained within soft tissue was a roughly spherical mass having a rim of calcified tissue. The vast majority of the tumor was composed of semi-translucent, friable and focally mucoid material. Approximately midway into the specimen, a sinus tract was found, which extended from a 2-cm abscess cavity to the pinpoint lumen of the trachea (Fig. 2C). The latter was displaced laterally to the extreme left portion of the mass. At no point could tumor be found at a surgical margin. All lymph nodes and the thyroid were negative.

Microscopically, the tumor was a well-differentiated chondrosarcoma with areas of myxoid chondrosarcoma (Fig. 3A,B). Endochondral bone formation accounted for the incomplete bony rim. No areas of anaplastic tumor were identified. Some

From the Departments of Otolaryngology and Pathology, Ochsner Medical Institutions, New Orleans.
Presented at the meeting of the American Laryngological Association, Palm Beach, Florida, May 1-2, 1982.
REPRINTS — Francis E. LeJeune, Jr, MD, Ochsner Clinic, 1514 Jefferson Highway, New Orleans, LA 70121.

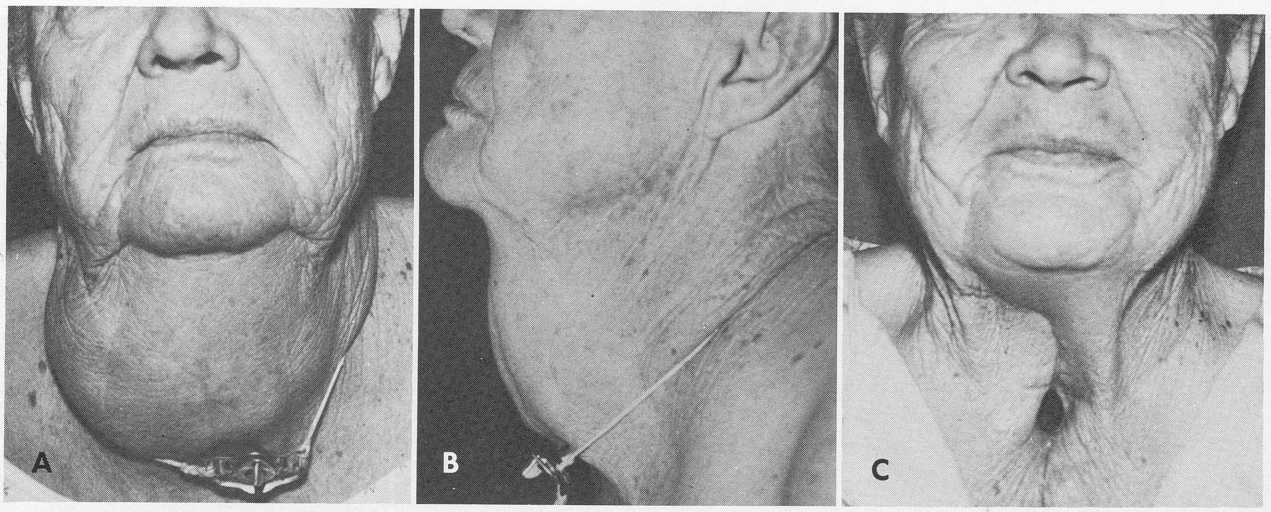

Fig. 1. A) Patient, 72-year-old female, with firm chondrosarcoma measuring approximately 15 x 18 cm, fixed to deep structures. B) Mass distorts neck contours, necessitating tracheotomy and causing progressive dysphagia. C) Six months postlaryngectomy, patient appears to be free of disease, and is being rehabilitated.

areas were very well-differentiated and adequate sampling was necessary to identify the various histologic pictures.

Only material from the 1979 excision was available for review. The tumor appeared no more aggressive in 1981 than in 1979.

DISCUSSION

The classic presentation of chondrosarcoma or of chondroma of the larynx includes hoarseness and dyspnea due to gradual expansion of the intraluminal tumor or dysphagia if the expansion extends toward the hypopharynx. A visible palpable mass will be present if the thyroid cartilage is involved.

At laryngoscopy, a smooth bulging contour is noted in the subglottic region. The mucosa overlying the mass is usually intact. Vocal cord motion may be limited if the mass encroaches. The firm nature of the mass makes the obtaining of an adequate biopsy specimen difficult.

Radiographic signs[3] include the location in the subglottis, often the posterior wall, of a mass which has a smooth surface but contains coarse, irregular scattered calcification; this does not provide a true distinction between benign and malignant masses.

Differential Diagnosis. Differential diagnosis should include the other primary lesions: neurilemoma, cylindroma, rhabdomyosarcoma, fibrosarcoma, calcified carotid artery, calcified thyroid adenoma, cysts, granular cell myoblastoma, amyloidosis, and tracheopathia osteoplastica. Metastatic lesions to the larynx are rare but prostatic and other primaries have been reported.

COMMENT

The slow growth of the lesion in the early years of this case seem to contrast with the more rapid expansion in the last several years. This apparent increase in rate of enlargement in its later states may be merely a function of its doubling time, a factor which can remain constant. To illustrate the exponential increase of this effect, if this page were

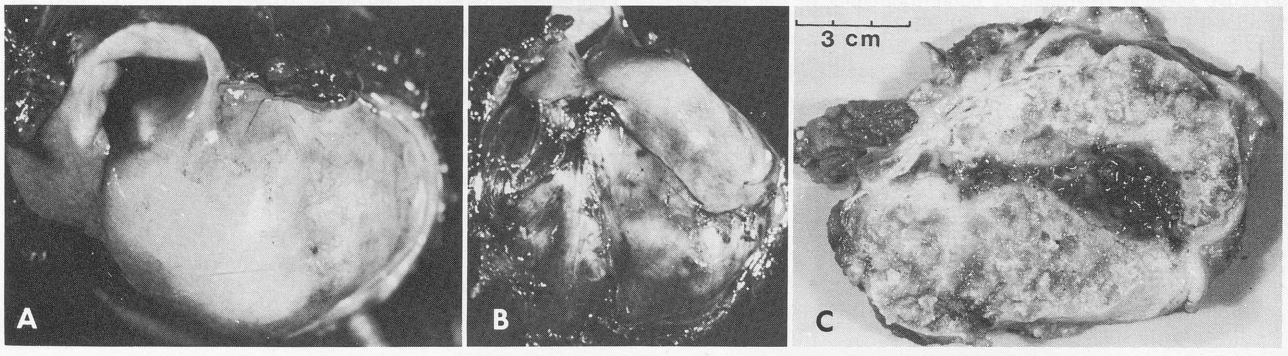

Fig. 2. A) Surgical specimen seen from above. Epiglottis and right arytenoid are seen in center. Mucosa covering right pyriform sinus is displaced by submucosal tumor, obliterating the sinus. B) Laryngectomy specimen viewed posteriorly. Chondrosarcoma mass and larynx measured 12.5 x 9 x 8.5 cm. C) Gross photograph of midsection of specimen, showing abscess cavity at right, with linear sinus tract to pinpoint trachea on the left.

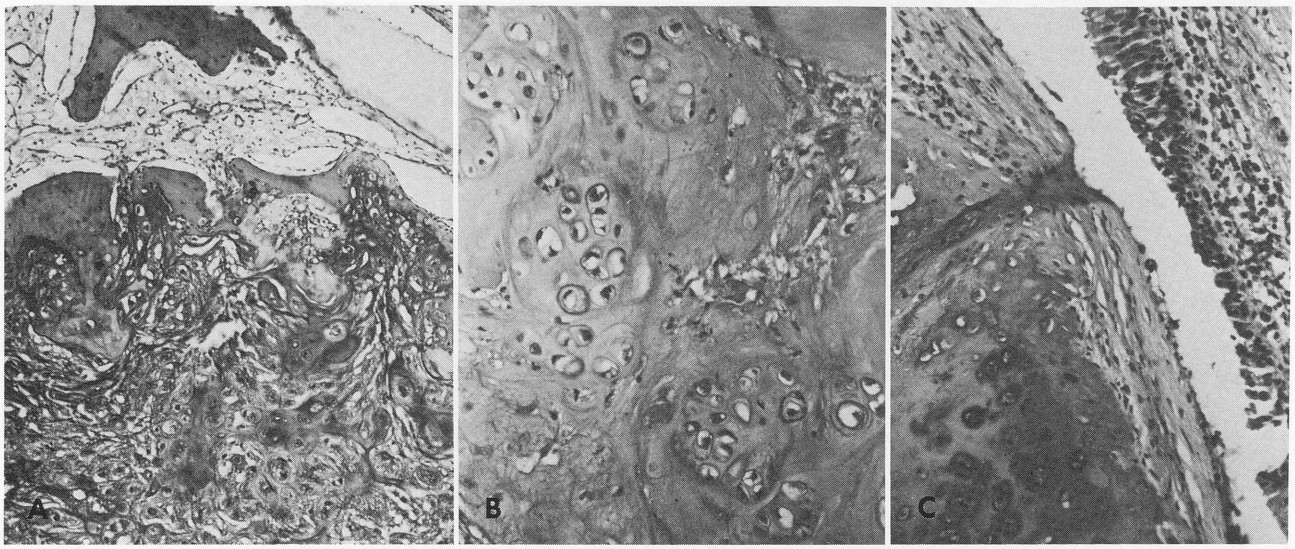

Fig. 3. A) Well-differentiated and myxoid chondrosarcoma, with areas of mature bone formation at periphery (H & E, x40). B) Well-differentiated chondrosarcoma, showing little myxoid change (H & E, x100). C) Pinpoint lumen of trachea, showing submucosal chronic inflammation at bottom and compressing chondrosarcoma at top (H & E, x 100).

torn in half and the two pieces of paper stacked and torn in half again and stacked and this were repeated for a total of 50 times, the stack of paper would reach far beyond the moon.

The apparent change in histologic pattern may represent a low-grade, well-differentiated chondrosarcoma with some areas closely resembling chondroma.

Management. The widely accepted rationale for treatment of cartilaginous tumor of the larynx by limited surgical resection[1,4-6] would appear to be supported by this case. Even though the initial surgical efforts were not successful in controlling the disease, the patient, by her strong rejection of greater surgical efforts, afforded an opportunity to see unaltered progression of the malignant disease. The eventual salvage of the patient in spite of the massive size of the lesion was possible because of its tendency to remain within the limits of the perichondrium of the larynx. No extension into adjacent tissues or structures was noted. Distant metastasis is an infrequent problem in the laryngeal chondrosarcoma cases studied, but is always a remote possibility.[7]

Conclusion. A case of chondrosarcoma of the larynx is reported in which the patient refused laryngectomy and survived 18 years before consenting to surgical extirpation. In spite of its long duration and massive size, the tumor appeared to be limited to the anatomical confines of the larynx at the time of wide field laryngectomy. She appears to be free of disease at this time, six months postlaryngectomy. Management by conservative excision of small lesions with laryngectomy reserved for large recurrent tumor is supported.

REFERENCES

1. Cantrell RW, Reibel JF, Jahrsdoerfer RA, Johns ME. Conservative surgical treatment of chondrosarcoma of the larynx. Ann Otol Rhinol Laryngol 1980; 89:567-71.

2. Busuttil A, Forbes J. Chondrosarcoma of the thyroid cartilage. J Laryngol Otol 1978; 92:633-8.

3. Zizmor J, Noyek AM, Lewis JS. Radiologic diagnosis of chondroma and chondrosarcoma of the larynx. Arch Otolaryngol 1975; 101:232-4.

4. Damiani KK, Tucker HM. Chondroma of the larynx. Arch Otolaryngol 1981; 107:399-402.

5. Hyams VJ, Rabuzzi DD. Cartilaginous tumors of the larynx. Laryngoscope 1970; 80:755-67.

6. Singh J, Black MJ, Fried I. Cartilaginous tumors of the larynx. Laryngoscope 1980; 90:1872-9.

7. Ross DE. Chondrosarcoma of the larynx invading thyroid gland. Laryngoscope 1971; 81:379-86.

EXTENDED TRANSANTRAL APPROACH TO PTERYGOMAXILLARY TUMORS

CHARLES J. KRAUSE, MD SHAN R. BAKER, MD

ANN ARBOR, MICHIGAN

A review of 14 patients treated between 1975 and 1979 is reported. The lesions were quite extensive in most of the patients, having extended beyond the nasopharynx in all but one. An extended transantral approach was utilized in nine of the patients to facilitate removal of lateral and superior extensions of tumor. Two of the patients (14%) developed recurrent tumor, one six months and one nine months following treatment. The extended transantral approach appears to be an effective method of approaching the pterygomaxillary extension of the tumor.

INTRODUCTION

The nasopharyngeal angiofibroma is an uncommon, highly vascular tumor which has a predilection for the nasopharynx of adolescent boys. Though only occasionally invasive, the tumor tends to spread anteriorly into the nasal cavity and ethmoid cells, and laterally through the sphenopalatine foramen and into the pterygomaxillary space (Fig. 1). From there the tumor may extend superiorly through the inferior orbital fissure, across the orbital apex, and through the superior orbital fissure into the middle cranial fossa (Fig. 2). Because of the predilection to lateral extension, preoperative evaluation with arteriography should always be done.

Many surgical approaches to these tumors have been advocated, including a vertical split of the soft palate, an anterior fishmouth approach through the palate, a transethmoid approach, a lateral rhinotomy and blunt dissection of the retromaxillary space. Selection of a preferred approach depends upon the extent of the tumor and the individual surgeon's experience and preference. Frequently more than one approach should be combined to offer optimum exposure.

When there is extensive involvement of the pterygomaxillary space, a transantral approach alone or in conjunction with other approaches offers access to the laterally extending tumor, to the internal maxillary artery for the purpose of ligation, and allows gentle dissection of tumor extending through the inferior orbital fissure. The technique employed and the results when utilized in a series of patients will be presented.

METHOD

An extended sublabial incision is made from the midline, laterally to the maxillary tuberosity, and carried down through the periosteum of the maxilla. The periosteum is elevated up to the infraorbital foramen and the face of the maxilla is widely excised using a Kerrison rongeur. The posterior wall of the sinus is then widely excised, allowing access to the pterygomaxillary portion of the tumor. Whenever possible, the internal maxillary artery should be ligated before beginning the tumor removal. By removing the medial wall of the sinus, the surgeon achieves access to the nose and nasopharynx (Fig. 3). When the tumor extends into the ethmoid cells, they may be opened from the antrum, and the tumor carefully dissected. When the tumor extends further laterally, the lateral wall of the sinus may be removed to improve exposure (Fig. 4). Finally, this approach allows excellent access to the inferior orbital fissure (Fig. 3) to allow gentle dissection of the tumor extending upward through the fissure.

The transantral approach may be combined with a transpalatal or external ethmoidectomy approach when tumor extension dictates. We prefer the fishmouth incision for the transpalatal approach, extending the incision behind the maxillary tuberosity on the side of greatest extension. The nasal mucoperiosteum is incised and sufficient bone is removed from the posterior edge of the hard palate to provide adequate access to the nasopharynx. An incision is then made through mucoperiosteum of the nasopharynx circumferentially around the tumor base. Using a periosteal elevator, dissection is carried all around the large feeding vessels which enter the pedicle at the base of the tumor. The vessels are then transected and the nasopharynx is packed for 5-7 days. Care must be taken to completely remove all tumor extensions.

RESULTS

Fourteen patients with nasopharyngeal angiofibroma who were treated at the University of Michigan between 1975 and 1979 were evaluated. A summary of their treatment and outcome is listed in the table. The age at onset ranged from 13 to 25, with the median being 15. Epistaxis and nasal obstruction were the most common symptoms noted at presentation, being present in all but one case. Four patients had been treated prior to undergoing surgical excision at the University of Michigan, including two who had received irradiation for extensive intracranial tumor. Arteriograms were performed in all patients preoperatively. In addition, computerized tomography (CT) scans were obtained in four patients. The extent of the tumor in each case is summarized in the table. All but two patients had lateral involvement of the pterygomaxillary space,

From the Department of Otorhinolaryngology, University of Michigan, Ann Arbor.

Presented at the meeting of the American Laryngological Association, Palm Beach, Florida, May 1-2, 1982.

REPRINTS — Charles J. Krause, MD, Department of Otorhinolaryngology, University of Michigan Hospitals, Ann Arbor, MI 48109.

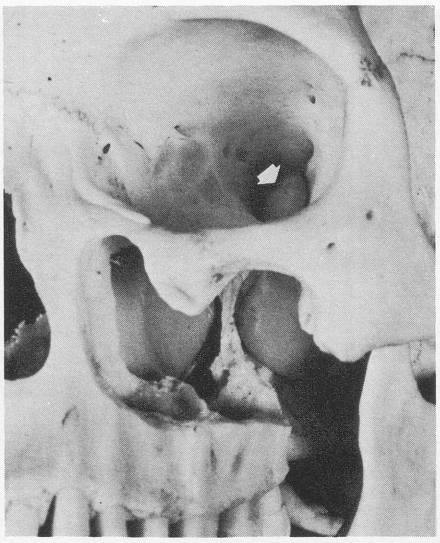

Fig. 1. Tumor extending through sphenopalatine foramen into pterygomaxillary space. Arrow indicates tumor crowding orbital apex.

and in five cases the tumor had extended intracranially as well. The extended transantral approach was utilized in 9 of the 14 patients, being combined with a transethmoid or transpalatal approach in 4 of them.

Five of the patients were found to have intracranial extension of their tumor; in 1 a craniotomy was performed to remove tumor, and 2 were successfully treated with radiation therapy. In the other two patients, the small amount of intracranial tumor was pulled downward through the inferior orbital fissure. Two of the patients developed recurrent tumor after treatment at the University of Michigan, one at nine months and one at six months. Both of these patients had been previously treated elsewhere, and had developed recurrent tumor prior to treatment at our institution. The remaining patients have been followed 18-60 months with no evidence of recurrence.

DISCUSSION

Angiofibromas appear to arise from fibrovascular

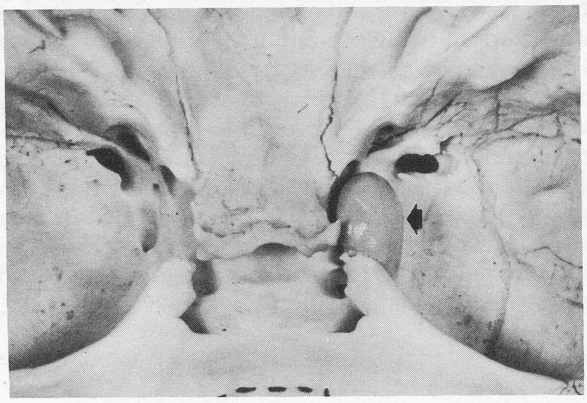

Fig. 2. Tumor extending through superior orbital fissure into middle cranial fossa.

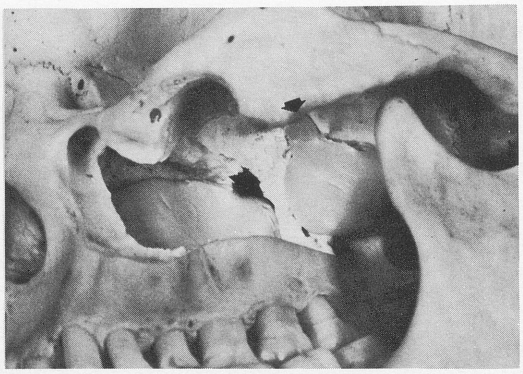

Fig. 3. Medial wall removed to provide access to nasopharynx and nasal cavity. Arrow indicates tumor extending upward through inferior orbital fissure.

stroma present in the nasopharynx,[1] most commonly from a broad base in the posterosuperior wall. The tumor, which consists of varying ratios of fibrous stroma and thin-walled vascular spaces, gradually enlarges and spreads, picking up blood supply as it goes.

The tumor tends to fill the nasopharynx and posterior choanae, then extends into the maxillary or ethmoid sinuses. Laterally it tends to extend through the sphenopalatine foramen into the pterygomaxillary space. From there the tumor extends upward through the inferior orbital fissure, and thence through the superior orbital fissure intracranially. Alternatively or additionally, the tumor may extend superiorly from the nasopharynx through the sphenoid sinus and into the sella turcica.[2]

Nasopharyngeal angiofibromas are nearly always found in males, with the onset of symptoms most commonly found during adolescence. More than a century ago, Gosselin suggested that angiofibromas spontaneously regress after adolescence.[3] It is of interest that one of our patients was more than 25 years of age when he began having symptoms, and

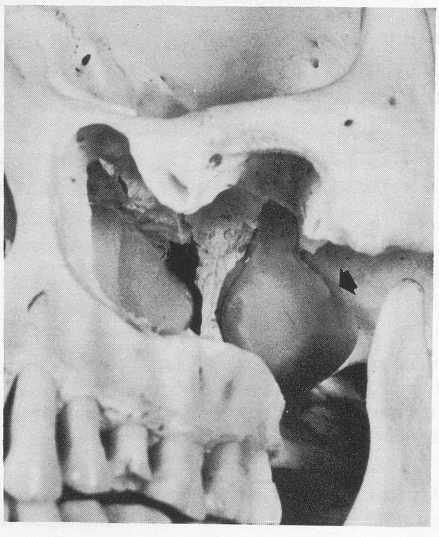

Fig. 4. Lateral wall of antrum has been removed along with posterior wall to provide access to lateral extension.

REVIEW OF PATIENTS TREATED FOR NASOPHARYNGEAL ANGIOFIBROMA

Pt. No.	Age at Onset	Symptoms	Duration of Symptoms (Mo)	Extent of Tumor	Procedure	EBL	Present Condition	Follow-up (Mo)	Comment
1	13	Epistaxis	12	Nasophar.	Transpalatal	500	NED	52	
2	13	Epistaxis Nasal obs.	12	Nasophar. P-M space Orbit	Transantral	1600	Recur	9	Had surgical excision prior to U of M Tx.
3	16	Nasal obs.	12-15	Nasophar. P-M space Orbit Intracran.	Transantral	1100	NED	18	
4	13	Epistaxis Nasal obs.	3	Nasophar. P-M space	Transantral	500	NED	20	
5	14	Epistaxis	4	Nasophar.	Transpalatal	250	Recur	6	2 previous surgical procedures
6	25	Nasal obs.	18	Nasophar. P-M space Ethmoid	Transpalatal Transethmoid	3000	NED	48	
7	18	Headache; proptosis	4	Nasophar. P-M space Orbit Intracran.	Transantral	7100	NED	24	
8	21	Nasal obs.	24	Nasophar. P-M space Orbit Intracran.	Transantral Craniotomy	2000	NED	23	
9	25	Nasal obs.	60	Nasophar.	Transantral	1100	NED	24	Radiation therapy for intracranial tumor
10	15	Nasal obs.	12	Nasophar. P-M space	Transantral Transethmoid	6000	NED	60	Treated with irradiation 1 yr earlier
11	14	Epistaxis Nasal obs.	12	Nasophar. P-M space	Transantral Transpalatal	—	NED	24	
12	13	Nasal obs. Mass R cheek	24	Nasophar. P-M space	Lat rhinotomy Blunt dissection of P-M space	1100	NED	24	
13	18	Epistaxis Nasal obs.	1	Nasophar. Ethmid	Transethmoid	600	NED	Lost to f/u	
14	14	Nasal obs.	12	Nasophar. P-M space	Transantral Transpalatal	—	NED	84	

EBL - Estimated blood loss; Nasal Obs. - Nasal obstruction; P-M - Pterygomaxillary space.

one other developed a recurrence of his tumor at 25 years of age, experiencing progressive nasal obstruction and epistaxis.

Most of these tumors were found to be quite extensive at the time of presentation here. The importance of including arteriography preoperatively to determine the extent of disease is illustrated by the fact that all but one of our patients were found to have extension of tumor beyond the nasopharynx, with lateral extension into the pterygomaxillary space in 12 of the 14 patients, and with tumor extending upward through the inferior orbital fissure in 4. In each of the latter patients it was possible to gently dissect the tumor downward out of the orbit.

Controversey exists regarding the use of hormone therapy preoperatively in an attempt to cause "maturation" of the angiofibroma. Martin et al[4] advocated testosterone, whereas Walike and MacKay[5] as well as Schiff[6] have reported beneficial effects from estrogen therapy. Only five of the patients in our study received estrogen therapy preoperatively, with no significant change in the size of the lesion noted.

Many different surgical approaches to nasopharyngeal angiofibromas have been advocated, ranging from a simple midline palatal split to craniotomy. The selection of an appropriate surgical approach is based primarily upon how extensive the tumor is, and which structures and spaces are involved. The extended transantral approach is primarily of benefit when there is extensive tumor in the pterygomaxillary space or evidence of extension upward through the inferior orbital fissure. The ability to safely dissect tumor from the orbit and even intracranially is primarily dependent upon having a limited amount of tumor to remove and the absence of feeding vessels of significant size located in these sites.

Only two of our patients (14%) developed a recurrence of their tumor; in both instances they

had been treated earlier and had recurred prior to referral to this institution for treatment. These recurrences occurred nine and six months following completion of treatment here. This incidence of recurrence is somewhat lower than that of approximately 50% cited in many series.[2,7]

REFERENCES

1. Patterson CN. Juvenile nasopharyngeal angiofibroma. Otolaryngol Clin North Am 1973; 6:839-61.

2. Batsakis JF. Tumors of the head and neck. 2nd ed. Baltimore: Williams & Wilkins Inc, 1979.

3. Gosselin P. Clinique chirugicale de l'Hopital de la Charite. 2nd ed. Paris: JB Bailliere et Fils, 1876.

4. Martin H, Ehrlich HE, Abels JD. Juvenile nasopharyngeal angiofibroma. Ann Surg 1948; 127:513-36.

5. Walike JW, MacKay B. Nasopharyngeal angiofibroma light and electron microscopic changes after stilbesterol therapy. Laryngoscope 1970; 80:1109-21.

6. Schiff M. Juvenile nasopharyngeal angiofibroma. Laryngoscope 1959; 69:981-1016.

7. Smith MFW, Boles R, Work W. Cryosurgical technique in removal of angiofibroma. Laryngoscope 1964; 74:1071.

PRIMARY MANAGEMENT OF LARYNGEAL TRAUMA

STEVEN D. SCHAEFER, MD

DALLAS, TEXAS

The management of 87 laryngeal trauma patients over the past 17 years is reported. During the last four years, 35 of these patients were prospectively studied by the author after drawing upon the treatment policies of the earlier experience. The results of this study demonstrate a successful program to preserve or restore the phonatory and airway function of the acutely injured larynx.

Laryngeal trauma threatens both the quality and preservation of life. Essential to the preservation of the phonatory and airway sphincter functions of the larynx is restoration of the skeletal framework and epithelium of this organ.[1] Various opinions exist regarding the extent of clinical evaluation and the indications, timing and form of surgical management.[1-4] With the exception of a few articles, most published reports are limited by the number of available patients to retrospective reviews of patients treated by several surgeons within a multiple-hospital institutional setting.[3,5]

Paralleling the experience of Harris and others over the past 17 years, the faculty of the University of Texas Health Science Center at Dallas adopted an aggressive and immediate management protocol for laryngeal trauma. A prior publication by the author reviewing results from the past 13 years permitted the identification of four treatment groups.[6] Utilizing the policies derived from this earlier work, a prospective study was begun four years ago to further clarify laryngeal injuries which might benefit from operative intervention and to test the rationale for various surgical procedures.

The purpose of this paper is to report a primary or immediate management protocol for blunt and penetrating trauma to the larynx that has yielded both predictable and successful results.

MATERIALS

Between 1965 and 1978, 52 laryngeal trauma patients were evaluated after treatment by the faculty of the University of Texas Health Science Center at Dallas Affiliated Hospitals (Parkland Memorial Hospital, Veterans Administration Medical Center, Presbyterian Hospital, and John Peter Smith Hospital). This retrospective report consisted of chart review and examination of available patients from one month to nine years after injury. After January 1978, 35 patients were prospectively managed by the author, primarily at Parkland Memorial Hospital (Table 1). Records were kept by the author beginning at the time of injury, and this information was supplemented by chart review. Follow-up in this population ranged from months to two years.

With the exception of two patients, diagnosis and treatment was performed within 24 hours after injury. Patients initially managed at other institutions or in whom a laryngeal injury was not immediately recognized have been excluded from this paper (one patient in the originally reported retrospective population has been eliminated for this reason).[6] This form of selection is intentional since the theme of the paper is the early management of acute laryngeal injuries, rather than secondary management of the late sequellae of laryngeal trauma.

MANAGEMENT

The diagnosis of laryngeal trauma was based on the history and physical examination (Table 2).[1] Emergent measures included preservation of the airway, cardiac resuscitation, control of hemorrhage, and stabilization of neural and spinal injuries, followed by a systemic search for other organ system trauma. The unstable airway was managed by tracheotomy, rather than endotracheal intubation. In the patient with a nondeteriorating airway, indirect laryngoscopy was considered an important part of the diagnostic evaluation.

Throughout the 17 years encompassed by this paper, lateral soft tissue x-ray examination of the neck was routinely performed, along with radiographic examination of the cervical spine. In the past two years, computerized tomographic scanning (CT) was selectively employed to identify patients who would benefit from surgery. Management in both the prospective and retrospective populations was divided into four groups.

Group 1. Findings included minor endolaryngeal hematomas or lacerations, and absence of a detectable laryngeal fracture. Computerized tomographic scanning was performed to confirm the clinical impression of the injury. Management consisted of close observation, head-of-bed elevation, and humidification of inspired air.

Group 2. Findings included edema, hematoma or minor mucosal disruption without exposed cartilage. Management consisted of tracheotomy, direct laryngoscopy and esophagoscopy. As was true of group 1, no further operative intervention was attempted because the potential for spontaneous resolution of the injured site was felt to be superior to surgery. Utilization of the CT scanner permitted examination of fracture sites. In the prospective group, nondisplaced fractures accompanied by hematoma or minor laceration and requiring tracheotomy were spared open exploration. Prior to CT application, such injuries might have undergone thyrotomy if the mucosal edema was massive enough to preclude an optimal direct endoscopic examination.

Groups 3 and 4. Findings included massive edema, mucosal tears, exposed cartilage and cord immobility. Following tracheotomy and endoscopy, the larynx was explored either through a midline thyrotomy or a laryngofissure in the case of a paramedian fracture. Computerized tomographic scanning was omitted

From the Department of Otolaryngology, The University of Texas Health Science Center at Dallas.

Presented at the meeting of the American Laryngological Association, Palm Beach, Florida, May 1-2, 1982.

REPRINTS — Steven D. Schaefer, MD, Department of Otolaryngology, The University of Texas Health Science Center at Dallas, 5323 Harry Hines Boulevard, Dallas, TX 75235.

TABLE 1. TREATMENT GROUPS (N = 87)

Group	Retrospective 1965-1977	Prospective 1978-1982	Total
1	7	7	14
2	5	17	22
3	14	4	18
4	26*	7	33
			87

*Excludes one patient in a previous report.

because these injuries were so significant that it was obvious that further surgery was needed. *All* mucosal injuries were carefully identified and approximated using 5-0 or 6-0 absorbable suture. The anterior free margin of each true vocal cord was sutured to the cartilage or external thyroid perichondrium at the thyrotomy site to reconstitute the anterior commissure. Particularly in the prospective group, this technique permitted one to avoid stenting if a mucosa-covered anterior commissure could be established. When the anterior half of the larynx (true and/or false vocal cords) were disrupted or the skeleton was likely to remain unstable, a lumen-keeping stent was employed. In group 4 patients, stability and mucosal injuries usually were of similarly severe magnitudes, with two or more fracture sites often accompanied by massive trauma to the laryngeal lining.

In the retrospective population, stenting was performed using either commercially available stents, a finger of a surgical glove filled with sponge rubber or a Portex endotracheal tube stent.[3,7] After 1975, the Portex stent was used exclusively. These "lumen keepers" were fixated with 2-0 Prolene suture passed externally through laryngeal ventricle and cricothyroid membrane. Further sutures were placed from the inferior stent to the chest skin via the tracheotomy and from the superior stent to the nose, to permit recovery of the stent if the fixation sutures failed. Prior to 1975, wire was used to fix these stents and was thereafter abandoned in three patients due to breakage. At no time during the entire 17 years covered by the study were skin or mucous membrane grafts utilized. Cartilage was repaired with either wire or nonabsorbable suture, with the latter method most often used in the prospective group. Removal or debridement of the laryngeal skeleton was limited to fragments which were totally avulsed from their perichondral blood supply. In both study populations, stents were removed by endoscopy under general anesthesia at four weeks.

RESULTS

The mechanism of injury for the prospective group is given in Table 2. The results by management group for both the retrospectively and prospectively treated patients are summarized in Table 3. Success was measured by the quality of the voice and airway. A good voice was one that was close to normal or comparable to the patient's preinjury voice. Moderate to marked hoarseness was described as a fair voice, and phonation just above a whisper was classified as poor. Airway quality was judged good if the patient denied restriction; fair with mild to moderate restriction; and poor if permanent tracheotomy was necessary.[6]

In groups 1 and 2 all 36 patients (12 retrospective and 24 prospective) obtained a good voice and airway. Within group 1, four patients were managed by observation only because CT examination showed nondisplaced fractures and hematomas which were likely to spontaneously resolve (Fig. 1). The CT scanner also proved useful in group 2 patients. In particular, one patient underwent an emergency tracheotomy in the emergency room. Computerized tomographic scanning revealed an intact laryngeal skeleton and massive edema was identified at direct laryngoscopy. Without CT examination and with edema that precluded adequate endolaryngeal assessment, open exploration would have been the next step in the care of this patient. Instead, further surgery was avoided and the patient was decannulated at five days with a good airway and voice. Nine prospectively managed patients in group 2 underwent concurrent open neck exploration without thyrotomy for vascular and pharyngeal injuries. Two of these patients had minor fracture dislocations which were repaired without entering the larynx.

Ten of the 18 group 3 patients were available for follow-up, ranging from one month to five years. One patient (prospective group) died from sepsis nine days after injury, following disruption of C-4 vertebrae, quadriplegia and CSF fistula secondary to a gunshot wound. With the exception of the one death, all patients were decannulated without complication within 14 to 35 days. Airway results were good in all patients, with nine having a good voice without further surgery. Another patient (retrospective group) suffered a thyroid-cricoid fracture and was explored at 48 hours. This patient developed a good airway and a fair voice. Six months after injury, one patient (prospective group) underwent left true vocal cord Teflon injection for recurrent laryngeal nerve paralysis. Following this procedure the patient achieved a good voice.

Thirty-three group 4 patients (26 retrospective and 7 prospective) were treated, and followed from two months to nine years postinjury. In this group, one patient died three days following injury from transection of the spinal cord and cerebral anoxia following carotid artery disruption from a missile wound. Another patient was assaulted and died three days after removal of the Portex stent. Stents consisted of soft sponge in 19 patients (retrospective group only) and Portex tube in 14 (7 retrospective and 7 prospective); both were removed four weeks

TABLE 2. PROSPECTIVE POPULATION PROFILE

	Presenting Symptoms							Method of Injury		
Group	Hoarseness	Pain/ Tenderness	Hemoptysis	Dysphagia	Subcut Emphysema	Impaired Respiration	Hematoma	MVA	Assault Blunt	Assault Penetrating
1	5	4						4	2	1
2	6	2	2	1	3	5	3	5	4	8
3	2	2	1	1		3		1		4
4	2	2		1	1	5		1	2	4

MVA - Motor vehicle accident.

TABLE 3. RESULTS OF TREATMENT OF EVALUABLE PATIENTS (N = 73)

Group	Voice			Airway		
	Good	Fair	Poor	Good	Fair	Poor
1	14	—	—	14	—	—
2	22	—	—	22	—	
3	9*	1	—	10	—	—
4†	18	8	—	25	—	2

*One patient achieved a good voice after Teflon injection of the true vocal cord following recurrent nerve injury.

†One patient not evaluated due to prolonged coma.

after injury. Decannulation varied from 35 to 100 days after injury, with two patients in the retrospective group requiring permanent tracheotomy. In one of these patients, cannulation was required for pulmonary toilet necessary for anoxic brain damage suffered following cardiac arrest. The other patient was an elderly woman who continued to use a small-diameter tracheotomy tube with a fair voice and a fair airway clinically (classified as poor for purposes of study) but refused decannulation.[6] Twenty-five other patients were available for evaluation, all of whom achieved a good airway. Eighteen (14 retrospective and 1 prospective) patients had a good voice and 7 (6 retrospective and 1 prospective) a fair voice. Complications in the group 4 patients included 1) avulsion of the entire mucosa of one side of the larynx following endotracheal intubation (Fig. 2), 2) slippage or expulsion of stent secondary to wire breakage in three patients (retrospective group), 3) total airway obstruction following attempted endotracheal intubation in four patients who were successfully rescued by tracheotomy, and 4) perichondritis nine years after injury necessitating temporary tracheotomy and hospitalization for antibiotic therapy.[6]

Antibiotics, usually a cephalosporin, were given for ten days or less to patients who underwent a surgical procedure. Infection was limited to those with massive pharyngeal and spinal column trauma following gunshot wounds. As stated earlier, such injuries accounted for the two deaths in this series. Steroids were used in a few of the group 1 patients, making their benefits difficult to assess.

DISCUSSION

The results following the prospective management of laryngeal trauma by the author for the past four years are considered along with the concepts established over the previous 13 years. A comparison of the two study populations shows an increase in the relative number of assaults and a decrease in automobile-related injuries. The intent of this paper is to draw upon this experience to improve airway and voice function following the various forms of laryngeal trauma.

Emergent Care. There is an unfortunate tendency for nonlaryngologists to regard all airway emergencies as best managed by endotracheal intubation. Following laryngeal trauma, intubation

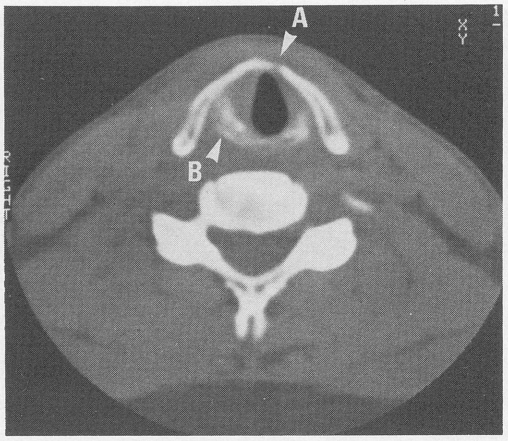

Fig. 1. Computed tomographic scan of patient with nondisplaced thyroid cartilage fracture (A). Right true vocal cord is enlarged due to hematoma, and right arytenoid (B) lies superior to left arytenoid, resulting from hematoma within cricoarytenoid joint.

is hazardous. The few patients so managed (initial care conducted by nonotolaryngologist) developed serious iatrogenic complications. These findings lead the author to reinforce the statement of others recommending tracheotomy under local anesthesia for all suspected laryngeal trauma patients requiring airway support for either further diagnostic or surgical management.[1-3,5,6,8,9] In this series, stridor and difficulty breathing were the most consistent symptoms with severe airway trauma, and hence, the need for tracheotomy (Table 2).

Diagnostic Evaluation. In the stable airway, indirect laryngoscopy permits rapid assessment of the site and degree of injury. Computerized tomographic scanning has further refined this evaluation allowing one to visualize the skeleton and soft tissue of the larynx. However, as a costly radiographic procedure, the CT scan should be applied to those cases where the findings will influence a therapeutic decision, not to confirm a clinically obvious massive injury. Esophagoscopy was performed concurrently with direct laryngoscopy to exclude pharyngeal and esophageal injuries, and remains a valuable diagnostic adjunctive procedure.[10]

Operative Intervention. Beyond the need to establish an airway by tracheotomy, surgical therapy should be considered when spontaneous resolution of the laryngeal injury is unlikely. The results of this study and others suggest that a full recovery without operative treatment is likely with edema, hematomas without mucosal disruption, single nondisplaced thyroid cartilage fractures in the otherwise stable larynx and small lacerations (and moderate lacerations of the supraglottic larynx) not involving the anterior commissure.

The CT scan may complement the indirect laryngoscopy by evaluating the laryngeal skeleton and soft tissue, thereby either avoiding or supplementing direct laryngoscopy in *certain cases*. Open ex-

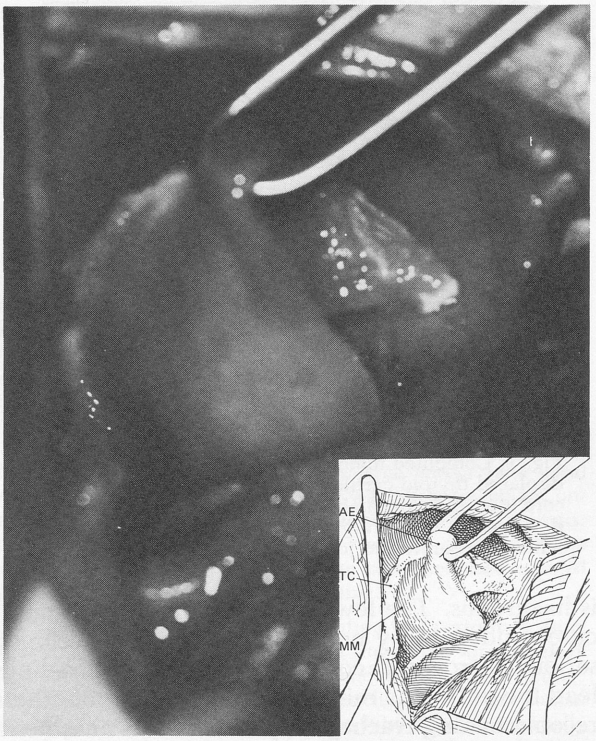

Fig. 2. Operative findings in patient with avulsion of right mucous membrane of larynx following false passage of endotracheal tube. Inset) Artist's drawing of same.AE -Avulsed epiglottis; TC - Thyroid cartilage; MM - Mucous membrane.

ploration of the larynx is felt to be indicated for large mucosal lacerations (particularly of the anterior commissure), displaced or comminuted cartilage fractures, avulsed mucosa and dislocated arytenoids.

Operative Timing. Acute operative management (within 24 hours) evolved as a policy at the University of Texas Health Science Center at Dallas in response to the large volume of trauma patients treated at Parkland Memorial Hospital and has been reinforced by other reports.[1-3,6,7] The results of the current study lend strong evidence to the efficacy of an early surgical management program, rather than waiting several days for edema to resolve.[11] Immediate surgical intervention aided identification of mucosal, muscular and cartilaginous injuries, permitting *primary* approximation of *all* involved tissues.

Laryngeal Stents. Internal stents or lumen keepers serve to splint unstable fractures and allow mucosal wounds to heal without leading to webs, adhesions or stenosis. Since many of the more severe injuries disrupt the anterior commissure and involve multiple cartilaginous fractures, stenting following thyrotomy is often indicated. In the present series, stenting was avoided when the laryngeal skeleton remained stable after open reduction and the mucous membrane of the anterior commissure was intact prior to open exploration. Stents were used when the anterior commissure had been traumatically disrupted despite primary repair of the mucous membrane to avoid the possible formation of a web. In choosing a stent, the surgeon should avoid rigid materials which might lead to further mucosal trauma. The stent should be fixed within the endolarynx in such a way that it moves with the larynx during swallowing and is consistently recoverable at endoscopy without further traumatizing the larynx.[2,7,11]

Grafts. In the present study (retrospective and prospective), skin or mucosal grafts were not utilized because in all 51 explored cases wounds were primarily closed. Grafts have been advocated as a supplement to primary closure to epithelialize areas of potential mucosal loss, and such a policy is certainly reasonable and well established.[1-3] The author would only comment that grafts *should not* be considered as a substitute for careful approximation of mucosa, muscle and cartilage necessary to preserve the dynamic function of the larynx.

The results presented in this paper represent an evolving process in diagnostic and surgical treatment of laryngeal trauma. From this work the term "primary management" has come to signify two meanings. In one sense, "primary" indicates immediate or acute surgical intervention. In another sense, "primary" refers to the tissue closure method which is possible in the early injury period. Following these concepts, it is possible to restore phonation and respiratory function to the acutely injured larynx.

REFERENCES

1. Cohn AM, Larson DL. Laryngeal injury: a critical review. Arch Otolaryngol 1976; 102:166-70.

2. Harris HH, Ainsworth JZ. Immediate management of laryngeal and tracheal injuries. Laryngoscope 1965; 75:1103-15.

3. Harris HH, Tobin HA. Acute injuries of the larynx and trachea in 49 patients. Laryngoscope 1970; 80:1376-84.

4. Chadwick DL. Closed injuries of the larynx and pharynx. J Laryngol Otol 1960; 74:306-24.

5. Downey WL, Owen RC, Ward PH. Traumatic laryngeal injury — its management and sequelae. South Med J 1967; 60:756-61.

6. Trone TH, Schaefer SD, Carder HM. Blunt and penetrating laryngeal trauma: a 13-year review. Otolaryngol Head Neck Surg 1980; 88:257-61.

7. Schaefer SD, Carder HM. Fabrication of a simple laryngeal stent. Laryngoscope 1980; 90:1561-3.

8. Bryce DP. The surgical management of laryngotracheal injury. J Laryngol Otol 1972; 86:547-87.

9. Curtin JW, Holinger PH, Greeley PW. Blunt trauma to the larynx and upper trachea. J Trauma 1966; 6:493-502.

10. Krekorian EA. Laryngopharyngeal injuries. Laryngoscope 1975; 85:2069-85.

11. Olson NR. Surgical treatment of acute blunt laryngeal injuries. Ann Otol Rhinol Laryngol 1978; 87:716-21.

ASSESSMENT OF INTUBATION IN CROUP AND EPIGLOTTITIS

JOHN J. ZULLIGER, MD
DAVID E. SCHULLER, MD
THOMAS P. BEACH, MD
JOHN P. GARVIN, MD
HERBERT G. BIRCK, MD
JOHN E. FRANK
COLUMBUS, OHIO

Nasotracheal intubation for the management of airway obstruction in acute epiglottitis has become a well-received practice. However, the same technique has not received widespread support in laryngotracheobronchitis. The purpose of this study was to update the series of nasotracheal intubations in croup and epiglottitis from Columbus Children's Hospital with the specific intent to evaluate its effectiveness. All patients were evaluated for any immediate and delayed complications. Delayed complications were evaluated using parent interviews and measuring expiratory flow rates. This study of 45 children intubated for epiglottitis and 83 intubations for croup reconfirms the earlier report from this institution about its safety in both conditions. However, it has identified a subset of the croup patients who are definitely at risk to develop complications of the technique. In those children under 1 year of age, a disturbingly high incidence of subglottic stenosis was identified and this appeared to be related to the patient's age, tube size, serial intubations (dilatations), and duration of intubation. Suggested guidelines for airway management in the light of the new information are presented.

INTRODUCTION

The treatment of laryngotracheobronchitis (croup) and acute epiglottitis has been gradually evolving over a number of years. Morgan and Wishart[1] cited a 75% mortality for these diseases in 1928. This rate improved dramatically as the importance of good airway management was appreciated. Although the use of endotracheal tubes for the relief of inflammatory upper airway obstruction was suggested as early as 1880 by MacEwan,[2] tracheotomy became the initial treatment of choice because of its effectiveness and supposed relative safety. The first modern use of nasotracheal intubation in the treatment of croup and epiglottitis patients was reported by Allen and Steven in 1965.[3] Since then there have been numerous reports in the literature demonstrating the safety of nasotracheal intubation in the airway management of epiglottitis patients.[4-9] However, there is little information available regarding the safety of intubation in croup cases.[4,10-14]

It is the purpose of this paper to expand the original series of intubated croup and epiglottitis patients from the Columbus Children's Hospital with particular attention being directed to the use of intubation in croup patients. The immediate and delayed complications directly attributable to nasotracheal intubation in croup and epiglottitis will be analyzed as well as technical factors felt to be responsible for them.

SUBJECTS AND METHODS

All patients admitted to Columbus Children's Hospital with either infectious croup or epiglottitis from January 1973 through December 1979, were included in the study (Table 1). However, three patients were admitted after tracheotomy had been performed at another institution and were subsequently excluded. The study population, therefore, included 626 cases of croup and 55 cases of epiglottitis. Eighty-three (13%) of the croup and 45 (82%) of the epiglottitis patients underwent endotracheal intubation.

Evidence of immediate intubation complications was collected from each patient's hospital record. The presence of delayed complications was investigated by three means: 1) the medical records were examined for records of subsequent hospital admissions related to upper airway obstruction, 2) the parents were contacted and carefully questioned regarding the persistence of any symptoms referrable to clinically significant upper airway damage, and 3) the peak expiratory flow rate was measured using the adult model Wright Peak Flowmeter, a pulmonary function test that has been found useful in assessing obstructive airway disease in children. This particular test was chosen because the normal values have been determined by testing over 4000 subjects and have shown close agreement among distinct, independent studies.[15,16]

RESULTS

Means of Intubation. The technique is the same as that described in an earlier paper from this institution.[4] Intubation is accomplished ideally in the operating room by a staff anesthesiologist, as performed in 76% of the epiglottitis intubations and 87% of the croup intubations. A greater percentage of the epiglottitis patients were intubated in the emergency room or at outlying hospitals than the croup patients, again revealing the fulminant nature of this disease.

It was not unusual for the first tube selected to be too large, requiring the selection of a smaller diameter tube. This was particularly true in the croup cases. Twenty-five percent of the croup patients had the initial tube replaced with a larger tube.

From the Department of Otolaryngology and the Department of Anesthesiology, The Ohio State University College of Medicine, and the Columbus Children's Hospital, Columbus. This research was supported in part by grant 1 K07 NS00417-04 from the National Institute of Neurological and Communicative Disorders and Stroke (Teacher-Investigator Award), and in part by grant 7430Z from the Columbus Children's Hospital Research Foundation.

Presented at the meeting of the American Laryngological Association, Palm Beach, Florida, May 1-2, 1982.

REPRINTS — David E. Schuller, MD, Department of Otolaryngology, The Ohio State University, 456 Clinic Drive, Columbus, OH 43210.

TABLE 1. PATIENTS ADMITTED WITH CROUP OR EPIGLOTTITIS

	No. Cases	Primary Tracheotomy	Population Studied	Nonintubated Cases	Intubated Cases No.	Intubated Cases %
Croup	629	3	626	543	83	13
Epiglottitis	55	0	55	10	45	82
Totals	684		681		128	19

This was only necessary in seven percent of the epiglottitis patients. The tube changes occurred because of inadequate size for maintenance of the patient's airway. This often resulted in a dilatory effect on the edematous tissue. The critical factor with respect to tube size is that an *adequate* airway is established and *not a maximal* airway which would be more traumatic to the inflamed tissue. Uncuffed polyvinyl chloride tubes are used, and the tube is usually one or two sizes smaller than normal for the patient (Table 2). The tube is secured to a Logan bow which is taped to the face. Moderate to severe difficulty, as recorded on the anesthesia record, was encountered in intubating 29% of the epiglottitis patients and 35% of the croup patients. There have been no cases where an endotracheal tube could not be inserted.

Course of Intubation. The average duration of intubation was 60 hours in the epiglottitis and 144 hours in the croup patients (Table 3). Twenty-three (18%) of the patients extubated themselves accidentally and 14 of them required reintubation for continuing respiratory distress. In addition, seven (8%) of the croup patients required reintubation because of tube occlusion with thick secretions. The vital signs, especially temperature, and the patient's return to near-normal activity, were the parameters used to determine the optimal time for elective extubation. This was routinely done in the recovery room with a staff anesthesiologist in constant attendance. However, 19 (23%) of the intubated croup patients and one (2%) of the intubated epiglottitis patients continued to have respiratory distress following the tube removal and subsequently needed reintubation. Seven (8%) of the croup patients underwent tracheotomy because of inability to extubate after prolonged intubation. The intubated epiglottitis patients remained in the hospital an average of six days versus ten days for the croup patients.

Immediate Complication Rate. In the group of 45 intubated epiglottitis patients, there were no immediate complications. One patient had hypoxic brain injury before intubation at an outlying hospital.

In the group of 83 intubated croup patients, 73 (88%) had no immediate complications. One patient extubated himself the night of intubation and suffered hypoxic encephalopathy and a permanent neurologic deficit. Nine patients (11%) developed subglottic stenosis with seven of these patients requiring tracheotomy before discharge. One patient's tracheotomy tube became decannulated the night before discharge and he died.

Because of the disturbingly high incidence of subglottic stenosis in the patients intubated for croup, these patients were analyzed in greater detail in order to determine any similarities. Seven of these nine patients were under 1 year of age with the average being 11 months. Of the 20 intubated croup cases under 1 year of age, seven patients (35%) developed subglottic stenosis. Among the 7 of 9 stenosis patients in which nasotracheal tube sizes are reported, 6 had the inflamed subglottic larynx "dilated" with a larger tube which was felt to be a better size for airway maintenance. In addition, the tube sizes in the stenosis patients were usually larger and frequently approached the sizes generally used in children with normal airways (Table 2). The children who developed stenosis were intubated longer than those who did not develop stenosis (10.5 days vs 5.3 days). This longer duration reflects the

TABLE 2. SIZE OF ENDOTRACHEAL TUBE USED IN CROUP PATIENTS (N = 78)

Tube Size (mm)	Age 0-6 mo	7-11 mo	1 yr	2 yr	3 yr	4 yr	5 yr	6 yr	7 yr	8 yr	9 yr
3.0	6 (1)	1									
3.5	3	4	7 (1)	3							
4.0	3 (2)	4 (2)	14	7	1						
4.5			4	8	3	1		1			
5.0					2 (1)	1			1		
5.5							1			1	
6.0									1		1

( ) - Subglottic stenosis.

//// - Tube size usually used in children with normal upper airways.

▒▒ - Recommended *maximal* tube size in croup patients.

TABLE 3. COURSE OF INTUBATION

	Croup (n = 83)	*Epiglottitis (n = 45)*
Self-extubation	18 (22%)	5 (11%)
Reintubation	12 (67%)	2 (40%)
Tube occluded and reintubated	7 (8%)	0
Total	25 (30%)	5 (11%)
Reintubation after elective extubation	19 (23%)	1 (2%)
Tracheotomy	7 (8%)	0
Average duration of intubation	144 hours	60 hours
Average hospital stay	10 days	6 days

difficulty encountered with extubation. An attempt was made to electively extubate all but one of the stenosis patients by the sixth day of intubation and two patients developed stenosis after being intubated for only three and four days respectively. All the stenosis patients underwent subsequent laryngoscopies with dilatations and/or steroid injection (range 1-23 procedures). Six of the seven patients requiring tracheotomy have been successfully decannulated with the one exception who is presently wearing a Silastic T-tube after laryngoplasty.

Delayed Complication Rate. A group of 43 croup patients (52%) were located for evaluation of any delayed complications. Inquiry regarding the existence of any postextubation symptoms revealed 100% to be asymptomatic. Measurements of peak expiratory flow rates were then attempted in 40 of these same patients. Due to the young age and resultant inability to comprehend the task in some cases, it was possible to obtain measurement in 36 of the patients, with 100% being normal. Of the 45 intubated epiglottitis patients, 26 (58%) were asymptomatic and 21 had normal peak flow rates.

DISCUSSION

Some guidelines for the management of acute upper airway obstruction in children have been formulated from the literature over the past decade. Several articles[4,6-9,17,18] have described the favorable use of nasotracheal intubation in the management of epiglottitis patients. The safety of this technique is reconfirmed in the present study. At the same time, other surgeons have reported large series of epiglottitis patients managed by tracheotomy with comparable morbidity and mortality.[5,19-23] Given the nearly equal morbidity and mortality for these two techniques, nasotracheal intubation appears to be preferable to tracheotomy because a surgical procedure is obviated and the duration of hospitalization is shortened, as reported in most series.[7,18,23]

Although there is now adequate guidance in the literature for the management of the airway in epiglottitis, a paucity of reports exists for croup. This is somewhat surprising as croup associated with respiratory failure is more frequently seen than epiglottitis. The few reports in the literature specifically addressing the use of nasotracheal intubation in croup patients have given mixed conclusions regarding its safety. Allen and Steven[24] concluded that nasotracheal intubation in croup patients was a safe technique as long as strict guidelines were followed. They reported three subglottic stenoses in 129 patients (2.3%) intubated for croup. Downes et al[10] reported three cases of subglottic stenosis and two cases of subglottic granuloma formation in 11 intubated patients. In a subsequent report,[11] they advised tracheotomy for croup patients suggesting that the nasotracheal tube acted as a foreign body which further irritated the inflamed, edematous mucosa. The previous report from our institution concluded that nasotracheal intubation for croup was a safe procedure. This report confirms that conclusion, but it also reveals some limitations of this technique for a particular group of children.

TABLE 4. RECOMMENDED MAXIMAL TUBE SIZE IN INTUBATED CROUP PATIENTS

Age	*Tube Size (ID mm)*
Neonate-1year	3.0
1-2 years	3.5
2-5 years	4.0
5-8 years	4.5
8 years- +	5.0

Management of the croup patient with respiratory failure is more difficult than that of the epiglottitis patient and this is probably related to the different histopathology. Unlike epiglottitis, croup is a diffuse inflammatory process involving the entire upper and lower airway. These patients are more difficult to intubate and the first tube selected will often not pass beyond the inflamed subglottic tissue. The younger age of children with croup compared with epiglottitis further exacerbates the problem. Thus, the clinician is caught between placing a tube large enough to adequately ventilate the patient, but not so large that it irritates the injured subglottic larynx.

The copious secretions seen in croup patients is a further complicating factor. These secretions, along with the smaller diameter tubes, account for the 8% incidence of tube occlusion. The higher incidence of self-extubation in croup (22%) compared to epiglottitis (11%) is probably related to the fact that the duration of intubation was twice as long with croup. Two thirds of the self-extubated croup children required emergency reintubation versus 40% for the self-extubated epiglottitis patients. Additionally, there is the high incidence of reintubation (23%) following elective extubation. When the patients who developed subglottic stenosis are analyzed for contributing factors, *young age*, *tube*

size, duration of intubation, and *"dilating" the subglottic larynx* appear to be the most important. The infant larynx already injured by acute inflammation does not tolerate the additional insult of relentless pressure by an endotracheal tube.

Because of the unacceptably high incidence of subglottic stenosis in children with croup under 1 year of age, the following guidelines for airway management in children are currently being considered. When a croup patient develops signs of respiratory failure, he is taken to the operating room where nasotracheal intubation with general inhalational anesthesia is performed using the tube size listed in Table 4 (modified after Allen and Steven).[24] This table lists the *maximal* tube size utilized for each age group and does not correspond to the maximal tube size for normal children of a similar age. Gentle advancement of the tube beyond the edematous tissue is emphasized. If the first tube selected will not *gently* pass through the larynx, then a smaller size is attempted. After a tube is inserted, a larger tube should not be substituted. The edematous subglottic larynx should not be further stressed by dilating it. If the successfully passed tube seems too small in diameter to adequately sustain the patient's ventilation or is too small to permit effective suctioning, then an orderly tracheotomy should be performed.

After the tube is successfully passed, it is securely fixed to the patient's head and the patient is placed in the medical intensive care unit where he will receive continuous surveillance. All patients receive frequent suctioning and constant humidification to the tube. The use of restraints and/or sedation is important to hopefully avoid self-extubation. Techniques of objectively assessing the time for elective extubation are currently being developed. Those patients who require reintubation will undergo tracheotomy and subsequent laryngoscopy before tracheal decannulation.

Eighty-eight percent of the intubated croup patients in the present series and 92% in the total experience were successfully treated without serious complications. However, the percentage of patients less than 1 year old developing subglottic stenosis is too high. The above-mentioned recommendations will hopefully result in a dramatic improvement.

REFERENCES

1. Morgan EA, Wishart DES. Laryngotracheobronchitis — a statistical review of 549 cases. Can Med Assoc J 1947; 56:8-15.

2. MacEwan W. Clinical observations of introduction of tracheal tubes by mouth instead of a tracheotomy. Br Med J 1880; 2:122-65.

3. Allen TH, Steven IM. Prolonged endotracheal intubation in infants and children. Br J Anaesth 1965; 37:566-73.

4. Schuller DE, Birck HG. The safety of intubation in croup and epiglottitis: an eight year follow-up. Laryngoscope 1975; 85:33-46.

5. Cantrell RW, Bell RA, Morioka WF. Acute epiglottitis: intubation versus tracheotomy. Laryngoscope 1978; 88:994-1005.

6. Battaglia JD, Lockhart CH. Management of acute epiglottitis by nasotracheal intubation. Am J Dis Child 1975; 129: 334-6.

7. Oh TH, Motoyama EK. Comparison of nasotracheal intubation and tracheostomy in management of acute epiglottitis. Anesthesiology 1977; 46:214-6.

8. Blanc VF, Weber ML, Leduc C. Acute epiglottitis in children: management of 27 consecutive cases with nasotracheal intubation with special emphasis on anaesthetic considerations. Can Anaesth Soc J 1977; 24:1-11.

9. Tos M. Nasotracheal intubation in acute epiglottitis. Arch Otolaryngol 1973; 97:373-5.

10. Downes JJ, Striker TW, Stool S. Complications of nasotracheal intubation in children with croup. N Engl J Med 1966; 274: 226-7.

11. Striker TW, Stool S, Downes JJ. Prolonged nasotracheal intubation in infants and children. Arch Otolaryngol 1967; 85:210-3.

12. Thomson PD, Olinsky A. Nasotracheal intubation in acute laryngotracheobronchitis. S Afr Med J 1975; 49:785-8.

13. Wesley AG, Desai S, Holloway R. Nasotracheal intubation in the management of infective croup. S Afr Med J 1972; 46: 839-42.

14. Rahbar N, Krishnan V, Rapkin RH. Endotracheal intubation in laryngotracheobronchitis. J Med Soc NJ 1977; 74:771-3.

15. Nairn JR, Bennet AJ, Andrew JD, MacArthur P. A study of respiratory function in normal school children: the peak flow rate. Arch Dis Child 1961; 36:253-8.

16. Polgar G, Promadhat V. Pulmonary function testing in children: techniques and standards. Philadelphia: W. B. Saunders Company, 1971:188-94.

17. Milko DA, Marshuk G, Striker TW. Nasotracheal intubation in the treatment of acute epiglottitis. Pediatrics 1979; 53: 674-7.

18. Rowe LD. Advances and controversies in the management of supraglottitis and laryngotracheobronchitis. Am J Otolaryngol 1980; 1:235-44.

19. Baxter JD. Acute epiglottitis in children. Laryngoscope 1967; 77:1358-67.

20. Cohen SR, Chai J. Epiglottitis: twenty year study with tracheotomy. Ann Otol Rhinol Laryngol 1978; 87:461-7.

21. Mjeon S, Dahl T, Swenson T, Westheim A. Acute epiglottitis in children — an evaluation of the role of tracheotomy. J Laryngol Otol 1979; 93:995-1001.

22. Bjure J, Ejnell H, Jeppsson PH, Martinell S, Sixt R, Tornquist C. Tracheotomy — a satisfactory method in the treatment of acute epiglottitis. A clinical and functional follow-up. Int J Pediatr Otorhinolaryngol 1981; 3:37-43.

23. Crumley RL. Airway management of croup and epiglottitis. West J Med 1977; 126:184-9.

24. Allen TH, Steven IM. Prolonged nasotracheal intubation in infants and children. Br J Anaesth 1972; 44:835-40.

TREATMENT OF SEVERE SUBGLOTTIC STENOSIS WITHOUT TRACHEOTOMY

A PRELIMINARY REPORT

LAUREN D. HOLINGER, MD

CHICAGO, ILLINOIS

Subglottic stenosis in neonates, infants and children is one of the most challenging problems confronting the pediatric otolaryngologist today. Small patients with congenital or acquired stenosis severe enough to require tracheotomy must undergo repeated endoscopic procedures or laryngotracheal reconstruction; weeks, months, or years may be required to attain a lumen large enough to permit decannulation. During 1981, six infants and children with severe subglottic stenosis were managed without tracheotomy. The surgical technique employed involves endoscopic excision of the offending subglottic tissue using the CO_2 laser and suspension microlaryngoscopy. Intraoperative intubation is avoided by using an insufflation technique for general anesthesia which permits unobstructed visualization of the larynx, thereby avoiding laryngeal trauma and edema.

In 1974, Fearon and Cotton[1] startled the pediatric otolaryngologic community with their report of a 24% mortality rate in 25 infants and children with severe subglottic stenosis and tracheotomy who were managed conservatively. While the mortality in another series[2] (85 tracheotomy-dependent patients with subglottic stenosis) was considerably less (5.9%), the fact remains that the mortality among these small children is significant. Cotton and Evans,[3] among others, therefore began to advocate a more aggressive approach to the management of these patients; of 103 patients who underwent laryngotracheal reconstruction to treat mature, hard, fibrous, unresponsive scar in the subglottic larynx, they had only 1 surgical mortality: a mortality rate of less than 1%.

Ideally, severe subglottic stenosis would be treated without tracheotomy at all. Cotton and Seid[4] have been able to accomplish this in premature infants by using an anterior crocoid split as an alternative to tracheotomy when extubation attempts failed. Johnson and Stewart[5] and Downing and Johnson[6] have used the infant urethral resectoscope to treat three children with subglottic stenosis without tracheotomy. Koufman et al[7] reported endoscopic management of subglottic stenosis with the CO_2 surgical laser; tracheotomy was avoided in three children who had severe subglottic stenosis. The present report presents the preliminary results of six infants and children with severe subglottic stenosis managed endoscopically without tracheotomy using the CO_2 laser.

The indications for laser management of severe subglottic stenosis without tracheotomy are not yet well defined. It seems that any premature infant, full term infant, or child requiring tracheotomy who is stable and healthy enough to breathe spontaneously and undergo general anesthesia, would be a candidate for the procedure. The ideal application for the described technique is a discrete, short, soft tissue subglottic stenosis which does not involve the entire circumference of the subglottic larynx (Fig. 1). However, the technique has been used successfully in cases which have also had involvement of the supraglottic or glottic larynx, or upper trachea as well. A case report of the first child with severe subglottic stenosis managed without tracheotomy illustrates the indications and usefulness of the procedure.

CASE REPORT

Case 3. The patient was a 4½-month-old female who had been well until age 2 months, when she had begun to have typical symptoms of upper airway obstruction. Endoscopic evaluation by a pediatric surgeon yielded no specific diagnosis but the laryngeal aperture was felt to be slightly small. The patient was placed on steroids and her symptoms remained stable for one month. Increasing symptoms prompted the parents to seek the opinion of an otolaryngologist who observed a small larynx; severe respiratory distress following the laryngoscopy necessitated intubation. The patient extubated herself the night following the procedure; immediate reintubation was necessary.

When first seen by the author, the patient was resting comfortably with a 3.0# orotracheal tube securely in place. Chest x-ray films and barium esophagram had been normal; lateral xeroradiogram of the neck suggested airway compromise at the glottic or subglottic level. She was extubated 48 hours later. In spite of steroids and racemic epinephrine she developed progressive airway distress with increasing pCO_2 and therefore was taken to the operating room for laryngoscopy and bronchoscopy under general anesthesia. The larynx was erythematous and edematous throughout; the subglottic larynx had a fullness on the left covered with normal but traumatized mucosa. An eschar was present posterolaterally on the left where there was also early granulation tissue formation. Telescopic examination of the trachea and main bron-

From the Division of Otolaryngology and Communicative Disorders, Department of Surgery, The Children's Memorial Hospital, and the Department of Otolaryngology and Bronchoesophagology, Rush Medical College, Rush-Presbyterian-St. Luke's Medical Center, Chicago.

Presented at the meeting of the American Laryngological Association, Palm Beach, Florida, May 1-2, 1982.

REPRINTS — Lauren D. Holinger, MD, 155 North Michigan Avenue, Chicago, IL 60601.

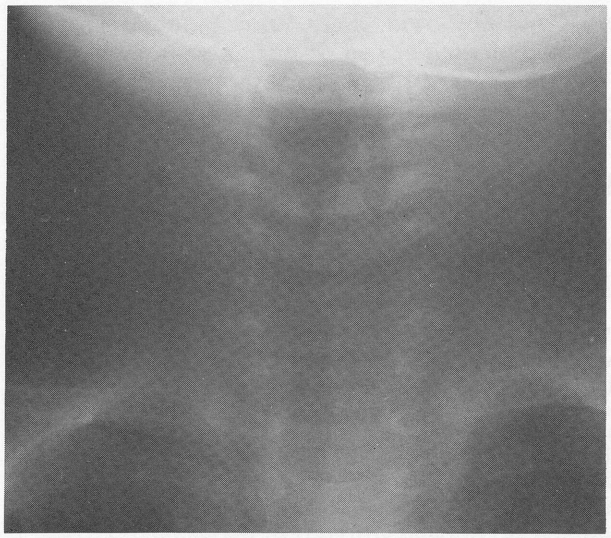

Fig. 1. (Case 4) Posteroanterior chest x-ray film demonstrating subglottic stenosis primarily involving left subglottic larynx.

chi was normal. Biopsies of the subglottic area showed fragments of columnar and squamous mucosa with inflammation and hyperplasia. The subglottic lumen was enlarged endoscopically with the CO_2 laser, removing tissue primarily from the left.

The patient had no respiratory symptoms for five days following the procedure. Over the next two days she developed intermittent stridor which responded dramatically to racemic epinephrine. At direct laryngoscopy seven days following the first laser procedure, an eschar was observed in the left subglottic larynx compromising the airway by 50%. It was removed with cupped forceps and the area was again biopsied. An 18 French brass laryngeal dilator was passed easily. The biopsy showed small fragments of squamous epithelium and fibrous tissue with acute and chronic inflammation and occasional foreign body giant cells.

Although she remained asymptomatic endoscopic re-evaluation was accomplished one week later. The mucosa in the left subglottic larynx was somewhat rough but the airway appeared normal; the 18 French dilator passed with ease through the larynx. She was discharged to be followed by her pediatrician.

Ten and one-half months later the parents were contacted to obtain follow-up information for the present study. Stridor and wheezing had recurred, which her pediatrician had diagnosed as asthma and was treating with bronchodilators. Shortly thereafter she developed acute, more severe respiratory distress which did not respond to subcutaneous epinephrine; racemic epinephrine and systemic steroids did relieve symptoms somewhat. A croup-like cough developed. Lateral xeroradiogram of the neck showed airway compromise at the glottic and subglottic larynx. The patient underwent endoscopic re-evaluation and laser excision of subglottic tissue on the left within one week (Fig. 2). Another similar procedure one week later relieved recurrent symptoms; she has had occasional mild stridor since.

METHODS AND MATERIALS

During 1981, 24 patients with subglottic stenosis were diagnosed by the author at The Children's Memorial Hospital and Rush-Presbyterian-St. Luke's Medical Center in Chicago. Follow-up is reported through May 1, 1982. A detailed review was made of the six patients whose subglottic stenosis was severe enough the require tracheotomy but in whom tracheotomy was avoided by enlarging the airway with the CO_2 laser (Table 1).

The diagnosis was confirmed endoscopically. Laryngoscopy and bronchoscopy were carried out in all patients to identify any other abnormalities of the larynx and tracheobronchial tree; usually this was not done at the initial procedure because of the extreme degree of airway obstruction. Any instrumentation of the subglottic larynx might have produced traumatic edema and precipitated tracheotomy. Examination of the tracheobronchial tree was accomplished without passing a bronchoscopic tube in three patients. They were examined with the Hopkins rod telescope (from a 3 mm x 20 cm Storz bronchoscope) which was passed carefully through the subglottic area into the trachea and each main bronchus, thus avoiding the additional trauma of the larger bronchoscopic tube.

The Cavitron CO_2 laser coupled to a Zeiss operating microscope was used for all patients. One to 1.5 mg/kg of dexamethazone (Decadron) was given intravenously prior to or during most endoscopic procedures to minimize postoperative edema. Postoperatively, patients were kept on high humidity oxygen or an ultrasonic nebulizer to minimize eschar formation. Build-up of fibrinous exudate and eschar formation often necessitated follow-up procedures to remove the eschar and re-establish an adequate airway. Typically, this occurred 3-6 days following a laser procedure. Racemic epinephrine (0.1-0.5 ml, 2.25% diluted in 2.5 cc normal saline) delivered with a nebulizer with 100% O_2 via face mask often provided temporary relief from respiratory distress.

Most patients were premedicated with atropine only (0.03 mg/kg). Pentazocine (Talwin), narcotics and barbituates were avoided because of their tendency to depress respiration. General

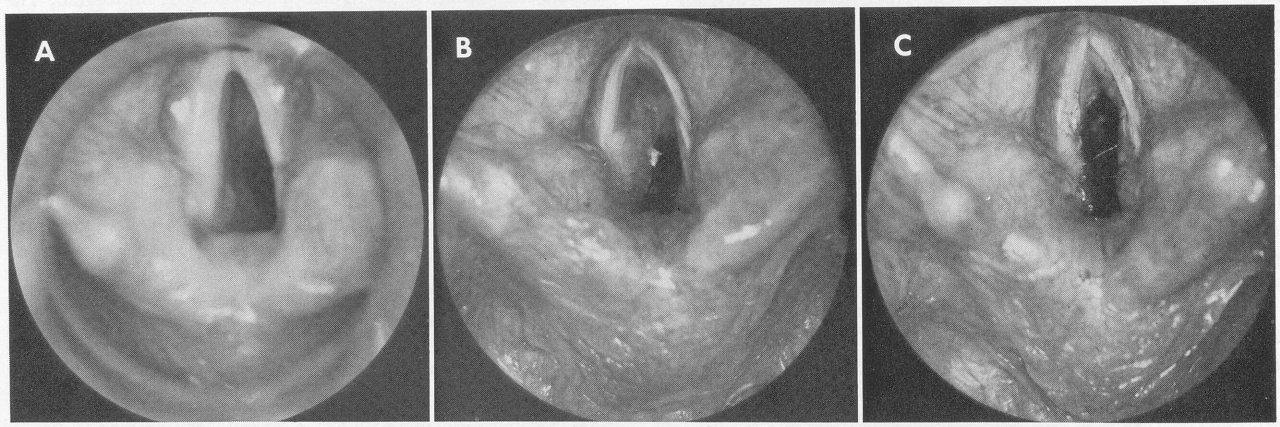

Fig. 2. (Case 3) A) Preoperative endoscopic view of recurrent soft subglottic stenosis at direct laryngoscopy. Lesion is primarily left-sided. Because laryngoscope is in right corner of mouth right vocal cord obscures right subglottic area. B) Intraoperative view. Laser excision of lower portion of stenosis has been accomplished. Trauma from laryngoscope has produced edema in anterior and superior portions of subglottic area. C) Immediate postoperative view. Endoscopic excision has been completed with enlargement of airway. Mucosa at the anterior commissure has been spared.

TABLE 1. SEVERE SUBGLOTTIC STENOSIS PATIENTS TREATED WITHOUT TRACHEOTOMY

Patient No.	Sex	Age at Onset of Symptoms	Age at Diagnosis (1st Endo.)	Nature of Airway Compromise	Clinical History	Duration of Intubation	No. of Procedures Laser	No. of Procedures Total Endo.	Etiology
1	M	18 mo	4½ yr	Subglottic: fibrous, circumferential (focal submucosal fibrosis, chronic inflammation) Glottic: bilateral cysts, posterior commissure synechia	Prematurity; RDS/BPD, croup 2/yr; 2 days severe progressive respiratory distress	2 mo	3	3	Acquired (following intubation)
2	F	14 mo	14½ mo	Subglottic: soft tissue; granulation tissue Glottic: anterior glottic web Supraglottic: bilateral ventricular protrusions; tracheal and bronchial compression	Aspiration and respiratory arrest 6 mo after division of vascular ring. Failed extubation	2 days x 2	3	10	Acquired (following intubation)
3	F	2 mo	4½ mo	Subglottic: soft tissue (acute and chronic inflammation, glandular hyperplasia, foreign body giant cells)	Progressive biphasic stridor; required intubation following diagnostic endo.	4 days	3	5	Congenital
4	F	3 wk	10 wk	Subglottic: soft tissue, left (glandular hyperplasia, chronic inflammation, foreign body giant cells)	Progressive stridor and barking cough; acute obstruction after diagnostic endo.	0	7	11	Congenital
5	F	Birth	8 wk	Subglottic: anterior, firm (not biopsied)	Progressive biphasic stridor; intubated and transferred following diagnostic endo. elsewhere	1 day	1	1	Congenital
6	F	5 mo	5 mo	Subglottic: soft tissue; edema, granuloma, exudate (necrosis, acute inflammation) Trachea: circumferential, high (7 mm below cords) fibrous stenosis; aberrant innominate artery	Failed extubation following meningitis, coma and seizures	0	2	9	Acquired (following intubation)
	Total						19	39	

Endo - Endoscopic or endoscopy; RDS - Respiratory distress syndrome; BPD - Bronchopulmonary dysplasia.

anesthesia was used in all cases. Routine induction was by mask using halothane (Fluothane), nitrous oxide and oxygen. Spontaneous respiration was maintained throughout, assisting the patient during induction only if necessary. Topical anesthesia using 1-2% lidocaine (Xylocaine) was administered to the trachea, larynx and hypopharynx with an atomizer. The dose of lidocaine did not exceed 3 mg/kg. After deepening anesthesia, a large bore suction catheter or a small (3-3.5 mm) endotracheal tube was placed through one nostril for delivery of anesthetic gases into the hypopharynx by insufflation. The position of the tip of the catheter in the pharynx was checked with a laryngoscope and the catheter carefully held or secured with a small piece of tape to the nose or cheek. The fraction of inspired oxygen (FiO_2) was limited to 50% (0.5).

A pediatric anterior commissure microlaryngoscope was used to visualize the larynx then stabilized with a Lewy laryngoscope holder supported on a Mayo stand brought across the patient's chest and abdomen (Fig. 3).

Biopsies were taken when the airway was adequate. The operating microscope and laser were positioned for removal of the offending subglottic tissue. If anesthesia lightened and the patient began to cough or if respiration became too shallow or ceased, intubation was easily accomplished through the laryngoscope. The endotracheal tube was removed when spontaneous respiration was restored, permitting an unobstructed view of the larynx for endoscopic surgery.

The laser may be used to remove tissue from the subglottic larynx and upper trachea, sometimes as far as 2 cm below the superior surface of the vocal cords. This is possible in some infants as well as children and adults. Trials with different pediatric microscopic laryngoscopes and various angles of alignment are necessary to determine which works best with each individual patient. Use of the left hand to manipulate the larynx and upper trachea while aiming the laser with the right obviates continual realignment of the laryngoscope and operating microscope (Fig. 4). One attempts to align the target area more perpendicular to the direction of the laser, giving a more precise burn rather than a tangential one. Removal of tissue from the entire circumference of the lumen at one procedure is avoided.

RESULTS

Six of seven infants and children with severe subglottic stenosis who were considered for (laser) treatment to avoid tracheotomy have indeed avoided tracheotomy. A total of 24 infants and children were diagnosed as having subglottic stenosis during 1981 (Table 2). Twelve of these had subglottic stenosis severe enough to require tracheotomy, only 6 of whom actually underwent tracheotomy; the other 6 were treated with endoscopic laser surgery and tracheotomy was avoided. For various reasons of logistics or timing, no attempt could be made to use the laser as an alternative to tracheotomy in five patients. In one patient, a laser procedure could not be initiated because of extreme respiratory distress, laryngospasm, and difficulty atttaining an adequate exposure for suspension microlaryngoscopy.

The clinical data of the six patients who were spared tracheotomy are presented in Table 1. These six patients underwent a total of 39 endoscopic procedures, an average of 6.5 procedures each. The

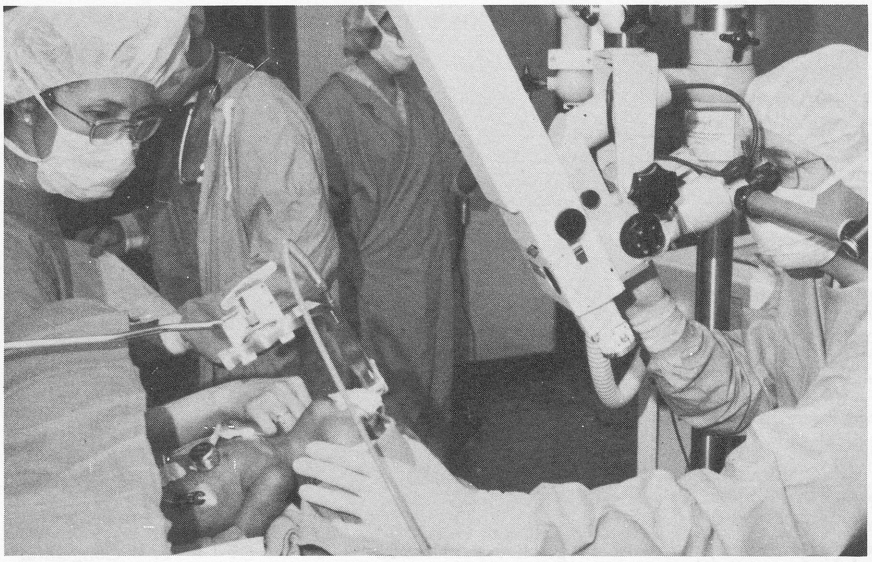

Fig. 3. Suspension microlaryngoscopy in a 3200 g infant undergoing laser removal of subglottic tissue. General anesthesia is maintained using insufflation technique.

laser was used in 19 (49%) of the procedures; the other 20 were done to remove eschar, to dilate or biopsy the larynx, or for diagnostic purposes only. Biopsies were taken when possible; the severity of the airway compromise precluded biopsy completely in one patient. Biopsies were sometimes taken at later procedures when a better airway had been established. Four of the six patients (cases 2, 3, 4, 6) exhibited a tendency for the soft tissue narrowing to recur; this tissue was quite soft and not a hard, fibrous, cicatricial or cartilaginous stenosis. Repeated biopsies showed no suggestion of hemangioma in any of these patients.

Of the 6 patients with severe subglottic stenosis treated without tracheotomy 5 were female, 1 male. The onset of symptoms occurred at age 14 months or younger in all except one patient; in four patients the onset of symptoms occurred under 6 months of age (Table 1). Three of the stenoses were congenital; three were acquired secondary to endotracheal intubation.

No deaths occurred in these patients, nor were any major complications encountered. One minor anesthetic complication occurred when the insufflation catheter was inadvertantly passed too far and entered the esophagus. The stomach was rapidly and massively distended with anesthetic gases. The problem was immediately recognized, the tube withdrawn and the stomach evacuated by passing a nasogastric tube. No long-term sequelae occurred.

DISCUSSION

Several authors have demonstrated the feasibility of treating subglottic stenosis without tracheotomy; anterior cricoid split,[4] the infant urethral resectoscope,[5,6] and the CO_2 laser[7] are the means by which this has been achieved. Of the many surgeons who have used the laser to treat subglottic stenosis, most have reported experience with patients in whom a tracheotomy was already in place and most report treatment exclusively or primarily of adult patients. Three children in the series of Koufman et al[7] had laser excision of subglottic tissue as an alternative to tracheotomy. Healy and his coauthors have used the laser in similar fashion in infants and children with subglottic hemangioma,[8] avoiding tracheotomy in many such patients. The use of the laser to treat severe subglottic stenosis without tracheotomy in infants and children is a logical application of these indications and techniques.

The use of the insufflation technique for administering general anesthesia to infants and small children is a most important technical aspect of the endoscopic treatment of severe subglottic stenosis without tracheotomy. It allows the surgeon unobstructed access to the subglottic space, since no tracheal tube of any type is used in the larynx. The technique is difficult and some anesthesiologists are reluctant to use it. Complete cooperation between the surgeon and the anesthesiologist is required; the anesthesiologist must allow the surgeon to accept full responsibility for the airway. Intermittent

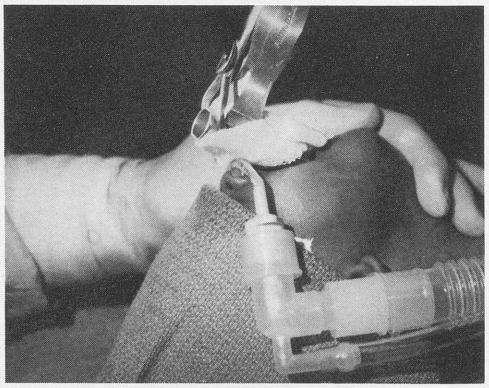

Fig. 4. Close-up of infant illustrated in Fig. 3 showing 3 mm endotracheal tube entering right nostril; tube tip rests in nasopharynx. A moist sponge protects the infant's gums and lips. Fingers of surgeon's left hand manipulate larynx and upper trachea.

TABLE 2. TRACHEOTOMY AND DEGREE OF SUBGLOTTIC STENOSIS

	No. of Patients
Mild or moderate subglottic stenosis	
Tracheotomy unnecessary	9
Tracheotomy for pulmonary pathology or pathology other than subglottic stenosis	3*
Severe subglottic stenosis	
No opportunity for laser	5*
Unable to use laser (laryngospasm and exposure problems)	1*
Tracheotomy avoided	6
Total	24

*Underwent tracheotomy.

laryngospasm and apnea occasionally complicate the procedure; another drawback is the exposure of operating room personnel to inhalation anesthetics. Scavenging of anesthetic vapors is performed whenever possible. For adequate protection, personnel in the immediate proximity (especially the surgeon and anesthesiologist) should wear an oxygen (or air) mask, or an activated charcoal absorbent mask.[9]

The term subglottic stenosis has been used with less precision recently, particularly by specialists in fields other than otolaryngology. By definition, the term applies to a narrowing or stricture of the subglottic larynx: the region extending from the insertion of the conus elasticus into the vocal cords to the inferior margin of the cricoid cartilage; the upper trachea is not included. The term should exclude all conditions such as neoplasms, extrinsic compression (such as vascular rings) and acute inflammatory conditions (such as croup).

Subglottic stenosis may be categorized in three ways: 1) etiology (congenital or acquired); 2) clinical/anatomic (hard or soft, degree [percent] of stenosis and precise anatomic location); 3) histopathology. The histopathologic classification is most helpful since knowledge of the precise histopathology of a lesion makes the treatment of choice almost self-evident. At present, however, it is possible to make this determination in two ways: 1) at the time of laryngotomy for a reconstructive procedure or 2) postmortem with whole-section organ mounts of the larynx. Continued advances in the technology of computer-assisted tomographic scanning will likely make earlier, more precise diagnosis possible in the future. At this time, however, the clinician is limited to the clinical/anatomic description of any particular lesion. This is correlated with the likely histopathologic diagnosis and therapy determined accordingly.

The more accurate the histopathologic diagnosis, the more precise and appropriate will be the treatment. Table 3 outlines the histopathologic classification of subglottic stenosis. Hard subglottic stenoses fall into two categories: fibrous (which can be dilated but tend to restenose shortly after each dilation) or cartilaginous (which cannot be dilated).

TABLE 3. HISTOPATHOLOGIC CLASSIFICATION OF SUBGLOTTIC STENOSIS

- Cartilaginous stenosis
  - Cricoid cartilage deformity (stenosis)
    - Normal shape
      - Small for infant's size
    - Abnormal shape
      - Large anterior lamina
      - Oval (elliptical) shape
      - Large posterior lamina
      - Generalized thickening
      - Submucous (occult) cleft
      - Other congenital cricoid stenoses
  - Trapped first tracheal ring
- Soft tissue stenosis
  - Submucosal fibrosis (fibrous connective tissue)
  - Submucosal mucinous gland hyperplasia
  - Granulation tissue

The clinical importance of diagnosing cartilaginous stenosis is that these stenoses are not responsive to dilation and must either be treated by a laryngotracheal reconstructive procedure or the child must wear a tracheotomy tube for an extended period of time (years) until the problem is outgrown. The prognosis for a hard, fibrous, cicatricial acquired subglottic stenosis is likely to be the same.

Soft subglottic stenoses usually represent granulation tissue, submucosal mucinous gland hyperplasia, or combinations in association with submucosal fibrosis. These stenoses dilate readily but collapse upon withdrawal of the dilator. Acquired subglottic or tracheal stenoses with loss of catilaginous support behave similarly. Soft tissue stenoses may be congenital (especially submucosal mucinous gland hyperplasia) or acquired (as with submucosal fibrosis and granulation tissue). The six cases reported here which were treated successfully without tracheotomy were soft stenoses; none were cartilaginous, nor had any of the acquired stenoses progressed to become the firm, circumferential, cicatricial type.

Many stenoses are not purely one histopathologic type or another. Often they are not confined exclusively to the supraglottic larynx but involve the glottic or supraglottic larynx or the upper trachea as well. Similarly, it is not unusual to find patients in whom an underlying congenital subglottic stenosis is complicated by submucosal fibrosis or granulation tissue acquired from endotracheal intubation. The ideal lesion for application of the technique described herein is a discrete, short, soft stenosis which does not involve the entire circumference of the subglottic larynx. However, it appears that the laser technique can be considered for any premature infant, full term infant, or child with adequate lungs who fails extubation or requires tracheotomy for congenital or acquired laryngeal (or high tracheal) chronic or subacute pathology.

The histopathologic classification of subglottic stenosis outlined in Table 3 incorporates recent con-

tributions of Tucker et al[10] and a review by Morimitsu et al.[11] The latter article presents a case of congenital cricoid stenosis and contains an excellent illustrated diagrammatic summary of cartilaginous stenoses reported up to 1981. Tucker[10] has reported and detailed in a fine histopathologic study the trapped first tracheal ring and a small elliptical cricoid ring. He has also observed two cases of submucous (occult) clefts of the posterior cricoid lamina which probably represent incomplete laryngotracheoesophageal clefts (personal communication 1982).

In conclusion, six infants and children with severe subglottic stenosis have successfully undergone endoscopic laser surgery to avoid tracheotomy. All patients survived; no major complications occurred. The surgical technique employs suspension microlaryngoscopy and the CO_2 laser. An insufflation technique for administration of general anesthesia is used; spontaneous respiration is maintained and intubation avoided. The technique may be considered for any premature infant, full term infant, or child with adequate lungs who must undergo tracheotomy for severe subglottic stenosis.

ACKNOWLEDGMENTS — The author thanks Ms Carla Gaona for her assistance in the preparation of the tables and manuscript. Lucida Rita, MD, provided information for the description of the insufflation technique of general anesthesia. Gabriel F. Tucker, MD, contributed his expertise and advice for the histopathologic classification of subglottic stenosis.

REFERENCES

1. Fearon B, Cotton RT. Surgical correction of subglottic stenosis of the larynx in infants and children: progress report. Ann Otol Rhinol Laryngol 1974; 83:428-31.

2. Holinger PH, Kutnick SL, Schild JA, Holinger LD. Subglottic stenosis in infants and children. Ann Otol Rhinol Laryngol 1976; 85:591-600.

3. Cotton RT, Evans JNG. Laryngotracheal reconstruction in children: five year follow-up. Ann Otol Rhinol Laryngol 1981; 90:515-20.

4. Cotton RT, Seid AB. Management of the extubation problem in the premature child: anterior cricoid split as an alternative to tracheotomy. Ann Otol Rhinol Laryngol 1980; 89:508-11.

5. Johnson DG, Stewart DR. Management of acquired tracheal obstructions in infancy. J Pediatr Surg 1975; 10:709-17.

6. Downing TP, Johnson DG. Excision of subglottic stenosis with the urethral resectoscope. J Pediatr Surg 1979; 14:252-7.

7. Koufman JR, Thompson JN, Kohut RI. Endoscopic management of subglottic stenosis with the CO_2 surgical laser. Otolaryngol Head Neck Surg 1981; 89:215-20.

8. Healy GB, McGill T, Strong MS. Surgical advances in the treatment of lesions of the pediatric airway: the role of the carbon dioxide laser. Pediatrics 1978; 61:380-3.

9. Brummitt WM, Fearon B, Brama I. Anesthesia for laryngeal laser surgery in the infant and child. Ann Otol Rhinol Laryngol 1981; 90:475-7.

10. Tucker GF, Ossoff RH, Newman AN, Holinger LD. Histopathology of congenital subglottic stenosis. Laryngoscope 1979; 89:866-76.

11. Morimitsu T, Matsumoto I, Okada S, Takahashi M, Kosugi T. Congenital cricoid stenosis. Laryngoscope 1981; 91: 1356-64.

INFANT TRACHEOTOMY

CAROL ROBERTS GERSON, MD GABRIEL F. TUCKER, JR, MD

CHICAGO, ILLINOIS

The pediatric and neonatal tracheotomies done on our patients at Children's Memorial Hospital since 1975 have been reviewed. Patients' ages, birth weights, rates of complications, decannulations and deaths have been studied. As compared to previous studies, the proportion of procedures done on children in the first year of life has dramatically increased. A technique which has been modified for the small infant is described.

INTRODUCTION

Infant tracheotomy continues to evolve as the proportion of smaller patients increases. A number of modifications of operative technique for the neonate have seemed appropriate. These along with statistical analysis of our current experience are reported.

TECHNIQUE (Fig. 1)

Whenever possible, regardless of the age of the patient, all tracheotomies are performed under general anesthesia in the operating room with a controlled airway. Since many patients have an indwelling endotracheal tube and further need for prolonged ventilatory support, it is felt safest to perform the tracheotomies over the endotracheal tube and to defer definitive inspection of the larynx until the time of the initial tube change, usually one week. In all but three of these cases the tracheotomy was performed with an airway established and maintained easily with an endotracheal tube or bronchoscope. In these three cases attempts to pass either an endotracheal tube or a bronchoscope failed. One patient was a Pierre Robin child with an extremely small mandible, another was a case of massive maxillofacial and head trauma, and the third was a case of severe tongue swelling following a cleft palate repair in an infant.

A shoulder roll is placed and the patient is prepped and draped except for the face which is left visible both to the otolaryngologist and the anesthesiologist so that the patient's respiratory status and oxygenation can be easily monitored and the airway kept accessible. The hyoid bone and the cricoid cartilage are palpated (the neonatal thyroid cartilage is often difficult to palpate). The incision begins at the cricoid cartilage and extends 1-2 cm inferiorly, after injecting with a small amount of local anesthetic combined with 1:200,000 epinephrine. The soft tissues are dissected in the midline with sharp and blunt dissection and with the use of hemostats as retractors. When the thyroid isthmus is exposed a suture is placed in the trachea immediately below the cricoid cartilage and above the isthmus and thyroid. A suture is preferable to a hook since it will not disengage or tear the tracheal tissue as easily. Using the suture for traction, the trachea is elevated and a second suture is placed behind the thyroid isthmus. This suture can then be used to elevate the isthmus so that it is more easily dissected from the tracheal wall. The isthmus is double-clamped, divided, and oversewn with chromic suture, left long until the stay sutures are placed. The isthmus is always divided to prevent it from obscuring the tracheal incision in the event of an accidental decannulation. The isthmus divided, the initial suture can be laddered downward to provide traction slightly lower on the tracheal wall. The trachea is cleaned with cotton swabs and two black silk stay sutures are placed just to the right and left of the midline, circling tracheal rings 3 and 4. These sutures are tied several centimeters from the trachea and left long to be taped to the chest at the termination of the procedure. After the stay sutures are in place the thyroid sutures may then be cut and a vertical incision is made in the tracheal wall beginning inferiorly and proceeding superiorly to avoid traumatizing a high cupula or any mediastinal contents. An attempt is made to incise just the tracheal rings and then to complete the incision through the tracheal mucosa with a small hemostat to avoid any possibility of trauma to the posterior tracheal wall. A Shiley "neonatal" tracheotomy tube is placed in the incision under direct vision using the sutures as traction after the endotracheal tube has been withdrawn to just above the tracheal incision under our direct vision.

Once the tube is in place, the anesthesiologist then attaches to the tracheotomy tube and when adequate ventilation is assured, the endotracheal tube is fully withdrawn. Stay sutures are taped to the chest and kept in place for one week. At this

---

From the Division of Bronchoesophagology/Otolaryngology, Children's Memorial Hospital, Chicago. Support of the Edward Shedd Wells Fund is gratefully acknowledged.

Presented at the meeting of the American Laryngological Association, Palm Beach, Florida, May 1-2, 1982.

REPRINTS — Gabriel F. Tucker, Jr, MD, The Children's Memorial Hospital, 2300 Children's Plaza, Chicago, IL 60614.

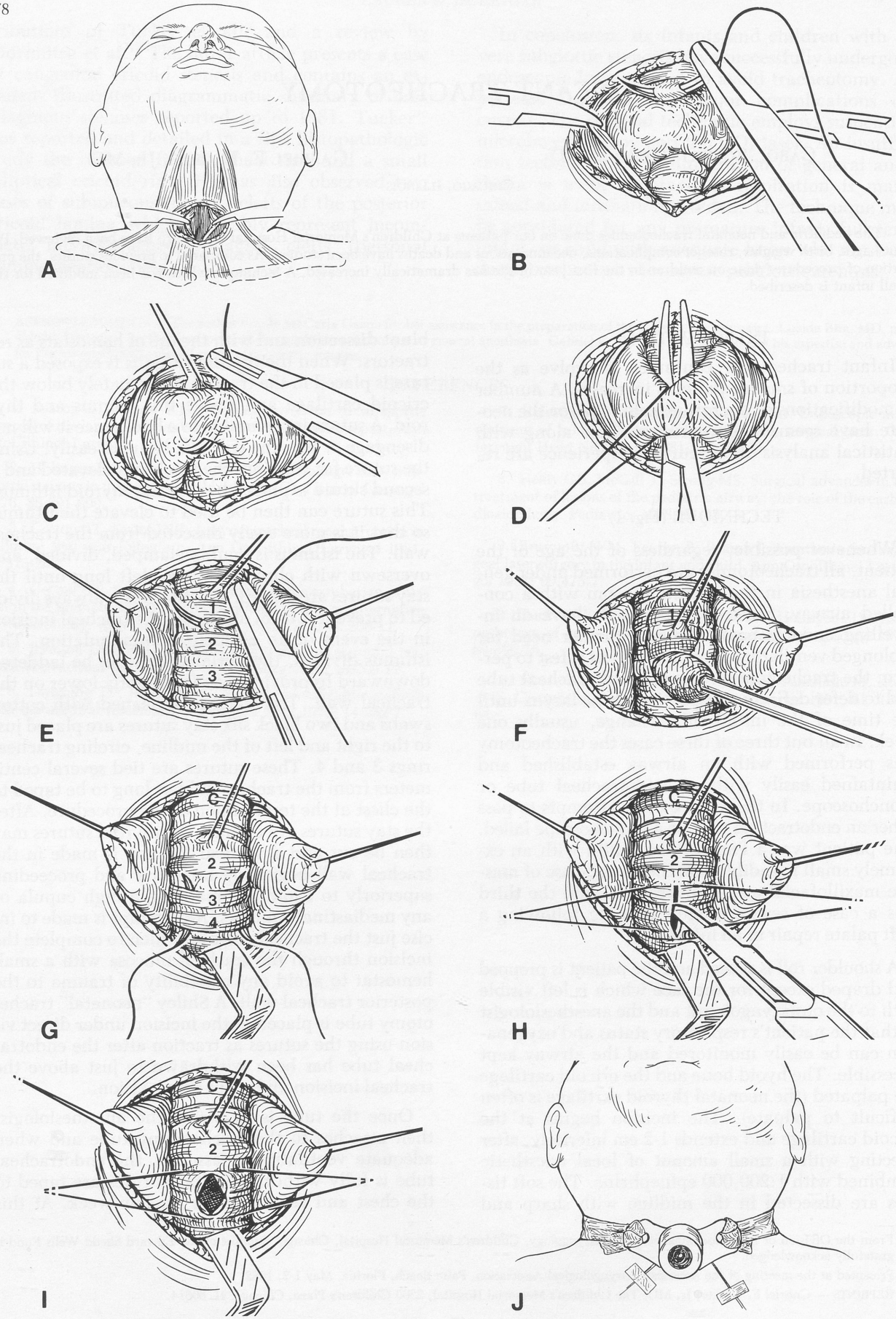
A
B
C
D
1
2
3
E
F
C
2
3
4
G
C
2
H
C
2
I
J

time it is hoped that the stoma will have begun to form. The initial tube change is done in the operating room under general anesthesia with the airway under endoscopic control, thus permitting a leisurely controlled inspection of the laryngeal pathology at a time when mucosal reaction, tube imprints, etc., have settled down. Further tracheotomy changes can be carried out by the resident or the nursing staff on a regular hospital floor. Daily tube changes, both in the hospital and at home, are advised to minimize stomal reaction, granulation tissue, etc; an antibiotic and/or steroid ointment is used to lubricate the replacement tube.

At this time it is worthwhile to note the introduction by Shiley of the neonatal tracheotomy tube. This is manufactured in the same sizes as the "pediatric" tube and has been modified to have a shorter cannula, more appropriate for the infant's trachea, and a smaller flange, more appropriate for the size of the infant's neck. This modifies the plastic pediatric tube to specifications similar to that of the silver Holinger tube.

Although developed for the neonate, the technical points just elaborated have been found applicable to the infant and child.

STATISTICS

Since 1975, 123 patients have undergone tracheotomy. Although previous studies have reported a consistent 2:1 male to female ratio, only 60% of the patients were male.[1-3] Over the last ten years there has been a significant change in the proportion of patients under one year of age who require tracheotomies. Sixty-four percent of the patients were less than 1 year of age, and 21% were between 1 and 5 years, only 11% being 5 years or older (Fig. 2).[1] This distribution is similar to that reported by Hawkins and Williams.[4] There were 18 premature infants included in this study. Their birth weights ranged from 600 to 2000 g, and gestational ages from 26 to 32 weeks. The age range of these patients at the time of tracheotomy was between 2 and 9 months. Most of the patients have been intubated for a significant portion of their lives prior to tracheotomy. A few who were intubated early in life were able to be extubated, but were found to have a subglottic stenosis and an inadequate airway after several months of extubation. There were seven full-term infants who were tracheotomized within the first 28 days of life.

The indications for tracheotomy were many and varied. There were a few patients, especially the neonates, who had primary upper airway insufficiency. These included bilateral cord paralysis, Pierre Robin syndrome, Treacher-Collins syndrome, arthrogryposis, and severe congenital subglottic stenosis. Most of the other patients were tracheotomized secondary to other medical problems, many of which were multisystem and complicated. There were numerous children with complex cardiac disease, significant neurological problems, and many with pulmonary disease related to prematurity. There were a few patients with tumors, several with head injuries and maxillofacial trauma, especially among those over five years of age. Only one patient was tracheotomized for upper airway respiratory infection.

There were few complications thought to be directly related to the procedure: two cases of pneumothorax, one case of which was secondary to displacement of the tube in the Neonatal Intensive Care Unit and attempts to ventilate through a tube in subcutaneous tissue. There were three cases of tube displacement within the first 24 hours after the procedure. There were two cases of postoperative bleeding, neither of which were directly related to the tracheostome; both appeared to be from dilated bronchial vessels traumatized by a suction catheter and to be coming from below the level of the tracheostome. A cardiac arrest occurred in one patient at the conclusion of the procedure, due to transient hypoxia when the tracheotomy tube replaced the endotracheal tube. The patient survived without sequelae. In one patient with a tracheoesophageal fistula the tip of the tracheotomy tube persistently fell into the fistula and rested in the esophagus. There were no operative deaths.

Thirty percent of our patients who are still alive have been decannulated. There are no patients at this time who are unable to be decannulated because of persistent stomal problems. Twenty percent of the original group of patients have died. In only one of these patients was there a suspicion that the death may have been caused by obstruction of the airway in a patient with an obligate tracheotomy. All other deaths were felt to be secondary to a progressive primary disease or multisystem failure. Because of the extreme fragility of our youngest babies, we have found a higher percentage of these patients do not survive; 36% of the premature babies died.[5]

DISCUSSION

There are several points which are of interest in reviewing these patients. As noted above, there is a higher proportion of females than in many of the previous studies. The significant preponderance of tracheotomy performed for infectious disease noted

Fig. 1. Technique used in infant tracheotomy. A) Incision in the midline with the use of hemostats as retractors. B) Traction suture above the thyroid isthmus. C) Suture behind the isthmus for easier dissection from the trachea. D) Elevation of the isthmus. E) Laddering downward of the traction suture. F) Cleaning of the trachea with cotton swabs. G) Stay sutures placed on either side of the midline between rings 3 and 4. H) Incision of the tracheal wall, to the mucosa, with a knife blade pointing superiorly. Mediastinum protected with a retractor. I) Use of the traction sutures to hold the incision open. J) Placement of the neonatal tube with a small flange; traction sutures taped to the chest. (Note: The thyroid isthmus reaches the second tracheal ring by the seventh week of fetal life.)

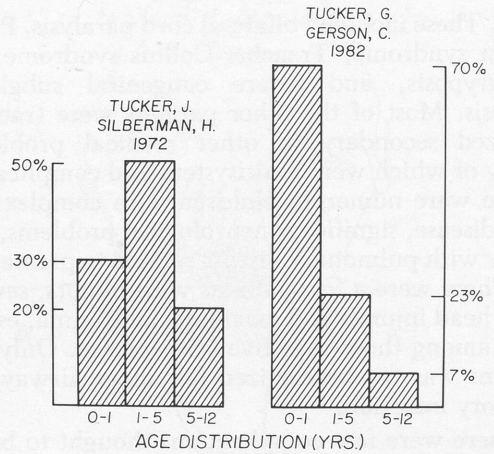

Fig. 2. Age incidence of tracheotomy under 12 years of age.

in previous studies has changed. Tracheotomies are not being performed for epiglottitis at The Children's Memorial Hospital today. We very rarely find it necessary to tracheotomize a patient secondary to laryngotracheobronchitis.[6] We are tracheotomizing many more very young and premature infants. It is possible that the change in emphasis on the indication for tracheotomy may relate to the change in sex distribution.

As our technology and skills in salvaging the premature and damaged child improves, the number of candidates in the youngest age group will, of course, increase. The youngest babies seemed to be carried for longer periods of time with endotracheal tubes in place than many of the older children. If our cardiac surgeons foresee a prolonged period of ventilation for a patient, they will request a tracheotomy after one or two weeks of intubation. The neonatologists, however, will frequently keep small infants intubated for a period of months. Only two of the premature infants have been successfully decannulated, whereas 13 of 21 children with congenital cardiac disease are decannulated. (Cardiac patients who have poor mucosal microcirculation might be expected to have more mucosal damage and a poorer chance for decannulation but this was not the case.) On the average, the patients with congenital cardiac disease were older, at least by gestational age, and larger in size than the premature infants. To begin with, the larynx in the older group is larger. This, and the fact that they were tracheotomized after a much shorter period of intubation, are the factors that may be significant. The prolonged need for a tracheotomy does not seem, to us, a complication of the tracheotomy procedure itself, but a complication of either the child's primary disease or of the prolonged period of intubation necessitated by that disease. If the smaller infants had been tracheotomized earlier it is possible that many of them would be decannulated at this point. In the home institution it is possible for the laryngologist to emphasize the need for the smallest endotracheal tube which can successfully ventilate the patient. It is not, however, possible to control this in patients transferred from multiple referring institutions. Many of these patients arrive with disproportionally large endotracheal tubes for the size of the child and significant laryngeal damage from those tubes.

The problem of tube displacement within the first 24 to 48 hours after the tracheotomy can be avoided by paying close attention to the tubes at the time the patient is moved from the operating table to the litter. If heavy ventilating equipment must be attached to the tracheotomy tube, it must be well supported externally so that it does not place torque on the tube itself. The pediatric tubes are quite flexible and the drag of heavy equipment can easily twist them out of the trachea. The division of the thyroid isthmus and the presence of stay sutures are important precautions to allow replacement of the tube with ease by whomever is present should an accidental decannulation occur. Keeping the dissection entirely in the midline and away from the mediastinum aids in preventing problems with pneumothoraces and pneumomediastina. Many of our patients have significant pulmonary disease and they have some hyperinflation of the lungs. It is not unusual to visualize the cupula of the lung in the lateral aspect of the operating field. In the three emergency tracheotomies there were no major complications of the procedure itself. It is, however, a procedure to be avoided whenever possible by prudent evaluation of any critical airway and placement of either an endotracheal tube or a bronchoscope.

SUMMARY

The records of 123 tracheotomized patients have been evaluated. The proportion of children treated in the first year of life is quite high. The use of techniques specifically designed for small infants can help avoid complications. The use of the neonatal tracheotomy tube allows a better fit for the small infant.

ACKNOWLEDGMENTS — We would like to thank Kathy Sisson and Robert Ossoff, DMD, MD, for their work on the illustration of technique.

REFERENCES

1. Tucker JA, Silberman HD. Tracheotomy in pediatrics. Ann Otol Rhinol Laryngol 1972; 81:818-24.

2. Oliver P, Richardson JR, Clubb RW, et al. Tracheotomy in children. N Engl J Med 1962; 267:631-7.

3. Holinger PH, Brown WT, Maurizi DG. Tracheostomy in the newborn. J Surg 1965; 109:771-9.

4. Hawkins DB, Williams EH. Tracheostomy in infants and young children. Laryngoscope 1976; 84:331-8.

5. Perrotta RJ, Schley WS. Pediatric tracheotomy. Arch Otolaryngol 1978; 104:318-21.

6. Bridges CP, Ryan RF, Longenecker CG. Tracheostomy in children: a 20-year study at Charity Hospital in New Orleans. Plast Reconstr Surg 1966; 37:117-20.

LARYNGEAL PARALYSIS IN CHILDREN
A LONG-TERM RETROSPECTIVE STUDY

SEYMOUR R. COHEN, MD
JEFFREY W. BIRNS, MD
KENNETH A. GELLER, MD
JEROME W. THOMPSON, MD
LOS ANGELES, CALIFORNIA

The charts of 100 children with laryngeal paralysis were reviewed. The patients in this study had either unilateral or bilateral abductor vocal cord paralysis. The literature and pathophysiology are reviewed. A statistical analysis of each group of patients according to etiology is reported. The follow-up, progress and recovery are detailed. The need for observation and conservative therapy is reinforced by the tendency for spontaneous recovery. Suggestions regarding treatment are given.

INTRODUCTION

The records of 100 infants and children with the diagnosis of laryngeal paralysis were reviewed.

Paralysis of the larynx is an important consideration in the differential diagnosis of airway obstruction, voice change and aspiration syndromes. The early recognition of this problem and the application of appropriate therapy will prevent potential life-threatening sequelae from hypoxia, anoxia or contamination of the lower respiratory tract.

This retrospective study reviews the literature and pathophysiology of laryngeal paralysis, summarizes the neuroanatomy, analyzes the historical data of these children, details the endoscopic findings in the larynx and studies the changes which occur over a period of months and years. The treatment of the child with a paralyzed larynx is analyzed and the details are reported. There is no similar study of long-term follow-up in the otolaryngological literature.

LITERATURE REVIEW

The otolaryngological and surgical literature is replete with papers on the subject of laryngeal paralysis in the adult patient. Fewer studies have been written on this problem in children and there are none which give an intensive long-term follow-up or detail the outcome of the infant and child with a paralyzed larynx. Clerf[1] in 1953 reported a series of 293 patients with unilateral vocal cord paralysis. Ten percent of the patients in this review had paralysis of congenital origin. The left recurrent nerve was involved two times more often than the right. Of the 19 patients with congenital paralysis, 13 had bilateral associated with various anomalies such as meningomyelocele, hydrocephalus, congenital heart disease and tracheoesophageal fistulae.

Cunning[2] in 1955 estimated that 10% of the unilateral cases of paralysis were caused by tumor, abscess, bulbar paralysis or by vascular accident and intracranial disease prior to the nerve leaving the skull. In his estimation 90% were caused by peripheral lesions along the course of the recurrent laryngeal nerve.

Holinger and Brown[3] in 1967, in a paper on congenital anomalies of the larynx, state that paralysis of one or both vocal cords in the newborn infant is usually a serious laryngeal manifestation of a gross anomaly of another organ system. These authors felt that bilateral vocal cord paralysis was rarely seen in an otherwise normal infant and that it was associated with cerebral agenesis, severe mental retardation, meningomyelocele and birth trauma.

Morse[4] in 1969 reported on paralysis of the larynx and gave the etiological factors as follows: 90% were due to trauma, neoplasms, cardiovascular disease, infections, toxins, heavy metals, and drugs; 10% were idiopathic.

Goff[5] in 1970 analyzed 229 cases of laryngeal paralysis and divided the etiology into congenital and acquired, unilateral or bilateral and sudden or gradual.

Bluestone et al[6] in 1972 reported 12 patients with vocal cord paralysis associated with hydrocephalus and meningomyelocele. Six of the 12 patients died during the first year and 2 died during the second year of life. Only 3 of these 8 patients had been tracheotomized. Paralysis of the larynx was described as being due to 1) compression of the vagus nerve, 2) traction of the cervical rootlets of the vagus nerve by caudal displacement of the brainstem and 3) brainstem dysgenesis.

Kirsch et al[7] in 1967 reported five patients with

From the Department of Surgery, Division of Otolaryngology, the Childrens Hospital of Los Angeles and the University of Southern California School of Medicine, Los Angeles.

Presented at the meeting of the American Laryngological Association, Palm Beach, Florida, May 1-2, 1982.

REPRINTS — Seymour E. Cohen, MD, 1300 North Vermont Avenue, Los Angeles, CA 90027.

abductor paralysis of the larynx in association with meningomyelocele with Arnold-Chiari malformation and hydrocephalus. These authors felt that a tracheotomy was necessary to relieve airway obstruction until the hydrocephalus could be controlled by ventricular taps and shunting procedures. Restitution of laryngeal function in their patients appeared to be dependent on reducing intracranial pressure.

Fearon and Ellis[8] in 1972 reported a series of 28 cases of vocal cord paralysis; 30% were bilateral, 70% were unilateral. Seventy-five percent had symptoms at birth and were diagnosed prior to 6 months of age. The etiology of the paralysis was neurogenic, meningomyelocele with hydrocephalus, birth trauma, cerebral agenesis and spastic paralysis. Thirty percent of the patients in this study required a tracheotomy.

Hengerer and Tucker[9] in 1973 described the use of a nerve pedicle graft using a motor branch with sternohyoid muscle to restore abduction in the paralyzed canine larynx.

Tucker[10] in 1975 described the use of the ansa hypoglossiomohyoid muscle pedicle graft to restore innervation of the paralyzed larynx in the human. He states that should this procedure fail, an arytenoidectomy may still be used.

Gacek[11] in 1976 reported a family in which the father and two sons had hereditary bilateral vocal cord paralysis; another 4 siblings, 1 male and 3 females, were normal. His patients also had other neurological findings later in life indicating possible association with the laryngeal defect.

Whitaker and Griffith[12] in 1977 reported three patients receiving vincristine and vinblastine, who developed hoarseness and were found to have recurrent laryngeal paralysis. In none of these patients was airway obstruction a problem. The incidence of side effects of these drugs in adults is three times greater than in children.

Holinger et al[13] in 1978 reviewed 21 infants and children with respiratory obstruction and apnea who had bilateral abductor vocal cord paralysis associated with meningomyelocele, hydrocephalus and Arnold-Chiari malformation. Tracheotomy, while relieving airway obstruction, did not stop the abnormal respiratory pattern or apnea and cyanosis. Fifteen of the 21 patients required a tracheotomy; 5 children died of significant apnea and all 5 had been tracheotomized. Ten patients had chronic aspiration from dysphagia. Autopsy on one patient revealed a paucity of neurons and degeneration of residual neurons in the nucleus ambiguus.

Ishak et al[14] in 1980 reported on the intraoperative dysfunction of the autonomic system in Arnold-Chiari malformation. Kinking and herniation of the brainstem is thought to cause impairment of its blood supply and the resultant ischemia leads to bilateral abductor vocal cord paralysis. Most of the signs of dysfunction are reversed with lowering of the intracranial pressure with ventriculoperitoneal shunting or decompression of the posterior fossa. Reduction of intracranial pressure by shunting or revision of a malfunctioning shunt may not relieve the apnea or bradycardia even with a tracheotomy.

Cohen et al[15] in 1977 reviewed 124 records of neonates requiring endoscopic procedures. Reported were 29 patients with vocal cord paralysis. The etiology of the paralysis was idiopathic in 25, 4 were associated with central nervous system (CNS) disease and 1 of these 4 had an associated meningomyelocele. Of the 4 patients born by breech delivery, 1 had a recurrent vocal cord paralysis. Of the 17 children born by cesarean section, 6 had vocal cord paralysis. Thirteen of the 29 patients with laryngeal paralysis required a tracheotomy.

Cohen[16] reported on the effectiveness of arytenoidectomy in children and performed this surgery in the preschool age period.

Pathophysiology. Dedo[17] in 1970 gave a detailed evaluation of laryngeal paralysis in humans and dogs. His work amply reinforces the following facts experimentally produced in dogs. 1) Section of the recurrent nerve causes momentary spasm with subsequent paralysis of the vocal cord in the paramedian position often with the arytenoid tilted forward. As the true cord becomes completely immobile, it lengthens and adducts slightly with each subsequent phonation. 2) Section of the superior laryngeal nerve with an intact ipsilateral recurrent laryngeal nerve always led to little or no visible change in the contracture of the vocal cords. However, the cricothyroideus muscle stopped contracting after spasm at the moment of dissection. 3) Section of the recurrent laryngeal nerve followed by ipsilateral section of the superior laryngeal nerve caused the essentially immobile cord in the paramedian position to become completely paralyzed in the more lateral position.

Gilmer et al[18] in 1970 reviewed the histological findings in two patients and confirm the modern concept of laryngeal paralysis.

Kirsch et al[7] gave a detailed study of laryngeal paralysis in association with meningomyelocele, hydrocephalus and Arnold-Chiari malformation in five patients. They gave an excellent review of the pathophysiology which follows in capsule form. Krause[19] in 1884 reported aphonia in dogs after bilateral extirpation of the gyrus precrucialis. Cushing[20] described coordinated laryngeal movements incidental to stimulating the human cortex at its caudal extremity adjacent to Broca's area. It was Foerster[21] who postulated the necessity of a bilateral lesion as a requisite to supranuclear laryngeal disturbances. Semon and Horsley[22] defined the topog-

raphy of the medullary laryngeal centers in dogs by correlating regional stimulation along the floor of the fourth ventricle with direct laryngoscopy.

Furstenberg and Magielski[23] confirmed and extended these observations and defined the functional pattern of cerebral organization in the primate nucleus ambiguus. This nuclear group is considered a substrate for peripheral motor innervation for the ipsilateral branchiomerically derived skeletal muscle of the larynx, esophagus and pharynx in both primate and the human. The human nucleus ambiguus is an elongated structure approximately 2 cm in length and 0.3 cm in width and extends from the upper border of the medulla and stria medullosis caudalward to the level of the motor decussation. The small rostral segment of the nucleus is the somatomotor center for palate and pharynx, with a motor outflow via the glossopharyngeal and cephalad vagal rootlets. The larger caudal extent of the nucleus ambiguus subserves laryngeal function exclusively and mediates its effect via the vagus nerve. The four paired groups of muscles responsible for vocal cord movements and one unpaired interarytenoid muscle group have discreet regional representation within the nucleus ambiguus.

Pressman and Keleman[24] in 1955 presented evidence that laryngeal muscles were innervated by two branches of the vagus nerve, the recurrent and the external branch of the superior laryngeal nerve. The latter nerve, which supplies the cricothyroideus muscle, a cord tenser and adductor, originates from the cell bodies situated in the central portion of the laryngeal segment of the nucleus ambiguus. The posterior cricoarytenoideus which functions as a vocal cord abductor is innervated by the recurrent laryngeal nerve fibers derived from cells located immediately subjacent to the cricothyroid cell group. The remaining arytenoid muscles receive their nerve supply from the most caudally disposed cells within the nucleus ambiguus through the recurrent laryngeal nerve.

Murtagh and Campbell[25] observed that adductor fibers continue to propagate action potentials despite a chemical or thermal blockade sufficient to paralyze abductor function. In addition, the chronaxy of adductor fibers, one of the most rapid thus far identified (0.1 ms) is tenfold shorter than that found in fibers subserving abduction.

METHOD

This study is an analysis of the charts of 100 children with laryngeal paralysis treated at the Childrens Hospital of Los Angeles. The charts were chosen at random by the record room personnel and it is estimated that there is an equal number of children who had laryngeal paralysis who had been treated but are not included in this review.

All of the children were examined by the authors and two other senior endoscopists. The direct laryngoscopy was performed either awake or with the use of a light general anesthetic. The patient breathed spontaneously during the examination. The speculum of the laryngoscope was placed into the vallecula and the sensory and motor function of the larynx was evaluated. In children who had a tracheotomy, the tube was always occluded in order to observe laryngeal mobility. Bronchoscopy was performed in all children to evaluate the tracheobronchial tree and to perform the tracheotomy when it was necessary. The larynx was examined at monthly intervals whenever possible.

FINDINGS

The findings as a result of this study are related to the sex of the patient, etiological factors, the onset of the disease, the type of pregnancy of the mother and the type of delivery of the child, symptoms related to the disease, the type of paralysis and the vocal cord position, the need for a tracheotomy and the age of decannulation, the preoperative diagnosis, the neurological status of the patient, the congenital and associated anomalies, the course and progress of the disease with statistics on recovery and resolution.

The results of this study are divided into the above statistical analysis related to all children as a group and then are presented in detail according to each specific etiological factor.

Sex. In this study, 59 patients were male and 41 patients were female.

Etiological Factors. The causes of laryngeal paralysis were as follows. Central nervous system disease occurred in 18% of the patients. Meningomyelocele with Arnold-Chiari malformation and usually with an associated hydrocephalus occurred in 14% of the patients. Birth trauma accounted for 19% of the paralyses; surgical and blunt trauma to the neck caused 11% of the paralyses; idiopathic causes were noted in 36% of the patients; a tumor, ie, a neuroblastoma of the neck, was the cause for paralysis in one of the patients and a familial cause was found in one patient.

Onset of Paralysis. The mean age of onset of laryngeal paralysis in all etiological categories was 38 days. Fifty-eight percent of the paralyses occurred within the first 12 hours of life, 66% by the second day of life and 80% within the first 36 days of life.

Mother's Pregnancy. The mother's pregnancy was completely normal in 77% of the children in this study. The pregnancies were abnormal in 23%. The abnormalities were premature labor, abruptio placenta, placenta previa, abnormal bleeding, eclampsia, maternal diabetes, drug overdose and hepatitis.

Type of Delivery. The child's delivery was completely normal in 65% of the patients. Thirty-five percent of the children had complicated deliveries with cesarean section in 15 and forceps delivery in 20. The complicated deliveries were usually due to abnormal presentation of the infant. Of the children born by cesarean section, 43% presented with bilateral abductor vocal cord paralysis and 57%

with unilateral vocal cord paralysis. Of the 20 born by forceps delivery, two thirds had bilateral abductor vocal cord paralysis and one third had unilateral vocal cord paralysis.

Symptoms. Stridor was prominent in 71% of the children, obstruction occurred in 44%, dysphonia was seen in 35%, dysphagia occurred in 38% and aspiration was seen in 14% of the patients.

Type of Paralysis. In patients of all categories, unilateral paralysis occurred in 38%. In five patients the side was not specified. In 33 of the patients in which the side was recorded, the right side was involved in 21% and the left was involved in 79%. Bilateral abductor vocal cord paralysis occurred in 62% of the patients.

Vocal Cord Position. In the group of 100 patients, the vocal cords were in the median position in 43% of the patients, paramedian in 30%, lateral in 5% and 23% were normal.

Tracheotomy. A tracheotomy was not necessary in any patient with unilateral vocal cord paralysis except when another obstructive lesion or aspiration problem was present. In 62 patients with bilateral abductor vocal cord paralysis, 45 (73%) required a tracheotomy. The mean age at which tracheotomy was performed varied with the etiology of the paralysis. The mean age of performing a tracheotomy in children with laryngeal paralysis in all categories was 34 days. In 89% of the patients who required a tracheotomy, the procedure was performed at the time the diagnosis was confirmed.

Of the 45 patients with tracheotomy, only 43 charts had a statement regarding decannulation. Fifty-four percent of these patients were decannulated within a mean period of 33 months. The remaining patients were lost to follow-up. Decannulation was readily accomplished in all five patients who had an arytenoidectomy. In those patients who had either congenital or postintubation subglottic stenosis, decannulation was delayed by this complication although the paralysis had recovered.

Preoperative Diagnosis. The preoperative diagnosis as determined by otolaryngologists was as follows: laryngomalacia in 11%, subglottic stenosis in 10%, vocal cord paralysis in 48% and stridor of undetermined origin in 26%. A specific diagnosis was not made in 5% of the patients. A specific diagnosis could only be confirmed by direct laryngoscopy.

Neurological Abnormalities. Laryngeal paralysis was of neurological origin in 33% of the patients. The neurological abnormalities were as follows: hypotonia (floppy child), Möbius' syndrome, neurogenic arthrogryposis multiplex congenita, Charcot-Marie-Tooth disease, cerebral palsy, hypoxic encephalopathy, Arnold-Chiari malformation with meningomyelocele and one patient with neonatal meningitis who had an associated laryngeal paralysis.

Congenital Anomalies and Associated Abnormalities. The congenital anomalies associated with laryngeal paralysis were pulmonary in 12, cardiovascular in 10, esophageal in 10, cervical abnormalities in 6, bronchial anomalies in 4 and meningomyelocele in 14 patients. One patient with meningomyelocele in this group did not have hydrocephalus. Other associated abnormalities were congenital subglottic stenosis, Pierre-Robin syndrome, hemivertebrae and urinary tract abnormalities.

Course and Progress. The mean age of resolution of the paralyzed larynx in all categories was 21.4 months. One third of the patients were followed for a mean of 35.2 months. In 33% of the patients, observation showed that there was a gradual change from paralysis to paresis progressing to complete recovery.

Recovery occurred in 48% of all patients. Thirty-three percent of the bilateral abductor vocal cord paralysis patients (21) recovered completely. Forty-four patients were lost to follow-up, almost all of them unilateral paralysis patients and many of them having been endoscoped only on one occasion. Of the 38 patients with unilateral paralysis, 13 were known to have completely recovered.

DATA RELATED TO SPECIFIC ETIOLOGY

Central Nervous System Disease. There were 18 patients in this etiological category. The mean age of onset was ten days. A tracheotomy was required in 12 of the 18 patients. The mean duration of a tracheotomy in this group was 48 months. Bilateral abductor vocal cord paralysis was present in 14 patients, unilateral paralysis was present in 4 patients.

Sixty-six percent of all patients recovered. Three of 4 patients with unilateral paralysis recovered completely and 1 died of apnea due to CNS disease. Of the 14 patients with bilateral abductor vocal cord paralysis, 5 completely recovered, 4 partially recovered, 3 did not recover and 2 of the patients had no information regarding recovery. The mean follow-up period of this group was 64.4 months, the mean age of recovery was 26 months, the mean duration of a tracheotomy was 48 months. Seven of the 12 tracheotomized patients were decannulated.

Birth Trauma. There were 19 patients in this category. The mean and median age of onset of symptoms was 5.6 days. A tracheotomy was required in six (31%) of the patients. The mean duration of tracheotomy in 4 of the 6 patients was 49 months. In two patients there was no follow-up available. Paralysis in this group was bilateral in 12 (63%) and unilateral in 7 patients (37%).

Nine of the 19 patients are known to have recovered. In ten of the patients there was no information available regarding recovery. Of the seven patients with unilateral paralysis, one completely recovered. No information was available in six pa-

tients. There is no record of patients showing partial or no recovery in this group. Of the 12 patients with bilateral paralysis, 5 recovered completely, 3 recovered partially and 4 had no available information. The mean follow-up period was 25 months. The mean age of recovery was 29 months. The mean duration of a tracheotomy was 49 months.

In this group of 19 patients, 8 were delivered with forceps, 9 were delivered by cesarean section, 1 patient by breech delivery and 1 patient presented with shoulder dystocia. All of these patients had been the product of a normal pregnancy. Nine of these patients had respiratory problems at the time of the delivery and three had been intubated at the time of birth. When only partial recovery occurred in this group, it was usually on the left side. When recovery was complete, it was always on the right side.

Meningomyelocele. There were 14 patients in this group. The mean age of onset of symptoms was 47 days. A tracheotomy was required in 71% of the patients. The mean duration of the tracheotomy was 37.2 months. In 13 patients (93%) paralysis was bilateral and in 1 patient it was unilateral. Recovery was noted only in the bilateral vocal cord paralysis patients. No information regarding recovery was available in the one patient with a unilateral paralysis. Of the 13 patients with bilateral abductor vocal cord paralysis, 6 completely recovered, 2 partially recovered, 3 did not recover and 2 had no information available regarding recovery.

The mean follow-up period was 37.9 months. The mean age of recovery was 21.5 months; the mean duration of a tracheotomy was 37.2 months. Of the 14 patients, 7 were decannulated, 3 were not decannulated and 4 of the patients were lost to follow-up.

Idiopathic Category. There were 36 patients in this group. The mean age of onset of paralysis in this group was 53 days. A tracheotomy was performed in ten patients (28%). The mean age of decannulation of these patients who were followed was 33.5 months.

Paralysis in this group was bilateral in 19 patients (53%) and unilateral in 17 patients (47%).

Recovery of motion of the vocal cords was as follows. In the unilateral group of 17 patients, complete recovery was noted in 4. No information was available in 12, 0 had partial recovery and 1 did not recover. Of the 19 patients with bilateral abductor vocal cord paralysis, 4 completely recovered, 7 partially recovered, 3 did not recover. No information was available in five of these patients. The mean age of follow-up was 75.6 months and the mean age of recovery was 13 months.

Six of the ten patients who were tracheotomized were decannulated, 1 patient died of overwhelming sepsis. Two patients are still being followed and one patient was lost to follow-up.

Surgery. There were nine patients in this group. In eight patients the paralysis followed repair of a tracheoesophageal fistula and/or atresia. One patient developed paralysis following ligation of a patent ductus arteriosus. The mean age of onset of symptoms in this group was 42 days. A tracheotomy was required in three of the patients. The mean duration of a tracheotomy was 28 months.

The type of paralysis was bilateral in four and unilateral in five. Of the 5 children with unilateral paralysis, 1 completely recovered and 4 had no information available regarding recovery. Of the 4 patients with bilateral vocal cord paralysis, 2 completely recovered, 1 partially recovered and 1 had insufficient information regarding recovery.

The mean follow-up period in this group was 33.3 months. The mean age of decannulation was 28 months. Three of the nine patients had a tracheotomy. One child still has a tracheotomy and two have been decannulated.

Blunt Trauma. There were three patients in this group. One of the patients required a tracheotomy. In two of the patients, the paralysis was bilateral and in one it was unilateral. The tracheotomized child was lost to follow-up. In two patients in whom there was adequate follow-up, the mean duration of the paralysis was 6.5 months.

Familial Group. In this category of one patient, a female, the paralysis was bilateral. A tracheotomy was performed at the age of 14 months. An arytenoidectomy was performed at age 5 years and 1 month. The patient was decannulated three months later. The symptoms in this child were chiefly stridor with obstruction to the airway. This patient had the early diagnosis of arthrogryposis multiplex congenita which later, after further neurological developments, was diagnosed as Charcot-Marie-Tooth disease. This patient is still seen periodically almost 11 years after her arytenoidectomy and has had multiple orthopedic procedures requiring intubation.

Tumor. There was one patient in this group. His diagnosis was a primary neuroblastoma of the neck. The age of onset of symptoms in this child was 1 month. Two weeks following the diagnosis a tracheotomy was performed and was necessary for 17 months. The paralysis was unilateral and on the left side. This patient had been intubated prior to his tracheotomy and developed a laryngeal subglottic stenosis. He also had a mild form of laryngomalacia. The left vocal cord paralysis never recovered.

TREATMENT

The patients who have laryngeal paralysis require close observation. To prevent chronic hypoxia

and brain damage a tracheotomy is mandatory in children with an inadequate airway. One should not await the development of cyanotic episodes before instituting an artificial airway. Isolated unilateral paralysis requires no treatment. Even when there is no recovery, compensation by the normal vocal cord gives adequate phonation except when the paralysis is in the lateral position.

In patients with bilateral abductor vocal cord paralysis due to meningomyelocele with Arnold-Chiari malformation, tracheotomy should not be performed until a shunt procedure has been done. The airway may be supported by a small endotracheal tube. If a functioning shunt tube does not clear the paralysis, a tracheotomy should be performed. This is especially necessary in children who display severe aspiration or apnea spells. The authors have seen a number of patients in whom shunt failure recreated bilateral abductor vocal cord paralysis. When the shunt tubes were revised and became functional, the vocal cord paralysis resolved.

In children who had arytenoidectomies performed, uniformly good results were obtained. The voice was excellent and an adequate airway was obtained so that decannulation was possible. Some exercise intolerance occurred in most of these patients.

A nerve pedicle reinnervation has not been done in any of the patients in this study. There has been no report of a large series of patients in the pediatric age group in which this procedure was performed successfully.

DISCUSSION AND CONCLUSIONS

The causes of laryngeal paralysis in the pediatric population are different from those in the adult. In the latter, unilateral vocal cord paralysis is the result of surgical procedures, trauma, neoplasia of the neck and chest, CNS disease, peripheral neuropathies and idiopathic causes. Bilateral abductor vocal cord paralysis in the adult may be the result of surgical injury, most often thyroidectomy, neurological disorders, malignancies of the neck and upper chest, in addition to other causes such as neuropathies.

In children, in contrast to the adult, the major causes of vocal cord paralysis, both unilateral and bilateral, are birth trauma, CNS disease, meningomyelocele with Arnold-Chiari malformation and hydrocephalus, idiopathic, surgical trauma and disease of the heart and great vessels.

A thorough examination of the larynx was performed in all children with care to evaluate both motor and sensory function. Cricoarytenoid fixation was excluded by direct palpation of the joint.

The sex distribution in this study tends to support the fact that the male is more often involved than the female.

The etiological factors as determined by this study were CNS disease, birth trauma, meningomyelocele with Arnold-Chiari malformation and hydrocephalus, idiopathic, surgical trauma, blunt trauma to the neck, familial and tumor of the neck. In this study, idiopathic laryngeal paralysis is so labeled when a specific etiological factor could not be elicited after extensive studies. The term familial paralysis is applied to the one child reported in this series because the mother and a sister of this patient also had bilateral abductor vocal cord paralysis associated with Charcot-Marie-Tooth disease.

The overall mean age of onset of symptoms of all categories was 38 days. The earliest evidence of laryngeal paralysis was in the group of children with birth trauma. Children with CNS disease showed evidence of laryngeal paralysis within the first ten days of life. However, in the group of patients with meningomyelocele with Arnold-Chiari malformation and hydrocephalus, the mean age of onset was 47 days. This delay in onset of symptoms may be related to the progressive development of hydrocephalus which followed the repair of the meningomyelocele. Uncomplicated hydrocephalus does not produce laryngeal paralysis. In the postoperative surgery and idiopathic groups, the mean age of onset of symptoms relates to the specific cause of the paralysis.

Complicated delivery with abnormal presentation or positioning of the infant and the need for cesarean section birth was associated with laryngeal paralysis in almost 20% of the patients. The relatively high incidence of bilateral abductor vocal cord paralysis in association with complicated deliveries should alert the physician to this group of high risk patients.

The symptoms of paralysis varied in degree of severity within the different etiological categories. Stridor was the most common presenting symptom; it was always inspiratory and crowing in character. The stridor was most pronounced in patients with CNS disease, surgical or birth trauma and meningomyelocele with Arnold-Chiari malformation. Severe obstruction to the airway, which required immediate intubation, was seen most commonly in patients with bilateral abductor vocal cord paralysis following surgical procedures and complicated deliveries. An endotracheal tube was usually inserted to insure the airway and to allow for possible recovery of the paralysis. In some of these patients, subglottic stenosis developed which prolonged the need for a tracheotomy even after the laryngeal paralysis had recovered. Dysphagia was more common in the CNS group of patients, frequently because of a poor suck reflex or associated cranial nerve deficiencies. Aspiration occurred in children

with loss of laryngeal sensation, cranial nerve defects and lateral position of one or both vocal cords. This problem occurred in patients with CNS disease and meningomyelocele with Arnold-Chiari malformation which would indicate a defect of both superior and recurrent laryngeal nerves. Dysphonia was an uncommon symptom whether the paralysis was unilateral or bilateral. Apnea occurred in some patients with CNS disease and meningomyelocele with Arnold-Chiari malformation even after the hydrocephalus had been corrected by a shunt procedure or after a posterior fossa decompression had been performed. Patients with apnea required a tracheotomy for ventilation and in some patients a diaphragm pacemaker was necessary to control respirations.

The type of paralysis varied within each etiological category. Sixty-six percent of the patients in this study had bilateral abductor vocal cord paralysis. In the remaining patients with unilateral paralysis, the left side was involved in almost 80% of the children. It is significant that in the group with CNS disease, meningomyelocele and Arnold-Chiari malformation and birth trauma, that the right and left vocal cords were equally involved, whereas in the other categories the left vocal cord paralysis predominated. Although bilateral and unilateral vocal cord paralysis occurred in all etiological groups of patients, an overwhelming majority of the patients with meningomyelocele with Arnold-Chiari malformation and CNS disease had bilateral abductor vocal cord paralysis. Within the groups of birth and blunt trauma, bilateral vocal cord paralysis occurred in two thirds of the patients. In the other groups, the type of paralysis was almost equal in numbers.

In 5% of the patients, lateral position occurred in association with sensory paralysis and severe aspiration. This defect occurred in 2 patients within the meningomyelocele with Arnold-Chiari malformation group, 1 in the CNS group and 1 in the idiopathic group. The child with a unilateral vocal cord paralysis in the lateral position (idiopathic group) did not aspirate, but had an extremely poor voice.

A tracheotomy was not necessary in any patient with an isolated unilateral paralysis. In 73% of the patients with bilateral abductor vocal cord paralysis a tracheotomy was performed. The mean age of tracheotomy was 34 days.

Arytenoidectomy was performed in five patients who did not have spontaneous recovery from laryngeal paralysis. All of these patients were decannulated following surgery; they all had a good voice and adequate airway, but some had reduction in exercise tolerance.

Tracheotomy was necessary in patients with bilateral abductor vocal cord paralysis secondary to meningomyelocele with Arnold-Chiari malformation and hydrocephalus, CNS disease and in patients with surgical and birth trauma. In the patients with CNS disease and birth trauma, the tracheotomy was required for approximately four years. It should be noted that when a child with bilateral abductor vocal cord paralysis due to birth trauma did not require a tracheotomy, recovery was uniform within six months or less. Children with meningomyelocele with Arnold-Chiari malformation and hydrocephalus required a tracheotomy for almost three years. The presence of a subglottic stenotic lesion delayed decannulation.

When a neurological or congenital abnormality was associated with laryngeal paralysis, it was usually of a serious nature.

Some of the patients in this study were followed for a period of seven years or more. Almost all of the 14 patients who were lost to follow-up had unilateral paralysis. Of the patients with bilateral abductor vocal cord paralysis, one third recovered completely.

It must be emphasized that since recovery from paralysis of the larynx may occur in children, even after a period of a year or more from the time of its onset, observation rather than active surgical treatment must rule.

ACKNOWLEDGMENT — Gratitude is expressed to Rose Marie Lapicola for her dedication and help in the preparation of this manuscript. Gratitude is also expressed to Drs. Alden H. Miller and Max K. Pierce for allowing their patients to be included in this study.

REFERENCES

1. Clerf LH. Unilateral vocal cord paralysis. JAMA 1953; 151:900-3.

2. Cunning DS. Unilateral vocal cord paralysis. Ann Otol Rhinol Laryngol 1955; 64:487-93.

3. Holinger PH, Brown WT. Congenital webs, cysts, laryngoceles and other anomalies of the larynx. Ann Otol Rhinol Laryngol 1967; 55:744-52.

4. Morse HR. Vocal cord paralysis. Gen Pract 1969; 40: 79-84.

5. Goff WF. Vocal cord paralysis, analysis of 229 cases. JAMA 1970; 212:1378-9.

6. Bluestone CD, Delerme AN, Samuelson GH. Airway obstruction due to vocal cord paralysis in infants with hydrocephalus and meningomyelocele. Ann Otol Rhinol Laryngol 1972; 81: 778-83.

7. Kirsch WM. Duncan BR, Black FO, Stears JC. Laryngeal palsy in association with meningomyelocele, hydrocephalus and the Arnold-Chiari malformation. J Neurosurg 1968; 218:207-14.

8. Fearon B, Ellis D. The management of long-term airway problems in infants and children. Ann Otol Rhinol Laryngol 1971; 80:669-77.

9. Hengerer AS, Tucker HM. Restoration of abduction in the paralyzed canine vocal cord. Arch Otolaryngol 1973; 97:247-50.

10. Tucker HM. Human laryngeal reinnervation. Laryngoscope 1976; 86:769-79.

11. Gacek RR. Hereditary abductor vocal cord paralysis. Ann Otol Rhinol Laryngol 1976; 85:90-3.

12. Whittaker JA, Griffith IP. Recurrent laryngeal nerve paralysis in patients receiving vincristine and vinblastine. Br Med J 1977; 1:1251-2.

13. Holinger PC, Holinger LD, Reichert TJ, Holinger PH. Respiratory obstruction and apnea in infants with bilateral abductor vocal cord paralysis, meningomyelocele, hydrocephalus and Arnold-Chiari malformation. J Pediatr 1978; 92:368-73.

14. Ishak BA, McLone D, Seleny FL. Intraoperative autonomic dysfunction associated with Arnold-Chiari malformation. Childs Brain 1980; 7:146-9.

15. Cohen SR, Eavey RD, Desmond MS, May BC. Endoscopy and tracheotomy in the neonatal period. Ann Otol Rhinol Laryngol 1977; 86:577-83.

16. Cohen SR. Arytenoidectomy in children. Laryngoscope 1973; 83:1293-9.

17. Dedo HH. The paralyzed larynx: an electromyographic study in dogs and humans. Laryngoscope 1970; 80:1455-1517.

18. Gilmer WS, Arnold GE, Stephans CB. Vocal cord position in laryngeal paralysis. Two further neurohistologic studies. Arch Otolaryngol 1970; 91:575-80.

19. Krause H. Über die Beziehungen der Grosshirnrinke zu Kehlkeps und Rachen. Arch Physiol 1884; 8:203-10.

20. Cushing H. A note upon faradic stimulation of the postcentral gyrus in conscious patients. Brain 1909; 32:44-53.

21. Foerster O. Motorishe Felder un Bahnen. In: Bunke O, Foerster O, eds. Handbuch der Neurologie. Vol 6.; Berlin: Verlag von Julius Springler, 1936:1-357.

22. Semon F, Horsley H. On the relations of the larynx to the motor nervous system. DT Med Wschr 1890; 16:672-9.

23. Furstenberg AC, Magielski JE. A motor pattern in the nucleus ambiguus: clinical significance. Ann Otol Rhinol Laryngol 1955; 64:788-93.

24. Pressman JJ, Keleman G. Physiology of the larynx. Physiol Rev 1955; 35:506-54.

25. Murtagh JA, Campbell CJ. Physiology of the recurrent laryngeal nerve: report on progress. J Clin Endocrinol Metab 1952; 12:1395-1401.

LARYNGEAL PAPILLOMA: RESULTS OF TREATMENT WITH THE CO_2 LASER AND PODOPHYLLUM

HERBERT H. DEDO, MD ROBERT K. JACKLER, MD

SAN FRANCISCO, CALIFORNIA

From 1976 to 1982, 109 patients with recurrent laryngeal papillomas were treated with a total of 548 CO_2 laser excisions followed by podophyllum painting. There was high incidence of multiple sites of involvement, especially the tracheobronchial tree (18.3%) and palate (8.3%). Four patients had pulmonary parenchymal involvement. Patients were treated at 2-month intervals until they entered remission. Thereafter, microdirect laryngoscopies were advised at longer intervals. Remission was achieved in 41%; it occurred at all ages although it was most common during adolescence and rarest in the very young and very old. Many patients obtained remission with the CO_2 laser after multiple prior cup forceps removals had not achieved remission. Only two tracheotomies (1.8%) were required and no deaths occurred. When compared with mechanical methods of papilloma removal, CO_2 laser excision with podophyllum painting represents a clear advance in terms of preservation of laryngeal physiology and avoidance of life-threatening complications.

INTRODUCTION

Laryngeal papillomas (LP) were first described during the 17th century by Marcellus Donalus who wrote describing them as "warts in the throat."[1] A clear description did not emerge until the late 19th century when MacKensie differentiated papillomas from other benign lesions of the larynx.[2]

Squamous papillomas are the most common laryngeal tumor occurring in children. They are also among the most frequently encountered benign laryngeal growths at any age. Histologically, they are composed of multiple finger-like projections consisting of a central core of fibrous tissue covered by a fairly regular stratified squamous epithelium. On clinical rather than histological grounds they have been divided into two forms, adult and juvenile. In children, the disease often takes a more virulent course characterized by a rapid growth, formation of large exophytic clusters, and involvement of other areas of the upper aerodigestive tract in addition to the larynx. Adults, on the other hand, generally have a more quiet course with less frequent recurrences and better anatomic confinement. Malignant transformation has been reported to occur in a small percentage of cases most often following radiation therapy.[3]

ETIOLOGY

It is commonly held that LPs are caused by a virus of the papova group, although absolute proof has been elusive.[4] Recently, using an immunoperoxidase stain, human papilloma virus (HPV) has been identified in approximately 50% of LP.[5] Even more convincing is the work of Lancaster and Jenson who employed sophisticated DNA hybridization techniques to show the presence of papilloma virus genus-specific DNA sequences in LP tissue.[6] Unfortunately, reproducible tissue culture for HPV has yet to be achieved, and isolation of virus from LP has not yet been reported.

In a classical experiment Uhllman transplanted papilloma from a child with LP to his arm and then to the mucous membrane of a dog.[7] Others, more recently, have been unable to duplicate this work. Clinically, person-to-person transmission has long been suspected in neonates, but not in adults. The majority of young children with LP have a positive maternal history of genital warts (condyloma acuminata) during pregnancy.[8] The frequent association of LP and skin warts lends further circumstantial evidence of the viral etiology of this disease.

THERAPY

Although papillomas are histologically benign, they can potentially be life-threatening. As they grow within the larynx or tracheobronchial tree, they may compromise the airway, sometimes leading to asphyxiation. Goals of therapy are maintenance of airway patency, preservation of voice, and elimination of papillomas.

The plethora of real and purported therapies for LP testify to the frustration of the physicians who have dealt with this disease over the years (Table 1). Basically, three approaches have been used: 1) chemical inhibition of papilloma growth (eg, antimetabolites, hormones, podophyllum), 2) physical removal (eg, cup forceps removal, cryosurgery, ultrasound, laser), and 3) enhancement of the immune response (eg, vaccines, transfer factor, interferon). Standard care up to this time has consisted of repeated surgical removal with either cup forceps or the CO_2 laser. We believe this study clearly shows

From the Department of Otolaryngology-Head and Neck Surgery, University of California School of Medicine, San Francisco.

Presented at the meeting of the American Laryngological Association, Palm Beach, Florida, May 1-2, 1982.

REPRINTS — Herbert Dedo, MD, 727A, University of California School of Medicine, San Francisco, CA 94143.

TABLE 1. TREATMENT OF LARYNGEAL PAPILLOMA*

Medical
- Antibiotics (Aureomycin, chloramphenicol, etc)
- Chemotherapeutic agents (methotrexate, bleomycin, etc)
- Electrolytes (calcium, magnesium)

Immunologic
- Heterohemotherapy
- Interferon
- Lymphokines
- Transfer factor
- Vaccine (smallpox, bovine wart, inactivated autogenous)

Physical
- Cryosurgery
- Diathermy
- Electrocautery
- Laser
- Radiation
- Ultrasound

Surgical
- Cup forceps removal
- Thyrotomy with skin or vein graft
- Tracheotomy for "laryngeal rest"

*Partial list.

the advantage of the laser approach.

Although many techniques have been proposed to control the disease, a true cure most probably awaits elucidation of the host-virus immune interaction or the development of an effective antiviral agent. The latest enthusiasm is the use of interferon. Haglund et al[9] have reported seven patients treated with systemic leukocyte interferon with encouraging preliminary results. Unfortunately, papillomas had a tendency to recur following cessation of therapy.

MATERIALS AND METHODS

Patients who underwent laser excision of papillomas were admitted to the University of California Hospital, San Francisco (UCSF). Patients were usually discharged from the hospital on the morning following surgery, occasionally on the same day.

Most patients were referred to UCSF with the diagnosis of LP already having been made, but some were first diagnosed here. The diagnosis of pulmonary parenchymal extension presents a special problem. This was suspected in a patient with laryngeal or tracheal papillomas when radiographic evidence of bullous change, nodulation, or cavitation were present in the absence of an alternative explanation.[10]

For laser excision, patients were placed under general anesthesia via an endotracheal tube wrapped with aluminum tape. In children, a cuffless tube wrapped with 0.64 cm (¼ in) aluminum foil tape (Radio Shack Corp) was used. The wrap must begin at the very tip of the tube to protect against ignition. In adults, a 1.27 cm (½ in) tape (3M, Minnesota Mining & Manufacturing) was used, with the wrap commencing immediately above the endotracheal tube balloon. In both age groups, tape was carefully wound for 5.1 cm (2 in) up the tube. When a 5.1 cm wrap is used and the upper edge of the foil tape is set at the level of the tip of the epiglottis, the endotracheal tube tip will be at the correct level within the trachea. When necessary, for further protection, moist cottonoids attached to long strings were placed in the subglottic space. For best exposure, the smallest tube compatible with adequate ventilation was selected (Table 2). Laryngoscopy was performed with an adult, adolescent, or pediatric Dedo-Pilling laryngoscope using a tooth guard. For laser surgery this was held in a Lewy suspension arm supported by a Mayo stand over the patient's chest. While manipulating the laryngoscope, care was taken to avoid mucosal breaks which can lead to seeding of the

TABLE 2. ENDOTRACHEAL TUBE SIZE FOR CO_2 LASER SURGERY

Patient's Age	*Tube Size (ID)*	*Type of Tube*
Infant-3 yr	2.5 mm	Cuffless plastic
3-7 yr	3.0 mm	Cuffless plastic
7-10 yr	3.5 mm	Cuffless plastic
10-16 yr	20 F (4.5 mm)	Cuffed red rubber or plastic
Adult female	22 F (5.0 mm)	Cuffed red rubber or plastic
Adult male	24 F (5.5 mm)	Cuffed red rubber or plastic

ID - Internal diameter; F - French.

papillomas. Following mapping of the papillomas and photography, biopsies were taken with cup forceps and sent for routine pathology. A model 400 or 450 Coherent CO_2 laser was then used to vaporize the papillomas. The laser was controlled by a micromanipulator attached to a Zeiss operating microscope when treating papillomas of the larynx, pharynx, nasopharynx, nose, or skin. A Coherent 450 CO_2 laser bronchoscope was used to remove tracheal or main stem bronchial disease.

Papillomas were excised with a 0.5 to 1 mm cuff of surrounding normal-appearing tissue. Excision was carried just past the base of the papillomas to the submucosal loose areolar tissue (Reinke's space). Vocalis muscle and perichondrium were carefully preserved. Slightly deeper excisions were required in areas where papillomas repeatedly recurred in the same anatomic location. We have observed trapped microcysts in the scar tissue under recurrent papillomas. Only when these microcysts were removed did these recalcitrant areas with papillomas finally clear. Care was taken not to denude both free edges of the anterior 3 mm of the true or false vocal cords to avoid web formation. Laryngoceles of the false cord will develop if the orifice of the ventricle is denuded circumferentially. This is avoided by excising the edge of the false cord and its papillomas with our ventricle protector (Pilling) in place to preserve the mucosa on the top of the true vocal cord. Occasionally, an existing web or adhesion had to be lysed in order to expose occult papillomas in the ventricle or subglottic region. The ventricle was exposed by cutting the false vocal cord back until its raw inferior edge rested upon intact mucosa on the ventricle floor. When anterior commissure webs were simply divided with the laser they virtually always recurred. Definitive treatment for extensive (20% or more) anterior commissure webbing at the false or true cord level was undertaken with the endoscopic Teflon keel technique.[11]

When skin papillomas were brought to our attention by the patient they were excised with the CO_2 laser along with a 1-mm cuff of normal skin. When excision was carried through the basal layer these seldom recurred. Papillomas of the pharynx and palate were exposed with a mouth gag and, when in the nasopharynx, required the use of metallic mirrors to direct the laser beam. Following papilloma excision, in all locations except the skin, the bed was treated wtih 25% podophyllum.[12] This caustic resin is used to discourage papilloma reimplantation on raw surfaces. After extensive experience no adverse effects have been found with its use.

Postoperative respiratory distress was uncommon except in patients with convex vocal cords or extensive tracheal disease. These patients were promptly treated with humidified oxygen, nebulized racemic epinephrine, and intravenous methylprednisolone, usually with good results. Reintubation was avoided, when possible, and tracheotomy was done only as a last resort. Some of the patients who developed postoperative respiratory distress were found to have convex vocal cords even after thorough papilloma removal. The bulging portion has been found to contain numerous trapped microcysts which expand the vocal cords thus impinging upon the airway. When the CO_2 laser was used to excise the convex portion back to a straight line from the anterior commissure to the arytenoid, postoperative distress did not recur.

Patients were scheduled for repeat treatments at 2-month intervals. Occasionally, a child with very rapidly growing disease required removal more often, even as frequently as once a week. When a patient became free of disease, he was re-examined under

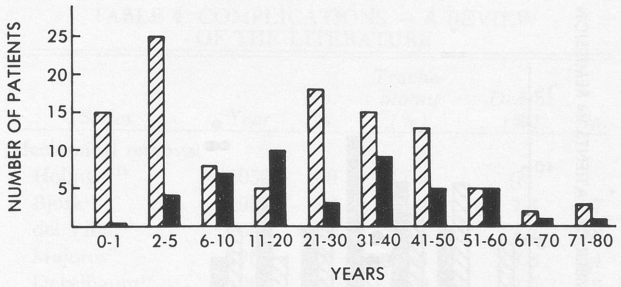

Fig. 1. Age at onset (▨ - 109 patients) compared with age at remission (■ - 45 patients).

anesthesia in approximately twice the preceding interval (4, 8, 16 months, etc), providing that papillomas had not recurred.

RESULTS

Over a 6-year period (1976 to 1982) a total of 109 patients underwent 548 laser removals of laryngeal papillomas. This averages just over five procedures per patient. Prior to commencing laser therapy, these same patients had undergone approximately 1050 conventional surgical removals, approximately 10 per patient, without eradication of their disease.

Sex Ratio. There were 66 male patients (60.6%) and 43 (39.4%) patients were female. This agrees with the slight male predominance often noted in the literature.

Race. A wide racial distribution was found: white — 81 (74.3%); black — 15 (13.7%); Hispanic — 8 (7.3%); oriental — 3 (2.8%); and Arab — 2 (1.8%). This is not substantially different from the distribution of patients within our referral population at large.

Geographic Location. The majority of our patients were from California with 44 (40.4%) residing in the San Francisco Bay area, and 46 (42.2%) from more distant parts of the state. Fifteen patients (13.8%) came from other states, and 4 (3.6%) from other countries.

Age at Onset. This was considered to be the age at which the patient first underwent a surgical procedure for papillomas (Fig. 1). Longer histories of hoarseness often existed, but accurate estimation of this period is difficult. Although no age is immune from LPs, they most often begin in childhood and are uncommon in old age. Forty-eight of our patients (44%) developed their disease in the first ten years of life, of these 40 (36.7%) in the first five years.

Sites of Involvement. We have confirmed the findings of others that this disease represents a diathesis of the entire upper aerodigestive tract, rather than a disease limited to the larynx (Table 3). Thirty-two of our 109 patients (29.4%) manifested extralaryngeal involvement. One half of these were under five years of age at the onset of their disease. Virtually

TABLE 3. SITES INVOLVED IN LARYNGEAL PAPILLOMATOSIS

Site	*No. of Patients*	*%*
Larynx	109	100.0
Trachea	17	15.6
Main stem bronchi	3	2.8
Lung parenchyma (suspected)	4	3.7
Pyriform sinus	2	1.8
Pharyngeal wall	4	3.7
Vallecula	4	3.7
Tongue	2	1.8
Tonsils	5	4.6
Palate	9	8.3
Oral mucosa	2	1.8
Nose	2	1.8
Nasopharynx	5	4.6
Skin	7	6.4

all of the patients with widespread disease involving multiple sites were young children. Tracheobronchial disease was found in 20 patients (18.3%) making it the most common extralaryngeal site. Next common were the soft palate — 9 (8.3%), skin — 7 (6.4%), nasopharynx — 5 (4.6%), and tonsils — 5 (4.6%).

Pulmonary Papillomatosis. Four patients had suspected pulmonary parenchymal involvement. Only one patient (Case 2) developed this problem while undergoing laser therapy.

Case 1. A 29-year-old female whose disease began at age 2 years had a tracheotomy in infancy and has never been decannulated. She has lost count after more than 100 procedures including frequent removals from the tracheobronchial tree. Chest x-ray film reveals widespread scarring and chronic right upper lobe consolidation and abscess secondary to papillomas obstructing the right upper lobe bronchus.

Case 2. A 9-year-old male whose disease began at age 5 has had 17 procedures with frequent removals from the tracheobronchial tree, but no tracheotomy. His disease began on the tonsils and then spread sequentially to the larynx, trachea, and finally the lungs. At this time his only remaining disease is in the lung parenchyma. Chest x-ray film now reveals bilateral diffuse nodular disease.

Case 3. A 76-year-old male whose disease began at age 62 had a tracheotomy early in his disease course and was never decannulated. He has undergone 59 procedures with frequent removals from the trachea. Chest x-ray film reveals cavitary and bullous changes in both lungs.

Case 4. A 13-year-old male whose laryngeal disease began at age 9 has had neither trachoebronchial disease nor a tracheotomy. He has undergone 25 procedures to date. Chest x-ray film reveals severe bullous changes in both upper lobes.

Number of Procedures. The majority of patients, 66 (60.6%), had from 2 to more than 100 cup forceps removals prior to beginning laser therapy (Fig. 2). Another 24 patients (22%) had only a single diagnostic cup forceps removal prior to referral. Only 19 patients (17.4%) began their treatment with the laser. The average patient had a lifetime total of approximately 15 procedures, 5 of these being laser.

Remission Rate. Forty-five patients (41.3%) were free of disease at their last examination. In 80%, including all of the children, this was deter-

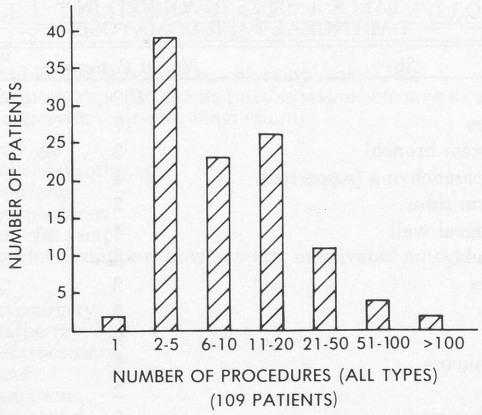

Fig. 2. All types of procedures (109 patients).

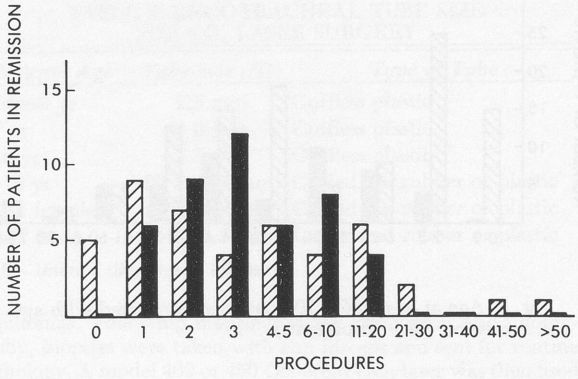

Fig. 3. Number of prior cup forceps removals without remission (▨ - 45 patients) compared with the number of laser removals required to achieve remission (■ - 45 patients).

mined at microdirect laryngoscopy. A few selected adults with easily visualized larynges were followed by indirect examination alone after no papillomas were evident at one microdirect laryngoscopy and symptoms were absent. However, it is preferable to use microdirect laryngoscopy for follow-up as indirect examination alone frequently misses subtle or anatomically hidden papillomas. We have had approximately ten patients in whom indirect laryngoscopy appeared clear while papillomas were found at microdirect laryngoscopy the very next day. Length of follow-up varied from two months to two years with the average being 8.5 months. There was a tendency for patients not to return for follow-up after two or three examinations revealed no papillomas.

Remissions occurred at all ages (Fig. 1), although it was most common in adolescence and rarest in the very young and very old. While 32.1% of patients developed their disease from birth to age 5, only 8.9% of remissions occurred in this age group. On the other hand, the 11- to 20-year-old group accounted for 22.2% of all remissions, while only 4.6% developed their disease during these years. We did not find the paucity of midlife remissions reported by Strong et al.[8]

The number of prior cup forceps removals bore little relation to the likelihood of achieving remission on laser therapy (Fig. 3). Fifty-two percent of patients who had undergone more than two previous mechanical removals entered remission on laser therapy. Twelve patients obtained remission despite more than ten previous cup forceps removals without remission. Two of these patients had more than 40 previous mechanical removals.

It has been our observation that most patients require several laser treatments before achieving remission (Fig. 3). This is because of the necessity of working on only one side of the anterior commissure at a time. Although our protocol calls for repeat excision at 2-month intervals, alternate sides of the anterior commissure are thus, in reality, treated only every four months. Occasionally, especially in children, this allows considerable regrowth during the interim. Patients not responding at all after ten laser treatments seldom enter remission. However, contrary to Strong et al,[8] we had four patients who remitted after more than 11 laser treatments.

Complications. Only two patients (1.8%) required tracheotomy while undergoing laser therapy. They were young, aged 1 and $2\frac{1}{2}$ years. In each case, rapidly growing, circumferential, obstructing laryngeal papillomas resulted in acute upper airway obstruction. One patient was successfully decannulated three months post-tracheotomy and went on to have a clear larynx after 19 laser treatments over a 4-year period. The other remained cannulated despite multiple procedures and is now followed elsewhere. There were 12 patients who had undergone tracheotomy prior to beginning laser therapy. Decannulation was achieved in six of these.

Nine patients required endoscopic Teflon keel placement[11] for significant anterior glottic webbing; in seven of these the webbing was present upon referral. In two patients substantial webbing developed while undergoing laser therapy. These occurred early in our series before development of anterior commissure protectors (Pilling Co) which made it possible to remove papillomas precisely to the anterior midline.

No deaths have occurred to date, but there have been several close calls in patients with severe airway compromise.

Malignant Degeneration. Three adults, age 45, 72, and 78, developed squamous cell carcinoma of the larynx. All developed their papillomatous disease during adulthood at ages 43, 56, and 76 respectively. They had from 6 to 14 laser and cup forceps excisions prior to the diagnosis of malignancy. The final histology in each case was verrucous carcinoma. Earlier pathology specimens, when reviewed, still appeared to show benign squamous papillomas. In contrast to the literature, none of

TABLE 4. COMPLICATIONS — A REVIEW OF THE LITERATURE

Series	Year	No. Pts.	Tracheotomy (%)	Deaths (%)	No.
Mechanical removal					
Holinger[13]	1950	109	17.4	(?)	
Bjork[14]	1956	98	8.2	7.1	7
del Villar[15]	1956	112	52.7	7.1	8
Majoros[16]	1964	101	64.3	13.8	14
Dekelbaum[17]	1965	67	17.9	3.0	2
Klos[18]	1970	62	11.3	8.0	5
Cohen[19]	1980	90	4.4	3.3	3
Laser removal*					
Strong[8]	1976	110	2.7	0	
Dedo & Jackler	1982	109	1.8	0	

*Includes only tracheotomies performed while undergoing laser therapy.

our patients gave a history of prior irradiation therapy to the neck. All three are alive and well after laryngectomy, although one patient continues to form papillomas in the tracheostome.

DISCUSSION

Although laryngeal papillomatosis is a benign disease, it is traditionally associated with a substantial morbidity and mortality. The major sources of morbidity are 1) airway obstruction secondary to laryngeal stenosis or exophytic papilloma growth, 2) deterioration of voice, 3) pulmonary infections, and 4) loss of time from work or school. Mortality most often results from asphyxiation caused by exuberant papilloma growth, blockage of the tracheotomy tube, or postoperative edema. A high correlation between the presence of a tracheotomy and mortality exists. Death may also occur with malignant degeneration or where pulmonary papillomatosis results in extensive destruction of lung tissue.

A literature review (Table 4)[13-19] of seven major studies over the last 30 years reflects the high potential for complications in this disease. An average of 25% tracheotomies and 7% deaths was obtained with conventional therapy. Using CO_2 laser excision followed by podophyllum painting we had only 1.8% tracheotomies and no deaths in 109 patients. This agrees quite well with the only other large laser series in the literature, that of Strong et al.[8] They required only 2.7% tracheotomies and also were without deaths. We believe that these statistics demonstrate the clear-cut superiority of CO_2 laser therapy over traditional mechanical methods.

There are several factors contributing to the paucity of morbidity and mortality in this series. Most important is the combination of microdirect laryngoscopy and the surgical CO_2 laser which permits more precise, complete, and bloodless papilloma excision. The relatively minimal postoperative edema following laser surgery circumvents many of the acute airway problems encountered following mechanical avulsion. Also, the long-term effects of scarring, webbing, and stenosis are infrequent. Another important factor is the regular eradication of papillomas on a scheduled basis before extensive regrowth occurs. Formerly, many surgeons waited until symptoms of airway obstruction or severe vocal disturbance occurred before undertaking treatment. This only encourages complications and minimizes chances of remission. Also essential is skillful anesthesia performed by those experienced with using pediatric techniques and the smallest possible endotracheal tubes.

Another advantage of the CO_2 laser is the maintenance of vocal quality. In an earlier review of 67 papilloma patients treated with cup forceps at our own institution[17] 50% of patients had persistent hoarseness secondary to "thickened vocal cords, fibrotic changes, and recurrent papilloma." Although exact qualitative data are lacking, we have the strong clinical impression that vocal quality is better preserved with CO_2 laser therapy than with cup forceps removal.

The ultimate goal of papilloma therapy is a lasting cure. Unfortunately, this has been elusive, and papillomas may recur even after long periods of absence. The terms used in the literature to describe favorable results and duration of follow-up are highly variable. For future use we propose a nomenclature to classify the long-term follow-up of papilloma patients: 1) remission — no papillomas visible at the most recent examination; 2) clearance — no papillomas for three years; and 3) cure — no papillomas for five years. In this respect ours has been a preliminary study and we are in the process of collecting statistically significant data from 3- and 5-year follow-ups. Favorable immediate term results have been seen in those patients who have undergone first cup forceps removal and then laser excisions. These patients, who served as their own longitudinal controls, achieved a 52% remission rate on CO_2 laser therapy after repeated cup forceps removals had failed to control their disease. A few of these patients have now even gone four and five years without recurrence. Our hope is that meticulously done CO_2 laser excision, followed by podophyllum painting will achieve better long-term papilloma control than that obtainable with mechanical removal.

In summary, we have found that the treatment of LP with CO_2 laser followed by podophyllum painting represents a clear advance over traditional mechanical methods of papilloma removal when voice quality, remission rate, and especially incidence of complications, and occurrences of death are considered.

REFERENCES

1. Webb WW. Papillomata of the larynx. Laryngoscope 1956; 66:871-918.

2. MacKensie M. Essays on growth in the larynx with reports and an analysis of one hundred consecutive cases treated by the author. Philadelphia: Lindsay and Blakiston, 1871.

3. Batsakis JG. Tumors of the head and neck. Baltimore: Williams and Wilkins, 1979, 137-9.

4. Quick C, Faras A, Krzysek R. The etiology of laryngeal papillomatosis. Laryngoscope 1978; 88:1789-95.

5. Lack E, Jenson AB, Smith H, et al. Immunoperoxidase location of human papilloma virus in laryngeal papillomas. Intervirology 1980; 14:148-54.

6. Lancaster W, Jenson AB. Evidence for papillomavirus genus — specific antigens and DNA in laryngeal papillomas. Intervirology 1981; 15:204-12.

7. Uhllman EVL. On the etiology of laryngeal papillomatosis. Acta Otolaryngol (Stockh) 1923; 5:317.

8. Strong MS, Vaughn CW, Healy GB, Cooperband SR, Clemente MACP. Recurrent respiratory papillomatosis — management with the CO_2 laser. Ann Otol Rhinol Laryngol 1976; 85:508-16.

9. Haglund S, Lundquist P, Cantell K, et al. Interferon therapy in juvenile laryngeal papillomatosis. Arch Otolaryngol 1981; 107:327-32.

10. Rosenbaum HD, Alavi S, Bryant L. Pulmonary parenchymal spread of juvenile laryngeal papillomatosis. Radiology 1968; 90:654-60.

11. Dedo HH. Endoscopic Teflon keel for anterior glottic web. Ann Otol Rhinol Laryngol 1979; 88:467-73.

12. Hollingsworth J, Kohlmoos H, McNaught RL. Treatment of juvenile papilloma of the larynx with resin of podophyllum. Arch Otolaryngol 1950; 52:82-7.

13. Holinger P, Johnston K, Anison G. Papilloma of the larynx. A review of 109 cases with preliminary report of aureomycin therapy. Ann Otol Rhinol Laryngol 1950; 59:547-63.

14. Bjork H, Weber C, Papilloma of the larynx. Acta Otolaryngol (Stockh) 1956; 34:499-513.

15. del Villar R, Echeverria E, deAcosta V, et al. Laryngeal papillomatosis. Arch Otolaryngol 1956; 64:480-5.

16. Majoros M, Parkhill E. Devine K. Papilloma of the larynx in children. Am J Surg 1964; 108:470-5.

17. Dekelbaum A. Papillomas of the larynx. Arch Otolaryngol 1965; 81:390-7.

18. Klos J. Clinical course of laryngeal papillomatosis in children. Ann Otol Rhinol Laryngol 1970; 79:1132-8.

19. Cohen S, Seltzer S, Geller K, et al. Papilloma of the larynx and tracheobronchial tree in children. Ann Otol Rhinol Laryngol 1980; 89:497-503.

LEUKOCYTE INTERFERON IN PATIENTS WITH JUVENILE LARYNGEAL PAPILLOMATOSIS

HELMUTH GOEPFERT, MD
JORDAN U. GUTTERMAN, MD
WILLIAM J. DICHTEL, MD
ROY B. SESSIONS, MD
AYTEN CANGIR, MD
MARCELLE SULEK, MD

HOUSTON, TEXAS

Fourteen patients with aggressive juvenile laryngeal papillomatosis were treated with systemic administration of alpha-type interferon (IFN). The initial dosage of 2 million units alpha-interferon/m^2 was modified if a favorable response in the papilloma growth occurred, or if persistent drug-related side effects developed. Half of the patients showed a sustained response while on IFN, and two patients had a complete response. Persistent elevation in SGOT was the main dose-limiting toxicity, especially in infants below age seven years. All side effects subsided after the drug was discontinued. Further studies are recommended.

INTRODUCTION

Juvenile laryngeal papillomatosis (JLP) is the most common benign proliferative condition seen in the larynx of children,[1] has a relentless propensity for recurrence and a befuddling lack of behavioral predictability. The papillomas are consistently localized in the larynx and have an overall low incidence of growth in the tracheobronchial tree below the site of origin. Although the mortality from the disease is generally thought to be low, it has been reportedly high in several series.[2] Local aggressiveness can be a dominant feature and, in rare instances the disease has been associated with carcinoma of the larynx and cancer of the lung.[3,4]

The mainstay of treatment remains surgical ablation of all visible papillomas; however, recurrence in the majority of patients requires repeat surgery under general anesthesia. Cryosurgery, diathermy, electrofulguration, ultrasound, radiotherapy, topical application of podophyllin, steroid hormones, tetracycline, cytotoxic drugs, antimetabolites, and biologic response modifiers have also been utilized as treatment.[5-17] CO_2 laser vaporization has been the most popular method used in recent years.[18] The general philosophy of management is to control the growth of the papillomas with minimum danger to normal tissues in the hope that the aggressiveness of the tumor will diminish in time.

It seems that younger children are afflicted with more aggressive forms of the disease than are adolescents, and that in the adult, laryngeal papillomatosis tends to be even less active.[19] Contradictions in the disease's natural history and clinical behavior are plentiful. Puberty has been associated with spontaneous involution of disease and diminution of growth of papillomas in some patients; however, this finding has been inconsistent. It is uncertain at this time if pregnancy is associated with any significant change in growth pattern.[22] A spontaneous cessation of growth and even complete remission after periods of very active proliferation have been recognized. These variables make the evaluation of any therapeutic modality difficult.

Evidence of viral cause for JLP has not been conclusive. Indirect evidence of viral etiology is supported by the presence of tumorigenic intranuclear DNA virus belonging to the papovavirus group and by many past observations.[20,21] As early as 1890, Thost[22] described the concomitant occurrence of cutaneous and laryngeal papillomas in the same patient. Ullman[23] and Ishikawa[24] independently performed self-inoculation experiments with laryngeal papillomatosis. Meesen and Schutz,[25] Pinsker and Proud[26] and Timmel[27] made the initial cellular morphologic observations that suggested a viral etiology.

Papilloma viruses are a subgroup of the papova viridae family. These viruses are not only host- but tissue-specific and induce epithelial and fibroepithelial tumors in skin and mucosal epithelia.[28,29] Five different viruses have been identified in cutaneous papillomas in humans. It has been assumed that the human papilloma virus may not only be responsible for cutaneous lesions but may also be associated with mucosal papillomas such as laryngeal and anal genital warts. However, in vitro isolation has not yet been reproducibly accomplished. The data of Quick et al[29] suggests that the viruses that produce papillomas and cutaneous verrucae are of a similar family subgroup. Most cases of JLP would

---

From the University of Texas, M.D. Anderson Hospital and Tumor Institute at Houston, and the Departments of Otolaryngology and Communicative Sciences, Baylor College of Medicine, Houston. Supported by Grant CA 05831, National Cancer Institute, and Hoffman-La Roche, Inc. Research conducted in part by the Interferon Foundation and the Clayton Foundation for Research.

Presented at the meeting of the American Laryngological Association, Palm Beach, Florida, May 1-2, 1982.

REPRINTS — Helmuth Goepfert, MD, Department of Head and Neck Surgery, University of Texas, M.D. Anderson Hospital, 6723 Bertner, Houston, TX 77030.

be caused by one or more of the different serotypes of human papilloma viruses.

Because JLP seems to be a virally related disorder, there has been hope that interferon (IFN) may be helpful in its treatment. Interferon is a naturally occurring substance with clearly demonstrated antiviral and antiproliferative effects.[31-35] It has been used against myxovirus and herpes simplex virus infections by topical application to the respiratory mucosa and corneal epithelium, respectively. Haglund et al[36] recently reported the results using human leukocyte IFN (alpha-IFN) to treat seven patients with JLP. All seven patients showed some regression of papilloma growth. We report here the preliminary results of a study using alpha-IFN in patients with JLP.

INTERFERON — BACKGROUND

Interferons are potent antiviral, antiproliferative, and immunomodulating proteins. Since their discovery in 1957, a substantial body of knowledge on their biology and biochemistry has been promulgated.[37-44]

The IFN system itself is a complex defense mechanism involving the release of substances from cells infected with viruses. IFN is able to confer antiviral resistance on virus-susceptible cells. By itself, IFN has no direct antiviral action; however, it does induce synthesis of intracellular enzymes that act to control viral growth.[32]

Many cells are capable of producing IFN. In vivo, cells of the reticuloendothelial system are good producers; thus the lymphocyte, and probably the macrophage, are important sources of the substance. Fibroblasts are very productive of IFN. Transformed human lymphoid cells, such as those isolated from a Burkitt's lymphoma patient, can produce high levels of leukocyte IFN.[2,39,40]

The two major types of IFN are type I, which is induced by viruses, and type II, which is induced by antigens or mitogens. Type I IFNs include leukocyte (alpha) and fibroblast (beta); type II, or immune IFN, is called gamma. At present, alpha-IFN has been the main source for clinical trials, and most of the current knowledge of the pharmacokinetics, toxicity, and clinical efficacy is based on its study.

The IFNs are polypeptides and those that are produced in response to an antigenic challenge, ie, gamma-IFN, probably come from the T lymphocytes. Because IFN is a protein, it was originally anticipated that standard biochemical procedures would induce a pure, homogeneous material. This has not, in fact, been the case, and purification of the end-product has posed a major problem. Recently, however, progress has been made in this area, and homogeneous leukocyte IFN produced bacterially by recombinant DNA technology has been reported.[41]

IFN has an antiproliferative property that inhibits the division of tumor cells grown in culture, and the cell-multiplication-inhibition effects seem to influence inhibition of lymphocyte transformation as well as antibody synthesis.[42] In contrast, IFN enhances phagocytosis by increasing macrophage activation, increases sensitized cytotoxic lymphocyte activity, and activates the natural killer (NK) cell. Although little evidence exists regarding the in vivo role of NK cells in the antiviral activities of IFN, it is thought to be involved. It has been demonstrated that IFN has the capacity to induce certain tumor regressions;[42-44] however, the precise mechanism is unclear. A variety of immunopotentiating agents have been administered to cancer patients for the last decade, but tumor regression has rarely been observed. Thus, it is unlikely that the immune-enhancing properties of IFN are solely responsible for tumor regression. It may be that the direct effect of IFNs on the growth of tumor cells is important.[33]

METHODS

A randomized prospective study was conducted between March 1981 and February 1982 on 14 patients with aggressive laryngeal and/or laryngotracheobronchial (LTB) papillomatosis. Characteristics of the patient population are summarized in the table. Three patients had papillomatas in all three areas: larynx, trachea, and bronchi (patients 7,12,13). The adult patients had required two or more therapeutic endoscopies within the preceding year, and all children had four or more such procedures during that time. All patients required numerous endoscopies previously, with two patients requiring more than 60 procedures and one with over 300 endoscopies in his lifetime. Eight patients had previously required or were currently dependent on tracheostomy. Six patients had histories of at least one major crisis during their illnesses, such as acute airway obstruction or cardiopulmonary arrest. Eleven patients were male and 3 were female; there were 5 adults, 2 adolescents, and 7 were less than 10 years old. Ages ranged from 2 to 35 years. All patients were white.

Alpha-IFN was obtained from the Finnish Red Cross and Blood Transfusion Laboratories, Helsinki, Finland. Before the patients were admitted in the study, detailed histories were taken and physical examinations were performed. Complete blood counts, platelet count, liver function studies, serum urea nitrogen, creatinine determinations, and chest roentgenograms were obtained. Direct laryngoscopy and appropriate laser vaporization were performed on all patients prior to initiation of IFN treatment. Parents and patients received extensive counseling, and informed consent was obtained prior to each patient's enrollment in the study. Once treatment was initiated, patients underwent monthly laryngoscopies during the first three months, followed by laryngoscopies at 2 to 3-month intervals as dictated by clinical progress. Eleven of the 14 patients underwent laryngoscopies by the same surgeon (RBS). Papillomas were removed by endoscopic instrumentation as needed in the trachea and bronchi and by carbon dioxide laser vaporization in the larynx. The extent and distribution of papillomas were recorded diagrammatically in each case.

During each patient's treatment, complete blood differential and platelet counts were obtained weekly during the first month of treatment, twice a month during the second, and monthly during the remainder of the period of IFN administration. Liver and renal function studies were performed monthly for the first three months of treatment and subsequently on a bimonthly basis.

The initial dose of IFN was 2 million units/m^2 daily, intramuscularly. The frequency of administration was changed to three times weekly whenever the papilloma growth rate decreased or

SUMMARY OF CHARACTERISTICS OF PATIENT POPULATION

				Papilloma Natural History					IFN Treatment		
Patient	Sex	Age (yr)	Onset Age (yr)	Location	Crisis*	Endos	Months	Toxicity	Initial Response	Sustained Response	Dose Dependency
1	M	3	1.5	Larynx	Yes	Many	7	Slight-liver	Slight	Yes	—
2	M	35	32	Larynx	No	Many	11	Slight-liver, WBC	Complete	Yes	Yes
3	M	3	1.5	Larynx/trachea (tracheostomy)	No	Many	11	Slight-liver, WBC	Complete	Yes	No
4	M	9	6	Larynx	No	Many	6	Marked-liver, WBC	None	—	—
5	M	30	25	Larynx (tracheostomy)	Yes	Many	10	None	Complete	No-grew at 7 mo	Yes
6	F	5	3	Larynx	No	Many	7	Marked-liver	Complete	LTF at 8 mo	No
7	F	2	1	Larynx, TBP (tracheostomy)	Yes	Many	12†	None	Moderate	No-grew at 6 mo	Yes
8	M	26	2	Larynx (tracheostomy)	No	60+	11	None	Complete	No-grew at 4 mo	No
9	M	27	2	Larynx (tracheostomy)	No	300+	9	None	Good	Yes	Yes
10	M	12	5	Larynx	Yes	60+	12	Moderate-liver, WBC	Good	No	Yes
11	F	8	5	Larynx (tracheostomy)	Yes	Many	11	Moderate-liver, WBC	Good	No-grew at 4 mo	Yes
12	M	14	4	Larynx, TBP (tracheostomy)	No	Many	7	Slight-WBC	Slight	Yes	No
13	M	4	2	Larynx, TBP (tracheostomy)	Yes	Many	12	None	Moderate	Yes	Yes
14	F	8	—	Larynx	No	Many	4	Marked-liver	Slight	No	—

TBP - Tracheobronchial pulmonary involvement; LTF - Lost to follow-up.

*History of either respiratory obstruction necessitating tracheostomy or cardiorespiratory arrest.

†Continuing.

remained stable over two successive endoscopies. Furthermore, changes in frequency and/or reduction in the individual dose (to 1 million units/m²) was called for whenever the WBC count dropped below 2500/cu mm, or the level of SGOT rose above 100 units/ml. If toxicity persisted despite dosage changes, IFN was temporarily discontinued until blood test values returned to normal. Patients or family members were instructed in the technique of injection for at-home IFN administration. Withdrawal of the patients from IFN therapy was considered on an individual basis.

Response to treatment was graded by the evaluation of diagrammatic representation seen at the time of each endoscopy. A response was considered complete when no evidence of papilloma was present in the laryngotracheobronchial area; good response, an estimated 75% reduction of the overall papilloma volume relative to the disease at the time of entrance into the study; moderate response, 50 to 75% estimated reduction; and slight response, 25 to 50% reduction. If no discernible reduction in growth occurred or if growth increased, it was considered a negative response. Reductions in size were assumed to represent a response to IFN.

RESULTS

Twelve of the 14 patients completed a minimum of seven months of alpha-IFN therapy. Patient 4 was removed from the study because of continued toxicity (primarily SGOT elevation) despite dose modifications. Patient 14 was removed from the study at parental request after the first signs of significant liver toxicity. These two patients had shown no response or slight response while receiving the drug.

The responses were distributed as follows among the 12 evaluable patients: 5, complete response (2 of 5 having sustained responses); 3, good response (1 of 3 sustained); 2, moderate response (1 of 2 sustained); and 2, slight response (2 of 2 sustained).

Of the 5 complete responders, there were 3 adults and 2 children, ages 3 and 5 years. All the adults showed complete or good response. The two patients in whom slight responses were seen were 3 and 14 years of age. Six of the 12 patients who responded sustained the initial response throughout the entire period of IFN administration. One patient who showed a complete response was lost to follow-up after one month of observation (patient 6), and the remaining six patients had breakthrough of disease suppression and failed to sustain the initial tumor response. There was no apparent correlation between the degree of initial response and the predictability of sustaining such.

The response-dose relationship of individual responders cannot be judged on any patient with less than a moderate response. Of the ten complete, good, or moderate responses only four patients showed substantial changes in tumor response with alterations of the IFN dosage. Although there was a striking fluctuation of growth rate relative to dosage in very sensitive patients (2,5 and 9), it would

appear that the sensitivity of response to this IFN is essentially an "all or none" phenomenon.

IFN has been discontinued in all but one patient (7). Nine patients were evaluated for periods longer than 7 months — three, 12 months; four, 11 months; one, 12 months; and one, 9 months. Eight patients have had at least one month's examination following cessation of IFN treatment. Two of these patients (1 and 12) had slight increase in growth relative to the volume of tumor noted at the time of IFN withdrawal. Two of these four patients (9 and 11) had marked and moderate increases in growth, respectively. Patient 13 showed a transient diminution of disease for approximately one month after cessation of treatment followed by renewed growth of papillomas. Patients 2,3, 5, and 6 have been followed for 1 to 3 months without any signs of increased growth. Patients 2 and 3 with complete responses remain free of disease until the present.

Toxicity was evaluated in 14 patients. Of the 9 patients who demonstrated signs of toxicity, 3 were in the group of complete responses, 2 had good responses, 3 had slight responses and 1 had no response. Neither of the two with moderate responses demonstrated any toxicity.

Temperature elevation was common during the first few injections of IFN but did not appear after the patients had received multiple doses. Malaise, fatigue, and a slight anorexia were not ignored but were usually thought to be of minor significance. As a matter of fact, the infants who showed marked regression of tumor usually became more active and had increased appetites. Toxicity was measured by WBC drop, and elevation in the SGOT level. The degrees of toxicity were classified as slight (1+) when the SGOT remained under 100 and returned to normal with the adjustment of the IFN dosage. It was considered moderate (2+) when the SGOT level was above 100 but returned to normal with proper dosage adjustment. Toxicity (3+) was considered marked when the SGOT level was progressive and forced discontinuation of the protocol. Two of the nine patients with toxicity were taken off the study because of persistent side effects. Depression of the WBC or elevation of the liver enzyme has been totally reversed by alteration of IFN level or cessation of the drug altogether.

No correlation between the response of papillomas and the susceptibility of the patient to IFN toxicity was seen. It is noticeable, though, that of the 8 patients who were under ten years of age, 6 demonstrated SGOT elevations and 4 of these 8 patients had myelosuppression as well. Only one of the five adult patients showed mild liver enzyme elevation and a slight bone marrow suppression. From these numbers, it appears that age of the patients is an important factor in tolerance to IFN.

DISCUSSION

Not only are there variations in the natural history of JLP from patient to patient, but in time different patterns of aggressiveness may be seen in the same patient. Several internal and external influences on the host, some of which escape our present knowledge, induce variations in the behavior of this benign tumor and add to the difficulty of evaluation of its treatment. More aggressive forms of the disease in the larynx, which is the site of most frequent involvement, or over the mucosa of the trachea and bronchi, have necessitated a variety of treatments other than surgical ablation of tumor. Chemotherapy, given systemically or applied topically, has enjoyed transient popularity, but, by and large, it has not given consistent results.[1-18,23]

The IFN system is described as a complex mechanism of cellular defense triggered or induced usually by the influence of viral antigen. The different types of IFN have species-specific antiviral, antiproliferative and antitumor effects.[32]

The majority of clinical studies have been carried out with leukocyte or alpha-IFN. This study was conducted using the product, originally developed by Cantell,[39] of the Finnish Red Cross Blood Transfusion Center and the Central Public Health Laboratory in Helsinki. The preparation obtained is approximately of 1% purity. Lymphoblastoid IFN and IFN obtained through the recombinant DNA technology are of 80-95% purity, respectively. Furthermore, it has been shown that the alpha-IFN obtained by the Cantell method is probably a mixture of several sub-types of IFN, each one with a specific activity.

This present study to a large extent duplicates what was reported by Haglund et al.[36] Although we administered a substantially higher dose of IFN on a daily basis to our patient population, neither the magnitude nor the rate of response could be judged to be very different, if we consider that the two patient populations are compatible. Most patients continued to receive IFN for over nine months without a substantial increase in the response rate. By and large, the beneficial effects of the drug were noticed within 6 to 12 weeks of therapy, and the dose-response relationship was only present in 4 of 10 patients. We did not find that severity of disease or amount of papillomas had any influence on the response rate of this drug. By study design, it was required that all patients have aggressive papillomatosis, and this may have had some influence on the relatively low response rate.

The most accurate possible documentation of any objective changes within the larynx and the tracheobronchial tree are mandatory. Photographic records of the laryngoscopic findings will only reflect the superficial and more proximal appearance of the papillomatosis and certainly fall short of any

tumor volume determination. Graphic-pictorial documentation used in this study depends on the accuracy of the observer and is fraught with some margin of discrepancy. We believe that having one endoscopist (RBS) follow up the majority of the patients provided the most accurate, objective evaluation. Despite the method of recording disease some subtleties of change are difficult to describe. One finding that is difficult to document is the appearance of the epithelium of the papillomas during IFN treatment. Some studies have verified histologic changes of degeneration in the papilloma under the influence of treatment.[32,34] On repeated occasions, the observers noticed that under the influence of IFN, the florid, cauliflower-like raised, pinkish papillomas gradually changed to a flat, cobblestone-like pale mucosa, and that these changes reverted to the previous form when the disease process became more active. These visual findings require histologic and ultrastructural verification. Papilloma specimens were taken from all patients during their treatment, and these histologic and ultrastructural changes are under study and will be reported in the future.

Interferon acts as a biologic modifier; therefore, it is possible that when substantial numbers of papillomas are present, the benefits from treatment will be limited. For this reason, we believe that future studies should be designed in such a way that patients would, by conventional means, be rendered free of as much obvious papilloma as possible, prior to beginning IFN treatment. If we assume that papillomas are virally-induced, the best time to administer IFN is before the target cell is stricken by the virus. Furthermore, the antiproliferative and antitumor effects of IFN are most likely to be effective on a relatively small volume of papillomas.

An interesting observation was the increased papilloma proliferation and growth when IFN had to be reduced in dose or frequency of administration. This supports previous studies and places emphasis on the need to determine the optimal dose-time schedule to achieve the best results. A reverse rebound or delayed response effect was observed in patient 13 three weeks after the drug was discontinued when the endoscopist noted a striking improvement. Unfortunately, this was a short-lasting response. The exact mechanism of this rebound response is unknown, but similar effects have been noticed occasionally in patients with solid tumors treated with interferon.[42]

All patients experienced drug-related symptoms during treatment. Fever was present only following the first few injections, and malaise, fatigue, and anorexia were not considered significantly important. On the other hand, patients who had complete responses experienced a sensation of well-being and an increase in appetite.

The main dose-limiting side effect in our patient population has been an SGOT elevation. It is striking that this was particularly noticeable in the younger patients but, again, was not a consistent finding. In every instance, the laboratory values returned to normal within a week after IFN was discontinued and, in all, remained within normal range or slightly above normal when IFN was resumed at either lower dosage or a reduced frequency of administration (three times a week). All patients had slight decreases in WBC primarily due to a decrease in neutrophils. The myelosuppression was mild, with leukopenia below 3,000 in only a few instances. Opportunistic infections did not occur. At this time, the exact mechanism of the SGOT elevation is unclear, and it appears that it is not a manifestation of the IFN itself but may be due to the impurities of the preparation. From studies done in patients with solid tumors, this toxic effect is absent when the purified preparations are used.[43] The multiple anesthetics necessary for endoscopic surgery could be partially responsible for this enzyme elevation. None of the side effects nor the signs of toxicity have persisted after withdrawal from the drug.

Subsequent studies with IFN will have to be designed in such a way that maximum experience is gained to determine the exact dosage and route of administration. It is plausible that the drug could be used locally to the affected organ, which would lessen significant systemic side effects.[44] Whether daily treatment is necessary or an intermittent pulse schedule is more appropriate can only be answered by properly designed randomized studies. Pharmacologic data must be obtained and serum levels will, in part, reflect the degree of IFN-binding to the target tissues.

It is possible that the method of production of alpha-IFN influences its activity. The New York Blood Center has been producing IFN by methods similar to that used by Cantell and collaborators in Finland. Because of some methodologic differences in extraction, the final product may contain a different mixture of active substances. We are presently using this compound in all patients in whom disease continues to be active and who have failed to respond to previous treatment protocols.

The use of a biologic product in young organisms with a potential of a delayed sequela must be evaluated with care. In newborn animals, IFN may be toxic, not only to the hepatic, but also to the renal parenchyma.[38] Thus far, it has been confirmed in human studies.

Our data suggests the relatively impure preparations of alpha-IFN can lead to regression of papilloma. Our observations confirm that further studies and controlled trials in patients with laryngeal papillomas of a variety of clinical presentations are necessary.

REFERENCES

1. Quick CA, Foucan E, Dehner L. Frequency and significance of epithelial atypia in laryngeal papillomatosis. Laryngoscope 1979; 89:550-60.

2. Klos J. Clinical course of laryngeal papillomatosis in children. Ann Otol Rhinol Laryngol 1970; 79:1132-8.

3. Olofsson J, Bjelkenkrantz K. Grontoft O. Malignant degeneration of laryngeal papilloma. J Otolaryngol 1980; 9:329-33.

4. Brach B, Blein RC, Matthews AJ, Cook EW. Papillomatosis of the respiratory tract. Arch Otolaryngol 1978; 104:413-6.

5. Holinger PH, Schild JA, Mauriz DG. Laryngeal papilloma: a review of etiology and therapy. Laryngoscope 1968; 78: 1462-74.

6. Singleton GT, Adkins WY. Cryosurgical treatment of juvenile laryngeal papillomatosis. An eight year experience. Ann Otol Rhinol Laryngol 1972; 81:784-90.

7. Frookot NJ, Rogers JH. The treatment of juvenile multiple laryngeal papillomatosis by section and diathermy. J Laryngol Otol 1979; 93:373-81.

8. Birck HG, Mankart HE. Ultrasound for juvenile laryngeal papillomas. Arch Otolaryngol 1963; 77:603-8.

9. Land FT: Papillomata of the larynx. J Laryngol Otol 1950; 64:205-7.

10. Hollingsworth JB, Kohlmoos HW, McNaught RC. Treatment of juvenile papilloma of the larynx with resin of Podophyllum. Arch Otolaryngol 1950; 52:82-7.

11. Szpunner J. Laryngeal papillomatosis. Acta Otolaryngol (Stockh) 1967; 63:74-86.

12. Holinger PH, Johnson KC, Anison GC. Papillomas of the larynx: review of 109 cases with a preliminary report on aureomycin therapy. Ann Otol Rhinol Laryngol 1950; 59:547-64.

13. Sakurai S, Takahasi M, Nakajima Y, Ishizaka T. Juvenile papilloma of the larynx treated by bleomycin. Keio J Med 1975; 24:11-7.

14. Smith HG, Healy GB, Vaughan GW, Strong MS. Topical chemotherapy of recurrent respiratory papillomatosis. Ann Otol Rhinol Laryngol 1980; 89:472-8.

15. Holinger PH, Shipkowitz NL, Worland MC. Studies of etiology of laryngeal papilloma and an autogenous laryngeal papilloma vaccine. Acta Otolaryngol (Stockh) 1968; 65:63-9.

16. Stephens CB, Arnold GE, Butchko GM, Hardy CL. Autogenous vaccine treatment of juvenile laryngeal papillomatosis. Laryngoscope 1979; 89:1689-96.

17. Quick CA, Behrens HW, Bunton-Darnell M, Good RA. Treatment of papillomatosis of the larynx with transfer factor. Ann Otol Rhinol Laryngol 1975; 84:607-13.

18. Strong MS, Vaughan CW, Healy GB, Cooperband SR, Clemente MACP. Recurrent respiratory papillomatosis: management with the CO_2 surgical laser. Ann Otol Rhinol Laryngol 1976; 85:508-16.

19. Rubin JA. Papilloma of the larynx. Can Med Assoc 1954; 71:572-5.

20. Boyle WF, Riggs JL, Oshior LS, Lennette EH. Electromicroscopic identification of papova virus in laryngeal papillomatosis. Laryngoscope 1973; 83:1104-8.

21. Arnold W. Tubular forms of papova viruses in human laryngeal papilloma. Arch Otorhinolaryngol 1979; 225:15-9.

22. Thost A. Die gutartigen Neubildungen des Kehlkopfes. In: Denker A, Kahler O, eds. Handbuch der Hals-Nasen-Ohren-Heilkundemit Einschluss der Grenzgebiete. Band 5. Berlin: J Springer, 1926-29.

23. Ullman EV. On the etiology of the laryngeal papilloma. Acta Otolaryngol (Stockh) 1923; 5:317-34.

24. Ishikawa K. Klinische und Experimentelle untersuchungen über die Entstehungsursachen der Papilloma. Fukuoka Acta Med (abstr) 1936; 29:87-8.

25. Meesen H, Schutz H. Elektronenmikroskopisher Nachweis des Virus in Kehlkopfpapillom des Menschen. Klin Wochenschr 1957; 35:771-3.

26. Pinsker OT, Proud GO. Studies on the etiology of papilloma of the larynx. Arch Otolaryngol 1958; 56:268-70.

27. Timmel H. Zur Submicroskopischen Morphologie rezidivierender Larynxpapillome. Klin Wochenschr 1961; 39:307-8.

28. Faras AJ, Krzyzek RA, Ostrow RS, et al. Genetic variation among papilloma viruses. Ann NY Acad Sci 1980; 354:60-70.

29. Quick CA, Faras A, Krzyzek R. The etiology of laryngeal papillomatosis. Laryngoscope 1978; 88:1789-95.

30. Lack EE, Jenson AB, Smith HG, Healy GB, Pass F. Immunoperoxidase localization of human papilloma virus in laryngeal papilloma. Intervirology 1980; 14:148-54.

31. Krim M. Toward tumor therapy with interferons: part 2. Blood 1980; 55:875-84.

32. Gutterman JU. Clinical investigation of the interferons in human cancer. Cancer Bull 1981; 33:271-8.

33. Grossberg SE. The interferons and their inducers: molecular and therapeutic considerations. Part 3. N Engl J Med 1972; 287(3):122-8.

34. Strander H, Cantell K, Carlstrom G, Jakobsson PA. Clinical and laboratory investigations on man: systemic administration of potent interferon to man. JNCI 1973; 51:733

35. Strander H. Interferons: anti-neoplastic drugs? Blut 1977; 35:288-99.

36. Haglund S, Lundquist P, Cantell K, Strander H. Interferon therapy in juvenile laryngeal papillomatosis. Arch Otolaryngol 1981; 107:327-32.

37. Grossberg SE. The interferons and their inducers: molecular and therapeutic considerations. Part 1. N Engl J Med 1972; 287(1):13-9.

38. Strander H. Anti-tumor effects of interferon and its possible use as an anti-neoplastic agent in man. Tex Rep Biol Med 1977; 35:429-35.

39. Cantell K, Hirvones S, Mogensen KE, Pyhala L. Human leukocyte interferon: production, purification, stability and animal experiments. In Vitro 1974:35-8.

40. Berg K, Heron I. Production, purification and properties of human interferons. In: Stringfellow DA, ed. Interferon and interferon inducers. New York: Marcel Dekker, Inc, 1980.

41. Goeddel DV, Yelverton E, Ullrich A, et al. Human leukocyte interferon produced by E. coli is biologically active. Nature 1980; 287:411-6.

42. Gutterman JU, Blumenschein GR, Alexanian R, et al. Leukocyte interferon induced tumor regression in human metastatic breast cancer, multiple myeloma, and malignant lymphoma. Ann Intern Med 1980; 93:399-406.

43. Gutterman J, Fein S, Quesada J, et al. Recombinant leukocyte A interferon: pharmacokinetics, single dose tolerance and biologic effects in cancer patients. Ann Intern Med (in press).

44. Padovan I, Brodarec I, Ikic D, Kenzevic M, Soos E. Effect of interferon in therapy of skin and head and neck tumors. J Cancer Res Clin Oncol 1981; 100:295-310.

CRICOTHYROIDOTOMY: THE IMPACT OF ANTECEDENT ENDOTRACHEAL INTUBATION

ERNEST A. WEYMULLER, JR, MD CHARLES W. CUMMINGS, MD

SEATTLE, WASHINGTON

In light of the current debate regarding cricothyroidotomy, we elected to study the procedure at our institution. Cricothyroidotomy was instituted whenever tracheotomy was necessary for airway management. After a fairly short period of time, some significant complications of cricothyroidotomy were apparent and the study was aborted prior to achieving statistically significant results. The report reviews 15 consecutive cricothyroidotomies. Five (33%) developed significant complications requiring surgical intervention. Of the five, two had life-threatening airway obstruction. The major underlying factor in patients who developed complications was prolonged intubation prior to the institution of cricothyroidotomy. The study suggests that cricothyroidotomy should not be performed after prolonged intubation. The issue of primary cricothyroidotomy for short-term airway control remains unanswered.

INTRODUCTION

In 1976, Brantigan and Grow rekindled interest in cricothyroidotomy and initiated a debate marked by much emotional rhetoric.[1] Their study of 655 patients stands as the single largest accumulation of data on the subject of airway management. Their contention that cricothyroidotomy is an appropriate substitute for tracheotomy is resisted by traditionalists in otolaryngology who favor tracheotomy largely due to the influence and teachings of Chevalier Jackson.[2-5] Our study was initiated to attempt a further assessment of cricothyroidotomy with the intent of including careful laryngeal follow-up.

MATERIAL AND METHODS

Patients identified for the study were those who would have required tracheotomy for airway management. The patients fell into two major groups: 1) those intubated for prolonged periods and in need of further airway support, and 2) head and neck surgical cases without prior intubation who required cricothyroidotomy for airway management.

Patients requiring the procedure were taken to the operating room and, under sterile conditions, a standard cricothyroidotomy was accomplished and a No. 6 cuffed Shiley tracheotomy tube was inserted. Postoperative care included careful wound management using Betadine dressings and routine suctioning and humidification as normally applied to tracheotomy. None of the patients required mechanical ventilation for more than 24 hours.

The patients were registered in a follow-up system and carefully monitored by the authors. Each patient was followed after removal of the cricothyroidotomy tube (decannulation). When stridor or other airway symptoms developed, the patient was evaluated and treated with appropriate intervention.

Each patient in this series has been examined at least two months subsequent to decannulation or completion of therapy for complications of the cricothyroidotomy.

RESULTS

The study was aborted prior to accumulating a large group because significant complications became apparent in the patients who had prolonged intubation prior to cricothyroidotomy.

The total number of patients was 19; 3 died before removal of the cricothyroidotomy and were thus excluded, another patient disappeared one week after decannulation and is excluded. The study group consists of 15 patients, 10 of whom had prolonged intubation prior to cricothyroidotomy. In the group with prolonged endotracheal intubation, the average endotracheal intubation time was 14 days (range 11-21 days), and the average duration of cricothyroidotomy was 50 days (range 14-120 days). In the patients who had no antecedent endotracheal intubation, the average duration of cricothyroidotomy was 24 days (one patient 90 days, others 5-12 days).

There were no complications in ten patients (67%). Five patients (33%) developed significant complications. Two had progressive airway problems subsequent to the removal of the cricothyroidotomy. Each complication was relatively easy to manage with no permanent stenotic sequelae. All the complications occurred during the first month of decannulation.

Of the five patients with complications, four had prolonged endotracheal intubation, the fifth had a cricothyroidotomy performed for airway control (nonemergent) during management of a submandibular gland abscess.

The four patients with prolonged endotracheal intubation had anterior subglottic granulomata and fibrosis managed with endoscopic removal and steroid injection. The incidence of significant complications in this group was 4/10 (40%).

The fifth complication developed in a patient whose cricothyroidotomy became contaminated

From the University of Washington, School of Medicine, Seattle.

Presented at the meeting of the American Laryngological Association, Palm Beach, Florida, May 1-2, 1982.

after drainage of a submandibular abscess. The same bacterial organisms grew from the wound and the sputum on the seventh postoperative day and the same organisms were identified in subglottic granulation tissue one month later when stenosis was noted. The patient developed circumferential subglottic and tracheal edema. Successful therapy required four weeks of intravenous antibiotics. There was no vocal cord fixation and no irreversible stenosis as a complication of cricothyoidotomy in this series.

DISCUSSION

The detractors of elective cricothyroidotomy wax effusive but stumble over a lack of objective data. Two cases presented by Kennedy as complications of cricothyroidotomy have some limitations which must be mentioned.[3] The first patient had penetrating trauma of the neck and chest. The cricothyroidotomy is not clearly the source of the laryngeal pathology (fixed left vocal cord and anterior glottic and subglottic stenosis). The second patient had an endotracheal tube in place for four days after which she extubated herself with resultant airway obstruction requiring a cricothyroidotomy. It is clear in this instance that laryngeal pathology existed prior to the establishment of cricothyroidotomy. Mitchell cautions his readers against cricothyroidotomy without any case reports.[2] Carden responds emotionally to the subject without any objective substantiation.[5] Montagano and Passy mention seven cases of subglottic stenosis in a brief letter to the editor but fail to describe the cases and, therefore, leave much open to question.[4]

The champions of cricothyroidotomy on the other hand provide us with much clinical information (cumulatively numbering close to 1,000 patients).[1,6-9] Although their studies can be criticized for lack of patient follow-up, it is clear that the incidence of immediate and long-term complications of cricothyroidotomy in these authors' hands is notably low.

Experimental data from Nelson would suggest that cricothyroidotomy is unsafe.[10] He performed standard cricothyroidotomy on 3 dogs and noted moderate stenosis in 2, minimal stenosis in 1. This was a higher incidence of stenosis than in tracheotomized dogs. More recent studies using a total of 72 dogs have shown that cricothyroidotomy is safe in the experimental setting — even when some of the dogs had removal of cricoid mucosa at the time of cricothyroidotomy.[11,12]

It is important to note that even among the supporters of cricothyroidotomy, there are limitations to the procedure. Most importantly because of occasional complications, the authors are recommending that cricothyroidotomy is contraindicated subsequent to prolonged intubation.[8,13]

Although our series is limited in number, it seems appropriate to conclude that prolonged intubation is a contraindication to cricothyroidotomy. The presence of an endotracheal tube must be considered a source of acute laryngeal inflammation and mucosal ulceration and, therefore, a predisposing factor to complications from cricothyroidotomy.

It is interesting to note that even with a cricothyroidotomy in place for as long as 120 days, the subsequent granulation tissue and fibrosis were relatively easily managed with microscopic removal and instillation of steroids.

Two of the patients who developed complications did not give evidence of an airway problem until sometime after the removal of the cricothyroidotomy. All patients gave clear evidence of their complication within the first month after decannulation and two of them had acute evolution of obstruction, requiring urgent tracheotomy for airway control.

One patient from the series with complications was not examined by the authors after removal of her cricothyroidotomy. This patient had an urgent tracheotomy performed in another city after transfer from our hospital. The otolaryngologist who managed her subglottic stenosis reported that it responded readily to endoscopic dilitation and instillation of steroids. He has examined the patient and confirmed the return to a normal laryngeal status.

One patient had a cricothyroidotomy performed in the face of a rather severe upper airway infection, albeit nonlaryngeal. It would appear that this cricothyroidotomy was contaminated by the draining abscess and this would suggest the relative contraindication of cricothyroidotomy in the face of proximate soft tissue infection.

CONCLUSION

1. This series demonstrates the high probability of complication (40%) from cricothyroidotomy in the face of previous endotracheal intubation. It is the conclusion of the authors that prolonged intubation is a contraindication to routine cricothyroidotomy.

2. The few patients who had cricothyroidotomy without prolonged intubation had a totally benign course, but are too few in number to justify any conclusion.

3. The data in support of cricothyroidotomy as an elective procedure without antecedent intubation seem quite reasonable and the authors support the ongoing clinical research efforts to clarify the exact complication rate of primary cricothyroidotomy.

REFERENCES

1. Brantigan CO, Grow JB. Cricothyroidotomy: elective use in respiratory problems requiring tracheotomy. J Thorac Cardiovasc Surg 1976; 71:72-81.

2. Mitchell SA. Cricothyroidotomy revisited. Ear Nose Throat J 1979; 58:54-60.

3. Kennedy TL. Epiglottic reconstruction of laryngeal stenosis to cricothyroidotomy. Laryngoscope 1981; 90:1130-6.

4. Montagano J, Passy V. Letter to the editor. Plast Reconstr Surg 1981; 67:98.

5. Carden ET. Letter to the editor. Plast Reconstr Surg 1981; 67:99.

6. Boyd AD, Conlan AA. Emergency cricothyroidotomy: is its use justified? Surg Rds 1979; 2:19-23.

7. Brantigan CO, Grow JB. Cricothyroidotomy revisited again. Ear Nose Throat J 1980; 59:26-38.

8. Morain WD. Cricothyroidotomy in head and neck surgery. Plast Reconstr Surg 1980; 65:424.

9. Habel DW. Cricothyroidotomy as a site for elective tracheotomy. Trans Pac Coast Otophthalmol Soc 1977; 58:181.

10. Nelson TG. Tracheotomy: a clinical and experimental study. Am Surg 1957; 23:660-94, 750-83, 841-81.

11. Koopman CF, Feld RA, Coulthard SW. The effects of cricoid cartilage injury and antibiotics in cricothyroidotomy. Am J Otolaryngol 1981; 2:123-238.

12. Romita MC, Colvin SB, Boyd AD. Cricothyroidotomy — its healing and complications. Surg Forum 1977; 28:174-5.

13. Romita MC. Letter to the editor. Plast Reconstr Surg 1981; 67:98.

NERVE-MUSCLE PEDICLE REINNERVATION OF THE LARYNX: AVOIDING PITFALLS AND COMPLICATIONS

HARVEY M. TUCKER, MD

CLEVELAND, OHIO

The procedure for reinnervation of bilateral vocal cord paralysis using nerve-muscle pedicle technique has now been well established in the literature. Moreover, several other centers have reported success using this technique. Nevertheless, the author is aware that a significant number of well trained otolaryngology-head and neck surgery practitioners have found difficulty in making the procedure successful in their hands. It therefore seems appropriate to address those aspects of patient evaluation, technique and postoperative follow-up that have brought a satisfactory level of success in the author's hands. Preoperative evaluation of patients is the cornerstone of success in nerve-muscle pedicle reinnervation. It is imperative that the larynx be properly evaluated to be certain that there does not exist fixation or ankylosis of one or both arytenoids in addition to paralysis. Clearly if such fixation exists, nerve-muscle pedicle reinnervation cannot be successful. Several pertinent aspects of technique with special reference to the identification of the proper nerve-muscle pedicle, the design of the pedicle and proper identification of the posterior cricoarytenoid muscle will be discussed. Postoperative evaluation of patients may be difficult for inexperienced operators. The author has seen at least three patients who were operated on by other surgeons who were referred because of "failure" of the procedure only to find that all three of them were successfully reinnervated with satisfactory motion of the reinnervated cord for reasonable day-to-day activity. All aspects of postoperative evaluation and management will be discussed as well.

The procedure for reinnervation of bilateral vocal cord paralysis using nerve-muscle pedicle technique has now been well established in the literature.[1-3] Success with this technique has been reported from several centers.[4-6] Nevertheless, capable surgeons have informed the author of difficulty in achieving satisfactory results. This report is intended to address those aspects of patient evaluation, surgical technique and postoperative follow-up that have brought us success with the procedure and which may help to avoid complications or failure if adhered to closely.

PREOPERATIVE EVALUATION AND PATIENT SELECTION

Proper selection of patients and preoperative evaluation are the cornerstones of success in nerve-muscle pedicle reinnervation. In general, the procedure may be considered for any patient with unrecovered bilateral vocal cord paralysis which either has existed for one year from onset or in cases wherein it is known beyond any doubt that there can be no hope of recovery of either of the two recurrent nerves. The majority of patients that meet these criteria have suffered bilateral paralysis as the result of neck surgery, usually for carcinoma of the thyroid or other thyroid lesions.[7]

Analysis of over 200 cases of bilateral vocal cord paralysis that had existed for at least one year[7] shows that fully one third of the patients exhibited fixation or at least severe limitation of motion of one or both of the cricoarytenoid joints in addition to the recurrent nerve paralysis. Since it would be pointless to attempt to reinnervate a bilaterally paralyzed larynx which also exhibits significant fixation, it is imperative that patients be evaluated preoperatively to determine if the arytenoids are passively mobile. This should be accomplished under general anesthesia with paralysis either after performance of a tracheotomy or without intubation and by mask anesthesia only. With a hand-held anterior commissure laryngoscope in place and taking great care to position the laryngoscope so that it does not in any way affect or restrict movement of the vocal cords, a spatula or suction tip is introduced between the vocal cords to palpate them. It is important that the palpating instrument be placed as far posterior in the larynx as possible so that the body of the arytenoid will be displaced rather than the tip of the vocal process or the membranous vocal cord itself (Fig. 1). A normally mobile vocal cord will be easily displaced from its opposite neighbor and will produce a significant increase in the posterior glottic chink. If the arytenoid is ankylosed, it may be possible to displace it from its resting position, but in so doing the opposite arytenoid will be dragged along with it and there will be no significant increase in the posterior glottic chink (Fig. 2). On the other hand, if the palpating instrument is placed too far forward either on the vocal process or on the membranous cord itself, the observer can be easily misled, since the membranous vocal cord and vocal process can often be displaced even when the body of the arytenoid is fixed (Fig. 3). If the palpating instrument is placed too deeply into the larynx, it may impinge upon the cricoid itself and thus give a false impression of fixation of the arytenoid when in fact

From the Department of Otolaryngology and Communicative Disorders, The Cleveland Clinic Foundation.

Presented at the meeting of the American Laryngological Association, Palm Beach, Florida, May 1-2, 1982.

REPRINTS — H. M. Tucker, MD, Chairman, Department of Otolaryngology and Communicative Disorders, The Cleveland Clinic Foundation, 9500 Euclid Avenue, Cleveland, OH 44106.

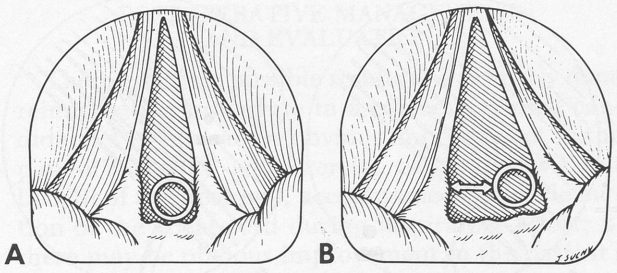

Fig. 1. A) Placement of palpating suction tip in posterior glottic chink. B) Note that lateral pressure is applied to body of arytenoid posterior to tip of vocal process, widening posterior glottic chink in mobile larynx.

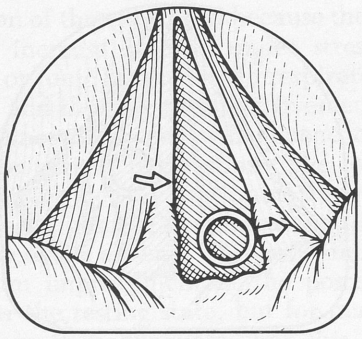

Fig. 2. Fixed arytenoid may still appear to be displaced by suction tip (right arrow). Arytenoid moves laterally, but opposite arytenoid is carried along with it (left arrow).

the joint is normally mobile.

Another factor to be considered in preoperative evaluation is that there must be no uncorrectable restriction of the airway other than the vocal cord paralysis itself. Clearly, if there is subglottic stenosis or other significant narrowing of the airway below the vocal cords, correction of the vocal cord paralysis will still not allow decannulation. As a general rule, such mechanical stenoses should be corrected before any attempt is made at reinnervation.

Another possible pitfall lies in the etiology of the paralysis. Only a 40-50% success rate has been achieved in reinnervating patients whose paralysis is the result of central nervous system problems such as Guillain-Barré syndrome or bulbar poliomyelitis. Any general neurologic disease process that might produce paralysis of the recurrent nerves also may interfere with the activity of the ansa hypoglossi which is necessary to reinnervation. Degeneration of the laryngeal muscles themselves, or direct damage to the nerves from surgery or radiation may interfere with development of the necessary nerve-muscle pedicle and thus prevent successful reinnervation.

SURGICAL TECHNIQUE

The details of surgical technique for nerve-muscle pedicle reinnervation have been described in several previous communications.[1-3] Discussions with several surgeons who have attempted the procedure indicate that the two major areas of potential technical difficulty are related to design of the pedicle and to proper identification of the posterior cricoarytenoid muscle. The pedicle is designed by identifying the branch of the ansa hypoglossi to the anterior belly of the omohyoid muscle. It is not essential that this particular branch be used since any of the strap muscles are suitable, but this nerve is fairly constant, is easily located in the surgical field, and is almost always of sufficient length and size to allow design of a good pedicle. The nerve is traced to the anterior belly of the omohyoid and the pedicle is designed about the actual point of entry of the nerve into the muscle. The nerve will often travel for 2-3 mm between muscle bundles before it actually arborizes into its terminal fibers (Fig. 4). It is essential, therefore, to gently separate these muscle fibers to observe the point of entry so that when the pedicle is designed, most of the terminal fibers and their subtended motor end-plates will be included. On the other hand, the pedicle should not be larger than 2 or 3 mm on a side. This small pedicle is quite adequate to include at least 80% of the subtended motor end-plates, provided it is placed at the very end of the nerve. More important, it avoids the possibility of excessive fibrosis that might occur if a larger pedicle were employed. Although it is true that free grafts of muscle measuring as much as 2 cm on a side can be readily transplanted and will survive, there will be significant loss of bulk and fibrous tissue replacement at the periphery of the graft if such a large piece of muscle is transposed. Since one of the mechanisms whereby nerve-muscle pedicle reinnervation occurs involves neurotization of the recipient muscle by invading nerve buds from the pedicle muscle, it is obviously important that fibrosis between the muscles should be minimized. Since the vasa nervora which are preserved in designing the pedicle will support the nerve but not the muscle, it is clear that the smaller the block of muscle used that will be adequate for preservation of a sufficient number of motor end-plates, the better. Excessively precise dissection of the soft tissue surrounding the nerve itself should be avoided. Since the vasa nervora are essential to the survival of the nerve, it is just as well to leave a fair amount of fat or areolar tissue intact on the surface of the nerve during its dissection to prevent unnecessary injury to these tiny vessels.

The other major potential area for error in the performance of nerve-muscle pedicle reinnervation is related to identification of the posterior cricoarytenoid muscle. After the pedicle has been prepared and laid aside, the lateral border of the thyroid cartilage is palpated and the retropharyngeal space is entered and is opened widely from the tip of the greater cornu of the thyroid cartilage to a point below the cricoid cartilage. If possible, the palpating finger should traverse this space and feel the posterior edge of the thyroid ala on the opposite side. This is relatively easy to do in children, young

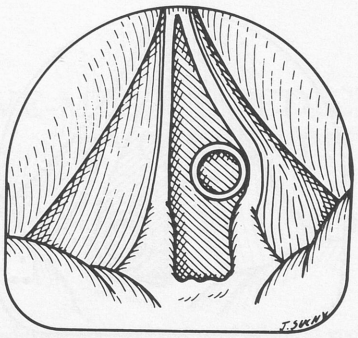

Fig. 3. Apparent displacement of arytenoid. Suction tip has been placed anterior to vocal process and therefore only membranous cord is being displaced.

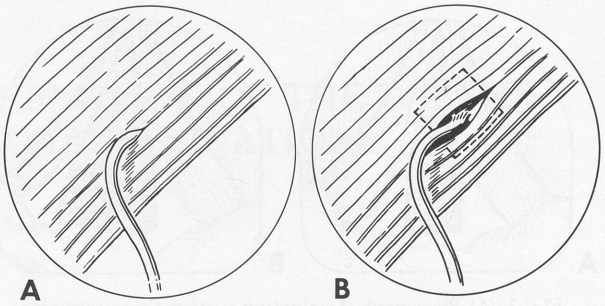

Fig. 4. Design of nerve-muscle pedicle. A) Apparent point of entry; B) actual point of entry. It is important to note point of aborization and entry of nerve into muscle by separating adjacent muscle bundles. (Reprinted with permission.[1])

people and patients who are fairly thin. The larynx can then be rotated almost 180°, which presents the posterolateral aspect of the cricoid and thyroid cartilages to the operator and fixes the larynx in position. The inferior cornu of the thyroid cartilage is then palpated and the approach through the inferior constrictor muscle is begun at a point 2 or 3 mm above the inferior cornu. Dissection is kept as close to the posterior edge of the thyroid cartilage as the anatomy will permit. The fascia is gently dissected free and the direction of the fibers of the inferior constrictor is noted. They travel from posterosuperior to anteroinferior. The fibers are separated along their long axes at the chosen point and widely retracted. In many patients, the inferior constrictor muscle is divided into two leaflets, an external one which inserts along the posterior edge and outer border of the thyroid cartilage and an internal one which inserts along the inner surface of the thyroid ala (Fig. 5). There will often be a plane of loose areolar tissue between these two leaflets. Therefore, having passed through what appears to be the entire inferior constrictor muscle and encountering such a fascial plane, it is easy to be misled into thinking that the next layer of muscle is the posterior cricoarytenoid muscle when it is actually the internal leaflet of the inferior constrictor muscle. It is important to note that the direction of the fibers of the posterior cricoarytenoid muscle is at right angles to those of the inferior constrictor. In most cases, having traversed both leaflets of the inferior constrictor, the reflection of the pyriform sinus mucosa will be encountered and this structure must be bluntly displaced from inferior to superior. In the majority of patients, an easily identifiable muscle structure will be encountered next, the fibers of which pass from posteroinferior to anterosuperior or at right angles to those of the inferior constrictor. This is the posterior cricoarytenoid muscle. If there remains any question as to its identity, the operator can simply pass through the muscle and will encounter the posterior aspect of the cricoid cartilage. When this has been done, if the operator "backs out" one muscle layer, he will have identified the posterior cricoarytenoid muscle. In the occasional patient, this muscle (although still present and capable of reinnervation) will have undergone sufficient wasting that it will be a fairly thin layer. If there is any question, a biopsy can be obtained to demonstrate that it represents striated muscle. Once the muscle has been identified, the nerve-muscle pedicle is sutured to it with one or two sutures of 5-0 nylon. These sutures are first placed through the muscle of the posterior cricoarytenoid and then carried through the muscle in the pedicle. It is only necessary to make contact between the raw surface of the transposed muscle block and the outer surface of the posterior cricoarytenoid muscle. The muscles of the larynx in this area have little or no fascia and in the process of dissecting the reflection of the pyriform sinus off the posterior cricoarytenoid muscle, the surface will be sufficiently denuded to allow good physiologic contact.

In some of the cases where the reinnervation procedure has failed, we have operated through the same incision in an effort to perform an arytenoidectomy and, in the process, have been able to inspect the nerve-muscle pedicle to try to determine reasons for failure. Lack of survival of the nerve-muscle pedicle and/or displacement of the pedicle from the recipient bed have been encountered only once, thus suggesting that these findings are not frequent reasons for failure.

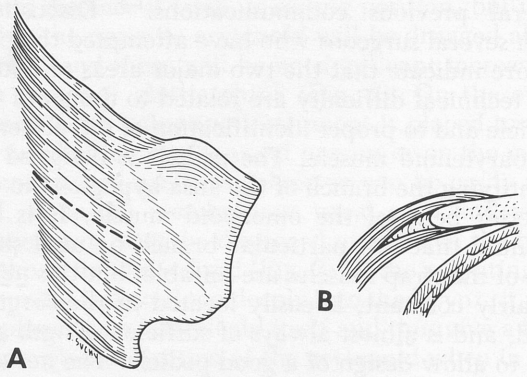

Fig. 5. A) Point of separation of fibers of inferior constrictor muscle (dotted line) to facilitate exposure of the pyriform sinus. B) Deepest muscle layer representing posterior cricoarytenoideus. Horizontal section of larynx at point of entry. External and internal leaflets of inferior constrictor muscle are visible as they insert on free edge of thyroid ala.

POSTOPERATIVE MANAGEMENT AND EVALUATION

There are three possible results of a properly done reinnervation procedure in a correctly chosen candidate: 1) there can be obvious improvement in the patient's airway and exercise capability without benefit of tracheotomy, accompanied by visible motion of the vocal cord during inspiratory effort; 2) there may be obvious improvement in the patient's airway and exercise capability without apparent movement of the vocal cord on inspiratory effort; and 3) there may be no appreciable improvement in the airway.

In the first situation, the success of the procedure is obvious and little need be said. These results will be obtained in approximately 40% of properly selected patients. In the third situation, postoperative evaluation is also fairly straightforward. If there is no visible motion in the cord, even with stress, and if the patient's airway with the tracheotomy tube occluded remains clinically inadequate six months after attempted reinnervation, the operation has failed and further improvement is not to be expected. Such a patient can be left with the tracheotomy tube as a more or less permanent solution to the bilateral cord paralysis problem or some type of vocal cord lateralization can be undertaken. In our current experience in over 200 cases, 20% of all patients subjected to reinnervation will have no improvement.

In the remaining 40%, the patient will have definite clinical improvement in airway and exercise capability with the tracheotomy tube occluded but there will be little or no visible motion of the vocal cord, even with inspiratory effort. These patients should be stressed by running in place with the tube occluded until they are panting and then observed again. In most of them, the reinnervated vocal cord will now be noted to have appropriate abduction with inspiratory effort (although not necessarily with each inspiratory effort) or there will be tonic abduction of the vocal cord. This phenomenon can be explained as follows. In many patients with bilateral vocal cord paralysis, the resting airway is at least adequate for resting ventilatory needs and even perhaps for a small amount of exertion. Since the nerve used to reinnervate abductor function of the vocal cord is derived from an accessory muscle of respiration which becomes highly active only under increased respiratory demand, there would be little or no motion expected unless the patient was stressed. In some patients there will be tonic contraction of the vocal cord because the strap muscles may increase activity under stress in either rhythmic or tonic fashion when respiratory effort is increased and thus the type of movement produced in the reinnervated cord will depend on which is true in the patient in question. The tonic type of contraction can be very subtle and it requires experience to really observe the increase in the cross-sectional area of the airway. This may amount to only 2 or 3 mm improvement at the posterior glottic chink over the resting state, but for many patients this is more than adequate. For this reason, the single most important factor in assessing whether or not a patient should be extubated after reinnervation is his ability to tolerate corking of the tracheotomy tube and still have satisfactory exertional capability. We have examined at least four patients who had successful reinnervation surgery by others, but the surgeon had been reluctant to remove the tube because of lack of apparent movement of the cord. In each of these cases, the patient reported definite improvement in exertional capability with the tracheotomy tube corked. In several of them it was possible to demonstrate subtle but definite lateralization of the reinnervated cord with appropriate exertional testing. All four of these patients were extubated and remained long-term successes.

In some patients a small improvement may be achieved by reinnervation surgery which perhaps is not sufficient for an optimal result. In such cases, if the opposite arytenoid was passively mobile and remained so, we have been able to perform reinnervation on the second side and achieve enough additional improvement that the patients could then be extubated with ability to exert themselves and with safety of the airway.

CONCLUSIONS

Nerve-muscle pedicle reinnervation for rehabilitation of bilateral vocal cord paralysis has been described in the literature and has been successful in the hands of its originator as well as in those of several other authors. Inability to reproduce these results may be related to pitfalls in at least three aspects of management of these patients, including preoperative assessment and selection of patients, design of the nerve-muscle pedicle, proper identification of the posterior cricoarytenoid muscle and postoperative evaluation. With further explanation and attention to these aspects of reinnervation surgery, we hope that other otolaryngologists will find that the procedure can be useful in their own practices.

REFERENCES

1. Tucker HM. Human laryngeal reinnervation: long-term experience with the nerve-muscle pedicle technique. Laryngoscope 1978; 88:598-604.

2. Tucker HM. Reinnervation of paralyzed larynx: a review. Head Neck Surg 1979; 1:235-42.

3. Tucker HM. Laryngeal paralysis: etiology and management. In: English GM, ed. Otolaryngology. Vol. 3. Hagerstown, MD: Harper and Rowe, 1981.

4. Applebaum EL, Alan GW, Sisson GA. Human laryngeal reinnervation: the Northwestern experience. Laryngoscope 1979; 89:1784-7.

5. May M, Lavorato AS, Bleyaert AL. Rehabilitation of the crippled larynx: application of the Tucker technique for muscle-nerve reinnervation. Laryngoscope 1980; 90:1-18.

6. Ward PH, Berci G. Observations on nerve-muscle preparation reinnervation of the paretic larynx — an evaluation of the Tucker procedure. Laryngoscope 1982 (in press).

7. Tucker HM. Vocal cord paralysis — 1979: etiology and management. Laryngoscope 1980; 90:585-90.

SURGERY OF THE INFERIOR NASAL TURBINATES

WILLIAM H. SAUNDERS, MD

COLUMBUS, OHIO

The inferior turbinates are responsible for nasal obstruction more often than commonly thought. When there is no other obvious cause for nasal obstruction, and when allergic disorder or other medical condition is not responsible, attention should be given to treatment of the inferior turbinates in many instances of nasal obstruction. Such treatment is usually surgical and may consist of submucous resection of the turbinate bone or excision of redundant hyperplastic turbinate tissue, or a combination of the two. Other treatments consist of electrocautery or cryotherapy. Injection of corticosteroids have produced blindness through embolism and, in general, this treatment is discouraged. The paper discusses in some detail which patients are best suited for submucous resection and which for excision of soft tissue. Techniques, which are simple, are also described.

Chronic nasal obstruction is one of the commonest complaints made by patients to their otolaryngologist. I look forward to seeing these patients with nasal obstruction, since there is virtually always something that can be done to improve their condition. Also, these patients, properly treated, tend to be grateful.

There are, of course, many causes of nasal obstruction. Some are medical causes, such as overuse of nosedrops producing rhinitis medicamentosa, and use of the rauwolfia drugs. An occasional patient has nasal obstruction because of overt hypothyroidism and others because of allergic conditions. All of these causes must be considered in the diagnosis and treated if possible. In this paper we assume none of these conditions to be present.

Surgically correctable conditions causing nasal obstruction include the deviated nasal septum, nasal polyposis, benign and malignant tumors, foreign bodies, and other conditions. One of the most common is disease or structural abnormality of the inferior turbinate. Often two or more causes of nasal obstruction exist together and should be treated simultaneously, but for the purpose of this paper we will consider only disorders of the inferior turbinate and make incidental references to other conditions.

INTRANASAL EXAMINATION

The first step is to establish an accurate diagnosis. To examine the intranasal chamber properly a system of bright lighting is needed. The head mirror reflecting light from a 150-W clear or bulls-eye bulb is the time-honored method because this permits an accurate focusing of light in the posterior aspects of the nose. I have found that the Zeiss operating microscope fitted with a straight head and a 250-mm objective lens offers brilliant illumination, magnification, and binocular vision. Proficiency in this technique is easy to acquire.

Also let me state in passing that while modern nasopharyngoscopes, such as the Machida and Olympus, are useful for special examination, they are not the primary tool for intranasal or postnasal examination.

Whenever the patient has nasal obstruction as a chief complaint, the intranasal examination should include the use of a vasoconstrictor, but not until after the nose has been inspected without the vasoconstrictor. I generally use 3% ephedrine applied on cotton pledgets, although other drugs will do. I do not use topical adrenalin because it produces too intense an effect. Occasionally I use small doses of topical anesthesia, such as Cetacaine spray (contains 2% tetracaine) to facilitate the examination.

An adequate examination must include a careful look at the postnasal space. Sometimes gagging or an inadequate space between the soft palate and posterior pharyngeal wall discourages observation. One must persist, however, since failure to see clearly in the epipharynx is one of the major pitfalls associated with accurate diagnosis. In my opinion the best method of examination is with the number zero nasopharyngeal mirror. Occasionally a palate retractor is needed. Also Valium, 10 mg intravenously, is useful to reduce gagging.

INFERIOR TURBINATE

Normally (Fig. 1A) the inferior turbinate does not obstruct breathing except occasionally when the patient is reclining. Then as blood and tissue fluids pool in the head he may find that one or the other side of his nose is blocked. By turning over in bed, the dependent, obstructive side becomes uppermost and the obstruction is relieved. Such alternating enlargement and diminishing of the soft tissue of the turbinates occurs several times daily regardless of posture, but usually does not cause symptoms. In

From the Department of Otolaryngology, The Ohio State University, Columbus.

Presented at the meeting of the American Laryngological Association, Palm Beach, Florida, May 1-2, 1982.

REPRINTS — William H. Saunders, MD, Dept. of Otolaryngology, The Ohio State University, 456 Clinic Drive, Columbus, OH 43210.

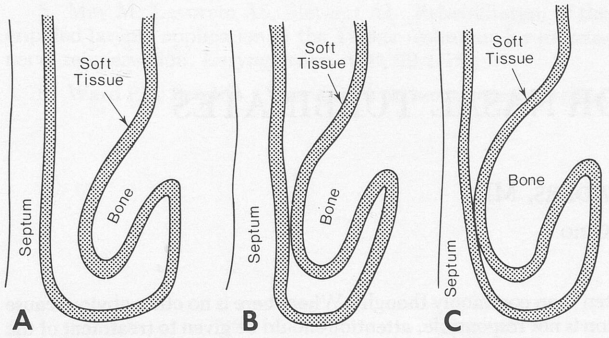

Fig. 1. Bone of inferior turbinate. A) Normal alignment. B) Bone approximates septum; small inferior meatus. C) Bone approximates septum; substantial inferior meatus.

short, the normal inferior turbinate should warm and moisten the air without producing symptoms.

Symptoms other than nasal obstruction such as headpain and postnasal discharge are not likely to be caused by deformity or disease of the turbinates and the patient should understand clearly, preoperatively, that the only symptom the surgeon is trying to relieve is nasal obstruction. Otherwise the operation, at least in the mind of the patient, fails before it starts.

There are, in general, three ways in which the inferior turbinate produces nasal obstruction. First, an undue prominence of the bony structure of the turbinate may cause it to touch or approximate the nasal septum (Fig. 1B). In this case application of vasoconstrictors reduces the size of the turbinate only minimally. When one palpates the turbinate it is apparent that the enlargement is bony and that the obstruction is not merely due to soft tissue engorgement or hyperplasia.

Treatment in this case consists of submucous resection of all or part of the turbinate bone so that the obstructive turbinate is reduced and no longer touches or nearly touches the nasal septum. This is best accomplished with the patient under local anesthesia. An incision is made down to the bone of the turbinate along most of its medial length. Then the soft tissue is elevated upward and downward and a substantial amount of bone exposed and removed. A chisel may be needed to fracture the bone, but often pieces can be broken off using a hemostat or submucous elevator. Gauze packing (preferably impregnated with Terramycin ointment) is applied and left in place at least 48 hours to prevent bleeding. The only complication of this procedure is postoperative hemorrhage, which is seen chiefly when packing is removed too soon. To be safe, I leave packs in place three to four days and remove them on an outpatient basis.

Sometimes it is worthwhile to crush an inferior turbinate laterally (toward the inferior meatus) when it is the bone of the turbinate that causes obstruction and not soft tissue. This procedure works best if the turbinate is first displaced toward the nasal septum and then pressed laterally. Even so, in most instances this procedure is not entirely effective since the fracture produced tends to be of the greenstick variety and later the turbinate tends to return to its original position. Lateral displacement works best in cases where there is a large inferior meatus to receive the newly displaced turbinate (Fig. 1C).

Second, there are patients with redundant hyperplastic turbinate mucosa (Fig. 2A). Their nasal obstruction may be severe unilaterally or bilaterally. The bony turbinate may or may not be enlarged, but certainly the soft tissue of the turbinates is excessive. Shrinkage with vasoconstrictors is incomplete and palpating the redundant lower and medial surfaces of the turbinate shows it to be flaccid and polypoid (Fig. 2B). The treatment here

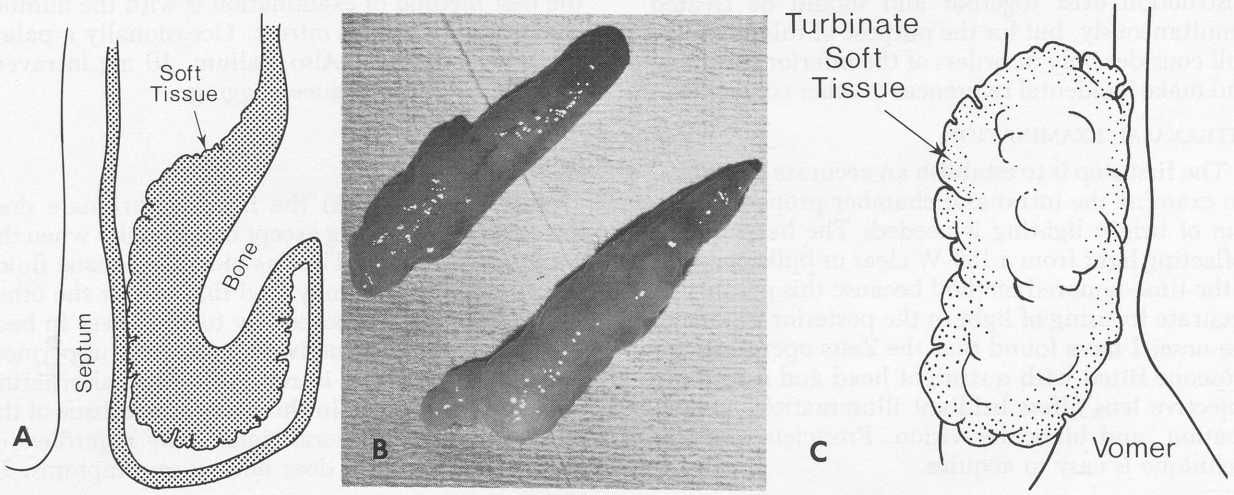

Fig. 2. A) Hyperplastic soft tissue of inferior turbinate with other relationships normal. B) Typical redundant, hyperplastic turbinate mucosa. This excision represents less than half of the entire turbinate tissue. C) Hyperplastic posterior tip of inferior turbinate.

(we assume no allergic condition) is to excise generously the redundant tissue with scissors. In addition, submucous resection of the bone may be required. In my opinion at least half of the soft tissue of the hyperplastic turbinate can be excised without danger of producing atrophic rhinitis.

Sometimes likened to a mulberry, the hyperplastic posterior end of the inferior turbinate may be so large as to fill one choana completely (Fig. 2C). The time to assess appearance of the posterior tip of the turbinate is preoperatively in the office using the postnasal mirror — not at the time of surgery. A snare passed around the posterior tip will cut it off, but there usually is need for additional work on the turbinate anteriorly. Even if only the posterior tip is snared away, be sure to pack the nose for three to four days or postoperative bleeding may be profuse.

Third, turbinates are often enlarged because of vasomotor changes. They seem simply engorged, and the mucosa is not particularly redundant or polypoid and the turbinate bone is not prominent. Vasoconstrictors should produce shrinkage. Again, it is assumed that there are no allergies identified.

Treatment may be with electrocautery by stripping the surface of the turbinate with the blade of the cautery instrument or inserting an electrode submucosally. In any case the result is tissue destruction and scarring so that there comes to be a reduction in the size of the turbinate. The treatment may have to be repeated. Local injectable anesthesia is adequate and the procedure may be done on an outpatient basis. Also, in patients of this type there is no reason that submucous resection of the turbinate should not be effective, and, as a matter of fact, I prefer it to cautery. Formerly, some doctors injected sclerosing solutions into the inferior turbinate to cause shrinkage, but now that there are reports of blindness from similar injections with steroids such injections are no longer done by most doctors.

MIDDLE TURBINATE

The middle turbinate also may contribute to nasal obstruction. When it does it is apt to be because of an ethmoidal air cell that dilates the turbinate. Also I have seen examples of mucoceles of the middle turbinate. In either case the treatment is easy: simply incise into the thin, shell-like structure and either crush it with a hemostat or other forceps, or resect some portion of the bone.

CORRECTION OF POSTERIOR GLOTTIC INCOMPETENCE FOLLOWING HORIZONTAL PARTIAL LARYNGECTOMY

HUGH F. BILLER, MD
WILLIAM LAWSON, MD, DDS STEVEN SACKS, MD
NEW YORK, NEW YORK

Posterior glottic insufficiency following horizontal partial laryngectomy results in persistent aspiration. A new method of correction of this occurrence is described. The procedure is an extralaryngeal approach. A tracheotomy is not required. The procedure was successful in 4 of 6 patients.

Closure of the glottis on deglutition is essential for rehabilitation following horizontal partial laryngectomy or partial laryngopharyngectomy. Failure to achieve glottic closure in these cases is associated with chronic aspiration and recurrent or persistent pneumonitis. At the time of resection every effort is made to ensure adequate glottic closure postoperatively. Glottic insufficiency usually results from one of the following: 1) partial or total arytenoid removal; 2) partial resection of the true cord to obtain a tumor-free inferior margin; or 3) inadvertent injury of the recurrent laryngeal nerve during cricopharyngeal myotomy.

The first circumstance is the most common cause. Partial arytenoid resection with exposure of the residual cartilage frequently leads to arytenoid fixation in the abducted position. In these cases coverage of the exposed cartilage with a mucosal flap may avoid chondritis and, ultimately, fixation. Resection of the superior aspect of the arytenoid to the level of the vocal process will lead to fixation in most cases, even though mucosal coverage is performed. In these cases, even if the arytenoid moves when the anesthesia is lightened, the vocal cord should be fixed in the midline. This fixation is accomplished with a nonabsorbable submucosal suture extending from the vocal process to the perichondrium of the cricoid cartilage. This suture, when tightened, rotates the arytenoid internally, resulting in a vocal cord fixed in the midline. However, the defect created following complete arytenoid resection cannot be corrected by simply suturing the vocal process to the cricoid. Any attempt to do so will result in a defect in the posterior glottis postoperatively. In these cases, a free or pedicled cartilage graft is shaped to conform to the defect and is wired to the cricoid. The cut margin of the vocal process is then anchored, in the midline, to this piece of cartilage with a nonabsorbable suture. The entire reconstruction is now covered by a mucosal flap from the medial wall of the pyriform sinus.

Despite immediate reconstruction at the time of resection, a small number of patients will aspirate postoperatively because of incomplete glottic closure posteriorly. This failure may result from scarring, resorption of the cartilage graft, or inadequate reconstruction at the time of surgery.

This presentation introduces a technique for correction of postoperative posterior glottic deficiency. The diagnosis of postoperative posterior glottic incompetence is determined by indirect laryngoscopy in the patient with persistent aspiration. This circumstance is frequently, but not always, accompanied by a breathy voice. Indirect laryngoscopy confirms the diagnosis and also determines whether the defect is anterior in the membranous cord, or posterior at the arytenoid location. This determination is important for each area requires a different type of correction. Correction of deficiencies anteriorly along the membranous portion of the vocal cord has been adequately covered in previous papers[1-4] and will not be considered here.

TECHNIQUE AND MATERIALS

The approach entails an extralaryngeal exposure similar to the arytenoidectomy procedure as described by Woodman.[5] The operation is performed under general anesthesia utilizing endotracheal intubation with a 6.5 mm tube. If a neck dissection has been performed, a vertical incision is used so as to avoid exposure of the carotid. If a neck dissection has not been performed a horizontal incision (Fig. 1A-b) is made in the anterolateral neck. The remaining portion of the posterior border of the thyroid ala is identified. The attachment of the inferior constrictor muscle to the posterior border is divided. The cricothyroid articulation is separated and the posterior border of the thyroid cartilage is retracted anteriorly with a hook. The pyriform sinus mucosa is reflected superiorly and the posterior aspect of the cricoid cartilage is identified. A subperichondrial dissection is performed, if possible, exposing the posterior-superior cricoid border (Fig. 1B). The mucosa is elevated from the superior aspect of the cricoid laterally and to the midline. A piece of cartilage or bone is obtained, tailored and wired on to the cricoid at the arytenoid area (Fig. 1C). If a tear in the mucosa occurs, it is sutured. Direct laryngoscopy is then performed to evaluate whether the defect is adequately corrected (Fig. 2). Additional cartilage may be placed if necessary.

From the Department of Otolaryngology, The Mount Sinai Medical Center, New York.
Presented at the meeting of the American Laryngological Association, Palm Beach, Florida, May 1-2, 1982.
REPRINTS — Hugh F. Biller, MD, Dept. of Otolaryngology, Mount Sinai Hospital, 100th St. & 5th Ave., New York, NY 10029.

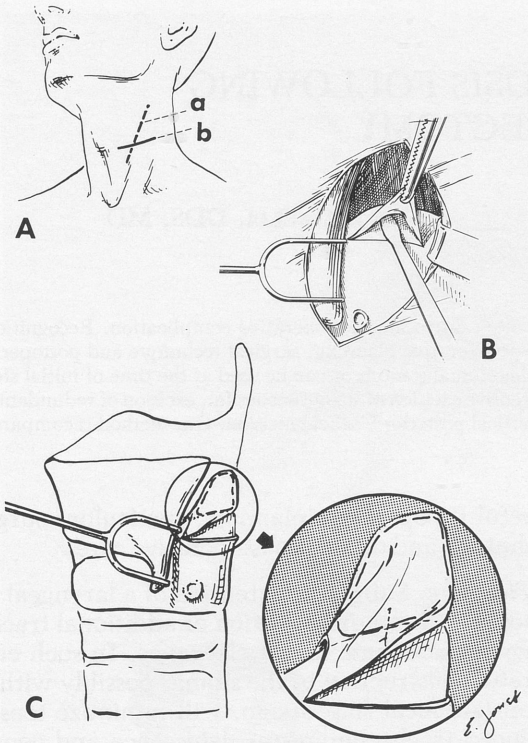

Fig. 1. A) Skin incision. a - Anterior border of sternocleidomastoid muscle; b - Horizontal incision in the anterolateral neck. B) Disarticulation of the cricothyroid articulation and subperichondrial dissection of arytenoid joint. C) Insertion and fixation of graft.

This procedure has been performed on six patients. The reconstructive effort occurred four months to two years following the initial extirpative surgery. Two of the six patients had partial laryngopharyngectomies performed for pyriform sinus cancers with complete excision of the arytenoid cartilage. Four patients had supraglottic carcinomas resected with partial or complete arytenoid removal. All patients aspirated sufficiently to require gastrostomy or nasogastric tube feedings. Three of the six patients had prior injection of Teflon without improvement.

RESULTS

Surgery was considered successful following the extralaryngeal cartilage implants in 4 of the 6 patients. These patients were able to feed orally without aspiration, gained weight, and had their nasogastric or gastrostomy tubes removed. These four patients have been followed for a minimum of 18 months. There has been no evidence of recurrence of the defect or aspiration.

One of the two patients who failed was noted to have extensive granuloma formation at the time of surgery, presumably secondary to the extravasation of Teflon. In this patient the anatomy was distorted and though a graft was inserted, minimal correction of the defect was obtained. The other failure had a graft which was small and only partially corrected the defect.

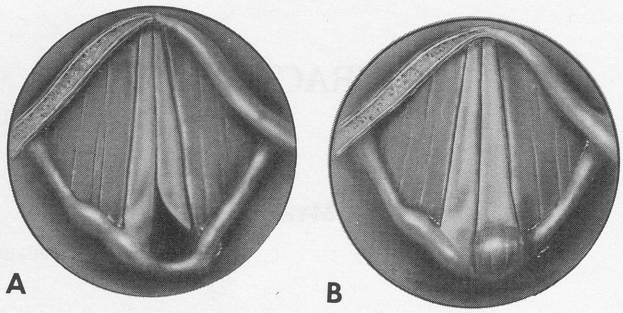

Fig. 2. A) Posterior defect and B) corrected.

DISCUSSION

The correction of late posterior glottic deficiency has received limited attention in the literature. Teflon injection, although successful in correcting the lateralized vocal cord secondary to paralysis or minimal scarring, is uniformly unsuccessful in the treatment of posterior glottic defects. The reason for this is that the dense adherence of the mucosa to the cricoid does not permit installation of this substance.

The only previous article addressing this problem is by Sessions et al.[3] These authors advocated correction of posterior defects by performing a thyrotomy and then dissecting a pocket between the vocal cord and the thyroid cartilage. This pocket was elevated posteriorly to the cricoid, following which a piece of cartilage was inserted. In our experience, this anterior approach is unsatisfactory because the cartilage graft is not fixed in position and, therefore, yields unpredictable results. A tracheotomy is also required. These deficiencies with correction through a thyrotomy led to the formulation of the present extralaryngeal approach. This extralaryngeal approach provides excellent exposure, wide mucosal undermining, permanent fixation of the graft, accurate assessment of the correction by direct laryngoscopy at the time of surgery and eliminates the requirement of a tracheotomy.

One of the failures in this series probably was due to prior extravasation of Teflon. It is apparent from our experience that Teflon installation should not be attempted for these posterior defects but rather cartilage grafting performed by the procedure described.

REFERENCES

1. Waltner J. Surgical rehabilitation of the voice following laryngo-fissure. Arch Otolaryngol 1958; 67:99-101.

2. Arnold G. Vocal rehabilitation of paralytic dysphonia IX. Technique of intracordal injection. Arch Otolaryngol 1962; 76: 358-68.

3. Sessions D, Ogura J, Ciralsky R. Late glottic insufficiency. Laryngoscope 1975; 85:950-9.

4. Meurman Y. Operative medial fixation of the vocal cord in complete unilateral paralysis. Arch Otolaryngol 1952; 55:544-53.

5. Woodman D. A modification of the extralaryngeal approach to arytenoidectomy for bilateral abduction paralysis. Arch Otolaryngol 1946; 43:63.

TRACHEOSTOMAL STENOSIS FOLLOWING TOTAL LARYNGECTOMY

EUGENE N. MYERS, MD, FACS LOUIS J. GALLIA, DDS, MD

PITTSBURGH, PENNSYLVANIA

Stenosis of the tracheostoma after laryngectomy is an infrequent but often distressing postoperative complication. Recognition of possible predisposing factors will allow appropriate preventive measures in preoperative planning, surgical technique and postoperative care. We describe a surgical technique which can be utilized to correct tracheostomal stenosis or can be used at the time of initial stomal construction. Our method emphasizes mobilization of the tracheal stump, extensive excision of subcutaneous fat, excision of redundant skin and creation of a posterior-superior skin flap which is interdigitated into a vertical posterior tracheal incision. Our method is compared to other techniques described in the literature.

INTRODUCTION

Stenosis of the tracheostoma after laryngectomy is an infrequent but often distressing postoperative complication. It may occur in the immediate postoperative period or years later. Stomal stenosis will compromise not only optimum air exchange but also the ability to clear tracheobronchial secretions. The tracheal lumen may be reduced 50% in all diameters (resulting in a 75% reduction in luminal surface area) and a patient with normal lungs will maintain tolerance for normal exercise.[1] In a patient with emphysema or a chronic productive cough, the same defect may produce respiratory insufficiency. Stomal stenosis acts as a barrier to mucociliary transport resulting in a stagnation of mucus and a potential for recurrent pulmonary infection.[1] Severe stenosis, especially with the addition of crusting, may result in asphyxia.[2]

ETIOLOGICAL FACTORS

Factors contributing to stomal stenosis[2] include:

1. Radiation therapy
2. Excessive scar tissue formation
3. Wound dehiscence with healing by secondary intension
   a. Skin tension
   b. Infection
   c. Steroid usage
4. Keloid formation
5. Defective or absent tracheal rings
6. Inadequate excision of peristomal skin and fat at initial stomal construction
7. Recurrent tumor

PREVENTIVE MEASURES

The ideal method of dealing with tracheostomal stenosis is prevention. Preventive measures include careful preoperative planning, meticulous surgical technique and diligent postoperative care.

Planning. Subglottic extension of a laryngeal carcinoma will require resection of additional tracheal rings for adequate tumor clearance. In such cases, careful construction of the stoma, possibly with appropriate local flap design, will minimize tension-induced tracheocutaneous dehiscence and concentric scarring. There is a tendency for this dehiscence to occur in patients on chronic steroid administration; such cases should be constructed virtually tension-free.

If preliminary tracheostomy is required a few days or more prior to laryngectomy one may expect an extensive local inflammatory response which may predispose to stomal stenosis. A tracheal ring defect due to chondritis may predispose to stomal collapse.

In the grossly obese patient, the fat-laden peristomal tissues tend to bulge into the stoma resulting in a pseudostenosis. In the black patient, examination of previous wounds including surgical incisions will provide clues as to the potential for stomal keloid formation.

The stomal stenosis seen after radiation therapy presumably results from concentric scarring. Local flap transposition designed to enlarge the stoma and prevent formation of a circular scar may prevent the problem.

Surgical Technique. The primary objectives in the surgical prevention of tracheostoma stenosis are careful approximation of skin and mucous membrane, elimination of extensive compressive forces, active tension on the stoma margins, increased circumference, and redistribution of the forces of scar contraction.

From the Department of Otolaryngology, University of Pittsburgh School of Medicine, Eye and Ear Hospital.

Presented at the meeting of the American Laryngological Association, Palm Beach, Florida, May 1-2, 1982.

REPRINTS — Eugene N. Myers, MD, FACS, Professor and Chairman, Eye and Ear Hospital, 230 Lothrop Street, Pittsburgh, PA 15213.

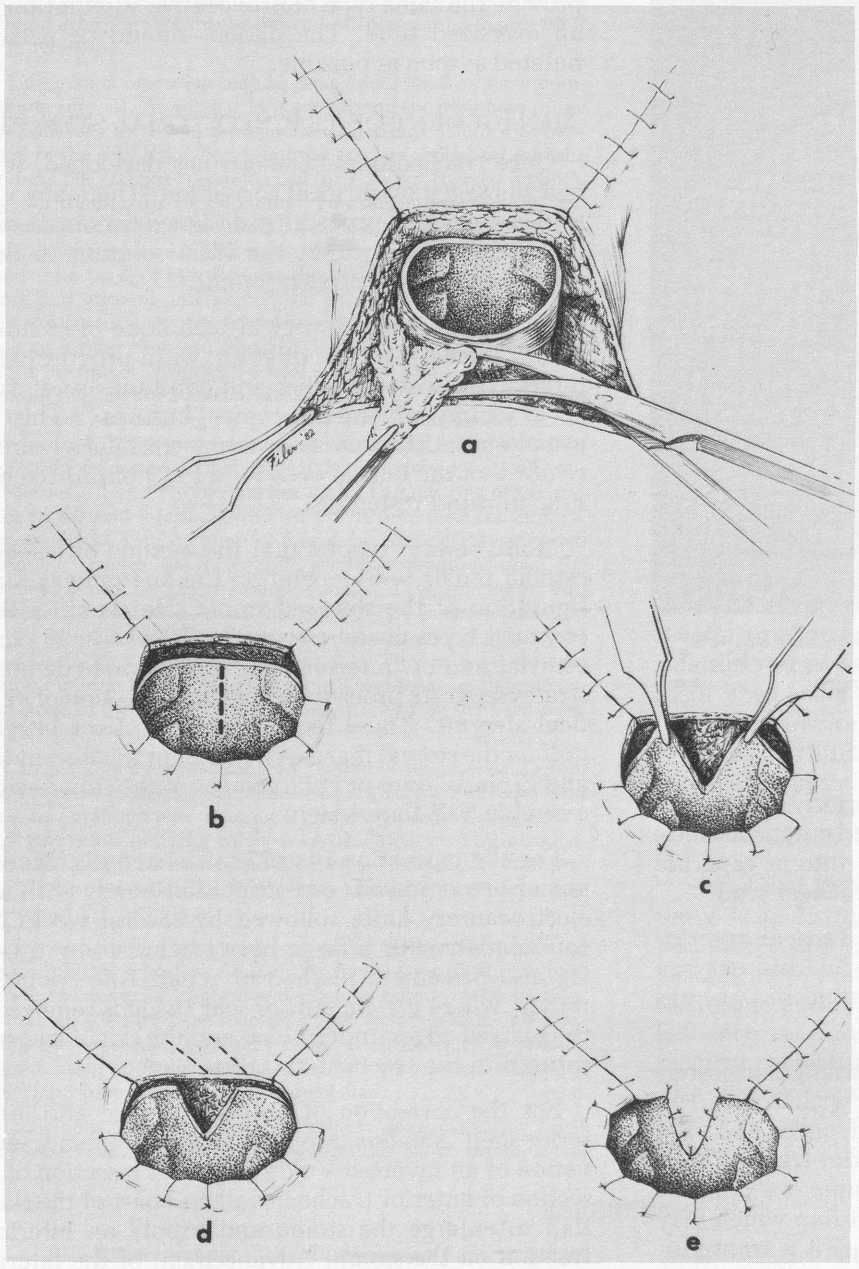

Fig. 1. a) Excision of peristomal adipose tissue. b, c) Incision in membranous posterior wall of trachea. d, e) Creation and transposition of local skin flap into tracheal incision with completion of stomal skin closure.

The most common techniques[2,3-5] to prevent stenosis include 1) oblique section of the tracheal stump (to increase stomal diameter); 2) semicircular or circular incision, to increase the circumference of the skin margin to adapt to the tracheal stump (to achieve tension radially on the stoma); 3) complete coverage of the cut edge of the tracheal cartilage with through and through or vertical mattress sutures.

In the obese patient, excision of excess adipose tissue will minimize the external compressive force of the adipose tissue.

Clairmont,[6] Jatho,[7] Isshiki and Tanabe,[8] Trail et al,[9] and Hartwell and Dykes[10] described a variety of similar techniques employing Z-plasty, double V and V-Y flap design methods of primary tracheostomal construction at the time of laryngectomy in order to prevent stenosis by enlarging the stoma and redirecting the forces of scar contraction.

Clairmont[6] created a "butterfly" or "bowtie" stoma by excising inferiorly based wedge-shaped triangles from the anterior and posterior tracheal stump. Superior and inferior skin flaps, created by lateral skin excision, are inset into the apex of the tracheal defects.

Trail et al[9] use a method of double rotation flap Z-plasty utilizing the skin posterior to the stoma transposed into an oblique incision in the posterior membranous tracheal wall. A small flap of mucosa of posterior tracheal wall is then transposed into the

Fig. 2. Healed tracheal stoma in patient who had total laryngectomy and radical neck dissection one year following full course "curative" radiation therapy.

tumor site of the skin flap.

Isshiki and Tanabe[8] utilize superiorly based double skin flaps, created by a Y-shaped cutaneous incision, each of which is inserted into a separate oblique incision of the posterior tracheal wall.

Jatho[7] enlarges the stoma by a vertical anterior tracheal incision; edges created by this cut are pulled apart by permanent subcutaneous sutures which are affixed to the clavicle.

Hartwell and Dykes[10] created a triangular posterior-superior skin flap by excising a wedge of skin on each side of this flap. The flap is advanced and inset into a vertical incision of the posterior trachea. This technique differs from the technique we describe only in that this is an advancement flap which may tend to be redundant, whereas ours is a transposition flap.

Mumma and Pressman[11] described implantation of a subcutaneous tantalum ring around the stoma to prevent stenosis.

Postoperative care. Basic tenets of care which will minimize stomal stenosis include proper tube selection, meticulous local wound care and timely decannulation.

Some feel that an oversized tube may produce stenosis by producing mucosal inflammation and de-epithelization with subsequent concentric scarring. Removal of pericannular crusts and secretions, along with application of antibacterial agents such as Betadine, should minimize bacterial contamination and infection. Prolonged cannulation and especially prolonged mechanical ventilation provide the same type of provocative stimulation as an oversized tube. The patient should be decannulated as soon as possible.

MANAGEMENT OF TRACHEOSTOMAL STENOSIS

Once tracheostomal stenosis has developed, it is best managed by surgical correction. The many varieties of surgical procedures designed to correct stomal stenosis imply that the ideal solution to this problem has not yet been found.

An alternative nonsurgical technique of stenosis management involves dilation with progressively larger tracheostomy tubes and constant use of one of a variety of tracheostomy "buttons." This is usually unsatisfactory as a permanent solution since removal of the button even for a few hours often results in rapid restenosis.

Montgomery[2] reports that the method of tracheostoma repair will depend on the anatomical configuration of the stenosed stoma. He classifies the common types of stenosis as a) vertical slit, b) concentric, and c) "inferior shelf" stenosis. He demonstrates separate procedures for the correction of vertical stenosis. These techniques will effect lateral pull on the stomal margins by straight advancement and Z-plasty flaps or enlargement of the stoma with a double V-Y flap design.

For the correction of concentric stenosis, Montgomery recommends radial incisions made with an electrocautery knife followed by several weeks of cannulation with a large bore tracheostomy tube. He also presents a method of repair (the "donut" repair) where a 1 cm cuff of scar tissue is removed, the scarred edges undermined and the skin edges resutured to the tracheal margins.

For the correction of both concentric and "inferior shelf" stenosis, Montgomery recommends elevation of an inverted V skin flap with resection of a section of anterior tracheal wall and part of the skin flap to enlarge the stoma and supply an inferior traction on the stoma. Advancement of the lateral marginal incision supposedly applies additional pull on the stoma.

Converse[12] describes a swastika-shaped incision around the stenosed stoma; the stenosed skin is excised and the four created flaps are rotated, thus presumably creating a lateral tension to prevent recurrence.

Maruyama et al[13] utilized a 5 flap reconstruction consisting of two Z-plasties combined with a Y-V advancement which break up the superior of the stenosis and increase the circumference of the stoma.

TECHNIQUE

In the patient who has stomal stenosis following total laryngectomy, the most common problem is that there is a band of scar tissue present which concentrically narrows the stoma. Usually

the caliber of the trachea is otherwise normal. The goal of this revision procedure is to excise this concentric scar and to prevent it from recurring.

The revision operation may be done under local or general anesthesia (Fig. 1). An incision is made around the periphery of the tracheostoma including the band of scar tissue. Clamps are applied to the scar tissue band and the trachea pulled up into the wound. The trachea is skeletonized for 1-2 rings thereby mobilizing the trachea for repositioning. The skin inferior to the tracheostoma is undermined for 2-3 cm, and the subcutaneous adipose tissue is removed. The excess skin in this area should be excised. The band of scar tissue is then excised from the tracheostoma and utilizing interrupted 3-0 chromic catgut sutures, the skin is sutured to the tracheostoma with a meticulous technique making certain that skin overlaps the raw edges of the cartilage and is in contact with the tracheal mucosa. This suturing is carried out to a level of 3 and 9 o'clock on the tracheostoma. The skin of the neck surrounding the posterior wall of the trachea is then undermined. Adipose tissue and redundant skin are excised. The membranous posterior tracheal wall is then incised vertically approximately 1 cm into the trachea itself. The suturing of the trachea to the skin inferior to the trachea is resumed. The circumference of the tracheostoma will now be considerably widened since the trachea has been split, thereby spreading open the tracheal lumen. A small incision is made in the redundant skin posterior to the trachea such that a small flap is developed. The flap is then transposed and sewn into the incision which has been made in the posterior wall of the trachea. The same 3-0 chromic suture material is utilized in this area. This breaks up the concentric circle of the tracheostoma thereby preventing the narrowing by scar tissue in the future.

Our technique emphasizes mobilization of the tracheal stump, the extensive excision of subcutaneous fat, excision of redundant skin, and creation of a posterior-superior skin flap which is interdigitated into a posterior tracheal vertical incision. The introduction of this flap breaks up the concentric circle of scar and prevents future stenosis. This is probably the single most important feature of this technique.

Our technique most closely resembles that of Hartwell and Dykes[10] in that a posterior-based skin flap is inserted into an incision in the posterior tracheal wall. Our technique seems to differ in that we advocate extensive subcutaneous fat excision and trimming the peristomal skin back as far as is necessary to provide slight tension on the closure. We also advocate a small transposition flap rather than an advancement flap.

Clairmont,[6] Isshiki and Tanabe,[8] Maruyama et al,[13] Converse,[12] and Montgomery[3] utilize the same principles of stomal enlargement and inhibition of circular scarring but are needlessly complex in design. We feel the simplest technique to accomplish the goal should be used. Our technique is adaptable to any type of stenosis, and the altering of the repair to the type of stenosis, as advocated by Montgomery, is probably unnecessary.

Implantation of foreign bodies as recommended by Mumma and Pressman[11] and Jatho[7] may result in infection, inflammation and actually accentuate scar formation and stenosis.

We have now begun to incorporate this exact same technique routinely in fashioning the tracheostoma in all patients undergoing total laryngectomy (Fig. 2). We believe that this is of particular importance to anticipate the potential for tracheostoma stenosis in patients who will receive postoperative radiation therapy particularly involving the tracheostoma.

DISCUSSION

In patients in which the tracheostoma area has been radiated postoperatively, extreme caution should be taken and minimal undermining should be carried out. Our three patients who have had complications from this type of tracheostomal revision all fall into this category. One patient had had several previous revision procedures. She lost considerable skin following our revision and restenosed. Two other patients lost some peristomal skin following revision, but did heal by secondary intention and fortunately did have correction of their tracheal stenosis.

SUMMARY

Stenosis of the tracheostoma after total laryngectomy is a distressing postoperative complication. Stomal stenosis can be prevented or minimized by careful preoperative planning, meticulous surgical technique and diligent postoperative care. Etiological factors, preventive measures, and a review of surgical corrective techniques have been described. The authors describe a technique which has provided a satisfactory solution to tracheostomal stenosis in most cases.

REFERENCES

1. Bain J. Late complications of tracheostomy and prolonged endotracheal intubation. Int Anesthesiol Clin 1972; 10:225-44.

2. Montgomery W. Stenosis of tracheostoma. Arch Otolaryngol 1962; 75:76-9.

3. Montgomery W. Surgery of the upper respiratory system. 2nd ed. Vol. 2. Philadelphia: Lea and Febiger, 1979.

4. Nauman HH. Kopf und Hals-chirurgie. Band 1. Stuttgart: Georg Thieme Verlag, 1972.

5. Barbosa JF. Surgical treatment of head and neck tumors. New York: Grune and Stratton, 1974.

6. Clairmont A. Tracheostoma construction during laryngectomy: techniques to prevent stenosis. J Laryngol Otol 1978; 92:75-8.

7. Jatho K. Das Kanul en Freie Tracheostoma Nack Kehlkopf Totol Extirpation. Laryngol Rhinol 1976; 55:631-6.

8. Isshiki N, Tanabe M. A simple technique to prevent stenosis of the tracheostoma after total laryngectomy. J Laryngol Otol 1980; 94:637-42.

9. Trail M, Chambers R, Leonard J. Z-Plasty of tracheal stoma at laryngectomy. Arch Otolaryngol 1968; 88:110-2.

10. Hartwell SW, Dykes ER. Construction and care of the end tracheostomy. Am J Surg 1967; 113:498-500.

11. Mumma C, Pressman J. A surgical technique to eliminate the tracheotomy tube after laryngectomy. Trans Am Acad Ophthalmol and Otolaryngol 1951; 55:418-23.

12. Converse JM. An operation for relief of stenosis of the stoma following total laryngectomy. Arch Otolaryngol 1950; 52: 950-1.

13. Maruyama Y, Kubota J, Nakajima H. A 5-flaps procedure for repair of stenosed tracheostoma. Acta Chir Plast (Prague) 1980; 22:107-10.

PREDICTING ESOPHAGEAL SPEECH

GEORGE A. GATES, MD ERWIN M. HEARNE III, PHD

SAN ANTONIO, TEXAS

Patients undergoing laryngectomy in the 1980s have a low rate of acquisition of esophageal speech. The interaction of the factors of postoperative physical performance status, preoperative phonation duration, postoperative dysphagia, site of lesion, patient income, and postoperative radiation therapy correctly predict the acquisition of esophageal speech in 83% of cases and the failure to acquire esophageal speech in 96%. Such information may be helpful in selecting patients for alternative forms of postlaryngectomy speech rehabilitation.

INTRODUCTION

In spite of advances in diagnosis and therapy, about 7000 Americans lose their larynx to cancer every year. Most agree that the best method of postlaryngectomy rehabilitation for these patients is esophageal speech. In the past, the proportion of patients able to communicate effectively with esophageal speech was as high as 86%.[1] Subsequently this number has fallen to between 64-69%[2] and as low as 43%.[3] However, these reports[1-3] were based on retrospective studies. Using prospectively obtained data, we have determined that currently 26% of patients overall acquire esophageal speech and, if those who do not attempt to learn are excluded, the determinate success rate is 34%.[4]

The factors that influence esophageal speech are many and varied, but it appears to us that physical factors, ie, anatomical and physiologic, which affect esophageal speech acquisition directly, are the most difficult to overcome. In contrast, psychosocial factors, except for lack of motivation, are potentially susceptible to active intervention. In a previous communication[5] we identified and discussed individual factors that influence rehabilitation. In this paper we further analyze our data base to determine interactions among and combinations of multiple variables that might be useful to the physician in predicting which patients would be likely to fail to acquire esophageal speech. Such information would be of value in the early selection of patients for alternative methods of postlaryngectomy speech rehabilitation.

METHODS AND MATERIALS

The study records of 53 patients undergoing laryngectomy in the San Antonio area between 1975-1978 were analyzed. These records comprised all of the 103 patients with a clinical diagnosis of laryngeal cancer examined preoperatively during that time period who subsequently underwent laryngectomy. Of these, 47 patients were available for re-evaluation six months following the completion of their cancer therapy. The details of those examinations have been reported previously.[4]

The following variables were investigated as possible "discriminators" between esophageal speakers and nonspeakers in these 47 patients. They were chosen on the basis of logic, trial and error, and review of our data. For the first trial of the discriminant analysis, variables 1-6 were used. For the second trial all nine variables were used. These variables, along with brief definitions and their abbreviated symbol (in parentheses), are:

1. Tumor stage (STGE): 1 = T1N0M0, 2 = T2N0M0, 3 = T3N0M0, 4 - T3N1-3M0, 5 = T4N0M0, 6 = T4N1-3M0.
2. Postoperative radiation therapy (RADI): 1 = yes, 2 = no.
3. Physical status scale (PHYS): 5 = premorbid status, 1 = moribund.
4. Difficulty in swallowing (SWAL): 1 = yes, 2 = no.
5. Tumor site (SITE): 1 = glottic or supraglottic, 2 = pyriform sinus.
6. Preoperative phonation duration (DURA): the time, in seconds, that a subject could say /a/ on a single breath.
7. Education (ED): 1 = none, 2 = 1st-8th, 3 = 9th-12th, 4 = 1-2 college, 5 = 3-4 college, 6 = MA.
8. Number of homemates (HMATE).
9. Patient income (INC).

Of the 47 patients, eight nonspeakers were excluded from the first discriminant analysis because they were not able to participate in the preoperative phonation duration test (eg, because of a tracheostomy tube, or too ill) or because the data were missing. None of the eight subsequently acquired esophageal speech. For the second discriminant analysis one nonspeaker was excluded because no income information was available. Therefore, 39 patient records were included in the first analysis, 12 esophageal speakers and 27 nonspeakers, and 38 patients records in the second, 12 speakers and 26 nonspeakers.

The discriminant analysis was performed using forward stepwise selection of the variables. This technique chooses the variable with the largest F-statistic value, as long as the F is greater than or equal to 1. Then, the rest of the variables are chosen in a stepwise fashion, and the procedure is stopped when a variable has an F-statistic value of less than 1. Only the selected variables are used in the discriminant function.

RESULTS

The mean values of each variable for each group of subjects are displayed in Table 1. The results of the stepwise procedures are presented in Table 2. Notice that the only variables not selected as "significant" discriminators were tumor stage, education and number of homemates. The following

From the Division of Otorhinolaryngology, Department of Surgery, The University of Texas Health Science Center at San Antonio. This study was supported by a grant (RO1 CA 18629-02) from the National Institutes of Health.

Presented at the meeting of the American Laryngological Association, Palm Beach, Florida, May 1-2, 1982.

gives the standardized discriminant function for the first analysis.

$$Y = .28\ \frac{(X_{RADI} - 1.5)}{.51} + .37\ \frac{(X_{PHYS} - 2.5)}{1.14} + .61\ \frac{(X_{SWAL} - 1.6)}{.49} - .39\ \frac{(X_{SITE} - 1.3)}{.44} + .78\ \frac{(X_{DURA} - 10.1)}{7.09}$$

The general form of the equation is

$$Y = \frac{K_1(X_1 - \bar{X}_1)}{SD(X_1)} + \ldots + \frac{K_n(X_n - \bar{X}_n)}{SD(X_n)}$$

where Y = speaker score, ie, Y = 1 represents speaking and Y = 0 nonspeaking. The Xs are the data for a given patient. It should be noted that the absolute magnitude of the constants on the Xs show the relative importance of each discriminator, ie, preoperative phonation duration (DURA) was the most important variable.

The standardized discriminant function from the second analysis (9 variables) is as follows:

$$Y = .55\ \frac{(X_{RADI} - 1.5)}{.51} + .53\ \frac{(X_{PHYS} - 2.5)}{1.2} + .43\ \frac{(X_{SWAL} - 1.6)}{.49} - .41\ \frac{(X_{SITE} - 1.3)}{.45} + .85\ \frac{(X_{DURA} - 10.2)}{7.2} - .86\ \frac{(X_{INC} - 6981)}{5654}$$

The Ys for each patient can be used to "statistically" classify patients to the speaking or nonspeaking group. Table 3 presents the results of this classification. Notice that 66.7% of the speakers were correctly classified, and 85.2% of the nonspeakers were correctly classified, yielding an overall correct classification rate of 79.5% for the first trial. By adding the additional variables to the discriminant analysis the predictive ability increased to 92% overall with a correct classification score of 83% for speakers and 96% for nonspeakers.

DISCUSSION

Discriminant analysis is a powerful statistical method that allows inferences to be made about the relative weighting of multiple factors for purposes of predicting outcome. By applying the discriminant function to our patients we were able to "assign" them correctly to the appropriate category 80 to 92% of the time. Whether this predictive accuracy will hold up in other populations of laryngectomees remains to be seen; we hope it would be confirmed by other workers in the field.

We performed several trials of the discriminant analysis using a number of variables. We have chosen to include the two trials which most accurately reflect the interaction of the variables used in this study and our interpretation of their significance. This we did to indicate to those without an advanced background in statistics that there is an "art" as well as a "science" in this method of gleaning information about possible relationships from a large amount of data. Given this sample size and these subjects, it may be that these tests applied to different samples would give somewhat different results. The reader is urged to keep this in mind when applying this information to patient care. We do not suggest that this information will be 92% accurate when applied to any given group of patients.

It should also be stressed that statistical correlation does not imply causation. Even though factor A may be correlated strongly with factor B, both may be due to a third or more factors rather than the direct action of one on the other. For example, the mechanism whereby preoperative phonation duration influences the acquisition of esophageal speech is not readily apparent. Indeed, it might be a spurious coincidence or there may be a direct effect that should be studied further. One could postulate that patients with unimpaired phonation had smaller tumors, or that the patients in this category had better pulmonary function, or that they were not bashful about performing a phonatory test. In any event, this phenomenon carried too strong a statistical relationship to ignore even though the pathophysiology of this relationship is not obvious.

Logically, physical performance status would be expected to have a more direct effect upon acquiring esophageal speech. The physical rating scale we employed was relatively arbitrary. It varied from 1-5 with 5 being equivalent to the patients' preillness status and 1 indicating a bed-ridden preterminal condition. Common experience indicates that learning and using esophageal speech requires a fair amount of energy and vigor. Therefore, patients weakened by their disease, the effects of therapy, or depression would be expected to have difficulty speaking esophageally.

TABLE 1. MEANS ± STANDARD ERRORS OF THE MEANS (SEM) FOR EACH GROUP OF SUBJECTS

Group	*N*	*STAG**	*RADI*	*PHYS*	*SWAL*	*SITE*	*DURA*	*ED*	*HMATE*	*INC*
Speakers	12	3.3± .28	1.7± .14	3.3± .31	1.9± .08	1.1± .08	13.8± 2.2	2.8± .28	1.8± .55	4755± 1105
Nonspeakers	26	3.4± .25	1.4± .10	2.2± .21	1.5± .10	1.3± .10	8.5± 1.3	3.1± .20	1.1± .16	8008± 1199
Combined	38	3.4± .19	1.5± .08	2.5± .19	1.6± .08	1.3± .07	10.2± 1.2	3.0± .16	1.3± .20	6981± 917
Excluded nonspeakers	9	4.4± .48	1.2± 1.5	2.8± .47	1.5± .19†	1.4± .18	—	3.4± .24	1.8± .49	3457± 919§

* See text for definitions of variables.

† Based on N = 8.

§ Based on N = 7.

TABLE 2. STEPWISE VARIABLE SELECTION RESULTS

	Step	*Variable*	*F*
First trial	1	PHYS	8.6
	2	DURA	6.3
	3	SWAL	4.8
	4	SITE	3.2
	5	RADI	1.2
Second trial	1	PHYS	8.2
	2	DURA	6.0
	3	INC	8.3
	4	RADI	6.8
	5	SITE	3.5
	6	SWAL	2.9

Similarly the effect of dysphagia would also appear to be direct. We categorized patients at their sixth month posttreatment examination into three groups on the basis of this variable: 1) those who had no difficulty swallowing, 2) those with mild to moderate difficulty but who did not require treatment, and 3) those who required dilations. None of the ten patients who needed dilations was able to make an esophageal voice. Only one of the esophageal speakers had dysphagia; 50% of the nonspeakers had dysphagia.

In the initial analysis of these patients the site of the cancer had no significant statistical relationship to esophageal speech acquisition. However, if the subjects were divided into two groups — 1) glottic and supraglottic vs 2) pyriform sinus — the success rate for group 1 was 33% and for 2 it was 7% (1/14) (Table 4). Thus one would conclude that patients with pyriform sinus cancer are less likely to develop esophageal speech than those with glottic or supraglottic primaries. Broken down according to tumor stage, the pyriform sinus group was staged: $T_{1-2} - 4$, $T_3 - 5$, and $T_4 - 6$; one half had clinically evident cervical metastasis preoperatively. It is a common experience that the amount of pharyngeal mucosa available for closure of the pharynx is much less in patients with pyriform sinus cancer. The dysphagia rate (62%) for the pyriform sinus group differed ($p = .051$) from that of the glottic-supraglottic group of patients (30%). Therefore we may conclude that pharyngeal dysfunction leading to dysphagia is an important factor in mediating the deleterious effect of pyriform sinus cancer upon learning of esophageal speech.

The effect of radiation therapy appears to be confined to those who received postoperative therapy. In our previous report,[5] 4/12 esophageal speakers had postoperative radiation therapy in comparison to 23/35 nonspeakers. The statistical significance of this difference was $p = .06$. We postulate that postoperative radiation therapy has a direct effect upon learning esophageal speech because patients experience pharyngeal pain and dryness during the period in which they are attempting to learn esophageal speech. The majority of patients discontinue their speech lessons during radiation therapy; most do not resume. Therefore, we wonder about alternative rehabilitation plans, such as postponing the start of speech therapy until the effects of radiation therapy have subsided. We certainly do not advocate avoiding or postponing postoperative radiotherapy because of this effect but we do urge that it be considered in the rehabilitation planning.

TABLE 3. CLASSIFICATION RESULTS

	Actual Group	*Predicted Group Membership* *Speaking*	*Nonspeaking*
First trial	Speaking	8 (66.7%)	4 (33.3%)
	Nonspeaking	4 (14.8%)	23 (85.2%)
		(79.5%)	
Second trial	Speaking	10 (88.3%)	2 (16.7%)
	Nonspeaking	1 (3.8%)	25 (96.2%)
		(92.1%)	

The importance of the patient income variable deserves comment. Contrary to previous reports which would indicate that the personal characteristics associated with affluence are important in motivating people toward learning esophageal speech, it is our opinion that socioeconomic status per se has a weak clinical relationship to esophageal speech. Even though our data would indicate statistically that low income predicts success, we interpret this finding to mean that high income does not influence success and that other factors, particularly physical factors, are far more important. We note that the mean income of the eight patients excluded from analysis because of missing data on phonation duration was much lower than the rest of the nonspeaker group. It is our impression that if these patients could have been included in the analysis, the predictive power of this variable would still be significant although statistically weaker.

We have not compared these data with the work of others in the literature for several reasons. First, our data were from a prospectively studied group, whereas all studies with which we are familiar were based on retrospectively obtained information. Second, our subject population was heterogeneous, coming from private, indigent clinic, military, and veterans' facilities, and cannot be compared to, for example, an all-male, veteran patient group. Third, this technique of analysis has not been applied previously to predicting outcome of postlaryngectomy rehabilitation. We look forward to the results of future studies of a similar nature.

It appears to us that substantive changes have occurred in the selection of patients for treatment of

TABLE 4. RELATIONSHIP OF SPEECH ACQUISITION TO SITE OF CANCER

	Glottic & Supraglottic	*Pyriform Sinus*
Speakers	11 (33%)	1 (7%)
Nonspeakers	22 (67%)	13 (93%)

(Corrected $X^2 = 2.3$, $p = .13$)

laryngeal cancer. Today's laryngectomee is more likely to be older, have more advanced disease, and receive multimodality therapy than was the case in the past. Thus, fewer patients are able to learn esophageal speech. Identification of patients who would be unlikely to be able to learn esophageal speech could result in the early use of alternative forms of speech rehabilitation for this high-risk group. Thus, months of delay and frustration could be replaced by early communication. For the 40% whose cancer therapy is not curative and whose lives are enriched by effective interpersonal communication, such early identification would greatly enhance the quality of their remaining days.

REFERENCES

1. Hunt RB. Rehabilitation of the laryngectomee. Laryngoscope 1964; 74:382-95.

2. Snidecor JC. Some scientific foundations for voice restoration. Laryngoscope 1975; 85:640-7.

3. King PS, Lowlles ES, Peirson GA. Rehabilitation and adaptation of laryngectomy patients. Am J Phys Med 1968; 97: 192-203.

4. Gates GA, Ryan W, Cooper Jr JC, et al. Current status of laryngectomee rehabilitation: I. Results of therapy. Am J Otolaryngol 1982; 3:1-7.

5. Gates GA, Ryan W, Cantu E, Hearne E. Current status of laryngectomee rehabilitation: II. Causes of failure. Am J Otolaryngol 1982; 3:7-14.

PRIMARY VOCAL REHABILITATION USING THE BLOM-SINGER AND PANJE VOICE PROSTHESES

MICHAEL D. MAVES, MD RALEIGH E. LINGEMAN, MD

INDIANAPOLIS, INDIANA

Vocal rehabilitation by means of tracheoesophageal puncture and placement of either the Blom-Singer or Panje silicone prosthesis has become a standard method of speech production following total laryngectomy. The same technique has been employed primarily at the time of the laryngectomy by the Department of Otolaryngology-Head and Neck Surgery, Indiana University Medical Center, and our experience with 11 patients undergoing this technique forms the basis for this report. Of the ten patients available for evaluation, all have developed satisfactory prosthetic speech 2-12 weeks following total laryngectomy. Advantages of this technique include the utilization of standard laryngectomy without compromise of oncologic principles, elimination of a second procedure to place the tracheoesophageal puncture, elimination of the nasogastric tube, care in the pharyngeal closure to afford the maximum success of prosthetic speech production, and finally, the psychological boost. Limitations of the technique have been few but relate to limited voicing with postoperative radiotherapy and unrealistic patient expectations.

INTRODUCTION

Following total laryngectomy vocal rehabilitation by means of tracheoesophageal puncture and placement of either the Panje or Blom-Singer prosthesis has become a standard method of speech production with a high degree of success.[1-4] These two techniques, similar in concept and design, have offered new hope to many laryngectomees unable to use other means of communication and have found wide application. However, little has been written regarding the use of this technique primarily at the time of the ablative procedure. The purpose of this study was to evaluate the use of primary tracheoesophageal puncture as a means of vocal rehabilitation. A related phase of this investigation was to determine if alteration in the method of pharyngeal closure would have an effect on the incidence of pharyngoesophageal spasm in these prosthetic speakers.

SURGICAL TECHNIQUE

Primary tracheoesophageal puncture was performed following standard widefield laryngectomy or laryngopharyngectomy by creating a fistula in the superior midportion of the posterior tracheal wall. A finger is placed within the pharynx, exerting pressure on the party wall, while making an incision approximately 5 mm in length, 5-10 mm below the planned superior mucocutaneous junction of the stoma through the posterior tracheal wall into the esophagus. Once entrance into the esophagus has been made, the incision is gently dilated with a hemostat, and a 14 French Keofeed tube is introduced into the stomach and secured to the peristomal skin with an 0-silk suture.

Pharyngeal closure was altered in an attempt to decrease postoperative pharyngoesophageal spasm following the technique of Saunders.[5] A 36 or 38 French dilator was placed through the oral cavity into the pharynx for use as a "darner" or form to sew across. The mucosa and submucosa were then closed over this dilator in an interrupted fashion. The esophageal dilator, acting as a darner, allows the surgeon to detect gaps in the all-important first suture line. It also ensures that enough mucosa is present to prevent a tight pharynx. If one is unable to close the pharyngotomy defect with the 36 or 38 French dilator in place, then a myocutaneous flap or other augmentation should be used to reconstruct the pharynx. All closures were done in a T-shaped configuration. In no instance was an attempt made to close the pharyngeal musculature since it was suspected that traditional, tight, multilayered pharyngeal closures would increase the amount of scarring and lead to an increased incidence of pharyngoesophageal spasm.

In three preoperative irradiated cases, this same closure technique was used, but the suture line was reinforced with a pectoralis muscle flap in two cases and augmented with a pectoralis myocutaneous flap in another case.

Blenderized feedings were given through the fistula tube until the 10th to 14th postoperative day when oral alimentation was begun and the Keofeed tube was replaced with a 14 French silicone stent. Speech rehabilitation was initiated as early as the tenth postoperative day with voicing through the fistulous tract. Thereafter, fitting with either a Blom-Singer or Panje prosthesis was accomplished and standard instruction in the care of these appliances was begun.

RESULTS

Eleven patients undergoing total laryngectomy and primary tracheoesophageal puncture for T3 and T4 laryngeal and pyriform sinus neoplasms at the Indiana University Medical Center from July 1981 until April 1982 formed the basis for this report. Ten of these patients are available for evaluation. The unevaluable patient is currently still hospitalized and has been physically unable to begin voicing. Nine patients were male and all patients were in the sixth and seventh decades of life. Four patients underwent simultaneous radical neck dissection. Three patients received preoperative radiotherapy and the same number underwent postoperative irradiation.

All patients developed satisfactory, fluent, intelligible speech. The period of time from laryngectomy

---

From the Department of Otolaryngology-Head & Neck Surgery, Indiana University School of Medicine, Indianapolis.

Presented at the meeting of the American Laryngological Association, Palm Beach, Florida, May 1-2, 1982.

REPRINTS — Michael D. Maves, MD, Department of Otolaryngology-Head & Neck Surgery, 1100 W. Michigan Street, Indianapolis, IN 46223.

to the development of speech ranged from 2-12 weeks with an average of 5.2 weeks. If two patients requiring 12 weeks until voicing are eliminated, then the average time to voicing becomes 3.5 weeks.

Six patients were initially fitted with Panje prostheses and four with Blom-Singer. The choice of prosthesis type was based on the configuration of the stoma and final position of the tracheoesophageal fistula.

No difference in the eventual success of vocal rehabilitation was noted with patients undergoing either preoperative or postoperative radiotherapy. However, in two patients undergoing postoperative radiotherapy, voicing became limited because of peristomal reaction and pharyngeal edema.

Two patients, originally felt to be satisfactory prosthetic speakers, eventually used their prosthetic voice less. One of these individuals has a history of psychiatric illness and motivation tends to parallel his mood. Initial success was met with limited reception in another patient because of probable unrealistic preoperative expectations. There was one postoperative complication, a fistula in an unirradiated case. There was no evidence of pharyngoesophageal spasm.

DISCUSSION

Primary tracheoesophageal puncture has been found to be a procedure with favorable initial results. Standard wide-field laryngectomy or laryngopharyngectomy with no departure from established oncologic criteria may be performed. New techniques for approaching laryngeal neoplasms through subtotal laryngectomy have currently been under development and evaluation.[6] These techniques offer the hope of retention of limited laryngeal function and extension of traditional indications for conservation laryngeal surgery while maintaining the cure rates for laryngeal carcinoma now treated with total laryngectomy. However, further evaluation and follow-up are necessary before this can become a standard method of treatment. In the interim, primary tracheoesophageal puncture offers a single-stage method of prosthetic vocal rehabilitation with known cure rates.

Importantly, care can be given to the pharyngeal closure at the time of a laryngectomy. In our series, it was felt that by closing only the mucosa and submucosa we have allowed the wide myotomy of the pharyngeal constrictors which is present at the end of the laryngectomy to remain, and that this would result in a loose pharyngoesophageal segment less likely to spasm with air insufflation. In a large series of patients undergoing prosthetic vocal rehabilitation, Singer and Blom have noted an incidence of pharyngoesophageal spasm of 12% and postulate that it may even be higher.[7] Similar rates of pharyngoesophageal spasm have been noted by other investigators.[4,8,9] Although our initial results are encouraging, further investigation concerning variations of pharyngeal closure following laryngectomy and the role that such techniques play in the eventual production of pharyngoesophageal spasm merits further consideration.

By creating the tracheoesophageal fistula at the time of the ablative procedure, the puncture can be easily placed and a second operation, albeit a minor one, is avoided. The need for a nasogastric tube is also eliminated since feedings may begin via the tube in the fistula and this can be of considerable comfort to the patient who depends on central or enteral tube feeding for 10 to 14 days postoperatively.

Although vocal rehabilitation may begin as soon as 10 to 14 days postoperatively, this ideal was not always realized in our patient population. A patient with a postoperative fistula required a considerably longer interval to develop sustained effective voicing. In two of three patients undergoing postoperative radiotherapy some limited voicing was begun postoperatively only to decrease with radiotherapy because of pharyngeal edema and peristomal reaction. On the other hand, while postoperative radiation may limit voicing during radiotherapy, in no case was any long-term sequela apparent.

Finally, it must be emphasized that considerable psychological boost is given to both the patient and surgeon who realize that even in the face of total laryngectomy, efforts can be made at the time of the laryngectomy which will assist in postoperative vocalization. However, we have been careful to emphasize to our patients that the resultant voice will not be the same as their preoperative voice and that fluency will not come without diligent work and therapy. In one of our patients, unrealistic preoperative expectations led to disillusionment regarding tracheoesophageal speech and eventual decrease in the frequency of use, although he still wears his prosthesis. Considerable care in the selection of these patients is therefore required and one cannot yet advocate this as a universal standard technique to be applied to all laryngectomees. Lastly, it can be emphasized that in some of our patients initial efforts at esophageal speech were enhanced by the presence of the tracheoesophageal fistula. In fact, several patients have elected to proceed with education regarding esophageal speech and now use both methods of communication. One cannot regard this as a failure of tracheoesophageal speech; rather it reflects the interrelationship of these different modalities of postoperative vocal rehabilitation.

ACKNOWLEDGMENTS — The authors would like to recognize the invaluable assistance of James C. Shanks, PhD, and R. Edward Stone, PhD, who provided speech therapy for these patients, and Rhea Reynolds who typed the manuscript.

REFERENCES

1. Singer MI, Blom ED. An endoscopic technique for restoration of voice after laryngectomy. Ann Otol Rhinol Laryngol 1980; 89:529-33.

2. Panje WR. Prosthetic vocal rehabilitation following laryngectomy — the voice button. Ann Otol Rhinol Laryngol 1981; 90: 116-20.

3. Singer MI, Blom ED, Hamaker RC. Further experience with voice restoration after total laryngectomy. Ann Otol Rhinol Laryngol 1981; 90:498-502.

4. Panje WR, Van Demark D, McCabe BF. Voice button prosthesis rehabilitation of the laryngectomee — additional notes. Ann Otol Rhinol Laryngol 1981; 90:503-5.

5. Saunders WH. Techniques in laryngectomy to minimize postoperative complications and permit immediate feeding. Ann Otol Rhinol Laryngol 1963; 72:431-40.

6. Pearson BW. Subtotal laryngectomy. Laryngoscope 1981; 91:1904-11.

7. Singer MI, Blom ED. Selective myotomy for voice restoration after total laryngectomy. Arch Otolaryngol 1981; 107:670-3.

8. Donegan JO, Gluckman JL, Singh J. Limitations of the Blom-Singer technique for voice restoration. Ann Otol Rhinol Laryngol 1981; 90:495-7.

9. Wood BG, Rusnov MG, Tucker HM, Levine HL. Tracheoesophageal puncture for alaryngeal voice restoration. Ann Otol Rhinol Laryngol 1981; 90:492-4.

CHEMICAL MODULATION OF THE HYPOXIC FRACTION IN THE TREATMENT OF HEAD AND NECK CANCER

RALPH R. WEICHSELBAUM, MD
THOMAS J. ERVIN, MD DANIEL MILLER, MD
BOSTON, MASSACHUSETTS

Treatment of large squamous carcinomas of the head and neck often requires intensive or multidisciplinary treatment. Despite such aggressive measures, local recurrence is common. Possible reasons for such local failure are numerous. Hypoxic but viable tumor cells may be one means of resistance to radiotherapy and chemotherapy. If surgical removal cannot eliminate these cells, tumor regrowth may occur. Modulation of the hypoxic fraction is one means of potentially altering resistance to radiotherapy. Misonidazole, a radiosensitizer, has been thought to increase free radical formation in hypoxic cells in vitro thus increasing the radiosensitivity. This observation is discussed with reference to advanced head and neck cancer.

Cancer therapists, regardless of discipline, have as their goal the elimination of the last clonogenic tumor cell or at least a reduction of the tumor cell burden so that the natural body defenses may eliminate any cell with malignant potential. In individuals with head and neck cancer, adequate local control may cure a large proportion of these patients. However, large tumors (T4) have considerably lower local control rates than smaller (T1) lesions.[1] Explanations frequently offered for this fact are 1) a larger tumor cell burden in T4 lesions, 2) greater efficiency of repair of x-ray and/or drug damage, 3) the presence of hypoxic cells which may reduce the efficacy of both drug and x-ray treatments, and 4) inherent or induced cellular resistance to drugs and x-rays.[2,3]

Survival curve analysis, whether involving x-rays or chemotherapeutic agents, has proven important in the conceptual design of cytotoxic cancer therapy. Figure 1 shows an x-ray survival curve. A logarithmic plot of the surviving fraction is shown on the ordinate and dose in rad on the abscissa. It should be noted that survival cures for chemotherapeutic agents are graphed in a similar fashion with concentration of drug on the abscissa instead of dose in rad. The inverse of the slope of the straight line portion of an x-ray or drug survival curve is known as the D_o (radiosensitivity or chemosensitivity). The back-extrapolation of the slope to the ordinate is known as the $\bar{n}$ or extrapolation number and represents the ability of cells to accumulate and repair sublethal damage. Survival enhancement after x-ray treatment, as reflected in a recapitulation of the extrapolation number, indicates that cells repair sublethal x-ray damage and any chemotherapeutic agent or host factor which influences this process is of great importance.

Thomlinson and Gray,[4] after histologic examination of lung tumors, noted that cells more than 150 μm from a capillary were necrotic and surrounded by a rim of hypoxic cells. This observation may be of great importance to the clinical cancer therapist, since the cytotoxic action of ionizing radiation and some chemotherapeutic agents such as adriamycin or cyclophosphamide in biological matter is mediated by production of free radicals. Free radicals contain unpaired electrons which create the chemical reactions that lead to molecular lesions which produce damage to DNA. The major forms of this damage are DNA strand breaks and/or base damage. Thus, when bacterial or mammalian cells are exposed to hypoxia (an environment less capable of free radical production), radioresistance or chemoresistance occurs (Fig. 2). A generalization is that in in vitro or in vivo treatment systems, absence of oxygen will result in a *decreased* cytotoxic effect. Conversely, it should be noted that radiosensitivity of virtually all hypoxic biological systems can be significantly *enhanced* in the presence of oxygen. Although the radiation dose necessary to produce a given degree of cell killing may be different under various conditions, the shape of the survival cures are identical when they are in aerated or hypoxic conditions. As Figure 2 shows, the ratio of the doses to reach the same biological end-point under oxic or hypoxic conditions is the same at each level of survival. This ratio is called the oxygen-enhancement ratio (OER) and can be calculated as the ratio of D_o values for hypoxic and aerated cells.[5] Tumors containing large fractions of hypoxic cells will be resistant, possibly as much as by a factor of three, to ionizing radiation. A clinical corollary to this phenomenon would be that tumors containing a population of hypoxic cells may require a dose of irradiation which exceeds normal (ie, oxic) tissue tolerance for local control.

From the Joint Center for Radiation Therapy and Sidney Farber Cancer Institute, Harvard Medical School, Boston.
Presented at the meeting of the American Laryngological Association, Palm Beach, Florida, May 1-2, 1982.
REPRINTS — Ralph R. Weichselbaum, MD, Joint Center for Radiation Therapy, 50 Binney Street, Boston, MA 02115.

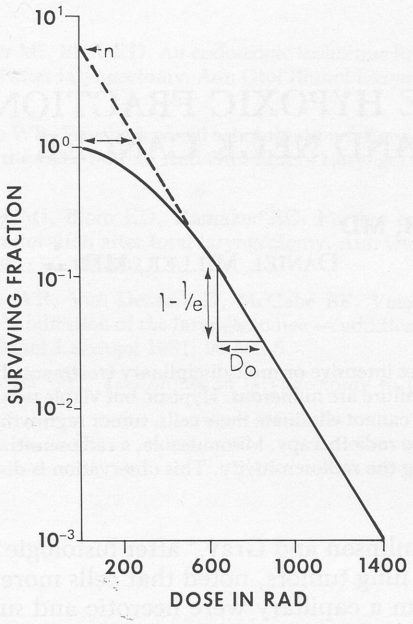

Fig. 1. Typical survival curve for mammalian tumor cells exposed to increasing doses of irradiation (or chemotherapy). Actual curve has initial "shoulder," and back-extrapolation of curve to ordinate (extrapolation number $\bar{n}$) is a measure of ability of treated cells to accumulate sublethal damage. Slope of curve (D_0) reflects sensitivity of cells to treatment.

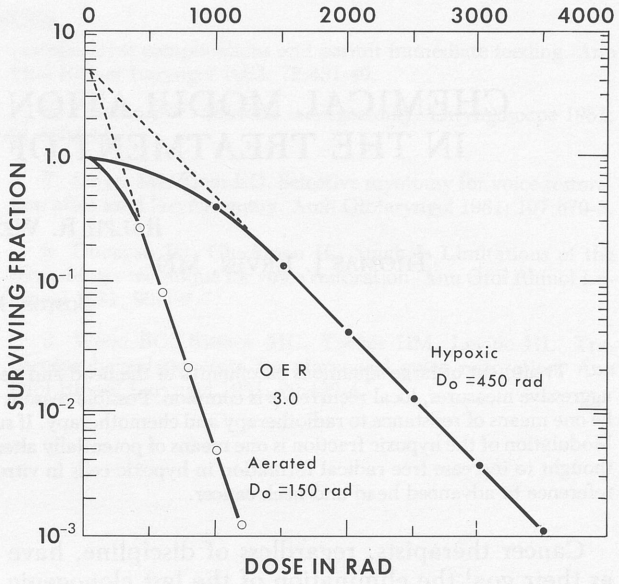

Fig. 2. Effect of hypoxia on cell survival following irradiation.

Several strategies have emerged by which hypoxia may be circumvented in radiotherapy. Although hyperbaric oxygen chambers have been employed with varying results, a more practical strategy has been the introduction into clinical radiotherapy of the nitroimidazoles as sensitizers of hypoxic cells.[6] These agents are electronic affinic compounds which have as their major mode of action the creation of free radicals in hypoxic cells. The prototype compound, metronidazole, a trichomonicide (Flagyl), was quickly followed by the development of misonidazole which is currently being investigated in clinical trials.[7] Figure 3 shows the effect of metronidazole in hypoxic cells in vitro. Note that the OER in the presence of metronidazole is decreased and the hypoxic cells are more like their well-oxygenated counterparts in their response to irradiation.[8] An increased cure rate in animals bearing tumors which contain a large hypoxic fraction of cells has been shown after the combined use of radiation and misonidazole.[9] Thus, it may be possible to enhance the therapeutic ratio in head and neck cancer with the employment of combinations of hypoxic cell, sensitizers and radiation therapy.

Rose and his colleagues[10] investigated the enhancement in tumor cell-kill which occurs when misonidazole is administered in combination with chemotherapeutic agents in animals bearing the Lewis lung carcinoma. Enhancement of melphalan cytotoxicity in tumors occurred when animals received misonidazole up to four hours before or one hour after melphalan. Enhancement was most marked with simultaneous administration (Fig. 4). Although misonidazole enhanced the response of intestine and bone marrow to melphalan treatment, enhancement ratios were considerably less than tumor enhancement ratios, resulting in a true therapeutic gain. Although the mechanism of potentiation of chemotherapeutic agents by the nitroimidazoles was unclear, Rose et al proposed that misonidazole might enhance melphalan activity by potentiating cytoxic action at the intracellular level by elaborating potentially toxic metabolites within the hypoxic tumor cells. These authors further suggested that these metabolites occur in concentrations insufficient to produce cytotoxicity by themselves, but which enhance the action of simultaneously delivered chemotherapy, perhaps through some electron affinic process.[10]

It is thus tempting to speculate that the nitroimidazoles originally investigated as radiation sensitizers may find use as chemosensitizers and that hypoxic cells originally thought to limit the effectiveness of radiation may alter the effectiveness of chemotherapy as well. Future clinical trials may include the employment of misonidazole with chemotherapy as well as during radiation itself.

In a previous study at the multidisciplinary Head and Neck Clinic at the Sidney Farber Cancer Institute and the Joint Center for Radiation Therapy, patients presenting with advanced stage III and stage IV squamous carcinoma of the head and neck were treated with high dose methotrexate (3-7 g/m^2 dose, with leucovorin rescue) given weekly for one month prior to definitive radiation and/or surgery. Six of 11 patients who showed a significant response (greater than 50% reduction of tumor to high-dose methotrexate) are alive and well at three years as opposed to 1 of 10 patients who showed less than a

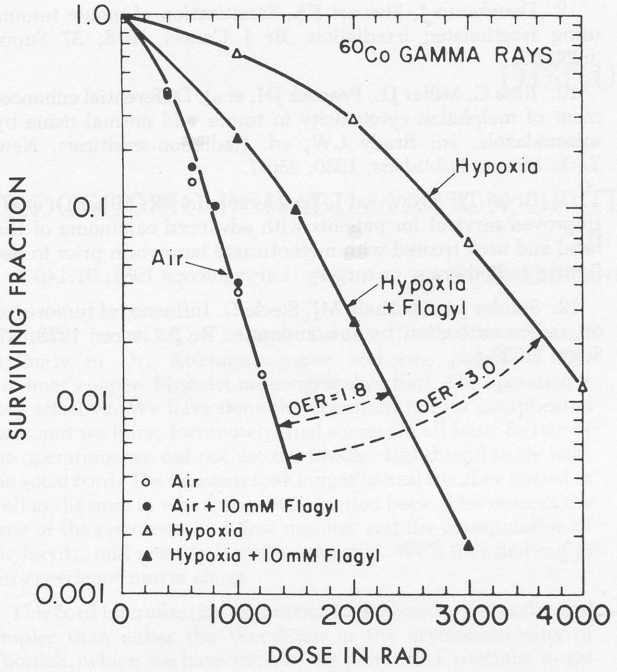

Fig. 3. Effect of misonidazole (Flagyl) on hypoxic inhibition of cell death following irradiation.

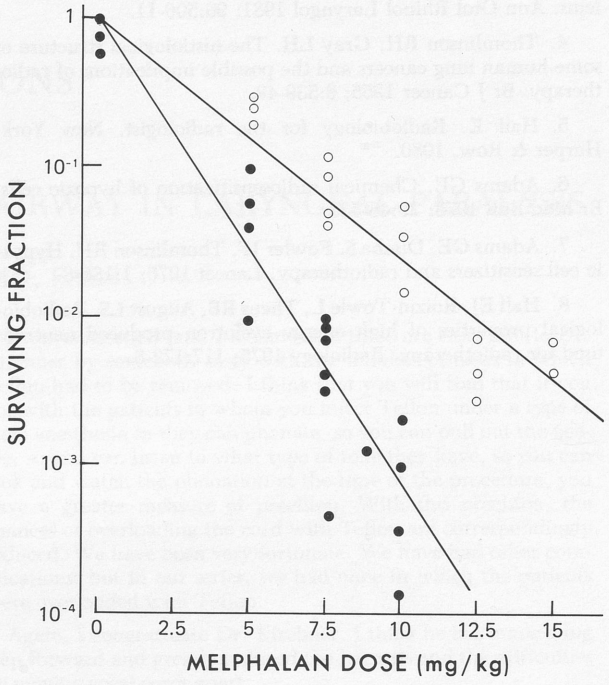

Fig. 4. Effect of misonidazole on cell survival after melphalan treatment.

50% reduction in tumor size.[11] An obvious interpretation is that an enhancement in cytoreduction was achieved by the chemotherapy and that the superiority in survival was solely due to a significant decrement in tumor cell burden. The fact that both the responding and nonresponding groups had the same incidence of distant metastases, however, suggests that the log-kill in the responding group might not have been significantly greater than in the nonresponding group. It is possible that the cytoreduction in the responding group was enough only to effect local control. This may have occurred by decreasing the local tumor burden or decreasing the local hypoxic cell population, thus making radiation surgery more effective. In explaining the effect of cytoreduction, several interesting experimental observations may be relevant. For example, several authors have shown experimentally that cells in small tumors are more sensitive to cytotoxic agents than those in large tumors. Also, in animals, pulmonary tumors as small as 20 mm in volume contain substantial numbers of hypoxic, presumably resistant, cells.[9,12] Thus, pre-definitive-treatment chemotherapy may have had the effect of reducing the hypoxic fraction by reducing the gross size of the tumor and rendered radiotherapy and presumably surgery more effective by size reduction as well.

The above principles have important implications for the surgical oncologist, since surgery may be curative by itself or in combination with chemotherapy and radiotherapy. Sound principles of oncologic management should be common to all disciplines involved in the care of head and neck cancer patients. For example, surgical debulking has been widely misinterpreted, but should take the form of complete excision of tumor deposits leaving only microscopic disease behind. Thus, cytoreductive surgery may be beneficial, not only because it reduces the total number of tumor cells, but may also reduce the number of hypoxic cells, leaving smaller numbers of well-oxygenated cells to be treated by chemotherapy and radiotherapy.

Tumor cell hypoxia is an example of only one problem which is common to all oncologic disciplines and demonstrates the necessity for combined clinical approaches to head and neck cancer. Other physiologic differences between tumors and normal tissues should be exploited. Potentiators of chemotherapy and radiotherapy and protectors of normal tissues which selectively take advantage of such differences should be explored. The nitroimidizoles and possibly hyperthermia are examples of such investigative efforts. With surgery, such interdigitation of disciplines might improve the therapeutic results for advanced squamous carcinoma of the head and neck.

REFERENCES

1. Fletcher G. Textbook of radiotherapy. Philadelphia: Lea & Febiger, 1980; 229-46.

2. Weichselbaum RR, Schmidt A, Little JB. Cellular factors influencing the radiocurability of human malignant tumors. Br J Cancer 1982; 45:10-6.

3. Ervin T, Karp D, Weichselbaum RR, Posner MR, Fabian RL, Miller D. The role of chemotherapy in the multidisciplinary approach to advanced head and neck cancer: potentials and prob-

lems. Ann Otol Rhinol Laryngol 1981; 90:506-11.

4. Thomlinson RH, Gray LH. The histiological structure of some human lung cancers and the possible implications of radiotherapy. Br J Cancer 1955; 9:539-49.

5. Hall E. Radiobiology for the radiologist. New York: Harper & Row, 1980.

6. Adams GE. Chemical radiosensitization of hypoxic cells. Br Med Bull 1973; 29:48-53.

7. Adams GE, Dische S, Fowler JF, Thomlinson RH. Hypoxic cell sensitizers and radiotherapy. Lancet 1976; 1:186-8.

8. Hall EJ, Roizin-Towle L, Theus RB, August LS. Radiobiological properties of high energy cyclotron produced neutrons used for radiotherapy. Radiology 1975; 117:173-8.

9. Denekamp J, Stewart FA. Sensitization of mouse tumors using fractionated irradiation. Br J Cancer 1978; 37 Suppl 3:259-63.

10. Rose C, Millar JL, Peacock JH, et al. Differential enhancement of melphalan cytotoxicity in tumor and normal tissue by mizonidazole. In: Brady LW, ed. Radiation-sensitizers. New York: Masson Publishers, 1980; 250-7.

11. Ervin TJ, Kirkwood J, Weichselbaum RR, Miller D, et al. Improved survival for patients with advanced carcinoma of the head and neck treated with methotrexate leucovorin prior to definitive radiotherapy or surgery. Laryngoscope 1981; 91:140-5.

12. Stanley JA, Peckham MJ, Steele G. Influence of tumor-size on radiosensitization by mizonidazole. Br J Cancer 1978; 37 Suppl 3:220-4.

SINGLE-STAGE CORRECTION OF THE TWISTED NOSE

M. EUGENE TARDY, MD TOM LAWRENCE, MD

CHICAGO, ILLINOIS

Satisfactory correction of the twisted nose eludes the experienced surgeon and resident physician alike. Undiagnosed deformities, coupled with unpredictable healing occasioned by intranasal scarring and bony irregularities, may further complicate a controlled repair. Since major septal abnormalities co-exist with asymmetries of the osseocartilaginous vault in most twisted noses, some surgeons advocate a two-stage approach, accomplishing septoplasty initially, followed by external nasal reconstruction at a later date. Precisely because these abnormalities are intimately related and interdependent, requiring correction of each to satisfactorily correct the whole, a one-stage reconstruction of the functional and aesthetic aspects of the crooked nose is advocated.

Manuscript not available

From the Division of Head and Neck Plastic Surgery, Department of Otolaryngology, University of Illinois Medical Center, and St. Joseph Hospital, Chicago.

Presented at the meeting of the American Laryngological Association, Palm Beach, Florida, May 1-2, 1982.

DISCUSSIONS

ENDOSCOPIC REHABILITATION OF THE AIRWAY IN LARYNGEAL PARALYSIS (p. 46)

F. R. KIRCHNER, MD, FACS

ROBERT LEWY, MD (Chicago): I would like to address myself explicitly to Dr. Kirchner's paper and two phases of Dr. Kirchner's paper. First, let me congratulate him. The operation is very effective. We have done the operation in four complicated cases and we have, fortunately, had success in all four. In two of the operations we did not use the needles and thread to tie back the vocal cord. The incisions took longer to heal but they healed as well as the ones in which the cord was tied back. This reduces the time of the operation by a few minutes and the manipulation of the larynx, and possibly that's worthwhile. We'll find that out as our experience moves along.

This cord lateralization operation, in our hands, was easier and simpler than either the Woodman or the arytenoidectomy of Thornell, which we have tried in the past. If we continue to get this kind of result, I will be devoted to it.

I was concerned (and I assume that these are cases sent to Dr. Kirchner by somebody else) with the number of cases in which Teflon had to be removed. I think that you will find that if you do, with the patients in whom you inject Teflon under a type of local anesthesia so they can phonate, so you can pull out the needle, so you can listen to what type of tone they have, so you can look and watch the phonation at the time of the procedure, you have a greater measure of precision. With this precision, the chances of overloading the cord with Teflon are correspondingly reduced. We have been very fortunate. We have had other complications, but in our series, we had none in which the patients were overloaded with Teflon.

Again, I congratulate Dr. Kirchner. I think he has made a big step forward and greatly reduced the hazards and the difficulties on moving vocal cords apart.

DIAGNOSIS AND CONSERVATIVE SURGICAL MANAGEMENT OF CHONDROSARCOMA OF THE LARYNX (p. 53)

J. N. HICKS, MD; E. E. WALKER, MD; E. E. MOOR, MD

CHONDROSARCOMA OF THE LARYNX: EXCISION OF MASSIVE RECURRENCE (p. 56)

F. E. LEJEUNE, JR, MD, FACS; H. W. VAN HORN, III, MD; G. H. FARR, MD

EXTENDED TRANSANTRAL APPROACH TO PTERYGOMAXILLARY TUMORS (p. 59)

C. J. KRAUSE, MD; S. R. BAKER, MD

JOHNSON PUTNEY, MD (Charleston, SC): As it has been pointed out, no one individual has a great deal of experience with this type of tumor, but I would like to relate a couple of points that I have had in my experience. The chondromas have presented no problem. Excision always included a portion of the cricoid cartilage, when that was involved, or a portion of the thyroid cartilage. The results have been universally good, although follow-up of 14 years may not be sufficient. In the chondrosarcomas, the point I would like to make is that these recur after many years. We've had two recurrences after eight years. The last case, one of 17 years, had a massive chondrosarcoma so that the entire larynx was removed. I certainly agree with the conservative treatment of these lesions, but I would recommend that they be followed very thoroughly for a long period of time because of the likelihood of recurrence. Chondrosarcoma may involve other portions of the larynx other than the actual tumor which was removed at the original surgery.

CARTILAGINOUS TUMORS OF LARYNX

Site	*Size (cm)*	*Type*	*Treatment*	*Result*
Cricoid	1.0	Chondroma	Excision	L/W-6 yr
Thyroid	0.5	Chondroma	Excision	L/W-14 yr
Thyroid	3.5	Chondroma	Excision	Deceased (Hodgkins)
Cricoid	2.0	Chondrosarc.	Excision	Rec 8 yr
Cricoid	3.0	Chondrosarc.	Excision	Rec 8 yr
Cricoid	Entire post. plate	Chondrosarc.	Laryngectomy	L/W-17 yr

L/W - Living/well; Rec - Recurrence.

WILLIAM MONTGOMERY, MD (Boston): I enjoyed these last two papers and would like to make a couple of points. One is that in my experience with a fairly large number of chondromas and chondrosarcomas, I have yet to meet a pathologist who can differentiate by tissue section alone a chondroma from a chondrosarcoma without the patient's record. I agree with the statement that these should be treated aggressively and that one should consider them chrondrosarcomas regardless of whether the pathologist diagnoses one as chondroma or chondrosarcoma. The external operation is the treatment of choice, removing the entire tumor with the surrounding normal cricoid. This offers the best chance for cure. These tumors can recur after 15 or 20 years in spite of repeated surgery. When the larynx is rendered incompetent by disease, a total laryngectomy is indicated.

LUIZ DEMOURA, MD (Mount Clemons, Mich): We do have a case exactly like the one presented here; we removed three fourths of the larynx and could preserve the vocal cord. The only difference is that this patient has a history of 30 years of laryngeal problems, was irradiated 3 years ago on the neck area because of histiocystic lymphoma. The questions I would like to ask are: Is there any relationship between radiation and chondrosarcoma or chondroma? Did this patient have chondroma for 30 years, or did he have chondrosarcoma for 30 years? Did the radiation change the outcome of the case?

JULIUS N. HICKS, MD (closing): In preparing this paper, I did not obtain a meaningful article on the x-ray treatment of chondrosarcoma of the larynx.

PRIMARY MANAGEMENT OF LARYNGEAL TRAUMA (p. 63)

S. D. SCHAEFER, MD

GABRIEL F. TUCKER, JR, MD (Chicago): I very much enjoyed Dr. Schaefer's paper. It has been my thought during the last several years that we are not seeing laryngeal trauma in patients who are wearing either lap belts or shoulder belts. I wonder if Dr. Schaefer could tell us, with his large series, if any of his patients with blunt trauma were so restrained.

STEVEN D. SCHAEFER, MD (closing): I really do not know of anyone that was restrained. I feel the same way about the need for lap belts and restraints, so I would hope that no one was injured while wearing these devices. The interesting thing I noted again was that personal assaults really dominate in the last four years of the study, whereas trauma from automobile accidents was by far the largest mechanism of injury in the first 13 years of the study.

ASSESSMENT OF INTUBATION IN CROUP AND EPIGLOTTITIS (p. 67)

J. J. ZULLIGER, MD; D. E. SCHULLER, MD; T. P. BEACH, MD; J. P. GARVIN, MD; H. G. BIRCK, MD; J. E. FRANK

TREATMENT OF SEVERE SUBGLOTTIC STENOSIS WITHOUT TRACHEOTOMY
A PRELIMINARY REPORT (p. 71)

L. D. HOLINGER, MD

GABRIEL F. TUCKER, MD (Chicago): I enjoyed both of these papers, but I couldn't help but think about the material in Dr. Holinger's last slide about the histopathologic classification of subglottic stenosis as I listened to the first presentation. I think we have to be sure, in listening to the first paper, that what is called "infant croup" is really "croup," and I have a serious question when I see a 6-month-old baby. It was Dr. Holinger, Sr, who pointed out that most subglottic stenoses are not even diagnosed until 6 or 12 months of age. So the question I have here is, the small child who is supposedly croupy who doesn't respond well to intubation, maybe he really indeed has some underlying congenital abnormality which is presenting as croup, but this may not have been a normal larynx to begin with.

CHARLES D. BLUESTONE, MD (Pittsburgh): I would like to also congratulate the two presenters. I think this is very important information for us who care for babies with these problems. I would like to re-emphasize Dr. Tucker's comments that when any patient is intubated, preferably in the operating room rather than the Intensive Care Unit (ICU) or Emergency Room, an otolaryngologist should inspect the larynx to rule out the possibility of a concurrent congenital subglottic stenosis in infants who have so-called croup in the first year of life. I think that [what] Dr. Benjamin has called this "atypical croup" is frequently [caused by] a congenital anomaly.

My comment is that I think the work at Columbus Children's Hospital confirms the way we treat patients at the Children's Hospital of Pittsburgh, where we also use intubation for epiglottitis which has a known natural history and a known etiology, ie, *Hemophilus influenzae*. But in laryngotracheobronchitis, we never know from season to season what kind of viruses or bacteria are involved, and, therefore, for patients who fail medical management — eg, racemic epinephrine, hydrocortisone, humidification, hydration, and so forth — instead of resorting to intubation, we still advocate tracheotomy. The reason is, we have no idea how long the patient will be intubated. As a matter of fact, if you look at the data just presented, many of the patients had "prolonged" intubation in the ICU so that the intensive care treatment of an intubated patient who has croup, which I consider laryngotracheobronchitis or laryngotracheitis, was much longer than that for epiglottitis. In addition, there was a high incidence of subglottic stenosis which Dr. Holinger now tells us is extremely difficult to manage. I would like to ask him to comment on the fact that instead of saying these patients are "at high risk" and "need special care," that these children really need tracheotomy to reduce the number of days in the ICU and to prevent subglottic stenosis.

HOWARD G. SMITH, MD (Boston): I enjoyed both presentations and I congratulate the speakers. Those of us at the Children's Hospital in Boston, Dr. Healy and my other associates, would echo what Dr. Bluestone has just said about the treatment of croup. We have found an increasing incidence of bacterial involvement of the subglottic area and the trachea in patients who have prolonged problems with laryngotracheobronchitis. This is a feature of the disease which is not often emphasized in the literature.

The other comment that I would make concerns the rather high incidence of spontaneous extubation or self-extubation reported by Dr. Zulliger. This represents a serious problem for any unit which is managing intubated pediatric patients. This is particularly true for patients with epiglottitis in whom an unexpected extubation would necessitate an urgent reintubation, often under less than ideal circumstances. Intubated patients require appropriate sedation and at times gentle restraint. We prefer that the nasoendotracheal or endotracheal tubes not be connected to other tubes providing humidified air or oxygen. The use of mist tents can minimize the tendency for extubations caused by patient movement.

I would also recommend that an otolaryngologist be involved in the intubation of children with epiglottitis or croup. A careful examination of the airway at this time is often invaluable for planning subsequent therapy. Telescopic and flexible fiberoptic visualization of the airway may help minimize trauma to the subglottic area during intubation.

HERBERT DEDO, MD (San Francisco): For removal of subglottic swelling with a laser, Pilling has made for me a laryngoscope with a side tube adjacent to the light carrier on the left side that the anesthesiologist can use with a Sanders ventilating device to ventilate the patient. I don't think it's prudent to do this with papillomas because of the risk of blowing papilloma virus or particles out in the periphery of the lung, where they are incurable and lethal if followed long enough. Even though you can ventilate a patient using the Sanders ventilator, or as was done with a high level of anesthetic gases in the hypopharynx, I feel it is safer to go ahead and do the tracheotomy. Patients have enough of a problem with postoperative edema, even after laser removal of this subglottic swelling, and several have developed a granuloma postoperatively. A repeat direct laryngoscopy should be done automatically in two months to check for a subglottic granuloma and remove it, if present. If one is removed, a following direct laryngoscopy should again be done in two months.

I think the paper by Dr. Zulliger emphasizes the importance of using the smallest possible endotracheal tube with these patients — not the largest one you can get in. At our institution we have this rule that was started by Dr. Gregory, an anesthesiologist, (some anesthestiologists refer to it as the Gregory Rule): It is all right to use an endotracheal tube for epiglottitis or even croup if you can have an endotracheal tube which gives an adequate airway, but which allows an audible air leak around the tube at 15 cm of air pressure when the patient is ventilated with the bag. As a practical matter, with a small infant it is difficult to obtain an adequate airway through an endotracheal tube and still have that air leak around it. Our experience has been that we can use smaller endotracheal tubes than the sizes [selected as] given above and successfully ventilate pediatric patients.

We have found that in a neonate up to 1 year, we can ventilate with a 2.5-mm ID tube; from 1-5 years a 3-mm; from 5-10 a 3.5-mm tube; adolescent and adult female 4-mm (22F); adult male 4.5-mm (24F). The basic problem is that anesthesiologists, like ear, nose and throat doctors, want to put in the largest tube possible rather than the smallest. Incidentally, we stress that a tracheotomy tube also needs to be the smallest you can ventilate and suction through and not the largest.

JOHN J. ZULLIGER, MD (closing): In regard to Dr. Tucker's suggestion that some of these stenosis patients possibly may have had pre-existing or congenital stenosis, these patients were carefully reviewed as was described in the presentation. There was no history in any of these patients of any pre-existing upper respiratory complaints as well. All nine of these patients who developed stenosis presented with a classic upper respiratory infection prodrome and laboratory studies and febrile courses compatible with acute laryngotracheal bronchitis or croup. In response to Dr. Bluestone's suggestion that this data might suggest that tracheotomy would be the more optimal treatment of those patients needing respiratory support under one year of age, in our combined experience over the last 15 years, 92% of the croup patients intubated have done so without any complications whatsoever. Now I can't stress enough that an 8% incidence of subglottic stenosis, or even a 1% incidence, is too high. But in this present study, I think we have identified those factors which can be rectified, and it is hoped that by rigidly adhering to the above-outlined management schema, that this incidence of stenosis will be dramatically reduced. As far as Dr. Smith's very good suggestion about the importance of nursing care because of the unacceptable high incidence of self-extubation and tube occlusions, I can't echo these sentiments enough as well, and this goes further to stress the importance of excellent nursing care, humidification, and suctioning.

LAUREN HOLINGER, MD (closing): I thank the discussants of my paper and first would like to comment on Dr. Zullinger's paper to reinforce the comments of previous discussants. In 1976 we reviewed 158 cases of subglottic stenosis in infants and children and found that of the 115 congenital ones, 34% presented with recurrent or persistent episodes of croup ("atypical croup" as Dr. Bruce Benjamin says). Atypical croup must, therefore, be investigated endoscopically to rule out underlying airway pathology. These cases, furthermore, have great potential for using the laser to avoid either intubation or tracheotomy. If the surgeon will begin to think of emergent airway situations (due to soft tissue narrowing in the subglottic area) in terms of avoiding instrumenting the larynx and using the laser instead, perhaps many tracheotomies can be avoided, and safely.

I must take issue with Dr. Herbert Dedo's comment about it being better, or perhaps safer, to put a tracheotomy in these children when using the laser. The purpose of this technique is to advance the sophistication and improve the management of these patients one degree by avoiding tracheotomy entirely. Certainly the surgeon can't just use the laser and then discharge the patient. They must be followed very carefully. High humidity, careful observation and repeat endoscopy (3-6 days later, as the eschar forms and enlarges) are most important. Patients who come from some distance away will probably have to stay in the hospital or very close by for a prolonged period of time.

One final comment: I agree that this insufflation technique, or jet technique, should probably not be considered for patients with papillomas because of the possibility of seeding the lungs.

LARYNGEAL PARALYSIS IN CHILDREN: A LONG-TERM RETROSPECTIVE STUDY (p. 81)

S. R. COHEN, MD; K. A. GELLER, MD; J. W. BIRNS, MD; J. W. THOMPSON, MD

INFANT TRACHEOTOMY (p. 77)

C. R. GERSON, MD; G. F. TUCKER, JR, MD

HERBERT BIRCK, MD (Columbus): To your paper, Dr. Geller, I would have to ask one question only. Why not combine in Arnold-Chiari (which is a clear-cut case of bilateral, irreversible vocal cord paralysis) the arytenoidectomy with intubation? We reported on that six or seven years ago.

To the Gerson-Tucker paper: if we confine it to the title, neonatal, which means premie and two weeks after birth, I would have the following remarks. As to technique, in this day and age where we think about the beauty of the human being, why not do a horizontal incision instead of a vertical one for the tracheotomy? We know vertical incisions create, in some patients, quite a bit of scarring.

To make it easier to get to the trachea, we routinely excise the subcutaneous fat pad which is right in the incision area. This gives better healing in the end, a nicer scar and also a shorter distance from skin to trachea. It is very helpful.

In my experience of 20 years in the field of pediatric ENT, I have yet to see, in the neonate or premie, an isthmus of the thyroid which I would have to divide. It should be known that congenitally the thyroid is descending from the tongue, and two weeks after birth, if we are confining our tracheotomies to this age group, it hasn't arrived over the first and second ring. I enjoyed both papers.

BLAIR FEARON, MD (Toronto): I was especially interested in both of these very well-presented papers, and, in particular, the paper by Drs. Tucker and Gerson. I highly disagree with Dr. Birck's statement that a vertical incision causes a greater scar than the horizontal incision — to the contrary, in fact. I do agree with him that it is not necessary to transect the thyroid isthmus. Fifteen years or so ago, at a meeting of this association in fact, we reported that babies even under 1,000 g could be tracheotomized successfully. We did the tracheotomy with a specially designed bronchoscope in place and made the incision in the trachea even lower than Dr. Tucker described without creating a problem as a consequence. We still prefer the Holinger metal tracheotomy tubes with our own modification of the inner tube designed to accept anesthetic connections. We do not divide the thyroid isthmus. We make a small fenestra in the trachea for the tracheotomy tube. We think that with a bronchoscope in place, employing a small vertical skin incision and using small ribbon retractors, the operation can be done quickly, safely and without significant complications. However, Dr. Birck's results in his cases are good and so that one can't be too condemnatory. I did enjoy both of these papers greatly.

SEYMOUR R. COHEN, MD (Los Angeles): I'd like to make some remarks on the paper on tracheotomy in the neonate by Dr. Tucker and associate. It is difficult, and hopefully not insulting, to tell surgeons how to do one of the oldest operations. If a surgeon is comfortable, has few if any complications, and has good end-results, he should continue to use his own techniques. In an infant with a bronchoscope in place, we rarely see let alone divide the thyroid isthmus. If this becomes necessary we consider ourselves too high. The Jacksons taught that one should not be too high nor too low, but just right. In neonates, newborns up to 28 days of age, tracheotomy is not a difficult operation when the airway is controlled with a bronchoscope. We always do our tracheotomy surgery with a transverse skin incision, midline dissection down to the trachea, and a transverse incision between the cartilage rings to insert the tube. We do not use stay sutures in the trachea but sew the tracheotomy tube to the skin to prevent accidental extrusion. We do about two to three tracheotomies a month in neonates, rarely see complications, and have had no deaths for many years.

CHARLES D. BLUESTONE, MD (Pittsburgh): First I would like to congratulate both presenters. They were very interesting papers by both groups and it stimulates a lot of interest in all of us who take care of these babies. I would like to make several comments. One is that we have had a great deal of experience with infants with the Arnold-Chiari syndrome who have had bilateral vocal cord paralysis and require an endotracheal intubation followed by a shunt, or if the shunt is already in and blocked, then it should be unblocked as soon as possible. A tracheostomy is usually not required in most babies. I would not advise it unless the vocal cords remain paralyzed and I certainly would not do an arytenoidectomy. This brings me to the next question that I would like to ask Dr. Cohen, who is the senior author of the paper. For congenital idiopathic vocal cord paralysis, what are his indications for doing laryngeal reconstructive surgery? In 20 years Dr. Stool and I have never had to do one of these operations for this condition, either arytenoidectomy or the Harvey Tucker procedure (which we have not performed in any children). I would like to know what his indications are because we have not followed a child who has required such a procedure. We have been able to extubate all of our babies — it may take us two or three years in an occasional case, but they are all extubated. My next comment concerns the type of skin incision. When Dr. Stool came to the Children's Hospital of Pittsburgh in 1975 we had a conflict over the type of skin incision to use. I think the vertical incision is correct because I had learned from Dr. Paul Holinger, my teacher, that the vertical incision was better. Dr. Stool had always used the horizontal incision. After seven years together with each of us using a different skin incision, I have not seen any substantial difference in the complication rate such as stomal granulations, or in the appearance of the scar. Of course, we both use a very small skin incision.

KENNETH A. GELLER, MD (closing): Thank you very much for your comments on the papers. Dr. Birck, with the patients with Arnold-Chiari malformation, the main point we made was that most of the time we do not need to do a tracheotomy on these patients. Most of them will recover vocal cord mobility with shunting procedures. However, should the shunt procedure not resolve the problem, which does occasionally happen, then rather than intubating the patient for a prolonged period of time and risking subglottic stenosis, we do a tracheotomy and continue to follow them. Most of the time, as they get older, they will resolve and can be extubated.

Dr. Bluestone, concerning the vocal cord paralysis: we haven't done any Tucker procedures. We have done five arytenoidectomies. The arytenoidectomies were done on patients at the age of

approximately four years. These were in children who have vocal cord paralysis who have been followed for a long period of time and have not resolved. They still have a tracheotomy and they are ready to go to school. This is in bilateral cord paralysis. We felt that after this period of time the chances of recovery are small and they will probably not recover an adequate airway without an arytenoidectomy.

GABRIEL F. TUCKER, JR, MD (closing): First of all, let me agree, it may be inappropriate for us to have gone step-by-step, but these are tricks which have worked for us and we wanted to share them; we certainly weren't trying to *tell* anybody how to do anything. I don't think I'll ever convince Dr. Birck about vertical versus horizontal. This is not a plastic procedure. This is not a procedure which is to be associated with a primary closure. We're not doing exploratory tracheotomies where we incise the trachea, look around, and make a primary closure on the way out. These, whether they are vertical or horizontal, all heal secondarily like an umbilicus, so I don't think the plastic argument applies to the vertical versus horizontal. I think Dr. Cohen, Dr. Fearon and I are talking about a little difference in technique. The need for the isthmus, the hooks, I agree. If the procedure is not done over a bronchoscope, but is done over an endotracheal tube, you have a lot more to lift forward. You don't have the need for the hook. On the other hand, I think it was Dr. Fearon who started me worrying about hooks because not only can they tear cartilage, but what is really more annoying is, if you relax your tension a little, they disengage. One of the things that wasn't mentioned about the hook suture is that you can relax it, lift up and down and it stays there; it's really a very gentle approach. I have no experience with Dr. Birck's idea of trying to resect the pretracheal fat, but maybe I'm thinking of a different bunch of neonates. These are scrawny little 800-1200 g babies whose fat isn't something that is a problem.

LARYNGEAL PAPILLOMA: RESULTS OF TREATMENT WITH THE CO_2 LASER AND PODOPHYLLUM (p. 89)

H. H. DEDO, MD; R. K. JACKLER, MD

LEUKOCYTE INTERFERON IN PATIENTS WITH JUVENILE LARYNGEAL PAPILLOMATOSIS (p. 95)

H. GOEPFERT, MD; R. B. SESSIONS, MD; J. U. GUTTERMAN, MD; A. CANGIR, MD; W. J. DICHTEL, MD; M. SULEK, MD

STUART STRONG, MD (Boston): I am pleased to have this opportunity to discuss these two superb papers. I am indebted to the authors for sending me a copy of their manuscripts ahead of time so that I had the opportunity of reading them in toto. Many points have been brought up so I won't be able to address myself to more than a few of them. First, the points in the Drs. Jackler and Dedo paper. Their experience has paralleled our experience in Boston very closely. One point is very clear — that the disease is a diathesis involving many of the mucous membranes of the upper and lower airways. It is ubiquitous in the nose, nasopharynx, larynx, tracheobronchial tree and lung parenchyma. It affects all ages. I think "laryngeal papillomas" is not a very good term for this disease. The name that we have used for eight years is recurrent respiratory papillomatosis (RRP). I think that just about says it all. Remission is a topic that we need to talk about because, unless we know how long the remission is, it doesn't mean very much. I think a remission without any visible evidence of disease for less than a year is merely encouraging. Recurrences can occur at any time — 1 year, 4 years — we've had documentation of one recurrence after 19 years of apparent total freedom from the disease. I think that all we can hope for is a life-long remission because a cure is not likely to appear in the foreseeable future. I'm fascinated by three malignancies: we've had four cases in previously nonirradiated patients. One was squamous cell; the patient was treated by irradiation. The tumor has vanished but he still produces papillomas. The other three were verrucous carcinoma and they were treated by endoscopic excision using the CO_2 laser. All of our four patients were smokers. I would like to ask Dr. Jackler if the three patients that developed malignant degeneration were smokers or not. If they are, it should not surprise us at all. I really wonder about the value of podophyllum. I really don't think it is of any value. We tried it in Boston and the only thing we accomplished was some stomachache in a few children where it spilled over into the hypopharynx and they swallowed it! I don't think this report demonstrated the efficacy of podophyllum.

I enjoyed the presentation of Dr. Goepfert and colleagues very much. I think this is a very necessary study upon which they have embarked. We obviously need an effective adjuvant therapy. We have tried a transfer factor; out of nine patients we made two much worse. We have tried 5FU as a topical agent, and in summary I would say that it had a very profound effect initially, but after eight months the patients all broke through and now it is the turn of interferon. Early anecdotal experience suggests that it is effective. I am just interested in the complete responders. If we don't get complete response, I think we should move on to the next adjuvant therapy. I noted that three of the responses have been sustained but no mention is made of how long. Partial responses, I think, are of no significance. They just demonstrate the biology and natural history of the disease. Dr. Brian McCabe from Iowa was sorry he couldn't be here because he wanted to discuss these papers. He called me yesterday to ask me to pass on his experience with a study that has been ongoing for six months: 11 children between the ages of 2 and 9 have been treated with the New York Blood Center interferon, 3 million units three times a week intramuscularly. Four are free of disease after 3 and up to 6 months; seven are improving. Bear in mind, however, that this study has been ongoing for 6 months. I offer my congratulations to the authors; I think they are doing something that is very important and very useful and I encourage them to continue. But I think we should all be cautious about drawing any conclusions concerning the efficacy of podophyllum or interferon on the basis of results reported so far. I'm not a pessimist, but I find it hard to be anything other than very cautious about what the outcome of these medications will be in the future.

STEVEN SCHAEFER, MD (Dallas): Have you looked at the ultrastructural effects?

ROBERT JACKLER, MD (San Francisco): We agree with Dr. Strong's comments about remission. This is a disorder which is not really cured by any known therapy, rather it is controlled with varying degrees of success. We do hope that an effective agent to influence either viral growth or alter the host-papilloma relationship will eventually be developed. As far as our three patients with malignancies, to the best of my recollection, all three were smokers in their 50s and 60s. Concerning the use of podophyllum, we have no strong scientific evidence of its efficacy, although it

has long been used on skin and perineal warts with some success. The main reason we use it, according to Dr. Dedo, is that it simply makes him feel better to do a little something more for this often very frustrating problem. We have not seen nausea or abominal discomfort following its use; perhaps this is because we use just one drop on a Q-Tip applied to the raw surfaces only.

ROY B. SESSIONS, MD (Houston): In response to the latter of the two questions, we have collected tissue from each particular patient on each endoscopy which will ultimately reflect the running histologic tabloid of these cases. We have not yet done any ultrastructural study. The light microscopy histomorphology parallels what one sees clinically; in those patients that develop a cobblestone and dry-looking papilloma, the histomorphology is usually less prolific, less succulent and less active. It's a more dormant-looking papillary growth pattern. That may be true in general, however, regardless of whether or not the patient is taking interferon. The subject of ultrastructural characteristics in the interferon group is an ongoing study and that will be presented with our secondary data.

Thank you, Dr. Strong, for your remarks. We're most interested in the information that was presented out of Iowa in the *New York Times*. You may have read it and are awaiting follow-up publications. We have spoken to Dr. McCabe regarding this and it's those very patients that have failed in our group that we're going to put on the New York State Blood Bank interferon. We're taking the failures from our study and putting them on the interferon that is supposed to have had 100% success. We'll see what happens. This will provide a reasonable noncontrolled adjuvant to a reasonably noncontrolled preliminary study. With regard to the complete responders (3 of 5), two have maintained the response up to 3 or 4 months. One has recurred, and in fact, he was one of the rebounders. He is over the line with much more papilloma than he had previously. So, two of the five have not been followed long enough. We look upon this as something to investigate in the future.

LARYNGEAL SARCOIDOSIS: REPORT OF 13 PATIENTS (p. 23)

H. B. NEEL, III, MD, PHD; T. J. MCDONALD, MD

CRICOTHYROIDOTOMY: THE IMPACT OF ANTECEDENT ENDOTRACHEAL INTUBATION (p. 101)

E. A. WEYMULLER JR, MD; C. W. CUMMINGS, MD

NERVE-MUSCLE PEDICLE REINNERVATION OF THE LARYNX: AVOIDING PITFALLS AND COMPLICATIONS (p. 104)

H. M. TUCKER, MD

PAUL WARD, MD (Los Angeles): I've been asked to discuss only Dr. Tucker's paper but I want to congratulate Drs. Tardy, Neel, and Weymuller on the excellent quality of their presentations. I wish to thank Dr. Tucker also for the courtesy of providing a manuscript for review prior to the meeting. This is not the usual circumstance in many cases. With that said, I'm now going to go ahead and talk about his procedure rather than his particular paper, commenting at the end, and then asking him several questions.

Certainly the nerve-muscle preparation and reinnervation of the larynx offers hope of being a very innovating and promising approach to the rehabilitation of the paralyzed larynx. Unfortunately, as has been mentioned, a number of competent surgeons have been unable to reproduce its success. Dr. Tucker and his colleagues have conducted initial experimental work in dogs where they demonstrated that intact nerve terminal branches and motor end-plates are present in the transposed nerve-muscle pedicles and in the receptor muscles of the implantation site. They then performed the procedures in adults and reported remarkable successes. Two other groups have published articles that I know of, confirming the success of the technique. Dr. Crumley, this year's Mosler award winner in his Triological thesis entitled *Experiments in Laryngeal Reinnervation*, however, has not been able to reproduce these results in dogs. He very carefully monitored these dogs, performed electron microscopy, histochemical techniques and observations, and will be reporting that data. Dr. Rice, also of our institution, in performing experiments for his Triological thesis, was also unable to demonstrate reinnervation. Nevertheless, there appears to be a subtle favorable phenomenon taking place in patients with reinnervation of the paralyzed larynx by the Tucker procedure. We have carefully documented a series of patients, in fact we had Dr. Tucker out to perform the first two cases, and for those cases along with the others, we've obtained serial motion pictures, prior to and after the surgery, and during exercise and at rest. These will be presented, at I told Dr. Tucker, as an advertisement for the paper that we're going to present on Thursday to the Head and Neck Society. There you will be able to see what's actually happening rather than having pictures drawn for you; you can observe the degree of improvement in several of the cases. Dr. Tucker, in this paper, has outlined the pitfalls that may be responsible for the inability of some to achieve success with this technique. If the technique has merit, then it behooves other surgeons to heed these pitfalls and learn to meticulously perform the procedures. I have several questions that Dr. Tucker can perhaps give us some information on from his extensive experience. That is, what is the timing of attempted reinnervation following denervation? What's the relationship with the type of injury, whether it be trauma or actual division or section of the nerve? Which side should we select; should we select the diskinetic but still partially innervated side that has good muscle tone, although it's diskinetic in its motion? Or should we select the paralytic side where there may be atrophy and protect the side that still has some slight motion?

Should recurrent nerve branches of the adductors be cut? Or should the recurrent nerve itself be cut when we've done a reinnervation? Perhaps the most positive thing that can be said is that the operation causes no harm and has minimal complications. It does not prohibit going ahead with an arytenoidectomy or arytenoidplexy or the performance of a permanent tracheotomy in the presence of its failure. Further, carefully documented clinical and animal studies are therefore warranted in order to determine the effectiveness of the nerve-muscle preparation technique.

HARVEY TUCKER, MD (closing): Thank you, Dr. Ward, for your kind comments and for your piercing questions. I would like to mention that in addition to the studies that Dr. Ward mentioned regarding the animal work, these experiments were repeated in Dr. Ogura's lab by a subsequent investigator. A series of three papers were published in the *Laryngoscope* and their conclusion was that they were able to reproduce the findings in animals that we had previously published. With regard to the other questions that Dr. Ward has raised, first, that of timing of reinnervation: obviously the optimal time is as soon after the event that produces paralysis as the situation will permit. Unlike the other means of rehabilitation of a bilaterally paralyzed larynx, such as a lateralization procedure (excluding tracheotomy), our procedure does not preclude the possibility of spontaneous recovery. Therefore, one could consider reinnervation even after an acute injury in which it was not absolutely certain that the recurrent nerves could not be expected to recover. Such an injury might be one of these "clothes-line" injuries in which the trachea is transected but in which it is not apparent whether the recurrent nerves have also been transected. It is probably not advisable to explore such cases since one is likely to produce more damage in the acutely traumatized state. We have successfully reinnervated larynges paralyzed as long as 20 years, but the shorter the paralysis the better the results seem to be. This is mainly because progressive ankylosis of the joints may occur and not because of the inability of the muscles to be reinnervated. I certainly would not consider any other procedure acutely than reinnervation if there is not absolute certainty that the recurrent nerves have been destroyed. We are not absolutely certain which is the best side to reinnervate if one cord retains slight motion. It is tempting to preserve a vocal cord on the side that has some little bit of movement and good tonus in favor of reinnervating the absolutely nonmoving opposite cord. Wasting of the muscle is not necessarily an ominous sign. We have biopsied several larynges that have been paralyzed for prolonged periods and have found that the muscle is decreased in bulk, but there is live, striated muscle present in almost every case, even after many years, and this is at least theoretically capable of reinnervation. It is extremely important to be sure that the arytenoid is passively mobile. Finally, the question of whether or not we should cut the recurrent nerve on the side that is being reinnervated in order to assure that no adductor fibers are left: I have not been doing this, but it isn't a bad thought. Since there are seven times as many adductor as abductor fibers, if even a few of these successfully regenerate or cross the damage site, it would tend to interfere with the ability to abduct the vocal cords by reinnervation. This is probably a worthwhile suggestion to pursue. Finally, I would like to reiterate that even if it is shown that this procedure is successful, and I am hopeful that Dr. Ward will demonstrate that to everyone's satisfaction, if it cannot be learned by the well-trained otolaryngologist and incorporated into his practice for properly selected patients with reasonable expectation of success, then it isn't worth much and it will be bypassed in favor of better procedures.

LARYNGOTRACHEAL INVASION BY THYROID CARCINOMA (p. 27)

M. FRIEDMAN, MD; V. K. SHELTON, MD; E. M. SKOLNIK, MD; F. G. BERLINGER, MD; M. ARAB, MD

HERBERT H. DEDO, MD (San Francisco): I think there is another alternative that is not mentioned. When there is microscopic or even small macroscopic involvement of the cricoid cartilage or other vital structures, postoperative x-ray therapy to get papillary or follicular carcinoma can be utilized. The results of this were reported in a paper by Shelline and Galante in 1966; I submit that it provides a viable alternative.

PRIMARY VOCAL REHABILITATION USING THE BLOM-SINGER AND PANJE VOICE PROSTHESES (p. 122)

M. D. MAVES, MD; R. E. LINGEMAN, MD

WILLIAM R. PANJE, MD (Iowa City): I would like to thank Drs. Maves and Lingeman for providing me with this paper with sufficient time so I could review it as well as pull out some of our data to show some comparisons. I think Drs. Maves and Lingeman have brought forth several important concepts. Of these, I think the primary one is that immediate tracheoesophageal fistula (TEF) formation following laryngectomy (following full-course irradiation or postoperative irradiation therapy is unlikely) can be done with a high degree of success. In addition it would appear that immediate TEF formation might decrease the time interval to gain esophageal speech as well as improve the overall success rate. There is also a better chance for patient rehabilitation with concomitant earlier return to his job and social environment. The second concept is that closure of the pharyngotomy following laryngectomy appears to play a major role in determining TEF speech success. Of course, we must pay tribute to Dr. Saunders in that, in his 1963 paper, he demonstrated that closure of the pharyngotomy over a dilator (No. 34 to No. 38 French) seemed to improve the time and ease with which swallowing was attained in the laryngectomy patient. Drs. Maves and Lingeman simply applied this maneuver to their patients to increase their chances of achieving TEF speech. We have been doing this same maneuver in our patients for over 1½ years now and have found that the fistula rate has decreased 10% to 4% while TEF speech success increased by 18%. I might hasten to add that our patient group was highly selected (all had endolaryngeal lesions). When we looked at patients that had TEF following laryngectomy for the extralaryngeal lesion, our success rate was not as good, additionally having marked variability in quality of speech. Added benefit of doing an immediate TEF is that the nasogastric tube can be passed through the fistula, thus avoiding patient discomfort of having the nose intubated during the postoperative period.

Drs. Maves and Lingeman showed that either the Panje voice prosthesis or the Blom-Singer prosthesis could be utilized with equally good results. Dr. Maves adapted the advantages of each of these prostheses to the patient's needs. He found no difference of one prosthesis being more advantageous in attaining speech.

I would suggest a few precautions for Drs. Maves and Lingeman as they continue with their study. They should avoid doing immediate fistulization procedures on patients who are going to have postoperative irradiation. From our experience the patient will have an inordinate amount of crusting, skin breakdown, poor speech production, TEF granulation and bleeding. All these nuances will aggravate the patient as well as his doctor. If the reason for laryngectomy is extralaryngeal disease, ie, pyriform sinus disease, we have seen an adverse effect on achieving TEF speech. This is probably due to a lack of enough pharyngeal mucosa for easy closure as well as the possibility of distortion of the walls from scarring.

I would encourage Drs. Maves and Lingeman to continue their study, and would enlist them to document the lesions they are dealing with as well as how much pharyngeal mucosa is left after the laryngectomy.

MARK SINGER, MD (Indianapolis): It's a pleasure to be here this afternoon and comment on this paper. Only two years ago at this meeting, I presented the concept of tracheoesophageal puncture to this group with my coworker, Dr. Eric Blom, and it has been very rewarding to see how it has grown and prospered. I am no longer at the University where Drs. Maves and Lingeman are, but it's great to see what's going on in Indianapolis; things are alive and well. I agree with the idea that tracheoesophageal puncture for alaryngeal voice rehabilitation is uncomplicated and is often effective in a primary state. I think that the paper is particularly important because it reports a near 100% success rate in these speakers, although there is some deterioration over time, without the considerable oncologic risk and surgical risk of the Staffieri neoglottic type procedures that we have witnessed in the last several years. The authors bring up the concept of altering muscle closure as described by Dr. Maves and earlier by Dr. Saunders. This must be assessed in regard to two issues. The first is the incidence of fistula formation and swallowing function changes, and second, the speech acquisition aspects of the problem. The series reports ten patients collected between July 1981 and April 1982, which is a rather small series with only three patients irradiated preoperatively. There were only four in this group of ten patients that had concomitant radical neck dissection. So it is very difficult to comment as to whether these techniques are safe from a standpoint of fistula formation. In addition, three patients had myocutaneous flap closures which further makes it difficult to truly assess the incidence of fistula formation with this variant closure. On Wednesday we will present our experience with closure techniques and fistula formation. As Dr. Maves mentioned, leaving the muscles open at laryngectomy should insure a wide myotomy, and I would have to take issue with this. No matter how widely they appear at the time of one's closure, when reexplored, the constrictor muscle system will reconstitute itself in the midline by fibrosis. We have a series now of over 300 cases with nearly 100 myotomies, and it has been a consistent finding that there is reapproximation at this level and significant spasm. I would like to ask Drs. Lingeman and Maves two questions regarding their paper. First, was there a difference between the two prosthetic methods? This is an important issue since the voice button was introduced last year. We've asked our colleagues at Purdue University to study the voice button, and not to trouble you with these numbers, but this resistence is given in ohms. The airflow across the voice button is considerable; in fact, ten times the normal subglottic airflow pressures of the larynx. The duckbill voice prosthesis is approximately three times, or two and one half. This is significant because increased intrathoracic pressures increase the problem of pharyngoesophageal spasm and speech failure. Second, I would like to ask if the two patients in the group who elected to eliminate the use of the prosthesis did this for the reason of excessive work to drive one or both prostheses or the excessive work in driving air across the pharyngoesophageal segment. Finally in conclusion, and to avoid presenting another paper, the primary tracheoesophageal puncture technique is useful to restore voice in the laryngectomized state. It will eliminate hazardous procedures that have been on the scene, but it does require extra work by the surgeon and by the patient, and this should be considered very carefully prior to getting involved with this technique. This is a patient who had a primary procedure done in Indianapolis. He is currently going through radiation therapy and wearing a duckbill voice prosthesis. He was able to talk his entire way through radiation therapy and, for this patient, it was a great success. But for the successes, there are failures, as those who have used the various prostheses know, and I would recommend, as Dr. Maves has, that one be very critical in the selection of the patients.

M. D. MAVES, MD (closing): First I will answer Dr. Panje's question concerning the role of postoperative radiation therapy and the effectiveness of this procedure. In some of the individuals who underwent primary TEP, we were not planning on giving them postoperative radiotherapy. It was only after studying the neck dissection specimen, seeing that there were multiple levels of nodes in multiple locations, did we decide to give them postoperative radiotherapy. As we were uncertain as to just what role primary TEP would play in individuals who were receiving postoperative radiotherapy, our plan was to allow these individuals to try to voice through postoperative radiotherapy. Of the three individuals who did have postoperative radiotherapy, and these numbers are small obviously, two to them have problems, did have limited voicing, had to stop for several weeks until radiotherapy was completed, but then again were able to resume it. One individual, much like what Dr. Singer showed, was able to voice completely through radiotherapy without any difficulty whatsoever. I think that you need to use care in the patient with postoperative radiotherapy. They will have crusting, and it just demands a lot of attention on both your part and the part of the speech pathologist who helps you.

Dr. Singer, to your two questions: First of all, I can just keep talking and we'll discuss whether there was any difference between the two prostheses. I can tell you that again, anecdotally, based upon a very small number of patients in comparison to either your series or Dr. Panje's series, that I don't appreciate a significant difference between the prostheses. I don't think that the prosthesis itself is necessarily the important variable in this equation. I think that the patient, the diligence of the surgeon, the speech pathology team, and the amount of work that all of those individuals do is probably more indicative of the eventual success of tracheoesophageal speech, whether it be primarily or secondarily, rather than either prosthesis itself. I'm aware of the data from Purdue and looked at this quite carefully, and it is correct that on the bench, the Panje prosthesis does require considerably more pressure to drive the air across the pharyngeal esophageal segment. We're currently looking at and are going to try to evaluate this situation. However, actually within the patient, one variable (and this may be somewhat eliminated with the second generation Blom-Singer prosthesis with the phalange) is how much of the end of the duckbill actually sticks out into the pharyngoesophageal segment. In other words, on the bench, the entire open mouth of the duckbill can be widely open as air is put across it, but how much of that is limited actually in the patient? I'm not sure. But I will agree with you that I am familiar with that data. At least on the bench it tends to have a greater pressure, but again in individual patients, I have not run into that problem. It does seem to require a little bit more effort on them initially, but long-term down the line, six months to a year, I'm not aware of a big difference between the effectiveness of either of those two populations of prosthetic speakers. Lastly, the final question concerning the two individuals who gradually use their prostheses less and less: one individual, as it turns out, has a Blom-Singer and one has a Panje prosthesis. Again, the numbers are so small. Let me discuss the major influences on each of those individuals. One person is an individual who has an overlying psychological problem. His effectiveness of prosthetic speech tends to parallel his mood and I think, in retrospect, he was a poor patient to be selected for primary tracheoesophageal speech. I don't think I would select him again. The other individual was an individual who, I don't think, was properly informed of the difference in his speech quality prelaryngectomy versus postlaryngectomy. He was disturbed by the low guttural quality of the voice, and again, I don't find that a failure in him. I think that's a failure in us in looking back at that. We may well not have selected him at this time as a primary tracheoesophageal puncture candidate.

WILLIAM R. PANJE, MD: Excuse me, Dr. Lingeman, for coming back to the podium, but I would like to comment on Dr. Singer's statement concerning the increased resistance of airflow through the Panje voice prosthesis as compared to the duckbill. We have also looked at this problem, and indeed found that with the earlier-produced voice buttons there was a definite increase in airway resistance over that of the original prototypes. This has since been corrected by quality-testing each product before shipment from the factory. In fact, most recently comparing airflow resistance between the voice button and duckbill, we have found the latter prosthesis to have consistently higher and widely varying opening pressures than the voice button.

MEMORIALS



PAUL A. CAMPBELL
1902-1982

Paul A. Campbell, MD, became an Active Fellow in the American Laryngological Association in 1945 and in 1966 he joined the ranks of Emeritus Fellows; he died on January 10, 1982. Paul was internationally known for his research into the medical problems of space flight.

He was a 1950 cofounder, with John Marberger and A. C. Ivy, of the Space Medicine Branch of the Aeromedical Association, now the Aerospace Medical Association. When the ALA accepted the space group as a branch, Dr. Campbell served as its President.

Dr. Campbell was born in Frankfort, Indiana, in 1902 and received his MD degree from the University of Chicago's Rush Medical College. From 1930 to 1934 he was a surgeon and Chief of the Medical Staff at Culver Military Academy. After a year of postgraduate work in Vienna, he returned to Chicago, where he specialized in otolaryngology.

A member of the Army Reserves since 1928, he went on active duty in 1940, completed the Flight Surgeon's Course at the School of Aviation Medicine, Randolph Field, Texas, and during most of World War II served as the school's Director of Medical Research. After the war, he went to Europe with the Air Staff Intelligence Team to study the records of German scientists and recruit them to work in the United States. It was here that he first learned of the possibility of using German rockets for space research and, later, manned space flight.

In 1946, he returned to his private practice in Chicago for four years. In 1950 he received a regular commission in the US Air Force and returned to the school at Randolph as Director of Research. From 1953 to 1956 he was Assistant Air Attache at the US Embassy in London and from 1956 to 1958 was Special Assistant to the Commander, USAF Office of Scientific Research, Washington, DC.

In 1958 he returned to the school at Randolph to organize and head its Space Medicine Division, which had first been organized as a Department in 1948 by Col. Harry G. Armstrong. When the USAF Medical Center was organized at Brooks AFB, Texas, in 1959, Col. Campbell became Assistant to the Commander and Chief of the Advanced Studies Group. He was Director of the school at Brooks from February 1962, until his mandatory retirement in December.

It was in 1950 at Randolph that he helped organize the first international symposium on "Physics and Medicine of the Upper Atmosphere." In 1958, and again back at Randolph, he helped organize the second international symposium on "Physics and Medicine of the Atmosphere and Space." In 1960 he organized a symposium on the "Medical and Biological Aspects of the Energies of Space," and later edited the book of the same title.

He was a Fellow of the Aerospace Medical Association, American Medical Association, American Academy of Ophthalmology and Otolaryngology, American College of Surgeons, and nearly a dozen more professional organizations. He received the AsMA's Louis H. Bauer Founders Award in 1963 for significant contributions to space medicine; Melbourne Boynton Award for space flight safety contributions by the American Astronautical Society; the 1972 Hubertus Strughold Award of the Space Medicine Branch; and a host of other awards, citations, military decorations and other honors.

A prolific author, Dr. Campbell published or presented more than 70 scientific papers, wrote chapter in more than 24 textbooks, compiled and edited six volumes of proceedings, and in 1965, published *Earthman/Spaceman/Universal Man*.

(Reprinted with permission from the Aerospace Medical Association.)

FRENCH K. HANSEL
1893-1981

Dr. French K. Hansel was born on January 25, 1893, in Fidelity, Illinois. He received his MD degree from St. Louis University and did his residency in ear, nose and throat at the Mayo Clinic. He financed his education through high school, college and medical school by waiting tables, working in foundries and doing clerical work. He was a star on St. Louis University's first basketball team in 1915. He was affiliated with the Department of Otolaryngology at Washington University School of Medicine, St. Louis, where he studied cytology of nasal secretions and developed the specialized stain (Hansel's stain) which permitted rapid cytologic differential diagnosis of nasal secretions. His concern and disappointment with the extensive and frequently repetitive nasal surgery practiced at that time led him to explore alternative medical solutions for some of the acute rhinologic problems which were encountered. He believed that the routine use of antibiotics was far in excess of their need in the treatment of infections.

Early in his career, Dr. Hansel became disenchanted with the then current treatment of allergy, the "maximal dose" therapy, which often produced severe constitutional reactions. He developed and utilized the low or "optimal dose" therapy based on the principle of the introduction of that amount of allergen or antigen which will produce tolerance. This principle is used in clinical allergy by members of the American Society of Ophthalmologic and Otolaryngologic Allergy. Dr. Hansel also advanced the use of sublingual therapy, incorporating small amounts of offending substances in rapidly dissolving tablets in an effort to potentiate the effects of injections.

For many years he made accurate pollen counts from plates exposed outside his office, which were reported daily to the news media.

Dr. Hansel became a teacher at Washington and St. Louis Universities, author, editor, organizer of specialty allergy units, clinical investigator, botanist and pathologist. He published *Allergy of the Nose and Paranasal Sinuses* in 1936. His second text, *Clinical Allergy*, published in 1953, was a revision of the earlier book.

He conducted private courses in his office for those interested in allergy. In 1935, with approximately 40 students, he participated in the formation of the American Society of Ophthalmologic and Otolaryngologic Allergy. The Hansel Foundation, organized in 1948, received an estimated 2,000 otolaryngologists for allergy training. It has been estimated that Dr. Hansel taught at least 3,000 more otolaryngologists in instructional courses presented over 36 years as a member of the American Academy of Ophthalmology and Otolaryngology. He was one of the organizers of the American College of Allergists and was its second president. He was honored as a Fellow Distinguished in 1975 and received the Award of Merit in 1977. He was the editor of the *Annals of Allergy* from 1943 to 1954. In 1940, Dr. Hansel received the prestigious Casselberry Award from the American Laryngological Association, and in 1980 he was awarded a Presidential Citation as the "Father of Otolaryngologic Allergy" by the American Academy of Otolaryngology.

In collaboration with Jack Anderson, MD, he coauthored *Allergy and Immunity in Otolaryngology* in 1959. After his retirement, he continued his studies. He will be remembered by his colleagues and by his grateful patients for his willingness to assist them at all times.

E.R.W.



JAMES A. HARRILL
1909-1982

"Man is the measure of all things."
Protagoras (5th century BC)

What is the measure of a man? First, there are the unadorned facts. James A. Harrill was born in Mooresville, North Carolina, in 1909. Following his graduation, with honors, from Wake Forest College, he entered the 2-year medical science program. Subsequently he transferred to the University of Pennsylvania, receiving his MD degree in 1935. An internship and residency in otolaryngology followed at King County Hospital in Brooklyn. In 1938 he returned to his native North Carolina, establishing an otolaryngology practice in Winston-Salem. The medical science program at Wake Forest was expanded to four years and moved to Winston-Salem in 1941 as The Bowman Gray School of Medicine. Dr. Harrill was appointed to the original faculty as Chairman of the Section on Otolaryngology, remaining in that capacity until his retirement in 1980. This span of almost 40 years saw momentous changes in otolaryngology and Dr. Harrill was in their forefront. Retirement was only a change of pace and he remained in an active practice and teaching role until his death.

What is the measure of a man? Second, there are his contributions to his profession and to society. By any measure, Dr. Harrill's contributions were impressive. He served as president of his county medical society, president of the North Carolina Otolaryngological Society, on numerous committees of his medical school; he was a member of all the major otolaryngological societies and served as an officer in most of them. A partial list of offices held would include Vice-President of the American Broncho-Esophagological Association, Vice-President of the American Laryngological Association, member of the Executive Committee of the Society of Academic Chairmen of Otolaryngology and President of the Society of University Otolaryngologists. For years he served as a Director of the American Board of Otolaryngology and was a member of its Executive Committee. His contributions to the Triological Society were of particular note, serving first as Secretary and later as Vice-President of the Southern Section. In 1975 he was honored by being elected to the presidency of the Triological Society.

Perhaps his greatest contribution to otolaryngology lay not in his acknowledged leadership role, but in his influence as a member of the National Institutes of Health Training Grant and Research Grant Committees. He, along with other giants of his day, Drs. Bordley, Lederer, Lierle, Sooy, Walsh, Work, etc, infused new life into our specialty through the training and research grant programs. Those of us who follow will be forever in their debt.

What is the measure of a man? Third, there is his influence on those whose lives he touches. Many can attest to his leadership qualities. He led by example, not by coercion, threats or commands. His strength lay in his gentlemanly and kind demeanor, his consideration for others, his unfailing good humor and his absolute lack of pretentiousness. These qualities endeared him to countless students, residents, colleagues and patients. A privileged few have shared with him his love of nature, on hunting or fishing trips or in his mountain retreat.

Personally I mourn the loss of a teacher, a counselor and a friend who for 25 years guided me in my career. I could not call him "Jimmy;" to me he was "The Chief." Sir William Osler, in his essay *Aequanimitas*, expressed my feelings.

Whatever way my days decline,
I felt and feel, tho' left alone,
His being working in mine own
The footsteps of his life in mine.

This tribute to Dr. Harrill is also a tribute to his lovely wife, Grace, and their talented and successful children. Beloved and respected by family, friends, patients and colleagues, his passing leaves a void. Surely his footsteps will long be felt in our lives and in our specialty.

W.R.H.

JOHN R. LINDSAY
1898-1981

John Lindsay's death occurred on December 21, 1981, just two days prior to his 83rd birthday. His admirable personal qualities and scientific achievements will long be cited for their major influence in the field of otology.

Dr. Lindsay came to the University of Chicago at age 30 as an assistant professor of surgery to organize a section of otolaryngology in the newly-opened University of Chicago Medical School. This became the first department in the country with a completely full-time faculty and it has remained so through the years. Dr. Lindsay had an outstanding career as a surgeon, teacher, investigator and department chairman over a period of 53 years. Although identified chiefly with otology, he was skilled in other aspects of his specialty. A roster of the men he trained includes the names of many current and past professors and department chairmen in this country and Canada, among whom are some whose special interests include head and neck surgery. He was elected to Fellowship in the American Laryngological Association in 1949 and became Emeritus in 1967.

Dr. Lindsay was born in Renfrew, Ontario, in 1898. He received his MD degree from McGill University, interned at the Civic Hospital in Ottawa and served residencies in otolaryngology at Montreal's Royal Victoria Hospital and the Toronto Hospital for Sick Children. The remainder of his professional career was spent at the University of Chicago. He was named Thomas D. Jones Professor of Surgery in 1963 and continued an active teaching and writing career until near the end of his life. Dr. Lindsay's studies on the ear were of major significance, particularly in the fields of pathology of hearing and vestibular disorders. His laboratory, devoted to the microscopic study of temporal bones was internationally recognized and he directed one of this country's first temporal bone banks. He was the author of more than 150 articles as well as numerous chapters in textbooks.

Among the organizations which honored John Lindsay by election to presidency were the Chicago Laryngological and Otological Society; the American Otological Society; the American Laryngological, Rhinological and Otological Society; the American Academy of Ophthalmology and Otolaryngology and the Collegium Oto-Rhino-Laryngologicum Amicitae Sacrum. An honorary degree from the University of Uppsala in Sweden and the American Otological Society's Award of Merit were among his other numerous awards.

John Lindsay was a scientist in the truest sense. His work was precise and done with the utmost care. His was an uncanny ability to recognize and appreciate scientific truth and he was never swayed by enthusiasm for the unproven. He was an inspiration to the men he trained and his calm, gentle, compassionate manner endeared him to patients and colleagues alike.

A memorial service for Dr. Lindsay was held at Rockefeller Chapel of the University of Chicago on April 30, 1982. He is survived by his wife, Libby, three daughters, six grandchildren and a sister.

S.A.F.



KENNETH A. PHELPS
1888-1980

In his medical generation Kenneth A. Phelps was the premier peroral endoscopist of the north central states. He generously contributed time and skill in the teaching program of the Department of Otolaryngology of the University of Minnesota Medical School in the period 1920 to 1945.

Dr. Phelps was a careful and patient surgeon and was temperamentally well suited to the skills necessary to foreign body removal. He was the final authority in the region, and as was customary with peroral endoscopists, enjoyed showing his large collection.

Dr. Phelps retired from practice in the late 1940s — about the time that the technique of peroral endoscopy was maturing into the medical and surgical discipline of bronchoesophagology. His early retirement and inherent longevity combined to afford him a long and pleasant life. For some years he attended our meetings when they were held conveniently near his retirement home. He was a well-humored and quiet man and an altogether delightful teacher and friend.

J.A.H.

ROSTER OF FELLOWS
1982

Date indicates year admitted to active fellowship. Attendance at meetings is shown by figures following each name. Asterisk (*) indicates year paper was read.

Active Fellows — 92

1974 Alford, Bobby R., 1200 Moursund Ave., Houston, TX 77025, 1974, '78, '80-'82.

1969 Andrews, Albert H. Jr, 122 S. Michigan Ave., Chicago, IL 60603, 1970-'74*-'81, '82.

1969 Ausband, John R., Emory Univ., 1365 Clifton Rd., NE, Atlanta, GA 30322, 1970-'73, '75, '78, '81.

1975 Bailey, Byron J., Dept. of Otol., UTMB, Galveston, TX 77550, 1975, '76*, '77, '78, '81, '82.

1970 Ballenger, John J., 723 Elm St., Winnetka, IL 60093, 1971-'82.

1963 Baxter, James D., 687 Pine Ave. West, Montreal, P.Q. H3A 1A1, Canada 1963, '65*-'74, '76-'80, '82.

1975 Biller, Hugh F., Mt. Sinai Hosp., 100th St. & Fifth Ave., New York, NY 10029, 1975- '77*, '78*, '79*, '80*, '81*, '82*.

1977 Blaugrund, Stanley M., 115 E. 61st St., New York, NY 10021, 1977-'82.

1975 Boles, Roger, Dept. of Otolaryngol., Univ. of California, San Francisco, CA 94122, 1975-'82.

1955 Bordley, John E., Johns Hopkins Hosp., Baltimore, MD 21205, 1955-'57, '59, '60, '62-'67, '69-'73*-'80, '82.

1959 Brewer, David W., 1100 E. Genesee St., Syracuse, NY 13210, 1959, '60*, '61, '62*, '63, '66, '70, '73, '74*, '77, '80, '81.

1976 Briant, Thomas D. R., St. Michael's Hosp., 30 Bond Street, 4B Wing, Toronto, Ont. M5B 1W8, Canada, 1976, '77, '78, '80-'82.

1955 Brown, Lester A., 490 Peachtree St., NE, Atlanta, GA 30308, 1955-'59, '61, '63, '65, '68-'73*-'80, '82.

1963 Bryce, Douglas P., O.P.D. Toronto General Hosp., Toronto, Ont. M5T 1P7 Canada, 1963*, '64, '66*, '67*, '68*-'76-'79*, '81.

1979 Calcaterra, Thomas C., UCLA Med. Ctr., Los Angeles, CA 90224, 1979.

1976 Cantrell, Robert W., Univ. of Virginia Med. Ctr., Charlottesville, VA 22901, 1976, '77*-'80*-'82.

1968 Chandler, J. Ryan, 1700 NW 10th Ave., Miami, FL 33136, 1968, '69*-'79*-'82.

1967 Cocke, Edwin W., Jr, 920 Madison, Memphis, TN 38103, 1967-'70, '72, '74-'78, '80, '82.

1964 Cody, Claude C. III, 7777 Southwest Freeway, Houston, TX 77074, 1964, '65, '67, '69, '71, '73, '77-'79, '81.

1971 Cohen, Seymour R., 1300 N. Vermont Ave., Los Angeles, CA 90027, 1971, '72*, '73*, '74, '75*, '76*, '77, '78*, '80*, '81*, '82*.

1957 Conley, John J., 211 Central Park West, New York, NY 10024, 1958*, '60*, '61, '62*, '63*, '64, '65, '70, '72, '74*, '75*-'78, '80, '82.

1980 Cummings, Charles W., Dept. of Otolaryngol., Univ. of Washington, Seattle, WA 98195, 1980-'82*.

1973 Dedo, Herbert H., Univ. of California, S.F. School of Med., Rm. 495U, San Francisco, CA 94122, 1973*, '74, '75*, '76*-'79*-'82*.

1966 Devine, Kenneth D., Mayo Clinic, Rochester, MN 55901, 1966-'68, '72*, '74*, '76*.

1976 Doyle, Patrick J., 1081 Burrard, Vancouver, B.C. V62 1Y6, Canada, 1976, '77*, '80*, '81*.

1973 Duvall, Arndt J. III, Univ. of Minnesota Hosp., A-605 Mayo Memorial Bldg., Minneapolis, MN 55455, 1973*, '75-'78, '80, '81.

1968 Farrior, Richard T., 505 DeLeon, Tampa, FL 33608, 1968-'70*, '72, '74, '76-'81.

1964 Fearon, Blair, 308 Medical Arts Bldg., Toronto, Ont., M5R 2M7, Canada, 1964, '66-'71*, '72*, '73*, '74*-'78*-'81*, '82.

1982 Fee, Willard E., Jr, Stanford Medical Center, Stanford, CA 94305, 1982.

1970 Frazer, John P., 601 Elmwood Ave., Rochester, NY 14642, 1971-'82.

1977 Fredrickson, John M., Dept. of Otolaryngology, Washington University, St. Louis, MO 63110, 1977-'79*.

1956 Friedberg, Stanton A., 1725 West Harrison St., Chicago, IL 60612, 1956, '57*-'65*-'71*-'76*, '78*, '79*, '80, '82.

1977 Gacek, Richard R., State Univ. Hosp. of the Upstate Med. Ctr., 750 E. Adams St., Syracuse, NY 13210, 1977*-'82.

1981 Gates, George, 7703 Floyd Curl Dr., San Antonio, TX 78284, 1981, '82*.

1959 Goldman, Joseph L., 55 E. 87th St., New York, NY 10028, 1959, '60*-'72*-'78*-'80, '82.

1974 Hudson, William R., Duke Univ. Med. Ctr., E.N.T., P.O.P., 3805, Durham, NC 27710, 1974-'78*, '81, '82.

1965 King, James T., 3250 Howell Mill Rd., NW, Atlanta, GA 30327, 1965-'67, '69-'71, '73-'76, '80.

1975 Kirchner, Fernando R., 155 S. 18th St., Kansas City, KS 66102, 1975*-'77, '79, '82*.

1963 Kirchner, John A., 333 Cedar St., New Haven, CT 06510, 1963, '65*, '67*-'69*-'71*, '72*-'75*, '77, '78, '80*, '82.

1979 Krause, Charles J., Univ. Hosp., Ann Arbor, MI 48109, 1979-'82*.

1981 Lawson, William, 19 E. 98th St., New York, NY 10029, 1981*, '82.

1979 LeJeune, Francis E., Jr., 1514 Jefferson Hwy., New Orleans, LA 70121, 1979-'82*.

1966 Lewis, John S., 3 East 71st St., New York, NY 10021, 1966-'69*-'72, '74-'76*, '78-'82.

1961 Lewy, Robert B., 25 East Washington St., Chicago, IL 60602, 1961, '62*, '63, '65*, '67-'71, '73-'76*-'82.

1976 Lingeman, Raleigh E., 1100 W. Michigan St., Indianapolis, IN 46202, 1976, '77*-'82*.

1973 Lore, John M., Jr, 2121 Main St., Buffalo, NY 14214, 1974*, '76, '77*, '78*, '81.

1978 Lyons, George D., 120 N. Jefferson Davis Pkwy., New Orleans, LA 70119, 1978-'80, '82.

1966 McCabe, Brian F., Dept. of Otolaryngol., Univ. Hosp., Iowa City, IA 52242, 1966, '69, '72*, '73, '75*,'76, '79*, '81*.

1976 Miglets, Andrew, 456 Clinic Dr., Rm. 4118, Columbus, OH 43210, 1976, '77, '78*, '80, '82.

1952 Miller, Alden H., 1407 N. Vermont Ave., Los Angeles, CA 90027, 1952, '53*, '55, '57, '58*, '61, '62, '64, '66, '67*-'73*, '74*, '76-'78*, '79, '81.

1965 Miller, Daniel, 110 Francis St., Boston, MA 02215, 1965-'69*-'73*-'77*-'81*, '82*.

1964 Montgomery, William W., 243 Charles St., Boston, MA 02114, 1964, '65*, '66*, '68*, '70-'72, '74*-'76*-'78, '80*-'82.

1972 Morse, Harry R., 645 Powell Dr., Fort Walton Beach, FL 32548, 1972, '75, '79-'81.

1979 Myers, Eugene N., Dept. of Otolaryngol., 230 Lothrop St., Pittsburgh, PA 15213, 1979, '80, '82*.

1975 Nahum, Alan M., 225 W. Dickinson, San Diego, CA 92103, 1975, '76, '79.

1981 Neel, H. Bryan III, 200 First St., S.W., Rochester, MN 55901, 1981, '82*.

1980 Nichols, Richard D., Henry Ford Hosp., 2799 W. Grand, Detroit, MI 48202, 1980, '81.

1956 Norris, Charles M., 3401 N. Broad St., Philadelphia, PA 19140, 1956-'58*-'61*-'64, '66-'68*-'70*-'78*-'82.

1961 Ogura, Joseph H., 517 S. Euclid Ave., St. Louis, MO 63110, 1961*, '62*-'64*-'66*-'68*-'71*-'73*, '74*, '75*, '76*-'78*-'82.

1958 O'Keefe, John J., 130 S. Ninth St., Philadelphia, PA 19107, 1958-'59*, '60, '62, '64, '67, '71, '73-'75, '78, '80.

1982 Olson, Nels R., St. Joseph Mercy Hospital, P. O. Box 944, Ann Arbor, MI 48106, 1982.

1961 Pang, Lup Q., 1374 Nuuanu Ave., Honolulu, HI 96817, 1961, '62*, '64, '66, '67, '69, '71-'73, '75, '77, '79-'82.

1961 Pastore, Peter N., 5503 Riverside Dr., Richmond, VA 23225, 1961, '62*, '64, '66, '67, '69-'76, '78, '80, '82.

1972 Pennington, Claude L., Jr, 800 First St., Macon, GA 31201, 1972, '73, '75, '76*, '78, '82.

1967 Pratt, Loring W., 325-B Kennedy Memorial Dr., Waterville, ME 04901, 1967-'82.

1963 Reed, George F., 750 E. Adams St., Syracuse, NY 13210, 1963, '65*, '66, '68, '69*-'73, '75-82*.

1974 Ritter, Frank N., 2675 Englave Dr., Ann Arbor, MI 48103, 1974, '75, '77-'79, '81, '82.

1982 Rontal, Eugene, 3774 Wabeek Lake Dr. West, Bloomfield Hills, MI 48013, 1982.

1981 Sasaki, Clarence T., 333 Cedar St., New Haven, CT 06510, 1981.

1964 Saunders, William H., Ohio State Univ., Rm. 3110, 456 Clinic Dr., Columbus, OH 43210, 1964-'66, '68*-'70*, '71-'75*-'80, '82*.

1978 Sessions, Donald G., 1960 Grassy Ridge Rd., Kirkwood, MO 63122, 1979*, '80*, '81.

1979 Shapiro, Myron J., 349 E. Northfield Rd., Livingston, NJ 07039, 1979-'81.

1962 Sisson, George A., Northwestern U. Medical School, 303 E. Chicago Ave., Chicago, IL 60611, 1962, '63*, '65, '66, '68-'73, '76-'82.

1964 Skolnik, Emanuel M., 1855 W. Taylor St., Abraham Lincoln School of Medicine, Chicago, IL 60612, 1964*, '65, '66*-'70*-'73, '75*-'80*-'82*.

1974 Snow, James B., Jr, 3400 Spruce St., Philadelphia, PA 19104, 1974-'75*-'77, '78*, '79, '81, '82.

1972 Soboroff, Burton J., 307 N. Michigan Ave., Chicago, IL 60601, 1972-'77, '79, '80, '82.

1973 Som, Max L., 121 E. 60th St., New York, NY 10022, 1973, '74*, '75*, '76-'78*, '79*, '80, '82.

1954 Sooy, Francis A., Univ. of California Hosp., 3rd & Parnassus Ave., San Francisco, CA 94122, 1954, '56*, '58, '60, '62-'65*, '67, 68*, '71, '78, '79, '81.

1979 Spector, Gershon J., Dept. of Otolaryngol., 517 S. Euclid, St. Louis, MO 63110, 1979-'82.

1975 Sprinkle, Philip M., West Virginia Univ. Med. Ctr., Morgantown, WV 26505, 1975-'78*-'82.

1975 Strong, M. Stuart, 720 Harrison Ave., Boston, MA 02118, 1975, '76*, '77, '78*, '79*, '81, '82*.

1963 Tabb, Harold G., Dept. of Otolaryngol., Tulane Medical School, New Orleans, LA 70112, 1963, '65-'69, '71, '72, '74, '77-'82.

1979 Tardy, M. Eugene, 2913 N. Commonwealth, No. 430, Chicago, IL 60657, 1979, '82*.

1982 Thawley, Stanley E., 517 S. Euclid, St. Louis, MO 63110, 1982.

1954 Thornell, William C., 2328 Auburn Ave., Cincinnati, OH 45219, 1955*, '57, '59-'63, '68, '70, '72, '74, '77, '78, '80.

1978 Toomey, James M., 550 N. Main St., Attleboro, MA 02703, 1979*, '80, '81.

1967 Trible, William M., 1234 19th St., NW, Washington, DC 20036, 1967-'69*, '71-'82.

1970 Tucker, Gabriel F., Jr, The Children's Memorial Hosp., 2300 Children's Plaza, Chicago, IL 60614, 1970*-'73*-'74*-'75*-'77*-'78*-'82*.

1979 Tucker, Harvey M., Dept. of Otolaryngol., Cleveland Clinic, Cleveland, OH 44106, 1979, '80*, '81, '82*.

1973 Tucker, John A., Hahnemann Hosp., 230 N. Broad St., Philadelphia, PA 19102, 1973*, '74*, '75*, '76, '77*, '78*, '80-'82.

1980 Vrabec, Donald P., Dept. of Otolaryngol., Geisinger Med. Ctr., Danville, PA 17821, 1980, '81*.

1974 Ward, Paul H., UCLA School of Medicine, Los Angeles, CA 90024, 1974*-'76, '77*, '78*, '79*, '81*, '82*.

1971 Williams, Russell I., 414 E. 23rd St., Cheyenne, WY 82001, 1971, '72*-74, '76-'78*, '80.

1951 Woodman, DeGraaf, P. O. Box 560, Easton, MD 21601, 1951, '53-55*-'56, '58-'76*-'80, '82.

1981 Yanagisawa, Eiji, 98 York St., New Haven, CT 06511, 1981, '82*.

Honorary Fellows — 7

1978 (1959) Barretto, Plinio de Mattos, Rua Cons Torres, Homen 371, Sao Paulo, Brazil, 1960, '69, '73, '80.

1957 (1925) Clerf, Louis H., 5575 Eighth Ave., North, St. Petersburg, FL 33710, 1957-'61, '63-'66,'68-'72*-'78*.

1978 (1971) Harrison, D. F. N., 330/332 Gray's Inn Road, London, W.C.I., England, 1971, '77, '81*.

1966 (1957) Ono, Jo, 6-13, 6-Chome, Roppongi, Minato-Ku, Tokyo, Japan, 1971.

1968 (1937) Portmann, Prof. Dr. Georges, Clinique S, Augustin, 114, Avenue d'Ares, Bordeaux, France, 1947.

1968 (1957) Ruedi, Prof. Dr. Luzius, Kurhausstrasse 50, Zurich, Switzerland, 1957.

1962 (1932) Schall, LeRoy, A., P. O. Box 136, Barnstable, MA 02630, 1964, '66, '68-'69, '72-'77.

Corresponding Fellows — 14

1978 Arauz, Juan Carlos, 2150 Cangallo, Buenos Aires, Argentina, 1040, 1980.

1972 Arslan, Prof. Michele, Otorinolaringoiatrica dell' Universita da Padova, 37 Via Altinate, Padova, Italy, 1972.

1959 Bateman, Sir Geoffrey H., Thorney-Graffham, Petworth, West Sussex, England.

1980 Benjamin, Bruce, 229 Macquarie St., Sydney, N.S.W. 20000 Australia, 1980, '81.

1964 Cleves, Carlos, 12, 20-69 Bogota, Columbia, 1970.

1966 Dohlman, Gosta, 304 Cresdent Dr., E. Bradenton, FL 22505, 1966.

1970 Halliday, Sir George C., 143 Macquarie St., Sydney, N.S.W. Australia.

1970 Hutcheon, Jack, Morris Towers, 149 Wickham Terrace, Brisbane, Australia, 1971, '78, '80.

1978 Kleinsasser, Oskar, Deutschhausstrabe 3, 355 Marburg (Lahn), Cologne, West Germany, '1982*.

1971 Macbeth, Ronald G., Meadow Close Church Hanborough, Oxford, England.

1968 Nakamura, Fumio, Kyoto Prefectural U. Medicine, Kawara-Mach 1, Kamikyo-Ku, Kyoto, Japan.

1964 Perez, Alfredo C., Instituto Celis Perez, Avenida Montes Deoca, Valencia, Venezuela, 1965.

1952 Tapia-Acuña, Ricardo, Av. Insurgentes, Sur No. 300, Mexico 7 D.F., 1953, '57, '60*, '67, '73, '75, '81*.

1936 Vialle, Jacques, 27 Rue de France, Nice (Alpes Maritimes), France.

Emeritus Fellows — 41

1980 (1962) Arnold, Godfrey E., 2500 N. State St., Jackson, MS 39216, 1962, '63*, '64*, '66, '69, '70, '72, '73, '75, '77, '79.

1973 (1944) Boies, Lawrence R., Dept. of Otolaryngol., A-605, Mayo Memorial Bldg., Minneapolis, MN 55455, 1944, '46-'48*-'50-51*, '53-'68*-'69, '71.

1965 (1942) Canfield, Norton, 59 Whitfield St., Guilford, CT 06437, 1982.

1978 (1959) Cracovaner, Arthur J., 170 W. End Ave., New York, NY 10023, 1959-'61*-'63, '65-'69, '72, '74-'76, '78-'79.

1982 (1960) Daly, John F., 16 N. Brae Ct., Tenafly, NJ 07670, 1960, '61*, '79*, '81.

1977 (1951) Davison, Francis W., Geisinger Med. Ctr., Danville, PA 17821, 1951-'53*-'63*-'67*-'69*-'73*-'75, '77, '78*, '79.

1980 (1968) DeWeese, David D., 3181 SW Sam Jackson Park Rd., Portland, OR 97202, 1968-'69*, '73-'80, '82.

1972 (1962) Erich, John B., Mayo Clinic, 102 Second Ave., Rochester, MN 55901.

1982 (1963) Ferguson, Charles R., P. O. Box 313, Osterville, MA 02655, 1963, '64*, '66, '67*, '68, '69*-'74*-'78* -82.

1979 (1955) Fitz-Hugh, Glassell S., 145 Blue Ridge Rd., Charlottesville, VA 22903, 1955, '57, '59-'62*, '64-'67*, '68-'77*, '78.

1970 (1940) Goodale, Robert L., 141 Argilla Rd., Ipswich, MA 01938, 1971, '74-'76.

1963 (1928) Goodyear, Henry M., 2012 Edgecliff Point, Cincinnati, OH 45206.

1980 (1965) Hanckel, Richard W., Jr, 9 Valley Forge Dr., Nashville, TN 37205, 1965-'67, '69-'74, '77-'80.

1978 (1960) Harris, Herbert H., 3457 Meadow Lake Lane, Houston, TX 77027, 1960, '61*-'65*-'75, '77-'79, '81, '82.

1968 (1942) Heatley, Clyde A., 2500 East Ave., Rochester, NY 14610, 1942, '46*, '49, '50, '52-'53*-'55, '57, '58, '60, '61, '65.

1978 (1959) Henry, G. Arnold, Suite #2, Group Box 24, Lagoon City, RR #1, Brechin, Ont., L0K 1B0, Canada, 1959, '61, '63, '66, '67, '69, '70, '73.

1980 (1955) Hilger, Jerome A., 393 Dunlap St., Suite 6A, St. Paul, MN 55114, 1955-'56*-'60, '62-'66, '68-'71, '75-'78, '80, '82.

1977 (1957) Holmes, Edgar M., Graydale Circle, Auburndale, MA 02166, 1957, '59, '61, '63, '68, '70-'72, '74-'76, '80.

1961 (1950) Kline, Oram R., 896 Lake Ave., Woodbury Heights, NJ 08097, 1961, '63, '70, '72, '74.

1977 (1963) Lathrop, Frank D., R.D.1, Pittsford, VT 05763, 1963, '64*, '67*, '69-'78, '80-'82.

1964 (1952) McCall, Julius W., 22880 Canterbury Lane, Shaker Heights, OH 44122, 1964, '66, '68-'73, '75-'78.

1980 (1963) McGovern, Francis H., 139 S. Main St., Danville, VA 24541, 1963, '64, '66, '68, '71, '72, '74, '75, '77, '79, '81, '82.

1974 (1951) McHenry, Lawrence C., 1607 Glenbrook Terrace, Oklahoma City, OK 73116, 1953*, '62-'66, '68, '71.

1970 (1931) McNally, William J., 25 Redpath Pl., Montreal, Canada, H3G 1E2, 1972-'75.

1978 (1957) Munoz-MacCormick, Carlos Eduardo, 71 de Diego, Santurce, PR 00911, 1957-'80, '82.

1971 (1953) Murtagh, John A., 1198 A1A Apt. 240, Hillsboro Beach, Pompano, FL 33062, 1953-'56*, '57-'61, '62-'63, '65-'67, 69, '70, '72, '74, '76, '78-'80, '82.

1981 (1958) O'Keefe, John J., 111 S. 11th St., Philadelphia, PA 19107, 1958-'59*, '60, '62, '64, '67, '71, '73-'75, '78, '80.

1976 (1951) Priest, Robert E., 322 Medical Arts Bldg., Minneapolis, MN 55402, 1977-'81.

1980 (1951) Putney, F. Johnson, 80 Barre St., Charleston, SC 29401, 1951-'53*-'58*-'63*-64*-'68*-'69*-'70*-'72, '74-'78*, '79*, '82.

1972 (1956) Richardson, John R., P.O. Box 52, Searsport, ME 04974.

1981 (1959) Sanders, Sam H., 1286 Peabody Ave., Memphis, TN 38104, 1959-'63, '65, '70-'73, '75, '78.

1977 (1958) Simonton, Kinsey M., % Foster, Duxbury, MA 02332, 1958, '59*, '62, '64, '66, '67, '69, '72, '74, '75, '78, '82.

1969 (1950) Smith, Austin T., 235 Lancaster Ave., Devon, PA 19333, 1970-'74.

1982 (1961) Suehs, Oliver W., 2805 Robbs Run, Austin, TX 78705, 1961, '62*-'64, '66, '68-'72, '74-'78, '80.

1973 (1963) Tolan, John F., 3419 47th Ave., NE, Seattle, WA 98105, 1963-'67, '69, '71, '73.

1961 (1941) Viole, Pierre P., 241 South Windsor, Los Angeles, CA 90004, 1964.

1977 (1962) Weaver, Delmar F., Med. Professional Bldg., P. O. Box 862, Culpeper, VA 22701, 1962-64*, '65, '67*, '69-'70, '72, '74, '76.

1975 (1953) Work, Walter P., 172 E. Paseo de Golf, Green Valley, AZ 85614, 1953, '54, '56, '58, '59*, '62, '63*, '65, '67-'69, '72, '73, '75, '76, '78*, '79*, '82.

OFFICERS 1982-1983

≈

PRESIDENT

M. STUART STRONG, MD

VICE-PRESIDENT (PRESIDENT-ELECT)

JOHN S. LEWIS, MD

SECRETARY

EUGENE N. MYERS, MD

TREASURER

LORING W. PRATT, MD

HISTORIAN-EDITOR

GABRIEL F. TUCKER, JR, MD

≈

COUNCIL

FIRST COUNCILOR

JOHN A. KIRCHNER, MD

SECOND COUNCILOR

DANIEL MILLER, MD

THIRD COUNCILOR

HAROLD G. TABB, MD

COUNCILORS AT LARGE

HERBERT H. DEDO, MD

CLAUDE L. PENNINGTON, MD

INDEX

AUTHORS

A

Arab, Mohammad 27

B

Baker, Shan R. 59
Beach, Thomas P. 67
Berlinger, Frederick G. 27
Biller, Hugh F. 112
Birck, Herbert G. 67
Birns, Jeffrey W. 81
Blalock, P. David 36

C

Cangir, Ayten 95
Cohen, Seymour R. 81
Cummings, Charles W. 34, 101

D

Dedo, Herbert H. 89
Dichtel, William J. 95

E

Ervin, Thomas J. 125

F

Farr, Gist H. 56
Frank, John E. 67
Friedman, Michael 27

G

Gallia, Louis J. 114
Garvin, John P. 67
Gates, George A. 118
Geller, Kenneth A. 81
Gerson, Carol R. 77
Goepfert, Helmuth 95
Gutterman, Jordan U. 95

H

Healy, Gerald B. 48
Hearne, Erwin M. III 118
Hicks, Julius N. 53
Holinger, Lauren D. 71

J

Jackler, Robert K. 89

K

Kirchner, Fernando R. 46
Kleinsasser, Oskar 42
Koufman, James A. 36
Krause, Charles J. 59

L

Lawrence, T. 128
Lawson, William 112
LeJeune, Francis E., Jr 56
Lingeman, Raleigh E. 122

M

McDonald, Thomas J. 23
McLaurin, James W. 14
Maves, Michael D. 122
Miller, Daniel 125
Moor, E. Eugene 53
Myers, Eugene N. 114

N

Neel, H. Bryan III 23

R

Reed, George F. 16

S

Sacks, Steven 112
Saunders, William H. 109
Schaefer, Steven D. 63
Schuller, David E. 67
Sessions, Roy B. 95
Shapshay, Stanley M. 48
Shelton, Vicki K. 27
Simpson, George T. 48
Skolnik, Emanuel M. 27
Stearns, Michael P. 34
Strong, M. Stuart 48
Sulek, Marcelle 95

T

Tabb, Harold G. 15
Tardy, M. Eugene 128
Thompson, Jerome W. 81
Tucker, Gabriel F., Jr 77
Tucker, Harvey M. 104

V

Van Horn, Herbert W. III 56
Vaughan, Charles W. 48

W

Walker, E. Earl 53
Weichselbaum, Ralph R. 125
Weymuller, Ernest A., Jr 101

Y

Yanagisawa, Eiji 18

Z

Zulliger, John J. 67

SUBJECTS

A

Address, Guest of Honor 14
  Presidential 13
Awards
  Casselberry 12
  DeRoaldes 12
  Newcomb 12

B

Baker, Daniel C., Jr, Memorial Lecture
  Subcertification: a dilemma for otolaryngology-head and neck surgery 16
Blom-Singer and Panje voice prostheses, primary vocal rehabilitation using 122

C

Cancer of head and neck, chemical modulation of hypoxic fraction in treatment of 125
Carbon dioxide laser, and podophyllum in treatment of laryngeal papilloma 89
Carcinoma, thyroid, laryngotracheal invasion by 27
Chondrosarcoma of larynx
  Diagnosis and conservative surgical management of 53
  Excision of massive recurrence of 56
Cricothyroidotomy, antecedent endotracheal intubation and 101
Croup and epiglottitis, assessment of intubation in 67

D

Discussions 129

E

Endotracheal intubation, antecedent, and cricothyroidotomy 101
Epiglottitis and croup, assessment of intubation in 67
Epithelium of monkey larynx, age-related changes in 34
Esophageal speech, predicting 118
Executive Sessions
  First Session, Minutes of 7
  Second Session, Minutes of 7
  Reports 8

F

Fellows, Registration, Annual Meeting 5
Roster of 142

G

Glottic incompetence, posterior, correction of following horizontal partial laryngectomy 112

Guest of Honor Address 14
Introduction 14

H

Hypoxic fraction, chemical modulation in treatment of head and neck cancer 125

I

Infant tracheotomy 77

Interferon, leukocyte, and juvenile laryngeal papillomatosis .. 95

Intubation
Antecedent endotracheal, and cricothyroidotomy 101
Assessment in croup and epiglottitis 67

Invasion, laryngotracheal, by thyroid carcinoma 27

L

Laryngeal papilloma, treatment with carbon dioxide laser and podophyllum 89

Laryngeal papillomatosis, juvenile, and leukocyte interferon .. 95

Laryngeal paralysis
In children 81
Endoscopic rehabilitation of airway in 46

Laryngeal sarcoidosis 23

Laryngeal and tracheal stenosis, endoscopic management of .. 48

Laryngeal trauma, primary management of 63

Laryngectomy, horizontal partial correction of posterior glottic incompetence following 112

Laryngectomy, total, tracheostomal stenosis following 114

Larynx, chondrosarcoma of
Diagnosis and conservative surgical management of 53
Excision of massive recurrence in 56

Larynx
Age-related changes in epithelium of monkey 34
Endoscopic rehabilitation of airway in laryngeal paralysis 46
Nerve-muscle pedicle reinnervation of 104
Office telescopic photography of 18

Leukocyte interferon, juvenile laryngeal papillomatosis with .. 95

M

Memorial Fund: Laryngeal Research Fund 11

Memorial Lecture, Eighth Daniel C. Baker, Jr:
Subcertification: a dilemma for otolaryngology-head and neck surgery 16

Memorials:
Campbell, Paul A. 137
Hansel, French K. 138
Harrill, James A. 139
Lindsay, John R. 140
Phelps, Kenneth A. 141

N

Nasal turbinates, inferior, surgery of 109

Nerve-muscle pedicle reinnervation of larynx 104

O

Officers 1981-1982 4
1982-1983 145

Otolaryngology-head and neck surgery, dilemma of subcertification in 16

P

Panje and Blom-Singer voice prostheses, primary vocal rehabilitation using 122

Papilloma, laryngeal, treatment with carbon dioxide laser and podophyllum 89

Papillomatosis, juvenile laryngeal, leukocyte interferon use in 95

Paralysis, laryngeal
In children 81
Endoscopic rehabilitation of airway in 46

Pedicle, nerve-muscle, reinnervation in larynx 104

Photography, telescopic, of larynx in office 18

Podophyllum and carbon dioxide laser, treatment of laryngeal papilloma with 89

Polyps, vocal cord, pathogenesis of 42

Pterygomaxillary tumors, extended transantral approach to ... 59

R

Registration of Fellows for Annual Meeting 5

Reports
Accountant 9
Historian-Editor 8
Governor of the American College of Surgeons 8
Nominating Committee 8
Secretary 8
Treasurer 9

S

Sarcoidosis, laryngeal 23

Speech, esophageal, predicting 118

Stenosis, laryngeal and tracheal, success or failure in endoscopic management of 48
Severe subglottic, treatment without tracheotomy 71
Tracheostomal, following total laryngectomy 114

Subcertification, otolaryngology-head and neck surgery and ... 16

Subglottic stenosis, severe, treatment without tracheotomy ... 71

T

Telescopic photography of larynx in office 18

Thyroid carcinoma, laryngotracheal invasion by 27

Tracheal and laryngeal stenosis, endoscopic management of .. 48

Tracheostomal stenosis following total laryngectomy 114

Tracheotomy
Infant 77
Treatment of severe subglottic stenosis without 71

Trauma, laryngeal, primary management of 63

Turbinates, inferior nasal, surgery of 109

Tumors, pterygomaxillary, extended transantral approach to 59

V

Vocal cord polyps, pathogenesis of 42

Vocal rehabilitation, primary, use of Blom-Singer and Panje voice prostheses in 122

Voice disorders, functional, classification and approach to patients with 36