















TRANSACTIONS  
AMERICAN  
LARYNGOLOGICAL ASSOCIATION

1983

VOLUME ONE HUNDRED FOUR



"DOCENDO DISCIMUS"

≈

ONE HUNDRED FOURTH ANNUAL MEETING

THE FAIRMONT HOTEL

NEW ORLEANS, LOUISIANA

APRIL 10 AND 11, 1983

≈

PUBLISHED BY THE ASSOCIATION  
ST LOUIS, MISSOURI  
GABRIEL FREDERICK TUCKER, JR, MD, Editor



## CONTENTS

Officers for 1982-1983 .....	4
Registration of Fellows .....	4
Annual Photograph .....	5
Minutes of Executive Sessions .....	6
Reports	
Secretary, E. N. Myers, MD .....	7
Historian-Editor, G. F. Tucker, Jr, MD .....	7
Governor, American College of Surgeons, G. F. Tucker, Jr, MD .....	7
Research Committee, R. Boles, MD .....	7
Treasurer, L. W. Pratt, MD .....	8
Recipients of De Roaldes, Casselberry and Newcomb Awards .....	10
The Memorial and Laryngological Research Funds .....	10
Presidential Address. M. Stuart Strong, MD .....	11
Introduction of Guest of Honor Daniel Miller, MD. M. Stuart Strong, MD .....	12
Guest of Honor Address. Daniel Miller, MD .....	12

## SCIENTIFIC SESSIONS

Ninth Daniel C. Baker, Jr, Memorial Lecture. Orientation in Flight.* R. Malcolm, PhD	
The Irradiated Larynx: A Surgical Dilemma. J. S. Lewis, MD; A. Vallejo, MD; T. Kusonruksa, MD .....	14
Glottographic Measurement of Vocal Dysfunction. A Preliminary Report. D. G. Hanson, MD; B. R. Gerratt, PhD; P. H. Ward, MD .....	17
Quantitative and Objective Evaluation of Vocal Cord Function. E. Rontal, MD; M. Rontal, MD; H. J. Jacob, MD; M. I. Rolnick, PhD .....	25
Three-Dimensional Computer Reconstruction of the Distribution of Neuromuscular Junctions in the Thyroarytenoid Muscle. M. Rosen, MD; L. T. Malmgren, PhD; R. R. Gacek, MD .....	28
Videolaryngoscopy. A Comparison of Fiberscopic and Telescopic Documentation. E. Yanagisawa, MD; T. W. Owens, MD; G. Strothers, MD; K. Honda, MD .....	34
Voice Change in the Pediatric Patient. A Differential Diagnosis. S. R. Cohen, MD; J. W. Thompson, MD; K. A. Geller, MD; J. W. Birns, MD .....	41
Quantification of Intralaryngeal Pressure Exerted by Endotracheal Tubes. E. A. Weymuller, Jr, MD; M. J. Bishop, MD; B. R. Fink, MD; A. W. Hibbard, MD; F. A. Spelman, PhD .....	48
Congenital Laryngeal Hemangioma. B. Benjamin, FRACS; P. Carter, FRACS .....	52
Further Observations on the Treatment of Recurrent Respiratory Papillomatosis with Interferon: A Comparison of Sources. R. B. Sessions, MD; H. Goepfert, MD; D. T. Donovan, MD; W. J. Dichtel, MD; J. U. Gutterman, MD .....	60
Training Singing Children During the Phases of Voice Mutation. I. M. Blatt, MD .....	66
Laryngeal Nerve Crush for Spastic Dysphonia. H. F. Biller, MD; M. L. Som, MD; W. Lawson, MD, DDS .....	73
The Memorable Life of Hosmer A. Johnson, Early Midwestern Laryngologist. S. A. Friedberg, MD .....	74
Teflon Injection of the Vocal Cord: Complications, Errors, and Precautions. R. B. Lewy, MD .....	77
Early Experiences with Vocal Ligament Tightening. F. E. LeJeune, MD; C. E. Guice, MD; P. M. Samuels, MA .....	79
Muscle Transposition in the Rehabilitation of the Paralyzed Larynx. G. D. Neal, MD; M. Stearns, FRCS; R. Trachy; D. Sutton, PhD; C. W. Cummings, MD .....	82
Intralaryngeal Release for Tracheal Anastomosis. M. E. Sachs, MD; J. Conley, MD; D. D. Rabuzzi, MD .....	86
Preoperative Irradiation and Surgery for Carcinoma of the Base of the Tongue. S. E. Thawley, MD; J. R. Simpson, MD; J. E. Marks, MD; C. A. Perez, MD; J. H. Ogura, MD .....	89

\*Paper not submitted for publication.

Adenoid Cystic Carcinoma of the Subglottic Region. D. T. Donovan, MD; J. Conley, MD .....	95
Muscular Tension Dysphonia. M. D. Morrison, MD, FRCS(C); L. A. Rammage, BA, MSc; G. M. Belisle, MD; C. B. Pullan, MA; H. Nichol, MD, FRCP(C) .....	100
Why Investigate Vocal Function? W. H. Perkins, PhD .....	104
Effects of Stomach Acid on the Larynx. N. R. Olson, MD .....	108
Panel on Organic Voice Disorders.* H. H. Dedo, MD, moderator; G. A. Gates, MD; W. Perkins, PhD; H. Von Leden, MD; C. W. Vaughan, MD .....	
Discussions .....	113



Memorials	
Frank D. Lathrop, MD .....	121
Julius W. McCall, MD .....	122
Roster of Fellows .....	123
Officers 1983-1984 .....	126
Index .....	127

\*Paper not submitted for publication.



## OFFICERS 1982-1983

### PRESIDENT

M. STUART STRONG, MD

### VICE-PRESIDENT (PRESIDENT-ELECT)

JOHN S. LEWIS, MD

### SECRETARY

EUGENE N. MYERS, MD

### TREASURER

LORING W. PRATT, MD

### HISTORIAN-EDITOR

GABRIEL F. TUCKER, JR, MD

### FIRST COUNCILOR

JOHN A. KIRCHNER, MD

### SECOND COUNCILOR

DANIEL MILLER, MD

### THIRD COUNCILOR

HAROLD C. TABB, MD

### COUNCILORS-AT-LARGE

HERBERT H. DEDO, MD

CLAUDE L. PENNINGTON, MD



## REGISTRATION OF FELLOWS

### ACTIVE

ALFORD, BOBBY R.  
ANDREWS, ALBERT H., JR  
BALLENGER, JOHN J.  
BILLER, HUGH F.  
BLAUGRUND, STANLEY  
BORDLEY, JOHN E.  
BREWER, DAVID W.  
BRYCE, DOUGLAS P.  
CANTRELL, ROBERT W.  
CHANDLER, J. RYAN  
CODY, CLAUDE C.  
COHEN, SEYMOUR R.  
CUMMINGS, CHARLES W.  
DEDO, HERBERT H.  
FEARON, BLAIR  
FEE, WILLARD E., JR  
FREDRICKSON, JOHN M.  
FRIEDBERG, STANTON A.  
GACEK, RICHARD R.  
GATES, GEORGE  
GOLDMAN, JOSEPH L.

GOLDSTEIN, JEROME C.  
HEALY, GERALD B.  
HICKS, JULIUS N.  
HUDSON, WILLIAM R.  
JAKO, GEZA J.  
JOHNS, MICHAEL E.  
KIRCHNER, JOHN A.  
LAWSON, WILLIAM  
LEJEUNE, FRANCIS E., JR  
LEWIS, JOHN S.  
LEWY, ROBERT B.  
LYONS, GEORGE D.  
MILLER, DANIEL  
MYERS, EUGENE N.  
NEEL, H. BRYAN III  
NORRIS, CHARLES M.  
OLSON, NELS R.  
PENNINGTON, CLAUDE L.  
REED, GEORGE F.  
RITTER, FRANK N.  
SASAKI, CLARENCE T.  
SAUNDERS, WILLIAM H.  
SESSIONS, DONALD G.

SESSIONS, ROY B.  
SNOW, JAMES B.  
SOOY, FRANCIS A.  
STRONG, M. STUART  
TABB, HAROLD G.  
THAWLEY, STANLEY E.  
TRIBLE, WILLIAM M.  
TUCKER, GABRIEL F., JR  
TUCKER, JOHN A.  
VRABEC, DONALD P.  
WARD, PAUL H.  
WOODMAN, DEGRAAF  
YANAGISAWA, EIJI  
YARINGTON, CHARLES T., JR

### EMERITUS

HARRIS, HERBERT  
MUNOZ-MACCORMICK, CARLOS

### CORRESPONDING

BENJAMIN, BRUCE



FELLOWS IN ATTENDANCE AT THE ONE HUNDRED FOURTH ANNUAL MEETING

*First Row:* Ritter, Boles, Dedo, Myers, Miller, Strong, Lewis, Tabb, Kirchner, Cohen, G. Tucker.

*Second Row:* Hudson, Biller, Friedberg, Goldman, Blaugrund, Fearon, Andrews, Reed, Yanagisawa, Lawson.

*Third Row:* Olson, Cummings, Healy, MacCormick, R. Sessions, D. Sessions, Cody, Ballenger, Woodman, Pennington, Hicks, Lejeune, Vrabec.

*Fourth Row:* Gacek, Yarrington, Benjamin, Norris, Lewy, Snow, Neel, Jako, Brewer, Fee, Johns, Ward.



## MINUTES OF THE EXECUTIVE SESSIONS

### FIRST SESSION — APRIL 10, 1983

The First Executive Session of the 104th Annual Meeting was convened at 8 AM in the Grand Ballroom of the Fairmont Hotel, M. Stuart Strong, MD, Boston, presiding. The following candidates, having been recommended for Fellowship by the Council, were unanimously elected:

#### *To Active Fellowship:*

Jerome C. Goldstein, MD, Albany, New York  
Gerald B. Healy, MD, Boston, Massachusetts  
Julius N. Hicks, MD, Birmingham, Alabama  
Geza J. Jako, MD, Melrose, Massachusetts  
Michael Johns, MD, Charlottesville, Virginia  
Roy B. Sessions, MD, Houston, Texas  
Charles T. Yarrington, Jr, MD, Seattle, Washington

#### *To Emeritus Fellowship:*

Stanton A. Friedberg, MD, Chicago, Illinois  
Robert B. Lewy, MD, Chicago, Illinois  
William C. Thornell, MD, Cincinnati, Ohio  
Russell I. Williams, MD, Cheyenne, Wyoming

Following their election the new Active Fellows were introduced to the Association by their respective sponsors, presented with certificates of fellowship and welcomed by President Strong. The Emeritus members were all presented with a Certificate of Merit recognizing their many contributions to the Association.

The following Fellows were elected as members of this year's Nominating Committee:

Charles Norris, Chairman  
Blair Fearon  
Stanton Friedberg  
Francis LeJeune  
Burton Soboroff

Secretary Myers announced that the banquet would be held at the Plimsoll Club beginning at 6:30 PM, that it would be black tie, and that transportation would not be provided.

### SECOND SESSION — APRIL 11, 1983

The Second Executive Session was opened by President Strong at 8 AM and the report of the Nominating Committee was received from the Chairman, Dr Charles Norris. Those nominated to next year's Council were:

John Lewis	John Kirchner
Gabriel Tucker	Harold Tabb
Loring Pratt	M. Stuart Strong
Eugene Myers	Roger Boles
James Snow	Byron Bailey

The reports of the following officers and committees were submitted and duly accepted:

Report of the Secretary  
Report of the Treasurer  
Report of the Historian-Editor  
Report of the Laryngeal Research Committee

The meeting was then adjourned until the end of the Scientific Session.

At the close of the Scientific Session the Executive Session was reconvened by President Strong. The slate of officers for the Council was unanimously approved by the membership. The Directors organized themselves for the year 1983-1984 as follows:

President: John Lewis, MD  
Vice-President (President-Elect): Gabriel F. Tucker, Jr, MD  
Secretary: Eugene N. Myers, MD  
Treasurer: Loring W. Pratt, MD  
Historian-Editor: James B. Snow, Jr, MD  
First Councilor — John A. Kirchner, MD  
Second Councilor — Harold G. Tabb, MD  
Third Councilor — M. Stuart Strong, MD  
Councilors-at-Large: — Byron J. Bailey, MD  
Roger Boles, MD

Following the organization of the Directors, outgoing President Strong thanked the Council and Fellows for their support during his year and introduced Dr John Lewis, who adjourned the meeting.

## REPORTS

### REPORT OF THE SECRETARY

The membership at the present time is 7 Honorary, 36 Emeritus, 94 Active, and 14 Corresponding, for a total of 151.

The banquet was held at the Plimsoll Club and seemed to be quite successful. This year there was only one donation to the Memorial Fund. We hope that additional donations will be made in the future.

In conclusion I wish to thank President Strong and the other

members of the Council for their support during my first year as Secretary. I also wanted to thank Dr William Tribble and his secretary, Miss Finneyfrock, for the tremendous wealth of information and guidance with which they provided us during this organizational year.

Respectfully submitted,  
Eugene N. Myers, MD  
Secretary

### REPORT OF THE HISTORIAN-EDITOR

As Historian, I have the sad duty to report the deaths of two Emeritus Fellows. Frank Damron Lathrop (elected 1963) served the Association as Secretary from 1968 to 1972, at which time he was elected President, presiding at the 1973 meeting. In 1977 he was elected to Emeritus Fellowship. He died November 14, 1982. Julius Watkins McCall was elected an Active Fellow of this Association in 1952. He was elected First Vice-President in 1961 and to Emeritus Fellowship in 1964. He died last winter.

As Editor, I can report that all papers presented were submitted on time and were in turn published by the *Annals* in the July-August issue (with the exception of one paper which was withdrawn during the editorial process). The papers published in the *Annals* were then combined with the business portions of our meeting and the *Transactions* reached the Fellowship just before Christmas.

As we enter preparation for another volume, one change should be noted in that the *Annals* has requested that papers presented be

subject to the usual review process. To this end, it was required by the President in his acceptance of speakers that they have the manuscripts in Dr McCabe's hands by March 1, 1983. In spite of the fact that this was a new procedure, over half the manuscripts were indeed received by Dr McCabe last month. This has resulted so far in the rejection of two papers by the *Annals*. They will, however, be published as part of our *Transactions*, with the Association bearing the cost of this publication. The cost of last year's *Transactions* was over \$6,000, but less than the cost of the previous year's volume.

We await with interest the outcome of the newly established review process and sincerely hope that it will not only result in a higher standard of published material, but actually contribute to the papers presented at the meetings.

Respectfully submitted,  
Gabriel F. Tucker, Jr, MD  
Historian-Editor

### REPORT OF THE AMERICAN LARYNGOLOGICAL ASSOCIATION GOVERNOR OF THE AMERICAN COLLEGE OF SURGEONS

The American College of Surgeons met in Chicago in October 1982. The Board of Governors received reports from the College officers and were updated on a number of matters of general interest to the College, including reports from the various specialties; the one from otolaryngology was delivered by Dr Stuart Strong, our President.

Subsequent to that meeting, the Advisory Council for Otolaryngology met. Here it should be noted that our Regent, Dr Loring Pratt, was replaced by Dr James Snow, another one of our Fellows. It should also be noted that the dues of the College of Surgeons has been increased from \$225 to \$245. Pertinent to last year's Baker Lecture is a statement from the Board of Regents:

Training programs may be developed in Institutions with proper capability conforming to the standards and review mechanisms established for such programs by appropriate bodies. However, such special interest in training should not be recognized by form of certification or by issuance of a certificate of special competence by a specialty Board or by an accrediting body. However, such recognition may be awarded by the training institution.

Of more recent interest is the action of the Board of Regents at its February 6 meeting, recording their determined opposition to proposed revisions of the Joint Commission for the Accreditation of Hospitals (JCAH) medical staff standards. The proposed revisions were tentatively approved by the JCAH Commissioners on December 11, and, if ultimately adopted, will replace the term "medical staff" with the term "organized staff" and would permit, at the hospital's option, any limited licensed practitioner to admit patients. Final action by the JCAH on these proposed regulations has been deferred pending further discussion at the AMA's House of Delegates next June. I have been assured by the College of Surgeons' office that they will continue to work for the elimination of these proposals. The College Advisory Council for Otolaryngology will meet here in New Orleans next Tuesday.

Respectfully submitted,  
Gabriel F. Tucker, Jr, MD  
Governor, American College of Surgeons

### REPORT OF THE AMERICAN LARYNGOLOGICAL ASSOCIATION RESEARCH COMMITTEE

The research committee met in New Orleans on April 11, 1983. Those present were R. Boles, MD, P. Ward, MD, J. Snow, MD, and J. Fredrickson, MD. Those absent were Arndt Duvall, MD, and Hugh Biller, MD.

Suggestions were made for research speakers for the 1984 meeting. Received by John Fredrickson, MD, was Collin Painter, PhD, Toronto; by Paul Ward, MD, was George Berci, MD,

UCLA; by Roger Boles, MD, was Bjorn Fritzell, MD, Sweden; David Brewer, MD, Syracuse; and James Gould, MD, New York; and by J. Snow, MD, was Bernard Marsh, MD, John Hopkins.

The following research activity in ALA was encouraged:  
1. Continue to include research as distinct part of annual ALA program



2. Direct ALA representation on National Otolaryngology Research Coordinating Committee centralized in AAO/HNS Office which has John Fredrickson, MD, as chairman
3. Publicize the Casselberry Award and award it more regularly than in past
4. ALA seriously consider the feasibility of developing a fund-raising organization which would provide seed money for meritorious research ideas and projects proposed by young investi-

gators (much like DRF in Hearing)

5. ALA seriously consider the feasibility of developing and funding research fellowships in laryngology and phoniatry (much like clinical fellowships of AAFPRS, only for research in laryngology).

Respectfully submitted,  
Roger Boles, MD  
Chairman

## REPORT OF THE TREASURER

### ACCOUNTANT'S REPORT

To the Officers and Directors of the  
American Laryngological Association

The accompanying balance sheets of the general fund and trust funds of the American Laryngological Association as of March 31, 1983, and the related statements of income and retained earnings have been compiled by us. A compilation is limited to presenting in the form of financial statements, information that is the representation of management.

We have examined and verified the underlying data. The reports are on the cash basis method of accounting, and accordingly, an unqualified opinion cannot be expressed. The method of accounting is consistent with that of prior years.

Emil N. Northup  
Certified Public Accountant, PA

March 31, 1983

### STATEMENT OF ASSETS, LIABILITIES AND FUND BALANCES — MARCH 31, 1983

ASSETS	
<i>General Fund:</i>	
Cash (deficit) .....	\$ 119
<i>Trust Fund:</i>	
Current Assets:	
Cash due from General Fund .....	5,192
8 <sup>7</sup> / <sub>8</sub> % Treasury note due 5/30/83 .....	20,060
11 <sup>7</sup> / <sub>8</sub> % Treasury note due 8/15/83 .....	14,981
Certificates of deposit due 6/13/83 .....	109,256
Common stock .....	13,980
<i>Total Assets</i> .....	<u>\$163,588</u>
LIABILITIES	
None	
FUND BALANCES	
<i>General Fund</i> .....	\$ 119
<i>Trust Funds</i> .....	163,469
<i>Total Fund Balances</i> .....	<u>\$163,588</u>

See accountant's letter and notes to financial statements.

### STATEMENT OF RECEIPTS AND EXPENSES — GENERAL FUND FOR THE FISCAL YEAR ENDED MARCH 31, 1983

<i>Receipts:</i>	
Dues .....	\$12,450
Annual meeting .....	10,403
Council meeting .....	814
Sale of <i>Transactions</i> .....	2,066
Interest on NOW checking account ..	330
Miscellaneous .....	122
Total .....	<u>\$26,185</u>
<i>Disbursements:</i>	
Expenses of Annual Meeting:	
Banquet .....	7,246
Miscellaneous .....	81
Council travel and expenses .....	4,645
<i>Transactions</i> expense .....	6,028
General Expenses:	
Printing, postage and supplies .....	1,271
Professional fees .....	1,250
Bond .....	40
Sponsors for Research and	
Contributions .....	2,446
Miscellaneous .....	160
Total .....	<u>23,167</u>
<i>Net Income (Loss)</i> .....	3,018
General Fund Balance	
Beginning of year, April 1, 1981 .....	(2,899)
End of year, March 31, 1983 .....	<u>\$ 119</u>

See accountant's letter and notes to financial statements.

### STATEMENT OF INDIVIDUAL TRUST FUNDS, MARCH 31, 1983

	Fund Balance 4/1/82	Receipts				Fund Balance 3/31/83
		Total	Donations	Invest- ment Income	Disburse- ments	Transfers
Daniel C. Baker, Jr, Memorial Fund .....	\$ 29,441	\$ 2,866	\$ 100	\$ 2,766	\$ 657	\$ 31,650
Casselberry Fund .....	14,180	1,340		1,340		15,520
Johnston Fund .....	13,437	1,270		1,270		14,707
DeRoaldes Fund .....	8,037	748		748	180	8,605
Newcomb Trust Fund .....	5,277	494		494		5,771
Newcomb Prize Fund .....	1,222	113		113		1,335
Research Fund .....	49,696	4,670		4,670		57,075
Memorial Fund .....	28,806	2,709		2,709		28,806
Total .....	<u>\$150,096</u>	<u>\$14,210</u>	<u>\$ 100</u>	<u>\$14,110</u>	<u>\$ 837</u>	<u>\$163,469</u>

See accountant's letter and notes to financial statements.

## GENERAL FUND — RESUME

	1974	For the Year Ended March 31,			1978	1979	April 1, 1978 Through March 15,			
		1975	1976	1977			1980	1981	1982	1983
EXPENSES										
Annual meeting	\$ 5,204	\$ 4,525	\$ 5,664	\$ 3,615	\$ 6,930	\$ 18,391	\$ 9,033	\$ 8,051	\$ 16,195	\$ 7,327
Council	1,800	1,360	1,906	2,042	3,348	4,097	3,972	4,163	3,176	4,645
Transactions	2,833	5,124	4,458	4,824	4,124	6,544	5,358	—0—	12,112	6,028
General	3,279	3,697	2,373	4,585	5,512	6,550	7,434	6,339	8,206	5,167
Totals	13,116	14,706	14,401	15,066	19,914	35,582	25,797	18,553	39,689	23,167
INCOME	14,723	13,284*	16,752*	16,621*	14,788*	21,426	27,257	23,271	28,603	26,185
GAIN (LOSS)	\$ 1,607	\$ (1,422)	\$ 2,351	\$ 1,555	\$ (5,126)	\$ (14,156)	\$ 1,460	\$ 4,718	\$ (11,086)	\$ 3,018

\*Excluding centennial assessments.

See accountant's letter and notes to financial statements.

STATEMENT OF TRUST FUNDS  
FOR THE YEAR ENDED MARCH 31, 1983

## Receipts:

Interest income (Note 2):	
US Treasury notes	\$ 3,556
Certificates of deposit — banks	9,488
	\$ 13,044
Dividends on common stock	1,066
	14,110
Donation:	
Baker fund	100
	14,210

## Disbursements:

Baker fund:	
Award	\$ 657
DeRoaldes Fund Medal	180
	837

Net Income	13,373
Fund Balance, April 1, 1982	150,096
March 31, 1983	\$163,469

\*See accountant's letter and notes to financial statements.

## FUND BALANCES

	General Fund	Trust Fund
MARCH 31,		
1974	9,240	81,410
1975*	7,817	111,075
1976*	10,168	114,564
1977*	11,723	119,548
1978*	6,597	125,095
MARCH 15,		
1979	1,816	130,768
1980	3,469	130,783
1981	8,187	140,591
1982	(2,899)	150,096
1983	119	163,469

\*Excluding centennial assessments.

See accountant's letter and notes to financial statements.

## TRUST FUND INVESTMENTS, MARCH 31, 1983

	Cost	March 10, 1983		Share Value 3/10/83	Shares	Market Value 3/10/83
STOCK PORTFOLIO		High	Low			
Common Stocks						
American Telephone and Telegraph	\$10,790	66 <sup>3</sup> / <sub>8</sub>	65 <sup>3</sup> / <sub>4</sub>	66 <sup>1</sup> / <sub>4</sub>	200	\$13,250
International Business Machines	1,321	102 <sup>5</sup> / <sub>8</sub>	100 <sup>1</sup> / <sub>8</sub>	100 <sup>1</sup> / <sub>4</sub>	40	4,010
McDonnell-Douglas Corp	1,194	47 <sup>7</sup> / <sub>8</sub>	47 <sup>1</sup> / <sub>8</sub>	47 <sup>1</sup> / <sub>8</sub>	165	7,775
McIntyre-Porcupine*	675	24 <sup>1</sup> / <sub>2</sub>	24	24 <sup>1</sup> / <sub>4</sub>	15	364
	<u>\$13,980</u>					<u>\$25,399</u>

	March 31, 1982	March 10, 1983
Common stocks (at cost)	\$13,980	\$13,980
Market value	19,656	25,399
Market in excess of cost	<u>\$ 5,676</u>	<u>\$11,419</u>
Dow Jones Industrials — March 31, 1982		882.77
March 10, 1983		1,120.94

\*McIntyre-Porcupine Mines LTD — Name changed to McIntyre Mines, LTD. Last dividend paid 6/1/78.

See accountant's letter and notes to financial statements.

## \*Notes to Financial Statements

## 1. Accounting Policies

The organization uses the cash basis method of accounting and is a nonprofit entity exempt from Federal and State income taxes.

## 2. Allocation of Investment Income

Interest on US Treasury Notes, Certificates of Deposit, as well as dividends on common stock are credited as income to the Trust Fund.

The Trust Fund income is further allocated to each fund in the ratio the fund bears to the total value of the trust funds at the beginning of the year, except that by action of the Council, January 3, 1976, current income from the Memorial Fund is transferred to the Principal and Retained Earnings of the Research Fund.

Respectfully submitted,  
Loring W. Pratt, MD  
Treasurer



## RECIPIENTS OF THE DE ROALDES AWARD

1928 Dr Chevalier Jackson  
 1931 Dr D. Bryson Delavan  
 1934 Dr Harris P. Mosher  
 1937 Dr Lee Wallace Dean  
 1943 Dr Ralph A. Fenton  
 1949 Dr George M. Coates  
 1951 Dr Arthur W. Proetz  
 1954 Dr Louis H. Clerf  
 1959 Dr Albert C. Furstenberg



1960 Dr Dean M. Lierle  
 1961 Dr Frederick T. Hill  
 1966 Dr Paul H. Holinger  
 1970 Dr Francis E. LeJeune  
 1973 Dr Lawrence R. Boies  
 1976 Dr Anderson E. Hilding  
 1979 Dr Joseph H. Ogura  
 1982 Dr John J. Conley

## RECIPIENTS OF THE CASSELBERRY AWARD

1923 Dr George Fetterolf  
 and Dr Herbert Fox  
 1928 Dr Ralph A. Fenton  
 and Dr O. Larsell  
 1929 Dr Richard A. Kern  
 and Dr Harry P. Schenck  
 1929 Dr Edward H. Campbell

1931 Dr Arthur W. Proetz  
 1934 Dr Anderson C. Hilding  
 1936 Dr Francis E. LeJeune  
 and Dr Joel J. Pressman  
 1939 Dr H. Marshall Taylor  
 and Dr Brien T. King  
 1940 Dr French K. Hansel

1941 Dr Noah D. Fabricant  
 1946 Dr Paul H. Holinger  
 1949 Dr Henry B. Orton  
 1962 Dr Hans von Leden  
 1966 Dr John A. Kirchner  
 and Mr Barry D. Wyke  
 1968 Dr Joseph H. Ogura

## RECIPIENTS OF THE NEWCOMB AWARD

1941 Dr Burt R. Shurly  
 1942 Dr Francis R. Packard  
 1943 Dr George M. Coates  
 1944 Dr Charles J. Imperatori  
 1947 Dr Harris P. Mosher  
 1948 Dr Gordon Berry  
 1949 Dr Gordon B. New  
 1950 Dr H. Marshall Taylor  
 1951 Dr John D. Kernan  
 1952 Dr William J. McNally  
 1953 Dr Frederick T. Hill  
 1954 Dr Henry B. Orton  
 1955 Dr Thomas C. Galloway  
 1956 Dr Dean M. Lierle

1957 Dr Gordon F. Harkness  
 1958 Dr Albert C. Furstenberg  
 1959 Dr Harry P. Schenck  
 1960 Dr Joel J. Pressman  
 1961 Dr Chevalier L. Jackson  
 1962 Dr Paul H. Holinger  
 1963 Dr Francis E. LeJeune  
 1964 Dr Fred W. Dixon  
 1965 Dr Edwin N. Broyles  
 1966 Dr Lyman G. Edwards  
 1967 Dr Joseph H. Ogura  
 1968 Dr Walter P. Work  
 1969 Dr John A. Kirchner  
 1970 Dr Louis H. Clerf

1971 Dr Daniel C. Baker, Jr  
 1972 Dr Alden H. Miller  
 1973 Dr DeGraaf Woodman  
 1974 Dr John J. Conley  
 1975 Dr Francis W. Davison  
 1976 Dr Joseph L. Goldman  
 1977 Dr F. Johnson Putney  
 1978 Dr John F. Daly  
 1979 Dr Charles F. Ferguson  
 1980 Dr Charles M. Norris  
 1981 Dr Stanton A. Friedberg  
 1982 Dr William M. Tribble  
 1983 Dr Harold G. Tabb



## THE MEMORIAL AND LARYNGOLOGICAL RESEARCH FUNDS

The Council earnestly requests that Fellows of the Association give consideration to making a special bequest to these important funds, or to become a Benefactor.

### MEMORIAL FUND DONORS

Dr Daniel C. Baker, Jr  
 Dr John F. Barnhill  
 Dr August L. Beck  
 Dr Gordon Berry  
 Dr William E. Casselberry  
 Dr Cornelius G. Coakley  
 Dr Lee Wallace Dean  
 Dr Arthur W. deRoaldes  
 Dr Fred W. Dixon

Dr George Fetterolf  
 Dr Joseph L. Goodale  
 Dr William E. Grove  
 Dr Gordon F. Harkness  
 Dr Frederick T. Hill  
 Dr George E. Hourn  
 Dr Samuel Johnston  
 Dr James E. Newcomb  
 Dr Henry B. Orton

Dr Lup Q. Pang  
 Dr Lyman G. Richards  
 Dr Burt R. Shurly  
 Dr Lester T. Sunderland  
 Dr H. Marshall Taylor  
 Dr Walter H. Theobald  
 Dr Francis L. Weille  
 Dr Eiji Yanagisawa

### BENEFACTORS

Mrs Sally Sample-Aall  
 Mrs Daniel C. Baker, Jr  
 Dr Edwin N. Broyles  
 Dr Louis H. Clerf  
 Dr Seymour R. Cohen  
 Dr John J. Conley  
 Dr John F. Daly  
 Dr and Mrs Francis W. Davison

Dr Stanton A. Friedberg  
 Dr Thomas C. Galloway  
 Dr Joseph L. Goldman  
 Dr Robert L. Goodale  
 Dr Edley H. Jones  
 Zelda Radow Weintraub  
 Cancer Fund, Inc  
 Dr A. P. Marchessini

Dr Francis H. McGovern  
 Dr Charles M. Norris  
 Dr Samuel Salinger  
 Dr Sam H. Sanders  
 Dr Harry P. Schenck  
 Dr William M. Tribble  
 Dr DeGraaf Woodman

## PRESIDENTIAL ADDRESS

M. STUART STRONG, MD

It is with great pleasure that I welcome you all to the 104th meeting of the American Laryngological Association.

During the past year, it has been a distinct privilege and pleasure to have served as your president. To have served with such a distinguished council was pure delight. I am happy to report that the American Laryngological Association is alive and well! With the addition of seven new active Fellows, to date the membership consists of 96 active Fellows, 40 emeritus, 16 corresponding, and seven honorary. The new Fellows are drawn from several professional arenas: private practice, academia, and group or clinic practice. The original purpose of the American Laryngological Association, to advance and promote the science of medicine and surgery in the upper respiratory tract, will be well

served by the new Fellows; without a doubt, these members are dedicated to excellence in rhinology and laryngology.

The program for the 104th meeting, you will notice, has a particular emphasis on voice; in contrast, many other programs of former meetings emphasized respiration, deglutition, or the ravages of neoplasia. In a small way, it seems as if laryngology is in a position similar to that of otology in the pretympaanoplasty days, when the emphasis shifted to conservation of hearing rather than the control of infection. This year's program will feature methods of measurement and documentation, the pathophysiology of voice disorders, and a plea from the research speaker for more research on the pathogenesis of organic voice disorders. I feel sure you will find the program useful and also enjoyable.



## INTRODUCTION OF GUEST OF HONOR DANIEL MILLER, MD

M. STUART STRONG, MD

It is a rare pleasure to be able to select the Guest of Honor for the American Laryngological Association, and when this opportunity presented itself to me, there was no question in my mind as to who it should be! By way of introduction, I would beg your indulgence in a little nostalgia on my part. I would like you to picture with me a clinicopathologic conference in the conference room of the Mosher Laboratory of the Massachusetts Eye and Ear Infirmary in an October of the 1950s; it was the first occasion in which I, as a young man, attended such a conference accompanied by two of my mentors, Dr Walter B. Hoover and Dr Frank D. Lathrop. I was, of course, anxious to identify two of the greats in laryngology who were in attendance at the meeting, Dr Harris B. Mosher and Dr Leroy A. Schall. Having had these two gentlemen pointed out to me, I noticed a young man in the front row who frequently rose to his feet to comment on the clinical problem under discussion. His questions were always pertinent, his commentary always il-

luminating, and his delivery articulate and eloquent. I recognized Dr Daniel Miller at that time as a gifted and committed otolaryngologist.

Dr Miller's career has been inextricably entwined with the Massachusetts Eye and Ear Infirmary, the Massachusetts General Hospital, and Harvard Medical School, where he is Clinical Professor of Otolaryngology. He has had an interest in the broad field of otolaryngology, but especially in head and neck oncology. He has been Chief of the Head and Neck Clinic at the Massachusetts General Hospital and is presently Chief of the Head and Neck Clinic at the Dana-Farber Cancer Institute. Dr Miller has been President of the American Society of Head and Neck Surgery, the Triological Association, and the American Laryngological Association.

Dan, you have been a good friend and a trusted colleague to me and countless others, you have served otolaryngology well, and today we salute you as the Guest of Honor of the American Laryngological Association.

## GUEST OF HONOR ADDRESS

DANIEL MILLER, MD

Your invitation to me to be your Guest of Honor of the American Laryngological Association is one of the highlights of my professional career. When I recall the stature of the previous Guests of Honor of this Society I truly feel the historical weight of your choice for 1983.

In the past I thought of the Guests of Honor as older, venerable people whose very names frequently caused shudders among our recent resident graduates who took their board examinations from such men. However, they all seem to have mellowed with age and were then considered kindly gentlemen who helped set the stage for the continuing advances in our discipline. Perhaps my misguided belief in my own immortality may test the credence of your choice this year as exemplified by the slide of my two little daughters, Laura Anne, age 7, and Diane Lee, age almost 3, with their mother. To them I owe much for allowing me so much valuable time to pursue some of my more recent clinical investigations for presentation before this Society.

Although time is endless for the pursuit of increasing knowledge in our discipline in medicine, it is racing along behind us, beside us, above and below us. We must all look at the patient now through prismatic eyes, heretofore done in a less complex manner. The discovery of the new biology which has transformed medical education has forced us to view our patients much differently. So many of us view paintings at the museums either from the standpoint of the subject portrayed, the texture and technique of the painting, the colors blended, etc., all giving us different dimensions of what we look at. We must also extrapolate how we view the patient. We must all now see our patients from a greater total picture in depth. We must look at them from a humanistic, socioenvironmental point of view; we must see him or her in the light of the new information now available which makes the biologic human being that we have looked at before an even more complex machine than previously. Its components aren't any longer just cell systems and gross anatomy and physiology. We must see the in-

dividual in the light of the sequences of information such as the macromolecules and micromolecules which interact with each other, the energy-transforming reactions that affect the genetic code of all living organisms, the biochemical reactions that occur in transforming the genetic messages from DNA to RNA and from RNA to other functioning proteins. We must begin to better understand the dynamic state of our bodies' constituent parts if we are to treat disease more efficiently. For example, recent studies demonstrate that the immune system can be altered by long-term tobacco smoking by changing the ratio of T-cells and thus possibly contributing to the pathogenesis of respiratory cancer. Clinical evaluations of the past are now reinterpreted for the future, it would seem. It is these very T-cells which make up 80% of the disease-fighting cells; if they run out of control it may then result in autoimmune diseases, hitherto mysterious diagnostic problems.

This new concept of the intricacies of our bodies should begin to instill fear in many of us. Will we be able to understand and manage that knowledge of the chemical composition of our genes, or will many of us give up before this somewhat frightening knowledge which we find difficult to assimilate and to apply? The so-called halo about the physicians' head now sits precariously. There is just so much we can absorb of this new cascade of information. I envy the medical student and house officer who is now exposed to this myriad of information and can learn to utilize it while picking the wheat from the chaff from the previous learnings and teachings that we older members of the discipline of Otolaryngology-Head and Neck Surgery have tried to pass on to them.

However, let not the new knowledge of the polypeptides or the polysaccharides or prostaglandins, the use of monoclonal antibodies or the recombi-

nant genetic manipulations, etc, sidetrack us from our view of the individual, from the humanistic point of view. The patient is more than cells and systems.

For a brief moment let us look at the otolaryngologist of the future based on this newer knowledge. It is our hope and belief that the newer subset of otolaryngologists will have the ability to learn much of this knowledge and utilize it for the best possible care for their patients. However, let us recognize reality and accept the fact that even today's advanced knowledge is not cemented in perpetuity. Therefore the message must be that we should be able to learn to relate to change no matter what generation we find ourselves in, practicing the art and skills of medicine. Xenophobic nonchalance regarding this new knowledge is no longer an affordable luxury. I close this short dissertation with the feeling that I wish I had 25 years more of this precious life to be part of the evolution of the newer understanding of the human body. However, it is a good feeling to look out over this audience to see so many younger faces of those who will carry on the management of health care in a much more sophisticated and enlightened manner than their predecessors. It hopefully will be a better world because of the concern for the patient by such concerned otolaryngologists and their never-ending spirit of inquiry as exemplified by our scientific program today.

Stuart, it has been a great pleasure for me to be your Guest of Honor and I am truly indebted to you for the privilege of addressing the members and guests of the American Laryngological Association on this important date of April 10, 1983, and, before passing from the scene, to share some of my thoughts regarding the intricacies of intracellular life as it unfolds before us.



# SCIENTIFIC SESSIONS\*

## THE IRRADIATED LARYNX: A SURGICAL DILEMMA

JOHN S. LEWIS, MD

ALVARO VALLEJO, MD

TERMSAK KUSONRUKSA, MD

NEW YORK, NEW YORK

Ionizing radiation administered in curative doses to the larynx for a T1 or T2 lesion may cause considerable local reaction. To a clinician, the mucosal edema, perichondritis, and radiation necrosis may manifest itself for months and years. Local persistence or recurrence of cancer may also be hidden from view, which neither clinical examination, repeated open biopsy, or routine x-ray film may reveal. The authors report four cases of laryngeal cancer in which only sophisticated radiographic diagnosis suggested the presence of recurrent cancer years after radiotherapy, and all of which required total laryngectomy for diffuse submucosal disease. The problem of radiation necrosis was more prevalent during the days of orthovoltage radiotherapy. Diagnosis and management of this problem are discussed.

The diagnostic and therapeutic dilemma of the irradiated larynx has long been a problem to the laryngologist. In 1974 Ward et al<sup>1</sup> presented a paper at the Centennial Conference on Laryngeal Cancer in Toronto in which they pointed out the difficulty with postradiation edema lasting more than 6 months following full-dose radiotherapy administered from 5,700 to 7,200 rad. Only two of the 11 cases that proved to have recurrent carcinoma were salvaged surgically in the T3 and T4 groups. The difficulty of obtaining a positive biopsy was stressed, and the authors demonstrated microscopic nests of tumor cells present in the endolarynx, or the edema of the larynx so protean that the carcinoma was deep to the biopsy.

During the past 2 years we have been impressed with the number of patients referred for a second opinion following radiotherapy for cancer of the larynx. These patients usually complained of persistent hoarseness, dysphagia, and otalgia, and had received cobalt 60 radiotherapy for T1 and T2 lesions of the glottic larynx. A few patients with supraglottic carcinoma including epiglottic and pyriform recess were also examined. These events prompted us to look at our own experience with four particularly difficult patients with T1 and T2 epidermoid carcinoma of the larynx who had been irradiated many years before and subsequently required total laryngectomy.

A classic on this subject was published in 1982 by Keene et al from the University of Toronto.<sup>2</sup> Histologic studies of 265 laryngeal whole-organ specimens obtained following total laryngectomy or

at autopsy showed the incidence and location of chondronecrosis and osteomyelitis in both irradiated and nonirradiated cases. In their series chondronecrosis occurred in only one of 41 early (T1 and T2) tumors. In 143 advanced tumors (T3 and T4) treated with radical radiotherapy and containing residual carcinoma, 27% had evidence of significant radionecrosis compared with 24% of those not irradiated. The arytenoid cartilage was most frequently involved when chondronecrosis occurred in association with radiotherapy; age, sex, tumor grade, and previous laryngeal surgery did not appear to be significant factors in the development of necrosis in irradiated patients. The incidence of clinical perichondritis appeared to be low, but histologic chondronecrosis and osteomyelitis were present in 26% of all the larynges studied, and particularly in those treated with advanced supraglottic cancer.

### CASE REPORTS

*Case 1.* A 53-year-old man developed glottic carcinoma, and clinical examination at another institution revealed a T2 lesion of the left vocal cord. He was irradiated, the factors were cobalt 60, approximately 6,200 rad tumor dose administered through two opposing ports. He was referred 2 years after complaining of throat pain and hoarseness of about 3 month's duration. Clinical examination showed swelling of the left hemilarynx, without neck nodes. Direct laryngoscopy showed marked swelling of the left ventricular band, and multiple biopsy specimens had acute and chronic inflammation. Four months later the patient had persistent symptoms, laryngoscopy and biopsy were repeated, but no evidence of malignancy was found. Nine months from the first visit, the swelling of the left hemilarynx increased and a node was now palpable in the left midjugular chain. Tomograms showed a submucosal mass involving the left hemilarynx. Total laryngectomy and left radical neck dissection was carried out without

From the Department of Otolaryngology and Radiology, St Luke's-Roosevelt Hospital Center, New York.

Presented at the meeting of the American Laryngological Association, New Orleans, April 10-11, 1983.

REPRINTS — John S. Lewis, MD, Department of Otolaryngology and Radiology, St Luke's-Roosevelt Hospital Center, 428 West 59th St, New York, NY 10019.

\*The papers on pages 17-99 were published in the *Annals of Otolaryngology, Rhinology, and Laryngology*, September-October 1983; the paper beginning on this page and those on pages 100-112 are published here for the first time. The discussions that followed the papers are on pages 113-120.

event. The tumor was submucosal, involving the left false cord, with supraglottic extension to the pyriform recess. The pathology report indicated deeply infiltrating squamous carcinoma of the larynx with metastases to all levels of the jugular chain and soft tissue of the neck, and vascular permeation. Postoperative radiotherapy was given to the dissected nonradiated neck. The patient is alive and well 8 months following his surgery.

*Case 2.* A 47-year-old woman presented with soreness of the throat and dysphagia of 4 months' duration. Four months previously she had had a hysterectomy for uterine carcinoma. Clinical examination showed a T2 lesion in the right pyriform recess. Biopsy was positive for squamous carcinoma. She required surgery and received approximately 6,000 rad tumor dose to the involved area. Following radiotherapy she developed edema of the larynx with hoarseness. A node appeared in the right neck 14 months after the radiotherapy which on needle biopsy was positive, and a right neck dissection was performed. The larynx was examined at the time of surgery and biopsy of the larynx was negative. Esophagogram and laryngeal tomograms were performed and were negative. Twenty months after her radiotherapy she had increased swelling of the right hemilarynx, and a CAT scan of the larynx was performed that suggested the presence of recurrent tumor. Total laryngectomy was carried out without a positive biopsy. Extensive submucosal carcinoma was present in the right hemilarynx with involvement of the posterocoid area and penetration of the right thyroid ala. She healed per primam and is 1 year postlaryngectomy.

*Case 3.* A 76-year-old man presented with a T1 lesion of his right vocal cord for which he received approximately 6,000 rad cobalt 60 radiotherapy to the larynx. Four years later he developed a tight feeling in his throat with increasing respiratory difficulty. He appeared to have edema of the larynx with a ragged-appearing right vocal cord. Direct laryngoscopy was performed and biopsy of the cord was negative. Tomograms of the larynx and trachea suggested a tracheal tumor, but repeat direct laryngoscopy showed no pathological condition in the trachea but in the subglottic region which was positive for carcinoma. A total laryngectomy was performed revealing submucosal involvement of the entire larynx. The postoperative course was uneventful and he is 9 months postlaryngectomy.

*Case 4.* A 52-year-old woman had been radiated 20 years previously for carcinoma of the larynx. She had a T1 lesion of the right vocal cord and received 6,200 rad cobalt 60 treatment. Because of subglottic and glottic stenosis she underwent a left arytenoidectomy and tracheostomy. The patient could not be decannulated, and when examined 4 months later, had completed subglottic and glottic stenosis. A total laryngectomy was carried out. She developed an excellent esophageal voice and is asymptomatic 9 years later. The laryngeal specimen showed necrosis of the thyroid cartilage with stenosis, but no evidence of cancer was present.

## DISCUSSION

The rationale for choosing radiation therapy in the treatment of squamous cell carcinoma of the larynx lies in the ability to eradicate the disease and yet preserve function. Cure can be accomplished by irradiation alone in the majority of early glottic and supraglottic tumors (T1 and T2), reserving surgery for persistent or recurrent disease. With this policy, preservation of the voice can be accomplished. Should radiotherapy fail, curative surgery, in many cases only partial laryngectomy, is still possible without an unusual rate of complications.<sup>3</sup>

With the relatively high dose required to control squamous cell cancer of the larynx, there is always the risk of inducing radiation necrosis and/or edema. Fortunately, the incidence of these compli-

cations is small when proper patient selection, dose fractionation, technique, and treatment planning are employed.

Normal cartilage covered by normal mucosa can tolerate high doses of radiation as long as infection or trauma do not occur. Either infection or trauma may precipitate a response in the irradiated cartilage, resulting in edema, perichondritis, cartilage necrosis, and sequestration of the entire irradiated tissue. These complications are most likely to occur if the laryngeal lesion is far advanced, in cases of deeply infiltrating tumors with extensive ulceration, when there is radiographic evidence of involvement of the thyroid cartilage by tumor, or if surgery, such as partial laryngectomy, preceded the irradiation.

The two most important factors that influence the development of laryngeal edema and cartilage necrosis with the use of irradiation are the size of the treatment field and the dose-time relationship of the treatment program. Necrosis will be most frequent after irradiation of large lesions which require large treatment portals. The incidence of postradiation laryngeal cartilage necrosis can be correlated with treatment volume, although this is a direct reflection of tumor site and extent. Fletcher and Klein<sup>4</sup> found an increased frequency of mucosal reaction when the treatment portal size exceeded 35 cm. Most studies show that the incidence of laryngeal edema and necrosis increases significantly with increase in dose or shorter treatment time. Fletcher and Klein demonstrated that when doses of 4,850 rad delivered in daily treatment over 4 weeks were increased to 5,500 rad in 4 weeks, the complications of the treatment program, ie, edema or necrosis, were doubled (three out of 74 patients to eight out of 73 patients).

Since higher total dosage and larger field sizes are used for more advanced lesions, it is not surprising that the incidence of laryngeal edema and necrosis also increases with the stage of the disease. It is for this reason that surgery is the preferred treatment method for the most advanced lesions (T3 and T4), since the high dose required to control such lesions will produce an unacceptable rate of complications, defeating the main reason for selecting radiation therapy as the treatment of choice, which is the preservation of voice.

Even in the treatment of favorable lesions and with the use of meticulous technique, some degree of laryngeal edema can appear by the end or following a course of curative radiotherapy. In the majority of cases the edema is temporary and slowly subsides. The continued use of excessive amounts of tobacco or alcohol and the injudicious use of the voice can act as irritants, worsening the severity of the edema. However, persistent or progressive edema in a significant percentage of cases may represent persistent or recurrent disease. In the



study of Fu and coworkers,<sup>5</sup> laryngeal edema persistent for more than 3 months following radiotherapy developed in 38 out of 247 (15.4%) patients irradiated for carcinoma of the glottic larynx. In 17 (44.7%) of these patients, the laryngeal edema was associated with persistent or recurrent disease, although only 25.4% of all the patients in whom treatment failed had laryngeal edema.

The management of the patient with persistent edema of the larynx following definitive radiotherapy is extremely difficult. Direct and indirect laryngoscopy are usually not helpful since the mucosa in an edematous larynx may appear smooth and intact, and only when deep biopsies are performed is tumor found in the submucosa. Biopsy of the superficial tissues may not be representative and multiple biopsies may be necessary to obtain a histologic confirmation of persistent tumor. These biopsies, however, are dangerous in the heavily irradiated larynx since the trauma may aggravate the edema and increase the risk of chondronecrosis. In our experience, radiographic evaluation of the irradiated larynx is of little value in the differential diagnosis between radiation damage and persistent or recurrent disease.

A reasonable policy in the management of the patient with postirradiation laryngeal edema is to adopt an initially conservative attitude, recommending voice rest, urging discontinuation of alcohol and cigarette consumption, considering the use of antibiotics and steroids if infection is suspected, and closely observing with periodic follow-

up examinations. If there is no improvement with these conservative measures, and there is a strong suspicion of recurrent or persistent disease, direct laryngoscopy and biopsies are carried out in an attempt to confirm the presence of cancer, followed by definitive surgery. A total laryngectomy may be necessary even in the absence of a positive biopsy. Surgery has come to be the treatment of choice for the patient with severe edema or necrosis as well as for those with obvious postradiation recurrent or persistent disease.

In our small series of four cases, three larynges were removed and confirmed the suspicion on clinical grounds that gross recurrent cancer was present 20, 24, and 48 months after the T1 and T2 carcinoma had been irradiated. In the fourth case a suspicion of recurrent carcinoma was present, but the patient also developed laryngeal stenosis and an elective total laryngectomy was carried out. No cancer was found in this case. In all of our cases radionecrosis of the thyroid cartilage and arytenoids was present.

The laryngeal surgeon must be concerned about the possibility of recurrent tumors in the symptomatic patient with persistent laryngeal edema. Although there are medical-legal reservations about removal of a larynx without a preoperative or intraoperative endoscopic biopsy, there are strong clinical grounds for performing an elective total laryngectomy. Surgical debridement of necrotic cartilage and bone has no place in the management of the irradiated larynx.

#### REFERENCES

1. Ward PH, Calcaterra TC, Kagan AR. The enigma of postirradiation edema and recurrent or residual carcinoma of the larynx. *Laryngoscope* 1975; 85:522-9.
2. Keene M, Harwood AR, Bryce DP, Van Nostrand PAW. Histopathological study of radionecrosis in laryngeal carcinoma. *Laryngoscope* 1982; 92:173-80.
3. Ballantine AJ, Fletcher G. Surgical management of irradiation failures of non-fixed cancers of the glottic region. *AJR* 1974; 1:164-8.
4. Fletcher G, Klein R. Dose-time-volume relationships in squamous cell carcinoma of the larynx. *Radiology* 1964; 82:1032-42.
5. Fu K, Woodhouse R, Quivey J, Phillips T, Dedo H. The significance of laryngeal edema following radiotherapy of carcinoma of the vocal cord. *Cancer* 1982; 49:655-8.

# GLOTTOGRAPHIC MEASUREMENT OF VOCAL DYSFUNCTION

## A PRELIMINARY REPORT

DAVID G. HANSON, MD

BRUCE R. GERRATT, PHD

PAUL H. WARD, MD

LOS ANGELES, CALIFORNIA

Objective measurement of vocal function is important in evaluating phonatory disorders, planning treatment, and documenting the effects of therapy. Glottographic measurement, ie, measures that describe glottal movement, can be performed and analyzed relatively easily, and can be related to the pathophysiology of vocal dysfunction. In our clinic, simultaneous recording of acoustic, photoglottographic and electroglottographic signals is being used in the evaluation of patients with voice disorders associated with neurologic impairments. Our experience with these measures indicates that they may provide detailed information about the vibratory patterns of the vocal folds, which appears to differentiate some phonatory characteristics among patients with differing types of disorders.

### INTRODUCTION

Historically, physicians have relied on two basic techniques in the assessment of laryngeal pathology: listening to the voice and viewing the larynx with a mirror or other device. While much can be learned by the perceptual evaluation of voice quality, these judgments often are unreliable in a clinical setting. Although careful visual examination is of fundamental importance, particularly in the case of anatomical abnormalities, indirect laryngoscopy is limited by lack of objective documentation. Normal-speed cine or video documentation of the laryngoscopic examination allows the examiner to review the movements of the laryngeal structures at a slightly reduced speed,<sup>1</sup> but fine details of vocal fold vibration which are intimately related to voice production are not captured by these techniques.

Other means of measuring vocal function can provide more objective information. Acoustic measurements, such as perturbation analysis of frequency,<sup>2,3</sup> and amplitude<sup>4</sup> of the acoustic voice signal and various spectral measures of signal to noise,<sup>5-7</sup> provide reliable information which has been related to listener evaluation of roughness, breathiness, and other deviant vocal qualities. Although acoustic measurements are important clinically applicable techniques, they do not necessarily have a direct physiological correspondence to abnormal glottal activity.<sup>8</sup> Aerodynamic measures such as glottal air flow and subglottal air pressure offer another perspective on voice production from which some inferences on abnormal glottal configurations can be made. These measures also have been reported to be related to listener ratings of deviant voice dimensions.<sup>9</sup> Electromyographic recording of laryngeal muscle activity has provided important and useful information about the physiology of

specific muscles during phonation. However, while there are special clinical applications for electromyography, this technique has not been generally accepted as a clinical tool.

Measurements that can be directly related to the pathophysiology of laryngeal behavior are highly desirable. Since phonatory dysfunction usually manifests itself in abnormal oscillatory movements, the measurement and analysis of the vibratory pattern of the vocal folds has the potential to provide detailed information on the pathophysiology of the vocal folds during phonation. Movement of the vocal folds can be observed by ultra-high-speed filming (4,000-10,000 frames/s). Frame-by-frame analysis can yield measures such as glottal area and excursion of selected points on the visible surface of the vocal folds. Such measures provide valuable information to help understand the pathophysiology of individual patients. Although high-speed filming does provide useful data, it is technically difficult to use with untrained subjects or patients, and is especially limited by the great time and expense of frame-by-frame data analysis. In fact, the difficulties of this method are so great that over 40 years after first being used, it is estimated that not more than five minutes of ultra-high-speed film of vocal fold vibration have been analyzed in detail.<sup>10</sup>

As a rapid and relatively inexpensive alternative to high-speed filming, glottographic techniques have received considerable attention in the study of normal laryngeal activity. The analysis of glottal waveforms, ie, waveforms that describe glottal movement during phonation, has potential for measuring vocal fold activity with little discomfort to the subject. In addition, data analysis can be performed much faster than by the frame-by-frame method of analysis used in high-speed filming.

From the Veterans Administration Medical Center (Hanson, Gerratt), and Division of Head and Neck Surgery, School of Medicine (Hanson, Gerratt, Ward), University of California, Los Angeles. This work was supported by Veteran's Administration medical research funds and NIH grant NS17115. Presented at the meeting of the American Laryngological Association, New Orleans, April 10-11, 1983.

REPRINTS — David G. Hanson, MD, 691W/112C, VA Medical Center, Wilshire and Sawtelle Boulevards, Los Angeles, CA 90073.





sustain phonation at specific pitch and loudness levels. In this situation, patients are asked to sustain phonation at normal conversational levels and lowest and highest pitches at low, normal and high levels of loudness.

The signals from the electroglottograph, photoglottograph, and microphone are recorded on FM channels of an instrumentation recorder (Tandberg, model 115D). After each subject's recording, a 100-Hz triangular wave is amplified and fed to a loudspeaker placed 5 cm in front of the microphone. This tone is recorded as a sound pressure level calibration signal for each subject.

**Data Analysis.** Representative, stable, 1-second portions from the middle of vowel productions are selected for analysis. A pulse is then placed at the beginning of these segments on another channel of the instrumentation recorder as a trigger for analog-to-digital conversion. Each of the three signals on the FM channels are then low-pass filtered (Krone-Hite, model 3343) at 3 kHz, digitized at 10,000 times/s, and stored in disk memory of a LSI 11/23 computer (DEC). Since the digital sampling of each signal begins at the same place on the tape, synchronization of all three signals is assured.

A general purpose, custom designed software package (MAP) is used to display, edit, and perform the necessary calculations on the acoustic EGG and PGG waveforms. First, the EGG and PGG signals are differentiated in order to derive their velocities, and all four waveforms are displayed simultaneously on a video terminal.

For appropriate interpretation of the glottographic waveforms, it is helpful to know where along each waveform the glottis first opens and where it first closes. The precise moment of opening of the glottis may be difficult to define by PGG alone,<sup>19,20</sup> particularly in patients with abnormal vocal cord posture. For example, it appears that in many patients with Parkinson's disease, complete vocal cord closure does not occur, as in case 1. In order to make comparisons between temporally related events among patients, the point of opening on the PGG waveform was defined, for the purpose of the measurements demonstrated here, as the time corresponding to the peak of opening velocity of the differentiated EGG (DEGG) signal. Krishnamurthy et al<sup>21</sup> found that the peak DEGG velocity during opening corresponded very closely to the exact moment of visible upper vocal cord opening on simultaneously filmed ultra-high-speed film, and that the peak of closing EGG velocity occurred at the point of visible upper vocal cord closure. Since each of the displayed waveforms has the same time base, the peak velocities of opening and closing were related to points on the EGG and PGG signals by projection of straight lines perpendicular to the x axis, from the DEGG waveform. Patients with Parkinson's disease who do not have complete cord closure may also have a poorly defined peak opening velocity in the EGG, but usually a peak is present. Thus the timing measurements represent "most open phase" and "most closed phase" as

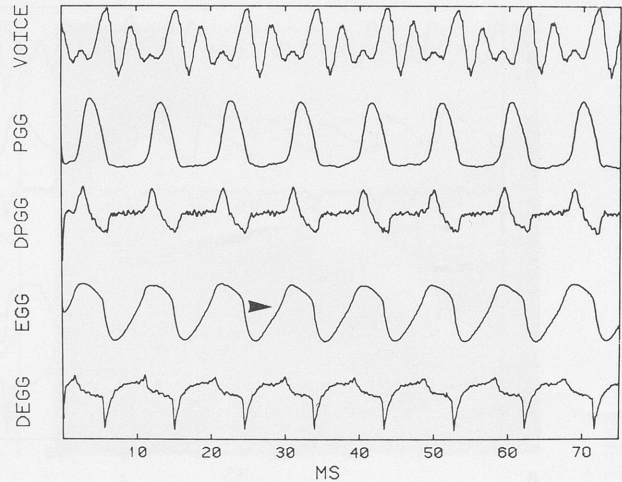


Fig 2. Simultaneous display of acoustic (voice), photoglottographic (PGG), differentiated photoglottographic (DPGG), electroglottographic (EGG), and differentiated electroglottographic (DEGG) signals of vowel production from 35-year-old man with normal voice.

defined by the maximum peaks in opening and closing velocities of the DEGG. In the case where opening is very poorly defined, this definition may be somewhat inaccurate. We are evaluating a method using computer-triggered stroboscopy to provide more accurate details of glottal opening. This method will be reported separately.

Measurements of various amplitudes, times, and velocities of the waveforms are then made. Some formulas for these measurements are presented in the Appendix. A number of duration measures are computed from the PGG. These include the time from moment of opening, as defined by the peak in opening velocity in the DEGG, to the peak of opening and the time from the peak in opening to the moment of closure, again defined by the peak in the closing velocity from the DEGG. The fundamental frequency, the open quotient (duty cycle), speed quotient,<sup>22</sup> and fundamental frequency perturbation<sup>3</sup> are calculated from these duration values.

Another perturbation measure, the PGG amplitude fluctuation, was chosen to portray the cycle-to-cycle variability in light transmitted through the glottis. In addition, measures were developed to assess the magnitude, symmetry, and variability in glottal opening and closing slopes. First, the means of the maximum opening and closing velocities are measured from the differentiated PGG (DPGG) waveform. Next, a peak velocity quotient is calculated to assess the symmetry of the opening and closing slopes. The closer this value approaches unity, the more symmetrical the slopes. Finally, the cycle-to-cycle variability in this quotient, peak velocity fluctuation, is computed to measure the stability in the opening and closing velocities.

## CASE REPORTS

The Table presents some representative results of the time, amplitude, and velocity measures in a normal subject and three patients with normal larynges who have distinct phonatory abnormalities. These representative patients were selected because they appear, on the basis of clinical evaluation and laryngoscopy, to have distinctly different phonatory problems.

For purposes of comparison with the case report waveforms, data from a 35-year-old man with a normal voice, phonating at an Fo of 106 Hz and an intensity level of 90 dB SPL, is presented in Fig 2. The relatively high intensity values found in these recordings can be attributed in part to the 5-cm microphone distance which was used during the recording session. The acoustic signal (voice) shown in Fig 2 is quite stable from cycle to cycle. It lags slightly because of the time it takes for the acoustic

## TIME, AMPLITUDE, AND VELOCITY MEASURES

Measure	Normal Subject	Case 1	Case 2	Case 3
Fundamental frequency (Hz)	106.00	119.00	158.00	197.00
Mean period (ms)	9.43	8.40	6.31	5.70
Mean frequency perturbation	0.13	0.35	0.13	0.15
Frequency perturbation ratio	3.27	41.67	19.81	29.48
Open quotient	0.44	0.84	0.42	0.55
Speed quotient	1.13	5.20	2.66	1.90
Lateral excursion/entire cycle (%)	23.00	71.00	27.00	31.00
Medial excursion/entire cycle (%)	21.00	14.00	12.00	23.00
PGG amplitude fluctuation ratio	30.74	114.82	55.18	362.59
Peak velocity quotient	0.95	1.29	0.98	1.12
Peak velocity fluctuation ratio	73.48	72.77	150.93	436.09



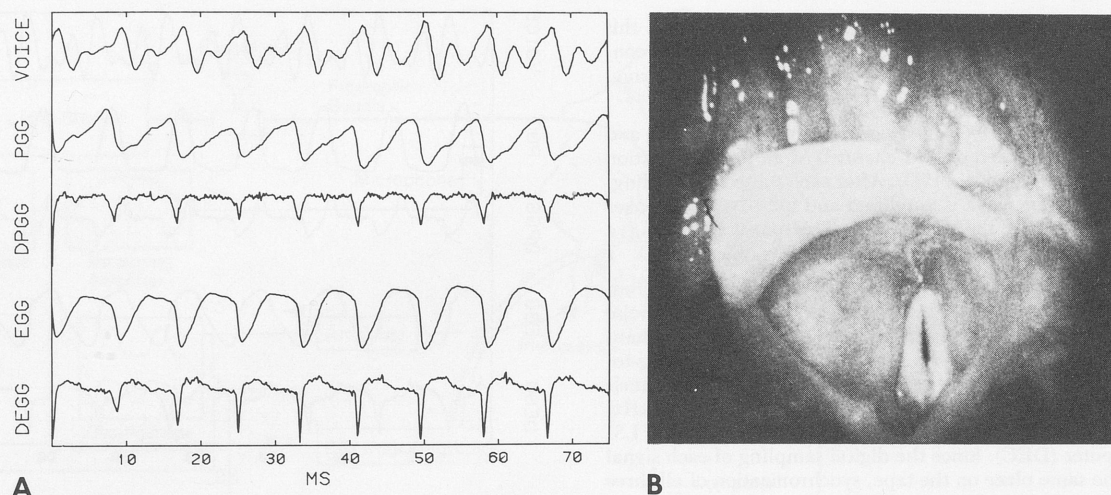


Fig 3. (Case 1) Production of vowel /i/ by 72-year-old man with Parkinson's disease. A) Simultaneous display of acoustic (voice), photoglottographic (PGG), differentiated photoglottographic (DPGG), electroglottographic (EGG), and differentiated electroglottographic (DEGG) signals. B) Reproduction of single 16 mm-frame taken from cine photography of larynx at 12 frames/s.

energy to travel from the glottis, through the vocal tract, to the microphone.

The PGG waveform is similarly stable in normal subjects. Increased light transmission during glottal opening is represented in the PGG waveform by increased voltage. As the vocal folds begin to separate, there is a sharp upward deflection of the waveform. Maximum opening corresponds to the peak, while the beginning of glottal closure is signalled by the sharp downward deflection. Return to the baseline is associated with maximum glottal closure which can take up a considerable proportion of time during a complete glottal cycle in an individual with normal phonation. The shape of the area function peaks derived from PGG is somewhat between a half sinewave and a triangular wave, as would be predicted by the Flanagan-Ishizaka two-mass model.<sup>23</sup> Opening and closing velocities are relatively symmetrical and repeat regularly, indicated by the similarity in amplitude of the peaks in the DPGG waveform of this representative normal subject.

Complementary information is contained in the EGG waveform. Increased impedance occurring as medial vocal fold contact decreases also is represented by increased voltage in the EGG waveform. Portions of the EGG waveform have been related to the sequence of physiological events occurring along the glottal cycle.<sup>24</sup> The lowest point on the waveform corresponds to the most closed period when the vocal folds are compressed at their medial edges. The waveform begins to rise as the lower margins of the vocal folds begin to separate. At the discontinuity in the slope of the waveform, ie, a slight indentation at the large arrowhead in Fig 2, the upper margins of the vocal folds probably first open. It is interesting that the point immediately above this indentation, as the slope begins to rise more steeply, corresponds in time to the point on the PGG waveform signalling the start of a glottal opening phase in the cycle. Following this ascent, there is a short, relatively flat region corresponding to the period when the vocal folds are maximally apart. The slope then descends rather slowly, a period associated with medial adduction of the vocal fold margins, until the waveform falls steeply to the baseline. The instant of glottal closure is probably close to the point corresponding to the minimum of the DEGG waveform.<sup>21</sup> In abnormal phonation, these physiological distinctions may be more difficult to make.

The waveform seen in this example corresponds closely to other normal subjects that we have recorded. The exact waveform shapes vary, of course, with frequency and intensity; however, the basic features described above are present in normal modal phonation. The normal range of waveform characteristics and their derived measures remain to be described for a large population of subjects to account for normal variations and changes with age and sex.

#### CASE 1

Data from a 72-year-old man with Parkinson's disease, phonating at an Fo of 119 Hz and an intensity level of 76 dB SPL, is shown in Fig 3A. The patient's voice is breathy, weak, and lacks normal pitch and loudness changes. The position of the patient's vocal cords is seen in Fig 3B, taken from a single frame of cine film during phonation of the vowel /i/.

The PGG waveform is markedly different from normal. It remains at the baseline for only a short proportion of the cycle, demonstrated in the abnormally high open quotient value (Table). In fact, of the entire glottal cycle, only 15% of the time was spent in the "most closed period." The opening portion takes up 71% of the entire cycle, while the closing phase takes up only 14%. In addition, the maximum and minimum intensity of light transmission varies from cycle to cycle, as measured in the PGG amplitude fluctuation ratio, suggesting variation in degree of maximum glottal closure and opening across cycles. The opening and closing slopes are rather asymmetrical, a condition reflected in the peak velocity quotient. In addition, waveform shape varies widely from cycle to cycle, suggesting marked variability in the control of vocal fold posture.

The EGG and DEGG waveforms indicate less easily identifiable segments for physiological interpretation. The rising slope is constant, without the indentation described in the characteristic EGG waveform of the illustrated and other normal speakers. The flat section is wider, indicating a longer period of maximal glottal separation. The waveform then descends to baseline with a constant slope, instead of a gentle descent followed by a steep roll-off, observed in the normal case. One interpretation of this pattern is that the vocal folds move toward the midline, but do not make complete contact at their medial edges. Consequently, the rising and falling slopes lack the discontinuities associated with the medial contact of the upper and lower vocal fold margins occurring during normal phonation. The overall picture is one of little or no glottal closure, allowing the breathy escape of air through the glottis.

**Comment.** The waveforms generated from the phonation of this patient with Parkinson's disease are quite different from normal. Furthermore, they deviate from normal patterns in a manner that is predictable from observation of the phonatory posture of the patient's larynx during phonation. His vocal folds remain bowed during phonation. There is a visibly greater than normal glottic gap during phonation. This correlates with breathy voice production, short phrasing of speech, and decreased ability to sustain phonation. This basic appearance of phonatory posture is observed in a majority of patients with Parkinson's disease that we have studied with cine laryngoscopy.<sup>25</sup> The recorded glotto-

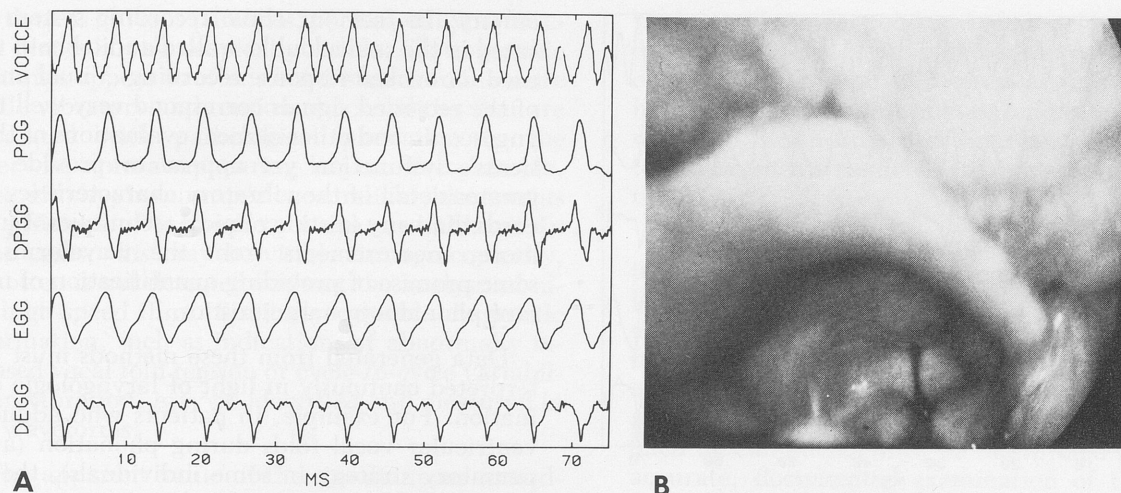


Fig 4. (Case 2) Production of vowel /i/ by 52-year-old man with spastic dysphonia. A) Simultaneous display of acoustic (voice), photoglottographic (PGG), differentiated photoglottographic (DPGG), electroglottographic (EGG), and differentiated electroglottographic (DEGG) signals. B) Reproduction of single 16 mm-frame taken from cine photography of larynx at 12 frames/s.

graphic signals correlate well with the laryngoscopic examination in this patient, and in others that we have examined with these methods. The lack of effective closure is documented in both the PGG and the EGG signals.

#### CASE 2

Waveform data from a 52-year-old man with spastic dysphonia of the adductor type, phonating at 158 Hz at an intensity level of 95 dB SPL, is presented in Fig 4A. The patient's phonatory and speech abnormalities are typical for mild to moderate spastic dysphonia. He has moderate strain-strangled quality during most of his phonation. He demonstrates particular difficulty with the initiation of phonation in voiced phonemes occurring in the initial position of words. Laryngoscopic examination demonstrates an appearance which is typical of adductor spasticity. Laryngeal posture during vowel production in this patient is pictured in Fig 4B. There is hyperadduction of the true cords and contraction of the supraglottal musculature.

The PGG waveform shows relatively long closure periods during the glottal cycle, a condition confirmed by the slightly smaller open quotient than that of the normal individual. Actually, 61% of the entire cycle is spent in glottal closure. The greatest difference from normal among the duration measures is the speed quotient, caused primarily by the abnormally short closing phase. In fact, of the entire cycle, only 12% of time is spent in medial excursion of the vocal folds. This pattern may reflect increased tension in the vibrating folds as compared to normal. The small indentation in the rising slope of the EGG signal described in the normal case is much more pronounced in all of the cycles portrayed in Fig 4B. This event can be identified as a notch in the upper segment of each cycle of the DEGG signal. There is no relatively flat area at the top of the peaks in the EGG waveform, indicating the short duration of maximum glottal opening. The impedance reaches a peak and then drops sharply during closure, in contrast to the normal pattern of slow followed by quick change in velocity. Again, the visible changes in the recorded waveforms correspond well with the pathological conditions in this case.

*Comment.* The data from this patient's phonation are quite different from those of the patient with parkinsonism. This is expected since the two cases represent somewhat opposite extremes in phonatory posture. This patient's voice sounds strained and at times strangled, while the patient with Parkinson's disease has a voice that is weak and breathy. These perceived vocal characteristics appear to relate to greater than normal tension in vocal fold vibration, on one hand, versus incomplete glottic closure on the other, as identified in the respective glottographic recordings of these two patients.

The waveforms presented in Fig 4A represent this patient's "best" voice. Although the voice sounds tensed during this sustained vowel production, the patient does not demonstrate the spasmodic and effortful "squeezing" of the glottis that occurs during spontaneous speech production. Nevertheless, these glottographic signals are quite visibly different from those of normal speakers, and seem to correlate well with laryngoscopically documented spastic function during phonation.

#### CASE 3

Data from a 39-year-old man who suffered severe acute arsenic poisoning 7 years prior to this examination is represented in Fig 5. He is phonating at 197 Hz at an intensity level of 87 dB SPL. The patient is confined to a wheelchair and has severe loss of tactile, vibratory, and proprioceptive sense throughout his body. His voice is distinctly abnormal and is best characterized as harsh and tremulous. Attempts at prolonged phonation produced marked variation in quality, pitch and intensity, and there were periods of diplophonia and vocal fry. This segment is taken from a period of phonation in which the voice sounds diplophonic, ie, two distinct tones are apparent to the ear.

The peaks in the PGG waveform vary widely in amplitude and shape; however, this variability seems to occur in a regular fashion across every five cycles. In other words, every fifth cycle appears to be similar in shape. This impression of variability is confirmed in the extremely large fluctuation values. The PGG amplitude fluctuation ratio is over 11 times as great as that for the normal individual. Since little vertical laryngeal movement was observed laryngoscopically during this phonation, we assume that these changes in light intensity correspond to variation in maximum glottal opening from cycle to cycle. Peak velocity fluctuation ratio is similarly much larger than this measure in the normal individual, confirming the visibly large changes in the symmetry of opening to closing slopes. In addition, the lack of a flat segment at the baseline indicates that the period of glottal closure is short.

The EGG signal also varies in a five-cycle pattern. There is little or no flat segment at the top of the peaks, indicating a very short or incomplete period of glottal opening. Additionally, the point of minimal impedance varies from cycle to cycle, suggesting a noticeable variability in degree of medial vocal fold contact during glottal closure.

*Comment.* Arsenic poisoning is known to affect the nervous system, with particular loss of peripheral sensory function.<sup>26</sup> This patient evidences marked loss of phonatory control. The waveform pattern that recurs over several cycles correlates with listener perception of diplophonia. Such a pattern conceivably could re-



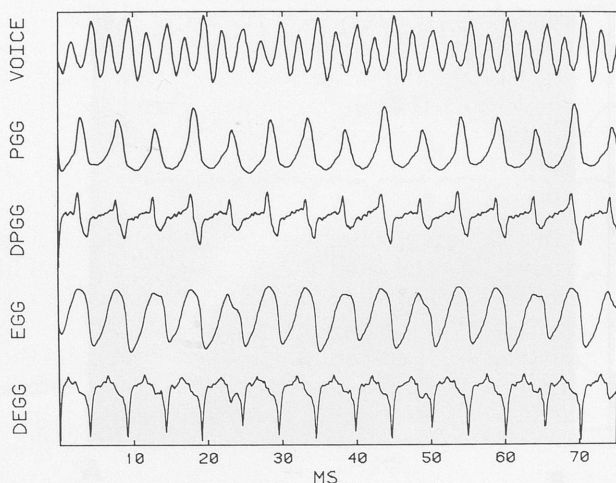


Fig 5. (Case 3) Simultaneous display of acoustic (voice), photoglottographic (PGG), differentiated photoglottographic (DPGG), electroglottographic (EGG), and differentiated electroglottographic (DEGG) signals from vowel /i/ produced by patient poisoned by arsenic.

sult from vibration of each vocal fold at different frequencies or by the generation of subharmonic frequencies when two or more natural tissue modes are excited in the same vocal fold.<sup>27</sup> This is an example where high-speed filming or waveform-triggered stroboscopy would clarify understanding of the vibratory mode which results in this perceived voice characteristic.

## DISCUSSION

While the methods described here have been used primarily for the study of the normal voice, these methods are potentially of great value to the clinical laryngologist. Laryngologic surgery has evolved from basically lifesaving operations, which often left significantly disturbed phonatory function to sophisticated conservation and reconstructive techniques. For example, a number of innovative surgical approaches recently have been reported to improve neuromuscular function in certain laryngeal disorders. These procedures are being performed and evaluated by a number of individuals. Assessment of the results of such procedures have been noticeably impaired by lack of quantitative measures which can be applied in clinical settings. There is great clinical need for measures that can be related directly to vocal function to compare the results of different treatment techniques, to diagnose specific disorders of function, and to monitor changes with treatment.

Glottographic measures are not new or untested. The techniques have been used individually in research laboratories for many years. More recently, the use of simultaneously recorded glottographic measures has been advocated by speech scientists as a reasonable approach to the measurement of vocal function in normal individuals.<sup>28</sup> Our clinical experience with the application of these techniques to patients has been encouraging. The described techniques are relatively noninvasive and require no more time to perform than brainstem evoked audi-

ometry. In fact our clinic recording system is located in the same double-walled audio booth that is used for evoked response recording. Visual analyses of the recorded signals correspond very well to laryngoscopic and other clinical evaluations of the patients' dysfunction yet appear to provide much greater detail of the vibratory characteristics of the cords than any existing clinical techniques. Furthermore, measurements from the waveforms hold some promise of providing quantification of important phonatory characteristics.

Data generated from these methods must be interpreted cautiously in light of laryngologic examination. For example, in patients who adduct the ventricular vocal folds during phonation (a compensatory strategy in some individuals), the PGG signal may not represent the glottal area accurately. In patients who have significant asymmetry in vocal cord closure (ie, one cord is crossed over the other), the PGG waveform also may not reflect the glottal opening, since it may not be oriented perpendicularly to the light.

Although the EGG waveform is obtained easily in nearly all patients, a few abnormal conditions can also make interpretation difficult. For example, the presence of a tissue or mucous bridge between the vocal folds, or contact of the ventricular folds, may affect the impedance between the two electrodes in an aberrant manner. Simultaneous recording of several measures with fiberoptic laryngoscopic monitoring allows informed interpretation of the glottographic measures.

Certainly, one of the most appealing features of these procedures is the graphic picturability of the waveforms. An overall impression of the pathophysiology can be gained rather quickly upon viewing the PGG and EGG waveform patterns. Moreover, documentation with quantitative data from the signals can be obtained. We have used a few traditional measurements such as the open quotient, speed quotient, and fundamental frequency perturbation. We have also developed some measures which appear to differentiate among subjects with differing pathologies. In addition, other measures may prove better able to define subtle changes in laryngeal control in patients with voice disorders. In theory, given the proper parameters, one may be able to reconstruct the glottal configuration and details of vocal fold tissue movement from glottographic waveforms.<sup>17</sup>

In our clinical practice we find that information obtained from glottographic studies is often diagnostically helpful, particularly in patients with voice abnormalities associated with neuromuscular disorders. Diagnosis of the dysphonia of a patient who has a vocal cord carcinoma, nodule, or polyp is fairly straightforward. However, determination of the cause of dysphonia in the patient who has an anatomically normal larynx may be very difficult un-

less there is obvious paralysis, paresis, or hyperfunction that is laryngoscopically visible. Glottographic techniques appear to offer some insight into the more subtle vibratory and tension abnormalities that are associated with pathological phonation in the otherwise normal-appearing larynx. For example, glottography, in our experience, reliably documents the presence of incomplete vocal cord closure. In some cases, this may be visible laryngoscopically, but often is not detected without the analysis of ultra-high-speed films. Similarly valuable diagnostic information, such as indications of abnormally increased vocal fold tension or cycle-to-cycle variability in vibration, may be identified and measured in the waveforms.

The apparent value of the simultaneous recordings of glottographic signals requires confirmation in sizable populations of clinical patients. Our experience to date indicates that the use of simultaneously recorded glottographic signals for better understanding of phonatory disorders has excellent potential, and such studies are probably well worthwhile. We are currently using these techniques for the analysis of phonatory disturbances in several populations of patients with movement disorders. The voice abnormalities of such patients are rela-

tively poorly understood and often neglected. Glottographic studies of patients with anatomical vocal cord lesions are also of interest as they appear to help describe the effect of mass lesions on vocal fold vibration. Recordings over time may also be useful to document the results of treatment in a given patient.

In summary, glottographic measurements appear to have potential as a valuable component in a multi-level analysis of voice disorders. Simultaneous recordings of objective measures of glottal vibratory function are feasible in a clinical setting, and they appear to differentiate phonatory characteristics of patients with distinct phonatory abnormalities. Such measurements must be interpreted in light of accurate, documented examination of the larynx during phonation and ideally should be compared with simultaneously recorded photographic data. Our experience indicates that information from these measurements may be useful diagnostically in individual patients to understand the pathophysiology of abnormal phonatory characteristics, to plan therapy, and to follow the effects of treatment. Further data are likely to clarify the potential role of these techniques in general clinical care of the voice patient.

ACKNOWLEDGMENTS — The authors wish to thank Douglas Noffsinger, Peter Ladefoged, Gunnar Fant, and Donald Dirks for their valuable contributions to this work. The engineering and technical support provided by Steven Hunt and Robert Vanderveen is also gratefully acknowledged.

## REFERENCES

1. Ward PH, Hanson DG, Berci G. Observations on central neurologic etiology for laryngeal dysfunction. *Ann Otol Rhinol Laryngol* 1981; 90:430-41.
2. Koike Y. Application of some acoustic measures for the evaluation of laryngeal dysfunction. *Stud Phonologica* 1973; 7: 17-23.
3. Horii Y. Fundamental frequency perturbation observed in sustained phonation. *J Speech Hear Res* 1979; 22:5-9.
4. Koike Y. Vowel amplitude modulations in patients with laryngeal diseases. *J Acoust Soc Am* 1969; 45:839-44.
5. Yumoto E, Gould WJ, Baer T. The harmonics-to-noise ratio as an index of the degree of hoarseness. *J Acoust Soc Am* 1982; 71:1544-50.
6. Lively MA, Emanuel FW. Spectral noise levels and roughness severity ratings for normal and simulated rough vowels produced by adult females. *J Speech Hear Res* 1970; 13:503-17.
7. Sansone FE, Emanuel FW. Spectral noise levels and roughness severity ratings for normal and simulated rough vowels produced by adult males. *J Speech Hear Res* 1970; 13:489-509.
8. Berke GS, Gerratt BR, Hanson DG. An acoustic analysis of the effects of surgical therapy on voice quality. *Otolaryngol Head Neck Surg* 1983 (in press).
9. Netsell R, Shaughnessy AL, Lotz WK. Laryngeal aerodynamics for selected vocal pathologies. *Abstr Assoc Res Otolaryngol* 1983; 80.
10. Childers DG. Laryngeal pathology detection. *CRC Crit Rev Bioeng* 1977; 2:375-425.
11. Holmes J. An investigation of the volume velocity waveform at the larynx during speech by means of an inverse filter. In: *Proceedings of the Speech Communications Seminar*. Stockholm: Royal Institute of Technology, 1962.
12. Rothenberg M. A new technique for deriving the glottal airflow waveform during voicing. *J Acoust Soc Am* 1973; 53: 1632-45.
13. Sonesson B. On the anatomy and vibratory pattern of the human vocal folds. *Acta Otolaryngol (Stockh)* 1960; 156 (suppl): 1-80.
14. Fabre P. Un procede electrique percutane d'inscription de l'accolement glottique au cours de la phonation. *Bull Acad Natl Med (Paris)* 1957; 141:66-99.
15. Fourcin AJ. Laryngograph examination of the vocal fold vibration, ventilatory and phonatory control mechanisms. In: Wyke B, ed. *Ventilatory and control systems*. London: Oxford University Press, 1974.
16. Rothenberg M. Some relations between glottal air flow and vocal fold contact area. In: Ludlow CL, O'Connell HM, eds. *Proceedings of the conference on the assessment of vocal pathology*. *Am Speech Hear Soc Rep* 1981; 11:88-95.
17. Titze IR. Mathematical models of glottal area and vocal fold contact area. *J Acoust Soc Am* 1982; 72 (suppl 1):S48.
18. Ward PH, Berci G, Calcaterra T. Advances in endoscopic examination of the respiratory system. *Ann Otol Rhinol Laryngol* 1974; 83:754-69.
19. Kitzing P, Sonesson B. A photoglottographic study of the female vocal folds during phonation. *Folia Phoniatr (Basel)* 1974; 26:138-49.
20. Hutter B. Problems in the use of the photoelectric glottograph. Copenhagen: University of Copenhagen, 1976:275-312.
21. Krishnamurthy AK, Naik JM, Childers DG. Laryngeal function: electroglottograph, ultra-high-speed films, and speech inverse filtering. *J Acoust Soc Am* 1982; 72(suppl):S65.
22. Timke H, Von Leden H, Moore P. Laryngeal vibrations: measurement of the glottic wave I. The normal vibratory cycle. *Arch Otolaryngol* 1958; 68:1-9.



23. Ishizaka F, Flanagan JL. Synthesis of voiced sound from a two mass model of the vocal cords. *Bell Syst Tech J* 1972; 51: 1233-68.

24. Lecluse FLE, Brocaar MP, Verschuure J. The electroglottography and its relation to glottic activity. *Folia Phoniatr (Basel)* 1975; 27:215-44.

25. Hanson DG, Gerratt BR, Ward PH. Cinegraphic observations on laryngeal dysfunction in Parkinson's disease. *Laryngoscope* 1983 (in press).

26. Ishinishi N, Kodoma Y, Nobutomo K, et al. Outbreak of chronic arsenic poisoning among retired workers from an arsenic mine in Japan. *Environ Health Perspect* 1977; 19:121-5.

27. Titze J. In discussion, Monsen RB. The use of a reflectionless tube to assess vocal function. In: Ludlow CL, O'Connell M, eds. *Proceedings of the conference on the assessment of vocal pathology*. Am Speech Hear Assoc Rep 1981; 11:149.

28. Baer T, Lofquist A, McGarr N. Laryngeal vibrations: a comparison between high speed filming and glottographic techniques. *J Acoust Soc Am* 1983; 73:1304-7.

## APPENDIX

### FORMULAS USED IN GLOTTOGRAPHIC MEASUREMENT

Open quotient:

$$\frac{\text{duration glottis is open}}{\text{total duration of glottal cycle}}$$

Speed quotient:

$$\frac{\text{duration of lateral excursion in ms}}{\text{duration of medial excursion in ms}}$$

Mean frequency perturbation:

$$\frac{\Sigma \text{ absolute difference between consecutive periods in ms}}{\text{number of periods}}$$

Frequency perturbation ratio:

$$\frac{\text{mean frequency perturbation}}{\text{mean period}} \times 1,000$$

Mean PGG amplitude:

$$\frac{\Sigma \text{ baseline to peak intensity in volts}}{\text{number of cycles}}$$

Mean PGG amplitude fluctuation:

$$\frac{\Sigma \text{ absolute difference in PGG amplitude between consecutive cycles}}{\text{number of cycles}}$$

PGG - Photoglottograph; DPGG - Differentiated photoglottograph.

PGG amplitude fluctuation ratio:

$$\frac{\text{mean PGG amplitude fluctuation}}{\text{mean PGG amplitude}} \times 1,000$$

Mean maximum glottal opening velocity:

$$\frac{\Sigma \text{ baseline to positive peak in the DPGG}}{\text{number of cycles}}$$

Mean maximum glottal closing velocity:

$$\frac{\Sigma \text{ baseline to negative peak in the DPGG}}{\text{number of cycles}}$$

Peak velocity quotient:

$$\frac{\text{mean maximum glottal opening velocity}}{\text{mean maximum glottal closing velocity}}$$

Mean peak velocity fluctuation:

$$\frac{\Sigma \text{ absolute difference between velocity quotients from consecutive cycles}}{\text{number of cycles}}$$

Peak velocity fluctuation ratio:

$$\frac{\text{mean peak velocity fluctuation}}{\text{mean peak velocity quotient}} \times 1,000$$

# QUANTITATIVE AND OBJECTIVE EVALUATION OF VOCAL CORD FUNCTION

EUGENE RONTAL, MD  
SOUTHFIELD, MICHIGAN

H. JOHN JACOB, MD  
SOUTHFIELD, MICHIGAN

MICHAEL RONTAL, MD  
SOUTHFIELD, MICHIGAN

MICHAEL I. ROLNICK, PHD  
ROYAL OAK, MICHIGAN

Objective and quantitative evaluation of vocal cord function is a goal that has been difficult for voice clinicians to obtain. To be useful as a clinical screening tool it must be easy to perform, it must produce numerical storable data, it must have a high degree of accuracy, and it must be cost-effective. The results of this study have shown that using the perturbation factor and the equipment described, a successful rate of greater than 93% can be obtained in evaluating vocal cord dysfunction. The results further indicate that this equipment can be used much in the same way as an audiogram to follow-up and clinically evaluate on an objective basis the function of the vocal cords.

## INTRODUCTION

The ability to accurately and quantitatively screen vocal cord function is a goal that voice clinicians have long sought. To attain this goal, four objectives must be met: 1) the method must be easy to perform; 2) it must produce numerical and storable data; 3) it must have a high degree of accuracy; and 4) it must be cost-effective. Over the years, many attempts have been made to achieve these four criteria. Usually one or two of them have been satisfied, but the measurement technique has always fallen short of wide acceptance as a clinical tool.

Of the many techniques described in the past, the evaluation of cycle-to-cycle variation of vocal cord closure or perturbation seems to have been the most promising.<sup>1</sup> Liebermann has shown that perturbation can give accurate evaluation of the hoarse voice in a variety of pathologic conditions.<sup>2,3</sup> Von Leden and Koike have further applied perturbation to an analysis of vocal cord disease.<sup>4</sup> It has been widely recognized that perturbation is an accurate, quantitative method for evaluating vocal dysfunction. Unfortunately, this method has never been widely accepted by clinicians because of the cumbersome, research-oriented equipment which produces accurate but difficult-to-assemble information. Other techniques such as spectrographic analysis, harmonics-to-noise ratios, high-speed photography and pneumotachography have also been utilized but are equally difficult to quantitate.<sup>5-9</sup>

Recently, developments in microprocessors have enabled the scaling down of the size, cost, and complexity of the equipment necessary to produce an effective perturbation analysis. The twofold purpose of this paper is first, to show how the simplified

electronics needed to produce a perturbation factor can accomplish the four criteria listed for a satisfactory screening procedure, and second, to attempt to demonstrate the effectiveness of this technique in the clinical practice of laryngology and speech pathology.

## METHODS AND MATERIALS

To carry out this investigation, patients with a variety of pathological conditions of the vocal cord were selected. These included vocal cord nodules, polyps, and contact ulcers, as well as unilateral and bilateral vocal cord paralysis, spastic dysphonia, carcinoma, and functional disorders. All of these patients were examined either with indirect or fiberoptic laryngoscopy to determine the type of condition present. Sixty patients with known vocal cord pathology were used in this study.

Each patient was tested with a Kay Elemetrics Visi-Pitch (model 6787) to first measure their vocal fundamental frequency. Then a prototype Digi-Pert expansion module (model 6090) in tandem with the Visi-Pitch was employed to determine the vocal jitter or irregularity of vocal cord movement. The fundamental frequency is produced by a timing circuit to extract from the vocal signal a voltage which is directly proportional to fundamental frequency and inversely proportional to the fundamental frequency period. This voltage is then put through a log circuit to make the voltage logarithmically proportional to pitch frequency. The jitter or roughness characteristic of the vocal cord changes the fundamental frequency on a cycle-by-cycle basis. This rapidly changing nature of vocal cord activity adds an AC component to the otherwise slowly changing DC pitch voltage from the fundamental frequency. The perturbation measurement then uses an AC type voltmeter to filter the output voltage from the fundamental frequency and to display only the AC (roughness) component. Since the pitch voltmeter has been put through a log circuit, the perturbation display is proportional to the percent of roughness in the voice. This perturbation is designed to display a numerical average roughness over a fixed one-third second.

This numerical value is the variation, either higher or lower than the fundamental frequency, during a one-third second examination of a steady-state vowel. For example, if the fundamental frequency is 100 cycles/s and the jitter or perturbation varies from 95 to 105 cycles/s, then there is a swing of 5 cycles/s on either

From the Department of Otorhinolaryngology, University of Michigan Medical School, Ann Arbor, and the Section of Otolaryngology, Sinai Hospital, Detroit (Rontal, Rontal); the Department of Otolaryngology, Wayne State University Medical School, Detroit (Jacob); and the Department of Speech and Language Pathology, William Beaumont Hospital, Royal Oak (Rolnick), Michigan.

Presented at the meeting of the American Laryngological Association, New Orleans, April 10-11, 1983.

REPRINTS — Eugene Rontal, MD, 21700 Northwestern Hwy, Tower 14, Suite 545, Southfield, MI 48075.



MEAN PERTURBATION RESULTS

Diagnosis	Number	Mean Perturbation (% Roughness)
Normal	20	11.20
Nodule	22	100.20
Polyp	14	133.40
Vocal cord paralysis — unilateral	6	150.40
Vocal cord paralysis — bilateral	7	238.50
Spastic dysphonia	5	208.90
Postglottic or supraglottic laryngectomy	1	476.50
Vocal cord granuloma	1	32.80
Carcinoma	2	85.17
Hysterical dysphonia	2	360.50

side of the fundamental frequency. This is a total of 10 cycles/s variation. This 10-cycle/s variation over the fundamental frequency gives a 10% figure or a 10% roughness perturbation determination.

Six perturbation measurements were taken from each patient while they produced steady-state vowels. A mean was taken of each of these six readings since variations could be found due to mucus on the vocal cords or to the patient's natural pitch variation.

To establish whether these measurements could separate a normal from a hoarse voice, a series of normal patients were also analyzed. Twenty normals with random age and sex distribution were evaluated. There was no distinction made in this study of normals between smokers and nonsmokers. A normal subject was considered to be any individual who had no complaints of vocal cord dysfunction and/or no evidence of vocal cord disease on indirect or fiberoptic examination of the larynx. The fundamental frequency and perturbation measurements for normal subjects were determined using the above-described technique and equipment. These normal scores were then compared to those of the 60 patients with known pathologic entities.

A statistical analysis was performed to determine whether this method yielded data that showed a significant difference between the normal and pathologic groups. Following this, an analysis was made as to the range of acceptable hoarseness or perturbation present in the normal voice. This analysis rendered a number of false-negative values, ie, those who had pathologic conditions on the vocal cords with normal perturbation scores. The second analysis indicated the number of false-positives, ie, those who were normal but exhibited high perturbation scores. To be satisfactory for this study the results had to show that an accuracy of 90% or better could be obtained with this method in terms of screening a hoarse from a nonhoarse voice. That is, a false-positive and false-negative rate of 10% would be considered acceptable for a screening tool for hoarseness.

## RESULTS

The Table displays the mean perturbation scores and the various pathological conditions studied. Welch's test of unequal variances was utilized to determine if significant differences in perturbation were present between the normal and pathologic groups. This test showed that significant differences were indeed present at the 0.05 level of confidence.

The mean perturbation or percent roughness scores of 95% of the normal subjects ranged from 0% to 19.6% roughness based on the 120 readings obtained from the 20 individuals measured. The average normal perturbation reading was 11.2%.

The range of false-negatives in this study in-

dicated that 6.7% of patients with known vocal cord pathological conditions were at a level below 19.6% roughness. This meant that 93.4% of the patients with known vocal cord pathological conditions had abnormal perturbation scores.

When a figure of 19.6% vocal roughness was used, 95% of normal individuals fell within the range indicated with a 5% false-positive rate present above 19.6% roughness.

Based on these results, individuals with perturbation scores below 20% may be considered lacking vocal cord pathology with a 6.7% chance for error. Patients with readings above 20% should be further investigated.

## DISCUSSION

Two definitions must be recognized by the clinician in utilizing this technique. One definition is that of the fundamental frequency of the voice ( $f_0$ ) and the other is perturbation. Fundamental frequency by definition refers to the actual number of vibrations per second of vocal cord closure. Without pathologic conditions, the fundamental frequency falls into specific ranges and tends to be constant. Perturbation, on the other hand, refers to the degree of hoarseness of the voice. It is a measure of inconstancy within the waveform of the fundamental. Vocal pathology may cause variation or asynchrony of vocal cord closure, and therefore, an increase in perturbation.

Since perturbation scores are a direct measure of variation in cord closure and hoarseness, they are thus a direct measure of vocal cord dysfunction. This conclusion has been demonstrated repeatedly by many authors. Liebermann has shown that vocal cord pathology reliably gives high perturbation scores.<sup>2,3</sup> Von Leden and Koike have further indicated the effectiveness of perturbation results by correlating them with a variety of pathologic entities.<sup>4</sup> Other authors have supported the findings of these articles.<sup>10,11</sup>

The results of our studies corroborate the findings of previous authors, specifically that abnormal perturbation scores are a direct indication of vocal cord dysfunction. By assessing normal values of percent roughness for this procedure, a range of normals could be established. With a greater than 95% assurance, patients with known pathological conditions of the vocal cords will produce abnormally high perturbation scores. By using 19.6% roughness as the upper range of normal, false-negatives were seen in 6.7% of the cases and false-positives were seen in 5% of the cases. This means that the procedure used has a greater than 93% accuracy in determining a hoarse voice.

Because perturbation scores are a measure of hoarseness, there is now a procedure available that can directly measure the dysfunction of the voice.

With the development of improved electronic techniques and microprocessors, this previously cumbersome type of instrumentation can now be scaled down to a clinically useful tool.

This tool, as shown in the present paper, satisfies the four criteria listed above for a quantitative objective screening tool. First, the technique is easy to perform. Our experience has shown that this analysis can be done within a period of 60 to 90 seconds and must not necessarily be carried out by a professional. Second, the results here produce numerically storable data. The subjective determination of hoarseness is thereby replaced with numerical index values, which can be processed by a computer and analyzed for mass screening. Third, the technique has shown a high degree of accuracy. Ninety-three percent of patients with known pathological conditions of the vocal cords show positive results on their perturbation values. Further, only 5% of normal individuals showed evidence of perturbation scores outside the range of normal. Fourth, the technique is cost-effective. It no longer requires a cumbersome piece of equipment and long hours of computation to determine a value. The results can be processed within 60 to 90 seconds on an instrument which costs in the range of a normal audiometer.

This simplified procedure gives the clinician several useful tools in treating patients. First, the technique can be used to provide accurate, quantifiable and cost-effective screening of vocal cord dis-

ease. The test results may be used much like an audiogram. It has been shown that the incidence of vocal cord dysfunction (polyps, nodules and chronic laryngitis) is relatively high in industry.<sup>12</sup> Individuals with preexisting vocal cord dysfunction can be screened and isolated prior to any employment. Current employees who work in high vocal-risk areas can be evaluated prior to a medical examination. Accurate computerized records can be utilized with this equipment to provide long-term follow-up on these individuals.

Second, this technique has potential application as an office tool for the clinician. By performing baseline perturbation results on hoarse individuals, objective, quantitative measurements can be obtained. Subsequent follow-up testing can be utilized to evaluate the progress of treatment. Again, this is utilized in much the same way as an audiogram.

Several words of caution must be made regarding the present test. This is not a diagnostic test to determine a type of disease. Our results indicate that polyps, nodules, papillomas, granulomas, carcinomas, and other vocal cord diseases can give similar perturbation results (Table). This method will only indicate the potential of an existent vocal cord dysfunction. Second, it is not a cancer-detection technique. Should there be any disease of the larynx outside the vocal cords, this technique will most likely be unreliable. Third, this test is not a substitute for accurate examination of the larynx by direct or indirect methods.

#### REFERENCES

1. Timcke R, von Leden H, Moore P. Laryngeal vibrations: measurements of the glottic wave. Part I. The normal vibratory cycle. *Arch Otolaryngol* 1958; 68:1-19.
2. Liebermann P. Perturbations in vocal pitch. *J Acoust Soc Am* 1961; 33:597-602.
3. Liebermann P. Some acoustic measures of the fundamental periodicity of normal and pathologic larynges. *J Acoust Soc Am* 1963; 35:344-53.
4. Von Leden H, Koike Y. Detection of laryngeal disease by computer technique. *Arch Otolaryngol* 1970; 9:3-10.
5. Moore P, Thompson C. Comments on physiology of hoarseness. *Arch Otolaryngol* 1965; 81:97-102.
6. Timcke R, von Leden H, Moore P. Laryngeal vibrations: measurements of the glottic wave. Part II. Physiologic variations. *Arch Otolaryngol* 1959; 69:438-44.
7. Rontal E, Rontal M, Rolnick MI. Objective evaluation of vocal pathology using voice spectrography. *Ann Otol Rhinol Laryngol* 1975; 84:662-71.
8. Yumoto E. The quantitative evaluation of hoarseness. *Arch Otolaryngol* 1983; 109:48-52.
9. Hippel K, Mrowinski D. Examination of patients with normal and abnormal voice by pneumotachography. *HNO* 1978; 26:421-3.
10. Koike Y. Vowel amplitude modulations in patients with laryngeal diseases. *J Acoust Soc Am* 1969; 45:839-44.
11. Murry T, Doherty ET. Selected acoustic characteristics of pathologic and normal speakers. *J Speech Hear Res* 1980; 23: 361-9.
12. Rontal E, Rontal M, Jacob HJ, Rolnick MI. Vocal cord dysfunction — an industrial health hazard. *Ann Otol Rhinol Laryngol* 1979; 88:818-21.



# THREE-DIMENSIONAL COMPUTER RECONSTRUCTION OF THE DISTRIBUTION OF NEUROMUSCULAR JUNCTIONS IN THE THYROARYTENOID MUSCLE

MARC ROSEN, MD

LESLIE T. MALMGREN, PhD

RICHARD R. GACEK, MD

SYRACUSE, NEW YORK

Microinjections of botulinum toxin have recently been shown to be effective in the treatment of strabismus, and it has also been suggested that microinjections of this myoneural blocking agent might be of value in the treatment of spastic dysphonia. The success of such a microinjection technique would rely on a precise knowledge of the distribution of myoneural junctions in the thyroarytenoid muscle. In view of this potential application as well as the need for such information in reinnervation procedures, we have used computer graphics to reconstruct the three-dimensional distribution of motor end-plates in the thyroarytenoid muscle. Three cat and one human (fresh autopsy specimen) larynges were frozen and sectioned on a cryostat. Serial sections were then processed for the histochemical localization of acetylcholinesterase activity to demarcate the neuromuscular junctions. An X-Y digitizer was used to reference the position of the motor end-plates in each serial section, and the three-dimensional distribution of the neuromuscular junctions was reconstructed on a computer graphics terminal. The results are discussed in regard to their applicability to clinical treatment of spastic dysphonia and other disorders of phonation.

## INTRODUCTION

Spastic (spasmodic) dysphonia may be a disabling voice disorder often referred to as stuttering with the vocal cords.<sup>1</sup> It was first described by Traube in 1871<sup>2</sup> and is characterized by a strained, muffled, creaking, choking, jerky, squeezed, staccato, effortful voice. Patients with spastic dysphonia, however, usually have no problem with whispering, singing, laughing or phonating a high-pitched "EE," which usually produces a normal laryngological examination.<sup>3</sup> The pathophysiology of the disease is believed to be due to hyperadduction of the true and false vocal cords which can be seen using direct videofiberoptic laryngoscopy.<sup>4</sup>

The etiology of spastic dysphonia was originally believed to be a psychoneurosis, specifically a conversion-reaction,<sup>5,6</sup> since a history of a stressful event preceding the onset of symptoms could usually be elicited. Recently there have been reports of the possibility of an organic etiology for the disease as well. Robe et al<sup>7</sup> have shown that 90% of these patients displayed abnormal electroencephalograms and 83% had pyramidal tract signs. Aronson and Hartman<sup>8</sup> have shown that spastic dysphonia is often associated with essential voice tremor. Dedo et al<sup>3</sup> and Boccino and Tucker<sup>9</sup> reported demyelination in segments of recurrent laryngeal nerves excised from patients with spastic dysphonia, but Ravits et al<sup>10</sup> were unable to confirm this.

Early therapy for spastic dysphonia based primarily on voice and psychotherapy has been largely

unsuccessful.<sup>6,11</sup> Recently, however, Dedo<sup>12</sup> and Dedo and Izdebski<sup>13</sup> have achieved good results by transecting the recurrent laryngeal nerve unilaterally. Other modifications of this procedure have been suggested in order to prevent permanent loss of one recurrent laryngeal nerve in case the contralateral nerve is paralyzed subsequently. These include the recurrent laryngeal nerve crush<sup>14</sup> and selective section of the anterior branch of the recurrent laryngeal nerve.<sup>15,16</sup>

Recently, microinjections of botulinum toxin in selected extraocular muscles have been shown by Scott<sup>17</sup> to be effective in the treatment of strabismus. Carefully administered microinjections of this myoneural blocking agent may also be helpful in the treatment of spastic dysphonia. In order to provide guidance for successful injections into the vocal cords as well as to provide important information for the design of reinnervation procedures, it would be useful to know the precise distribution of the motor end-plates in the thyroarytenoid (TA) muscle. Previous work has demonstrated innervation patterns<sup>18</sup> (specifically motor-fiber types) and specific aspects of the synapses,<sup>19</sup> but the motor end-plates have not been visualized three-dimensionally. In the present study we have used computer graphics to reconstruct in three dimensions the distribution of motor end-plates in the TA muscle of the cat and human.

## MATERIALS AND METHODS

Three cat and one human (fresh autopsy specimen) larynges

From the Department of Otolaryngology and Communication Sciences, State University of New York, Upstate Medical Center, Syracuse. This project was supported by NIH grant NS 18265.

Presented at the meeting of the American Laryngological Association, New Orleans, April 10-11, 1983.

REPRINTS — Leslie T. Malmgren, PhD, Department of Otolaryngology and Communication Sciences, Upstate Medical Center, 766 Irving Ave, Syracuse, NY 13210.

were frozen in *n*-methyl butane cooled to its freezing point with liquid nitrogen. Two parallel holes were drilled through each specimen perpendicular to the plane of sectioning to aid in the three-dimensional reconstruction. The specimens were then mounted on microtome chucks with Tissue Tek OCT compound. The thyroid cartilage was removed from the human larynx before sectioning. Ossification of the thyroid cartilage precluded sectioning without prior decalcification which would have destroyed acetylcholinesterase (AChE) enzyme activity. The specimens were then sectioned (50  $\mu$ m) coronally in a cryostat, mounted on coverslips, and allowed to dry at room temperature. The AChE activity of the motor end-plates was localized histochemically according to Karnovsky and Roots<sup>20</sup> using an incubation time of one hour. Prior to incubation, the sections were preincubated (4°C; 15 minutes) in a solution consisting of 6.5 mL 0.1M sodium hydrogen maleate (pH 6.0), 1 mL  $10^{-3}$ M iso-OMPA (tetra-isopropylpyrophosphoramide; selective inhibitor of pseudocholinesterase) and 2.5 mL distilled water, in order to allow the inhibitor to diffuse into the tissue before the histochemical reaction. The incubation was carried out at 4°C in a solution containing 5 mg acetylthiocholine iodide, 6.5 mL 0.1M sodium hydrogen maleate (pH 6.0), 0.5 mL 0.1M sodium citrate, 1 mL 30 mM CuSO<sub>4</sub>, 1 mL  $10^{-3}$  iso-OMPA and 1 mL of 5 mM potassium ferricyanide. After the histochemical reaction was completed, the coverslips were mounted in glycerin jelly. The distributions of neuromuscular junctions were then examined in numerous serial sections from each specimen. Three to five sections were taken from each series at regularly spaced intervals in order to produce a simplified and representative computer reconstruction of the three-dimensional distribution of motor end-plates. These sections were projected from an Aus Jena Dakumator DL2 onto the screen of a backscreen projector. A computer (Cyberchron C11/23 minicomputer) interfaced X-Y digitizer (Numonics 1220) was then used to reference the position of the motor end-plates in each serial section. The three-dimensional distribution of motor end-plates was reconstructed on the screen of a Tektronics 4027 graphics terminal using a program written by a member of our anatomy department.

## RESULTS

The results in both the human and the cat were similar. A representative section through a cat and a human true and false vocal cord is shown in Figures 1A and 2A. The locations of motor end-plates appear as darkly stained dots which indicate the sites of high AChE activity characteristic of neuromuscular junctions. The short incubation time used in this histochemical technique insured that only motor end-plates would possess sufficient AChE to stain darkly.

The appearance of motor end-plates in the cricothyroid muscle of the cat represents the typical arrangement found in most muscles (Fig 3). In such muscles the motor end-plates are usually found in a band along the midpoint of the muscle. Motor end-plates in the TA muscle were arranged very differently. Figures 1B and 2B represent the computer-based three-dimensional reconstruction of the motor end-plates of the cat and human, respectively. Only the outlines of the muscles are shown for simplicity. The crosses represent the motor end-plates. The end-plates are diffusely located throughout the TA muscle rather than limited to a band or any other clustered configuration.

Furthermore, a substantial number of motor end-plates were scattered in the false vocal cord. Although this structure mainly contains glandular ele-

ments and adipose tissue, a variable number of muscle fibers may be seen in routine histological preparations of the larynx. The location of the motor end-plates for these muscle fibers has never been demonstrated.

## DISCUSSION

Spastic dysphonia continues to be a disabling voice disorder which places great strains on the patient's personal and social life. Whether the disease is primarily psychogenic or organic, some form of therapy is often required to alleviate the symptoms. Somewhat effective treatment has been provided by unilaterally denervating the larynx either permanently (recurrent laryngeal nerve transection) or temporarily (recurrent laryngeal nerve crush). Both of these open surgical procedures require general anesthesia with the risk of damaging major structures in the region of the recurrent laryngeal nerve. Moreover, transection of the recurrent laryngeal nerve can create a severe airway problem if the contralateral vocal cord is subsequently paralyzed by another process.

The use of botulinum toxin in the treatment of spastic dysphonia may have several advantages. First of all, the paralysis is related to dose. This would allow evaluation of response during injection. Second, the procedure can be performed endoscopically using local or general anesthesia. Third, the response can be titrated. Since a single injection lasts anywhere from weeks to months, periodic injections could be used until the voice stabilized at a functional level.

The major risk associated with this technique for rendering muscles paralyzed is the toxicity of the botulinum toxin. If the amount of toxin used is large and not limited to the muscle fibers of concern, nearby muscle systems responsible for actions other than phonation may also be affected. In order to control its placement the toxin must be used in small amounts injected precisely into the location of the motor end-plates. Most muscles, including probably most other laryngeal muscles, contain motor end-plates compactly arranged in a band at the midpoint of the muscle belly. However, the TA muscle has its end-plates diffusely distributed throughout the muscle. This diffuse arrangement of end-plates probably reflects the complex makeup of the TA with muscle fibers oriented along many vectors and inserting on various structures in the larynx.

The distribution of end-plates in the TA provides guidance for the microinjection of the toxin into the vocal cord. Multiple injections covering all areas of the muscle rather than a single locus at its midpoint would be optimal in order to achieve complete paralysis of the cord. It is conceivable that various degrees of TA paralysis may be desired in the treatment of other spastic voice disorders. Perhaps even



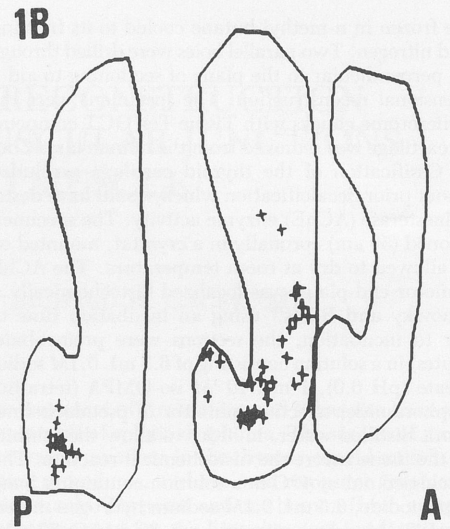
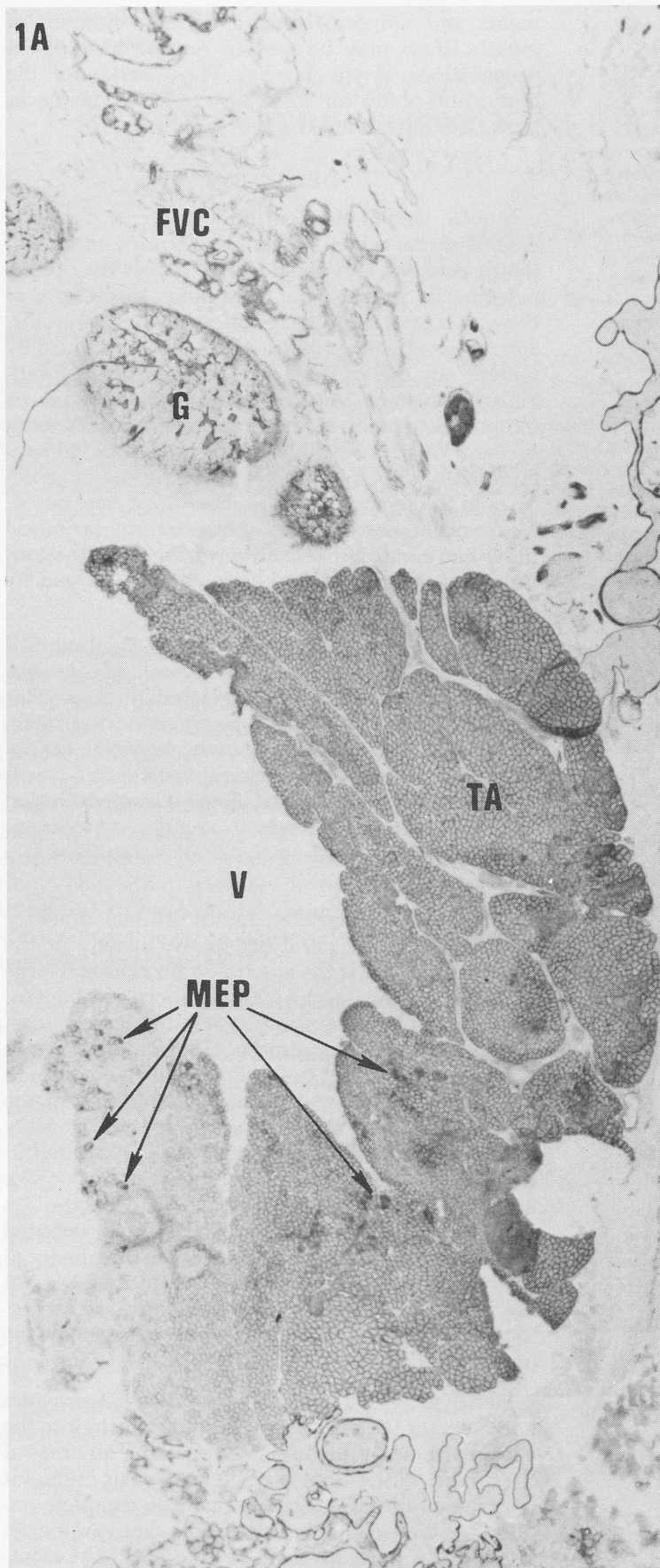


Fig 1. A) Representative section through cat true vocal cord (thyroarytenoid [TA]) and false vocal cord (FVC). Motor end-plates (darkly staining dots) are labeled MEP and are also found in FVC. V - Ventricle; G - Glandular elements. B) Three-dimensional computer reconstruction of motor end-plates, represented by crosses, in cat. Orientation is same as in A. Distances between sections is proportional and dependent on angle of rotation. P - Posterior; A - Anterior.

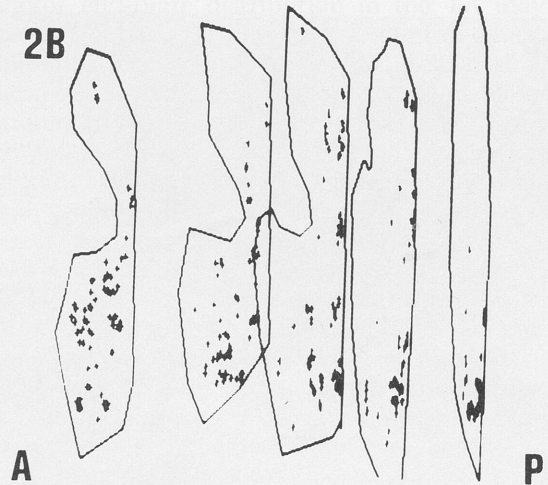
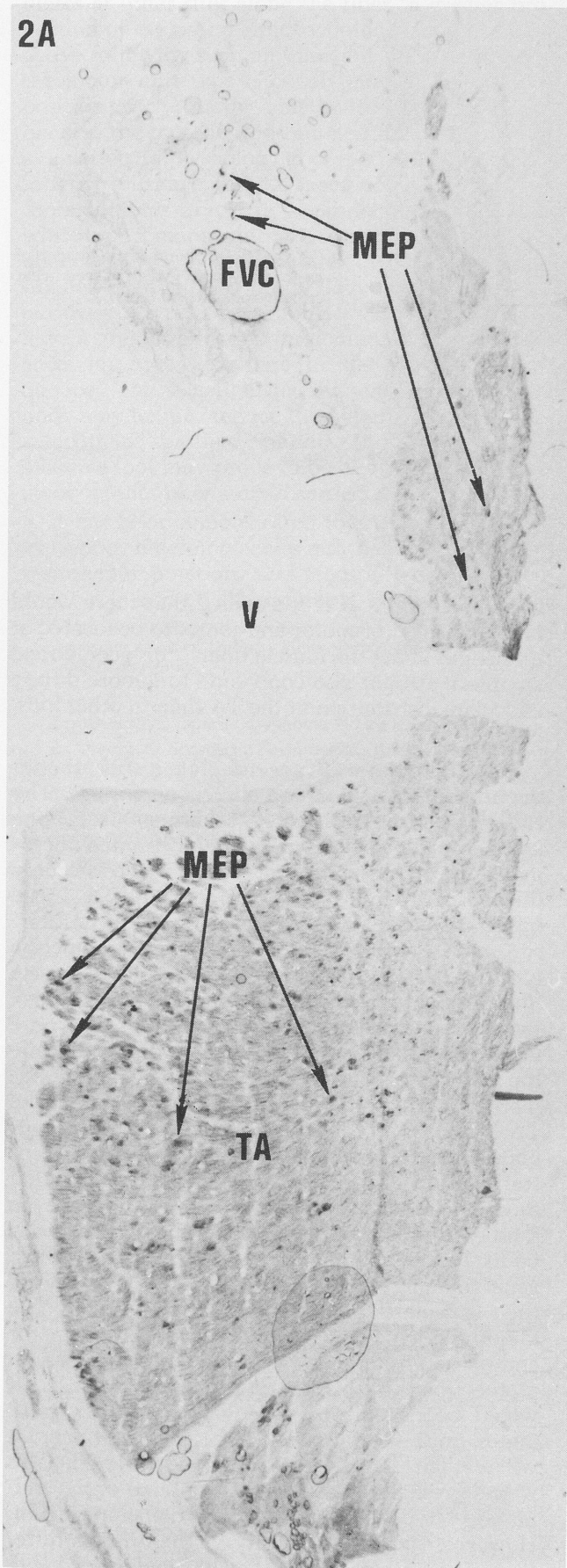


Fig 2. A) Representative section through human true vocal cord (thyroarytenoid [TA]) and false vocal cord (FVC). Motor end-plates (MEP) (darkly staining dots) can be seen in both TA and FVC. V - Ventricle. B) Three-dimensional computer reconstruction of motor end-plates, represented by crosses, in human. Orientation is same as in A. A - Anterior; P - Posterior.



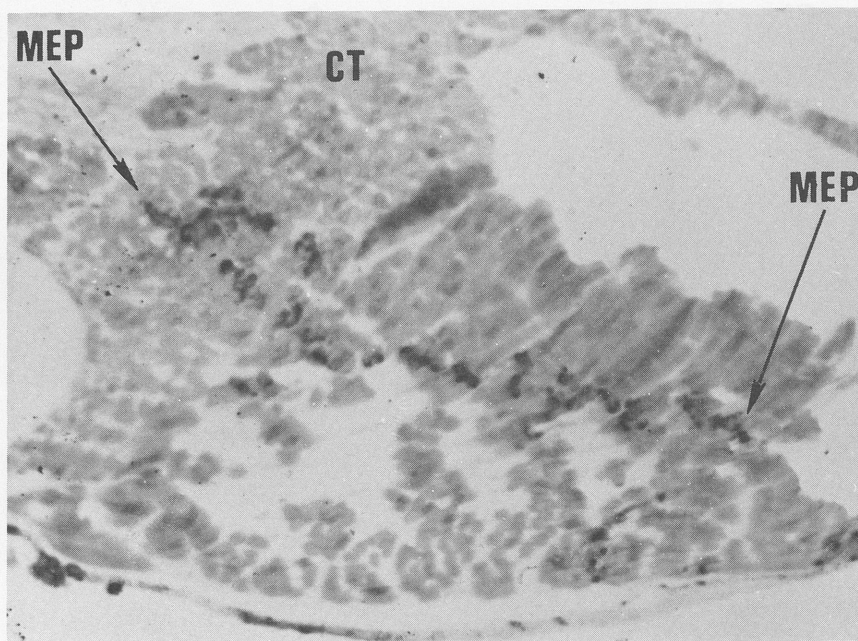


Fig 3. Typical band arrangement of motor end-plates (MEP) as seen in cat cricothyroid muscle (CT).

the voice rest desirable after vocal or surgical trauma may be insured by a titrated toxic paralysis. However, it will be important to obtain more specific information concerning the long-term effects of botulinum toxin on the TA and its innervation through the use of animal models before such an application can be responsibly considered.

The number and arrangement of motor end-plates in the human false vocal cord was somewhat unexpected. The variable number of muscle fibers often observed in this region are usually regarded as a derivative of the TA muscle. However, the recent study of Rosenberg, Malmgren and Gacek (unpublished observations) indicating the possibility of significant numbers of motor axons in the internal branch of the human superior laryngeal nerve, suggests that these muscle fibers innervated by the superior laryngeal nerve may belong to a separate muscle contained in the false cord. Further experimental studies can be designed to answer this question definitively. Nevertheless, this observation suggests that botulinum toxin may also be considered in the treatment of spastic voice disorders caused by hyperadduction of the false cords (dysphonia plica ventricularis).

Several factors could account for the diffuse end-plate distribution observed in the TA muscle. Unlike muscle fibers found in most other adult mammalian muscles, muscle fibers in the human TA muscle have multiple motor end-plates.<sup>18,21</sup> Since the distances between end-plates on the same fiber have been indicated to be as great as  $5,640\mu$ ,<sup>18</sup> the existence of multiple motor end-plates innervating muscle fibers in the TA would contribute to the observed diffuse end-plate distribution. In addition, the TA muscle is geometrically complex in that fibers in this muscle differ from one another in their

attachment sites. If it is assumed that there would be a tendency for motor end-plates to be located at midlength along the muscle fibers, this geometrical complexity might also contribute to a more diffuse end-plate distribution in the TA than in other muscles.

Our finding of a diffuse end-plate distribution in the human TA may offer a clinical advantage. The end-plates are sufficiently separated from one another to allow selective, regionally limited micro-injections of the toxin that would inactivate only the end-plates in a specific region of the TA. Little information is available concerning motor unit territories in the human TA, and it is as yet unclear whether the multiple end-plates on a single muscle fiber originate from single or multiple neurons.<sup>18,22</sup> It has been indicated that the majority of type 1 muscle fibers have multiple motor end-plates, while the majority of type 2 fibers have single motor end-plates.<sup>18</sup> If the diffuse end-plate distribution in the TA is due to a dislocation of multiple motor end-plates away from the more typically observed central band of end-plates, the end-plate distribution in the TA may be specific to the muscle fiber type (and type of motor unit). If this is the case, it would be likely that the majority of type 2 fibers, which generally have single motor end-plates, would have their end-plates at midlength along the fiber. The majority of type 1 fibers would have multiple motor end-plates with end-plates spread along the length of the fiber. If this distribution in fact exists, it would be possible to selectively paralyze type 2 motor units by injection in the region of the TA where their single end-plates are clustered. This would presumably also inactivate some of the end-plates of type 1 fibers found in the same region. However, since the majority of these fibers differ from type 2 fibers in that they have additional end-

plates at other sites along the fiber, a greater proportion of the type 1 fibers would probably remain active following such an injection. In most muscles the motor unit type is closely correlated with the position of the motor unit in the recruitment sequence, the motoneuron/muscle-fiber ratio, as well as a variety of physiological properties including the fatigue resistance and the speed of contraction.<sup>23-26</sup> Type 1 motor units are generally recruited early, while type 2 motor units are recruited late in the sequence. Type 1 motor units are also generally smaller than type 2 units. Therefore, a selective paralysis of type 2 motor units would be expected to have a greater effect on large motor units that generate large tensions late in the recruitment sequence. The selective inactivation of such motor units may help to reduce the hyperadduction characteristic of spastic dysphonia. In addition, such a selective tool may prove to be of value in the treatment of other phonatory disorders.

It has been demonstrated that a wide variety of exogenous macromolecules may be taken up at neuromuscular junctions and transported to the neuronal cell body.<sup>27</sup> Therefore, a knowledge of the

motor end-plate distribution in the TA may also provide a basis for other future clinical procedures based on local microinjections of other biologically active substances followed by uptake at the neuromuscular junction and retrograde axonal transport to the neuronal cell body. For example, recent studies have demonstrated that certain toxic lectins may undergo retrograde axonal transport to motoneuron or sensory neuron cell bodies, where they inactivate ribosomes and result in neuronal death.<sup>28</sup> Furthermore, the lesion resulting from these lectins was limited to neurons projecting to the injection site.<sup>28</sup> The use of toxic lectin injections may therefore provide a means of permanently and selectively destroying certain motoneurons or sensory neurons. Since botulinum toxin injections produce a long-lasting but not permanent paralysis, the use of lectin injections would offer a different type of tool which would be more desirable in situations where a more permanent inactivation of certain neurons is beneficial. However, in view of the toxicity of lectins, adequate experimentation using animal models will be necessary before toxic lectins can be considered for clinical use.

ACKNOWLEDGMENTS — We thank Carol Etzler and Michael Lyon for their excellent technical advice and assistance; Stephen Falen for writing the computer program; Dr Larry Miller, Pathology Department, for his cooperation in providing human tissues; and Dr Raffi Mesrobian for his help in data interpretation.

## REFERENCES

1. Arnold GE. Spastic dysphonia I. Logos 1959; 2:3-14.
2. Traube L. Spastische Form der Nervösen Helsekeit. Gesammelte Beitrage zur Pathologie und Physiologie 1871:2:677.
3. Dedo HH, Isdebski K, Townsend JJ. Recurrent laryngeal nerve histopathology in spastic dysphonia. Ann Otol Rhinol Laryngol 1977; 86:806-12.
4. Parnes SM, Lavorato AS, Myers EN. Study of spastic dysphonia using videofiberoptic laryngoscopy. Ann Otol Rhinol Laryngol 1978; 87:322-6.
5. Bloch P. Neuro-psychiatric aspects of spastic dysphonia. Folia Phoniatri (Basel) 1965; 17:301-64.
6. Brodnitz FS. Spastic dysphonia. Ann Otol Rhinol Laryngol 1976; 87:210-4.
7. Robe E, Brumlik J, Moore P. A study of spastic dysphonia: neurologic and electroencephalographic abnormalities. Laryngoscope 1970; 70:219-45.
8. Aronson AE, Hartman DE. Adductor spastic dysphonia as a sign of essential (voice) tremor. J Speech Hear Disord 1981; 46:52-8.
9. Bocchino JV, Tucker HM. Recurrent laryngeal nerve pathology in spasmodic dysphonia. Laryngoscope 1978; 88:1274-80.
10. Ravits JM, Aronson AE, DeSanto LW, Dyck PJ. No morphometric abnormality of recurrent laryngeal nerve in spastic dysphonia. Neurology (NY) 1978; 29:1376-82.
11. Cooper M. Modern techniques of vocal rehabilitation. Springfield, Ill: Charles C Thomas, 1973:177.
12. Dedo HH. Recurrent laryngeal nerve section for spastic dysphonia. Ann Otol Rhinol Laryngol 1976; 85:451-9.
13. Dedo HH, Izdebski K. Intermediate results of 306 recurrent laryngeal nerve sections for spastic dysphonia. Laryngoscope 1983; 93:9-15.
14. Biller HF, Som ML, Lawson W. Laryngeal nerve crush for spastic dysphonia. Ann Otol Rhinol Laryngol 1979; 88:531-2.
15. Carpenter RJ, Henley-Cohn JL, Snyder GG. Spastic dysphonia: treatment by selective section of the recurrent laryngeal nerve. Laryngoscope 1979; 89:2000-3.
16. Carpenter RH, Snyder GG, Henley-Cohn JL. Selective section of the recurrent laryngeal nerve for the treatment of spastic dysphonia: an experimental study and preliminary clinical report. Otolaryngol Head Neck Surg 1981; 89:986-91.
17. Scott AB. Botulinum toxin injection into extraocular muscles as an alternative to strabismus surgery. Ophthalmology (Rochester, Minn) 1980; 87:1044-9.
18. Bendiksen FS, Dahl HA, Teig E. Innervation pattern of different types of muscle fibres in the human thyroarytenoid muscle. Acta Otolaryngol (Stockh) 1981; 91:391-7.
19. Morales J, Rama J, Gayoso M. Some aspects of the nerve endings and synapses in the vocalis muscle. J Laryngol Otol 1980; 94:1047-63.
20. Karnovsky MJ, Roots L. A "direct coloring" thiocholine method for cholinesterases. J Histochem Cytochem 1964; 12:219-21.
21. Rossi G, Cortesina G. Morphological study of the laryngeal muscles in man. Acta Otolaryngol (Stockh) 1965; 59:575-92.
22. Rudolph G. Multiple innervation von Muskelfasern im M vocalis des Menschen. Experientia 1960; 16:551-3.
23. Burke RE, Levine DN, Zajac FE, Tsairis P, Engle WK. Mammalian motor units: physiological-histochemical correlation in three types in cat gastrocnemius. Science 1971; 174:709-12.
24. Burke RE, Levine DN, Tsairis P, Zajac FE. Physiological types and histochemical profiles in motor units of the cat gastrocnemius. J Physiol 1973; 234:723-48.
25. Burke RE, Levine DN, Saloman M, Tsairis P. Motor units in cats soleus muscle: physiological, histochemical and morphological characteristics. J Physiol 1974; 238:503-14.
26. Garnett RAF, O'Donovan JJ, Stephans JA, Taylor A. Motor unit organization of human medial gastrocnemius. J Physiol 1979; 287:33-43.
27. Malmgren L, Olsson Y, Olsson T, Kristensson K. Uptake and retrograde axonal transport of various exogenous macromolecules in normal and crushed hypoglossal nerves. Brain Res 1978; 153:477-93.
28. Wiley TG, Blessing WW, Reis OJ. Suicide transport: destruction of neurons by retrograde transport of ricin, abrin and medecine. Science 1982; 216:889-90.



# VIDEOLARYNGOSCOPY

## A COMPARISON OF FIBERSCOPIC AND TELESCOPIC DOCUMENTATION

EIJI YANAGISAWA, MD  
GORDON STROTHERS, MD

TERRYL W. OWENS, MD  
KIYOSHI HONDA, MD

NEW HAVEN, CONNECTICUT

Videolaryngoscopy is a most useful and effective method of evaluation and documentation of physiological and pathological conditions of the larynx. It is of great value for making accurate diagnosis and planning proper treatment. It permits instant and simultaneous voice and video recording and later analysis. Videolaryngoscopy can be accomplished with either a flexible fiberscope or a rigid right-angled telescope. Fiberscopic videolaryngoscopy is more useful for voice analysis of speech disorders and evaluation of such functions of the larynx as phonation, singing, and swallowing. Telescopic videolaryngoscopy is superior for critical evaluation of anatomical and pathological changes of the laryngeal structures as well as close-up examination of vocal cord function. While fiberscopic laryngoscopy is technically easy, fiberscopic video documentation is much more difficult than telescopic video documentation. Telescopic videolaryngoscopy provides clearer and sharper images of the larynx. Advantages and disadvantages of each method are discussed.

Videolaryngoscopy — laryngoscopy using a video camera and a fiberscope or a telescope — is a most useful and effective method of evaluation and documentation of physiological and pathological conditions of the larynx. It can be accomplished using either a flexible fiberscope<sup>1-14</sup> or a rigid right-angled telescope.<sup>15-25</sup>

Since the introduction of flexible fiberoptic laryngoscopy by Sawashima and Hirose in 1968,<sup>1</sup> the flexible fiberscope has been used for various conditions of the larynx, including evaluation of voice therapy,<sup>3,12</sup> postlaryngectomy speech,<sup>4</sup> stuttering,<sup>8</sup> spastic dysphonia,<sup>9</sup> and difficult endotracheal intubation.<sup>2,7,11</sup>

One of the most significant advances in endoscopic photography is the development of the telescope with the new rod lens system by Hopkins.<sup>15,18</sup> The air-containing spaces between the conventional series of lenses have been replaced with glass rods, with polished ends separated by small "air lenses." The optics of this new invention are such that light transmission and magnification are significantly increased, thereby providing a brighter and more easily perceived image and the improved resolution of depth. Perhaps the most attractive feature of this telescopic system is the ease with which the video camera can be coupled with the telescope.<sup>15</sup> Telescopic videolaryngoscopy has been widely used for examination and documentation of laryngeal diseases.<sup>15-25</sup> A simple method of videolaryngoscopy, using a right-angled telescope and a low-cost home video color camera was described by Yanagisawa et al in 1981.<sup>21</sup>

The purpose of this paper is to present our experience with fiberscopic and telescopic videolaryngos-

copy and compare them in the documentation of physiological and pathological conditions of the larynx.

### EQUIPMENT

#### VIDEO CAMERA

There are several fine quality miniature color video cameras specially designed for endoscopic documentation (Circon, Zeiss-Circon, Medicon, Olympus, and Syn-Optics). We have tried most of these and found them to be "almost equally effective." The cost of these cameras is, however, often prohibitive for the practicing otolaryngologist. Because of recent technological advances and widespread use of home video equipment, many compact, low-cost, portable color video cameras have now become available. A number of home video cameras have been tried for videolaryngoscopy; one of these, the Panasonic WV-3150 (or WV-3160) Newvicon color camera, fulfilled many requirements of laryngeal videotaping (Fig 1). We primarily used this camera for our study. This camera is an improved model of the WV-3100 previously described.<sup>21</sup>

The Panasonic WV-3150 is a fully self-contained, compact, and lightweight color camera. It weighs 2.75 kg. The camera has a 16-mm integral stripe filter electrostatic focus, magnetic deflection, separate mesh Newvicon tube ("low light" tube equivalent to Saticon). It receives its power from a Panasonic portable video cassette recorder (VCR) or an AC adapter. The 35-mm viewfinder, which is also used for VCR playback, is mounted on the camera head and its position can be easily changed so that the examiner can view the larynx during the procedure. The WV-3150 comes with telephoto lens

From the Section of Otolaryngology, Department of Surgery, Yale University School of Medicine, the Section of Otolaryngology, Department of Surgery, Hospital of St Raphael, and Haskins Laboratories, New Haven, Connecticut.

Presented at the meeting of the American Laryngological Association, New Orleans, April 10-11, 1983.

REPRINTS — Eiji Yanagisawa, MD, 98 York St, New Haven, CT 06511.



Fig 1. Panasonic WV-3150 home video color camera. Telephoto lens of camera is removed and replaced with video camera adapter to which fiberscope or telescope is attached.

6:1 (12.5 to 75 mm) f1.4 power zoom for routine televising.

The WV-3160 comes with 12:1 (10 to 120 mm f2.0) power zoom. The only difference between these two models is their zoom lens. Since the lens is not used for videolaryngoscopy, the less expensive WV-3150 model is recommended.

The zoom lens is detachable and a video adapter can be connected to the C-mount coupler on the camera body. A convenient power switch allows the camera to be turned off when not in use. This will spare the Newvicon tube. Another advantage of this camera is that its pistol grip is adjustable and can be turned in such a way that the examiner can hold the pistol grip comfortably in one hand.

The price of this camera at the time of this writing is about \$900 to \$950 (\$1,000 to \$1,100 for WV-3160).

It is important to emphasize that not all the home video cameras can be used for this videolaryngoscopy with a rigid telescope. Only the cameras equipped with a detachable lens, a C-mount coupler, and an adjustable or detachable hand-grip can be used for this technique.

In some cases, the JVC KY-2000 camera was also used with Wittmoser's articulated arm (Karl Storz).

#### LARYNGOSCOPES

Videolaryngoscopy can be accomplished with a flexible fiberoptic nasopharyngolaryngoscope or a rigid right-angled telescopic laryngoscope.

**Flexible Fiberscopes.** Two commonly used fiberscopes are 1) the Olympus ENF-P flexible fiberscope, and 2) the Machida ENT 4L (or ENT 3L) nasopharyngolaryngoscope. We used the Olympus ENF-P for this study (Fig 2A). We also used the Olympus ENF-L flexible fiberscope in some cases.

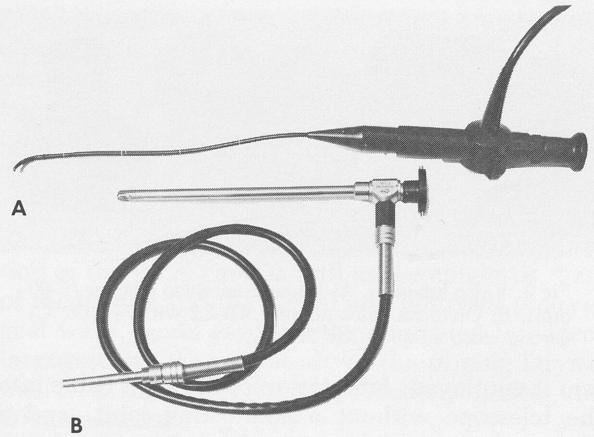


Fig 2. A) Olympus ENF-P flexible fiberscope. B) Nagashima SFT-1 rigid telescope.

The Olympus ENF-P is a slim scope 3.7 mm in diameter. It gives the wide angulation range, specifically 130° up and 90° down, providing easy and comfortable maneuverability. Simple thumb-movement control of tip bending in the ENF-P is an obvious advantage over designs with a knob on one side of the control head that calls for two-handed control. This is particularly true when it is used with the video camera.

**Rigid Right-Angled Telescopes.** Right-angled telescopes more commonly used today are 1) the Berci-Ward indirect laryngopharyngoscope with Hopkins telescope (8702D), 2) the magnifying laryngoscope with Hopkins telescope (8704D), 3) Stuckrad magnifying laryngoepipharyngoscope (Wolf), and 4) Nagashima SFT-1 laryngoscope.<sup>15,18,25</sup> We primarily used the Nagashima SFT-1 laryngoscope for this study (Kelleher Medical) (Fig 2B). The cost at the time of this writing is \$2,630. The Berci-Ward and Wolf magnifying telescopes were also used in some cases.

The Nagashima laryngoscope is a single integrated unit composed of a telescope and a light transmission system. It measures 24.5 cm in length and 9 mm in outer diameter. The angle of the prism at the tip of the laryngoscope is 70°, providing a right-angled view of the larynx. The rectangular outlets on each side of the lens offer well-balanced illumination of the viewing field. Each measures approximately 2 x 4 mm. The front lens diameter measures 4 x 3 mm. It gives a clear view of the larynx.

The telescope is connected to the 60-mm attachment lens on the video camera and its fiberoptic light cable to a xenon light source.

Light transmission of the Nagashima laryngoscope was excellent and provided brighter definition of the image than other endoscopes we tried. The reasons for this appeared to be the wide diameter of the telescope, the newer optical lens sys-






Fig 3. Video adapters. A) Nagashima video adapter (F-60 mm); B) Olympus video adapter AR-L2 with MC-08; C) Circon video adapter (MB 9885).

tem it employed, integration of the light cable into the telescope without a connecting joint, and a higher number of fibers in the light-transmitting system. The laryngoscope requires no additional light cable nor a special photographic sheath.

#### LIGHT SOURCE

The xenon cold light fountain (Karl Storz 487C), which produces approximately 6,000 K ("instant sunlight") and 300 W, was used for both fiberoptic and telescopic video documentation. The xenon light source is indispensable at present for satisfactory fiberoptic laryngoscopy.

#### VIDEO (CINE) ADAPTER

The Circon cine adapter and Olympus AR-L2 (Fig 3) were used with the Olympus ENF-P fiberoptic laryngoscope. We also experimented on our own cine adapter system consisting of a regular SLR camera lens and adapters. The Nagashima video adapter (f60 mm) (Fig 3) was used with the Nagashima laryngoscope for telescopic videolaryngoscopy.

#### VIDEO RECORDER AND MONITOR

Technically, any three-fourths inch (18-mm) or one-half inch (12.5-mm) video recorder can be used. Three-fourths inch Sony video cassette recorders V02610 and V05600 were used in this study. When needed, the three-fourths inch videotapes can be transferred to a one-half inch format through a series of commercially available coupling devices. A color monitor is ideal for televised laryngoscopy, but a more economical portable color television may be substituted.

#### METHOD

For telescopic videolaryngoscopy, the Nagashima laryngoscope was used in the majority of cases. The Berci-Ward laryngoscope (Karl Storz 8702D) and Stuckrad magnifying laryngoscope (Wolf) were used in some cases.

The patient and examiner sit facing each other (Fig 4). The soft palate and the posterior half of the tongue are topically anesthetized with 2% tetracaine hydrochloride (Pontocaine) solution. The telescope is connected to the video camera via the video adapter and its fiberoptic light cable to the xenon illuminator (Fig 4). The tip of the telescope is dipped in warm water and dried to prevent fogging of the lens during the examination. The video camera and then the illuminator are turned on. The xenon illuminator is set in the medium filming mode. The examiner holds

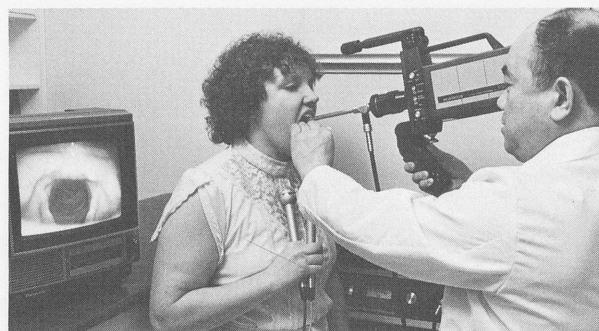

Fig 4. Technique of telescopic videolaryngoscopy. Larynx is viewed and centered on screen of TV monitor next to patient.

the video camera in one hand and inserts the telescope into the mouth while holding the patient's tongue with the other hand (Fig 4). When the desired image appears on the monitor screen, video recording is begun. The laryngeal image is centered on the screen by using the viewfinder of the camera or the television monitor.

For fiberoptic videolaryngoscopy, the Olympus ENF-P was primarily used with the Circon TV adapter or Olympus AR-L2 adapter. In some cases the Karl Storz adapter was used. We also experimented with our own video adapter system which will be reported later.

The nose is first examined and sprayed with 3% ephedrine to admit the fiberoptic without traumatizing hypertrophied turbinates. The side of the nose without septal spur and with wider air passage is chosen. The nose is lightly anesthetized with 2% tetracaine hydrochloride spray. The tip of the flexible fiberoptic is lightly lubricated and inserted into the nose gently (Fig 5). While observing the viewfinder of the camera or the monitor, the fiberoptic is gradually advanced until it reaches the posterior wall of the nasopharynx. Then the tip is bent downward and the fiberoptic advanced. The epiglottis is soon visible. The scope is passed to the level of the epiglottis, the larynx is centered on the screen, and the patient is ready for videotaping.

Every effort should be made to stabilize the camera and the laryngoscope to prevent image movement during videotaping. In some cases the camera was mounted on the tripod and the patient passed the fiberoptic into the nose with one hand while adjusting the control knob of the fiberoptic with the other hand.

An articulated optical attachment was used in some cases between the fiberoptic and the video adapter.

For both fiberoptic and telescopic videolaryngoscopy, the larynx was examined and videotaped on 1) respiration, 2) phonation, 3) singing, 4) effort closure, and 5) swallowing.

#### RESULTS

Of the 150 consecutive patients who had telescopic videolaryngoscopy, the procedure was successfully performed in all but five patients who could not tolerate the procedure because of anxiety and/or hyperactive gag reflex.

Of the 50 consecutive patients who had fiberoptic videolaryngoscopy, the procedure was successfully performed in all but two patients. One patient had a hypersensitive gag reflex and complained of severe pain in the nose. He was found to have a sharp septal spur. Another patient developed laryngospasm during the procedure as the tip of the fiberoptic touched the false cords. He became restless and his color turned blue. The fiberoptic

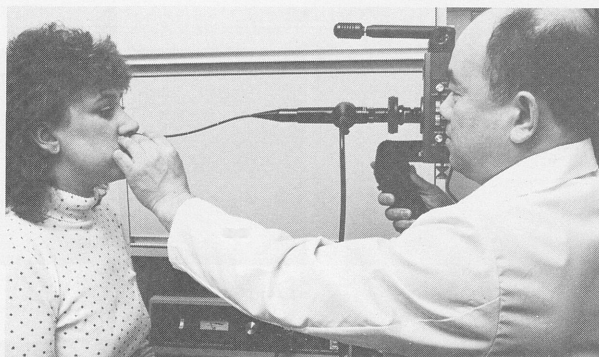


Fig 5. Technique of fiberoptic laryngoscopy. Examiner holds fibroscope and adjusts position of tip of fibroscope in one hand while holding camera in other hand.

was immediately removed. He fell to the floor and became unconscious. After immediate establishment of his upper airway and pounding of the chest, his color improved and he regained consciousness. There were no further complications.

#### PHYSIOLOGICAL FUNCTION

**Respiration.** During quiet inspiration the vocal cords abduct, widening the glottis (Fig 6A,C). During expiration they adduct slightly toward the midline (Fig 6B,D). The larynx moves as a body during respiration, downward during inspiration, and upward during expiration.<sup>26</sup>

These subtle changes of the vocal cords were well visualized by both the fibroscope and the telescope. Minute changes of vocal cords were, however, better appreciated by telescopic videolaryngoscopy (Fig 6C,D). The fiberscopes provided a panoramic view of the entire larynx, including the epiglottis, but even upon careful observation, fine mucosal change could not be well appreciated (Fig 6 A,B).

**Phonation.** Normal conversational speech could only be documented well by fiberoptic videolaryngoscopy (Fig 6E). When the tongue was held forward for telescopic documentation, the speech was distorted and difficult to understand.

Vibration of vocal cords during "eeh" phonation could be clearly demonstrated and videotaped by the telescope (Fig 6F-H). Fine segmental movement of the vocal cords at different frequencies could be well appreciated. With high-pitched sound, not only the true vocal cords but also false cords, aryepiglottic folds, and the entire wall of the hypopharynx vibrated.

**Singing.** Observation of the larynx during singing could much more effectively be studied by fiberoptic videolaryngoscopy (Fig 6I). Telescopic videolaryngoscopy provided a very poor, inadequate view of the larynx and distorted the singing voice. During singing, the vocal cord could not be seen except when the singer inhaled (Fig 6J). When simple effortless phonation was made, the entire vocal cord

could be well seen; this was not true during forceful effortful singing. The entire larynx moved and appeared to close and pull the base of the tongue backward, thus obstructing the laryngeal image by the base of the tongue and epiglottis even though the tongue was held tight (Fig 6J).

Fiberoptic videolaryngoscopy provided an unobstructed view of the entire larynx, and the vibration of the vocal cord as well as the epiglottis, base of the tongue and the lateral and posterior pharyngeal walls, could easily be demonstrated by videolaryngoscopy. For the study of the singing larynx, this is a superior method of demonstration and documentation (Fig 6E,I).

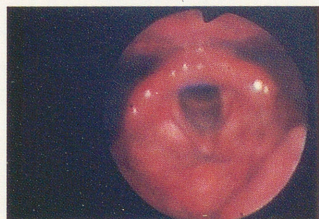
However, since the epiglottis moves up and down and tends to cover the anterior part of the vocal cord, the tip of the fibroscope may have to be carefully placed at the right height, usually just above the level of the tip of the epiglottis. When the tip was brought close to the vocal cord, then the epiglottis touched the fibroscope, making it difficult to sing. Fogging of the tip of the fibroscope was one of the problems during the examination. This could be eliminated by having the patient swallow. In this way, the lens of the fibroscope was wiped clean by the epiglottis or base of the tongue and a clear view of the larynx was obtained.

**Glottal Effort Closure.** Video photography could better be accomplished by telescopic photography because this gave an unobstructed view of the entire vocal cords since the tongue is pulled outward. Both light and forceful coughing were easily observed. Slow motion is easily obtained with the recorder's pause and slow-motion features. The fiberoptic examination could not show the entire phase of coughing because the epiglottis moved too much and prevented good visualization of the vocal cords (Fig 6K,L). This also produced repeated glares on the TV monitor. Telescopic examination is an excellent way to study this vital function of the larynx (Fig 6M-P).

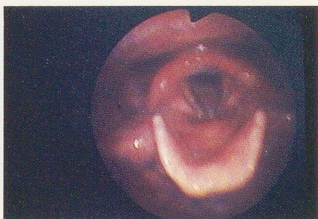
**Swallowing.** One of the chief functions of the larynx is to protect the lungs from ingestion of solids and liquids. Consequently, closure of the airway during swallowing is essential. The epiglottis serves as a laryngeal shield to direct swallowing of food laterally into the pyriform fossae and away from the midline laryngeal aperture. This protective function is enhanced by elevation of the larynx toward the nasal cavity during the height of the deglutition. The corniculate and the cuneiform cartilages are contained in the aryepiglottic folds to provide stiffness and support to these structures.

The larynx was observed while the patients swallowed liquids and pills (Fig 6Q-T). The function of swallowing is better studied by the flexible fibroscope. Since the tongue is held in telescopic laryngoscopy, it is impossible to see the active swallow-

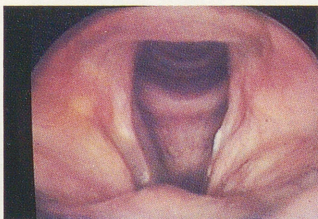




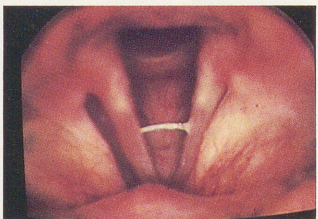
A



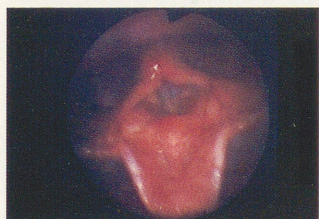B



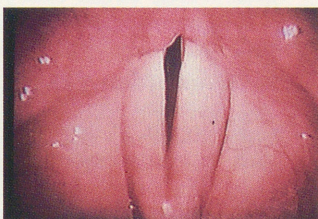
C



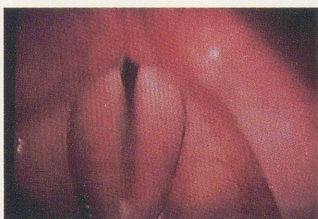
D



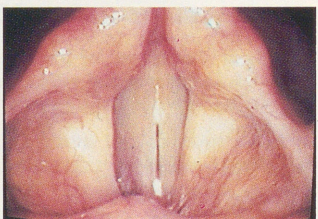
E



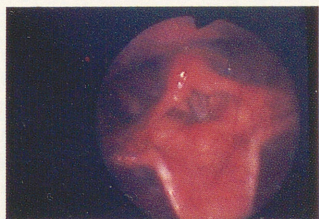F



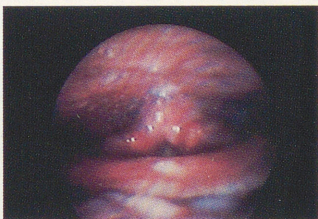G



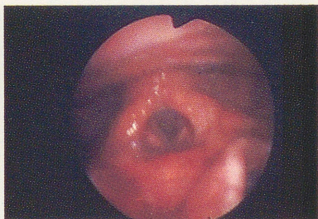
H



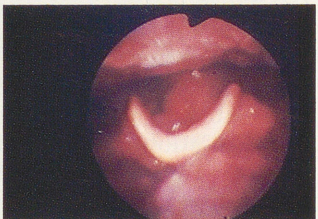
I



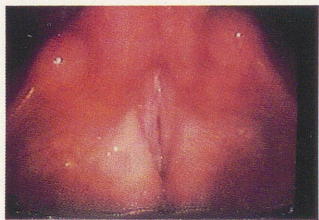
J



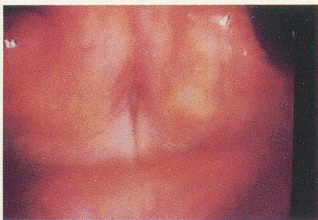K



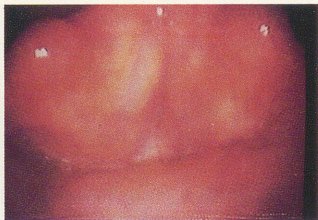
L



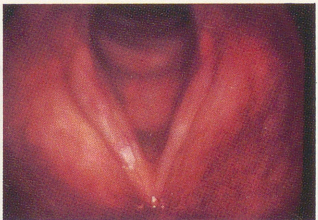
M



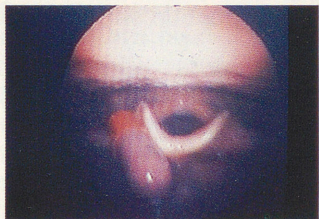
N



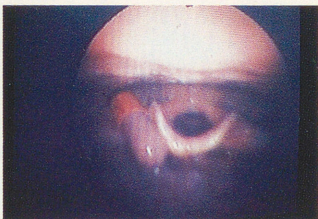
O



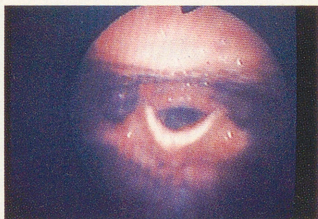P



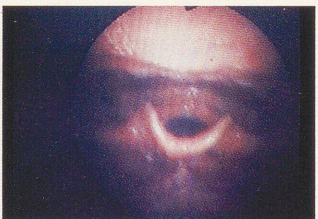
Q



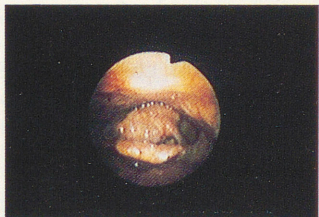R



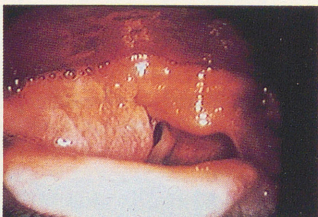
S



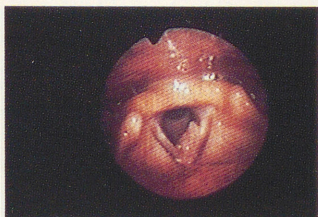
T



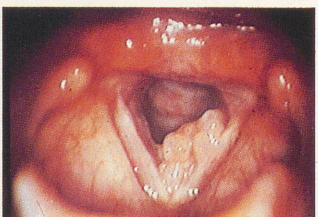
U



V



W



X



## COMPARISONS OF FIBERSCOPIC AND TELESCOPIC VIDEOLARYNGOSCOPY

	<i>Fiberscopic Videolaryngoscopy</i>	<i>Telescopic Videolaryngoscopy</i>
Laryngoscope	Olympic ENF-P Total length 475 mm Outer diameter 3.7 mm Approx cost \$3,000	Nagashima SFT-1 Total length 245 mm Outer diameter 9 mm Approx cost \$2,630
Video camera	Panasonic Newvicon WV 3150 (\$900-1,000) WV 3160 (\$1,000-1,100) Circon (\$9,000 & up) JVC KY-2,000 (approx \$10,000)	Panasonic Newvicon WV 3150 (\$900-1,000) WV 3160 (\$1,000-1,100)
Adapter	Olympus AR-L2 with MC-08 Circon	Nagashima video adapter (f-60 mm)
Image resolution	Fair-good	Excellent
Patients' acceptance	Excellent with topical anesthesia	Very good-excellent with topical anesthesia
Physiology-phonation (vocal cord vibration)	Fair-good	Excellent minute detail
Respiration	Excellent	Excellent
Effort closure (coughing)	Very good	Very good-excellent
Swallowing	Excellent	Not recommended for fear of aspiration (difficult to swallow with tongue pulled)
Singing	Excellent (for singers and professionals)	Poor, "distorted" voice (both visualization and voice recording)
Pathology		
Clarity	Very good	Excellent
Upper border of tumor	Excellent	Excellent
Lower border of tumor	Very good	Poor

ing, or it may even be dangerous since there is a chance of aspiration of ingested material.

## PATHOLOGICAL CONDITIONS

Pathological states of the larynx could be studied effectively either by fiberoptic or telescopic examination (Fig 6U-X). While the upper extent of a tumor could be appreciated well either by the fiberoptic or the telescope, the lower end could be better visualized and documented by fiberoptic examination. This is because the tip of the small size fiberoptic could be passed beyond the area of the obstruction. However, this examination should be done with caution, since it may precipitate laryngospasm. It should be done under light topical anesthesia and with the emergency upper airway equipment near at hand. In general, telescopic documentation provided a much clearer, sharper image on the screen than the fiberoptic laryngoscopy (Fig 6V,X). In case of paralysis of the vocal cord, the shortening of the true and false cords on the normal side could be better appreciated by telescopic observation than fiberoptic observation.

## COMMENTS

Both fiberoptic and telescopic videolaryngoscopy have advantages and disadvantages (Table).

One of the most significant advantages of fiberoptic laryngoscopy is the ease of the examination. Fiberoptic videolaryngoscopy is the procedure of choice for children or hypersensitive adult patients whose larynx cannot be examined either by a mirror or a telescope. The use of the fiberoptic may prevent unnecessary direct laryngoscopy under general anesthesia for these patients.

Fiberoptic videolaryngoscopy is of great value for voice analysis of functional and organic disorders and for evaluation of the physiological functions of the larynx. Respiration, phonation, glottal effort closure, and swallowing can be studied effectively with the fiberoptic. It is very useful for the voice therapist or speech pathologist because they can demonstrate normal and abnormal speech patterns both to the patient for counseling and in order to teach about such functional disorders as psychogenic dysphonia, spastic dysphonia, and stutter-

Fig 6. Representative video images of laryngeal conditions photographed from TV monitor screen. A,B) Olympus ENF-P, JVC KY-2000. A) Inspiration; B) Expiration. C,D) Nagashima SFT-1, Panasonic WV 3150. C) Inspiration; D) Expiration. E) Olympus ENF-P, JVC KY-2000. Phonation. F-H) Nagashima SFT-1, Panasonic WV 3150. F) Phonation at low pitch; note only minimal vibration of true cords. G) Phonation at medium range intensity; note increased range of vocal cord vibration. H) Phonation at high pitch and intensity; note intense approximation of vocal cords. I) Olympus ENF-P, JVC KY-2000. Singing; note entire vocal cords are visible. J) Nagashima SFT-1, Hitachi HV 9015. Singing; epiglottis obstructs visualization of vocal cords. K) Olympus ENF-P, Panasonic WV 3150. Effort closure; note beginning of approximation of false cords. L) Olympus ENF-P, Panasonic WV 3150. Effort closure; note closure of laryngeal inlet by arytenoids, false cords, and epiglottis. M-P) Nagashima SFT-1, Panasonic WV 3150. Coughing. M) Approximation of true vocal cords. N) Elevation of arytenoids, approximation of false cords, posterior displacement of epiglottis. O) Complete enclosure of laryngeal inlet just prior to expulsion. P) Inspiration immediately after coughing. Q-T) Olympus ENF-P, Panasonic WV 3150. Swallowing. Q) Swallowed capsule in vallecula. R) Capsule entering pyriform sinus. S) Capsule at bottom of pyriform sinus. T) Disappearance of capsule into esophagus. U) Olympus ENF-P, Panasonic WV 3150. Squamous carcinoma of aryepiglottic fold. V) Nagashima SFT-1, Panasonic WV 3150. Squamous carcinoma of aryepiglottic fold. W) Olympus ENF-P, Panasonic WV 3150. Papilloma of larynx. X) Nagashima SFT-1, Panasonic WV 3150. Papilloma of larynx.



ing.<sup>3,8,9,12</sup> Fiberscopic videolaryngoscopy is very useful for singers to study and improve their own methods of singing. It also provides an opportunity to observe and document disorders of the upper airway structures such as the nasal cavities, nasopharynx, the posterior surface of the soft palate, as well as the larynx.

Some of the disadvantages of fiberscopic videolaryngoscopy are: 1) it provides smaller, less clear, more distorted pictures of the larynx, 2) it requires a very powerful light source (xenon) for videotaping because of the small size of the fiberscope (3 mm in diameter) and the long distance between the larynx and the camera (475 mm), and 3) it may not demonstrate minor mucosal changes and early lesions of vocal cords clearly.

Telescopic photography provides much clearer, sharper, brighter, and larger images of the larynx. For documentation of anatomical or structural changes of the larynx, telescopic videolaryngoscopy is far superior in our experience (Fig 6C,D,F-H, M-P). The most significant advantage of telescopic videolaryngoscopy is the clear video image of high resolution. Photography of the laryngeal image on the TV screen produces surprisingly good pictures (Fig 6A-T).

Although telescopic videolaryngoscopy is not ideal for evaluation of speech and singing, the vibration

of vocal folds on phonation is much more clearly shown by this system than by fiberscopic videolaryngoscopy. The vocal cords usually vibrate at 100 to 300 Hz during normal conversation and even at 1,000 Hz or more during singing.<sup>27</sup> For observation of such vibrations, stroboscopy and ultra high-speed photography have been recommended.<sup>27</sup> Stroboscopy is very useful for clinical purposes. Ultra high-speed photography has been employed chiefly for research and clinical purposes. The apparatus for these methods is too expensive and the data processing is too time consuming for most clinicians. The authors feel that telescopic videolaryngoscopy is the simpler and far less expensive method of observation of vocal cord vibration. The changes of vocal cord vibration by different pitch can also be observed.<sup>21</sup>

For precise evaluation and adequate documentation of both functional and structural changes of the larynx, the authors recommend the use of the telescope as a basic tool and the fiberscope as a backup or supplemental equipment.

Some of the disadvantages of telescopic videolaryngoscopy are that 1) children and some adults with hyperactive gag reflexes may not be able to tolerate this procedure, 2) fogging of the telescopic lens during the procedure is more common, and 3) normal speech and singing voice are distorted and laryngeal image is difficult to observe during speech and singing.

ACKNOWLEDGMENT — The authors wish to express their appreciation to Dr John A. Kirchner for his critical review of this paper.

## REFERENCES

1. Sawashima M, Hirose H. New laryngoscopic technique by use of fiber optics. *J Acoust Soc Am* 1968; 43:168-9.
2. Davidson TM, Bone RC, Nahum AM. Flexible fiberoptic laryngobronchoscopy. *Laryngoscope* 1974; 84:1876-82.
3. Brewer DW, McCall G. Visible laryngeal changes during voice therapy: fiber-optic study. *Ann Otol Rhinol Laryngol* 1974; 83:423-7.
4. Brewer DW, Gould LV, Casper J. Fiber-optic video study of the post-laryngectomized voice. *Laryngoscope* 1975; 85:666-70.
5. Dellon AL, Hall CA, Chretien PB. Fiberoptic endoscopy in the head and neck region. *Plast Reconstr Surg* 1975; 55:466-71.
6. Williams GT, Farquharson IM, Anthony J. Fiberoptic laryngoscopy in the assessment of laryngeal disorders. *J Laryngol Otol* 1975; 89:299-316.
7. Silberman HD, Wilf H, Tucker JA. Flexible fiberoptic nasopharyngolaryngoscope. *Ann Otol Rhinol Laryngol* 1976; 85:640-5.
8. Conture EG, McCall GN, Brewer DW. Laryngeal behavior during stuttering. *J Speech Hear Res* 1977; 20:661-8.
9. Parnes SM, Lavorato AS, Myers EN. Study of spastic dysphonia using videofiberoptic laryngoscopy. *Ann Otol Rhinol Laryngol* 1978; 87:322-6.
10. Tobin HA. Office fiberoptic laryngeal photography. *Otolaryngol Head Neck Surg* 1980; 88:172-3.
11. Witton TH. An introduction to the fiberoptic laryngoscope. *Can Anaesth Soc J* 1981; 28:475-8.
12. Chapey R, Salzberg A. The speech clinician's use of fiberoptics in indirect laryngoscopy. *J Commun Disord* 1981; 14:87-90.
13. Sessions DG. Recent advances in surgery of the larynx and trachea. *Head Neck Surg* 1982; 5:42-52.
14. Welch AR. The practical and economic value of flexible system laryngoscopy. *J Laryngol Otol* 1982; 96:1125-9.
15. Ward PH, Berci G, Calcaterra TC. Advances in endoscopic examination of the respiratory system. *Ann Otol Rhinol Laryngol* 1974; 83:754-60.
16. Strong MS. Diagnosis of carcinoma of the larynx: a review of current methods. *Laryngoscope* 1975; 85:516-21.
17. Andrews AH Jr, Gould WJ. Laryngeal and nasopharyngeal indirect telescope. *Ann Otol Rhinol Laryngol* 1977; 86:627.
18. Berci G. Analysis of new optical systems in bronchoscopy. *Ann Otol Rhinol Laryngol* 1978; 87:451-60.
19. Gould WJ, Kojima H, Lambiasi A. A technique for stroboscopic examination of the vocal folds using fiberoptics. *Arch Otolaryngol* 1979; 105:285.
20. Saito S, Isogai Y, Fukuda H, et al. A newly developed curved laryngotelescope. *J Jpn Bronchoesophagol Soc* 1981; 32:328-31.
21. Yanagisawa E, Casuccio JR, Suzuki M. Video laryngoscopy using a rigid telescope and video home system color camera. A useful office procedure. *Ann Otol Rhinol Laryngol* 1981; 90:346-50.
22. Konrad HR, Hopla DM, Bussen J, Griswold FC. Use of videotape in diagnosis and treatment of cancer of larynx. *Ann Otol Rhinol Laryngol* 1981; 90:398-400.
23. Hirano M. Phonosurgery, basic and clinical investigations. *Otologia (Fukuoka)* 1975; 21 (suppl 1):239-440.
24. Yoshida Y, Hirano M, Nakajima T. A video-tape recording system for laryngo-stroboscopy. *J Jpn Bronchoesophagol Soc* 1979; 30:1-5.
25. Yanagisawa E. Office telescopic photography of the larynx. *Ann Otol Rhinol Laryngol* 1982; 91:354-8.
26. Aronson AE. Clinical voice disorders, an interdisciplinary approach. New York: Thieme-Stratton, 1980.
27. Hirano M. Clinical examination of voice. Disorders of communication. New York: Springer-Verlag Wien, 1981.

# VOICE CHANGE IN THE PEDIATRIC PATIENT

## A DIFFERENTIAL DIAGNOSIS

SEYMOUR R. COHEN, MD  
KENNETH A. GELLER, MD

JEROME W. THOMPSON, MD  
JEFFREY W. BIRNS, MD

LOS ANGELES, CALIFORNIA

This paper reviews the causes of voice change in the infant and child. Symptoms of dysphonia can be very early evidence of a serious problem, either within the larynx or resulting from a systemic disease. The need to investigate the cause of voice disturbances is stressed. The large number of diseases in which voice change occurs makes a complete examination of the child, both local and systemic, absolutely necessary in order to arrive at a specific diagnosis. The mechanism of voice change is described in each category of the numerous causes of dysphonia.

### INTRODUCTION

The cry of the newborn infant heralds its arrival into a completely new environment. An abnormal cry should alert the attendants and physician to the possibility of a potentially serious pathological process. The child's voice will be expressive of health and disease throughout its life. Very early in infancy the voice will express pain, hunger, and discomfort. Later, phonation will evolve into the important means of expression and communication so necessary for a normal life. When the newborn infant's voice lacks normal volume, pitch, or quality, those in attendance should be on guard and search for the possibility of a local laryngeal abnormality, an airway problem, or genetic or systemic disease. In later life, changes of the voice will indicate the possibility of a potentially serious abnormality.

The larynx, frequently referred to as the organ of voice, was not originally intended as such. In the evolution of the larynx, its primary function was respiratory, its secondary function was protective, and finally the organ developed a phonatory function.<sup>1</sup> The larynx, originally intended to adapt the organism from a water to a land animal, undergoes further adaptation with the development of a phonatory function in order to protect the species by alerting it to potential danger. The broad phonatory range in the human is closely allied to the high degree of development of the central nervous system (CNS).<sup>1</sup>

The importance of voice change in the child has not been stressed in the literature. Dysphonia in the adult creates concern because of the possibility of a malignancy and is, therefore, more likely to initiate early investigation. In clinical practice, probably because of the rarity of malignancy and the difficulty of examination of the child's larynx, it is common to postpone examination when voice change

occurs. The physician or parent frequently dismisses this symptom as being due to laryngitis, from infection or abuse, and assumes that the symptom is temporary and will resolve itself. This delay may be responsible for progressive laryngeal obstruction and other potentially serious complications. The larynx must be fully mature and without defect at birth to function normally. It will grow and mature from the newborn period throughout adolescence and early adult life.

### PURPOSE AND METHOD

The presentation of this paper was stimulated by the relative lack of concern by professionals who see and treat children with voice change. Examination or referral was postponed in many children, and in some instances serious life-threatening airway problems occurred. While it is true that in a large percentage of these patients postponement was not of great importance, in some children serious laryngeal problems resulted. It is the purpose of this paper to stress the importance of voice change in the pediatric age group and to document the multiple causes of vocal disturbances. An explanation of the mechanisms of these changes will be outlined. The multiple conditions producing dysphonia are so extensive that it would be impossible to be absolute and complete in these listings.

It is hoped that by this presentation the physician will have available a detailed outline of the causes and mechanisms of voice change in the child. The following causes will be discussed: 1) neurological, 2) congenital and genetic anomalies, 3) tumors, 4) infection and granulomatous disease, 5) trauma, 6) endocrine and metabolic, 7) physiological, 8) psychogenic, and 9) iatrogenic.

### PATHOGENESIS

Voice change depends on the size and location of

From the Department of Surgery, Division of Otolaryngology, The Childrens Hospital of Los Angeles, and the University of Southern California School of Medicine, Los Angeles.

Presented at the meeting of the American Laryngological Association, New Orleans, April 10-11, 1983.



TABLE 1. INTRACRANIAL AND EXTRACRANIAL CAUSES OF VOICE CHANGE

<i>Intracranial</i>	<i>Extracranial</i>	<i>Intracranial and Extracranial</i>
Cortical neuronal	Motor unit	Trauma
Kernicterus	Toxins	Birth
Globoid cell leukodystrophy	Botulism	Blunt
Krabbe's disease	Myasthenia gravis	Surgical
Chediak-Higashi disease	Muscular dystrophy	Cardiac
Wilson's disease (Cu)	Werdnig-Hoffmann's disease	Great vessel abnormalities
Toxins (Pb, Hg)		Mediastinal disease
Metabolic storage defects	Others	
Hemorrhage	Meningitis	
Trauma	Infectious mononucleosis	
Anoxic encephalopathy	Deep neck infections	
Ischemia	Chemotherapy	
Neoplasia		
Cortical axonal		
Hallervorden-Spatz disease		
Multiple sclerosis		
Huntington's chorea		
Ramsay-Hunt syndrome		
Neoplasia		
Nuclear		
Pseudobulbar palsy		
Syringobulbia		
Syphilis		
Polyneuritis		
Postencephalitic syndrome		
Trauma (skull base)		
Neoplasia		
Meningomyelocele		
Arnold-Chiari malformation		

the lesion. It always indicates some abnormality of structure, function, or development. Given the infinite delicacy of the process of phonation, minimal alteration can produce changes in the voice. Slight changes produced by any of the multiple diseases may alter the glottic airflow, pitch, volume, timbre, or resonance. This paper deals only with the phonatory aspect of the voice, which is distinct from that of speech. For the normal mechanism of voice production, the reader is referred to the work of Fink and Demerest on laryngeal biomechanics.<sup>2</sup>

#### CAUSES OF VOICE CHANGE

*Neurological Dysfunction.* The neuroanatomy is complex and the distance traversed by the nerves is great. This anatomic feature creates increased vulnerability of nerves to injury or disruption. Three major divisions will be considered in discussing these anatomic features: 1) intracranial, 2) extracranial, and 3) motor unit.

The intracranial region has three subcomponents, neuronal, axonal, and ganglionic. The initial impulses that lead to phonation begin in the cerebral cortex located in the frontal, parietal, and occipital areas. The lower portion of the precentral gyrus which predominates is known as Broca's speech area and gives rise to the central axonal nerve fibers that run through the lower motoneuron nuclei which control the laryngeal muscles (corticobulbar tracts).<sup>3</sup> These fibers reach the bulbar nuclei after passing through the internal capsule, cerebral peduncles, pons, and pyramidal tracts, and partially decussate before entering the nucleus ambiguus.<sup>4</sup> It is from this area that the peripheral axons arise

and descend into the jugular ganglion and enter the extracranial nodose ganglion.

When intracranial neurons and axons are damaged, the hoarseness that results is due to spastic incoordination, which is a direct result of loss of upper motoneuron inhibitory control of competitive muscles.<sup>5</sup>

The most proximal site, the cortical neuron itself, may degenerate as a result of many diseases associated with toxins, and metabolic and storage diseases.<sup>6-9</sup> These substances bring about destruction and dysfunction and produce hoarseness with a spastic paralysis. The neuron can also be damaged during stroke, anoxia, hemorrhage, or trauma by producing physical compression and ischemic damage (Table 1).

The central axon or corticobulbar tracts can be affected by numerous diseases which cause degeneration (Table 1). These diseases produce spastic paralysis or pareses.<sup>10-14</sup>

The nucleus ambiguus or lower motoneuron ganglia of the laryngeal nerve is intracranial, but is the first site where an injury produces a flaccid paralysis as a result of partial or complete interruption of transmission whether competitive or synergistic.<sup>15,16</sup> (Table 1). All of the intracranial and extracranial fibers can be affected by inflammation or neoplastic disease with destruction of the neurons and axons (Table 1).

As with bulbar lesions, extracranial involvement tends to produce a flaccid paralysis because of the lack of any signal being transmitted through damaged, severed, or dead nerves (Table 1). Cardiovas-

TABLE 2. CONGENITAL AND CHROMOSOMAL CAUSES OF VOICE CHANGE

<i>Congenital</i>	<i>Chromosomal</i>	<i>Miscellaneous</i>
Atresia	Achondroplasia	Epidermolysis bullosa
Laryngomalacia	Bloom's syndrome	Arthrogyposis multiplex congenita
Subglottic stenosis	Cockayne's syndrome	
Webs	Diastrophic dwarfism	
Cysts	De Lange's syndrome	
Paralysis	Dubowitz's syndrome	
Clefts	Dysautonomia	
	G syndrome	
	Osteochondromuscular dystrophy	
	Shprintzen-Goldberg syndrome	
	Williams' syndrome	
	Cri du chat syndrome	
	Lysozymal storage disease	
	Hunter's disease	
	Hurler's disease	
	LeRoy's syndrome	
	Maroteaux-Lamy disease	
	Morquio's disease	
	Pseudo-Hurler's disease	
	Sanfilippo's disease	

cular disease and trauma are most likely to produce compression or disruption in the long extracranial axonal segment of the system.<sup>17</sup>

The motor end-plate is the last area where disease can produce neuromediated voice change. The long peripheral axons terminate at the synapses near the muscle fibers. It is here that presynaptic dysfunction occurs as is seen in certain toxins such as botulism,<sup>18</sup> and an autoimmune disease, myasthenia gravis<sup>19</sup> (Table 1).

The final site of neuromotor dysfunction is the motor unit itself. Failure of the laryngeal muscles to function and thus produce voice change is seen in muscular dystrophies. These are felt to be due to abnormal surface proteins leading to altered function and the development of dystrophic fibers. For the laryngologist, Duchenne's progressive muscular dystrophy is of importance since it may affect the muscles of the larynx and pharynx<sup>20,21</sup> (Table 1).

Werdnig-Hoffman's disease (spinal muscular atrophy) is of unknown etiology and produces denervation of muscle fibers progressing to atrophy. Severe hypotonia occurs at birth and is associated with a muffled, hoarse cry.

It should be stressed that voice change may be the earliest clinical sign or symptom of a catastrophic neurological disorder.

*Congenital and Chromosomal Defects.* Not all congenital defects of the larynx produce voice change. The observer should be cautious about misinterpreting sounds emanating from the child's airway as being phonatory when in actuality it is stridor. The voice is distinct from these sounds whether volitional or reflex. Dysphonia is produced by a number of congenital defects<sup>22</sup> and chromosomal defects (Table 2).

The most serious form of congenital deformity of the larynx is complete atresia in which the voice is absent and the airway is completely obstructed.<sup>23</sup> Immediate tracheotomy is essential. Laryngomalacia, while usually not associated with voice change, can, in the severe arytenoid type, produce hoarseness. Webs of the glottic area produce serious impairment of the voice and like cysts of the vestibular area, also produce airway obstruction. Subglottic stenosis varies in severity and reduces airflow so that the voice may be of normal pitch but lacks loudness. While the voice in abductor paralysis may be normal, although breathy, the voice is modified by the position of the vocal cords. In adductor paralysis, voice change may be severe with associated varying degrees of aspiration.<sup>24</sup> Posterior cleft larynx and laryngotracheoesophageal clefts are always associated with voice change and aspiration problems. The defect or absence of the tracheoesophageal septum and the interarytenoid muscle prevents apposition of the posterior portion of the larynx, thus creating dysphonia.<sup>25</sup>

*Tumors.* Tumors of the larynx which cause voice change may be benign or malignant. Fortunately, most of the tumors of the larynx seen in children are benign; malignant tumors are extremely rare. While a lesion in the larynx may appear benign, adequate biopsy is mandatory to rule out the possibility of a malignancy. Malignant and benign tumors produce voice change of varying degrees. Theoretically, every type of tumor seen in the adult can occur in the pediatric larynx.<sup>26</sup>

Benign tumors may be considered nonneoplastic or neoplastic<sup>26</sup> (Table 3). Nonneoplastic tumors are of inflammatory, traumatic, or infectious origin. Irritative processes within the larynx play an important role in the development of this type of tumor which grows slowly and never infiltrates. Some of



TABLE 3. TUMORS OF THE LARYNX CAUSING VOICE CHANGE

<i>Benign Nonneoplastic</i>	<i>Benign Neoplastic</i>	<i>Malignant</i>	<i>Unusual</i>
Squamous papilloma	Papilloma	Squamous cell carcinoma	Wegener's granulomatosis
Vocal nodules	Hemangioma	Fibrosarcoma	Lymphogranulomatosis
Polyps	Hygroma	Lymphosarcoma	
Granulomata*	Cysts	Chondrosarcoma	
Prolapsed ventricle	Neurofibroma	Rhabdomyosarcoma	
Hematoma	Hamartoma	Plasmacytoma	
Fibroangioma	Myxoma	Leukemia	
Fibroma	Xanthoma	Neuroblastoma	
Reinke's edema	Granular cell myoblastoma		
	Fibromatosis		
	Ectopic thyroid		
	Chondroma		
	Myoma		
	Adenoma		

\*Infection, foreign body, trauma, caustic ingestion.

these lesions are produced by trauma, caustic ingestion, infections, or foreign body intrusion. Tumors of this type, which arise from the vocal cords, create dysphonia by changes in the mass of the vocal cords. The most common lesion of this type is the vocal cord nodule which results from vocal abuse and is always in the anterior one third of the true vocal cords. These lesions are almost always symmetrical and bilateral and occur in children with cleft palate and velopharyngeal valving problems.<sup>27</sup> Surgical treatment is rarely necessary for this condition, but other lesions in this category of benign tumors require surgical management.

Of the benign neoplastic tumors of the larynx, papilloma and hemangioma are the most common. These produce voice change only when the true vocal cords, arytenoids, or cricoarytenoid joints are involved. Other benign tumors produce voice change by encroachment upon the vocal cords or surrounding structures (Table 3). Diagnosis must be made by direct laryngoscopy and biopsy so that appropriate therapy may be instituted.

Malignant tumors of the larynx in children are extremely rare and may arise from elements of epithelium, connective tissue, neural tissue, and hematological tissue, and may, on rare occasions, be of metastatic origin.<sup>28</sup> Malignant tumors arising anywhere within the larynx will be invasive and may produce vocal problems quite early (Table 3).

**Infections.** Infections may involve the larynx in many ways. Viral infections produce hoarseness through edema of the vocal mucosa, often with superficial ulcerations. All major respiratory viruses (Table 4) have been reported to cause hoarseness which may be present in up to 20% of common respiratory illnesses. Smallpox, chickenpox, and herpes simplex viruses may produce vesicular laryngeal lesions.<sup>29</sup>

Bacterial laryngitis due to *Streptococcus pneumoniae* and *Staphylococcus aureus* generally produce vocal cord hyperemia and edema. In some forms of bacterial laryngitis ulcerative lesions may

occur. Diphtheritic membrane may interfere with vocal cord adduction and produce hoarseness by its mass effect<sup>30</sup> (Table 4).

Eighty percent of rhinoscleroma patients suffer laryngeal involvement. The initial catarrhal stage is followed by granulomatous nodules usually in the glottis, but may occur anywhere in the larynx, eventually leading to ulceration and fibrosis.<sup>31</sup>

Actinomycosis is rarely primary in the larynx which is affected by extension from cervical or mandibular regions. Ulceration, chondritis, and fibrosis cause cricoarytenoid joint fixation.

Granulomatous diseases,<sup>31,32</sup> of which tuberculosis is the most common, produce early diffuse hyperemia and edema ultimately resulting in chondritis. In tuberculosis, the larynx is almost invariably accompanied by active pulmonary and frequently cavitory disease. Some of the granulomatous diseases are associated with infiltration or nerve involvement with resultant polyneuritis as is seen in sarcoidosis (Table 4). Fungal diseases such as coccidioidomycosis<sup>32</sup> produce proliferative granulomatous lesions of the larynx leading to ulceration and fibrosis (Table 4). Congenital syphilis may produce erythematous and edematous patches in the larynx, and when associated with secondary bacterial infection, ulceration and scarring may occur.<sup>29</sup>

**Trauma.** External trauma to the neck, whether by open or closed injury, may compress the larynx against the cervical spine and produce soft-tissue edema within the endolarynx. Dislocation, contusion, and fractures of the hyoid, thyroid or cricoid cartilages may occur. The cricoarytenoid joint may be dislocated, fractured, ankylosed, or distorted by adhesions or granulations. Direct injury to the laryngeal elevator and depressor muscles needed to stabilize the larynx for phonation, or injury to the cricothyroid muscle required to tense the vocal cords, may affect vocal register<sup>30</sup> (Table 4).

Endotracheal intubation may produce vocal cord edema, hematoma, mucosal laceration or ulcera-

TABLE 4. INFECTIONS, GRANULOMATOUS DISEASES, AND TRAUMA CAUSING VOICE CHANGE

Viral	Bacterial	Fungal	Miscellaneous	Trauma (direct)	Extra-laryngeal
Influenza	<i>S pneumoniae</i>	Blastomycosis	Wegener's granulomatosis	External	Skull
Rhinovirus	<i>S aureus</i>	Histoplasmosis	Sarcoidosis	Intubation	Cervical
Adenovirus	<i>Haemophilus influenzae</i> , type B	Coccidioidomycosis	Amyloidosis	Nasogastric tube	Thoracic
Parainfluenza		Aspergillosis		Foreign body	Surgical
Coxsackie A21	<i>Salmonella typhi</i>	Rhinosporidiosis		Burns	
Herpes simplex	<i>Pseudomonas</i>	<i>Candida</i>		Smoke	
Varicella	<i>Fusobacterium</i>			Gastroesophageal reflux	
Variola	Diphtheria			Irradiation	
	Rhinoscleroma			Irradiation	
	Actinomycosis			Abusive	
	<i>Mycobacterium tuberculosis</i>				
	<i>Mycobacterium leprae</i>				

tions, granulations, and avulsions of the true vocal cords or the arytenoid. Anterior commissure webbing or cricoarytenoid joint fixation followed by posterior glottic stenosis may occur.

An indwelling nasogastric tube may erode the posterior cricoid lamina, producing cricoid chondritis with laryngeal edema or cricoarytenoid joint fixation.<sup>33</sup>

Noxious agents and aspirated or inhaled foreign bodies produce hyperemia and edema. Stomach contents from gastroesophageal reflux produce chronic changes of hyperemia and edema with potential stenosis. In advanced stages, Reinke's edema will occur with diffuse irregular thickening of the vocal cord mucosa.

Extralaryngeal trauma with injury to the recurrent nerves may be produced by trauma to the neck or surgery on the cervical and thoracic areas (Table 4).

**Metabolic and Endocrine Diseases.** Numerous metabolic and endocrine diseases involve the larynx and are associated with dysfunction and voice change.<sup>34</sup> Any of the errors of metabolism which disrupt normal enzymatic sequences can cause faulty nerve and muscle function. Numerous metabolic substances can infiltrate and also thereby disrupt normal neuromuscular function or result in abnormal connective tissue affecting normal joint mobility of the larynx.

Hypocalcemia leads to motor nerve hyperexcitability and produces laryngospasm, generalized seizures, and cyanosis from airway obstruction. The DiGeorge syndrome is associated with parathyroid hypoplasia, thymic hypoplasia, and cardiovascular abnormalities. Hypocalcemia is associated with numerous conditions.

In hypoparathyroidism, inorganic serum phosphorous increases and serum calcium decreases, leading to increased neuromuscular excitability secondary to disruption of membrane permeability to sodium and potassium ions.

Hypothyroidism can be present at birth and is usually caused by aplasia of the thyroid gland in 70% to 80% of these patients.<sup>34</sup> The cause is unknown. In severe hypothyroidism, there is generalized hypotonia of the muscles including the laryngeal musculature. In addition, voice change is produced by myxedematous infiltration of the laryngeal musculature.

Hypoglycemia in infants and children may cause hoarseness due to generalized muscle weakness and may be associated with mental retardation and/or severe neurological deficiency.

The lipid-storage diseases are characterized by various enzyme deficiencies which lead to the accumulation of abnormal lipids in the reticuloendothelial system and CNS. Hypertonicity with dysphagia and laryngospasm (Gaucher's disease) and hypotonicity and CNS deterioration (Niemann-Pick disease) are seen in this category of diseases. In Tay-Sachs disease, a deficiency of a ganglioside catabolic enzyme, hexosaminidase A, rapid neurological deterioration with blindness and convulsive seizures, and laryngeal dysfunction occurs.

Muscular dystrophy is caused by defects in the energy-producing or contractile mechanisms of the muscle fibers. Laryngeal involvement is not uncommon.

Myotonic disorders are caused by an abnormally prolonged contractile state of the skeletal muscles. Myotonia congenita is a familial disease known as Thomsen's disease. Associated symptoms are difficulty in chewing, speaking, and breathing. Myotonia atrophica, or Steinert's disease, is a dystrophy of muscle preceded by a myotonic phase occurring in adolescence. There is gradual muscle wasting, especially in the face and neck, with involvement in the pharynx, larynx, and esophagus. Dysphagia, aspiration, and dysphonia are common.

Juvenile rheumatoid arthritis is commonly associated with laryngeal involvement, especially in the cricoarytenoid joints.



Mucopolysaccharidoses are metabolic disorders of childhood. This category of diseases (Table 2) is associated with an abnormal accumulation of chondroitin sulfate or heparitin sulfate. Neuronal transmission becomes abnormal because of abnormalities created in surface membranes and the intercellular matrix. These disturbances have profound neurological consequences, and in many cases are fatal. A disease which is related to the Hunter-Hurler type, but is one of the glycolipidoses, is I-cell disease. The exact nature of this defect is unknown. Central nervous system and bone dystrophy similar to Hurler's syndrome occurs. Hepatosplenomegaly is not present. The disease progresses to death usually within the first 10 years of life. The abnormal metabolic material is deposited within the larynx and tracheobronchial tree.

It can be seen that endocrine and metabolic problems in children which affect neuromuscular activity can lead to laryngeal dysfunction. In some instances such as hypocalcemia, hypothyroidism, or hyperthyroidism and hypoglycemia, laryngeal dysfunction can be one of the primary presenting signs and symptoms.

*Physiological Causes.* Puberty, particularly in the male, is known to produce voice change. In order to make the metabolic transition to puberty, normal pituitary, adrenal and gonadal functions are necessary. Puberty begins at about age 10 in the male, and there is a 2- to 3-year growth spurt which includes laryngeal structures causing voice change. In the female, reports suggest that trained, as well as untrained, voices become hoarse during the premenstrual phase of the menstrual cycle. This has been ascribed to an edematous condition unevenly increasing the mass of the vocal cords. Newer data do not support the contention that hoarseness is a feature of the premenstrual cycle in young women without vocal training.<sup>35</sup>

*Psychogenic Causes.* Hysterical aphonia is uncommon in children. Its true incidence is unknown.

Seen predominantly in the female, all ages may be affected. The onset may be sudden, at which time the voice may be reduced to a bare whisper or complete aphonia. Functional aphonia constitutes an extreme stage of hypofunctional dysphonia.<sup>36</sup> Organic disease, especially neurological disturbances, must be ruled out.

## DISCUSSION

Iatrogenic causes of voice change have not been discussed in this study. It should be obvious that injudicious and ill-advised surgical procedures on the larynx in children can cause serious damage. In addition to surgically imposed anatomic defects, children may develop functional dysphonia from lack of emotional preparation preoperatively and by unnecessary restrictions such as insistence on silence or voice rest in the postoperative period.

Voice change may be one of the earliest symptoms and signs of a serious local or systemic disease. Because of the vast number of diseases that produce voice change, many of which are very threatening, progressive voice change not reverting to normal for a suitable length of time should stimulate a thorough examination. A search for a local laryngeal or paralaryngeal abnormality or systemic defect should be performed. The physician should not be totally dependent on x-ray studies for a diagnosis, and direct inspection of the larynx and surrounding structures with a biopsy, when indicated, are essential.

Without this approach, the risk to the child may be unexpectedly high. A "wait and see" attitude exposes the child to hazards which may end fatally. Whether the larynx is examined by mirror, flexible fiberoptic instrumentation, or rigid endoscopic measures under anesthesia, remains a personal preference and will be dependent upon the experience of the attending physician. The physician should not be disarmed by wishful thinking, and a relentless search for a local or systemic disease may be essential. Hopefully, this paper will stimulate a greater interest and concern on the part of those who treat children with voice abnormalities.

ACKNOWLEDGMENT — Deep appreciation is expressed to Rose Marie Lopicola for her time given so generously in the preparation of this manuscript.

## REFERENCES

1. Negus VE. Comparative anatomy and physiology of the larynx. London: William Heinemann Medical Books Ltd, 1949.
2. Fink BR, Demerest RJ. Laryngeal biomechanics. Cambridge, Mass: Harvard University Press, 1978.
3. Capps FC. Abductor paralysis in theory and practice. Semon lecture. J Laryngol Otol 1958; 72:1-31.
4. Furstenberg AC, Magielski JE. A motor pattern in the nucleus ambiguus. Ann Otol Rhinol Laryngol 1955; 65:788-93.
5. Arnold GE. Vocal rehabilitation of paralytic dysphonia. III. Present concepts of laryngeal paralysis. Arch Otolaryngol 1957; 65:306-17.
6. Maisels MJ. Neonatal jaundice. In: Avery GB, ed. Neonatology. Philadelphia: JB Lippincott Co, 1975:335.
7. Andrews JM, Cancilla PA, Grippo J. Globoid cell leukodystrophy (Krabbe's disease). Morphological and biochemical studies. Neurology 1971; 21:337-52.
8. Sung JH, Meyer JP, Stadler EM, Cowen O, Wolf A. Neuropathological changes in Chediak-Higashi disease. J Neuropathol Exp Neurol 1969; 28:86-118.
9. Slovis TL. Variable manifestations of Wilson's disease. J Pediatr 1971; 78:578-84.
10. Dooling EC, Schoene WC, Richardson EP Jr. Hallervorden-Spatz syndrome. Arch Neurol 1974; 30:70-83.
11. Liversedge LA. Management of multiple sclerosis. Br Med Bull 1977; 33:78-83.
12. Goebel HH, Heipertz R, Scholz W, Iqbal K, Tellez-Nagel I. Juvenile Huntington's chorea. Clinical ultrastructure and biochemical studies. Neurology 1978; 28:23-31.

13. Hunt JR. Dyssynergia cerebellares myoclonica. *Brain* 1922; 44:490-538.
14. Graham MD. Bilateral vocal cord paralysis associated with meningocele in the Arnold-Chiari malformation. *Laryngoscope* 1963; 73:85-92.
15. Hogan PJ. Vocal cord paralysis. *Ann Otol Rhinol Laryngol* 1963; 72:306-12.
16. King BT, Gregg R. An anatomical reason for various behaviors of paralyzed vocal cords. *Ann Otol Rhinol Laryngol* 1948; 57:925-44.
17. Plotz M, Books MJ. Vocal cord paralysis in heart disease. *Arch Otolaryngol* 1951; 54:273-8.
18. Gutmann L, Pratt L. Pathophysiological aspects of human botulism. *Arch Neurol* 1976; 33:175-9.
19. Mittag T, Kornfeld P, Tormay A, Woo C. Detection of anticholinergic receptor factors in serum and thymus from patients with myasthenia gravis. *New Engl J Med* 1976; 294:691-4.
20. Roland NP. The cerebral defect and myopathy in Duchenne muscular dystrophy. *Neurology* 1970; 20:147-59.
21. Thompson EJ, Yasin R, Von Beers G, Nurse L, El-Anis S. Myogenic defect in human muscular dystrophy. *Nature* 1977; 268:241-3.
22. Holinger PH, Brown WT. Congenital webs, cysts, laryngoceles and other anomalies of the larynx. *Ann Otol Rhinol Laryngol* 1967; 76:744-52.
23. Cohen SR. Congenital atresia of the larynx with endolaryngeal surgical correction: a case report. *Laryngoscope* 1971; 81:1607-15.
24. Cohen SR, Celler KA, Birns JW, Thompson JW. Laryngeal paralysis in children: a long-term retrospective study. *Ann Otol Rhinol Laryngol* 1982; 91:417-24.
25. Cohen SR. Cleft larynx: a report of seven cases. *Ann Otol Rhinol Laryngol* 1975; 84:747-56.
26. Batsakis JG. Tumors of the head and neck. Clinical consideration and pathology. Baltimore: Williams and Wilkins Co, 1974.
27. McWilliams BJ, Lavorato AS, Bluestone CD. Vocal cord abnormalities in children with velopharyngeal valving problems. *Laryngoscope* 1973; 83:1745-53.
28. Cohen SR, Landing BH, Isaacs H, et al. Compendium of rare diseases of the larynx in the pediatric age group. *Ann Otol Rhinol Laryngol* 1978; 87:(suppl 52):5-31.
29. Remington JS. Infectious diseases of the fetus and newborn infant. Philadelphia: WB Saunders Co, 1976:803-5.
30. Mandell GL. Principles and practice of infectious disease. Vol 2. New York: Wiley Medical Publications, 1979:441-2, 1623.
31. Calderelli DD, Friedberg SA, Harris AA. Medical and surgical aspects of granulomatous diseases of the larynx. *Otolaryngol Clin North Am* 1979; 12:767-81.
32. Ward PH. Coccidioidomycosis of the larynx in infants and adults. *Ann Otol Rhinol Laryngol* 1977; 86:655-60.
33. Friedman M, Baim H, Shelton V, et al. Laryngeal injuries secondary to nasogastric tubes. *Ann Otol Rhinol Laryngol* 1981; 90:469-74.
34. Kelley VC, ed. Metabolic, endocrine and genetic disorders of children. Hagerstown, Maryland: Harper and Row Publishers, Inc, 1974.
35. Silverman EM, Zimmer C. Effects of the menstrual cycle on voice quality. *Arch Otolaryngol* 1978; 104:7-10.
36. Brodnitz FS. Functional aphonia. *Ann Otol Rhinol Laryngol* 1969; 78:1244-53.



# QUANTIFICATION OF INTRALARYNGEAL PRESSURE EXERTED BY ENDOTRACHEAL TUBES

ERNEST A. WEYMULLER, JR, MD

MICHAEL J. BISHOP, MD

ARLIS W. HIBBARD, MD

B. RAYMOND FINK, MD

F. A. SPELMAN, PHD

SEATTLE, WASHINGTON

Prolonged endotracheal intubation in critically ill patients has become an accepted routine. One notable consequence of this form of management is injury to the posterior aspect of the glottis, apparently an injury caused by the presence of an endotracheal tube. Utilizing two types of sensing devices, the pressure exerted by endotracheal tubes was measured in the canine larynx via a laryngofissure approach. Pressure in excess of 200 mm Hg was consistently noted in the region of the arytenoid cartilage. A variety of tubes were tested with similar results.

## INTRODUCTION

Over the past two decades the accepted duration of endotracheal intubation has increased dramatically. It is now commonplace for patients requiring intensive ventilatory management to be intubated for as much as 14 to 21 days prior to consideration of a tracheotomy.<sup>1,2</sup> Much longer periods of intubation have been reported in the literature.<sup>3-5</sup> The phenomenon of increasingly prolonged endotracheal intubation is due to generally favorable results from the technique and the well-recognized morbidity and mortality associated with tracheotomy.<sup>6</sup> However, prolonged translaryngeal intubation can result in varying degrees of posterior glottic stenosis which is potentially a source of substantial morbidity.<sup>7-11</sup>

This study quantifies the pressure exerted by endotracheal tubes of various sizes and compositions in the canine larynx. The data should provide a baseline for further research in endotracheal tube design and management.

## MATERIALS AND METHODS

A series of three dogs were used, each weighing between 20 and 30 kg. Anesthesia was obtained with 30 mg/kg pentobarbital followed by transglottic intubation. The animal was ventilated with a Harvard piston ventilator and a low tracheotomy was performed. The transglottic tube was removed and the ventilator was connected to the tracheotomy tube. A laryngofissure leaving the cricoid ring intact was then accomplished.

*Dog 1.* A pressure-sensitive constant infusion catheter (1-mm diameter) was sewn over the vocal process of one arytenoid cartilage. The dog was transorally intubated with a series of polyvinylchloride endotracheal tubes. The pressure exerted by each tube against the catheter was recorded using a Konigsburg pressure transducer amplifier attached to a Grass model 7 polygraph recorder. This system has been validated by Pope.<sup>12</sup>

*Dog 2.* Using the same sensing system not sewn to the arytenoid, a constant infusion catheter was inserted via the laryngofissure. For each of a series of transorally placed polyvinylchloride endotracheal tubes, the catheter was manipulated between the internal surface of the larynx and the wall of the tube to find the region of highest pressure. Readings were confirmed by repeating each measurement.

*Dog 3.* The recordings of pressure were made using a Millar "Mikro-Tip" catheter tip pressure transducer, model PC-460 (1.3-mm diameter). This system had been calibrated to 300 mm Hg in an aluminum airtight calibration box using a standard mercury manometer. A series of endotracheal tubes were placed transorally. The pressure sensitive catheter was positioned between the endotracheal tube and the internal surface of the larynx using the laryngofissure exposure. Each reading represents the maximum pressure encountered.

## RESULTS

*Dog 1.* The side-port infusion catheter was fixed to the vocal process. Pressure on the vocal process of the arytenoid increased with increasing tube diameter. It was noted that the smaller tubes, for the most part, rested posterior to the vocal process of the arytenoid and only contacted the pressure monitor tangentially. In this preparation the recorded pressures varied from 75 to 375 mm Hg (Table 1).

*Dog 2.* The side-port infusion catheter was positioned to read the highest pressure. By manipulating the catheter to find the peak pressure point exerted by each size tube, the range of pressure was 225 to 400 mm Hg. The smaller tubes exerted this pressure over a smaller area located just posterior to the vocal process of the arytenoid. The large tubes exerted pressure over a wider area including the vocal process (Table 2).

*Dog 3.* The calibrated solid-state catheter tip pressure transducer was used. The solid-state catheter revealed pressures in the range of 200 to 400 mm

From the Department of Otolaryngology (Weymuller, Hibbard) and the Bioengineering Division, Regional Primate Center (Spelman), the Department of Anesthesiology and Medicine (Bishop), and the Department of Anesthesiology (Fink), the University of Washington, Seattle. Supported by NIH grant R01-HL-19975-03 and the Grace Foundation.

Presented at the meeting of the American Laryngological Association, New Orleans, April 10-11, 1983.

TABLE 1. PRESSURE RECORDINGS FROM SIDE-PORT INFUSION CATHETER (DOG 1)

PVC Endotracheal Tube Inside Diameter (mm)	Peak Parietal Pressure (to nearest 25 mm Hg)
6.0	75
7.0	95
8.0	180
9.0	375

PVC - Polyvinylchloride.

Hg for all tubes tested (Table 3). The elevated pressures were always localized to the posterolateral aspect of the larynx and there was no change in pressure when the animal's head was flexed or extended, nor was there a decrease in pressure when the animal was paralyzed.

## DISCUSSION

This pilot study was undertaken to establish an animal model for quantification of pressure exerted by endotracheal tubes within the larynx. Previous measurements of this sort have not been performed. Two different methods of assessing the pressures were used because the pressures were so excessive when measured by the first system that a second independently calibrated system was selected to confirm our results. The first monitoring system consists of a 1-mm polyvinylchloride catheter sealed at its end and perforated just above the tip. Using a constant infusion of saline and a pressure transducer in line with the system, the mucosal closing pressure was monitored as described by Pope.<sup>12</sup> The main technical difficulty with this procedure was establishing the location of highest pressure and maintaining the pressure monitor in that location. For this purpose it was necessary to perform a laryngofissure. After placing an endotracheal tube in the larynx, the pressure monitor was inserted and manipulated between the wall of the endotracheal tube and the larynx until it encountered the highest pressure. Invariably this point of high pressure existed over the posterolateral larynx and, after repeated trials with various size tubes, it was obvious that this region is the area of most substantial pressure. The experiment was repeated with a calibrated Millar solid-state transducer. Some limitations of this study must be addressed.

1. A small number of animals were used because the individual pressure readings were reproducible in each animal. We felt no advantage would be gained by further repetition since the pressures measured were so far in excess of capillary perfusion pressure.

2. The canine larynx is not precisely analogous to the human. There is a deep posterior sulcus in the canine larynx which caused lower pressure readings with a fixed sensor in dog 1. The size of the glottis in our animals was a reasonable approximation of the human. It seems likely that similar pressures are generated in the clinical setting.

3. The pressure-sensitive catheters occupied a portion of the space available in the glottis and

TABLE 2. HIGHEST PRESSURE RECORDINGS FROM SIDE-PORT CATHETER (DOG 2)

PVC Endotracheal Tube Inside Diameter (mm)	Peak Parietal Pressure (to nearest 25 mm Hg)
6.0	225
7.0	> 400
8.0	> 400
9.0	> 400

therefore contributed to the total pressure. We consider this to be a negligible concern in light of the large pressures demonstrated to exist. The catheter could not have contributed more than 10% to 20% of the transverse diameter of the system being measured, ie, the endotracheal tube.

The data confirming pressure far in excess of mucosal capillary perfusion pressure are particularly relevant in light of increasing use of prolonged endotracheal intubation. Over the past two decades, more prolonged use of endotracheal intubation has become commonplace and accepted. The reasons for this phenomenon include 1) the mortality and morbidity associated with tracheotomy, 2) the improvement of techniques used in daily monitoring and management of endotracheal intubation, 3) improved tube materials with diminished biological reactivity, and 4) a recognized low order of significant complications of endotracheal intubation.<sup>1,2</sup> Cases of extremely prolonged endotracheal intubation (50 to 150 days) are also reported and used as evidence of the relative tolerance of the larynx for endotracheal intubation.<sup>3-5</sup> In the 1960s intubation for longer than 2 to 3 days was considered an indication for tracheotomy.<sup>7,8</sup> Even with those brief periods of intubation, the existence of significant laryngeal injury was noted and studied pathologically. The histopathology of human intubation injury is well defined and consists of ulceration over the cricoid and arytenoid cartilages with ischemic necrosis being noted in all patients intubated more than three to four days.<sup>13,14</sup> The process of epithelial injury created by transmucosal pres-

TABLE 3. PRESSURE RECORDINGS FROM SOLID-STATE CATHETER TRANSDUCER (DOG 3)

Tip	Endotracheal Tube Inside Diameter (mm)	Peak Parietal Pressure (to nearest 25 mm Hg)
Silicone	5.0	225
	6.0	400
	7.0	275
	8.0	300
	9.0	400
Polyvinylchloride	6.0	200
	7.0	300
	8.0	400
	9.0	300
Armored	5.5	200
	8.0	400
Red rubber	8.0	400



sure begins with loss of mucosal integrity and proceeds to deeper infection, granulation tissue, and subsequent scarring.<sup>15,16</sup> The sensitivity of tracheal mucosa to pressure was well demonstrated in an elegant study by Nordin et al.<sup>17</sup> Using isotope-labeled microspheres they determined tracheal capillary perfusion pressure to be approximately 30 mm Hg. The pressures we have recorded clearly exceed capillary perfusion pressure.

In vitro techniques have been devised to assess the force generated when an endotracheal tube bends to conform to the anatomic contours of a patient. This is known as the deforming force. It differs from the pressure measured in our experiment in that it is exerted posteriorly and varies in location and degree according to the position of the patient and the mechanical properties of the tube.<sup>18,19</sup>

Severe posterior glottic stenosis is not a common problem but its occurrence can create substantial disability for the survivor of prolonged ventilatory support. The most common cause of posterior glottic stenosis is prolonged intubation.<sup>9,10,20</sup>

We have been monitoring patients in the intensive care unit with direct laryngoscopy to assess the impact of endotracheal intubation after ten to 14 days. The typical and predictable finding at ten to 14 days consists of an ulceration over the arytenoid cartilages with granulation tissue surrounding the point of contact of the endotracheal tube. The free portion of the vocal cords is usually mildly edematous, but otherwise unchanged, and for the most part the cricoid region is uninvolved. When the lesion is severe, a horseshoe-shaped lesion communicates the ulcerations on the arytenoids across the posterior commissure. Our readings of high pressure in the dog model localized to the arytenoid cartilage are wholly consistent with these observations.

The following thoughts are suggested by our data and a review of the literature:

1. A point of pressure far in excess of capillary perfusion pressure exists in the posterior lateral portion

of the larynx where an endotracheal tube is in contact with the mucosa and underlying cartilage. This pressure is in the range of 200 to 400 mm Hg even with small tubes.

2. The point of highest pressure is identical to the area of injury noted by endoscopic assessment and pathologic analysis of the human larynx. The area of pressure is larger with larger tubes and the pressure appears to be higher with large tubes.

3. It would appear that modifications of tube contour cannot be expected to eliminate these forces. No matter what shape the tube, it will require a certain internal and external diameter to deliver ventilation. The physical presence of a tube which does not conform to laryngeal anatomy imparts these high pressures to the posterolateral portion of the laryngeal framework.

4. We expect all commercially available tubes to exert these pressures regardless of their composition.

5. Given the current selection of endotracheal tubes, the smallest tube consistent with adequate ventilation for the patient should be selected.<sup>21</sup>

6. In the future we must determine whether prolonged endotracheal intubation is a better alternative than tracheotomy especially in light of the fact that more patients are surviving prolonged ventilatory support.

7. If it is possible early in the course of a patient's care to predict that prolonged ventilatory assistance will be necessary, an early tracheotomy would be preferred if laryngeal protection is an issue, since tracheotomy after prolonged intubation may predispose to posterior glottic stenosis.<sup>20</sup>

## CONCLUSIONS

1. All tubes tested created 200 to 400 mm Hg pressure centered over the posterolateral larynx.

2. Smaller tubes made lower pressures over smaller areas.

3. Laryngeal injury from prolonged endotracheal intubation is unavoidable using currently available equipment.

## REFERENCES

1. Stauffer JL, Olson DE, Petty TL. Complications and consequences of endotracheal intubation and tracheotomy. *Am J Med* 1981; 70:75-6.
2. El-Naggar M, Sadagopan S, Levine H, Kantor H, Collins VJ. Factors influencing choice between tracheostomy and prolonged translaryngeal intubation in acute respiratory failure: a prospective study. *Anesth Analg* 1976; 55:195-201.
3. Via-Reque E, Rattenborg CC. Prolonged oro- or nasotracheal intubation. *Crit Care Med* 1981; 9:637-9.
4. Yamashita M, Satoh Y, Kondoh A, Matsuki A, Oyama T. Long term nasotracheal intubation in an adult patient. *Anaesthetist* 1977; 26:575-9.
5. Vogelhut MM, Downs JB. Prolonged endotracheal intubation. *Chest* 1979; 76:110-1.
6. Chew JY, Cantrell RW. Tracheostomy complications and their management. *Arch Otolaryngol* 1972; 96:534-45.
7. Lindholm CE. Prolonged endotracheal intubation. *Acta Anesthesiol Scand* 1969; (suppl 33).
8. Harrison GA, Tonkin JP. Prolonged (therapeutic) endotracheal intubation. *Br J Anaesth* 1968; 40:241-9.
9. Kirschner JA, Roberts DD. Laryngeal complications of endotracheal intubation. *Conn Med* 1978; 42:151-5.
10. Olson NR, Bogdasarian RS. Posterior glottic laryngeal stenosis. *Otolaryngol Head Neck Surg* 1980; 88:765-72.
11. Keane WM, Denny JC, Rowe LD, Atkins JP. Complications of intubation. *Ann Otol Rhinol Laryngol* 1982; 91:584-7.
12. Pope CE II. Effect of infusion on force of closure measurements in the human esophagus. *Gastroenterology* 1970; 58:616-24.
13. Donnelly WH. Histopathology of endotracheal intubation. *Arch Pathol* 1969; 88:511-20.

14. Bergstrom J, Mobert A, Orell SR. On the pathogenesis of laryngeal injuries following prolonged intubation. *Acta Otolaryngol* (Stockh) 1962; 55:342-6.
15. Way WL, Sooy FA. Histologic changes produced by endotracheal intubation. *Ann Otol Rhinol Laryngol* 1965; 74:799-812.
16. Hilding AC. Laryngotracheal damage during intratracheal anesthesia. *Ann Otol Rhinol Laryngol* 1971; 80: 565-81.
17. Nordin U, Lindholm C-E, Wolgast M. Blood flow in the rabbit tracheal mucosa under normal conditions and the influence of tracheal intubation. *Acta Anaesthesiol Scand* 1977; 21:81-94.
18. Lindholm C-E, Carroll RG. Evaluation of tube deformation pressure in vitro. *Crit Care Med* 1975; 3:196.
19. Steen JA, Lindholm C-E, Brdlik GC, Foster CA. Tracheal tube forces on the posterior larynx: index of laryngeal loading. *Crit Care Med* 1982; 10:186-9.
20. Kirchner JA, Sasaki CT. Fusion of the vocal cords following intubation and tracheostomy. *Trans Am Acad Ophthalmol Otolaryngol* 1973; 77:88-91.
21. Stenqvist O, Sonander H, Nilsson K. Small endotracheal tubes, ventilator and intratracheal pressures during controlled ventilation. *Br J Anesth* 1975; 51:375-80.



# CONGENITAL LARYNGEAL HEMANGIOMA

BRUCE BENJAMIN, FRACS

PETER CARTER, FRACS

SYDNEY, AUSTRALIA

Congenital subglottic hemangioma consistently occurs in a site below the vocal cord. It is a distinct clinical entity with typical clinical features. However, congenital hemangioma in other sites can cause airway obstruction. An anatomical classification is proposed on the basis of review of 23 consecutive cases. It is important to accurately identify the site and distribution of the lesion before commencing treatment. Radiation has been an acknowledged form of treatment, and in our hospital we have confirmed that radiation therapy, either by external beam, or by insertion of a radioactive gold grain, gives good results. The theoretical possibility of radiation-induced malignancy in the thyroid gland is reduced to an absolute minimum by use of a radioactive grain for localized tumor-dose with minimum radiation of surrounding tissue.

Hemangiomas are congenital malformations which form from mesodermal rests of vasoformative tissue. In most anatomical sites they can be managed conservatively. The one exception is narrowing of the airway. The hemangioma of childhood that is the biggest threat to life is the subglottic hemangioma; expectant management in the past was attended by mortality reported by Ferguson and Flake<sup>1</sup> as approximately 50%. It is now recognized that early active treatment is indicated.

In 1921 Sweetser<sup>2</sup> first differentiated subglottic hemangiomas in infants from glottic and supraglottic hemangiomas in adults. Since then the clinical features have been clearly defined by many authors.<sup>1,3-6</sup> The symptoms are stridor, intermittent at first and then persistent; harsh barking cough; and failure to thrive. An erroneous diagnosis of "croup" may be made at first. In approximately half the patients there is also an hemangioma of the skin, usually in the head and neck region. Females are affected twice as often as males. Although a rare tumor, the exact incidence is not known; of 846 cases of congenital laryngeal anomalies described by Hollinger and Brown,<sup>7</sup> 13 were subglottic hemangiomas. The majority of the lesions are of the capillary cavernous type with vascular spaces surrounded by endothelial cells.<sup>8</sup> The hemangioma develops in the submucosa and follows a typical growth pattern with increase in size during the first 6 to 12 months of age. Radiographic examination of the airways, either an x-ray film or xeroradiogram, can be useful (Fig 1) although not necessarily diagnostic.<sup>6</sup>

Diagnosis is made by endoscopic examination. The need for biopsy is controversial, as it may be dangerous in patients who do not already have tracheotomies. A typical subglottic hemangioma appears as a smooth pink or blue compressible mass of soft or firm consistency. A previous paper in 1978

by Benjamin<sup>9</sup> reported promising results using a radioactive gold grain inserted into the hemangioma. The present paper confirms those results and presents a classification according to anatomical site.

## CASE MATERIAL

During the 17 years from 1966 to 1982 inclusive, 23 proven cases of laryngeal hemangioma were managed at the Royal Alexandra Hospital for Children, Sydney (Table). The diagnosis was made by direct examination under general anesthetic, using magnification, either a Hopkins fiberoptic telescope or the operating microscope. The appearance alone was sufficient for an experienced endoscopist to make the diagnosis.

## RESULTS

There were 14 females and 9 males, confirming the known preponderance in females. In all but three patients stridor commenced within the first 8 weeks of life, in six within the first 2 weeks, and in two of these at birth. The supraglottic pedunculated hemangioma limited to the false cord did not cause symptoms until 7 months of age.

Of 23 patients nine had cutaneous hemangiomas of the head, face, and neck, and one of these had further cutaneous hemangiomas on the trunk. There was no correlation to side or site of laryngeal lesion. One patient with a massive hemangioma of the eye, face, neck, chest wall, and mediastinum died of intractable cardiac failure (case 14). In 19 patients the lesions were in the typical subglottic site; 11 were on the left side, five were on the right side, and three were bilateral. There was posterior commissure extension in four patients. In three patients the lesions were limited to the upper trachea (cases 14, 16, and 18), and in one patient a pedunculated lesion arose from the false cord (case 10).

From the Royal Alexandra Hospital for Children, Sydney, New South Wales, Australia.

Presented at the meeting of the American Laryngological Association, New Orleans, April 10-11, 1983.

REPRINTS — Bruce Benjamin, FRACS, 231 Macquarie St, Sydney, New South Wales, 2000 Australia.

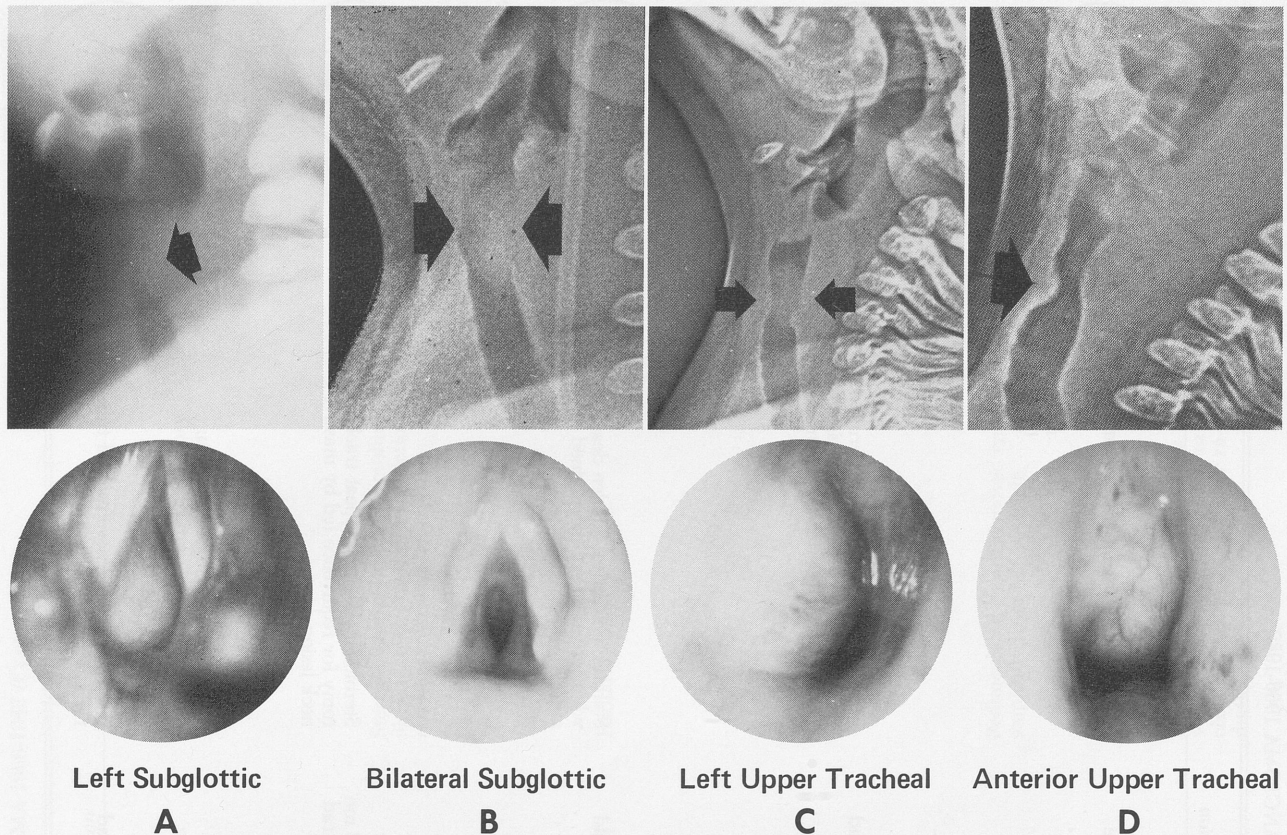


Fig 1. Radiographic studies and endoscopic photographs. A) (Case 8) X-ray film shows subglottic soft-tissue mass of unilateral subglottic lesion. B) (Case 23) Xeroradiogram clearly shows radio-opacity of bilateral subglottic hemangiomas. C) (Case 18) Xeroradiogram shows upper tracheal lesion on the left side. D) (Case 16) Xeroradiogram shows upper tracheal lesion.

#### DIAGNOSIS

Lateral x-ray study of the upper airway showed changes consistent with subglottic soft-tissue swelling in ten patients, and later in the series (after 1975), xeroradiograms more clearly demonstrated a subglottic abnormality in six patients (Fig 1). Seven patients had a diagnostic biopsy, five at our institution and two elsewhere. Histological confirmation was obtained in another seven patients from tissue submitted during the course of management. Therefore 14 of the 23 patients had histological confirmation of the diagnosis.

#### TRACHEOTOMY

Twenty patients had tracheotomies, usually at the time of diagnostic endoscopy. Three patients did not require tracheotomies. One required no treatment (case 16). One patient early in the series (case 5) was managed by nasotracheal tube only during and after external irradiation, a period of 4 weeks. One hemangioma in the upper trachea (case 18) was removed through an external incision and required nasotracheal intubation for 1 week.

#### TREATMENT

Early in the series seven patients had external beam irradiation using doses from 375 to 600 rad, and 11 patients presenting after January 1974 were

treated by insertion of a radioactive gold grain. Two patients were treated surgically and three patients had no treatment for the hemangioma.

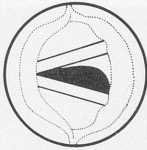

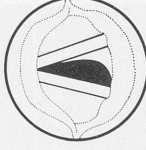
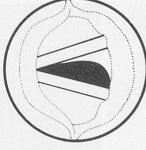

The gold grain, 2.5 mm by 0.8 mm, had a radioactive dose of 1 mCi with a half-life of 4.7 days.<sup>9</sup> The dose at 3 mm from the center of the grain is 2,400 rad and at 10 mm is 200 rad. The grain is inserted into the hemangioma through a small incision just below and medial to the edge of the vocal cord using microsurgical techniques. A lateral x-ray film confirms the position. Shrinkage of the hemangioma occurs over several months and is assessed by endoscopy approximately 8 to 10 weeks after insertion.


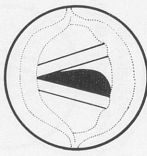
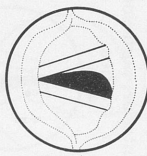

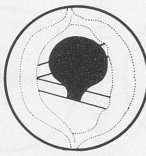
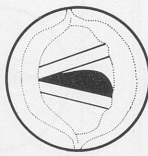
*Results of Treatment.* The first patient in the series had no treatment and the tracheotomy was not removed until the age of 2 years. The results with external radiotherapy were satisfactory and the duration of tracheotomy was usually a matter of months. External radiation was not used after 1973 because it was realized that radiation to the thyroid gland could be minimized and tumor radiation maximized by use of a radioactive gold grain.

There was a sudden unexpected death in one patient (case 3) 4 weeks after the external irradiation and while the tracheotomy was still in place. Autopsy did not show the cause of death. All pa-





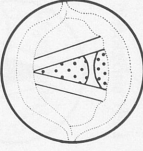

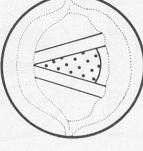

## CASES OF CONGENITAL HEMANGIOMA 1966-1982

Case No.	Sex	Year	Presenting Age	Age at Diagnosis	Cutaneous Hemangioma	Duration of Tracheotomy	Biopsy Proved	Radiation	Comments	Outcome	Site
1	M	1966	16 wk	18 wk	None	19 mo	Yes	None	No treatment except tracheotomy; decannulated aged 2 yr	Slowly reduced in size	 Left subglottic
2	F	1967	2 mo	5 mo	None	1½ mo	Yes	600 rad	First patient treated with external radiotherapy. 3 endoscopic excisions of residual tissue after radiation	Cured	 Right subglottic
3	F	1968	1 wk	5 wk	Face	NA	Yes	375 rad	Steroids ineffective; sudden death 4 wk after radiation unexplained at autopsy	Died, cause unknown	 Left subglottic
4	F	1969	6 wk	7 wk	Massive face, Neck	2 mo, 4 mo	No	500 rad; 6 mo later, 400 rad	Steroids ineffective; repeat tracheotomy for recurrence fed by massive neck lesion	Cured	 Left subglottic
5	F	1969	8 wk	14 wk	Face, neck	—	No	500 rad	No tracheotomy; nasotracheal tube for 4 wk after radiotherapy	Cured	 Left subglottic

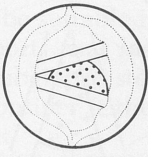
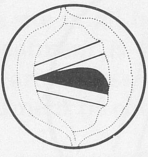


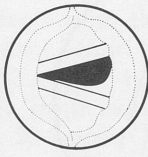

Case No.	Sex	Year	Presenting Age	Age at Diagnosis	Cutaneous Hemangioma	Duration of Tracheotomy	Biopsy Proved	Radiation	Comments	Outcome	Site
6	F	1972	7 wk	8 wk	Neck, trunk	14 mo	Yes	500 rad	Severe pneumonia and respiratory infections delayed decannulation	Cured	 Right subglottic
7	F	1973	2 wk	8 wk	None	3 mo	Yes	Grain	Steroids ineffective despite cushionoid changes; prolonged intubation elsewhere without benefit	Cured	 Left subglottic
8	M	1973	6 wk	12 mo	None	2 mo	Yes	500 rad	Radiation only	Cured	 Left subglottic
9	F	1973	1 wk	12 wk	Face, neck	2½ mo	No	500 rad	Steroids ineffective	Cured	 Bilateral subglottic
10	M	1973	7 mo	7 yr	None	2 wk	Yes	None	Pedunculated tumor removed endoscopically from left ventricle	Cured	 Left false cord
11	M	1974	Birth	12 mo	None	5 mo	Yes	Grain	Prolonged intubation elsewhere without benefit. 2 endoscopic excisions of residual tissue after radiation	Cured	 Left subglottic



CASES OF CONGENITAL HEMANGIOMA 1966-1982 (Continued)

Case No.	Sex	Year	Presenting Age	Age at Diagnosis	Cutaneous Hemangioma	Duration of Tracheotomy	Biopsy Proved	Radiation	Comments	Outcome	Site
12	M	1975	4 wk	12 wk	None	4½ mo	Yes	Grain	2 endoscopic excisions of residual tissue after radiation	Cured	 Bilateral subglottic
13	M	1975	2 mo	3 mo	None	3½ mo	Yes	Grain	Grain only	Cured	 Right subglottic
14	F	1977	2 mo	4½ mo	Head, face, neck, mediastinum	NA	No	None	Steroids ineffective, cardiac failure from progressive enlargement of massive, widespread hemangioma	Died of cardiac failure	 Anterior, posterior trachea
15	M	1978	1 mo	4 mo	None	8 mo	Yes	Grain	Initial laser treatment with temporary improvement; recurrence resolved after insertion of grain	Cured	 Left subglottic, posterior extension
16	F	1978	15 wk	18 wk	None	—	No	None	No serious symptoms; no treatment necessary	Resolved without treatment	 Anterior upper trachea
17	F	1979	2 mo	2 mo	Face	3½ yr	Yes	Grain	2 small laser treatments of residual tissue followed by subglottic stenosis; tracheotomy removed after 3½ years	Subglottic stenosis due to laser	 Left subglottic, posterior extension

CONGENITAL HEMANGIOMA

Case No.	Sex	Year	Presenting Age	Age at Diagnosis	Cutaneous Hemangioma	Duration of Tracheotomy	Biopsy Proved	Radiation	Comments	Outcome	Site
18	F	1980	2 mo	4 mo	None	—	Yes	None	External approach and surgical excision from upper trachea; nasotracheal tube for 1 wk postoperatively	Cured	 Left upper trachea
19	F	1980	2 wk	2 mo	None	2 mo	No	Grain	Grain only	Cured	 Left subglottic
20	M	1980	Birth	3½ mo	Face	3½ mo	No	Grain	Grain only	Cured	 Right subglottic, separate posterior
21	F	1981	6 wk	5 mo	None	2½ mo	Yes	Grain	No treatment elsewhere for 13 mo and no improvement; good response to grain only	Cured	 Left subglottic, posterior extension
22	M	1982	5 wk	8 wk	None	3 mo	Yes	Grain	Endoscopic excision of residual tissue after grain radiation	Cured	 Right subglottic
23	F	1982	8 wk	4½ mo	Face, neck	6 mo	No	Grain	Grain in left side only; 2 superficial laser treatments of residual tissue on right side	Cured	 Bilateral subglottic



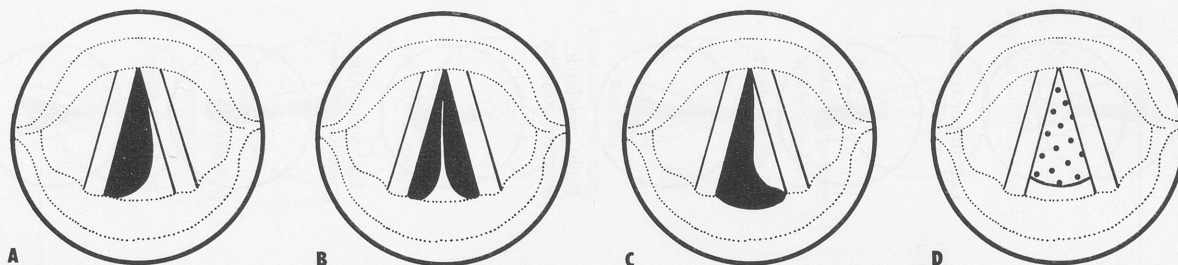


Fig 2. Classification of congenital laryngeal hemangiomas according to site. A) Unilateral; B) Bilateral; C) Unilateral with posterior extension; D) Upper tracheal.

tients treated by insertion of a gold grain had satisfactory responses and were successfully extubated in from 2 to 5 months. Endoscopic examination was performed some years later in two cases during general anesthesia for unrelated reasons, and the subglottic region was found to be normal with the gold grain shining through the superficial mucosa, allowing easy removal.

**Other Treatment.** Steroids were used systemically in six patients and locally in one. The dosage used was according to the recommendation of Cohen and Wang.<sup>10</sup> In one patient there was detectable but insufficient improvement accompanied by cushingoid changes, and further treatment using a radioactive grain was required to achieve removal of the tracheotomy. Steroids are no longer used in our institution.

Endoscopic microsurgical laser destruction was attempted in two patients. The first (case 15) had three treatments with initial improvement, but the lesion enlarged over the next 3 months. A gold grain was then inserted, and extubation was possible 2 months later. The second patient (case 17) developed subglottic stenosis after several laser treatments despite careful technique to avoid this complication, and extubation was not possible for over 3 years.

Endoscopic piecemeal excision of residual tumor was used as an adjunct to external radiation in one patient and after use of the radioactive gold grain in three cases. The supraglottic lesion (case 10) was safely and simply removed by microlaryngeal surgery. The sessile tracheal lesion whose upper edge was 6 mm below the glottic level (case 18) was excised through the trachea via an external approach in the neck.

#### DISCUSSION

Infantile subglottic hemangioma has generally been regarded as a unilateral lesion, but this is not always so. With modern anesthesia and sophisticated endoscopic techniques using magnification, an exact evaluation of the site and distribution of the lesion can be made. In the 20 cases reported by Narcy,<sup>11</sup> reference was made to one case which was bilateral and to three cases which showed posterior extension.

Analysis of our own total of 23 cases showed 19 localized in the subglottic area. Of these, three were bilateral and four had extension into the posterior commissure. The remaining cases which were not subglottic were comprised of three in the upper trachea and one supraglottic lesion. We therefore suggest a classification of congenital hemangiomas (Fig 2). The lesion may be subglottic when it can be unilateral, with or without posterior extension, or bilateral. Sometimes the lesion may be in the upper trachea, and lastly it may occur very rarely in other sites, for example in the supraglottic area (case 10).

The airway obstruction in all our cases of subglottic hemangioma became severe and life-threatening. Some patients presented with acute obstruction and required relief immediately, either by tracheotomies or by temporary intubations followed later by tracheotomies. Tracheotomy was necessary both for the patient's safety and to enable treatment to be carried out.

Many forms of treatment have been advocated, and the proponents of each describe a successful outcome for their patients. These include:

1. Tracheotomy and no active treatment with an expectant attitude awaiting spontaneous regression<sup>12</sup>
2. Temporary or prolonged endotracheal intubation with or without steroids<sup>13</sup>
3. Injection of sclerosant<sup>14</sup>
4. Use of systemic steroids<sup>10,15</sup>
5. Excisional surgery<sup>12,16</sup>
6. Cryosurgery<sup>17</sup>
7. Laser surgery<sup>18</sup>
8. Radiation therapy either with external beam irradiation<sup>1,8,19</sup> or a radioactive gold grain.<sup>9,20</sup>

The advocates of each form of therapy report successful results, and it may well be that various modalities of treatment achieve the same outcome. The success of any treatment depends on careful assessment of the anatomical distribution of the hemangioma and avoidance of possible complications, especially subglottic stenosis.

Our experience with laser surgery in general shows that reactive granulation tissue, scarring, and stenosis can certainly occur. In the treatment of congenital subglottic hemangioma itself, laser

treatment with a 2-mm spot size is not considered by us to be suitable in this site in all infants. Long-term reports that laser treatment is free from the risk of subglottic stenosis are necessary before we would consider it the treatment of choice.

Radiation therapy has previously been an acknowledged treatment used for many years and reported by many authors<sup>1,8,19</sup> with reliable results and as yet no reports whatever of untoward effects, despite the theoretical possibility of radiation-induced malignancy of the thyroid gland. Calcaterra<sup>12</sup> expressed doubts about any worthwhile effect from external irradiation on the histological evaluation of one irradiated subglottic hemangioma and on theoretical grounds.

It is clear that radiation therapy is no longer favored in the United States, and yet our own experience with radiation, either with external beam or with radioactive gold grain, has been satisfactory in achieving resolution of the lesion and prompt

removal of the tracheotomy. However, the specter of long-term side effects from the radiation in the neck remains and cannot be put to rest without very long-term follow-up. Li et al<sup>21</sup> reported virtually no increase in mortality from radiotherapy in 4,726 patients followed for 20 years. Criticism of irradiation has usually been made in cases where wide fields have been radiated, for example the thymus gland or large face and neck malformations.

We advocate the use of a radioactive gold grain for maximum localized tumor-dose and minimum radiation of surrounding tissue. We assess the effect 8 to 10 weeks after insertion of the grain, and in some cases shrunken residual tissue may require local removal. At times we choose piecemeal removal with cupped forceps and scissors, and at other times we choose laser vaporization as the more suitable method of removing this tissue. The choice of treatment depends on the variation in anatomical exposure and surgical visibility in the subglottic region in infants.

#### REFERENCES

1. Ferguson CF, Flake CG. Subglottic hemangioma as a cause of respiratory obstruction in infants. *Ann Otol Rhinol Laryngol* 1961; 70:1095-112.
2. Sweetser TH. Hemangioma of the larynx. *Laryngoscope* 1921; 31:797-806.
3. Ferguson GB. Hemangioma of the adult and of the infant larynx: review of the literature and report of two cases. *Arch Otolaryngol* 1944; 40:189-95.
4. Baker DC, Pennington CL. Congenital hemangioma of the larynx. *Trans Am Laryngol Rhinol Otol Soc* 1956; 84-9.
5. Doermann P, Luneth J, Segnitz RH. Obstructing subglottic hemangioma of the larynx in infancy. *N Engl J Med* 1958; 258:68-71.
6. Leikensohn JR, Benton C, Cotton R. Subglottic hemangioma. *J Otolaryngol* 1976; 5:487-92.
7. Holinger PH, Brown WT. Congenital webs, cysts, laryngoceles and other anomalies of the larynx. *Ann Otol Rhinol Laryngol* 1967; 76:744-52.
8. Garfinkle TJ, Handler SD. Hemangioma of the head and neck in children — a guide to management. *J Otolaryngol* 1980; 9:439-50.
9. Benjamin B. Treatment of infantile subglottic hemangioma with radioactive gold grain. *Ann Otol Rhinol Laryngol* 1978; 87:18-21.
10. Cohen SR, Wang CI. Steroid treatment of hemangioma of the head and neck in children. *Ann Otol Rhinol Laryngol* 1972; 81:584-90.
11. Narcy P, Manach Y, Brasnu U, Daussy E. Angiomes sous-glottiques du nourrisson. A propos de 20 observations. *J Fr Otorhinolaryngol* 1980; 29:361-5.
12. Calcaterra TC. An evaluation of the treatment of subglottic hemangioma. *Laryngoscope* 1968; 78:1956-64.
13. Dillard RG. Subglottic hemangioma: a new approach to management. *Am J Dis Child* 1979; 133:753.
14. Pierce MK. Subglottic hemangiomas in infants. A presumptive clinical test for diagnosis. *Ann Otol Rhinol Laryngol* 1962; 71:1057-62.
15. Overcash KE, Putney FJ. Subglottic hemangioma of the larynx treated with steroid therapy. *Laryngoscope* 1973; 83:679-82.
16. Mawson S. Subglottic haemangioma of the larynx treated by excision. *J Laryngol Otol* 1961; 75:1076-81.
17. Karja J, Ralva A, Jokineu K. Cryotherapy in the treatment of subglottic hemangioma in infants. *Acta Otolaryngol (Stockh)* 1979; 360:58-60.
18. Healy GB, Fearon B, French R, McGill T. Treatment of subglottic hemangioma with the carbon dioxide laser. *Laryngoscope* 1980; 90:809-13.
19. Tefft M. The radiotherapeutic management of subglottic hemangioma in children. *Radiology* 1966; 86:207-14.
20. Holborrow CA, Mott TJ. Subglottic haemangioma in infancy. *J Laryngol Otol* 1973; 87:1013-7.
21. Li FP, Cassady R, Barnett E. Cancer mortality following irradiation in infancy for hemangioma. *Radiology* 1974; 113:177-8.



# FURTHER OBSERVATIONS ON THE TREATMENT OF RECURRENT RESPIRATORY PAPILLOMATOSIS WITH INTERFERON: A COMPARISON OF SOURCES

ROY B. SESSIONS, MD

HELMUTH GOEPFERT, MD

WILLIAM J. DICHTTEL, MD

DONALD T. DONOVAN, MD

JORDAN U. GUTTERMAN, MD

HOUSTON, TEXAS

Between June 1982 and March 1983, 11 patients with aggressive recurrent respiratory papillomatosis were treated with alpha or human leukocyte interferon (IFN) that was produced by and purchased from the New York Blood Center, Inc. The year before, nine of these patients had been on a similar protocol utilizing alpha-IFN that had been supplied by the Finnish Red Cross Blood Transfusion Service. Comparisons regarding response and toxicity were made and are reported. In our series we have not seen an overall difference in response of papillomatosis to these two IFNs. As many of our patients responded better to the New York product as responded worse. There is a suggestion, however, that the New York product is associated with less toxicity than the Finnish IFN.

## INTRODUCTION

Substantial interest has resulted from the relatively recent usage of interferon (IFN) in several preliminary, but noncontrolled, studies of patients with recurrent respiratory papillomatosis (RRP) treated for varying lengths of time.<sup>1-3</sup> Human leukocyte IFN (HLIFN) has been employed in these studies, and by and large it is from this type of IFN that the bulk of the basic knowledge of the pharmacokinetics of the substance has been learned. Last year, we reported<sup>2</sup> on a series of 12 patients with aggressive RRP that we had treated with HLIFN that was made in the method described by Cantell et al<sup>4</sup> and purchased through the Finnish Red Cross Blood Transfusion Service. Those 12 patients were studied from 7 to 12 months; their response to the IFN was mixed, but encouraging. Our results supported the earlier data of Haglund et al<sup>1</sup> and pointed out the need to pursue further studies. McCabe and Clark<sup>3</sup> have recently published information derived from the 6- to 12-month treatment of a similar but somewhat larger group than ours in which they used HLIFN that had been developed and purchased from the New York Blood Center, Inc. This IFN is theoretically the same as that obtained from the Scandinavian sources, but there was suspicion that not only was it more effective against RRP than the Finnish IFN (FIFN), but also the toxicity seen with the New York product seemed to be less. In light of these suggestions, it seemed reasonable as well as valuable that we should utilize the patients of our series that had been treated with the Finnish product in a similar trial with the IFN from the New York Blood Center, Inc. (NYIFN).

The goal of this paper, then, is to report our observations in those nine patients of this original study group who, after the 1-year trial of FIFN was stopped, were put on a similar time/dose schedule of NYIFN. The study was prospectively designed and was jointly conducted by the Baylor College of Medicine and the Departments of Otorhinolaryngology and Head and Neck Surgery at the M.D. Anderson Tumor Institute.

## BACKGROUND

*Recurrent Respiratory Papillomatosis.* Although the incidence of RRP is low in the overall context of population studies,<sup>5</sup> the morbidity, the relentlessness of lesional reappearance, and the threat to life associated with the treatment of these airway-compromising growths impose a substantial emotional and financial burden on the families of those afflicted.

Recurrent respiratory papillomatosis occurs predominantly in the larynx of youngsters, but on occasion has its onset in the adult years. It would seem that, as a rule, the disease is more aggressive in the younger age group. Certainly the smaller size of the child's larynx renders any intraluminal encroachment by these warty lesions a more formidable compromise of the airway; in infants, strategically located growths of any size create hazardous circumstances both in the awake state and especially during the administration of general anesthesia. This unique laryngeal distribution represents a predominant circumstance, but there are exceptions. For instance, RRP occasionally occurs in the tracheobron-

From the Department of Otorhinolaryngology and Communicative Sciences, Baylor College of Medicine (Sessions, Donovan, Dichtel); and the Department of Head and Neck Surgery (Goepfert), and the Department of Developmental Therapeutics (Gutterman), M. D. Anderson Tumor Institute, Houston. Research supported by the Interferon Foundation and the Clayton Foundation for Research, and in part by the James E. Lyon Foundation. Presented at the meeting of the American Laryngological Association, New Orleans, April 10-11, 1983.

REPRINTS — Roy B. Sessions, MD, Division of Head and Neck Surgery, Dept of Surgery, Memorial Sloan-Kettering Cancer Center, 1275 York Ave, New York, NY 10021.

chial tree as well as in the hypopharyngeal area. The reasons for this peculiar pattern of mucosal distribution is not known.

Regarding behavior, RRP is the master of predictable unpredictability. These lesions are unique among the papillomas seen in humans, not only in their distribution, but also because of their proclivity for extremely variable activity. They can demonstrate intense and relentless growth noticeable even on a day-to-day basis. This state can exist for a variable period that can be followed by a period of total quiescence. Following such a period the growths may reappear at any given time, or the patient might remain disease-free indefinitely. We have seen these very behavior problems in several patients. Other behavioral peculiarities can exist. Patients with RRP during preschool years can experience total resolution during puberty and can remain papilloma-free until lesional reappearance during middle age. We have also seen this occurrence. The reasons for this waxing and waning are totally unknown. More commonly, RRP grows in a chronic manner, requiring periodic surgical intervention. The enigmatic nature of the behavior of this disorder is, to say the least, impressive, and this fact makes the evaluation of any therapeutic modality difficult.

Despite considerable investigative effort, the exact etiology of RRP remains indefinite, but it is almost certainly viral, a contention supported by the observations in these lesions of a tumorigenic, intranuclear DNA virus belonging to the papova group.<sup>6,7</sup> Human papilloma virus (HPV) has not been isolated in these mucosal lesions, however, and a lack of a successful cell-culture system has hampered study of the molecular biology and genetics of HPV.<sup>3,8</sup> That the presumably responsible viral agent is of the papova family is significant. Five different viruses have been identified in cutaneous papillomas of man. Immunohistochemical techniques suggest that the viruses that produce laryngeal papillomas and cutaneous warts are of a similar family subgroup.<sup>9</sup> These viruses are apparently both host- and tissue-specific, and induce epithelial and fibroepithelial lesions.<sup>10</sup> It has also been suggested that an HPV may also be responsible for such mucosal papillomas as laryngeal and anogenital warts. The clinical observations in mothers of children afflicted with RRP is noteworthy in that a substantial number of them have a history of having anogenital warts. Although definitive data derived from prospective studies do not exist, other studies lend support to the implications of this clinical observation.<sup>11</sup>

The literature regarding past and present treatment methods of RRP is voluminous and provides a litany of clinical experimentation.<sup>10,12-19</sup> During recent years, carbon dioxide (CO<sub>2</sub>) laser vaporization of individual lesions has been the most popular

method used.<sup>12</sup> Whatever the treatment method employed, none has been curative. It is clear that the search for a definitive and more biologic treatment modality must continue, hence the interest in IFN, a substance with potent antiviral, antiproliferative, and immunomodulating properties.

*Interferon.* It is inappropriate to simply use the singular word "interferon" since there are many cells capable of producing different interferons. IFNs are antiviral, antiproliferative, and immunomodulating polypeptides. They are products of a complex defense mechanism that involves the release of substances from cells following certain challenges. They have no direct antiviral action, but instead are characterized by the ability to confer antiviral resistance on virus-susceptible cells by inducing the synthesis of intracellular enzymes that act to control growth.<sup>20</sup> The major types of IFN are those that are induced by viral stimulation and those induced by antigenic or mitogenic stimulus. The former group, type 1, includes leukocyte (alpha) and fibroblast (beta); the latter group, type 2, is derived from lymphocytes and is known as gamma. A more homogeneous leukocyte interferon can be produced bacterially by recombinant DNA technology<sup>21</sup> in which single clonal derivatives are the end products.

## METHODS

A nonrandomized study was conducted between June 1982 and March 1983 on 11 patients with aggressive laryngeal and/or laryngotracheobronchial (LTB) papillomatosis treated with partially purified HLIIFN obtained from the New York Blood Center, Inc. Two patients had never been treated with IFN and the other nine patients had undergone previous treatment with alpha-HLIIFN obtained from the Finnish Red Cross and Blood Transfusion Service, Helsinki. These nine patients were chosen because their disease had become refractory to the IFN or the RRP had become recurrent following completion of and removal from the previously reported protocol.<sup>2</sup> Before the patients were admitted to this study, detailed histories were taken and physical examinations were performed. Complete blood counts, platelet counts, liver function studies, serum urea nitrogen, creatinine interpretation, and chest radiographs were obtained. Suspension laryngoscopy and appropriate laser vaporizations were performed on all patients prior to each patient's enrollment in this study. All patients had required numerous endoscopies previously and six patients had at one time required or were currently dependent upon tracheostomies. Three patients had LTB involvement.

Once the treatment was initiated, the patients underwent monthly endoscopies as dictated by clinical progress. The extent and distribution of papillomas were recorded diagrammatically in each case in a manner that depicted the distribution and extent of the lesion in different dimensions.

All visible papillomas were removed by CO<sub>2</sub> laser vaporization in the larynx and tracheobronchial tree. The endoscopies and treatments were done by one endoscopist (RBS). This same person had done the endoscopy in the previous study that was conducted with FIFN.

On each patient, complete blood differential and platelet counts were obtained every other week; liver and renal function studies were performed monthly or more frequently if required because of abnormal findings.

The initial dose of IFN was 2 million units/m<sup>2</sup> daily given intramuscularly. The frequency of administration was changed to



TABLE 1. RESULTS OF ALPHA-IFN THERAPY

Case No.	Sex	Age (yr)	Onset (yr)	Natural History		Months on IFN		Toxicity		Response			
				Location	Endoscopies	NYIFN	FIFN	NYIFN	FIFN	Initial NYIFN	Initial FIFN	Sustained NYIFN	Sustained FIFN
1	M	3	1.5	Larynx	Many	9	7	1+	1+	Slight	Slight	No 6*	Yes
2	M	9	6.0	Larynx	Many	7	6	2+	3+	Good	None	Yes	—
3	M	30	25.0	Larynx (trach)	Many	8	10	None	None	Good	Complete	No 7*	No 7*
4	F	2	1.0	Larynx TBP (trach)	Many	8	12	1+	None	Slight	Mod	—	No 6*
5	M	27	2.0	Larynx (trach)	300+	8	9	1+	None	Complete	Good	Yes	Yes
6	M	12	5.0	Larynx	100+	8	12	1+	2+	None	Good	—	No 3*
7	F	8	5.0	Larynx (trach)	Many	8	11	1+	2+	Good	Good	Yes	No 4*
8	M	14	4.0	Larynx TBP (trach)	Many	8	7	1+	1+	Good	Slight	Yes	
9	M	4	2.0	Larynx TBP (trach)	Many	9	12	None	None	Mod	Mod	Yes	Yes
10†	M	2	1.0	Larynx	Many	7		1+		Slight		—	
11†	M	5	4.0	Larynx	Many	8		1+		None		—	

\*No. of months response sustained.

†These patients did not participate in the FIFN study.

Mod - Moderate.

TBP - Tracheobronchial pulmonary involvement.

three times weekly whenever the papilloma growth rate decreased or remained stable over two successive endoscopies. Furthermore, changes in frequency first (to three times weekly) and/or reduction of the individual dose (to 1 million units/m<sup>2</sup>) were called for whenever the absolute granulocyte count dropped below 1,000 or the level of SGOT rose above 100 units/mL. If toxicity persisted despite dosage changes, IFN was temporarily discontinued until the test values returned to normal. The patients themselves or family members were instructed in the technique of injection for "at home" IFN administration.

The response to treatment was graded from the diagrams that had been marked by the endoscopist. The diagram evaluation and grading was done in the same manner as was used in the evaluation of the responses to the FIFN in our previous study.<sup>2</sup> Additionally, the same individual (WJD) performed this task in both of these studies. A response was considered *complete* when no evidence of papilloma was present in the laryngotracheal bronchial area. A *good* response had an estimated 75% reduction of the overall papilloma volume relative to the disease at the time of entrance into the study, a *moderate* response had 50% to 75% estimated reduction, and a *slight* response had 25% to 50% reduction. If no discernible reduction in growth occurred or if growth increased, it was ruled a *nonresponse*. Reduction in papilloma volume was assumed to represent a response to IFN.

## RESULTS

All 11 patients completed a minimum of 8 months on alpha-IFN therapy, an arbitrary minimum that had been chosen in order to qualify these patients for comparison data (Table 1). The responses were distributed as follows among these 11 patients: one complete response (patient sustained response throughout study); four good responses (three of four sustained); one moderate response (patient sustained response throughout study); two slight responses; two, no response. In five of the six patients that demonstrated a moderate or better response, that response was sustained throughout the study.

Toxicity was evaluated in all 11 patients and was measured by WBC drop and SGOT elevation. The degree of toxicity was classified as slight (1+) when

the SGOT remained under 100 and returned to normal with the adjustment of the IFN dosage, was considered moderate (2+) when the SGOT level was above 100 but returned to normal with proper dosage adjustment, was considered marked (3+) when the SGOT level was progressive and forced discontinuation of the protocol. Temperature elevation to 40°C was seen in three patients during the early stages of the study, but was not a problem after several doses. Significant fatigue was present in two patients. One patient had anorexia and weight loss, and one of the two adult patients complained of loss of libido. One patient had intense myalgia while on treatment. None of these symptoms were considered as major signs of toxicity and were ignored.

Two patients had neither signs nor changes in laboratory values that could be attributable to IFN. All the other nine patients had either symptoms or signs that were directly attributed to the IFN. None of these lasted beyond a week after medication was discontinued.

SGOT elevation was present in four of the 11 patients and all of these responded to dose modification. Two cases required twofold dosage reduction, and one patient did not tolerate more than 1 million units/m<sup>2</sup> three times weekly without a rise in the SGOT beyond 100 units/mL.

An absolute granulocyte count below 2,000 was observed in seven patients. In three patients, the myelosuppression was parallel to the rise in SGOT, and in all three there was prompt response after dose modification. No thrombocytopenia occurred.

The general distribution of toxicity in adults as opposed to children could not be evaluated due to the fact that only two of the 11 patients were adults.

TABLE 2. COMPARISON OF RESPONSES IN TWO GROUPS OF PATIENTS

	NYIFN	FIFN
Complete response	1	5
Good response	4	3
Moderate response	1	2
Slight response	3	2
No response	2	0
Total patients	11	12

Both of these adults failed to show significant toxicity to IFN.

No correlation between the response of papillomas and the susceptibility of the patients to IFN toxicity was seen in these 11 patients.

#### COMPARISON OF RESULTS BETWEEN NYIFN AND FIFN

The comparative data accumulated is summarized in Table 1. Overall comparison of responses between these 11 patients treated with NYIFN versus the 12 patients from the previously reported group treated with FIFN shows that 55% of those in the NYIFN group recorded a moderate response or better, while 83% of the FIFN group responded at a level of moderate or better (Table 2). Considering the limited number of patients in these two series, one cannot ascribe statistical significance to this difference. This fact is supported by the obvious contradiction shown by a direct, patient-to-patient comparison of only those nine patients that participated in both protocols (Table 3). It is upon these nine patients that the attention of this analysis should be focused. In Table 3, one can see that in both the NYIFN and the FIFN groups, six of the nine patients showed a moderate or better response, ie, 67%. This direct method of comparison should more accurately reflect papilloma response to the two IFNs. Carrying the direct comparison even further, analysis shows that three of the nine patients who participated in both studies responded more substantially to the NYIFN than FIFN, three of the nine responded the same to each IFN, and three of the nine patients responded less to the New York product than to the Finnish product.

Of those nine patients who participated in both studies, six had either moderate, good, or complete responses while three had slight responses or none. The complete responder had been a good responder to the Finnish product. Two good responders had been a nonresponder and a slight responder respectively on the Finnish product. The other two good responders had been a complete responder and a good responder previously. The one moderate responder had been a moderate responder to the FIFN. The three patients who had either a slight or a nonresponse to the New York product were categorized as follows: one slight responder had previously been a slight responder, the other slight responder had previously been a moderate re-

TABLE 3. COMPARISON OF RESPONSES IN PATIENTS ON BOTH PROTOCOLS

	NYIFN	FIFN
Complete response	1	1
Good response	4	3
Moderate response	1	2
Slight response	2	2
No response	1	1
Total patients	9	9

sponder, and the nonresponder had previously been a good responder.

Toxicity data comparisons reveal that two of the nine patients demonstrated greater toxicity to the New York product, three of the nine demonstrated less, and in four of the nine patients, there was the same level of toxicity seen with the administration of both products.

Other specific observations about specific patients' responses and toxicity should be made. Patient 5, a complete responder to the NYIFN, became negligent with the administration of his medication midway through the course of this protocol and the papilloma promptly began to grow prolifically. Shortly after he restarted his injections, he had another complete response. The cycle of events occurred one other time with this same patient. Patient 6 had an extremely volatile toxicity response to the FIFN from the first injection, and was difficult to manage because of the "up and down" nature of both his liver enzymes and his WBC. He did seem, however, to have substantial papilloma response to IFN as long as he was taking the medication. On the other hand, his response to NYIFN has been noticeably different in that he has demonstrated only a slight degree of toxicity and has tolerated his medication quite well; however, his papilloma growth has been totally unresponsive.

#### DISCUSSION

The complexities of the natural history of RRP as well as the absence of hard data regarding its etiology have been explored and reexplored in the medical literature. Little would be accomplished by belaboring these topics in this paper; however, one should understand how these problems impact on the evaluation of any treatment modality. The many methods of management tried on this enigmatic disorder attest to the lack of consistent response associated with any one particular treatment. Although there is currently a great deal of interest being shown in the IFNs, and the studies thus far are encouraging, the final answer is clearly not yet available. The natural history of RRP is so variable both from individual to individual, and also from one occurrence to the other in any given patient, that measuring response of the lesions to any treatment modality is difficult; thus any conclusions must be arrived at with considerable skepticism. It is, in essence, difficult for one to judge



whether a variation in papilloma volume or distribution is related to the administration of IFN or is, in fact, secondary to natural cycling of an erratically behaving affliction, or whether such variations are related to a combination of both factors. With these reservations in mind, clinical impressions about treatment success or failure must be based on striking rather than subtle changes in papilloma volume. It follows that in our clinical study, the most emphasis should be placed on the complete and good responders. In the lesser responders, the suggestion of response to IFN can be implied, but only with stern reservations.

Considering that only 1,500 or so new papilloma patients are encountered each year in the United States,<sup>22</sup> generating a statistically meaningful patient population in any one institution presents a formidable task. Current ongoing, multiinstitutional studies on IFN treatment of RRP will hopefully provide the necessary numerical volume lacking in this and other studies.<sup>2,3</sup>

An additional factor in gaining a confidence level in judging the effects of IFN on RRP would be a double-blind approach to treatment of these patients. This has not, however, been practical due to the fact that often the administration of IFN is associated with a transient febrile reaction as well as other telltale systemic sensations such as a feeling of general malaise. Disguising a placebo under such circumstances is, to say the least, unreliable.

Considering all of these factors, then, limited but nonetheless valuable goals can be sought in studies such as ours. The pilot clinical studies in a general way serve to augment overall knowledge through the observations of experienced endoscopists, but more importantly, suggest direction of the more elaborate and enormously expensive multiinstitutional studies. Additionally, we have attempted to capitalize on the unique opportunity to sequentially treat the same group of patients with two different sources of IFN, and while using the same standards of observation by the same endoscopist, make comparisons on the responses to each.

With regard to the IFNs themselves, most of the basic knowledge gained in the treatment of RRP has been with alpha or HLIFN. The relatively impure varieties made by the two sources discussed in this paper, ie, FIFN and NYIFN, are both alpha IFNs, supposedly made by similar methods, ie, from buffy coat lymphocytes that are stimulated to produce an IFN that contains a variety of subtypes or clones, all of which have probably not been identified.<sup>3</sup> Through recombinant DNA technology, individual clones or subtypes of various IFNs can be produced, rather than the mixture that is harvested *in vitro* by these other techniques. These *in vitro* responses to various biochemical manipulations are not, however, necessarily the way the *in vivo* interferon is produced. Much remains to be learned in this gen-

eral area, and, as is often the case in many areas of scientific investigation, the more that is learned, the more complicated this entire system becomes. At the time we published our original data<sup>2</sup> last year on the FIFN, the unpublished preliminary data from Iowa suggested that the NYIFN might become more effective against RRP than the Finnish product. In our publication, we speculated on the actual occurrence of an array of different subtypes in the two products, and even speculated on RRP being subtype-specific.

Using FIFN we had showed a substantial response in a majority of the patients, but not all of them sustained their response. The results were clearly discouraging and our overall impression was that in certain patients, the IFN that we were using was quite helpful. With the suggestion of an even higher response rate and less toxicity with the NYIFN, we were anxious to use that product and did so in nine of those original 12 patients in a manner similar to the first study. Our impressions are not what we expected; we have seen no clear-cut difference in responses in this group using the New York product. Using the same criteria for response evaluation, similar percentages responded substantially to the NYIFN as to the FIFN (Table 3). In fact, of those nine patients treated with both the IFNs, an equal number of patients (three) responded to a lesser degree to the NYIFN as responded to a greater degree. Since our publication, McCabe and Clark's report on 19 RRP patients treated with NYIFN has been published.<sup>3</sup> Overall response rates are similar, but we are especially interested in their seemingly higher percentage of complete responders. Assuming, of course, that the two patient populations are similar, one could only account for this by either a sampling error or a dosage/time schedule difference between the two studies. Since it is our impression that dosage level, although important, is not the critical factor in response, we would tend to explain this difference between McCabe and Clark's complete response rate and ours by sampling error, ie, our small series.

There is a suggestion that there is less toxicity associated with the administration of NYIFN, and there does seem to be a more stable acceptance of this product. Regarding toxicity, it was originally thought to be related to impurities in the IFN products. This is apparently not the case, since such toxicity manifestations are seen in those patients treated with the much more pure lymphoblastoid IFN and also the clones produced by recombinant technology. The toxicity phenomenon is apparently due to the IFNs themselves and, if one carries this line of thinking even further, the alterations in measurable parameters that we are seeing may not be manifestations of "toxicity" at all, but may be natural biochemical alterations induced by IFN. In a similar way, one can hardly refer to myelosuppression as toxicity, since this is a reflection of one of

the main characteristics of IFN, namely an antiproliferative activity. As a matter of practical necessity, however, in these patients treated with NYIFN just as in those of the FIFN group, SGOT elevation was a dose-limiting factor. Since no liver biopsies were done, the histomorphologic state of the liver under these circumstances is not known. Whether or not there was an inflammatory tissue response is uncertain; all such elevations returned to normal following either lowering of dosage or temporary cessation of the IFN altogether. The exact pathogenesis of the liver response is further compounded by the fact that most of these patients have had multiple general anesthetics, a circumstance that may influence overall liver health.

Overall, this is a vast and fertile area for research. Currently there are several horizons in this general area of clinical research that we would like to mention. There are two current clinical trials being undertaken, one using alpha-HLIFN from the

New York Blood Center, Inc, on a large group of patients, hopefully of sufficient size to establish statistical credibility to our initial clinical impression that a substantial percentage of RRP patients benefit from IFN. Secondly, there is another study in which a group is being treated and studied with lymphoblastoid IFN, supposedly a substantially purer version of alpha IFN. We hope that the results of these studies will lead to at least limited approval by federal regulatory agencies for usage of IFN in RRP. Regarding its general use, it is essential to bear in mind that in tampering with the immune system, clinical investigators assume responsibilities that are far-reaching. Thus far, the problems reported are nil; however, consistent standards should be maintained. Patients with aggressive and troublesome RRP should be selected for treatment rather than those with less aggressive and slow-growing RRP that can be easily controlled with conventional means.

#### REFERENCES

1. Haglund S, Lundquist P, Cantell K, Strander H. Interferon therapy in juvenile laryngeal papillomatosis. *Arch Otolaryngol* 1981; 107:327-32.
2. Goepfert H, Sessions RB, Gutterman J, Cangir A, Dichtel W, Sulek M. Leukocyte interferon in patients with juvenile laryngeal papillomatosis. *Ann Otol Rhinol Laryngol* 1982; 91:431-6.
3. McCabe B, Clark K. Interferon and laryngeal papillomatosis: the Iowa experience. *Ann Otol Rhinol Laryngol* 1983; 92:2-7.
4. Cantell K, Hirvones S, Morgenson KE, Pykala L. Human leukocyte interferon: production, purification, stability and animal experiments. *In Vitro* 1974;35-8.
5. Quick CA, Foncan E, Dehner L. Frequency and significance of epithelial atypia in laryngeal papillomatosis. *Laryngoscope* 1979; 89:550-60.
6. Boyle WF, Riggs JL, Oshior LS, Lennette EH. Electromicroscopic identification of papova virus in laryngeal papillomatosis. *Laryngoscope* 1973; 83:1104-8.
7. Arnold W. Tubular forms of papova viruses in human laryngeal papilloma. *Arch Otorhinolaryngol* 1979; 225:15-29.
8. Faras AJ, Krzyzek RA, Ostron RS, et al. Genetic variation among papilloma viruses. *Ann NY Acad Sci* 1980; 354:60-70.
9. Quick CA, Faras A, Krzyzek R. The etiology of laryngeal papillomatosis. *Laryngoscope* 1978; 88:1789-95.
10. Quick CA, Behrens HW, Bunton-Darnell M, Good RA. Treatment of papillomatosis of the larynx with transfer factor. *Ann Otol Rhinol Laryngol* 1975; 84:607-13.
11. Cook TA, Cohn AM, Brunschwig JP, et al. Wart viruses and laryngeal papillomas. *Cancer* 1973; 1:782-5.
12. Strong MS, Vaughan CW, Healy GB, Cooperband SR, Clemente MACP. Recurrent respiratory papillomatosis: management with CO<sub>2</sub> surgical laser. *Ann Otol Rhinol Laryngol* 1976; 85:508-16.
13. Birk HG, Mankart HE. Ultrasound for juvenile laryngeal papillomas. *Arch Otolaryngol* 1963; 77:603-8.
14. Hollingsworth JB, Kohlmoos HW, McNaught RC. Treatment of juvenile papilloma of the larynx with resin of Podophyllum. *Arch Otolaryngol* 1950; 52:82-7.
15. Holinger PH, Johnson KC, Anison GC. Papillomas of the larynx: review of 109 cases with a preliminary report on aureomycin therapy. *Ann Otol Rhinol Laryngol* 1950; 59:547-64.
16. Sakurai S, Takahasi M, Nakajima Y, Ishizaka T. Juvenile papilloma of the larynx treated by bleomycin. *Keio J Med* 1975; 24:11-7.
17. Smith HG, Healy GB, Vaughan GW, Strong MS. Topical chemotherapy of recurrent respiratory papillomatosis. *Ann Otol Rhinol Laryngol* 1980; 89:472-8.
18. Holinger PH, Shipkowitz NL, Worland MC. Studies of etiology of laryngeal papilloma and an autogenous laryngeal papilloma vaccine. *Acta Otolaryngol (Stockh)* 1968; 65:63-9.
19. Stephens CB, Arnold GE, Butchko GM, Hardy CL. Autogenous vaccine treatment of juvenile laryngeal papillomatosis. *Laryngoscope* 1979; 89:1689-96.
20. Gutterman JM. Clinical investigation of the interferons in human cancer. *Cancer Bull* 1981; 33:271-8.
21. Goeddel DV, Yelverton E, Ullrich A, et al. Human leukocyte interferon produced by *E. coli*. *Nature* 1980; 287:411-6.
22. Strong MS, Vaughan CW. Recurrent respiratory papillomatosis. In: Healy CB, McGill TJ, eds. *Laryngotracheal problems in the pediatric patient*. Springfield, Ill: Charles C. Thomas Publishers; 1979:88-98.



# TRAINING SINGING CHILDREN DURING THE PHASES OF VOICE MUTATION

IRVING M. BLATT, MD

NEW ORLEANS, LOUISIANA

Development of singing ability in children is well documented and frequently fraught with admonitions to postpone formal training until the age of 17 or 18 years for boys and 16 years for girls, when voice change is usually complete and the risk for damaging developing structures is minimal. The author contends that the interval of voice mutation, a time of rapid physical change, is precisely the period when the young singer should pursue human musical instrument training under tutelage of singing teachers knowledgeable and experienced in the training techniques described herein and with the guidance of an otorhinolaryngologist to evaluate and monitor fitness. Voice mutation is viewed as a natural process of maturation, which can be enhanced by a formal training program.

## PROBLEM AND CHALLENGE OF THE MUTATIONAL VOICE

Whether or not to sing during the time of voice mutation continues to be an interesting controversy of empirical and scientific phoniatry. The corollary challenges the successful transformation of the prepubertal singing voice through the mutational period to the adult voice, regardless of the ultimate compass of the mature singing voice.

The author's thesis is that the problem of successful voice mutation can be solved by devising a training program for singing children during prepubertal, pubertal, and adolescent phases of voice mutation to develop stable techniques in the dynamic process of singing: respiration, phonation, resonance, and phonetics.

## HISTORICAL REVIEW

During the monophonic Graeco-Roman period, the prepubertal boy's voice was important for solo singing accompanied by the reeded aulo and the stringed kithara.<sup>1</sup> The art-loving societies of that antiquity were aware of pubertal voice change, and some teachers "prepared" children for singing careers by infibulation and castration.<sup>2</sup>

Surviving examples of fourth century Byzantine music in the early eastern Christian church include parts written for castrati.<sup>3</sup> Female singers were excluded from church choirs in accordance with Paulist doctrine as noted in I Corinthians 14:34, "The women should keep silent in the churches, for they are not permitted to speak, but should be subordinate, even as the law says."<sup>4</sup>

After the development of polyphony in music during the 11th century,<sup>1</sup> extensive use was made of boys' voices in the churches of Christendom. Payment was made for children's services at this time, and reportedly some boys were kidnapped to sing.<sup>2</sup>

From the Julius Lempert Memorial Clinic, Metairie, Louisiana.

Presented at the meeting of the American Laryngological Association, New Orleans, April 10-11, 1983.

REPRINTS — Irving M. Blatt, MD, Louisiana Neurosensory Clinic, 4770 I-10 Service Road, Suite 210, Metairie, LA 70001.

With secular solo and choral singing, particularly during the mature Baroque period of the 17th century, all registers of male voices became popular for both oratorio and opera,<sup>1</sup> and the successful transformation from boy's to adult voice was of significant concern.

In the 19th century, it also became fashionable to attend the pubertal change in the girl's voice, which was found to be a less profound problem. The whole subject of how to manage the period of vocal mutation was brought into sharp focus in the latter 19th century by ethical differences of opinion between the singing teacher who invented the mirror laryngoscope, Manuel Garcia, and a contemporary laryngologist, Sir Morell MacKenzie. Garcia and his proponents forbade all singing for the entire period of pubertal voice change,<sup>5</sup> while MacKenzie and his allies favored varied degrees of continued singing.<sup>6</sup>

At the turn of the 20th century, Dawson<sup>7</sup> worked to diminish the hazards of mutation for the ensuing adult voice by systematic singing at the time of mutation. This choirmaster frequently evaluated the compass of the voices of his boys, kept them singing, and led them safely through their mutation periods, preventing even the breaking of the boys' speaking voices.

Thus the stage has been set for consideration of a systematic singing training program for boys' and girls' voices in the 1980s to insure a successful transition. The program we developed, which may be considered *voice habilitation* for singing children, includes hygienic skills designed to maintain healthy structures and prevent pathological conditions that can develop during mutation.

## MATERIAL AND METHODS

### EXPRESSIONS RELATED TO SINGING

*Training.* This term means forming and directing by instruc-

TABLE 1. CHARACTERISTICS OF SUBJECTS STUDIED (N = 175)

Category	Age (yr)		Length of Study		Sex		Total Children
	Range	Average	Range	Average	M	F	
Voice class participants in Louisiana gifted and talented program	7-16	11.6	2 mo-4 yr	1.4	44	64	108
Children receiving private individual instruction	7-16	10.4	5 mo-8 yr	2.6	21	46	67

tion, discipline, and drill; training includes diet, exercise, and hygiene.

**Technique of Singing.** Technique refers to a method of performance. The concept of technique described here is that the fundamental principles of singing are identical for all voices of every age and type. The only difference in performance is the degree of execution and refinement. Singing technique involves total body action for human musical instrumentation. It is essentially an athletic event for artful sound production.

**Singing Voice Mutation.** This term refers to physiologic changes in the developing child expressed as voice changes which occur over time until the adult form is achieved. Pathological conditions are not the natural consequence of voice change and have not been experienced in this study utilizing the singing techniques described.

**Prepubertal Singing Voice.** This refers to "head voice," as distinct from "chest voice," and is usually identified in children aged 5 through 11 (elementary grades 1 through 6).

**Pubertal Singing Voice.** The voice of the developing child is usually identified at age 12 and 13 (middle and junior high school grades 7 through 9).<sup>8</sup>

**Adolescent Singing Voice.** The voice of the young adult emerges usually at age 14 through 17 years (grades 10 through 12).

#### CRITERIA FOR SELECTION OF SUBJECTS

Published observations on training children to sing include discussions of the following criteria: specific capabilities of children at different age levels, some as early as age 3;<sup>9,10</sup> intrasensory and intersensory perception of transfer of melodic contour;<sup>11</sup> motor skill development relevant for music;<sup>12</sup> designated frequency range;<sup>13</sup> and peer behavior in the form of modeling, tutoring, and encouragement of student work in the process of vocal instrument learning.<sup>14,15</sup>

Our children, selected from the public and Catholic school systems of southern Louisiana, were found to possess prospective singing talent, acting ability, musical intelligence, and physical vigor. The criteria for selection include the following traits:

1. Vocal tone and quality, with carrying power; "ring" sonority and command (ability to have and use); a sense of pitch (ability to hear, duplicate, and produce).
2. Ability to hear and interpret rhythms accurately and to identify musical intervals. Reading experience was not necessary for selection.
3. Responsive personality, with imagination.
4. Eagerness and enthusiasm for learning.
5. A healthy human musical instrument.

**Characteristics of Subjects.** The study included more than 1,000 children from southern Louisiana, 175 of whom were ob-

served and trained in this technique (Table 1). The remaining children (Table 2) were primarily under the tutelage of their own choral directors and singing teachers who applied the principles and techniques of training and hygiene herein described. Thus the population consisted of two groups (Tables 1 and 2).

#### RESULTS OF PREVIOUS STUDY

In 1977, Astraquillo et al.<sup>16</sup> published the results of a 6-year study of singing techniques practiced by undergraduate college voice majors utilizing electromyography, a laboratory method for evaluating muscle function. Observations were made on the relationship between abdominal muscle discipline and the act of singing, utilizing a series of graduated vocalises. The findings are important for proper breathing for singing, and the methods were similar to the methods used for this study.

1. Muscle action potentials (MAP) from all recorded locations for any tested tonal frequency increased as the air supply decreased.
2. With both staccato and legato articulation, muscle activity often preceded the onset of voice. This was true with low tones with low volumes as well as high tones with high volumes. With high pitch at high intensity, phasic muscle activity was evident in all MAP locations, especially with trained subjects.
3. Untrained subjects were found to have more thoracic activity as monitored by impedance pneumography.
4. Phasic muscle activity with good abdominal control was most readily observed in trained subjects during staccato articulation. In legato singing, with high pitch and high-tone volume, muscle activity was constant in trained subjects.
5. All muscles did not return to their previous resting potential between articulations. The faster the exercise or vocalise and the higher the tonal quality of the vocalise, the more active (shorter resting length) and more constant the muscle activity was in trained subjects.

#### OBJECTIVES

The present study explores the following questions. Can children ages 6 to 16 develop singing concepts and skills and perform musically with comprehension of style, musical structure, and nuance after a training program similar to that used with college-level subjects?

Can the techniques making up the program be used from childhood through the period of mutation by both boys and girls without damage? What effect on the cambiata, or boy's voice, can be detected?

What is the role of the physician in voice development and training of singing children?

Objectives, activities designed to accomplish the objectives, and end-result behaviors are presented in detail in Table 3.

TABLE 2. PUBLIC AND CATHOLIC SCHOOL CHILDREN TRAINED WITH DESCRIBED PROTOCOL

Site, Grade Level & Age Range	Type of Singing Training	Onset of Program	Children Per Year (avg)
Elementary school, East Baton Rouge Parish public schools, grades 4-9, ages 9-14	Choral & some individual instruction	1979	100
Junior high school, Lafourche Parish public schools (Thibodaux, La), grades 7-9, ages 12-14	Choral & some individual instruction	1976	100
Ascension Parish high school, grades 10-12, ages 15-17	Choral & some individual instruction	1981	100
Catholic church parishes of Lafayette, Opelousas, Mamou, Grand Coteau, & Sunset, grades 1-10, ages 6-15	Church choir & some individual instruction	1978	200



TABLE 3. TRAINING PROGRAM FOR SUCCESSFUL SINGING THROUGH PERIOD OF VOICE MUTATION

<i>Objective</i>	<i>Activities</i>	<i>Results</i>
Promote understanding of facts about singing & overall knowledge of requisite skills to clarify & guide future study	In formal lesson or classroom setting, team member to define & describe technical goals, displaying attitudes of enthusiasm, interest & pleasure, demonstrating technique & musicianship necessary for success in singing; practice of good vocal hygiene described, instituted, & supervised	Gradual reduction in consciousness, nervousness & fright in performance
Develop understanding of fundamental principles of efficient breath control, learn to coordinate physical effort, vocalize sound	Regular practice of following exercises, drills, behaviors supervised by team member or by student alone: posture exercises; different types of breath control (aimed at ultimate adoption of most of efficient type); practice of coordinating breathing with sung sound, pulsated drills, vibrato exercises, vocal initiation (attack), release, vocal phrasing, staccato, legato articulations	Improvement in posture, carriage, less heaving with upper chest & shoulders; perceptions of state of buoyancy based on practice of vocal patterns; elimination of habits of "scooping" to tone; legato phrasing "neat" & definite but not explosive
Establish clear accurate mental control & concepts of tone production in instantaneous coordination of respiration-phonation-resonance (prephonatory tuning).	Utilization of pictures, models, & demonstrations to teach singing with entire body, using axial and appendicular skeleton for lever action, attached voluntary muscles as force generators, ligaments and tendons as loaded springs, trunk as air energizer, larynx as sound oscillator, head & neck as resonator system, & nervous system as prephonatory-conceptualizer-tuner with its peripheral sensory receptor & motor effector mechanisms	Awareness of body as total human musical instrument; conscious control of vocal conduct
Know technical concepts of tone production	Regular practice to initiate & develop open throat; drills, exercises, selection of music for equalized vocal registers, bridging transitions for male & female voices, dynamic controls of 3 gradations of intensity (piano, mezzo forte, forte); agility & flexibility drills	Relaxed tones characterized by fewer breaks in vocal line or scale, richness, carrying power; child experiencing state of buoyancy, not stiff, going easily from one tone to another
Devise and select vocalises fundamental, manageable, practical, & adaptable to every phase of vocal development for designated voice in children	Appropriate vocalization methods for specific vocal problems of individual voices. Supervised practice vocalizing vowel sounds for developing, conditioning, coordinating singing process	Optimum physical power for young voice at given level, persistent attention to good tone production, gratification of vocal growth, interest in further serious vocal study
Promote carryover of vocal-musical controls from structured vocalises to vocal literature providing backbone for teaching musical style & interpretation	Teaching of vocalises as part of songs learned & vocalises created to realize & fulfill music	Agility & articulation speed produced with ease; even and undistorted scales resulting from balanced muscular control & breath pressure
Encourage & guide disciplined regular practice to establish pattern of coordination, the basis of all singing	Learning process achieved in home with direct involvement and guidance of parents who promote positive attitudes toward vocal practice. Length of practice dependent on age differential of child, attention span, stamina, experience, goal or objective to be achieved	Musical achievement, self-reliance; successful singing through period of mutation

## VOCALISES

**Definition and Purposes.** Vocalization in musical terminology is the formation or utterance of vocal sounds. Practice singing exercises using vowel sounds are called vocalises. Vocal objectives are achieved through proper vocalization methods. Vocalizing vowel sounds is a developing, conditioning, and coordinating process. The value of the vocalise is not the exercise per se, but the manner in which it is performed. Of greatest concern is the way the entire vocal mechanism reacts as it responds to the exercises selected. The purpose of any vocalise is to provide feedback. Unless there is continuous sensory awareness, a singer cannot adequately monitor his or her singing performance; without monitoring, the exercise is useless. As musicians become accustomed to the demands of intense concentration, they are able to attend to sensory stimuli for increasingly longer periods of practice.

**Structure.** These exercises are carefully constructed from simple to complex, to help the singers control a given aspect or skill of vocal production which they wish to establish or modify. As they gradually achieve improved control based upon enhanced use of feedback, they are able to maintain improved vocal production in more complex exercises. Then, a vocal control program can be planned through various levels of vocalises to action and song literature. Vocalises are also constructed to develop high degrees of auditory acuity and psychophysical and biomechanical alertness. The vocalises evolve from primary intervals to traditional major and minor scales according to the ability and needs of the singer. Rhythmic execution is of primary importance in establish-

ing the permanence and flow of pulse patterns and durational units. The singer soon gets the idea that the whole body is involved in singing. Flexibility and agility exercises are introduced which enhance the continuity of breath and sung sound and which also serve to divert mechanical stress on vocal mechanisms by establishing deep breathing patterns. The exercises are structured to develop musical hearing ability by intensifying rhythmic and tonal memory.

**Programming.** The vocalises are arranged in a hierarchical setup, starting with basic aspects of tonality and graduating to more complex levels. Musical experience is absorbed first before understanding the related notation of patterns. Vocal skills are not taught in isolation but as part of songs learned. The exercises are created to assist in mastering the music. Thus the singer experiences the end-result toward which the concepts and skills are directed.

## ROLE OF THE PHYSICIAN IN THE MANAGEMENT-TRAINING TEAM

### PLANNING A SYSTEM OF CARE

Supervision of medical care for singing children allows the otorhinolaryngologist to experience some of the romance of practicing the art of scientific medicine, which embraces both hygiene and therapeutics. In the 1980s, the physician has the oppor-

tunity and responsibility to become increasingly involved with health planning for children who sing, in the sense of preventive medicine and health maintenance.

Health preservation means not only that harm is avoided, but that the body is kept in optimal working order. In conceptualizing the human musical instrument, health care for singing children should encompass the broad concept enunciated in 1887 by Sir Morell MacKenzie,<sup>6</sup> that singers are athletes as well as artists, and more daily exercise is required to fit them for their arduous exertions than is required for runners or football players. A vocal artist, from childhood on, must always be in training.

#### INSTRUCTION IN GROWTH AND DEVELOPMENT

Physical growth and development over long periods result in changes in the size and function of the organism which have an effect on voice development. It is often observed that children seem to be bigger than they used to be, which is quite correct. Measurements of boys and girls made in various parts of the world during the past 100 years demonstrate that the average size of children at all ages has increased markedly.<sup>17</sup> Although the increase in adult size accounted for part of the size increase in children, a greater part of the increase in children's size was related to earlier maturation. During the past 50 to 100 years, children in North America, Europe, and parts of Asia, have shown pubertal changes earlier.<sup>17</sup> The trend toward earlier maturation is probably controlled primarily by environmental variables, better nutrition being the most obvious. In the 1980s, children in many areas of the United States are reaching puberty 3 to 5 years sooner than in decades gone by. The average age at which growth stops is also younger. At this time it is unusual for a male to grow more than a few centimeters after reaching 19 years of age. The complex metabolic and physical changes associated with puberty must be recognized by the otorhinolaryngologist and communicated to singers and their families as they relate to voice change and development.

Intellectual growth and development, particularly communicative skills and the ability to handle abstract, symbolic and integrative materials and concepts, are difficult to measure. Based on previous experience with college voice majors,<sup>16</sup> the traditional concept of "voice" as consisting of throat and vocal cords has given way to the larger view of voice as the human musical instrument. The role of the otorhinolaryngologist is to explain to the singer and other laymen the biomechanics of artful sound production. The following information should be transmitted:

1. The act of singing requires a total body biomechanical discipline to produce artful sound, the singer's only product.<sup>18</sup>
2. The human musical instrument includes a

framework: the axial and appendicular skeleton for linkage and lever action, with attached voluntary muscles as force generators; ligaments and tendons functioning as loaded springs for unloading potential energy precisely and with deliberation.

3. With training, the anatomical trunk (chest and abdomen) can be used to provide effective breathing for singing. In effective breathing, the inhalation process is planned and under voluntary control, and the exhalation process is a controlled state of forced exhalation for energizing the human musical instrument.<sup>18</sup>
4. The glottic vibrator-oscillator or the larynx functions as a folding system for generating acoustic waves.<sup>19</sup>
5. The head and neck provide a tubed resonator.
6. The nervous system acts as a prephonatory conceptualizer-tuner, with peripheral sensory receptor and motor effector mechanisms. Thus the musicolinguistic event of singing is instantaneously created and recreated after its prevocalic conceptualization.

Emotional growth and development is an important objective of a hygiene regimen for the singing child and depends on the child's ability to establish supportive bonds with others, to develop the capacity for love and affection, and to handle anxieties arising from the frustration which can accompany singing training, including peer approval and disapproval.<sup>15</sup> Learning is an essential component of acculturation. If a pattern of behavior is consistently associated with pleasant circumstances in the singing training environment, a positive pattern is likely to emerge, even though aspects of the student's life or home environment may be unpleasant. The physician may explain the principles of behavior modification and shaping<sup>20</sup> to parents and other family members and encourage application of behavioral techniques to the training regimen of singing children.

#### HEAD AND NECK EVALUATION

The usual history and medical record is established for each child prior to a more individualized evaluation. Four types of people participate in the initial "interview": subject, parents, office nurse (witness), and physician. Parents are advised that the singing teacher has referred the child for medical evaluation as a human musical instrument. The physician's role is to evaluate the health of the child, provide therapy if needed, and encourage hygienic practices aimed at health maintenance.

Every effort is made to gain the confidence and cooperation of singers and their families. The concept of voice mutation is carefully explained, and the role of the physician is outlined as an integral part of the management-training team whose primary objective is to successfully bring the child singer through the mutational process.



TABLE 4. ST LANDRY CATHOLIC CHURCH BOYS' CHOIR, FEBRUARY 1983

Boy	Age (yr)	Time Singing/ Training	Voice Class	Frequency Range*	Comment on Range
1	10	1 yr	High soprano, tenor	g to D <sup>3</sup>	Unusual; more than 2 octaves
2	13	3 yr	Soprano	a to C <sup>3</sup>	Unusual; more than 2 octaves
3	13	5 yr	Soprano	g to B <sup>2</sup>	Unusual; more than 2 octaves
4	9	7 mo	Soprano	a to C <sup>3</sup>	Unusual; more than 2 octaves
5	15	2 yr	Soprano, almost baritone	c to B <sup>2</sup>	Unusual; more than 2 octaves
6	13	3 mo	Soprano	b <sup>6</sup> to B <sup>2</sup>	2 octaves
7	9	5 mo	Soprano	g to G <sup>2</sup>	2 octaves
8	7	3 mo	Soprano	a to A <sup>2</sup>	2 octaves
9	11	4 mo	Soprano	a to A <sup>2</sup>	2 octaves
10	11	2 mo	Soprano	a to A <sup>2</sup>	2 octaves
11	11	3 mo	Soprano	g to G <sup>2</sup>	2 octaves
12	16	3 yr	Mutational voice	d to D <sup>2</sup>	2 octaves
13	13	5 yr	Mutational voice	f to D <sup>2</sup>	Less than 2 octaves
14	9	7 mo	Early age mutation	g to D <sup>2</sup>	1½ octaves
15	13	1 yr	Mutational voice	f to D <sup>2</sup>	Less than 2 octaves
16	10	1 yr	Mutational voice	a to F <sup>2</sup>	Less than 2 octaves
17	13	6 yr	Mutational voice	d to G <sup>2</sup>	Less than 2 octaves
18	11	3 yr	Mutational voice	a to a <sup>1</sup>	1 octave
19	16	6 yr	Bass baritone	D to G <sup>2</sup>	Changed voice (early adult voice)

\*Lowest and highest tones singer is able to produce. Superscripts refer to number of times note is encountered moving up keyboard from lower limit of range.

Since the head and neck examination in this context is a teaching as well as diagnostic tool, it should be conducted with the following instructional goals in mind.

**Laryngeal Examination.**<sup>21</sup> In this context of management of the mutational voice, the art of medical practice can embellish the science. Some ceremony should accompany the laryngeal examination, which is performed with a short focal length head mirror and a 100- to 150-W unfrosted light bulb for a reflected light source. The physician should relate some of the history of the laryngeal mirror, particularly its invention by a singing teacher, Manuel Garcia, who first described the appearance of the larynx in 1855. The child should understand that the mirror image is reflected, reversed, and illusionary as compared to the direct laryngoscopic view. Diagrams and photographs of the *normal larynx* should be explained. Mirror laryngoscopy without local anesthesia is usually accomplished without side effects, although minimal irritability of the mouth and pharynx may result. During this examination, the physician stresses that the throat and larynx are but components of the whole body system for singing. The concepts of biomechanics of singing are introduced (Astrakillo et al, unpublished observations).

**Physiologic Occlusion.**<sup>22</sup> In the developing and mutational singing child, effort to achieve tonal focus, optimum pitch, and resonance may cause damage. The physician, the dentist (general practitioner), and the singing teacher need to recognize occlusion in the child as both friend and foe to singing, especially during mixed dentition stages. Occlusion should be explained in terms appropriate to the child as a system which includes the teeth and the supporting soft tissues, the temporomandibular

joints and attached ligaments which limit movement, the masticatory musculature, and the jaws (maxilla and mandible). These structures are involved in singing pathology such as "tight immobile jaw" and a moving jaw that "chews" every vowel.

Oral health and hygiene is presented to the child as a system of gnathostomatics,<sup>23</sup> or the maintainability of the teeth and their supporting structures in harmony with the muscles, bones, joints and ligaments of the mouth and jaws. It is important to emphasize that a disturbance of one part throws the entire system out of balance. Orthodontic movement of teeth by various appliances may create or exacerbate occlusal disharmony, temporarily creating actual and/or potential aberrations in the singing child. The otorhinolaryngologist and the singing teacher need to be alert to occlusal stress as one of the most important factors in mutational singing pathology and must work closely with the dentist(s) providing care during these years. It is important that the physician who deals with singers have a thorough grounding in occlusal dentistry and in orthodontics.

## RESULTS

**Vocal Skills.** Videotape recordings of the subjects performing vocalises, folk songs, art songs, or opera arias demonstrated vocal skills of high ability (virtuosity) and advancement in relatively short periods of time (a minimum of 6 months to 1 year). Although the rate of progress varied from child to child, there were no significant differences in achievement related to socioeconomic conditions.

**Breathing for Singing.** The following breathing skills for children aged 1 to 17 were achieved:

1. Production of artistic vocal qualities which satisfy the basic requirements of breathing in

the act of singing: initiating, supporting, and sustaining vocal tone.

2. Capability of singing smooth and long phrases (all aged from 7 to 15 years).
3. Ability to sing rapid and florid passages and difficult intervals.

*Phonation-Registration-Resonation.* The singing voices of boys and girls in this study were indistinguishable until the time of voice change in adolescence, as reported in other studies.<sup>24,25</sup>

"Breaking" of the voice was not observed in any of the children in this study; they experienced no range difficulties to cause voice breaks.

The musical voice range for girls (aged 7 to 17 years) and unchanged boys' voices (aged 7 to 13 years) was middle C to high C, two octaves above (C<sup>1</sup> to C<sup>3</sup>) and identical for each sex.

The voices of five boys (aged 9 to 15) showed exceptional ranges of more than two octaves (Table 4). The voices of six boys (aged 7 to 13) demonstrated a range of two octaves, which is also unusual. Six boys with mutational voices (aged 9 to 16) demonstrated 1½-octave ranges, which is unusual for changing voices. None of the last group displayed breaks in either singing or conversational voices.

Two boys (aged 10 and 15) displayed two voices; each boy had a range of more than two octaves and could sing in either the soprano or changed-voice category. They were encouraged to maintain these abilities until their singing voices settled into adult male ranges.

*Creativity.* Subjects exhibited sufficient control over the voice to carry melodic and rhythmic-phrases independent of piano accompaniment, usually a skill required as adults. In general, the more gifted the child, the more rapid was his or her progress.

*Physician Participation.* Both students and

parents readily accepted physician-direction as an integral part of the singing training program.

## DISCUSSION

This 7-year study did not include measurements of body changes during puberty, although the developing singing voice may be affected by changes in the larynx, trunk, and hearing and nasal structures.<sup>26-30</sup> The primary thrust of this work was to determine whether the period of voice mutation could be successfully bridged by a training program which would enable continued development of the voice as a human musical instrument (and the individual as a musician) without damage to changing structures.

In this endeavor, the author and his collaborators attempted *to cause a vocal event*, and not to describe how it came to pass. Singing is defined as a sense and motion experience that demands instantaneous creation and recreation as a musical-linguistic event which must be first conceived, then understood, and finally communicated to a listener.<sup>31</sup>

Results of this technique of voice training may be analyzed subjectively by trained and experienced listeners, since voice quality is best perceived by the human ear. However, it must be stated that the evaluation may be more meaningful when subjective auditory perception is combined with an objective qualitative/quantitative instrumental analysis such as long-time, average spectrum analysis.<sup>32</sup>

## SUMMARY

Voice mutation is a natural process of maturation which can safely occur along with ongoing development of singing skills and musicianship. The training program described is aimed at continuing musical achievement while reducing the risk of damage to the adult voice during the period of physiological change. The otorhinolaryngologist's role as educator and evaluator is integral to the mutational voice training program.

ACKNOWLEDGMENTS — This study was done with the collaborative efforts of Corbelita J. Astraquillo, MusD, Associate Professor, School of Music, Louisiana State University, Baton Rouge; and Dwight M. Hebert, Choir Director, St Landry Catholic Church, Opelousas, Louisiana.

## REFERENCES

1. Grout DJ. A history of western music. New York: WW Norton Co, 1960.
2. Weiss DA. The pubertal change of the human voice. *Folia Phoniatri* (Basel) 1950; 2:126-51.
3. Brodnitz FS. The age of the castrato voice. *J Speech Hear Disord* 1975; 40:291-5.
4. May HG, Metzger BM. The Holy Bible: the new Oxford annotated Bible. 2nd ed. New York: Oxford University Press 1971:1394.
5. Garcia M. Hints on singing. Garcia B, trans. New York: Shuberth Co, 1894:8.
6. MacKenzie M. The hygiene of the vocal organs: a practical handbook for singers and speakers. London: MacMillan Co, 1887.
7. Dawson JJ. The voice of the boy. New York: Kellogg, 1902.
8. Ingram MD, Rice WC. Vocal technique for children and youth. Nashville: Abington Press, 1962.
9. Jersild AT, Bienstock SF. The influence of training on the vocal ability of three-year-old children. *Child Dev* 1931; 2:272-91.
10. Jersild AT, Bienstock SF. A study of the development of children's ability to sing. *J Educ Psychol* 1934; 25:481-503.
11. Olson G. Intersensory and intrasensory transfer of melodic contour perception by children. *J Res Music Educ* 1978; 26:41-7.
12. Gilbert J. An assessment of motor music skill development in young children. *J Res Music Educ* 1980; 28:167-75.



13. VanOordt HWA, Drost HA. Development of the frequency range of the voice of children. *Folia Phoniatri* (Basel) 1963; 15:289-98.
14. Lehr J, Brown J. The influence of peer imitation on expressive movement to music. *J Res Music Educ* 1979; 27:143-8.
15. Hanser SB. The effect of peer approval and disapproval on improvement of pitch matching and group behavior. *J Res Music Educ* 1982; 30:221-8.
16. Astraquillo CJ, Blatt IM, Happel L, Martinez R. Investigation of the relationship between abdominal muscular discipline and the act of singing: an electromyographic study. *Trans Am Acad Ophthalmol Otolaryngol* 1977; 84:498-519.
17. Tanner JM. Earlier maturation in man. *Sci Am* 1968; 218:21-7.
18. Appelman DR. The science of vocal pedagogy. Bloomington: Indiana University Press, 1975.
19. Fink BR. The human larynx: a functional study. New York: Raven Press, 1975.
20. Surratt PR, Ulrich RE, Hawkins RP. An elementary student as a behavioral engineer. *J Appl Behav Anal* 1969; 2:85-92.
21. Gleason EB. A manual of diseases of the nose, throat and ear. 4th ed. Philadelphia: WB Saunders, 1920:20-6.
22. Ramfjord SP, Ash MM Jr. Occlusion. Philadelphia: WB Saunders, 1966.
23. Dawson PE. Evaluation, diagnosis and treatment of occlusal problems. St. Louis: CV Mosby, 1974:11-5.
24. Wassum S. Elementary school children's range. *J Res Music Educ* 1979; 27:214-26.
25. Wassum S. Elementary school children's concept of tonality. *J Res Music Educ* 1980; 28:18-33.
26. Greene JS. Atypical laryngeal and vocal changes in adolescence. *JAMA* 1942; 120:1193-7.
27. Curry ET. Voice changes in male adolescents. *Laryngoscope* 1946; 56:795-805.
28. Fairbanks G, Herbert EL, Hammond J. An acoustical study of vocal pitch in seven and eight year old girls. *Child Dev* 1949; 20:71-7.
29. Fairbanks G, Wiley JH, Lassman FM. An acoustical study of vocal pitch in seven and eight year old boys. *Child Dev* 1949; 20:63-9.
30. Kuersteiner KO, Cooper I. Teaching junior high school music. 2nd ed. Conway, Arkansas: Cambiata Press, 1973.
31. Appelman DR. Bulletin interviews. *The National Association of Teachers of Singing Bulletin* 1981; 37:4-6.
32. Wedin S, Leanderson R, Wedin L. Evaluation of voice training: spectral analysis compared with listeners' judgements. *Folia Phoniatri* (Basel) 1978; 30:103-12.

# LARYNGEAL NERVE CRUSH FOR SPASTIC DYSPHONIA

HUGH F. BILLER, MD

MAX L. SOM, MD

WILLIAM LAWSON, MD, DDS

NEW YORK, NEW YORK

Twenty-two patients with a diagnosis of spastic dysphonia were treated by laryngeal nerve crush. All patients had initial improvement. Success at 3-year follow-up was 13%. Laryngeal nerve crush is no longer advocated as treatment for spastic dysphonia.

In 1979 the authors reported the crushing of the recurrent laryngeal nerve in the treatment of spastic dysphonia.<sup>1</sup> In this pilot study three of the four patients so managed had complete elimination of vocal spasticity. It was proposed that laryngeal nerve crush offered the advantage over nerve section of not permanently paralyzing the vocal cord. The purpose of this paper is to present the results of nerve crush in a larger series of patients.

## MATERIAL AND METHOD

Twenty-two patients with the clinical diagnosis of spastic dysphonia were treated by crushing the left recurrent laryngeal nerve. All patients had received prior speech therapy. The injection of lidocaine to assess vocal improvement, preliminary to surgery, was performed only in the original four patients. Voice recordings were obtained prior to surgery.

The operative procedure was performed under general anesthesia, with the left recurrent laryngeal nerve isolated inferior to the thyroid gland and crushed with a hemostat.

## RESULTS

There were no complications related to the surgery. The left vocal cord was initially paralyzed in all patients. Complete resolution of the vocal spasticity occurred immediately in all cases. Some patients had a slightly breathy or husky voice which subsided in 1 to 2 weeks. In some patients abnormal

breathing patterns were present which resolved after one or two sessions of speech therapy.

Postoperatively, there was a return of vocal cord motion in all patients after 3 to 6 months. In 19 of the 22 patients, spasticity returned concurrent with the return of vocal cord motion or 3 to 4 months later. Although the degree of spasticity was diminished in 12 patients, the majority were dissatisfied with the operative result. Four patients subsequently underwent section of the recurrent laryngeal nerve. Two of these patients had a successful result and two patients developed recurrent spasticity within 12 months of surgery.

## DISCUSSION

As with many preliminary reports, initial success with a small sample of cases may not be maintained when a larger data base is analyzed. This has been the situation with laryngeal nerve crush. The conclusion of the authors' pilot study presented in 1979 has not been substantiated on long-term follow-up of a larger series of cases. Of the original four patients treated, two have remained free of spasticity. However, in only one of the following 18 cases has spasticity been eliminated.

The 13% success rate achieved with nerve crush does not compare to the 85% to 90% success rate reported by Dedo.<sup>2</sup> In view of the poor results with nerve crush, the authors now recommend nerve section as the preferred treatment for spastic dysphonia.

## REFERENCES

1. Biller HF, Som ML, Lawson W. Laryngeal nerve crush for spastic dysphonia. *Ann Otol Rhinol Laryngol* 1979; 88:531-2.

2. Dedo HH, Izdebski K. Intermediate results of 306 recurrent laryngeal nerve sections for spastic dysphonia. *Laryngoscope* 1983; 93:9-15.

From the Department of Otolaryngology, The Mount Sinai Medical Center, New York.

Presented at the meeting of the American Laryngological Association, New Orleans, April 10-11, 1983.

REPRINTS — Hugh F. Biller, MD, Department of Otolaryngology, Mount Sinai Medical Center, 100th St & Fifth Ave, New York, NY 10029.



## THE MEMORABLE LIFE OF HOSMER A. JOHNSON, EARLY MIDWESTERN LARYNGOLOGIST

STANTON A. FRIEDBERG, MD


CHICAGO, ILLINOIS

Hosmer A. Johnson, one of the early laryngologists in the Midwest, graduated in 1852 from Rush Medical College, and was the first intern in Chicago. With four other faculty members he left Rush in 1859 to establish what subsequently became the Northwestern University Medical School. He taught many subjects and was extremely active in local and national societies. An interest in diseases of the chest led him into laryngology and he became a charter member of the American Laryngological Association, where he reported on congenital tumors of the larynx, laryngeal paralysis, and cancer of the larynx. Dr Johnson was a master of six or seven foreign languages, a versatile civic leader, a talented orator, and was greatly admired for his medical skills. The breadth of his accomplishments and character made for a truly memorable life.

Hosmer Allen Johnson was one of the pioneers of the specialty of laryngology in the Midwest. He was born near Buffalo in 1822 and his family moved to Michigan when he was 12 years of age. He was instructed by his mother, worked on the family farm, and received a teacher's certificate at the age of 18. Hosmer taught school in the winter and attended a local academy in the summer. During this time he acquired a bronchial disability which was to plague him for the remainder of his life. His attendance at the University of Michigan was interrupted by illness, but he finally graduated in 1849 at the age of 27. He moved to Chicago that year and began the study of medicine with William B. Herrick, an early Rush faculty member. Entering Rush in the fall of 1850, he continued to teach school in order to support himself, and he graduated at the head of his class at Rush in 1852. In the same year he received an MA degree from the University of Michigan, having written his thesis in Latin. Dr Johnson became the first intern in Chicago, serving at the newly named Mercy Hospital, successor to the "Lake House" on Rush and North Water streets.<sup>1</sup>

Immediately upon finishing his internship, Dr Johnson became an active member of the Rush faculty, the Illinois State Medical Society, and the American Medical Association.<sup>2(p112)</sup> While a member of the Rush faculty, he served successively as lecturer in physiology, materia medica, therapeutics, and medical jurisprudence. He was interested in the legalization of anatomical dissection and also sought legislative action to enforce registration of births, marriages, and deaths.<sup>2(p116)</sup> He was a major contributor to the medical journals of the times.

During the 1850s a dispute over curriculum requirements and teaching methods between Drs Nathan Davis and Daniel Brainard led to the resignations of Drs Davis, Johnson, John Hollister, and



Hosmer A. Johnson, MD, LLD

William Byford, and the founding of a rival school known as the Medical Department of Lind University. Dr Johnson was elected president of the new faculty and the affiliation with Lind lasted until 1864. At that time negotiation for a union with the old University of Chicago began but nothing materialized. When Lind University lost its financial support in 1864, the Chicago Medical School was incorporated, and Dr Davis became president of the faculty. At the time of Dr Brainard's death from

From the Department of Otolaryngology and Bronchoesophagology, Rush-Presbyterian-St Luke's Medical Center, Chicago.

Presented at the meeting of the American Laryngological Association, New Orleans, April 10-11, 1983.

REPRINTS — Stanton A. Friedberg, MD, Rush-Presbyterian-St Luke's Medical Center, Chicago, IL 60612.

cholera in 1866, Dr Davis explored the possibility of a merger between the Chicago Medical College and Rush. One of the supporters of the proposal was Dr Ephraim Ingals of Rush, but again a compromise proposal came to naught. An affiliation between the Chicago Medical College and Northwestern University was established in 1870, and for the next 20 years there existed the "Chicago Medical College, the Medical Department of Northwestern University." Dr Johnson was a trustee and loyal faculty member during his remaining years. He was awarded an LLD degree by Northwestern University in 1883.<sup>3(pp14-75)</sup>

Dr Johnson served as president of the board of examining surgeons during the Civil War, was a member of the Chicago Board of Health, and played a leading role in the Relief and Aid Society following the great Chicago fire of 1871. At different times he held chairs of materia medica and therapeutics, physiology and histology, general pathology and pathologic anatomy, diseases of the chest, diseases of the respiratory and circulatory organs, clinical medicine, and the principles and practice of medicine.<sup>3(p425)</sup> During these years he was active in the legislative arena and is credited with being the single most influential individual in securing passage of the Anatomy Act which legalized anatomical dissection.

In 1875 Dr Johnson reported on 283 cases of phthisis, and one might surmise that his developing interest in chest diseases resulted not only from his own experience with pulmonary problems but the need to limit his practice. Prior to this time Dr Johnson had also practiced general surgery. He soon became involved in diseases of the chest, nose, and throat, and continued to maintain a general practice as well. As a consultant on diseases of the throat and lungs, he was regarded as one of the leading authorities in the Northwest, as well as in the country. Most laryngologists in those days were originally chest physicians. He became a founding member of the American Laryngological Association in 1879 and contributed several significant papers thereafter.

In 1883, at the Fifth Annual Meeting of The American Laryngological Association in New York, Dr Johnson reported on five cases of congenital tumors of the larynx. All of the children involved had been hoarse since birth. One had a solitary papillomatous lesion which was expelled during whooping cough. The other four died at various intervals following tracheotomy or thyrotomy. All had multiple papillomas.<sup>4</sup>

"Paralysis of the Larynx: With Reports of Thirty-Two Cases"<sup>5</sup> formed the basis of a presentation in Detroit in 1885. Prominent in this collection were

instances of hysterical aphonia. One such patient was cured by prayer, another by faradic current stimulation, and a third recovered following a runaway accident and a fall from a wagon. Also described were examples of vocal cord paralysis following typhoid fever, as well as some with central nervous system lesions and syphilis. The author reports on the difficulty in assessing ankylosis of the cricoarytenoid joint. Reference is made to recurrent laryngeal nerve involvement with aneurysm, mediastinal lymphadenopathy, external trauma, and viral infections.<sup>5</sup> Incidentally, the Transactions in which this article appears contains a listing of the library of the American Laryngological Association by Thomas French, librarian,<sup>6</sup> consisting of 34 bound volumes and 503 pamphlets on laryngology.

Dr Johnson was elected First Vice-President of The American Laryngological Association in 1886. His 1887 paper, "Cancer of the Larynx,"<sup>7</sup> described the paucity of previous literature on the subject. In three of the five reported cases, tracheotomy was performed with prolongation of life varying from 3 to 8 months.

The breadth of interest of men like Dr Johnson is illustrated by his role as a founding member of the Association of American Physicians in 1886, as a charter member and president of the Chicago Academy of Sciences, as president of the Chicago Astronomical Society, the Illinois Microscopical Society, the Chicago Literary Club, the American Public Health Association, and the Chicago Historical Society. One wonders where he found time for so many diverse activities.

Dr Johnson was familiar with six or seven foreign languages and was a master of English. His oratorical skill was legendary. He was devoted to outdoor life and travel, both of which seemed to afford some relief from his persistent chest problems. Frank Seward Johnson, his son, studied medicine and was dean of Northwestern University Medical School from 1898 to 1901.

Upon his death in 1891, just short of age 70, Dr Johnson received memorable tributes. Among the eulogies is the following:

As an orator, lecturer and teacher, he was clear and direct in expression: chaste, elegant and often eloquent in style; and always commanded the earnest attention of his hearers. As a physician, he was clear-handed, kind-hearted, faithful to every duty and skillful — enjoying the implicit confidence of his patrons. As a citizen he was patriotic, benevolent, honorable and ever ready to lend efficient aid in promoting the varied interests of civilized society.<sup>3(p427)</sup>

Another tribute reads: "Dr Johnson was much more than simply an eminent physician. He was a magnificent man, possessing a clear, trenchant intellect and a great, noble heart." His was truly a life to remember.



## REFERENCES

1. Chicago Medical Society. History of medicine and surgery and physicians and surgeons of Chicago. Chicago: Biographical Publishing Corp, 1922:63-4.
2. Davis DJ. History of medicine and surgery in Chicago, Vol 2, 1850-1900. Chicago: Illinois State Medical Society, 1955:112, 116.
3. Arey LB. Northwestern University Medical School, 1859-1959. Chicago: Northwestern University, 1979:14-75, 425, 427.
4. Johnson HA. Reports of five cases of congenital tumors of the larynx. Trans Am Laryngol Assn 1883; 68-75.
5. Johnson HA. Paralysis of the larynx; with reports of thirty-two cases. Trans Am Laryngol Assn 1885; 80-92.
6. French TR. Catalogue of the library of the American Laryngological Association. Trans Am Laryngol Assn 1885:167-83.
7. Johnson HA. Cancer of the larynx. Trans Am Laryngol Assn 1887; 191-5.

# TEFLON INJECTION OF THE VOCAL CORD: COMPLICATIONS, ERRORS, AND PRECAUTIONS

ROBERT B. LEWY, MD

CHICAGO, ILLINOIS

An effort is made to summarize errors and complications in Teflon vocal cord surgery. This represents accumulated experience from 240 cases. Concentrated advice and precautions are given to improve results and expectations of the surgery.

In reflecting on problems of vocal cord injection, it should be noted that the concept of an apparently simple operation with a high success rate can be deceptive. The failure rate, partial and/or complete, is usually higher with the occasional operator. It is hoped that the failure rate may be reduced with increased awareness of the clinical knowledge gained from a large series of cases.

No effort will be made here to describe the already well-established techniques for the procedure.<sup>1-3</sup> Since Arnold's<sup>1</sup> earliest reports in this country, medical literature is replete with this type of information. This report will deal with complications, errors, common problems, and solutions that will prevent or solve immediate difficulties. In addition, it will give a "fall back" position.

The most dangerous complication is respiratory obstruction. This is unusual but can occur immediately or as late as the fourth day. Postoperative safety is improved by steroid medication at the end of the procedure and for three days thereafter. Hospitalization is mandatory for protection against respiratory obstruction, and precautions against obstruction should include preparation for intubation and tracheotomy.

The most common "complication" is failure to achieve the desired results, and this occurs in about 10% of the cases. Its avoidance requires precision. Half of the failures will improve with an appropriately placed second injection at some later date after all local edema from the original procedure has disappeared. This is more likely to occur if the vocal cords are at different levels due to a forward pitch of the arytenoid pylon.

Errors in judgment contribute to complications and failures. Overinjection of the vocal cord can result when the desired voice change is not achieved. This occurs in some cases because injection of the posterior one third of the vocal cord simply does not work. Accidental injection into the false vocal cord is another important cause of failure or obstruction.

Injection into scar tissue only occasionally yields a satisfactory result.

There are several problems which the surgeon must solve to obtain a good result. 1) Hypertrophy of the false cord may obstruct access to the true vocal cord. Needle-pressure abduction of the plica or suction-tip abduction may bring the vocal fold into view. The very narrow atrophic cord is hard to reach and difficult to inject; lateral external pressure may help. 2) Usually, but not always, easiest access to the larynx is accomplished with the vertex of the head on the operating table. The patient's upside-down face faces the surgeon. If laryngeal access proves difficult, the head may be raised to approximate the Boyce position — neck flexed, head extended. This can be done with pillows. An under-the-shoulder roll is used for support and lift.

In addition to problems with exposure, instrumentation difficulties need the surgeon's attention. Precise injection requires a stabilized laryngoscope. Several good laryngoscope-holding systems are available. The best choice is a matter of personal preference and experience. The Bruning pistol-grip syringe has the disadvantages of requiring refilling and of breaking easily. A screw-type syringe requires two hands for effective use. If the laryngoscope is well stabilized this is not a problem. The standard leverage gear-holder is used most commonly. Strong's system, with a projected, lengthened laryngoscope handle plus suspension, and the Wolf gear-system are quite satisfactory. The Killian suspension is not advisable because it requires general anesthesia.

The laryngoscope should be inserted with the holder attached. It was deliberately designed for construction with hollow stainless steel and an anodized aluminum hub for lightness and strength to make this insertion possible. Always have a long narrow laryngoscope available on the instrument service table to fall back on if necessary. This usual-

Dr. Lewy is Clinical Professor Emeritus of Otolaryngology, University of Illinois, College of Medicine and Surgery, Pritzker School of Medicine, University of Chicago.

Presented at the meeting of the American Laryngological Association, New Orleans, April 10-11, 1983.

REPRINTS — Robert B. Lewy, MD, 25 East Washington St, Suite 1910, Chicago, IL 60602.



ly provides access when larger diameter instruments fail. Needles wear out; they may be bent out of shape, obstructed, or lose the upper or lower edge of the hub. It is best to check them personally prior to a procedure. The rarity of the procedure and the frequent change of nursing personnel make this desirable. Always have a second needle immediately available.

The surgeon must also face the problem of deciding how much Teflon to inject. Local anesthesia

with intravenous Innovar is desirable because it allows the patient to phonate on command. Changes in the cord size, position, and relationships are observed, and voice tone is monitored. Voice quality improvement during the procedure is an important and reliable guide and protects against excess injection.

It is hoped that these observations, representing accumulated experience from 240 cases, will aid the occasional operator and be of help to other clinicians.

#### REFERENCES

1. Arnold GE. Vocal rehabilitation of paralytic dysphonia. IX. Technique of intracordal injection. *Arch Otolaryngol* 1962; 76:358-68.
2. Lewy RB. Glottic reformation with voice rehabilitation in vocal cord paralysis. *Laryngoscope* 1963; 5:547-55.
3. Lewy RB. Experience with vocal cord injection. *Ann Otol Rhinol Laryngol* 1976; 85:440-50.

# EARLY EXPERIENCES WITH VOCAL LIGAMENT TIGHTENING

FRANCIS E. LEJEUNE, MD

CHARLES E. GUICE, MD

PAULA M. SAMUELS, MA

NEW ORLEANS, LOUISIANA

Loss of tension of the thyroarytenoid ligament is seen in elderly patients, in patients with chronic voice strain, and in patients who have had intubation trauma or laryngeal crush trauma. A tightening of the ligament by mobilizing a midline strip of the thyroid cartilage and advancing the upper end of this strip is described. The early results are encouraging; long-term results in older patients are not really known at this time.

## INTRODUCTION

Gradual loss of elasticity of the thyroarytenoid ligament causes imperfect approximation of the true vocal cords. There is loss of volume, increased breathiness, and loss of breath support. The rapid fatigue of the voice may simulate myasthenia. A bowing of the vocal cords may be obvious on indirect laryngoscopy. If the individual is a vigorous voice user, the true vocal cords may also show signs of voice strain, such as formation of polyps or nodules. An extensive Reinke's edema may be present, and may actually mask the underlying relaxation of the vocal ligament. In such a case, surgical removal of the polypoid tissue, even though performed meticulously, may result in an immediate worsening of the voice quality. Such cases may be interpreted as postoperative dysphonias,<sup>1</sup> and the patients may be quite difficult to manage because of their refractory nature and general hostility.

In the less vigorous speaker, the secondary signs of voice strain may be absent, but the bowing of the cords on phonation is more obvious. Progressive weakness of the voices of professional or supervisory workers may reduce their effectiveness and cause them to seek early retirement.

Other medical problems such as emphysema, strokes, and prolonged intubation, may exaggerate the voice weakness. The acute stretching of the ligament will usually improve with voice rest alone. Chronic stretching of the ligament due to loss of elastic fibers associated with aging and voice strain usually will not respond to many weeks or months of voice rest with or without speech therapy. More infrequently, a crush injury to the larynx occurs and causes a reduction in the anteroposterior diameter. This causes a relaxation of the vocal ligament and may reduce the voice to total aphonia.

In all of the above, the common problem is a loss of tension or tone of the thyroarytenoid ligament.

In order to correct this, a procedure was selected that is relatively noninvasive and would not be likely to cause a worsening of voice quality.

## CASE REPORTS

Six patients were selected because of breathy voice, bowing of vocal cords, and failure to improve following surgical and/or conservative therapy.

*Case 1.* A 62-year-old housewife was unable to attend night functions with her philanthropic husband because by night she could only speak in a whisper. Two trials of Teflon paste injection into the vocal cords had failed to improve her voice. On Sept 18, 1974, a vocal ligament tightening procedure was performed, and following this her phonation improved. However, she still rejected attendance at fund-raising dinners. She is considered the least successful case.

*Case 2.* A 24-year-old college student had fallen down a flight of stairs, crushing his larynx against a bannister, and producing a shortening of the anteroposterior diameter. A vocal ligament tightening procedure on July 8, 1975, improved his voice quality from a whisper so that he was able to speak to an audience of 300 persons without using amplification.

*Case 3.* A 42-year-old electronics technician noted hoarseness since early childhood; bowing of the true vocal cords had been observed. On Dec 7, 1976, a vocal ligament tightening was performed. The voice improved in quality but still lacked good tone.

*Case 4.* A 57-year-old personnel supervisor of a large restaurant had progressive hoarseness with the formation of large polyps on each vocal cord. After a careful excision of the polyps by an otolaryngologist, her voice quality was worse; she had less volume and more breathiness. One year of intermittent voice rest, speech therapy, steroid therapy, and psychotherapy failed to achieve any improvement. Vocal ligament tightening was performed on Sept 18, 1982, and 3 weeks later she was able to return to her demanding supervisory position with effective voice.

*Case 5.* A 59-year-old construction supervisor had noted progressive loss of volume for several years. Vocal ligament tightening was performed on Sept 7, 1982, but on his 3-week postoperative visit, his voice quality lacked volume, though it was less breathy. He had returned to work after 1 week and had strained his voice. Three more weeks of voice rest achieved some improvement in quality, but ideal quality was not attained.

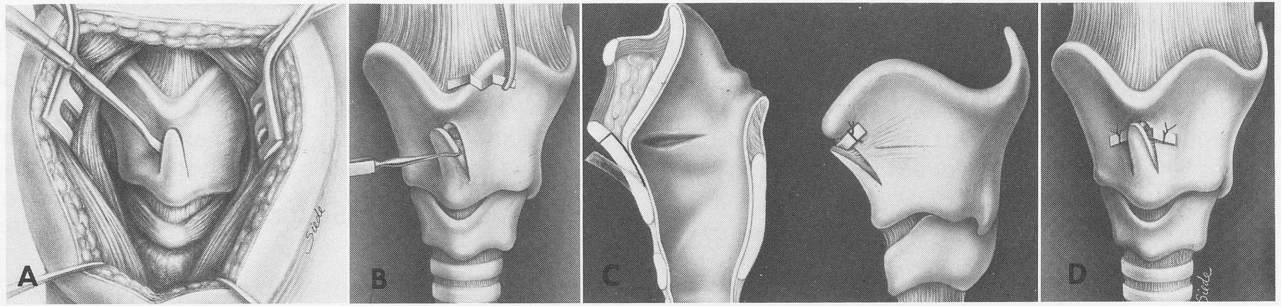
*Case 6.* A 52-year-old housewife had a 10-year history of progressive weakness of voice. A polyp or nodule had been removed 9 years earlier, and 2 years later Teflon paste had been injected into her left vocal cord to correct a concave defect. A weak, breathy

From the Department of Otolaryngology (LeJeune, Guice), and the Division of Communicative Disorders (Samuels), Ochsner Clinic and Alton Ochsner Medical Foundation, New Orleans.

Presented at the meeting of the American Laryngological Association, New Orleans, April 10-11, 1983.

REPRINTS — Francis E. LeJeune, Ochsner Clinic, 1514 Jefferson Highway, New Orleans, LA 70121.





Tightening of thyroarytenoid ligament. A) Midline strip of cartilage is created by nearly parallel incisions which meet near upper end of thyroid cartilage. Inner periosteum remains intact anteriorly but is elevated laterally for several millimeters from inner surface of thyroid alae. B) Springboard is elevated by careful traction with small hook to receive metal strip. Broyle's ligament is preserved as anterior commissure is advanced. True vocal cord is thus stretched approximately 2 mm. C) Cut-away view approximately 3 mm to left of midline shows effect of advancing anterior commissure. True vocal cord is stretched. D) Tantalum metal strip is placed beneath upper end of cartilage strip to preserve tension on vocal cord. Absorbable sutures secure metal strip to periosteum of thyroid ala.

voice had persisted. A vocal ligament tightening was performed on Jan 14, 1983, and 3 weeks later a definite improvement in voice quality was evident, but maximum improvement had not been attained.

### PROCEDURE

A horizontal skin incision is made in the neck in a natural skin crease near the thyroid prominence. The thyroid cartilage is exposed. Tightening of the thyroarytenoid ligament is accomplished by advancement of the anterior commissure of the glottis. A midline strip of thyroid cartilage is formed by carefully making two vertical incisions, one on either side of the midline. These incisions are almost parallel, but curve medially to meet near the upper border of the thyroid ala. The incisions are made approximately 3 mm on either side of the midline and extend to within 3 mm of the inferior border of the thyroid cartilage. The incisions are made through the outer perichondrium, through the thyroid cartilage, which may be ossified, but not through the inner perichondrium (Fig. A). The lumen of the larynx is never entered. By use of a small elevator, the inner perichondrium is elevated from the ala on the lateral side of the incision for 3 mm or 4 mm. No attempt is made to elevate medial to the incision in order to preserve the dense insertion of ligament fibers into the cartilage known as Broyle's ligament.

The "springboard" strip of cartilage thus created is attached and is stable inferiorly, but mobile superiorly. The upper end of the strip is then lifted approximately 3 mm above the surface of the thyroid cartilage (Fig. B). A strip of tantalum metal, approximately 2 mm wide, is inserted beneath the elevated tip to stabilize its position relative to the main body of the thyroid cartilage (Fig. C).

By this maneuver, the anterior attachment of the vocal ligament, located about one third of the distance down from the superior end of the cartilage strip in females and halfway in males,<sup>2</sup> is advanced approximately 2 mm. This distance is about 10% of the anatomical length of the vocal ligament. In the

male, the length of the ligament ranges from 1.8 cm to 2.4 cm. In the female, the range is 1.5 cm to 2 cm.

The sound-producing element of the vocal cord is thus tightened in a manner similar to the tightening of a guitar string. Instrumentation to determine the exact degree of tension is still in the developmental stage at this time. A visual inspection of the glottis is made immediately before and after tensing the ligament. With a small-sized endotracheal tube in place (6-mm or 7-mm diameter), the cords can be readily inspected with a laryngoscope. As an assistant puts tension on the cartilage strip, visible straightening of the free-edge of the cords can be seen. Placing too great a tension on the strip could result in avulsion of the ligament so that the surgeon makes a prudent judgment and avoids using excessive force. The lumen of the larynx is never actually entered, as all manipulation is carried out submucosally; contamination of the operative field with laryngeal secretions is thus avoided. After the metal strip is positioned beneath the cartilage springboard, the lateral extensions of the metal are bent downward to lie smoothly against the sloping contours of the thyroid ala and are secured there by absorbable sutures passed through the perichondrium (Fig. D). A small rubber drain is led out from the wound as soft tissues are closed over the larynx. Antibiotic coverage is advisable. In most cases, the patient may be discharged within 48 hours and followed as an outpatient. No airway problems have been encountered.

### RESULTS

Indirect laryngoscopy performed one day after surgery usually reveals some ecchymosis and edema of the glottis, and voice quality is fair to poor. As the acute inflammatory response resolves, the voice greatly improves. By 3 weeks there is a noticeable improvement, and by 8 weeks voice quality begins to reach its best.

All six patients reported here had improvement in

voice quality, with the youngest patient, 24 years of age, showing the best results. The poorest results were in the two patients who had had prior injection of Teflon paste. One of these was also the oldest patient, age 62. The next best group consisted of the patients who had had polyps excised from the cords and had experienced no improvement from this or from the medical and instructional efforts that followed. One patient returned to work after resting only 1 week and probably strained his voice prematurely, delaying the ultimate in quality of voice.

The long-term effects of the procedure are not fully known. Our longest follow-up of the 24-year-old student covered 7½ years. If, through the aging process, gradual loss of elastic fibers continues, the vocal cords are likely to stretch and lose tension again in a few years. Close follow-up with a speech therapist may lessen the chance of straining the voice and recreating the hoarseness.

### DISCUSSION

It is fairly well recognized in the literature that the thyroarytenoid ligament is the principle sound-producing structure in the larynx.<sup>2,3</sup> Variations in its tension during phonation are produced by the interplay of the intrinsic laryngeal muscles. Proctor<sup>4</sup> describes how increase in tension causes a thinning of the vocal fold, and how a lengthening of it occurs with a rise in pitch. A procedure was sought that would increase the tension in the cords, but since no precise data are available on what the normal tension of the thyroarytenoid ligament is, and no measurements have been made on the relaxed ligaments, the procedure must depend upon estimates of what the normal or proper tension should be. Since the primary method of tensing the vocal cord is contraction of the cricothyroid muscle,<sup>5</sup> tilting the thyroid cartilage forward and thereby lengthen-

ing the cord, our original approach was to reinforce this action with a wire joining the thyroid and cricoid anteriorly in the midline. As the wire was twisted, the thyroid cartilage was drawn down to meet the cricoid, and some tensing of the cord occurred. However, the effect was not great enough to produce any noticeable change in voice quality or in physical appearance. Limited thyrotomy was chosen as a more direct way of lengthening the cord while disrupting laryngeal physiology the least. Our current "springboard advancement" of the anterior commissure was first performed in September 1974. This initial procedure had limited success, possibly because of the presence of much Teflon paste in each cord, which modified their vibratory characteristics.

In 1974, Isshiki et al<sup>6</sup> described the use of thyroplasty as a means of altering the tension of vocal cords, and reported on its use in ten adult dogs. In one, a median strip was developed and recessed into the thyroid cartilage, causing a lowering of the pitch of the voice. This effect was reversed by returning the segment to its anatomical position.

The incidence of elderly patients with voice problems may be best known by our coworkers in speech pathology. At the Center for Communication Disorders at the University of Wisconsin, Mueller<sup>7</sup> reported that 35% of the 500 patients seen in that facility in a 4-year period were elderly people complaining about their voices.

It is possible that some patients who are now classified as having functional voice disorders may possibly be unrecognized victims of ectasia (or stretching) of the vocal ligaments.<sup>1</sup> If so, that segment of patients might stand to benefit from this relatively uncomplicated procedure. Our early experience is encouraging; we will await with interest the broader experience of others.

### REFERENCES

1. Koufman JA, Blalock PD. Classification and approach to patients with functional voice disorders. *Ann Otol Rhinol Laryngol* 1982; 91:372-7.
2. Tucker HM. Surgery for phonatory disorders. Monographs in clinical otolaryngology. New York: Churchill Livingstone, 1981:76.
3. Fink BR, Demarest RJ. Laryngeal biomechanics. Cambridge, Mass: Harvard University Press, 1978:11.
4. Proctor DF. Breathing, speech, and song. New York: Springer-Verlag Wien, 1980:59.
5. Aronson AE. Clinical voice disorders. New York: Thieme-Stratton, Inc, 1980:26.
6. Isshiki N, Morita H, Okamura H, Hiramoto M. Thyroplasty as a new phonosurgical technique. *Acta Otolarygol (Stockh)* 1974; 78:451-7.
7. Mueller PB. Communicative disorders in a geriatric population. Presented at the Annual Convention of the American Speech and Hearing Association, San Francisco, 1978.



# MUSCLE TRANSPOSITION IN THE REHABILITATION OF THE PARALYZED LARYNX

G. DAVID NEAL, MD

SAN ANTONIO, TEXAS

MICHAEL STEARNS, FRCS

LONDON, ENGLAND

DWIGHT SUTTON, PHD

SEATTLE, WASHINGTON

RON TRACHY

SEATTLE, WASHINGTON

CHARLES W. CUMMINGS, MD

SEATTLE, WASHINGTON

Muscle transposition of the innervated omohyoid muscle into the tendon of the paralyzed posterior cricoarytenoid muscle was studied in a small series of subhuman primates. A similar procedure was described previously by King for treatment of bilateral recurrent nerve injuries. Our studies confirm that this procedure adequately enlarges the airway to allow normal activity without a tracheostomy. Histologic studies appear to show nerve ingrowth occurring at 6 months as in other neuromuscular pedicle procedures. The procedure is easily performed and causes no other muscle denervation.

By the words "rehabilitation of the paralyzed larynx" we mean the reversal of the observed functional deficit. Ideally, return to normal function would include return of neurologic control by means of nerve regeneration. The neuromuscular pedicle technique described by Tucker and associates<sup>1</sup> was one of many efforts to reinnervate the paralyzed larynx. It was known that denervated muscle was receptive of local nerve ingrowth for periods of months to years, but muscle atrophy occurred in the absence of neurotropic influences. The time course of this reinnervation or atrophy was predictable in the striated muscle of the limbs, but clinical experience suggested that the laryngeal musculature might be different.

Clinical efforts at laryngeal rehabilitation using the omohyoid nerve-muscle pedicle to the posterior cricoarytenoid (PCA) muscle were reported to be successful even in patients with long-standing bilateral vocal cord palsies.<sup>2</sup> Yet in animal experiments failures did occur, and PCA muscles were seen to be significantly replaced by noncontractile fibrous tissue at 6 months following the surgical procedure.<sup>3</sup> We speculated that this scar tissue which formed as a result of the postsurgical healing would explain the early clinical improvement. Our videotape recordings of canine respiration under maximal stimulus showed a barely noticeable lateralization of the previously paralyzed vocal fold.<sup>4</sup> This lateralization was noted early as in the human experience and was observed at a time when no phasic electrical activity could be detected from the PCA muscle. Crumley has observed that tethering of the arytenoid laterally would accentuate the lateral rocking movement that is a natural concomitant of laryngeal descent during inspiration.<sup>5</sup> Our

observations supported this concept and led us to revive the work of Evoy,<sup>6</sup> who tried to dynamically rehabilitate the paralyzed cord by attaching it to a strap muscle such as the sternothyroid. His work was merely an extension of the King procedure described in 1939.<sup>7</sup>

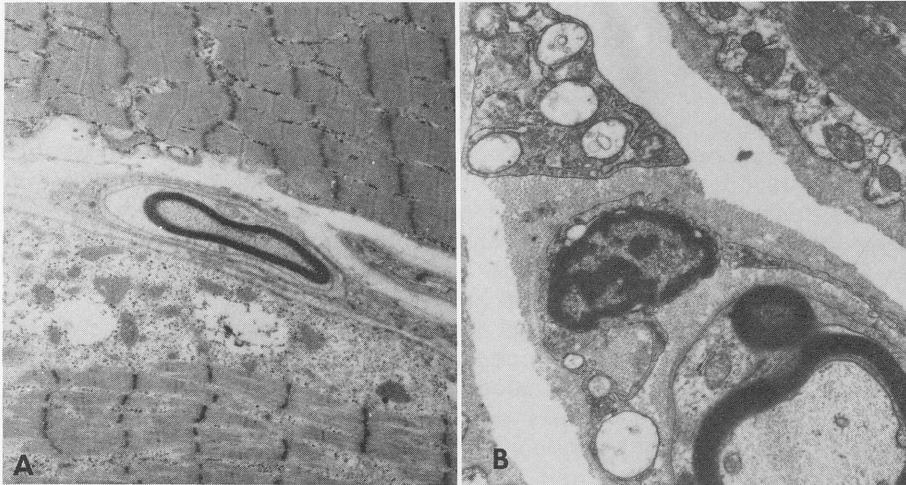
Like the omohyoid muscle, the sternothyroid muscle contracts at the onset of inspiration during stimulated respiratory efforts. We have stimulated this ventilatory effort by two means. One is by giving the animals CO<sub>2</sub> to breathe, thereby inducing respiratory acidosis. The other is by occluding their tracheostomies and forcing them to generate large negative intrathoracic pressures. Both methods presumably act via central reflexes which are dependent on sensory as well as motor innervation. Clearly the stimulus is more similar to an acute, clinical situation than that usually seen in clinical practice. However, the slight widening of the glottic opening during times of increased oxygen demand may be sufficient to allow the patient with bilateral vocal cord palsy to be decannulated. This small series of animal experiments was designed to demonstrate the feasibility of reanimating the paralyzed vocal cord by using a muscle transposition. This would take advantage of both the tethering effect and the late possibility of reinnervation occurring by intermuscular neurotization.

## METHODS

All animals were anesthetized with intravenous pentobarbital anesthesia to a light surgical plane. Two rhesus monkeys and two macaques were used for transpositions involving the omohyoid muscle. In these animals, the omohyoid muscle was separated from its hyoid insertion and the cut end was ruptured with nonabsorbable suture to the PCA muscle. The nerve and vascular supplies to the omohyoid were carefully preserved. Contractility was

From the Otolaryngology Laboratory of the University of Washington, Seattle.

Presented at the meeting of the American Laryngological Association, New Orleans, April 10-11, 1983.



Myelinated nerve fiber and muscle fibers from macaque PCA. A) Six months following denervation and muscle transposition. B) Control.

tested using 1 mA of galvanic current. At the time of the transposition, the recurrent laryngeal nerve was divided ipsilaterally and a 2-cm segment excised. The creation of a unilateral vocal cord palsy was checked by laryngoscopy at the end of the procedure.

A similar procedure was performed in two mature dogs using the sternothyroid muscle. The sternothyroid muscle was severed from its attachment to the thyroid ala, the posterior edge of that ala was removed, and the free end of the sternothyroid muscle was sewn to the PCA muscle. Once again a segment was excised from the ipsilateral recurrent laryngeal nerve.

After 6 to 8 weeks the animals were again anesthetized to a plane with spontaneous respirations but depressed corneal reflexes. The larynx was visualized via direct laryngoscopy in both quiet and stimulated respirations. Stimulations to maximal ventilatory effort were achieved by increasing the CO<sub>2</sub> in the inspired mixture for ten inspirations. In animals that were to be killed for histologic samples, cuffed tracheostomies were inserted. These animals were forced to inspire against an occluded tube for several breaths to stimulate maximal effort.

Tracheostomized animals were videotaped via a straight-viewing Hopkins rod optical telescope for later analysis by several viewers. During the observation period, bipolar electromyograms (EMGs) were obtained from the PCA muscles. Prior to killing, the transposed muscles with their nerves were directly stimulated with a 1-mA galvanic stimulus during endoscopic observation.

Segments of right and left PCA were removed from the animals within minutes of death and fixed in 2.5% glutaraldehyde in phosphate buffer (pH 7.4). Subsequent TEM was performed after embedding of the muscle in Epon. Thin sections were made at right angles to the long axis of the muscle fibers.

## RESULTS

One dog was evaluated at 6 weeks and killed. There was no apparent laryngeal movement in this animal on the muscle transposition side even with direct electrical stimulus to the strap muscle. No significant electrical activity could be recorded from the PCA muscle and no tissue was submitted for histology because of the dense scar tissue found in the region. The second dog was videotaped at 10 weeks following the transposition procedure and no movement was observed in the paralyzed cord. A bilateral recurrent nerve paralysis was then created by sectioning the vagus nerve contralateral to the muscle transposition to see if the animal could survive. The appearance of the larynx showed that the

cord on the side of the muscle transposition was in a more lateral position than its mate which had had no muscle transposition. This dog survived without a tracheostomy though it was voiceless.

In the monkeys, the results were the same using the omohyoid transfer. Even though phasic inspiratory electrical activity could be recorded from the omohyoid muscle after the transposition, no inspiratory abduction was noted at periods up to 6 months from the transposition. Galvanic stimulation of the omohyoid nerve pedicle caused muscle contraction which was translated to the larynx and caused a lateral twitch of the hemilarynx. It was only after a bilateral vocal cord paralysis was created that the superiority of the side with the transposition was noted. The transposition clearly caused lateralization of the paralyzed cord.

Electron microscopy uniformly showed the presence of both myelinated and unmyelinated nerve fibers in the PCA on the denervated side. The striated muscle of the reinnervated side looked very similar to the control side at 6 months postdenervation (Figure). Our attempts to show horseradish peroxidase (HRP) transport via the ansa hypoglossi to the cervical spinal cord motor neurons were never successful. However, there was transport of HRP from the PCA to the nucleus ambiguus on the same side as the recurrent nerve section. It was not possible to exclude the possibility that HRP diffused from the PCA into surrounding vagally innervated muscles or glands.

## CONCLUSIONS

A careful reading of the work of King<sup>7</sup> or Evoy<sup>6</sup> would lead to the same conclusions as are possible from this work, but we think they bear restating in light of the time intervening since those publications. These results can be applied only to cases of bilateral vocal cord palsies from recurrent nerve injury at the time of thyroidectomy. In these cases the position of the vocal folds is too adducted to allow sufficient airway for any increased metabolic de-



mand. Only a very slight improvement in the size of the airway is needed to obtain a significant clinical improvement and allow the closure of the tracheostomy.

The muscle transposition operation that eventually became known as the King procedure did not have innervation as its goal, but this study shows clearly that nerve ingrowth takes place in the paralyzed posticus (PCA) muscle. Our studies at a period of 4 to 6 months after this surgery did not show significant EMG activity in this muscle, but the muscle fibers were morphologically similar to the control muscle of the contralateral side. The experimental studies reported by Evoy were done on over 70 sheep that were kept alive up to 6 months prior to being killed. Despite his best efforts, he was unable to prevent the formation of dense, hyperplastic scarring between the arytenoid and the ala of the thyroid cartilage. It is of interest that King made special mention of the need to suture the arytenoid laterally in order to prevent tension on his muscle sutures. We have not kept any animal alive for a period longer than 6 months, but are aware of the 18-month follow-up in one of Evoy's sheep. This animal was reported to have the laryngoscopic appearance of arytenoid adduction on inspiration and was found to have a contractile muscle pedicle to faradic stimuli at the time of being killed. In this animal the scar tissue had become much less noticeable and was remarkable for its nearly normal pliancy.

The problem of reinnervation of the intrinsic muscles of the larynx is a difficult one and we do not claim the solution for it. It appears that all of the procedures that have described a lateral approach to the larynx with exposure of the PCA muscle have one thing in common. They create a tethering of the arytenoid to the inferior portion of the ala of the thyroid cartilage. Since the ala of the cartilage is the site of attachment of the sternothyroid and thyrohyoid muscles, this tethering allows the inspiratory contractions of these muscles to have an effect on the vocal folds. If we go further and link the omohyoid muscle directly to the arytenoid or posticus muscle, we find that the tethering tissue may itself contract. After many months or perhaps a year there may be a superiority of the contractile muscle tethering over the other procedures, but this will not likely be noticed clinically. As far as eventual reinnervation of the paralyzed muscle is concerned, the movement of the omohyoid muscle with an intact nerve and vascular supply into direct contact with the PCA has all the same mechanisms for reinnervation as the other procedures. Nerve sprouting from the innervating muscle forms functional neuromuscular end-plates. The time parameters of the reinnervation are not exactly known, but a period of up to 6 months after denervation does not lead to irreversible atrophy. Actually, reinnervation prob-

ably takes place if the transposition occurs any time up to 2 years.

Our study was not designed to prove that reinnervation of the PCA muscle occurred from the omohyoid muscle. We have tried unsuccessfully to trace the innervating fibers from the PCA to the motor neurons of the ansa hypoglossi using HRP. Since the nucleus ambiguus was strongly labeled in this study, it is likely that the nerve fibers from the cut recurrent laryngeal nerve or the disrupted superior laryngeal fibers have reinnervated the paralyzed PCA muscle. It is quite possible that these are the myelinated nerve fibers seen in the electron micrographs of the muscle. However, no significant phasic action potentials were noted on EMG and it is our conclusion that the rehabilitation we have observed is not dependent on reinnervation of the paralyzed PCA. The omohyoid muscle has been transposed so that it now acts to lateralize the vocal cord and widen the glottis. Complete reinnervation may be noted at 6 months, but we have not maintained animals for this duration.

This study was undertaken to solve a clinical problem and that is why primates were used as the experimental animals. The omohyoid muscle is thought to be unique to humans and apes and certainly is a likely source for a muscle transposition. The exposure of the posterior larynx does not differ from that described by Tucker,<sup>2</sup> and the length of the omohyoid is more than sufficient to be attached to the PCA muscle or to the arytenoid itself as was described by King.<sup>7</sup> It is technically somewhat easier to perform than the neuromuscular pedicle procedure or direct nerve anastomosis techniques. The loss of the omohyoid action on one or both sides is probably of no significance to the respiratory movements of the larynx, making it highly unlikely that the procedure would lead to any long-term respiratory compromise. King reported good results in the three patients with bilateral vocal cord palsies in whom he performed the transposition procedure. His follow-up did not extend beyond several months, and no large series of these procedures has subsequently been reported. With the advances being made in thyroid disease on both the medical and surgical fronts, it seems unlikely that there will be any great need for a rehabilitative procedure for bilateral recurrent laryngeal nerve paralysis in the future. There are, however, a number of patients with a need for greater abduction of their cords after intubation injuries and neck trauma. The lateral approach to the cricoarytenoid joint with transposition of the omohyoid muscle has utility equal to the arytenoidectomy operation for such patients and leaves them with a better voice. This operation deserves to be raised from the literature once again for its general utility because it can only improve abductor function while reinnervation takes place from whatever source.

## REFERENCES

1. Tucker HM, Harvey J, Ogura JH. Vocal cord remobilization in the canine larynx. *Arch Otolaryngol* 1970; 92:530-3.
2. Tucker HM. Human laryngeal reinnervation. Long-term experience with the nerve-muscle pedicle technique. *Laryngoscope* 1978; 88:598-604.
3. Hengerer AS, Tucker HM. Restoration of abduction in the paralyzed canine vocal cord. *Arch Otolaryngol* 1973; 97:247-50.
4. Neal GD, Cummings CW, Sutton D. Delayed reinnervation of the unilateral vocal cord paralysis in dogs. *Otolaryngol Head Neck Surg* 1981; 89:608-12.
5. Crumley RL. Experiments in laryngeal reinnervation. *Laryngoscope* 1982; 92 (suppl 30):1-27.
6. Evoy M. Experimental activation of paralyzed vocal cords. *Arch Otolaryngol* 1968; 87:155-61.
7. King BT. A new and function restoring operation for bilateral abductor cord paralysis. *JAMA* 1939; 112:814-23.



# INTRALARYNGEAL RELEASE FOR TRACHEAL ANASTOMOSIS

MICHAEL E. SACHS, MD

JOHN CONLEY, MD

DANIEL D. RABUZZI, MD

NEW YORK, NEW YORK

An operation for obtaining additional length in order to achieve end-to-end anastomosis of the trachea without significant suture-line tension is described. The intralaryngeal procedure lengthens the larynx approximately 1 to 2 cm without restricting its function. It is an expedient, effective technique when used primarily, or adjunctively, with a suprahyoid or mediastinal release.

The increasing incidence of tracheal stenosis is well documented and results from two primary sources. The first is external trauma secondary to our high-velocity mobile society. The second is from our increased use of sophisticated resuscitation and assisted-ventilation equipment.

The most appropriate treatment for circumferential tracheal stenosis is sleeve resection and end-to-end anastomosis.<sup>1</sup> The successful completion of this procedure, however, is in large part related to suture-line tension. The recurrence of stenosis in the subglottic and tracheal areas is assured if excessive tension on the suture line is operative.<sup>2</sup>

Early experiments by Cantrell and Folse<sup>3</sup> elegantly demonstrate that in dog anastomoses, a tension of less than 1,700 g was necessary for consistent primary healing. Above this level there were unpredictable results, and when the tensions were greater than 2,200 g, the suture line invariably separated and restenosed. Histologic correlation of these findings revealed that a primary healing wound with minimal scarring was evident when the mucosa grew over the sutures, creating an intact ciliated epithelium across the anastomotic line. Montgomery is even more demanding and states that the tension on the suture line should not exceed 1,000 g to assure a successful reconstruction.<sup>4</sup>

Although the concept of minimal tension is generally agreed upon, the amount of tracheal resection which can be accomplished without release techniques is in some dispute. The controversy probably arises from the fact that as a patient ages, the relative elasticity of the annular ligaments of the trachea decreases. Thus, the younger patient has an improved chance of accommodating extended tracheal resections without release. Montgomery states that a tracheal gap of 3 cm can be closed without release techniques in a substantial percentage of patients.<sup>4</sup> Some authors, however, have reported

achieving successful primary anastomoses of up to 4 and 5 cm.<sup>5,6</sup> The key component, however, is tension, and this must be scrupulously tailored to a minimum in each individual case.

Previously there have been four methods of releasing tension at a tracheal anastomosis, aside from the technique of keeping the patient's head in extreme flexion for approximately ten days postoperatively. The first method is well accepted and is achieved by mobilizing the distal trachea from the thorax.<sup>7,8</sup> This lengthening procedure, however, is intrathoracic and the inherent dangers of mediastinal dissection exist. The maximum amount of mobilization accomplished with this technique is 6 cm.

The second technique is the lengthening of the annular ligaments of the trachea which can add up to 1.5 cm. Complete circumferential sectioning of the ligaments will disrupt the tracheal blood supply which runs in a vertical direction based on the superior and inferior thyroid arteries. A staggered effect must therefore be used, contralaterally sectioning the ligaments on either side of the anastomosis.

The third method for extending length is the suprahyoid release technique of Montgomery.<sup>4</sup> This is well tolerated by the patient, is easy to accomplish, and involves releasing the larynx or hyoid bone from its upper muscular attachments.

The fourth method is an infrahyoid release technique reported by Dedo,<sup>9</sup> which separates the thyroid cartilage from its attachments superiorly to the hyoid bone.

This paper now reports a fifth operative technique which can be used either primarily for minimal tracheal resection or as an adjunctive technique to any or all of the above-mentioned release techniques. This procedure does not interfere with the other release techniques, is well tolerated by the patient, and does not limit the physiologic functioning of the larynx, trachea, or upper aerodigestive tract.

From the Department of Otolaryngology-Head and Neck Surgery, New York Medical College (Sachs, Rabuzzi), the Division of Head and Neck Plastic and Reconstructive Surgery, New York Eye and Ear Infirmary (Sachs), and the Department of Otolaryngology, Columbia Presbyterian Medical Center (Conley), New York.

Presented at the meeting of the American Laryngological Association, New Orleans, April 10-11, 1983.

REPRINTS — Michael E. Sachs, MD, 310 East 14th St, New York, NY 10003.

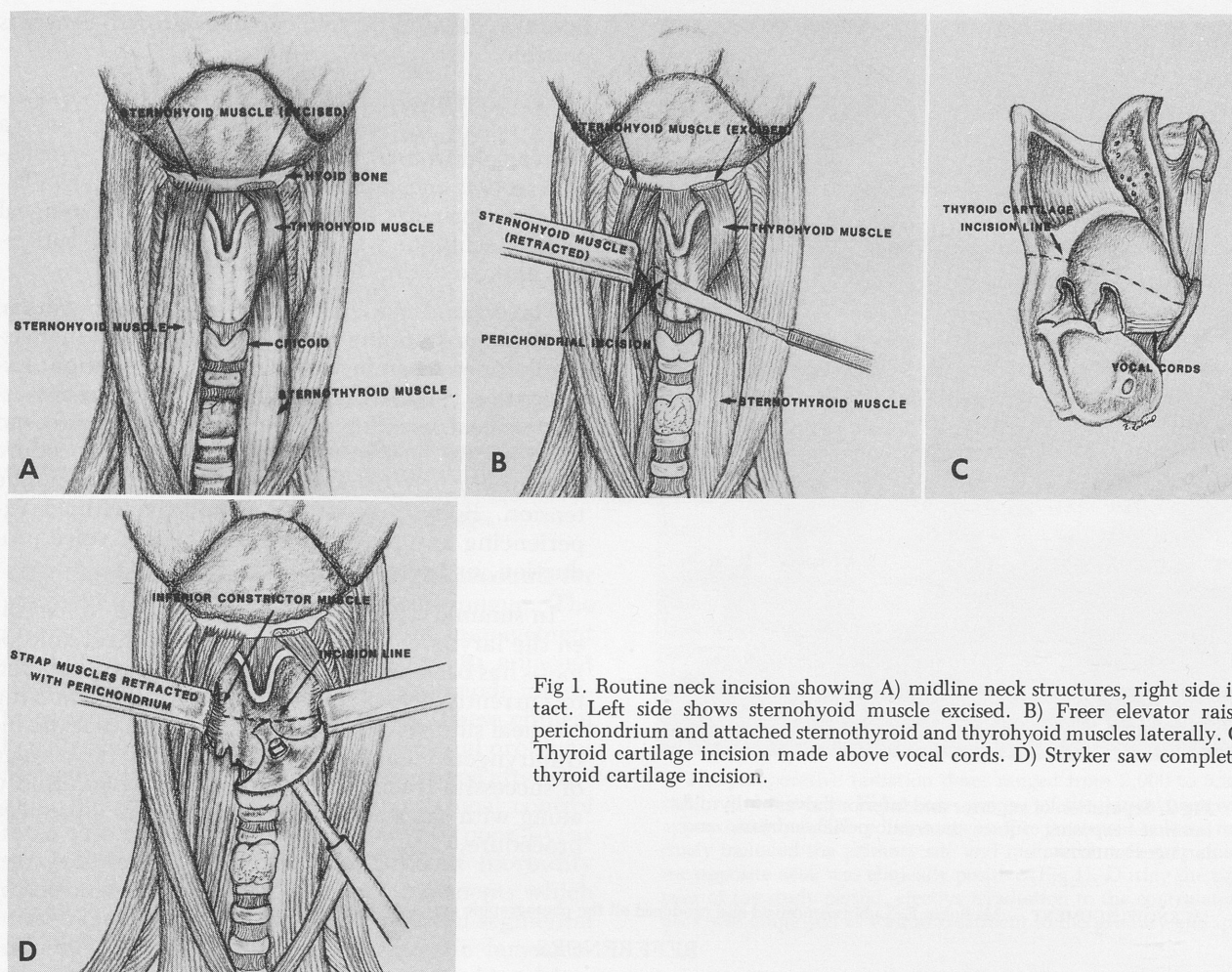


Fig 1. Routine neck incision showing A) midline neck structures, right side intact. Left side shows sternohyoid muscle excised. B) Freer elevator raises perichondrium and attached sternothyroid and thyrohyoid muscles laterally. C) Thyroid cartilage incision made above vocal cords. D) Stryker saw completes thyroid cartilage incision.

The experimental data substantiating the intralaryngeal release technique is derived from three sources. The technique was performed in canine experiments and consistently revealed at least 1 cm but no more than 2 cm of extension with a tension of less than 1,000 g. Fresh cadaver dissections allowed for a second source of experimental data and correlated well with the canine experiments, displaying a range of 1 to 2 cm with a control of 1,000 g tension. An additional experimental technique involving living patients undergoing total laryngectomy was performed intraoperatively before the larynx was removed, and in these cases a range of 1 to 2 cm was consistently accomplished with less than 1,000 g tension. This last piece of data, however, is somewhat skewed based on the fact that all these cases had an intrinsic laryngeal carcinoma which in some instances hindered the release of the laryngeal structures.

Routine neck incisions and flaps are outlined and raised exposing the midline neck structures. Dissection is carried out between the strap muscles down to the anterior tracheal and laryngeal surfaces. The thyroid cartilage is exposed between retractors (Fig 1A) and the subglottic stenosis is appropriately

handled as dictated by the individual clinical situation. The intralaryngeal release procedure is then performed. The sternohyoid muscles are retracted laterally, exposing the sternohyoid and thyrohyoid muscles. These are then elevated with the perichondrium of the thyroid cartilage until the edge of the posterior margin of the thyroid ala is reached (Fig 1B). A transverse cut in the thyroid perichondrium just above the vocal cords is outlined (Fig 1C), and a Stryker saw completes the incision (Fig 1D). The inner perichondrium of the thyroid cartilage is incised, exposing a thick inner thyroid membrane composed of a confluence of the inner laryngeal mucosa and the inferior extent of the thyroepiglottic ligament (Fig 2). This highly elastic membrane stretches, completing the procedure.

It should be noted that the intrinsic laryngeal structures are not exposed, and the superior laryngeal nerves, both internal and external, as well as the recurrent laryngeal nerves are preserved. The technique can be used adjunctively or as a primary technique for minimal tracheal resection. A postoperative course of neck flexion for ten days is considered helpful in all cases. We caution the use of this technique in children where interruption of the



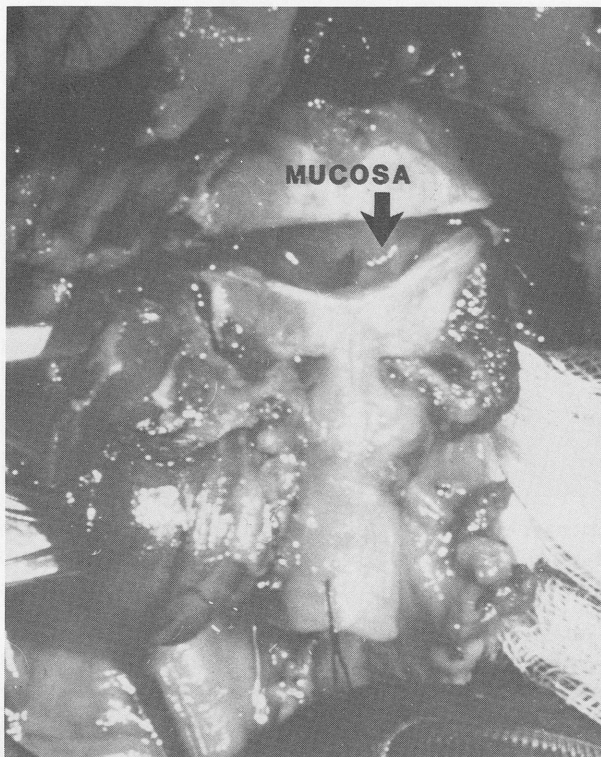

Fig 2. Separation of superior and inferior halves of thyroid laminae exposing intact internal perichondrium and laryngeal mucosa.

laterally situated thyroid cartilage growth center is possible.

This technique has been used successfully as a primary release in two cases. The first patient was a 54-year-old woman who underwent primary tracheal resection encompassing three tracheal rings (T2-T5) for a primary hemangioma. The intralaryngeal release technique was performed to enhance suture-line approximation by decreasing tension.

The second patient was a 48-year-old woman with a long-standing history of stridor and increasing dyspnea secondary to traumatic intubation. Examination revealed a subglottic stenosis necessitating tracheal resection of three rings with end-to-end anastomosis. The intralaryngeal release procedure was performed primarily to decrease suture-line tension. Both cases healed primarily without experiencing any problems of deglutition, voice production, or breathing.

In summary, a new procedure utilized to lengthen the larynx when accomplishing tracheal anastomosis has been described, illustrated, and compared to currently acceptable techniques for minimizing tracheal suture-line tensions. It is hoped that the intralaryngeal technique will increase the percentage of successful tracheal reconstructions when utilized along with the standard operations or as a primary procedure.

ACKNOWLEDGMENT — Ms Robin E. Lubins conceived and produced all the photographic and illustrative components of this paper.

#### REFERENCES

1. Montgomery W. Reconstruction of the cervical trachea. *Ann Otol Rhinol Laryngol* 1964; 73:5-11.
2. Ekstrom S, Carlens E. Teflon prosthesis in tracheal defects in man. *Acta Chir Scand [suppl]* 1959; 245:71-5.
3. Cantrell J, Folse JR. The repair of circumferential defects of the trachea by direct anastomosis. Experimental evaluation. *J Thorac Cardiovasc Surg* 1961; 42:589-98.
4. Montgomery W. Suprahyoid release for tracheal anastomosis. *Arch Otolaryngol* 1974; 99:225-60.
5. Miscall L, McKittrick JB, Giordano RP, Noland RB. Stenosis of trachea resection and end-to-end anastomosis. Report of two cases. *Arch Surg* 1963; 87:726-31.
6. Mathey J, Binet JP, Galey JJ, Evrard C, Lemoine G, Denis B. Tracheal and tracheobronchial resections. Technique and results in 20 cases. *J Thorac Cardiovasc Surg* 1966; 51:1-13.
7. Grillo HC. Circumferential resection and reconstruction of the mediastinal and cervical trachea. *Ann Surg* 1965; 162:374-88.
8. Michelson E, Solomon R, Maun L, Ramirez J. Experiments in tracheal reconstruction. *J Thorac Cardiovasc Surg* 1961; 41:748-59.
9. Dedo H. Laryngeal release and sleeve resection for tracheal stenosis. *Ann Otol Rhinol Laryngol* 1969; 78:285-96.

# PREOPERATIVE IRRADIATION AND SURGERY FOR CARCINOMA OF THE BASE OF THE TONGUE

STANLEY E. THAWLEY, MD

JOSEPH R. SIMPSON, MD

CARLOS A. PEREZ, MD

JAMES E. MARKS, MD

JOSEPH H. OGURA, MD†

ST LOUIS, MISSOURI

From 1960 through 1978, 101 patients with histologically proven epidermoid carcinoma of the base of the tongue were treated with preoperative irradiation and surgery at Washington University School of Medicine. Local and regional control at 3 years was achieved in 65% of the patients, and at 5 years in 57%. Sixteen percent of patients who suffered local or regional failure were salvaged by further surgery. Distant metastases developed in approximately 18% of patients and second malignancies developed in 20%. It appears that the combination of preoperative irradiation plus surgery provides substantial local control rates and survival for patients with base of tongue cancer in both early and moderately advanced stages.

Carcinoma of the base of the tongue accounts for about 25% of cancers involving the tongue. The disease often presents a formidable management challenge due to its frequent spread to adjacent structures and high incidence of lymph node metastases at the time of initial diagnosis. These clinical features have been associated with several problems including 1) high rates of local recurrence after surgical therapy alone<sup>1-4</sup>; 2) inadequate local control rates with radiation therapy alone<sup>5-9</sup>; 3) poor 5-year survival rates<sup>5,6,10,11</sup>; and 4) significant morbidity associated with standard surgical treatments which may include partial glossectomy, partial segmental mandibulectomy, extended supraglottic laryngectomy, and at times total glossectomy and total laryngectomy.<sup>1,2,4,12-18</sup> Although occasional authors, notably Fletcher et al,<sup>7</sup> have reported excellent control rates with radiation therapy alone, most reported results are far less satisfactory.<sup>5,6</sup>

This report analyzes the experiences of the Division of Radiation Oncology and the Department of Otolaryngology at Washington University School of Medicine with the use of preoperative irradiation and surgery for squamous carcinoma of the base of the tongue. Local control, patterns of failure, no evidence of disease (NED) survival, and the morbidity of treatment are analyzed.

## MATERIALS AND METHODS.

The charts of all patients with histologically proven epidermoid carcinomas of the base of the tongue seen in the Division of Radiation Oncology between 1960 and 1978 were reviewed. The anatomical boundaries used were the circumvallate papillae and the anterior tonsillar pillar anteriorly and the vallecula posteriorly. The pharyngoepiglottic folds and glossopharyngeal sulci were also included. There were 150 patients seen; 33 of them were treated

with radiation alone because of either medical inoperability, palliative treatment intent, or enrollment in a national protocol. One hundred seventeen patients were, therefore, scheduled to undergo low-dose preoperative radiation followed by definitive surgery, which was the treatment policy during this period of time. Patients were staged according to the 1978 American Joint Committee Convention for Cancer Staging and End Results Reporting.<sup>18</sup>

The preoperative radiation doses ranged from 2,000 to 5,000 rad in 2 to 5 weeks. Eighty-one percent of the patients received approximately 3,000 rad in 3 weeks. The treatment volume routinely included the primary site and ipsilateral neck only unless the opposite neck was clinically positive (Fig 1). During the final year of the study period, elective irradiation to the contralateral neck was employed as well as treatment to the primary and ipsi-

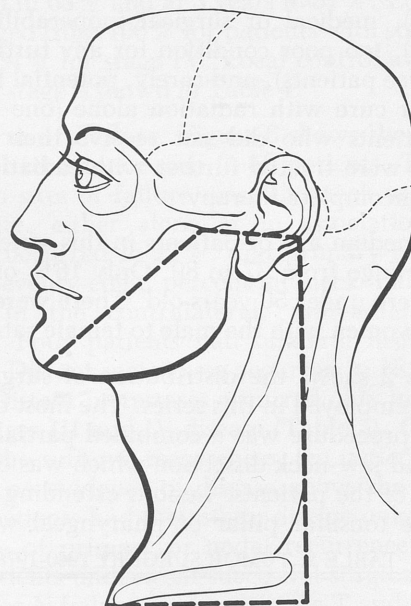


Fig 1. Radiation therapy ports.

From the Department of Otolaryngology and the Division of Radiation Oncology, Mallinckrodt Institute of Radiology, Washington University School of Medicine, St Louis.

Presented at the meeting of the American Laryngological Association, New Orleans, April 10-11, 1983.

†Deceased April 1983.

REPRINTS — Stanley E. Thawley, MD, Department of Otolaryngology, Washington University School of Medicine, St Louis, MO 63110.



TABLE 1. PREOPERATIVE IRRADIATION AND SURGERY: DISTRIBUTION OF PATIENTS 1960-1978

	Stage Distribution				Total No. of Patients
	N <sub>0</sub>	N <sub>1</sub>	N <sub>2</sub>	N <sub>3</sub>	
T <sub>1</sub>	4	7	3	2	16
T <sub>2</sub>	9	13	8	6	36
T <sub>3</sub>	9	13	10	8	40
T <sub>4</sub>	4	0	3	2	9
Total no. of patients	26	33	24	18	101

Stage I: T<sub>1</sub>N<sub>0</sub> — 4 (4%).

Stage II: T<sub>2</sub>N<sub>0</sub> — 9 (9%).

Stage III: T<sub>3</sub>N<sub>0</sub>, T<sub>1-3</sub>N<sub>1</sub> — 42 (42%).

Stage IV: T<sub>4</sub> any N, 2-3 any T — 46 (45%).

lateral neck. The interval between completion of preoperative irradiation and surgery ranged from 1½ to 5 weeks with most patients being operated usually at 3 to 4 weeks.

Patients were followed for a minimum of 4 years or until death. No patient was lost to follow-up. Survival data were computed using a life table method, and statistical significance was determined using Mantel-Cox and Breslow tests.

### RESULTS

The distribution of T and N stages for this group of patients is shown in Table 1. Seventy-four percent had nodal spread and nearly 50% had advanced local disease (T<sub>3</sub> or T<sub>4</sub>). Twenty-six of 101 patients had clinically negative necks.

Of 117 patients, 101 (86%) completed the planned radiation and surgery course. Sixteen patients did not complete the surgical part of the therapy for a variety of reasons. Failure to complete the surgical part of the therapy was due to patient refusal (three patients), medical or surgical inoperability (nine patients), too poor condition for any further therapy (three patients), and rarely, potential for treatment for cure with radiation alone (one patient). The patients who did not receive their surgical therapy were treated further with radiation alone or had incomplete therapy.

The median age of patients in this series was 58 with a range from 37 to 89. Only 16% of the patients were under 50 years old. There were 75 men and 26 women with the male to female ratio of 3:1.

Table 2 shows the distribution of surgical procedures employed in this series. The most commonly used procedure was a combined partial glossectomy and jaw-neck dissection which was employed in 44% of the patients. Lesions extending laterally onto the tonsillar pillar or pharyngeal wall were

TABLE 2. TUMOR SURGERY 1960-1978

Type of Surgery	No. of Patients
Jaw-neck dissection*	44
Supraglottic laryngectomy, neck dissection	33
Partial glossectomy, neck dissection	13
Other	9
Total glossectomy and laryngectomy	2
Total	101

\*Number with mandible preservation — 18 (41%).

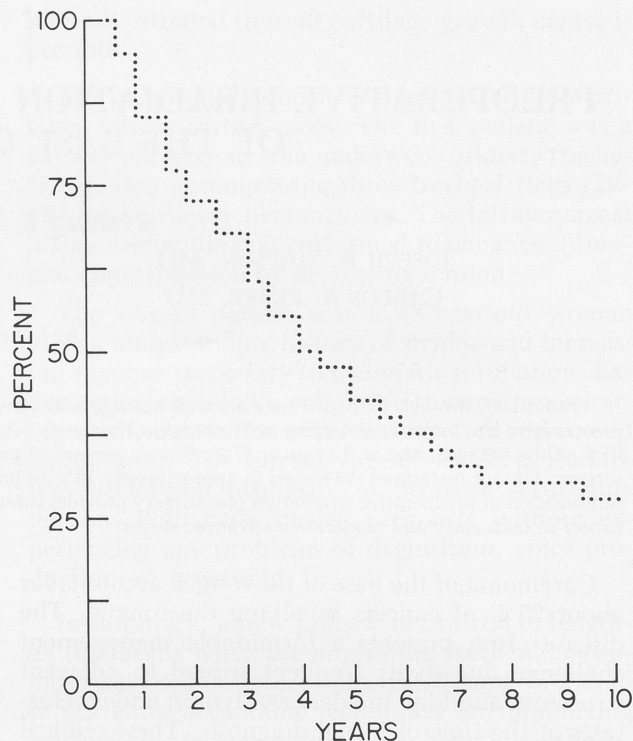


Fig 2. Actuarial survival of all patients.

usually treated by this surgical approach. In 41% of these patients, the surgery was accomplished with preservation of the mandible, while in the remainder a segmental mandibulectomy was done along with removal of the primary tumor. Central lesions limited to the base of the tongue or vallecula without extension onto the tonsillar pillar were

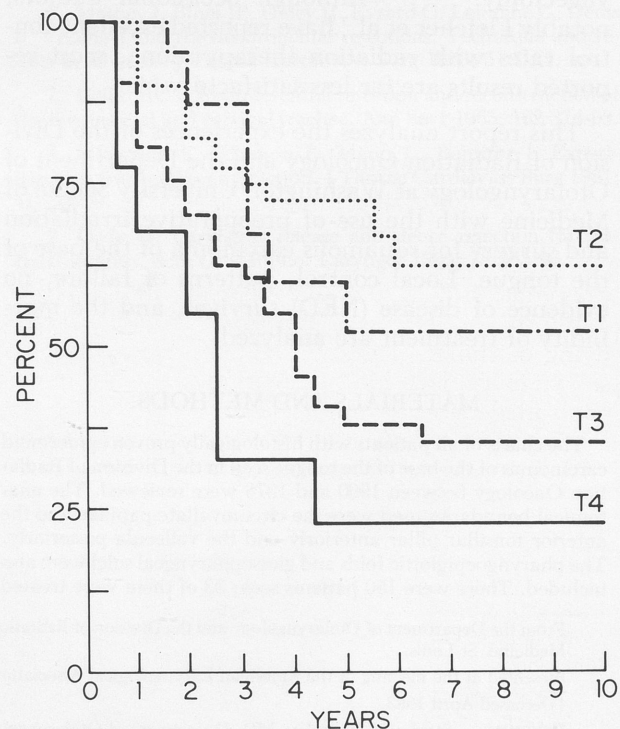


Fig 3. Adjusted survival by T stage.

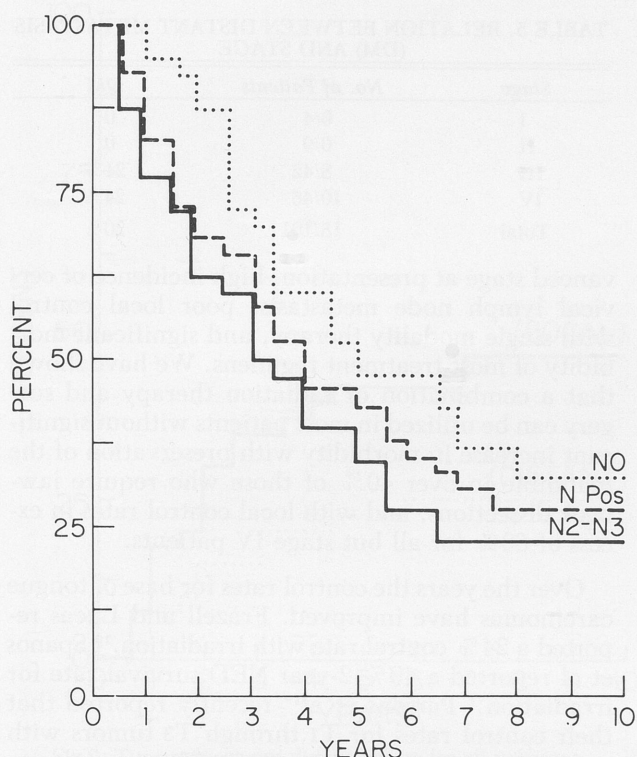


Fig 4. Actuarial survival by nodal status at diagnosis.

generally treated by partial glossectomy and extended supraglottic laryngectomy and neck dissection. A total glossectomy and laryngectomy was rarely done.

**Survival.** The actuarial survival of all patients completing therapy is shown in Fig 2. Forty-five percent of patients survived 5 years. The 5-year survival rate varied significantly with T stage, ranging from 57% for T1 and 72% for T2 to only 22% for T4 (Fig 3). As a group, patients with clinically positive necks survived as well as patients who were N0. A clinically lower 5-year survival was associated with advanced nodal disease, however (Fig 4). Men had a lower 5-year survival than women (33% v 42%) but the stages were not equally distributed between the sexes. More women had earlier disease at presentation, with 75% having stages I and II compared to 36% for men. The proportion of patients dying of tumor of intercurrent disease by stage is shown in Table 3. Most patients died because of uncontrolled tumor, although 20% of patients dying by 5 years succumbed from intercurrent disease without evidence of tumor relapse. It is therefore

TABLE 3. DISEASE STATUS AT FIVE YEARS

	Stages				Total
	I	II	III	IV	
Dead with disease	0	2	13	21	36
Dead, intercurrent disease	2	2	6	10	20
Alive and well	2	4	19	13	38
Alive with disease	0	0	2	1	3
Alive, no evidence of disease <5 yr-follow-up	0	1	2	1	4
Total	4	9	42	46	101

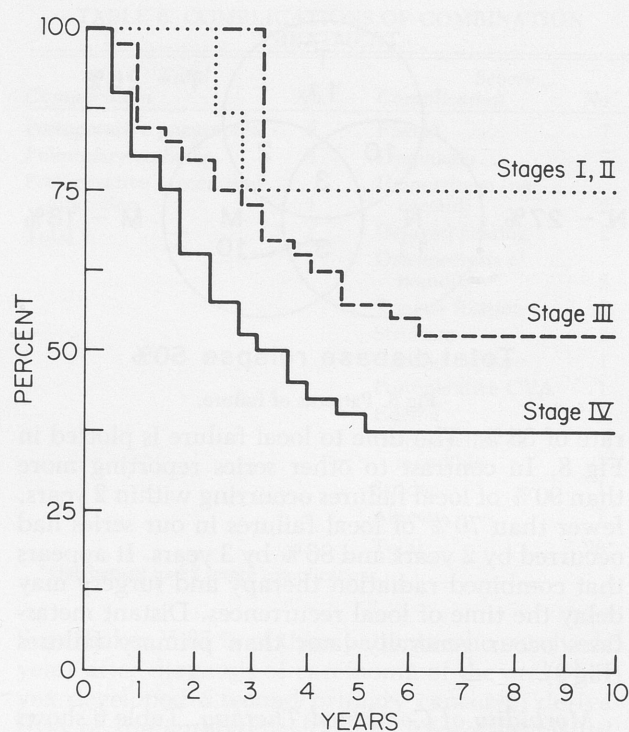


Fig 5. Adjusted survival by stage.

useful to compare adjusted actuarial survivals for this population. Figure 5 shows the adjusted survival by stage.

**Local and Regional Control.** Control at the primary site and necks for a minimum of 3 years was obtained in 65% and at 5 years in 57%. Local control ranged from 100% for patients with stage I disease to 54% for stage IV. Local control at 3 and 5 years by stage is shown in Table 4.

**Patterns of Failure.** Figure 6 shows the patterns of initial recurrence seen in 50 patients. The most common sites of failure were the neck or the primary site, either alone or in association. Neck failures occurred in 27%, and primary failures in 26%. Seventy-eight percent of neck failures occurred in the contralateral, unirradiated neck (21/27). Four patients had bilateral neck failure (Fig 7). Distant metastases occurred in 18% of patients. Distant metastases occurred only in patients with stages III and IV disease (Table 5). Of 50 patients who suffered recurrences, ten patients (20%) showed no evidence of disease above the clavicle. These patients had metastatic disease only with no evidence of primary or nodal recurrence (Fig 6). Five patients underwent successful surgical salvage after T or N failure for an ultimate T and N failure

TABLE 4. LOCAL CONTROL BY STAGE

Stage	No. of Patients	3 yr	5 yr
I	4	100%	100%
II	9	75%	75%
III	42	74%	67%
IV	46	53%	40%



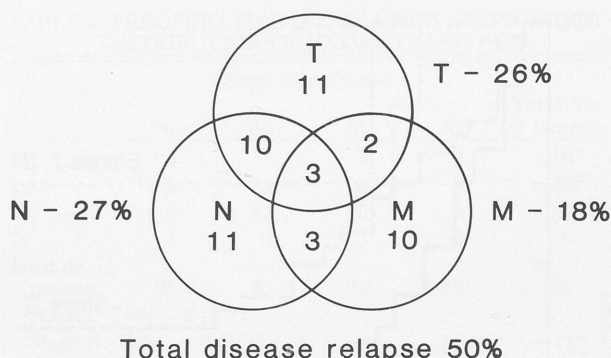


Fig 6. Patterns of failure.

rate of 35%. The time to local failure is plotted in Fig 8. In contrast to other series reporting more than 90% of local failures occurring within 2 years, fewer than 70% of local failures in our series had occurred by 2 years and 86% by 3 years. It appears that combined radiation therapy and surgery may delay the time of local recurrences. Distant metastases occur generally later than primary failures (Fig 9).

**Morbidity of Combined Therapy.** Table 6 shows the complications seen in this series. Four percent of patients suffered fatal postoperative complications including pneumonia, pulmonary embolism, and myocardial infarction. Nonfatal complications of a severe degree were seen in 28%, including one patient with two severe complications.

**Second Malignancies.** Twenty percent of patients in this series developed second malignancies following initial therapy. The incidence of subsequent development of a second cancer by stage is shown in Table 7. The majority of these cancers occurred in the upper aerodigestive tract with the lung being the most common site. Individual cases of lymphoma and breast cancer were also seen. Treatment of these secondary malignancies was uniformly unsuccessful.

#### DISCUSSION

Carcinoma of the base of the tongue remains a significant management problem because of ad-

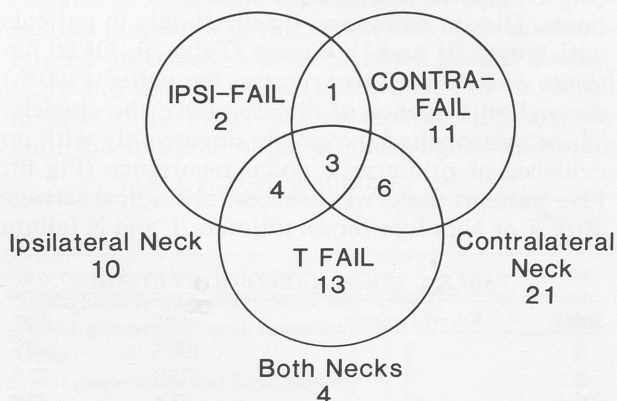


Fig 7. Distribution of T and N failures.

TABLE 5. RELATION BETWEEN DISTANT METASTASIS (DM) AND STAGE

Stage	No. of Patients	DM
I	0/4	0
II	0/9	0
III	8/42	21%
IV	10/46	24%
Total	18/101	20%

vanced stage at presentation, high incidence of cervical lymph node metastasis, poor local control with single modality therapy, and significant morbidity of most treatment regimens. We have shown that a combination of radiation therapy and surgery can be utilized in most patients without significant increase in morbidity with preservation of the mandible in over 40% of those who require jaw-neck dissections, and with local control rates in excess of 60% for all but stage IV patients.

Over the years the control rates for base of tongue carcinomas have improved. Frazell and Lucas reported a 24% control rate with irradiation.<sup>16</sup> Spanos et al reported a 49% 2-year NED survival rate for irradiation.<sup>7</sup> Parsons et al<sup>19</sup> recently reported that their control rates for T1 through T3 tumors with radiation were greater than 60%. This is similar to the local failure rate of 21% following irradiation by similar techniques reported from the M.D. Anderson Hospital.<sup>20</sup> Riley et al<sup>21</sup> reported improved local control rates in patients receiving combined surgery and radiation. Most authors agree that operation will salvage only a few irradiation failures, and results of secondary treatments for recurrences

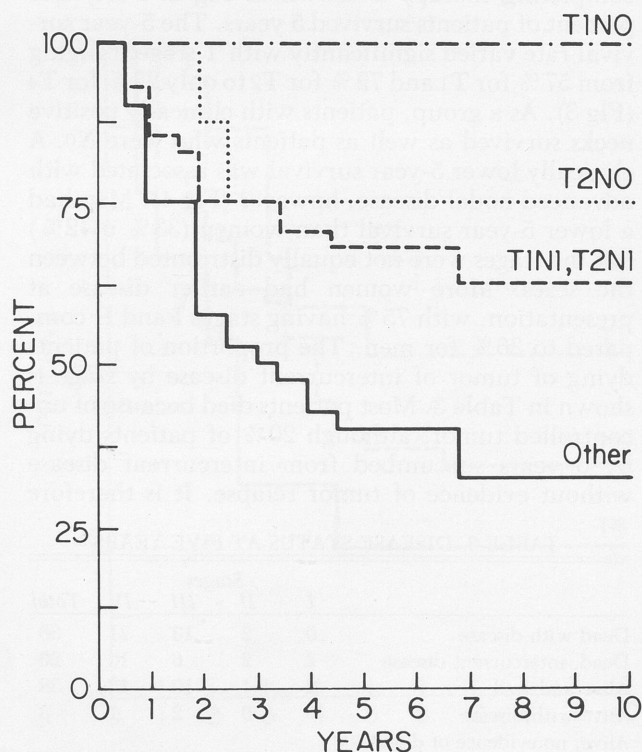


Fig 8. Time to local failure by TN stage.

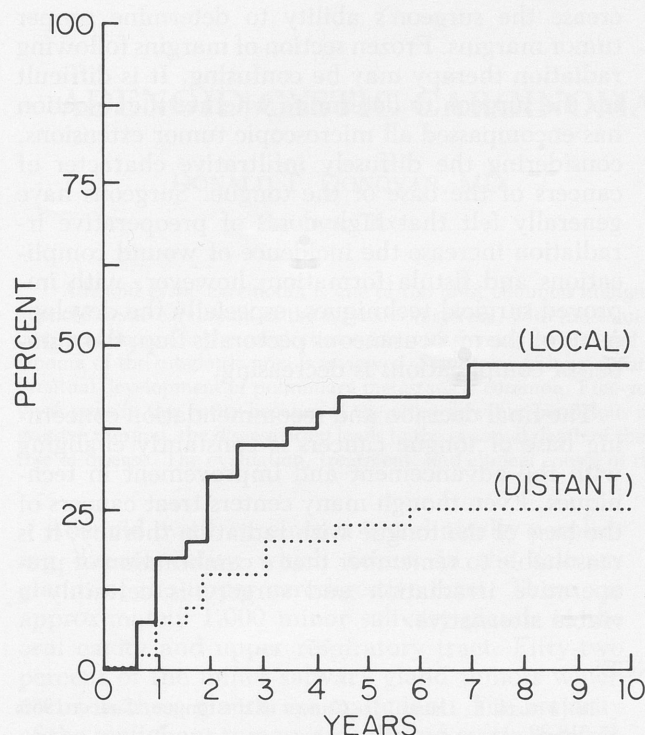


Fig 9. Time to local and distant failure for all patients.

following operation are disappointing.<sup>17,20,22,23</sup> Additional modalities to improve local regional control which should correlate with improved cure rates in this population include the use of linear energy transfer radiation, interstitial irradiation boosts, the utilization of hypoxic-cell sensitizers<sup>24</sup> and the employment of effective preoperative chemotherapy as well as radiation therapy.

A study by Lester and co-workers at the University of Chicago<sup>25</sup> reported favorable responses to combination chemotherapy in 36% of 34 patients with advanced recurrent head and neck cancer, including complete responses in 14% of 28 evaluable patients. They concluded that these objective responses were reflected in increased survival since these patients had a significantly longer median survival than did nonresponders.<sup>25</sup>

Such reports are encouraging not only for the prospect of increasing local control but also because of the possible impact of chemotherapy on the appearance of distant metastases, which may occur in up to 20% of all patients and in higher percentages in those who present with advanced disease.<sup>26</sup> The impact of hypoxic-cell sensitizers on local-regional tumor control and the potential of distant metastases is unknown at present and awaits maturation of current clinical trials such as those being conducted by the radiation therapy oncology group.<sup>24</sup>

Patients with cancer of the oral pharynx who survive their primary malignancy have a significant chance of developing a second malignancy in the upper aerodigestive tract.<sup>26</sup> In a study by Jesse and

TABLE 6. COMPLICATIONS OF COMBINATION TREATMENT

<i>Fatal</i>		<i>Severe</i>	
<i>Complication</i>	<i>No.</i>	<i>Complication</i>	<i>No.</i>
Postoperative pneumonia	2	Fistula	7
Pulmonary embolus	1	Dysphagia	5
Postoperative myocardial infarction	1	Hemorrhage (not carotid)	2
Total	4	Delayed healing	2
		Osteonecrosis of mandible	2
		Tongue fixation	2
		Stricture	2
		Carotid rupture	1
		Postoperative CVA	1
		Edema	1
		Osteomyelitis of mandible	1
		Stridor	1
		Abscess	1
		Total	28*

\*One patient had 2 severe complications.

Sugarbaker,<sup>17</sup> 37% of their patients who survived 5 years after diagnosis of carcinoma of the oral pharynx developed a second primary cancer in derivatives of the embryonic foregut. Those second primary sites were divided almost equally between the oral cavity, hypopharynx, and the esophagus and lung. Of note, the second cancer generally occurred in patients who had early stage, ie, T1 through T2, N0 oropharyngeal primaries. This is similar to the results seen in our series and is reasonable to expect since these are patients who are successfully treated initially. Common etiologic factors of tobacco and alcohol are cited to explain these multiple cancers.<sup>27</sup> As treatment of second malignancies is generally unsuccessful, it would appear that preventive measures aimed against smoking and alcohol intake, as well as treatment, should be a primary effort in this disease.

Cancers of the base of the tongue generally tend to be diffusely infiltrative and more extensive than clinical examination suggests. Understaging is probably frequently reflected by similar control rates for early and moderately advanced lesions both in our series and in others. Because of the more extensive disease than is clinically apparent, surgical or radiation techniques that treat very limited volumes of tissue commonly will result in recurrent disease. Bilateral cervical regional lymphatics should be comprehensively treated since failure in the contralateral neck is not unusual.

TABLE 7. INCIDENCE OF SUBSEQUENT PRIMARY CANCERS BY STAGE

<i>Stage</i>	<i>Incidence</i>	<i>%</i>
I	2/4	50
II	3/9	33
III	11/42	29
IV	4/46	11
Total	20/101	22



The theoretical advantages of preoperative radiation therapy combined with surgery are as follows:

1. There is theoretic potential to decrease the number of micrometastases occurring at the time of surgery in a lesion which has been treated with preoperative radiation therapy.
2. By decreasing the amount of preoperative irradiation therapy as compared to a full course of radiation therapy, the morbidity secondary to irradiation should be less.
3. The amount of radiation given to the necks preoperatively should be enough to control regional cervical metastatic disease.
4. The amount given to the primary tumor should be enough to control the peripheral edges of the tumor which are well oxygenated, thus decreasing the bulk of the primary tumor.<sup>28, 29</sup>

The use of preoperative radiation therapy does have certain disadvantages. The tumor regression produced by the preoperative radiation may de-

crease the surgeon's ability to determine proper tumor margins. Frozen section of margins following radiation therapy may be confusing. It is difficult for the surgeon to determine whether the resection has encompassed all microscopic tumor extensions, considering the diffusely infiltrative character of cancers of the base of the tongue. Surgeons have generally felt that high doses of preoperative irradiation increase the incidence of wound complications and fistula formation; however, with improved surgical techniques, especially the development of the myocutaneous pectoralis flap, the number of complications is decreasing.

The final decision and recommendation concerning base of tongue cancers is constantly changing with the advancement and improvement in techniques. Even though many centers treat cancers of the base of the tongue with radiation therapy, it is reasonable to remember that a combination of preoperative irradiation and surgery is certainly a viable alternative.

#### REFERENCES

1. Harrold C. Surgical treatment of cancer of the base of the tongue. *Am J Surg* 1967; 114:247-51.
2. Novack A. Treatment of carcinoma of the base of the tongue and the larynx. *Laryngoscope* 1975; 89:1332-43.
3. Whitaker LA, Lehr HB, Askovitz SI. Cancer of the tongue. *Plast Reconstr Surg* 1972; 50:363-70.
4. Spiro R, Strong E. Surgical treatment of cancer of the tongue. *Surg Clin North Am* 1974; 54:233-9.
5. Dalley VM. The place of radiotherapy in the treatment of tumors of the base of the tongue. *AJR* 1965; 93:20-8.
6. Rollo J, Rosenbom CV, Thawley SE, Korba A. Squamous carcinoma of the base of the tongue. *Cancer* 1981; 47:333-42.
7. Spanos W Jr, Shykovsky L, Fletcher G. Time, dose, and tumor volume relationships in irradiation of squamous cell carcinomas of the base of the tongue. *Cancer* 1976; 37:2691-9.
8. Blumberg A, Fu K, Phillips T. Results of treatment of carcinoma of the base of the tongue, the UCSF experience, 1957-1976. *Int J Radiat Oncol Biol Phys* 1979; 5:1971-6.
9. Scanlon PW, Soule EH, Devine KD, McBean JB. Cancer of the base of the tongue. *Radiology* 1969; 105:26-36.
10. Fletcher G. *Textbook of radiotherapy*. 3rd ed. Philadelphia: Lea & Febiger, 1980.
11. Crews Q, Fletcher G. Comparative evaluation of the sequential use of irradiation and surgery in primary tumors of the oral cavity, oropharynx, larynx and hypopharynx. *AJR* 1971; 111:73-7.
12. Whicker JH, DeSanto LW, Devine KD. Surgical treatment of squamous cell carcinoma of the base of the tongue. *Laryngoscope* 1972; 82:1853-60.
13. Sessions DG, Stallings JO, Brownson RJ, Ogura JH. Total glossectomy for advanced carcinoma of the base of the tongue. *Laryngoscope* 1971; 81:39-50.
14. Donald PJ. Complications of combined therapy in head and neck carcinomas. *Arch Otolaryngol* 1978; 104:329-32.
15. Dupont A, Guillaumondegui O, Jesse R. Surgical treatment of advanced carcinomas of the base of the tongue. *Am J Surg* 1978; 114:501-3.
16. Frazell E, Lucas J Jr. Cancer of the tongue. *Cancer* 1962; 15:218-32.
17. Jesse R, Sugarbaker E. Squamous cell carcinoma of the oropharynx: why we fail. *Am J Surg* 1976; 132:435-8.
18. American Joint Committee for Cancer Staging and End Results Reporting. *Manual for staging of cancer*. Chicago: 1977, 33-5.
19. Parsons JT, Million RR, Cassisi NR. Carcinoma of the base of the tongue: results of radical irradiation with surgery reserved for irradiation failure. *Laryngoscope* 1982; 92:689-96.
20. Gelinas M, Fletcher G. Incidence and causes of local failure of irradiation in squamous cell carcinoma of the faucial arch, tonsillar fossa and base of tongue. *Radiology* 1973; 108:383-7.
21. Riley RW, Fee WE, Goffinet D, Cox R, Goode RL. Squamous cell carcinoma of the base of the tongue. *Otolaryngol Head Neck Surg* 1983; 91:143-50.
22. Schleuning AJ, Summers GW. Carcinoma of the tongue: review of 220 cases. *Laryngoscope* 1972; 82:1446-54.
23. Williams RG. Recurrent head and neck cancer: the results of treatment. *Br J Surg* 1974; 61:691-7.
24. Wasserman TH, Setz J, Phillips TL. Clinical trials of misomidazole in the United States. *Cancer Clin Trials* 1980; 57:387-96.
25. Lester EP, Kinnealey AM, Matz GJ. Sequential combination chemotherapy for advanced squamous cell carcinoma of the head and neck. *Laryngoscope* 1979; 89:1921-9.
26. Dennington ML, Carter DR, Meyers AD. Distant metastases in head and neck epidermoid carcinoma. *Laryngoscope* 1980; 90:196-201.
27. Schottenfeld D. Alcohol as a co-factor in the etiology of cancer. *Cancer* 1979; 43:1962-6.
28. Strong MS, Vaughan CW, Kayne HL, et al. A randomized trial of preoperative radiotherapy in cancer of the oropharynx and hypopharynx. *Am J Surg* 1978; 136:494-500.
29. Perez C, Marks J, Powers W. Preoperative irradiation in head and neck cancer. *Sem Oncol* 1977; 4:387-97.

# ADENOID CYSTIC CARCINOMA OF THE SUBGLOTTIC REGION

DONALD T. DONOVAN, MD  
HOUSTON, TEXAS

JOHN CONLEY, MD  
NEW YORK, NEW YORK

Adenoid cystic carcinoma is one of the most common malignancies of the minor salivary glands in the head and neck. However, adenoid cystic carcinoma of the larynx is very rare, with less than 75 cases reported in the literature. We present three cases of adenoid cystic carcinoma of the subglottic region with 6-year, 9-year, and 18-year follow-up, respectively. The literature on adenoid cystic carcinoma of the subglottic area is reviewed. Symptoms of long duration, slow progressive growth with tendency for local recurrence, and eventual development of pulmonary metastasis is common. Five-year survival statistics do not appear as relevant as 10- and 20-year survival rates in this entity because of the often slow but pernicious nature of adenoid cystic carcinoma of the subglottic area. Despite aggressive therapy, the disease often leads to the eventual death of the patient. In our series one patient died, and two patients are alive and free of disease. The evaluation, treatment, and clinical course of this disease is discussed.

Adenoid cystic carcinoma is a clinically perplexing disease entity which occurs in the salivary glands of the upper aerodigestive tract. There are approximately 1,000 minor salivary glands in the oral cavity and upper respiratory tract. Fifty-two percent of the minor salivary gland tumors which occur in these glands are malignant. The majority of the malignant tumors are adenoid cystic carcinomas.<sup>1</sup> In a review of 492 cases of mucous gland tumors of the head and neck, Spiro et al<sup>2</sup> found 35% to be adenoid cystic carcinoma.

While minor salivary gland tissue occurs throughout the upper respiratory tract, including the larynx, carcinoma of the mucous glands to the larynx accounts for less than 1% of all malignancies occurring in the larynx. In a review of 888 cases Sessions et al<sup>3</sup> could only find nine cases of carcinoma of mucous gland origin. Of 2,052 cases of carcinoma of the laryngopharynx, Ferlito presented 21 cases that originated in the mucous glands.<sup>4</sup> The Table demonstrates the findings of several large series.<sup>3-7</sup> Adenocarcinoma accounts for less than 0.8% of all laryngeal carcinomas. Adenoid cystic carcinoma accounts for less than 0.25% of all carcinomas of the larynx.

Adenoid cystic carcinoma of the subglottic region is, therefore, an uncommon entity. Evaluating the incidence and nature of adenoid cystic carcinoma of the larynx and subglottic area is made difficult because of several factors. First, the multiplicity of names under which adenoid cystic carcinoma has appeared in the literature has made review of previous experience difficult. Secondly, as Olofsson and Van Nostrand<sup>8</sup> have pointed out previously, difficulty in reviews has been compounded by the use of the same patients in different series. Third, the rarity of the disease has prevented any large

single experience with this tumor in this location, and as a result, the literature contains a large number of single case reports, many of which had little or no follow-up data that might help delineate the natural history of this disease process or its most appropriate treatment. A review of the literature discloses that there are probably less than 40 documented cases of adenoid cystic carcinoma of the subglottic region. We had three additional cases of adenoid cystic carcinoma of the subglottic region with a description of the characteristic signs and symptoms, diagnostic evaluation, as well as appropriate treatment and prognosis. We also present long-term follow-up of these cases to further clarify the natural history of this disease process.

## HISTORICAL PERSPECTIVE

Billroth is generally credited with the original description of adenoid cystic carcinoma.<sup>9</sup> However, Robin and Laboulbène<sup>10</sup> provided an excellent description of the histopathology of this tumor in 1853, three years before Billroth's earliest description. They described three patients with tumors in the maxillary antrum, parotid gland, and nasal cavity, respectively, which demonstrated the characteristic cylindric structure and provided drawings typical of adenoid cystic carcinoma. They named these lesions "tumeurs heteradentique" because they felt they were glandular tumors arising in nonglandular tissue. In 1856 Billroth presented a case of a lacrimal gland tumor and documented two other tumors with similar histologic findings and coined the term *cylindroma*.<sup>9</sup> This provided a less cumbersome and more descriptive name than Robin's "heteradenic tumors," and it became the most commonly accepted term.

However, progress in studying these tumors was hindered by the lack of consensus regarding nomen-

From the Department of Otorhinolaryngology and Communicative Sciences, Baylor College of Medicine, Houston. This report was made possible in part by a grant from The Moody Foundation, Galveston, Texas.

Presented at the meeting of the American Laryngological Association, New Orleans, April 10-11, 1983.

REPRINTS — Donald T. Donovan, MD, Department of Otorhinolaryngology and Communicative Sciences, Baylor College of Medicine, 1200 Moursund, Houston, TX 77030.



INCIDENCE OF ADENOID CYSTIC CARCINOMA OF LARYNX

Studies	Cancer of Larynx	Adenocarcinoma	Adenoid Cystic Carcinoma
Sessions et al <sup>3</sup>	888	9	3
Ferlito <sup>4</sup>	2,052	—	1
Cady et al <sup>5</sup>	2,500	17	3
Whicker et al <sup>6</sup>	3,100	27	9
Eschwege et al <sup>7</sup>	1,342	—	5
Total	9,882	53	21

clature and a lack of understanding of the origin of these tumors. Tauxe et al<sup>11</sup> gave an excellent review of the early pathology literature regarding this tumor. Histopathologic patterns consistent with adenoid cystic carcinoma have been presented in the past and have been given such names as tubal cancer, proliferating mucous angioma, endothelioma, and hyalin carcinoma, to name a few. In fact, Tauxe et al found the tumor described under no less than 20 different names. Krompecher in 1918 coined the term *basalioma*.<sup>12</sup> Spies in 1930 used the term *adenoid cystic carcinoma* in describing a group of basalioimas.<sup>13</sup> New and Childrey<sup>14</sup> confused the classification by referring to these as adenocarcinoma of the mixed tumor type. (It is probable that MacFarland<sup>15</sup> in his extensive review of mixed tumors of the parotid gland included several adenoid cystic carcinomas.) Dockerty and Mayo<sup>16</sup> in 1942 referred to these tumors as adenocarcinoma of the cylindromatous type and were the first authors since Robin and Laboulbène to stress the propensity of these tumors to invade nerves. Foote and Frazell<sup>17</sup> preferred the term adenoid cystic carcinoma over previous names as it stressed the malignant nature of the tumor and separated it out from other adenocarcinomas of the salivary glands. They attributed the term to Ewing<sup>18</sup> who had used the term as early as 1928. Today, the commonly preferred term is adenoid cystic carcinoma.

#### TOPOGRAPHY OF THE MUCOUS GLANDS OF THE LARYNX

The larynx is lined with ciliated respiratory epithelium throughout its extent, with the exception of the posterior surface of the epiglottis and the free margin of the true cord and a portion of aryepiglottic fold. All of this ciliated mucosa is associated with submucosal mucous glands which are, in fact, invaginations of the glandular structures from the overlying epithelium and not truly submucosal. Glands are scarce in areas that do not have ciliated respiratory epithelium as in those locations mentioned above. The mucous glands are most numerous in the area of the false cords and immediately inferior to the anterior commissure.<sup>19</sup> The laryngeal mucous glands are of the exocrine type and produce seromucinous material almost exclusively. The free surface of the true vocal cords is generally devoid of mucous glands. The location of mucous gland carcinomas of the larynx corresponds very well to the

location of the mucous glands within the larynx. The majority occur in the subglottic and supraglottic area with only a very small number of true glottic adenocarcinomas ever being reported. Tumors of the minor salivary glands of the upper respiratory tract occur most commonly in the oral cavity, oral pharynx, nose, and paranasal sinuses. They occur only rarely in the pharynx and trachea. This may be due in part to the relative density of the mucous glands in these two areas, as there are fewer minor salivary glands in the trachea and larynx compared to the oral cavity. However, these differences in relative density do not appear to completely account for the wide disparity in glandular neoplasms of the oral cavity and nasal area as compared with the larynx and trachea. Minor salivary glands occur along the entire course of the tracheobronchial tree. According to Grillo,<sup>20</sup> adenoid cystic carcinoma is the second most common malignancy of the trachea. But in his experience the most common location of adenoid cystic carcinoma is the carina and lower trachea. In a series of 90 patients with tracheal carcinoma, he had only three with adenoid cystic carcinoma which involved the subglottic larynx. Pearson et al,<sup>21</sup> in a series of 16 cases of adenoid cystic carcinoma of the trachea, found only three of the patients had involvement in the subglottic area.

#### CASE REPORTS

*Case 1.* A 42-year-old woman was in good health until March 1969 when she first noted mild dysphagia and a tender mass in the region of the right thyroid gland. In the summer of 1969, she underwent a right thyroid exploration with right partial thyroidectomy. However, the patient was found to have a neoplasm involving the thyroid gland, trachea, and esophagus. A biopsy was taken and interpreted as adenoid cystic carcinoma. The operating surgeon closed her wound and referred her for further treatment. She was seen in November 1969. A general physiological survey at that time did not demonstrate any evidence of disseminated disease. Endoscopic examination of the patient revealed normal vocal cords, normal supraglottic larynx, but a large submucosal mass in the right subglottic area pushing into the right pyriform sinus. In late November 1969 the patient underwent a right radical neck dissection, total laryngectomy, hypopharyngectomy, and cervical esophagectomy. Histologically she had adenoid cystic carcinoma with extensive invasion of the subglottic area, upper trachea wall, esophagus strap muscles, and paratracheal area. Lymph nodes were negative for tumor. Between November 1969 and May 1970 the patient underwent staged reconstruction of the pharynx and esophagus. She did well, eventually was able to tolerate a soft diet, and was followed as an outpatient. In December 1971 the patient developed a left submandibular mass. The biopsy was positive for metastatic adenoid cystic carcinoma and she underwent a left radical neck dissection. She did well until March 1972 when she developed a mass in the tail of the right parotid gland. A biopsy demonstrated only lymph node hyperplasia. In March 1973 a routine chest x-ray film revealed multiple pulmonary nodules consistent with metastatic disease. In October 1973 the patient developed a left submental mass consistent with recurrent disease. In June 1974 the patient received 3,600 rad to the left submental area with a complete disappearance of the mass. In addition she received 1,500 rad to the right lower lung with reduction in the size of the nodules in that area. She remained stable until the summer of 1976 when she developed severe coughing spasms and a mass at the right anterior neck which was treated with 4,000 rad by megavoltage linear accelerator. The patient's symptoms and mass resolved on this regimen. The patient remained clinically and radiographically stable

until September 1977 when a liver-spleen scan showed an enlarged liver with multiple filling defects. In May 1978 the patient was treated with 2,400 rad to her liver and a 400-rad booster for a subcutaneous nodule in the right flank. She was treated with Adriamycin and 5 fluoro-uracil chemotherapy. However, the disease progressed and the patient died in the summer of 1978.

*Case 2.* The patient is a 70-year-old woman who in the late 1960s first noted shortness of breath and dyspnea on exertion. She was noted to have wheezing on occasion and was treated by her physician for asthma. In the spring of 1976 the patient began to note a gradual change in her voice with increased difficulty in breathing and obstruction of her airway. In June 1976 endoscopy revealed a large subglottic mass extending to the upper trachea. Biopsy of the lesion was consistent with adenoid cystic carcinoma. The patient refused total laryngectomy; however, she consented to and underwent resection of the subglottic area, cricoid, upper trachea, and thyroid gland. She was reconstructed utilizing bipediced cervical skin flaps. The patient did well postoperatively with the exception of a persistent tracheocutaneous fistula secondary to granulation tissue. In January 1977 the patient's tracheal granulations were removed with marked improvement in her airway. She has done well postoperatively since that time. The patient's right vocal cord is mobile, and her left vocal cord is slightly paretic. She has remained in stable condition with no evidence of recurrent disease for 6 years since her initial surgery and continues to do satisfactorily.

*Case 3.* A 58-year-old woman at age 38 in the spring of 1964 developed shortness of breath, eventual upper airway obstruction, and respiratory stress. In May 1964 the patient underwent a neck exploration and was found to have a submucosal mass on the base of the vocal cords at the posterior commissure extending inferiorly along the membranous trachea to the upper tracheal rings. She underwent a thyroidectomy with excision of the mass in the subglottic and upper trachea and had primary closure. Pathology report was consistent with Hashimoto's thyroiditis and cylindroma of the subglottic larynx and trachea. The patient did well following that procedure until February 1978 when she developed shortness of breath, dyspnea on exertion, with eventual two-to-three pillow orthopnea. In July 1978 the patient was seen and found to have a subglottic mass compromising the subglottic airway. The patient underwent a tracheostomy with direct laryngoscopy and biopsy. The biopsy was positive for adenoid cystic carcinoma. The patient underwent a total laryngectomy, cervical tracheal resection, total thyroidectomy, and paratracheal dissection. The closure of the trachea was accomplished with advancement of bipediced chest flaps. The patient did well until August 1981 when she developed a mass in the right neck medial to the right carotid and lateral to the esophagus just superior to the tracheostoma. Excisional biopsy demonstrated a metastatic adenoid cystic carcinoma. She had no other grossly visible or palpable disease in either neck. Following excision, the patient's wound has healed well, she has returned to all of her regular daily activities, and she is currently being followed as an outpatient — 1½ years following treatment of her recurrence. There is no gross evidence of disease at this time.

## DISCUSSION

An extensive review of the literature reveals that there have been 69 well-documented cases of adenoid cystic carcinoma of the larynx. In those cases where the site of origin has been stated, 36 occurred in the subglottic area,<sup>6,8,21-36</sup> 15 have been supraglottic,<sup>6,8,25,27,37-41</sup> four have been transglottic,<sup>25</sup> and three were reported as originating in the glottic area.<sup>7,41,42</sup> The location of the origin of these tumors is consistent with the distribution of mucous glands in the larynx. The three additional cases presented above originated in the subglottic larynx.

In adenoid cystic carcinoma of the subglottic re-

gion, an approximately equal male-to-female distribution appears to exist. In those reports in which the sex was stated, and including the above-mentioned patients, the male-to-female ratio was 17:13. The age range in which the tumor has been reported extends from 26 years of age to 75 years of age with an average of 51 years. There is a peak incidence in the sixth decade. This is very close to the age of the patients of adenoid cystic carcinoma of the supraglottic region where the average age of the patients was 53 years. The patients we have presented demonstrate the wide range over which the disease is known to occur.

The symptoms with which these patients present are most commonly shortness of breath and dyspnea on exertion, as the patients presented in cases 2 and 3 demonstrated, occasionally accompanied by hoarseness. This is in contrast with supraglottic tumors, which most commonly present with hoarseness and dysphagia. Less commonly, patients present with a neck mass as in case 1. It is interesting that several patients have been misdiagnosed as asthmatic and treated for this problem for some time;<sup>20</sup> this was seen in our second case. Pain can be a prominent symptom in some cases. This appears to be due to the propensity of this tumor to invade nerves. Symptoms of adenoid cystic carcinoma of the subglottic larynx often begin insidiously and are often ignored by the patient. Several patients in the literature presented with symptoms that had been present for only 2 or 3 months. The majority of patients present anywhere from 6 months to over 5 years after symptoms were first noted. The patient presented in case 3 had only experienced 3 months of shortness of breath; however, the patient in case 1 experienced symptoms for over 6 months and in case 2 over 5 years. While this reflects the probable slow growth of these tumors, it also signifies that they are often far advanced when first seen.

The diagnosis for the majority of these patients was made either following endoscopy with a biopsy of the subglottic area, or following open neck biopsy. Characteristic findings at endoscopy have been the presence of a submucosal mass, most often with normal respiratory epithelial mucosa overlying the mass in the immediate subglottic area. Depending on the length of the presence of the lesion, the mass may encroach on the pyriform sinus laterally, the upper trachea inferiorly, or extend anteriorly into the thyroid and adjacent neck structures. Each of these circumstances was seen in the patients just presented at some point in their course. While the diagnosis is made only after obtaining tissue for histologic examination, the evaluation of these patients should include a complete physical examination, especially of the neck and related structures, as well as a chest x-ray study and either tomograms of the larynx and trachea or CT scan of the neck and upper chest.



Adenoid cystic carcinoma occurring in other regions of the head and neck has a propensity to develop distant metastasis. In the cases reviewed from the literature, a statement regarding distant metastasis was found in 25 cases. In lesions originating in the subglottic region, distant metastases were seen in only two of 11 cases.<sup>20,31</sup> In supraglottic and glottic tumors, it was seen in nine of 14 cases.<sup>7,25,37,38,41-43</sup> In our patients, only one had developed evidence of distant metastasis. Her disease spread to her lung and her liver. The most common site of metastasis has been the lungs, although spread to the liver and bone have been reported.<sup>25</sup>

Regional spread either by direct local extension or lymphatic metastasis was recorded in two cases of subglottic adenoid cystic carcinoma out of nine in which it was evaluated.<sup>8,25</sup> In contrast, five of nine supraglottic tumors had direct or lymphatic regional spread.<sup>25,37,38,40</sup> In two of our three cases, patients had local extension or regional spread at some point in the course of their disease to date.

Recommendations regarding appropriate treatment for these lesions in the past has been quite variable. These tumors have been treated by local excision, radical excision, radiotherapy alone or in combination with a local or radical excision. There does not appear to be any consensus regarding the best treatment for these lesions. While wide surgical resection is most often the treatment advocated, a review of the literature reveals that in cases in which treatment was indicated, many patients had some form of partial laryngectomy, local excision, or x-ray therapy alone.

Based on a large clinical experience with adenoid cystic carcinoma in other areas of the head and neck,<sup>44</sup> patients in this series were treated with wide surgical resection which included total laryngectomy, resection of the upper trachea, and wide local excision of the surrounding tissue with appropriate reconstruction. In the case of the second patient presented, the biggest operation which could be rationally developed within the constraints of the patient's consent was employed. Local conservative surgical reintervention has been employed in local and regional recurrences with some success as well. Radiation has been judiciously employed in the treatment of recurrent disease and in the treatment of metastasis. Chemotherapy, while attempted to no avail in the first patient, will probably play an increasing role in the future, and further trials to measure the efficacy of cisplatin and other newer agents is warranted.

Long-term results of treatment have been difficult to assess in the past. Most of the individual cases reported in the literature have little or only

short-term follow-up. In the patients with 3- to 5-year follow-up, many have no evidence of disease or good local control. However, in patients with 6- to 10-year follow-up, increasing numbers of patients are alive with disease, or in most cases, dead of disease. Only one patient with greater than 10-year follow-up could be found in the literature. This patient developed several recurrences over many years with eventual distant metastasis and died of her disease 16 years after the onset of her symptoms.<sup>31</sup> The patients presented above have followed similar courses. The patient presented in the first case showed good response to treatment initially, but her disease pursued a relentless course of recurrence and spread, and she succumbed 9 years after her initial diagnosis. The second patient who has no evidence of disease has only been followed for 7 years since her treatment. In case 3 the patient has had two episodes of recurrence but is currently alive and well with no gross evidence of disease. She has now survived 19 years since her initial diagnosis was made. She represents the longest reported survivor of adenoid cystic carcinoma of the subglottic larynx. It is unrealistic to say that she is cured in the light of the nature of adenoid cystic carcinoma of the subglottic region in general, and in the course her disease has followed, in particular. However, she has had long symptom-free intervals over the years and has had good local control up to the present time with the treatment principles advocated above.

In summary, adenoid cystic carcinoma of the subglottic region is an uncommon entity which presents with symptoms of shortness of breath, dyspnea on exertion, and occasionally hoarseness, and pain often of long duration. Physical findings are usually that of a submucosal or subglottic mass which not infrequently spreads to local tissue. The natural history of the disease appears to be one of slow progressive growth. Untreated, it leads to airway obstruction, invasion of local tissue, distant metastasis, and death. With adequate local treatment, the natural history appears to be one of local recurrence and distant metastasis, most commonly in the lungs. This disease often follows a slow but pernicious course. The recommended treatment is the biggest operation that is rationally feasible. Recurrences should be managed by wide local reexcision. Radiotherapy is an effective adjunct as the tumor appears to be radiosensitive and radiation can be used to assist local control, or recurrence, or distant metastasis. The role of chemotherapy will probably be expanded in the years ahead, as it is clear from the data presented that despite aggressive surgical therapy the disease often leads to the death of the patient.

#### REFERENCES

1. Batsakis JG. Tumors of the head and neck. 2nd ed. Baltimore; Williams and Wilkins, 1979; 77.
2. Spiro RH, Koss LG, Hajdu SI, Strong EW. Tumors of minor salivary origin. A clinicopathologic study of 492 cases. *Cancer* 1973; 31:117-29.

3. Sessions DG, Murray JP, Bauer WC, Ogura JH. Adenocarcinoma of the larynx. *Can J Otolaryngol* 1975; 4:293-6.
4. Ferlito A. Histological classification of larynx and hypopharynx cancers and their clinical implications. *Acta Otolaryngol (Stockh)* 1976; (suppl 342):1-88.
5. Cady B, Rippey JH, Frazell EL. Non-epidermoid cancer of the larynx. *Ann Surg* 1968; 167:116-20.
6. Whicker JH, Neel HB III, Weiland LH, Devine KD. Adenocarcinoma of the larynx. *Ann Otol Rhinol Laryngol* 1974; 83:487-90.
7. Eschwege F, Cachin Y, Micheau CH. Treatment of adenocarcinomas of the larynx. *Can J Otolaryngol* 1975; 4:290-2.
8. Olofsson J, van Nostrand AWP. Adenoid cystic carcinoma of the larynx. A report of four cases and a review of the literature. *Cancer* 1977; 40:1307-13.
9. Billroth T. Die Cylindergeschwurst in Untersuchungen über die Entwicklung der Blutgefäße: nebst Beobachtungen aus der königlichen Chirurgischen Universitäts-Klinik zu Berlin. Berlin: F Reimer 1856:55-69.
10. Robin C, Laboulbène. Comptes rendus de seances. Memoire sur trois productions morbides non decrites. *C R Soc Biol (Paris)* 1853; 5:185-96.
11. Tauxe WN, McDonald JR, Devine KD. A century of cylindromas. Short review and report of 27 adenoid cystic carcinomas arising in the upper respiratory passages. *Arch Otolaryngol* 1962; 75:364-76.
12. Krompecher E. Der Basallzellen Krebs. *Arch Laryngol Rhinol* 1918; 31:443-9.
13. Spies JW. Adenoid cystic carcinoma. Generalized metastases in three cases of basal cell type. *Arch Surg* 1930; 21:365-404.
14. New GB, Childrey JH. Tumors of the tonsil and pharynx (three hundred and fifty-seven cases). II. Adenocarcinomas of the mixed tumor type (seventy-four cases). *Arch Otolaryngol* 1931; 14:699-712.
15. MacFarland J. Three hundred mixed tumors of the salivary glands, of which sixty-nine recurred. *Surg Gynecol Obstet* 1936; 63:457-68.
16. Dockerty MB, Mayo CW. Primary tumors of the submaxillary gland with special reference to mixed tumors. *Surg Gynecol Obstet* 1942; 74:1033-45.
17. Foote FW Jr, Frazell EL. Tumors of the major salivary glands. In: Atlas of tumor pathology. Washington DC: US Armed Forces Institute of Pathology, 1954; see IV, fasc 11:103-15.
18. Ewing J. Neoplastic diseases: a treatise on tumors. 3rd ed. Philadelphia: WB Saunders, 1928.
19. Nassar VH, Bridger GP. Topography of the laryngeal mucous glands. *Arch Otolaryngol* 1971; 94:490-8.
20. Grillo HC. Tracheal tumors: surgical management. *Ann Thorac Surg* 1978; 26:112-25.
21. Pearson FG, Thompson DW, Weissberg D, Simpson WJK, Kergin FG. Adenoid cystic carcinoma of the trachea: experience with 16 patients managed by tracheal resection. *Ann Thorac Surg* 1974; 18:16-29.
22. Bardwil JM, Reynolds CT, Ibanez ML, Luna MA. Report on one hundred tumors of the minor salivary glands. *Am J Surg* 1966; 112:493-7.
23. Baydur A, Gottlieb LS. Adenoid cystic carcinoma (cylindroma) of the trachea masquerading as asthma. *JAMA* 1978; 234:829-31.
24. Berdal P, Mylius E. Cylindromas of the respiratory tract, the upper part of the digestive tract and adjoining organs. *Acta Otolaryngol (Stockh)* 1954; (suppl 118):32-44.
25. Toomey JM. Adenocarcinoma of the larynx. *Laryngoscope* 1967; 77:931-61.
26. Dallachy R. Adenoid-cystic carcinoma of the larynx. *J Laryngol Otol* 1969; 83:1013-21.
27. Fleisher K, Glanz H, Kleinsasser O. Adenoidzystische Karzinome des Kehlkopfes. *Laryngol Rhinol Otol (Stuttg)* 1978; 57:218-24.
28. Ide D, Cahn HL. Subglottic cylindroma: with special reference to its clinical course. *Laryngoscope* 1948; 58:328-35.
29. Kramer R, Som ML. Cylindroma of the upper air passages. A cylindromatous type of mixed tumor. *Arch Otolaryngol* 1939; 29:356-70.
30. Leroux-Robert J. Panel discussion on glottic tumors. IV. A statistical study of 620 laryngeal carcinomas of the glottic region personally operated upon more than five years ago. *Laryngoscope* 1975; 85:1440-52.
31. Leroux-Robert J, Courtial C. Tumeurs mixtes et cylindromes du larynx. *Ann Otolaryngol (Paris)* 1965; 82:1-14.
32. Mankodi RC, Shah RM. Laryngeal adenoidcystic carcinoma. *J Postgrad Med* 1979; 25:115-6.
33. Pietratoni L, Leonardelli GB. La malignité des cylindromes; considerations anatomocliniques sur 22 cas de cylindromes de l'extrémité cephalique. *Ann Otolaryngol (Paris)* 1957; 74:15-31.
34. Pincini G, Mandelli PG. Subglottic cylindroma? *Minerva Otorhinolaryngol* 1921; 21:219-23.
35. Ranger D, Thackray AC, Lucas RB. Mucous gland tumors. *Br J Cancer* 1956; 10:1-16.
36. Soboroff BJ. Cylindromas of the upper digestive and respiratory passages — a correlative study of their histologic patterns, clinical findings and modes of therapy. *Laryngoscope* 1959; 69:1381-410.
37. Adams GL, Duvall AJ III. Adenocarcinoma of the head and neck. *Arch Otolaryngol* 1971; 93:261-70.
38. Ahued SV. Cylindroma of epiglottis. Report of a case and review of the literature. *Arch Otolaryngol* 1956; 63:366-71.
39. Gross CW, Nakamura T, Maguda TA, Gros JC. Malignant minor salivary gland tumors — a report of 32 cases. *Can J Otolaryngol* 1974; 3:56-63.
40. Putney FJ, McStravog LJ. Salivary gland type tumors of the head and neck. *Laryngoscope* 1954; 64:285-97.
41. Spiro RH, Hajdu SI, Lewis JS, Strong EW. Mucus gland tumors of the larynx and laryngopharynx. *Ann Otol Rhinol Laryngol* 1976; 85:498-503.
42. Suehs OW. Cylindroma (adenoid-cystic carcinoma) of the larynx and trachea. *Tex State J Med* 1960; 56:934-44.
43. Havens FZ, Parkill EM. Tumors of the larynx other than squamous cell epithelioma. *Arch Otolaryngol* 1941; 34:1113-22.
44. Conley J, Dingman DL. Adenoid cystic carcinoma in the head and neck (cylindroma). *Arch Otolaryngol* 1974; 100:81-90.



# MUSCULAR TENSION DYSPHONIA

MURRAY D. MORRISON, MD, FRCS(C)

VANCOUVER, BRITISH COLUMBIA

LINDA A. RAMMAGE, BA, MSc

VANCOUVER, BRITISH COLUMBIA

C. BRUCE PULLAN, MA

BILLINGHAM, WASHINGTON

GILLES M. BELISLE, MD

SHERBROOKE, QUEBEC

HAMISH NICHOL, MD, FRCP(C)

VANCOUVER, BRITISH COLUMBIA

Muscular tension dysphonia (MTD) is a condition commonly seen in young and middle-aged women. It is manifested by excess muscle tension in the paralaryngeal and suprahoid areas, an open posterior glottic chink, larynx rise, and frequently by mucosal changes on the vocal cords. These mucosal changes are usually fleshy vocal nodules (VN). About 80% of VNs are found in patients exhibiting features of MTD. The two types of VNs require different therapeutic approaches. One hundred out of 500 patients seen consecutively at the Voice Clinic at the University of British Columbia exhibited the features of MTD. These patients are discussed and an etiologic hypothesis is presented.

In the two years following December 1980, approximately 500 patients visited the multidisciplinary Voice Clinic at the University of British Columbia. Among this group were approximately 100 who had been given the diagnosis of "vocal nodules" (VNs) or "chronic recurring laryngitis." Many of these patients were professional voice users. Throughout the first year of the clinic, we began to make more detailed observations about the precise nature of the problem in this group of patients. Several were enthusiastic singers and at a follow-up joint visit with the otolaryngologist, the speech pathologist, and the voice teacher, certain postural misuses and tight muscle groups were noticed. These patients tended to jut the chin forward and upward. The atlanto-occipital and upper cervical spine areas were held in extension. Head and neck palpation revealed an excessive degree of tension in the suprahoid muscle groups in the midline. Many of these patients were noted laryngoscopically to have a rather widely open posterior glottic chink between the arytenoid cartilages which extended a short distance anterior to the vocal processes. A number also had fleshy VNs at the point of apposition of the vocal cords. It was noted that the muscular tightness in the suprahoid area increased with an increasing vocal pitch or loudness and the larynx could be seen to rise in the neck as the sung pitch increased up the scale. This larynx rise was also easily seen on the videotaped laryngoscopy.

While working in the Voice Clinic with several of the patients exhibiting these features, we were able to demonstrate that the posterior glottic chink could be narrowed through various singing techniques designed to relax muscle groups or to change resonance, and that by doing this an easier voice would result.

This symptom and sign complex does not exist only in untrained singers but also is commonly seen in other patients, such as school teachers, who usually have stress-related vocal activity.

Throughout the following year, we became aware of the consistency and predictability of these clinical features and began to use the term "muscular tension dysphonia" (MTD). We also developed a hypothesis to explain the cause of the posterior glottic chink and subsequent mucous membrane changes on the vocal cords.

## CLINICAL FEATURES AND CLASSIFICATION

*Type I.* In MTD type I the larynx is structurally normal (Fig 1A). On phonation, however, an open posterior glottic chink is left between the arytenoid cartilages (Fig 1B). The medial surfaces of the cartilages do not appose and they are angled somewhat towards the point at which the vocal cords eventually come together near their middle. The vocal cords themselves have a convexity medially so that only the anterior half, or slightly more than half, of the vocal cords are directly apposed. On indirect laryngoscopy, the larynx is noted to move closer to the mirror during pitch increase and away from the mirror during pitch decrease on a sung scale. When palpating the suprahoid musculature within the mandibular arch from below, the digastric and mylohyoid muscles are noted to be very tight on phonation. The jaw is often protruded while singing and at rest.

*Type IIA.* In MTD type IIA the same changes associated with type I are seen with the addition of chronic changes that have taken place in the mucosal lining of the vocal cords. In most patients, this takes the form of VNs in the usual position at the

From the Division of Otolaryngology (Morrison), the Voice Clinic (Rammage, Pullan), and the Department of Psychiatry (Nichol), University of British Columbia, Vancouver; and the Department of Otolaryngology, University of Sherbrooke, Quebec (Belisle).

Presented at the meeting of the American Laryngological Association, New Orleans, April 10-11, 1983.

REPRINTS — Murray D. Morrison, MD, Division of Otolaryngology, 865 West 10th Avenue, Vancouver, BC, V5Z 1L7, Canada.

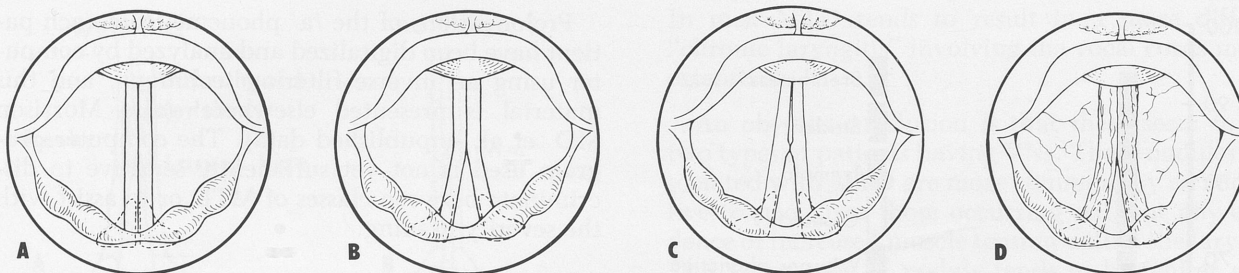


Fig 1. Laryngoscopic findings in various types of muscular tension dysphonia. A) Normal larynx. B) MTD type I, posterior chink only. C) MTD type II A, posterior chink with nodules. D) MTD type II B, posterior chink with chronic laryngitis.

junction of the anterior and middle third of the cords (Fig 1C). These nodules tend to be rather fleshy and sessile and associated with a variable amount of edema elsewhere in the cords. This type of mucosal change was found to be more common in girls, women, and boys rather than in men.

**Type IIB.** Muscular tension dysphonia type IIB (Fig 1D) shows similar features of posterior chink, larynx rise, and characteristic posture, but the mucosal changes within the cord are more diffuse and involve the whole length of the vocal cord. Most of these patients have been previously diagnosed as having chronic laryngitis. There are an equal number of males and females in this group.

**Patient Population.** Approximately one fifth of all patients referred to the multidisciplinary Voice Clinic have now been identified as having the signs and symptoms of MTD. The first 86 patients given this diagnosis have been studied in considerable detail.

Figure 2 shows the overall incidence by diagnosis and by sex. The nine patients labelled as having VNs were those in whom the nodules were not associated with the other features of MTD. As noted above, MTD with coexisting VNs is classified as type IIA, which is the most common form of MTD. The overwhelming preponderance of females in types I and IIA is clear. Interestingly, the average

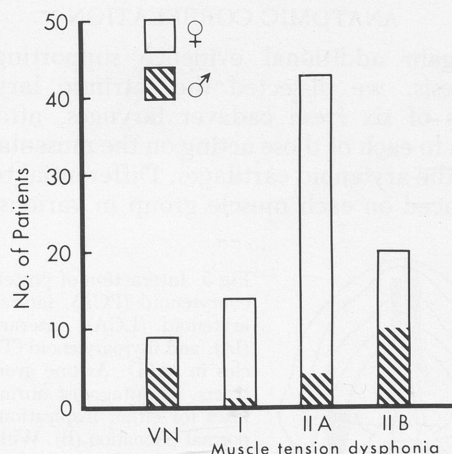


Fig 2. Incidence by diagnosis and by sex of non-MTD VNs and MTD from among 500 consecutive Voice Clinic patients.

age of males in MTD type IIA was 13, indicating that types I and IIA are almost exclusively seen in females and prepubertal males. The adult males with MTD are found in MTD type IIB associated with chronic laryngitis.

The average age of patients in the group with MTD type I was 36 and in the group with MTD type IIA the average age was 28. In the group with MTD type IIB the average age was 40.

The videotaped laryngoscopic recordings of each patient were viewed by an independent observer. The overall visual severity of the condition based on the size of the posterior chink, the size of the VNs, or the severity of the chronic laryngitis was graded using the Jewish Hospital scale, in which 1 and 2 are mild, 3, 4, and 5 are moderate, and 6 and 7 are severe. Figure 3 shows that patients with MTD type I exhibit posterior glottic chinks that are relatively small in size, having been given a severity rating of 1, 2, or 3. Severity ratings of MTD types IIA and IIB spread up into the moderate and severe categories.

A trained listener appraised the voice quality of all MTD patients as recorded on audiotape. Only a

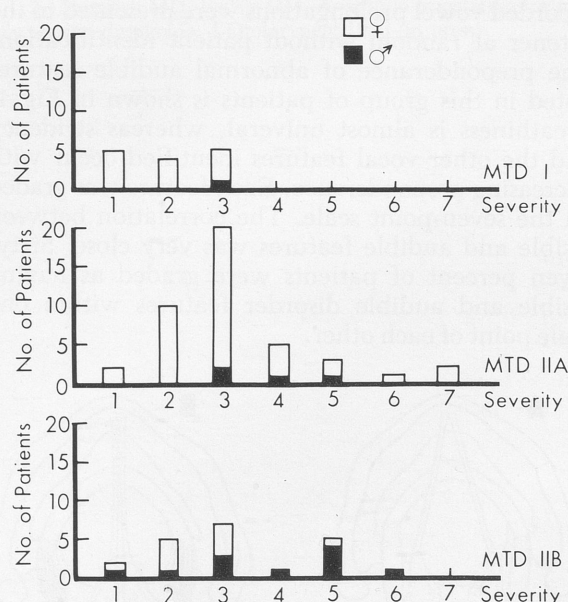


Fig 3. Severity scale ratings on size of VNs and/or size of open posterior glottic chink in cases of MTD.



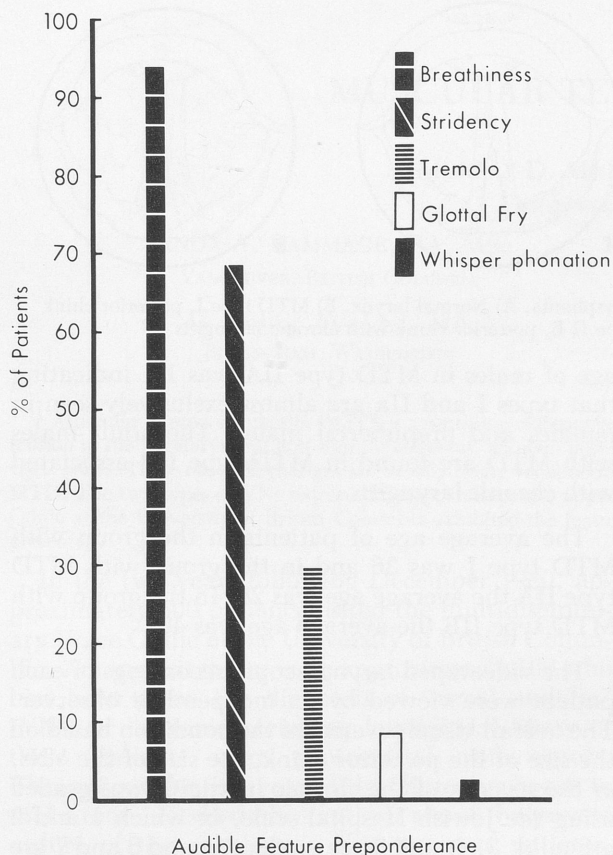


Fig 4. Preponderance of abnormal audible characteristics associated with MTD.

prolonged /a/ phoneme was assessed because only this amount of information is currently being acoustically analyzed by the computer. It was our wish to compare audible voice abnormalities with those detectable by computer acoustic analysis. The recorded vowel prolongations were presented to the listener at random without patient identification. The preponderance of abnormal audible features noted in this group of patients is shown in Fig 4. Breathiness is almost universal, whereas stridency and the other vocal features identified occur with decreasing preponderance. Each feature was graded on the seven-point scale. The correlation between visible and audible features was very close. Sixty-seven percent of patients were graded as having visible and audible disorder features within one scale point of each other.

Prolongations of the /a/ phoneme from each patient have been digitalized and analyzed by computer using an inverse filtering technique, and this material is presented elsewhere<sup>1</sup> (also Morrison MD et al, unpublished data). The computer program used is not yet sufficiently sensitive to discriminate between classes of MTD or to assist with the severity grading.

#### PATHOPHYSIOLOGIC HYPOTHESIS

Most patients with MTD seem to have problems coping with stress. Tightness in paralaryngeal muscle areas was undeniably confirmed by direct visualization and palpation. This implied to us that the intrinsic muscles of the larynx would be in a similarly tense state. When these muscles are normally relaxed, phonation is permitted by the contraction of lateral cricoarytenoid and interarytenoid muscles with simultaneous relaxation of the posterior cricoarytenoids, with the reverse occurring during inspiration (Fig 5A,B). In MTD (Fig 5C), the inability of the opposing intrinsic laryngeal muscles to relax adequately inhibits the proper functioning of the contracting muscle group. Thus, during phonation the lateral cricoarytenoid and interarytenoid muscles contract; however, the posterior cricoarytenoid muscles do not relax adequately. This prevents the arytenoid cartilages from moving fully medially to close the glottis. To compensate for the space between the arytenoid cartilages and to produce any sound at all, the thyroarytenoid muscles within the soft tissue of the vocal cords must tighten further to achieve some apposition of the cords more anteriorly. This produces convex reverse bowing of the glottic aperture and the consequent space in the posterior glottis. Understandably, excessive phonation through a tense larynx will eventually lead to mucosal changes on the vocal cords. These changes usually consist of fleshy VNs. Less commonly, diffuse edema and fibrosis of the vocal cords develops.

#### ANATOMIC CORRELATION

To gain additional evidence supporting this hypothesis, we dissected the intrinsic laryngeal muscles of six fresh cadaver larynges, attaching threads to each of those acting on the muscular process of the arytenoid cartilages. Differential tension was placed on each muscle group in various com-

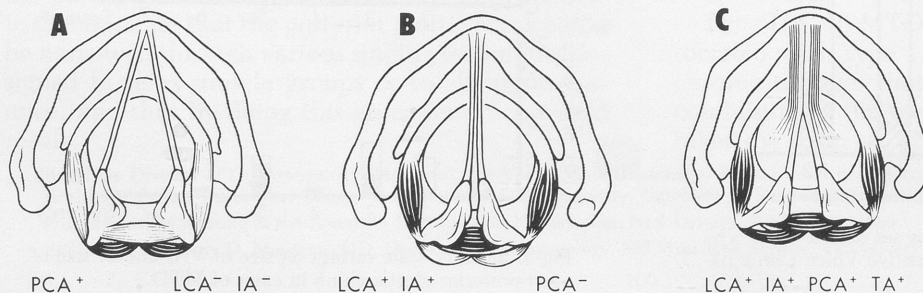


Fig 5. Interaction of posterior cricoarytenoid (PCA), lateral cricoarytenoid (LCA), interarytenoid (IA), and thyroarytenoid (TA) muscles in MTD. As one group contracts, its antagonist normally relaxes for either inspiration (A) or normal phonation (B). With MTD, insufficient relaxation of posterior cricoarytenoid is counteracted by overcontraction of thyroarytenoids (C).

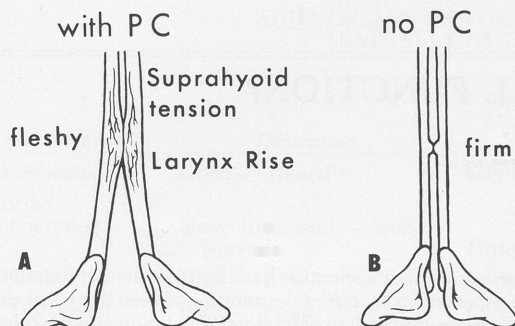


Fig 6. Two types of VNs. A) Nodules associated with MTD exhibit a posterior glottic chink, suprahyoid tension, larynx rise, and fleshy, edematous nodules. B) Nodules occurring in absence of MTD are firmer and not associated with posterior glottic chink.

binations and the resultant glottic shapes were recorded photographically and on videotape. Videotape recordings of the cadaver larynges were taken using the same equipment used for the patient population. Any increased tension on the posterior cricoarytenoids could be easily seen to be preventing normal closure of the posterior glottis. The glottal shapes produced closely resembled those seen in MTD. Detailed results of this study are presented elsewhere.<sup>2</sup>

#### DISCUSSION

The clinical features of MTD have been found to be consistent and predictable. This disease is mostly found in females but when it does occur in males it tends to result in a different type of mucosal change. In females and boys, MTD produces fleshy VNs in association with posterior glottic chink, increased suprahyoid muscle tension, and larynx rise.

In men MTD tends to result in a more diffuse "chronic laryngitis" involving the vocal cords more extensively.

An obvious conclusion is that there seem to be two types of patients having VNs. Those nodules associated with MTD are more common, by a ratio of five to one, over those occurring without any evidence of increased muscle tension within the larynx. This latter type of nodule tends to be whiter and firmer, and seems to resolve more slowly with voice therapy alone. The clinical differentiation of VNs into two types has significant management implications. Muscular tension dysphonia type IIA is a disorder of muscle function and is related to difficulties dealing with stress and other abnormalities of behavior. Voice therapy and associated psychotherapy form the basis for treatment. Surgery has a very minor role. Vocal nodules without muscular tension should probably be removed surgically in association with pre- and postoperative voice therapy. The basic differences between the two types of VNs are shown diagrammatically in Fig 6.

Muscular tension dysphonia is obviously a type of functional dysphonia, when "dysphonia" is used in a broad sense. Other types of functional dysphonia, such as that associated with ventricular band approximation, bowed vocal cords, or conversion-reaction aphonia, have a much stronger psychiatric component than does the more common MTD described here. In MTD there seems to be a generalized increase in all of the intrinsic and extrinsic laryngeal muscles concurrently, whereas with the other functional or psychiatric dysphonias there may be a specific overactivity or underactivity of various muscle groups.

#### REFERENCES

1. Morrison MD. Computerized evaluation of voice in the assessment of laryngeal pathology. *Trans Pac Coast Otolaryngol Soc* 1982; 63.
2. Morrison MD, Belisle GM. Anatomic correlation for muscle tension dysphonia. *J Otolaryngol* 1983 (in press).



# WHY INVESTIGATE VOCAL FUNCTION?

WILLIAM H. PERKINS, PHD

LOS ANGELES, CALIFORNIA

Lack of research interest in vocal function leaves laryngologists and voice clinicians without a scientific basis for treatment of functional voice disorders. Although pitch regulation has been studied more than any other aspect of voice, our understanding of even this vocal element provides a dubious basis for phonosurgical procedures. Even more dubious is our understanding of loudness regulation and the other elements of vocal control that have been identified, especially insofar as effects of interactions among these elements are concerned. At least four different laryngeal patterns of pitch adjustment are apparent. Thus, prediction of the outcome of treatment of voice by phonosurgery or voice therapy is more a matter of clinical intuition than scientific probability.

A state-of-the-art report of peer-reviewed publications between 1976 and 1982 on assessment and treatment of voice revealed 170 articles.<sup>1</sup> Clearly, spastic dysphonia and laryngeal paralysis have dominated this literature. Some attention has been given to tissue-damaging consequences of vocal abuse, but hardly any reports (two case studies of biofeedback effects on reduction of hyperfunction) have shown interest in evaluating effectiveness of voice therapy. What is most notable by its absence, however, is any attention to causes of vocal abuse or to the nature of laryngeal functioning in any form of phonation, whether abusive or optimal.

## IMPLICATIONS OF VOCAL FUNCTION FOR PHONOSURGERY

The price of this lack of interest in vocal function is paid by the laryngologist as well as by the voice clinician. Voice clinicians have nothing but intuition and personal impressions on which to base voice therapy. The extent of effectiveness of their treatment is virtually unknown, at least by scientific standards. Laryngologists, who have responsibility for patients whose complaints range from nodules and polyps to myasthenia laryngis and vocal fatigue,<sup>2</sup> must base their therapy on the best understanding available to them of how the larynx functions in production of the various elements of voice.

Eleven of these elements have been identified to date.<sup>1</sup> There may be more, but probably not many more. Just as painters can produce any color from three primary colors, so can speakers or singers produce any tones of which their voices are capable by adjusting the various vocal elements. The importance of these elements to voice clinicians is that with them, voices can be tuned to improved levels of efficiency. These are the elements that the clinician adjusts in voice therapy.

For laryngologists, the importance of under-

standing the vocal elements is less direct, but equally, if not more, significant. Any phonosurgical procedure intended to improve phonatory quality is based on an assumption about the relationship between laryngeal function and the voice that is produced. Unfortunately, our current understanding of these relationships hardly scratches the surface of the effects on voice of the complex interactions among vocal elements and related physiological functions. We will examine this premise by using two of the most familiar elements, pitch and loudness, for illustration.

## IMPLICATIONS OF PITCH CONTROL

Physiologically, the laryngeal factors which presumably control pitch, as well as all of the other vocal elements, are cord mass and stiffness. These are the myoelastic factors that can be adjusted rapidly enough to be functionally related to rapidly changing elements of voice, especially pitch. Vocal cord viscosity is also a factor, but it does not seem to be subject to the rapid alterations needed for voice regulation, so we will not include it in our discussion.

Historically, cord length has been considered to be a factor for adjusting pitch by virtue of stretching the vocal cords. By analogy to string instruments, the amount of tension in the cord has been presumed to be a result of the extent to which it is stretched. Carrying this analogy further, falsetto adjustment has been thought to be a condition in which the vocal ligament is stretched to its limit so that falsetto pitch changes are made by adjusting tension in that ligament.

Current evidence does not support either of these conceptions of vocal physiology. The vocal ligament is known to be longer when abducted than it is for any phonatory adjustment, including falsetto.<sup>3</sup> Therefore, it cannot be considered to be stretched to its limit for any form of phonation. Accordingly,

From the Department of Communication Arts and Sciences, Otolaryngology and Speech Science and Technology, University of Southern California, Los Angeles.

Presented at the meeting of the American Laryngological Association, New Orleans, April 10-11, 1983.

ADJUSTMENTS OF VOCAL ELEMENTS FOR OPTIMALLY EFFICIENT,  
MINIMALLY HYGIENIC, AND COMPENSATORY TUNING

<i>Vocal Element</i>	<i>Dimension</i>	<i>Appropriate Measurement Scale</i>	<i>Optimal Scale Value</i>	<i>Optimally Efficient</i>	<i>Clinical Value</i>	
					<i>Minimally Hygienic</i>	<i>Compensatory for Vocal Abuse</i>
Constriction	Open — Closed	Ordinal ratio	Open	Vital	Important	Vital
Focus						
Sharpness	Sharp (compact) — Dull (spread)	Ordinal ratio	Sharp	Vital	Important	Important
Vertical	High — Low	Ordinal ratio	High	Vital	Vital	Important
Horizontal	Back — Front	Ordinal ratio	Personal preference	Slight	Slight	Slight
Loudness	Soft — Loud	Ordinal ratio	Flexible, wide range	Moderate	Important	Vital
Voicing	Voiced — Voiceless	Ordinal ratio	Flexible	Moderate	Important	Vital
Size						
Length	Long — Short	Ordinal ratio	Long	Important	Moderate	Moderate
Volume	Large — Small	Ordinal ratio	Large	Important	Moderate	Moderate
Mode	Pulsated — Heavy — Light	Nominal	Heavy	Important	Important	Important
Plane	Level — Sloped	Ordinal ratio	Level	Important	Moderate	Moderate
Pitch	High — Low	Ordinal ratio	Flexible, wide range	Slight	Moderate	Important

any surgical procedure that elongates the vocal cords in an attempt to stretch the vocal ligament, and thereby facilitate phonation, will distort the laryngeal interrelationships by which voice is normally produced.

Although cord length is involved in pitch regulation, it is not by virtue of controlling tension in the vocal folds. Instead, it is the mechanism by which the mass of the folds is thickened or thinned. Length adjustments are systematically related to pitch within any given voice, but they do not correlate well with absolute pitch; the same cord length can result in pitches with more than an octave difference in different voices.<sup>3</sup> Mass, on the other hand, comes closer to correlating with a given pitch.<sup>4</sup> Even so, mass can only account for a portion of the pitch changes possible.<sup>5</sup> Some other mechanism must play a dominant role in pitch regulation.

Vocal cord stiffness, which some still refer to as tension, seems to qualify as that mechanism.<sup>5</sup> It is controlled not by cord length, which would be isotonic tension, but by thyroarytenoid muscle contraction, which provides isometric tension, as Arnold<sup>6</sup> pointed out several years ago. Just as the biceps, for example, can be relaxed or stiff (depending on its contraction) whether the arm is flexed or extended, so can the vocalis muscle be compliant when relaxed or stiff when contracted, irrespective of its length. Thus, phonosurgery that is undertaken to raise or lower pitch by altering vocal fold mass should contribute to the intended result, but this would provide only a gross background adjustment against which neuromuscular fine tuning of cord stiffness would still be required as the major mechanism of pitch control.

## IMPLICATIONS OF LOUDNESS CONTROL

What little research has been done on the physi-

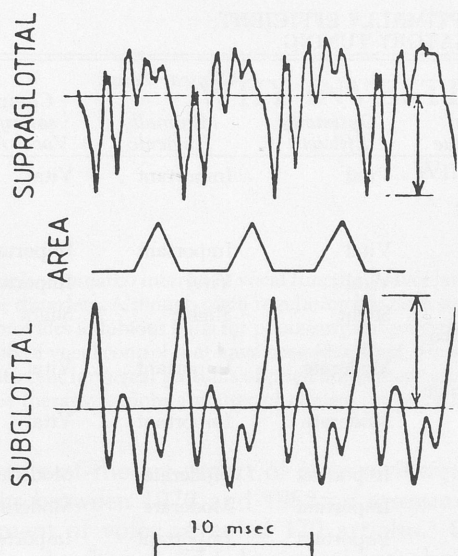
ology of loudness has been done on only a small group of subjects, so very little direct evidence is available. What that evidence suggests is that loudness is largely a function of glottal resistance, subglottal pressure, and airflow.<sup>7</sup> It also indicates that within a glottal cycle, the portion of time that the cords are closed increases with loudness,<sup>8</sup> which means that the cords take longer to absorb the impact of collision with each vibration if the voice is loud rather than if it is soft.

More recently, Sundberg<sup>9</sup> has demonstrated that the abruptness with which air flow through the glottis (GAF) is terminated by cord closure is closely related to loudness. With gradual termination, subglottal pressure is relatively low, the cords do not close completely, and the voice is breathy. As subglottal pressure rises and abruptness of termination increases, so does loudness.

This straightforward relationship of subglottal pressure, GAF termination, and loudness became more complex, though, when Sundberg<sup>9</sup> manipulated a vocal element that he called "pressed" phonation which corresponds to the element "constriction" in the Table. (The Table shows the 11 vocal elements by which voice is controlled, the scale dimensions along which each element can be measured, the optimal scale value of the element when the voice is produced efficiently, and the importance of each element to achievement of three clinical objectives that differ according to vocal needs, interests, and abilities of a patient.) With pressed phonation, the cords were forcefully adducted so that almost twice as much subglottal pressure was required to maintain a loudness level that was much less than that achieved when adduction was moderate.

Pursuing the same line of investigation, Rothen-





Coincidence of peak changes of subglottal and supraglottal pressures with instant of cord closure (shown schematically as area). (Reprinted with permission.<sup>10</sup>)

berg<sup>10</sup> has shown that the opening and closing of the vocal folds during phonation is only indirectly related to the conversion of the volume velocity of air flow into the acoustic signal which the listener hears as loudness. The abrupt termination of air flow, which is the basis for generating a voice with "carrying power," is mainly a function of the extent to which subglottal pressure exceeds supraglottal pressure just prior to the instant of cord closure.

Koike's<sup>11</sup> evidence, which was gathered simultaneously from miniaturized pressure transducers positioned just below and just above the glottis, shows exactly this relationship, as is seen in the Figure. The peak increase in subglottal pressure coincides with the peak decrease in supraglottal pressure, and both reach that peak at the instant prior to cord closure. The Figure also reveals pressure fluctuations of subglottal and supraglottal pressures attributable to tracheal and supraglottal resonances. Rothenberg<sup>10</sup> doubts that tracheal resonance can be adjusted, considering the fixed cavity sizes involved. He argues, however, that tuning of vocal tract resonators so that the peak drop in supraglottal pressure is timed to coincide with the terminal phase of cord closure would contribute to the pressure differential necessary to produce a powerful voice.

The clinical significance of this evidence is twofold. As far as phonosurgery is concerned, it casts considerable doubt on the efficacy of treating myasthenia laryngis by elongation of the vocal ligament. Loudness is regulated by glottal resistance to subglottal pressure. This resistance can be altered effectively by adjusting cord stiffness. It can also be altered by the extent of adduction, but with excessive medial compression, this technique of obtaining resistance becomes counterproductive and the vocal result resembles spastic dysphonia. To alter glottal

resistance by elongating the cords would produce the reverse of the effect intended. It would thin the mass and thereby reduce resistance rather than increase it.

The other significance of this evidence about the physiology of loudness is that it may hold a clue to the mechanism by which tissue damage is caused by vocal abuse. The location of functional tumors, such as nodules and polyps, at the midpoint of the membranous glottis where cord-closure impact is greatest argues for the prediction that voices in which the cords collide hardest, fastest, and over longest periods would be the most subject to tissue damage.

In untrained voices, this seems to be true. But it does not account for vocal survival of singers and actors especially, who use their voices at pitch and loudness extremes requiring greater impactful cord closures than most laymen manage for spectator sports. Whereas we novices are hoarse after one game, professionals' voices can remain clear after two- to four-hour performances, often daily, and sometimes with matinees, twice daily. Their careers depend on vocal survival. Although some do not survive, many remain trouble-free throughout their professional lifetimes. Clearly, they use quite different vocal adjustments than do mere vocal mortals with untrained voices.

*Clinical Implications.* What the evidence we reviewed in this section points to are two different types of loudness control, one by obtaining the necessary subglottal-supraglottal pressure difference with glottal resistance, the other by obtaining it with vocal tract resonance tuning. With glottal resistance, vocalis contraction is required to stiffen the cords to provide the necessary opposition to subglottal pressure. Increased loudness requires increased pressure which requires increased cord stiffness. By contrast, obtaining the necessary pressure difference with resonator tuning requires less subglottal pressure, hence less glottal stiffness to resist that pressure.

Consider, now, the significance for impact damage of these two adjustment techniques. Using a resonance technique, stiffness (hence, vocalis contraction) would be low relative to a given level of loudness. With this condition, the cords would tend to be compliant and absorptive of impact force, much in the fashion of two soft pads colliding. Using a stiffness adjustment, loudness would be directly related to vocalis contraction; the louder the tone, the stiffer the vocalis would become. With increased stiffness, the cords would become increasingly like two hard pads colliding. Using stiffness as the technique of pitch and loudness control increases the probability of impact damage to the epithelium and superior layer of the lamina propria as these tissues are "hammered" against relatively firm vocalis muscles in a contracted condition. By con-

trast, a resonance technique would apparently minimize vocalis contraction, increase impact absorption, and thereby reduce glottal edge tissue damage.

#### NEED TO UNDERSTAND VOCAL FUNCTION

However the physiology of vocal abuse operates, the fact is self-evident that techniques of vocal control can be learned that will minimize or eliminate it, even under the most strenuous vocal conditions. This means that optimally efficient use of voice involves different adjustments among the vocal elements in the Table than are used in abusive vocal production. Two of the elements in particular, constriction and vertical focus, separate well-trained from untrained voices, professionals consistently keep the feeling of an open throat and a focal point of the tone high in the head. This is how they survive vocally.

The feeling of how the voice is produced is entirely different with a high focus than with a low focus, so presumably, the physiology is equally different. Yet, important as this vocal element is, virtually nothing is known about it scientifically. Glimpses of its effects on loudness and pitch are apparent, however.

With loudness, singing, shouting, even screaming can be sustained without vocal fatigue with an op-

timally high focus. The physiology involved could well be the resonance-tuning adjustment discussed earlier. With pitch, maximum flexibility is available with a high focus. That the physiology of pitch control can vary within the individual, let alone among individuals, was pointed up by research in which a semi-trained vocalist performed much the same pitch changes four times. Each time, the pattern of physiological adjustments being measured differed drastically from each other; in two attempts, the patterns were completely reversed.<sup>12</sup> Whether these differences were attributable to differences in vertical focus was not studied in the experiment. Whatever the basis, the fact is evident that pitch regulation can involve at least four different patterns of adjustment.

#### CONCLUSION

The point of this brief analysis of vocal function is that behaviorally and physiologically, vocal control is far more complex than our scientific literature would indicate. Pitch is the only vocal element which has been studied to any extent, but even those investigations have hardly covered the surface of its multiple interactions with the other vocal elements. Against this dearth of understanding of vocal function, the voice clinician and laryngologist must make patient-care decisions without scientific basis for determining what should be done for the voice and what the predicted outcome would be.

#### REFERENCES

1. Perkins W. Assessment and treatment of voice disorders: state of the art. In: Costello J, ed. Recent advances: speech disorders in adults. San Diego: College-Hill Press (in press).
2. Sander E, Ripich D. Vocal fatigue. *Ann Otol Rhinol Laryngol* 1983; 92:141-5.
3. Hollien H, Moore P. Measurements of the vocal folds during changes in pitch. *J Speech Hear Res* 1960; 3:157-65.
4. Hollien H. Vocal fold thickness and fundamental frequency of phonation. *J Speech Hear Res* 1962; 5:237-43.
5. Zemlin W. Speech and hearing science. Englewood Cliffs, NJ: Prentice-Hall, 1981.
6. Arnold G. Physiology and pathology of the cricothyroid muscle. *Laryngoscope* 1961; 71:687-753.
7. Isshiki N. Regulatory mechanisms of voice intensity variation. *J Speech Hear Res* 1964; 7:17-29.
8. Fletcher W. A study of internal laryngeal activity in relation to vocal intensity [Dissertation]. Northwestern University, 1950.
9. Sundberg J. The voice as a sound generator. In: Sundberg J, ed. Research aspects on singing. Stockholm: Royal Swedish Academy of Music, 1981.
10. Rothenberg M. The voice source in singing. In: Sundberg J, ed. Research aspects on singing. Stockholm: Royal Swedish Academy of Music, 1981.
11. Koike Y. Sub- and supraglottal pressure variation during phonation. In: Stevens K, Hirano M, eds. Vocal fold physiology. Tokyo: University of Tokyo Press, 1981.
12. Perkins W, Yanigahara N. Parameters of voice production: I. Some mechanisms for regulation of pitch. *J Speech Hear Res* 1968; 11:246-67.



# EFFECTS OF STOMACH ACID ON THE LARYNX

NELS R. OLSON, MD

ANN ARBOR, MICHIGAN

Gastroesophageal reflux (GER) is being recognized as the cause of common laryngeal symptoms and diseases, some of which have been attributed to "postnasal drip." The hypothesis that GER causes laryngeal problems is discussed by means of case reports, literature review, and logical deduction. Throat clearing, laryngitis, irritative cough, laryngospasm, contact ulcer, and intubation granuloma are believed to be caused by GER. That cricoarytenoid joint arthritis and certain carcinomas of the larynx may also be caused or exacerbated by GER is postulated.

## INTRODUCTION

Recent publications present the argument that a variety of laryngeal (and other head and neck) symptoms and diseases<sup>1-6</sup> are caused by gastroesophageal reflux (GER). In this article, I add to the arguments in support of this hypothesis by a partial review of the literature and by citing some of my own experiences and impressions. I focus mainly on the larynx and the problems of throat-clearing, nonspecific laryngitis, nonproductive cough, laryngospasm, contact ulcer, and intubation granuloma, and speculate about the role of GER in cricoarytenoid arthritis and carcinoma of the larynx.

Patients and some physicians have for many years blamed the nose and sinuses for some of these symptoms ("postnasal drip" hypothesis). The increasing appreciation of the importance of GER explains why nasal treatments and surgery have proven ineffective many times, to the point that this approach has gained a bad name in some peoples' view.

## MATERIALS AND METHODS

Since Delahunty and Cherry<sup>7</sup> and Cherry and Margulies<sup>8</sup> published on contact ulcer and made the elegantly simple argument that it is a peptic ulcer of the larynx, I have accepted the hypothesis that a variety of symptoms and/or diseases arise this way. I have proven this to my own satisfaction by the use of a therapeutic trial as have other authors in the field.<sup>1-4</sup> Scientific proof of this hypothesis of causation of laryngeal disease is, and will be, difficult to obtain. Circumstantial evidence and therapeutic results, however, are very convincing as one practices from day to day using the hypothesis that may be expressed as follows: Stomach or duodenal contents often reflux into the laryngopharynx and pharynx. These materials may be neutral, acid, or alkaline,<sup>9(p29)</sup> and, if acid or alkaline, may cause mucosal irritation or injury in the larynx. The most susceptible mucosae are those that are thinnest and available for repeated exposure and a certain amount of trauma, such as 1) vocal processes of the arytenoids, 2) vocal cords, and 3) arytenoid prominences and interarytenoid area.

## CASE REPORTS

These case reports are presented as examples of patients I have seen with laryngeal symptoms or disease who were relieved by treatment of GER, supporting the main hypothesis above.

### CASE 1

A 28-year-old college teacher was evaluated by his students as spending too much time during lectures clearing his throat. On the suspicion he was refluxing stomach contents, his wife, an otolaryngologist, suggested he try an antacid before class. He had no prior history of stomach trouble, but the antacid treatment eliminated the behavior. He eventually became known in his department for his public speaking without apparent nervousness. Some of the other teachers have successfully used the same method of treating throat-clearing.

*Comment.* Many of my medical and nonmedical colleagues and friends have successfully used antacids before public speaking to prevent throat-clearing.

### CASE 2

A 46-year-old man frequently awoke during the night with nonproductive coughing. No other symptoms were present except occasional upset stomach. He usually had a snack before bed. On the suspicion he was refluxing at night, he was advised to avoid food just before bed and to take an antacid before lying down. These measures stopped the coughing entirely.

*Comment.* Nocturnal nonproductive cough is a frequent complaint in persons who reflux. Reflux while lying down at night is more severe and prolonged than it is during the daytime when out of bed. Daytime irritative cough is also often caused by reflux and treatable with antacids.

### CASE 3

A 34-year-old man presented with symptoms of throat "drainage" dating back 1 year along with frequent throat-clearing. He occasionally had symptoms of heartburn. On examination, a small granuloma was noted on the right vocal process of the arytenoid. He was placed on cimetidine and antacids. No speech modification or other measures were recommended. The granuloma cleared in approximately 3 months.

*Comment.* This is one of four consecutive cases in recent years of contact granuloma or ulcer cleared by antacid therapy alone in my practice (Table 1). Some patients required dietary modification and elevation of the head of their bed in addition to antacids and cimetidine. One has suffered a relapse but has cured it by reinstating the program. No voice therapy, antibiotics, steroids, voice rest, or antihistamines were used in these patients.

### CASE 4

A 46-year-old man presented in 1976 with hoarseness and very symptomatic reflux consisting mainly of heartburn. He smoked one pack of cigarettes a day for 10 years and occasionally drank alcohol, mostly beer. Examination revealed a large granuloma of the right vocal process along with posterior laryngitis. He was placed on an antacid-antireflux program but failed to show prompt improvement in a month. A biopsy was done showing invasive

From the Department of Otorhinolaryngology, University of Michigan, and the Department of Otolaryngology, St Joseph Mercy Hospital, Ann Arbor. Presented at the meeting of the American Laryngological Association, New Orleans, April 10-11, 1983.

TABLE 1. CONTACT ULCERS AND GRANULOMA

Age	Sex	Laryngeal Finding	Treatment	Result
34	M	Granuloma, right vocal process (no biopsy)	Antacid-antireflux program, cimetidine, reduced alcohol use	Healed in 3 mo
76	M	Contact ulcer, left vocal process (no biopsy)	Antacid-antireflux program, cimetidine, metoclopramide, reduced coffee use	Healed in 6 mo
58	M	Contact ulcer, right vocal process (no biopsy)	Antacid-antireflux program, cimetidine	Healed in 3 wk
65	M	Contact ulcer, left vocal process (2 biopsies)	Antacid-antireflux program, cimetidine later for recurrence	Healed in 3 wk, recurred in 3 yr, healed in 2 mo

squamous cell carcinoma. Radiation therapy was given, but in 1979, a recurrence necessitated total laryngectomy. Since then he has done well, but still requires continuous cimetidine and antacid therapy for symptomatic reflux.

*Comment.* This is one of five similar patients with very symptomatic reflux and carcinoma on or near the vocal process of the arytenoid (Table 2). Many of them had other "trigger" factors for laryngeal carcinoma, but the unusual posterior location of the cancers and the presence of highly symptomatic reflux raises the question of a heretofore unrecognized trigger being operative.

#### CASE 5

A 26-year-old woman was intubated for a caesarean section. After the delivery, she did well but gradually developed a breathy, hoarse voice. Examination revealed a large granuloma of the right arytenoid. She was treated with voice rest, antibiotics, and two surgical removals of the granuloma. Each time the lesion recurred. Because of my favorable experience treating contact ulcers with antacids and because of her history of heartburn, even after delivery, it was decided to remove the granuloma a third time and employ an antacid-antireflux program. This combination resulted in healing of the granuloma.

*Comment.* The combination of mucosal breakdown by an endotracheal tube and acid bathing the wound is probably responsible for the development of a chronic granuloma in some patients who are intubated, even for a short period.

#### CASE 6

A 54-year-old woman with Parkinson's disease awoke one morning with stridor and dyspnea. She had a 6-month history of progressive hoarseness diagnosed as the result of laryngitis. She had symptomatic GER and an upper gastrointestinal radiograph showed a hiatus hernia. Laryngeal examination revealed posterior erythema and edema with a maximum glottic opening of 3 mm caused by limited vocal cord abduction. Chest radiograph, complete blood cell count, and computerized tomography scan of the larynx and upper trachea were normal. Therapy consisted of oxygen, humidity, ampicillin, steroids, cimetidine, antacids, and elevation of the head of the bed. In 4 days her stridor was much improved and abduction of the vocal cords improved slightly. Steroids, antibiotics, and oxygen were stopped, but the antacid program was continued with considerable relief of her laryngeal symptoms and no recurrence of significant stridor to date.

#### DISCUSSION

Some of the symptoms and diseases discussed here are traditionally presumed to be on the basis of postnasal drip, sinus drainage, or mouth-breathing. Initial treatment often consists of antibiotics and antihistamines. Later, referral to a specialist sometimes results in nasal surgery, such as septoplasty or nasoantral windows. Unfortunately, in my experience, these procedures have often failed to correct the complaint, and some patients have been forced to seek second and third opinions in an effort to get relief. Thus, over the years, we have had to deal with a hypothesis of nasal causation of many throat symptoms — mainly nonspecific laryngitis with hoarseness, dry throat, throat drainage, lump in the throat — which has not, in my opinion, been supported by the results of therapy. Since the late 1960s, the hypothesis that these symptoms are caused by GER has gradually gained acceptance as an explanation for some of them.

The basic clearly understood and widely accepted symptoms and signs of GER are heartburn, distal esophagitis (sometimes with bleeding), acid belching, repeated swallowing, regurgitation, upset stomach, epigastric pain, nausea, and others. Incompetency of the lower esophageal segment is a proven entity, although the details of mechanism are still being debated.<sup>10</sup> The possibility of GER causing laryngeal problems has been rather slow to catch on, possibly because of the distance from stomach to larynx, and because of the traditional postnasal drip hypothesis. Recent articles<sup>2-5,11</sup> have extended the spectrum of symptoms and diseases of the esophagus, pharynx, larynx, and lungs resulting from reflux to a lengthy list (Table 3). Useful inves-

TABLE 2. POSTERIOR LARYNGEAL CANCER AND GASTROESOPHAGEAL REFLUX

Age	Sex	Laryngeal Finding	GER History	Therapy	Result
46	M	SCCA right vocal process	Severe heartburn, smoked 10 pack-years, social drinker	Irradiated 1976, laryngectomy 1979	No recurrence after laryngectomy
58	M	SCCA right arytenoid and vocal process	Hiatus hernia, esophagitis, smoked 40 pack-years, social drinker	Irradiated 1982	No recurrence to date
69	M	SCCA in situ right vocal process	Severe heartburn, acid laryngitis, heavy smoker, occasional beer	Irradiated 1981	No recurrence to date
67	M	SCCA right arytenoid	Severe heartburn, acid laryngitis, social drinker (beer), average cigarette smoker	Irradiated 1976	No recurrence to date
56	M	SCCA right posterior vocal cord	Severe reflux symptoms, bleeding esophagitis, social drinker (beer), average cigarette smoker	Irradiated 1982, partial laryngectomy 1983	Recent postoperative

SCCA - Squamous cell carcinoma. GER - Gastroesophageal reflux.



TABLE 3. SYMPTOMS AND DISEASES ATTRIBUTED TO GASTROESOPHAGEAL REFLUX

Intractable cough	Water brash (excess salivation)
Globus	Regurgitation
Foreign body sensation in throat	Vomiting
Hoarseness	Aspiration
Neck pain	Buccal pain
Laryngeal granuloma	Aerophagia
Choking sensation	Halitosis
Chronic sore or dry throat	Esophageal strictures and webs
Redness of posterior larynx (acid laryngitis)	Cricopharyngeal muscle dysfunction
Pachydermia of larynx	Torticollis
Contact ulcer	Zenker's diverticulum
Throat-clearing	Dental problems
Laryngospasm	Recurrent respiratory disease
Hyperkeratosis of posterior commissure	Apneic spells
Plummer-Vinson syndrome	Barrett esophagus
Subglottic stenosis	Carcinoma of esophagus
Weak voice	Mouth ulceration
Pyrosis	Painful or difficult swallowing
Hemorrhage	

tigations to prove the relationship postulated are few. The proof is basically in the history-taking and in the therapeutic response, usually reported anecdotally, as in this communication.

Important features to seek in the history include heartburn, upset stomach, frequent swallowing, antacid use, rush of fluid into the mouth, sudden coughing and laryngospasm while lying down, nausea, prior history of stomach radiographs, previous gastric surgery, dysphagia, and, importantly, a history of heartburn or ulcers in years past, now "cured."

The physical examination in patients with symptomatic reflux is often negative, but authors recently have frequently noted redness and swelling of the arytenoid area as possibly being caused by GER (so-called posterior or acid laryngitis),<sup>1,3,4,12</sup> sometimes interpreted in the past as rhinitic laryngitis.<sup>13</sup>

As has often been noted, objective proof of reflux to the larynx is difficult to get and has not as yet been obtained in humans. Proof of reflux in heartburn patients is also not always obtainable in every case. Reflux into the pharynx, however, is frequently reported subjectively.<sup>9(p48)</sup>

As a result of these considerations, I feel treatment of certain minor symptoms and diseases may proceed on an empiric basis with extensive work-up reserved for patients who do not promptly respond. Such cases include patients with GER symptoms together with laryngeal symptoms such as nonspecific laryngitis, daytime or nighttime nonproductive irritative cough, choking, laryngospasm, and throat-clearing.

Contact ulcer and granuloma are a bit more controversial. Doctors vary on the importance of biopsy. There is a legitimate concern that the ulcer or

TABLE 4. SAMPLE INSTRUCTIONS FOR PATIENTS WITH SYMPTOMS CAUSED BY GER

In some people, irritating acid stomach juices may leak out of the stomach and into the esophagus and throat. This causes irritation and muscle spasm in the throat. Some of the symptoms that people have from this include coughing, burning or soreness, hoarseness, throat-clearing, excess mucus, bad taste, and a sensation of a lump in the throat.

The following instructions are designed to help neutralize the stomach, reduce the production of acid, and prevent acid from coming up the esophagus. You should use as many of these suggestions as needed to get relief. *If these measures do not help, or if your symptoms get worse, you should let me know about it.*

1. Take an antacid in liquid form (Gelusil, Maalox, or others of your choice) 30 to 40 minutes after meals and at bedtime. If symptoms are severe, take antacids every 1½ or two hours between meals.
2. If you are overweight, you should reduce.
3. Diet restrictions help control symptoms. A bland diet divided into multiple small meals is recommended. Symptoms may be aggravated by ingestion of aspirin, chocolate, sweets, citrus fruits and juices, highly spiced foods, alcohol, tobacco, and caffeine-containing beverages, such as coffee, tea, Coke, or Pepsi.
4. When you chew or suck on candies, gum, breath fresheners, lozenges, etc, there is an outpouring of stomach acid, and these practices should be avoided.
5. Do not eat for three or four hours before retiring. Avoid lying down after any meals.
6. For nighttime relief, sleep with the head of your bed elevated because symptoms are more likely to occur if you lie flat. The best way to achieve elevation is to place cinder blocks, wood, or bricks under the legs at the head of the bed. The desired elevation ranges from 10 to 27.5 cm, with 20 cm a customary average. If this is not practical, sleep on two or three pillows. Sometimes sleeping on the right side helps prevent distressing attacks.
7. Clothing that fits tightly across the midsection of the body should be avoided. Women should not wear a girdle. Men should not wear a belt, but use suspenders. Use of abdominal supporting belts should be prohibited.
8. You should practice abdominal or diaphragmatic breathing when you are having symptoms. This means that you concentrate on pushing out the stomach with each breath instead of expanding the chest.
9. Do not bend or stoop any more than is absolutely necessary. This includes activities such as gardening and exercises requiring lifting or bending.
10. Maintaining a relaxed attitude in your activities helps to reduce symptoms.

granuloma may, rarely, be malignant (case 4).<sup>14</sup> Biopsy of a benign contact ulcer or granuloma, on the other hand, is frequently followed by a prompt recurrence. This would be expected if acid burning of the area is etiologic, because biopsy creates a larger mucosal defect than present originally. My current plan is the same as that advised by Bain et al.<sup>3</sup> Chodosh,<sup>1</sup> and Ward and Berci,<sup>4</sup> who have suggested treating contact ulcers without biopsy at first, but to biopsy in case of failure to improve in a month.

The granulomas occurring after short- or long-term intubation (case 5) are probably acid-induced lesions as well. Causation solely by trauma is not

likely because this does not occur as often as would be predicted considering the large number of intubations done and that mucosal breakdown probably occurs after approximately an hour of intubation.<sup>15</sup> An additional irritant factor is needed to account for the failure to heal, and refluxed acid may logically be blamed in some, if not all, such patients. I feel that the heavy granulations seen with the use of lumen keepers in the larynx after repair of acute traumatic lesions or chronic stenosis may also be stimulated by refluxed acid caught between larynx and mold.

The acid reflux hypothesis may apply to other laryngeal diseases not currently felt to be reflux-induced. Posterior laryngeal carcinoma and cricoarytenoid joint arthritis are two such diseases.

A major point presented here is that acid reflux to the larynx is a noxious irritant. The possibility of chronic laryngitis predisposing to laryngeal cancer has been raised by Glanz and Kleinsasser<sup>16</sup> and by Gabriel and Jones.<sup>17</sup> Other studies have already shown that GER is a possible carcinogen in the lower esophagus and stomach, especially in patients with gastric mucosa creeping up the lower esophagus after reflux destruction of the normal lining (Barrett esophagus).<sup>11</sup> Plummer-Vinson syndrome, which is premalignant, has been tied to GER.<sup>5</sup> Other forms of chronic irritation of the esophagus such as achalasia and lye stricture have also been judged possibly carcinogenic.<sup>18</sup> Outside the esophagus, chronic irritation is the apparent cause of carcinomas in burn scars (Marjolin ulcer),<sup>19</sup> and neoplasms may arise in any chronically irritated and incompletely healed wound as noted by Peacock and VanWinkle.<sup>19</sup> Thus, circumstantial evidence is that chronic acid irritation of the posterior larynx, especially with ulceration, could be a trigger factor in carcinoma of this area.

We occasionally see patients with apparent limited adduction and abduction of the arytenoids who apparently do not have paralysis. They have no history of a head, neck, or chest lesion that could cause bilateral paralysis and do not have cord atrophy.

The voice remains strong, but inspiratory stridor sometimes occurs. It is my tentative observation in two patients of this type who had severe GER that the posterior laryngitis probably extends to and limits the cricoarytenoid joint. This speculation is offered in the hope that other physicians will confirm this impression in their own future observations.

Treatment of GER has been outlined in many articles and is not within the scope of this communication. A gastroenterologist and/or dietitian will be helpful in determining the best therapy. A handout sheet listing methods for neutralizing the stomach and preventing GER is very helpful for use in office practice (Table 4). Criteria for performing antireflux operations have been established.<sup>9(p81)</sup>

I feel that intubated patients or those wearing laryngeal molds should always be kept on an antacid-antireflux regimen. In my experience, the use of voice rest, antibiotics, speech therapy, steroids, antihistamines, or operations on the nose have not proven to be as effective for the laryngeal symptoms and disorders herein described as have antacid-antireflux measures.

#### SUMMARY

This paper has attempted to persuade the reader of the importance of the hypothesis that stomach acid will reflux to the level of the larynx and cause clinical symptoms and diseases in that area. At the same time, the profession is encouraged to discard the postnasal drip hypothesis on which many doctors have depended over the years to explain some of these symptoms.

In addition to the minor problems of throat-clearing, hoarseness, coughing, choking, contact ulcer, and minor laryngospasm, speculation has been put forth that more serious diseases of the larynx such as cricoarytenoid joint arthritis and carcinoma may be caused or triggered by chronic GER. The potential danger of mucosal breakdown by an indwelling tube or mold in the larynx combined with acid irritation is also stressed.

#### REFERENCES

1. Chodosh PL. Gastro-esophago-pharyngeal reflux. *Laryngoscope* 1977; 87:1418-27.
2. Hallewell JD, Cole TB. Isolated head and neck symptoms due to hiatus hernia. *Arch Otolaryngol* 1970; 92:499-501.
3. Bain WM, Harrington JW, Thomas LE, Schaefer SD. Head and neck manifestations of gastroesophageal reflux. *Laryngoscope* 1983; 93:175-9.
4. Ward PH, Berci G. Observations on the pathogenesis of chronic non-specific pharyngitis and laryngitis. *Laryngoscope* 1982; 92:1377-82.
5. Smiley TB. Cricopharyngeal complications of gastroesophageal reflux. In: Sorensen HR, Jepsen O, Pedersen SA, eds. *The function of the esophagus*. Odense: Odense University Press, 1972:64-8.
6. Skinner DB, Belsey RHR, Hendrix TR, Zuidema GD. *Gastroesophageal reflux and hiatus hernia*. Boston: Little, Brown and Co, 1972:33-4.
7. Delahunty JE, Cherry J. Experimentally produced vocal cord granulomas. *Laryngoscope* 1968; 78:1941-7.
8. Cherry J, Margulies SI. Contact ulcer of the larynx. *Laryngoscope* 1968; 78:1937-40.
9. Henderson RD. Motor disorders of the esophagus. Baltimore: Williams and Wilkins, 1976:29, 48, 81.
10. Dodds WJ, Dent J, Hogan WJ, et al. Mechanisms of gastroesophageal reflux in patients with reflux esophagitis. *N Engl J Med* 1982; 307:1547-52.
11. Radigan LR, Glover JL, Shipley FE, Shoemaker RE. Barrett esophagus. *Arch Surg* 1977; 112:486-91.



12. Delahunty JE. Acid laryngitis. *J Laryngol Otol* 1972; 86:335-42.
13. Foxen EHM. Lecture notes on diseases of the ear, nose and throat. Oxford: Blackwell, 1972:115.
14. Ward PH, Zwitman D, Hanson D, Berci G. Contact ulcers and granulomas of the larynx: new insights into their etiology as a basis for more rational treatment. *Otolaryngol Head Neck Surg* 1980; 88:262-9.
15. Donnelly WH. Histopathology of endotracheal intubation: an autopsy study of 99 cases. *Arch Pathol* 1969; 88:511-20.
16. Glantz H, Kleinsasser O. Chronic laryngitis and carcinoma. *Arch Otorhinolaryngol* 1976; 212:57-75.
17. Gabriel CE, Jones DG. The importance of chronic laryngitis. *J Laryngol Otol* 1960; 74:349-57.
18. Mannell A. Carcinoma of the esophagus. *Curr Prob Surg* 1982; 19:560.
19. Peacock EE, VanWinkle W. Wound repair. Philadelphia: WB Saunders, 1976.

## DISCUSSIONS

### GLOTTOGRAPHIC MEASUREMENT OF VOCAL DYSFUNCTION. A PRELIMINARY REPORT (p 17)

D. G. HANSON, MD; B. R. GERRATT, PHD; P. H. WARD, MD

### QUANTITATIVE AND OBJECTIVE EVALUATION OF VOCAL CORD FUNCTION (p 25)

E. RONTAL, MD; M. RONTAL, MD; H. J. JACOB, MD; M. I. ROLNICK, PHD

### VIDEOLARYNGOSCOPY. A COMPARISON OF FIBERSCOPIC AND TELESCOPIC DOCUMENTATION (p 34)

E. YANAGISAWA, MD; T. W. OWENS, MD; G. STROTHERS, MD; K. HONDA, MD

PETER W. ALBERTI, MB, PHD (Toronto): It is a privilege to be here this morning to discuss these interesting papers which all deal with that very important topic — documentation of voice — of which I think we will be hearing more. I would like to deal with the papers individually and then make some general statements.

Dr Rontal describes a technique which is simple, and if not already commercially available, soon will be. He suggested a screening tool to use to distinguish between a normal and a hoarse voice. He further suggests that hoarseness may equate with pathology. He also tells us that a screening technique should be easy, quantitative, accurate, and cost-effective. I would add to that reproducible. There was nothing in his paper to suggest that there had been test-retest trials on either the normal subjects or his pathological cases. I think that would be an important next step. The paper demonstrates a fine idea but, as with all preliminary studies, it requires much more work. His normal group was, I judged, deliberately chosen to be heterogeneous. I believe it would have been better had it been broken down by age, sex, and in particular by smoking and nonsmoking. The pathological group, I notice, includes some functional problems; an hysterical aphonia was thrown in as having one of the wildest perturbation figures. The pathological group was also extremely heterogeneous. These were examples, I recognize that; but in some of the groups there were only one or two subjects with a given pathology. I would like to have seen not only mean perturbation figures but also ranges. What overlap was there between the normals and the pathological, and between different groups of pathologies? As a screening test I imagine it was only necessary to know the difference between pathological and nonpathological. For this, obviously, larger numbers are going to be necessary. I would like to know if the perturbation figures vary from time to time within the pathological group. In other words, is the figure of 20% perturbation which he suggests as a cut-off proven as the accurate cut-off? I think there is much to do, but it is an interesting, simple idea, and it may well prove to be a technique which we could use. I would have some discussion also with him on the other areas of its use, as for example, in industrial screening, but I think that's for another time.

The paper by Dr Hanson and his colleagues utilizes well-known techniques. The unusual thing here is that they have been packaged together. The voice recording, photoglottography, electroglottography, and photographs as described are very much voice laboratory tools. I think this is important because there are more and more voice laboratories being established. What the authors

are telling us is what belongs in voice laboratories. As I've seen them spring up all around the country, as we get more and more into phonosurgery, it is important for those trying to establish this type of laboratory to know what to put into them. I was intrigued that the very interesting measures of vocal dysfunction that they showed were all examples of neurological speech problems. I would like to see how these techniques work out with vocal cord pathologies. I look forward to seeing that in the future. The electroglottograph (EGG) is commercially available and is an easy technique to use, but needs standardizing. I would like to have seen the comparison between it and electromyographic studies, particularly in these neurological disorders. In one of his diagrams he showed an arrow of the opening point in the EGG. I wonder whether that would change with falsetto use? It was described as representing where the lips of the cords moved apart; that's a low-pitch voice phenomenon. I wonder what care was taken to standardize the neutrality of voice. Much was made of the opening and closing quotients and we know that they change with emotion, with anger, with tightness, with different use of the voice, and I think that before this technique is adopted in the laboratory, we will have to find some way of neutralizing the voice; heaven forbid the rainbow passage again! I agree with his conclusions that a combination of measures which will provide the most useful information requires a multidimensional approach on a large group of patients. What we heard today was not the first step but certainly not far down the path either.

What can I say about Eiji's video demonstration! He and I have had a good thing going for many years now and he has become the master par excellence of video representation of the larynx. He's given you a very good example of the relative merits of the flexible v the rigid scope and as I am a rigid scope man from way back, I liked his comments. The flexible scope is useful to get a dynamic feel for the whole vocal tract, the singing voice (to see the pharynx moving and so on with vibrato); you wouldn't get this view with a rigid scope, but one sees detail better with a rigid scope. The flexible scope is good for dynamics but poor in optics. The rigid is best of all for the vocal cords. It's very good at showing the respiratory movements of the cords. I think the other two papers have been dealing much more with the phonatory function of the cords. Here optical representation is being left way behind because we really can't do high-speed photography and our TV isn't quite ready yet to reproduce stroboscopy. Television is cheaper than film but also its resolution isn't as good. I hesitate to say this after the resolution that we saw this morning, but project even those excellent images onto a big screen as one would with



films and they would be found wanting. There are changes coming, and there will be better resolution. Let's talk first of all of the monitors. Most monitors themselves have worse resolution than some of the component TV sets, such as the Sony Profeel, which has about 30% better resolution than standard TV. Half-inch recorders have less resolution than three-quarter inch recorders, which have less resolution than the 2-inch recorders. If one wants really good resolution, bigger recorders must be used. So it is with cameras: the single tube Saticon gives a good image, but still not as good resolution as three-tube cameras. Three-tube cameras are getting cheaper, but still cost \$20,000 as opposed to the \$1,000 that we were being told about this morning, or the \$10,000 which is the usual price of lightweight medical cameras. But the resolution is usually double, 550 lines as opposed to the 250 or 300 lines, and so on it goes. There are going to be technical changes here. I hope that with all the pictures that we take we don't end up like some orthopedic surgeons I know. They have taken movies of every child with an abnormal gait, and after 20 years, they have had to build another storage room which is full of unlooked at, uncataloged clips. If we're going to make use of the video, we must view, we must catalog, we must store, and we must review

and review and review, because everytime we look at the tapes, we learn something. The more we look, the more we see.

Now, just to sum up. There are many ways available to assess voice. Up to now it has been functional assessment, a crude acoustic assessment. We listened to that rainbow passage, we have relied on the trained ear; that encompasses the whole package: respiratory function, phonation, vocal tract change, articulatory function, neurological status. Even when we look at the fundamental frequency, we've looked first of all to the spectrograph which has far too much information for anyone to make anything of it routinely. We've been shown this morning some simpler techniques. This is a final point I would like to make: I think we need to choose which technique to standardize. We have to choose which we can quantify in an easily comparable way. We're rather like otologists in the days of Edmund Fowler, Sr, when he introduced his first audiometer. Which test should we standardize for the very important end product of measuring the function of the larynx in pretreatment and posttreatment phonatory or functional surgery? We need to do something both for the diagnosis and for the evaluation of what we are doing. These papers this morning gave us a good start.

### MUSCULAR TENSION DYSPHONIA (p 100)

M. D. MORRISON, MD, FRACS(C); L. A. RAMMAGE, BA, MSC; G. M. BELISLE, MD;  
C. B. PULLAN, MA; H. NICHOL, MD, FRCP(C)

### THREE-DIMENSIONAL COMPUTER RECONSTRUCTION OF THE DISTRIBUTION OF NEUROMUSCULAR JUNCTIONS IN THE THYROARYTENOID MUSCLE (p 28)

M. ROSEN, MD; L. T. MALMGREN, PHD; R. R. GACEK, MD

### VOICE CHANGE IN THE PEDIATRIC PATIENT. A DIFFERENTIAL DIAGNOSIS (p 41)

S. R. COHEN, MD; J. W. THOMPSON, MD; K. A. GELLER, MD; J. W. BIRNS, MD

GEORGE GATES, MD (San Antonio, Tex): Let me rearrange the order of the presentation slightly and begin with the paper by Dr Cohen, which you just heard. We've come to expect scholarship and fine detail from Dr Cohen and his group, and we were not disappointed in this paper. It's good for us to be reminded of how extensive is the differential diagnosis of dysphonia in infants and children and to be reminded of two important points. First, childhood dysphonia may be a sign of a potentially fatal disease and therefore should not be ignored, nor should the work-up be delayed. And second, that in some serious conditions, dysphonia may not be present or may only be appreciated by the experienced observer. Subglottic stenosis and epiglottitis are two good examples. I congratulate Dr Cohen and his colleagues on a fine review.

Dr Morrison is to be congratulated for adopting a multidisciplinary approach to the study of voice disorders. His group includes an otolaryngologist, a music teacher, a speech pathologist, and a psychiatrist. As all music teachers know, excessive tension in the neck muscles is a common strategy adopted by beginning singers to attempt to increase the power and projection of their voices. Unfortunately, it doesn't work, and as discussed by Dr Morrison, is actually counterproductive. As we know, the tension should be in the abdominal muscles; the neck muscles should be relaxed. A second fault of these patients is laryngeal rise. The singing larynx should be kept low at all times and should not move upward in the neck with increasing pitch. Failure to pay attention to these two important physiological aspects of singing can lead to

the formation of singer's nodules. Up to this point I fully agree with the observation of Morrison and his coworkers. However, when we begin to move to the discussion of the posterior open glottis, our views begin to diverge.

I have three problems with the inclusion of the posterior open glottis as part of the syndrome of muscular tension dysphonia, and as Dr Morrison pointed out, it is not present in all of his cases. First, some people phonate normally with a slightly open posterior glottis, as Dr Yanagisawa's beautiful film showed us. Second, I know of no physiological or anatomical way to explain the angled appearance of the vocal cords and the thyroarytenoid muscle as depicted by the authors in Fig 1 of their paper. It suggests that the arytenoids rotate on a vertical axis whereas most students of laryngeal function and anatomy describe a rocking motion of the arytenoids rather than rotation. And third, I believe that there is an alternative explanation, namely that the fleshy, edematous, anterior vocal folds approximate in phonation and thus physically contribute to the breathiness due to air escaped posteriorly and exaggerate the appearance of the posterior open glottis. I think we need to study this phenomenon further to explain the lack of congruence between these observations on their beautifully done video recordings and our ability to explain them. Additional points need to be made. I believe that vocal nodules all begin as a fleshy edematous process that over time consolidates to form the hard fibrous nodule. I believe that Morrison et al are correct in describing the two types of nodules and also in their therapy. But I believe that these represent a pathophysiological continuum rather than two different disorders.

I would like now to turn attention to the paper by Rosen et al from Syracuse. Mark Rosen did this work as a senior medical student under the supervision of Dr Malmgren. The former is to be congratulated for taking the time and initiative to do it, and the latter for supervising the work and providing research training under Dr Gacek's leadership. Basic science work like this results when the proper research environment is established.

This is a very nice piece of work which contributes new knowledge to our understanding of the larynx. The finding that the motor end-plates are scattered throughout the thyroarytenoid muscle raises many interesting possibilities and the authors have discussed them fully. They call our attention to the fact that type I muscle fibers have multiple motor end-plates and that the fiber geometry of the thyroarytenoid muscle is very complex. Therefore, we would not expect to see the single band of motor end-plates in the middle of the muscle belly as we see in the cricothyroid muscle. In addition, they identify motor end-plates in the false vocal folds and raise interesting possibilities about the pathogenesis of plica dysphonia ventricularis. The histochemical technique must be applied systematically to many more human larynges before we can draw any firm conclusions about this possibility.

The possibility of using botulinum toxin for therapy is most intriguing, but as we all recognize, highly premature. Much additional work will have to be conducted before I could convince my patients to willingly let me inject this dread toxin into their larynx. Nonetheless, it offers some very exciting possibilities about better understanding the function of the larynx. For example, in an animal model one could selectively inhibit discrete muscles, for

example the lateral cricoarytenoid or the interarytenoid muscles, and then determine the effects on vocalization in this model. I would be encouraged to inject the lateral cricoarytenoid and the interarytenoid in patients with spastic dysphonia rather than the thyroarytenoid muscle because these are much more important in closing the glottis. If these were not satisfactory, the microinjections of extremely dilute solutions into the thyroarytenoid muscle might help relieve some of the increased tension there. I would point out that if you want to read the paper by Scott, you'll have to look in the *Journal of Pediatric Ophthalmology and Strabismus*, vol 17; where they discuss their experience of doing this in strabismus surgery using an EMG electrode to find the right muscle and then injecting an extremely dilute concentration of the material into the muscle. This then allows the other muscles to gain strength over time as the operative muscle is weakened and allows approximations to be made on a more physiologic basis.

MARC ROSEN, MD: We did realize there were other muscles that were also important in adduction of the cords, and those certainly are planned to be looked at also. In addition, we do have the cat as a good animal model that we can use to selectively try these techniques and see what their future effect is.

MURRAY D. MORRISON, MD (closing): Thank you, Dr Gates, for your comments. Your feelings are identical to what mine were 2 years ago, and therefore, I can't disagree with your conclusions too much except that my only rejoinder would be to invite you to comment after 30 or 40 hours of looking at our collected video tapes. I would hope that perhaps we might be able to modify your thoughts slightly.

## QUANTIFICATION OF INTRALARYNGEAL PRESSURE EXERTED BY ENDOTRACHEAL TUBES (p 48)

E. A. WEYMULLER, JR, MD; M. J. BISHOP, MD; B. R. FINK, MD;  
A. W. HIBBARD, MD; F. A. SPELMAN, PHD

## CONGENITAL LARYNGEAL HEMANGIOMA (p 52)

B. BENJAMIN, FRACS; P. CARTER, FRACS

## FURTHER OBSERVATIONS ON THE TREATMENT OF RECURRENT RESPIRATORY PAPILLOMATOSIS WITH INTERFERON: A COMPARISON OF SOURCES (p 60)

R. B. SESSIONS, MD; H. GOEPFERT, MD; D. T. DONOVAN, MD; W. J. DICHTTEL, MD; J. U. GUTTERMAN, MD

GERALD HEALY, MD (Boston): Dr Weymuller certainly confirmed what many of us have suspected for a long time and that is that the major portion of laryngeal injury from prolonged endotracheal intubation, at least in adults, is in the posterior commissure. Basically, the three locations of injury that occur from endotracheal intubation are the posterior commissure, the anterior commissure, and the subglottic space. Certainly in children the subglottic space seems most sensitive to injury, and perhaps Dr Weymuller might address why this is so in future research from his laboratory. I also wonder whether nasotracheal intubation injures the same location in the larynx. The injuries that were presented by Dr Weymuller, of course, were produced by an orally placed tube in the canine larynx, but we know that orally placed tubes produce similar injury in the human larynx. These are still great areas of interest left to be investigated in our specialty.

Another interesting point is that children tolerate prolonged intubation much better than adults. Is this because of the configuration or the consistency of their larynx? There is also no question that neonates can tolerate prolonged intubation for much longer

periods than adults. Again, this is another important question that perhaps deserves some future consideration from the experimental level.

Dr Benjamin always brings very useful information to his North American colleagues, and certainly this paper on his long experience with the treatment of congenital hemangioma is very important. There is no question that there are differences in this lesion depending on the child. The patient presented today has a condition which I call hemangiomatosis of the head and neck. This is the patient with the multiple sites of hemangioma (larynx, skin, trachea). This differs from the patient with the isolated capillary type of hemangioma of the subglottic larynx. Within the larynx itself, frequently there are differences in these hemangiomatosis. The patient with a supraglottic hemangioma usually has a lesion more of the cavernous type whereas the subglottic lesion, in my experience, is more of the capillary type.

I am sorry to hear that Dr Benjamin has had a bad experience with the use of the CO<sub>2</sub> laser, because our experience, as he knows, has been somewhat different. We now have experience



with 17 subglottic capillary lesions, lasering them on either one or two applications. I have heard isolated reports of stenosis as Dr Benjamin has mentioned. Perhaps we get a little aggressive with this instrument and produce circumferential charring. This will produce scarring without question. If there is a lesion of the whole posterior part of the larynx, it should probably be done in stages. This avoids the creation of opposing raw surfaces. The number of times a patient is done is really inconsequential. We have had one patient in our experience that required three applications because we did not want to produce multiple sites simultaneously which might lead to scarring.

I must say that I am very uneasy about inserting radioactive material in the pediatric larynx. I am not only concerned about the development of thyroid cancer in later years, but more concerned about local laryngeal cancer. The medicolegal situation in the United States at this time would also not favor the use of this form of therapy and perhaps other alternatives may be necessary in the treatment of this lesion as far as the practice in this country goes.

Dr Sessions' paper presents very important information because it really stops rumors that have been circulating around this country regarding these two types of interferon. It had a definite impact on the study which we are conducting for the National Institute of Allergy and Infectious Disease on choosing which interferon would be used. I will share with you the fact that the Fin-

nish interferon was going to be used in our study until new information came out of the Iowa study. This definitely changed the government's mind as to which product to utilize in our study. We did not want to start a large trial only to find out many months into the study that a different type of interferon was more effective. Thus, this is an important paper in this regard in that it dispels this misinformation and shows us that there probably is little difference between the two in terms of response.

If we look at this horrible disease from a laryngological standpoint, I think historically we see a plethora of treatment modalities, none of which has really been studied in a controlled fashion. Now we are faced with another treatment which has shown promise, but again a good controlled clinical trial has not been undertaken until recently. Currently, our NIH protocol utilizes  $2 \times 10^6$  or 2 million units per meter square, daily for the first week, and then three times a week for 1 year. The second study to which Dr Sessions referred is currently being managed by Dr Kashima from Johns Hopkins Hospital. The important thing is that I think we need to wait before we start giving patients, especially young children, this substance without some definitive information as to whether, in a controlled situation, it is going to make a difference in the treatment of our patients. So I would hope that, although the information from Houston and Iowa has shown us that there may be a definite improvement in patients treated with interferon, we can wait at least a year or so until we have some hard information to prove these points.

## TRAINING SINGING CHILDREN DURING THE PHASES OF VOICE MUTATION (p 66)

I. M. BLATT, MD

## LARYNGEAL NERVE CRUSH FOR SPASTIC DYSPHONIA (p 73)

H. F. BILLER, MD; M. L. SOM, MD; W. LAWSON, MD, DDS

HERBERT DEDO, MD (San Francisco): The multimedia presentation (by Dr Blatt) was interesting. It certainly had better tone quality and was certainly more melodious than our routine papers. However, two aspects still remain controversial. One is whether the otolaryngologist's participation is necessary in the hygiene training of child and adolescent singers with normal voices. The other is whether it is not only harmful but undesirable to have singing training before and during puberty for people who aspire to be professional singers in adulthood. I for one can't routinely see the vocal cords indirectly in 5-year-olds as easily and as routinely as the author describes. And I hate to insist on it when the voice is normal, since the possibility of finding pathology which could be treated and benefit the patient when the voice is normal is very small in my experience. Long-term follow-up on the author's series will be illuminating, regarding the effect of prepubertal singing on the adult professional singing voice. I'm impressed by the observation which I first heard made by Dr Hans von Leden about the alumni of the Vienna Boys' Choir in Europe. This is probably the most famous singing training a boy could have over the last few hundred years, and it's my understanding that after several hundred years and a considerable production of alumni, according to Dr von Leden, there have been no famous adult professional singers from that group. A specific problem for boy singers who sing in the choirs with professional training, even with professional training and guidance, is that the boy soprano is taught to sing without vibrato; I happen to know several adult male singers whose careers were hampered or blocked by the fact that they had difficulty developing a proper adult male vibrato voice in the tenor or baritone range. In any case, I commend the author's attempts to help these singers use good abdominal rather than chest muscle activity during singing and to try to help these singers achieve as relaxed laryngeal muscle activi-

ty during singing as possible. As a practical matter, perhaps most of these children are not interested or concerned about being professional singers as adults.

As for the paper by Drs Som, Biller, and Lawson, I commend the authors on their excellent follow-up report. We also now agree that lidocaine injection is not necessary to determine operability. It is an imperfect test and only a poor prediction because it's hard to avoid also paralyzing the superior laryngeal nerve which causes the cord to be farther out than it will be after the pure recurrent nerve section (which is easy to achieve at surgery without worrying about the superior laryngeal nerve). We feel the best test for determining operability is listening with a trained ear. In spite of multiple attempts to develop a quantitative test so that one can have numbers or look at a curve on an oscilloscope, we find that the trained, experienced ear is still the best thing to use in determining whether a person should have recurrent nerve section. We've also had the same experience with crushing the nerve. We've had four patients who were not prepared to have recurrent nerve section and wanted to have the crushing instead, and we had the same result — the spasticity cleared temporarily, but the motion and spasticity returned after 4 to 6 months. I might add that all four of these were happy enough with the results during the period while the nerve was not functional, so that they then wished to have recurrent nerve section. The disadvantage of this approach is that it requires two operations. As far as recurrent spasticity after nerve section is concerned, we're seeing it in about 15% of patients, which is lower than reported in other series. We feel this is related to the fact that we are mainly seeing it in patients with severe spastic dysphonia, and if a series is being performed only on patients with severe spasticity, then you're going to get a higher recurrence rate of

spasticity. We have been able to clear this by doing what I call a laser vocal cord thinning in which I endoscopically remove tissue from the thyroarytenoid muscle. It is, thus, a reverse Teflon injection, and therefore it achieves the reverse of Teflon injection, that is to say, it moves the free edge of the cord laterally so it makes it

harder for the mobile cord, which of course still has the spasticity and incoordination in it, to reach the paralyzed cord. Sometimes it has been necessary to do it two or three times, but ordinarily we've been able to eliminate the spasticity.

## TEFLON INJECTION OF THE VOCAL CORD: COMPLICATIONS, ERRORS, AND PRECAUTIONS (p 77)

R. B. LEWY, MD

## EARLY EXPERIENCES WITH VOCAL LIGAMENT TIGHTENING (p 79)

F. E. LEJEUNE, MD; C. E. GUICE, MD; P. M. SAMUELS, MA

HARVEY M. TUCKER, MD (Cleveland): It is an honor to be allowed to discuss these two papers, both of them by men who, because of their writings and in some cases direct contact, have been my teachers. I would like to discuss Dr LeJeune's paper first. Last fall when I was here in New Orleans for another meeting, I had the opportunity to visit with Dr LeJeune, we discussed this technique and I had a chance to see one or two of his patients. The idea struck me as such a good one that, with his permission, I went home and now can report that we have performed this procedure in a number of patients in the interim. It is clearly too soon to say if this will be useful for a large number of patients and if so for how long. However, there are in all of our practices patients with loose, flaccid, and bowed vocal cords who are refractory to almost any other means attempting to produce a strong, less breathy voice. This is particularly true in elderly patients. The procedure, I can tell you, is technically simple, very straightforward and probably could be performed under local anesthesia if one chose to do so. We've had no complications either in the postoperative period or long term. Probably the best analogy to this procedure is the face-lift operation. One is simply tightening up what nature has allowed to loosen, and if our experience with face-lift holds true, after a while the tightening that is produced may deteriorate. This has not been Dr LeJeune's experience to this time. At our institution we have the dubious honor of having a fairly active transsexual clinic in which people who God saw fit to put in the wrong body, at least as they see it, are corrected, and one of the things that bothers most of them, especially those who undergo male to female transformation, is the appearance of the Adam's apple, which is often a giveaway, and secondarily the voice. We have dealt with most of them by teaching them good control falsetto, but this is not very satisfactory. This operation may, with additional experience, prove useful in raising the pitch slightly in an otherwise normal male voice by tightening the vocal cords. I'm not prepared yet to report our success with this, although we have done it in one patient. I think that the one other area in which this may be extremely useful is the patient with bilateral superior laryngeal nerve paralysis. The diagram Dr LeJeune provided clearly demonstrates that his operation overcomes the loss of tension that might be produced by nonactivity of the cricothyroid muscles.

I would like then to go on to the paper by Dr Lewy. Dr Lewy

has pointed out to us many of the possible pitfalls and little tricks that years of experience have provided him for obtaining a high incidence of success with this very common procedure. I had my early laryngoscopic training in Philadelphia, and general anesthesia — and, therefore, any kind of suspension apparatus — was seldom used for endoscopy. We were all required to become as skillful as our gifts permitted with the hand-held laryngoscope. In my experience with Teflon injection, I have rarely performed this procedure with the suspension laryngoscope, but almost invariably with a hand-held laryngoscope. This has provided certain advantages in that once the larynx is exposed adequately, it has allowed us to promptly release tension on the petiole of the epiglottis and therefore more accurately, perhaps, to assess the voice result after a limited injection which might be distorted by the forward push of a suspension laryngoscope left tightly controlled. I certainly agree with Dr Lewy that local anesthesia is the procedure of choice. I can think of very few circumstances in which I would consider a Teflon injection under general anesthesia because this leaves the operator entirely in the dark in his judgment as to how much Teflon to use. We have not found it necessary either to hospitalize patients or to give steroids in any of our cases. My experience is considerably less than Dr Lewy's, but it does fall somewhere in excess of 50 or 60 patients, and I have not had a single incidence of significant airway obstruction. I do this as an in-and-out operation; the patient comes in the morning without premedication, is anesthetized and local anesthesia is used throughout, and within an hour he may go home. There have been some patients that have developed some hoarseness as a result of cord edema, but it has not been sufficient to produce significant airway obstruction. I would like to point out one area that hasn't been touched upon, perhaps because it is so obvious: it is absolutely mandatory not to inject Teflon into a mobile or partially mobile vocal cord, because in such circumstances the Teflon simply doesn't stay where it is placed. It usually ends up in the subglottic area. Finally, I would like to submit that the use of Gelfoam as an interim measure allows one to use this injection technique in patients in whom voice is not the only issue, but in whom aspiration or the need for a good effective cough is a major problem as well. In such cases, one may want to intervene much earlier than one would dare with permanent material such as Teflon.



## EFFECTS OF STOMACH ACID ON THE LARYNX (p 108)

N. R. OLSON, MD

MUSCLE TRANSPOSITION IN THE REHABILITATION  
OF THE PARALYZED LARYNX (p 82)

G. D. NEAL, MD; M. STEARNS, FRCS; R. TRACHY; D. SUTTON, PHD; C. W. CUMMINGS, MD

PAUL WARD, MD (Los Angeles): It's a real opportunity to discuss these two papers because of my personal interest in both subjects. Both of these papers address significant clinical problems that are difficult to scientifically evaluate and clinically document. Treatment for both of the problems in general has been rather unsatisfactory.

Dr Olson has again brought to our attention the disease process generated by reflux regurgitation of acid contents from the stomach. Manometric measurements indicate this may occur in normals as many as 20 times per night. In some of our patients we have measured demonstrated reflux as many as 156 times during the night. This occurred in a patient with hiatal hernia who was, of course, predisposed to reflux. Even in patients with strong histories of reflux symptoms, Trendelenberg cinefluoroscopy with barium swallow studies may fail to demonstrate the reflux. Dr. Olson has presented his clinical observations and experiences with both the diagnosis and treatment of irritation to the epithelial surfaces of the posterior larynx, pharynx, and oral cavity. He has emphasized clearly that laryngitis, irritative cough, and contact granulomas may be secondary to gastroesophageal reflux. When I first heard the hypothesis by Delahunty and Cherry, I thought it was nonsense. I was only convinced through personal experience of having a hiatal hernia and experiencing gastroesophageal reflux, particularly at meetings like this after one has eaten late and had too much to drink. Overindulgence caused me to have laryngitis, as I have today, and nocturnal laryngospasm. I developed a personal interest in the subject also by observing and taking more thorough histories from my patients and correlating these with the signs and symptoms of serial motion pictures before and after the treatment program that Dr Olson has outlined in his paper. Personal experience and following a series of more than 100 patients with nonspecific laryngitis and contact granulomas with serial motion pictures attest to the validity of Dr Olson's contentions. The author has presented evidence of chronic irritation from gastroesophageal reflux that may be a triggering mechanism for developing carcinoma of the posterior larynx, an unusual place for laryngeal carcinoma. I must say I think this observation certainly deserves further investigation and documentation for it may be important. He has also provided an excellent hand-out for his patients and many of us — and I know I certainly will — copy this and utilize it for my patients. Although we may explain the program of avoiding reflux, they may soon forget it when they leave the office and this will reemphasize the points and make it

much more convenient for them. I congratulate you, Dr Olson, on an excellent presentation on a timely topic. I challenge those of you who are not yet convinced of this process to take more careful histories, particularly in cases of nonspecific laryngitis and contact granuloma, and evaluate the effectiveness of medical trials before going to repeated, unnecessary, and sometimes detrimental manipulation with laryngoscopies.

Dr Neal and his colleagues have made a serious scientific effort to approach the problem of bilateral adductor paralysis of the vocal cords. They have revived the surgical procedure described by King and Amboy with modifications and may have provided an explanation for the lack of predictability of the reinnervation procedure introduced by Tucker and utilized by a number of us in this audience. Instead of transpositioning and implanting a small tenuous nerve muscle pedicle, they have used an innervated omohyoid muscle that has been severed distally and implanted into the posterior cricoarytenoid muscle, as you've seen in the illustrations. In their animal and human cases that have undergone the Tucker procedure, something definitely has happened. Their videotapes and our moving pictures presented at last year's spring meetings demonstrate some lateralization of the vocal cord on the operated side in some subjects. There is also a very definite motion and in one of our cases we had a glottic chink that opened to 4 mm wide. All of these are easily measurable on films that can document both the preoperative and postoperative effect of your surgery. The authors have speculated that the operative procedure and the resulting scar tissue formation derives from a tethering of the arytenoid with resulting lateralization of the cord and reinnervation coming on later. Minimal movements were observed with maximal expiratory efforts. Without question, reinnervation of viable neuromuscular end-plates is possible. These experiments raise significant questions: When should reinnervation or transposition procedures be performed? Should they be immediate or as soon as possible after the injury? Should the adductor and tensor innervation be sacrificed at the time of reinnervation of the adductors? Is it worthwhile to perform these procedures after lengthy periods of paralysis when the muscles may be atrophied? The jury is still waiting for the final evidence to determine when and even if these procedures are worthwhile. The decision or basis for the decision will come when further carefully planned experiments such as these have been meticulously performed. I congratulate Dr Neal and his colleagues on the excellent presentation and a small but well-documented series.

## INTRALARYNGEAL RELEASE FOR TRACHEAL ANASTOMOSIS (p 86)

M. E. SACHS, MD; J. CONLEY, MD; D. D. RABUZZI, MD

## THE IRRADIATED LARYNX: A SURGICAL DILEMMA (p 14)

J. S. LEWIS, MD; A. VALLEJO, MD; T. KUSONRUKSA, MD

DOUGLAS P. BRYCE, MD (Toronto): These two papers are of great interest to me and I am pleased to be asked to discuss them. The first paper deals with a new method of intralaryngeal release for cases in which additional length of trachea is required for direct anastomosis after resection. If one studies the sagittal section of the larynx, it is certainly possible that extra length can be obtained by the type of incision described by the authors. The soft tissues in the preepiglottic space and the thyroepiglottic ligament will allow elongation of the larynx by this method. However, looking at these pictures of the surgical procedure presented by the authors, I was reminded of a similar picture which occurs when there is a supraglottic fracture as the result of trauma. In these cases, the fracture is exactly in the area that the proposed incision would occupy, and the superior part of the larynx including the epiglottis and the aryepiglottic folds are moved posteriorly and superiorly. In these cases of course, the mucosa is torn which is not the case in the surgical procedure which is being advocated. It has been my custom to use a suprathyroid release of the larynx when doing a tracheal anastomosis and resection, mainly because it is very easily done and only adds a few minutes to the operation, whereas, in my opinion, the suprahyoid drop is more complicated surgically. I would suggest that we await further experience by these authors in the method that they suggest, particularly as the majority of the problems we deal with these days are due to subglottic stenosis which would not be appropriate for this type of surgery.

Dr Lewis's paper was very timely indeed. There is no doubt that radiation is an effective treatment for laryngeal cancer, and so is appropriate surgery. When radiation is properly given and the radiotherapists are expert, the results that can be obtained in carcinoma of the larynx with primary radiation are as good as surgery and the functional results are better. Therefore I anticipate that the problem of the postirradiation larynx will be with us for some time. In general I agree entirely with Dr Lewis's summation of the management of this problem. In the paper he referred to we reviewed the histopathological evidence of chondronecrosis and radiation necrosis following irradiation in surgical larynges. The subclinical histopathological occurrence of car-

tilage and bone necrosis is high, but the clinical evidence of persisting edema and airway obstruction that Dr Lewis refers to is quite rare, so the problem is not with us very often. The determination of recurrence or not in a larynx which is showing postirradiation edema and possibly necrosis is difficult. The answer probably lies in the care and frequency with which the larynx is observed following radiotherapy. If a lesion in the larynx which is radiated responds by disappearance of the lesion and the voice returns to normal, and this happy state is followed by a regression in the symptoms so that the voice becomes hoarse and the larynx which was previously almost back to normal becomes swollen and unhealthy looking, then you are certainly suspicious that there is a recurrence. In these cases, negative biopsies are almost useless, whereas of course, positive biopsies do give you the answer. Unfortunately, repeated negative biopsies merely increase the frequency of subsequent necrosis and difficulty for the patient. In general, if the lesion was a T3 or T4 prior to irradiation and there is a regression in symptoms, the larynx should be removed. It is very likely that there is indeed recurrence as this will occur in more than 50% of cases, and also if indeed there is no cancer present, the degree of radiation necrosis and edema may make the larynx useless to the patient.

A further question with regard to irradiation is the question of radiation-induced malignancy at some period probably more than 10 years later. When the radiation has been properly applied and the dosage has been an appropriate one, the production of radiation-induced secondaries in the radiation field is very low indeed. We are sure of this because of our recent reviews of more than 300 postradiation larynges which have been observed for more than 10 years. There is a new condition, however, which may develop in a postradiated larynx after 10 years or more, and that is gradual stenosis no doubt secondary to subclinical cartilaginous and tissue necrosis as a result of radiation. I have seen three or four of these in the last 2 or 3 years, two which developed complete supraglottic stenosis without evidence of new neoplasm of any kind. As more patients are successful in having their cancers cured by radiotherapy, more cases of late stenosis will be seen.

## PREOPERATIVE IRRADIATION AND SURGERY FOR CARCINOMA OF THE BASE OF THE TONGUE (p 89)

S. E. THAWLEY, MD; J. R. SIMPSON, MD; J. E. MARKS, MD; C. A. PEREZ, MD; J. H. OGURA, MD

## ADENOID CYSTIC CARCINOMA OF THE SUBGLOTTIC REGION (p 95)

D. T. DONOVAN, MD; J. CONLEY, MD

ROGER BOLES, MD (San Francisco): With regard to Dr Thawley and his group's paper relating to carcinoma of the base of the tongue, I want to congratulate him on a monumental study. Any of you or us who have participated in such extensive statistical

reviews know just how much work that is and how difficult it often is extracting the material from the medical records over such a long period of time. This is indeed a statistically important study from a prestigious institution that has been responsible for so



much of the progress in head and neck cancer from all parts of the head and neck over the last few decades. It is a well-documented statement of the state of the art of tongue-base cancer over the two decades described, the 1960s and 1970s. The problems with such extended longitudinal studies are embarked upon by Dr Thawley and his group are surely inherent in that study and in the paper, but these do not detract from the statistical value of the paper. Such things as changes and modifications in treatment, improvements that take place over a two-decade span of time, and the multiplicity of therapists that participate often make it difficult to derive specific therapeutic recommendations from such a study. One thing in particular I was glad to see mentioned in the paper is the proclivity of tongue-base cancers to metastasize to both sides of the neck. I think I can remember when we didn't quite treat the opposite side of the neck with radiation therapy in the preoperative period, and indeed they were not doing so at Washington University of St Louis in the early part of the study, which may have accounted for a high contralateral failure in the necks. In the last year of their study, the radiation therapist did treat both sides of the neck which would seem to be appropriate for such a midline tumor which does not respect fascial and midline planes as tumors in other parts of the head and neck do. The paper and study certainly point out the remaining challenges in tongue-base cancer. One, of course, is accurate diagnosis.

Dr Thawley mentioned in his study that most of the tumors were of very late stage, and tumor staging often was difficult with understaging in a fair number of cases. I believe that CT scanning and perhaps even NMR scanning will be helpful to us in making diagnoses of some of the submucosal tumors and in better assessing their full size and extent in the future. Certainly careful routine attention to all symptoms of the throat that may be initially passed off as infectious disease or other less serious problems should be given to these cases by all of us. These tumors often can be subtle in their initial presentation. The immunologic and epidemiologic challenges remain with this terrible disease. Notwithstanding this fact, I think we can safely say that the 60% 5-year local control rate that was achieved by the Washington University St Louis group in those two decades was indeed a marvelous improvement over what had been taking place in the decades previously. Still and all, it is clear from this data that 40% of the patients died for reasons beyond the control of this group, 20% with distant metastasis and 20% who developed second primary lesions. This indeed is a challenge to us and particularly to the immunologist in the future. As Dr Thawley pointed out, adjuvant chemotherapy and immunologic therapy may give considerable improvement in this hopelessly large segment of all head and neck cancers.

With regard to the paper of Drs Donovan and Conley, I again think that CT scanning and NMR scanning are probably going to help us with some of the laryngeal tumors and particularly with subglottic tumors that are sometimes difficult to see by either in-

direct or direct endoscopic examination and may become quite large before diagnosis by routine means. I was struck by the sensitivity with which the distant metastasis as well as the regional and local recurrences responded to even rather low doses of radiation therapy. We have been struck by that same radiosensitivity that wasn't always thought to be there in previous times, and have exploited that sensitivity by incorporating irradiation therapy into the primary treatment program, rather than withholding it and utilizing irradiation only for ultimate metastasis or local unresectable recurrences. This was the experience at the University of California, San Francisco, over a period of years, and the data seemed rather compelling and led us to the habit of incorporating radiation therapy for the poor-risk tumors of which the adenoid cystic carcinoma is one. Incorporating radiation therapy into primary treatment, those patients who received postoperative irradiation therapy had only a 14% local recurrence rate when there was tumor at or near the surgical margin, in contrast to the group who received surgery only and in whom there was a considerably higher local recurrence rate. It led us to this sort of treatment advocacy for adenoid cystic carcinomas, and in fact, carcinomas of all of the high-risk groups of the salivary glands, and that is gross total removal of all disease followed by full-course irradiation therapy. Actually since Dr Conley was one of the authors of the paper, I might just steal his descriptions of the various operations, the "big-big," the "big-littles," and the "little-bigs." We think that acknowledgment of the radiosensitivity of these tumors has allowed us to do something less than the "big-big" operations. We have come to believe that the surgeon will probably never cure adenoid cystic carcinoma alone, except in the very small tumors. They go everywhere, along perineural lymphatics, along fascial planes, and blood vessels. They tend to always recur if given enough time, just beyond where the surgeon felt he could go even with a large operation. The radiation therapist is not confined by such a surgically defined field so that we believe in fact that the surgery can sometimes be more conservative and conserving of some of the surrounding critical structures, particularly in the parotid area (and the same would obtain in the neck anywhere), and yet perhaps achieve the same end result by exploiting the irradiation therapy for a wider margin. We use postoperative irradiation therapy for the following indications: all large lesions and certainly for any metastatic disease, disease at or near the surgical margins, and deep-lobe malignant tumors of the parotid. The problem that was pointed up by the authors, and that we all see altogether too often in salivary gland tumors and adenoid cystic carcinomas in particular, are experiences of 50% ultimate distant metastatic rates. This, as with Dr Thawley's squamous cell carcinomas of the base of the tongue, exists in a group of patients we have never been able to deal with well in the past and remains a challenge in the future. I believe it is time we got into national protocol studies as we have been encouraged to do and as some of us are beginning to embark upon — using adjuvant chemotherapy and immunotherapy to try to obviate this previously uncontrollable metastatic problem.

## MEMORIALS



FRANK D. LATHROP  
1905-1982

Writing a memorial for Frank Lathrop does not come easily. It might not have been difficult if we had not been friends for many years. He was first my teacher, soon an inspiration, and much more.

He was born in Portland, Oregon, April 2, 1905, the son of Frank A. and Grace R. Lathrop. His medical education at the University of Michigan provided ample stimulus for a career in otolaryngology. His pioneer work in facial nerve surgery developed during World War II while he served with the US Army Medical Corps in England, where he was decorated for his innovative accomplishments.

At the close of the war Frank returned to Boston where his alert mind and skillful hands at the Lahey Clinic propelled him into greater prominence. He was never satisfied to be a spectator; he never sat still. His interests were varied and intense, but always orderly.

In 1963 he became a member of the American Laryngological Association. During the 1968 meeting he presented a provocative paper and was elected Secretary of the Society. Lyman Richards, relinquishing the office of Secretary, acknowledged to the Society, "You have selected a successor who will do a far better job and make fewer mistakes." He served as Secretary until 1972 when he was se-

lected to be President and to preside at the 1973 meeting.

His interests in the overall specialty of otolaryngology led him to other honors. He was also a member of the American Otological Society, served as its President in 1969, and received the Award of Merit in 1977. In 1961 he was Vice-President of the Triological Society and was guest of honor in 1980. His activities led him to membership in the American Medical Association, Facial Nerve Study Group, American College of Surgeons, Otosclerosis Study Group, American Broncho-Esophagological Association, American Society of Head and Neck Surgery, and he was emeritus Clinical Professor of Otolaryngology at the University of Vermont.

He was a strong and vital man with more interests than one might count. Frank had a host of admiring friends, many of whom often turned to him for advice, and for us the void he left is endless. He died November 14, 1982, in Vermont where he lived with his wife Margaret. She was his constant companion in leisure hours and on the farm where they raised Morgan horses. We extend our sympathy to her, a son and two daughters.

B.W.A.





JULIUS W. MCCALL  
1892-1982

Dr Julius W. McCall of Shaker Heights, Ohio, died at the age of 90 on October 10, 1982. He had been ill for approximately 3 weeks due to a cerebrovascular ailment, and death was caused by pneumonia. He practiced for over 40 years in the Cleveland community as an otolaryngologist with a particular interest in patients with cancer of the larynx. He was one of the first people in the city of Cleveland to perform laryngectomy surgery. He was an advocate of the concept that cancer could be cured by wide-field resection of the cancer including normal tissues. He was a founding member of the Lost Chord Club of Cleveland, a group associated with the Cleveland Speech and Hearing Center dedicated to teaching patients to develop alaryngeal speech after laryngectomy.

Dr McCall received his bachelor's degree in 1914 from Auburn University and a medical degree in 1918 from Tulane University. He served as a captain in the US Army in World War I.

He completed his internship at the Charity Hospital in New Orleans and his residency at the Postgraduate Hospital in New York. He was a native of Montgomery, Alabama. He was licensed to practice medicine in the state of Ohio in 1923, began his medical career in Youngstown, then practiced in

the downtown Cleveland area until his retirement in 1975. He became a member of the American Laryngological Association in 1952 and was elevated to Emeritus status in 1964.

He was a member of the staff of St Luke's Hospital of Cleveland and was active in the residency training program associated with that hospital. He was an active member in the national otolaryngologic community and fondly attended the meetings of the American Laryngological Association until his mid-80s. Although not in active practice, he would attend the academic sessions of the Society and was stimulated by the various treatments of laryngeal cancer by the generation that followed him.

Dr McCall was an avid sportsman who had an interest in hunting and fishing at his family property in Alabama and in the Cleveland area. He is survived by his wife Nancy. The McCalls had no children and no surviving family and therefore Mrs McCall has elected to dedicate Dr McCall's estate to establish a Julius W. McCall Professorship of Otolaryngology-Head & Neck Surgery at Case Western Reserve University School of Medicine.

S.E.K.

## ROSTER OF FELLOWS 1983

Date indicates year admitted to active fellowship. Attendance at meetings is shown by figures following each name. Asterisk (\*) indicates year paper was read. Year and \* in parentheses indicates coauthor of paper but not present at meeting.

### *Active Fellows — 94*

- |  |   |
|--|---|
| <p>1974 Alford, Bobby R., 1200 Moursund Ave, Houston, TX 77025, 1974, '78, '80-'83.</p> <p>1969 Andrews, Albert H. Jr, 122 S Michigan Ave, Chicago, IL 60603, 1970-'74*-'81-'83.</p> <p>1969 Ausband, John R., Emory Univ, 1365 Clifton Rd, NE, Atlanta, GA 30322, 1970-'73, '75, '78, '81.</p> <p>1975 Bailey, Byron J., Dept of Otol, UTMB, Galveston, TX 77550, 1975, '76*, '77, '78, '81, '82.</p> <p>1970 Ballenger, John J., 723 Elm St, Winnetka, IL 60093, 1971-'83.</p> <p>1963 Baxter, James D., 687 Pine Ave West, Montreal, P.Q. H3A 1A1, Canada 1963, '65*-'74, '76-'80, '82.</p> <p>1975 Biller, Hugh F., Mt Sinai Hosp, 100th St &amp; Fifth Ave, New York, NY 10029, 1975-'77*, '78*, '79*, '80*, '81*, '82*, '83*.</p> <p>1977 Blaugrund, Stanley M., 115 E. 61st St, New York, NY 10021, 1977-'83.</p> <p>1975 Boles, Roger, Dept of Otolaryngol, Univ of California, San Francisco, CA 94122, 1975-'82.</p> <p>1955 Bordley, John E., Johns Hopkins Hosp, Baltimore, MD 21205, 1955-'57, '59, '60, '62-'67, '69-'73*-'80, '82, '83.</p> <p>1959 Brewer, David W., 1100 E Genesee St, Syracuse, NY 13210, 1959, '60*, '61, '62*, '63, '66, '70, '73, '74*, '77, '80, '81, '83.</p> <p>1976 Briant, Thomas D. R., St Michael's Hosp, 30 Bond Street, 4B Wing, Toronto, Ont M5B 1W8, Canada, 1976, '77, '78, '80-'82.</p> <p>1955 Brown, Lester A., 490 Peachtree St, NE, Atlanta, GA 30308, 1955-'59, '61, '63, '65, '68-'73*-'80, '82.</p> <p>1963 Bryce, Douglas P., O.P.D. Toronto General Hosp, Toronto, Ont M5T 1P7 Canada, 1963*, '64, '66*, '67*, '68*-'76-'79*, '81, '83.</p> <p>1979 Calcaterra, Thomas C., UCLA Med Ctr, Los Angeles, CA 90224, 1979.</p> <p>1976 Cantrell, Robert W., Univ of Virginia Med Ctr, Charlottesville, VA 22901, 1976, '77*-'80*-'82, '83.</p> <p>1968 Chandler, J. Ryan, 1700 NW 10th Ave, Miami, FL 33136, 1968, '69*-'79*-'82, '83.</p> <p>1967 Cocke, Edwin W. Jr, 920 Madison, Memphis, TN 38103, 1967-'70, '72, '74-'78, '80, '82.</p> <p>1964 Cody, Claude C. III, 7777 Southwest Freeway, Houston, TX 77074, 1964, '65, '67, '69, '71, '73, '77-'79, '81, '83.</p> <p>1971 Cohen, Seymour R., 1300 N Vermont Ave, Los Angeles, CA 90027, 1971, '72*, '73*, '74, '75*, '76*, '77, '78*, '80*, '81*, '82*, '83*.</p> <p>1957 Conley, John J., 211 Central Park West, New York, NY 10024, 1958*, '60*, '61, '62*, '63*, '64, '65, '70, '72, '74*, '75*-'78, '80, '82, ('83*).</p> <p>1980 Cummings, Charles W., Dept of Otolaryngol, Univ of Washington, Seattle, WA 98195, 1980-'82*, '83*.</p> <p>1973 Dedo, Herbert H., Univ of California, S.F. School of Med, Rm 495U, San Francisco, CA 94122, 1973*, '74, '75*, '76*-'79*-'82*, '83.</p> | <p>1966 Devine, Kenneth D., Mayo Clinic, Rochester, MN 55901, 1966-'68, '72*, '74*, '76*.</p> <p>1976 Doyle, Patrick J., 1081 Burrard, Vancouver, BC, V6Z 1Y6, Canada, 1976, '77*, '80*, '81*.</p> <p>1973 Duvall, Arndt J. III, Univ of Minnesota Hosp, A-605 Mayo Memorial Bldg, Minneapolis, MN 55455, 1973*, '75-'78, '80, '81.</p> <p>1968 Farrior, Richard T., 505 DeLeon, Tampa, FL 33608, 1968-'70*, '72, '74, '76-'81.</p> <p>1964 Fearon, Blair, 308 Medical Arts Bldg, Toronto, Ont, M5R 2M7, Canada, 1964, '66-'71*, '72*, '73*, '74*-'78*-'81*, '82, '83.</p> <p>1982 Fee, Willard E., Jr, Stanford Medical Center, Stanford, CA 94305, 1982, '83.</p> <p>1970 Frazer, John P., 601 Elmwood Ave, Rochester, NY 14642, 1971-'82.</p> <p>1977 Fredrickson, John M., Dept of Otolaryngology, Washington University, St Louis, MO 63110, 1977-'79*, '83.</p> <p>1977 Gacek, Richard R., State Univ Hosp of the Upstate Med Ctr, 750 E Adams St, Syracuse, NY 13210, 1977*-'82, '83*.</p> <p>1981 Gates, George, 7703 Floyd Curl Dr, San Antonio, TX 78284, 1981, '82*, '83.</p> <p>1959 Goldman, Joseph L., 55 E 87th St, New York, NY 10028, 1959, '60*-'72*-'78*-'80, '82, '83.</p> <p>1983 Goldstein, Jerome C., AAO-HNS, 1101 Vermont Ave NW, Washington, DC 20005, 1983.</p> <p>1983 Healy, Gerald B., 300 Longwood, Boston, MA 02115, 1983.</p> <p>1983 Hicks, Julius N., 924 S 18th St, Birmingham, AL 35205, 1983.</p> <p>1974 Hudson, William R., Duke Univ Med Ctr, E.N.T., P.O.P., 3805, Durham, NC 27710, 1974-'78*, '81, '82, '83.</p> <p>1983 Jako, Geza J., 8 Porter St, Melrose, MA 02176, 1983.</p> <p>1983 Johns, Michael, Box 430, Univ Virginia Hosp, Charlottesville, VA 22908, 1983.</p> <p>1965 King, James T., 1890 W Paces Ferry Rd, Melrose, MA 02176, 1965-'67, '69-'71, '73-'76, '80.</p> <p>1975 Kirchner, Fernando R., 155 S 18th St, Kansas City, KS 66102, 1975*-'77, '79, '82*.</p> <p>1963 Kirchner, John A., 333 Cedar St, New Haven, CT 06510, 1963, '65*, '67*-'69*-'71*, '72*-'75*, '77, '78, '80*, '82, '83.</p> <p>1979 Krause, Charles J., Univ Hosp, Ann Arbor, MI 48109, 1979-'82*.</p> <p>1981 Lawson, William, 19 E 98th St, New York, NY 10029, 1981*, '82, '83.</p> <p>1979 LeJeune, Francis E. Jr, 1514 Jefferson Hwy, New Orleans, LA 70121, 1979-'82*, '83*.</p> <p>1966 Lewis, John S., 428 W 59th St, New York, NY 10019, 1966-'69*, '72, '74-'76*, '78-'83*.</p> <p>1976 Lingeman, Raleigh E., 1100 W Michigan St, Indianapolis, IN 46202, 1976, '77*-'82*.</p> <p>1973 Lore, John M. Jr, 2121 Main St, Buffalo, NY 14214, 1974*, '76, '77*, '78*, '81.</p> |
|--|---|



- 1978 Lyons, George D., 120 N Jefferson Davis Pkwy, New Orleans, LA 70119, 1978-'80, '82, '83.
- 1966 McCabe, Brian F., Dept of Otolaryngol, Univ Hosp, Iowa City, IA 52242, 1966, '69, '72\*, '73, '75\*, '76, '79\*, '81\*.
- 1976 Miglets, Andrew, 456 Clinic Dr, Rm 4118, Columbus, OH 43210, 1976, '77, '78\*, '80, '82.
- 1952 Miller, Alden H., 1407 N Vermont Ave, Los Angeles, CA 90027, 1952, '53\*, '55, '57, '58\*, '61, '62, '64, '66, '67\*-'73\*, '74\*, '76-'78\*, '79, '81.
- 1965 Miller, Daniel, 110 Francis St, Boston, MA 02215, 1965-'69\*-'73\*-'77\*-'81\*, '82\*, '83.
- 1964 Montgomery, William W., 243 Charles St, Boston, MA 02114, 1964, '65\*, '66\*, '68\*, '70-'72, '74\*-'76\*-'78, '80\*-'82.
- 1972 Morse, Harry R., 645 Powell Dr, Ft Walton Beach, FL 32548, 1972, '75, '79-'81.
- 1979 Myers, Eugene N., Dept of Otolaryngol, 230 Lothrop St, Pittsburgh, PA 15213, 1979, '80, '82\*, '83.
- 1975 Nahum, Alan M., 225 W Dickinson, San Diego, CA 92103, 1975, '76, '79.
- 1981 Neel, H. Bryan III, 200 First St, SW, Rochester, MN 55901, 1981, '82\*, '83.
- 1980 Nichols, Richard D., Henry Ford Hosp, 2799 W Grand, Detroit, MI 48202, 1980, '81.
- 1956 Norris, Charles M., 3401 N Broad St, Philadelphia, PA 19140, 1956-'58\*-'61\*-'64, '66-'68\*-'70\*-'78\*-'83.
- 1982 Olson, Nels R., St Joseph Mercy Hospital, P O Box 944, Ann Arbor, MI 48106, 1982, '83\*.
- 1961 Pang, Lup Q., 1374 Nuuanu Ave, Honolulu, HI 96817, 1961, '62\*, '64, '66, '67, '69, '71-'73, '75, '77, '79-'82.
- 1961 Pastore, Peter N., 5503 Riverside Dr, Richmond, VA 23225, 1961, '62\*, '64, '66, '67, '69-'76, '78, '80, '82.
- 1972 Pennington, Claude L. Jr, 800 First St, Macon, GA 31201, 1972, '73, '75, '76\*, '78, '82, '83.
- 1967 Pratt, Loring W., 325-B Kennedy Memorial Dr, Waterville, ME 04901, 1967-'82.
- 1963 Reed, George F., 750 E Adams St, Syracuse, NY 13210, 1963, '65\*, '66, '68, '69\*-'73, '75-'82\*, '83.
- 1974 Ritter, Frank N., 2675 Englave Dr, Ann Arbor, MI 48103, 1974, '75, '77-'79, '81, '82, '83.
- 1982 Rontal, Eugene, 3774 Wabeek Lake Dr West, Bloomfield Hills, MI 48013, 1982, ('83\*).
- 1981 Sasaki, Clarence T., 333 Cedar St, New Haven, CT 06510, 1981, '83.
- 1964 Saunders, William H., Ohio State Univ, Rm 3110, 456 Clinic Dr, Columbus, OH 43210, 1964-'66, '68\*-'70\*, '71-'75\*-'80, '82\*, '83.
- 1978 Sessions, Donald G., 1960 Grassy Ridge Rd, Kirkwood, MO 63122, 1979\*, '80\*, '81, '83.
- 1983 Sessions, Roy B., 6501 Fannin, Houston, TX 77030, 1983\*.
- 1979 Shapiro, Myron J., 349 E Northfield Rd, Livingston, NJ 07039, 1979-'81.
- 1962 Sisson, George A., Northwestern U Medical School, 303 E Chicago Ave, Chicago, IL 60611, 1962, '63\*, '65, '66, '68-'73, '76-'82.
- 1964 Skolnik, Emanuel M., 1855 W Taylor St, Abraham Lincoln School of Medicine, Chicago, IL 60612, 1964\*, '65, '66\*-'70\*-'73, '75\*-'80\*-'82\*.
- 1974 Snow, James B. Jr, 3400 Spruce St, Philadelphia, PA 19104, 1974-'75\*-'77, '78\*, '79, '81-'83.
- 1972 Soboroff, Burton J., 307 N Michigan Ave, Chicago, IL 60601, 1972-'77, '79, '80, '82.
- 1973 Som, Max L., 121 E 60th St, New York, NY 10022, 1973, '74\*, '75\*, '76-'78\*, '79\*, '80, '82, ('83\*).
- 1954 Sooy, Francis A., Univ of California Hosp, 3rd & Parnassus Ave, San Francisco, CA 94122, 1954, '56\*, '58, '60, '62-'65\*, '67, '68\*, '71, '78, '79, '81, '83.
- 1979 Spector, Gershon J., Dept of Otolaryngol, 517 S Euclid, St Louis, MO 63110, 1979-'82.
- 1975 Sprinkle, Philip M., West Virginia Univ Med Ctr, Morgantown, WV 26505, 1975-'78\*-'82.
- 1975 Strong, M. Stuart, 720 Harrison Ave, Boston, MA 02118, 1975, '76\*, '77, '78\*, '79\*, '81, '82\*, '83.
- 1963 Tabb, Harold G., Dept of Otolaryngol, Tulane Medical School, New Orleans, LA 70112, 1963, '65-'69, '71, '72, '74, '77-'82, '83.
- 1979 Tardy, M. Eugene, 2913 N Commonwealth, No 430, Chicago, IL 60657, 1979, '82\*.
- 1982 Thawley, Stanley E., 517 S Euclid, St Louis, MO 63110, 1982, '83\*.
- 1978 Toomey, James M., 550 N Main St, Attleboro, MA 02703, 1979\*, '80, '81.
- 1967 Tribble, William M., 4504 Greta St, Bethesda, MD 20814, 1967-'69\*, '71-'83.
- 1970 Tucker, Gabriel F. Jr, The Children's Memorial Hosp, 2300 Children's Plaza, Chicago, IL 60614, 1970\*-'73\*-'74\*-'75\*-'77\*-'78\*-'82\*, '83.
- 1979 Tucker, Harvey M., Dept of Otolaryngol, Cleveland Clinic, Cleveland, OH 44106, 1979, '80\*, '81, '82\*.
- 1973 Tucker, John A., Hahnemann Hosp, 230 N Broad St, Philadelphia, PA 19102, 1973\*, '74\*, '75\*, '76, '77\*, '78\*, '80-'82, '83.
- 1980 Vrabec, Donald P., Dept of Otolaryngol, Geisinger Med Ctr, Danville, PA 17821, 1980, '81\*, '83.
- 1974 Ward, Paul H., UCLA School of Medicine, Los Angeles, CA 90024, 1974\*-'76, '77\*, '78\*, '79\*, '81\*, '82\*, '83\*.
- 1951 Woodman, DeGraaf, P O Box 560, Easton, MD 21601, 1951, '53-55\*-'56, '58-'76\*-'80, '82, '83.
- 1981 Yanagisawa, Eiji, 98 York St, New Haven, CT 06511, 1981, '82\*, '83\*.
- 1983 Yarrington, Charles T. Jr, 1100 9th Ave, POB 900, Seattle, WA 98111, 1983.

#### Honorary Fellows — 7

- 1978 (1959) Barretto, Plinio de Mattos, Rua Cons Torres, Homen 371, Sao Paulo, Brazil, 1960, '69, '73, '80.
- 1957 (1925) Clerf, Louis H., 5575 Eighth Ave, North, St Petersburg, FL 33710, 1957-'61, '63-'66, '68-'72\*-'78\*.
- 1978 (1971) Harrison, D. F. N., 330/332 Gray's Inn Road, London, W.C.I., England, 1971, '77, '81\*.
- 1966 (1957) Ono, Jo, 6-13, 6-Chome, Roppongi, Minato-Ku, Tokyo, Japan, 1971.
- 1968 (1937) Portmann, Prof Dr Georges, Clinique S, Augustin, 114, Avenue d'Ares, Bordeaux, France, 1947.
- 1968 (1957) Ruedi, Prof Dr Luzius, Kurhausstrasse 50, Zurich, Switzerland, 1957.
- 1962 (1932) Schall, LeRoy A., P O Box 136, Barnstable, MA 02630, 1964, '66, '68-'69, '72-'77.

#### Corresponding Fellows — 14

- 1978 Arauz, Juan Carlos, 2150 Cangallo, Buenos Aires, Argentina, 1040, 1980.
- 1972 Arslan, Prof Michele, Otorinolaringoiatrica dell' Università da Padova, 37 Via Altinate, Padova, Italy, 1972.

- 1959 Bateman, Sir Geoffrey H., Thorney-Graffham, Petworth, West Sussex, England.
- 1980 Benjamin, Bruce, 229 Macquarie St, Sydney, N.S.W. 2000 Australia, 1980, '81, '83\*.
- 1964 Cleves, Carlos, Apt 202, Carrea 14, No 44-54, Bogota, Colombia, SA.
- 1966 Dohlman, Gosta, 304 Crescent Dr, E Bradenton, FL 22505, 1966.
- 1970 Halliday, Sir George C., 143 Macquarie St, Sydney, N.S.W. Australia.
- 1970 Hutcheon, Jack, Morris Towers, 149 Wickham Terrace, Brisbane, Australia, 1971, '78, '80.
- 1978 Kleinsasser, Oskar, Deutschhausstrabe 3, 355 Marburg (Lahn), Cologne, West Germany, 1982\*.
- 1971 Macbeth, Ronald G., Meadow Close Church Hanborough, Oxford, England.
- 1968 Nakamura, Fumio, Kyoto Prefectural U Medicine, Kawara-Mach 1, Kamikyo-Ku, Kyoto, Japan.
- 1964 Perez, Alfredo C., Instituto Celis Perez, Avenida Montes Deoca, Valencia, Venezuela, 1965.
- 1952 Tapia-Acuña, Ricardo, Av Insurgentes, Sur No 300, Mexico 7 DF, 1953, '57, '60\*, '67, '73, '75, '81\*.
- 1936 Vialle, Jacques, 27 Rue de France, Nice (Alpes Maritimes), France.
- Houston, TX 77027, 1960, '61\*-'65\*-'75, '77-'79, '81-'83.
- 1968 (1942) Heatley, Clyde A., 2500 East Ave, Rochester, NY 14610, 1942, '46\*, '49, '50, '52-'53\*-'55, '57, '58, '60, '61, '65.
- 1978 (1959) Henry, G. Arnold, Suite #2, Group Box 24, Lagoon City, RR #1, Brechin, Ont, L0K 1B0, Canada, 1959, '61, '63, '66, '67, '69, '70, '73.
- 1980 (1955) Hilger, Jerome A., 1700 S Lexington, St Paul, MN 55118, 1955-'56\*-'60, '62-'66, '68-'71, '75-'78, '80, '82.
- 1977 (1957) Holmes, Edgar M., Graydale Circle, Auburndale, MA 02166, 1957, '59, '61, '63, '68, '70-'72, '74-'76, '80.
- 1961 (1950) Kline, Oram R., 896 Lake Ave, Woodbury Heights, NJ 08097, 1961, '63, '70, '72, '74.
- 1983 (1961) Lewy, Robert B., 25 E Washington, Chicago, IL 60602, 1961, '62\*, '63, '65\*, '67-'71, '73-'76\*, '82, '83\*.
- 1980 (1963) McGovern, Francis H., 139 S Main St, Danville, VA 24541, 1963, '64, '66, '68, '71, '72, '74, '75, '77, '79, '81, '82.
- 1974 (1951) McHenry, Lawrence C., 1607 Glenbrook Terrace, Oklahoma City, OK 73116, 1953\*, '62-'66, '68, '71.
- 1970 (1931) McNally, William J., 25 Redpath Pl, Montreal, Canada, H3G 1E2, 1972-'75.
- 1978 (1957) Munoz-MacCormick, Carlos Eduardo, 71 de Diego, Santurce, PR 00911, 1957-'80, '82, '83.
- 1971 (1953) Murtagh, John A., 1198 A1A Apt 240, Hillsboro Beach, Pompano, FL 33062, 1953-'56\*, '57-'61, '62-'63, '65-'67, '69, '70, '72, '74, '76, '78-'80, '82.
- 1981 (1958) O'Keefe, John J., 1499 Monk Rd, Gladwyn, PA 19035, 1958-'59\*, '60, '62, '64, '67, '71, '73, '75, '78.
- 1976 (1951) Priest, Robert E., 48 Groveand Ter, Minneapolis, MN 55403, 1977-'81.
- 1980 (1951) Putney, F. Johnson, 80 Barre St, Charleston, SC 29401, 1951-'53\*-'58\*-'63\*-'64\*-'68\*-'69\*-'70\*-'72, '74-'78\*, '79\*, '82.
- 1972 (1956) Richardson, John R., PO Box 52, Searsport, ME 04974.
- 1981 (1959) Sanders, Sam H., 1286 Peabody Ave, Memphis, TN 38104, 1959-'63, '65, '70-'73, '75, '78.
- 1977 (1958) Simonton, Kinsey M., c/o Foster, Duxbury, MA 02332, 1958, '59\*, '62, '64, '66, '67, '69, '72, '74, '75, '78, '82.
- 1969 (1950) Smith, Austin T., 8401 Roosevelt Bldg, Philadelphia, PA 19152, 1970-'74.
- 1982 (1961) Suehs, Oliver W., 2805 Robbs Run, Austin, TX 78705, 1961, '62\*-'64, '66, '68-'72, '74-'78, '80.
- 1983 (1954) Thornell, William C., 2328 Auburn Ave, Cincinnati, OH 45219, 1957, '59, '63, '68, '70, '72, '74, '77, '78, '80.
- 1973 (1963) Tolan, John F., 3419 47th Ave, NE, Seattle, WA 98105, 1963-'67, '69, '71, '73.
- 1961 (1941) Viole, Pierre P., 241 South Windsor, Los Angeles, CA 90004, 1964.
- 1977 (1962) Weaver, Delmar F., Med Professional Bldg, PO Box 862, Culpeper, VA 22701, 1962-64\*, '65, '67\*, '69-'70, '72, '74, '76.
- 1983 (1971) Williams, Russell I., 414 E 23rd St, Cheyenne, WY 82001, 1971, '72\*-'74, '76-'78\*, '80.
- 1975 (1953) Work, Walter P., 172 E Paseo de Golf, Green Valley, AZ 85614, 1953, '54, '56, '58, '59\*, '62, '63\*, '65, '67-'69, '72, '73, '75, '76, '78\*, '79\*, '82.
- Emeritus Fellows — 36*
- 1980 (1962) Arnold, Godfrey E., 2500 N State St, Jackson, MS 39216, 1962, '63\*, '64\*, '66, '69, '70, '72, '73, '75, '77, '79.
- 1973 (1944) Boies, Lawrence R., Dept of Otolaryngol, A-605, Mayo Memorial Bldg, Minneapolis, MN 55455, 1944, '46-'48\*-'50-'51\*, '53-'68\*-'69, '71.
- 1965 (1942) Canfield, Norton, PO Box 1383, Miami, FL 33133, 1982.
- 1978 (1959) Cracovaner, Arthur J., 170 W End Ave, New York, NY 10023, 1959-'61\*-'63, '65-'69, '72, '74-'76, '78-'79.
- 1982 (1960) Daly, John F., 16 N Brae Ct, Tenafly, NJ 07670, 1960, '61\*, '79\*, '81.
- 1977 (1951) Davison, Francis W., Geisinger Med Ctr, Danville, PA 17821, 1951-'53\*-'63\*-'67\*-'69\*-'73\*-'75, '77, '78\*, '79.
- 1980 (1968) DeWeese, David D., 3181 SW Sam Jackson Park Rd, Portland, OR 97202, 1968-'69\*, '73-'80, '82.
- 1972 (1962) Erich, John B., Mayo Clinic, 102 Second Ave, Rochester, MN 55901.
- 1982 (1963) Ferguson, Charles R., P O Box 313, Osterville, MA 02655, 1963, '64\*, '66, '67\*, '68, '69\*-'74\*-'78\*-'82.
- 1983 (1956) Friedberg, Stanton, 1725 W Harrison St, Chicago, IL 60612, 1956, '57, '65\*, '71\*, '76\*, '78\*, '79\*, '80, '82, '83\*.
- 1979 (1955) Fitz-Hugh, Glassell S., 145 Blue Ridge Rd, Charlottesville, VA 22903, 1955, '57, '59-'62\*, '64-'67\*, '68-'77\*, '78.
- 1970 (1940) Goodale, Robert L., 141 Argilla Rd, Ipswich, MA 01938, 1971, '74-'76.
- 1963 (1928) Goodyear, Henry M., 2012 Edgecliff Point, Cincinnati, OH 45206.
- 1980 (1965) Hanckel, Richard W. Jr, 506 E Cleves, Florence, SC 29501, 1965-'67, '69-'74, '77-'80.
- 1978 (1960) Harris, Herbert H., 3457 Meadow Lake Lane,



## OFFICERS 1983-1984

≈

### PRESIDENT

JOHN S. LEWIS, MD

### VICE-PRESIDENT (PRESIDENT-ELECT)

GABRIEL F. TUCKER, JR, MD

### SECRETARY

EUGENE N. MYERS, MD

### TREASURER

LORING W. PRATT, MD

### HISTORIAN-EDITOR

JAMES B. SNOW, JR, MD

### FIRST COUNCILOR

DANIEL MILLER, MD

### SECOND COUNCILOR

HAROLD G. TABB, MD

### THIRD COUNCILOR

M. STUART STRONG, MD

### COUNCILORS AT LARGE

BYRON J. BAILEY, MD

ROGER BOLES, MD

# INDEX

## AUTHORS

<b>B</b>		<b>J</b>		<b>R</b>	
Belisle GM	100	Jacob HJ	25	Rabuzzi DD	86
Benjamin B	52			Rammage LA	100
Biller HF	73	<b>K</b>		Rolnick MI	25
Birns JW	41	Kusonruksa T	14	Rontal E	25
Bishop MJ	48			Rontal M	25
Blatt IM	66	<b>L</b>		Rosen M	28
Boles R	7	Lawson W	73		
<b>C</b>		LeJeune FE	79	<b>S</b>	
Carter P	52	Lewis JS	14	Sachs ME	86
Cohen SR	41	Lewy RB	77	Samuels PM	79
Conley J	86, 95			Sessions RB	60
Cummings CW	82	<b>M</b>		Simpson JR	89
<b>D</b>		Malmgren LT	28	Som ML	73
Dichtel WJ	60	Marks JE	89	Spelman FA	48
Donovan DT	60, 95	Miller D	12	Stearns M	82
<b>F</b>		Morrison MD	100	Strong MS	11, 12
Fink BR	48	Myers EN	7	Strothers G	34
Friedberg SA	74			Sutton D	82
<b>G</b>		<b>N</b>		<b>T</b>	
Gacek RR	28	Neal GD	82	Thawley SE	89
Geller KA	41	Nichol H	100	Thompson JW	41
Gerratt BR	17			Trachy R	82
Goepfert H	60	<b>O</b>		Tucker GF Jr	7
Guice CE	79	Ogura JH	89		
Guterman JU	60	Olson NR	108	<b>V</b>	
<b>H</b>		Owens TW	34	Vallejo A	14
Hanson DG	17			<b>W</b>	
Hibbard AW	48	<b>P</b>		Ward PH	17
Honda K	34	Perez CA	89	Weymuller EA Jr	48
		Perkins WH	104		
		Pratt LW	8	<b>Y</b>	
		Pullan CB	100	Yanagisawa, E	34

## SUBJECTS

<b>A</b>		Carcinoma of base of tongue, preoperative irradiation and surgery for		89
Acid, stomach, effects on larynx	108	Computer reconstruction, three-dimensional, of distribution of neuromuscular junctions in thyroarytenoid muscle		28
Address, Guest of Honor	12	Congenital laryngeal hemangioma		52
Presidential	11	<b>D</b>		
Adenoid cystic carcinoma of subglottic region	95	Discussions	113	
Anastomosis, tracheal, intralaryngeal release for	86	Dysphonia		
Awards		Muscular tension	100	
Casselberry	10	Spastic, laryngeal nerve crush for	73	
DeRoaldes	10	<b>E</b>		
Newcomb	10	Endotracheal tubes, quantification of intralaryngeal pressure exerted by	48	
<b>B</b>				
Base of tongue, carcinoma of, preoperative irradiation and surgery for	89			
<b>C</b>				
Carcinoma, adenoid cystic, of subglottic region	95			



## Executive Sessions

First Session, Minutes of .....	6
Second Session, Minutes of .....	6
Reports .....	7

## F

Fellows, Registration of .....	4
Roster of .....	123

## G

Guest of Honor Address .....	12
Introduction .....	12

## H

Hemangioma, congenital laryngeal .....	52
--	----

## I

Interferon, a comparison of sources in treatment of recurrent respiratory papillomatosis .....	60
Intralaryngeal pressure exerted by endotracheal tubes, quantification of .....	48
Intralaryngeal release for tracheal anastomosis .....	86
Irradiated larynx, surgical dilemma of .....	14

## J

Johnson, Hosmer A: early midwestern laryngologist .....	74
---	----

## L

Laryngeal nerve crush for spastic dysphonia .....	73
Larynx	
Effects of stomach acid on .....	108
Irradiated, surgical dilemma of .....	14
Paralyzed, muscle transposition in rehabilitation of .....	82
Ligament tightening, vocal, early experiences with .....	79

## M

Memorial Fund: Laryngeal Research Fund .....	10
Memorials:	
Frank D. Lathrop .....	121
Julius W. McCall .....	122
Muscle transposition in rehabilitation of paralyzed larynx .....	82
Muscular tension dysphonia .....	100
Mutation, voice, training singing children during phases of .....	66

## N

Nerve crush, laryngeal, for spastic dysphonia .....	73
Neuromuscular junctions in thyroarytenoid muscle, three-dimensional computer reconstruction of distribution of .....	28

## O

Officers 1982-1983 .....	4
1983-1984 .....	126

## P

Papillomatosis, recurrent respiratory, comparison of sources of interferon in treatment of .....	60
Pediatric patient, voice change in .....	41
Preoperative irradiation and surgery for carcinoma of base of tongue .....	89

## R

Recurrent respiratory papillomatosis, comparison of sources of interferon in treatment of .....	60
Registration of Fellows for Annual Meeting .....	4
Reports	
Accountant .....	8
Historian-Editor .....	7
Governor of the American College of Surgeons .....	7
Research Committee .....	7
Secretary .....	7
Treasurer .....	8

## S

Spastic dysphonia, laryngeal nerve crush for .....	73
Stomach acid, effects on larynx .....	108
Subglottic region, adenoid cystic carcinoma of .....	95
Surgery, preoperative irradiation and, for carcinoma of base of tongue .....	89

## T

Teflon injection of vocal cord .....	77
Thyroarytenoid muscle, three-dimensional computer reconstruction of distribution of neuromuscular junctions in .....	28
Tongue, base of, carcinoma of, preoperative irradiation and surgery for .....	89
Tracheal anastomosis, intralaryngeal release for .....	86

## V

Videolaryngoscopy: comparison of fiberoptic and telescopic documentation .....	34
Vocal cord, Teflon injection of .....	77
Vocal cord function, quantitative and objective evaluation of .....	25
Vocal dysfunction, glottographic measurement of .....	17
Vocal function, why investigate .....	104
Vocal ligament tightening, early experiences with .....	79
Voice change in pediatric patient .....	41
Voice mutation, training singing children during phases of .....	66











