

San Bernardino
New York
6/26/87

TRANSACTIONS
AMERICAN
LARYNGOLOGICAL ASSOCIATION

1986

VOLUME ONE HUNDRED SEVEN



"DOCENDO DISCIMUS"

≈

ONE HUNDRED SEVENTH ANNUAL MEETING

THE BREAKERS

PALM BEACH, FLORIDA

MAY 4 AND 5, 1986

≈

PUBLISHED BY THE ASSOCIATION
ST LOUIS, MISSOURI
JAMES B. SNOW, JR, MD, Editor

CONTENTS

Annual Photograph	4
Officers for 1985-1986	5
Registration of Fellows	5
Minutes of Executive Sessions	7
Reports	
Secretary, Eugene N. Myers, MD	8
Historian-Editor, James B. Snow, Jr, MD	8
Governor, American College of Surgeons, Michael E. Johns, MD	8
Treasurer, John M. Fredrickson, MD	9
Recipients of De Roaldes, Casselberry, and Newcomb Awards	11
The Memorial and Laryngological Research Funds	11
Presidential Remarks. Douglas P. Bryce, MD	12
Introduction of Guest of Honor Emanuel E. Skolnik, MD. Douglas P. Bryce, MD	14
Guest of Honor Address. International Professional Relationships (World Peace and Medicine). Emanuel E. Skolnik, MD	15


SCIENTIFIC SESSIONS

Carbon Dioxide Laser Resection of Superficial Oral Carcinoma: Indications, Technique, and Results Thomas L. Guerry, MD; Sol Silverman, Jr, DDS; Herbert H. Dedo, MD	21
Anesthetic Management for Tracheobronchial Laser Surgery Michael Rontal, MD; Eugene Rontal, MD; Milford E. Wenokur, MD; Lawrence Elson	30
Twelfth Daniel C. Baker, Jr, Memorial Lecture. Victor Negus: 57 Years Later Donald F. N. Harrison, MD, PhD	35
Lymphangiomas of the Larynx in Infants and Children. A Survey of Pediatric Lymphangioma Seymour R. Cohen, MD; Jerome W. Thompson, MD	41
Imbrication Reconstruction Following Partial Laryngectomy Chen Liu, MD; Paul H. Ward, MD; Lawrence Pleet, MD	61
Long-Term Results of Concurrent Polychemotherapy and Radiotherapy in Patients With Stomal Recurrence After Total Laryngectomy A. J. M. Balm, MD, PhD; G. B. Snow, MD, PhD; A. B. M. F. Karim, MD, PhD; R. J. J. Versluis, MD; K. H. Njo, MD; R. M. Tiwari, FRCS, PhD	66
Posterior Glottis. Morphological Study in Excised Human Larynges Minoru Hirano, MD; Shigejiro Kurita, MD; Kensuke Kiyokawa, MD; Kiminori Sato, MD	70
Experience With Partial Cricoid Resection and Thyrotracheal Anastomosis F. G. Pearson, MD, FRCS(C); L. Brito-Filomeno, MD; J. D. Cooper, MD, FRCS(C)	76
Staged Repair of Extensive Tracheal and Laryngotracheal Stenoses Hugh F. Biller, MD; William Lawson, MD, DDS; Verne Weisberg, MD	80
Diagnosis and Treatment of Small Cell Carcinoma of the Larynx: A Critical Review Alfio Ferlito, MD	84
The Quiet Revolution. Techniques of Cell Biology Applied to Tissue Diagnosis A. W. Peter van Nostrand, MD, FRCP(C)	95
Demonstration of Human Papillomavirus Capsid Antigen in Carcinoma in Situ of the Larynx Haskins Kashima, MD; Phoebe Mounts, PhD; Francis Kuhajda, MD; Mark Loury, MD	97
Estrogen Receptor in the Larynx of the Aged Baboon (<i>Papio Cynocephalus</i>) G. Richard Holt, MD; Thomas B. Aufdemorte, DDS; Peter J. Sheridan, PhD	102
Vocal Cord Paralysis in Small Children: Principles in Management Harvey M. Tucker, MD	112
Vocal Cord Paralysis in Children 1 Year of Age and Younger Richard D. Gentile, MD; Robert H. Miller, MD; Gayle E. Woodson, MD	116
Risk Factors for Neonatal Acquired Subglottic Stenosis Steven K. Dankle, MD; David E. Schuller, MD; Richard E. McClead, MD	120
Three-Year Experience of Treating Recurrent Respiratory Papilloma With Interferon Rodney P. Lusk, MD; Brian F. McCabe, MD; Janis H. Mixon, RN	125
New Technique of Soft Palate Reconstruction Using a Hypopharyngeal Myomucosal Flap Yasushi Murakami, MD; Taketsugu Ikari, MD; Shigiji Saito, MD; Jo Ono, MD	130
Incidence of Large Saccules in Laryngectomy Specimens Derek Birt, MB, FRCS(C)	135

Immunohistochemistry: Help in Diagnosis of Histologically Ambiguous Lesions of the Head and Neck Robert C. Bone, MD; James A. Robb, MD	145
Clinical and Computed Tomographic Correlations of Pharyngolaryngeal Cancer With Whole Organ Serial Sections in the Axial Plane. Historadiographic Analysis of 60 Cases Patrick J. Gullane, MD; Tom E. Havas, MB; Anne Keller, MD; A. W. P. van Nostrand, MD; Ivo Brodaric, MD; Harry S. Shulman, MD	149
Endoscopic Management of Laryngeal Stenosis With the Carbon Dioxide Laser (Abstract) M. Stuart Strong, MD	154
Discussions	155
~	
Memorials	
Francis H. McGovern, MD	162
John A. Murtagh, MD	163
Roster of Fellows 1986	165
Officers 1986-1987	169
Index	170

INDEX

ABRAHAM, BENJAMIN
 ABLESON, EDWARD
 ADAMS, BYRON J.
 ADAMS, JOHN
 ADAMS, JAMES D.
 ADAMS, HUGH F.
 ADAMS, STANLEY
 ADAMS, ROGER
 ADAMS, ROBERT C.
 ADAMS, T. DAVEN
 ADAMS, DOUGLAS
 ADAMS, ROBERT W.
 ADAMS, JAMES R.
 ADAMS, PAUL E.
 ADAMS, EDWIN W.
 ADAMS, SEYMOUR
 ADAMS, HENRY L.
 ADAMS, CHARLES W.
 ADAMS, HERBERT H.
 ADAMS, PATRICK J.
 ADAMS, ARTHUR L.
 ADAMS, RICHARD T.
 ADAMS, BLAIR W.
 ADAMS, WILLIAM L. JR.
 ADAMS, JAMES P.
 ADAMS, JOHN M.
 ADAMS, RICHARD H.
 ADAMS, GEORGE A.
 ADAMS, JEROME C.
 ADAMS, CHARLES W.
 ADAMS, GERALD B.
 ADAMS, JULIUS N.
 ADAMS, LAUREN D.



FELLOWS IN ATTENDANCE AT THE ONE HUNDRED SEVENTH ANNUAL MEETING

First Row: Farrior, Chandler, Skolnik, Harrison, Shaw, Hirano, Briant, Cocke, Bryce, Sooy, Ferlito, D. Sessions, Pratt, Myers, Dedo, G. Tucker, J. Tucker.

Second Row: Cohen, Murakami, J. Kirchner, Som, Rontal, Biller, Blaugrund, Lewis, Fearon, Woodman, Kashima, Harris, Bordley, Miller, Sisson, Norris, Baxter, Frazer.

Third Row: Boles, G. Snow, Bone, Ward, Gates, Healy, Tabb, Morrison, Holinger, Cantrell, Strong, Doyle, Alford, Ritter, Shapiro, Schild, Soboroff, Conley, Lewy, Ballenger.

OFFICERS 1985-1986

PRESIDENT

DOUGLAS P. BRYCE, MD

VICE-PRESIDENT (PRESIDENT-ELECT)

LORING W. PRATT, MD

SECRETARY

EUGENE N. MYERS, MD

TREASURER

JOHN M. FREDRICKSON, MD

HISTORIAN-EDITOR

JAMES B. SNOW, JR, MD

FIRST COUNCILOR

M. STUART STRONG, MD

SECOND COUNCILOR

JOHN S. LEWIS, MD

THIRD COUNCILOR

GABRIEL F. TUCKER, JR, MD

COUNCILORS-AT-LARGE

PATRICK J. DOYLE, MD

GERALD B. HEALY, MD

REGISTRATION OF FELLOWS

ACTIVE

ALFORD, BOBBY R.
APPLEBAUM, EDWARD L.
BAILEY, BYRON J.
BALLENGER, JOHN J.
BAXTER, JAMES D.
BILLER, HUGH F.
BLAUGRUND, STANLEY M.
BOLES, ROGER
BONE, ROBERT C.
BRIANT, T. DAVID R.
BRYCE, DOUGLAS P.
CANTRELL, ROBERT W.
CHANDLER, JAMES R., JR
CHODOSH, PAUL L.
COCKE, EDWIN W., JR
COHEN, SEYMOUR R.
CRUMLEY, ROGER L.
CUMMINGS, CHARLES W.
DEDO, HERBERT H.
DOYLE, PATRICK J.
DUVALL, ARNDT J. III
FARRIOR, RICHARD T.
FEARON, BLAIR W.
FEE, WILLARD E., JR
FRAZER, JOHN P.
FREDRICKSON, JOHN M.
GACEK, RICHARD R.
GATES, GEORGE A.
GOLDSTEIN, JEROME C.
GROSS, CHARLES W.
HEALY, GERALD B.
HICKS, JULIUS N.
HOLINGER, LAUREN D.

HUDSON, WILLIAM R.
JOHNS, MICHAEL E.
KASHIMA, HASKINS K.
KIRCHNER, FERNANDO R.
KRAUSE, CHARLES J.
LAWSON, WILLIAM
LEJEUNE, FRANCIS E., JR
LEWIS, JOHN S.
LINGEMAN, RALEIGH E.
LORÉ, JOHN M., JR
MCCABE, BRIAN F.
MONTGOMERY, WILLIAM W.
MORRISON, MURRAY D.
MYERS, EUGENE N.
NEEL, H. BRYAN III
NOYK, ARNOLD M.
PENNINGTON, CLAUDE L.
PRATT, LORING W.
REED, GEORGE F.
RICE, DALE H.
RITTER, FRANK N.
RONTAL, EUGENE
SASAKI, CLARENCE T.
SAUNDERS, WILLIAM H.
SCHILD, JOYCE A.
SESSIONS, DONALD G.
SESSIONS, ROY B.
SHAPIRO, MYRON J.
SISSON, GEORGE A.
SKOLNIK, EMANUEL M.
SNOW, JAMES B., JR
SOBOROFF, BURTON J.
SPRINKLE, PHILIP M.
STRONG, M. STUART

TABB, HAROLD G.
TARDY, M. EUGENE, JR
TUCKER, GABRIEL F., JR
TUCKER, HARVEY M.
TUCKER, JOHN A.
VAUGHAN, CHARLES W.
VRABEC, DONALD P.
WARD, PAUL H.
WOODMAN, DEGRAAF
YARINGTON, CHARLES T., JR

EMERITUS

BORDLEY, JOHN E.
HARRIS, HERBERT H.
KIRCHNER, JOHN A.
LEWY, ROBERT B.
MILLER, DANIEL
PASTORE, PETER N.
PUTNEY, F. JOHNSON
SOOY, FRANCIS A.

HONORARY

CONLEY, JOHN J.
HARRISON, D. F. N.
NORRIS, CHARLES M.

CORRESPONDING

FERLITO, ALFIO
HIRANO, MINORU
MURAKAMI, YASUSHI
SHAW, HENRY
SNOW, GORDON B.

MINUTES OF THE EXECUTIVE SESSIONS

FIRST SESSION — MAY 4, 1986

The First Executive Session of the 107th Annual Meeting was convened at 7 AM in the Venetian Room of The Breakers, Palm Beach, Florida, Douglas P. Bryce, MD, Toronto, presiding. The following candidates, having been recommended for Fellowship by the Council, were elected to *Honorary Fellowship*: Wilbur J. Gould, MD, New York; to *Active Fellowship*: Lauren D. Holinger, MD, Chicago; Murray D. Morrison, MD, Vancouver; Arnold M. Noyek, MD, Toronto; to *Emeritus Fellowship*: John E. Bordley, MD, Baltimore; Lester A. Brown, MD, Atlanta; Francis A. Sooy, MD, San Francisco; to *Corresponding Fellowship*:

Alfio Ferlito, MD, Padua, Italy; Rolando Fonseca, Buenos Aires, Argentina.

Following their election the new Active Fellows and Dr Alfio Ferlito were introduced to the Association by their respective sponsors, presented with certificates of fellowship, and welcomed by President Bryce.

The following Fellows were elected as members of the Nominating Committee: Roger Boles, Chairman; Michael E. Johns; Harold G. Tabb; T. David R. Briant; Charles W. Cummings.

SECOND SESSION — MAY 5, 1986

The Second Executive Session was opened by President Bryce at 12:30 PM, and the report of the Nominating Committee was received from the Chairman, Dr Roger Boles. The following Fellows were nominated to the Council and elected unanimously: Loring W. Pratt; Blair Fearon; Eugene N. Myers; John M. Fredrickson; James B. Snow, Jr; John S. Lewis; Gabriel F. Tucker, Jr; Douglas P. Bryce; Hugh F. Biller; John A. Tucker.

The reports of the following officers were submitted and duly accepted: Report of the Secretary, Report of the Historian-Editor, and Report of the Treasurer. Dr Michael E. Johns presented the Report of the Governor of the American College of Surgeons. The meeting was adjourned until the end of the Scientific Session.

At the close of the Scientific Session, the Executive Session was reconvened by President Bryce. At the President's direction, the newly elected members of the Council, acting as Directors of the Association, organized themselves for the year 1986-1987 as follows: President: Loring W. Pratt, MD; Vice-President (President-Elect): Blair Fearon, MD; Secretary: Eugene N. Myers, MD; Treasurer: John M. Fredrickson, MD; Historian-Editor: James B. Snow, Jr, MD; First Councilor: John S. Lewis, MD; Second Councilor: Gabriel F. Tucker, Jr, MD; Third Councilor: Douglas P. Bryce, MD; Councilors-at-Large: Hugh F. Biller, MD; John A. Tucker, MD. Dr Eugene N. Myers thanked Dr Bryce for his outstanding work as President of the Association. Dr Bryce introduced Dr Loring W. Pratt as the new President of the Association.

REPORTS

REPORT OF THE SECRETARY

The membership at the present time consists of 9 Honorary members, 44 Emeritus members, 22 Corresponding members, and 95 Active members.

The meeting of the Council of the American Laryngological Association will be held in conjunction with the meeting of the Eastern Section of the Triological Society at the Westin Hotel, Boston, Massachusetts, January 29-31, 1987.

The next meeting of the American Laryngological Association will be held at the Fairmont Hotel in Denver, Colorado, April 25-26, 1987.

Respectfully submitted,
Eugene N. Myers, MD
Secretary

REPORT OF THE HISTORIAN-EDITOR

I have the sad duty to report the deaths of two Emeritus Fellows. Francis H. McGovern was elected to Fellowship in 1963 and was elevated to Emeritus Fellowship in 1980. He was a Benefactor of the Laryngological Research Fund. He died on July 9, 1985. John A. Murtagh was elected to Fellowship in 1953 and served the Association as Vice-President in 1968. He was elevated to Emeritus Fellowship in 1971. He died on January 15, 1986.

The papers presented at this meeting will be published in the November-December 1986 issue of the *Annals of Otology, Rhinology & Laryngology*.

The library of the Historian-Editor of the Association does not have a copy of the *Transactions* for the years 1879-85, 1888-89, 1891, 1893-97, 1899-1915, 1917, 1920-29, 1932-33, 1939, 1940, 1943, 1955, 1958, 1960, 1970, and 1976. The Association will

gratefully receive copies of the missing issues as tax deductible contributions. A complete set from 1879 through 1985 belonging to the Association is maintained in the library of the Eye and Ear Hospital in Pittsburgh.

Issues are available for sale to Fellows of the Association for \$2.00 per copy for the years 1918, 1942, 1944-49, 1951, 1953-54, 1958-59, 1962, 1964-69, 1971-75, 1977-85.

Manuscripts for the 1987 meeting should be in the hands of the Editor of the *Annals of Otology, Rhinology & Laryngology* by March 1, 1987.

Respectfully submitted,
James B. Snow, Jr, MD
Historian-Editor

REPORT OF THE GOVERNOR OF THE AMERICAN COLLEGE OF SURGEONS

Thank you for allowing me to serve as your Governor to the American College of Surgeons. Since the last annual meeting of this Association, I have participated in the activities of both the Maryland chapter of the American College of Surgeons and the annual meeting of the American College of Surgeons. The American College of Surgeons has identified the concerns of its members, and they include first and foremost the professional liability crisis. In addition, other concerns include alternate health care delivery systems, reimbursement and fees, changing hospital management practices, and DRGs. The American College of Surgeons has begun to address these issues with vigor, typifying the change in the College's direction. Although its tradi-

tional roles have centered on education, standards, and ethics, it has altered its stance, and has increased its activities in the area of socioeconomics. This new attitude, which will allow it to serve its constituency more aggressively than in the past, has become rapidly evident. I believe the American College of Surgeons will be a strong force in molding the future of surgery in this country, and we must take an active part in directing its policy activities.

Respectfully submitted,
Michael E. Johns, MD
Governor, American College of Surgeons

REPORT OF THE TREASURER

To the Board of Directors of the
American Laryngological Association

We have compiled the accompanying statement of assets, liabilities, and fund balances of the American Laryngological Association (a not-for-profit corporation) as of March 31, 1986; the related statements of income, fund balance, and changes in financial position; and additional information for the year then ended, in accordance with standards established by the American Institute of Certified Public Accountants.

A compilation is limited to presenting, in the form of financial statements, information that is the representation of management. We have not audited or reviewed the accompanying financial statements and additional information and, accordingly, do not express an opinion or any other form of assurance on them.

Rothaus, Bartels, Wolfe & Company, PC
Certified Public Accountants

St Louis, Missouri
April 22, 1986

STATEMENT OF ASSETS, LIABILITIES, AND
FUND BALANCES — MARCH 31, 1986

ASSETS

Current Assets:

Cash and cash equivalents	\$133,154
Accounts receivable — dues	3,750
Accrued interest receivable	4,692
Deposits	508
	<u>142,104</u>
Marketable securities	78,958

Total Assets \$221,062

LIABILITIES AND FUND BALANCES

Liabilities:

Accounts payable	\$ 1,762
Prepaid dues income	3,450
	<u>5,212</u>

Fund Balances:

General Fund	\$ 14,274
Trust Fund	201,576
	<u>215,850</u>

Total Liabilities and Fund Balance \$221,062

See accountants' compilation report and notes to financial statements.

STATEMENTS OF INCOME AND FUND BALANCE —
TRUST FUNDS
FOR THE YEAR ENDED MARCH 31, 1986

STATEMENT OF INCOME

Income:

Interest income (note 3):	
US Treasury notes	\$ 8,570
Certificates of deposit	5,051
Miscellaneous	1,000
	<u>14,621</u>
Dividend income (note 3)	1,553
Memorial Fund donation: Leroy Schall ..	125

16,299

Expenses:

Baker Fund	1,834
Casselberry Fund	1,000
De Roaldes Fund	398

3,232

Net Income (Loss) \$ 13,067

STATEMENT OF FUND BALANCE

Fund Balance, March 31, 1985, as previously reported	\$185,587
Cumulative effect on prior years of retroactive restatement for accounting change (note 3)	<u>2,922</u>
Fund Balance, March 31, 1985, as restated	188,509
Net Income (Loss)	13,067
Fund Balance, March 31, 1986	<u>\$201,576</u>

See accountants' compilation report and notes to financial statements.

STATEMENTS OF INCOME AND FUND BALANCE —
GENERAL FUND
FOR THE YEAR ENDED MARCH 31, 1986

STATEMENT OF INCOME

Income:

Dues	\$17,625
Tickets — annual meeting	7,650
Tickets — council meeting	719
Sale of publications	2,036
Interest	<u>3,994</u>

32,024

Expenses:

Annual meeting and banquet	12,475
Council travel and expenses	4,919
General and administrative expenses:	
Printing, postage and supplies	9,016
Professional fees	2,100
Wages — clerical	<u>2,119</u>

30,629

Net Income (Loss) \$ 1,395

STATEMENT OF FUND BALANCE

Fund Balance, March 31, 1985, as previously reported	\$(587)
Cumulative effect on prior years of retroactive restatement for correction of error (note 2)	16,991
Cumulative effect on prior years of retroactive restatement for accounting change (note 3)	<u>(3,525)</u>
Fund Balance, March 31, 1985, as restated	12,879
Net Income (Loss)	1,395
Fund Balance, March 31, 1986	<u>\$14,274</u>

See accountants' compilation report and notes to financial statements.

STATEMENT OF CHANGES IN FINANCIAL POSITION
FOR THE YEAR ENDED MARCH 31, 1986SCHEDULE OF MARKETABLE SECURITIES
MARCH 31, 1986

Sources of Cash:

Net income	\$ 14,462
Sale of marketable security	19,974
Increase in accounts payable	<u>1,762</u>
	<u>36,198</u>

Uses of Cash:

Increase in accounts receivable	3,750
Increase in accrued interest receivable	1,770
Increase in deposits	508
Decrease in prepaid dues income	<u>75</u>
	<u>6,103</u>
Increase in Cash	30,095
Cash, March 31, 1985	103,059
Cash, March 31, 1986	<u>\$133,154</u>

See accountants' compilation report and notes to financial statements.

		Cost	Market Value
US Treasury note \$65,000 12.375 %, due Aug 31, 1986		\$64,978	\$ 66,521
Stocks:			
American Telephone & Telegraph	200 shares	3,093	4,525
Ameritech	20 shares	1,122	2,255
Bell Atlantic	20 shares	1,138	2,295
Bell South	60 shares	1,471	3,120
IBM	40 shares	1,321	6,035
McDonnell Douglas	165 shares	1,194	12,926
McIntyre Mines Ltd	15 shares	675	444
Nynex	20 shares	1,068	2,195
Pacific Telesis	20 shares	897	1,765
Southwestern Bell	20 shares	1,030	1,765
US West	20 shares	971	1,930
		<u>13,980</u>	<u>39,255</u>
		<u>\$78,958</u>	<u>\$105,776</u>

See accountants' compilation report and notes to financial statements.

SCHEDULE OF INDIVIDUAL TRUST FUNDS FOR THE YEAR ENDED MARCH 31, 1986

	Fund Balance 3/31/85	Receipts			Disbursements	Transfers	Fund Balance 3/31/86
		Donations	Investment Income	Total			
Daniel C. Baker, Jr, Memorial Fund	\$ 33,446	—	\$ 2,870	\$ 2,870	\$(1,834)	—	\$ 34,482
Casselberry Fund	18,628	—	1,598	1,598	(1,000)	—	19,226
Johnston Fund	17,624	—	1,512	1,512	—	—	19,136
De Roaldes Fund	10,328	—	886	886	(98)	—	10,816
Newcomb Trust Fund	6,915	—	593	593	—	—	7,508
Newcomb Prize Fund	1,608	—	138	138	—	—	1,746
Research Fund	70,620	—	6,059	6,059	—	\$ 2,518	79,197
Memorial Fund	29,340	\$125	2,518	2,643	—	(2,518)	29,465
Total	<u>\$188,509</u>	<u>\$125</u>	<u>\$16,174</u>	<u>\$16,299</u>	<u>\$(3,232)</u>	<u>\$ —</u>	<u>\$201,576</u>

See accountants' compilation report and notes to financial statements.

NOTES TO THE FINANCIAL STATEMENTS — MARCH 31, 1986

Note 1. Summary of significant accounting principles

- Accounting basis. The Association uses the accrual method of accounting for financial statement reporting purposes, and the cash method of accounting for income tax reporting purposes.
- Nature of operations. The Association shall have for its purposes: the advancement and promotion of the study of the science of medicine and surgery, devoting special attention to the upper aerodigestive tract and to engage in, and to encourage, research with respect thereto; the elevation of standards of the fundamental study and teaching of rhinology and laryngology in the undergraduate and postgraduate medical schools of America; the publishing annually of the proceedings of this Association; and the honoring of those who, by their contributions in the field of rhinology and laryngology, have aided in its advancement.
- Marketable securities. Marketable securities are carried at the lower of cost or market.
- Income taxes. The Association has been granted exempt status under section 501(c)(10) of the Internal Revenue Code as an organization referred to in code sections 170(b)(1)(A)(vi) and 509(a)(1). Under this status, the organization does not pay any Federal or state income taxes.

Note 2. Prior period adjustment

The Association did not record various cash receipts in prior years. The accompanying 1986 financial statements have been restated to correct the error. The effect of the restatement was to increase general fund balance and increase cash at April 1, 1985, by \$16,991.

Note 3. Change in accounting principal

During 1986 the Association changed its method of accounting from cash basis to accrual basis. The Association believes that the new method more accurately reflects its financial position and results of operations. The effect of this change was to increase General Fund net income by \$3,525 and decrease Trust Funds net income by \$2,922 during 1986. Fund balances have been adjusted for the effect of retroactive application of the new method.

Note 4. Allocation of investment income

Interest on US Treasury notes, Certificates of Deposit, as well as dividends on common stock are credited as income to the Trust Fund.

Trust Fund income is further allocated to each individual fund in the ratio each fund bears to the total value of the trust funds at the beginning of the year, except that by action of the Council, Jan 3, 1976, current income from the Memorial Fund is transferred to the fund balance of the Research Fund.

Respectfully submitted,
John M. Fredrickson, MD
Treasurer

RECIPIENTS OF THE DE ROALDES AWARD

1928 Chevalier Jackson
1931 D. Bryson Delavan
1934 Harris P. Mosher
1937 Lee Wallace Dean
1943 Ralph A. Fenton
1949 George M. Coates
1951 Arthur W. Proetz
1954 Louis H. Clerf
1959 Albert C. Furstenberg



1960 Dean M. Lierle
1961 Frederick T. Hill
1966 Paul H. Holinger
1970 Francis E. LeJeune
1973 Lawrence R. Boies
1976 Anderson E. Hilding
1979 Joseph H. Ogura
1982 John J. Conley
1985 John A. Kirchner
1985 Charles M. Norris

RECIPIENTS OF THE CASSELBERRY AWARD

1923 George Fetterolf
and Herbert Fox
1928 Ralph A. Fenton
and O. Larsell
1929 Richard A. Kern
and Harry P. Schenck
1929 Edward H. Campbell

1931 Arthur W. Proetz
1934 Anderson C. Hilding
1936 Francis E. LeJeune
and Joel J. Pressman
1939 H. Marshall Taylor
and Brien T. King
1940 French K. Hansel
1941 Noah D. Fabricant

1946 Paul H. Holinger
1949 Henry B. Orton
1962 Hans von Leden
1966 John A. Kirchner
and Barry D. Wyke
1968 Joseph H. Ogura
1985 H. Bryan Neel III

RECIPIENTS OF THE NEWCOMB AWARD

1941 Burt R. Shurly
1942 Francis R. Packard
1943 George M. Coates
1944 Charles J. Imperatori
1947 Harris P. Mosher
1948 Gordon Berry
1949 Gordon B. New
1950 H. Marshall Taylor
1951 John D. Kernan
1952 William J. McNally
1953 Frederick T. Hill
1954 Henry B. Orton
1955 Thomas C. Galloway
1956 Dean M. Lierle
1957 Gordon F. Harkness

1958 Albert C. Furstenberg
1959 Harry P. Schenck
1960 Joel J. Pressman
1961 Chevalier L. Jackson
1962 Paul H. Holinger
1963 Francis E. LeJeune
1964 Fred W. Dixon
1965 Edwin N. Broyles
1966 Lyman G. Edwards
1967 Joseph H. Ogura
1968 Walter P. Work
1969 John A. Kirchner
1970 Louis H. Clerf
1971 Daniel C. Baker, Jr
1972 Alden H. Miller

1973 DeGraaf Woodman
1974 John J. Conley
1975 Francis W. Davison
1976 Joseph L. Goldman
1977 F. Johnson Putney
1978 John F. Daly
1979 Charles F. Ferguson
1980 Charles M. Norris
1981 Stanton A. Friedberg
1982 William M. Tribble
1983 Harold G. Tabb
1984 Daniel Miller
1985 M. Stuart Strong
1986 George A. Sisson

THE MEMORIAL AND LARYNGOLOGICAL RESEARCH FUNDS

The Council earnestly requests that Fellows of the Association give consideration to making a special bequest to these important funds, or to become a Benefactor.

MEMORIAL FUND DONORS

Daniel C. Baker, Jr
John F. Barnhill
August L. Beck
Gordon Berry
William E. Casselberry
Cornelius G. Coakley
Lee Wallace Dean
Arthur W. de Roaldes
Fred W. Dixon

George Fetterolf
Joseph L. Goodale
William E. Grove
Gordon F. Harkness
Frederick T. Hill
George E. Hourn
Samuel Johnston
James E. Newcomb
Henry B. Orton

Lup Q. Pang
Lyman G. Richards
Burt R. Shurly
Lester T. Sunderland
H. Marshall Taylor
Walter H. Theobald
Francis L. Weille
Eiji Yanagisawa

BENEFACTORS

Mrs Sally Sample-Aall
Mrs Daniel C. Baker, Jr
Edwin N. Broyles
Louis H. Clerf
Seymour R. Cohen
John J. Conley
John F. Daly
Francis W. and Mrs. Davison

Stanton A. Friedberg
Thomas C. Galloway
Joseph L. Goldman
Robert L. Goodale
Edley H. Jones
Zelda Radow Weintraub
Cancer Fund, Inc

A. P. Marchessini
Francis H. McGovern
Charles M. Norris
Samuel Salinger
Sam H. Sanders
Harry P. Schenck
William M. Tribble
DeGraaf Woodman

PRESIDENTIAL REMARKS

DOUGLAS P. BRYCE, MD

It is with great pleasure that I hereby open the 107th annual scientific meeting of the American Laryngological Association. It has been a signal honor for me to be your President this past year and, together with the membership, to develop this year's program, which I believe reflects the preeminent and international nature of this historic Association.

Each year your President must, as I have done, reflect on the past history of the Association and on the long and distinguished list of those specialists in the field of laryngology and rhinology who have been proud of their membership in the American Laryngological Association and have enjoyed and benefited from the relationship with their colleagues, both socially and scientifically.

A review of the subject matter presented at the past annual meetings records the growth of knowledge and information in laryngology from its beginnings. The current activities of the Association reflect the state of the art in laryngology and its related disciplines.

The early members of this Association did not have at their disposal the awesome armamentarium for diagnosis and treatment of laryngeal diseases that we enjoy today. These advances can be broadly grouped into three main areas. The development of the computer perhaps is the most significant, in that it has allowed the classification, recording, and follow-up of patients that makes possible the comparison of treatment protocols and allows the rational assessment of therapeutic regimens. The computer has also allowed the development of imaging, which in a major way helps to determine the spread of disease within the larynx and the appropriate areas for excision and treatment.

Surgical techniques were well developed early in this century, but their scope and effectiveness have been tremendously expanded by the introduction of antibiotics and the development of the concepts of preoperative and postoperative care best illustrated in our intensive care units today.

Finally, beginning about 1922, it became apparent that radiotherapy would offer an alternative to surgical excision in the management of cancer in the head and neck. This treatment modality has been constantly improving in effectiveness, and its practitioners have also become particularly skillful and interested in specific areas of malignancy. Perhaps most important of all is the concept that surgery



and radiotherapy do not compete in the management of malignant disease but rather complement each other when skillfully combined.

The early members of this Association did not realize how ignorant and disadvantaged they were, perhaps because they were richly endowed with imagination, ability, and above all and most essentially, the inquiring mind that constantly asks, "Why can we not do better and how can this be achieved?" A stubborn, questioning, irreverent disbelief is essential for the advancement of the medical sciences. We have the advantage of standing upon "broad shoulders," but we must not as an Association be satisfied with this, but indeed, constantly we must review our activities with a critical and restless energy.

It was 25 years ago that I first gave a paper before this Association. Naturally enough it was a review of the management of several hundred cases of cancer of the larynx. This subject has been my major interest, and I have come to a few conclusions that I propose to share with you, on the assumption that such an extensive period of retrospection should add to them weight if not wisdom.

I believe that we have the knowledge and skills to reduce to an irreducible minimum the deaths of patients from cancer of the head and neck and especially the larynx. That there is an irreducible minimum at this time there can be no doubt. Untreated cancer is a fatal disease, and with each type of cancer there is a varying percentage of cases that cannot be controlled by any method or combination of treatment methods available to us. In early laryngeal cancer I believe this figure to be 3% to 5%. It will probably be greater in more advanced lesions and in other sites.

Cancer of the head and neck tends to develop in patients with a shorter life span than that of the general population. The common causal factors of heavy smoking and drinking are also associated with the development of chronic cardiac and respiratory diseases and liver disorders. Thus, in any large population of patients with head and neck and laryngeal cancer, perhaps 25% will die of diseases unrelated to their malignancy within the usually adopted period of 5 years.

It is also true that patients with head and neck and laryngeal cancer develop secondary malignancy at a higher rate than the general population. This rate varies from five times more frequently with glottic cancer to 15 to 20 times more frequently for supraglottic malignancies. The effect of this fact has a varying influence on the irreducible minimum depending on when the second cancer develops and its site and nature. Thus, with cancer of the larynx in any series sufficiently large and properly representative of the various stages and sites of the disease, there is a maximal survival figure somewhere between 70% to 75%. It does not appear likely that this will change in the near future.

In any population of patients with cancer of the larynx, which is sufficiently large to reduce the factor of selection to a minimum, we have now the knowledge and tools available to us to achieve the optimum survival figure. The present state of diagnostic imaging and clinical examination is sufficient for us to delineate accurately the extent of the patient's cancer at the first examination. These same tools allow us to determine the effect of the management technique upon the tumors. Such a definition of the extent of the tumor is the essential infor-

mation to determine which treatment modality, among the three, surgery, radiation, and chemotherapy, should be applied. The appropriate blending of these treatment tools requires a skillful and experienced team of properly trained clinicians, working with auxiliary personnel, to allow essential follow-up and rehabilitation. All these personnel, all the knowledge, and all the necessary equipment are available to us to reach that goal of optimum survival for patients with laryngeal cancer.

Throughout the world, four fifths of the people on this planet live in countries that are too poor, in which the population is too numerous, or whose political ideologies do not allow a sufficiently high priority for medicine, to achieve these results in the treatment of laryngeal cancer. In North America and in many parts of Europe, we are among the favored few whose medical facilities have the capability of combating cancer with the full potential of modern scientific medicine with its great concern for the maintenance of life and the quality of that life after treatment. In these areas, we have advanced greatly in the past 20 years. Despite this, we fall far short of achieving the optimum survival from the disease. I do not believe that the repetition of clinical trials in the absence of a new modality of treatment will be helpful. Our emphasis and energies must switch toward making our great advances in diagnostic facilities and the meld of treatment modalities developed by us available to all our patients.

This is no easy task. It begins with education, and we are taking the first steps in this direction with the fellowships for advanced training in head and neck cancer. These fellowships must have the support of the American Board of Otolaryngology if they are to survive. The recognition of added qualifications by the Board that is under current consideration is an essential and inevitable step forward. The care of a cancer patient by a physician, radiotherapist, or surgeon working in isolation is an anachronism. Whatever social or economical changes are necessary to develop the informed team approach to cancer management must be recognized and, in the fullness of time, be brought about. This is the challenge of the foreseeable future. It is one worthy of the energy and genius of this organization in which leadership must be found.

INTRODUCTION OF GUEST OF HONOR EMANUEL E. SKOLNIK, MD

DOUGLAS P. BRYCE, MD

The terms energy, leadership, and genius lead me naturally to the introduction of our Guest of Honor, Emanuel Skolnik, MD, who is indeed one of the greats of laryngology. Manny, as he is known everywhere in this country, is one of the pioneers in the management of head and neck cancer. He has written extensively for 30 years and has been in demand for innumerable courses, seminars, and visiting professorships. He has generously presented his work at international and national meetings in our specialty. His international reputation as a head and neck surgeon is perhaps second to none. Almost always, when I have traveled across the ocean to attempt to "spread the gospel," Manny had either just been there or was expected. He brightened the many years we both served on the American Board of Otolaryngology, for he is a great raconteur. We welcome him and his charming wife, Helen, to this meeting of the American Laryngological Association, in his special status this year as Guest of Honor. Manny, it is a pleasure for me to ask you to come forward to the podium to give us your words of wisdom.



GUEST OF HONOR ADDRESS

INTERNATIONAL PROFESSIONAL RELATIONSHIPS (WORLD PEACE AND MEDICINE)

EMANUEL M. SKOLNIK, MD

I am proud of my long association with the American Laryngological Association and to have had the opportunity to work with a great many of you. You have enriched my life, and I humbly thank you for selecting me as your Guest of Honor. This is an emotional milestone in my life of 40 years in otolaryngology-head and neck surgery.

I have selected for my address a subject most appropriate at this time — our role in world peace through medicine. We are embarking upon the quest for civilization's most elusive goal. The efforts we set in making this noble achievement a guiding force in our lives and the example set by people of understanding and compassion, founded on the principle of benevolence, lead us all to ask our role in this struggle.

Although the most commonly held definition of peace is the absence of war, this is only one element of true peace. Peace must also include freedom from economic and social tyranny and from the threat of famine and disease. Clearly, the field of medicine, including its medical and surgical specialties, is concerned with the treatment and prevention of disease. The value of this objective is self-evident. Yet, physician and nonphysician providers of health care must view their roles in a broader context if they are to have a significant impact in the effort to bring about the true well-being of the human species. We must examine our place in the political, economic, and medical joint venture required to implement a plan for world peace. In attempting to gain a global perspective on the world peace issue, where medicine can play a part, we must first identify the most serious problems.

Global overpopulation is a critical issue. Drastic measures in China and India have begun the process of population control, but the magnitude of the problem, the severity of both the overpopulation and the scarcity of economic, industrial, and agricultural resources will demand decades to change. Africa, Central America, and South America are even more unsophisticated in their attempts to control their burgeoning populations. In the face of devastating health problems, their population growth far exceeds ours; the constant threat of early

mortality and lack of education are stimuli to uncontrolled reproduction.

Political obstacles interfere with adequate provision of medical services. In developing countries, donor and recipient nations are guilty of using medical care as chips in a cynical game of political poker. Badly needed funds for health and sanitation are diverted to nonmedical purposes causing not only the short-term deprivation of adequate health care but also prevention of funding for long-range teaching and training programs.

Inadequate health delivery planning in the form of organizational competition and complicated plans that lack coordination within the political and health care hierarchies frustrates many sincere attempts to achieve a real improvement in substandard conditions. Even where funding is available, lack of a well-conceived delivery system makes the expenditure ineffective.

Collapse of traditional health care systems in the postcolonial period, especially in the Far East and Africa, has left many of the old European colonies without the support structure that provided what little health coverage they had. In these areas, medicine is dispensed by medicine men or faith healers. These areas present a great organizational challenge to the western physician accustomed to our highly structured medical system. There are requirements to understand complex cultural, social, economic, and demographic networks.

No one cause of these problems can be identified. No straightforward solution presents itself, but the evidence is clear that a solution must be found. It can be argued from a moral standpoint that we are all obligated to help those in need, but on a far less abstract basis we must understand that as long as poverty, sickness, and despair hold a majority of the world in a state of turmoil, there can be no enduring peace. There must be a unified effort to address the universal obstacles to peace. Physicians have begun and must continue to play a vital role in this process.

The news of famine in Chad, epidemics in Pakistan, and new evidence of the gruesome long-range

effects of atomic radiation as a result of the bombings of Hiroshima and Nagasaki are obvious indicators that none of us has done enough. Nonetheless, the medical profession has made dramatic gains in establishing a framework within which significant progress can be made toward solving many of the medical problems that most threaten the stability essential to world peace.

In great part this framework is based on the principle of international interdependence. For centuries nations forged their domestic and foreign policies in the fire and rhetoric of national independence. During these many hundreds of years, fear, distrust, disease, aggressive nationalism, religious and political fanaticism, and the regional and global conflicts they engender have flourished. Ever-accelerating gains in technology have made national isolation an anachronism and have brought us the opportunity to reach out to our neighbors throughout the world. The ever more clearly defined specter of cataclysm makes the opportunity a necessity.

The medical profession and several of its component organizations have worked diligently to promote a sense of medical, technological, and human interdependence.

Good Ship Hope has been in existence for many years providing specialty care in a home environment and working with local physicians to teach and relate their expertise in the management of disabilities.

Physicians for Social Responsibility (PSR) is evidence of the concern of the medical communities, both in the developed countries and the developing countries, to alleviate the frustrations of disease. This association of concerned scientists, in which multiple countries are involved, exchanges technologies and ideologies in pursuit of a peaceful coexistence.

PUGWASH is an international organization of medical doctors formed to promote peaceful methods of problem solving. Its members are motivated not only by their concern for the survival of all creatures, but by the conclusion that they could not possibly take care of the injured after a nuclear conflict.

The International Peace Academy Committee (IPAC) was founded in Vienna in 1970. This group organized projects to test the idea that practical training in peace arts was possible. Because of the Vienna pilot study, we now are able to assess more accurately what attitudes and resources are necessary to do transitional training well. One hundred forty individuals from 50 countries and numerous professions collaborated on the development of educational designs that can be incorporated into the program of the International Peace Academy.

The participants came from diverse cultures and political systems. The enterprise was carried out successfully with courses given by private individuals without substantial support. Many governments sent qualified officials to the Vienna courses. Four major demands are essential: 1) conceptual language and application made readily accessible; 2) practical development in problem solving; 3) coordination of training proposals to eliminate causes; and 4) stimulation.

The World Health Organization (WHO) is a specialized agency of the United Nations established in 1948 to further international cooperation for improved health conditions. Although it inherited specific tasks relating to epidemic control, quarantine measures, and drug standardization from the Health Organization of the League of Nations (set up in 1923) and the International Office of Public Health at Paris (established in 1909), WHO was given a broad mandate under its constitution to promote the attainment of "the highest possible level of health" by all peoples. The World Health Organization defines good health positively as "a state of complete physical, mental, and social well-being, and not merely the absence of disease or infirmity."

With administrative headquarters in Geneva, WHO operates through three principal organs: the World Health Assembly, which meets annually as the general policy-making body, an executive board of health specialists, and a secretariat, which in January 1973, had a staff of about 3,500 including regional offices and field staff. Six regional offices have been established in Alexandria, Egypt; Brazzaville, Republic of Congo; Copenhagen; New Delhi; Manila; and Washington, DC.

The work of WHO can be divided into three distinct categories.

1. It provides a central clearing house and research services. The central WHO Secretariat keeps member countries informed of the latest developments in the use of vaccines, cancer research, nutritional discoveries, control of drug addiction, and health hazards of nuclear radiation.
2. It sponsors measures for the control of epidemic and endemic disease such as tuberculosis, malaria, and venereal disease.
3. It encourages efforts to strengthen and expand the public health administrations of member nations. Teachers are available for on-the-spot training. In addition, it grants traveling fellowship awards to doctors, public health administrators, nurses, sanitary inspectors, and laboratory technicians.

According to Sir John Wilson (Deafness in developing countries. *Arch Otolaryngol* 1985;111:2-9), the urgent need exists for reciprocal programs, particularly in the developing countries, that would be

mutually beneficial to all. These programs would expand greatly the opportunities for specialist training. The relationship with universities and research institutions, and their promotion of international cooperation and staff exchange, would implement the development of regional, national, and international efforts. Public and political attention is paramount, in addition to that of the medical community. This interchange of teaching centers would be most stimulating and would satisfy the insatiable curiosity to learn more and at the same time help humanity, particularly in areas where the quantity of material exists, but the effort toward quality control is essential.

In his article Wilson detailed the alarming incidence of impaired hearing and blindness in the world today, especially in the developing countries. According to the United Nations 80% of these infirmities prevail in the underdeveloped areas. The prevention and treatment of all disabilities and diseases is an option available to the concerted effort of the international community. This cooperative venture is a challenge to our perceptions and assumptions.

There exist many communities of the world with an abundance of teaching material for clinical evaluation and treatment. Unfortunately the patient population is overwhelming and it is difficult to critically analyze the quality of care rendered, and for clinical and basic science research to be conducted. Centers in the developed countries can help because of established standardized systems of care, research, and retrieval of data.

Numerous organized programs exist throughout the world engaged in excellent basic research and clinical trials of significance. Together these citadels of learning can establish a mutual expression of our efforts and extend our skill and research facilities to the underdeveloped countries. The United Nations has adopted a fortuitous plan to aid countries in need. The international communities must, of necessity, extend a cooperative interaction, not only among themselves, but to escalate mutual exchange programs among the developing countries. There is a growing awareness among industrialized countries' international and regional professional societies of the needs of less fortunate countries to care for the overwhelming disabilities that prevail. The technologies, research, and clinical care programs are essential to meet the global needs.

However, today many global programs for health care in underdeveloped countries are available but in need of better trained personnel, specialist and paramedical, to achieve the ultimate goals of the United Nations. Many of the excellent programs in existence in the world continue to exchange information on clinical and basic research levels. There is interaction between our residents and faculties

with these of other centers. International programs continue to bring together specialists from all countries to relate to each other scientifically and personally. This is exciting and continues to foster better understanding and friendly relations. I have had numerous opportunities during the past 35 years to participate in such endeavors and to work in various centers.

A program between the University of Illinois College of Medicine and the University of Thailand in Chiangmai existed in the early 1960s. One of their physicians trained in our Department of Otolaryngology and returned home to implement a center. I spent some time in Chiangmai examining patients and operating in rather primitive settings compared to our more sophisticated programs. The wealth of material in head and neck cancer was overwhelming and provided fertile ground for training and experience.

There is already a precedent at the University of Illinois Department of Ophthalmology for active interaction with the Aravind Eye Hospital in Madurai, India. At present, our Department of Otolaryngology is exploring such a reciprocal program with India. This will provide an abundance of material for residents and faculty of both areas and complement the training programs. Better quality care can be attained rather than quantity, and facilities for research projects can be established and supervised with a mutual understanding and satisfactory controls. The cooperative venture will ultimately result in better scientific analysis and quality care for the patients as well as enhance the training of personnel. Their participation in our academic programs and observation of patient care in the clinical and operating room settings will secure a more orderly approach to the many medical problems in developing countries. This protocol should be pursued by all sophisticated programs in our global sphere.

China has embarked on a very intensive and well-organized program for cancer control. Efforts will be made to study the cause, prevention, early detection, and treatment of cancer. Epidemiologic investigations have been computerized and research has begun on the relationship between pathogenesis of cancer and environmental factors. Chinese medicine has been combined with western medicine for cancer prevention and treatment — another step toward international professional relations.

The role of US physicians in foreign countries deserves the same attention as has been given to foreign physicians in the United States. The current and future supply and demand for US physicians for international health and peace are essential.

The achievement of acceptable controls, to the satisfaction of the international community, of the many disabilities confronting the world (deafness,

blindness, cancer, genetic disorders, malnutrition, and infectious diseases) remains a challenge to all professionals. We are living in a shrinking world. It is important to stimulate the intellectuals in these developing countries, academically and scientifically, and to create a climate of excellence. The primary objective is for personnel to work in the respective countries.

In order to engineer effectively such programs one must choose countries that offer political stability and a democratic form of government. The American Medical Association helped establish the World Medical Association and supported the work of the World Health Organization and the International Refugee Organization. In the past decade, the AMA Volunteer Physicians for Vietnam Program made it possible for almost 1,000 physicians to serve in a troubled part of the world. The AMA was a force in the establishment of the National Council for International Health (NCIH), which provides a forum to help coordinate international health activities. Attempting to capitalize on accepted concepts in international exchange, Richard Egan has proposed the idea of a "physician peace corps." Similarly, Ralph Crawshaw suggests a "doctor-to-doctor" program modeled after the "people-to-people" program. E. Grey Dimond describes exciting new ideas about how to further international relations and peace through medicine and health. Each of these medical institutions and men have taken an international approach to solving worldwide health problems. Each has attempted to chart a path in an increasingly complex international arena, an arena made especially complex by paradoxes that are peculiar but, like so many modern phenomena, are as old as civilization.

Perhaps the best known paradox is exemplified by the work of Alfred Nobel, developer of dynamite in 1862. Nobel's invention has been put to uses that have been responsible for massive destruction and loss of life for over 100 years. Notwithstanding the destructive capacity of dynamite, no man's name is more closely associated with peace. The Nobel Prize represents Nobel's thinking that the pursuit of peace must be international as well as interdisciplinary. Each year the prize is given in categories including physics, chemistry, literature, physiology, medicine (Karolinska Institute), and peace.

Today, we face the nuclear enigma. The technology of modern weapons, especially nuclear weapons, poses a critical threat to the health of all people. In addition to the unprecedented risk of massive destruction to all living things posed by their use, the consumption of the resources used in production of nuclear arsenals, estimated worldwide at \$800 billion annually, causes an economic threat to the health of populations even if the weapons are never used. The psychological impact of generations growing up under the fear of impending, instant

annihilation is virtually incalculable. While the nuclear threat is ominous, the nuclear promise is an encouraging counterbalance. Nuclear modalities have proved invaluable in the diagnosis and treatment of disease. Modern technology has revolutionized precise and therefore earlier treatment, dramatically improving results. Such a valuable addition to our medical armamentarium has innumerable advantages. Nuclear medicine has become an essential component in today's health standards worldwide.

Technology has become the gold of the 20th century, enriching the countries that have it and isolating those that do not. The promise of new research technologies, most spectacularly recombinant DNA and monoclonal antibody techniques, has made it possible for scientists to investigate almost any question. This is an era of great excitement and confidence among biomedical researchers who are certain that the new technologies will produce beneficial effects on humanity not only in this nation, but in all the developing countries of the world. Unless this technological promise can be kept on an international basis, we will have failed in our peace mission.

International tensions are making that mission increasingly difficult. Scientific exchanges between the United States and the Soviet Union are currently at their lowest point in over a decade. In 1975, at the height of détente, over 2,000 US and Soviet scholars and officials participated in exchanges under the auspices of 13 different programs. In 1982, this number dropped to about 300 under eight agreements. The principal causes of the severe decline in exchange programs were the Soviet invasion of Afghanistan and the suppression of freedom in Poland.

Without an improvement in the current scientific and cultural exchange situation, we will find it impossible to monitor or influence Soviet restrictions on academic freedom to which we object. Without giving explicit or implicit approval to suspensions of political or scientific freedom, we need to find a new way to insure that scientists from all countries have a rapport that is not contingent upon the whims of political expediency. Information counteracts ignorance, social contact is a first step toward friendship, and nearness creates romance. Negotiators concerned about weapons limitations could well include in their agreements obligatory academic exchanges. An unarmed quarter of a million university-level students integrated into each other's society would be agents of security for both sides. Why are there 10,000 Chinese scholars in our US universities today: the offspring of China's intellectual and political leadership? Surely, they must have some value as guarantors of peace.

At present there are 41 wars in existence around the world. Wars are analogous to a cancer on socie-

ty. Is there a cure? Can preventive measures play a significant role in its elimination, or is the malignancy beyond control? Every avenue for its cure is essential as a composite approach. Education, economics, politics, and medicine comprise the major areas of pursuit. The balance between war and peace is becoming ever more precarious. Politics, accordingly, is fully burdened with the glaring absurdity that, with one hand, it builds for a future, and with the other hand, it prepares to destroy. Albert Einstein insisted that peace among nations could be maintained in the atomic age only by bringing all men together under a system of world law.

The current UN Secretary acknowledges, however, that we have strayed far from the UN charter. He states that the body resolutions are increasingly defied or ignored by those nations that feel themselves strong enough to do so. We are perilously near to a new international anarchy.

With the need for interaction and understanding at critical levels, we often seem more helpless than ever to influence our fate. The very technology that promises us the future is the weapon that threatens to eliminate it. More and more often, even among the very young, we hear a jaded cynicism about the future that is as terrifying as the nuclear weapons that threaten us. In a recent survey, 85% of high school students and 80% of elementary school stu-

dents surveyed said that they believed that there would be a nuclear war. Our greatest challenge may be to educate the world to the possibilities we have to achieve peace.

Our country is at the forefront of the most important movements of our time: educating both young and old that peace is possible. One is reminded of thought expressed by Wilhelm Steckel, "The mark of the immature man is that he wants to die nobly for a cause, while the mark of the mature man is that he wants to live humbly for one." Years ago the well-known commentator Ed Morrow captured the philosophical heart of our obligation stating, "We can deny our heritage, but we can no longer deny our responsibility for the future of mankind." This has never been more true than it is today.

The ability to get along with and interact with people is essential. Forbearance and consideration in human relations seems axiomatic. Always find strength to take a vigorous stand for what is just for fellow humans. Moral courage, intellectual enthusiasm, and a disciplined mind will be influential. Participation in civic life is an obligation of us all in order to attain a better way of life. This will bring stability to government at all levels and acceptable international relations. Service being a social force, the goal is to do something fine and enduring, for we grow only when we are thoughtful and serve with dignity.

SCIENTIFIC SESSIONS*

*The papers on pages 21-129 were published in the *Annals of Otology, Rhinology & Laryngology*, November-December 1986 and March-April 1987; the remaining papers on pages 130-153 are published here for the first time. The discussions that followed the papers begin on page 155.

CARBON DIOXIDE LASER RESECTION OF SUPERFICIAL ORAL CARCINOMA: INDICATIONS, TECHNIQUE, AND RESULTS

THOMAS L. GUERRY, MD

SOL SILVERMAN, JR, DDS

HERBERT H. DEDO, MD

SAN FRANCISCO, CALIFORNIA

A retrospective medical record review was done of 51 consecutive patients with 56 biopsy-proven squamous cell carcinomas of the oral cavity and oropharynx treated for cure by one of the authors (H.H.D.) using the carbon dioxide laser via microdirect pharyngoscopy. All 51 patients were followed for at least 3 years unless they died, and 27 were followed for 5 years. The tumors treated were superficial, accessible lesions without bone involvement or clinically apparent metastases. Eighteen patients had had irradiation or surgery at the same site, so were having salvage CO₂ laser surgery. Indications and technique are discussed. Local recurrence and disease control rates were comparable to those of conventional local surgical excision at 3 and 5 years. Complication rate was low. Carbon dioxide laser resection with microscopic control is, we propose, an excellent modality for transoral excision of carefully selected lesions, and it offers increased precision, better visualization, minimal bleeding, and decreased postoperative morbidity compared to other surgical techniques.

KEY WORDS — carbon dioxide laser, mouth, oropharynx, squamous cell carcinoma.

INTRODUCTION

The pioneering work of Jako¹ and Strong and Jako² in the early 1970s established the feasibility of microscopic, endoscopic carbon dioxide laser surgery in the larynx. In 1973, Strong et al³ reported the use of the CO₂ laser in other areas of the upper aerodigestive tract, including treatment of superficial carcinoma in the oral cavity. In 1979, Strong et al⁴ reported the first series of patients with localized oral cavity carcinoma treated with the CO₂ laser. They concluded that transoral resection of accessible localized carcinomas of the oral cavity was appropriate and was facilitated by use of the CO₂ laser with the operating microscope. They found this technique offers low morbidity with a low complication rate, and early results indicated that disease control rates were acceptable. Subsequent publications^{5,6} have agreed with these conclusions. However, long-term results of this technique have not yet been reported. With this in mind, we present our surgical indications, technique, and results 3 and 5 years after CO₂ laser resection of 56 oral cavity and oropharyngeal squamous cell carcinomas in 51 patients.

MATERIALS AND METHODS

Surgical Indications. In 1976 we began using the CO₂ laser in the treatment of superficial selected oral ("oral" will be used to include oral cavity and oropharynx) lesions in patients who could be relied on to maintain close follow-up. The initial squamous cell tumors treated for cure with the CO₂ laser were localized lesions that recurred after radiation therapy or surgery; that were in the field of radiation therapy treatment of a prior cancer; or that ap-

peared in patients already having oral dysfunction, usually resulting from treatment of a prior cancer. Results appeared satisfactory in these cases, and indications for this technique were extended to include carcinomas in patients without prior treatment or dysfunction. We now use the CO₂ laser for resection of accessible, superficial (less than 4 mm thick by clinical examination) oral squamous cell carcinomas without evidence of cervical or distant metastases or direct bone involvement. We have used the CO₂ laser only rarely for palliation in advanced oral squamous cell carcinomas.

Surgical Method. All of our transoral CO₂ laser resections of oral lesions are performed with the patient under general anesthesia (Figs 1 and 2). The CO₂ laser is coupled to an operating microscope. Tracheotomy has not been necessary. Preoperative or intraoperative antibiotics or steroids are not given, and local vasoconstrictors are not used. For soft palate resection, a McIvor or Crowe Davis tonsil retractor is installed and a moist 4 x 4 gauze pad is inserted behind the soft palate. The laser is used at 20 to 26 W, continuous mode to incise the soft palate (and if necessary the upper anterior and posterior pillars), first on the side of least involvement, up to the hard palate well medial to the carotid artery and the torus tubarius. Resection is carried along the edge of the hard palate across the midline 1 cm. Then the soft palate is incised 1 cm lateral to the tumor on the side of the greater involvement from the upper tonsil fossa to the edge of the hard palate to a depth of only 1 cm. Then the specimen is retracted anteriorly so the laser can make the mucosal incision in the dorsum of the soft palate just anterior to the torus with the torus tubarius in view so the eusta-

From the Departments of Otolaryngology-Head and Neck Surgery (Guerry, Dedo) and Stomatology (Silverman), University of California School of Medicine and School of Dentistry, San Francisco.

Presented at the meeting of the American Laryngological Association, Palm Beach, Florida, May 4-5, 1986.

REPRINTS — Herbert H. Dedo, MD, Professor and Vice Chairman, Otolaryngology-Head and Neck Surgery, UCSF 717A, San Francisco, CA 94143.

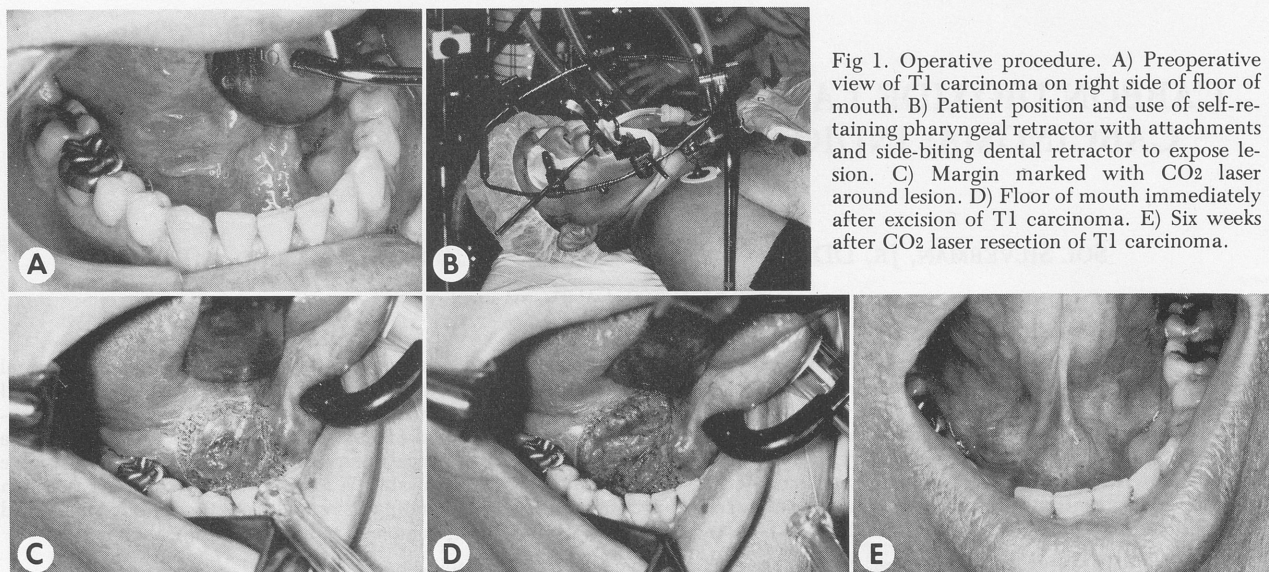


Fig 1. Operative procedure. A) Preoperative view of T1 carcinoma on right side of floor of mouth. B) Patient position and use of self-retaining pharyngeal retractor with attachments and side-biting dental retractor to expose lesion. C) Margin marked with CO₂ laser around lesion. D) Floor of mouth immediately after excision of T1 carcinoma. E) Six weeks after CO₂ laser resection of T1 carcinoma.

chian tube will not be transected. Then the incisions in the anterior and posterior soft palate on this side are joined and the specimen removed. The occasional artery or vein not controlled with the laser is immediately cauterized with the Bovie electrocautery.

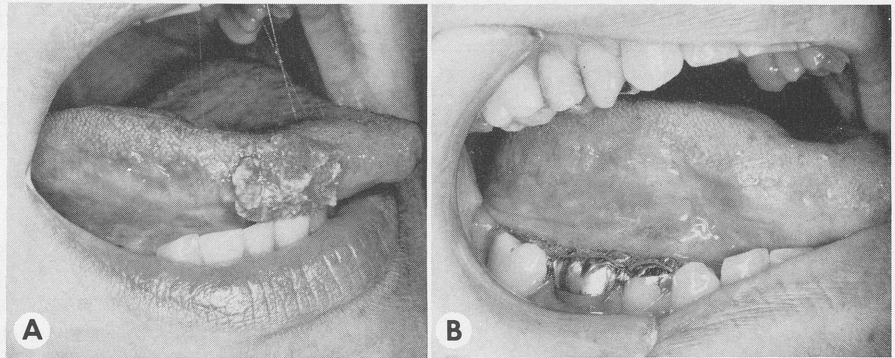
Exposure of the other oral areas is obtained using a retractor of our design (Pilling Company, Fort Washington, Pa), which consists of a hexagonal ring with attached universal joints to hold modified United States retractors and tongue retractors (Fig 1B). This provides excellent exposure of the floor of the mouth; buccal region; lateral, ventral, and dorsal tongue; and retromolar trigone. It extends the indications for transoral CO₂ laser surgery by increasing lesion accessibility. When used for anterior floor of mouth or ventral tongue lesions, the tongue is retracted with a heavy silk suture through the tip that is tied to the hexagonal ring. Occasionally the laryngoscope is used for more posterior lesions on the base of the tongue or the pharyngeal wall. Once exposed, the lesion and surrounding mucosa are stained by applying 1% aqueous toluidine blue with a cotton-tipped applicator. After 30 seconds, the area is rinsed with water, then decolorized with 1% acetic acid using another cotton-tipped applicator. Areas of mucosal dysplasia and carcinoma will retain the dye.⁷

For transoral resection we use the Coherent 450 or 451 XLG (Coherent Medical Group, Palo Alto, Calif) CO₂ laser coupled with a Wild M650 (Wild Heerbrugg Limited, Heerbrugg, Switzerland) operating microscope. This provides the precise delivery of a focused beam of infrared (wavelength 10.6 μ m) light controlled with a manual micromanipulator and a visible coaxial helium-neon laser-aiming beam. Excellent illumination and magnification of the operative field is thus achieved. The CO₂ laser produces a surface thermal effect, which can be seen well through the microscope. With adequate power

density (power output per beam spot area at the point of application), the result is tissue vaporization. Laboratory studies have shown that the depth of damage to remaining tissues is limited to only about 15 to 18 cell layers. The surgical defect is sealed, including lymphatic and blood vessels up to 0.5 mm in diameter, by a thin protein coagulum, and all debris in the laser plume is nonviable.^{8,9} The wound is sterilized, and hemostasis is excellent.

Carbon dioxide laser soft tissue removal can be accomplished by excision or vaporization. To excise tissue, the laser beam focal spot diameter is minimized (approximately 1 mm with the Coherent 451 XLG CO₂ laser at a working distance of 400 mm) and power set high enough (eg, a console reading of 20 W at 0.05 to 0.1 second up to continuous) to provide a power density capable of rapid vaporization. The incision line is then marked 7 to 10 mm outside any visible or palpable tumor margin using short bursts of laser energy (Fig 1C). With the margin determined, a "moat" 4 to 9 mm deep is then created, and the specimen edge is elevated with Adson forceps or a clamp and is cut 7 to 10 mm beneath to the estimated depth of tumor invasion. The surgeon uses one hand to manipulate the laser and the other for suction or traction. An operative biopsy is taken first in the most suspect area(s) of the lesion if desired. The specimen is then delivered, and before sending it for histological examination, a labelling suture is placed in one margin for orientation if desired. Suspicious or leukoplakic mucosa can be removed by vaporization if it is surrounding a lesion or involving a portion of a lesion. Vaporization of mucosa and 1 to 2 mm of submucosal connective tissue is performed with repeated 0.05- to 0.5-second applications of the CO₂ laser with power density reduced from that used for excision by reducing the power output to 10 to 15 W at the same spot diameter or increasing the spot size by defocusing and either leaving power output the same or increasing

Fig 2. T2 squamous cell carcinoma of right lateral tongue. A) Preoperative view, B) postoperative view 3 months after CO₂ laser resection, showing excellent healing.



output slightly (eg, 20 to 25 W). All abnormal mucosa is vaporized in this way, including a margin of 6 to 8 mm of surrounding, apparently normal mucosa. Increased depth of vaporization can be achieved by increasing power density or exposure time. When using the CO₂ laser with the operating microscope, it is relatively easy to visually determine when the mucosal layer has been removed uniformly, including a 1- to 2-mm layer of submucosal connective tissue. We prefer to leave periosteum intact, if possible, and to avoid direct laser contact with bare cortical bone. (If periosteal or bony removal is required to provide a margin, a conventional oscillating saw is used for this portion of the procedure.) Laser application to the teeth should be avoided.¹⁰ Carbon dioxide laser transection of Wharton's duct is performed if necessary to assure adequate lesion removal.

The resection area is left open and allowed to granulate and epithelialize secondarily (Fig 1D). This avoids the suture closure of oral defects that can result in deep, dense scar lines, which can increase postoperative dysfunction and bury residual tumor, delaying appearance of recurrent disease. Postoperative edema is minimal, and respiratory distress has not been a problem. Patients can usually be discharged the night of surgery or the following day. Pain may be maximal 3 to 4 days after surgery but rarely requires hospitalization for hydration or analgesia. Oral penicillin or tetracycline is given four times daily for 10 days postoperatively, and oral care consists of frequent rinses with water. Wound

infection has not been encountered. Pain usually subsides in 3 weeks. Healing has been excellent (Figs 1E and 2B), but may take up to 8 weeks over bone or for large defects. Our experience supports clinical^{4-6,10,11} and experimental¹² observations that CO₂ laser-created mucosal defects are associated with significantly less inflammation and scar contraction and result in less postoperative dysfunction than defects created with a scalpel or electrocautery.

Clinical Material. The medical records of 51 consecutive patients with biopsy-proven squamous cell carcinoma of the oral cavity or oropharynx who were treated more than 3 years before for cure by one author (H.H.D.) were reviewed. The distribution of lesions by site, T stage, and treatment history is presented in Table 1. Eight patients had two separate CO₂ laser procedures. Five of these eight had one procedure at two separate sites, and three had two laser procedures at a single site. The laser resection was the initial treatment for cancer at 38 of the 56 sites. The laser was used for salvage surgery after failure of radiation therapy at 14 sites, after failure of both radiation therapy and conventional surgery at three sites, and after failure of conventional surgery alone at one site. In the three patients who had two procedures at a single site, the second laser surgery was for salvage of local recurrence after the previous laser surgery.

During follow-up 11 new primary tumors appeared in ten of the 51 patients (20%), all in the oral cavity or oropharynx. None of the nonsmokers,

TABLE 1. LESION SITE, TREATMENT STATUS, AND T STAGE AT PRESENTATION

Site	Previously Treated		Previously Untreated		Total	
	T1	T2	T1	T2	No.	%
Mobile tongue	0	0	12	3	15	27
Soft palate, anterior pillar	1	4	6*	1	12	21
Floor of mouth and adjacent tongue	2	1	7	0	10	18
Base of tongue and anterior pillar	3	1*	3	0	7	12
Buccal mucosa	1	2	1*	0	4	7
Gingiva	1	0	3	0	4	7
Oropharyngeal wall	0	1†	0	1	2	4
Tonsil	0	1	0	0	1	2
Hard palate	0	0	1	0	1	2
Total	8 (14%)	10 (18%)	33 (59%)	5 (9%)	56	100

*One local recurrence after laser surgery at each of these sites was subsequently treated for salvage using laser.

†Only T3 lesion.

TABLE 2. LOCAL RECURRENCE, NECK METASTASIS, DISEASE SALVAGE, AND LOCAL CONTROL RATES 3 YEARS AFTER LASER SURGERY

	Previously Treated						Previously Untreated					
	T1		T2		Total		T1		T2		Total	
	No.	%	No.	%	No.	%	No.	%	No.	%	No.	%
Sites	8		10		18		33		5		38	
Local	3	38	6	60	9	50	5	15	0	0	5	13
Neck	0	0	1	10	1	6	5	15	2	40	7	18
Disease salvage												
Local recurrence only	2/3		1/6		3/9		2/2		0		2/2	
Neck metastasis only	0		1*		1*		1/2		2/2		3/4	
Local recurrence and neck metastasis	0		0		0		0/3		0		0/3	
3 yr indeterminate* sites	0/8		1/10		1/18		1/33		0		1/38	
3 yr local control rates	7	88	4	40	11	61	28	85	5	100	33	87

*Died of heart attack or carotid rupture without evidence of disease.

14% of the patients who subsequently quit smoking, and 33% of those who continued to smoke developed new primary tumors, confirming the importance of stopping smoking.

Fifty-one patients were at risk of dying for at least 3 years, and 27 were at risk of dying for at least 5 years after CO₂ laser surgery. No patient was lost to follow-up. The mean follow-up time was 47 months, and the median follow-up time was 45 months. The longest follow-up period was 9½ years.

RESULTS

Disease-free survival at 3 and 5 years after the initial laser surgery was calculated by the direct method¹³ for those patients at risk of dying for at least 3 and at least 5 years. Local recurrence, neck metastasis, disease salvage, and local control rates at 3 years after CO₂ laser surgery for previously untreated and previously treated T1 and T2 carcinomas are shown in Table 2. The number of patients at risk and disease status at 3 and 5 years after presentation for CO₂ laser surgery of previously untreated and previously treated T1 and T2 carcinomas are displayed in Table 3. The disease status at 3 years was indeterminate in two patients in the 3-year follow-up group. One of these, in the previously untreated lesion group, died without disease of a heart attack 17 months after laser surgery. The other, in the previously treated lesion group, died of carotid rupture in the perioperative period after composite resection for control of neck metastasis. The disease

status at 5 years was indeterminate in three patients who died without apparent disease. Of the ten patients in whom disease control had failed by 3 years, three had anterior tongue primary tumors and two had buccal primary tumors. Three patients not at risk for 5 years developed disease after 3 years: one patient had local recurrence of an anterior tongue carcinoma in the fourth year of follow-up and was salvaged with CO₂ laser excision; another patient with an anterior tongue primary had neck disease only salvaged as of 3 years that subsequently failed in the same neck; and one patient with a buccal primary tumor had an uncontrollable local recurrence in the fourth year of follow-up. One failure in the 3-year follow-up group was a patient with a primary tumor of the tongue and both local recurrence and neck disease who was controlled locally with composite resection and radiation therapy but subsequently developed distant metastases. This was the only patient in the entire series who developed distant metastases before local or neck disease became incurable.

Table 4 shows local recurrence, neck metastatic, disease salvage, and disease control rates at 3 and 5 years in the 14 patients treated with CO₂ laser resection for cancer after failure of radiation therapy only. The overall timing of local recurrence, neck metastasis, and new primary squamous cell carcinoma after CO₂ laser surgery is presented in Table 5.

Neck Metastasis. Metastatic disease developed only in the ipsilateral neck. Four of the six non-

TABLE 3. DISEASE STATUS AT 3 AND 5 YEARS AFTER CARBON DIOXIDE LASER SURGERY FOR T1 AND T2 CARCINOMAS

	Previously Treated						Previously Untreated					
	T1		T2		Total		T1		T2		Total	
	No.	%	No.	%	No.	%	No.	%	No.	%	No.	%
3 Years												
Patients at risk	8		10		18		28		5		33	
Treatment failure	1		5		6		4		0		4	
Indeterminate	0		1		1		1		0		1	
NED	7	88	4	40	11	61	23	82	5	100	28	85
5 Years												
Patients at risk	3		6		9		15		3		18	
Treatment failure	0		4		4		2		0		2	
Indeterminate (died NED)	1		1		2		1		0		1	
NED	2	67	1	17	3	33	12	80	3	100	15	83

Patients are categorized by presenting features of their first primary tumor treated with CO₂ laser. NED — no evidence of disease.

TABLE 4. DISEASE CONTROL IN PATIENTS TREATED WITH LASER SURGERY AFTER RADIATION THERAPY FAILURE (N = 14)

Patient Status	No.	Population	%
Local recurrence	7	14	50
Salvage of local recurrence (with composite resection)	3	7	
Neck metastasis	1	14	7
Salvage of neck metastasis (with neck dissection)	0	1	
3 yr NED	9	14	64
5 yr NED	5	8	63

smokers and four of the six patients under 40 years of age developed neck disease. Three of the four nonsmokers and all four of the patients under 40 presented with previously untreated primary tumors of the anterior tongue. Disease control with initial therapy, local recurrence, neck metastatic, and distant metastatic rates at 3 years for previously untreated T1 and T2 anterior tongue carcinomas is shown in Table 6. One of these patients developed a local recurrence in the fourth year of follow-up and was salvaged with the CO₂ laser, and one patient with neck disease only who had been salvaged as of 3 years subsequently failed in the same neck.

Overall, three of the eight patients with neck disease had associated local recurrence, and all died. Two of the five patients with neck disease only were salvaged, both with a combination of neck dissection and radiation therapy.

New Primary Tumors. Eight of the ten patients with new primary disease after laser treatment of a separate primary tumor were treated for cure, while the remaining two could be treated for palliation only due to the extent of disease. Nine sites were treated in these eight patients. Two patients (one of them with two new primary tumors) had no evidence of disease at one site after CO₂ laser resection, but were followed for less than 3 years. In the remaining seven sites in seven patients, there was no evidence of disease at 3 years in six: three after CO₂ laser surgery, one after conventional wide local excision, one after wide local excision after laser failure, and one after CO₂ laser salvage of a conventional local excision failure. All successfully treated new primary tumors were T1 lesions at presentation. The remaining patient died of locally recurrent disease after unsuccessful wide local excision by conventional means. In the three patients who succumbed to new primary disease, the new primary was a T2 lesion or larger at presentation and was discovered more than 5 years after treatment for the prior primary tumor.

Complications. The 59 CO₂ laser procedures were complicated by bleeding at postoperative days 7 or 8 in three patients after resection of tongue lesions. This was controlled by cautery or ligation, and required return to the operating room and general anesthesia in one case. No transfusions or tracheotomies were necessary. Pneumonia developed

TABLE 5. TIME FROM LASER SURGERY TO REAPPEARANCE OF DISEASE

	Local Recurrence (N = 16)	Neck Metastasis (N = 8)	New Primary Tumor (N = 11)
Appearance within:			
1 yr	44 %	63 %	8 %
2 yr	81 %	88 %	36 %
3 yr	88 %	100 %	36 %
4 yr	100 %	100 %	45 %
5 yr	100 %	100 %	64 %
Mean	16 mo	11 mo	49 mo
Range	1-48 mo	1-33 mo	12-108 mo

in one patient postoperatively and resolved on appropriate antibiotic therapy. Wharton's duct was intentionally transected on four occasions, and submaxillary salivary gland obstruction developed in two of these cases but did not require treatment. The surgical defect was sutured closed on only two occasions early in the series, otherwise wounds were left open to close secondarily. There were no cases of significant local or neck infection. Granuloma formation occurred in three patients and delayed healing. Excisions were performed in the office with eventual satisfactory healing in all three cases. One patient had limitation of tongue movement after removal of a lesion from the tongue and floor of the mouth. Two patients developed mucous retention cysts, one resolving spontaneously and the other requiring marsupialization. Five patients had mild persistent pain for more than 3 weeks after surgery, but this resolved after a few weeks. Laser resection through periosteum down to the bone was performed in four cases. Three healed well, and one patient developed an oroantral fistula during palliative radiation for recurrent disease after CO₂ laser excision of a hard palate primary tumor that recurred after prior radiation therapy.

DISCUSSION

The data presented here are collected from a personal series of consecutive patients with carefully selected localized oral squamous cell carcinomas treated for cure using CO₂ laser surgery.

We have found vital staining with toluidine blue very helpful as an adjunct to the clinical examination of the oral mucosa. The dye is retained by mucosal dysplasia and carcinoma and can help by improving the accuracy of biopsy and by delineating the extent of mucosal abnormality associated with suspect lesions. Our experience shows a 2% false-negative rate in staining of oral mucosal dysplasia and malignancy.⁷ In the absence of clinically apparent metastases, primary tumor site, size, and especially depth remain the best prognostic indicators of chance of metastasis or cure.

Treatment failure will occur in the neck or distantly if viable cancer cells have become implanted in these areas before primary tumor removal and if

TABLE 6. TREATMENT RESULTS AFTER 3-YEAR FOLLOW-UP OF PREVIOUSLY UNTREATED T1 AND T2 ANTERIOR TONGUE CARCINOMAS (N = 15)

Results	T1 (N = 12)	T2 (N = 3)	Total	%
No subsequent disease	8	1	9	60
Local recurrence*	2	0	2	13
Neck metastasis	4	2	6	40
Distant metastases (lung)	1	0	1	7
NED	9/12	3/3	12	80

*An additional patient developed local recurrence after 3 years.

they are not adequately treated. Local recurrence is usually thought to be the result of failure to excise all cancer cells of the primary tumor. However, it has been postulated, given the multicentric nature of squamous cell carcinoma, that local recurrence can also be the result of transformation of abnormal epithelium surrounding the cancer defect. In 1953, based on gross and microscopic pathological examinations, Slaughter et al¹⁴ used the term "field cancerization" to describe a regional carcinogenic activity of the upper aerodigestive tract that resulted in multiple areas of dysplasia and carcinoma and that were most common in a particular anatomical microenvironment, but also likely to occur in other areas of exposed squamous epithelium. The multifocal abnormalities in virtually all excised oral squamous cell carcinomas and the fact that new primary carcinomas are found most frequently in the same site or region as the first primary tumor¹⁵ support this concept. Furthermore, studies of oral leukoplakia have shown a significant overall rate of transformation of this lesion into squamous cell carcinoma, and this rate is dramatically increased in those lesions which show dysplasia on histological examination.¹⁶ Therefore, it is conceivable that local recurrence may occur as the result of a form of new primary disease.

Once initial treatment has failed to control oral carcinoma, chance of cure with further therapy is much lower compared to that of primary treatment because the cancer is likely to be more widespread and because its extent is more difficult to determine. Salvage therapy must necessarily incorporate a large area, and for this reason radiation therapy alone may entail less damage than extensive surgery if it can still be given and if combination therapy is not indicated. If the recurrent lesion is small and localized, wide local excision may be tried and more radical treatment immediately undertaken if cancer recurs. In our hands salvage of small local recurrences by wide local excision has been more successful in treating recurrence after radiation therapy than after surgical removal. In such cases we now prefer laser excision, which minimizes the healing problems in a radiated field, since delayed healing can be difficult to distinguish from recurrent disease.

The CO₂ laser is a surgical tool with a unique set of characteristics that distinguishes it from sharp

dissection and electrosurgical or cryosurgical techniques. The advantageous technical features of the CO₂ laser are that it allows precise, orderly tissue dissection; access to more areas than with other transoral techniques; immediate tissue removal with provision of an acceptable specimen for histological examination; and low morbidity, all without compromise of further treatment options. The unique aspect of this technique is the ability to remove extensive areas of abnormal mucosa in addition to the main tumor specimen, leave the wound bed open, and still have excellent healing. This has the theoretical advantages of not delaying the recognition of recurrent disease and of decreasing local recurrence rate, although clinical data examining this last concept could only be obtained from large, carefully controlled studies in oral carcinoma and leukoplakia. In such cases, it is most appropriate to use CO₂ laser resection as opposed to other transoral surgical techniques because the reduction in morbidity is enough to significantly reduce length of hospitalization or degree of postoperative confinement and dysfunction.

One of the disadvantages of the CO₂ laser is that it is an expensive, delicate instrument that requires specially trained personnel to use and maintain it. Clinical experience is also necessary to master this surgical technique, particularly to assess and achieve appropriate margins of normal tissue around and beneath the cancer. While the major advantage of the laser is in achieving surface margins, the deep margin, as with any technique of local resection, can be very difficult to determine, and this difficulty increases with the depth of the cancer. Deeper lesions consequently require bigger margins, and the resulting defect may be large enough so that the differential in morbidity as compared with other techniques may no longer be significant. Obviously, greater lesion depth also increases the likelihood of metastatic disease, and for these reasons we currently limit the use of the CO₂ laser to superficial carcinomas.

Comparing these results to others,¹⁷ it is important to consider several factors. There are very small numbers of previously untreated lesions at any one site, and these lesions were selected on the basis of absence of deep invasion or metastatic disease. Many of the lesions, although small, were located at the junction of anatomical areas so that the usual anatomic classifications could not be strictly used. Lesions were grouped together as soft palate and anterior pillar, or ventral tongue and floor of mouth, of base of tongue and anterior pillar, for instance. Most lesions (73%) were T1 size; there was only one T3 lesion; and almost all of the remainder were small rather than large superficial T2 lesions (Table 1). The data for previously untreated and previously treated lesions will be considered separately.

There were no significant differences in survival

rates at 3 and 5 years between patients with T1 and T2 previously untreated lesions (Table 3). The overall 3-year survival rate for 33 patients in this group was 85% as compared to 83% in 18 patients at risk for 5 years. The most important prognostic factor for survival was site of lesion, as will be discussed below. In the group of patients with previously treated cancers, on the other hand, there was a difference in survival rates between patients with T1 and T2 lesions, and perhaps between 3- and 5-year survival rates, although numbers are small in these groups. Both T1 and T2 lesions had about the same local recurrence rate, which was higher than those in the untreated patient group. Salvage of these recurrences was better, however, in the T1 than in the T2 group. This resulted in 88% survival of eight patients in the T1 previously treated lesion group, comparable to survival in the untreated group. Three-year survival was poor in the T2 previously treated lesion group, with only 40% of ten patients without disease at 3 years and 17% of six patients at 5 years.

Local control rate is the most direct measure of the success of CO₂ laser excision. All but two local recurrences occurred by 3 years, and these two occurred during the fourth year after CO₂ laser surgery (Table 5). The timing of recurrence did not vary for previously treated versus previously untreated lesions, and there was no significant difference between recurrence rates for T1 and T2 lesions within these groups (Table 2). In the 38 previously untreated carcinomas, 13% had recurred at 3 years and 16% by the conclusion of the study. Half of these recurrences were associated with the appearance of neck metastasis, and no patient with both local and neck disease was salvaged. All three patients in this group with local recurrence only were salvaged, giving local control in 33 of 38 lesions (87%) at 3 years.

In the 18 previously treated lesions, local recurrence rate was about three or four times higher: 50% at 3 years and 56% overall. None of the local recurrences was associated with neck metastasis, but salvage for local recurrence only was worse than in the untreated lesion group and worse for T2 compared to T1 presenting lesions. The two patients who were found at laser surgery to have a lesion deeper than about 4 mm were both in this group, and both had local recurrence that could not be controlled. There was local control at 3 years in seven of eight T1 lesions (88%), although one patient later had a local recurrence that could not be salvaged. This compared to local control in four of ten T2 lesions (40%), with the status of one lesion indeterminate because of death from other causes. No particular method of local salvage appeared superior in any group.

The appearance of neck disease depends more on

the process of patient selection than on the success of surgery, since, in the absence of local recurrence, neck metastasis must be due to the presence of occult neck disease at the time of local surgery. Eight of the 51 patients (16%) developed neck disease over the full follow-up period, all in the ipsilateral neck, and all within 3 years of CO₂ laser surgery (Table 5). In three of the eight cases, there was associated local recurrence. Two of the five patients who developed neck disease only were salvaged, both with neck dissection and radiation therapy. Analysis of the data showed that neck metastasis was most strongly dependent on the site of the primary cancer. Two of four buccal lesions and five of 15 anterior tongue lesions accounted for all primary sites associated with the subsequent appearance of neck metastasis. While numbers are too small in the first site, there are enough anterior tongue carcinomas to examine and make comparisons. This demonstrates again the high risk of lesions at this site and the ineffectiveness of our current staging system.

Our series had 12 T1 and three T2 anterior tongue squamous cell carcinomas, all superficial, and all without prior treatment. For purposes of comparison, we will consider these as a single group comparable to stage I lesions since no clinically deeply invasive lesions are included. Nine (60%) were cured by CO₂ laser resection only as of 3-year follow-up, and three with appearance of neck disease only were salvaged, giving 80% without disease at 3 years. Local recurrence rate at 3 years was 13%, and the neck metastatic rate was 40% (Table 6). Only four lesions failed treatment in the entire follow-up period in the previously untreated lesion group. One was a buccal lesion and the other three were anterior tongue lesions. Lesions of the ventral tongue that included the floor of the mouth were categorized with floor of the mouth lesions. This confirms the high risk nature of anterior tongue lesions, and the suggestion of treating the necks with postoperative radiation therapy for T2 lesions and histologically aggressive T1 lesions seems reasonable. A potential problem with using the laser in this situation could be a delay of radiation therapy if a large defect needed to be epithelialized, but this can be avoided by leaving the healing site out of the irradiation field. The high proportion of nonsmokers and patients under 40 with neck disease appeared to be a direct result of these patients having tongue lesions. Whether or not this was a result of preferential selection of accessible carcinomas is unclear. The very low incidence of neck disease in the group with previously treated lesions may be explained mainly by the lack of high risk sites in this group (since all anterior tongue lesions were in the untreated lesion group), or perhaps because most of them had received prior radiation therapy and were chosen for CO₂ laser therapy because they had failed only locally.

Carbon dioxide laser treatment of lesions after failure of primary radiation therapy showed a local recurrence rate of 50% (seven of 14), and three of these seven subsequent local recurrences were salvaged with composite resection for no evidence of disease at 3 and 5 years in more than 60% (Table 4). These results support the fact that wide local excision after radiation failure can be curative, while failure does not greatly lower the chance of salvage with composite resection. Our data do not agree with the suggestion of others¹¹ that CO₂ laser resection is contraindicated in the treatment of radiation therapy failures.

The proportion of patients developing new primary disease (20%) was about as expected and emphasizes that this must be anticipated in treatment planning. Risk of new primary disease was greatest in those who had already had multiple primary tumors and in those who continued to smoke and drink alcohol. All new primary tumors were located in the oral cavity or oropharynx, supporting the concept that multiple primary tumors are most likely to develop in the same anatomical region. Only three of these ten patients died from their new primary tumor, about half the expected death rate. Two of the patients had lesions that have been at risk of failure for less than 3 years, and none of the patients had new primary esophageal disease, which carries a dismal prognosis. The patients who did fail had relatively large lesions at presentation at a time when they were only being followed every 6 months, and an argument can be made for continuing more frequent follow-up than this, even more than 5 years after treatment. The longest interval between the first occurrence and the new primary tumor in this series was 9 years (Table 5).

The complication rate was low, and healing was excellent in almost all cases.

CONCLUSIONS

A retrospective study of 51 consecutive patients with at least 3-year follow-up after transoral CO₂ laser resection of oral cavity and oropharyngeal squamous cell carcinomas is presented. Microscopically controlled CO₂ wide local resection has control rates comparable to or better than conventional surgery or irradiation, heals well, does not preclude irradiation for occult neck disease or subsequent composite resection for recurrences, and can be used repeatedly for multiple primary tumors when irradiation cannot.

The CO₂ laser has several inherent advantages. 1) It allows precision of removal. 2) It achieves a virtually bloodless field because mucosal and muscle capillaries are sealed by the laser beam's heat and the occasional larger vessels are then easily cauterized with the electrocautery. Thus, assistants are not having to constantly sponge and suction, which interferes with the surgeon's view of the tongue (much less the soft palate), spreads cancer cells around the wound, and tends to dislodge the self-retaining retractors. 3) The CO₂ laser improves visualization of the lesion. Because of the dry field and the intense illumination and magnification of the operating microscope, subtle mucosal abnormalities are seen well. 4) Mucosa can be removed easily and thoroughly to a constant depth, and margins can be easily enlarged if desired because abnormal cells have not been incised and spread around, but have been vaporized and made nonviable. 5) The CO₂ laser does not thrombose the vascular supply for the wound and damage the nerve fibers to the depth that electrocautery resection does. This may be the reason they appear to heal with less pain and scarring after CO₂ laser resection. 6) Most important of all, microscopically controlled CO₂ laser resection has cured the cancer without the composite resection that would have been required in the past in more than a dozen of these patients.

REFERENCES

1. Jako GJ. Laser surgery of the vocal cords. An experimental study with carbon dioxide lasers on dogs. *Laryngoscope* 1972; 82: 2204-16.
2. Strong MS, Jako GJ. Laser surgery in the larynx. Early clinical experience with continuous CO₂ laser. *Ann Otol Rhinol Laryngol* 1972; 81:791-8.
3. Strong MS, Jako GJ, Polanyi TG, Wallace RA. Laser surgery in the aerodigestive tract. *Am J Surg* 1973; 126:529-33.
4. Strong MS, Vaughan CW, Healy GB, Shapshay SM, Jako GJ. Transoral management of localized carcinoma of the oral cavity using the CO₂ laser. *Laryngoscope* 1979; 89:897-905.
5. Carruth JAS. Resection of the tongue with the carbon dioxide laser. *J Laryngol Otol* 1982; 96:529-43.
6. Frame JW. Removal of oral soft tissue pathology with the CO₂ laser. *J Oral Maxillofac Surg* 1985; 43:850-5.
7. Silverman S Jr, Miglioni C, Barbosa J. Toluidine blue staining in the detection of oral precancerous and malignant lesions. *Oral Surg* 1984; 57:379-82.
8. Hall RR, Hill DW, Beach AD. A carbon dioxide surgical laser. *Ann R Coll Surg Engl* 1971; 48:181-8.
9. Mihashi S, Jako GJ, Incze J, Strong MS. Laser surgery in otolaryngology: interaction of CO₂ laser and soft tissue. *Ann NY Acad Sci* 1976; 267:263-94.
10. Vaughan CW. Management of oral lesions. In: Andrews AH Jr, Polanyi TG, eds. *Microscopic and endoscopic surgery with the CO₂ laser*. Littleton, Mass: John Wright PSG, Inc, 1982: 164-70.
11. McDonald GA, Simpson GT. Transoral resection of lesions of the oral cavity with the carbon dioxide laser. *Otolaryngol Clin North Am* 1983; 16:839-47.
12. Fisher SE, Frame JW, Browne RM, Tranter RM. A comparative histological study of wound healing following CO₂ laser and conventional surgical excision of canine buccal mucosa. *Arch Oral Biol* 1983; 28:287-91.
13. Beahrs OH, Myers MH. *Manual for staging of cancer*. 2nd ed. Philadelphia: JB Lippincott Co, 1983:11-21.
14. Slaughter DP, Southwick HW, Smejkal W. "Field cancerization" in oral stratified squamous epithelium, clinical implica-

tions of multicentric origin. Cancer 1953; 6:963-8.

15. Berg JW, Schottenfeld D, Ritter F. Incidence of multiple primary cancers. III. Cancers of the upper digestive system as multiple primary cancers. JNCI 1970; 44:263-74.

16. Silverman S Jr, Gorsky M, Lozada F. Oral leukoplakia and

malignant transformation. A followup study of 257 patients. Cancer 1984; 53:563-8.

17. Leipzig B, Cummings CW, Chung CT, Johnson JT, Sagerman RH. Carcinoma of the anterior tongue. Ann Otol Rhinol Laryngol 1982; 91:94-7.

ANESTHETIC MANAGEMENT FOR TRACHEOBRONCHIAL LASER SURGERY

MICHAEL RONTAL, MD
MILFORD E. WENOKUR, MD

EUGENE RONTAL, MD
LAWRENCE ELSON

DETROIT, MICHIGAN

The use of the laser has become a well-recognized means of treating obstructing lesions of the tracheobronchial tree. Patients with lower airway compromise are in a precarious state of equilibrium. Everything done by the endoscopy-anesthesiology team tends to change this balance. Cooperation and coordination of this well-disciplined team is needed for efficient treatment of difficult cases. This paper outlines our surgical techniques, which have been tempered and modified to an anesthetic technique that provides the greatest safety with comfort. We detail the basic anesthetic methods for drug usage, pulmonary ventilation, and patient monitoring that we now use. A careful analysis of our results is presented to show that this technique does provide relatively safe anesthesia in this difficult setting.

KEY WORDS — anesthetic administration, carbon dioxide laser, laser surgery, lower airway compromise, neodymium: yttrium aluminum garnet laser.

INTRODUCTION

The advent of laser surgery in the bronchus has opened up new avenues of therapy for both benign and malignant disease of the airway.¹ Patients with benign lesions that heretofore required major open procedures can now be treated definitively with the laser as outpatients. Malignant lesions, which cause death by suffocation, can be treated by endoscopic coring because they are unresectable. However, these new advances have also brought new problems in the medical management of critically ill patients. These patients may have high-grade respiratory obstruction with marked hypoxemia and may also have associated cardiac problems. In addition, they may have poor pulmonary toilet with trapping of secretions and associated pulmonary infection. All these factors must be taken into account by the surgeon and anesthesiologist when assuming the management of these patients.

Because of the precarious physical state of these individuals, close interaction between surgeon and anesthesiologist is necessary. For success, a routine must coordinate the techniques of surgeon and anesthesiologist. Methods of oxygenation, maintenance of airway patency, and administration of medication need to be well understood before treating these patients. This is not a simple and routine endoscopic procedure to be performed on an occasional basis.

This paper presents our experience with the team approach to endoscopic surgery during our last 126 consecutive procedures and discusses our coordinated anesthetic-surgical techniques for laser surgery using the bronchoscope.

METHODS AND MATERIALS

Team Approach. Intrinsic to all these procedures is the team approach, with everyone aware of the entire procedure and disciplined in their role. Our team consists of the surgeon; the anesthesiologist and anesthetic technician; a laser technologist; and circulating, scrub, and postoperative nurses. They must be familiar with both the techniques of laser surgery and the varieties of equipment required.

Preoperative Work-Up. The preoperative work-up may vary, depending on the emergency of the situation. Our basic assessment of the patient consists of a careful preanesthetic evaluation, a preoperative chest x-ray examination with special attention to luminal size of both the trachea and main stem bronchi, and an ECG. These provide a gross assessment of the tracheobronchial obstruction so that problems at the operative site can be anticipated. If possible, we add pulmonary function studies with flow volume loops, arterial gases, and either tomography of the trachea and main stem bronchi or computed tomographic scans. These indicate the amount of pulmonary reserve and the involvement of the extrabronchial structures.

Surgical Technique. A rigid bronchoscope was used whenever possible in this series. The choice of bronchoscope tube may vary depending upon the operative objective and the personal experience of the surgeon; our choice was the Sharplan 781 bronchoscope with the Sharplan 743 80-W carbon dioxide laser. This features continuous wave, pulse, repeat pulse, and superpulse, and had a three times proximal magnifier, continuous variable defocus, and spit windows. The Sharplan micromanipulator

From the Department of Otolaryngology-Head and Neck Surgery, University of Michigan (M. Rontal, E. Rontal); the Departments of Otolaryngology (M. Rontal, E. Rontal), Anesthesiology (Wenokur), and Laser Technology (Elson), Sinai Hospital of Detroit; and the Department of Anesthesiology, Wayne State University School of Medicine (Wenokur), Detroit.

Presented at the meeting of the American Laryngological Association, Palm Beach, Florida, May 4-5, 1986.

REPRINTS — Michael Rontal, MD, Tower 14, Suite 545, 21700 Northwestern Hwy, Southfield, MI 48075.

had a 200-, 300-, and 400-mm focusing lens. When the neodymium: yttrium aluminum garnet (Nd:YAG) fiber was used, we employed the Quantronics 117 Nd:YAG laser at 0 to 100 W and the Cooper Lasersonics 8000 Nd:YAG laser system. The Nd:YAG fiber can be passed either through the rigid scope or through the flexible bronchoscope. When the flexible bronchoscope is used (Olympus BF-IT), it is passed through the rigid scope. The flexible scope is used only when the rigid scope cannot be inserted, eg, in cases of severe cervical spine disease or limited temporomandibular joint excursion. If a tracheostomy was in place, the rigid scope was placed either transorally into the tracheobronchial tree or through the tracheal stoma.

For safety with the CO₂ laser, all individuals working with the laser in the operating room must wear plastic visitor glasses with side panels (Midland Optical, model 410 clear). When the Nd:YAG laser was used, all were required to wear green goggles with an optical density of 14 at 1.06 μ m (Glen-dale Optics). Further, eyepieces were used to filter the laser and protect the eyes of the surgical team. These eyepieces were coated, clear reflective filters which can attach to the bronchoscope or into a video beam splitter (Circon) and television (Cooper Lasersonics).

For further safety, there should be cautionary signs on doors leading to the operating room and opaque covering over the windows so that Nd:YAG light cannot escape the operating room and injure unsuspecting bystanders. The patient's eyes are wrapped in a standard fashion for laser surgery.

Precautions for bleeding are taken by having endoscopic forceps and gauze packing available. If bleeding occurs, the packing is used to close off the bleeding site and respiration is maintained in the other lung through the rigid bronchoscope.

A video monitor is used in all procedures, and all members of the operating team view the surgery. The television is attached either to the rigid or the flexible bronchoscope. The system used is the Circon endovideo camera and MV-9862 beam splitter.

The Nd:YAG laser was used to circumferentially photocoagulate the margins of the tumor at power outputs not greater than 45 W. The central core is then removed using the CO₂ laser or rod telescopic bronchial forceps. Whenever possible, the surgery was done as an outpatient procedure.

The choice of anesthetic technique was made preoperatively. General anesthesia was used in the proximal trachea, in individuals who chose not to undergo local anesthesia, and in patients with an existing tracheostomy. Use of local anesthesia was favored in the middle and lower third of the trachea whenever possible and especially when the obstruction was emergent or life threatening, the cross-section

area of the trachea was decreased by greater than 50% as seen on x-ray film, or the disease extended out of the main stem bronchus, past the carina, and into the trachea. Many patients with disease in this area were in a precarious medical state.

All patients operated on while under local anesthesia were premedicated with an anticholinergic, glycopyrrolate (0.2 mg) being our drug of choice. In addition, depending on the patient's condition, hydroxyzine (25 to 50 mg) or judicious amounts of meperidine hydrochloride (Demerol; 25 to 75 mg) or fentanyl citrate (0.05 to 0.1 mg) may be given intramuscularly. Oral lorazepam (2 mg) 2 hours preoperatively was found to be very useful in producing amnesia; however, it was avoided in the elderly. In the very poorest risk patients, all drugs except the anticholinergic were administered only upon arrival in the operating room. In those patients who were to receive sedation only, 10 to 15 mL of 4% lidocaine was administered via an ultrasonic nebulizer, either through an aerosol mask or a mouthpiece, approximately 15 minutes before the procedure.

Upon the patient's arrival in the operating room, an ECG and automatic blood pressure monitor were connected. Early in our experience, an indwelling arterial catheter for blood gas measurements was inserted. More recently, the use of the pulse oximeter was considered so useful that it has practically replaced invasive monitoring.

Patients under local anesthesia were given small amounts of droperidol (2.5 mg), diazepam (Valium; 2.5 to 5.0 mg), and ketamine hydrochloride (10 to 20 mg), the drugs used depending on the anesthesiologist's preference. Narcotics are generally avoided except for the premedication dose or at most, 0.05 mg of fentanyl citrate, since these patients are frequently already hypoxemic and additional respiratory depression from the narcotic may not be tolerated.

Before the bronchoscope is inserted the base of the tongue and mucous membranes of the upper lip are sprayed with a total of 60 mg of 10% lidocaine to help the patient tolerate the pressure of the rigid bronchoscope. Additional amounts of sedative drugs are given during the procedure if it is prolonged or the patient indicates discomfort. The anesthesiologist must distinguish between discomfort and hypoxia. If coughing occurs during the procedure, 1 to 2 mL of 4% lidocaine is instilled through the bronchoscope, or up to 1.5 mg/kg of 2% lidocaine is given intravenously (IV).

Hypertension is treated with propranolol IV, or more recently it has been our practice to start a nitroglycerin drip (5 mg/250 mL of saline) in hypertensives and patients with coronary artery disease. A jet injector and endotracheal tube should be im-

mediately available for all of these cases.

Patients under general anesthesia were usually sedated with thiobarbiturate (3 to 4 mg). Muscle relaxation was produced with vecuronium bromide (0.08 mg/kg), a relatively short-acting nondepolarizer, and anesthesia was maintained with isoflurane and oxygen mixed with nitrogen or helium at a 30% oxygen to 70% helium ratio. Inhalation agents were administered through the ventilating bronchoscope, or in those patients with a tracheostomy tube, a plastic endotracheal tube was inserted a short way into the patient's metal tracheostomy tube. In all cases with an existing tracheostomy, a metal tube was required during the laser procedure. At the completion of the procedure, if complete neuromuscular transmission had not returned, as determined with the nerve stimulator, neostigmine (5 mg) and glycopyrrolate (1 mg) were administered to reverse the blockade. Again, as with local anesthetic cases, hypertension was controlled with either propranolol or nitroglycerin or both. Both groups of patients generally received IV steroids, usually 8 mg of dexamethasone. After the procedure, when the patients were ventilating adequately, they were taken to the recovery room, where humidified oxygen was administered.

Depending on the ventilating state of the patient, supplementary oxygen was administered; under local anesthesia 100% oxygen was given through the side arm of the bronchoscope; during the period that the laser was used, it was shut off and the patient was maintained on room air. Under general anesthesia, the patient was ventilated on a mixture of 30% oxygen and 70% helium. In the postanesthetic care unit, the patient was carefully monitored for signs of airway obstruction. If progressive airway obstruction was noted within a 3-hour period following the surgery, a repeat bronchoscopy was performed to ascertain whether tumor slough was the cause.

Patients Studied. There were 126 procedures on 45 patients in this series. These patients ranged in age from 17 to 79 years. There were 24 males and 21 females. Fifteen of the patients had granulomas, papillomatosis, or benign disease such as strictures. Thirty patients had malignant disease with diagnoses including squamous cell carcinoma, adenocarcinoma, carcinoid, and lymphoma of the lung. Sixty-five of these procedures were performed on inpatients and 61 on outpatients. Eighty-eight of the procedures were performed with the patient under local and 38 under general anesthesia. Of the patients studied with benign disease, 36 were under general and two under local anesthesia. Of the patients studied with malignant disease, two were under general and the remainder, or 86, under local anesthesia. One patient with a carcinoid in the lingular bronchus required conversion to general anesthesia during the procedure because of inability

to provide adequate, relatively safe sedation.

RESULTS

The results of this study of 126 consecutive laser bronchoscopies on 45 patients showed 11 complications. Of these cases, six represented individuals requiring a return to the operating room in the immediate postoperative period to remove obstructing tumor slough. One patient had respiratory distress in the recovery room caused by subglottic edema and was treated successfully with racemic epinephrine. There was one ignition of the flexible bronchoscope, which was immediately recognized and the bronchoscope removed into the rigid scope without tracheal or laryngeal burns. Two patients had pneumothoraces: one had tracheal papillomata removed under general anesthesia; the other had almost total respiratory obstruction from tumor and blood clots and required controlled ventilation with very high pressures through an endotracheal tube. There was no evidence of extraluminal penetration of the laser in either case. It was postulated that the pneumothoraces occurred from high ventilatory flow rates and pressure associated with assisted respiration in a markedly obstructed airway. There were two postoperative deaths within 48 hours of surgery. Both involved sudden death secondary to arrhythmia, probably related to tumor infiltration of the pericardium.

The incidence of operative hypertension appeared to be similar whether these patients had local or general anesthesia during surgery. Operative hypertension was defined as a greater than 25% increase over baseline systolic pressure. Twelve of the 38 cases under general anesthesia and 19 of 88 cases under local anesthesia had an elevation of pressure. The incidence of intraoperative arrhythmia was extremely low. Two patients had significant premature ventricular contractions, one under local and one under general anesthesia. One patient had ventricular fibrillation under local anesthesia that was converted successfully. This patient had several previous laser procedures on his bronchus and was near death when the arrhythmia occurred.

There were two patients in whom rigid bronchoscopy could not be performed. One had cervical traction from a cervical vertebral fracture and could not be intubated. This patient was given a general anesthetic through his tracheostomy tube, and the flexible scope was passed transorally through the larynx to remove granulation tissue below the tracheal stoma. The other patient had tracheal papillomata and a previous cervical laminectomy. A rigid bronchoscope could not be inserted. Again, a flexible bronchoscope was passed from above while anesthetic was administered through the existing tracheostomy.

DISCUSSION

As in all endoscopic procedures, the anesthesiolo-

gist and endoscopist must work as a team. This is particularly true in these cases where a surgical treatment (ie, laser coring of the airway) of a medical condition (eg, poor alveolar ventilation and toilet) is being performed. In the larynx and upper trachea, it is usually possible to intubate or perform a tracheostomy to open the occluded airway. In the lower trachea, at the carina or in the bronchus, the patient may be treated successfully only with rapid removal of the obstruction and control of bleeding. Our experience indicates several factors necessary to ensure relatively safe endobronchial laser surgery.

First in our protocol is the presence of an experienced laser surgical team. The anesthesiologist must understand the surgical procedure as if he or she were performing the operation. In a similar manner, the surgeon must understand any anesthetic problems to foresee in order to avoid disaster. A laser technologist must be present to ensure that the equipment is functioning properly. The high temperatures produced by the laser create the chance of malfunction. The inability of the surgeon and anesthesiologist to both operate with and check on the equipment necessitates the technologist's presence. The anesthesiologist must have an experienced assistant to help in managing the patient. The circulating and scrub nurses must have expertise in the laser procedure. They must be familiar with both the different approach of laser surgery and the different instrumentation needed. Finally, the postanesthetic recovery room nurses must be aware of the potential recurrence of airway obstruction.

Mandatory to our team approach is the use of video monitoring. By viewing the video monitor, the anesthesiologist can anticipate the patient's needs, and the nurses can be prepared for the endoscopist. In addition, video monitoring produces a video record, which is helpful in reviewing the case, planning the next procedure, and developing new approaches.

Second in providing a relatively safe endoscopy is a preference for local anesthesia whenever possible. This is particularly true in emergency situations with high-grade airway obstruction, where a thorough knowledge of the patient's cardiorespiratory reserve and tumor extent cannot be ascertained. Our arbitrary criteria are that local anesthesia should be used when the middle or lower tracheal lumen is decreased by greater than 50% of its cross-sectional airway as seen on x-ray film, in emergency situations with high-grade obstruction, or when the lesion projects out of the main stem bronchus and involves the trachea above the carina. The reasons usually given for the use of general anesthesia are patient comfort, greater ability to adequately ventilate the patient, and more controlled operating conditions. Local anesthesia is reserved by some authors for less severe disease.² The results of this

study refute this concept, showing that relatively safe local anesthesia can be provided without increased risk to critically ill patients. While spontaneous respiration is possible under general anesthesia, the agents used may significantly depress respiration in patients who may not tolerate decreased ventilation because of their high-grade obstruction or associated cardiac disease. The ability of the patient to spontaneously create negative intrathoracic pressure under local anesthesia may be the margin of safety that the patient needs to maintain oxygenation. This is in agreement with techniques for spontaneous respiration during laser surgery advocated by others.³⁻⁶ Further, in our series of patients, positive pressure ventilation may conceivably add to the airway obstruction by causing a "ball-valve effect," a hyperinflated lung, and pneumothorax.⁷ Further, this assisted ventilation either through a side arm or with a jet ventilator may force blood and debris onto the bronchoscope, obscuring the vision of the surgeon. Perry and Sander-son⁸ have shown that PCO₂ increases during bronchoscopy under general anesthesia while remaining relatively normal under sedation alone. Brutinel et al⁹ have shown that with general endotracheal anesthesia, the PO₂ and the difference between arterial and alveolar oxygenation remain markedly abnormal when general anesthesia is used. As an added advantage to local anesthesia, the inhaling of room air alone decreases the risk of ignition of flammable materials. Patients under local anesthesia in our series were generally amnesic, comfortable, and immobile.

General anesthesia may be the method of choice for certain patients. First, benign disease of the more proximal trachea seemed well treatable under general anesthesia. Bleeding and clot formation were less frequent than with malignant tumors, and the positive pressure or jet inhalation was less likely to cause ball-valving because of the larger segment of normal distal trachea and bronchus beyond the obstruction. Second, general anesthesia appears to be the method of choice in children, young adults, and those few patients who for psychological reasons cannot tolerate local anesthesia. Third, in some patients with existing tracheostomies, a general anesthetic delivered through the tracheostomy tube is preferred. Lastly, general anesthesia is acceptable in treatment lesions of the distal bronchus where topical anesthesia may be difficult to achieve and adequate ventilation of the remaining lung is not a problem.

Third in our criteria for providing relatively safe anesthesia for laser bronchial surgery is our adherence to the use of a rigid bronchoscope whenever possible.²⁻⁶ The use of a rigid bronchoscope has been advocated by other investigators. The 7- to 9-mm bronchoscope offers clearer access to the lower lung and is the quickest way to access obstructive lesions and debris and to control bleeding.

If the flexible bronchoscope is required, it can be passed through the rigid bronchoscope. The use of the rigid bronchoscope as the carrier for the fiberoptic scope with the Nd:YAG fiber also has advantages compared to the endotracheal tube. The larger internal diameter significantly reduces airway resistance, and the fire hazard is reduced because of the lack of a potentially combustible endotracheal tube.¹⁰

Fourth in our protocol are some innovations in anesthetic technique. Ultrasonic nebulization of lidocaine produces good preoperative anesthesia of the laryngotrachea. This is supplemented by topical application in the operating room where necessary. Blood samples after nebulization have shown non-toxic levels (M. Macon, unpublished observations). The pulse oximeter measures oxygen saturation, and sudden changes will alert the anesthesiologist to an impending problem. The use of IV nitroglycerin aids in maintaining normotension during procedures that produce intense sympathetic stimulation. Also, the use of helium to dilute the concentration of oxygen both decreases flammability and provides decreased gaseous viscosity that improves flow through areas of air turbulence and obstruction.

Fifth, postanesthetic observation is extremely im-

portant. Reobstruction with tumor debris may necessitate repeat bronchoscopy. Only by continuous close postoperative observation will untoward sequelae be prevented. Therefore, the patients are kept in the recovery room for a longer period than usual.

Lastly, once an adequate airway was established, we were successful in administering repeat treatments to patients as outpatients. This allowed a minimum of time loss in the hospital by the patient, many of whom had only weeks or months left to spend at home with their families.

Complications noted in this paper are similar to those described by other authors. Pneumothorax appears to be more likely under controlled ventilation, since increase in positive pressure may force air subcutaneously.^{7,11} As in other laser procedures, we try to avoid endotracheal tubes. The use of a rigid scope will help in preventing any untoward sequelae from ignition of the fiberoptic bronchoscope because the ignited substance can be retracted inside the scope.^{6,12,13} Finally, persistent obstruction postoperatively from tumor debris and slough must be recognized as a potential complication, and the postanesthetic recovery room team must be aware of this possibility.

REFERENCES

1. Dumon JF, Reboud E, Garbe L, Aucomte F, Meric B. Treatment of tracheobronchial lesions by laser photoresection. *Chest* 1982; 81:278-84.
2. Shapshay SM, Beamis JF Jr. Safety precautions for bronchoscopic neodymium-YAG laser surgery. *Otolaryngol Head Neck Surg* 1986; 94:175-80.
3. Shapshay SM, Dumon JF, Beamis JF Jr. Endoscopic treatment of tracheobronchial malignancy. Experience with Nd-YAG and CO₂ lasers in 506 operations. *Otolaryngol Head Neck Surg* 1985; 93:205-10.
4. Dumon JF, Shapshay S, Bourcureau J, et al. Principles for safety in application of neodymium-YAG laser in bronchology. *Chest* 1984; 86:163-8.
5. Ossoff RH, Karlan NS. Safe instrumentation in laser surgery. *Otolaryngol Head Neck Surg* 1984; 92:644-8.
6. Eisenman TS, Ossoff RH. Anesthesia for bronchoscopic laser surgery. *Otolaryngol Head Neck Surg* 1986; 94:45.
7. Rontal E, Rontal M, Wenokur ME. Jet insufflation anesthesia for endolaryngeal surgery: a review of 318 consecutive cases. *Laryngoscope* 1985; 95:990-2.
8. Perry LB, Sanderson DR. Anesthesia for prolonged bronchoscopy. *Ann Thorac Surg* 1975; 19:248-53.
9. Brutinel WM, McDougall JC, Cortese DA. Bronchoscopic therapy with neodymium-yttrium-aluminum-garnet laser during intravenous anesthesia. *Chest* 1983; 84:518-21.
10. Warner ME, Warner MA, Leonard PF. Anesthesia for neodymium-YAG (Nd-YAG) laser resection of major airway obstructing tumors. *Anesthesiology* 1984; 60:230-2.
11. Toty L, Personne C, Colchen A, Vourc'h G. Bronchoscopic management of tracheal lesions using the neodymium yttrium aluminum garnet laser. *Thorax* 1981; 36:175-8.
12. El-Baz NM, Caldarelli DD, Holinger LD, Faber LP, Ivanovich AD. High frequency ventilation through a small catheter for laser surgery of laryngotracheal and bronchial disorders. *Ann Otol Rhinol Laryngol* 1985; 94:483-8.
13. Duncavage JA, Ossoff RH, Rouman WC, et al. Injuries to the bronchi and lungs caused by laser-ignited endotracheal tube fires. *Otolaryngol Head Neck Surg* 1984; 92:639-43.

TWELFTH DANIEL C. BAKER, JR, MEMORIAL LECTURE VICTOR NEGUS: 57 YEARS LATER

DONALD F. N. HARRISON, MD, PhD

LONDON, ENGLAND

The three-dimensional morphology of the mammalian larynx was studied for 15 years. Using specimens obtained from a wide variety of sources, efforts were made to correlate structure with function and thus explain the variations in size and morphology seen in over 150 families of mammals.

KEY WORDS — larynx, mammalian larynges.

The appointment in 1837 by the Royal College of Surgeons of England of Richard Owen as Hunterian Professor, with a commitment to give an annual course of 24 lectures on comparative anatomy and physiology, took place against a background of a clash between the functionalism of Cuvier and the structuralism of Geoffroy. Not only did it indicate a commitment by the college to comparative anatomy and paleontology, but it was seen as a means of elevating English medicine in Europe and raising the status of surgery in London.

Owen emerges as a major figure in 19th century biology, and although his interests changed from physiology to osteology during his 18-year tenure, he made fundamental contributions to improving classification of animals, reintroduced the microscope as an essential scientific instrument, formulated general laws of animal morphology, and was a pioneer in paleontology.

His research was based not only on the specimens in the Hunterian Collection but on material provided by the Zoological Society of London, sent from the colonies and from expeditions, including those of both Darwin and Livingstone. One publication of some 1,000 pages included nearly 6,000 specimens!

Owen was the first to distinguish clearly between analogous and homologous parts of organisms, giving the differentiation a clarity that only the breadth and depth of his systematic knowledge made possible. His work, however, was not without criticism, for the Royal College of Surgeons was repeatedly questioned as to why it focused its limited resources on comparative anatomy and paleontology, instead of on human and morbid anatomy or on surgery. The London medical schools had of course included comparative anatomy in their curriculum since at least 1835, and its intrinsic value in the practice of medicine and surgery had long been advocated. Owen himself argued that dissection and animal ex-

periments had greatly aided in the understanding of human anatomy and physiology. The *Medical Times* of 1844¹ commented "No one can acquire a clear insight into the physiology of the human organs unless he have borrowed from comparative anatomy the powerful light which that interesting science can alone shed upon his researches." By the time Owen resigned his Hunterian professorship in 1856, a student could obtain a medical education in one of 11 London hospital schools, all of which offered a full program of lectures including morbid and comparative anatomy.²

Not surprisingly, Owen's morphologic studies — which included a description of the anatomy of the opossum, wombat, and even the process of a kangaroo's birth — were of a generalized nature. Few had the time, funding, and motivation to study the comparative anatomy of a specific organ in detail. Today's anatomic publications bear witness to this sorry situation, being largely concerned with the ultrastructure of portions of organs rather than more general morphologic concepts.

Whether Victor Negus — the man who not only inspired the title of this lecture but also the work on which it is founded — was stimulated by Owen's writings I am unsure. It was 65 years after Owen's resignation that Negus commenced work in the same museum of the Royal College of Surgeons in London, using many of the same specimens enhanced with material from the Zoological Society of London. He gave only one Hunterian Lecture, but during the next 8 years carried out the comparative anatomic research that culminated in 1929 with the publication of his 528-page volume entitled *The Mechanisms of the Larynx*.³ This work has been generally recognized as showing the same patient power of assembling observation after observation as Darwin had and the same hot pursuit of function as was urged by Hunter. No one can deny such comparisons, particularly when it is remembered that these studies were

From The Institute of Laryngology and Otology, London.

Presented at the meeting of the American Laryngological Association, Palm Beach, Florida, May 4-5, 1986.

REPRINTS — Donald F. N. Harrison, MD, The Royal National Throat, Nose, and Ear Hospital, 330 Gray's Inn Rd, London, WC1X 8DA, England.

not by a professional anatomist or zoologist but by a surgeon busily engaged in acquiring surgical training and, later, a highly successful practice. The latter must have suffered during this period of intense time-consuming anatomic research, and Negus rightly acknowledges in his preface the financial support provided by his parents.

The appendices included in this monumental publication illustrate the wide range of species examined, but give no indication of the number of individual specimens. Most were macroscopic dissections, for time and financial restrictions would not have allowed the three-dimensional studies that have occupied my own attention for the past 15 years. Nevertheless, many of his findings were original, and his interpretation of the mechanism by which this unique organ functions provided the foundation for much of modern laryngologic practice.

Few individuals leave behind them memorials of such stature that, despite the passage of time, they continue to excite and stimulate. This has been my own excuse for devoting so much precious energy to furthering my knowledge of the morphology of the mammalian larynx. It would be presumptuous of me to describe my own researches as extensions of the studies of Owen and Negus; rather, I have attempted to utilize the facilities and expertise of today's technology to enhance and substantiate the brilliant conceptions of these pioneer comparative anatomists.

THE LAST 15 YEARS

The principle of symmorphosis has been defined as "a state of structural design commensurate to functional needs resulting from regulated morphogenesis, whereby the formation . . . of structural elements is regulated to satisfy but not exceed the requirements of the functional system."⁴ This relates to symmorphosis at peak aerobic demand and may therefore be particularly applicable to the larynx. In essence, the fundamental concept that structure is primarily related to function has guided my own investigations. Although Negus and others examined the morphologic structure of various animal larynges, little attention has been paid to interspecies variations in relation to age and sex. Detailed three-dimensional reconstruction necessitates sectioning in at least three planes and measurement of a wide range of morphologic parameters. Such research requires a large number of accurately documented specimens, considerable laboratory resources, and an inordinate amount of personal time. Thanks to the facilities of the Institute of Laryngology and Otology in London, the Zoological Society of London and many other zoos, anatomy departments, and colleagues, I acquired over 670 specimens, which included 150 different families, up to the end of 1985 (Table 1).

The methodology used in this continuing, long-

TABLE 1. 670 SPECIMENS OF MAMMALIAN LARYNGES REPRESENTING 150 FAMILIES

Order	No. of Families Examined
Carnivora	26
Pinnipedia	2
Proboscidea	1
Hyracoidea	1
Perissodactyla	5
Tubulidentata	1
Artiodactyla	49
Marsupialia	11
Insectivora	1
Chiroptera	10
Primates	18
Cetacea	2
Edentata	3
Lagomorpha	1
Rodentia	19
Total	150

term study has been described in a paper published in 1976.⁵ After detailed recording, using a custom-designed punch card based upon that developed in the Department of Otolaryngology, University of Toronto, for human laryngeal sectioning, decisions are made as to whether the specimen is to be sectioned histologically, converted into a museum specimen (of which there are now 82), or submitted to macroscopic dissection. Whatever the final outcome, information collection is the top priority and utilizes modern photographic and data collecting techniques. By this means data banks are available for future evaluation. The unique histologic section collection, prepared by modifications of the technique described by Tucker in 1963⁶ but using equipment that permits larynges as large as 15 x 15 cm (6 x 6 in) to be sectioned, allows a variety of different staining methods.

Although the acquisition of a well-documented, unique collection of macroscopic and histologically sectioned mammalian larynges provides the basis for present and future study, a carefully constructed research plan is necessary if the full potential is to be achieved. Negus himself admitted that his original purpose was to carry out research primarily aimed at obtaining a Mastership of Surgery. This was later developed into a study of voice production in animals and humans, although fortunately this worthy ambition was superseded by evaluation of the fundamental mechanism with which the larynx functions.

Apart from measuring and recording the morphologic and histologic features of many species of mammalian larynges unknown to most anatomists, it has been difficult to construct a clearly defined program. Only when a large, representative number of specific specimens become available is it possible to carry out reliable comparative research. Eutherian mammals are divided into ten orders, but these are based on specific morphologic characteristics that bear little or no relationship to physiologic behavior or ecologic separation. Both the 2.5-kg

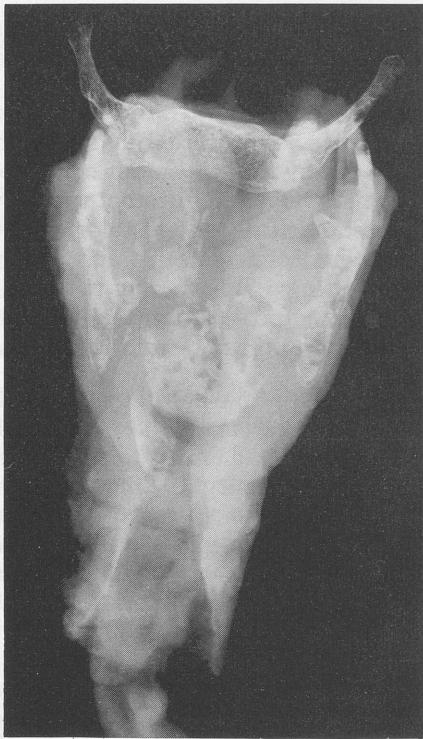


Fig 1. Radiograph of adult gorilla larynx.

mouse deer (*Tragulus javanicus*) and the 3,000-kg hippopotamus (*Hippopotamus amphibius*) belong to the order Artiodactyla but have little else in common. It has been necessary therefore to obtain additional information, largely from field studies of life history and natural behavior to supplement anatomic studies so that specimens are grouped realistically for analysis. This is clearly of importance in studies of the means whereby all young mammals avoid inhalation of milk when feeding, irrespective of their eating habits when mature. It is of paramount importance when analyzing the influence of laryngeal and tracheal size on maximum running speed,⁷ and it is then that the paucity of reliable behavior pattern data is appreciated. What better occasion than the 12th lecture in memory of that superb laryngologist with a most enquiring mind, Daniel Baker, to present a more comprehensive and scientific assessment of Negus's *The Mechanisms of the Larynx*.³ Unfortunately this is not possible, but I can offer a resume of the work carried out to date that encompasses the detailed analysis of certain specific problems, comprehensive research into one specific topic, and an overview of a major morpho-physiologic problem.

Ossification Within Primate Larynx.⁸ Despite considerable variations in size, behavior, vocal expression, and habitat, members of the order Primate have much in common. During the process of examining primate larynges, variations in ossification of the laryngeal cartilages were noticed on both radiologic examination and histologic section. Comparisons of the pattern of ossification in 145 serially

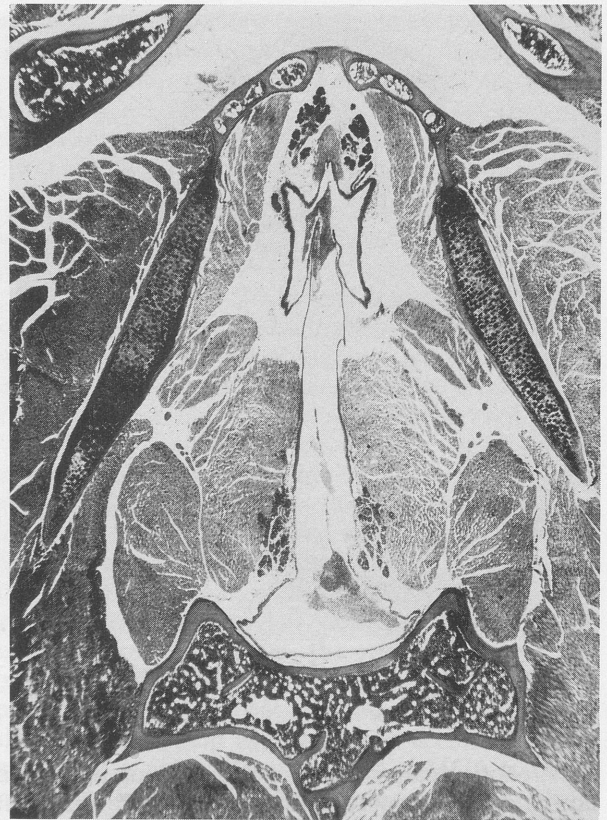


Fig 2. Transverse section of *Noctilio leporinus* larynx showing ossification of anterior portion of thyroid lamina and body of cricoid (original x20).

sectioned human larynges with 29 nonhominid primates, supplemented by radiographic assessment of 341 larynges, showed considerable similarity (Fig 1).

Although ossification of the hyoid was seen in some juveniles, it was never present in other laryngeal cartilages except in adults (the bat larynx is usually completely ossified, even in the immature animal) (Fig 2). It was concluded that as with humans, sites of ossification are related to areas of increased tension.

Biomechanics of Giraffe Larynx With Reference to Fiber-Size Frequency in Recurrent Laryngeal Nerves.^{9,10} The acquisition of a number of giraffe (*Giraffa camelopardus*) larynges together with the trachea provided an opportunity for investigating the intrinsic problems of vocalization in an animal that possesses an inordinate volume of tracheal dead space and a recurrent laryngeal nerve 2.5 m long. The volume of the dead space is approximately nine times and lung capacity eight times that of humans, with a tidal volume of between 2.7 and 4.1 L. However, this animal has evolved a variety of mechanisms for maintenance of alveolar ventilation with expiration assisted when running by diminution of the tracheal lumen by concentration of a posterior muscle (Fig 3), as in the horse. The near absence of sound production, except when calving or attacked, is probably related to low rates of air flow. How-

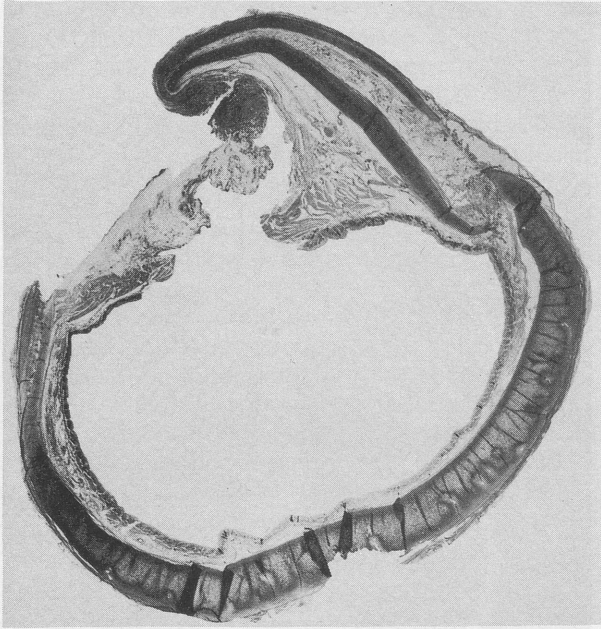


Fig 3. Transverse section of *Giraffa camelopardus* trachea showing involuntary muscle lying posteriorly between arms of cartilaginous ring.

ever, captive calves bellow when seeking milk, and adults have a repertoire of sounds little different from other ungulates. There is no reason for disbelieving that the motion of the vocal cords is asymmetrical despite a possible difference in length of 30 cm between the recurrent laryngeal nerves. This variation is present in all mammals and measurement of fiber-size frequencies using an Optomax Image Analyzer system with computer backup shows this difference to be associated with a greater preponderance of large fast-conducting fibers in the longer recurrent nerve. In some mammals, such as the giraffe, the recurrent laryngeal nerves carry

only motor fibers, sensory impulses being carried in a smaller, closely associated pararecurrent nerve.

Functional Anatomy of Immature Mammalian Larynx. One of the most exciting studies has been that carried out by Pracy¹¹ on our collection of immature larynges. Over 50 different species were examined morphologically and histologically to determine: 1) differences in relative and absolute size; 2) gross morphology; 3) variations in glandular content and activity; and 4) differences in relative size, shape, and structural importance of the cartilages.

A previous study of the morphologic and histologic anatomy of the larynx in the human infant had revealed important and unsuspected differences between it and the adult organ. Since all young mammals feed on milk for a period in their immediate extrauterine life, it was likely that identifiable differences existed between mature and immature larynges in other species of mammals.

Differences in size and gross morphology are most obvious on visual evidence, confirming the greatest change when the diet of the mature animal is composed of liquid with a bolus of solid food. The most striking difference is seen in the lion, where the cub's larynx looks more like that of a primate or herbivore. In the mature animal the arytenoids are relatively low with no lateral arytenoepiglottic folds (Fig 4). Indeed, the most obvious variations seen between adult and infant larynges lie in the lateral region of the larynx. High lateral folds are needed for the safe, and often rapid, injection of milk. These disappear when the diet is carnivorous. Measurements of the ratio between the height of the arytenoid complex relative to the height of the cricoid lamina were made in 70 larynges. These were carried out using calipers or by projections from histo-

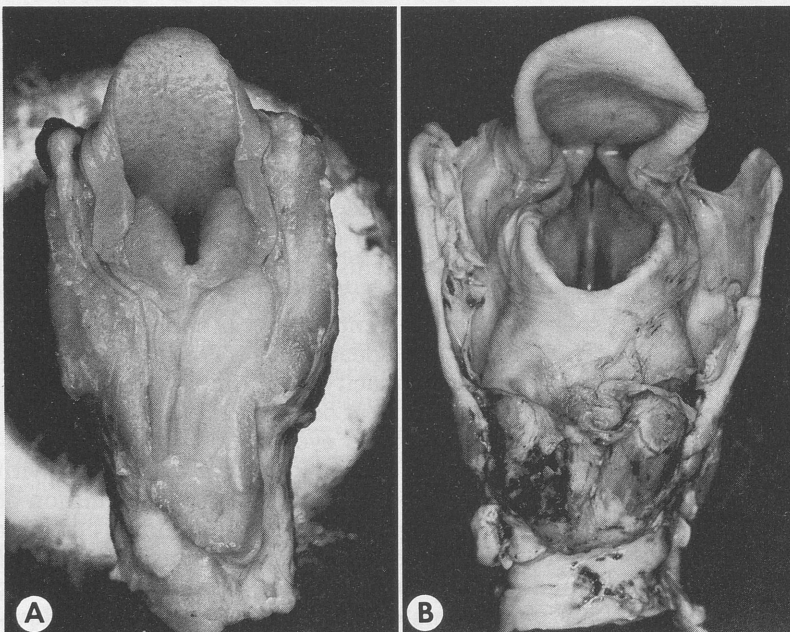


Fig 4. Lion larynges. A) Cub larynx showing upright epiglottis with lateral edges curled around arytenoids to create lateral food channels. B) Adult larynx showing epiglottis overhanging glottis with no aryepiglottic folds.

TABLE 2. RATIO BETWEEN HEIGHT OF CRICOID LAMINA AND HEIGHT OF ARYTENOIDS

Order	Adult Mean (cm)	Immature Mean (cm)
Carnivora	0.46	0.56
Primates	0.93	0.99
Perissodactyla	0.94	1.24
Artiodactyla	0.85	0.91

logic sections. These figures confirmed that diet was associated with a definite ratio range, the order Carnivora having the lowest posterior walls and Perissodactyla the largest (Table 2).

In most immature animals the mucosa covering the arytenoids is swollen by large quantities of secreting submucosal mucous glands. Support for the supraglottis is provided in some species by glandular enlargement, although unfortunately distribution is variable between orders and individual species. The use of "gland maps" (Fig 5) indicates that substantial support to the supraglottis can be provided by engorgement of mucous glands, although distribution is variable and the purpose of this secretion uncertain. However, many problems relating to fine structure and function of the immature larynx remain unsolved. Research is continuing on variations in the epithelial covering purpose of glandular secretion and the mechanism of drinking.

Scaling in Relation to Laryngotracheal Morphology. Fink¹² suggested that mammalian larynges display many adaptive innovations not possessed by other classes of animals, the larynx being the primary control mechanism for metabolic oxidative pathways. Variations in maximum glottic aperture (MGA) might therefore influence oxygen availability. The importance of maximal aerobic capacity for survival in terms of a prey-predator relationship emphasizes the significance of maximal rather than basal metabolic rates. Seeherman in 1981¹³ found that maximum aerobic capacity scaled with body mass in a manner not significantly different from basal metabolic rate, with an exponent of 0.75. Scaling of other parameters suggested that for animals of increasing body size there is a corresponding

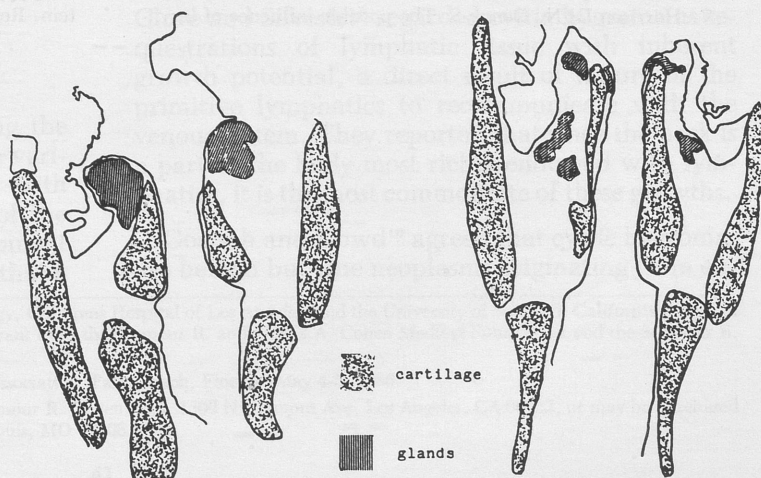
increase in respiratory structures over and above that which might be needed for normal aerobic capacity. Although many complex factors are implicated in the control of animal locomotion, the glottic aperture may well be the ultimate limiting factor to increasing air flow and oxygen uptake.

Measurements made from a large number and wide variety of mammalian larynges and tracheas available in my collection have been used to investigate the scaling of MGA, tracheal cross section, and maximum running speed with body mass. Initial results⁷ using vocal cords abducted manually took no account of joint and muscular fixation therapy, introducing an error that reduced glottic area. Further measurements have been made on larynges where all muscular attachments have been dissected free from the arytenoids, representing maximal anatomic airway rather than the physiologic state. While accepting that intrinsic errors exist in the measurement of maximum physiologic glottic airway, tracheal cross section, dead body weight, and maximum running speed, the results of linear regression analysis of these parameters for species grouped according to natural behavior patterns implies that maximum running speed is closely correlated with a proportional scaling of MGA to body mass. For MGA against body mass, the most likely exponent is 0.67 (an isometric scaling), and MGA against tracheal area confirmed an exponent of 1.33.

Although in general the available data confirm certain basic principles and expectations, considerable anomalies exist. It is surprising that many carnivores, which might be expected to have a relatively poor maximal aerobic capacity, have relatively large maximum glottic and tracheal areas. Some antelopes, on the other hand, appear to have proportionally smaller maximum glottic and tracheal areas for their body size. No simple explanation or correlation exists to explain the considerable variations in morphology that are seen between mammals of varying orders and families, and research continues.

Cricothyroid Muscle, Air Sacs, and Glands. Lit-

Fig 5. Schematic maps of hutias showing distribution of mucus-secreting glands (original x12). Left — infant, right — adult.



tle attention has been paid to the considerable variation in size, attachment, and relationship of the cricopharyngeus and inferior constrictor musculature in mammals of varying vocalization and dietary habits. Dissections provide considerable data, which will require analysis, for once again the relationship is not immediately obvious.

Histologic sectioning of specimens provides a three-dimensional concept of structures such as air sacs and secreting glands. Variations in size, situation, and function cannot be correlated with either species or natural behavior, although some rational explanation is to be expected.

CONCLUSIONS

Animals are not usually isometric even when organized on similar patterns. Instead, certain proportions change in a regular fashion. Such nonisometric scaling is often called allometry (from the Greek *allos*, meaning "different") and can be described as differences in proportions correlated with changes in absolute magnitude of the total organism. Many morphologic and physiologic variations will scale relative to body size conforming to a general allometric equation. Such mathematic expressions, although summarizing trends in available data, are no substitute for logical explanation. Indeed, biological measurements incorporate certain degrees of

variability stemming from experimental technique and the state of the animal. Variability on an absolute scale is less for smaller animals than for larger animals, but because body mass ranges over several orders of magnitude, even a 25% error in true mass will have only a minimal effect on the overall relationship.

The design of the respiratory system, in which the larynx plays such a vital role, is probably adapted to maximum challenge, not minimum demand. It would be expected, therefore, that the system would scale in proportion to oxygen requirements, particularly at maximum running speeds. Quadrupeds use a wide range of running gaits in relation to speed depending upon size. At high speeds nearly all gaits are about equally economical regarding energy lost, and therefore a meaningful relationship should exist between MGA and other morphologic characteristics of the respiratory system.

Negus's explanation of the mechanism by which the larynx functions was, not surprisingly, oversimplistic. However, three-dimensional studies and morphologic measurements of a wide range of mammals have served to emphasize the variability and complexity of function that exists within this fascinating organ. Further study will, I hope, offer some explanation for the structural differences which exist and relate them to the functional requirements of each species.

REFERENCES

1. Medical Times. 1844; 10:350-1.
2. Rupke N. Richard Owen's Hunterian lectures on comparative anatomy and physiology, 1837-1855. *Med Hist* 1985; 29: 237-58.
3. Negus VE. The mechanisms of the larynx. London: Heinemann, 1929.
4. Taylor CR, Weibel ER. Design of the mammalian respiratory system. I. Problem and strategy. *Respir Physiol* 1981; 44: 1-10.
5. Harrison DFN. A long-term comparative study of the mammalian larynx based on whole organ serial sectioning. *Acta Otolaryngol (Stockh)* 1976; 81:167-72.
6. Tucker G. Some clinical influences from the study of serial laryngeal sections. *Laryngoscope* 1963; 73:728-48.
7. Harrison DFN, Denny S. The possible influence of laryngeal and tracheal size on the running speed of animals. *Acta Otolaryngol (Stockh)* 1985; 99:229-35.
8. Harrison DFN, Denny S. Ossification within the primate larynx. *Acta Otolaryngol (Stockh)* 1983; 95:440-6.
9. Harrison DFN. Biomechanics of the giraffe larynx and trachea. *Acta Otolaryngol (Stockh)* 1980; 89:258-64.
10. Harrison DFN. Fibre size frequency in the recurrent laryngeal nerves of man and giraffe. *Acta Otolaryngol (Stockh)* 1981; 91:383-9.
11. Pracy R. The functional anatomy of the immature mammalian larynx [Thesis]. University of London, 1984.
12. Fink BR. Folding mechanism of the human larynx. *Acta Otolaryngol (Stockh)* 1974; 78:124-8.
13. Seeherman HJ. Design of the mammalian respiratory system. *Respir Physiol* 1981; 44:61-86.

LYMPHANGIOMAS OF THE LARYNX IN INFANTS AND CHILDREN

A SURVEY OF PEDIATRIC LYMPHANGIOMA

SEYMOUR R. COHEN, MD

JEROME W. THOMPSON, MD

LOS ANGELES, CALIFORNIA

Lymphangiomas are uncommon benign congenital lymphatic tumors of childhood. They are found in all parts of the body structure, but rarely occur in the larynx. This paper reviews charts of 160 patients with cystic hygroma (lymphangiomata) of whom ten had extensive involvement of the larynx. A benign but nevertheless challenging tumor, its treatment demands the patience and skill of the surgeon. The lesion is more common in the white patient, and 40% appear in the newborn. Fifty percent present by the end of the first year of life, and 75% by the end of the second. The onset is uncommon in the older child and a rare occurrence in the adult. The treatment of lymphangiomata is surgical excision, and is more difficult when in the larynx. Laser surgery has been most helpful when the lesion is in the laryngeal complex. Considering the extreme difficulties which lymphangioma present to the child and to the physician, the ultimate results of all forms of conservative surgical therapy can be rewarding. Excessive or radical surgery will not necessarily guarantee complete elimination of disease and may be harmful.

KEY WORDS — benign tumor of lymphatics, hygroma, laryngeal lymphangioma, lymphangioma, lymphatic tumor.

INTRODUCTION

Lymphangiomas are uncommon congenital benign malformations of the lymphatic system. They are considered clinically as tumors. However, pathologically they are defined by some authors as vasodilatory defects or hamartomas. Lymphangiomas rarely occur in the larynxes of infants and children. This study covers a period of 30 years and includes all available documented charts of 160 patients with the diagnosis of lymphangioma, cavernous lymphangioma, and cystic hygroma. We present an overview of cystic hygromas in children and report ten patients with extensive involvement of the larynx, the histopathology of the disease, forms of treatment, and complications. The endoscopic findings are documented and a differential diagnosis is outlined.

For the purpose of this study, lymphangioma and cystic hygroma will be used synonymously since most of the patients had more than one stage of the lymphangiomatous malformation. The paper reviews the literature and embryology, and gives the symptomatology, anatomic sites, and the differential diagnosis of the tumor.

LITERATURE REVIEW

A literature review is valuable in outlining the origin and development of the tumor and the various methods of treating the disease. It is with Sabin's^{1,2} monumental works on the origin of the lymphatic system from veins and the development of the lymph hearts and thoracic duct in pigs that a

better understanding of the embryology of the lymphatics was developed. With these scientific publications, the origin of congenital abnormalities of the lymphatic system could be better understood. Cystic hygroma, first identified by Wernher³ in 1843, was described as a tumor occurring in the head and neck with a predilection for certain sites in the body. Von Rokitsky⁴ was of the opinion that the lesion is due to an accumulation of serous fluid in the fetus and is limited by tissue spaces. Luschka⁵ suggested that it is a cystic outgrowth of the internal carotid gland. Virchow⁶ promoted Wernher's opinion, and it became generally accepted that lymphangiomas are tumor formations. It was Koester⁷ who demonstrated endothelial linings in the cyst by injecting silver solution, and was the first to use the term lymphangioma. Goetsch⁸ in 1938 demonstrated sprouts of endothelial tissue extending from the cyst wall engulfing nerves, muscle fibers, and blood vessels causing atrophy, fibrosis, and hyalinization of the engulfed tissue. He reported seeing two patients 38 and 34 years of age with hygromas and indicated that these tumors are more common in females and in white patients. McClure and Silvester⁹ regarded cystic hygroma as sequestrations of lymphatic tissue with inherent growth potential, a direct result of failure of the primitive lymphatics to recommunicate with the venous system. They reported that since the neck is a part of the body most richly endowed with lymphatics, it is the most common site of these growths.

Goetsch and Dowd¹⁰ agreed that cystic hygromas are benign but true neoplasms originating from en-

From the Department of Surgery, Division of Otolaryngology, Childrens Hospital of Los Angeles, and the University of Southern California School of Medicine, Los Angeles. This publication was funded by a grant from the Seymour R. and Odelia A. Cohen Medical Foundation and the Seymour R. Cohen Otolaryngology Fund.

Presented at the meeting of the American Laryngological Association, Palm Beach, Florida, May 4-5, 1986.

Additional copies of this publication are available from Seymour R. Cohen, MD, 1300 N Vermont Ave, Los Angeles, CA 90027, or may be purchased from Annals Publishing Company, 4507 Laclede Ave, St Louis, MO 63108.

dothelial sprouts. They reported that the individual tissue unit such as a muscle fiber may be isolated, surrounded, and destroyed, and may undergo hydropic and fatty degeneration. Small droplets of fat appear within the muscle fiber when this occurs; in groups of fibers distinct areas of adipose tissue commonly are seen in the walls of larger cysts and in adjoining tissues. This resolution into fat represents a replacement of normal tissues destroyed by the hygroma. They disagreed with Thompson and Keiller¹¹ and other writers that the extension of hygroma into neighboring regions is not due to invasive power on the part of the endothelium, but is caused by cyst formation in lymphatic anlagen occupying these regions. Their studies supported the view that this tumor arises from lymphatic sequestrations of the primitive jugular sac, and that the sequestered lymphoid tissue had within it an independent power of irregular growth. Vaughn¹² reviewed 64 cases from the literature and added one of his own. He reviewed the forms of therapy such as surgery, irradiation, observation, and needle aspiration. In 1924 New¹³ reported a case which was treated with irradiation, and Figi¹⁴ at the same institution used radium in 12 of 13 cases. Furstenberg¹⁵ suggested surgical excision as being the treatment of choice. He reinforced the idea that "these lesions are exceedingly resistant to irradiation."

Gross and Goeringer¹⁶ stated that the most common site of cystic hygromas is in the posterior triangle and also the supraclavicular fossa extending over the crest of the shoulder. When anteriorly placed they may extend high just beneath the angle of the jaw. Gross and Goeringer reported 27 patients: 17 had tumors on the left and ten had them on the right. In their series 55% were present at birth, 75% appeared within the first year of life, and 90% presented by the end of the second year. The oldest patient in this study was 14 years of age. It was the opinion of Gross and Goeringer that spontaneous regression of the mass does not occur and that expectant treatment should not be applied to this tumor. They reported that surgery is essential, aspiration of the tumor can encourage infection, and injection of sclerosing agents or the use of a seton may cause uncontrollable infection. They reviewed the Mayo Clinic report of Figi¹⁴ in which 12 patients received 3,000 to 7,000 mCi of radium; seven died of sepsis, five survived, only three were cured, and two improved.

Eggston and Wolff¹⁷ in 1947 suggested that lymphangiomas be classified as telangiectatic, cavernous, or cystic. They stressed that pathologically, capillary lymphangioma is very difficult to distinguish from capillary hemangioma. Anderson¹⁸ reviewed 167 tumors of vascular origin seen between 1935 and 1951; 20 were hemangiomas and 28 were hygromas. In his survey, tumors of vascular origin formed the largest group of mesodermal tumors. Freeman¹⁹ in 1953 added eight cases to the lit-

erature and indicated that there was no evidence of recurrence despite the fact that vestiges of the tumor had not been removed. Only one patient had a two-stage operation.

Briggs et al²⁰ in 1953 reported a series of 56 patients who were seen at the Childrens Hospital of Los Angeles over a 17-year period. They found that there is no sex difference and that the lesion is rare in black patients. They stressed the benefits of antibiotic use in relieving postoperative infection and compared operative results and x-ray therapy. Of the 56 patients they reviewed, 26 had tumors in the neck and five had them in the head and face. Symptoms were usually minimal unless complications occurred. Most of the tumors grew slowly and only four had rapid growth. Two of their patients were treated with irradiation with questionable improvement; one was lost to follow-up and the second child developed an abscess that required incision and drainage. Four years later this patient died elsewhere of endarteritis obliterans of the pulmonary vessels. One death occurred 18 hours after surgery. Briggs et al suggested that remnants of remaining cysts should be opened and that this may prevent recurrences.

Childress et al²¹ reviewed the embryonic origin and 17 cases of mediastinal lymphangiomas in the literature, and added one case of their own. They felt that the cases they reviewed supported the postulate that these cysts neither retain connection with their parent vein nor enter into union with the lymphatic system.

Morfit²² in 1960 reported eight patients with lymphangioma of the tongue who were otherwise normal in all respects. The tumors appeared on the surface of the tongue and adjacent floor of the mouth with periodic episodes of ulceration and enlargement of the tongue. Involvement was too extensive to permit eradication by resection and, in all of these patients, the tumor persisted. Long-term follow-up showed a grotesque distortion of the tongue, but the tumor did not continue to grow and arrested at the completion of adolescence. These patients also had involvement of the submandibular, parotid, and submaxillary areas. Of importance in patients with tongue involvement is the therapy required to treat the open bite and poor dental hygiene.

According to Meyerson,²³ the first accurate description of the terminal lymphatic vessels of the mucous membrane of the larynx was given by Teichman in 1871 who stated that the lymphatic system of the larynx is better developed in infants and young children who present with a greater number of channels and lymph nodes than in the adult. The lymphatic network of the larynx is well developed except along the free borders of the true vocal cords, the inferior aspect of the epiglottis, and the thyroepiglottic ligament. The lymphatics are densest where the mucous membrane is thickest. The supra-

glottic area consists of four to six channels which unite into a pedicle near the anterior part of the aryepiglottic fold of each side and then cross to folds in the corresponding lateral aspect of the epiglottis. Lymphangiomas, he stated, are extremely rare, but may vary in size from a millet seed to a large walnut. They occur in the epiglottis, aryepiglottic folds, and arytenoids. He cautioned that "biopsy may cause a flow of lymph which may last for many days."

Bill and Summer²⁴ in 1965 suggested that lymphangiomas and cystic hygromas are varying degrees of the same lesion. In a group of 61 patients, 25 tumors were in the neck, 35 were in the head, and one was in the larynx. Among the head tumors were eight in the tongue, seven in the cheeks, seven in the floor of the mouth, five in the parotid, two in the lip, and two in the nose. Of 3,000 new admissions to the Children's Orthopedic Hospital in Seattle, only five new patients with cystic hygroma were admitted per year. No instance of spontaneous regression occurred, but one patient with airway obstruction without a tracheotomy died. There were three deaths in this series. These authors disagreed with Goetsch⁸ in saying that in none of their series was there an impression of actively infiltrating surrounding tissue. Superficial blebs were noted in the skin of the trunk and abdomen and were especially prominent in the tongue. With tongue involvement there was associated prognathism and malformation of the jaws. Bill and Summer suggested that in the extremities amputation may become necessary.

Barnhart and Brown²⁵ in 1967 reported a 2-day-old newborn with a giant lesion of the right side of the face, neck, base of the tongue, and left neck who required a tracheotomy. Tongue swelling was treated with cautery, but there was no follow-up to this therapy: whether the larynx was involved is unknown. Proctor and Proctor²⁶ felt that the only acceptable method of treatment of lymphangiomatous lesions is surgery. They claimed that complete removal is not as essential as with branchial cleft cysts because recurrences are not as likely if all grossly abnormal tissue is removed. Ward et al²⁷ suggested that cystic hygroma is a variable lesion with rapid growth, slow enlargement, or intermittent growth; it becomes inactive or may undergo spontaneous regression. They felt that total extirpation is preferred, but if impossible to accomplish, the residual cysts should be opened as advised by Briggs and associates.²⁰ Ward et al²⁷ reported six cases with one mortality. One patient required a tracheotomy until he was 12 years of age. The status of the larynges of their patients is unknown.

Johner²⁸ reviewed the lymphatics of the larynx and recorded that much of the knowledge of the lymphatics of the head and neck is derived from the classic study by Rouviere in 1938.²⁹ Johner stated that if the lymphatic system is indeed derived from the venous system, there is no specific evidence to

prove distinct embryologic compartmentalization of the supraglottic and the subglottic lymphatics. Ruben et al³⁰ in 1975 reported a 20-month-old infant with a cystic lesion in the valleculae which filled the preepiglottic space. The lesion was aspirated and removed endoscopically but recurred 14 months later. It was removed again and had not recurred when the child was seen 5 years later. Histologically, the cyst was covered with stratified squamous epithelium, had several cystically dilated vascular channels within the specimen, and was considered a lymphangioma. Hebert et al³¹ in 1975, in a report on vascular tumors of the salivary glands in children, suggested that finding a calcification in the mass, particularly in a female, is diagnostic of a hemangioma, since lymphangiomas do not calcify.

Saijo et al³² reported that lymphangiomas have not been established as malformations, benign neoplasms, or hamartomas. They reported 177 patients with lymphangiomata, 164 confirmed by biopsy, who were seen between 1927 and 1964. Intra-abdominal lesions were not included. Fifty-six percent of the patients were male and 44% were female. One tumor invaded bone. Ninety-two percent of the patients were treated surgically, 4% were treated by aspiration, three were treated by irradiation, and eight had no treatment. Six patients died, three of postoperative complications, one with multiple congenital defects, one with hyaline membrane disease, one with enterocolitis, and one with multiple lymphangiomatosis. None of these patients had laryngeal involvement or malignancies. Those patients without therapy had residual asymmetry; one was followed-up until 10 years of age, another until 19 years of age. However, there was no tissue biopsy performed in either of these patients. Saijo et al stressed that mutilation may be avoided by repeated planned excision rather than extensive surgery, particularly in the facial area.

Jones et al³³ in 1976 reviewed benign tumors in the infant and child and reported that angiomas rarely cause any diagnostic difficulties and that lymphangiomas of the parotid are less common than hemangiomas. Levin et al³⁴ reported 121 lymphangiomas of the alveolar ridge occurring in 58 newborn infants. They described them as blue-domed fluid-filled lesions on the posterior crest of the maxillary and on the posterior lingual surface of the mandibular ridges. None were found in white neonates. The lesions were usually multiple and bilateral. During biopsy, fluid escaped and the lesion collapsed and might disappear during the trauma of eating or during tooth eruption. Surgical removal could be unnecessary. Schuller and McCabe³⁵ reviewed 587 noninvasive salivary gland neoplasms during the years 1938 to 1975. Only 19 or 3.2% of these tumors occurred in patients 16 years or younger. Approximately 60% of the benign tumors in this series were of vascular origin. There was a slight prevalence of lymphangiomas in this series, whereas

in other reports, hemangiomas are said to be the most common vascular tumor affecting the salivary glands. Jones et al,³⁶ in a symposium on benign neoplasms of the larynx, stated that lymphangiomas are rare and that the literature is sparse regarding this disease. They quoted El-Serafy³⁷ who reported a single case of an isolated intrinsic lymphangioma of the larynx in 1971 but they could find no reported cases of a similar lesion.

Holinger et al³⁸ considered lymphangioma to be a vascular anomaly and not a true neoplasm, and reported seeing six cases of laryngeal lymphangiomas in a series of 806 congenital abnormalities of the larynx. They felt the lesion represents an extension of a cystic hygroma from the neck and recorded a single case of cystic hygroma extending from the neck into the larynx. The infant required a tracheotomy at 7 days of age and had undergone a variety of procedures prior to being treated by the authors. A supraglottic laryngectomy was performed at age 14, but airway obstruction persisted and required two other endoscopic excisions prior to eventual decannulation. They reported two other men, 53 and 67 years of age, with isolated intrinsic laryngeal lymphangiomas. The tumors were pedunculated and were removed endoscopically. Both patients died from other causes and there was no evidence of tumor of the larynx after 9 months and 10 years, respectively. Nothing was found in the literature review which gave detailed studies of laryngeal lymphangiomata in childhood.

EMBRYOLOGY

Lymphangioma is caused by an abnormality of lymphatic development. The origin of the tumor is probably similar to that suggested for tumors composed of blood vessels. Ewing³⁹ proposed that the hemangioma is an anomaly of development of vascular segments which retain embryonal characteristics and do not fit into the circulatory system. Ribbert⁴⁰ studied the origin of simple angiomas and observed that the tumor develops and grows in a part of the blood vessel wall. There is a proliferation of newly formed blood vessels that invade the neighboring tissues but never connect with a normal blood vessel.

It is assumed that isolated lymph vessels take on neoplastic behavior and slowly proliferate, forming a network of new lymph channels, and like hemangiomas, never communicate with major lymph channels. The congenital lymphangiomas may be found in many parts of the body both superficial and deep. Sabin¹ confirmed that the lymphatic system is derived from veins and is of a vascular rather than mesenchymal origin. This countered the previously accepted theory⁴ that the system developed within mesenchymal spaces and serous cavities. Sabin's studies on the pig embryo revealed that the early lymphatic system starts from certain centers

and spreads gradually over the surface of the body. The first area is in the neck from which vessels grow over the head, shoulder, and neck. The second area is over the crest of the ilium from which vessels grow over the back and hip. Subsequent centers form the axilla and inguinal region from which vessels grow over the ventral aspects of the body wall and limbs.¹

The primary anlage of the lymphatic system is the bilateral and symmetrical jugular sac. The anlage is formed by small veins opening into the jugular vein that coalesce, are cut off from the vein, and thus form a sac entirely free from the vein for a time. The sac later rejoins the vein. The endothelial lining of the sac is derived from the endothelium of the veins.¹

In some mammals the lymphatic system starts as a series of sacs of which eight have been described. Three are paired: the jugular, subclavian, and posterior lymphatic sacs; and two are unpaired sacs: the retroperitoneal and cisterna chyli. In the human there are only six, since the subclavian sacs are really extensions of the jugular sacs. The mammalian sacs develop as a simple lining of endothelium and do not develop any muscle in their walls. The fate of the sacs is to become completely transformed into a group of lymph nodes, except for a cisterna chyli. The great primary groups of lymph nodes for each region, through which lymph must pass before entering the veins, originate in the lymph sacs. In the 80-mm embryo, the lymphatic system is similar to that of the adult, the primitive system is complete, and the sacs form the primary lymph nodes. The peripheral vessels extend to the skin and to the viscera and secondary nodes form along these vessels. Connection of the various sacs occurs by means of a cisterna chyli and thoracic duct.¹

PATIENT INFORMATION

STATISTICAL ANALYSIS

Of the 160 patients in this study, 90 were male and 70 were female. One hundred twenty-seven (79%) were white, 27 (16%) were black, and six (4%) were Oriental. The age at onset of symptoms and presentation of the tumor was the newborn period in 39.5%, by the age of 6 months in 51%, by the end of the first year in 57.5%, and by the end of the second year in 75%. Eighty-five percent appeared by the end of the fifth year, and over the next 12 years, 98% of the patients had documentation of the tumor. The oldest patient was 17 years of age, and three patients had no documentation of the onset of their symptoms or the appearance of the tumor.

Ten patients required tracheotomies to support airway obstruction. In nine of these patients laryngeal lymphangiomas were present that made tracheotomies mandatory. One patient with a lymphangioma of the tongue in whom the larynx was

normal was tracheotomized to support airway obstruction produced by the huge tongue filling the mouth and oropharynx. Two patients with postoperative obstruction caused by giant swelling of the tongue were treated with tongue sutures until the swelling subsided.

Three of the children in this study were one of twins. The site of their lesions varied and included almost every part of the body. The other twin in each case was perfectly normal without evidence of any lymphangiomas or cutaneous lesions. Five patients who had oral and/or laryngeal lymphangiomas required gastrostomies. Five patients with neck involvement had extensions into the mediastinum. Interesting were the associated findings of skin lesions in patients who had cystic hygromas, a fact that misled the examiner as to the true diagnosis. In one patient, the skin over the mass lesion had a hairy nevus, in another there was telangiectasis; three patients had port-wine stains, another had melanin deposits, and another had papilloma of the skin over the area of the lymphangioma. The color of the tumor varied. While in most of the patients the skin color was normal, a bluish or even hemorrhagic color was seen in 14 patients. This sometimes confused the diagnostician and caused the diagnosis of a hemangioma to be made. Infection in the lesion, either preoperative or postoperative, occurred in 15 patients, suggesting vulnerability to infection. Of this number, five patients had serious infection requiring prolonged antibiotic therapy. Tracheal and esophageal deviation occurred in five patients, but actual invasion of either of these two structures did not occur. All of the children were normal except one who had developmental delay following meningitis unrelated to his hygroma. While frequently described as a painless progressive swelling, the hygroma produced painful mass lesions for ten of the patients in this series. This condition was unrelated to trauma or infection within the hygroma. Whether compression of nerve elements accounted for the discomfort could not be determined.

SYMPTOMATOLOGY

Many of the patients had no symptoms except for the appearance of a slowly or rapidly enlarging mass. The mass was localized, single or multiloculated, and frequently it spread in an undefined fashion. Rapid growth or discoloration of the tumor created great concern to the physician and parents.

Symptoms varied with the site of the lesion. In the larynx, the two major symptoms were airway obstruction and voice change. Dysphagia was especially noted when the tongue, floor of the mouth, and larynx were involved. Occasionally, drooling and oral bleeding occurred. Involvement of the floor of the mouth with change of position of the tongue caused difficulties with feeding. When infection occurred within the tumor, it was frequently preceded by an upper respiratory infection, and

growth of the lesion was rapid. Speech difficulties were present in patients with floor of the mouth and tongue involvement. Dental malocclusions occurred in many of these patients requiring therapy after the oral tumor was controlled. Some patients had tenderness and pain, especially those with tumors of the extremities and shoulder. Cough, fever, wheezing, and chest pain were not uncommon in patients with mediastinal involvement. In one infant with a chest wall hygroma, dyspnea was prominent. When the abdomen was involved, a palpable mass, anemia, tachypnea, vomiting, diarrhea, cramps, pain, and anorexia initiated a search for a cause. In general, symptoms were nonspecific and related to the site of the lesion. The most important symptom was the appearance or palpation of a mass lesion.

SITES OF INVOLVEMENT

The most common site of lymphangioma was in the head and neck and occurred in 73 of the patients (45%). Few parts of the body were immune to primary or secondary involvement by the tumor. The upper and lower extremities were the next most common areas of involvement, and when the lesion extended into the terminal portions of the extremities such as the fingers, surgery was complex and recurrences were frequent. Of the 87 patients (55%) with cystic hygroma in parts of the body other than the head and neck, 37 were on the right side, 48 were on the left, and two were in the middle area. The site and side of the cystic hygromas of the head and neck are listed in the Table; it will be noted that in the neck there is a slight preponderance of right lesions.

It was uncommon to find isolated multiple lymphangiomata in this group of patients. However, five patients had two areas of involvement: one had abdominal and thigh involvement; another had a mass in the right cheek and tip of the tongue; another had a flank lesion and mass in the inguinal and scrotal area; one had a thigh and right lower quadrant abdominal tumor mass; and the fifth had both neck and mediastinal involvement. In the latter patient, the neck mass had been removed in the neonatal period and the mediastinal mass required removal at 3½ years of age.

ASSOCIATED ANOMALIES

Associated anomalies or defects were also uncommon and included congenital glaucoma, ventriculo-septal defect, Klippel-Trenaunay syndrome, aneurysm of the common iliac artery, hydrocele, pyloric stenosis, and neurofibroma of the scalp.

REVIEW OF PATIENTS

REPORTS

Patient 1. An 11-month-old black male was admitted to our hospital on Dec 7, 1981, after transfer from another hospital with the diagnosis of *Hemophilus influenzae* meningitis. The patient had had a resection of a cervicofacial hygroma and post-

SITES OF CYSTIC HYGROMAS IN HEAD AND NECK

Site	Number
Neck	60
R	30
L	21
Bilateral	9
Larynx	10
Parotid	2
Orbit	1
Face	3
R	2
L	1
Lip, midline	1
Cheek	2
R	1
L	1
Preauricular, R	2
Mouth and tongue	3
Tongue and floor of mouth	4
Neck, tongue, and mouth	4
Neck, mouth, tongue, and larynx	8
Neck and larynx	2

operatively had developed the complication of paralysis of the seventh, ninth, and tenth cranial nerves. On admission, the infant was acutely ill, showed evidence of developmental delay, and had otitic meningitis. Airway obstruction and feeding difficulties were prominent. There was residual lymphangioma on the right neck within the submandibular area with involvement of the right side of the floor of the mouth. An x-ray study of the chest revealed a right upper lobe mass with surrounding atelectasis. A computed tomographic scan of the head showed dilated ventricles. Because of airway problems, endoscopic examination and a tracheotomy were required, and a right extensive simple mastoidectomy was performed. The right arytenoid was extremely large, pale, and edematous, and protruded into the endolarynx. Exposure was difficult and the true vocal cords and tracheobronchial tree were normal. Direct laryngoscopy revealed the base of the tongue and right lateral pharyngeal wall to be extensively involved by a cystic hygroma. The mass lesion filled the valleculae and pushed the right aryepiglottic fold and right arytenoid into the endolarynx. The subglottic area was normal. A feeding gastrostomy was performed and the patient's progress was satisfactory.

On March 24, 1982, direct laryngoscopy showed the hygroma in the supraglottic area, and the right true vocal cord was paralyzed in the paramedian position. The airway was adequate and the child was decannulated. He was discharged on March 31. Following his discharge he had multiple admissions for pneumonia, suture granuloma removal from the neck, and periorbital cellulitis, and was noted to have a moderate residual right submandibular hygroma. His larynx was not reexamined on subsequent admissions, but there was no documented

evidence of airway obstruction. His last admission on April 18, 1985, was for recurrent swelling in the right neck, fever, and dysphagia. Examination revealed a 4 x 5-cm mass in the submandibular area. The swelling was tender and firm, and in addition to this finding, a right preauricular swelling was present. An x-ray study of the neck showed enlargement of the epiglottis and a soft tissue mass in the neck. He was treated for epiglottitis with methicillin sodium and chloramphenicol. Observation continued for about 5 days, and after ensuring that feedings were taken well, he was discharged on dicloxacillin sodium. An ear, nose, and throat consultation was not obtained. It is of interest that this child was suspected of having epiglottitis and was treated as such in spite of his past history of supraglottic lymphangioma. The lateral x-ray study was consistent with the original findings on direct laryngoscopy in 1982. His fever and dysphagia were due to infection in the residual cystic hygroma in the right neck. Further follow-up after discharge on April 18, 1985, was not available.

Patient 2. An 8-year-old white male was seen in consultation and was admitted to our hospital on July 22, 1980. The chief complaint was a tight throat and increasing respiratory difficulty, and he was referred for evaluation of the airway problem. His past history was significant in that he had had 11 or 12 operations at a northeastern medical center and two more surgical procedures on the west coast. He was born with a cervical, submental, and tongue hygroma. Examination on admission showed a large, soft, nontender swelling over the chin, submental area, and the jaw. The tongue was covered with papillary cystlike projections typical of lymphangiomatous lesions. Some of the projections from the tongue had a hemangiomatous appearance. The tongue was bound down to the floor of the mouth and there were multiple scars in the neck from past surgical procedures. There was residual tumor within the mandibular area and face. His laboratory findings were normal. Direct laryngoscopy revealed a large, pale, and smooth mass arising from the right vallecula and base of the tongue. The lingual surface of the epiglottis was also involved, and the swelling extended down the aryepiglottic folds on both sides. The mass filled two thirds of the oropharynx. When the cystic mass was elevated and pushed laterally, the larynx and subglottic space were seen to be normal. Under general jet anesthesia with suspension microlaryngoscopy, two thirds of the lesion was lasered and eradicated. Some residual tumor was allowed to remain so as not to fore-shorten the aryepiglottic folds. Postoperatively, the boy's airway was greatly improved and his voice was normal. He was discharged on the day after surgery but never returned for follow-up.

Patient 3. A 1-year-old white female was born with an extensive cervicofacial cystic hygroma involving the left cheek, parotid area, neck, subman-

dibular area, left mandible, floor of the mouth, tongue, and larynx. A tracheotomy had been performed to correct severe airway obstruction. Because of severe dysphagia she required a gastrostomy. She was first admitted to our hospital on March 23, 1980. Examination showed the infant to be in no distress. There was residual cystic hygroma of the left cheek, face, mandible, mouth, and tongue. She was aphonic. Her tongue was paralyzed and fixed to the posterior part of the palate. From previous surgery there was a long scar along the left side of the mandible and in the left neck. Vital signs and laboratory findings were normal. Direct laryngoscopy revealed the base of the tongue to be deformed. The left side of the tongue was heaped with cystic lesions. The valleculae were filled with hygromatous tissue that extended across the pharyngoepiglottic folds and filled the hypopharynx on each side. This narrowed the hypopharyngeal lumen. With the laryngeal speculum under the epiglottis, marked hygromatous involvement of the arytenoids, aryepiglottic folds, and false cords was viewed (Fig 1A). When these structures were separated, the true vocal cords and the subglottic area were normal. The arytenoid, particularly on the left, was redundant with hygroma that flopped medially. A fibroma was seen at the tracheotomy site. The floor of the mouth was also involved and the tonsil area on the left was indented medially by the neck mass.

The patient was taken to the operating room on March 24, 1980, and the plastic tracheotomy tube was replaced by a Holinger-type tube. Suspension microlaryngoscopy was then performed and the larynx was treated with the laser, which was applied to the left arytenoid, left vallecula, and also to the cystic mass in the lateral wall. Fluid was seen to exude from the cysts during laser surgery. The infant was discharged on the day of surgery and returned for monthly treatments with the laser. By September 9 the patient began taking oral feedings, and her gastrostomy tube was removed. By November 30 a great deal of the intralaryngeal lesion was controlled, but there was still marked involvement at the base of the tongue and arytenoids. The true vocal cords were normal and there was persistent involvement of the epiglottic area. Her last visit was on December 1 when the left vallecula and right side of the base of the tongue were treated with the laser. The findings at this last visit revealed the hygroma still to be present along the left lateral pharyngeal wall. The lesion also involved the base of the tongue, and the epiglottis was still markedly thickened and bulbous with lymphangiomatous tissue (Fig 1B). The family then moved out of the Los Angeles area and she was no longer followed up.

Patient 4. A 3-month-old white female was born with a huge cystic hygroma of the right side of the neck (Fig 2A). She was admitted to our hospital for elective surgical removal of the mass on Nov 26, 1978. Rapid growth of the tumor with increasing

airway obstruction made early surgery necessary. She was the product of a normal full term pregnancy, fed well, and was home on the third day after birth. Examination on admission showed an alert infant with an obvious right neck mass. The ear, nose, and throat examination was normal. There was a large serpiginous cystic mass over the entire right posterior triangle extending anteriorly to the midline of the neck. It was nontender, soft, compressible, and transilluminated clearly. Within the mass, multiple 2 x 2-cm firm lymph nodes were visible and palpable. Her chest, abdomen, and extremities were normal. The trachea was deviated to the left.

On November 27, excision of the large hygroma was undertaken by the pediatric surgery service. The mass was noted to compress the esophagus and trachea and was attached to the larynx. The right superior laryngeal nerve was cut at the time of surgery and was repaired under surgical microscopy. A postoperative transfusion was necessary. Direct laryngoscopy and bronchoscopy were performed, and because of airway obstruction by the tumor mass within the larynx, a tracheotomy was performed. Direct laryngoscopy showed the base of the tongue to be involved with cystic changes. The right pyriform sinus was encroached upon by tumor. The right false cord, arytenoid, and aryepiglottic folds were involved by cystic changes (Fig 2B). The arytenoids were redundant, swollen with pale, smooth enlargement, and flopped forward during inspiration. The right true vocal cord was poorly visualized because the cystic hygroma extended along the false vocal cord. The right vocal cord was limited in abduction either by paresis or paralysis. The subglottic area was normal.

On December 20, direct laryngoscopy showed the lymphangioma within the larynx and a right true vocal cord paralysis. Residual tumor was present in the neck and she was readmitted Jan 27, 1979, because of accumulation of fluid at the site of the surgery. An x-ray study of the chest revealed increased widening of the mediastinum. The neck was drained and she was discharged to be followed up as an outpatient. Monthly admissions followed, and the laryngeal tumor was treated with the laser. She was admitted June 10, and residual cystic hygroma of the neck was excised. She was discharged 3 days later. Again, monthly admissions for laser surgery to the lymphangioma of the larynx followed. On November 13, she was decannulated. Her voice and airway were excellent. At the age of 3, on July 5, 1981, she was readmitted for surgical management of the recurrent cystic hygroma at the base of the right neck. A clavicular bone deformity caused by erosion by the tumor was noted. The clavicle required surgical division in order to remove all of the mediastinal tumor. Direct laryngoscopy and bronchoscopy showed that the supraglottic larynx was normal, except for lymphangioma of

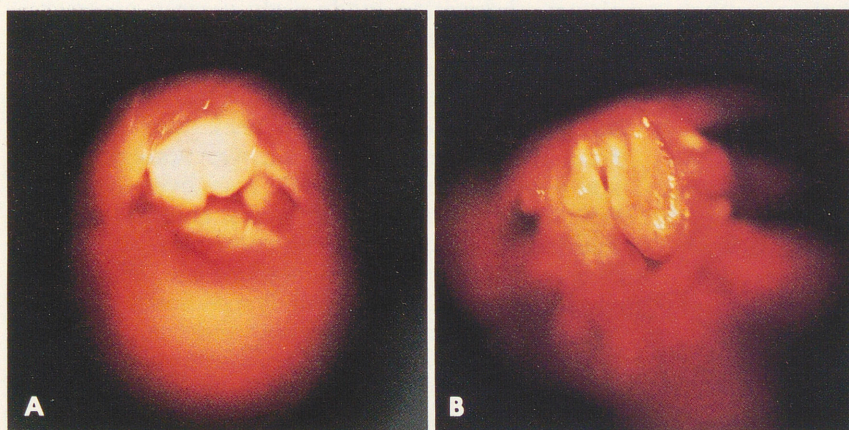


Fig 1. (Patient 3) A) Larynx before laser therapy. Epiglottis is infiltrated with hygroma and fullness of arytenoids. B) After laser therapy, residual hygroma is visible.

the right arytenoid and involvement of the posterior aspect of the right aryepiglottic fold, which was covered by remnants of lymphangioma (Fig 2C). The true vocal cords moved normally, and laryngeal sensations were normal. The girl was discharged on July 15. On Nov 23, 1982, she was admitted for closure of the tracheocutaneous fistula. Direct laryngoscopy showed slight involvement of the right arytenoid, aryepiglottic fold, and pharyngoepiglottic fold. A small area of the false cord on the right was involved with lymphangioma. She was discharged on the day after surgery and was followed up until her neck was completely healed. She is now free of symptoms and has done well.

Patient 5. A male Oriental (Korean), born in a regional hospital on Aug 21, 1976, was started on intravenous (IV) steroids on August 22, and was admitted to our hospital on August 25. He was the product of a 39-week gestation and was delivered by cesarean section. He was born with a large right posterior cervical mass, and within 3 days following his birth, he developed respiratory distress, stridor, retractions, and severe dysphagia. On admission, examination showed an infant with crowing stridor, retractions at the xiphoid process, and a large right cystic cervical mass. The mass extended from the angle of the right jaw to the clavicle and anteriorly

to the midline of the neck. There were also firm, palpable masses 2 x 3 cm in diameter within the large tumor. His respirations were grunting and there was slight asymmetry of the chest, the left side being greater than the right. The remainder of the examination was normal. Laboratory findings were all within normal limits, and multiple x-ray studies of the chest were normal except for deviation of the trachea to the left. The upper gastrointestinal x-ray studies were normal.

For the first few days, there was no increase in the size of the mass or in the airway obstruction. Direct laryngoscopy on August 26 revealed infiltration of the epiglottis (Fig 3A) with marked grapelike tumor masses rising from the laryngeal surface of the epiglottis extending down along the aryepiglottic folds and into the arytenoids and false cords (Fig 3B,C). The true vocal cords were normal and moved normally. The subglottic space was normal and the trachea was indented on the right by external compression. The mucosal lining of the trachea was normal. Involvement progressed later to include the right side of the pharynx in the region of the tonsil and the right side of the hypopharynx. Needle puncture and incision with a blade produced lymphlike fluid, but the masses did not change in size. Laryngoscopy and bronchoscopy on September 8, after 3 weeks of

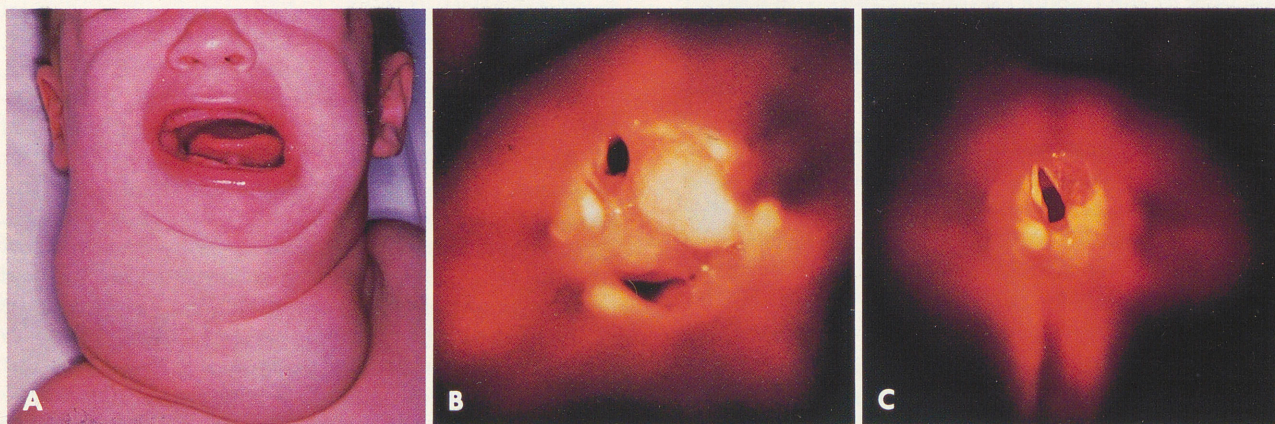
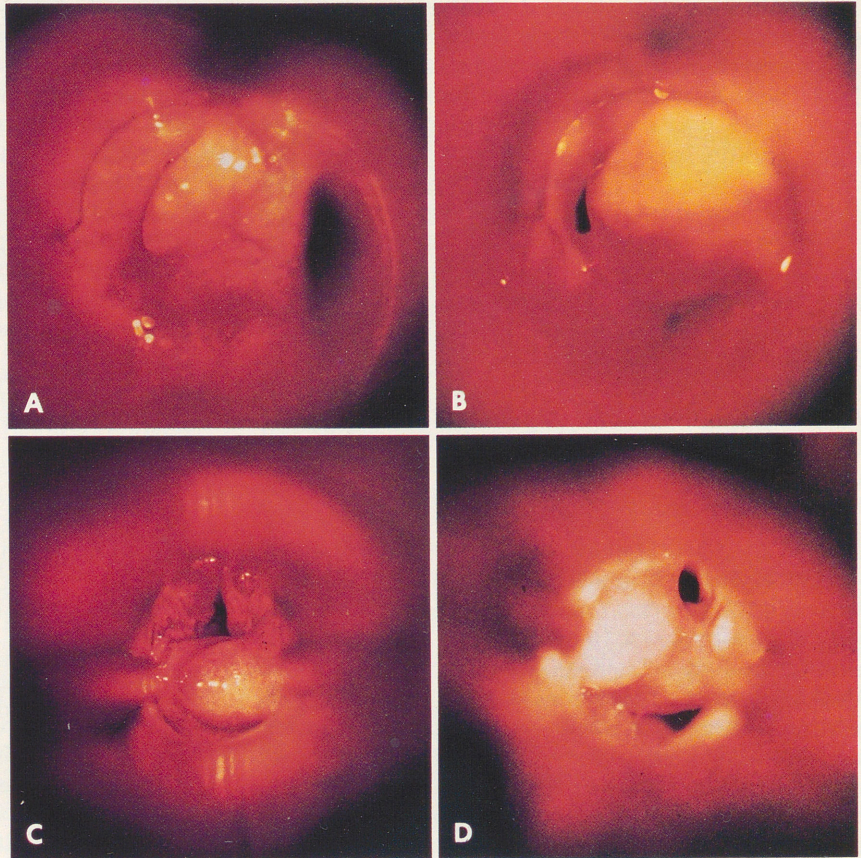


Fig 2. (Patient 4) A) Original photograph showing giant cervicofacial lymphangioma. B) Larynx infiltrated with cystic mass lesions. C) Larynx after treatment with laser surgery. Residual tumor is seen on right false cord.

Fig 3. (Patient 5) A) Larynx as visualized from above. Note compression and infiltration of vallecula and epiglottis being pushed to left. B) Extensive involvement of right arytenoid and aryepiglottic fold by cystic lesion. C) Persistence of large cystic mass involving right arytenoid and infiltration of ventricular bands. D) Bilateral infiltration of arytenoids, aryepiglottic folds, and extension to postcricoid area.



steroids, showed some improvement. However, because of continued airway obstruction, a tracheotomy was performed and steroids were continued, but tapered on September 21 because there was no decrease in the size of the mass in the neck. On November 7, excision of the tumor was performed by the pediatric surgical division. There were no postoperative complications except for a transient left upper lobe pneumonia that responded to antibiotic treatment. The biopsy showed a cystic hygroma. Endoscopic examinations on October 18 and November 3 showed increase in the size of the tumor in the supraglottic area. There was some subglottic narrowing that was felt to be due to intubation trauma. In addition, a large cyst was seen on the right side of the hypopharynx.

Multiple admissions followed the infant's discharge on November 4. On December 26 he was found to have a left corneal opacification and an ophthalmologic examination revealed a congenital glaucoma. During the next few months, local therapy by incision and puncture of the cysts showed no tendency for the laryngeal lymphangiomas to undergo change. Each time only a small amount of fluid was evacuated with puncture of the cysts. These procedures did not reduce the size of the tumor within the larynx. Therefore, cryosurgery was started on Jan 1, 1978. While initially there was improvement in the size of the laryngeal masses, by May 21 the right submandibular neck mass had in-

creased in size. For the next 1½ years, both cryosurgery and laser surgery were used. Improvement resulted and the boy was decannulated on Nov 21, 1979. On December 26, he was admitted for treatment of a cellulitis of the neck following a suppurative rhinitis and a streptococcal tonsillitis. This problem resolved with antibiotic therapy and he was discharged after 3 days of treatment.

On Feb 25, 1980, because of increasing stridor, especially during sleep, the boy was admitted for replacement of the tracheotomy tube. At intervals of 1 to 2 months, he was treated with laser surgery. On Dec 8, 1983, at 7 years of age, he was admitted for excision of the persistent right cervical mass. Extensive involvement of nerves, muscle tissue, and salivary gland by cystic hygroma was noted. The mass extended into the pharynx on the right side and was removed; the resultant defect in the pharynx was repaired. He did well postoperatively and was discharged on December 20. He was not seen again until Aug 1, 1984, when direct laryngoscopy showed the large mass on the left side of the epiglottis extending into the aryepiglottic folds, which were thickened as were the arytenoids (Fig 3D). The true vocal cords and subglottic area were normal. During laser therapy of the lymphangioma, fluid was noted to escape from the lesion and the mass completely disappeared from within the right arytenoid area. He was decannulated again, but 4 days later because of severe airway

obstruction during sleep, the tracheotomy was replaced. He was not seen for 1 year after replacement of the tracheotomy tube, and on July 15, 1985, he was readmitted for endoscopic examination. There was deviation of the epiglottis to the right, and the supraglottic area was deformed. The valleculae were free of lymphangioma, but the epiglottis appeared thickened. There was a mass in the right aryepiglottic fold and the right arytenoid. The ventricular band was infiltrated with hygroma. The true vocal cords and subglottic area were normal. The boy was readmitted on November 6, at which time the base of the tongue and the posterior portion of the false cord were involved by tumor. The right aryepiglottic fold lesion was biopsied and treated with laser. The tracheotomy tube is plugged during the day and well tolerated, and is opened only during sleep. Further therapy to the larynx is necessary.

Patient 6. An 11-hour-old white male (Hispanic) was admitted to our hospital on Aug 22, 1984. He was the product of a full term pregnancy. His mother had an influenzalike syndrome for about 5 days during the second month of pregnancy. At birth, he was found to have a left mandibular mass and increasing respiratory distress, with inspiratory and expiratory stridor and substernal, suprasternal, and intercostal retractions. On admission, his vital signs were normal. He had considerable sublingual edema and his tongue was enlarged. There was a $2\frac{1}{2} \times 2\frac{1}{2}$ -cm firm, mobile mass on the lateral aspect of the mandible, and bilateral submandibular cystic and somewhat fluctuant swellings. The lungs were clear. The remainder of the examination was normal. The laboratory findings were normal and an x-ray study of the chest was normal. Ultrasound of the neck showed bilateral cystic masses in the submandibular area. He was electively intubated and placed on continued positive pressure ventilation to treat his airway obstruction. Direct laryngoscopy on August 28 revealed involvement of the base of the tongue, valleculae, and the laryngeal surface of the epiglottis (Fig 4A). This extended laterally to the aryepiglottic folds and onto the arytenoids. The left lateral wall of the hypopharynx was involved. The glottis was inflamed, but tumor was not present (Fig 4B). The tracheobronchial tree was normal, but the glossoepiglottic folds were involved by the tumor. Because of airway obstruction, the infant was tracheotomized. Poor neck positioning caused the tracheotomy to erode the posterior wall of the trachea. This complication ultimately healed with fibrosis and without compromising the airway.

The infant was discharged on December 15, but continued to be admitted monthly for evaluation of the airway and treatment of the laryngeal disease. Swelling of the tongue and of the mouth increased, and the laryngeal findings showed increased involvement of the supraglottic larynx (Fig 4C). By

February 1985, diffuse bilateral submandibular swelling increased and extended onto his cheeks. The tongue was beefy and edematous and was covered with petechiallike lesions. Below the tongue and onto the floor of the mouth white exudate covered these lesions. In June the floor of the mouth elevation had receded and the tongue was smaller. Facial swelling continued bilaterally. In July laser surgery was applied to the lingual surface of the epiglottis and around the glossoepiglottic folds. Very little change occurred, and by October, sudden enlargement of the submandibular lymphangioma because of infection required treatment with IV antibiotics. The boy was discharged only to be readmitted 7 days later for anorexia, dehydration, and increased facial swelling. Antibiotics and steroids were ordered and consultation regarding a gastrostomy was requested. The consultant advised a red cell tag examination and an upper gastrointestinal tract x-ray study. It was evident that this patient had a mixed tumor of lymphangioma and hemangioma. These consultants' tests were never ordered and a gastrostomy has not been performed to date. With steroids and antibiotics, feeding has become easy and he continues on observation.

Patient 7. This 2-year 10-month-old Oriental male (Korean), following consultation, was admitted to our hospital on Nov 30, 1983. He had been treated at another institution with multiple operations for a congenital cervicofacial, oral, floor of the mouth, and lingual hygroma. He required a tracheotomy to support his airway and a gastrostomy for feeding purposes. He could not eat, drink, or chew. With the tracheotomy closed he had no airway and no voice. Examination on admission showed his tongue to be very large and elevated to the top of the palate, his facies were abnormal, the cheeks were full, and there were numerous scars in the neck from previous surgeries (Fig 5A,B). The tongue protruded from the mouth, was bulky on the left, atrophic on the right, and had coarse and fine fibrillations. Cystic lesions were seen on the floor of the mouth and over the surface of the tongue. A large soft, fluctuant mass in the submental area filled both submandibular triangles (Fig 5B). There was a marked open bite due to malocclusion produced by the large tongue. The neck was thin and no significant adenopathy was present. The tracheotomy tube and gastrostomy tube were in place.

Direct laryngoscopy revealed a large tongue elevated to the top of the palate and filling the oropharynx. At the base of the tongue, multiple cystic masses were seen (Fig 5C). The epiglottis, severely deformed with tumor involvement, projected downward into the larynx as a lid. The vallecular areas were filled with lymphangioma. Elevating the epiglottis and cystic masses revealed a large mass of lymphangioma over the right side of the larynx (Fig 5D). It was bulky and filled the area of the laryngeal lumen, projected into the right pyriform

sinus, and extended into the postcricoid area. The operculum of the epiglottis was invaded by the tumor that projected into the anterior commissure area. The left true vocal cord was foreshortened as was the anteroposterior diameter of the larynx. The right true vocal cord was hidden by the mass and extended into the right ventricular fold. The immediate subglottic area was normal. The trachea became a slitlike lumen, but was not invaded by tumor. The stenosis was a complication of the tracheotomy and was cartilaginous. The boy was discharged on the day of surgery.

Multiple admissions to the hospital were necessary. While fluid escaped during laser treatment, the tumor mass did not appear significantly reduced when the fluid distention was relieved. The submandibular mass continued to enlarge slowly, however, but by Sept 9, 1984, oral feedings improved and the gastrostomy tube was removed. With the monthly laser treatments to the larynx, the floor of the mouth became flatter, but the tongue filled the mouth. The tracheal stenotic lesion, a complication of the tracheotomy, was obstructive and did not respond to dilatation, so that on Sept 7, 1984, it was surgically excised. The stent was removed on the eighth day and the granulation tissue that developed was treated surgically and eventually cleared. Over a period of months, with bronchoscopic dilatations, the trachea became increasingly patent. In October 1985, the boy was admitted for excision of the submandibular hygroma. At surgery, extensive involvement by the hygroma throughout the fascial planes, salivary gland, and tongue muscle structures were noted. To avoid injury to vital structures, only partial excision was possible. The laryngopharynx was opened on the left and cystic lesions within the hypopharynx were removed. The resultant defect of the hypopharynx was closed without postoperative complications.

The boy's postoperative course, however, was complicated by tremendous swelling of the tongue (Fig 5E). Treatment with antibiotics and steroids, and nasogastric feedings were necessary for 2 weeks postoperatively. Gradually the swelling resolved and he was discharged 2½ weeks after surgery to continue on oral antibiotics. The tongue became smaller but remained large, and the floor of the mouth receded so that the oropharynx could be better visualized. On October 30, he was admitted for endoscopic evaluation. The right side of the larynx and base of the tongue were still involved by lymphangiomatous tumor. Because the tongue remained large, a partial left glossectomy was performed on December 6 by laser surgery. The boy's postoperative course was uneventful and he was discharged 3 days after surgery. Antibiotics were continued, and by Jan 28, 1986, he was infinitely improved. The tongue was deformed but greatly reduced in size. However, some cystic lesions could still be seen on the surface. He was referred for ortho-

odontic therapy. His tracheotomy tube is plugged throughout the day without evidence of airway obstruction. Further therapy to the larynx is necessary before decannulation can be accomplished.

Patient 8. A 15-month-old white female born on June 30, 1982, was first admitted to our hospital on Sept 6, 1983, for evaluation of her airway. The patient lived in northern California and was born with a cervicofacial hygroma that was treated surgically at 4 days of age. There was persistence of submandibular and infraparotid residual tumor. She did well for some months following her surgery and then developed increasing feeding difficulties because of a large cystic swelling in the floor of the mouth and associated enlargement of the tongue. In June 1983 she was treated with laser surgery to remove the hygroma from the floor of the mouth. This resulted in an almost immediate swelling of the entire face with closure of the eyes and edema of the floor of the mouth. While much of the swelling subsided, the tongue remained large and protruded from the mouth at least 2 to 3 cm. Endoscopic procedures showed involvement of the base of the tongue, larynx, and trachea, and she was referred for evaluation. Examination revealed that the tongue filled the mouth, protruded beyond the lips, and could not be manipulated back into the mouth (Fig 6A). There was tremor of the tongue and the bilateral submandibular irregular soft tissue masses extended to the area above the angle of the jaw. Nodular areas typical of lymph nodes were palpable within these masses. Direct laryngoscopy showed the base of the tongue and valleculae to be involved by cystic hygromatous lesions. The epiglottis was curled (Fig 6B), small, and compressed bilaterally to the midline by the base of the tongue and vallecular masses. The aryepiglottic folds were extremely thickened but could be elevated. The true vocal cords were normal, but the left had better abduction than the right. The false cords were edematous and obscured a view of the true vocal cords (Fig 6C). The subglottic area and tracheobronchial tree were normal. The base of the tongue was involved at the level of the pharyngoepiglottic and glossoepiglottic folds by lymphangiomatous invasion (Fig 6D). No treatment was given and she was referred back to her primary physicians with suggestions for continued care.

She was readmitted to our hospital on June 26, 1985, at 3 years of age to determine whether she could be decannulated. She had developed bleeding from the mouth following dental therapy. Examination showed the left ear canal to be narrowed by compression of the cystic hygroma within the parotid area. The right ear was normal. Many of her teeth were capped, the floor of the mouth was elevated with hemangiomatous and hygromatous tissue, and the tongue protruded from the mouth. There was a marked open bite due to the deformity of the jaws. The tongue was invaded with lesions that appeared

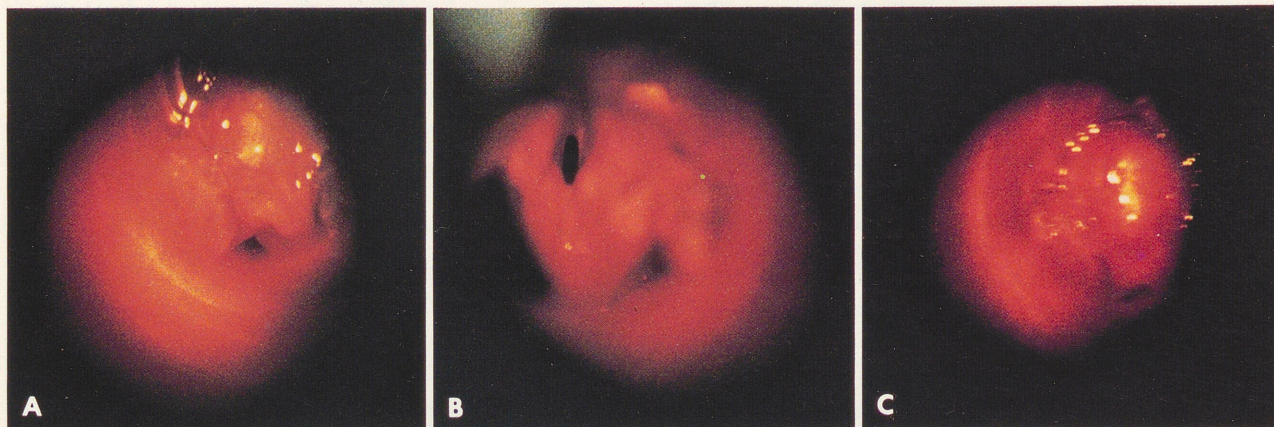


Fig 4. (Patient 6) Extensive infiltration by cystic hygroma in A) vallecule and epiglottis, B) ventricular bands postcricoid area, and C) right aryepiglottic fold filling supraglottic larynx.

verrucous and were composed of lymphangioma and hemangioma (Fig 6A). Direct laryngoscopy revealed the base of the tongue to be involved with cystic hygromatous masses extending to the level of the pharyngoepiglottic and glossoepiglottic folds. Invasion by hemangioma and lymphangioma was seen. The epiglottis was curled and compressed from the lateral aspects of the aryepiglottic area from the hygroma. The lesion extended onto the aryepiglottic folds and arytenoids. When the aryepiglottic folds were pushed apart, the true vocal cords were seen to be normal. Cryosurgery was applied to the bleeding angiomata of the tongue and

the child was sent back to her referring physicians for continued care.

Follow-up by a telephone call indicates that this child is doing poorly, has had continued bleeding from the mouth, and has had enlargement of the hygroma of the tongue, as well as of the neck and parotid area. Further surgery will be necessary, including wedge resection of the tongue.

Patient 9. An Oriental female (Korean) was born on July 26, 1980, and was admitted to our hospital at 1 day of age. Her transfer became necessary because of severe airway obstruction. The infant was born

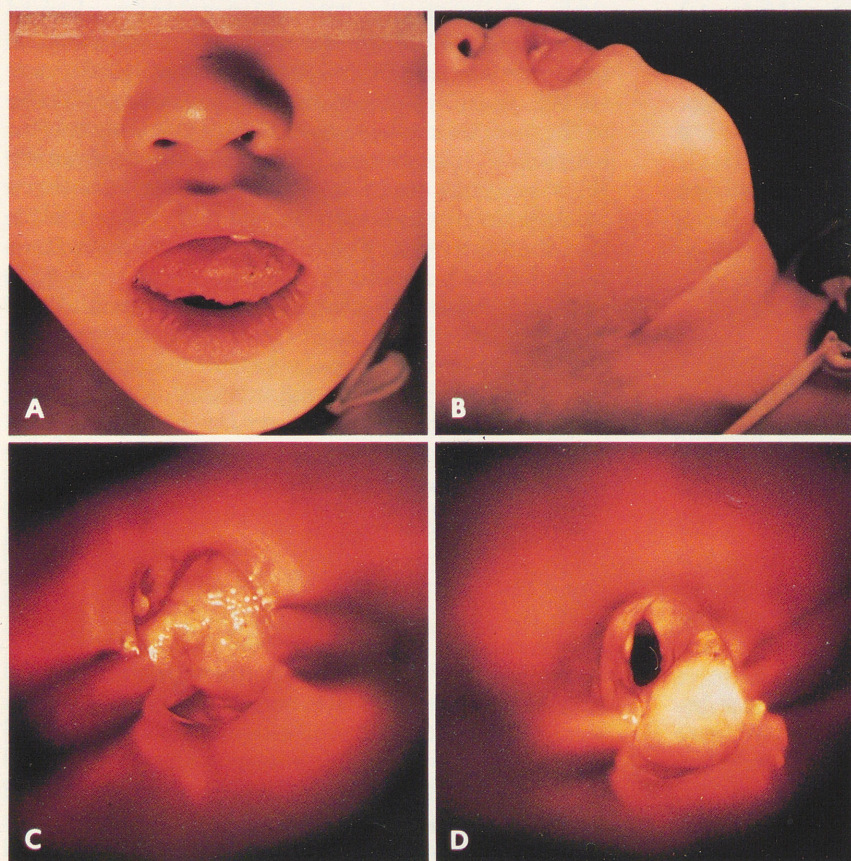
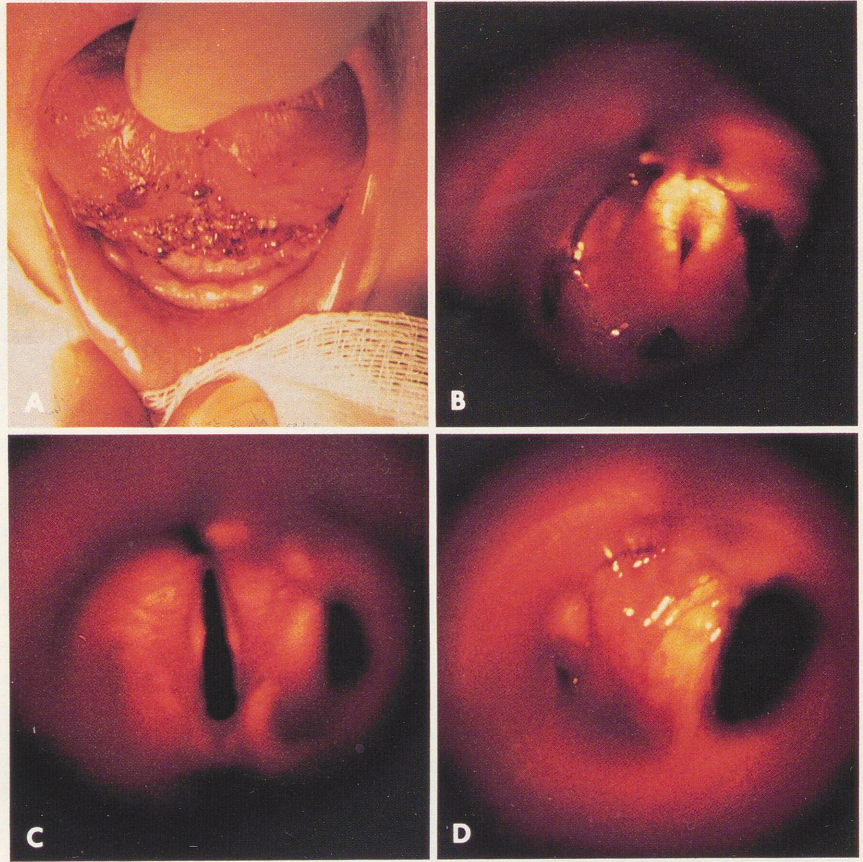


Fig 5. (Patient 7) A) Photograph after multiple operations. Note protrusion of tongue larger on left than right. B) Scarring in neck from previous surgery with mass lesion in submental and suprahyoid area. C) Larynx as seen from vallecule. Infiltrating cystic hygroma involves epiglottis, vallecule, and entire supraglottic structures. D) Cystic hygroma of right aryepiglottic fold and right arytenoid. Vocal cords are normal. E) Marked enlargement of tongue after partial removal of submental and suprahyoid mass lesion.

Fig 6. (Patient 8) A) Tongue is infiltrated with multiple cystic hemangiomatous and lymphangiomatous vesicular lesions. Note elevation of floor of mouth. B) View from above showing compression and infiltration of epiglottis by vallecular and supra-glottic tumor. C) Epiglottis has been elevated exposing infiltration of ventricular bands bilaterally. D) Laryngoscope has been brought out from larynx, exposing huge cystic hygroma of aryepiglottic fold extending down to arytenoid.



with a bilateral cervicofacial cystic hygroma (Fig 7A). During her hospitalization, the tumor grew rapidly and significant respiratory distress developed. Accordingly, on August 6, despite the patient's young age, surgical excision was clearly indicated. Prior to surgery by the pediatric general surgeon, endoscopy was performed. On arrival at the operating room, remarkable stridor and retractions were evident. The floor of the mouth and tongue were elevated, almost to the roof of the palate. Direct laryngoscopy revealed a large cystic hygroma arising from the left of the hypopharynx and extending

down to the level of the pyriform sinuses. On the right, a smaller cystic mass was present. The epiglottis was curled and the base of the tongue and false cords were involved with cystic lesions (Fig 7B). The epiglottis was compressed bilaterally by mass lesions at the base of the tongue and on each side within the valleculae (Fig 7C). Following endoscopic examination, the infant was intubated and under general anesthesia the gigantic bilateral neck hygroma was resected. The left side of the tumor was much larger than the right, but there was no apparent extension into the mediastinum. Immediately after

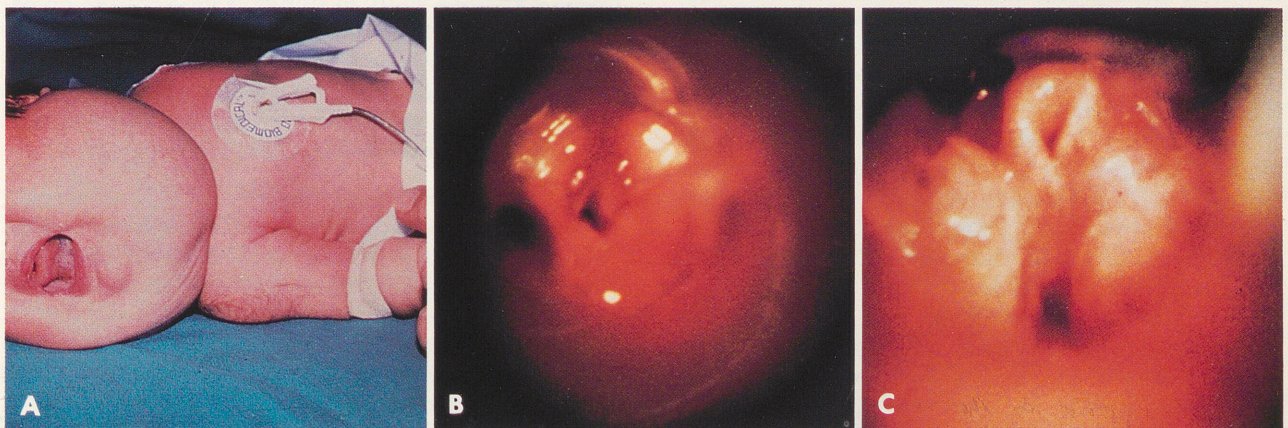


Fig 7. (Patient 9) A) Original photograph showing massive involvement by cervicofacial hygroma. B) Exposed larynx shows huge tumor involvement of ventricular bands extending to anterior commissure and under operculum of epiglottis. C) Supraglottic hemangioma compressing and invading epiglottis extending to aryepiglottic folds down to arytenoids.

surgery, nasotracheal intubation was necessary to support her obstructed airway. Postoperatively, the obstruction was due to the laryngeal tumor as well as remarkable swelling of the tongue and the hypopharynx. On August 13, a tracheotomy was performed because the lingual and oropharyngeal obstruction persisted. Subglottic edema was felt to be secondary to endotracheal intubation. A gastrostomy tube was required for feeding purposes.

At 5 months of age, laser surgery was started and was applied to the lateral pharyngeal cystic lesions. The patient was treated at monthly intervals by application of the laser to the hypopharyngeal masses and the base of the tongue and epiglottis. A biopsy of the base of tongue lesions revealed mucosal atrophy and submucosal fibrosis with scattered dilated hypoplastic channels. By March 1983, the gastrostomy tube could be removed. There was marked improvement in the subglottic laryngeal stenosis, but the hypopharyngeal masses were still obstructive. The floor of the mouth and tongue were still invaded by hygromatous lesions. Laser surgery was continued, and on March 23, 1984, residual cervicofacial hygroma was excised. The dissection was extremely difficult because of fibrosis and invasion of tissues by hygroma. The patient was discharged on April 1 without complications. Postoperatively, the floor of the mouth was lower within a month but the tongue still remained extremely large, with persistent involvement by tumor. In July she was decannulated, and on August 16, the tracheocutaneous fistula was closed. Residual tumor was present in the neck and she is being followed up periodically.

Patient 10. A 4-month-old black male infant was born on Sept 16, 1970, and was first admitted to our hospital on Jan 16, 1971.⁴¹ At 2 months of age he was noted to have a swelling at the angle of the left jaw. This growth enlarged progressively and there was associated swelling of the tongue and floor of the mouth. One week prior to his admission, he was seen by a physician who diagnosed an infection of the neck and mouth, and ordered antibiotics. One day prior to his admission, he developed severe dysphagia, drooling, and noisy breathing. The full term infant was the product of a normal, uncomplicated pregnancy. Examination on admission showed a tiny infant with a wide open mouth, a visible mass below the tongue, noisy breathing, especially when stressed, and excessive drooling (Fig 8A). The vital signs were normal and there was no skin hemangioma. There was a firm, movable 3 x 2-cm poorly defined mass below the angle of the left mandible that extended laterally, posteriorly, and anteriorly. The mouth continued to be open, and the left side of the tongue was markedly enlarged and protruded out of the mouth. Most of the mass was at the base of the left side of the tongue. A grade 2/6 harsh systolic ejection murmur was heard along the left sternal border. An x-ray study of the chest was normal but showed the soft tissue mass on the left side of the

mandible. There were no bony changes noted. Both an ECG and a skeletal survey were normal.

Over the next 3 days, the mass in the tongue began to ulcerate and bleed. On January 19, a tracheotomy and gastrostomy were performed because of the infant's increasing respiratory distress and difficulties in feeding. Direct laryngoscopy revealed the base of the tongue and larynx to be involved by large cystic masses (Fig 8B). Severe obstruction was present, the tracheobronchial tree was filled with secretions, the hygroma pushed the trachea into the right neck, and the hypopharynx was narrowed by cyst-like lesions. At tracheotomy, the tumor in the neck was seen to be typical of cystic hygroma. A biopsy was deemed unnecessary. The infant was placed on steroid therapy,⁴¹ and because of bleeding from the mouth, he required a transfusion. With improved nutrition and steroid therapy the tumor shrank slowly and bleeding was controlled completely. On February 1, he was scheduled for neck surgery, but the operation was cancelled because of his excellent response to steroid treatment. On February 5, he was started on a 2-month course of oral steroid at 60 mg/m². On February 22, direct laryngoscopy, incision, and drainage of the cystic mass in the larynx was accomplished. On March 8, the gastrostomy and tracheotomy tubes were removed and on March 9, a lateral x-ray view of the neck showed the airway to be normal (Fig 8C). The previously noted mass lesion appeared much smaller (Fig 8D), and the infant was discharged home. On March 17, he was seen in the outpatient clinic with some slight inspiratory and expiratory stridor, but there was no respiratory distress. The cervical mass was smaller, and he was followed up each month until November 5. At this time, he was seen for fever and cough and was noted to have bilateral perihilar pneumonia that was treated with antibiotics. He was not seen again.

RECURRENCES OR RESIDUAL TUMOR

In the group of 160 patients reviewed, 29 were known to have residual tumor. There was no correlation between the surgeon's opinion that total excision had been accomplished and the recurrence rate. Even disease-free surgical margins were no guarantee that all the tumor had been eradicated and that there would be no recurrences.

All ten patients with laryngeal lymphangiomata had cervical, facial, and/or submandibular hygromas. All except one had surgical resection of the original cervicofacial neck tumor. Residual growth or regrowth occurred in every one of these patients. Revision surgery of the neck masses was performed by the head and neck surgeon in four patients. The relationship between removal of the residual neck masses and resolution of the laryngeal lesions is of interest. In none of the four patients with secondary surgical removal of the recurrent suprahyoid lymphangioma did the lesions within the larynxes un-

dergo resolution. However, in those children who had hypopharyngeal tumors, neck surgery helped to remove these areas of obstruction and aided efforts to decannulate the patients. In the four patients, the pharynges were entered at the time the necks were opened, and the cysts were removed. The resultant defects were closed. Further laser treatment to the larynx was necessary to complete the elimination of the residual laryngeal tumors. Because the laryngeal lesions were supraglottic, control of the airways was easier to attain even though some tumor remained. Of the ten patients with laryngeal lymphangioma, eight had associated lesions in the neck, mouth, and tongue. Two of the patients with laryngeal disease had associated cervical masses and no other involvement in contiguous areas.

From evaluation of the data it is very apparent that the most debilitating and complex areas of involvement from the standpoint of therapeutics, return of function, and eradication of the lesion were the cervicofacial hygromas. All of these tumors were present at birth. While the abdominal and chest cavity cystic hygromas were alarming, they rarely produced immediate or instant life-threatening problems as was seen in the cervicofacial area where airway obstruction and dysphagia occurred. This latter area posed serious difficulties for 1) removing the tumor, 2) preventing disfigurement, 3) maintaining functional abilities, and 4) returning the child to normalcy.

Of the 60 patients with neck lesions, ten of whom had laryngeal involvement, the most common area of recurrence was in the suprahyoid, submandibular, submental, mandibular, and oral areas. To the surgeon these areas posed many problems in eradicating the tumor because of difficulties in removing the lesions without endangering vital structures. Of the patients with suprahyoid lesions, all had at least two or more operations. All tongue lesions were associated with elevation of the floor of the mouth and with submental or submandibular primary or residual hygromas. When the floor of the mouth and tongue were involved, surgery above the level of the hyoid produced massive enlargement of the tongue, compromising the airway. This complication should be expected and the consequences controlled with steroids, antibiotics, and artificial airways.

Complications. The most frequent complication was blood loss during the operative procedure. Designated donors were often requested. Fever associated with postoperative infection was relatively common, indicating that preoperative, intraoperative, and postoperative antibiotic therapy seemed mandatory. The persistence of drainage, frequently severe, indicated the opening of lymph channels with residual tumor. It is best to drain the surgical area postoperatively. However, a review of those patients with persistent drainage did not necessarily correlate with the recurrence rate of the tumor.

Swelling of the surrounding area postoperatively was usually an indication of existing tumor. The most common nerve paralysis was the mandibular division of the facial nerve; other cranial nerve palsies were uncommon. The postoperative swelling of the tongue with resultant airway obstruction created airway problems and dysphagia so that alternative methods of feeding and support of the airway were necessary. Fortunately most of the patients in whom this occurred were already tracheotomized. In one patient there was a postoperative stenosis of the external canal after removal of a parotid lymphangioma; tracheocutaneous fistulae that persisted after decannulation required surgical repair. In the follow-up of these patients with residual tumor, recurrent infection caused increased swelling, but in many patients, further surgical removal was unnecessary. There were no deaths due to the surgery or the disease in this series.

MALIGNANCY WITHIN LYMPHANGIOMATA

Patient 146 was a white male born on April 30, 1950. He was first admitted to our hospital on July 6, 1956, at 6 years 2 months of age. The history reflected that he had a tumor of the right arm present since 6 weeks of age which was thought to be a "muscle lump." In 1953, he was given one x-ray treatment. By June 1956 the mass grew to a "teacup" size. Surgery was performed and the biopsy diagnosis was a lymphangiosarcoma developing within a cystic hygroma. He was transferred to our hospital for consultation regarding whether therapy was appropriate. On examination, he was normal except for a tumor in the posterior portion of the right arm. There was a partially healed scar with crusting over the operative site. The right arm was larger than the left. The biopsy showed lymphangiosarcoma within a hygroma. He was observed for about 6 months and then he moved to northern California. A follow-up was not obtainable.

ANALYSIS OF HEAD AND NECK LYMPHANGIOMATA

The number of operations required in the head and neck area varied from one to 13. The fact that the child would have only one operation did not by any means indicate complete extirpation of the tumor. Once the tumor was removed, long-term follow-up was not attainable in the majority of these patients. Of the 73 patients with head and neck lymphangioma, three had no surgery performed, one is still in treatment, and the other two either refused surgery or sought therapy elsewhere. Forty-eight patients had one operation only, but this did not necessarily indicate complete extirpation of the tumor. Of the 48 patients having one operation, 16 are known to have residual tumor, nine were not followed up long enough to determine whether residual tumor or recurrences were present, and 23 had no evidence of residual or recurrent tumor. The need for multiple operations was most often seen in

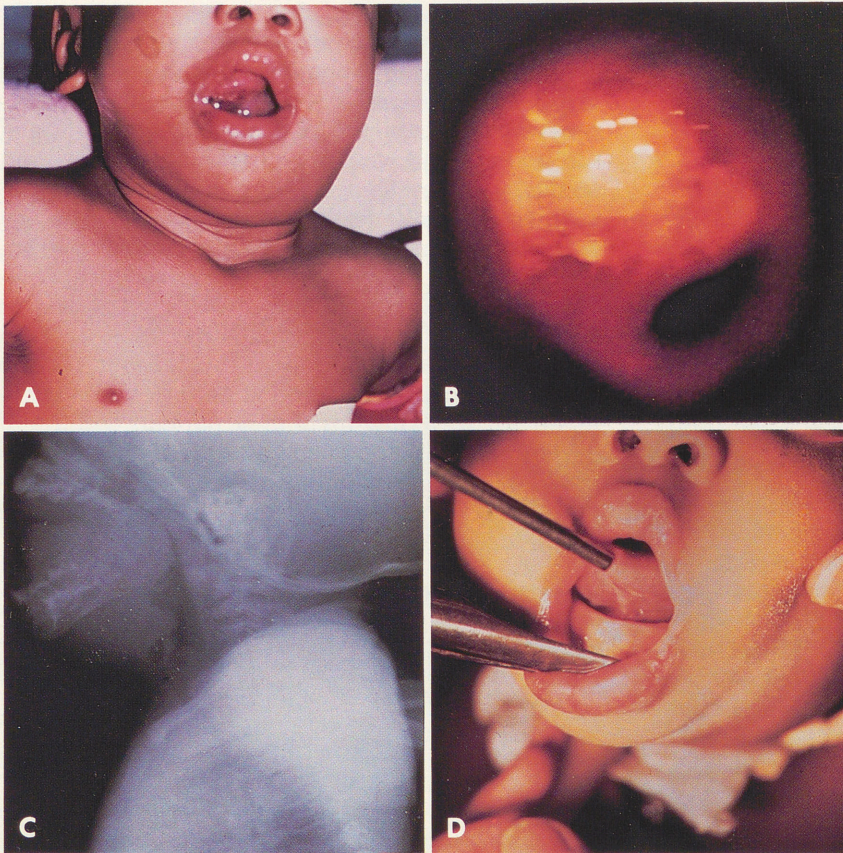


Fig 8. (Patient 10) A) Photograph on admission showing left submandibular mass and elevation of tongue. B) Complete occlusion of larynx and supraglottic area by hygroma involving epiglottis, aryepiglottic folds, and all supraglottic structures. C) Lateral x-ray film of airway showing improvement in air space but persistent mass in submandibular area. D) Changes in appearance of tongue and floor of mouth but persistent left neck hygroma present.

patients with tongue, floor of the mouth, and suprahyoid lesions. The recurrences were least in those patients who had supraclavicular tumor not invading the mediastinum and in whom the tumor was in the lower portion of the neck or in the midline. Thus the patient with a neck hygroma had a better prognosis when the lesion was below the hyoid level.

DISCUSSION

PATHOLOGY

It is likely that all lymphangiomas, whether simple, cavernous, or cystic, are not only of common embryologic origin, but represent different stages of the same disease. The various forms are probably dependent for their morphology on the site in which they exist.

The lesion is a benign tumor of lymphatics with endothelium-lined channels of varying dimensions. These channels vary from capillary-size lymphoid spaces to very large cystic spaces ranging from few to many centimeters. The different-sized space lesions may vary within a single patient. In at least some instances, the nature of the surrounding tissue in which the tumor lies may determine its course of development. Thus, in the extremities and within skin, the size of the lymphatic spaces will be smaller than where unlimited space is provided for extension and growth as in the neck, axilla, chest, or abdomen.

An analysis of the reports of the pathologic specimens of the patients reviewed in this paper is as follows. The gross specimens may be of different sizes, shapes, and texture. They vary from round, cystic, globular, nodular, smooth, soft to firm (or hard), spongy, rough, and irregular. The color of the specimen may be tan, gray, purple to red, hemorrhagic, or brown. Microscopically, the mass is usually surrounded by a fibrofatty connective tissue covering, and the cysts or slitlike spaces lined by endothelium frequently lie within fibrovascular stroma.

The specimens removed for pathologic examination varied tremendously in size. The size of the tumor had no bearing on the place of the body from which it was removed. However, when in a large body cavity, the size of the tumor created compression, displacement, torsion, or vascular limitation to surrounding organ function. No patient had actual invasion of a contiguous organ except one with a malignancy and patient 4, whose neck tumor invaded the mediastinum causing erosion of the undersurface of a clavicle.

In the head and neck, face, orbit, and oral cavity, the operative lesions ranged in size from 0.6 x 0.4 x 0.2 cm in a single lesion on the tongue, to 10 x 7 x 2.5 cm in the neck. In many instances, the pathologic specimen was a conglomerate of pieces removed at surgery since the entire tumor could not

be removed in toto because of hazards to vital structures. The mediastinal tumors were as large as 11 x 8 x 2.5 cm, and in the flank the largest tumor was 12 x 7.2 x 1.5 cm. In the abdominal cavity, masses were 12 x 7 cm and one, which was removed, weighed 850 g. While in the extremities the lesions were usually moderate to small, in the distal extremities recurrences were frequent. Thus the size of the specimen had no bearing on whether recurrences were prominent. One of the largest masses, in the shoulder, recurred three times; the original tumor was 18 x 14 cm.

In the head, neck, face, and orbit, the cyst ranged from a single space to multilocular spaces and varied from small to very large. Most of the specimens had large cystic lesions which on occasion communicated with one another. The septi were thin or thick and fibrosis was very common. In about one half of the specimens, the tumor was composed of slitlike channels lined by flat endothelial cells. Fluid within the cystic masses ranged from amber-yellow to bloody chocolate, and some of the cysts were empty. Microscopically, the fluid or contents of the spaces, cysts, or channels were empty or filled with RBCs, WBCs, or a combination of both. Proteinaceous or pink eosinophilic material was present in a large number of the specimens. Hemosiderin and cholesterol crystals were seen in some, and chronic inflammation was relatively common within the lymphangioma. Infection occasionally caused increase in size of residual tumor that receded with antibiotic therapy.

Grossly the walls of the cyst were frequently of a fibrous tissue type and microscopically the cyst consisted of dense fibrous tissue. The specimen was usually enclosed within a fibrofatty tissue and the cystic masses were surrounded by fibrous tissue. Attached to the mass were lobules of fat, and lymph nodes or lymphoid structures were commonly seen in the head and neck tumors. The lymph nodes were seen in some of the specimens even when there was a paucity of inflammation. On occasion, the lesions were necrotic and even showed evidence of thrombosis. At times, considerable difficulty was encountered in distinguishing those lesions which were partly hemangiomatous from those with mixed vascular elements. However, from microscopic examination in four of the patients, there was no question that the lesion was of a mixed angiomatous type, ie, lymphangioma or hemangioma.

DIAGNOSIS AND DIFFERENTIAL DIAGNOSIS

The diagnosis of lymphangioma of the head and neck is rarely difficult, especially when the tumor mass is seen in the newborn, infant, or very young child. The lesion, whether single or multilobular, usually presents in the posterior triangle of the neck and may extend from the supraclavicular area to the angle of the jaw. It may extend anteriorly to the midline and to the other side of the neck. Since most

cystic hygromas have poorly defined borders, they are different from other congenital cysts. An important differentiation is that lymphangiomas transilluminate clearly. When the tumor extends from the parotid area and submandibular area and involves the floor of the mouth and tongue, the diagnosis is easily made. However, when the lesion is within a cavity such as the chest and abdomen, it can pose serious problems in differential diagnosis.

In this series of patients, numerous diagnostic techniques were used depending on the site of the lesion and presenting symptoms. An x-ray study of the chest was invariably performed to define mediastinal involvement and/or other lung disease. A lateral x-ray film of the neck was usually taken to elicit the density of the mass and define its borders, to rule out bone disease, and to indicate the possible presence of calcifications. The airway could be defined with the lateral film so that extension from the neck could be determined. Lesions within the hypopharynx and larynx or impinging upon the upper esophagus and trachea could be better defined. A barium swallow esophagram was ordered when dysphagia was a prominent symptom and when mediastinal involvement was suspected. A CT scan was performed in three patients when chest and abdominal masses were presenting features. Ultrasound was ordered in only four patients, for two with abdominal lesions and for two with submandibular masses. Angiographic studies were necessary in three patients suspected of having vascular hemangiomatous lesions. It is important to stress that a needle biopsy performed in two patients was not diagnostic; in neither of these patients was cellular material obtainable for diagnosis, and the fluid content was nonspecific. The ultimate diagnosis was determined by excisional biopsy. The appearance of the tumor at the time of operation was so typical that frozen sections were rarely necessary. The potentially destructive pattern of multiple cystic lesions alerted the surgeon to the diagnosis. In some instances, the physician was misled by the skin discoloration over the mass lesion being involved with port-wine stains, telangiectasia, hemangiomas, or even melanotic deposits.

The differential diagnosis should include the following: 1) branchial cleft cysts; 2) congenital retention cysts, which are more solid usually and do not transilluminate; 3) thyroglossal duct cysts, which are much smaller usually and most often are within the midline; 4) dermoid cysts, which are more solid usually; 5) foregut cysts, which may pose a more difficult problem in differentiation; 6) malignant tumors, which are rare in young children, but may have cystic components; 7) deep hemangiomas, which may be differentiated by their compressibility; 8) infections of the neck, particularly lymphadenitis, which should pose no problems although cystic hygroma may present with trauma or infection; 9) lipomas, which can be ruled out by their

failure to transilluminate and are usually more solid tumors; and 10) when in the floor of the mouth, a ranula, which can be the most common misdiagnosis. While the color and form of the tumor can simulate a hemangioma, lymphangiomata are not compressible and transilluminate clearly.

THERAPY

The treatment of lymphangioma should be directed toward the following: 1) removal of the entire tumor when possible; 2) return of function of involved structures; 3) relief of associated complications due to pressure by the tumor such as airway obstruction, dysphagia, speech problems, and defects of dentition; 4) obtaining the best possible cosmetic results; and 5) relief and stabilization of emotional consequences of this formidable benign pathologic entity. Fortunately, the disease is an uncommon occurrence.

A review of the literature and the charts of 160 patients with lymphangiomata indicate that observation or patiently awaiting spontaneous resolution is hazardous and unrewarding since spontaneous regression rarely, if ever, occurs. The lesion may undergo sudden alarming growth to gigantic proportions, cause severe accompanying airway obstruction and dysphagia, and force the surgeon to operate. Postponement of surgery is inadvisable and injudicious.

However, unplanned and hurried radical surgery may be just as harmful. Surgery should be as complete as possible, yet not excessive, and staged surgery may be necessary to prevent life-threatening intraoperative and postoperative complications. Destructive surgery with compromise of vital structures is unwise, unwarranted, dangerous, crippling, and does not guarantee cure.

The lesion is radioresistant and, while claims have been made for improvement and resolution of the tumor by use of irradiation, the results have been inconsistent and the complications severe and uncompromising. The long-term hazards to the child should preclude use of this therapeutic modality in this benign lesion. Four patients in this series were subjected to irradiation and none showed any tendency toward resolution.

Incision and drainage or needle aspiration should be discouraged because of the risk of infection and the possibility of sepsis. Although this type of treatment is temporizing, it is not curative. Electrodesiccation was used in two patients in this series with no appreciable response.

Injection of sclerosing agents was not used in any of the 160 patients, although this therapy was reported in the literature. This treatment offers little curative value and may be harmful, especially if there are communications with major venous channels. Injections will cause scarring and create serious difficulty for surgical removal of the tumor.

In the ten patients with laryngeal lymphangiomata, steroids, cryosurgery, laser surgery, incision and drainage, and needle aspirations were used. The only valuable therapeutic modality within the larynx was laser surgery. Although tedious, prolonged, and time-consuming, this therapy eradicated much of the tumor and gave minimal to no destruction of local tissues. Supraglottic laryngectomy was neither considered nor performed. The procedure was considered excessively radical for such a benign lesion, but most of all it could not guarantee total extirpation of the disease. As reported by Holinger et al,³⁸ this form of surgery, which was performed in one patient, was not curative.

With the use of the laser, fluid exuded from the cysts, and the cyst walls could then be removed. Merely uncapping the cysts with the laser, like needle aspiration or incision and drainage, did not produce remission or resolution of the tumor. It was necessary to lase the tumor mass itself.

Surgical intervention in the suprahyoid portion of the neck, the most common area of recurrences or persistence of the tumor, often produced dramatic and alarming postoperative swelling of the tongue and floor of the mouth. This area of involvement was prone to be associated with lesions of the floor of the mouth and tongue. Postoperative swelling in these areas compromised the airway and a tracheotomy was absolutely necessary.

It is far better to treat patients with antibiotics early than to await the often frightening febrile course following surgical removal of cystic hygroma. The preoperative, intraoperative, and postoperative use of antibiotics was essential for the safety of the patient. As reported by many authors, impaired lymphatic drainage made infection extremely hazardous.

In many children with an airway problem of oral, lingual, or laryngeal involvement by the tumor, steroids used intraoperatively and postoperatively were most helpful in protecting the airway and reducing traumatic postoperative edema.

SUMMARY AND CONCLUSIONS

Lymphangiomas are benign but nevertheless challenging tumors, and exceptionally so when the larynx is involved. Treatment demands the patience and skill of the surgeon. Of the 160 patients seen at our institution between 1955 and 1985, the tumor was more common in the male and occurred predominately in the white population. While unusual in the Oriental (4%), three of the children in the group presented a much more challenging problem with involvement of the head and neck, oral cavity, tongue, larynx, and hypopharynx.

Forty percent of the hygromas presented in the newborn period, 50% were present by the end of

the first year, 75% were found by the end of the second year, and 85% had appeared by the end of the fifth year.

Tracheotomies were necessary in ten patients, and feeding gastrostomies were necessary in those with dysphagia. Three of the patients in the series were twins, and in each case the twin was normal.

Skin lesions over the tumor occasionally misled the physician in arriving at a correct diagnosis. Forty-five percent of the patients had lymphangioma of the head and neck, the most common site of involvement. There was a slight predilection of the lesion for the right side. Only five patients had multiple tumor sites. Associated anomalies were uncommon.

The treatment of lymphangioma is surgical. All other modalities such as awaiting resolution, needle aspiration of the lesion, incision and drainage, cautery, injection of sclerosing agents, electrodesiccation, and irradiation should be discouraged. Surgery, however, should be planned and even staged if necessary when the tumor is very extensive. Surgery should never be excessive or maiming, with preservation of all vital structures. The opinion of the surgeon that all tumor was removed had no bearing on recurrence rate, and even clear surgical margins had no true value regarding whether the tumor actually was completely removed. Recurrences were not uncommon even under these mentioned circumstances. The purpose of surgery was

to remove the tumor entirely if possible, return normal function of the involved surrounding structures, relieve associated complications due to the presence of the tumor, obtain the best cosmetic results, and allay emotional consequences of the lesion.

Treatment in the larynx was extremely difficult. The removal of surrounding neck tumor did not control the disease within the larynx but was very helpful in removing the intrahypopharyngeal or parapharyngeal disease. The intralaryngeal tumor responded only to the use of the laser. Like neck disease, it did not respond to incision and drainage, injection, or needle aspiration. The laser was the most effective modality and did not create serious injury to the laryngeal structures or function.

Bleeding at surgery was controlled and transfusions were not uncommon. When the patient was not treated with antibiotics, infection created serious problems and potential sepsis. Drainage from the postoperative wound was variable but controllable with time. Occasional nerve paralysis was rarely serious except where the surgeon attempted to remove the lesion completely. There were no deaths in this series of patients.

Considering the extreme difficulties which lymphangioma presents to the child and physician, the ultimate results will be rewarding. As in the neck, excessive or radical surgery applied to the larynx will not guarantee the elimination of this disease.

REFERENCES

1. Sabin FR. On the origin of the lymphatic system from the veins and the development of lymph heart and thoracic duct in the pig. *Am J Anat* 1901; 1:367-89.
2. Sabin FR. The lymphatic system in human embryos with a consideration of the morphology of the system as a whole. *Am J Anat* 1909; 9:43-91.
3. Wernher A. Die Angeborenen Zysten-Hygrome und die ihnen verwandten Geschwulste in anatomischer diagnostischer und therapeutischer Beziehung. Giessen, Hessa-Darmstadt: GF Heyer, 1843:76.
4. Von Rokitsky C. Lehrbuch der pathologischen Anatomie. 3rd ed. Vienna: W Braumuller, 1855:230.
5. Luschka H. Ueber die drüsenartige Natur des Sogenannten Ganglion intercaroticum. *Arch Anat Physiol* 1882; 4:405.
6. Virchow R. Die krankhaften Geschwulste. Berlin: A Hirschwald, 1863:170.
7. Koester K. Ueber Hygroma cysticum colli congenitum. *Verh Phys Med Ges Wirzh* 1872; 3:44.
8. Goetsch E. Hygroma colli cysticum and Hygroma axillae. *Arch Surg* 1938; 36:394-479.
9. McClure CFW, Silvester CF. A comparative study of the lymphatic-venous communications in adult mammals. *Anat Rec* 1909; 3:534-53.
10. Dowd CN. Hygroma cysticum colli: its structure and etiology. *Ann Surg* 1913; 58:112-32.
11. Thompson JE, Keiller VH. Lymphangioma of the neck. *Ann Surg* 1923; 77:385-96.
12. Vaughn AM. Cystic hygroma of the neck. *Am J Dis Child* 1934; 48:149.
13. New GB. Hygroma cysticum treated with radium. *Surg Clin North Am* 1924; 4:521-30.
14. Figi FA. Radium in the treatment of multilocular lymph cysts of the neck in children. *Am J Roentgenol* 1929; 21:473-80.
15. Furstenberg AC. A clinical and pathological study of tumors and cysts of the nose, pharynx, mouth and neck of teratological origin. Ann Arbor, Mich: Edwards Brothers Inc, 1936.
16. Gross RE, Goeringer CF. Cystic hygroma of the neck. *Surg Gynecol Obstet* 1939; 69:48-60.
17. Eggston AA, Wolff D. Histopathology of the ear, nose and throat. Baltimore: Williams and Wilkins Co, 1947.
18. Anderson DH. Tumors of infancy and childhood. *Cancer* 1951; 4:890-906.
19. Freeman GC. Conservative treatment of massive cystic lymphangioma: report of eight cases. *Ann Surg* 1953; 137:12-7.
20. Briggs JD, Leix F, Snyder WH, Chaffin L. Cystic and cavernous lymphangioma. *West J Surg Obstet Gynecol* 1953; 61:499-506.
21. Childress ME, Baker CP, Samson PC. Lymphangioma of the mediastinum: report of a case with review of the literature. *J Thorac Cardiovasc Surg* 1956; 31:338-48.
22. Morfit HM. Lymphangioma of the tongue. *Arch Surg* 1960; 81:101-7.
23. Meyerson MC. The human larynx. Springfield, Ill: Charles C Thomas, 1964.
24. Bill AH, Summer DS. A unified concept of lymphangioma and cystic hygroma. *Surg Gynecol Obstet* 1965; 120:79-86.
25. Barnhart RH, Brown AK. Cystic hygroma of the neck. *Arch Otolaryngol* 1967; 86:100-4.

26. Proctor B, Proctor C. Congenital lesions of the head and neck. In: Davison F, ed. Symposium on pediatric otolaryngology. Otolaryngol Clin North Am 1970; 3:236.
27. Ward PH, Harris PF, Downey W. Surgical approach to cystic hygroma of the neck. Arch Otolaryngol 1970; 91:508-14.
28. Johner CH. The lymphatics of the larynx. In: Sisson GA, ed. Symposium on problems of the larynx. Otolaryngol Clin North Am 1970; 3:439-50.
29. Rouviere H. Anatomy of the human lymphatic system. Ann Arbor, Mich: Edwards Brothers, Inc, 1938.
30. Ruben RJ, Kucinski SA, Greenstein N. Cystic lymphangioma of the vallecula. Can J Otolaryngol 1975; 4:180-4.
31. Hebert G, Oumet-Olivia D, Ladoriceur J. Vascular tumors of the salivary glands in children. Am J Roentgenol 1975; 123:815-9.
32. Saijo M, Munro IR, Mancer K. Lymphangioma: a long term followup study. Plast Reconstr Surg 1975; 56:642-51.
33. Jones PG, Campbell PE, Beardmore HE. Tumors of infancy and childhood. London; Blackwell Scientific Publications, 1976.
34. Levin SL, Jorgensen RJ, Bradley AJ. Lymphangiomas of the alveolar ridges in neonates. Pediatrics 1976; 58:881-5.
35. Schuller DE, McCabe BF. Salivary gland neoplasms in children. Otolaryngol Clin North Am 1977; 10:399-412.
36. Jones SR, Myers EN, Barnes L. Benign neoplasms of the larynx. In: Fried MP, ed. Symposium on the larynx. Otolaryngol Clin North Am 1984; 17:160-1.
37. El-Serafy S. Rare benign tumors of the larynx. J Laryngol Otol 1971; 85:837-51.
38. Holinger PH, Brown WT, Maurizi DG. Tracheotomy in the newborn. Am J Surg 1965; 109:771-8.
39. Ewing J. Neoplastic diseases. Philadelphia: WB Saunders, 1941.
40. Ribbert H. Geschwulstlehre fur Aertze und Studierende. Bonn, German Empire: F Cohen, 1914:226-31.
41. Cohen SR, Wang CI. Steroid treatment of hemangioma of the head and neck in children. Ann Otol Rhinol Laryngol 1972; 81:584-92.

IMBRICATION RECONSTRUCTION FOLLOWING PARTIAL LARYNGECTOMY

CHEN LIU, MD

TAIPEI, TAIWAN, REPUBLIC OF CHINA

PAUL H. WARD, MD

LOS ANGELES, CALIFORNIA

LAWRENCE PLEET, MD

LOS ANGELES, CALIFORNIA

Experience over a 16-year period with 38 patients who underwent partial laryngectomy with imbrication reconstruction is reviewed. We have found this technique to be an expeditious and highly successful means of eradicating T1 or T2 glottic cancer. The use of the patient's own full-thickness, adjacent normal tissue with imbrication of cartilage produces an adequate airway, an almost normal-appearing larynx, and a remarkable posttreatment voice quality, better results than from most cordectomies or vertical hemilaryngectomies. It is valuable as a salvage procedure after full-course radiation. Imbrication laryngoplasty is an alternative and a preferred modality for treatment of young people with early glottic carcinoma for whom the possible carcinogenic properties of radiation must be considered. The survival results are comparable with the more extensive vertical laryngectomies.

KEY WORDS — glottic carcinoma, imbrication, laryngoplasty, partial laryngectomy.

INTRODUCTION

Imbrication laryngoplasty for the reconstruction of the larynx after partial laryngectomy has been used in 38 patients with T1 or T2 glottic cancer during the past 16 years. This technique allows functional reconstruction of the larynx following a through-and-through excision of tumor, soft tissue, and laryngeal tissue. The residual false cord and aryepiglottic folds are imbricated medially in a pocket created in the residual subglottic or cricoid mucosa, producing an adequate airway, a near normal-appearing larynx, and a remarkable posttreatment voice quality superior to that obtained with most cordectomies or vertical partial laryngectomies.

Conservation surgery for patients with laryngeal cancer is designed to eradicate the local disease while maintaining the laryngeal function in patients carefully chosen to fulfill preselected criteria. Conservative laryngeal surgical techniques, which spare thyroid cartilage adjacent to a neoplastic lesion, may be inadequate since the internal perichondrium is only a relative barrier to neoplastic extension. Current popular techniques for partial laryngectomy involve removal of soft tissue from mucosa to, and including, the internal perichondrium of the thyroid cartilage.¹ The exposed cartilage is then covered with either skin graft, mucosal pedicle flaps, or transposed bipedal muscle flaps. In the extended partial laryngectomy (vertical and anterovertical) procedure, thyroid cartilage is included in the specimen.^{2,3} The larynx is reconstructed with insertion of cartilage or strap muscles to form the new hemilarynx. These techniques sometimes produce excellent results with adequate airway and a good voice but are unpredictable because the rigid sup-

port of thyroid cartilage is lost, leaving glottic closure to the vagaries of the healing process. Following application of the anterovertical technique, the reconstructed soft tissue bulk is variable because of late atrophy and scarring of transposed muscle flaps.

Wang⁴ stated that "tumors of the vocal cords which extend laterally into the ventricle and posteriorly onto the vocal process and face of the arytenoid are not highly curable by radiotherapy, but can be successfully extirpated by vertical hemilaryngectomy." T1 and T2 glottic lesions that are radiation failures and T2 glottic lesions that show a poor initial response to radiation therapy are also considered candidates for partial imbrication laryngoplasty.

The partial vertical hemilaryngectomy has been very successful in curing vocal cord carcinoma after radiation therapy failure, where the persistence or recurrence is superficial and limited to a mobile cord.³ The objective in partial laryngeal cancer surgery is to encompass the cancer rather than resect a designated portion of the larynx. The new technique of reconstruction following a partial through-and-through imbrication laryngoplasty has the advantage of removal of T1 and T2 glottic lesions to include adjacent laryngeal cartilage without sacrificing the rigid support provided by the noninvolved thyroid cartilage. Using the patient's own full-thickness adjacent normal tissue (ie, false cord and aryepiglottic fold), along with imbrication of the cartilage, provides a superior blood supply that allows extension of the indications for partial laryngeal surgery after radiation failure.

Our indications for partial laryngectomy are con-

From the Department of Surgery, Division of Head and Neck Surgery (Otolaryngology), The Jonsson Comprehensive Cancer Center, UCLA School of Medicine, Los Angeles.

Presented at the meeting of the American Laryngological Association, Palm Beach, Florida, May 4-5, 1986.

REPRINTS — Paul H. Ward, MD, Division of Head and Neck Surgery, UCLA School of Medicine, Los Angeles, CA 90024.

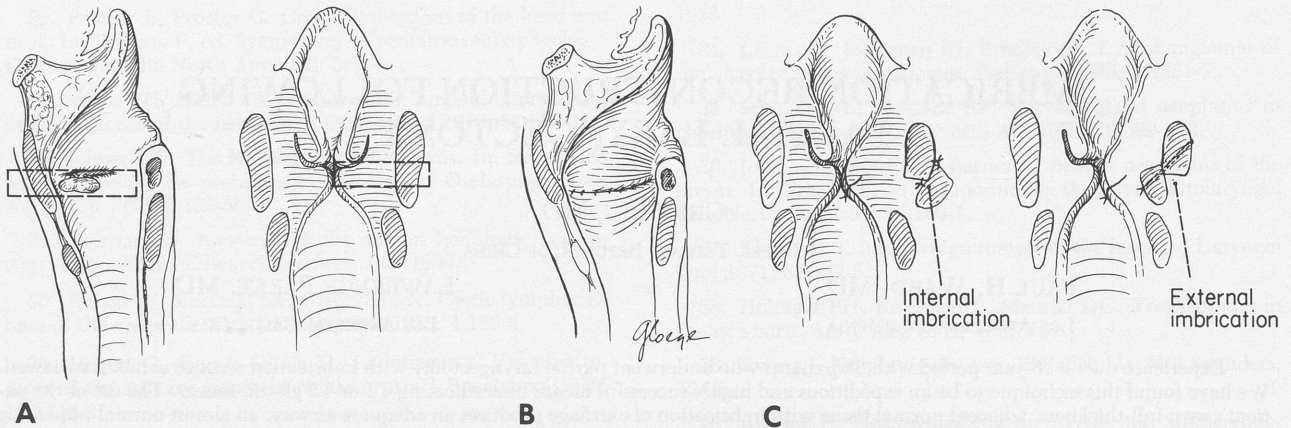


Fig 1. Technique of imbrication of larynx with lesion on vocal cord. A) Area of through-and-through resection outlined in broken lines. B) After resection, innervated and vascularized false cord and aryepiglottic fold are dropped down. C) Residual thyroid cartilage is imbricated either by internal or external technique.

sistent with those of Biller et al.⁵ They state that any or all of the following characteristics associated with T2 glottic lesions may be treated by conservation laryngeal surgery: 1) true cord lesion extending to involve the anterior commissure (the anterior commissure and up to 30% of the opposite cord); 2) a true cord lesion may involve the vocal process or the anterior or superior portions of the arytenoid; and 3) a true cord lesion may extend subglottically up to 10 mm. Biller et al also noted that "the involved cord may exhibit limitation or mobility but fixation of the vocal cord should not be present." From recent experience, it may be added that the ventricle and lower margin of the false cord may be involved as long as complete cordal fixation is not present.

This new procedure already appears to be the preferred modality of treatment for young people (under the age of 40) because they have an expected long survival, and second primary or radiation-induced cancer is possible.

TECHNIQUE

A preliminary tracheostomy is performed either under local or general anesthesia after passage of a small, cuffed endotracheal tube. A horizontal collar incision is made in a skin crease just below the cricoid cartilage. The midline cervical fascia is included, and the thyroid alae are exposed by retracting the strap muscles laterally. Muscle attachments at the site of cartilaginous cuts on the ala are freed using a blunt elevator.

The external thyroid perichondrium is incised vertically in the midline and elevated laterally, thereby protecting the external branch of the superior laryngeal nerve to the cricothyroid muscle.

Exploratory thyrotomy is performed for final determination of the extent of the cancer and suitability for the imbrication technique. Subglottic extension below the cricoid cartilages is a contraindication

for imbrication laryngoplasty. Elective neck dissection is not performed because of the extremely low incidence of neck metastases with T1 or T2 glottic lesions. After incision of the thyrohyoid membrane and the midline or lateral division of the thyroid cartilage, the alae are retracted and the lesion fully inspected.

The mucosal incision sites in the false cord and infraglottic region are infiltrated with 1% lidocaine epinephrine (Xylocaine, 1:100,000) to decrease bleeding. The horizontal incisions are then deepened through the internal perichondrium. The arytenoid cartilage or vocal process may be included in the dissection. The thyroid cartilage adjacent to the cordal tumor is also included with the specimen, thereby bisecting the thyroid ala horizontally. Care is taken to include the ventricular mucosa and sacculus, even when the superior incision is through the ventricular level. A 3- to 4-mm rim of cartilage is left on the superior and inferior portions, or both of the bisected alar margins, to provide more bulk for a neocord following imbrication, providing the depth of tumor invasion does not preclude retention of the cartilage. A pocket is then created by dissecting soft tissue from the superior cartilage in the subperichondrial plane and may extend to the thyrohyoid membrane. This may also be done on the inferi-

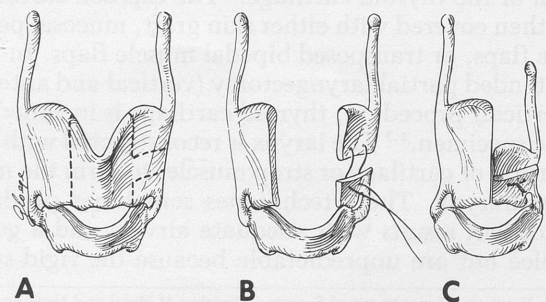
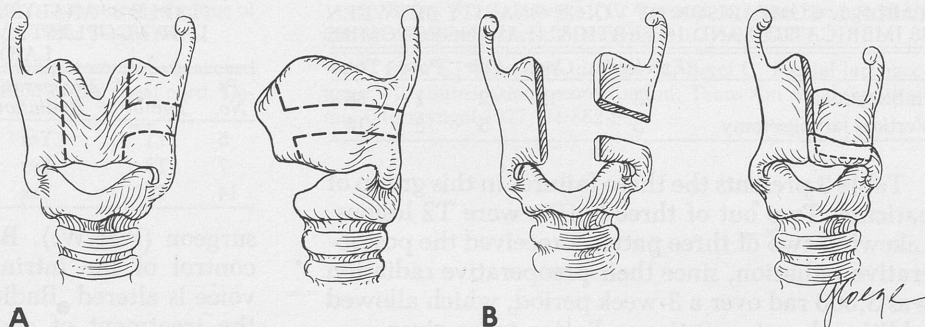


Fig 2. Excision of cartilage. A) Preresection. B) Holes are drilled and wire passed as illustrated (postresection wiring). C) Wire is tightened and cartilages and soft tissues imbricate.

Fig 3. Extended T resection for lesions extending into anterior commissure. A) T-shaped area of through-and-through resection, and B) postresection imbrication.



or cartilage portion in the subglottic cricoid area when the entire lower thyroid alae cartilage is resected. The superior and inferior cartilaginous halves are then imbricated so that primary soft tissue approximation is possible (Fig 1).

The laryngeal tissues are elastic, and no difficulty has been encountered in mobilization. Drill holes are placed through the apposed thyroid cartilage remnants, and permanent stainless steel wire or nylon sutures are used to keep them permanently imbricated (Fig 2). Closure of muscle and mucosa is now possible with little or no tension on the suture line. At least a 5-mm width of inferior thyroid cartilaginous strip is preserved when possible for imbrication with the upper strip. The anterior portions of the neocord and the contralateral cord are sutured to the external perichondrium to help prevent web formation. The use of stents and keels has not been necessary. Removal of the tracheostomy and oral feeding are usually possible within 7 days postoperatively.

Imbrication laryngoplasty has been modified to include combination with the anterior commissure technique of partial laryngectomy when the cordal lesion involves or extends beyond the anterior commissure.⁶⁻⁸ A T-shaped segment of laryngeal cartilage and full-thickness tissue is removed, the cross-bar of the T being the anterior commissure (Fig 3). The tumor may extend subglottically in the anterior commissure region to the inferior margin of the thyroid ala (1 cm below the anterior commissure) since the entire vertical strip of the ala is taken in the anterior commissure region.

Aspiration has been minimal even when the procedure was extended to include unilateral arytenoidectomy. The results are comparable to those reported by Bailey and Calcaterra⁸ of 31 patients who had bipedicle sternohyoid muscle flap laryngoplasty technique. None of these complained or had evidence of significant postoperative aspiration. The minimal aspiration in our series may be partially secondary to preservation of the superior laryngeal nerve as well as by the creation of a bulky neocord posteriorly with the imbrication technique.

The imbrication technique, while technically more difficult, appears superior to previous attempts at

replacement of cord bulk using sternohyoid muscle, tendon of the omohyoid, free cartilage, and a composite graft of thyroid cartilage and inferior constrictor muscle.

To date, 38 patients have undergone through-and-through resection and imbrication laryngectomy. The first case is now 16 years at risk, although most of the cases have been operated on during the past 9 years.

In several cases, the resection extended from the false cord to the cricoid. Only the medical imbrication technique is now utilized.

RESULTS

As seen in Table 1, there were 38 patients undergoing imbrication laryngoplasty. Eleven of these patients were previously reported.⁹ The majority (24 of 38) were T1 lesions with 14 T2 lesions. There were only three patients with fair or poor postoperative voices. The remaining patients achieved good to excellent voice on subjective analysis.

Table 2 compares the voices of patients who have undergone imbrication laryngectomy as opposed to vertical laryngectomy; all were performed by or under the supervision of one of the authors (P.H.W.). The results are varied and, in all but three cases of imbrication laryngectomy, there was good to excellent voice quality. With vertical laryngectomy, the range was from poor (three of 16) to fair (five of 16) to good (five of 16) to excellent (three of 16).

As anticipated, the lesser procedure with preservation of the arytenoid, homolateral cartilages provided better voices. The extended resections, including the signet of the cricoid cartilage, may explain some of the less satisfactory voices obtained with vertical hemilaryngectomies. The series is biased further because some of the patients for whom an imbrication was planned had their operations converted to more extended vertical hemilaryngectomies.

TABLE 1. POSTOPERATIVE VOICE IN 38 PATIENTS UNDERGOING IMBRICATION LARYNGOPLASTY

Glottic	Excellent	Good	Fair	Poor	Total
T1	14	9	1	0	24
T2	9	3	1	1	14

TABLE 2. COMPARISON OF VOICE QUALITY BETWEEN 38 IMBRICATION AND 16 VERTICAL LARYNGECTOMIES

	Excellent	Good	Fair	Poor	Total
Imbrication	23	12	2	1	38
Vertical laryngectomy	3	5	5	3	16

Table 3 presents the three failures in this group of patients. Two out of three lesions were T2 lesions. Likewise, two of three patients received the postoperative radiation, since their preoperative radiation was 3,500 rad over a 3-week period, which allowed additional postoperative radiation to be given.

There was no significant difference in the time of decannulation between the radiated and nonradiated patients. Aspiration was minimal in all patients. Two patients had thyroid cartilage perichondritis requiring treatment with intravenous antibiotics. There were no surgical or short-term mortalities. One patient died 6 years postoperatively of carcinoma of the lung, which was considered as a second primary.

DISCUSSION

As the scope of partial laryngeal surgery has increased to encompass cancers previously treated by total laryngectomy, emphasis has necessarily been placed on reconstruction of the larynx. Through-and-through partial laryngectomy with imbrication laryngoplasty represents extension of partial laryngectomy to achieve the following three goals of the laryngeal reconstruction: 1) maintenance of an adequate lumen to permit respiration without tracheostomy, 2) restoration of sphincteric competence during deglutition in order to avoid aspiration, and 3) reconstruction of a vibrating mechanism that allows vocal cord remnants to produce sound approximating the normal speaking voice.

Particular attention is devoted to sparing the internal and external branches of the superior laryngeal nerve. The intact sensory innervation supplied by the intact internal branch and residual tilting and tensing action from contraction of the cricothyroid muscle, with intact innervation by the external branch of the superior laryngeal nerve, provides a more functional larynx and protects from aspiration.

The present series demonstrates that the motion achieved by this technique produced an almost normal-appearing larynx with a remarkably strong and clear voice, better than that achieved by most partial vertical laryngectomies performed by the same

TABLE 3. ANALYSIS OF THREE FAILURES OF LARYNGOPLASTY WITH SUBSEQUENT TOTAL LARYNGECTOMY

Pt No.	Tumor	Preoperative Radiation	Localization of Lesion	Reasons and Observation
5	T1	Yes	Neocord	Smoking again
7	T2	Yes	Neocord	Margin tumor
14	T2	Yes	Other cord	Second cancer

surgeon (P.H.W.). Because of the loss of delicate control of the intrinsic musculature, the singing voice is altered. Radiotherapy thus continues to be the treatment of choice for T1 glottic lesions in singers and professional voice users, although it may result in damage to the voice secondary to edema. This technique was originally devised and is sometimes still used as an alternative to radiation for early lesions (specifically when patients reject radiation). Imbrication laryngoplasty has not totally replaced radiation because the postoperative voice is still unpredictable and is not uniformly as good as the normal voice achieved in 80% to 90% of the radiated cases.

A number of patients elect surgical resection and healing within a couple of weeks in preference to extended 6- to 7-week daily radiation treatments. Surgical resection is not only preferred, but probably is indicated in young people with carcinoma of the larynx, thereby avoiding radiation exposure. Surgery is a better selection than radiation in the unreliable alcoholic or drug addict who is noncompliant and unable to complete sequential radiation treatments. In some of these patients, there is limited chance for follow-up, and surgical resection is the only one-shot opportunity to eradicate the disease.

The new technique is simple but not easy. It requires greater manual dexterity and takes slightly more time than conventional vertical or anterovertical laryngectomy. The advantages of the bulk provided by the patient's own vascularized and innervated tissue far outweigh the disadvantages. When placed into the pocket created in the mucosa, the false cord and aryepiglottic fold make an excellent neocord directly opposing the normal true cord. Retaining the arytenoid when possible gives an even better voice.

Through-and-through resection of mucosa, tumor, soft tissue, adjacent perichondrium, and thyroid cartilage with imbrication reconstruction represents a significant and logical advancement in the management of patients with T1 and T2 glottic carcinoma and is of particular value in those cases with anterior commissure extension.

REFERENCES

1. Som ML. Cordal cancer with extension to the vocal process. *Laryngoscope* 1975; 85:1298-307.
2. Kirchner J, Som M. Clinical significance of fixed vocal cord. *Laryngoscope* 1971; 81:1029-44.
3. Kirchner J. Hemilaryngectomy for cancer of the vocal cord fixation. In: Kagan AR, Miles JW, eds. *Head and neck oncology*. Controversies in cancer treatment. Boston: GK Hall Medical Publishers, 1981:25-37.
4. Wang CC. Cancer of the larynx: radiation therapy. *CA* 1976; 26:212-8.
5. Biller HF, Ogura JH, Pratt LL. Hemilaryngectomy for T2 glottic cancers. *Arch Otolaryngol* 1971; 93:238-43.

6. Som ML, Silver CE. The anterior commissure technique of partial laryngectomy. Arch Otolaryngol 1968; 87:138-45.
7. Biller HF, Lawson W. Partial laryngectomy for vocal cord cancer with marked limitation or fixation of the vocal cord. Laryngoscope 1986; 96:61-4.
8. Bailey BJ, Calcatera TC. Vertical, subtotal laryngectomy and laryngoplasty. Arch Otolaryngol 1971; 93:232-7.
9. Pleet L, Ward PH, deJager H, Berci C. Partial laryngectomy with imbrication reconstruction. Trans Am Acad Ophthalmol Otolaryngol 1977; 84:882-99.

LONG-TERM RESULTS OF CONCURRENT POLYCHEMOTHERAPY AND RADIOTHERAPY IN PATIENTS WITH STOMAL RECURRENCE AFTER TOTAL LARYNGECTOMY

A. J. M. BALM, MD, PhD

R. J. J. VERSLUIS, MD

G. B. SNOW, MD, PhD

K. H. NJO, MD

A. B. M. F. KARIM, MD, PhD

R. M. TIWARI, FRCS, PhD

AMSTERDAM, THE NETHERLANDS

From 1978 through 1985, eight patients with stomal recurrence after total laryngectomy were treated with a combination of a cytotoxic regimen (vincristin sulfate, bleomycin, and methotrexate [VBM]) and radiotherapy. The essential feature of this combination is the synchronous administration of pulses of VBM and fractionated doses of external radiotherapy in order to achieve potentiation of radiotherapy. On average, four to five pulses of VBM were given. Severe mucositis is the main problem during treatment. Two patients needed nasogastric tube feeding, and treatment was carried out as an inpatient procedure. Five patients are alive with complete local remission at 7 years, 3 years, 2½ years, 14 months, and 8 months after treatment. These results appear to be spectacular, even though the number of patients is small. Of the three patients who died, only one had recurrent disease around the tracheostoma. The two other patients were free of disease in the neck when they died 6 and 16 months after treatment of, respectively, lung metastases and a second primary tumor in the lung. Patients with stomal recurrence after total laryngectomy are now routinely treated with synchronous VBM and radiotherapy.

KEY WORDS — polychemotherapy, radiotherapy, stomal recurrence.

INTRODUCTION

Stomal recurrence (SR) after total laryngectomy is considered to have an ominous prognosis. Without any form of therapy it leads to progressive tracheostomal obstruction or massive hemorrhage. Despite aggressive surgical therapy^{1,2} or high dose irradiation,³ prognosis is not substantially improved in older patients.

In 1965 Keim et al⁴ published their first study dealing with SRs and defined this disease as "a diffuse infiltrate of neoplastic tissue at the junction of the amputated trachea and the skin." In their description they extended the definition to include recurrence of tumor in areas adjacent to the stoma. In addition, Batsakis et al⁵ have pointed out that it is impossible to differentiate recurrent peristomal primary tumor from a metastasis replacing a paratracheal lymph node.

The incidence of postlaryngectomy tracheostomal cancer recurrence has been reported in the literature to range from 3.0% to 14.7% with an average of 7.5%.⁶ Several predisposing factors have been published in the pathogenesis of SR. The most prominent seems to be the subglottic extension of the tumor. Mantravadi et al⁷ reported a fivefold increase in the SR rate of patients who had initial subglottic involvement. Contrasting opinions have been published as to the relation between emergency tracheostomy and SR. Some authors reported high incidence rates of stomal recurrence in cases of emergency tracheostomy (40.9%⁴ and 22.0%⁸), whereas

opinions to the contrary were expressed by others.^{7,9,10} Previous conservative surgery has also been mentioned as a risk factor for the development of SR,^{11,12} but Stell and van den Broek¹³ and Weisman et al¹⁴ did not find any association. The involvement of paratracheal lymph nodes, particularly in subglottic tumors, has also been suggested as a main risk factor in the development of SR.^{15,16} It is needless to say that prevention of SR is highly desirable. In this respect it is generally accepted that both paratracheal lymph node chains must be radically resected when a total laryngectomy is performed for carcinomas of the subglottic and glottic larynx. Furthermore it is reported that elective irradiation of the stomal area in high risk patients is indeed an effective means of preventing SR.^{7,17,18}

Treatment of SR is almost invariably unsuccessful. Some improvement of survival has been described only following wide resection of SRs employing mediastinotomy. In 1977 Sisson et al² cited a 5-year survival rate of 17% after wide mediastinal dissection of SR. However, patients who were not selected as candidates for surgery were not included in the survival statistics. The results of radiotherapy alone for SR are discouraging and may only contribute to palliation of the disease.^{3,7} Chemotherapeutic agents have been applied only in some instances — sometimes in combination with radiotherapy — and have resulted only in a temporary regression of tumor^{13,19}; but long-term survival could never be achieved.

In this article we present the results of the treat-

From the Departments of Otolaryngology-Head and Neck Surgery (Balm, Snow, Versluis, Tiwari) and Radiotherapy (Karim, Njo), Free University Hospital, Amsterdam.

Presented at the meeting of the American Laryngological Association, Palm Beach, Florida, May 4-5, 1986.

REPRINTS — G. B. Snow, MD, PhD, Dept of Otolaryngology-Head and Neck Surgery, Free University Hospital, de Boelelaan 1117, 1081 HV Amsterdam, The Netherlands.

PATIENT DATA

Patient*	Age	Initial Site, Staging, Histology	Extent of Surgery	Mo Between TL and SR	Treatment of SR	Follow-Up After Treatment
1	58	Glottic/supraglottic L, T3N0M0, mod. diff. SCC	TL/HTh/TT	23	5 pulses VBM s 6,000 cGy in 39 d	Died 6 mo after treatment from distant metastases; CLR
2	61	Transglottic L, T3N0M0, well diff. SCC	TL/HTh/PET	18	4 pulses VBM s 6,200 rad in 51 d	Alive 7 yr after treatment; CLR
3	55	Pyriiform sinus L, T3N1M0, well diff. SCC	TL†/HTh/ND/TT	10	Cisplatin + 2 pulses VBM s 6,575 cGy in 36 d	Died 16 mo after treatment from 2nd primary in lung; CLR
4	43	Massive recurrent tumor after prior irradiation, well diff. SCC	TL/TTh/ND/EI	9	5 pulses VBM s 4,680 cGy in 41 d	Alive 2½ yr after treatment; lung metastases; CLR
5	69	Supraglottic, T4N0M0, mod. diff. SCC	TL/HTh/ND/EI	5	5 pulses VBM s 5,900 cGy in 56 d	Alive 3 yr after treatment; CLR
6	61	Transglottic R, T3N0M0, mod. diff. SCC	TL/HTh/ND/EI	6	3 pulses VBM + 2 pulses BM s 5,300 cGy in 49 d	80% regression of SR; died 8 mo after treatment from SR
7	50	Recurrent tumor after prior irradiation, well diff. SCC	TL/HTh/EI	16	5 pulses VBM s 5,940 cGy in 51 d	Alive 14 mo after treatment; CLR
8	63	Recurrent tumor after prior irradiation, varying degree of differentiation	TL/HTh/EI	32	4 pulses VBM s 6,200 cGy in 42 d	Alive 8 mo after treatment; CLR

B — bleomycin; CLR — complete local remission; EI — endotracheal intubation; HTh — hemithyroidectomy; M — methotrexate; mod. diff. — moderately differentiated; ND — neck dissection (radical — en bloc); PET — preoperative emergency tracheostomy; s — administered synchronously with; SCC — squamous cell carcinoma; SR — stomal recurrence; TL — total laryngectomy; TT — temporary tracheostomy at start of operation; TTh — total thyroidectomy; V — vincristin sulfate.

*All patients were men.

†With partial pharyngectomy.

ment of SR with the combination of a cytotoxic regimen using vincristin, bleomycin, and methotrexate (VBM) and fractionated doses of external radiotherapy according to the scheme published by O'Connor et al.²⁰

PATIENTS

From 1976 to 1985, 220 patients underwent total laryngectomy for cancers of the larynx and the laryngopharynx. A total of ten patients returned with recurrent cancer at the stomal site, an overall incidence of 4.5%. Two patients were treated by wide excision at the site of recurrence. Eight patients were treated by concurrent polychemotherapy and radiotherapy according to the scheme published by O'Connor et al.²⁰

From this last group of eight patients, five underwent primarily a total laryngectomy for T3-T4 carcinomas of the larynx. Three patients had total laryngectomy for recurrent carcinoma after radiotherapy. Patient 4 received prior radiotherapy for a T1 glottic carcinoma on the left side (6,600 cGy, tele-Cobalt), patient 7 for a T2 glottic carcinoma on the right (7,000 cGy, Megavolt) and patient 8 for a T1 supraglottic carcinoma on the left (7,000 cGy, Megavolt). In one patient (case 2), preoperative emergency tracheostomy was performed 1 month before total laryngectomy. In two patients a temporary tracheostomy was done under local anesthesia at the start of the operation. The other five patients had endotracheal intubation at the time of operation. As can be seen from the Table, hemithyroidectomy was done as a routine procedure during laryngectomy. In case 4 a total thyroidectomy and para-

thyroidectomy were performed because of massive tumor invasion into the thyroid gland. In this case the hypothyroidism and parahypothyroidism were managed by a supplement of calcium and levothyroxine sodium. Subglottic extension was seen in three cases.

The disease-free interval between primary surgery and diagnosis of tracheostomal recurrence varied from 5 to 32 months.

The location of the recurrent tumor around the circumference of the tracheostomy stoma was analyzed. In three cases the recurrent neoplasm was on the same side as the primary tumor. It was on the contralateral side in another three cases. The tumor was only located at the superior aspect of the stoma in the remaining two patients, whereas in three instances cranial extension from the lateral recurrences was observed. In six cases (patients 1, 3, 4, 6, 7, and 8), skin overlying the tumor was intact, and diagnosis of carcinoma was made by needle aspiration cytology. Exact information about grading could not be obtained from the aspiration cytology material. In cases 2 and 5, biopsies were taken from the peristomal ulcerating defect, and in these cases the histology was identical to the primary tumor.

The nutritional status of all patients at the start of therapy was within normal limits. The scores on the Karnofsky scale varied from 50% to 90%.

METHODS

Cytotoxic Treatment. The VBM regimen used for these patients is outlined below. Initially 2 mg of vincristin was given intravenously (IV), and 6 hours

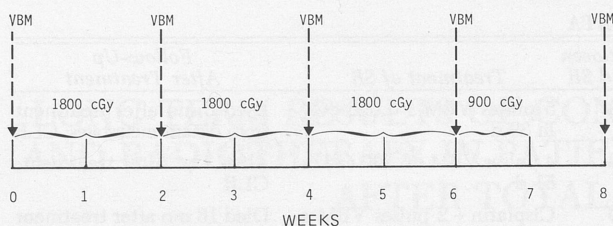


Fig 1. VBM-radiotherapy protocol.

later 30 mg of bleomycin was administered intramuscularly (IM). At 24 hours, a 200-mg IV infusion of methotrexate in 1,000 mL of saline was given over the next 24 hours. Leucovorin rescue commenced at 48 hours with 15 mg IV of folinic acid (leucovorin) followed by 15 mg IM every 6 hours for four doses. The total amount of leucovorin given to our patients was lower than that advocated by O'Connor et al.²¹ The patients were reassessed with blood counts and creatinine monitoring before starting each course of VBM. In six of eight cases, four to five courses of VBM could be completed. In case 3, cisplatin was given initially in combination with radiotherapy, but because of the severe toxic reactions after the administration of cisplatin, this drug could not be used for further therapy. In the event of neurotoxicity (case 6), vincristin was omitted after three pulses of VBM.

Because of toxic reactions in the treatment area, some patients had to be rested from treatment for up to 2 weeks to allow severe reactions to subside before completion of the treatment. Nasogastric feeding was necessary in two patients.

Radiotherapy. A full course of Megavolt therapy (considered as 5,900 to 6,500 rad) was given in approximately 6 to 7 weeks, usually in daily fractions of 180 cGy. In case 4, however, the maximum dose was 4,680 cGy in 41 days, because of prior radiotherapy (6,600 rad, tele-Cobalt) for his glottic carcinoma. Vincristin, bleomycin, and methotrexate were usually given combined with radiotherapy as follows. One VBM course was given before radiotherapy was commenced and another after completion of radiotherapy. Three further pulses of VBM were given during the radiotherapy — preferably on the weekends — at 2-week intervals. Radiotherapy was interrupted during the drug administration (Fig 1).

RESULTS

The findings, treatment, and results are summarized in the Table. In three cases (patients 1, 2, and 3), complete local tumor regression was achieved after only two to three pulses of VBM, whereas in cases 4, 5, 7, and 8 the malignant neoplasm disappeared completely after completion of four to five courses of the multidrug combination (Fig 2). However, in case 4 a considerable regression could already be observed after one course of VBM. In one patient (case 6) the maximum of tumor regres-

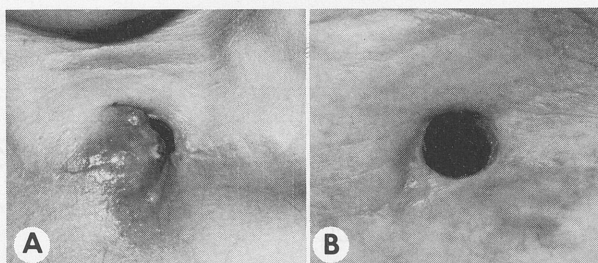


Fig 2. (Case 4). Stomal recurrence A) before and B) after treatment with combination of VBM and radiotherapy.

sion, which occurred after completion of VBM and radiotherapy, did not exceed 80%. This patient died 8 months after treatment with recurrent disease around the tracheostoma.

Intensified epithelial reactions due to combined treatment were observed in all cases, but they were not followed by unusual long-term damage to the normal tissue. Severe bone marrow depression did not occur during treatment.

Maintained complete remission of local disease was seen in seven patients. Four of these patients were alive 7 years, 3 years, 14 months, and 8 months after therapy, with no evidence of disease. Another patient was alive 2½ years after treatment, but had slowly growing lung metastases. Two patients died from distant metastases and a second primary tumor in the lung 6 and 16 months respectively, after successful treatment of their stomal recurrence.

DISCUSSION

Our data clearly demonstrate that the combined radiotherapy and VBM cytotoxic regimen can induce substantial regression of tracheostomal cancer recurrence after total laryngectomy. Complete regression of SR was achieved in seven of eight patients, and in one patient (case 6) a response rate of 80% was observed. These results appear to be spectacular even though the number of patients is small. It may also be emphasized that complete local remission was achieved even when the patient had been treated before with radiotherapy in the area.

O'Connor et al²¹ have published their 4-year results with this combined treatment in stage III and stage IV head and neck cancer patients and were able to achieve an 88% complete response rate in the combined modality group, versus only 58% in the radiation controls (the projected 4-year disease-free survival rates were 57% and 22%, respectively). Their and our results indicate that addition of cytotoxic drugs such as VBM can actively supplement the curative effects of radiotherapy in head and neck cancer when given in a stathmokinetic way.

Our study has also shown that acute epithelial reactions are more intense with combined VBM and radiotherapy than with radiotherapy alone. Results suggest that this type of treatment must be applied as an inpatient procedure with close patient super-

vision. However, the problem of enhanced acute mucosal and skin reactions encountered at the end of each treatment volume did not lead to any long-term damage to normal tissues in the treatment areas.

This brief report indicates that there is significant potential for concurrent polychemotherapy and radiotherapy as treatment for SRs after total laryngectomy. It is hoped that our favorable results will be reproduced by others in larger series.

REFERENCES

1. Sisson GA. Mediastinal dissection for recurrent cancer after laryngectomy. *Trans Am Acad Ophthalmol Otolaryngol* 1970; 74:767-77.
2. Sisson GA, Bytell DE, Becker SP. Mediastinal dissection — 1976: indications and newer techniques. *Laryngoscope* 1977; 87: 751-9.
3. Gunn WG. Treatment of recurrent cancer at the tracheostome. *Cancer* 1965; 18:1261-4.
4. Keim WF, Shapiro MJ, Rosin HD. Study of postlaryngectomy stomal recurrence. *Arch Otolaryngol* 1965; 81:183-6.
5. Batsakis JG, Hybels R, Rice DH. Laryngeal carcinoma: stomal recurrences and distant metastases. *Can J Otolaryngol* 1975; 4:906-16.
6. Davis RK, Shapsay SM. Peristomal recurrence: pathophysiology, prevention, treatment. *Otolaryngol Clin North Am* 1980; 13:499-508.
7. Mantravadi R, Katz AM, Skolnik EM, Becker S, Freehling DJ, Friedman M. Stomal recurrence. A critical analysis of risk factors. *Arch Otolaryngol* 1981; 107:735-8.
8. Bonneau RA, Lehman RH. Stomal recurrence following laryngectomy. *Arch Otolaryngol* 1975; 101:408-12.
9. De Jong PC. Intubation and tumor implantation in laryngeal carcinoma. *Pract Oto-Rhino-Laryngol* 1969; 31:119-21.
10. Condon HA. Post-laryngectomy stomal recurrence: the influence of endotracheal anesthesia. *Br J Anaesth* 1969; 41:531-3.
11. Myers EM, Ogura JH. Stomal recurrence: a clinicopathological analysis and protocol for future management. *Laryngoscope* 1979; 89:1121-8.
12. Bignardi L, Gavioli C, Staffieri A. Tracheostomal recurrences after laryngectomy. *Arch Otorhinolaryngol* 1983; 238: 107-13.
13. Stell PM, van den Broek P. Stomal recurrence after laryngectomy: etiology and management. *J Laryngol Otol* 1971; 85:131-40.
14. Weisman RA, Colman M, Ward PH. Stomal recurrence following laryngectomy. A critical evaluation. *Ann Otol Rhinol Laryngol* 1979; 88:855-60.
15. Norris CM. Causes of failure in surgical treatment of malignant tumors of the larynx. *Ann Otol Rhinol Laryngol* 1959; 68:487-508.
16. Harrison DFN. Laryngectomy for subglottic lesions. *Laryngoscope* 1975; 85:1208-10.
17. Schneider JJ, Lindberg RD, Jesse RH. Prevention of tracheal stomal recurrence after total laryngectomy by postoperative irradiation. *J Surg Oncol* 1975; 7:187-90.
18. Tong D, Moss WT, Stevens KR Jr. Elective irradiation of lower cervical region in patients at high risk for recurrent cancer at tracheal stoma. *Radiology* 1977; 124:809-11.
19. Modlin B, Ogura JH. Post-laryngectomy tracheal stomal recurrences. *Laryngoscope* 1969; 79:239-50.
20. O'Connor AD, Clifford P, Durden-Smith DJ, Edwards W, Hollis BA, Dalley VM. Synchronous VBM and radiotherapy in the treatment of squamous cell carcinoma of the head and neck. *Clin Otolaryngol* 1977; 1:347-57.
21. O'Connor AD, Clifford P, Dalley VM, Durden-Smith DJ, Edwards WG, Hollis BA. Advanced head and neck cancer treated by combined radiotherapy and VBM cytotoxic regimen — four-year results. *Clin Otolaryngol* 1979; 4:329-37.

POSTERIOR GLOTTIS

MORPHOLOGICAL STUDY IN EXCISED HUMAN LARYNGES

MINORU HIRANO, MD
KENSUKE KIYOKAWA, MD

SHIGEJIRO KURITA, MD
KIMINORI SATO, MD

KURUME, JAPAN

Two sets of investigations were conducted with excised human larynges. 1) The glottis was closely observed and photographed from above and below in three conditions: neutral, adduction, and abduction. 2) The structure surrounding the posterior glottis was histologically investigated in the same three conditions. The results are as follows. 1) The structure surrounding the posterior glottis consists of three portions: the posterior wall of the glottis, the lateral wall of the posterior glottis, and the cartilaginous portion of the vocal fold. 2) During vocal fold adduction, the posterior part of the larynx closes completely not at the glottis but at the supraglottis, resulting in formation of a conic space in the posterior glottis that can be viewed only from below. 3) The posterior glottis accounts for approximately 35% to 45% of the entire glottic length and 50% to 65% of the entire glottic area. 4) The mucosa of the posterior glottis has ciliated epithelium. The lamina propria consists of two layers. 5) The posterior glottis can be regarded as a respiratory glottis.

KEY WORDS — glottis, posterior glottis.

INTRODUCTION

The glottis consists of two parts: the intermembranous portion, or the anterior glottis, and the intercartilaginous portion, or the posterior glottis. The border of the two is defined by a line between the tips of the bilateral vocal processes. There have been numerous investigations of the anatomy and physiology of the anterior glottis. In contrast, the posterior glottis has been studied very little. Moreover, there has been considerable disagreement about terminology used to refer to some structures around the posterior glottis,¹ while yet other structures have not been named, identified, or described. The lack of interest in the posterior glottis may be attributed to two major factors. 1) The posterior glottis in many patients is not entirely exposed under a laryngeal mirror. Therefore, many laryngologists have limited opportunities to observe the structure and behavior of the posterior glottis very closely. 2) Diseases develop much more frequently in the anterior glottis than in the posterior glottis.

Recently, fiberscopes have been used in routine procedures at many laryngology clinics. As a result, many laryngologists have frequent opportunities to examine the morphology and physiology of the posterior glottis in daily practice, disclosing diseases of the posterior glottis more frequently than before. This change in practice and diagnosis of disease has motivated a series of investigations of the anatomy and physiology of the posterior glottis. This paper describes results of our current morphological studies with excised human larynges.

MATERIALS AND METHODS

The following two sets of investigations were con-

ducted with excised normal adult human larynges.

PHOTOGRAPHIC OBSERVATIONS AND MEASUREMENTS

A total of 20 larynges obtained from autopsy cases were used. Of the 20, ten were from men with ages ranging from 41 to 77 and a mean of 59 years, and ten were from women with ages ranging from 48 to 91 and a mean of 66 years. The larynges were fixed to a supporting frame at the cricoid cartilage. The epiglottis and the false folds were removed in order to expose the glottic structure. The location of the anterior commissure, the tip of the vocal processes, the posterior end of the laryngeal ventricles, and the midpoint of the posterior wall of the glottis were marked with a small triangular piece of black paper. A scale was placed on one vocal fold for the purpose of measurement calibration.

The laryngeal specimens were then closely observed and photographed from above and below under the following three conditions.

Neutral Condition. No force was applied to the laryngeal structure. The vocal folds were placed in the so-called cadaveric position. There were marked individual differences in the angle of the bilateral vocal folds at the anterior commissure.

Vocal Fold Adduction. The muscular processes of the bilateral arytenoid cartilages were pulled by thread in the direction of the combined force of the lateral cricoarytenoid and thyroarytenoid muscles, ie, anteromedioinferiorly. The vocal folds were positioned in the median position.

Vocal Fold Abduction. The muscular processes of the bilateral arytenoid cartilages were pulled by

From the Department of Otolaryngology-Head and Neck Surgery, Kurume University, School of Medicine, Kurume, Japan.

Presented at the meeting of the American Laryngological Association, Palm Beach, Florida, May 4-5, 1986.

REPRINTS — Minoru Hirano, MD, Dept of Otolaryngology-Head and Neck Surgery, Kurume University School of Medicine, 67 Asahi-machi, Kurumeshi, 830 Japan.

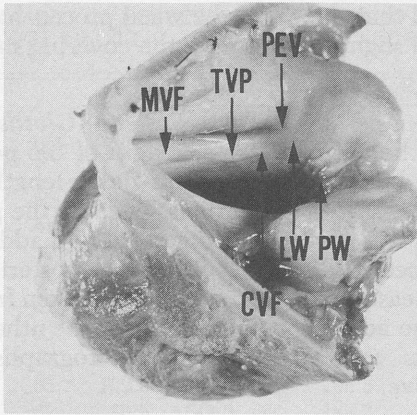


Fig 1. Structure around glottis. PW — posterior wall of glottis, LW — lateral wall of posterior glottis, PEV — posterior end of ventricle, CVF — cartilaginous portion of vocal fold, TVP — tip of vocal process, MVF — membranous portion of vocal fold.

thread in the direction of the force of the posterior cricoarytenoid muscle, ie, posteromedioinferiorly, fully abducting the folds. The angle of the bilateral vocal folds at full abduction differed markedly from larynx to larynx.

Results were obtained on the basis of close observations during the experiments and measurements on the photographs. On the photographs, we measured the anteroposterior length and area of the posterior glottis as well as the length and area of the entire glottis.

HISTOLOGICAL INVESTIGATION

A total of 28 normal larynges obtained from autopsy cases were used. Of the 28, 14 were from men aged 44 to 95 (mean 62 years), while the other 14 were from women aged 37 to 81 (mean 60 years). Horizontal serial sections were made with 18 larynges: ten in the neutral condition, four during vocal fold adduction, and four during vocal fold abduction. Coronal or frontal sections were made with seven larynges: six in the neutral condition and one during vocal fold adduction. With three larynges, sagittal sections were made in the neutral condition. Hematoxylin-eosin and elastica-van Gieson's stains were employed for each section.

RESULTS

MACROSCOPIC STRUCTURE OF POSTERIOR GLOTTIS

Neutral Condition. The posterior glottis was surrounded by a U-shaped structure, which could be divided into posterior and bilateral lateral aspects (Fig 1). There is no accepted anatomic terminology for these structures.

The posterior aspect presented an appearance of a vertical wall. The base of this structure was the top-most part of the lamina of the cricoid cartilage. We call this structure the posterior wall of the glottis.

The lateral aspect could be divided into two parts, which were bordered at the posterior end of the laryngeal ventricle. The part posterior to this border had a wall-like appearance. The base of this structure was the medial facet of the arytenoid cartilage. We call this structure the lateral wall of the posterior glottis. The part anterior to the posterior end of the ventricle presented the shape of a lip or a fold and looked like a continuation of the membranous vocal fold. The base of this structure was the vocal process of the arytenoid cartilage. We call this structure the cartilaginous portion of the vocal fold.¹ It should be noted that the bilateral vocal folds form a commissure at the anterior end but never at the posterior end.

Vocal Fold Adduction. As the adductory force was applied and increased, the anterior glottis closed first (Fig 2A). With a further increase in the force, the posterior part of the larynx also closed (Fig 2B). When the larynx was viewed from above, the posterior glottis was partly covered by the arytenoid eminences and could not be viewed. When the larynx was viewed from below during vocal fold adduction, there was a conic space in the posterior glottis (Fig 2C). In other words, the posterior part of the larynx was closed completely not at the level of the glottis but at the level of the supraglottis. There was a diagonal band of closure running posterosuperiorly from the base of the vocal process to the top of the arytenoid eminence.

The tip of the vocal process was located slightly medial and posterior to the paper mark placed on

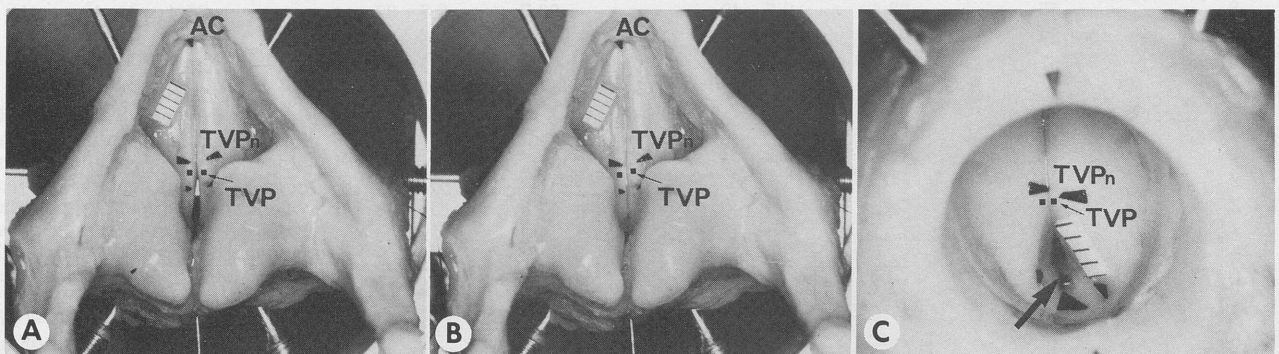


Fig 2. Glottis during vocal fold adduction. A) View from above during adductory force. B) View from above during increased force. AC — anterior commissure. C) View from below. Note conic space (large arrow) in posterior glottis. TVPn — tip of vocal process in neutral condition, TVP — tip of vocal process.

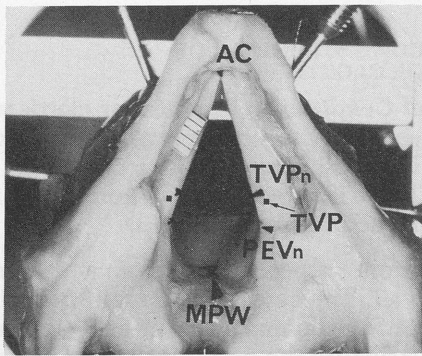


Fig 3. View of glottis from above during vocal fold abduction. AC — anterior commissure, TVPn — tip of vocal process in neutral condition, TVP — tip of vocal process, PEVn — posterior end of ventricle in neutral condition, MPW — midpoint of posterior wall.

the covering mucosa in the neutral condition. This indicated that the tip of the vocal process had been adducted to a slightly greater extent than the covering mucosa.

Vocal Fold Abduction. When the vocal folds were fully abducted, the glottis took on a roughly pentagonal shape (Fig 3). The posterior trapezoid of the pentagon was primarily located in the posterior glottis. The tip of the vocal process was located slightly anterolateral to the corner between the anterior triangle and the posterior trapezoid of the pentagon.

The tip of the vocal process was located slightly lateral and posterior to the paper mark placed on the covering mucosa in the neutral condition. This

indicated that the tip of the vocal process had been abducted slightly more than the covering mucosa.

DIMENSION

Anteroposterior Length of Posterior Glottis. Table 1 shows the anteroposterior length of the posterior glottis and its ratio to the entire glottic length in the three experimental conditions. Because the posterior glottis was covered during vocal fold adduction, as described earlier, the length of the posterior glottis was measured on the photographs taken from below in the adduction condition. All the other measurements were made on the photographs taken from above.

In the neutral condition, the length of the posterior glottis ranged from 8.1 to 10.8 mm with an average of 9.5 mm in men and from 5.1 to 7.9 mm with an average of 6.8 mm in women. It accounted for 35% to 41% (39% on the average) of the entire glottic length in men and 34% to 46% (42% on the average) in women. The absolute values of the length were greater in men than in women ($p < 0.01$), but the ratio did not differ significantly between the two sexes.

During vocal fold adduction, the length of the posterior glottis became shorter than that in the neutral condition in all cases. It ranged from 7.2 to 9.6 mm with an average of 8.2 mm in men and from 4.5 to 6.6 mm with an average of 5.7 mm in women, demonstrating significant differences between the two sexes ($p < 0.01$). The ratio of the length of the posterior glottis to the entire glottic length ranged from 30% to 37% (34% on the average) in men and 30% to 40% (36% on the average) in women.

TABLE 1. LENGTH OF POSTERIOR GLOTTIS AND ITS RATIO TO ENTIRE GLOTTIC LENGTH FOR LARYNGES IN THREE CONDITIONS

FOR ERRORS IN THREE CONDITIONS										
Case No.	Age	Neutral Condition			During Adduction			During Abduction		
		Entire (mm)	Posterior (mm)	(%)	Entire (mm)	Posterior (mm)	(%)	Entire (mm)	Posterior (mm)	(%)
Men										
1	57	22.5	8.1	36	23.7	7.2	30	24.0	9.6	40
2	41	27.0	10.7	40	27.3	8.6	32	26.8	10.4	39
3	51	23.8	8.8	37	24.3	7.8	32	25.5	10.8	42
4	65	22.8	9.4	41	22.1	8.0	36	23.5	9.7	41
5	61	25.5	8.9	35	25.3	7.7	30	27.3	9.9	36
6	53	24.8	9.9	40	23.8	8.2	34	25.5	9.9	39
7	77	28.0	10.8	39	27.5	9.6	35	28.8	11.1	39
8	55	23.5	9.5	40	23.7	8.7	37	25.4	10.4	41
9	62	22.7	8.8	39	22.3	7.8	35	22.6	8.2	36
10	67	24.6	9.7	39	23.9	8.7	36	25.4	9.8	39
Average	59	24.5	9.5	39	24.4	8.2	34	25.5	10.0	39
Women										
1	67	14.8	5.1	34	15.1	4.5	30	16.2	6.2	38
2	76	14.7	5.5	37	14.2	4.5	32	15.3	5.3	35
3	91	16.0	7.3	46	15.9	6.1	38	16.8	7.0	42
4	71	17.1	7.9	46	16.2	6.3	39	17.8	7.8	44
5	65	14.6	6.1	42	14.5	5.2	36	16.0	6.1	38
6	58	17.1	7.6	44	17.0	6.6	39	17.7	7.3	41
7	54	17.0	6.9	41	16.8	5.7	34	17.7	7.1	40
8	48	15.8	7.2	46	14.9	5.9	40	16.4	7.4	45
9	75	18.6	7.0	38	18.2	6.2	34	19.2	7.0	36
10	58	17.5	7.4	42	16.6	5.7	34	17.8	7.3	41
Average	66	16.3	6.8	42	15.9	5.7	36	17.1	6.9	40

TABLE 2. AREA OF POSTERIOR GLOTTIS AND ITS RATIO TO ENTIRE GLOTTIC AREA FOR LARYNGES IN TWO CONDITIONS

CONDITIONS							
Case No.	Age	Neutral Condition			During Abduction		
		Entire (mm ²)	Posterior (mm ²)	(%)	Entire (mm ²)	Posterior (mm ²)	(%)
Men							
1	57	43.6	26.3	60	145.8	83.1	57
2	41	92.1	45.9	50	224.0	128.2	57
3	51	51.6	30.9	60	170.3	103.3	61
4	65	59.5	36.5	61	138.0	82.6	60
5	61	76.3	38.9	51	151.1	85.1	56
6	53	114.8	73.6	64	240.9	147.0	61
7	77	100.7	51.5	51	143.6	77.6	54
8	55	102.0	52.6	52	192.5	115.9	60
9	62	80.5	42.3	53	139.3	78.6	56
10	67	75.0	47.0	63	177.7	108.7	61
Average	59	79.6	44.6	56	172.3	101.0	59
Women							
1	67	26.3	14.2	54	61.6	34.9	57
2	76	38.0	23.0	61	109.4	64.7	59
3	91	72.8	44.2	61	125.0	72.5	58
4	71	68.9	41.0	60	148.1	90.5	61
5	65	31.4	19.2	61	99.8	58.4	59
6	58	60.4	36.8	61	92.8	54.0	58
7	54	54.2	30.2	56	100.3	54.3	54
8	48	57.6	37.9	66	127.6	83.2	65
9	75	49.1	30.9	63	94.3	57.3	61
10	58	59.9	33.0	55	134.2	81.1	60
Average	66	51.9	31.0	60	109.3	65.1	59

to 40% (36% on the average) in women, demonstrating a decrease from the value in the neutral condition. The ratio did not differ significantly between men and women.

During vocal fold abduction, the length of the posterior glottis did not differ significantly from that in the neutral condition. The ratio of the length of the posterior glottis to the entire glottic length did not differ significantly either.

Area of Posterior Glottis. Table 2 shows the area of the posterior glottis and its ratio to the entire glottic area. In the neutral condition, the area of the posterior glottis ranged from 26.3 to 73.6 mm² (44.6 mm² on the average) in men and from 14.2 to 44.2 mm² (31.0 mm² on the average) in women, with both sexes showing great individual differences.

The individual differences were attributed not only to the differences in the length but also to the differences in the angle of the two vocal folds at the anterior commissure. The area of the posterior glottis was greater in men than in women ($p < 0.01$). The posterior glottis accounted for 50% to 64% (56% on the average) of the entire glottic area in men and 54% to 66% (60% on the average) in women. This ratio did not differ significantly between the two sexes.

During vocal fold abduction, the area of the posterior glottis was 77.6 to 147.0 mm² (101.0 mm² on the average) in men and 34.9 to 90.5 mm² (65.1 mm² on the average) in women. Again, the difference between the two sexes was significant ($p < 0.01$). The ratio of the area of the posterior glottis to that of the entire glottis ranged from 54% to 61% (59% on the average) in men and from 54% to 65% (59% on the average) in women. There was no significant difference in the ratio between men and women.

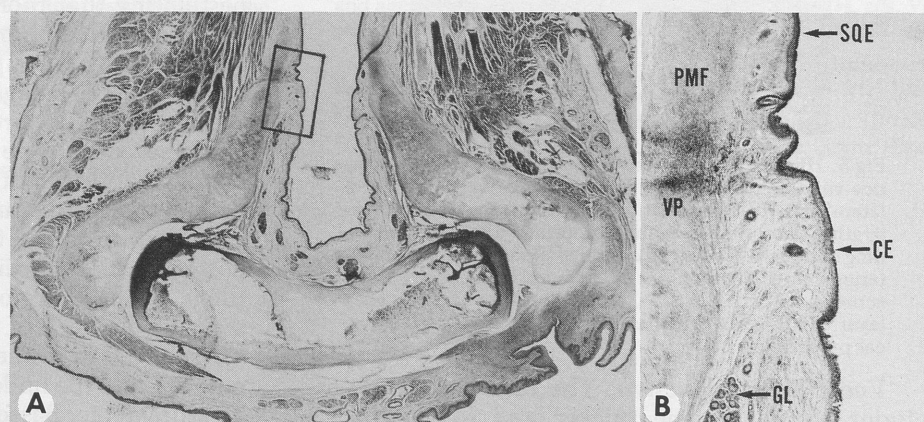
HISTOLOGICAL FINDINGS

Neutral Condition. Histologically, the structure around the posterior glottis consisted of the cartilage and the overlying mucosa (Figs 4 and 5).

The mucosa had pseudostratified ciliated epithelium in the posterior glottis. This was in contrast to the stratified squamous epithelium in the anterior glottis (Fig 4B). The lamina propria of the mucosa could be divided into two layers: the superficial and deep. The former was loose in structure, whereas the latter consisted of dense elastic and collagenous fibers and many glands. Many fibers in the deep layer ran vertically at the posterior wall of the glottis (Fig 5C), whereas most fibers ran in oblique directions at the lateral aspect of the posterior glottis (Fig 5B).

The underlying cartilage was the cricoid cartilage at the posterior wall and the arytenoid cartilage at the lateral aspect. The cricoid cartilage and most of the arytenoid cartilage consisted of hyaline cartilage. Only a part at the tip of the vocal process of the arytenoid cartilage was composed of elastic cartilage.

Fig 4. Histological structure around posterior glottis (H & E stain). A) Overview. B) Magnification of framed area in A demonstrating pseudostratified ciliated epithelium (CE) in posterior glottis in contrast to stratified squamous epithelium (SQE) in anterior glottis. PMF — posterior macula flava, VP — vocal process, GL — gland in posterior glottis.



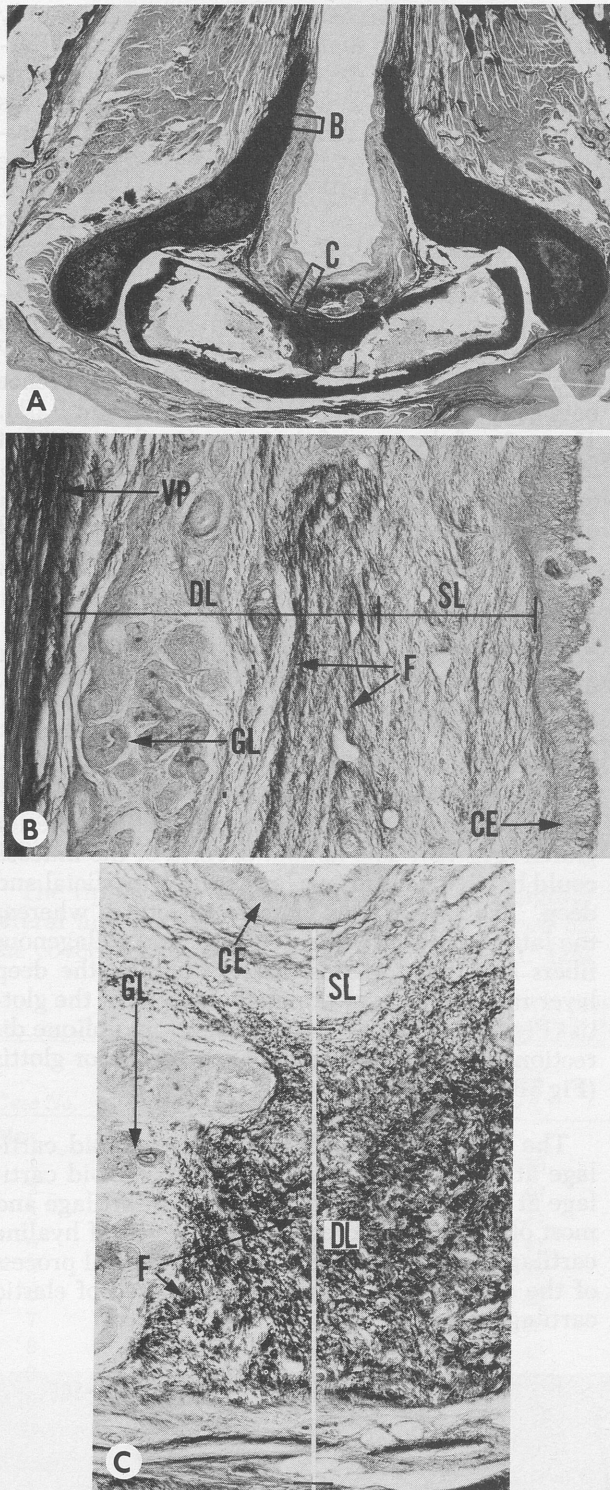


Fig 5. Histological structure around posterior glottis (elastica-van Gieson stain). A) Overview. B) Magnification of lateral aspect of posterior glottis (frame B in A), demonstrating two layers of lamina propria. Fibers (F) are running obliquely. C) Magnification of posterior aspect of posterior glottis (frame C in A), demonstrating many fibers running vertically. SL — superficial layer, DL — deep layer, CE — ciliated epithelium, GL — gland, VP — vocal process.

Vocal Fold Adduction. The mucosa of the posterior glottis became thicker and folded during

vocal fold adduction, especially at the posterior wall (Fig 6A). The direction of fibers in the posterior wall described earlier appeared to be suitable to the folding of the mucosa. The vocal process changed its shape in the adducted position, being almost convex in appearance.

Vocal Fold Abduction. The mucosa of the posterior glottis was thinned and stretched during vocal fold abduction (Fig 6B). The vocal process in the abducted position was nearly concave in contrast to the neutral position, where it was nearly straight.

DISCUSSION

TERMINOLOGY

In anatomy, the vocal fold is defined as the structure between the anterior commissure and the tip of the vocal process. No cartilaginous structure is included in the vocal fold. There is no accepted terminology for the structures surrounding the posterior glottis. On the other hand, many clinicians often use such terms as cartilaginous portion of the vocal fold, posterior commissure, and junction between the anterior and the middle third of the vocal fold, which are misleading.

No clear-cut definition had been given to the term cartilaginous portion of the vocal fold until Hirano and Kurita proposed to define it as the foldlike structure between the tip of the vocal process and the posterior end of the laryngeal ventricle.¹ As described earlier, there is no foldlike structure posterior to the posterior end of the ventricle.

The term posterior commissure has no relevance to the anatomical structure. The term commissure means a joining together.² The bilateral vocal folds never join at their posterior ends. The posterior aspect of the glottis is a wall. We, therefore, propose to call it the posterior wall of the glottis. The posterior part of the lateral aspect of the posterior glottis is also a wall. Therefore, we propose to call these parts the lateral walls of the posterior glottis.

The phrase, junction between the anterior and the middle third of the vocal fold, means the anteroposterior midpoint of the membranous vocal fold, postulating that there is a cartilaginous vocal fold which has a length of half that of the membranous vocal fold. If one employs Hirano and Kurita's definition of the cartilaginous portion of the vocal fold, the cartilaginous portion accounts for approximately one seventh to one sixth of the entire vocal fold in men and approximately one fifth in women.³ If one defines the cartilaginous vocal fold as the structure extending from the tip of the vocal process to the posterior end of the inner facet of the arytenoid cartilage facing the glottis, the cartilaginous portion accounts for 48% of the entire length.⁴ The ratio of 2:1 referred to in the phrase, junction between the anterior and the middle third, has no basis in actual measurements. Based on our measurements the cor-

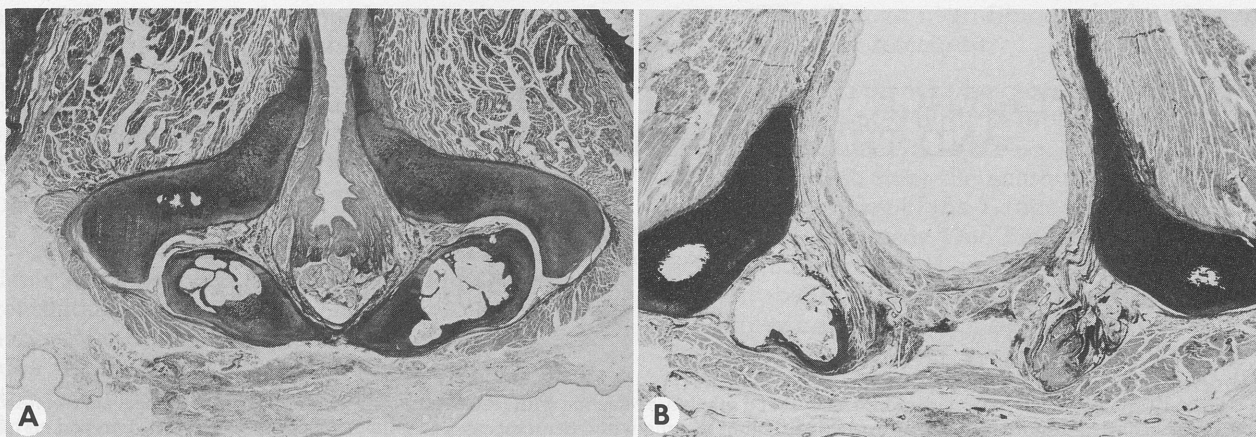


Fig 6. Changes in mucosa of posterior glottis. A) During vocal fold adduction. Mucosa, especially at posterior wall, is thickened and folded, and vocal process is convex. B) During vocal fold abduction. Mucosa is thinned and stretched, and vocal process is concave.

rect phrase should be the middle of the membranous vocal fold.

DIMENSION

The length of the posterior glottis accounts for approximately 35% to 45% of the entire glottic length in the present study. This roughly agrees with Hiramoto's results.⁵ The area of the posterior glottis occupies approximately 50% to 65% of the entire glottic area. This indicates that more respiratory air passes through the posterior glottis than through the anterior glottis, which may mean that the main role of the posterior glottis is as an airway. This finding may have important implications in planning laryngeal reconstruction. It is also interesting to speculate about the functional differences in children.³

CLOSURE OF POSTERIOR GLOTTIS

It should be noted that the posterior part of the larynx does not close completely at the level of the glottis, but it closes at the supraglottis. As a result, a conic space forms in the posterior glottis during vocal fold adduction. It must be pointed out, however, that the glottic closure in the present study was artificially created and differs from that in vivo. Contraction of the thyroarytenoid and inter-

arytenoid muscles was not simulated. We are currently conducting fiberoptic observations of the glottis through a tracheostoma. Our preliminary results have demonstrated that there is a conic space even in the posterior glottis of living humans during phonation. Details of the fiberoptic investigation will be reported in a separate publication.

ROLE OF POSTERIOR GLOTTIS VERSUS ROLE OF ANTERIOR GLOTTIS

There is no doubt that the anterior glottis plays the most important role for phonation. On the other hand, the posterior glottis appears to play an equally important role in respiration. The epithelium in the posterior glottis is a respiratory epithelium, whereas it is stratified squamous epithelium in the anterior glottis. Diseases of the anterior glottis usually cause voice problems. They disturb respiration only when they present a very large obstruction to the airway. On the other hand, diseases of the posterior glottis often result in respiratory distress. They do not affect phonation until they become very extensive and inhibit vocal fold closure. In conclusion, it is apparent from the data presented here that the posterior glottis is a respiratory glottis, while the anterior glottis is a phonatory glottis.

REFERENCES

1. Hirano M, Kurita S. Location of the posterior end of the vocal folds: an unrecognized controversy. *J Otolaryngol Jpn* 1982; 85:432-5.
2. Stedman's medical dictionary. Baltimore: Williams and Wilkins, 1966.
3. Hirano M, Kurita S, Nakashima T. Growth, development and aging of human vocal folds. In: Bless DM, Abbs JH, eds. *Vocal fold physiology*. San Diego: College-Hill Press, 1983:22-43.
4. Busuttill A, Davis BC, Maran AGD. The soft tissue/cartilage relationship in the laryngeal glottis. *J Laryngol Otol* 1981; 95:385-91.
5. Hiramoto M. Functional anatomy of the larynx. *Pract Otol (Kyoto)* 1977; 70:177-97.

EXPERIENCE WITH PARTIAL CRICOID RESECTION AND THYROTRACHEAL ANASTOMOSIS

F. G. PEARSON, MD, FRCS(C)

TORONTO, CANADA

L. BRITO-FILOMENO, MD

SÃO PAULO, BRAZIL

J. D. COOPER, MD, FRCS(C)

TORONTO, CANADA

Since 1973, 28 patients have undergone tracheal and subglottic resection with reconstruction by primary laryngotracheal anastomosis. Nine patients had postintubation stricture, eight had blunt trauma with cricotracheal disruption, seven had a neoplasm, two had an inhalation burn, and two had idiopathic stenosis. In all cases, the anterior cricoid arch was completely resected and a submucosal segment of the posterior cricoid plate was partially resected. A posterior shell of cricoid plate was preserved in 21 patients with intact laryngeal nerve function. Postoperatively, a Montgomery T-tube was used to stent the anastomosis and subglottic area in ten patients, all of whom had residual injury or disease at or immediately below the level of the cords. The proximal arm of the T-tube was positioned above the vocal cords. The tube was removed within 1 month in eight patients and remained for 3 and 18 months in the other two. The extent of resection varied from 2.5 to 7 cm. Tension-relieving procedures were added in 13 cases. Fourteen patients have been followed longer than 5 years, and five patients for more than 10 years. A widely patent anastomosis was maintained in 26 patients. In two patients, a partial restenosis resulted in some limitations of exercise tolerance. Voice and exercise tolerance have not deteriorated with the passage of time. Recurrent laryngeal nerve function was completely preserved in 20 of the 21 patients whose nerve function was intact before operation.

KEY WORDS — cricoid resection, primary anastomosis, recurrent nerve preservation, subglottic stenosis.

In 1975, we reported on a technique for subglottic resection with primary tracheal anastomosis including partial resection of the cricoid cartilage and preservation of recurrent laryngeal nerve function.¹ In the preceding year, Gerwat and Bryce² described their technique for primary reconstruction following subglottic resection using an oblique resection line, which removed the anterior cricoid ring but preserved the entire posterior plate or rostrum. Our operation involves subperichondrial resection of the anterior part of the posterior cricoid with subsequent transverse division of the airway within 0.5 cm of the inferior margin of the vocal cords. Successful experience with this operation has since been reported by Savary (M. Savary, personal communication), Grillo,³ and Couraud and Hafez.⁴

METHODS AND MATERIALS

Between 1972 and 1986, 28 patients have undergone tracheal and subglottic resection with reconstruction by primary thyrotracheal anastomosis. Pathologic conditions were postintubation stricture in nine patients, blunt trauma with cricotracheal disruption in eight, neoplasm in seven, inhalation burn in two, and idiopathic stenosis in two. There were 19 males and nine females, ranging in age between 16 and 72 years. A circumferential segment was resected in all cases and varied in length between 2.5 and 7 cm.

OPERATIVE TECHNIQUE

A detailed and illustrated description of the operative technique is provided in our original publica-

tion.¹ In all patients, the anterior cricoid arch was completely resected and a partial resection of a submucosal, or subperichondrial, segment of the posterior cricoid plate was included. A posterior shell of cricoid plate was preserved in all patients with intact laryngeal nerve function. A transverse, end-to-end primary anastomosis was performed between the distal trachea and the inferior margin of the thyroid cartilage and subglottic mucosa at levels between 0.5 and 1.5 cm from the inferior margin of the vocal cords. Interrupted sutures of No. 35 gauge stainless steel wire were used for the anastomosis in each case. In four patients, a concomitant laryngofissure was done in order to deal with stenosis and a disorder extending to the level of the actual glottis.

Contrary to the technique described in our original paper, we do not make a deliberate attempt to identify either recurrent laryngeal nerve unless the resection is for neoplasm, in which case an involved nerve must be identified and deliberately sacrificed.

A Montgomery T-tube was used postoperatively in ten patients (four cases of laryngofissure with concomitant glottic surgery, five cases with very high resections in which the possibility of glottic edema or hematoma was anticipated, and one late insertion due to partial dehiscence and impending restenosis. A No. 4 or 5 Jackson tracheostomy tube was placed in the distal trachea below the anastomosis in an additional 11 patients for 1 to 2 weeks. In the remaining eight patients, neither a T-tube nor a tracheostomy was used postoperatively, and

From the Division of Thoracic Surgery, University of Toronto (Pearson, Brito-Filomeno, Cooper); the Division of Thoracic Surgery, Toronto General Hospital (Pearson, Cooper); and the Division of Thoracic Surgery, Hospital Das Clinicas, University of São Paulo, São Paulo, Brazil (Brito-Filomeno). Presented at the meeting of the American Laryngological Association, Palm Beach, Florida, May 4-5, 1986.

REPRINTS — F. G. Pearson, MD, FRCS(C), BW1-636, Toronto General Hospital, Toronto, Ontario M5G 2C4, Canada.

one of these patients developed severe glottic and supraglottic edema necessitating an emergency tracheotomy. In the remainder, postoperative edema was well controlled with a combination of racemic epinephrine inhalations and bolus intravenous injections of steroid (Solu-Medrol).

CASE MATERIAL

Postintubation Strictures. All nine stricture patients sustained their injuries as a result of assisted ventilation using orotracheal intubation or a combination of orotracheal intubation followed by cuffed tube tracheostomy. Resection and primary reconstruction had been unsuccessfully attempted in three cases. Associated glottic disorders required concomitant laryngofissure in two cases.

Blunt Trauma With Cricotracheal Disruption. The injury was due to a forceful and localized anterior blow at the cricoid level in all eight trauma patients. The anterior cricoid arch was fractured in every case, and a vertical fracture of the posterior cricoid plate was associated with a laryngoesophageal fistula in four instances. The cervical trachea was completely transected in all cases and retracted distally into the upper mediastinum. Seven of these eight patients had disruption of both recurrent laryngeal nerves, and no attempt was made to reconstruct the divided nerves in any case. In three of these patients a primary repair was attempted within a few days of the original injury, but no attempt was made to resect any part of the cricoid ring and deal with damaged or avulsed mucosa within the lower part of this ring. All three were referred with severe subglottic stenosis and were operated on using the technique currently described. We saw only one patient with a fresh injury, which included a laryngoesophageal fistula, and which was successfully repaired primarily with closure of the esophageal defect and partial cricoid resection.

Four of these eight patients with posttraumatic disruptions suffered posterior cricoid fractures with a tear and fistula extending into the anterior wall of the upper esophagus. All four were successfully closed at the time of partial cricoid resection and thyrotracheal anastomosis.

Neoplasm. Seven patients had tumors involving the upper trachea and lower subglottic level: three had squamous cell carcinoma, one had adenoid cystic carcinoma, one had adenocarcinoma of the thyroid, one had leiomyosarcoma, and two had benign neurofibroma. Two of the three patients with squamous cell carcinoma presented as postradiation recurrences, having received 6,000 and 6,500 cGy. The patient with thyroid carcinoma had had a total thyroidectomy with bilateral neck dissection followed by radical irradiation and was referred with benign postradiation damage and stenosis involving the upper trachea, subglottis, and glottis. The patient with a leiomyosarcoma and one of the two pa-

tients with a benign neurofibroma had undergone incomplete prior resections.

All three patients who had received prior radical irradiation presented difficult problems in postoperative management. In each case, a Montgomery T-tube was used to stent the anastomosis and glottis, with the upper arm of the T-tube passing above the level of the vocal cords. One T-tube was left in place for 19 months before the patient could be successfully extubated. Persistent aspiration was a problem in all three cases and was assumed to be due to fixation of the larynx and hypopharynx following a combination of surgery and previous irradiation.

All patients had complete resections of their tumors, and no cases have shown local recurrence during follow-ups extending between 1 and 12 years.

Inhalation Burns. Two patients sustained injuries due to inhalation at the time of an explosion of corrosive chemical material: formaldehyde and hydrochloric acid in one case and antimony trichloride in the other. The injuries included damage to the hypopharynx and proximal esophagus in both patients and were successfully managed by the gastroenterologists in each case. Each patient developed a long and severe stricture extending from the glottis well down into the cervical trachea, and one sustained severe damage to the vocal cords requiring lateralization on one side, excision of the cord on the other, and the insertion of several mucosal grafts via laryngofissure before he was referred to our service. Details of these two cases are reported in our original publication.¹

Idiopathic Subglottic Stenosis. In two patients, both young women, the cause of a short subglottic stricture lying within the lower half of the cricoid ring was undetermined. One of these patients had been successfully treated for Goodpasture's syndrome with steroids and azathioprine (Immunan). The stricture was identified at the time of original diagnosis, at which time there was active inflammatory granulation tissue in the circumferentially involved segment. A Montgomery T-tube was left in place for 1 year, during which time the Goodpasture's syndrome came under complete control. Following removal of the T-tube the subglottic stricture promptly recurred, but it appeared mature and fibrous at this time and was successfully managed by resection and primary thyrotracheal anastomosis. No associated disorders were identified in the other case.

Twelve of the 28 patients presented with a chronic tracheostomy, through which anesthesia was induced in each case. In the remainder, orotracheal intubation was used, often requiring preliminary forceful dilatation with a rigid bronchoscope. Following division of the airway, anesthesia was maintained using sterile anesthetic connections carried

into the operative field with intermittent intubation of the distal airway during the anastomosis. Since 1981, we have used jet ventilation in selected cases, which hastens and facilitates the placing of anastomotic sutures.

A generous collar incision was used in 27 of 28 patients. In one patient requiring a 7-cm resection, a median sternotomy was added in order to permit intrapericardial release of the right pulmonary hilum and thus reduce tension on the anastomosis.

Superior release procedures were used in 13 of the 28 patients: superior laryngeal release⁵ in nine, and Montgomery's technique of suprahyoid release⁶ in four. In these 13 cases, more extensive lengths were resected and the release was added to minimize anastomotic tension.

RESULTS

COMPLICATIONS

There was no operative mortality. Twelve patients experienced significant problems with aspiration (particularly for liquids). This complication was transient in eight cases and subsided completely within a few weeks to 3 months of surgery. Aspiration remained a persistent problem in four patients: all four had an associated vocal cord palsy, and three of the four had undergone prior radical irradiation. Although a Montgomery suprahyoid release was used on only four occasions, two of these four cases experienced transient problems with aspiration.

Seven of the eight patients with cricotracheal disruption due to blunt trauma had bilateral disruption of both recurrent nerves and never recovered any vocal cord function. Five patients with intact vocal cord function prior to the operation developed a transient palsy on one side, and four recovered completely within 2 weeks to 4 months. The recurrent nerve was deliberately resected in one patient with squamous cell carcinoma. In only one patient, who had a benign stricture following previous total thyroidectomy and postoperative irradiation, was the right recurrent nerve inadvertently divided, which resulted in permanent cord palsy.

Four patients developed significant pneumonia in the postoperative period, and this was attributed to aspiration in all four cases. Two of these patients had bilateral cord palsy due to their original blunt trauma and subsequently improved when a cricopharyngeal myotomy was performed after it became apparent that aspiration was a persistent problem.

AIRWAY PATENCY

Follow-up in these 28 patients extended between 1 and 14 years with a mean length of 5.9 years.

Twenty-one of the 28 patients had intact recurrent nerve function before operation. The anastomosis has remained widely patent in 18 cases. Partial restenosis developed in two patients and pro-

duced some functional impairment of the airway. In neither case, however, was any further therapy considered necessary.

One patient with a widely patent anastomosis but with severe postradiation fixation of the larynx and hypopharynx continued to aspirate massively and has subsequently undergone operative closure of the subglottis in order to exclude the distal trachea from further aspiration.

Seven patients with bilateral vocal cord palsy due to traumatic cricotracheal disruption are considered to have a satisfactory compromise between a sufficiently patent airway and adequate voice. All of these cases have some degree of hoarseness and voice weakness along with some limitation of exercise tolerance at the extremes of exertion. In no case was lateral fixation of an arytenoid cartilage done at the time of original repair or subsequently. This addition was recommended by Ogura and Powers⁷ many years ago, and more recently by Mathiesen and Grillo,⁸ but does not appear necessary for cases managed by our operative technique. Four of these patients have been examined by one of our consultant otolaryngologists (D. P. Bryce) at 3, 4, 5, and 10 years following operation. He did not feel that any further surgical procedures were required, and noted a good preservation of mobility of the arytenoid cartilages in all four patients. There had been concern that the subperichondrial dissection of mucosa just below the vocal cords would produce some damage and ultimate scarring with fixation of the vocalis muscle and conus elasticus.

Five additional patients have had a late evaluation of anastomotic patency and vocal cord function by Dr Bryce at 3, 4, 5, 10, and 11 years after operation (two had postintubation strictures, two had tumor, and one was idiopathic). Airway patency, voice, and cord mobility were well preserved in all five.

DISCUSSION

The procedure described in this report represents a one-stage operation for resection and primary reconstruction of subglottic lesions in selected patients. There are innumerable reports of alternative approaches for these problems, which are reviewed in some detail in the publications by Grillo³ and Couraud and Hafez.⁴ Couraud and Hafez⁴ provide one of the most comprehensive reports on the diagnosis and management of subglottic stenosis that has yet been published. Since 1968 they have accumulated experience with 60 patients and have made practical observations concerning clinical presentation, diagnosis, and management. We concur with their observations about emergency management.

1. Emergency tracheotomy is unnecessary and should be avoided since it may only add to the severity of the pathologic lesion. In all cases, Couraud

and Hafez have been able to establish a safe upper airway using rigid bronchoscopy under general anesthesia. In recent years they have used the Nd:YAG laser in selected cases to complement the dilatation achieved at bronchoscopy. The decision for tracheostomy can then be made electively in selected cases.

2. Steroids and antibiotics are administered during this emergency period. Our group found the use of racemic epinephrine inhalation a beneficial addition.
3. Elective surgical management is deferred until maximal resolution of infection and inflammation in the lesion has been achieved.

In the report of 60 cases by Couraud and Hafez,⁴ a variety of approaches was used for management and reflects changes in understanding and technique that have developed since 1968. In early years, they used a variety of staged and plastic reconstructions, which included the use of free cartilage grafts, molded prostheses, stents, and such operations as the Rethi procedure. Subsequently, they report excellent results in a selected group of 16 patients (16 consecutive good results) in which the lesion was amenable to circumferential, segmental resection using the technique of partial cricoid resection and laryngeal nerve preservation originally described by us.¹

Grillo reported his experience with 18 patients with subglottic stenosis in 1982.³ Thirteen of these 18 cases were managed by an oblique resection, which included the anterior cricoid arch, but did not require resection of cartilage or mucosa proximal to the inferior border of the cricoid cartilage. In five patients, however, the posterior subglottic

mucosa was resected at a higher level, closer to the vocal cords. Reconstruction of the posterior mucosal defect without partial cricoid resection using a pedicle of membranous trachea from the distal tracheal margin is described. This is a technically more difficult anastomosis in the narrowest part of the subglottic airway, and when circumferential stenosis is present at this level, we believe there may be an advantage in adding a subperichondrial resection of the posterior cartilaginous plate. This will widen the rigid margins of the airway at this level and should increase the potential diameter of the subsequent thyrotracheal anastomosis. The subglottic mucosa at this upper resection margin is somewhat elastic and will stretch to some degree when anastomosed to the larger diameter, distal tracheal stump.

Couraud and Hafez⁴ also report on their unique experience with five patients in which the cricoid cartilage was entirely resected. These represent the most challenging problem in this group of subglottic lesions, and their experience with these five cases appears remarkable. They used prolonged nasotracheal intubation (up to 9 months) as the method of stenting and stabilizing the larynx and subglottic segment. It is difficult to evaluate the role played by their use of a free periosteal graft inserted in the interarytenoid position. Nevertheless, good results were obtained in four of the five patients within less than 1 year of initiating surgical management. We have had no experience with total cricoid resection, but are encouraged to consider this approach in the future. It would seem logical to replace the nasotracheal tube with a Montgomery T-tube for such prolonged stenting.

REFERENCES

1. Pearson FG, Cooper JD, Nelems JM, van Nostrand AWP. Primary tracheal anastomosis after resection of the cricoid cartilage with preservation of recurrent laryngeal nerves. *J Thorac Cardiovasc Surg* 1975; 70:806-16.
2. Gerwat J, Bryce DP. The management of subglottic laryngeal stenosis by resection and direct anastomosis. *Laryngoscope* 1974; 84:940-5.
3. Grillo H. Primary reconstruction of airway after resection of subglottic laryngeal and upper tracheal stenosis. *Ann Thorac Surg* 1982; 33:3-18.
4. Couraud L, Hafez A. Acquired and non neoplastic subglottic stenoses: report of 60 cases. In: Delarue NC, Eschepasse H, eds. *International trends in general thoracic surgery*. Vol 1. Philadelphia: WB Saunders, 1986 (in press).
5. Dedo HH, Fishman NH. Laryngeal release and sleeve resection for tracheal stenosis. *Ann Otol Rhinol Laryngol* 1969; 78:285.
6. Montgomery WW. Suprahyoid release for tracheal stenosis. *Arch Otolaryngol* 1974; 99:255-9.
7. Ogura JH, Powers WE. Functional restitution of traumatic stenosis of the larynx and pharynx. *Laryngoscope* 1964; 74:1081-110.
8. Mathiesen DJ, Grillo H. Laryngotracheal trauma. *Ann Thorac Surg* 1986 (in press).

STAGED REPAIR OF EXTENSIVE TRACHEAL AND LARYNGOTRACHEAL STENOSES

HUGH F. BILLER, MD

WILLIAM LAWSON, MD, DDS

VERNE WEISBERG, MD

NEW YORK, NEW YORK

The usual operative procedures (primary tracheal anastomosis, cricotracheal anastomosis, skin grafting and stenting, pedicle cartilage grafts, or free rib grafts) used to correct stenoses of great length involving the trachea or laryngotrachea have a high incidence of failure. An alternative method of reconstruction is the open technique, which requires three stages. The initial stage creates a trough after resection of the stenotic area, followed by subcutaneous embedding of a rigid material adjacent to the trough, and finally closure of the trough by reformation of the anterior wall. This staged procedure has been used in adult patients with tracheal stenoses greater than 4 cm, in patients with tracheal stenoses involving the cricoid, and in patients whose primary corrective operative procedures have failed. This paper critically assesses 30 patients who have had a staged reconstruction with a minimum follow-up of 12 months. The indications, number of procedures performed, time required for decannulation, complications, and analysis of failures are presented. The incidence of success in this series of patients is 76% (23/30).

KEY WORDS — laryngotracheal stenosis, reconstruction surgery, stenosis, trough reconstruction.

The correction of stenosis of the upper airway measuring 4 cm or greater in length, either isolated to the cervical trachea or involving the trachea and the subglottis, remains a difficult challenge for the laryngologist. One method for correction of these extensive stenoses is a staged repair.

The staged, or trough, technique of reconstruction for the correction of stenosis was initially published in the American literature by Fairchild¹ in 1927. Following resection of the stenotic segment, he advanced the adjacent neck skin into the defect to form a trough, which was closed later. He did not embed any material to maintain rigidity. In 1935, LeJeune and Owens² reported a method of staged reconstruction for laryngeal stenosis in which split-thickness skin grafts were used to resurface the defect resulting from scar tissue resection. The laryngostome was closed once the scar tissue was observed not to recur.

In 1951, Som³ established the basic principles of the staged reconstructive technique. The first stage was the excision of scar tissue and resurfacing of the denuded area with split-thickness skin grafts. In the second stage a rigid material was implanted subcutaneously adjacent to the trough. In the final stage the adjacent skin and subcutaneous tissue with the embedded rigid material was rotated to re-form the anterior wall of the reconstructed airway. In this publication Som reported the successful correction of a laryngotracheal stenosis measuring approximately 4.5 cm in length. The multistage reconstruction required 9 months for completion. An adequate airway was demonstrated at the 6-month follow-up examination.

Serrano et al,⁴ in 1959, reported four patients in whom rib cartilage was implanted for anterior wall rigidity in a staged technique of cervical tracheal reconstruction. They did not indicate the interval for successful reconstruction or the number of successful cases. Montgomery,⁵ in 1964, reported a similar staged technique but used a slightly different method of trap door formation and cartilage insertion. In 1966, Grillo⁶ published a successful case of staged reconstruction of the cervical trachea following tumor resection. His technique consisted of inserting plastic rings subcutaneously at the second stage. The completed reconstruction required 4 months. Bryce and Lawson,⁷ in 1967, presented three cases of reconstruction by the staged technique. Two of these cases were reconstructed in approximately 4 months, and the airway was excellent 4 months and 5 years following reconstruction. Krizek and Kirchner⁸ reported a staged reconstruction in 1972 using implanted septal cartilage for support for the anterior wall. The patient had an adequate airway at 1 year following reconstruction. Friedman et al⁹ in 1975 and Lawson et al¹⁰ in 1977 each presented a case of successful reconstruction with follow-up of 12 months and 24 months, respectively. Marlex mesh was the material embedded for tracheal support.

MATERIALS AND METHODS

The charts of all patients admitted to the Department of Otolaryngology of the Mount Sinai Medical Center from 1974 to 1985 with tracheal or laryngotracheal stenosis, reconstructed by the authors using the staged trough technique, were reviewed. The data extracted from the records included the site

From the Department of Otolaryngology, Mount Sinai School of Medicine, New York.

Presented at the meeting of the American Laryngological Association, Palm Beach, Florida, May 4-5, 1986.

REPRINTS — Hugh F. Biller, MD, Dept of Otolaryngology, Mount Sinai Medical Center, 100th St & 5th Ave, New York, NY 10029.

and length of the stenosis, the number of surgical procedures (other than laryngoscopies), and the final result. The follow-up interval was a minimum of 12 months after decannulation. Complications following decannulation were also noted.

RESULTS

Thirty patients are included in the review. Two of the 30 patients were children, 3 and 12 years of age. The stenosis was caused by prolonged endotracheal intubation in 23 patients and external trauma sustained in automobile accidents in seven patients. The length of the stenosis in the 28 adult cases measured 3.5 cm in two cases and 4 cm or greater in 26 cases. The stenoses in the 3- and 13-year-old children measured 2.5 cm and 3.5 cm, respectively. The location of the stenosis was glottic, subglottic, and tracheal in ten patients, subglottic and tracheal in 16, and tracheal alone in four. Twenty of the 30 patients had had one or more unsuccessful surgical procedures, including either resection and primary anastomosis or cartilage or bone grafts with skin grafting and stenting. Dilatation, steroid injections, and laser resection had also been employed in this group of patients either before or after the failed surgical procedures. All patients undergoing the staged surgical reconstruction had evidence of not only lumen stenosis secondary to fibrosis but also cartilage loss from chronic chondritis.

The number of surgical procedures required (the first being the formation of the trough and the last being the final closure) varied from three to eight. The time between the first procedure and the last procedure varied from 3 to 36 months. The reconstruction was completed in 3 to 6 months in nine patients, in 7 to 12 months in seven patients, in 13 to 18 months in five patients, and in 19 to 36 months in three patients.

Twenty-three of the 30 patients were permanently decannulated. Seven cases were considered failures; these patients never reached the final stage of closure or required a permanent tracheotomy following the final stage.

Six patients developed complications following successful decannulation. Neck abscesses occurred in two patients secondary to trauma at the closure sites. Drainage with extraction of the exposed Marlex mesh was performed without airway interference. Four patients required tracheostomies following the final stage of repair because of recurrent airway compromise. One patient required a tracheotomy following external trauma. This patient was decannulated after re-formation of the trough and a secondary closure. The second patient required a tracheotomy following intubation for 5 hours during abdominal surgery. The lower end of the trough was reopened and secondarily closed 6 weeks later. The third patient did well for 3 years following reconstruction of the laryngotrachea for stenosis of

the glottis, subglottis, and the first four tracheal rings. At the time of the original repair, the right vocal cord lacked mobility, which did not interfere with airway rehabilitation. However, the onset of left vocal cord paralysis 3 years later required a tracheotomy. The fourth patient required a tracheotomy for myasthenia gravis.

ANALYSIS OF FAILURES

Seven cases are considered to be failures. The first patient had a successful reconstruction, but at 10 months following the final stage it was necessary to reinsert the tracheotomy because of a relapse of myasthenia gravis. This patient continuously corks the tracheotomy tube except when on the respirator.

The second patient, who was 12 years of age, had total airway occlusion from the level of the supraglottis to the tracheotomy site with inability to speak. The reconstruction has allowed the patient to speak, but the airway is inadequate for decannulation.

The third patient had a tracheal stenosis that extended inferiorly to the level of a high innominate artery. Exteriorization of the trachea could not be performed safely at the inferior aspect. She continues to wear a Montgomery T-tube. When the T-tube is removed, the distal end of the trachea deep to the innominate artery becomes narrowed.

The fourth patient originally had a glottic, subglottic, and tracheal stenosis. She continues to have obstruction at the level of the glottis and requires a tracheotomy tube.

The fifth patient was diagnosed as having the pickwickian syndrome, and the second and third stages were not performed because of the excessive weight of the patient.

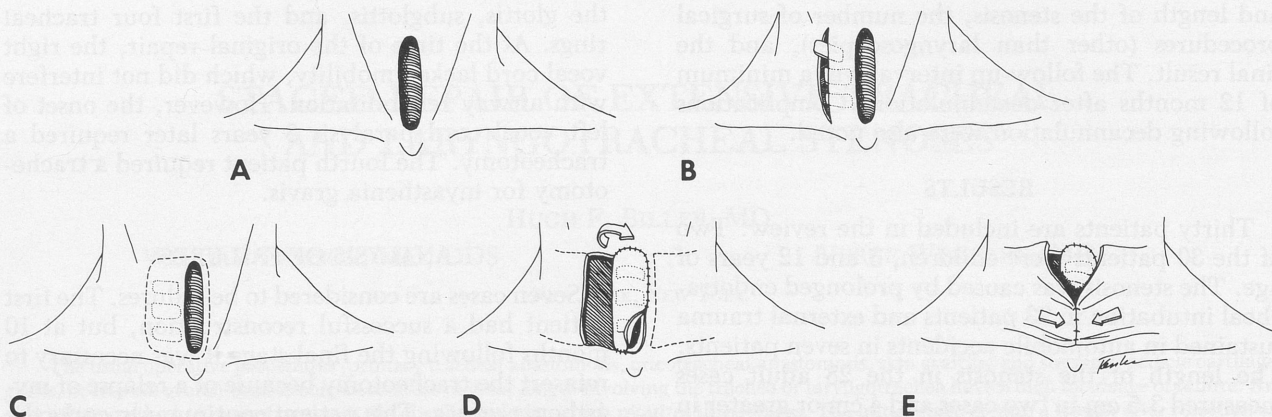
The sixth patient had severe chronic lung disease, and while the final stage was accomplished, the copious secretions could not be cleared and required a permanent tracheotomy.

The seventh patient died of a myocardial infarction, unrelated to the surgery, before the third stage operation.

RECONSTRUCTION TECHNIQUE

The basic principles of upper airway reconstruction following excision of the stenotic segment are the interposition and maintenance of an epithelial lining and the formation of a semirigid wall to prevent collapse with negative pressure (Figure).

The extent of the stenosis is assessed by endoscopy and computed tomographic scanning. However, the final decision whether primary or staged reconstruction is to be employed is frequently made at the time of exploration. If staged reconstruction is decided upon preoperatively, the midline is incised. If



Three-stage surgical procedure. A) First stage showing creation of trough following excision of scar tissue. B) Second stage showing insertion of Marlex mesh. C) Third stage showing circumferential incision. D) Third stage showing rotation of skin with embedded Marlex mesh. E) Third stage showing primary closure of overlying skin.

a horizontal incision has been selected and the decision is then made to perform a staged procedure, the elevated skin flap is split in the midline.

Following exposure of the thyroid cartilage, the subglottic area, and the trachea to the tracheotomy site, the stenotic segment is divided vertically in the anterior midline. The lumen is identified, and the stenosis is opened to its inferior and superior extent until a normal lumen is encountered. This may require incision of the cricoid or thyroid cartilage if the stenosis involves these sites.

The scar tissue is resected with preservation of whatever mucous membrane and normal cartilage is present. If mucosa is absent posteriorly, then a few millimeters' width of scar tissue is preserved for the extent of the resected area. The cartilage anteriorly and laterally is usually destroyed. Viable cartilage, if present laterally, is preserved. The skin flaps are then thinned and sutured to the cut margins of the residual mucosa bilaterally. If there is no mucosa, the skin is sutured to the few millimeter-wide posterior segment of scar tissue that is preserved. The preservation of this strip of scar tissue allows the skin flaps to be fixed posteriorly. If the skin flaps are sutured to one another posteriorly, the skin retracts and foreshortens the depth of the trough.

If the glottis is involved, a thyrotomy is performed, the scar tissue is resected, and the glottic and subglottic areas are resurfaced by advancement of the adjacent skin flaps. The cricoid is usually not divided posteriorly. However, if there is excessive bulk posteriorly that encroaches on the airway, the perichondrium is elevated and a cutting bur is used to trim the cartilage. The skin flaps are anchored to the posterior mucosa or scar with interrupted 4-0 silk sutures (Figure, A). The trough is packed with iodinated gauze, and a tracheotomy tube is inserted into the lower end of the trough. On the third or fourth postoperative day the gauze is removed and a Montgomery T-tube is inserted to bridge the gap and allow the patient to speak. A T-tube is used

only with tracheal or tracheal and subglottic reconstruction. If the glottis is involved, a T-tube is not inserted. The sutures are removed after 10 days.

The second stage is scheduled for 3 to 4 weeks later. At the second stage the trough is evaluated, and areas of narrowing from scar formation are corrected. The Marlex mesh to be inserted is cut into pieces measuring approximately 0.5 by 1.75 cm. These pieces are interposed at distances of approximately 0.5 cm (Figure, B). A vertical incision through the full thickness of the skin is made on one side of the trough. The distance of this incision from the edge of the trough is approximately 1.5 cm greater than the distance of one edge of the trough to the other edge of the trough. This incision extends the length of the trough. The Marlex is inserted in the subcutaneous tissue and maintained in position with a chromic catgut suture. The vertical incision is then closed.

The third stage is performed approximately 4 weeks later. The patient is admitted to the hospital several days prior to surgery. The T-tube is removed and the trough observed for narrowing to ensure that the T-tube is not acting as a stent. If the lumen of the trough decreases in size after removing the T-tube, revision surgery is performed to correct the area of narrowing and the final stage is deferred for another 6 weeks.

At the final stage, intubation is performed with a 7- or 7.5-mm nasotracheal tube. The previous vertical incision through which the Marlex mesh was inserted is reincised but carried more deeply to the anterior border of the strap muscles to prevent exposure of the mesh. The superior and inferior aspects of the incision are extended circumferentially around the trough. The incision is carried 2 cm above and below the ends of the trough. The contralateral vertical incision is approximately 1.5 cm from the margin of the trough (Figure, C). The skin and subcutaneous tissue is elevated. The flap containing the embedded Marlex is rotated 180° and

sewed to the cut margin of the opposite side of the trough with 3-0 chromic catgut using interrupted far-near-near-far sutures (Figure, D). Skin edges are therefore inverted, yielding an airtight closure. The donor site is closed primarily by elevating and advancing the neck skin on both sides of the trough (Figure, E). A tracheotomy tube is not used. The patient is awakened and returned to the intensive care unit, where frequent saline installation and suctioning of the nasoendotracheal tube are performed. The nasotracheal tube is removed at 48 hours. The patient remains in the intensive care unit for another 24 hours before being transferred from the unit. If airway obstruction develops, the lowermost portion of the skin incision is opened along with the lowermost portion of the trough incision, and a tracheotomy tube is inserted.

DISCUSSION

The successful correction of upper airway stenosis that involves cartilage loss and extends for a distance of 4 cm or greater is difficult to accomplish.

Limited stenosis of the cervical trachea is best treated by excision and primary anastomosis. Though at times extended segments measuring up to 5 or 6 cm may be resected and successfully repaired by primary anastomosis in young patients who possess elastic tracheal cartilage, it has been our experience that the incidence of success is less than 50% when the stenotic segment is 4 cm or greater in length.

The difficulties in reconstruction are further com-

pounded when the stenosis crosses the cricoid to involve both the subglottis and the trachea. Proposed reconstructive procedures using skin grafts and stents, the interposition of bone or cartilage grafts, and primary thyrotracheal anastomosis similarly experience poor results with stenoses of 4 cm or greater in length.

Therefore, the staged method of reconstruction is selected when primary anastomosis or thyrotracheal anastomosis is likely to fail because of the extended length of the stenosis; where the stenosis involves the glottis, subglottis, and trachea; or following previous attempts at repair by primary anastomosis or hyoid bone or rib interposition.

The advantages of the staged procedure are that one can observe the trough and treat granulations that form or revise any subsequent scar tissue formation. Prior to closure, the anterior aspect of the trough can be occluded with Vaseline gauze to assess the adequacy of the airway. There is a high prediction of long-term success once an adequate trough is formed.

The disadvantages of this technique are the necessity for multiple stages and the length of time until final closure. The anterior neck skin used must be free of hair, and the reconstructive segment is more susceptible to subsequent external and internal trauma than the normal trachea. Occasionally these patients will have crusting of the skin lining, which produces an unpleasant odor. In spite of these deficiencies, the ultimate success rate with this type of reconstruction is high, averaging 76% (23/30) in the present series.

REFERENCES

1. Fairchild FR. Reconstruction of the trachea. *Surg Gynecol Obstet* 1927; 44:119-22.
2. LeJeune F, Owens N. Chronic laryngeal stenosis. *Ann Otol Rhinol Laryngol* 1935; 44:354-63.
3. Som M. Reconstruction of the larynx and trachea. *J Mt Sinai Hosp* 1951; 17:1117-26.
4. Serrano A, Ortiz-Monasterio F, Andrade-Padillo J. Reconstruction of the cervical trachea. *Plast Reconstr Surg* 1959; 24:333-9.
5. Montgomery WW. Reconstruction of the cervical trachea. *Ann Otol Rhinol Laryngol* 1964; 73:5-15.
6. Grillo H. Circumferential resection and reconstruction of the mediastinal and cervical trachea. *Ann Surg* 1966; 162:374-88.
7. Bryce DP, Lawson VG. The "trough" method of laryngotracheal reconstruction. *Ann Otol Rhinol Laryngol* 1967; 76:793-803.
8. Krizek T, Kirchner J. Tracheal reconstruction with an autogenous mucochondrial graft. *Plast Reconstr Surg* 1972; 50:123-30.
9. Friedman WH, Biller HF, Som ML. Repair of extended laryngotracheal stenosis. *Arch Otolaryngol* 1975; 101:152-6.
10. Lawson W, Som M, Biller HF. Delayed tracheal reconstruction. *Trans Am Acad Ophthalmol Otolaryngol* 1977; 84:139-44.

DIAGNOSIS AND TREATMENT OF SMALL CELL CARCINOMA OF THE LARYNX: A CRITICAL REVIEW

ALFIO FERLITO, MD

PADUA, ITALY

Small cell carcinoma of the larynx is an uncommon neuroendocrine tumor with particular pathologic, therapeutic, and prognostic connotations. The first case of this lesion was observed in Canada in 1972. Fourteen cases of small cell carcinoma of the larynx were observed in the Ear, Nose, and Throat Department of Padua University in a series of 3,284 primary and secondary laryngeal and hypopharyngeal malignant neoplasms. This number constitutes the largest collection from a single institution in the literature and brings the total recorded cases to 66. The tumor is thought to arise from the argyrophilic Kulchitsky cells normally found in laryngeal mucosa. The diagnosis is based on the light microscopic appearance of the neoplasm and can be confirmed by electron microscopy. The differential diagnosis must be made from carcinoid, atypical carcinoid, small cell squamous carcinoma, small cell ductal carcinoma, lymphoma, mycosis fungoides, and metastatic lung small cell cancer. Systemic chemotherapy with radiation therapy is the accepted manner of treatment today. The survival of the patients treated with these modalities may be significantly improved, and some patients may be cured.

KEY WORDS — apudoma, neuroendocrine carcinoma, small cell carcinoma.

Small cell carcinoma (SCC) of the lung is a highly aggressive neoplasm with one of the highest mortality rates for cancer in humans. Reports of extrapulmonary primary SCC are appearing with increasing frequency in the literature. Other than in the larynx, these tumors may arise in the nasal cavity, paranasal sinuses, tongue, salivary glands, esophagus, trachea, stomach, pancreas, small and large bowel, uterine cervix, endometrium, breast, prostate, urinary bladder, skin, and thymus.¹⁻⁵ Sometimes the primary site of the lesion is unknown.⁶⁻⁹

The larynx appears to be one of the most common sites for extrapulmonary SCC, but this lesion accounts for less than 0.5% of the primary and secondary laryngeal malignancies in my material.¹⁰ To date 66 cases of this neoplasm^{2,3,7,11-47} have been described in the world literature. These include the present series, several cases of which have already been reported by our group.^{21,30,36,37,41,47} Other cases have only been mentioned.⁴⁸⁻⁵¹ The first case was observed in Canada and was reported by Olofsson and van Nostrand¹¹ in 1972.

Fourteen cases of SCC of the larynx are reported here and show that long-term survival is possible in some cases. This is the largest series from a single institution reported in the literature.

MATERIALS AND METHODS

From January 1966 through December 1984, 14 cases of SCC of the larynx were observed in the Department of Otolaryngology of Padua University, in a series of 3,284 primary and secondary laryngeal and hypopharyngeal malignant neoplasms. The biopsy fragments and surgical specimens were fixed in 10% formalin and embedded in paraffin. Sections

were stained with hematoxylin-eosin, PAS with and without diastase, and Gomori's silver reticulin stain. In all cases sections were stained with Grimelius and Fontana-Masson stains. In case 3, formalin-fixed, paraffin-embedded tissue was reprocessed for electron microscopy. The fragments were deparaffinized in xylene and hydrated with graded alcohols to a 0.2 M phosphate-buffered solution (pH 7.4), postfixed in osmium tetroxide, re-washed in 0.1 M phosphate-buffered solution (pH 7.4), dehydrated in acetone, and embedded in epoxy resin. Sections were cut with an ultramicrotome, and the ultrathin sections obtained were stained with uranyl acetate and lead citrate and examined by transmission electron microscopy.

Specimens for electron microscopy, consisting of fragments of primary tumor (case 12) and of both the primary tumor and the cervical lymph node (case 14), were fixed in 2% phosphate-buffered glutaraldehyde, postfixed in 1% phosphate-buffered osmium tetroxide, dehydrated in alcohol and propylene oxide, and embedded in epoxy resin. Semithin sections (about 600 μ m thick) were stained with toluidine blue and examined with a light microscope. Thin sections (about 80 μ m thick) from selected areas were stained with uranyl acetate and lead citrate and examined by transmission electron microscopy.

PATHOLOGIC FINDINGS

In a review of material from the Department of Otolaryngology, 14 cases of laryngeal tumors, histologically indistinguishable from typical SCC of the lung were identified. The tumors were arranged in sheets, and occasionally interconnecting ribbons of small cells with minimal cytoplasm and relatively large hyperchromatic oval, round, or spindle-shaped

From the Department of Otolaryngology, University of Padua, Padua, Italy.

Presented at the meeting of the American Laryngological Association, Palm Beach, Florida, May 4-5, 1986.

REPRINTS — Alfio Ferlito, MD, Dept of Otolaryngology, University of Padua, Nuovo Policlinico, Via Giustiniani 2, 35100 Padua, Italy.

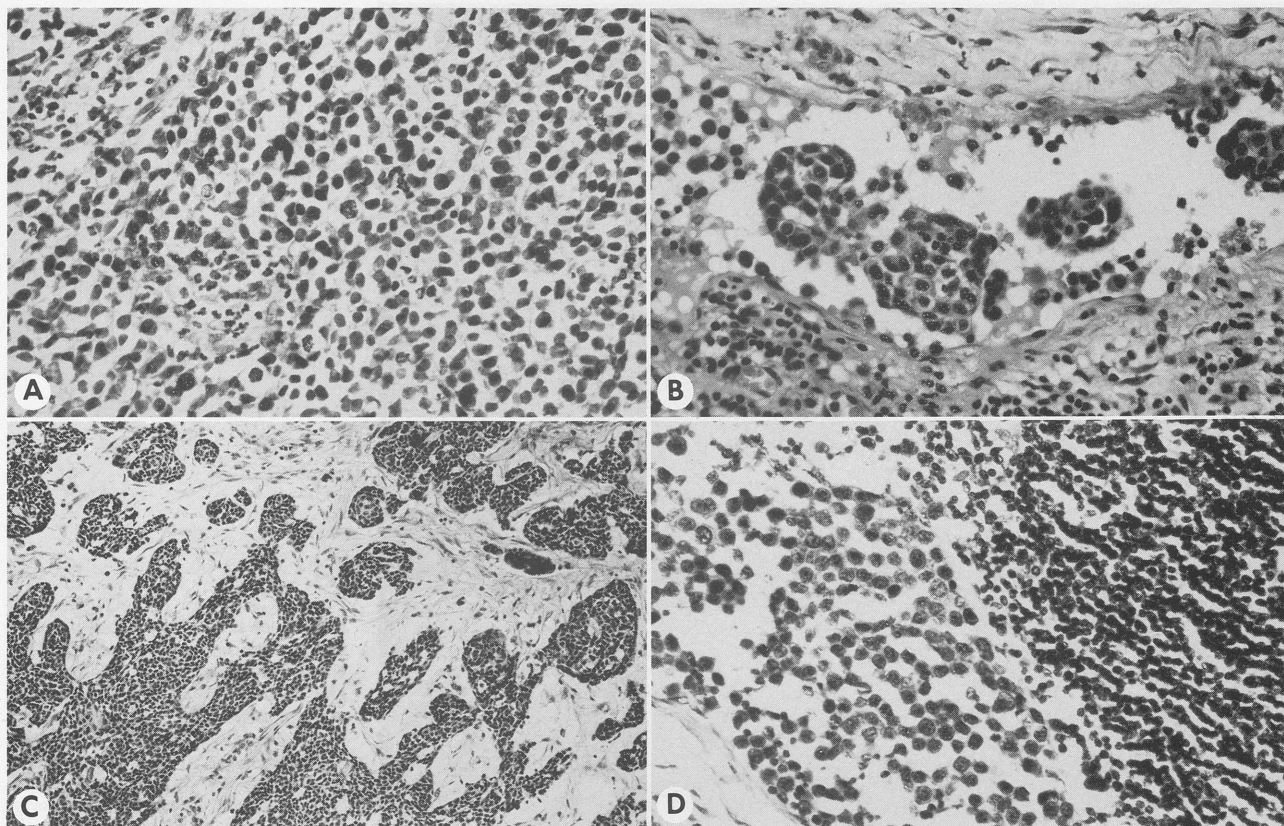


Fig 1. Light micrographs from patients in Table 2. A) (Case 5) Typical pattern of laryngeal SCC, oat cell type (H & E, original x100). B) (Case 3) Vascular invasion (H & E, original x100). C) (Case 3) Irregular cords and clumps of tumor cells separated by mucoid stroma (H & E, original x40). D) (Case 3) Lymph node metastasis from laryngeal SCC (H & E, original x100). Note size of neoplastic cells in comparison with lymphocytes.

nuclei with delicate chromatin and inconspicuous nucleoli could be seen (Fig 1A). Tumor necrosis was prominent. Typical crush artifact was present. Mitoses were numerous, and vascular (Fig 1B), perineural and skeletal muscle invasion was commonly seen. Rosette formations were rarely observed. The stroma was scanty and rarely mucoid (Fig 1C). Sometimes several neoplastic multinucleated giant cells were seen. Occasionally the cells appeared to cluster around alveolar-like spaces containing diastase-resistant PAS-positive material. Reticulin stain was negative. Grimelius and Fontana-Masson staining for argyrophilic and argentaffin cells, respectively, were negative in all cases. The microscopic features of the metastases were similar to those of the primary tumors (Fig 1D).

Of these 14 cases of primary SCC of the larynx, seven were oat cell carcinoma, six were combined SCC, and one was intermediate cell type.

In three cases (cases 3, 12, and 14), electron microscopy showed a small number of neurosecretory granules, 60 to 120 nm in diameter, with a dense central core and clear halo. In case 3, the granules appeared to be surrounded by ill-defined or well-defined limiting membranes and sometimes by a fragment of membrane. The neoplastic cells of both the laryngeal specimens (cases 12 and 14) and the

cervical lymph node (case 12) were connected to each other by scattered desmosomelike junctions, had indented nuclei with coarse chromatin clumps, and contained tonofilaments and membrane-bound neurosecretory granules (Figs 2 and 3). Occasionally tonofilament bundles, desmosomes, and dense core granules were present in the same cells (Fig 2). The cytoplasm was scanty and contained some mitochondria, polyribosomes, and in some cases, profiles of rough endoplasmic reticulum and a well-defined Golgi system. The lymph node metastasis had all the morphologic features of the primary tumor.

DISCUSSION

Primary neuroendocrine tumors of the larynx include atypical carcinoid, carcinoid, paraganglioma (or chemodectoma), and SCC, the commonest of this group.

The relevant clinical and pathologic data of the cases reported in the literature are summarized in Table 1 and from my 14 cases in Table 2.

The lesion may occur in any laryngeal region, although its incidence is relatively higher in the supraglottic and subglottic regions. The tumor occurs mainly in men of 60 to 70 years of age who have been heavy cigarette smokers. The symptoms and signs

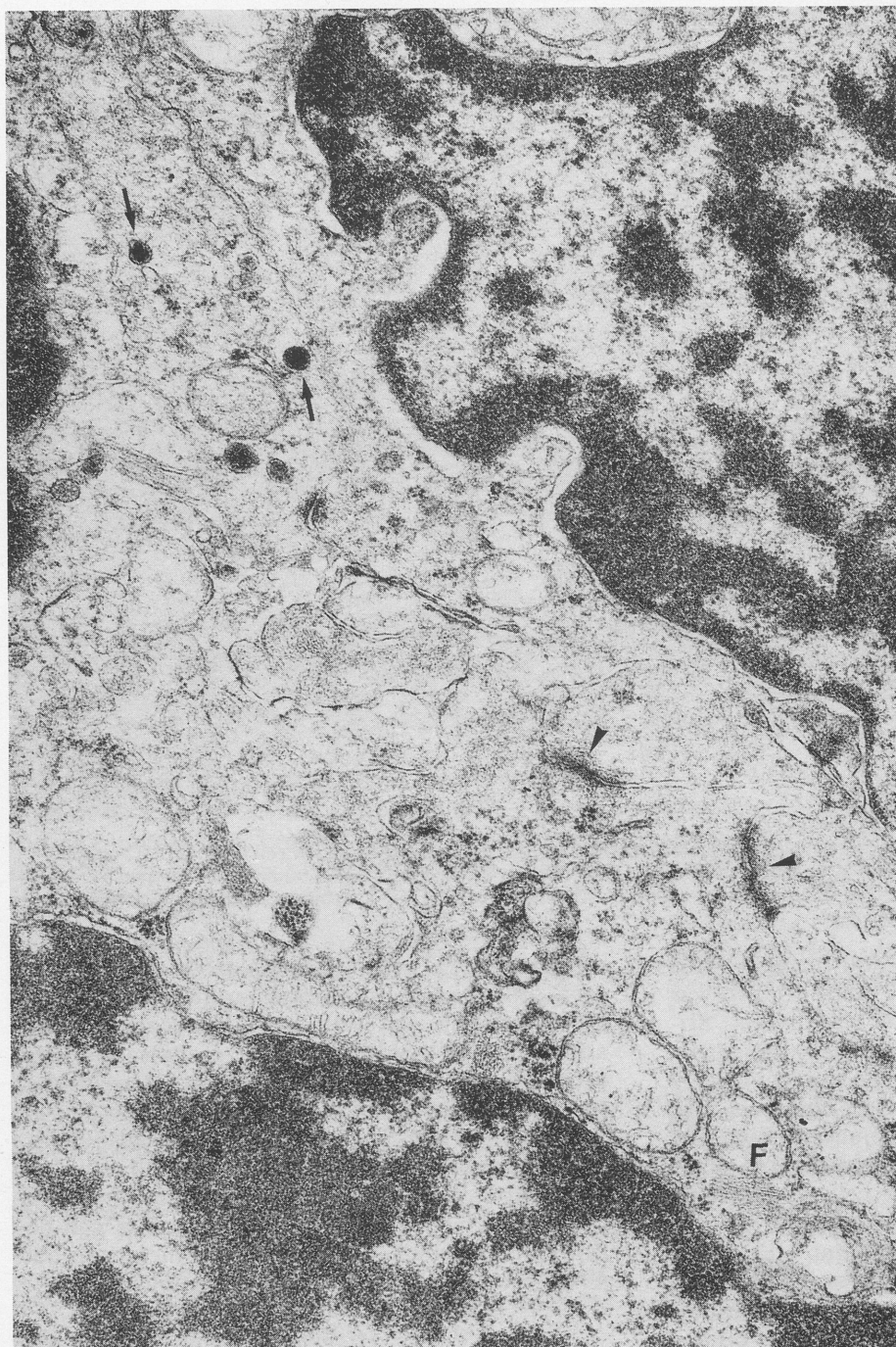


Fig 2. (Case 12 in Table 2) Neoplastic cells of larynx connected by scattered desmosomelike junctions (arrowheads), containing indented nuclei with coarse chromatin clumps, poor microfilaments (F), and membrane-bound neurosecretory granules (arrows) (uranyl acetate and lead citrate, original x24,000).

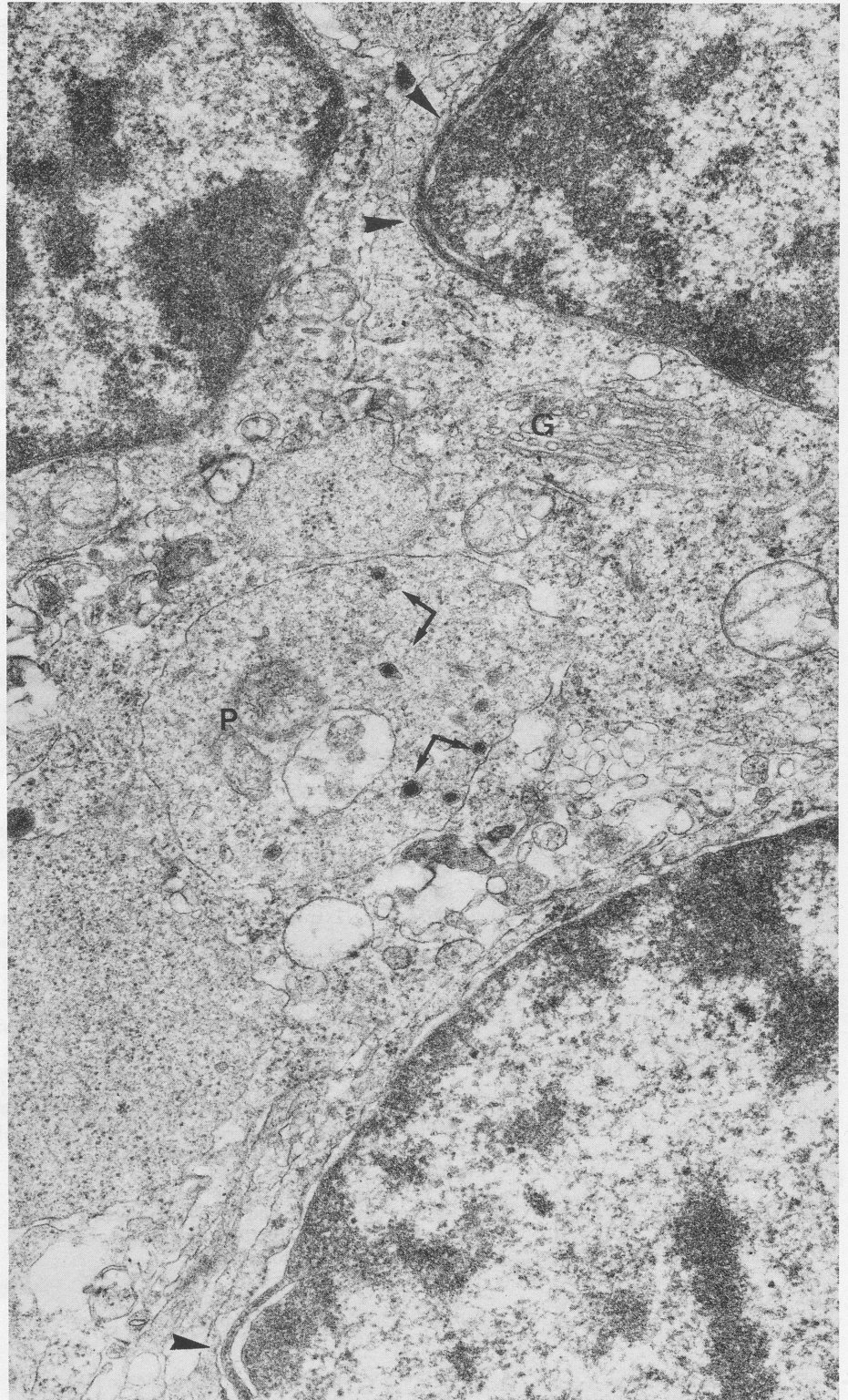
are similar to those of other laryngeal tumors and depend upon the region involved. In some cases, an early neck mass may be the presenting sign.

Small cell carcinoma is also referred to as oat cell carcinoma, anaplastic cell carcinoma, microcytoma, reserve cell carcinoma, undifferentiated carcinoma, undifferentiated SCC, anaplastic SCC, apudoma, neuroendocrine neoplasm, neuroendocrine carcinoma, small cell neuroendocrine carcinoma, Kulchitsky cell carcinoma, small cell tumor, and carcinoma with APUD cell differentiation.

It has been suggested that SCC and carcinoids of

the lung and larynx have a common precursor, the argyrophilic Kulchitsky cells or cells of the amine precursor uptake and decarboxylation (APUD)⁵² cell system, which are cells with similar cytochemical and ultrastructural features. Cells with the characteristics of gastrointestinal Kulchitsky cells have been found in the epithelium and submucosal glands of the lower respiratory tract.⁵³ Electron microscopy and histochemical techniques have produced evidence to support the theory that both pulmonary carcinoid tumors and SCC originate from these cells.⁵³ The same cells have been found in human and canine salivary glands,⁵⁴ in the laryngeal

Fig 3. (Case 14 in Table 2) Tightly packed oat cell carcinoma cells of larynx (uranyl acetate and lead citrate, original x28,000). Note nuclear projections (arrowheads) and small number of neurosecretory granules (thin arrows) with central dense core and clear halo in cytoplasmic process (P). One cell contains well-defined Golgi system (G).



mucosa of the rat^{55,56} and guinea pig,⁵⁷ and also in human laryngeal^{29,58} and esophageal mucosa.⁵⁹ Therefore, it is not surprising that SCC and carcinoid tumors should occur in the larynx, trachea, esophagus, and salivary glands, as well as in the lung.⁴¹ Furthermore, the association of primary small cell laryngeal cancer with the Schwartz-Bart-

ter syndrome²⁸ (hypersecretion of ADH) and the Eaton-Lambert syndrome⁴⁴ (myasthenic syndrome) support the theory that such tumors in the lung and larynx have a common origin from neuroendocrine cells. The theories about embryogenesis of the cells of the APUD cell system are still controversial. For many years these cells were believed to arise from

TABLE 1. CASES OF LARYNGEAL SMALL CELL CARCINOMA REPORTED IN LITERATURE

Case	Study	Age/Sex	Site	Stage
1	Olofsson and van Nostrand ¹¹	72/F	Subglottic region	I
2	Ferlito ^{12,13†}	67/M	R hemilarynx, subglottic region	II
3	Benisch et al ¹⁴	64/M	R true and false VCs, aryepiglottic fold, pyriform sinus	II
4	Gelot et al ¹⁵	68/F	R VC	II
5	Mirejovský and Hroboň ¹⁶	69/M	L laryngeal ventricle	II
6	Bitran et al ¹⁷	72/M	L true and false VCs	II
7	Bone and Deer ¹⁸	64/M	L false VC	II
8	Dietz and Wilhelm ¹⁹	31/F	Subglottic region	II
9	Eusebi et al ²⁰	63/M	R aryepiglottic fold, arytenoid, pyriform sinus, false VC	II
10	Kyriakos et al ²²	59/M	L false VC, aryepiglottic fold, epiglottis	II
11	Kyriakos et al ²²	53/F	L false VC, aryepiglottic fold	II
12	Myerowitz et al ²³	63/M	L false VC, epiglottis	I
13	Higazi ²⁴	40/F	R arytenoid, aryepiglottic fold	I
14	Johnson et al ²⁵	68/F	Subglottic region	I
15	Lorenz and Arena ²⁶	59/M	L VC, subglottic region	II
16	Mullins et al ²⁷	45/M	Epiglottis	II
17	Trotoux et al ²⁸	61/M	Subglottic region	II
18	De la Torre-Rendón et al ²⁹	49/M	Region below R VC	III
19	Leonardelli et al ³¹	63/F	R ventricle, true VC, subglottic region	II
20	Vrabec and Bartels ³²	55/M	Epiglottis, R aryepiglottic fold, pyriform sinus, subglottic region	II
21	Gould et al ²	59/M	R VC	I
22	José et al ³³	68/M	Epiglottis, R VC, aryepiglottic fold, arytenoid	I
23	Hay and Busuttill ³⁸	59/F	L aryepiglottic fold, false VC	I
24	Hay and Busuttill ³⁸	62/F	Subglottic region, anterior commissure	II
25	Lindell et al ³⁵	40/F	True VCs, upper trachea	
26	Lindell et al ³⁵	64/F	Entire side of L larynx, subglottic region	
27	Lindell et al ³⁵	53/M	R aryepiglottic fold, medial wall pyriform sinus	
28	Lindell et al ³⁵	63/M	R arytenoid, aryepiglottic fold	
29	Lindell et al ³⁵	50/M	R aryepiglottic fold	
30	Sun et al ³⁴	52/M	L true VC with extension beyond commissure	III
31	Thompson et al ³⁹	54/M	Subglottic region	I
32	Gnepp et al ⁴¹	64/M	Anterior commissure	III
33	Gnepp et al ⁴¹	51/M	R true VC, subglottic region	I
34	Gnepp et al ⁴¹	66/M	R false VC	I
35	Gnepp et al ⁴¹	66/M		II
36	Gnepp et al ⁴¹	43/M	R pyriform sinus, false and true VCs, cricoid, esophagus	II
37	Gnepp et al ⁴¹	60/M		I
38	Gnepp et al ⁴¹	91/M	Glottic, subglottic regions	I
39	Gnepp et al ⁴¹	23/M	R true VC	II
40	Gnepp et al ⁴¹	47/M	R false and true VCs, ventricle	II
41	Mills et al ⁴⁰	58/F	Subglottic region	I
42	Mills et al ⁴⁰	49/M	R pyriform sinus	II
43	Kimmelman and Haller ⁴²	44/F	Subglottic region	III
44	Posner et al ⁴³	58/F	Subglottic region	III
45	Posner et al ⁴³	61/F	R hemilarynx, aryepiglottic fold	I
46	Posner et al ⁴³	62/F	Supraglottic region	III
47	Posner et al ⁴³	69/M	Larynx, R pyriform sinus	I
48	Medina et al ⁴⁴	64/F	L aryepiglottic fold, false VC, epiglottis	II
49	Coakley ⁴⁶	82/M	Epiglottis	II
50	Weidauer et al ⁴⁵	42/M	Subglottic region	I
51	Baugh et al ⁷	63/F	R pyriform sinus, postcricoid region	II
52	Baugh et al ⁷	35/M	L lateral pharyngeal wall, pyriform sinus	II

C — chemotherapy, DOD — dead of disease, FN — follow-up not reported, NED — no evidence of disease, PHL — pharyngolaryngectomy, PL — partial laryngectomy, RND — radical neck dissection, RT — radiotherapy, TL — total laryngectomy, VC — vocal cord.

TABLE 1 (continued). CASES OF LARYNGEAL SMALL CELL CARCINOMA REPORTED IN LITERATURE

Case	Metastases		Treatment	Follow-up
	Initial	Late		
1			RND, RT, TL	Dead at 7½ yr, NED*
2	Cervical nodes†		RND, TL	DOD in 4 mo
3	Cervical nodes	R chest wall, liver	RND, RT, TL	DOD in 5 mo
4	Cervical nodes	Pleura	Excision of neck mass, PL, RT	DOD in 1 yr
5		Liver	PL	Dead at 2 mo of peritonitis
6	Cervical nodes	Liver	C, RT	DOD in 26 mo*
7	Cervical nodes	Pleura, mediastinum, ribs, diaphragm, heart, lungs, liver, mesentery, omentum, peria renal fat	PL, RND, RT	DOD in 4 mo
8	Paratracheal nodes		Partial thyroidectomy, RT, TL	Alive, NED at 6 mo
9	Cervical nodes		PL, RND	DOD in 2 yr*
10	Cervical nodes	Liver, bone marrow	RT	DOD in 3½ mo
11	Cervical nodes	Sternum, bone marrow	PL, RND, RT	DOD in 13½ mo
12		Cervical nodes, mediastinal nodes, lungs, liver, adrenal glands	C, PL, RND	DOD in 10 mo
13		Cervical nodes	RND, RT	FN
14		Cervical nodes, bone marrow, spleen, liver, pancreas, thyroid, anterior pituitary, lungs	RT, thyroid lobectomy, TL	DOD in 10 mo
15	Cervical nodes	Pancreas, liver	Partial thyroidectomy, RND, TL	DOD in 1 yr*
16	Cervical nodes	Liver	C, PL, RND, RT	DOD in 1 yr 7 mo*
17	Cervical nodes	Liver (?)	RND, RT	DOD in 4 mo
18	Liver, lungs		None	Dead before any active treatment
19	Cervical nodes		RT	Alive, NED at 1 yr
20	Cervical nodes		C, RT	Alive, NED at 3 yr 9 mo*
21		Mediastinum, liver, lungs	C, RT	DOD in 1 yr 6 mo
22		Metastases (unspecified)	RT, TL	DOD in 4 yr 6 mo*
23		Scalp, submandibular area, posterior chest wall, inner canthus	C, RT	DOD in 1 yr 3 mo
24	Cervical nodes	Liver	C, RT	DOD in 2 mo
25	Brain			FN
26				FN
27			PL, RT	FN
28	Groin, perineum			FN
29	Liver			FN
30	Cervical nodes, scapula	Lungs, vertebrae, brain, leptomeninges	RT	DOD in 2 mo
31			C, RT	Dead at 4½ yr of IgD myeloma*
32	Cervical nodes, lung, scapula		None	DOD in 1 mo
33		Humerus, iliac wing	C, RT, TL	DOD in 10 mo
34			Partial thyroidectomy, TL	Alive, NED at 7½ yr
35	Cervical nodes	Inguinal nodes, bone, liver, lung, adrenal gland, psoas muscle	RT	DOD in 6½ mo
36	Cervical nodes	Lungs, hilar nodes in axilla, liver, dura	RT	DOD in 1 yr 1 mo
37		Liver, lung, peritoneum, bone marrow	RND, RT, TL	DOD in 10½ mo
38			None	DOD in 1½ mo
39	Cervical nodes		RT	Dead at 11 mo of adenocarcinoma of pancreas
40	Cervical nodes	Brain	RND, RT, TL	DOD in 1 yr
41			C, RT, thyroidectomy, TL	DOD in 1 yr 1 mo
42	Cervical nodes		Lymphadenectomy, PHL, RT	Alive, NED at 6 mo
43	Bone (multiple)		C, RT	DOD in 1 yr*
44	Cervical nodes, bone marrow, liver, spleen, bone		C	DOD in 9 mo
45			C, RT	Alive, NED at 1 yr 3 mo
46	Cervical nodes, bone marrow, liver, spleen, bone, epidural		C	DOD in 6 mo
47		Liver	C, TL	DOD in 1 yr 7 mo
48	Cervical nodes	Several organs	C, RT	DOD in 10 mo
49	Cervical nodes		RT	DOD in 5 mo
50		Cervical nodes, liver, spinal cord	C, RND, TL	DOD in 10 mo
51	Cervical nodes		C, excision of neck mass	Alive, NED at 4 yr 7 mo
52	Cervical nodes		RT	Alive, NED at 1 yr 9 mo

*Current follow-up information received from direct communication with authors.

†This case was encountered at Verona Section of Department of Otolaryngology at Padua University.

TABLE 2. CASES OF LARYNGEAL SMALL CELL CARCINOMA DIAGNOSED FROM JANUARY 1966 TO DECEMBER 1984

Case	Age/Sex	Smoking History	Symptoms	Site	SCC Subtype and Stage	
1	50/M	20 Cig/d	Hoarseness	L hemilarynx	CS	I
2*	70/M	20 Cig/d	Hoarseness, neck mass	L true and false VCs, region below VC	ICS	II
3	57/M	40 Cig/d	Neck mass†	R PS	CS	II
4	59/M	40 Cig/d	Hoarseness	True VCs, anterior commissure	OCS	I
5	56/M	15 Cig/d	Dysphagia	Epiglottis	CS	I
6	53/M	20 Cig/d	Dysphagia	L aryepiglottic fold, arytenoid, PS	OCS	II
7	73/M	15 Cig/d	Hoarseness, dyspnea	Subglottic region	OCS	I
8	59/M	20 Cig/d	Hoarseness, dysphagia	Epiglottis, L false VC	OCS	II
9	45/M	5 Cig/d	Dysphagia	R aryepiglottic fold, PS	CS	II
10	47/M	20 Cig/d	Dysphagia, neck mass	R aryepiglottic fold, PS	CS	II
11	54/M	30 Cig/d	Hoarseness, neck mass	True VCs, anterior commissure, subglottic region	CS	I
12	58/M	20 Cig/d	Neck mass†	R PS, posterior hypopharyngeal wall	OCS	II
13	73/F	60 Cig/d	Dysphagia	Epiglottis	OCS	II
14	61/M	20 Cig/d	Hoarseness†	R hemilarynx	OCS	II

C — chemotherapy, Cig — cigarettes, CS — combined subtype, DOD — dead of disease, ICS — intermediate cell subtype, NED — no evidence of disease, OCS — oat cell subtype, PS — pyriform sinus, RND — radical neck dissection, RT — radiotherapy, SCI — symptomatic cranial irradiation, TL — total laryngectomy, TPH — total pharyngolaryngectomy, VC — vocal cord.

*Patient had squamous cell carcinoma 7 years earlier.

†Electron microscopy showed neurosecretory granules.

the neural crest, but recent data support an endodermal origin,³ since SCC may develop into squamous cell carcinoma and adenocarcinoma.^{44,60}

Using an immunoperoxidase technique, Springall et al⁴⁸ and Weidauer et al⁴⁵ recently demonstrated the presence of neuron-specific enolase (a marker for mammalian nerves and endocrine cells) in laryngeal SCC. Neuron-specific enolase has been found in various types of neuroendocrine tumors.⁶¹ It is possible that the determination of blood levels of specific peptides, such as serum neuron-specific enolase, may be a useful marker for staging, monitoring treatment, and predicting relapse in patients with SCC.⁶²

The histogenesis of combined SCC is not well understood. It is still not known whether such "composite" or "mixed" neoplasms derive from a common cell, with subsequent divergent differentiation into Kulchitsky cells, squamous cells, and/or glandular cells; from several stem cells; or from the differentiation of neoplastic cells into squamous, glandular, and neuroendocrine cell lines.⁴¹ The first possibility appears to be the most probable. The differentiation of a neoplastic stem cell into two or more morphologically and structurally different neoplastic cells has also been demonstrated experimentally,⁶³ and is well established in hematologic malignancies.⁶⁴ Recent evidence based on biochemical findings and pathologic morphology also supports this thesis.^{65,66} The coexistence of tonofilaments, desmosomes, neurosecretory granules, and intracellular lumen or mucous granules in a same cell in SCC of the lung⁶⁷ and of the larynx³⁴ supports the hypothesis that these tumors arise from a common primitive cell. Mills et al⁴⁰ investigated

two cases of SCC of the larynx ultrastructurally and found many cells exhibiting both squamous features (intracytoplasmic tonofilaments and desmosomes) and neuroendocrine differentiation (dense core granules). Moreover, one of the tumors was light microscopically biphasic, with both small cell and squamous components. Therefore different forms of differentiation were seen, not only within individual tumors, but also within individual tumor cells. Numerous dense core granules and abundant tonofilaments were also seen in an atypical carcinoid tumor of the larynx.⁶⁸

Six cases of combined SCC of the larynx were present in my series, and similar cases have been reported in the literature.^{20,40,41} In two of my cases of SCC (12 and 14), tonofilaments and a few desmosomes and neurosecretory granules were identified by electron microscopy in single neoplastic cells. Similar findings were observed in a metastatic lymph node of case 14.

Mucin production, the formation of intracellular lumens, tonofilaments, neurosecretory granules, and intercellular desmosomes were observed in the histologic and ultrastructural study of an interesting case of laryngeal SCC reported by Sun et al.³⁴ In particular, there was the unusual coexistence of tonofilaments and neurosecretory granules in the same cell. This finding suggests the occurrence of multidirectional differentiation in individual tumor cells, which can be demonstrated by ultrastructural and immunohistochemical studies, as well as by light microscopy.

The diagnosis of SCC cannot be made radio-

TABLE 2 (continued). CASES OF LARYNGEAL SMALL CELL CARCINOMA DIAGNOSED FROM JANUARY 1966 TO DECEMBER 1984

Case	Metastases		Treatment	Follow-up
	Initial	Late		
1		Cervical node (after 9 mo)	L RND (after 9 mo), RT, TL	DOD in 1 yr 2 mo
2	Cervical node		Excision of L cervical node, TL	DOD in 1 yr 8 mo
3	Cervical nodes	Ninth thoracic vertebra, 7th and 8th R ribs, 5th L rib (after 1 mo)	R RND, RT, TPH	DOD in 3½ mo
4			C, RT	Alive, NED at 7 yr 3 mo
5			C, RT	Alive, NED at 6 yr 6 mo
6	Cervical nodes	Lungs, brain	C, L RND, RT	DOD in 1 yr 7 mo
7			RT	DOD in 3 yr 3 mo
8	Cervical node		C, RT	Alive, NED at 6 yr 1 mo
9	Cervical nodes		C, RT	Dead in 1 yr 9 mo of squamous cell carcinoma of oral cavity
10	Cervical nodes	Lungs (after 2 yr 5 mo), brain and bone (after 3 yr 9 mo)	C, RT, C (after 2 yr 5 mo), SCI (after 3 yr 9 mo)	DOD in 4 yr
11			Bilateral RND, RT, TL	Alive, NED at 3 yr 6 mo
12	Cervical nodes		C, RT	Dead during course of treatment
13	Cervical nodes		RT	Alive, NED at 1 yr 3 mo
14	Cervical nodes	Subcutaneous, liver, mediastinal and abdominal nodes	Bilateral RND, C, hemilaryngectomy, RT	DOD in 1 yr 6 mo

graphically, and symptomatology is nonspecific.³⁵ The diagnosis is based essentially on the microscopic appearance of the tumor and confirmed by ultrastructural evidence of neurosecretory granules. Histochemical reactions and immunohistochemical investigations may support it. Useful criteria for diagnosing this tumor include the following.

1. Small tumor cells are of varied shapes with scanty cytoplasm and relatively large, extremely hyperchromatic, oval, round, or spindle-shaped nuclei, with delicate chromatin and inconspicuous nucleoli. Some cells may have a prominent nucleolus.
2. Mitotic activity is high.
3. Ribbons and occasionally rosettes may be present.
4. Tumor necrosis is usually prominent.
5. The stroma is scanty and may be mucoid.
6. Perivascular, intravascular, perineural, and skeletal muscle invasion is commonly seen.
7. Crushing artifact may be observed, particularly in small laryngeal biopsies.
8. Host response in the form of lymphocytes and fibroblasts is usually absent.
9. Margins are infiltrating.
10. Argyrophil methods (Grimelius, Sevier-Munger, Pascual, Churukian-Schenk, Bodian, Wilder) rarely produce positive results.
11. Generally the results of argentaffin methods (Fontana-Masson, Diazo, Schmorl) are negative.
12. Mucosubstance stains may show positive material within the glands as well as within individual neoplastic cells.
13. Cytoplasmic dense core endocrine-type granules are usually observed at electron microscopy. Occasionally tonofilaments and desmosomes are present.
14. Immunoperoxidase studies may give positive reactions for some histochemical markers (cal-

citonin, somatostatin, neuron-specific enolase, ACTH, etc).

15. Immunofluorescence, using antibodies against neurofilaments, may identify intermediate filaments.
16. Paraneoplastic syndromes may occur secondarily to laryngeal SCC.

Small cell carcinomas of the larynx have been divided into the oat cell type, intermediate cell type, and combined cell type.¹⁰ Small cell carcinomas of the oat cell type are characterized by uniform small cells with a very sparse cytoplasm. The intermediate form of SCC is very similar, but the neoplasm consists of polygonal or fusiform cells, and the cytoplasm is abundant and visible. Large cells may occur. Nuclear characteristics are more important than the size or shape of the neoplastic cells in reaching a correct diagnosis. Combined SCCs are tumors in which there is a definite component of SCC (oat cell carcinoma or intermediate cell type) together with squamous cell carcinoma or adenocarcinoma. Laryngeal SCC may exhibit exocrine (mucosubstance production) and neuroendocrine differentiation (dense core granules) and may be referred to as amphoteric tumors.

Sometimes these tumors produce a pseudoglandular appearance, which may resemble that of carcinoid tumor. In a few cases, several neoplastic multinucleated giant cells may also be identified in nonirradiated and untreated small cell tumors of the larynx, as with lung SCC.^{69,70}

It is important to recognize laryngeal SCC as a distinct clinicopathologic and biologic entity. It has an aggressive biologic behavior, with early invasion and metastases via the blood stream and lymphatic system, and a rapid clinical course. The most common sites of metastatic spread are the cervical lymph nodes, liver, lung (Fig 4A), bone (Fig 4B),

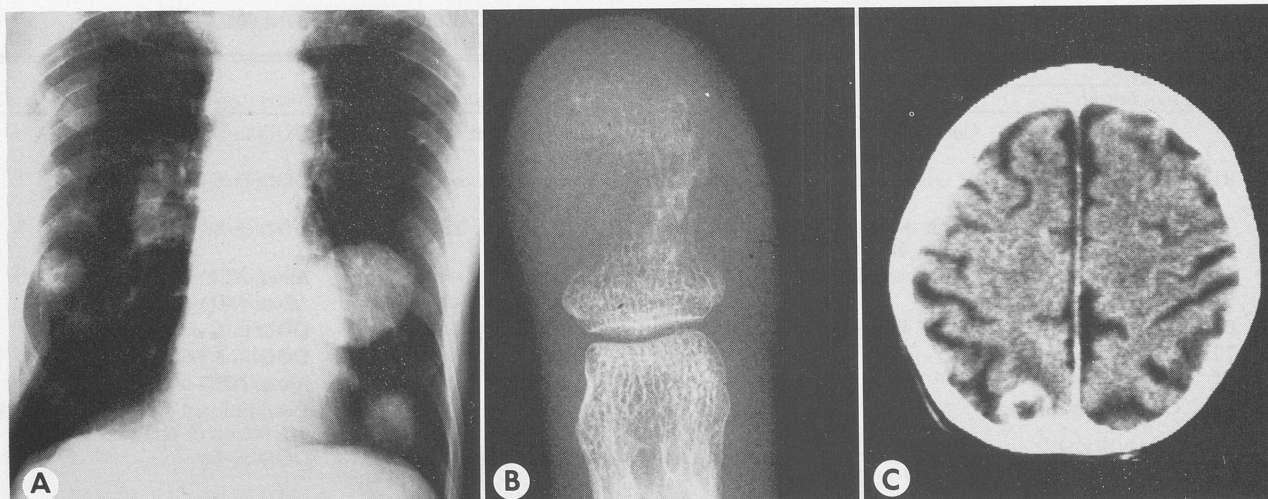


Fig 4. (Case 10 in Table 2) Radiographs. A) Chest x-ray film showing multiple metastases from combined SCC of larynx. B) X-ray film of right middle finger showing metastasis in distal phalanx. C) CT scan showing brain metastasis in left occipital lobe.

and bone marrow.

The differential diagnosis includes carcinoid, atypical carcinoid, small cell squamous carcinoma (or "pseudo" oat cell carcinoma), SCC of salivary duct origin, lymphoma, and mycosis fungoides. In addition, it is also important to ascertain whether the SCC is primary or a metastasis from a bronchogenic or tracheal SCC. This possibility is extremely rare, and only two cases were found in a recent review⁷¹ of the literature.

Laryngeal carcinoids^{2,3,10} show uniform cuboidal cells with pale cytoplasm, moderately prominent nucleoli, and sparse mitoses. Usually necrosis is absent. The neurosecretory granules are larger and more numerous than in SCC. Argyrophilic method results are usually positive in carcinoid. The primary difference between the two neuroendocrine tumors lies in the degree of differentiation. Atypical laryngeal carcinoid may present a particular diagnostic dilemma.⁶⁸

Electron microscopy is very useful in distinguishing between SCC and small cell squamous carcinoma, as it can reveal the presence of neurosecretory granules in the tumor cells. Dense core granules are absent in SCC of salivary duct origin. The presence of spindle-shaped cells, rosettes, and glandular structures in SCC and the usually high mitotic index may assist in the differential diagnosis with malignant lymphoma. In addition the neoplastic cells of SCC are larger and more pleomorphic than those of lymphoma. Studies with immunoperoxidase to document carcinoembryonic antigen within the tumor cells showed that it can appear in SCC but is absent in lymphoma.⁴³ Mycosis fungoides involving the larynx^{72,73} may also be difficult to distinguish from SCC. A polymorphic lymphocytic infiltrate, mycosis cell with cerebriform nuclei, and Pautrier mucosal microabscesses are distinguishing features of mycosis fungoides.

Tumor staging is mandatory for therapeutic and prognostic reasons, and examination should include the following: chest radiographs, whole lung tomography, panendoscopy, bone scintigraphy, liver echotomography, iliac crest bone marrow aspiration and biopsy, computed tomography of the brain, and laboratory investigations.

The tumors may be classified according to the following clinical staging system: stage I — limited (to larynx), stage II — locoregional (tumor is confined to larynx including ipsilateral and/or contralateral cervical and supraclavicular lymph nodes), and stage III — extensive (distant metastases are present).

Restaging is absolutely necessary to evaluate the disease's course and the results of therapy. The extent of the disease and the performance status of the patient are the most important prognostic indicators of survival. Biologic properties inherent in the neoplastic cells themselves may play a role in response to therapy.

Treatment of laryngeal SCC remains a challenge for physicians. Radical surgical procedures (total laryngectomy and radical neck dissection) have failed in the majority of cases reported. Radiotherapy combined with systemic chemotherapy, as for SCC of the lung, might improve the prognosis.^{7,17,74} Commonly used agents include cyclophosphamide, doxorubicin hydrochloride, vincristine sulfate, methotrexate, and lomustine. The role of surgery in the treatment of SCC of the larynx is still controversial. The first reports indicate that surgery alone is inadequate. Surgical therapy may be used initially in localized SCC of the larynx as part of a multidisciplinary therapy including chemotherapy and radiotherapy. But total laryngectomy is not justifiable if a form of treatment that preserves the voice and improves the clinical course is possible. Radiotherapy alone has been used successfully to control limited

neoplasm. However, in consideration of the early widespread dissemination, intensive systemic chemotherapy is usually indicated. Some patients may already have disseminated tumor at the time of the diagnosis, and in such cases a course of multiagent chemotherapy is warranted. Sometimes the disease is only apparently localized, and therefore the lesion should be treated aggressively. Only rigorous staging procedures can reveal the extent of the tumor. Occult metastases may be present, and it is advisable to avoid primary unimodality therapies, such as radiotherapy or surgery alone.

These observations support the view that a combination of multichemotherapy and radiotherapy is effective in some cases of laryngeal SCC and seems to

offer the best results. The survival of patients treated in this way may be significantly improved, and some patients can even be cured (cases 4, 5, and 8). Three of our patients are clinically disease-free (7 years, 3 months; 6 years, 6 months; and 6 years, 1 month after diagnosis). But long-term survival (greater than 5 years) is restricted to stage I (cases 4 and 5) and stage II (case 8) patients. Although local treatment, whether surgery, radiotherapy, or both, can occasionally give long-term survival,^{11,41} the possibility of occult metastases makes the use of systemic chemotherapy in the initial treatment advisable.

Metastases to the CNS are rare in SCC of the larynx (Fig 4C) and occur as a preterminal event. The use of prophylactic cranial irradiation is not indicated.

REFERENCES

1. Fer FM, Levenson RM Jr, Cohen MH, Greco FA. Extrapulmonary small cell carcinoma. In: Greco FA, Oldham RK, Bunn PA Jr, eds. Small cell lung cancer. New York: Grune and Stratton, 1981: 301-25.
2. Gould VE, Banner BF, Baerwaldt M. Neuroendocrine neoplasms in unusual primary sites. *Diagn Histopathol* 1981; 4: 263-77.
3. Gould VE. Neuroendocrine tumors in "miscellaneous" primary sites: clinical, pathologic, and histogenetic implications. In: Fenoglio CM, Wolff M, eds. Progress in surgical pathology IV. New York: Masson Publ, 1982: 181-98.
4. Hull MT, Eble JN, Warfel KA. Extrapulmonary oat-cell carcinoma of the tongue: an electron-microscopic study. *J Oral Pathol* 1984; 13:489-96.
5. Ibrahim NBN, Briggs JC, Corbishley CM. Extrapulmonary oat cell carcinoma. *Cancer* 1984; 54:1645-61.
6. Levenson RM, Ihde DC, Matthews MJ, et al. Small cell carcinoma presenting as an extrapulmonary neoplasm: sites of origin and response to chemotherapy. *JNCI* 1981; 67:607-12.
7. Baugh R, Wolf G, McClatchey KD. Small cell carcinoma of the head and neck. *Head Neck Surg* 1986; 8:343-54.
8. Fer MF, Oldham RK, Richardson RL, Hande KR, Greco FA. Extrapulmonary small cell carcinoma. *Proc Am Assoc Cancer Res* 1980; 21:475.
9. Kasimis BS, Wuerker RB, Malefatto JP, Moran EM. Prolonged survival of patients with extrapulmonary small cell carcinoma arising in the neck. *Med Pediatr Oncol* 1983; 11:27-32.
10. Ferlito A. Malignant epithelial tumors of the larynx. In: Ferlito A, ed. Cancer of the larynx. Vol 1. Boca Raton, Fla: CRC Press, 1985: 91-195.
11. Olofsson J, van Nostrand AWP. Anaplastic small cell carcinoma of larynx. Case report. *Ann Otol Rhinol Laryngol* 1972; 81: 284-7.
12. Ferlito A. Oat cell carcinoma of the larynx. *Ann Otol Rhinol Laryngol* 1974; 83:254-6.
13. Ferlito A. Oat cell carcinoma of the larynx [Letter to editor]. *Ann Otol Rhinol Laryngol* 1974; 83:834.
14. Benisch BM, Tawfik B, Breitenbach EE. Primary oat cell carcinoma of the larynx: an ultrastructural study. *Cancer* 1975; 36:145-8.
15. Gelot R, Rhee TR, Lapidot A. Primary oat-cell carcinoma of head and neck. *Ann Otol Rhinol Laryngol* 1975; 84:238-44.
16. Mirěšovský P, Hroboň M. Small cell carcinoma of the larynx. *Cesk Patol* 1975; 11:45-9.
17. Bitran JD, Toledo-Pereyra LH, Matz G. Oat cell carcinoma of the larynx. Response to combined modality therapy. *Cancer* 1978; 42:85-7.
18. Bone RC, Deer D. Oat cell carcinoma of the larynx. *Laryngoscope* 1978; 88: 1190-5.
19. Dietz R, Wilhelm HJ. Therapie des primären "oat-cell" Karzinoms des Larynx. *Laryngol Rhinol Otol (Stuttg)* 1978; 57: 1072-6.
20. Eusebi V, Betts CM, Giangaspero F. Primary oat-cell carcinoma of the larynx. *Virchows Arch [Pathol Anat]* 1978; 380: 349-54.
21. Ferlito A. Primary oat-cell carcinoma of the larynx following supraglottic laryngectomy for squamous cell carcinoma. *J Am Geriatr Soc* 1978; 26:278-83.
22. Kyriakos M, Berlin BP, De Schryver-Kecsckemeti K. Oat cell carcinoma of the larynx. *Arch Otolaryngol* 1978; 104:168-76.
23. Myerowitz RL, Barnes EL, Myers E. Small cell anaplastic (oat cell) carcinoma of the larynx: report of a case and review of the literature. *Laryngoscope* 1978; 88:1697-702.
24. Higazi MT. Primary oat cell carcinoma of the larynx. *J Laryngol Otol* 1979; 93:835-7.
25. Johnson GD, Abt AB, Mahataphongse VP, Conner GH. Small cell undifferentiated carcinoma of the larynx. *Ann Otol Rhinol Laryngol* 1979; 88:774-8.
26. Lorenz SA III, Arena S. Primary oat cell carcinoma of the larynx. *Penn Med* 1979; 82:41-2.
27. Mullins JD, Newman RK, Coltman CA Jr. Primary oat cell carcinoma of the larynx: a case report and review of the literature. *Cancer* 1979; 43:711-7.
28. Trotoux J, Glickmanas M, Sterkers O, Troussset M, Pinel J. Syndrome de Schwartz-Bartter: révélateur d'un cancer laryngé sous-glottique à petites cellules. *Ann Otolaryngol Chir Cervicofac* 1979; 96:349-58.
29. De la Torre-Rendón FE, Cisneros-Bernal E, Ochoa-Salas JA, Delfino-Reynoso HA. Carcinoma indiferenciado de células pequeñas de la laringe. Presentación de un caso con metástasis masivas al hígado. *Patología* 1979; 17:47-57.
30. Ferlito A, Polidoro F. Simultaneous primary oat cell carcinoma (apudoma) and squamous cell carcinoma of the hypopharynx. *ORL J Otorhinolaryngol Relat Spec* 1980; 42:146-57.
31. Leonardelli GB, Cova PL, Pignataro O, Sambataro G. Carcinoma anaplastico a piccole cellule (cd. microcitoma) primitivo della laringe (1 caso e revisione della letteratura). *Nuovo Arch Ital Otol* 1980; 8:175-84.
32. Vrabec DP, Bartels LJ. Small cell anaplastic carcinoma of the larynx: review of the literature and report of a case. *Laryngoscope* 1980; 90:1720-6.
33. José B, Conley JG, Tobin DA, Dorman DW. Primary oat

- cell carcinoma of the larynx: a case history and literature review. *J Surg Oncol* 1981; 16:43-7.
34. Sun CJ, Hall-Craggs M, Adler B. Oat cell carcinoma of larynx. *Arch Otolaryngol* 1981; 107:506-9.
 35. Lindell MM, Jing B, Mackay B. Primary oat cell carcinoma of the larynx. *AJR* 1981; 137:555-7.
 36. Pizzi GB, Sotti G, Zorat PL, et al. Chemo-radiotherapy regimen in the treatment of the oat-cell carcinoma of the larynx. Abstract presented at the UICC Conference on Clinical Oncology [Abstr 02-0104]. Lausanne, Switzerland, Oct 28-31, 1981.
 37. Ferlito A, Caruso G, Nicolai P, Recher G, Silvestri F. Primary small cell ('oat cell') carcinoma of the larynx and hypopharynx. A clinico-pathological study of 8 cases with a review of the literature. *ORL J Otorhinolaryngol Relat Spec* 1981; 43:204-22.
 38. Hay JH, Busuttill A. Oat-cell carcinoma of the larynx. *J Laryngol Otol* 1981; 95:1081-8.
 39. Thompson DH, Kao YH, Klos J, Fay J, Fetter TW. Primary small cell (oat cell) carcinoma of the larynx associated with an IgD multiple myeloma. *Laryngoscope* 1982; 92:1239-44.
 40. Mills SE, Cooper PH, Garland TA, Johns ME. Small cell undifferentiated carcinoma of the larynx: report of two patients and review of 13 additional cases. *Cancer* 1983; 51:116-20.
 41. Gnepp DR, Ferlito A, Hyams V. Primary anaplastic small cell (oat cell) carcinoma of the larynx. Review of the literature and report of 18 cases. *Cancer* 1983; 51:1731-45.
 42. Kimmelman CP, Haller DG. Small cell carcinomas of the head and neck. *Otolaryngol Head Neck Surg* 1983; 91:708-12.
 43. Posner MR, Weichselbaum RR, Carrol E, Fabian RL, Miller D, Ervin TJ. Small cell carcinomas of the larynx: results of combined modality treatments. *Laryngoscope* 1983; 93:946-8.
 44. Medina JE, Moran M, Goepfert H. Oat cell carcinoma of the larynx and Eaton-Lambert syndrome. *Arch Otolaryngol* 1984; 110:123-6.
 45. Weidauer H, Blobel GA, Nemetschek-Gansler H, Gould VE, Mall G. Das neuro-endokrine Larynxkarzinom vom kleinzelligen (oat-cell) Typ. Morphologische und immunohistochemische Befunde und ihre Bedeutung für die Therapie. *Laryngol Rhinol Otol* (Stuttg) 1985; 64:121-7.
 46. Coakley JF. Primary oat cell carcinoma of the larynx. *J Laryngol Otol* 1985; 99:301-3.
 47. Ferlito A, Recher G, Caruso G. Primary combined small cell carcinoma of the larynx. *Am J Otolaryngol* 1985; 6:302-8.
 48. Springall DR, Ibrahim NBN, Polak JM. Endocrine nature of oesophageal and laryngeal small cell carcinoma demonstrated by immunohistochemistry with antibodies to neuron specific enolase. *J Pathol* 1985; 145:79A.
 49. Fletcher GH, Goepfert H. The role of irradiation in the treatment of cancer of the larynx. In: Ferlito A, ed. *Cancer of the larynx*. Vol 3. Boca Raton, Fla: CRC Press, 1985: 69-114.
 50. Aguilar EA, Robbins KT, Stephen J, Batsakis JG, Dimery IW. Primary oat cell carcinoma of the larynx. Abstract presented at the XIII World Congress of Otorhinolaryngology [Abstr 358]. Miami Beach, Fla, May 26-31, 1985.
 51. Michaels L. *Pathology of the larynx*. Berlin: Springer-Verlag, 1984: 64.
 52. Pearse AGE. Common cytochemical properties of cells producing polypeptide hormones (the APUD series) and their relevance to thyroid and ultimobranchial C-cells and calcitonin. *Proc R Soc Lond [Biol]* 1968; 170:71-80.
 53. Bensch KG, Corrin B, Pariente R, Spencer H. Oat cell carcinoma of the lung: its origin and relationship to bronchial carcinoma. *Cancer* 1968; 22:1163-72.
 54. Bribiesca LB, Ramos MM, Horta RF, Vivar G. Celular del sistema Apud en glándulas salivales. *Patologia* 1978; 16:253-69.
 55. Ewen SWB, Bussolati G, Pearse AGE. Uptake of L-dopa and L-5-hydroxytryptophan by endocrine-like cells in the rat larynx. *Histochem J* 1972; 4:103-10.
 56. Lewis DJ, Prentice DE. The ultrastructure of rat laryngeal epithelia. *J Anat* 1980; 130:617-32.
 57. Kirkeby S, Romert P. Argrophilic cells in the larynx of the guinea pig demonstrated by the method of Grimelius. *J Anat* 1977; 123:87-92.
 58. Pesce C, Tobia-Gallelli F, Toncini C. APUD cells of the larynx. *Acta Otolaryngol* (Stockh) 1984; 98:158-62.
 59. Tateishi R, Taniguchi H, Wada A, Horai T, Taniguchi K. Argrophil cells and melanocytes in esophageal mucosa. *Arch Pathol* 1974; 88:87-9.
 60. Yesner R. Are small-cell carcinomas of the lung derived from neural crest? *N Engl J Med* 1980; 303:51.
 61. Tapia FJ, Polak JM, Barbosa AJA, et al. Neuron-specific enolase is produced by neuroendocrine tumours. *Lancet* 1981; 1: 808-11.
 62. Johnson DH, Marangos PJ, Forbes JT, et al. Potential utility of serum neuron-specific enolase levels in small cell carcinoma of the lung. *Cancer Res* 1984; 44:5409-14.
 63. Kobori O, Oota K. Neuroendocrine cells in serially passaged rat stomach cancers induced by MNNG. *Int J Cancer* 1979; 23:536-41.
 64. Richardson RL, Weiland LH. Undifferentiated small cell carcinomas in extrapulmonary sites. *Semin Oncol* 1982; 9:484-96.
 65. Baylin SB, Gazdar AF. Endocrine biochemistry in the spectrum of human lung cancer: implications for the cellular origin of small cell carcinoma. In: Greco FA, Oldham RK, Bunn PA Jr, eds. *Small cell lung cancer*. New York: Grune and Stratton, 1981: 123-43.
 66. Gazdar AF, Carney DN, Guccion JG, Baylin SB. Small cell carcinoma of the lung: cellular origin and relationship to other pulmonary tumors. In: Greco FA, Oldham RK, Bunn PA Jr, eds. *Small cell lung cancer*. New York: Grune and Stratton, 1981: 145-75.
 67. McDowell EM, Trump BF. Pulmonary small cell carcinoma showing tripartite differentiation in individual cells. *Hum Pathol* 1981; 12:286-94.
 68. Mills SE, Johns ME. Atypical carcinoid tumor of the larynx: a light and ultrastructural study. *Arch Otolaryngol* 1984; 110:58-62.
 69. Bégin P, Sahai S, Wang NS. Giant cell formation in small cell carcinoma of the lung. *Cancer* 1983; 52:1875-9.
 70. Matthews MJ. Pathology of small cell lung cancer. *Clin Oncol* 1985; 4:11-29.
 71. Ferlito A, Caruso G. Secondary malignant melanoma of the larynx. Report of 2 cases and review of 79 laryngeal secondary cancers. *ORL J Otorhinolaryngol Relat Spec* 1984; 46:117-33.
 72. Hood AF, Mark GJ, Hunt JV. Laryngeal mycosis fungoides. *Cancer* 1979; 43:1527-32.
 73. Ferlito A, Recher G. Laryngeal involvement by mycosis fungoides. *Ann Otol Rhinol Laryngol* 1986; 95:275-7.
 74. Reddy GN, Vrabec DP, Bernath AM. Primary oat cell carcinoma of the larynx. *Penn Med* 1980; 83:22.

ADDENDUM

Since submission of this article, two papers have appeared in the literature. 1) Woodruff JM, Huvos AG, Erlandson RA, Shah JP, Gerold FP. Neuroendocrine carcinomas of the larynx. A study of two types, one of which mimics thyroid medullary carcinoma. *Am J Surg Pathol* 1985; 9:771-90. 2) Chen DA, Mandell-Brown M, Moore SF, Johnson JT. 'Composite' tumor — Mixed squamous cell and small-cell anaplastic carcinoma of the larynx. *Otolaryngol Head Neck Surg* 1986; 95:99-103.

THE QUIET REVOLUTION

TECHNIQUES OF CELL BIOLOGY APPLIED TO TISSUE DIAGNOSIS

A. W. PETER VAN NOSTRAND, MD, FRCP(C)

TORONTO, CANADA

In the past decade many of the techniques of cell biology developed in the research laboratory have been applied to tissue diagnosis. Increasing use of electron microscopy has allowed ready differentiation of many neoplasms with an identical appearance under the light microscope. The identification of highly specific antigenic substances in individual cells using monoclonal antibodies in the immunoperoxidase technique has allowed a degree of diagnostic accuracy not previously available in tissue diagnosis. Recent efforts have been directed at more accurately predicting biological behavior on the basis of cellular characteristics. Techniques being introduced include morphometry (computer-assisted image analysis), cytophotometry (measurement of cellular DNA content), flow cytometry (analysis of cells in suspension for DNA content and other physical and chemical properties), scanning electron microscopy, and cytogenetics (the study of cellular chromosomes).

KEY WORDS — cytogenetics, cytophotometry, flow cytometry, immunoperoxidase, monoclonal antibodies, scanning electron microscopy.

The biomedical research of today will determine medical practice tomorrow. This dictum is particularly applicable to the laboratory techniques being used to establish tissue diagnoses and predict biological behavior in human cancer.

In the past decade many of the techniques of cell biology developed in the research laboratory have been applied to tissue diagnosis. While the examination of routine histologic sections by the light microscope remains the mainstay of tissue diagnosis, a number of innovative techniques have been developed that allow us to go beyond what can be accomplished by examining routinely stained histologic sections. While some of these techniques have come into widespread use, they have in no way supplanted the paraffin-embedded tissue section stained with hematoxylin and eosin; "microscopic examination of tissue continues to be the sole manner in which the unequivocal diagnosis of cancer is made."¹

TUMOR DIAGNOSIS

Many of the techniques currently being applied in tumor diagnosis are designed to provide a more precise and accurate histologic diagnosis. The increasing importance of these techniques has been stimulated by the development of new and specific treatment modalities that are effective only when applied to specific neoplasms. Such techniques, especially those using monoclonal antibodies, include electron microscopy and immunohistochemistry.

Electron Microscopy. The technique of electron microscopy has been available for more than 20 years. The greater magnification provided by this instrument allows ready differentiation of most small cell tumors occurring in the head and neck areas.

Malignant lymphomas, anaplastic carcinomas, esthesioneuroblastomas, malignant melanomas, pituitary tumors, and some inflammatory lesions may be "look-alikes" by the light microscope, but can usually be readily distinguished by the electron microscope.

Immunoperoxidase Technique. The development of the immunoperoxidase technique and its increasingly widespread use in laboratory diagnosis constitutes one of the most significant and fundamental new tools in medicine.² The ability to identify highly specific antigenic substances in individual cells has allowed the ready differentiation of epithelial cells (keratin producing) from mesenchymal cells (vimentin producing) and from cells of the lymphoid series (producing specific immunoglobulins).

Antisera Identification. Increasing use is being made of specific antisera to identify tumors of neurogenic origin, thyroid origin, parathyroid origin, prostatic origin, and colonic origin. Antigenic profiles produced by combining the results of specific antisera have been developed for tumors originating in the kidney, liver, lung, salivary gland, testis, and ovary.

Monoclonal Antibodies. The current classification of non-Hodgkin's malignant lymphomas rests very heavily on the identification of specific protein substances within the neoplastic cells. The production of monoclonal antibodies against these and literally hundreds of other specific substances using the hybridoma technique in mouse myeloma cells has opened the door to a new era of specificity in diagnostic medicine.

Tissue Removal. It is no longer acceptable for a surgeon faced with a young patient with an en-

From the Departments of Pathology and Otolaryngology, University of Toronto.

Presented at the meeting of the American Laryngological Association, Palm Beach, Florida, May 4-5, 1986.

REPRINTS — A. W. P. van Nostrand, MD, Toronto General Hospital, 200 Elizabeth St, Toronto, Canada M5G 1L7.

larged cervical lymph node to simply remove it, drop it into a bottle of formalin, and send it off to the pathology department for diagnosis. It is not necessary to have an electron microscope at your elbow or a whole battery of trained technologists and expensive antisera in order to take advantage of these and other techniques. What is required is a little forethought and clinical judgment regarding the proper harvesting of tissue. This judgment will be based on the clinical history, which the surgeon must provide in detail to the pathologist in order for the tissue to be handled appropriately in the laboratory. In order for many of these techniques to be performed satisfactorily, the specimen must be submitted to the pathologist in the fresh, rather than the fixed, state. For optimum results, the specimen should be provided as soon as possible after removal from the patient. A tiny snippet of tissue placed in fixative for electron microscopy, a small portion of a biopsy fixed in alcohol rather than formalin, or a small piece of tissue snap-frozen in liquid nitrogen may be all that is required to provide sophisticated diagnoses to patients in areas remote from university teaching centers.

PREDICTING BIOLOGICAL BEHAVIOR

Other techniques are currently being applied in tissue diagnosis that are designed to more accurately predict the biological behavior of the lesion being sampled. Early classifications of tumors into well-differentiated or poorly differentiated groups relied upon subjective evaluation and were found to be of limited value in predicting prognosis. Analysis of multiple histologic parameters has been suggested to correlate better with prognosis,^{3,4} but the technique has proved cumbersome and is not in widespread use.

Morphometry. Major efforts in recent years have been directed at using objective measurements of tumor cells to predict prognosis. Using computer-assisted image analysis, objective measurements of

cell components can be used to accurately predict the metastasizing potential of certain tumors.⁵ This technique, referred to as morphometry, is particularly of value in lesions of borderline malignancy.

Cytophotometry. Measurement of cellular DNA using the technique of cytophotometry is proving to have predictive value in premalignant atypias.⁶ The presence of cells having hypertetraploid amounts of DNA seems to be of particular prognostic significance.

Flow Cytometry. Quantitation of DNA content and measurements of a variety of other physical and biochemical properties of cells in suspension can now be readily accomplished using a flow cytometer. These instruments can also be used to separate different populations of cells in suspension, a process referred to as cell sorting. Labeling cells with specific antisera and fluorescent dyes allows rapid and accurate diagnosis of malignant lymphomas and a variety of other neoplasms.⁷

Scanning Electron Microscopy. Study of biopsy specimens from surface epithelium with the scanning electron microscope also may provide useful information regarding the likelihood of future development of invasive carcinoma in the larynx.⁸ Similar data is accumulating with reference to transitional cell carcinoma of the bladder (E. de Harven, personal communication).

Cytogenetics. The study of cellular chromosomes designed to demonstrate abnormal karyotypes, cytogenetics, has now been used to study malignant tumors from a variety of sites and has demonstrated a close relationship between aggressive biological behavior and abnormal karyotype.⁹

In conclusion, we appear to be on the threshold of a technological explosion, applying techniques of cell biology to human disease, that is likely to dramatically enhance our understanding of disease mechanisms and will rapidly revolutionize the manner in which we diagnose and treat our patients.

REFERENCES

1. Fechner RE. New and innovative aspects of pathology. In: Chretien PB, Johns ME, Shedd DP, Strong EW, Ward PH, eds. Head and neck cancer. Vol 1. Philadelphia: BC Decker Inc, 1985:18-26.
2. Falini B, Taylor CR. New developments in immunoperoxidase techniques and their application. Arch Pathol Lab Med 1983; 107:105-17.
3. Jakobsson PA. Histologic grading of malignancy and prognosis in glottic carcinomas of the larynx. In: Alberti PW, Bryce DP, eds. Centennial conference on laryngeal cancer. New York: Appleton-Century Crofts, 1976:847-52.
4. Crissman JD, Makuch R, Budhraj M. Histopathologic grading of squamous cell carcinoma of the uterine cervix. Cancer 1985; 55:1590-6.
5. Baak JPA, Oort J. A manual of morphometry in diagnostic pathology. Berlin: Springer-Verlag, 1983.
6. Bjelkenkrantz K, Lundgren J, Olofsson J. Single cell DNA measurements in hyperplasia, dysplasia and carcinomatous laryngeal epithelia, with special reference to the occurrence of hypertetraploid cell nuclei. Anal Quant Cytol 1983; 5:184-8.
7. Lovett EJ III, Schnitzer B, Keren DF, Flint A, Hudson JL, McClatchey KD. Applications of flow cytometry to diagnostic pathology. Lab Invest 1984; 50:115-40.
8. Lundgren J, Olofsson J, Hellquist H, Grontoft L. Scanning electron microscopy of vocal cord hyperplasia keratosis, papillomatosis, dysplasia and carcinoma. Acta Otolaryngol (Stockh) 1983; 96:315-27.
9. Wolman SR. Cytogenetics and cancer. Arch Pathol Lab Med 1984; 108:15-9.

DEMONSTRATION OF HUMAN PAPILLOMAVIRUS CAPSID ANTIGEN IN CARCINOMA IN SITU OF THE LARYNX

HASKINS KASHIMA, MD

FRANCIS KUHAJDA, MD

PHOEBE MOUNTS, PhD

MARK LOURY, MD

BALTIMORE, MARYLAND

We have undertaken a retrospective study to investigate the role of human papillomavirus (HPV) in the development of laryngeal carcinoma in situ (CIS). Sixty paraffin-embedded tissue specimens, collected from 20 patients with a history of laryngeal CIS, were examined for the presence of HPV capsid antigen. All but four individuals were men, with an average age at diagnosis of 64 years. An immunoperoxidase technique showed that 20 specimens from 14 patients contained detectable HPV capsid antigen. An independent evaluation for histopathologic features characteristic of HPV infection identified viral changes in the 14 patients as well as an additional two. No correlation was found between clinical course, as determined by histologic severity of vocal cord lesions, and presence of HPV. These results suggest that HPV should be considered an etiologic agent in the development of laryngeal CIS.

KEY WORDS — carcinoma in situ, human papillomavirus, immunoperoxidase assay, laryngeal carcinoma, viral histopathology.

INTRODUCTION

Carcinoma in situ (CIS) of the larynx is an epithelial disorder which, in a certain fraction of cases, develops into invasive glottic cancer. Histologically, the normal structure of squamous epithelium is replaced by malignant cells that do not invade beyond the basement membrane.¹ Lesser degrees of atypia are also recognized as having malignant potential.²⁻⁵ Because of these potential risks, a wide range of treatment options have been advocated including local excision, laryngofissure with cordectomy, radiotherapy, and even total laryngectomy. The restriction of the lesion to the epithelium implies that endoscopic excisional biopsy could be a curative procedure as demonstrated by Miller and Fisher^{6,7} and DeSanto.⁸ Autopsy studies by Auerbach et al⁹ and Muller and Krohn¹⁰ comparing reformed and active smokers indicate that most cases of CIS are reversible upon cessation of tobacco abuse. Other environmental risk factors include alcohol abuse, infectious agents, voice abuse, vitamin A deficiency, and exposure to various industrial irritants.¹¹ A survey of the literature^{2,3,6,8,12,13} shows that in 479 patients, 6% had recurrence of CIS after attempted curative treatment and 12% proceeded to invasive cancer. In these series, the majority (80% to 90%) of the patients are men in their fifth and sixth decades of life.

Human papillomavirus (HPV) has been shown to infect the respiratory tract.¹⁴⁻¹⁶ Human papillomavirus infection of the genital tract is associated with the development of malignant lesions,^{17,18} and the presence of HPV capsid antigen has been reported in 36% of laryngeal squamous cell carcinomas.¹⁹

Stimulated by the clinical, pathologic, and biological similarities of laryngeal and cervical dysplasias, we have undertaken a retrospective study to determine HPV association with laryngeal CIS. Using an immunoperoxidase technique, we have detected HPV capsid antigen in paraffin-embedded sections of laryngeal biopsy specimens in 14 of 20 patients with a history of laryngeal CIS. Although there appears to be no correlation between the clinical course of disease and the presence of HPV, these results suggest a viral role in the development of laryngeal CIS.

MATERIALS AND METHODS

The records of the Johns Hopkins Hospital Tumor Registry were reviewed for the years 1970 to 1983 to identify individuals with laryngeal CIS. Twenty individuals were selected for this study on the basis of having had repeated endoscopic excisions and having relevant clinical data and paraffin-embedded tissue specimens available.

Case Analysis. The following information was tabulated: age at diagnosis of CIS; histology of biopsy specimens removed before and after diagnosis of CIS, treatment, and outcome; sex, race, smoking, and alcohol consumption history; history of irradiation; and occurrence of synchronous benign and malignant tumors. The clinical course of each case was classified as progression when histologic severity of vocal cord lesions increased at succeeding operations, improvement when histologic severity decreased at succeeding operations, and no change when the histologic diagnosis demonstrated neither clear-cut progression nor improvement.

From the Departments of Otolaryngology-Head and Neck Surgery (Kashima, Loury) and Pathology (Kuhajda), Johns Hopkins Hospital, and the Department of Immunology and Infectious Diseases, Johns Hopkins School of Hygiene and Public Health (Mounts), Baltimore. This research was supported in part by Public Health Service grant S07-RR05445.

Presented at the meeting of the American Laryngological Association, Palm Beach, Florida, May 4-5, 1986.

REPRINTS — Haskins K. Kashima, MD, Dept of Otolaryngology-Head and Neck Surgery, Johns Hopkins Medical Institutions, 600 N Wolfe St, Baltimore, MD 21205.

TABLE 1. PRESENCE OF HPV CAPSID ANTIGEN IN 20 PATIENTS WITH CIS

Pt No.	No. of Operations	Follow-Up Duration (yr)	Clinical Course	No. of Specimens	HPV Antigen +
1	2	5	I	2	0
2	3	2	I	6	0
3	3	4	I	2	2
4	3	6	N	5	1
5	3	3	I	3	2
6	3	2	I	4	1
7	1	3	N	1	0
8	8	6	I	4	2
9	5	2	N	6	3
10	2	7	I	1	1
11	5	6	N	4	1
12	2	1	I	2	1
13	4	3	N	1	0
14	8	12	P	4	1
15	2	4	N	2	0
16	2	4	I	2	1
17	2	2	N	2	2
18	3	1	I	2	1
19	2	7	P	3	1
20	5	13	I	4	0

I — improved, N — no change, P — progressed.

Histologic Examination. Formalin-fixed laryngeal biopsy specimens previously had been routinely processed and stained with hematoxylin and eosin. For most patients, two to five tissue samples were available, representing biopsies from different anatomic sites or from different endoscopic operations. Specimens were assessed both for the presence of histologic changes associated with HPV infection and intraepithelial neoplasia. The intraepithelial neoplasia was graded as mild, moderate, or marked atypia, and in its most severe state, CIS. The grading of atypia was based on increasing degrees of cytologic atypia, mitoses, and dysmaturation of the squamous epithelium.

Viral changes associated with HPV infection of the uterine cervix have been well described and consist of the following histologic characteristics: hyperkeratosis, dyskeratosis, parakeratosis, acanthosis, koilocytosis, and multinucleation.²⁰ The presence of koilocytosis, defined as a cell with cytoplasmic vacuolization and a pyknotic irregular nucleus, was required for the diagnosis of viral change. The associated histologic characteristics were required to be present, and designation of viral change was not made without koilocytosis.

Detection of HPV Capsid Antigen. The presence and distribution of HPV capsid antigen in 4- μ m thick paraffin sections were determined using the avidin-biotin modification of the immunoperoxidase technique as previously described.¹⁴ Primary rabbit antibody (Accurate Chemical, Westbury, NY) generated against detergent-disrupted bovine papillomavirus particles cross-reacts with genus-specific antigens of all papillomaviruses.²¹ Brown nuclear staining of cells was scored as positive for viral antigen. Sec-

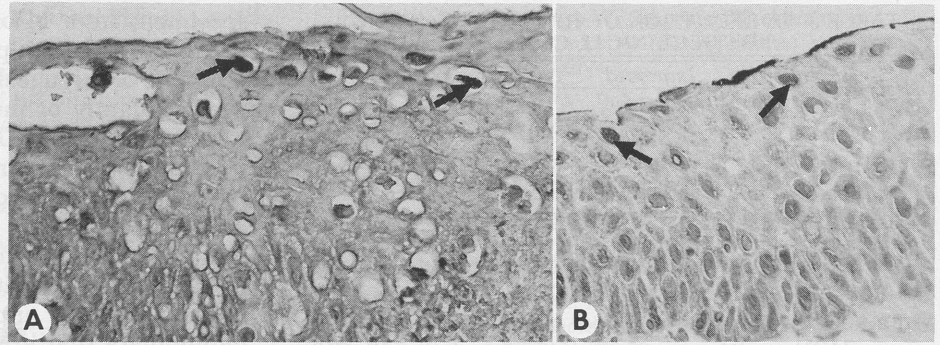
tions were stained with nonimmune rabbit serum or antihuman keratin rabbit serum (Accurate Chemical) as controls. Additional negative controls were biopsy specimens from 12 cases of benign laryngeal nodules stained with antipapillomavirus antibodies and evaluated in an identical manner.

RESULTS

Case Analysis. Twenty patients with biopsy-proven CIS formed the study group. All but four individuals were men. The mean age at diagnosis was 64, with an age range of 42 to 77 years. All but one patient (Table 1, patient 18) smoked tobacco, with nine individuals ceasing consumption at least 2 years before the initial laryngeal biopsy. Alcohol usage was variable, with seven patients imbibing a minimum of two drinks daily and two (patients 18 and 1) refraining from alcohol intake. Six individuals reported occasional usage, and no information was available for the remaining five cases. Patient 18 was a woman, a nondrinker, a nonsmoker, the youngest member of the group, and was anergic when intradermally tested with mumps, *Candida*, and *Trichophyton* antigens. Occupational or environmental exposure to carcinogens was rarely recorded in medical records. Though none had radiotherapy prior to the initial biopsy, four patients received a therapeutic course after diagnosis of in situ malignancy. It was employed after two in situ specimens had been removed in cases 4 and 19 and one biopsy in cases 7 and 8. Three of these individuals remained disease free, and patient 19 developed invasive carcinoma that was successfully managed endoscopically. Three patients had synchronous or metachronous malignancies. Patient 13 had chronic lymphocytic leukemia, and patient 19 developed fatal squamous cell carcinoma of the lung 4 years after diagnosis of his laryngeal disease. Patient 19 had unilateral breast carcinoma, CIS of the right soft palate and left anterior tonsil, as well as infiltrating squamous cell cancer of the hard palate, all at the time of her initial laryngoscopy. Later a second CIS of the true cord and a left base of tongue neoplasm were identified; all of the aerodigestive tract lesions were managed by excision.

The study group was selected on the basis of having had repeated endoscopic excisions with biopsy material available for examination. For each of the 20 patients, information on clinical course of disease, including number of operations, length of observation, and outcome of disease (ie, improvement, no change, or progression), which was determined by criteria described in Materials and Methods, is given in Table 1. Follow-up ranged from 1 to 13 years, during which time one to eight endoscopic operations (average of five) were performed. Eleven patients were considered to have improved, two progressed, and seven showed no change in histopathologic severity of vocal cord lesions.

Immunoperoxidase staining for HPV capsid antigen showing positive nuclear staining near epithelial surface (arrows). A) Mild atypia (methylene blue counter-stain, original x450). Note koilocytotic cells. B) Hyperplastic epithelium without atypia (methylene blue stain, original x600).



The following two case summaries are given as examples of clinical histories. Patient 11 had had several months of hoarseness when he was examined at the age of 63. His risk factors included a 95-pack per year smoking history and occasional alcohol intake. A left true vocal cord biopsy was interpreted as moderate atypia. A left cord biopsy 1 year later was diagnosed as CIS. Two months later, reexamination and biopsy showed marked atypia. He remained clinically disease free until 31 months after his first carcinoma biopsy, when a biopsy of the left vocal cord lesion revealed moderate dysplasia. A recurrent lesion 18 months later was diagnosed as CIS.

Patient 14, a 62-year-old smoker and occasional alcohol user, presented with hoarseness. Left true cord biopsy was interpreted as CIS. Subsequent biopsies at 1, 21, and 27 months were all negative for tumor with some hyperplasia observed. Nine years after the initial biopsy, a left vocal cord biopsy was diagnosed as CIS with focal microinvasion. Carcinoma in situ with infiltrating squamous cell carcinoma was found in specimens taken 2 and 3 months later. However, a specimen removed 4 months later was diagnosed as inflamed granulation tissue. Overall clinical course was evaluated as progression (Table 1).

Immunohistochemical Detection of HPV Capsid Antigen. Paraffin-embedded tissue specimens collected at endoscopic excisions for histopathologic evaluation were examined for the presence of HPV capsid antigen as described in Materials and Methods. The number of specimens examined for each patient is given in Table 1 and ranged from one to six, with an average of three. A specimen was scored

as positive when one or more nuclei stained positive, provided the cell was reactive in a serial section and not reactive when stained with nonimmune or anti-keratin rabbit serum. Most of the specimens had only a few antigen-containing cells (Figure, A). Fourteen patients had at least one biopsy specimen that contained viral capsid antigen; four had two positive biopsy specimens; and one had three positive specimens (Table 1). There was no apparent correlation of HPV positivity with any variable identified in medical histories. Of the four patients who received radiation therapy, patient 8 had two HPV-positive samples, patients 4 and 19 had one positive sample, and patient 7 had none. Three of the patients remained disease free, and patient 19 developed infiltrating carcinoma. Of four specimens examined for patient 11, whose case is outlined above, one specimen diagnosed as moderate dysplasia was antigen-positive. Of the four tissue samples examined from patient 14, the other index case, one specimen diagnosed as CIS with focal microinvasion was HPV-positive.

Correlation of Histologic Diagnosis and HPV Capsid Antigen. Of 60 tissue specimens tested, 20 had detectable HPV capsid antigen (Table 2). Twelve benign laryngeal nodules that were tested as negative controls did not give a positive reaction in the immunoperoxidase assay and did not manifest the histologic features described above as indicative of an HPV infection. Fifteen sections were evaluated as normal or hyperplastic epithelium without atypia, and four of these were positive for HPV capsid antigen (Figure, B). These results demonstrate HPV infection in the respiratory tract that is not associated with recurrent respiratory papillomatosis and sug-

TABLE 2. CORRELATION OF HISTOLOGIC DIAGNOSIS WITH HPV CAPSID ANTIGEN AND PATHOLOGIC INDICATIONS OF HPV INFECTION

Histologic Diagnosis	No. of Specimens	HPV Capsid Antigen +		HPV Histopathology +		HPV Antigen and Histopathology +
		No.	%	No.	%	
Epithelial hyperplasia, no atypia	15	4	27	0	0	0
Mild atypia	7	2	28	3	43	2
Moderate atypia	6	2	33	4	66	1
Marked atypia	7	3	43	5	71	2
Carcinoma in situ	25	9	36	11	44	5
Total specimens	60	20	33	23	38	10
Benign laryngeal nodules	12	0	0	0	0	0

TABLE 3. CORRELATION OF HPV CAPSID ANTIGEN WITH CLINICAL COURSE

	No. of Pts	Improved	No Change	Progressed
HPV +	14	8	4	2
HPV -	6	3	3	0
Total	20	11	7	2

Clinical course was determined by histologic evaluation of biopsy specimens collected during follow-up period given in Table 1.

gest that this infection may be more widespread than is currently recognized. Of the 20 tissue specimens with mild to marked atypia, seven (35%) were HPV-positive, and nine (36%) of the 25 CIS specimens were antigen-positive. In these 16 positive specimens, nine had antigen-containing cells adjacent to areas of atypia, but seven had antigen-containing cells in areas of atypia that ranged from mild (one specimen) to CIS (four specimens). The positive nuclei tended to be superficial but in two cases were distributed throughout the lesion.

Since only half of respiratory papillomata that are shown to contain HPV DNA contain capsid antigen,¹⁴ analyzing specimens for histologic features characteristic of HPV infection including koilocytosis and multinucleation, as described in Materials and Methods, may provide better indication of viral infection. Twenty-three specimens had histopathologic features of HPV infection, with ten of these showing capsid antigen (Table 2). Thirteen specimens were histopathology-positive but viral antigen-negative, with histologic diagnoses of mild atypia (8%), moderate atypia (23%), marked atypia (23%), or CIS (46%). Only two specimens (from patients 1 and 15) had histopathologic features associated with viral change without having antigen-positive specimens. Of the ten specimens that were antigen-positive but did not have histologic features characteristic of viral changes, four were hyperplastic epithelium, one was moderately atypical, one was markedly atypical, and four were CIS.

Correlation of HPV Capsid Antigen with Clinical Course. As shown in Table 3, there does not appear to be a correlation between clinical course and presence of HPV infection. In 21% of patients, capsid antigen was detected before the initial histologic diagnosis of CIS; in 43% antigen was detected after diagnosis of CIS, and in 36% at the same time. These results suggest that replication of HPV in the respiratory tract should be considered as a contributing factor in the development of laryngeal CIS.

DISCUSSION

We have detected the presence of HPV in biopsy

specimens from 14 of 20 patients with a history of laryngeal CIS. This population appears to be representative of laryngeal CIS patients in that it consists predominantly of men in the sixth decade with a history of smoking. There may, however, be a bias because patients were also selected on the basis of having had repeated endoscopic excisions on the assumption that the continued presence of a virus may be important in the development of CIS. The number of HPV-positive patients may be underestimated since only approximately half of respiratory papillomata that are shown to contain HPV DNA contain capsid antigen.¹⁴

Of the 60 tissue specimens examined, 20 were HPV-positive, with five patients having at least two positive specimens. In the uterine cervix, 50% of dysplastic lesions were HPV antigen-positive compared to 96% positive for HPV DNA.²² Using histopathologic features characteristic of HPV infection may provide a better indication of viral presence. Two additional patients had specimens with histopathologic features associated with viral change without having antigen-positive specimens. Analysis of biopsy specimens for the presence of HPV DNA is under way using more sensitive techniques to determine more accurately the infection rate and also to identify the type of HPV, since the malignant potential of different types of HPV may vary. For example, HPV type 6 is associated with benign respiratory and genital tract lesions,²³ and HPV type 16 is found in malignant genital tract lesions²⁴ and laryngeal verrucous carcinoma.²⁵

An evaluation of the clinical course indicated that 11 patients improved, seven showed no change, and two progressed to more advanced vocal cord disease. Although there appears to be no correlation between clinical course and presence of HPV, the follow-up may be too short (average of almost 5 years) and the number of cases too few to derive any convincing conclusions. Nonetheless, the risk of irradiating benign lesions and association of smoking with malignant conversion in patients with recurrent respiratory papillomatosis is recognized.²⁶ It is of interest that of four patients who received radiotherapy, three had HPV-positive specimens and one had HPV-positive specimens and developed infiltrating carcinoma.

These results suggest that HPV should be considered an etiologic agent in the development of laryngeal CIS. The precise role of HPV in epithelial dysplasia, whether cofactor, initiator, or promotor, remains to be determined.

REFERENCES

1. Fisher HR. Centennial conference on laryngeal cancer. Alberti PW, Bryce DP, eds. New York: Appleton-Century Crofts, 1976:116-9.
2. Hellquist H, Lundgren J, Olofsson J. Hyperplasia, keratosis, dysplasia and carcinoma *in situ* of the vocal cords — a follow-up study. Clin Otolaryngol 1982; 7:11-27.
3. Gillis TM, Incze H, Strong MS, Vaughan CW, Simpson GT. Natural history and management of keratosis, atypia, carcinoma-in-situ and microinvasive cancer of the larynx. Am J Surg 1983; 146:512-6.
4. Putney FJ, O'Keefe JJ. The clinical significance of keratosis

- of the larynx as a premalignant lesion. *Ann Otol Rhinol Laryngol* 1953; 62:348-57.
5. McGavran MH, Bauer WC, Ogura JH. Isolated laryngeal keratosis. Its relation to carcinoma of the larynx based on a clinicopathologic study of 87 consecutive cases with long-term follow-up. *Laryngoscope* 1960; 70:932-51.
 6. Miller AH, Fisher HR. Clues to the life history of carcinoma *in situ* of the larynx. *Laryngoscope* 1971; 81:1475-80.
 7. Fisher HR, Miller AH. Carcinoma in situ of the larynx: a ten year study of its histopathological classification, prognosis and treatment. *Ann Otol Rhinol Laryngol* 1958; 67:695-702.
 8. DeSanto LW. Cancers of the larynx: glottic cancer. *Surg Clin North Am* 1977; 57:611-70.
 9. Auerbach O, Hammond EC, Garfinkel L. Histologic changes in the larynx in relation to smoking habits. *Cancer* 1970; 25:92-104.
 10. Muller KM, Krohn BR. Smoking habits and their relationship to precancerous lesions of the larynx. *J Cancer Res Clin Oncol* 1980; 96:211-7.
 11. Baines L, Gnepp DR. Diseases of the larynx, hypopharynx and esophagus. In: Baines L, ed. *Surgical pathology of the head and neck*. New York: Marcel Dekker, Inc, 1985:141-203.
 12. Doyle PJ, Flores AD. Treatment of carcinoma *in situ* of the larynx. *J Otolaryngol* 1977; 6:363-7.
 13. Holinger PH. Carcinoma in situ of the larynx [Editorial]. *Arch Otolaryngol* 1966; 83:303-4.
 14. Mounts P, Shah KV, Kashima H. Viral etiology of juvenile- and adult-onset squamous papilloma of the larynx. *Proc Natl Acad Sci USA* 1982; 79:5425-9.
 15. Gissmann L, Diehl V, Schulz-Caulon HJ, zur Hausen H. Molecular cloning and characterization of HPV DNA from a laryngeal papilloma. *J Virol* 1982; 44:393-400.
 16. Steinberg BM, Topp W, Schneider PS, Abramson A. Laryngeal papillomavirus infection during clinical remission. *N Engl J Med* 1983; 308:1261-4.
 17. Fu YS, Reagan JW, Richard RM. Precursors of cervical cancer. *Cancer Surv* 1983; 2:359-82.
 18. Gissmann L. Papillomaviruses and their association with cancer in animals and in man. *Cancer Surv* 1984; 3:161-81.
 19. Syrjanen K, Syrjanen S, Pyrhonen S. Human papillomavirus antigens in lesions of laryngeal squamous cell carcinomas. *ORL J Otorhinolaryngol Relat Spec* 1982; 44:323-34.
 20. Meisels A, Fortin R, Roy M. Condylomatous lesions of the cervix. II. Cytologic, colposcopic and histopathologic study. *Acta Cytol (Baltimore)* 1977; 21:379-90.
 21. Jenson AB, Rosenthal JR, Olson C, Pass F, Lancaster W, Shah KV. Immunological relatedness of papillomaviruses from different species. *J Natl Cancer Inst* 1980; 64:495-500.
 22. Kadish AS, Burk RD, Kress Y, Calderin S, Romney SL. HPV of different types in precancerous lesions of the uterine cervix: histologic, immunocytochemical and ultrastructural studies. *Hum Pathol* 1986; 17:384-92.
 23. Mounts P, Wu T-C, Leventhal B, et al. Analysis of HPV type 6 in the respiratory and genital tracts during interferon therapy. Papillomaviruses: molecular and clinical aspects. *UCLA Symp Mol Cell Biol* 1985; 32:137-54.
 24. Durst M, Gissmann L, Ikenberg H, zur Hausen H. A papillomavirus DNA from a cervical carcinoma and its prevalence in cancer biopsies from different geographic regions. *Proc Natl Acad Sci USA* 1983; 60:3812-5.
 25. Abramson AL, Brandsma J, Steinberg B, Winkler B. Verucous carcinoma of the larynx: possible HPV etiology. *Arch Otolaryngol* 1985; 111:709-15.
 26. Mounts P, Shah KV. Respiratory papillomatosis: etiologic relation to genital tract papillomaviruses. *Prog Med Virol* 1984; 29:90-114.

ESTROGEN RECEPTOR IN THE LARYNX OF THE AGED BABOON (*PAPIO CYNOCEPHALUS*)

G. RICHARD HOLT, MD

THOMAS B. AUFDEMORTE, DDS

PETER J. SHERIDAN, PhD

SAN ANTONIO, TEXAS

Using autoradiographic techniques, tritiated estrogen-receptor complex intranuclear labeling was identified in certain laryngeal tissues of four aged female baboons; no complex labeling was found in the control animal. Three significant findings were felt to be derived from this study. One, surface epithelium of the larynx had essentially no estrogen-receptor activity. Two, all tissues of mesenchymal origin, especially lamina propria, muscle, dense connective tissue, and fat had consistently high levels of nuclear localization of the labeled estrogen. The binding affinity seemed to be the highest at the anterior commissure and the immediate anterior subglottic space. Three, there was a high level of receptor binding in laryngeal cartilage and perichondrium. Since the activated hormone-receptor complex modulates gene expression to alter the amount of mRNA, sex steroids have a direct regulatory effect upon the target cell and, perhaps through an induction process, can exert an indirect effect upon adjacent tissues. It is postulated that since the larynx is a sexually dimorphic organ, the sex steroids and their receptors may play a role in altered phonation during aging and possibly in the development of laryngeal neoplasms and other diseases. Therefore, hormonal manipulation may play a future role in the therapy of laryngeal diseases. This study represents the first demonstration of estrogen receptors by specific anatomic location in the primate larynx with significant localization in the mesenchymal tissues but not in the epithelial tissues.

KEY WORDS — estrogen-receptor complex, nuclear localization, primate larynx.

INTRODUCTION

Substantial evidence is being accumulated to indicate the importance of steroid hormone receptor levels in normal and diseased tissues. These steroid hormone receptors, which have a high affinity binding for specific sex steroids, are thermolabile proteins found in the soluble component of the cell or loosely bound to the nuclear matrix. In those target cells that are sensitive to the regulatory action of sex steroids, the complex formed by the binding of the sex steroid and the receptor protein has a regulatory effect on certain biochemical functions of the cell. Upon binding the sex steroid, the steroid-receptor complex is transformed in some yet unknown way such that it possesses a high affinity for the chromatin.¹ The transformed steroid-receptor complex then interacts with the chromatin to modulate gene transcription.² Thus, RNA synthesis is either stimulated or inhibited, depending upon the specific target cell and the hormone. The newly synthesized messenger RNA undergoes processing and transportation into the cytoplasm where it is translated into protein, and ultimately this protein is secreted or remains in the cell to modify cellular activity.

Because of their ability to effect expression of target cell and tissue capabilities, the sex steroid hormones play an important role in the differentiation and development of target tissues directly, and in the induction of adjacent tissue growth indirectly. Steroids and their receptors have been shown to

modify not only the development of the reproductive system but also the immune system. The clinical significance of these findings has directly affected the therapy of breast cancer, as approximately 50% of human breast cancers that contain estrogen receptors will respond to additive or ablative forms of endocrine therapy. Recent attempts have been made to quantify the estradiol receptors in normal and diseased tissues of the face, head, and neck, and to postulate the role of sex hormones in the development and/or progression of neoplasms.³ However, prior to clinical trials making use of this preliminary data, it is important to characterize further the location of sex steroid receptors in the normal tissues of the head and neck.

The larynx was chosen as the initial site of investigation for sex steroid receptor studies because of its unique developmental and aging sexual dimorphism. Aside from the organs associated with reproduction, the larynx appears to be the most responsive to circulating steroid levels of any other organ in the body. Males undergo radical changes in the structure, morphology, and physiologic function of the larynx during puberty — the induction process of these changes is undoubtedly under control of the sex hormones. The second major change in laryngeal function in men occurs in senescence when alterations of vocal function include weakness, pitch variability, and decreased phonation/time ratio.⁴ However, vocal function diminishment with

From the Division of Otorhinolaryngology (Holt), and the Departments of Pathology (Aufdemorte) and Molecular and Cellular Biology (Sheridan), The University of Texas Health Science Center, San Antonio. This research was supported by National Institutes of Health/National Institute of Neurological and Communicative Disorders and Stroke program project grant 1 P01 NS 19631-01.

Presented at the meeting of the American Laryngological Association, Palm Beach, Florida, May 4-5, 1986.

REPRINTS — G. Richard Holt, MD, Division of Otorhinolaryngology, 7703 Floyd Curl Dr, University of Texas Health Science Center, San Antonio, TX 78284.

aging is not confined solely to men, as Charlip⁵ and McGlove and Hollien⁶ have found decreased pitch variability in older female patients.

The baboon (*Papio cynocephalus*) was chosen as a model for the sex steroid receptor studies because of its phylogenetic proximity to humans and because of the excellent histologic and autoradiographic evidence of receptor sites in previous studies on a wide variety of tissue sites, including the cardiovascular system,⁷ esophagus,⁸ and brain stem.⁹ An earlier pilot study in identifying sex steroid receptors in the larynx of young baboons¹⁰ furnished valuable normative and descriptive data upon which to postulate the possible alterations in sex steroid receptor quantity, location, and function that might occur with the aging process. This study used female baboons injected with estrogen as the first arm of a four-part study using both female and male aged baboons injected with estrogen or testosterone. Since both estrogen and androgen are present in males and females, it was felt important to use the four-part study to determine whether any differences exist in receptor sites and levels. Hormone levels change with the aging process in both men and women.

The autoradiographic technique allows the identification of the cell types and the semiquantification of the labeled hormone-receptor complexes, which were taken up and retained by the nucleus, thus indicating a biologically active receptor binding process. This investigation identified the intranuclear receptor binding of labeled estrogen in aged female baboons to better understand the possible effects of aging on receptor number and location in the larynx. If estrogen receptors are found in regions of the larynx associated with the dimorphic development and differentiation of that structure, then a cellular basis for the anatomic and physiologic differences between sexes could be postulated.

METHODS AND MATERIALS

Subjects. For this experiment, five aged female baboons were used. In a previous pilot study, five young male baboons had been studied to obtain baseline data. Future experiments will address estrogens in aged male baboons. Forty-eight hours before the injection of tritiated estrogen and autopsy, both ovaries and both adrenal glands were removed under ketamine and halothane anesthesia, using the aseptic technique. Castration and adrenalectomy eliminated endogenous steroids and maximized binding of tritiated hormone. Shortly after the operation, each animal was given 100 mg of prednisolone sodium succinate.

We waited 48 hours after adrenalectomy and castration to inject the animals with ³H-estrogen for two reasons. First, the animals were injected with the prednisolone sodium succinate to assist the ani-

mals' recovery from the trauma of surgery. We wished to avoid any possible interaction between the huge quantity of corticoid and the estrogen receptors. The second reason is that nuclear retention of bound estradiol has been shown to occur as much as 24 hours after the ingestion of ³H-estradiol; thus, 48 hours was chosen as a safe time frame. It is also important that the long-term half-life (eg, beyond 6 hours) of tissue-bound estrogen may be as much as 12 to 18 hours.

Administration of Labeled Hormone. On the day of autopsy, 1 µg/kg of body weight of [2,4,6,7-³H] estradiol 17β (³H-E₂), 103 Ci/mmol, was injected into a femoral vein of each animal. Four aged female baboons received only the labeled estrogen, while one aged female baboon, serving as the control, received both the labeled estrogen as well as 100 µg/kg of body weight of unlabeled estrogen.

The control baboon served two functions. First, any inhibition with unlabeled estrogen could demonstrate that the uptake of estrogen is of limited capacity. Second, it allowed the elimination of positive chemical artifacts. Thus, localization in the nucleus seen after the injection of both unlabeled estradiol and ³H-estradiol would be considered artifact.

One hour after injection, the animal was placed under ketamine anesthesia and rapidly was exsanguinated through a femoral venous catheter. The vascular system was perfused with approximately 3 L of chilled Ringer's solution through a femoral arterial catheter. As the animal was exsanguinated and perfused, the body was also packed in ice to accelerate chilling. Following clearing of the perfusate, the body was dissected for tissue specimens. Tissue was taken from all major organ systems and prepared for sex steroid receptor identification to enable collaborating studies to be performed.

Tissue Dissection. The entire head and neck region was dissected free of the body at the level of the mid-trachea. The larynx was isolated by a laryngectomy-type procedure and split sharply down the midline posteriorly to expose the laryngeal and tracheal lumens (Fig 1). Following a standardized, detailed format, specimens were taken from all the regions of the larynx including epiglottis, aryepiglottic fold, false cord, true vocal cord (Fig 2), anterior commissure, arytenoid cartilage, vocalis muscle, interarytenoid muscle, posterior and lateral cricoarytenoid muscles, cricothyroid muscle, recurrent laryngeal nerve, and trachea. The specimens included surface epithelium and all subjacent tissues down to and including perichondrium and cartilage. Simultaneous studies were also performed on the brain; cutaneous, periodontal, and salivary tissues; the remaining aerodigestive tract; and the cardiovascular system.

Sample Preparation. The samples were labeled, classified, mounted on brass tissue mounts coated with minced liver, frozen in liquified propane, and

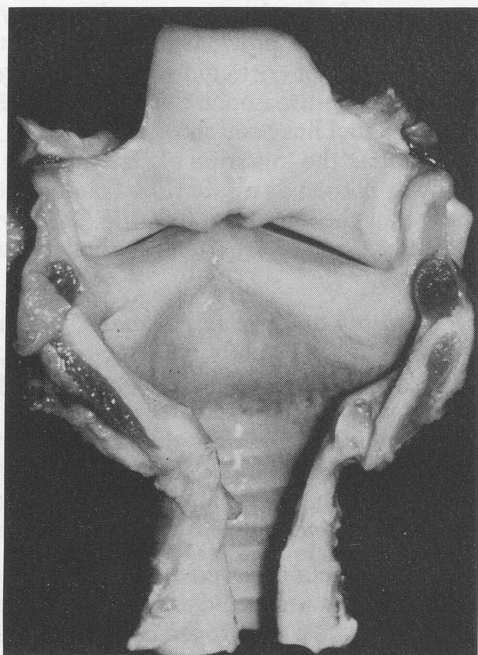


Fig 1. Representative laryngeal specimen. (Reprinted with permission.¹⁰)

stored in liquid nitrogen. Autoradiographs were prepared by cutting 4- μ m thick sections of the frozen tissues at -35°C using a Harris wide range cryostat. These were then mounted on slides coated with Kodak NTB-2 nuclear tract emulsion and stored at -15°C for exposure. After 3 months of exposure, the tissues were processed photographically, stained with hematoxylin and eosin, and examined microscopically for the location and degree of nuclear concentration of reduced silver grains, which are indicative of a steroid-receptor complex.^{11,12}

Hormone-Receptor Binding Identification. Only cells with nuclear concentrations of silver grains in excess of three times that of the surrounding cytoplasm or extracellular space were considered receptor positive.

Where tissues were sufficiently abundant and homogeneous, such as for muscle sites, counts of the number of labeled nuclei per 0.06 mm² at 400x were performed. For smaller areas, labeling was roughly quantitated according to total percent of cells labeled per high-power field, as follows: 0, 1+ (0% to 25%), 2+ (25% to 50%), 3+ (50% to 75%), and 4+ (75% to 100%). Nonuniform structures or very small structures were scored only as receptor present or absent.

RESULTS

Many sites of nuclear localization of tritiated estradiol (³H-E₂) were identified in the laryngeal areas studied (Table). The most conspicuous uptake was in mesenchymal tissues, which in some areas had uptake and retention of the labeled hormone in al-

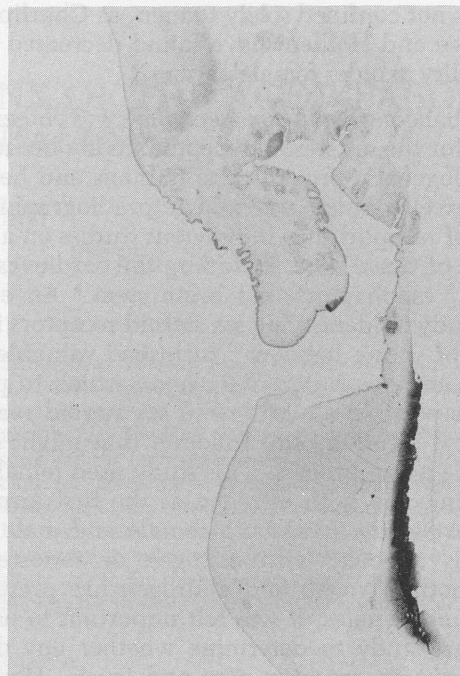


Fig 2. Photomicrograph of cross section of representative false vocal cord (top) and true vocal cord (bottom) with interposed ventricle, providing general orientation to some of areas processed for study (H & E, original x3). (Reprinted with permission.¹⁰)

most 100% of the nuclei. Conversely, surface epithelium, whether stratified squamous or pseudostratified ciliated columnar, was completely devoid of receptor positive cells in all areas sampled.

Beyond these two major observations, three general specific patterns of labeling were apparent: 1) some areas consistently labeled from site to site within the same animal as well as from animal to animal; 2) other sites consistently failed to demonstrate any uptake of the tritiated hormone, and 3) some tissues showed uptake of ³H-E₂ that was quite variable within the same animal, as well as among different animals.

EXTENT OF ESTRADIOL-RECEPTOR COMPLEX
INTRANUCLEAR LABELING IN TISSUES OF FOUR
AGED FEMALE BABOONS

Site	Extent of Nuclear Labeling
Cartilage and perichondrium	4+
Dense collagen, area of vocalis muscle and anterior commissure	4+
Laryngeal muscles	3+
Lamina propria, area of vocalis muscle and anterior commissure	3+
Adipose tissue	1+
Minor salivary glands	1+*
Endothelial cells	1+*
Fine motor nerves	1+*
Surface epithelium	0
Chronic inflammatory cells	0
1+ — 0% to 25% cells labeled, 3+ — 50% to 75% cells labeled, 4+ — 75% to 100% cells labeled.	
*Inconsistent labeling.	

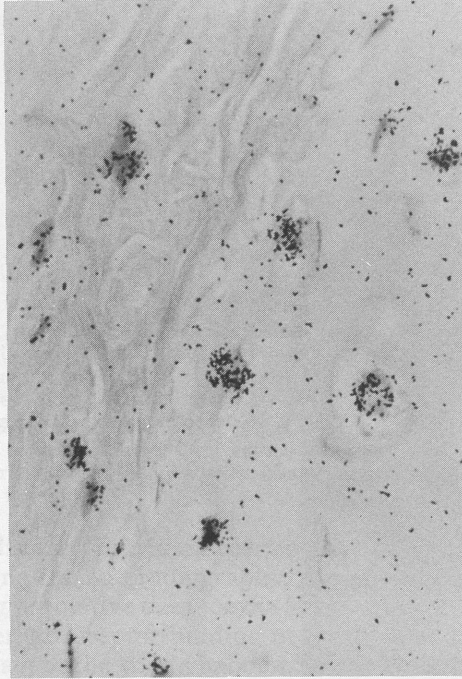


Fig 3. Photomicrograph of epiglottic cartilage showing intense nuclear labeling of both cells in perichondrium (left) as well as chondrocytes (right) (H & E, original x60).

Consistently Labeled Tissues. The most conspicuous finding, aside from the epithelial/mesenchymal dichotomy, was the consistent and heavy uptake of ^3H -E₂ by perichondrium and cartilage in all laryngeal sections taken where cartilage was present (Fig 3). This was true for each site in a particu-

lar animal, as well as in different animals. Thus, no laryngeal site with a cartilaginous component in any animal failed to show labeling of less than 75% to 100% of cells present. It should be noted that central zones of cartilage did not label, probably as a consequence of a diffusion gradient across the cartilaginous matrix.

More specifically, labeled cartilage was present in sections from epiglottis, arytenoids, trachea, anterior commissure, cricoid, thyroid, false cord, and subglottic mucoperiosteum. Thus the laryngeal cartilage, whether elastic or hyaline, and its perichondrium appear extremely rich in receptor binding protein for E₂.

Condensed or dense collagenous mesenchymal tissues surrounding or investing the laryngeal musculature were also very rich in receptors. This was best demonstrated in samples from around the vocalis muscle (Fig 4A), as well as the anterior commissure, where as many as 70 nuclei/0.06 mm² were labeled. This is contrasted to similar areas of vocalis muscle from the control animal that showed no localization of silver granules over nuclei (Fig 4B).

Muscle bundles were also consistently labeled but to a much lesser extent. Uptake appeared slightly greater in nuclei located in the interstitium between bundles than in sarcolemmal nuclei. While the degree of nuclear labeling varied from animal to animal and from muscle to muscle within the same animal, all contained nuclei labeled with ^3H -E₂. The vocalis muscle contained the greatest number of receptors of any laryngeal muscle studied (Fig 4C).

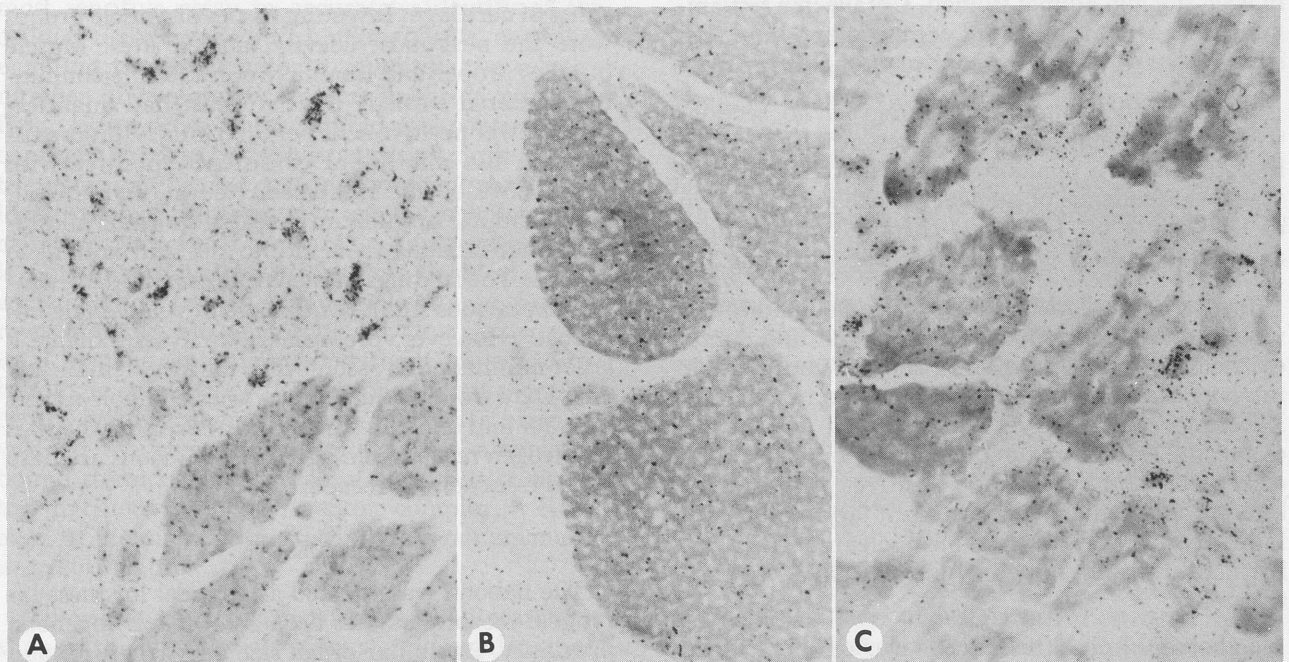


Fig 4. Photomicrographs of vocalis muscle and investing connective tissue (H & E, original x400). A) Experimental animal. Heavy labeling of nuclei in perivocalis mesenchymal tissues (top half) is shown. Muscle bundles may be seen at lower right. B) Control animal. Note absence of nuclear uptake in investing connective tissues at left or muscle bundles at right. C) Experimental animal. Nuclear uptake of ^3H -E₂ is shown.

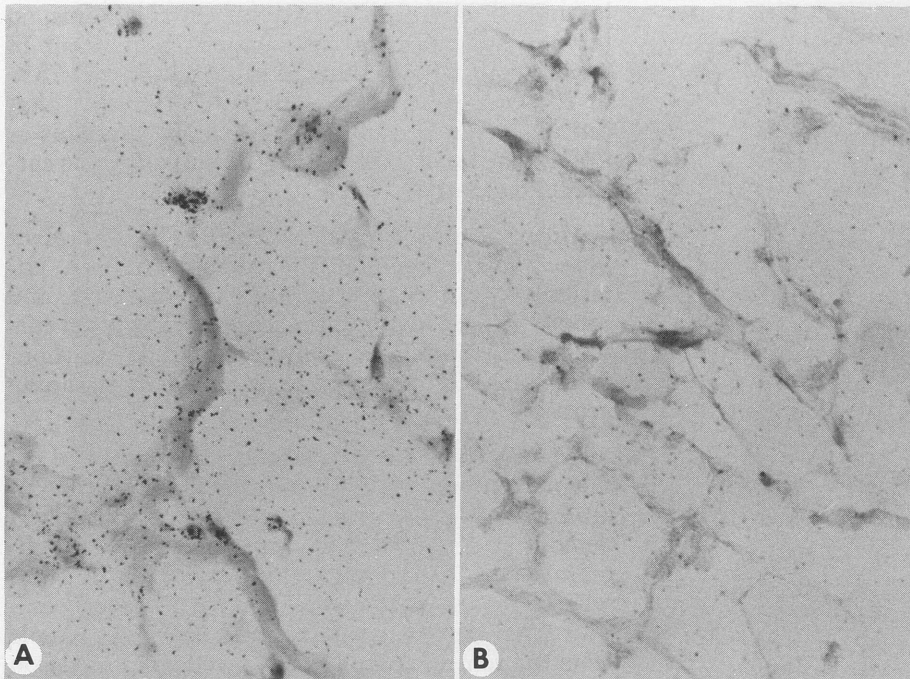


Fig 5. Sections of fat from area of false cord (H & E, original x400). A) Labeling of adipose nuclei. B) Control animal. Note complete absence of nuclear staining.

The lamina propria subjacent to epithelial surfaces also contained labeled cells; however, uptake was quite variable from site to site. The lamina propria of the vocalis muscle in the area of the anterior commissure and subglottic mucoperiosteum was the site of greatest uptake, with as many as 34 nuclei/0.06 mm² being labeled in some fields.

Adipose tissue, while quite variable in degree of labeling, was also consistently positive for receptors in each site and animal studied. Uptake in a test animal (Fig 5A) was compared with similar adipose tissue without uptake in the control animal (Fig 5B).

Consistently Unlabeled Tissues. In no sections where surface epithelium was present, either stratified squamous or pseudostratified ciliated columnar, was there evidence of nuclear uptake and retention of ³H-E₂ (Fig 6). Likewise, chronic inflammatory cells failed to show evidence of receptor binding.

Inconsistently Labeled Tissues. Nerve bundles and vascular endothelium, as well as acinar and ductal epithelium of mucous glands, showed considerable intra-animal and interanimal variation in labeling. Labeling occurred in very small nerves, and the nuclei of the small bundles coursing through the false cord were most consistently positive. Larger nerve bundles, particularly the recurrent laryngeal nerve, failed to show any appreciable nuclear localization. Perineural tissues, however, did contain a few positive cells.

Labeling of endothelial cells was quite variable, as was labeling of minor salivary glands. Many of these tissues were completely devoid of receptors, while a few were positive. No consistent pattern according to site was identified.

Control Animal Tissues. Parallel sections of each site studied from the control animal were negative for any steroid-receptor binding.

In summary, the principal and most consistent uptake of labeled estrogen occurred in tissues of mesenchymal origin. Epithelial tissues, with the exception of a few glands and ducts, were invariably negative. The most striking uptake was in perichondrium and other chondroblastic and chondrocytic zones of cartilage. Investing tissues of muscle groups were the next most heavily labeled sites. Muscle bundles proper and lamina propria, while containing scattered strongly positive cells, had quantitatively fewer positive cells per 0.06 mm². Adipose tissue was also mildly but consistently positive with 0% to 25% of nuclei labeled. Neural, endothelial, and glandular epithelium revealed sporadic and inconsistent labeling from site to site and animal to animal. The findings in the vocalis samples are similar to previous studies of this site in young male baboons.¹⁰ However, preliminary analyses indicate a lesser number of E₂ receptors in the aged female larynx. Data from young females is unavailable as yet. Current and ongoing studies are addressing the sites of estrogen receptors in aged male baboons as phase 2 of the sex steroid receptor study.

DISCUSSION

The baboon was selected as a model for these laryngeal receptor studies because of its phylogenetic proximity, its similar organ size and structure, and especially the close resemblance of the laryngeal anatomy to humans. Earlier studies performed at our institution have demonstrated the excellence of the baboon as a model for cardiovascular and pulmo-

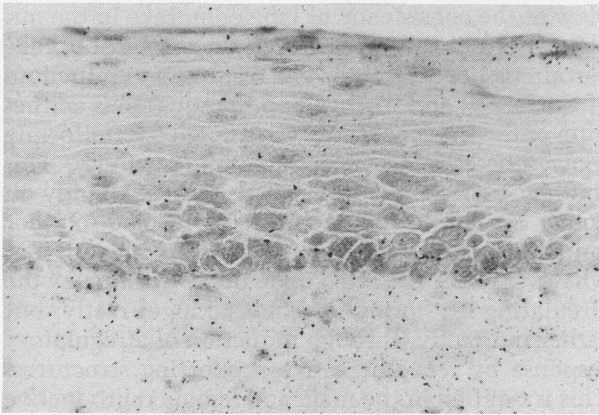


Fig 6. Representative section of stratified squamous epithelium from true cord of study animal receiving ^3H -E $_2$ (H & E, original x400). Note absence of nuclear uptake of tritiated hormone.

nary disease.⁷ Previous experience has assisted in developing the autoradiographic techniques for identifying normative data for the location and extent of sex steroid-receptor binding in the CNS and digestive tract of the young baboon.^{8,13} We are fortunate to have located within our university community the Southwest Foundation for Research and Education, which houses the largest baboon colony in captivity, thus allowing us access to baboons of all ages with complete medical histories and records.

The autoradiographic technique was chosen because of its specificity in identifying the localization of the bound hormone-receptor complex within the cellular nucleus, where it induces its regulatory action on mRNA production. This appears to be the most sensitive assay to accurately identify at the cellular tissue level where binding occurs, as well as enabling the investigator to quantify the relative number of receptor complexes in the given tissue field. Using precise histopathological control, concomitant changes in the histology or morphology of the tissue can be compared to the semiquantitative localization of the hormone-receptor complex in the cellular structure. It appears that autoradiography is more anatomically sensitive than the biochemical assay method, which homogenizes the entire segment of tissue into a cytosol form, thus assaying the total tissue receptor content without respect to the histologic location of the receptor complexes. Recently, immunochemical techniques have been developed to detect the receptor in the absence of bound steroid by the preparation of antibodies to the purified hormone-receptor complex.¹⁴ However, at the moment this technique is not amenable to quantification.

There is ever increasing data in the literature to support the possible role of sex steroid regulatory effects in the structure and function of the upper aerodigestive tract. The larynx is a target organ for gonadal steroids. In songbirds, syringeal tissues are rich in androgen receptors.¹⁵ This structure is analo-

gous to the larynx in primates. The amount of singing is directly related to testosterone levels. Adult female canaries respond to androgen therapy with malelike song. Voice changes at puberty and anatomic sexual dimorphism appear related to the onset of testicular androgen production. Additionally, exogenous sex hormones have been shown to alter vocal characteristics¹⁶ in patients with breast carcinoma. In a recent study from the Federal Republic of Germany, a direct correlation was shown between depth of voice and sex hormone levels in male singers.¹⁷

While Charlip⁵ found no significant change in the fundamental vocal frequency in women from young adulthood to advancing age, his studies and those of McGlove and Hollien⁶ demonstrated a decreased pitch variability in the older woman. In comparing their studies to observations in men in whom there was a greater change in pitch variability and decreased phonation/time ratio,⁴ they postulated that the anatomic changes in the female larynx with aging might not be the same as in the older male larynx due to the latter's extensive changes during puberty. These changes may be due to altered receptor function or content to the sex steroid hormones, which change with aging.

Other changes in the morphology of the aging neuromuscular tissues have a possible relationship to the study of speech in the elderly. Kawamura et al¹⁸ demonstrated that the cell bodies of lower motor neurons in spinal cord and cranial nerve nuclei show regressive structural changes and disappear with age. In some muscles of patients 50 years or older, Stalberg and Trontelj¹⁹ found increased "jitter" values during electromyographic testing, implying postsynaptic receptor deficit. Striated muscles may show a variety of regressive changes associated with aging. Some are clearly the expression of chronic partial denervation, while others seem to be primary, and may reflect diffuse or biologic aging of the muscle itself.²⁰ Following castration, the levator ani muscle in the rat undergoes severe atrophy.²¹ As receptors for testosterone are known to be present in motor neurons and muscle fibers, the observed morphologic changes might be under the control or regulation of testosterone.

Thus, a study of aged baboons given labeled sex steroid hormone provides a model to gain information about the tissue location and quantification of receptor complexes. It may be possible to relate this information about the steroid-receptor complexes to the known pathoclinical states of decreased laryngeal function with aging. That is, this study provides cellular level identification of estrogen receptors in the highly dimorphic muscular and connective tissue of the primate larynx as well as the cartilaginous supporting structures. It is now possible to state that the vocal characteristics of aging may be associated with anatomic and physiologic changes

in the musculoskeletal framework of the larynx that are mediated by the action of sex steroid receptors on their target tissues.

Another aspect of laryngeal function and structure in addition to vocal changes that must be considered is the increased incidence of neoplasia of the larynx with advancing age. Although alcohol consumption and smoking are clearly factors in the development of laryngeal carcinoma, the roles of the local tissue resistance to neoplasia and the competency of the immune system are felt to be contributory but not well understood. It is important to consider that cancer of the larynx is far more common in men than women, especially in view of the fact that the larynx is a dimorphic organ. Urinary androgen and estrogen excretion levels in men with pachyderma laryngis and cancer of the larynx are elevated in comparison to normal controls.²² Clinical trials using cyproterone acetate, a potent anti-androgen, in the treatment of laryngeal carcinoma have been reported and are based in part on the evidence that the larynx is a target organ for sex steroid hormones.²³ Since the extent and location of the sex steroid receptors in the larynx had not been well documented in the past, such therapy was considered premature and empirical. However, the data in this experiment provide the basic science information that could support the clinical trials of antagonistic drugs to the sex steroids. Some investigators have demonstrated concentration of radioactivity in mesenchymal cells of the larynx in fetal mice after injection of ³H-diethylstilbestrol, and as a result, have postulated theoretical risk in both males and females with in utero exposure to this hormone.²⁴

Sex steroid hormones appear to exert numerous significant and varied effects on their target tissue. These range from induction of synthesis of only a few peptides to control of cellular proliferation and/or death.²⁵ There may be both receptor- and nonreceptor-mediated effects. The diversity of effects include stimulation of collagen and protein synthesis, enhancement of vascular reactivity, alteration of vascular endothelial permeability, and prostaglandin synthesis. Perhaps some of the most important effects are on the immune system, where sex steroids have been shown to have regulatory effects on antibody formation and stem cell proliferation. In a study by Eidinger and Garrett,²⁶ changes in sex steroid levels exerted marked influence on immune responsiveness and stem cell differentiation by increasing the number and differentiation of functional cells, as well as by influencing antibody production. Others have shown inhibition of leukocyte migration by progesterone in rats²⁷ and suppression of human lymphocyte transformation.²⁸ It is also felt that estrogens may promote changes in connective tissues that inhibit spread of bacteria and toxins.

The findings in this study are very interesting in

view of the consistency of labeled uptake in the nuclei of certain cell types and in the extent of uptake certain tissues exhibited. The respiratory epithelium of the larynx and trachea and the squamous epithelium of the true vocal cords and epiglottis uniformly showed no estrogen-receptor binding activity. This finding corresponds well to a previous study in young baboons¹⁰ and to studies performed in other animal species.²⁴ This would tend to suggest that whatever effect is exerted upon the epithelium by the circulating sex hormones is not acting directly, but rather indirectly, through induction of a regulatory response by receptor active supporting structures. This is typified in the male and female reproductive tracts. Androgen- and estrogen-induced growth, morphogenesis, and cytodifferentiation of epithelium are controlled by the mesenchyma with which the epithelium is associated.²⁹ During this time the receptors for both steroids are in the mesenchymal tissues but not in the epithelial cells. Other nonsurface epithelial structures such as salivary gland tissue did have some labeled uptake, but can be considered to be affected differently by sex hormones than the surface epithelium.

The most consistent areas of receptor labeling were found in the mesenchymal tissues of the larynx, including the investing and supporting structures. The strongest areas of uptake of labeled estrogen included the lamina propria, the intrinsic and extrinsic laryngeal musculature, and the perichondrium and its underlying cartilage. Of particular interest was the very strong receptor labeling in the region of the anterior commissure and the mucoperiosteum of the immediate subglottic region. Mesenchymal tissues play a critical role in embryonic morphogenesis of epithelium and may influence its functional differentiation and programming. This suggests that factors that affect mesenchymal tissues may in turn influence epithelium. Since mesenchymal tissues in the area of the larynx studied were rich in estrogen receptors, critical levels or alterations in levels of sex hormones could indirectly result in epithelial alterations as they do in the developing reproductive tract.²⁹ The unopposed action of these hormones might lead to altered morphogenesis and functional differentiation of the epithelium with respect to the development of laryngeal neoplasms. Studies in the past, which attempted to demonstrate estrogen receptors in these laryngeal epithelial tumors, may have assayed only the tumors' epithelial components and not the underlying mesenchymal tissues where the receptors have been found to lie. An analogous mechanism is suggested in the baboon prostate where recent data show receptors to be present in mesenchymal rather than epithelial tissues.³⁰ While the laryngeal muscles showed consistent uptake in these aged female baboons, the labeling was consistently less than that seen in normative data from young male baboons that received either estrogen or testosterone.¹⁰ This suggests that, at least with this

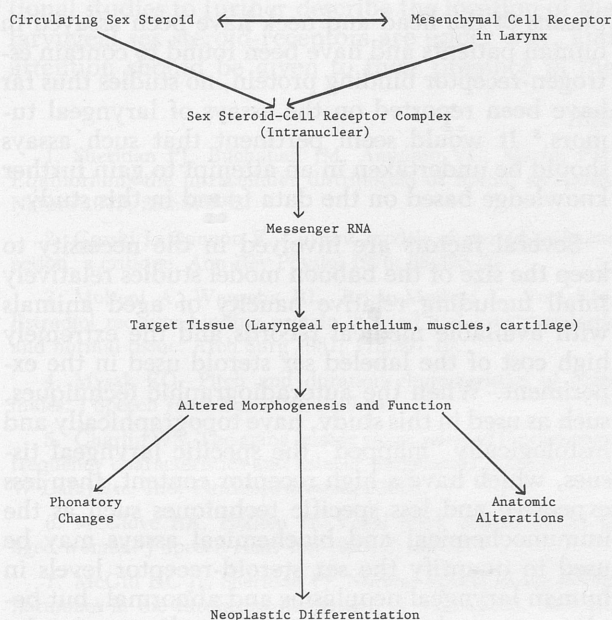


Fig 7. Target tissue alteration due to sex steroid-receptor complex mediation.

small sample of estrogen-labeled animals, there is a diminution in the number or function of receptors with age in a highly active tissue (muscle). Experiments are planned to study aged male baboons given $^3\text{H-E}_2$ to allow more precise comparisons.

Although not previously reported, the finding of consistent and strongly labeled nuclear uptake in the perichondrium and outer layers of the laryngeal and tracheal cartilages is important, as it would indicate that the supporting structures of the larynx continue to contain functioning, active estrogen receptors, even in senescence. Since adequate laryngeal function requires a strong musculoskeletal supporting system, alterations in cellular activity with changing hormone levels could in turn change the competency of muscles, ligaments, and cartilage. Thus, altered mobility, elasticity, and compliance of the functioning muscular and connective tissue of the larynx might give rise to a diminished response to active vocalization.

There was no evidence of consistent steroid-receptor binding and localization within the recurrent laryngeal nerve. Binding was seen sporadically but was not strong enough to suggest any direct influence of the sex hormone on the nerve itself. Evaluation of CNS tissue and ganglia obtained during this study is under way and may produce more evidence relating to a neurological effect of hormone-receptor binding in normal aging animals. In the present study, however, the peripheral laryngeal nerves were not seen to have a significant number of receptor sites to indicate their involvement in the hormonal regulatory process.

Several implications can be drawn from the results of this study in relation to their clinical signifi-

cance. First, it is very interesting that surface epithelium has no appreciable hormone-receptor binding activity. Superficially, it would be easy to imply that because sex steroid receptors are not found in the surface epithelium of the larynx, the sex steroids would play no role in pathologic states of this epithelium. However, it is well known that epithelial-mesenchymal interactions are of major importance in the development, differentiation, and sustained function of these surface structures, probably based on mutual inductive interactions.²⁹ As a consequence, receptors in mesenchymal tissues (abundant in the baboon larynx) could be readily postulated to have a number of indirect effects on the overlying epithelium (Fig 7). Maintenance of the integrity, the normal maturative sequence, and the resistance to metaplasia of the epithelium may be related to receptor-mediated connective tissue changes. Since the activated hormone-receptor complex is capable of "turning on" selective sites of genome, changes in the endocrine profile might have an effect on the maintenance of epithelial morphodifferentiation. The result might be a spectrum of clinical presentations from abnormal speech patterns with aging to dysplastic or neoplastic changes. Some degree of genetic predisposition to neoplastic changes may be facilitated by altered steroid-receptor complex activity. Certainly it is possible to enhance morphodifferentiation processes with exogenous carcinogens such as tobacco and alcohol. Pertinent to this hypothesis is the known effect of steroid-receptor binding on certain stem cell functions in the immune competency system of the individual and reproductive tract.²⁶⁻²⁹ Therefore, sex steroids may act singly or in concert with other agents to produce alterations in the surface epithelial structure and function. It is currently felt that endogenous steroid hormones, acting through the principle of neuroimmunomodulation may play a significant role in the development or containment of infectious and inflammatory processes of the body, primarily through the action of stem cells and the sympathetic nervous system.

It has been recently demonstrated that the growth of cutaneous "strawberry" hemangiomas can be significantly altered by the administration of exogenous steroids.³¹ Furthermore, cytosolic receptor assays on these hemangiomas showed a very high population of cytosol-specific estrogen-binding receptors in the majority of the biopsy specimens. This raises two questions for consideration. One, are subglottic hemangiomas in children high in estrogen receptors; and two, if so, is it prudent to consider using antiestrogen therapy rather than corticosteroids in the management of these lesions? Further research is needed to answer these questions.

The second major finding of the study was a high binding activity in all tissues of mesenchymal origin in the larynx. The possible role of connective tissue induction of changes in the overlying epithelium

has been previously discussed. The intrinsic and extrinsic laryngeal muscles all showed consistent labeling of the muscle cell nuclei; the activity of these high affinity estrogen receptors might have a direct effect on the skeletal muscle cells and may modulate their cellular activities. It was previously noted that the aged female baboons had less estrogen-receptor binding in their laryngeal muscles than did the young animals in a previous study.¹⁰ Alteration of either the sex steroid level or the number of receptor sites in these highly functional tissues may affect the muscular component of phonation, leading to a weak, poorly coordinated voice. An additional factor to be considered is the role of the connective tissue supporting structures (lamina propria, ligaments, and fascia), which also have high nuclear localization of labeled hormone. It is likely that the aging process involving the sex steroids and their receptors adversely affects the elasticity, compliance, and, where required, the stability of the connective tissue structures, perhaps leading to bowing of the vocal cords, which is so commonly seen in the elderly patient with phonation difficulties.

Since abundant estrogen receptors have been found in the esophagus of baboons, it is possible that the entire upper aerodigestive tract is regulated in part by these important receptor complex activations.⁸ Thus, this would help explain some of the dysphagia, aspiration, and poor motility of swallowing commonly seen in older individuals who also have speech abnormalities.

The third significant area of information arising from this study is reflected by the finding of consistent nuclear labeling of the perichondrium and outer layers of the laryngeal cartilages, including the arytenoid cartilages. These findings are particularly interesting in light of the fact that the growth and development of the larynx seems to be under dimorphic control of the sex steroid hormones. It is not known whether the male larynx has a significant growth spurt at puberty because of altered affinity of the receptors *in situ* or because of a change in the total number or distribution of a specific affinity receptor. Because of the pertinent information that could be obtained, future studies in this direction are currently contemplated.

It is tempting to relate the highly labeled nuclear receptor content of perichondrium and cartilage to a number of laryngeal structural abnormalities such as chondromalacia, chondroma, and chondrosarcoma; sex steroid-receptor assays should be performed on these tumors in the future to ascertain the receptor binding capacity. Such information could conceivably provide valuable therapeutic data for the possible prevention of or therapy for such pathological conditions by hormonal manipulation. The same principle would apply to any neoplasm of the larynx if it could be found to have high receptor assays to a specific sex steroid. While other neo-

plasms of the head and neck have been assayed in human patients and have been found to contain estrogen-receptor binding protein, no studies thus far have been reported on the assays of laryngeal tumors.³ It would seem pertinent that such assays should be undertaken in an attempt to gain further knowledge based on the data found in this study.

Several factors are involved in the necessity to keep the size of the baboon model studies relatively small including relative paucity of aged animals with available medical records and the extremely high cost of the labeled sex steroid used in the experiment. When the autoradiographic techniques, such as used in this study, have topographically and histologically "mapped" the specific laryngeal tissues, which have a high receptor content, then less expensive and less specific techniques such as the immunochemical and biochemical assays may be used to quantify the sex steroid-receptor levels in human laryngeal neoplasms and abnormal, but benign, mucosal tissues. Further studies are under way at our institution to obtain such normative information between the sexes in the baboon, using both estrogen and testosterone. It is postulated that the activity of the sex steroid-receptor complex plays an important role in regulating laryngeal structure and function in the aging process and in the development of neoplasms.

SUMMARY

Tritiated estradiol-receptor complex localization in the nuclei of laryngeal tissues was measured in four aged female and one control aged female baboons using the autoradiographic technique. Transformed nuclear steroid-receptor complexes interact with the chromatin to modulate gene expression, which leads to changes in both mRNA and protein synthesis. Thus, the hormone-receptor complex has a regulatory effect on the cell and a collective effect on the laryngeal tissues. The major findings in the study were threefold, based on the consistency of intranuclear labeling by the E₂-receptor complex. One, laryngeal surface epithelium did not bind the estrogen and can therefore be felt to have little or no receptor activity. Two, the supporting mesenchymal structures such as muscle, lamina propria, fat, and dense connective tissue had very high uptake of the labeled E₂. It is postulated that via the effect of the activated receptor complex on the mesenchymal cells, this tissue might regulate in part the morphodifferentiation and function of the overlying surface epithelium by an inductive process (Fig 7). This could lead to phonatory abnormalities or to the development of an epithelial neoplasm. Three, laryngeal cartilage and investing perichondrium are high in E₂-receptor localization and may account for the dimorphic growth of the larynx during puberty as well as pathologic states such as chondromalacia, chondroma, and perhaps chondrosarcoma. Addi-

tional studies to further describe the location of the laryngeal sex steroid-receptors are under way, and attention should be given to their presence in the

aging process and neoplastic diseases. Hormonal manipulation of laryngeal diseases may be a viable treatment option in the future.

REFERENCES

1. Sheridan PJ, Buchanan JM, Anselmo VC, Martin PM. Equilibrium: the intracellular distribution of steroid receptors. *Nature* 1979; 282:579-82.
2. Gorski J, Gannon F. Current models of steroid hormone action, a critique. *Ann Rev Physiol* 1976; 38:425-50.
3. Molteni A, Warpeha RL, Brizio-Molteni L, Fors EM. Estradiol receptor-binding protein in head and neck neoplastic and normal tissue. *Arch Surg* 1981; 116:207-10.
4. Mysak EO. Pitch and duration characteristics of older males. *J Speech Hear Res* 1959; 2:46-54.
5. Charlip WS. The aging female voice: selected fundamental frequency characteristics and listener judgements [Dissertation]. W Lafayette, Ind: Purdue University, 1968.
6. McGlove RE, Hollien H. Vocal pitch characteristics of aged women. *J Speech Hear Res* 1963; 6:164-70.
7. McGill HC Jr, Sheridan PJ. Nuclear uptake of sex steroid hormones in the cardiovascular system of the baboon. *Circ Res* 1981; 48:238-44.
8. Winborn WB, Sheridan PJ, McGill HC Jr. Autoradiographic demonstration of estrogen receptors in the esophagus of baboons. *Gastroenterology* 1983; 84:1563-7.
9. Sheridan PJ, Weaker FJ. Androgen receptor systems in the brain stem of the primate. *Brain Res* 1982; 235:225-32.
10. Aufdemorte TB, Sheridan PJ, Holt GR. Autoradiographic evidence of sex steroid receptors in laryngeal tissues of the baboon (*Papio cynocephalus*). *Laryngoscope* 1983; 93:1607-11.
11. Stumpf WE. Autoradiographic techniques for localization of hormones and drugs at the cellular and subcellular level. *Acta Endocrinol [Suppl] (Copenh)* 1971; 153:205-21.
12. Ison EJ, Sheridan PJ. Autoradiography of diffusible substances — a practical approach. *Am J Med Technol* 1981; 47:38-42.
13. Herbert DC, Sheridan PJ. Uptake and retention of sex steroids by the baboon pituitary gland. Evidence of sexual dimorphism with respect to dihydrotestosterone. *Biol Reprod* 1983; 28:377-83.
14. King WJ, Greene GL. Monoclonal antibodies localize estrogen receptor in the nuclei of target cells. *Nature* 1984; 307:745-7.
15. Lieberburg I, Noltebohm F. High-affinity androgen binding proteins in syringeal tissues of songbirds. *Gen Comp Endo* 1979; 37:286-93.
16. Kupperman HI. Iatrogenic endocrinopathies. In: Wilson RA, Craver BN, eds. Clinical uses of the female sex hormones and early diagnosis and treatment of mammary cancer. Amsterdam: Excerpta Medica, 1972:15-33.
17. Meuser W, Nieschlag E. Sexual hormone und Stimmlage des Mannes. *Dtsch Med Wochenschr* 1977; 102:261-4.
18. Kawamura Y, O'Brien PC, Dyck PJ. Lumbar motoneurons of man. I. Number of diameter histogram of alpha and gamma axons of ventral root. *J Neuropathol Exp Neural* 1977; 36:853-60.
19. Stalberg E, Trontelj JV. Single fiber electromyography. Surrey, England: Mirvalle Press, 1979.
20. Roth GS. Hormone receptor changes during adulthood and senescence: significance for aging research. *Fed Proc* 1979; 38:1910-4.
21. Tobin C, Pecot-Dechavassine M. Effect of castration on the morphology of the motor end-plates of the rat levator ani muscle. *Eur J Cell Biol* 1982; 26:284-8.
22. Koewit K, Schwartz S, Hussel B. Urinary androgen and estrogen excretion in men with pachyderma laryngis and cancer of the larynx. *Endo Krinologie* 1979; 73:151-6.
23. Saez S, Martin PM, Gignoux B. Androgen receptors in the normal mucosa and in epithelioma of the human larynx and pharynx. In: Thomson EB, Lippman ME, eds. Steroid receptors and the management of cancer. Vol 1. Boca Raton, Fla: CRC Press, 1979:205-13.
24. Narbaitz R, Stumpf WE, Sar M. Estrogen target cells in the larynx: autoradiographic studies with ³H-diethylstilbestrol in fetal mice. *Horm Res* 1980; 12:113-7.
25. Thompson EB, Lippman ME. Hormone receptors and hormone action. In: Thompson EB, Lippman ME, eds. Steroid receptors and the management of cancer. Vol 1. Boca Raton, Fla: CRC Press, 1979.
26. Eidinger D, Garrett TJ. Studies of the regulatory effects of the sex hormones on antibody formation and stem cell differentiation. *J Exp Med* 1972; 136:1098-116.
27. Contopoulos AN, Clemens LE, Ortiz S, Stites DP, Sitteri PK. Inhibition of leukocyte migration by progesterone. *Gynecol Obstet Invest* 1977; 8:110.
28. Clemens LE, Stites D, Sitteri PK. *In vitro* suppression of human lymphocytes transformation by progesterone. *Gynecol Obstet Invest* 1977; 8:20.
29. Cunha GR, Taguchi O, Shannon JM, Chung LWK, Bigsby RM. Mesenchymal role in hormone-induced epithelial development. In: Serio M, ed. Sexual differentiation: basic and clinical aspects. New York: Raven Press, 1984:33-51.
30. Weaker FJ, Sheridan PJ. Localization of ³H-estradiol in the reproductive organs of male and female baboons. *J Morphol* 1982; 172:151-7.
31. Sasaki GH, Pang CY, Wittliff JL. Pathogenesis and treatment of infant skin strawberry hemangiomas: clinical and *in vitro* studies of hormonal effects. *Plast Reconstr Surg* 1984; 73:359-68.

VOCAL CORD PARALYSIS IN SMALL CHILDREN: PRINCIPLES IN MANAGEMENT

HARVEY M. TUCKER, MD

CLEVELAND, OHIO

Vocal cord paralysis in children is an uncommon but often disabling problem. It may be congenital or acquired either in the immediate period surrounding birth or as a postpartum event. Because even unilateral vocal cord paralysis can result in severe respiratory distress in the newborn and in small children, recognition of this problem can be critical. A logical approach to diagnosis and management requires not only that the physician be alert to the problem but also that several procedures be established that can be used together or singly to address the problem, as is most appropriate to the individual case. The usefulness of intubation, tracheotomy, surgical lateralization of the vocal folds, and reinnervation in the management of these problems is discussed, and 30 cases of vocal cord paralysis in children under the age of 5 years are presented.

KEY WORDS — vocal cord immobility, vocal cord paralysis.

Vocal fold paralysis is infrequent in newborn infants and small children,¹ but when it does occur, it can be severely disabling. Bilateral involvement results in life-threatening airway compromise, of course, but even unilateral paralysis can produce severe respiratory distress in the tiny larynx of the newborn. Hoarseness, breathiness, and weakness of voice, on the other hand, although features of unilateral paralysis in children (as they are in adults), tend to be less severe and do not seem to affect normal speech development significantly.²

Paralysis (or, more correctly, immobility) of the vocal folds can be congenital or acquired. It is important to determine the cause whenever possible, since this knowledge may influence decisions on management in each case. Associated neuromuscular deficits (ie, swallowing and respiratory capability), the likelihood of progression or recovery from disease, life expectancy, and potential mental development are only a few of the factors that must be taken into account. The surgeon who plans to deal with these problems should have an orderly plan for diagnosis and management selection if he or she is to provide the best possible rehabilitation for children so afflicted.

BILATERAL PARALYSIS

The infant or small child with bilaterally immobile vocal folds is not likely to survive long without airway intervention, which is usually endotracheal intubation. Once the situation is in hand, the tube should be removed and spontaneous efforts at respiration should be observed. Assessment of vocal cord mobility can be very difficult in the newborn, even under general anesthesia. If circumstances permit, an attempt should also be made to palpate both arytenoid cartilages to determine

passive mobility. Cricoarytenoid fixation, posterior glottic webs, or vocal cord fusion can be distinguished from paralytic immobility of the vocal folds only in this way.

Bilateral vocal fold paralysis in pediatric patients can be managed in three general ways: 1) tracheotomy (bypass), 2) vocal fold lateralization (widening), or 3) reinnervation.

Tracheotomy. Although it is intended to be temporary in most cases, tracheotomy is a necessary measure in the management of virtually all children with bilaterally immobile vocal folds. Bypass of the glottis stabilizes the airway and creates an elective situation where an emergent one may have existed previously. Necessary diagnostic studies can then be undertaken and other medical problems attended to without serious concern about airway compromise. Advantages include a) prompt establishment of a stable airway, b) no further compromise of voice beyond that which accompanied the paralysis, and c) reversibility. Disadvantages are a) need for a surgical procedure and wearing a tube, b) difficulties and risks of ongoing tracheotomy care, and c) difficulty of extubation in very small children.

Vocal Fold Lateralization. Any of several techniques, including arytenoidectomy or cordectomy by laser technique or microlaryngoscopy, anterior thyrotomy, or lateral cervical approach (Woodman) can be used for vocal fold lateralization. Common to all of these procedures is the intention to improve the airway by lateralizing one or both of the vocal folds permanently. The airway that results will be inversely proportional to and at the expense of residual voice. Moreover, creating what may be an adequate airway for a small child by these essentially static techniques does not guaran-

From the Department of Otolaryngology and Communicative Disorders, Cleveland Clinic Foundation.

Presented at the meeting of the American Laryngological Association, Palm Beach, Florida, May 4-5, 1986.

REPRINTS — Harvey M. Tucker, MD, Dept of Otolaryngology and Communicative Disorders, Cleveland Clinic Foundation, 9500 Euclid Ave, A71, Cleveland, OH 44106.

TABLE 1. MANAGEMENT CHOICES IN VOCAL FOLD PARALYSIS IN SMALL CHILDREN

Bilateral
Tracheotomy
Vocal fold lateralization
Laser cordectomy
Widening of posterior commissure
Arytenoidectomy/lateralization
Reinnervation
No intervention
Unilateral
Tracheotomy
Teflon (or Gelfoam) injection
Surgical medialization
Reinnervation
Speech therapy
No intervention

tee that the airway will grow with the child and continue to be sufficient. For these reasons and because lateralization procedures are irreversible, they are not often the best choice to manage vocal fold paralysis in children. If reinnervation is not possible or is unsuccessful, long-term tracheotomy is the procedure of choice. Irreversible surgical decisions should be put off until the child has reached an age at which he or she can take an intelligent part in deciding whether or not to exchange voice for airway and only after a lengthy opportunity to assess how well tracheotomy can be incorporated into day-to-day existence.

Reinnervation. Reinnervation of one or both of the posterior cricoarytenoid muscles in an effort to restore abductive capability offers several potential improvements over other means of managing bilateral paralysis. Advantages include the following. a) The procedure restores the airway without further loss of residual voice. b) The procedure does not preclude successful use of other techniques if it fails. c) Because it neither fixes the vocal fold nor makes use of the recurrent laryngeal nerve, the procedure can be employed even when some possibility of spontaneous recovery remains. Its major disadvantage is that there is a delay of from 2 to 6 months after surgery before reinnervation may progress sufficiently to permit decannulation, even in successful cases.

Treatment Selection (Table 1). Because reinnervation is the most desirable procedure when it can be performed successfully, determination of cause and presence or absence of fixation is essential. Lateralization procedures are best avoided until a reasonable trial at long-term tracheotomy has been allowed. The occasional child with bilateral paralysis may not require surgical intervention, but this is the exception rather than the rule.

UNILATERAL PARALYSIS

Because of the elasticity, growth potential, and relatively small size of the pediatric airway, voice

tends to be much less profoundly affected by unilateral recurrent nerve paralysis than in adults. On the other hand, airway compromise is more likely to occur, especially in infants and small children. In the latter two groups, tracheotomy may even be necessary on a temporary basis. Although extubation can be difficult in very small children, the tube can usually be removed between 1 and 2 years of age if the only problem is unilateral paralysis.

Persistent voice change due to unilateral paralysis (or fixation, which is uncommon) can be managed by 1) Teflon (or Gelfoam) injection, 2) surgical medialization, or 3) reinnervation.

Teflon (or Gelfoam) Injection. Advantages of Teflon (or Gelfoam) injection are that it yields almost immediate improvement of voice and cough. Its many disadvantages in children include a) irreversibility, b) difficulty in judging amount to be injected, since few children can tolerate placement of Teflon under local anesthesia so that voice can be monitored, c) potential risks of long-term foreign material injection in children, d) changes in vibratory characteristics of the vocal fold because of the mass of Teflon injected, and e) possible airway compromise in small larynges.

Surgical Medialization. Any of several means,^{3,4} all of which have in common displacement of the paralyzed vocal fold toward the midline with ultimate fixation in this position, can be used for surgical medialization. Advantages include a) any size defect can be overcome, b) the procedure can be used even in cases of fixation, and c) it causes no change in mass and therefore in vibratory characteristics of the vocal fold (unless a subsequent Teflon injection is necessary for fine tuning). Disadvantages are a) need for temporary tracheotomy in most cases, b) use of open surgery with the patient under general anesthesia, c) potential airway restriction in small larynges, d) irreversibility, and e) difficulty in judging proper position for the vocal fold under general anesthesia.

Although surgical medialization is more often applicable in children than is surgical lateralization, it still suffers from irreversibility and does not restore tensioning capability. For this reason, the quality of voice achieved may be lower because of poor pitch control.

Reinnervation. Selective reinnervation of the adductors of the larynx is a viable alternative in the management of unilateral vocal fold paralysis in small children. Its advantages are as follows. a) There is no compromise of potential spontaneous recovery, thus permitting its use without waiting some fixed period. b) No foreign materials are required. c) Tracheotomy is not usually necessary. d) The procedure does not preclude eventual use of any other technique. e) It restores tensioning capability and therefore provides better pitch control, as

TABLE 2. CAUSE OF VOCAL FOLD IMMOBILITY IN 30 CHILDREN

Cause	N	Total
Bilateral		
Congenital		15
Arnold-Chiari malformation	6	
Hydrocephalus	3	
Eyelid-ptosis associated ^s	2	
Other	4	
Acquired		7
Surgical trauma	4	
Intubation injury	2	
Recurrent nerve injury	2	
Closed neck injury	2	
Polio	1	
Unilateral		
Congenital		3
Acquired		5
Closed neck injury	3	
Surgical trauma	2	
Total		30

well as medialization of the vocal fold. Disadvantages of reinnervation are a) need for an open surgical procedure and b) delay of up to 6 months before restoration of adduction may occur.

Although it is desirable to restore voice promptly after a rehabilitative procedure has been undertaken, children usually tolerate weak voice quite well, at least until they begin preschool or kindergarten. As a result, the delay in restoration of function after reinnervation for unilateral paralysis is outweighed by the superior voice quality possible and lack of irreversible damage afforded by this technique. As has been noted above, it is not often necessary to intervene surgically at all in small children with unilateral vocal fold paralysis, since the great majority compensate quite satisfactorily with appropriate speech therapy, and aspiration and poor cough are not often significant in this young and otherwise resilient age group.

Treatment Selection. The treatment of choice to improve voice in children with unilaterally immobile vocal folds is speech therapy (Table 1). Besides the possibility of spontaneous recovery in some cases, this approach avoids irreversible intervention while allowing the child's larynx to compensate, which is likely to happen in the majority of cases.

MANAGEMENT EXPERIENCES AND RESULTS

Thirty patients under the age of 5 who were suffering from vocal fold immobility have been managed according to these principles over the period July 1975 to June 1985. There were 22 with bilateral involvement: 14 males and eight females, and eight patients with unilateral paralysis: four males and four females. The study was limited to this younger age group because the management of vocal fold paralysis in older children does not differ appreciably from that of adults. The apparent dis-

TABLE 3. MANAGEMENT OF VOCAL FOLD IMMOBILITY IN 30 CHILDREN

Cause	N	Total
Bilateral		22
Tracheotomy	22	
Lysis of vocal fold adhesions	2	
Reinnervation	18	
Lateralization procedure	2	
Unilateral		8
Tracheotomy	6	
Reinnervation	3	
Gelfoam injection	2	
Teflon injection	0	
Surgical medialization	1	
Speech therapy	8	

Some patients had more than one procedure.

parity in incidence of unilateral versus bilateral paralysis is most likely a function of the relatively innocuous course of unilateral paralysis in children (probably leading to failure to diagnose in many patients), rather than to the actual frequency of either type of paralysis. Tables 2 and 3 outline the diagnosis and management selection for this group of patients.

Bilateral Immobility. Only two children had bilateral fixation of the cricoarytenoid joints. Both of these followed prolonged intubation and both were associated with significant laryngotracheal stenosis. After correction of the stenosis, both of these children had lateralization procedures, since spontaneous recovery or reinnervation could not be expected. Two others had what appeared to be bilateral paralysis or fixation, but in reality were found to have posterior web formation between the vocal processes of the arytenoid cartilages. Only careful laryngoscopy demonstrated the true diagnosis. Both of these cases were managed by carbon dioxide laser lysis of the adhesions, with immediate return to normal laryngeal mobility.

When the two cases of vocal cord adhesion and both cases of cricoarytenoid fixation were excluded, 18 children were felt to be suitable candidates for reinnervation. Nine of these attempts at reinnervation permitted eventual decannulation with good airway function and no further loss of voice. All of these nine patients who were successfully extubated were observed to have appropriate abduction of the reinnervated vocal fold(s) by either fiberoptic or direct examination.

The nine failures included the one case of polio myelitis, all six patients with Arnold-Chiari malformation, and two of the three cases of hydrocephalus. Good results were generally achieved in peripheral traumatic paralyses but not in the more centrally involved cases, suggesting that patients with CNS causes of bilateral vocal fold paralysis may not be good candidates for reinnervation. In some cases this may be due to the central disorder making the branches of the ansa hypoglossi that are used un-

suitable for reinnervation. Other central causes of denervation may have an as yet unappreciated effect on the involved muscles, which may interfere with eventual reinnervation. All of these failures have been managed with long-term tracheotomy.

Two patients were managed by initial tracheotomy, which eventually was successfully removed without any other airway manipulation. Indeed, it is not unusual to encounter adults whose bilateral vocal fold immobility was probably present from birth and who have survived with relatively little airway compromise and without tracheotomy. Often such cases are labeled "asthma" because no direct examination of the vocal folds is undertaken. Depending upon the resting position of the immobile vocal folds, body habitus, and other factors, it is clear that a child may survive and even exhibit reasonable exercise tolerance even in the face of uncorrected vocal fold paralysis.

Unilateral Immobility. Six of the children (all small infants) with unilateral vocal fold paralysis had sufficient airway compromise to require tracheotomy. All of these were successfully decannulated within 6 to 18 months. Temporary Gelfoam injection was employed in two cases because of poor cough and aspiration. Both of these compensated satisfactorily so that by the time the Gelfoam had been absorbed, no further intervention was deemed necessary. This suggests that slow relateralization of a paralyzed vocal fold as Gelfoam disappears may encourage gradual hyperadduction of the remaining vocal fold.

Surgical medialization was undertaken in only one patient. This was a child with multiple neurofi-

bromatoses in whom it was felt unwise to use a reinnervation technique that would employ a potentially involved nerve in rehabilitation. All three of the patients in whom reinnervation was attempted were treated successfully. Within 3 months they had recovered near normal voice with excellent pitch control, as judged by subjective evaluation by a panel of three speech professionals. Direct laryngeal evaluation demonstrated active adduction and tensing of the reinnervated vocal fold.

Speech therapy should be included in the management of all children with unilateral vocal fold paralysis, regardless of any other measures undertaken. In most cases, compensation can be speeded up and optimized, which is most often all that is required to achieve nearly normal voice. If surgical intervention of some kind is necessary, speech therapy is likely to optimize eventual recovery of function.

CONCLUSIONS

Management of children with immobility of one or both vocal folds demands a clear understanding of possible causes and available treatment alternatives if optimal results are to be accomplished. A conservative approach that aims to restore as much normal function as possible without irreversible compromise of voice seems best. Procedures that may result in further loss of voice while trying to achieve adequate airway without tracheotomy should be delayed until the child is old enough to take an intelligent part in such decisions. Reinnervation techniques, although not suitable for all patients, potentially can accomplish the desired results in many cases.

REFERENCES

1. Holinger LD, Holinger PC, Holinger PH. Etiology of bilateral abductor vocal cord paralysis. A review of 389 cases. *Ann Otol Rhinol Laryngol* 1976; 85:428-36.
2. Tucker HM, Rusnov M, Cohen L. Speech development in aphonic children. *Laryngoscope* 1982; 92:566-8.
3. Tucker HM. Surgery for phonatory disorders. New York: Churchill Livingstone, 1981: chap 6.
4. Isshiki N, Tanabe M, Sawada M. Arytenoid adduction for unilateral vocal cord paralysis. *Arch Otolaryngol* 1978; 104: 555-8.
5. Tucker HM. Congenital bilateral recurrent nerve paralysis and ptosis: a new syndrome? *Laryngoscope* 1983; 93:1405-7.

VOCAL CORD PARALYSIS IN CHILDREN 1 YEAR OF AGE AND YOUNGER

RICHARD D. GENTILE, MD

ROBERT H. MILLER, MD

GAYLE E. WOODSON, MD

HOUSTON, TEXAS

Twenty-two patients 1 year of age or younger were diagnosed as having unilateral or bilateral vocal cord paralyses between 1962 and 1985. There was a marked male predominance, and 12 of the paralyses were bilateral. Congenital neurological malformations were the cause in six patients, birth trauma in five, surgery in four, syphilis in one, and six cases were idiopathic. Tracheotomy was necessary in 11 of the patients with bilateral paralyses. Ten of the 16 patients for whom follow-up was available had resolution of the paralysis from 1 week to 5 years of age. The importance of making an accurate diagnosis is stressed, as is using the fiberoptic laryngoscope.

KEY WORDS — Arnold-Chiari malformation, infant, laryngoscopy, neonate, tracheotomy, vocal cord paralysis.

INTRODUCTION

Stridor in infants is not uncommon and is usually related to laryngomalacia, the most common congenital anomaly of the larynx.¹ Rarely does laryngomalacia require aggressive treatment because the symptoms resolve as the larynx matures. However, there are many other causes of stridor, one of which is vocal cord paralysis. Holinger and Brown found in their review that vocal cord paralysis comprised 10% of the congenital laryngeal anomalies,¹ and Cohen et al stated that laryngeal paralysis and paresis were the most common findings in their series of patients.² As with any disease, accurate diagnosis is the key to proper treatment. Recent advances in pediatric endoscopy allow the otolaryngologist-head and neck surgeon to assess the neonatal larynx accurately, and, consequently, it is important not to blindly ascribe noisy breathing in children to laryngomalacia.

Despite the importance of this entity and the fact that it is now possible to examine the larynx of even the youngest child thoroughly, there are very few reports that concentrate on vocal cord paralysis in children,¹⁻⁷ and even fewer that deal exclusively with very young children.^{8,9} Some of these reports are quite old, and the causes frequently encountered several years ago may be unusual today. Furthermore, neonates now survive prematurity and diseases that would have been fatal only a few years ago. We report our experience in the diagnosis and management of children 1 year of age and younger.

MATERIAL AND METHODS

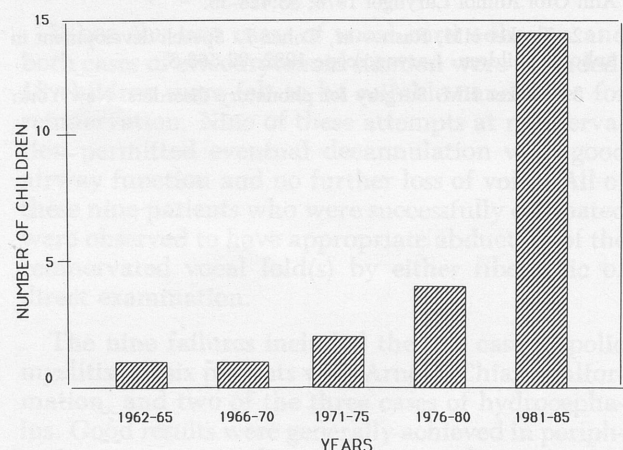
The charts of all children who were diagnosed as having vocal cord paralyses at 1 year of age or less were reviewed. The patients were diagnosed and treated at either Texas Children's Hospital or Jefferson Davis Hospital, Houston, from 1962 to 1985.

When possible, either the patient or treating physician was contacted by telephone in an effort to determine the long-term outcome. Resolution was defined as vocal cord movement confirmed at endoscopy.

RESULTS

There were 22 children 1 year of age or younger who were diagnosed as having vocal cord paralyses. Fourteen of the children were diagnosed in the last 5 years (Figure). The Table summarizes the data for the patients in this series, seven of whom were female, 15 male.

There was a slight predominance of bilateral paralysis (12 patients) over unilateral paralysis (ten patients). In the bilateral paralysis group, the vocal cord position was noted to be median or paramedian in ten patients and unspecified in the other two patients. Eight of the patients with unilateral paralysis were noted to have the vocal cords in the median or paramedian position, and again, the posi-



Distribution of patients by year of diagnosis.

From the Department of Otorhinolaryngology and Communicative Sciences, Baylor College of Medicine, Houston.

Presented at the meeting of the American Laryngological Association, Palm Beach, Florida, May 4-5, 1986.

REPRINTS — Robert H. Miller, MD, Dept of Otorhinolaryngology and Communicative Sciences, One Baylor Plaza, Houston, TX 77030.

SUMMARY OF PATIENT DATA

Patient No.	Sex	Cause of Paralysis	Side	Onset	Therapy	Outcome
1	M	Surgery	L	Postoperative	None	LTF
2	M	Surgery	L	Postoperative	None	LTF
3	M	Surgery	R	Postoperative	None	LTF
4	M	Surgery	L	Postoperative	None	Died
5	F	ACM	B	2 mo	T/S	18 mo*
6	F	ACM	B	3 mo	T/S	20 mo†
7	M	ACM	B	Birth	T/S	9 mo*
8	M	ACM	B	Birth	S/D	18 mo*
9	M	ACM	L	Birth	S	1 wk*
10	F	Encephalocele	B	1 mo	T/S	6 mo*
11	F	Birth trauma	B	Birth	T	12 mo†
12	M	Birth trauma	B	Birth	T	8 mo†
13	M	Birth trauma	B	Birth	T	LTF
14	M	Birth trauma	B	Birth	T	6 mo*
15	M	Birth trauma	R	Birth	None	1 wk*
16	M	Idiopathic	B	Birth	T	5 yr*
17	F	Idiopathic	B	Birth	T	6 mo*
18	M	Idiopathic	R	2 wk	None	1 mo*
19	M	Idiopathic	R	Birth	None	3 yr†
20	F	Idiopathic	L	Birth	None	1 mo†
21	M	Idiopathic	R	Birth	None	LTF
22	F	Syphilis	B	Birth	T	2 mo†

ACM — Arnold-Chiari malformation, B — bilateral, D — posterior fossa decompression, LTF — lost to follow-up, S — shunt, T — tracheotomy.

*Resolved.

†Unresolved.

tion in two patients was not noted. In the unilateral paralysis group, the right side was affected in five cases, with an equal number of patients with left side involvement.

Stridor, the most common symptom, was present in all 12 of the patients with bilateral paralyses, but in only seven of the patients with unilateral paralyses. Four of the patients with unilateral paralyses had hoarseness, which was not present in any of the patients with bilateral paralyses. Cyanosis was more common in the bilateral group (five of 12 patients) than in the unilateral group (two of ten patients), but choking was equally common in the two groups (two unilateral patients and three bilateral patients).

There were six patients whose vocal cord paralyses were due to congenital neurological malformations. Arnold-Chiari malformation (ACM) with associated meningomyelocele and hydrocephalus was present in five, and one was related to an occipital encephalocele and hydrocephalus. Five of these paralyses were bilateral, and one was unilateral. The onset of the symptoms (and presumably the paralysis) was at birth in three of the patients, while the other patients with congenital neurological lesions developed symptoms 1, 2, and 3 months after birth.

In six of the patients, no cause of the paralysis could be determined. There were no associated findings; four of these patients had unilateral paralyses, while the other two paralyses were bilateral. The onset of symptoms was at birth in five patients and at 2 weeks in one.

Birth trauma was the presumed cause of paralysis in five patients. The specific cause was prenatal anoxia in two patients, difficult forceps delivery in one, breech birth in one, and shoulder dystocia in one, the only unilateral paralysis in this group. The latter patient was also noted to have upper extremity weakness, while seizure disorders and other CNS deficits were noted in two of the other patients. In all cases, the onset of symptoms was at birth.

Four of the patients developed vocal cord paralyses following a surgical procedure. All of the paralyses were unilateral, and the onset was immediately postoperatively in all cases. Three of the patients underwent repair of a congenital cardiac defect, and one developed symptoms following parathyroidectomy.

One patient who was noted to have bilateral vocal cord paralysis at birth had congenital syphilis. She also had snuffles, and no other cause for the paralysis was found.

Tracheotomy was not required for any of the patients with unilateral paralysis. Eleven of the 12 patients who had bilateral paralysis underwent tracheotomy for airway distress. Three patients (all with bilateral paralysis) had pharyngoesophageal incoordination severe enough to require gastrostomy. Two of these three patients as well as one other underwent fundoplication for gastroesophageal reflux. All six of the patients with hydrocephalus underwent shunt placement (frequently multiple times for shunt malfunction).

Five of the patients with congenital neurological malformations and hydrocephalus have had return

of movement, one at 1 week, one at 6 months, another at 9 months, and two at 18 months. Their shunts were performed at 1, 2, 3, 12, and 16 weeks of age. One patient who was shunted at 8 weeks of age had not developed any movement 20 months later.

Three of the patients whose vocal cord paralyses were due to surgery were lost to follow-up, and the fourth died of unrelated causes. Of the patients whose paralysis was secondary to birth trauma, two developed movement at 1 week and 6 months, two had no movement at 8 and 12 months, and one was lost to follow-up. Three of the patients with unknown causes of paralyses developed movement at 1 month, 6 months, and 5 years, while two have no movement 1 month and 3 years after diagnosis. One was lost to follow-up. The one patient with congenital syphilis had no return of function at 2 months of age despite appropriate therapy.

DISCUSSION

One of the striking findings in this study is the distribution of the cases over the years included in the review. Although the charts of a 25-year period were examined, 66% of the cases were diagnosed in the last 5 years. One possible explanation for this finding would be poor medical records. However, the medical records departments at both institutions are quite good, and we have not seen a similar distribution when we have reviewed the charts of patients with other diseases. Another possible explanation is that a number of these children would have died from their associated anomalies in previous years when advanced neonatal intensive care units were not available.

One factor that appears to have increased the incidence of diagnosis of vocal cord paralysis is the use of the flexible laryngoscope. The flexible laryngoscope allows a prolonged view of the larynx in an atraumatic setting. Although it does not replace the Jackson laryngoscope, the fiberoptic scope does allow a panoramic view of the supraglottic and glottic areas without interfering with laryngeal movement, as can happen during direct laryngoscopy. One other advantage is that pediatricians seem less likely to empirically diagnose laryngomalacia in a child with noisy respiration and are more willing for the child to be examined when they know that the procedure can be performed atraumatically under topical anesthetic at the bedside.

There was a marked male predominance in this series, which both Cohen et al² and Holinger et al⁶ found in their series. More than half of the patients in this series had bilateral paralysis, also a finding made by Cohen et al⁸ and Holinger and Brown.¹ There was an even distribution of right and left cord involvement in the unilateral paralysis group. Cavanagh⁷ and Cohen et al² found a right predominance, whereas Holinger and Brown¹ found that over 70% of patients with unilateral paralysis had

left cord involvement. We do not have an explanation for these findings.

As has been noted by other authors, the causes of vocal cord paralysis are quite different in young children when compared to adults. Whereas surgery and neoplasms are the most common causes in adults,¹⁰ our series demonstrates the high incidence of paralysis secondary to ACM. Only four of the 20 cases in this series were caused by surgery. This is actually quite remarkable when one considers how many Texas Children's Hospital patients undergo surgery for congenital cardiac anomalies. Two of the five cases of birth trauma could be termed neurological because the paralysis was felt to be secondary to anoxic brain injury during delivery. This experience is somewhat different from that of Cohen et al,² as they reported in one series that the etiology was idiopathic in over 80% of their cases.

Syphilis was believed to cause the paralysis in one of the patients in this series. Specific reference to syphilis as the cause of vocal cord paralysis has not been made since Cavanagh⁷ quoted Bloch and Lemoine's 1936 paper¹¹ describing a child with vocal cord paralysis and congenital syphilis. Cavanagh also mentioned a case of congenital syphilis reported by Hussy in 1905.¹²

Sometimes the cause of vocal cord paralysis in infants is readily apparent, for example, ACM with associated meningomyelocele. The cause may also be elusive, as evidenced by the number of undiagnosed cases in our series and others. A systematic approach to uncovering the cause is warranted, beginning with a thorough history and physical examination. Particular attention should be given to complications in labor and delivery. In our group of children the delivery was complicated in more than half the births. Cohen et al likewise found that 35% of the children in his series had complicated deliveries, usually due to abnormal presentation of the infant.⁸ Head trauma, hypoxia, and shoulder dystocia are mechanisms that should be considered when evaluating these infants. Plain chest radiographs will aid in excluding the possibility of intrathoracic anomalies. A barium swallow study is essential to determine associated pharyngoesophageal dysfunction and gastroesophageal reflux, and it may be diagnostic in many congenital vascular disorders. Because of the high percentage of neurological abnormalities in these patients, enhanced computed tomography (particularly of the posterior fossa) to search for intracranial disorders is recommended. Magnetic resonance imaging may prove to be the test of choice in the future, but none of the patients in this series underwent this examination. Consultation with the pediatric neurologists is also recommended, as they frequently can find additional subtle neurological findings that may aid in making the diagnosis.

Treatment is determined by several factors, including the type of paralysis (unilateral or bilateral), the degree of respiratory obstruction, and to a lesser extent, the cause of the vocal cord paralysis. Experience has shown that in some children with hydrocephalus, CSF shunting results in resolution of the laryngeal paralysis.⁵ Moreover, shunt malfunction is often heralded by the onset of stridor and vocal cord paralysis, as was the case in one patient in the series. In our series, the six patients with hydrocephalus were shunted from 1 to 16 weeks of age. Five resolved (within 2 years), and one has been followed 20 months without resolution. Although the number of patients is small, there does not appear to be any correlation with the timing of the shunt and success in our series. The precise mechanism of vocal cord paralysis in these children remains unclear, but various theories have been proposed in the literature including brain stem dysgenesis, mechanical compression, or stretching of the vagus nerve, with or without resultant neuronal degeneration and circulatory impairment of the brain stem.¹³

The role of posterior fossa decompression in treating children with hindbrain malformations and vocal cord paralysis is promising. Wickramasinghe et al¹⁴ and Hoffman et al¹⁵ have discussed their results of posterior fossa decompression when signs of progressive brain stem dysfunction or apnea attacks

were manifested. Their combined series showed that 21 of 29 patients were permanently relieved of symptoms. They advocate posterior fossa decompression at the first sign of brain stem dysfunction, stating that if decompression is delayed too long, neurological recovery will not occur. One patient in our series underwent posterior fossa decompression at 20 months of age and had complete resolution of the paralysis.

Tracheotomy is usually required in infants with bilateral paralysis. In this series, tracheotomy was necessary to relieve respiratory obstruction in 11 of 12 patients with bilateral vocal cord paralysis. In two patients with hydrocephalus, tracheotomy was initially deferred in anticipation that the problem would resolve after shunting. One eventually required tracheotomy, and the other improved with shunting and posterior fossa decompression. If there is any doubt about the airway, it is far better to perform tracheotomy electively rather than wait until it is urgently required.

Our studies support the findings of Cohen et al that conservative therapy is appropriate in these patients.⁸ Overall, the prognosis for recovery in neonates and infants is reasonably good. In this series, ten of the 16 patients for whom follow-up data are available had resolution of the paralysis.

REFERENCES

1. Holinger PH, Brown WT. Congenital webs, cysts, laryngeal and other anomalies of the larynx. *Ann Otol Rhinol Laryngol* 1967; 76:744-52.
2. Cohen SR, Eavey RD, Desmond MS, May BC. Endoscopy and tracheotomy in the neonatal period. A 10-year review. *Ann Otol Rhinol Laryngol* 1977; 86:577-83.
3. Graham MD. Bilateral vocal cord paralysis associated with meningocele and the Arnold-Chiari malformation. *Laryngoscope* 1963; 73:85-92.
4. Gacek RR. Hereditary abductor vocal cord paralysis. *Ann Otol Rhinol Laryngol* 1976; 85:90-3.
5. Bluestone CD, Delorme AN, Samuelson GH. Airway obstruction due to vocal cord paralysis in infants with hydrocephalus and meningocele. *Ann Otol Rhinol Laryngol* 1972; 81:778-83.
6. Holinger LD, Holinger PC, Holinger PH. Etiology of bilateral abductor vocal cord paralysis. A review of 389 cases. *Ann Otol Rhinol Laryngol* 1976; 85:428-36.
7. Cavanagh F. Vocal palsies in children. *J Laryngol Otol* 1955; 69:399-418.
8. Cohen SR, Geller KA, Birns JW, Thompson JW. Laryngeal paralysis in children: a long-term retrospective study. *Ann Otol Rhinol Laryngol* 1982; 91:417-24.
9. Fearon B, Ellis D. The management of long term airway problems in infants and children. *Ann Otol Rhinol Laryngol* 1971; 80:669-77.
10. Woodson GE, Miller RH. The timing of surgical intervention in vocal cord paralysis. *Otolaryngol Head Neck Surg* 1981; 89:264-7.
11. Bloch A, Lemoine J. Apparition d'une paralysie des dilateurs chez un nourrisson de 6 mois. *Ann Oto-Laryngol* 1936; 1:427.
12. Hussy A. Lahmung der Glottiserweiterer im fruhen Kindesalter. *Jahrb Kinderheilkd* 1905; 61:4-84.
13. Holinger PC, Holinger LD, Reichert TJ, Holinger PH. Respiratory obstruction and apnea in infants with bilateral abductor vocal cord paralysis, meningocele, hydrocephalus, and Arnold-Chiari malformation. *J Pediatr* 1978; 92:368-73.
14. Wickramasinghe SF, Eckstein HB, Nixon HH. Posterior fossa decompression in shunt-treated hydrocephalic children. *Dev Med Child Neurol [Suppl]* 1968 (suppl 15):11-3.
15. Hoffman JH, Hendrick EB, Humphreys RP. Manifestations and management of Arnold-Chiari malformation in patients with meningocele. *Childs Brain* 1975; 1:255-95.

RISK FACTORS FOR NEONATAL ACQUIRED SUBGLOTTIC STENOSIS

STEVEN K. DANKLE, MD

DAVID E. SCHULLER, MD

RICHARD E. MCCLEAD, MD

COLUMBUS, OHIO

Endotracheal intubation has proven to be a relatively safe and effective means of securing the airway in neonates. Some concern remains, however, regarding airway management in critically ill infants who require assisted ventilation for extended periods. Among the various risk factors associated with the complication of acquired subglottic stenosis in neonates, the one most frequently cited has been "prolonged" intubation, although opinion varies regarding the definition of this term. Various recommendations exist that attempt to establish the limits of "safe" periods of intubation for infants. Some feel that tracheotomy is indicated when airway support is required beyond those limits. In an attempt to define important risk factors involved in the development of neonatal subglottic stenosis, a retrospective analysis of infants admitted to the Neonatal Intensive Care Unit of Columbus Children's Hospital who required intubation during a 3-year period from 1977 to 1980 was undertaken. Of 343 infants who survived hospitalization, five patients were identified as having acquired subglottic stenosis. The average duration of intubation for these five patients was 56.2 days. The incidence of subglottic stenosis for infants whose duration of intubation ranged from 3 to 50 days was 0.4% (1/245). Infants with birth weights less than 1,500 g appeared more susceptible to the development of intubation-related laryngeal injury. The conclusion of this study is that endotracheal intubation is an appropriate means of long-term airway management in neonates hospitalized in a pediatric intensive care unit, providing other known risk factors are minimized.

KEY WORDS — acquired subglottic stenosis, endotracheal intubation, respiratory distress.

INTRODUCTION

Few would argue against the use of endotracheal intubation as the initial means of airway stabilization in the neonate with respiratory distress, but its use over protracted periods is controversial. Irreversible subglottic stenosis is a well-recognized complication of intubation. Although several risk factors for the development of this complication have been proposed, the one most commonly cited is prolonged intubation. There is, however, no consensus of opinion regarding the definition of this term, and various recommendations exist that attempt to define the limits for "safe" periods of intubation. Many authors advise tracheotomy when ventilatory assistance is required beyond those limits.¹⁻³

Infant respiratory distress syndrome (IRDS) is the most common indication for ventilatory support in the neonate. Premature infants with birth weights less than 1,500 g appear to be particularly susceptible to this disorder.⁴ Mechanical ventilation has played a major role in the successful management of IRDS. In the majority of cases, endotracheal intubation is the safest and most expedient method of securing the airway in an infant experiencing respiratory distress. It has in fact been argued that all neonates with birth weights of 1,500 g or less should be immediately intubated at birth as an elective procedure, as opposed to therapeutic intubation after hypoxia becomes evident.⁵ Unfortunately, the pathophysiologic mechanisms responsible for IRDS are

often slow to resolve and may result in chronic pulmonary insufficiency. Frequently this will necessitate long-term ventilatory assistance, in some cases for many weeks.

The purpose of this study was to identify risk factors in the development of subglottic stenosis following endotracheal intubation of neonates. A specific goal was to assess the relationship between duration of intubation and the incidence of acquired subglottic stenosis. This was accomplished by a retrospective analysis of infants admitted to the neonatal intensive care unit who had survived various periods of intubation.

SUBJECTS AND METHODS

There were 508 patients admitted to the neonatal intensive care unit during a 3-year period from Jan 1, 1977, to Dec 31, 1980, who required endotracheal intubation. The study population consisted of 343 intubated infants who survived. No deaths were directly attributable to complications of intubation.

The majority of intubations were performed by pediatric residents, staff neonatologists, or pediatricians in outlying hospitals prior to transfer to Columbus Children's Hospital. Noncuffed polyvinyl chloride tubes were used exclusively, with tube sizes ranging from 2.0 to 4.0 mm. The oral route of intubation was used 98% (334/343) of the time, and the tubes were stabilized with a Logan bow and tape. In addition, elbow restraints were frequently applied. All

From the Departments of Otolaryngology (Dankle, Schuller) and Pediatrics (McClead), Columbus Children's Hospital and Ohio State University, Columbus.

Presented at the meeting of the American Laryngological Association, Palm Beach, Florida, May 4-5, 1986.

REPRINTS — David E. Schuller, MD, Dept of Otolaryngology, Rm 4100, 456 Clinic Dr, Columbus, OH 43210.

TABLE 1. INCIDENCE OF RISK FACTORS IN INFANTS DEVELOPING SIGNIFICANT SUBGLOTTIC STENOSIS (N = 5)

Duration of intubation	18-83 d
Birth weight	820-2,680 g
Multiple intubations	
2 intubations	2 pts
3 intubations	3 pts
Premature	4 pts
IRDS	5 pts

patients were provided with constant skilled nursing care with frequent suctioning. Endotracheal tubes were not routinely changed unless accidental extubation or obstruction by mucous plugs occurred.

The following variables were recorded for each study patient: age on admission, admitting diagnosis, birth weight, and maternal or infant-related antenatal or perinatal complications. Both the procedure and the period of intubation were characterized in terms of endotracheal tube size, difficulty of intubation, multiple intubations, and duration of intubations. All postextubation complications and their corresponding treatments were identified.

RESULTS

Among the study population of 343 infants, five patients were identified as having acquired subglottic stenosis following intubation. As indicated earlier, the intent of this study was to identify the important risk factors involved in the development of subglottic stenosis. The birth weights and duration of intubations for the five patients in this study who had severe acquired stenosis are shown in Table 1. Only one of these patients was intubated for less than 50 days, and that same patient was the only one of the group with a birth weight greater than 1,500 g. A comparison of all patients who were successfully extubated and those who developed stenosis severe enough to require tracheotomy is given in Table 2. The notable differences between these two subpopulations included birth weight, duration of intubation, and multiple intubations.

An analysis of the relationship between duration of intubation and the incidence of significant acquired subglottic stenosis is shown in Table 3. These results clearly demonstrate an increased risk of developing subglottic stenosis after 50 days of intubation. Conversely, acquired stenosis was a rare event when the duration of intubation was less than 50 days.

DISCUSSION

The data from the individual study parameters mentioned in the Subjects and Methods section has already been reported.⁶ In this previous publication, the majority of patients were less than 24 hours of age at the time of admission. Gestational ages were not routinely available, but 62% were identified as preterm. The admitting diagnosis was IRDS in 81%

TABLE 2. RISK FACTOR ANALYSIS

Risk Factor	Patients Successfully Extubated (N = 334)	Patients with Acquired Subglottic Stenosis (N = 5)
Av duration of intubation	7.8 d	56.2 d
Av birth weight	2,281.9 g	1,409.4 g
≥ 3 intubations	18/334 (5.3%)	3/5 (60%)
Antenatal problems	131/334 (39.0%)	4/5 (80%)
Traumatic intubation	31/334 (9.2%)	1/5 (20%)

of the study population. Other diagnoses were neonatal sepsis, perinatal asphyxia, and meconium aspiration among others. The average birth weight was 2,272 g with a range of 650 to 5,695 g. Antenatal or perinatal complications were noted in 39%. Technically difficult intubations were infrequent (10%). Endotracheal tube sizes and the average corresponding birth weights are listed in Table 4. Multiple intubations occurred in 34%.

The duration of intubation ranged from 1 to 104 days with a mean of 9.15 days. The overall incidence of acquired subglottic stenosis severe enough to require tracheotomy was 1.5% (5/343). There were additional tracheotomies performed in anticipation of the need for long-term respiratory support, but these infants had no evidence of subglottic stenosis at the time of surgery.

Airway management in patients requiring mechanical ventilation involves endotracheal intubation or tracheotomy. The relative merits of both methods have been argued for many years, particularly as they apply to children. The introduction of the polyvinyl chloride tube as well as improved techniques of mechanical ventilation have significantly reduced the incidence of complication from intubation. Consequently, the use of endotracheal intubation as an adjunct to mechanical respiratory support has become popular.

Despite the widespread popularity of intubation, a potential for the complication of acquired stenosis is well recognized. It is apparent that adults are at a greater risk for the development of this complication than are infants, presumably because of the balloon cuff on tubes used for the larger airway. Accordingly, adults who require respiratory support longer than 2 weeks are frequently advised to undergo tracheotomy.

TABLE 3. DURATION OF INTUBATION AND ACQUIRED SUBGLOTTIC STENOSIS

Duration of Intubation (d)	No. of Patients	Incidence of Stenosis	
		No.	%
≥ 3	253	5	2.0
≥ 7	112	5	4.5
≥ 3, ≤ 50	245	1	0.4
≥ 7, ≤ 50	104	1	1.0
≤ 50	335	1	0.2
All patients (1-140)	343	5	1.5

TABLE 4. ENDOTRACHEAL TUBE SIZE AND CORRESPONDING BIRTH WEIGHT

Tube Size (mm)	No. of Patients	%	Av Birth Wt (g)
2.0	2	6.0	650
2.5	18	5.2	1,586
3.0	105	30.6	1,769
3.5	109	31.8	2,548
4.0	24	7.0	3,538
No information available	85	24.8	—

Acquired subglottic stenosis following intubation of infants is not well understood. While many physicians agree that neonates can tolerate intubation for greater periods than adults, it has not been well established just how long a duration of intubation is acceptable. Furthermore, several recent reports have suggested that severe intubation-related laryngeal injury in infants is higher than is commonly appreciated.⁷⁻¹⁰ Other investigators, however, maintain that the incidence of acquired stenosis from neonatal intubation is low.^{4,6,11,12}

If one defines severe laryngeal injury as that which requires tracheotomy or major surgical intervention to correct, then it appears that this complication is indeed uncommon in neonates. Several authors have reported an incidence of acquired subglottic stenosis at less than 2% in infants.^{4,6,11,12} In each of these studies, all cases of stenosis were endoscopically confirmed, and all required tracheotomy. If, however, one includes patients with endoscopically confirmed laryngeal injury who are asymptomatic or who do not require surgical intervention, the incidence of complication will be higher.^{9,10}

A number of risk factors involved in the development of intubation-related laryngeal pathology have been addressed in other studies.^{4,7-15} These risk factors are listed in Table 5. This list excludes a number of risk factors that were important in the past but which have now been eliminated. For example, red rubber endotracheal tubes, which caused significant laryngeal injury, have been replaced by the less reactive polyvinyl chloride tubes. Currently used tubes are of uniform diameter as opposed to the Cole tubes, which tapered down in size as one progressed along the tube from distal to proximal. The tapered design has been felt to increase the risk of laryngeal trauma when used over prolonged periods.⁴ Also, endotracheal tubes are no longer reused, as it has been found that toxic residues are formed when polyvinyl chloride tubes are exposed to the ethylene oxide gas used for reesterilization.⁴

The most common underlying disease associated with acquired subglottic stenosis is IRDS, which is occasionally referred to as hyaline membrane disease. Hawkins⁴ has published an extensive review of this disorder from the perspective of an otolaryngologist. A separate clinical pattern of IRDS has also been seen in infants with little or no hyaline membrane disease and is thought to be related to prema-

TABLE 5. FACTORS INCREASING RISK OF NEONATAL ACQUIRED SUBGLOTTIC STENOSIS

Underlying systemic disease
Low birth weight ($\leq 1,500$ g)
Endotracheal tube size
Piston action of ventilatory circuit, tube motion
Traumatic intubation
Multiple intubations
Infection
Duration of intubation

turity.¹⁶ Chronic lung disease with poor pulmonary compliance may follow in either situation and is labeled bronchopulmonary dysplasia or chronic pulmonary insufficiency of prematurity depending on the antecedent clinical pattern. The pathophysiology responsible for these two forms of chronic lung disease in infants is not known, but may be related to the combination of oxygen, positive pressure, duration, and immature pulmonary status.

The severity of chronic lung disease may have an important role in the development of acquired subglottic stenosis in neonates. Poorly compliant lungs frequently require long-term mechanical ventilation at high peak airway pressures in order to maintain oxygenation. It is possible that air leaks around appropriately selected tubes will lead some to switch to the next larger tube size in order to maintain desirable peak pressures in this situation. The trade-off is improved oxygenation for a much greater chance of mucosal injury with tight-fitting tubes.

The use of excessively large endotracheal tubes will certainly increase the risk of subglottic stenosis. Guidelines for endotracheal tube sizes in children are often based on the age of the patient.¹⁷ In newborn infants, more accurate predictions of appropriate tube size may be based on body weight (Table 4). The absence of an audible air leak during mechanical ventilation is indicative of an excessively large tube. Large tubes may also exaggerate the amount of injury that may result from tube motion transmitted from the ventilator. A significant amount of tube motion can be controlled by careful stabilization with tape and by the application of elbow restraints to prevent self-extubation.

Low birth weight ($\leq 1,500$ g) appears to be a very important determinant of susceptibility to acquired subglottic stenosis. This has been noted by other investigators as well.¹² There are two possible explanations for this, with the obvious one being related to the small size and more delicate structure of the airway. Another is the relationship between very low birth weight and pulmonary immaturity with its associated need for ventilatory support.

Traumatic intubation has been previously cited as a risk factor for subglottic stenosis, although it was an infrequent problem in this study.^{14,15} It is possible that technically difficult intubations are poorly documented in hospital records. However,

one would expect that, if indeed traumatic intubation were a major cause of irreversible laryngeal injury, this complication might be seen more frequently with shorter durations of intubation. On the other hand, the need for multiple intubations was an important factor in this study, therefore suggesting that the trauma of repeated intubation may play a role in the development of subglottic stenosis. It should be noted, though, that multiple intubations are seen more frequently with longer durations of intubation, and therefore the relative significance of this factor is not clear. In any event, it is apparent that a policy of routine tube changes at predetermined time intervals is not necessary, providing sufficient humidification and intensive nursing care is available. Occasionally mucous plugs or self-extubations will necessitate the replacement of an endotracheal tube. However, the majority of reintubations seen at Columbus Children's Hospital are required because of failed extubation.⁶

The importance of infection as it relates to acquired subglottic stenosis is not entirely clear. Previous studies from this institution have supported the use of nasotracheal intubation in croup and epiglottitis, as it has been shown to be associated with fewer severe complications than tracheotomy.¹⁸ Subglottic stenosis following short-term intubation in these settings has been infrequent. Local and chronic infection following traumatic mucosal injury may, however, play a secondary role in the process of scar formation in the larynx.^{1,14}

The factor most frequently implicated as playing a major role in the development of acquired subglottic stenosis in the neonate has been labeled prolonged intubation. Opinions vary, however, regarding the definition of this term. Prior to the use of polyvinyl chloride tubes, the incidence of intubation-related stenosis was found to be quite high after 72 hours.¹³ In 1980, Conner and associates¹¹ reported an incidence of acquired stenosis of 0.7% (1/134) for surviving infants who required intubation for 72 hours or longer. In our study, the incidence of subglottic stenosis after 3 or more days of intubation was 2.0%. If one additionally excludes patients intubated for greater than 50 days, the incidence of stenosis was 0.4% (Table 3).

Fan and associates¹⁰ reported their prospective study of risk factors for neonatal acquired laryngeal injury in 1983 and found duration of intubation of 7 days or more to be significant. In that study, postintubation injury was found in 94%, with 9% described as having major injury. It should be noted, however, that no mention is made of the need for surgical intervention as treatment of these complications. In contrast, clinically significant stenosis was defined as the need for tracheotomy in patients who no longer needed ventilatory support in this study from Columbus Children's Hospital. While the incidence of stenosis in all infants intubated for

7 days or more was 4.5% (5/112), if one excludes those intubated more than 50 days, the incidence drops to 1% (1/104).

Ratner and Whitfield¹² reported an incidence of acquired stenosis of 1% in 1,767 surviving infants who had been intubated. In that study, the mean age at which subglottic stenosis was first clinically suspected was 7.6 weeks. Those results correspond to the findings in this study, as the average duration of intubation for infants diagnosed as having subglottic stenosis was 56 days. It is inevitable that some physicians recommend that the endotracheal tube be exchanged for tracheotomy when ventilatory support is required beyond a specified period in an attempt to avoid the complication of subglottic stenosis. Pickard and Oropeza¹ advised tracheotomy in infants who would require respiratory assistance beyond 12 to 24 hours. There is clearly no support for this recommendation at present. Gibson and Byrne² advised that tracheotomy be performed at 72 hours if ventilation were necessary beyond that time. Heroy and associates³ recommended that tracheotomy be performed when ventilatory support was required beyond 7 days.

The results of this study indicate that duration of intubation is not as important a risk factor for the development of acquired subglottic stenosis in neonates as was previously thought. It is apparent that infants can tolerate endotracheal intubation for many weeks with little risk of laryngeal injury, providing other factors are minimized by intensive medical and nursing care. While the risk of severe complications from tracheotomy in the neonate has been reduced significantly, it is still a formidable procedure in a small infant. Therefore, performing tracheotomies in newborn infants solely on the basis of prolonged intubation is not recommended.

Tracheotomy at Columbus Children's Hospital is performed for those infants who no longer require ventilation yet repeatedly fail attempts at extubation. With the introduction of the anterior cricoid split procedure, it is possible that even those infants who fail extubation may be spared a tracheotomy.¹⁹ It is, however, not exactly clear how long conservation management of acquired airway stenosis should be tried before a physician needs to intervene surgically. The earlier report from this institution demonstrated that not all cases of failed extubation because of airway obstruction require surgery.⁶ Some may be treated by reintubation and steroids with subsequent successful extubation. Others may remain extubated and be managed by cool mist, oxygen, etc. Therefore, the indications for surgical intervention in cases of intubation-related laryngeal injury, be it tracheotomy or anterior cricoid split, need further study.

CONCLUSIONS

1. Risk factors identified in recent literature as be-

ing involved in the development of acquired subglottic stenosis in neonates have included infection, underlying pulmonary and systemic disease, low birth weight, endotracheal tube size, traumatic intubation, multiple intubations, duration of intubation, and ventilator-transmitted tube motion.

2. This study has identified low birth weight, multiple intubations, and duration of intubation beyond 50 days as important factors associated with intubation-related laryngeal stenosis in infants.
3. The decision to replace endotracheal intubation with tracheotomy should not be based solely on duration of intubation in the neonate.

REFERENCES

1. Pickard RE, Oropeza G. Tracheotomy in premature infants. *Laryngoscope* 1971; 81:418-22.
2. Gibson R, Byrne JET. Tracheotomy in neonates. *Laryngoscope* 1972; 82:643-50.
3. Heroy JH, MacDonald MG, Mazzi E, Risemberg HM. Airway management in the premature infant. *Ann Otol Rhinol Laryngol* 1978; 87:53-9.
4. Hawkins DB. Hyaline membrane disease of the neonate. Prolonged intubation in management: effects on the larynx. *Laryngoscope* 1978; 88:210-24.
5. Drew JH. Immediate intubation at birth of the very-low-birth-weight infant. Effect on survival. *Am J Dis Child* 1982; 136:207-10.
6. Dankle SK, Schuller DE, McClead RE. Prolonged intubation of the neonate. *Arch Otolaryngol* 1986 (in press).
7. Papsidero MJ, Pashley NRT. Acquired stenosis of the upper airway in neonates. An increasing problem. *Ann Otol Rhinol Laryngol* 1980; 89:512-14.
8. Jones R, Bodnar A, Roan Y, Johnson D. Subglottic stenosis in newborn intensive care unit graduates. *Am J Dis Child* 1981; 135:367-8.
9. Fan LL, Flynn JW, Pathak DR, Madden WA. Predictive value of stridor in detecting laryngeal injury in extubated neonates. *Crit Care Med* 1982; 10:453-5.
10. Fan LL, Flynn JW, Pathak DR. Risk factors predicting laryngeal injury in intubated neonates. *Crit Care Med* 1983; 11:431-3.
11. Conner GH, Bushey MJ, Maisels MJ. Prolonged orotracheal intubation in the newborn. *Ann Otol Rhinol Laryngol* 1980; 89:459-61.
12. Ratner I, Whitfield J. Acquired subglottic stenosis in the very-low-birth-weight infant. *Am J Dis Child* 1983; 137:40-3.
13. Fearon B, MacDonald RE, Smith C, Mitchell D. Airway problems in children following prolonged endotracheal intubation. *Ann Otol Rhinol Laryngol* 1966; 75:975-86.
14. Strong RM, Passy V. Endotracheal intubation. Complications in neonates. *Arch Otolaryngol* 1977; 103:329-35.
15. Parkin JL, Stevens MH, Jung AL. Acquired and congenital subglottic stenosis in the infant. *Ann Otol Rhinol Laryngol* 1976; 85:573-81.
16. Krauss A, Klain D, Auld P. Chronic pulmonary insufficiency of prematurity. *Pediatrics* 1975; 55:55-8.
17. Abbott TR. Complications of prolonged nasotracheal intubation in children. *Br J Anaesth* 1968; 40:347-52.
18. Schuller DE, Birk HG. Safety of intubation in croup and epiglottitis: eight-year follow-up. *Laryngoscope* 1975; 85:33-46.
19. Cotton RT, Seid AB. Management of the extubation problem in the premature child. Anterior cricoid split as an alternative to tracheotomy. *Ann Otol Rhinol Laryngol* 1980; 89:508-11.

THREE-YEAR EXPERIENCE OF TREATING RECURRENT RESPIRATORY PAPILLOMA WITH INTERFERON

RODNEY P. LUSK, MD

ST LOUIS, MISSOURI

BRIAN F. MCCABE, MD

IOWA CITY, IOWA

JANIS H. MIXON, RN

IOWA CITY, IOWA

This paper presents the 3-year follow-up of the original 19 patients with recurrent respiratory papilloma treated with exogenous alpha human leukocyte interferon (α -IFN) at the University of Iowa. Two patients were dropped from the study because of poor patient compliance, and one was lost to follow-up. After approximately 1 year of α -IFN treatment, five patients were clear, and the rest continued to have disease: seven mild, two moderate, and two severe. A second course of α -IFN was administered to eight patients, all of whom had a decrease in the volume of the papilloma. The reduction in anatomic distribution was variable. During the observation period all patients either cleared (50%), improved (25%), or continued with severe disease (25%). In summary, the response of recurrent respiratory papilloma to α -IFN therapy is dramatic in some patients and slight in others.

KEY WORDS — interferon, recurrent respiratory papilloma.

INTRODUCTION

Recurrent respiratory papilloma (RRP) has been termed the most common benign proliferative lesion of the pediatric larynx.¹⁻³ Although there are only 1,500 new cases diagnosed each year,⁴ the morbidity and potential mortality are significant in those affected. The severity of the disease fluctuates, and recurrence is the rule.⁵

Therapeutic goals are directed toward airway maintenance and vocal function. Both surgical and medical treatments have had limited success in controlling the disease. Surgical ablation of papilloma with biopsy forceps, cryotherapy,⁶ diathermy,⁷ electrofulguration,⁷ ultrasound,⁸ and, most recently, the carbon dioxide laser⁵ may maintain the airway for a variable length of time. The poor surgical cure rates prompted chemotherapeutic trials with hormones,^{9,10} steroids,¹¹ podophyllin,¹² antibiotics,¹³ antimetabolites,¹⁴ and cytotoxic drugs.¹⁴ These medical treatments have also had little long-term success.

A substantial body of information now indicates that RRP is caused by a viral infection. The likely cause is several varieties of the human papovavirus.¹⁵⁻²⁴ The recognition that RRP was caused by a virus started the search for an antiviral therapeutic agent. Alpha human leukocyte interferon (α -IFN) has known antiviral and antiproliferative properties. In 1981, Hagland et al²⁵ reported encouraging results in controlling RRP with α -IFN. One year later, Goepfert et al²⁶ reported similar findings. Both pilot studies used α -IFN prepared in Finland. McCabe and Clark²⁷ reported additional encouraging results in a third pilot study using a similar

α -IFN prepared by another source, the New York Blood Center, Inc. However, long-term follow-up of these patients has not been available.

This report will focus on a 3-year follow-up of the 17 patients reported in the Iowa study.²⁷ The effect on the anatomic and volumetric distribution of the papilloma will be discussed.

METHODS

Seventeen patients were enrolled in the original pilot study. All patients required endoscopy more frequently than once every 3 months and had biopsy-proven papilloma. The papilloma was superficially removed with the CO₂ laser to maintain the airway throughout the study period. Endoscopy was performed at 3- to 4-month intervals in all the patients treated at Iowa. Seven of the patients were treated at collaborating institutions.

The patients were treated with partially purified (specific activity greater than 1 million units/mg of protein) human leukocyte alpha interferon from the New York Blood Center, Inc, and stored frozen until reconstituted for injection. The units were defined as the logarithm of the reciprocal dilution required to give 50% cytopathology of cells in culture (WISH amnion cells) when challenged with a vesicular stomatitis virus, Indiana strain. The assay is standardized against a reference α -interferon standard provided by the National Institutes of Health. Two patients (Nos. 9 and 14) were given α -IFN prepared by Schering during the second phase of their treatment. This preparation is an α -IFN produced by recombinant DNA technology.

From the Department of Otolaryngology-Head and Neck Surgery, University of Iowa, Iowa City (McCabe, Mixon). Dr Lusk is now at the Department of Pediatric Otolaryngology, Children's Hospital at Washington University Medical Center, St Louis.

Presented at the meeting of the American Laryngological Association, Palm Beach, Florida, May 4-5, 1986.

REPRINTS — Rodney P. Lusk, MD, Dept of Pediatric Otolaryngology, St Louis Children's Hospital, Washington University, 400 S Kingshighway, St Louis, MO 63110.

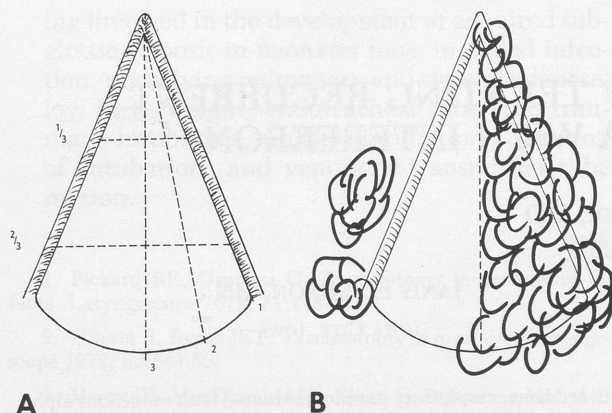


Fig 1. Diagnostic representation of true vocal cords. A) Transverse lines divide airway into thirds. Anteroposterior lines represent midline and half distance between midline and true vocal cord, respectively. B) Anatomic distribution of 8/12, or severe disease, and volumetric distribution of 3.

All patients were treated with an initial dose of 3 million units of α -IFN injected intramuscularly three times a week by family members. The original treatment period ranged from 52 to 72 weeks and was followed by a variable observation period. Those patients who progressed to severe disease during observation were given a second course of α -IFN, 5 million units/m² on Mondays, Wednesdays, and Fridays. All lesions were biopsy-proven RRP prior to the second course of therapy.

Potential toxicity was monitored throughout the study with a complete blood cell count (CBC) with differential, platelet count, serum glutamic-oxaloacetic transaminase (SGOT), lactic dehydrogenase (LDH), gamaglutamyl transaminase (GGT), vital signs, weight, and height as outlined in the original report.²⁷ Toxicity was defined as a drop in the WBC count below 4,000/ μ L, platelet count below 75,000, or SGOT greater than 100 IU/L.

Findings at the time of endoscopy were documented with drawings, photographs, and written descriptions of the anatomic distribution of the papilloma. During the second treatment period, a scoring system was used to measure both anatomic and volumetric distribution of the papilloma. The anatomic scoring system was applied retrospectively to the first treatment period.

The anatomic scoring system concentrates on the larynx and divides each true and false vocal cord into three equal segments (Fig 1A). A circumferential lesion involving both true and false cords would have 12 positive anatomic sites. If only one true cord was involved, three anatomic sites would be involved. One additional point was given for involvement of the posterior commissure. Disease extending out of the larynx and into the trachea or lungs was defined as severe disease. Involvement of greater than eight twelfths, or two thirds of the larynx, was also considered severe disease. Moderate

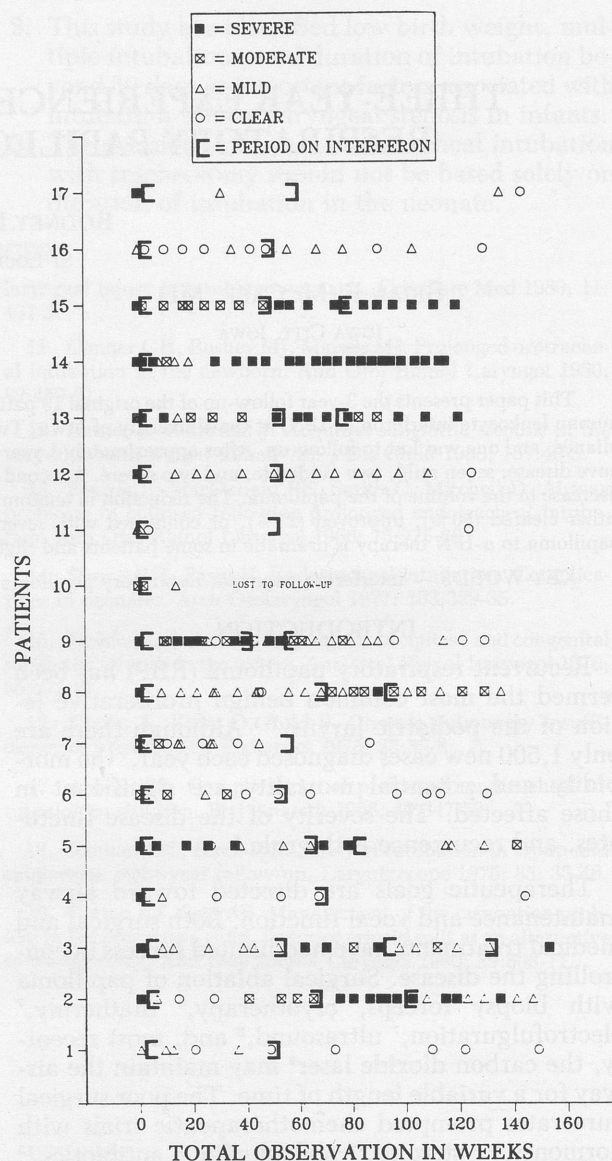


Fig 2. Anatomic severity at time of endoscopy. Frequency of endoscopy can be seen on x axis. Endoscopies performed when patient is on interferon are enclosed in brackets.

disease was defined as greater than four twelfths but less than eight twelfths, or between one third and two thirds of the larynx. Mild disease was defined as involvement of less than four twelfths, or one third of the larynx.

A system for estimating the volume of laryngeal papilloma occluding the glottic airway was devised by dividing the right and left halves of the glottis into three equal parts. If the papilloma covers only the vocal cords, with minimal extension into the lumen, a value of 1 is assigned. If the papilloma extends to the midline, a value of 3 is assigned. Intermediate extension is assigned a value of 2. The volume occupied by the papilloma is calculated by adding the value of the anterior two thirds of the glottis to the posterior one third of the glottis and dividing by two. The two halves are then added to-

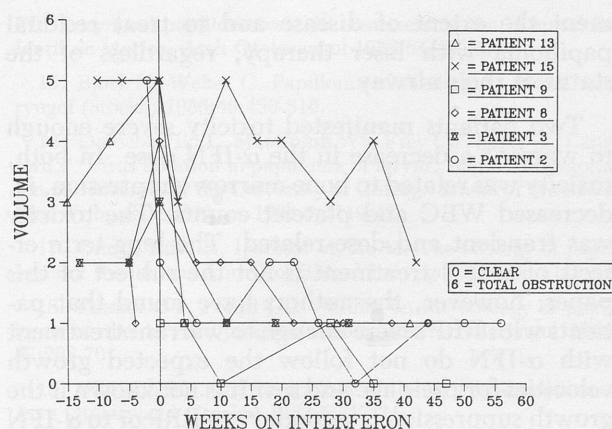


Fig 3. Area of glottis occluded by papilloma during second course of interferon. Ordinate (volume) is arbitrary unit used to characterize degree of airway occlusion. 6 — total occlusion, 3 — 50% occlusion.

gether to arrive at a total score for volume of the papilloma. Total occlusion of the airway would result in a value of 6, while obstruction of half of the airway, regardless of site, would be assigned a value of 3.

The anatomic distribution is classified as mild, moderate, or severe disease, while the degree of laryngeal obstruction caused by the papilloma is assigned a value of 0 to 6. An example lesion and score are depicted in Fig 1B. The numbering system of the patients used in this report is the same used in the original article.²⁷

RESULTS

Ten of the original 17 patients were followed throughout their entire course at the University of Iowa. One of the original 17 patients was lost to follow-up. She was recently located, and her physician noted recurrence requiring frequent endoscopy.

At the end of the initial treatment period, five patients were clear of disease by microlaryngoscopy, seven continued to have mild disease, two had moderate disease, and two had severe disease. The anatomic distribution and frequency of endoscopy of the patients is noted in Fig 2. At the end of the initial treatment period, two of the 17 patients showed no decrease in the anatomic distribution of the papilloma.

Four of the five patients (Nos. 1, 4, 6, 11) who were clear of disease at the end of the first treatment period remained clear of disease. Patient 16 had a mild recurrence during the observation period but subsequently underwent spontaneous resolution and remains clear.

Of the seven patients (Nos. 3, 5, 7, 8, 9, 12, 17) with mild disease at the end of the first treatment period, three (Nos. 7, 12, 17) underwent disease resolution, possibly as a result of their tumor load being reduced to a point where antibodies could deal with what remained, and the remaining four patients (Nos. 3, 5, 8, 9) continued with or pro-

gressed to severe disease. The four patients with disease progression responded to a second course of α -IFN therapy. One of these patients (No. 9) cleared during treatment; three (Nos. 3, 5, 8) improved to mild to moderate disease. Patient 3 finished the second course of therapy and continues with severe disease.

Two patients (Nos. 2, 15) progressed from moderate to severe disease and when treated with a second course of α -IFN continued to have moderate to severe disease. The two patients (Nos. 13, 14) with severe disease did not respond to a second course of α -IFN therapy.

A total of eight patients were treated with a second course of α -IFN at a dose of 5 million units/m². Seven of these patients were followed throughout their course at Iowa. The response of these patients to the second course of therapy (Fig 2) was variable. Four continued to have severe disease, one moderate disease, and two mild disease, and one patient actually underwent resolution for a short period of time.

The system described for evaluating the bulk of the laryngeal papilloma in the glottis was used to evaluate the response of the seven patients followed exclusively at Iowa. This system was not applied to the first treatment period because it would have been retrospective and lacking in validity. There was a reduction in the volume of papilloma during the second treatment course, and the individual results are shown in Fig 3. The average decrease in the score of these seven patients was 2.6, or almost half the area of the glottis.

Two patients manifested possible α -IFN toxicity. Patient 3 had a persistently low platelet count, and patient 15 had a low WBC count. The toxicity was transient and dose-related.

DISCUSSION

This paper reports the long-term follow-up of the 17 patients enrolled in the α -IFN study at Iowa. It was designed to be a pilot study and has all the shortcomings common in phase-I studies. The controls were the patients themselves during the initial observation period, the numbers were small, and statistical analysis was difficult. However, several trends are noteworthy and provide impressions which warrant careful evaluation in other clinical trials.

The authors agree with reports in the literature⁵ that the CO₂ laser is an important treatment modality for maintaining a patent airway. The laser was used to debulk the papillomatous tissue, with care not to invade the underlying normal tissue.

Two key areas should be considered we feel in reporting the effect of α -IFN on papilloma growth. One is the change in anatomic distribution of the

papillomas, and the other is the change in bulk or volume of the papilloma occluding the glottic airway. The latter is closely related to the degree of airway obstruction. The scoring system presented here attempts to quantify the anatomic distribution and volume of the papilloma in the airway.

There is a reduction in the anatomic distribution of the papilloma in most patients treated with α -IFN. The response is variable and not predictable. It is interesting to note that all but one patient (No. 16, who ultimately cleared) either cleared or progressed to severe disease after the first course of α -IFN therapy. The patients who cleared during treatment remained clear. Patients who continued to have moderate or severe disease during the initial treatment had little or no response to the second trial of α -IFN. It was impossible to predict the disease course during observation or the second treatment period in those patients with a partial (mild) response. No general relationship was noted between the initial severity of the disease and the ultimate response.

The volume of laryngeal papilloma, occluding the airway, decreased in all but one patient (No. 15) treated with α -IFN. The numbers available for analysis were small, and the analysis was used only in patients treated with a second course of α -IFN. Patient 15 had an initial reduction and then a significant increase in the volume of laryngeal papilloma. The increase in papilloma volume corresponded to a reduction in the α -IFN dose, necessary because of an unacceptably low WBC count.

The interval between endoscopies decreased during the treatment periods (Fig 2). It is difficult to assess how long some of the patients could have gone without endoscopy, because most patients underwent endoscopy at 3-month intervals to docu-

ment the extent of disease and to treat residual papilloma with laser therapy, regardless of the status of their airway.

Two patients manifested toxicity severe enough to warrant a decrease in the α -IFN dose. In both, toxicity was related to bone marrow suppression, ie, decreased WBC and platelet counts. The toxicity was transient and dose-related. The long-term effects of α -IFN treatment is not the subject of this paper; however, the authors have found that patients with RRP severe enough to warrant treatment with α -IFN do not follow the expected growth velocities for their age and sex. It is not known if the growth suppression is secondary to RRP or to α -IFN therapy.

In summary, the response of RRP to α -IFN therapy is mixed, but generally positive. Five of the 17 patients studied were clear at the end of the first course of treatment. One of these patients had recurrence but then cleared without additional treatment. Three additional patients cleared during observation and another is clear during the second course of treatment. In all, 50% of the children cleared during 3 years of evaluation. Most of the children in the study had severe disease. Thirty-six percent of the children with severe disease cleared. Of the nine remaining children, one was lost to follow-up during the observation period, and eight remain on α -IFN. Of the eight patients currently on or who have completed a second course of α -IFN, one is clear, two have mild, one has moderate, and four continue to have severe disease.

There are two multicenter trials currently evaluating the effectiveness of α -IFN therapy in treating RRP. It is hoped that their results will further elucidate the effectiveness of α -IFN as a therapeutic modality.

ACKNOWLEDGMENTS — The authors thank Dr Kenneth Grundfast, Children's Hospital National Medical Center, Washington, DC; Dr Francis LeJeune, Oshner Medical Hospital and Charity Hospital, New Orleans; and Dr Hollis Reed, Tulane University Hospital, New Orleans, for their referrals and assistance in following some of these patients.

REFERENCES

1. MacKenzie M. Essays on growths in the larynx with reports of an analysis of one hundred consecutive cases treated by the author. Philadelphia: Lindsay & Blakiston, 1871.
2. Clark JP. Papilloma of the larynx in children: a further consideration of the subject. *Trans Am Laryngol Assoc* 1980; 283-99.
3. Quick CA, Behrens HW, Brinton-Darnell M, Good RA. Treatment of papillomatosis of the larynx with transfer factor. *Ann Otol Rhinol Laryngol* 1975;84:607-13.
4. Jackson C, Coates GM. The nose, throat and ear and their diseases. Philadelphia: WB Saunders, 1929:5.
5. Strong MS, Vaughan CW, Healy GB, Cooperband SR, Clemente MACP. Recurrent respiratory papillomatosis: management with the CO₂ laser. *Ann Otol Rhinol Laryngol* 1976;85: 508-16.
6. Purtilo DT, Walsh GP, Storrs EE, Banks IS. The impact of cool temperature on transformation of human and armadillo lymphocytes as related to leprosy. *Nature* 1974;248:450-2.
7. Majoros M, Parkill E, Divine K. Papilloma of the larynx in children: a clinicopathologic study. *Am J Surg* 1964;108:470-5.
8. Bircik HG, Manhart HE. Ultrasound for juvenile laryngeal papillomatosis. *Arch Otolaryngol* 1963;77:603-8.
9. Broyles EN. Treatment of laryngeal papilloma in children with estrogenic hormone: preliminary report. *Bull Johns Hopkins Hosp* 1940;66:319-22.
10. Szpunar J. Treatment of papillomatosis of the larynx in children. *Acta Otolaryngol (Stockh)* 1957;47:369-74.
11. Silverblatt BL. The use of antibiotic-steroid combinations as nebulizing agents in the treatment of laryngeal conditions: a preliminary report. *Laryngoscope* 1958;68:1081-6.
12. Hollingsworth JB, Kohlmoos HW, McNaught RC. Treatment of juvenile papilloma of the larynx with resin of podophyllum: a preliminary report. *Arch Otolaryngol* 1950; 52:82-7.
13. Holinger PH, Johnston KC, Anison GC. Papilloma of the larynx: a review of 109 cases with a preliminary report of aureomycin therapy. *Ann Otol Rhinol Laryngol* 1950;59:547-64.
14. DelVillar R, Echeverria E, DeAcosta V, Dibildox JC, Diaz

- FL. Laryngeal papillomatosis: its treatment at the Hospital Infantil de Mexico. *Arch Otolaryngol* 1956;64:480-5.
15. Bjork H, Weber C. Papilloma of the larynx. *Acta Otolaryngol* (Stockh) 1956;46:499-516.
16. Dmochowski L, MacComb WS, Frey CE, Sykes JS, Langford P. Virus isolation in papilloma of larynx. Report of symposium on leukemia at the University of Chicago School of Medicine. *Med Tribune Med News* 1964;5:1119-42.
17. Ono J, Saito H, Igarashi M, Ito M. The etiology of papilloma of the larynx. *Ann Otol Rhinol Laryngol* 1957;66:1119-42.
18. Pinsker OT, Proud GO. Studies on the etiology of papilloma of the larynx: progress report. *Arch Otolaryngol* 1958;67:268-70.
19. Ullmann EV. On the etiology of the laryngeal papilloma. *Acta Otolaryngol* (Stockh) 1923;5:317-34.
20. West RA Jr, Boggs JD, Holinger PH. Studies in tissue culture growth of laryngeal papilloma. *Acta Otolaryngol* (Stockh) 1957;48:14-5.
21. Arnold W. Tubular forms of papova viruses in human laryngeal papilloma. *Arch Otolaryngol* 1979;225:15-9.
22. Boyle WF, Riggs JL, Oshiro LS, Lennette EH. Electron microscopic identification of papova virus in laryngeal papilloma. *Laryngoscope* 1973;83:1102-8.
23. Quick CA, Faras A, Krzyzek R. The etiology of laryngeal papillomatosis. *Laryngoscope* 1978;88:1789-95.
24. Lack EE, Jenson AB, Smith HG, Healy GB, Pass F. Immuno-peroxidase localization of human papilloma virus in laryngeal papilloma. *Intervirol* 1980;14:148-54.
25. Haglund S, Lundquist P, Cantrell K, Strander H. Interferon therapy in juvenile laryngeal papillomatosis. *Arch Otolaryngol* 1981;107:327-32.
26. Goepfert H, Sessions RB, Gutterman JU, Cangir A, Dichtel WJ, Sulek M. Leukocyte interferon in patients with juvenile laryngeal papillomatosis. *Ann Otol Rhinol Laryngol* 1982;91:431-6.
27. McCabe BF, Clark KF. Interferon and laryngeal papillomatosis: the Iowa experience. *Ann Otol Rhinol Laryngol* 1983;92:2-7.

NEW TECHNIQUE OF SOFT PALATE RECONSTRUCTION USING A HYPOPHARYNGEAL MYOMUCOSAL FLAP

YASUSHI MURAKAMI, MD
SHIGEJI SAITO, MD

TAKETSUGU IKARI, MD
JO ONO, MD

TOKYO, JAPAN

Large defects of the soft palate after resection of palatal tumors interfere with normal velopharyngeal function for speech and swallowing. Prosthetic management may fail to restore satisfactory function because of inadequate oronasal separation resulting in a leak of air and fluid into the nasopharynx and nose. In order to solve this rehabilitation problem, we developed an operative method for immediate repair of the entire soft palate using a superiorly based myomucosal flap obtained from the posterior pharyngeal wall through a lateral pharyngotomy approach. The flap pedicle is tubed to line the raw oral surface and leave choanae bilaterally. Patients had successful restoration of velopharyngeal function with normal speech, swallowing, and nasal breathing.

KEY WORDS — lateral pharyngotomy, myomucosal flap, reconstruction, soft palate, velopharyngeal function.

Subtotal resection of the soft palate is defined as the removal of a major part of the palate, not including the hard palate anteriorly and the faucial pillars posterolaterally. The resulting defect produces velopharyngeal dysfunction because of the loss of separation between the oropharyngeal and nasal cavities necessary for normal speech production and swallowing.

The reconstruction of soft palate function presents a completely different challenge than defects of the hard palate present.¹ Rehabilitation of the patient can be achieved by prosthetic management,² but this may be a difficult task for the maxillofacial prosthodontist, and a satisfactory result cannot always be obtained, since a watertight fit and adherence of the prosthesis to a dynamic (rather than a static) anatomic structure is difficult. Inadequate oronasal separation leads to leakage of air and fluid into the nasal cavity, which is uncomfortable for the patient and reduces speech intelligibility.

In order to solve this problem, we have developed an operative method facilitating immediate repair of the soft palate that uses a superiorly based myomucosal flap obtained from the posterior pharyngeal wall.

INDICATION

Most of the minor salivary gland tumors of the soft palate tend to remain localized even though they may grow to a large size. They do not respond well to radiation therapy, and surgical resection is the treatment of choice. The extent of resection depends on the biological behavior and size of the tumor. Most cases of pleomorphic adenoma or well-differentiated mucoepidermoid tumor can be

treated by careful surgery preserving a portion of the palatal musculature and the mucosal lining of the nasal surface of the palate, which may allow the restoration of velopharyngeal function by simple closure of the defect. However, in patients with very large or recurrent pleomorphic adenoma or carcinoma, subtotal resection of the soft palate is indicated as a primary modality of therapy. Over the past 10 years, we have treated 11 of these tumor cases: three large primary and two recurrent pleomorphic adenomas, three adenocarcinomas, two adenoid cystic carcinomas, and one poorly differentiated mucoepidermoid tumor.

In the rehabilitation of these patients, six were treated by prosthetic restoration with unsatisfactory results because of leakage of air and fluid into the nasal cavity. The other five patients had flap reconstruction, and all of them eventually obtained excellent velopharyngeal function and normal nasal breathing. The surgically reconstructed patients included a 25-year-old woman with adenocarcinoma, a 47-year-old woman and a 63-year-old man with recurrent pleomorphic adenomas, a 48-year-old man with adenoid cystic carcinoma, and a 65-year-old man with a large primary pleomorphic adenoma.

OPERATIVE TECHNIQUE

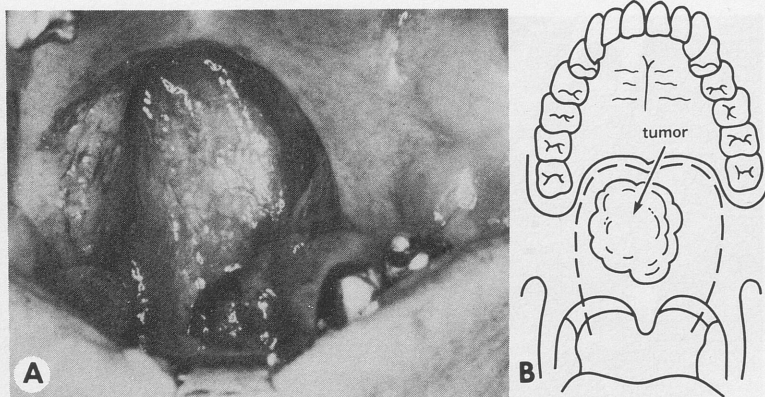
Tracheotomy. The operation is performed under general anesthesia with intubation through a tracheotomy. The tracheotomy is mandatory to facilitate approach to the posterior pharyngeal wall and to forestall the respiratory distress due to edema of the arytenoids that is observed in every patient postoperatively.

From the Department of Otolaryngology, School of Medicine, Keio University, Tokyo.

Presented at the meeting of the American Laryngological Association, Palm Beach, Florida, May 4-5, 1986.

REPRINTS — Yasushi Murakami, MD, Dept of Otolaryngology, School of Medicine, Keio University, 35 Shinanomachi, Shinjyuku-Ku, Tokyo, 160 Japan.

Fig 1. Subtotal soft palate resection. A) Large defect of soft palate after removal of recurrent pleomorphic adenoma. B) Diagram showing transection along dotted line.



Subtotal Soft Palate Resection. Anteriorly, the full thickness of the soft palate adjacent to the hard palate is horizontally transected by sharp dissection with a scalpel. Further transection extends posterolaterally along the border of the hard palate and may include a portion of the posterior maxillary alveolus, depending on the extent of the tumor. Thus, the resulting defect includes most of the soft palate (Fig 1).

Elevation of Myomucosal Flap. The hypopharyngeal cavity is exposed using a lateral pharyngotomy approach through a horizontal skin incision just below the level of the thyroid notch. For this purpose, we prefer to resect the superolateral one third of the thyroid ala and enter the cavity by a vertical incision through the anterior portion of the lateral wall of the pyriform sinus. The internal branch of the superior laryngeal nerve must be left intact. This incision provides sufficient exposure of the posterior hypopharyngeal wall extending superiorly to the oropharynx (Fig 2A).

A superiorly based myomucosal flap is designed on the posterior pharyngeal wall. The distal end of the flap is at the level of the arytenoids, and the width of the flap is that of the entire posterior pharyngeal wall (Fig 2B). At the margins of the flap, the incisions extend through both mucosal and muscular layers to the prevertebral fascia. The myomucosal flap is elevated superiorly along the underlying fascia to the oropharynx (Fig 2C). Hemorrhage from the donor alae is easily controlled by electrocautery using a bipolar hemostat. Without grafting a piece of skin to the donor defect, the hypopharyngeal cavity is closed primarily in layers with interrupted fine nylon sutures (Fig 2D). At this time the elevation of the distal two thirds of the flap is completed.

Using a transoral approach, further elevation of the flap from the posterior oropharyngeal wall is continued until the flap reaches the posterior margin of the hard palate without tension.

Palatal Reconstruction. The distal edge of the elevated flap, with the mucosal surface up, is sutured to the remaining soft tissue of the nasal surface of the hard palate. The initial suture is placed

in the midline and continued laterally using interrupted nylon sutures, closing the palatal defect with mucosa lining the nasal surface. The flap must not be sutured to the posterior faucial pillar, as the nasopharyngeal cavity is nearly completely separated from the oropharyngeal cavity, which prevents nasal breathing. The margins of the remaining flap pedicle are sutured together with four or five interrupted sutures, creating a myomucosal tube and thus providing mucosal lining for the oral side of the flap. This also creates lateral choanae for restoration of normal nasal breathing (Fig 3).

To prevent scar contraction that may result in an excessively wide choana with velopharyngeal incompetence, the remaining, rhomboid shaped, oral raw surface adjacent to the hard palate is covered with mucosa using a mucoperiosteal flap pedicled by a neurovascular bundle of the greater palatine artery and obtained from the anterior part of the hard palate (Fig 4).

A nasogastric feeding tube is inserted, and the use of a tracheal cannula eliminates the danger of airway obstruction by hemorrhage or excessive edema.

POSTOPERATIVE CARE AND FUNCTIONAL RESULT

Postoperative care is relatively simple and easy. The wound in the oral cavity must be cleaned by frequent suction of saliva and postnasal discharge. Antibiotics in adequate amounts prevent wound infection, and we have never experienced a salivary fistula in the neck. The flap heals very well without a high incidence of necrosis and dehiscence. There were no serious complications; however, all five patients developed severe edema in both arytenoids and remaining hypopharyngeal mucosa. Patients were permitted to take liquids on the tenth postoperative day; however, leakage into the nasal cavity was commonly observed. This was most likely caused by difficulty in swallowing through the narrowed and edematous hypopharyngeal cavity. The edema usually persisted for about a month postoperatively. By the end of 5 postoperative weeks, patients gradually were able to swallow foods and breathe through the nose as the edema subsided. It was not possible to remove the nasogastric feeding

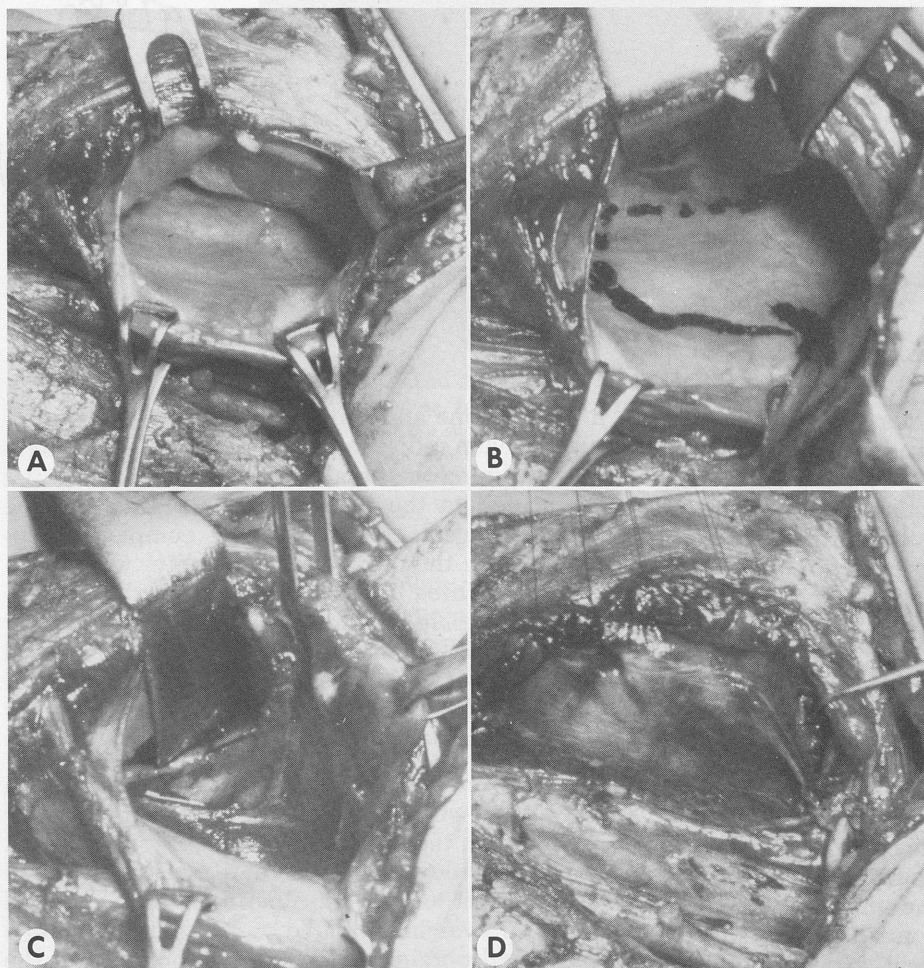


Fig 2. Elevation of myomucosal flap. A) Hypopharyngeal cavity exposed by lateral pharyngotomy, revealing marginal structures of larynx and posterior hypopharyngeal wall. B) Superiorly based flap using entire breadth of posterior hypopharyngeal wall. C) Myomucosal flap elevated along prevertebral fascia upward to oropharynx. D) Hypopharyngeal cavity closed primarily without grafting skin to donor defect.

tube and tracheal cannula until that time. Normal velopharyngeal function with excellent speech, swallowing, and nasal breathing were successfully restored at the end of 2 postoperative months and were well maintained even after the period of scar contraction (Fig 5).

The donor defect in the posterior wall crusted for a short period like the wound following tonsillectomy, but was eventually epithelialized by normal mucosa with minimal scar contracture, resulting in a sufficiently wide hypopharyngeal cavity.

DISCUSSION

A well-designed soft resin obturator that extends posteriorly from a dental prosthesis occluding the defect after subtotal resection of the soft palate may be effective for separating the oropharynx from the nasopharynx. This type of obturator is similar to that used for patients with cleft palate. The space between the obturator and the lateral and posterior pharyngeal walls allows nasal breathing but must be sealed to separate these cavities by the superior pharyngeal constrictor muscle.¹ Clinically, a watertight fit and adequate retention of the prosthesis is extremely difficult, even with cooperative consultation with the prosthodontist. This is especially true

in edentulous patients. Frequent modification and minor correction of the obturator and its parent prosthesis are mandatory for several months as healing of the defect progresses, otherwise they may cause contact ulceration of the neighboring mucosa or, conversely, result in incomplete oronasal separation. This is a very real problem for both physicians and patients.

Surgical repair of the defect is thus recommended. A small pharyngeal flap is often utilized for patients with cleft palate in association with a push-back operation.³⁻⁶ The flap obtained by the oral approach can effectively bridge a short aperture between the posterior pharyngeal wall and the soft palate, but can never be adequate for reconstruction of the entire soft palate. Larger regional flaps such as the forehead flap,⁷ the deltopectoral flap,⁸ or the cervical skin flap⁹ are available for larger defects in the oral cavity, but they are not recommended for this purpose because they are too bulky for the defect and difficult to introduce into the oral cavity. A posteriorly based midline tongue flap procedure¹⁰ may be performed in stages, but we prefer not to diminish tongue function because the use of a substantial part of the tongue may contribute to further velopharyngeal incompetence.

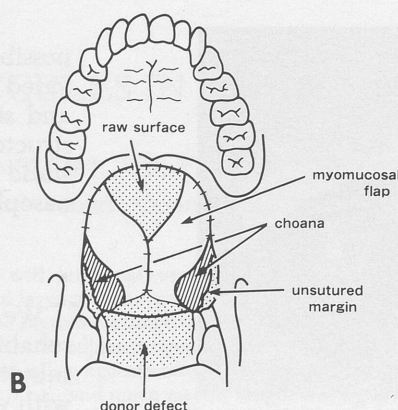
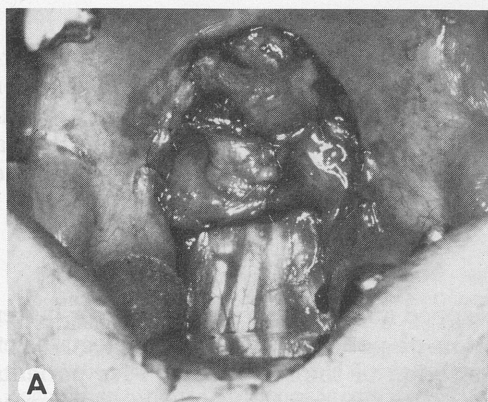


Fig 3. Palatal reconstruction. A) Flap transposed into defect and anastomosed with remaining palatal margins closing defect and providing mucosal lining of nasal surface. Remaining pedicle of flap is tubed to provide mucosal lining of oral surface and create choanae bilaterally. B) Diagram of reconstruction.

In order to resolve the problems with this surgery, we developed a new reconstructive method that uses a superiorly based myomucosal flap obtained from the posterior hypopharyngeal wall. We first used the procedure in 1980 for a patient with recurrent pleomorphic adenoma in the soft palate.¹¹ In 1982, Birt and Gruss¹² reported three successful reconstructions of the soft palate with a similar flap. They used an extended pharyngeal flap for the reconstruction of the palatal defect after commando excision of oropharyngeal cancer in combination with the pectoralis major myocutaneous flap. Harvesting the flap directly through a large wound after hemimandibulectomy, they used the flap as a flat plate and grafted a piece of meshed skin onto the entire raw surface of the flap and the donor defect. Theirs is the first report on the use of the extended pharyngeal flap, but it did not describe how they made the choana and how the patient could restore normal nasal breathing.

The flap has an abundant blood supply from branches of the ascending pharyngeal, facial, and maxillary arteries and is dependable enough to be designed as an axial pattern myomucosal flap. To obtain a large flap sufficient for reconstruction of the entire soft palate, the distal end must be at a level just behind the arytenoids and so cannot be reached by the oral approach, no matter what kind of tongue retractor is used. The width of the soft palate is almost equal to that of the posterior pharyngeal wall, and the flap must encompass the

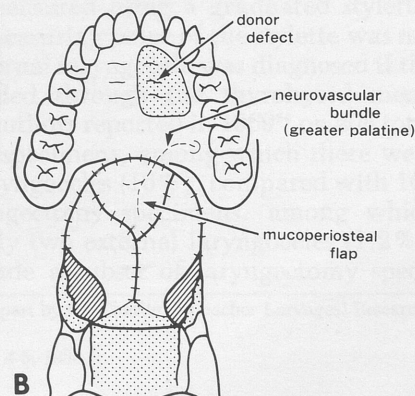
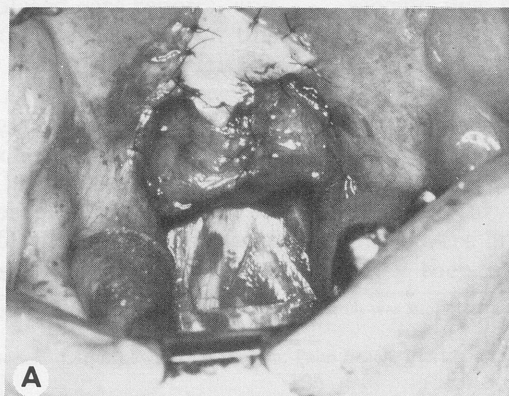
entire breadth of the posterior wall.

The donor defect may be lined with a split-thickness skin graft, but it can be re-epithelialized in a short period, thus restoring a sufficiently wide hypopharyngeal cavity with only minimum scar contraction. Complete separation of the oropharyngeal cavity from the nasopharyngeal cavity may be achieved by anastomosis of the flap with the full length of the palatal defect and may interfere with nasal breathing. For this reason, the pedicle of the flap must not be sutured to the faucial pillar, thus creating the choanae bilaterally. A mucoperiosteal flap obtained from the hard palate provides a lining for the raw surface on the oral side of the flap, which is necessary for preventing scar contraction.

The technique is relatively simple, fast, safe, and effective, and the patients receiving it can have their normal velopharyngeal functions and normal nasal breathing successfully restored. A patient with adenoid cystic carcinoma underwent postoperative radiotherapy, and the flap could tolerate a total dose of 56 Gy.

The only disadvantage of our method is the need for prolonged hospitalization. The patients cannot swallow foods until edematous swelling of the arytenoids and the remaining pharyngeal mucosa gradually diminishes by the end of 5 postoperative weeks. Nasogastric tube feeding and a tracheal cannula are thus necessary for a rather long time. It seems most likely that the difficulty in swallowing

Fig 4. Reconstructed palate. A) Raw surface of flap adjacent to hard palate covered with vascular pedicled mucoperiosteal flap. B) Diagram of reconstruction.



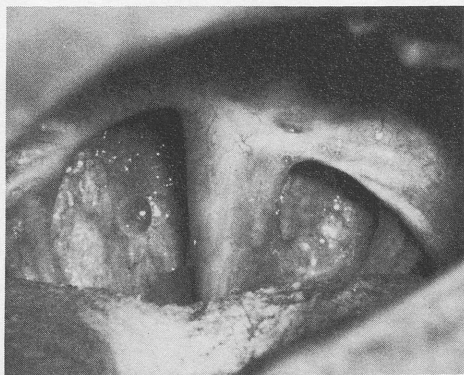


Fig 5. Ten months after operation. Sufficient velopharyngeal function with normal speech, swallowing, and nasal breathing was maintained even after period of scar contraction.

observed in these patients is mainly due to this edematous swelling and to the inability of the middle pharyngeal constrictor muscle to propel food through the pharyngeal cavity in the pharyngeal phase of normal swallowing, as the central part of the muscle forms a myomucosal flap. There is a

possibility that the flap may contain some innervated fibers of the superior pharyngeal constrictor and stylopharyngeus muscles and that the reconstructed palate may act as a dynamic rather than a static partition between the oropharyngeal and the nasopharyngeal cavities.

CONCLUSION

We developed a new operative method for better rehabilitation of patients with large defects after subtotal resection of the soft palate. Five patients with very large or recurrent pleomorphic adenomas or carcinomas of minor salivary gland origin underwent subtotal resection of the soft palate. The defect was primarily repaired using a superiorly based myomucosal flap obtained from the posterior hypopharyngeal wall by a lateral pharyngotomy. Excellent velopharyngeal functions with normal speech, swallowing, and nasal breathing were successfully restored in all patients. We conclude this method is relatively simple and effective and has many advantages over prosthetic management.

REFERENCES

1. Myers EN, Aramany MA. Rehabilitation of the oral cavity following resection of the hard and soft palate. *Trans Am Acad Ophthalmol Otolaryngol* 1977;84:941-51.
2. Aramany MA, Matalon V. Prosthetic management of post-surgical soft palate defects. *J Prosthet Dent* 1970;24:304-11.
3. Cronin TD. Method of preventing raw area on nasal surface of soft palate in push-back surgery. *Plast Reconstr Surg* 1957;20:474-9.
4. Skolnick ML, McCall GN. Velopharyngeal competence and incompetence following pharyngeal flap surgery. *Cleft Palate J* 1972;9:1-6.
5. Kaplan EN. Soft palate repair by levator muscle reconstruction and a buccal mucosal flap. *Plast Reconstr Surg* 1975;56:129-36.
6. Marsh JL, Wray RC. Speech prosthesis versus pharyngeal flap: a randomized evaluation of the management of velopharyngeal incompetency. *Plast Reconstr Surg* 1980;65:592-4.
7. McGregor IA. The temporal flap in intraoral cancer: its role in repairing the postexcisional defect. *Br J Plast Surg* 1963;16:318-35.
8. Bakamjian VY, Hoffmeister FS. Reconstructive surgery in the management of tumors of the head and neck. *New York Med J* 1963;63:301-11.
9. Bakamjian VY, Littlewood M. Cervical skin flaps for intraoral and pharyngeal repair following cancer surgery. *Br J Plast Surg* 1964;17:191-210.
10. Bracka A. The blood supply of dorsal tongue flaps. *Br J Plast Surg* 1981;34:379-84.
11. Ikari T, Murakami Y. Resection of recurrent pleomorphic adenoma in the soft palate and a primary reconstruction of the defect. Presented at the 30th meeting of the Tokyo division of the Japan Otorhinolaryngological Society, November 1980.
12. Birt BD, Gruss JS. Extended posterior wall pharyngoplasty for immediate reconstruction of the soft palate in commando excision of oropharyngeal neoplasms. *J Otolaryngol* 1982;11:116-8.

INCIDENCE OF LARGE SACCULES IN LARYNGECTOMY SPECIMENS

DEREK BIRT, MB, FRCS(C)

TORONTO, CANADA

Over 300 instances of the association of laryngocele with laryngeal carcinoma have been reported in Europe, but only seven in North America. In the present study, 353 serially sectioned total laryngectomy specimens were examined, and the saccules were measured with a steel ruler. Saccules extending superior or posterior to the thyroid cartilage were considered as large. Larynges were classified as cancer or normal, the latter being uninvaded organs from patients with adjacent disease. Among the 242 cancer larynges, there were 43 specimens where the saccule exceeded thyroid cartilage dimensions, a laryngocele rate of 17.8%. Mean saccule height was significantly greater in cancer than in normal specimens in coronal sections ($p = 0.04$), and mean saccule length was significantly greater in cancer than in normal specimens in horizontal sections ($p = 0.001$). The incidence of large saccules showed a difference between cancer and normal larynges that was highly significant ($p = 0.0002$).

KEY WORDS — laryngeal cancer, laryngocele, saccule.

INTRODUCTION

The saccule, or the appendix of the laryngeal ventricle, is present in the majority of human larynges. An abnormally enlarged saccule is termed a laryngocele, although there is disagreement over the precise definition of this term. A laryngocele may occur in an apparently otherwise normal larynx but has also been reported in association with several laryngeal disorders, particularly cancer. The European literature, notably that from France and Italy, reports over 300 instances of this latter association, while only seven are recorded in the United States. The bulk of the European cases was discovered in the course of special studies (radiographic, macroscopic, and microscopic) investigating the frequency of laryngocele in patients with laryngeal cancer. No such study has been performed in North America, and the author has, therefore, undertaken this retrospective review of serially sectioned laryngectomy specimens to ascertain whether the apparent tendency for enlarged saccules to be present in association with laryngeal cancer is peculiar to France and Italy, or may be found elsewhere by special search.

LITERATURE REVIEW

The first report of the coexistence of a laryngocele and laryngeal cancer was by Marschik in 1927.¹ Since then, there have been nearly 70 articles²⁻⁶⁸ in which the association is specifically addressed or reported. Most of them are isolated case reports, and a striking feature is the paucity of reports on this particular topic from North America. Although the association is referred to by authors from Chevalier Jackson in 1947⁶⁹ to Holinger et al in 1978,⁷⁰ the only case reports are those of Schall in 1944,⁹ the incidental finding of bilateral laryngoceles in a serially sectioned larynx with supraglottic carcinoma by Delahunty and Cherry in 1969,⁵⁵ Cassady and Mathur in 1973,⁶¹ and Canalis in 1976,⁶³ who reported

four cases of coexisting carcinoma and laryngocele and went on to analyze 64 patients culled from the world literature. The references indicate that none of these 64 patients lived in North America, and Canalis does not refer to the three earlier case reports mentioned above.

In Europe, however, several extensive investigations have been performed. As early as 1941, based on radiographic studies, Cova, in Milan,⁶ suggested that inflation of the laryngeal saccule indicated infiltration by tumor at the neck of the saccule. Meda¹⁵ in 1952 reported six cases of laryngocele among 650 cases of laryngeal cancer. In four of these, the diagnosis was on the basis of radiographs alone. Seven years later, Pietrantoni et al³⁰ enlarged the Milan series to 857 cases, in which they detected a laryngocele radiographically in 53 (six of these were cases already reported by Meda). Other reports on laryngocele and carcinoma based on radiographic studies were made from France in 1961 by Szigeti³⁵ and from Italy by Alajmo et al in 1964⁴² and Silvagni in 1965.⁴³ The most comprehensive studies to date were those of the group at the Institut Gustav-Roussy, Villejuif, France,^{41,54,56,67} which has reported on a steadily increasing number of laryngectomy specimens comparing laryngeal cancer specimens with pharyngeal cancer specimens. All specimens were recorded by drawings and photographs, and in each case the depth of the laryngeal saccule was measured using a graduated stylette. The inferior measuring point of the stylette was not given, but external laryngocele was diagnosed if the saccule extended through the thyrohyoid membrane. These authors reported in 1969⁵⁶ on 208 total laryngectomy specimens, among which there were 34 external laryngoceles (16%), compared with 162 pharyngolaryngectomy specimens, among which there were only two external laryngoceles (1.2%). They then made a subset of laryngectomy speci-

From the Department of Otolaryngology, University of Toronto. This research was supported in part by the Charlie Connacher Laryngeal Research Fund.

Presented at the meeting of the American Laryngological Association, Palm Beach, Florida, May 4-5, 1986.

TABLE 1. REPORTED INCIDENCE OF LARYNGOCELE IN LARYNGEAL CANCER POPULATION

Author	Year of Study	No. of Laryngeal Cancer Cases	Laryngocele (%)
Pietrantonio et al ³⁰	1959	857	6.20
Szigeti ³⁵	1961	512	6.10
Alajmo et al ⁴²	1964	342	9.90
Silvagni ⁴³	1965	624	4.20
Sesterhenn ⁶⁶	1977	615	0.16
Micheau et al ⁶⁷	1978	546	18.00
Grzesiakowska et al ⁶⁸	1982	626	1.90

mens by rejecting those in which they had found an external laryngocele, those in which the ventricle was obscured, or those in which they felt measurement would be difficult because of excessive destruction by tumor. This reduced the 208 specimens to 99, and these were compared with 80 pharyngolaryngectomy specimens, chosen because the tumor was confined strictly to the pyriform fossa without laryngeal invasion, according to the stylette measurements of their saccules. The mean depth for the laryngectomy group was 13.1 mm and that for the pharyngolaryngectomy group 10.2 mm. The difference of 2.9 mm was statistically significant.⁵⁶ By 1978 the numbers had increased to 546 total laryngectomy specimens, among which they found 104 laryngoceles (18%), and 360 pharyngolaryngectomy specimens, among which they found eight external laryngoceles (2%). They felt that the role of endolaryngeal cancer in the development of laryngocele was confirmed.⁶⁷

In 1977, Sesterhenn⁶⁶ in Cologne published a case report. This was apparently the first laryngocele discovered at his clinic in the course of 478 total and 133 partial laryngectomies, giving an incidence of laryngoceles of 0.16%. He stated that all laryngectomy specimens were examined histologically, but made no mention of serial sectioning. He stated, without providing definitions, that he counted only "true" laryngoceles and ignored saccules that were simply enlarged. He included a table that demonstrates various authors' reported incidence of laryngocele in the larynx cancer population. In 1982, Grzesiakowska et al⁶⁸ in Warsaw reprinted this table (without seizing the opportunity to update the Institut Gustav-Roussy material) and added 12 cases of laryngocele discovered on radiographic examination from among 626 cases of laryngeal carcinoma. With the updating mentioned above, this material is presented in Table 1.

Sesterhenn⁶⁶ reviewed the literature thoroughly^{11,18,20,36,39} and discovered 276 patients with coexisting laryngeal cancer and laryngocele. With revision and updating, the list of cases reported now numbers 336, and is ranked according to country of origin in Table 2.

The figures presented thus far in the literature suggest that the incidence of laryngocele in laryngeal cancer is approximately 60 times greater in

TABLE 2. REPORTED CASES OF LARYNGOCELE ASSOCIATED WITH LARYNGEAL CANCER

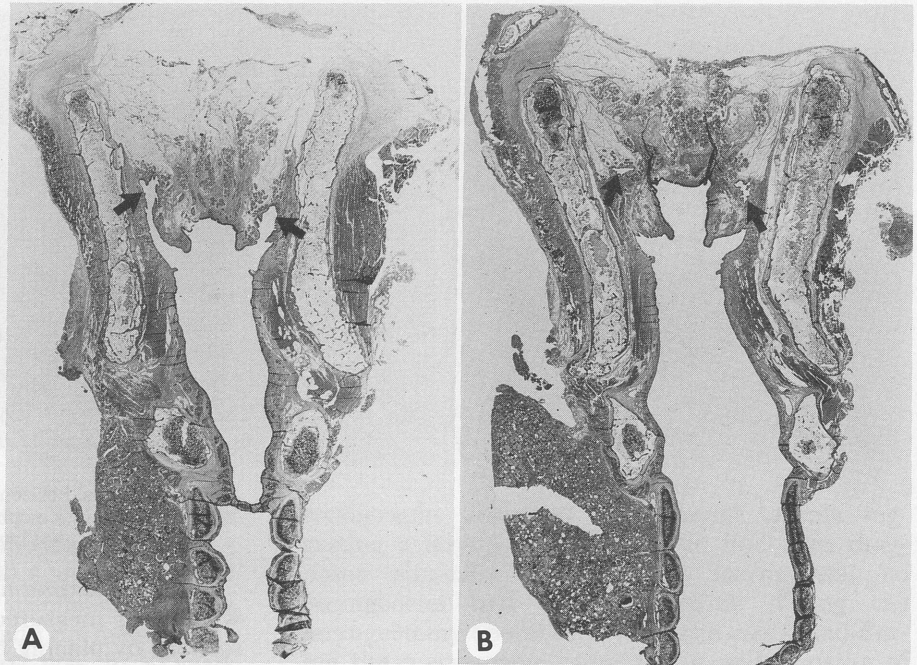
Country	No. of Cases
Italy	157
France	123
Poland	12
Uruguay	7
United States	7
Germany	5
Holland	5
Spain	5
Austria	4
England	4
Chile	2
Hungary	2
Russia	2
Belgium	1
Total	336

Italy or France than in North America. However, most of the cases in each of those countries have been found in centers that have developed protocols specifically designed to search for laryngoceles, either radiographically or by the anatomical and histologic examination of laryngectomy specimens. The author, therefore, entertained the hypothesis that a systematic search among laryngectomy specimens elsewhere would reveal hitherto unreported cases of laryngocele and, further, would confirm or contradict the French reports that in laryngeal cancer patients the measured saccule depth is significantly greater than in patients whose larynges have been removed for reasons other than intrinsic laryngeal carcinoma. This hypothesis was tested by a study undertaken at the University of Toronto Laryngeal Laboratory. The French study using a graduated stylette could not be duplicated in the absence of fresh specimens, and a retrospective study of serially sectioned larynges was performed, using a measuring technique that will be described in detail.

MATERIALS AND METHODS

The Laryngeal Laboratory houses a collection of serially sectioned larynges obtained from various hospitals within the University. Each larynx has a file recording the patient's laryngeal illness and treatment, together with a description of the specimen and a detailed report of the histologic findings. All the 495 specimens from 1966 through 1979 were reviewed by the author; eliminated from further study were 30 specimens that had been sectioned sagittally, 62 partial laryngectomy specimens, and 39 total laryngectomy specimens that had either had a previous partial laryngectomy or been rendered unsuitable for the present study by extensive biopsy harvesting prior to fixation. This study, therefore, included 353 larynges, of which 244 had been sectioned coronally and 109 horizontally. The larynx was recorded as normal if it showed no significant invasion; normal larynges had usually been removed from a patient with car-

Fig 1. Normal coronal specimen from patient with carcinoma of left pyriform fossa. A) Bilateral saccules (arrows) seen in continuity with ventricles. B) Section posterior to A but still anterior to vocal process of arytenoid. Note bilateral saccules (arrows) no longer in continuity with ventricles.



cinoma of the hypopharynx, thyroid, or trachea (Fig 1A). The other specimens were designated cancer, and all had squamous cell carcinoma or verrucous carcinoma of the larynx. Each larynx was coded under the heading "primary site" to assist data analysis and the reporting of results. Each larynx was classified in one of ten categories after review of the clinical and radiographic examination recorded prior to initial treatment, as well as the very full pathologist's report on the operation specimen (Table 3).

The dimensions of the saccule in each specimen were measured using a hand-held x8 jeweller's magnifier and a stainless steel scientific ruler graduated in half millimeters. A saccule was presumed only if it was (at least in part) lined by respiratory epithelium and goblet cells. A microscope was used if the nature of the lining epithelium was in doubt. The following measurements were made.

CORONAL SPECIMENS (FIG 2A)

Saccule Maximum Height. Saccule maximum height was the largest vertical distance found between the horizontal plane of the upper surface of the vocal cord (floor of the ventricle) and the horizontal plane of the uppermost portion of the saccule. Usually the highest point of the saccule lay posteriorly in the larynx. Anteriorly the saccule could always be found in continuity with the ventricle, but as the sections passed backward, it appeared as a separate structure, isolated in the tissue of the supraglottic larynx (Fig 1B). The saccule steadily rose within the larynx until it abruptly vanished from the sections. By thus tracing the saccule from the ventricle, by checking the epithelium with the microscope, and by observing the constantly present associated glandular tissue, there

was no difficulty in avoiding such pitfalls as misidentifying the anterior limit of the pyriform fossa as a dilated saccule.

Alar Maximum Height. Alar maximum height was always measured on the same slide as the saccule maximum height and was the distance between the horizontal plane of the upper surface of the vocal cord (floor of the ventricle) and the horizontal plane through the upper limit of the thyroid alar cartilage.

Saccule Maximum Width. The saccule maximum width was the largest distance observed where empty saccule lumen lay between the two walls, ie, without any projecting filiform fronds or infoldings of the saccule wall, and was not necessarily measured on the same slide as the saccule maximum height. The ruler was placed on each slide at right angles to the plane of measurement of maximum height and moved down over the saccule.

Saccule Maximum Length. Saccule maximum length was calculated from the number of sections

TABLE 3. DISTRIBUTION OF SPECIMENS BY PRIMARY SITE OF DISEASE

Specimen	Coronal Sections	Horizontal Sections
Normal	31	80
Glottic L	90	5
Glottic R	72	3
Glottic B	6	1
Supraglottic L	14	8
Supraglottic R	19	9
Supraglottic B	3	1
Subglottic L	3	1
Subglottic R	5	1
Subglottic B	1	0
Total	244	109
B — bilateral.		

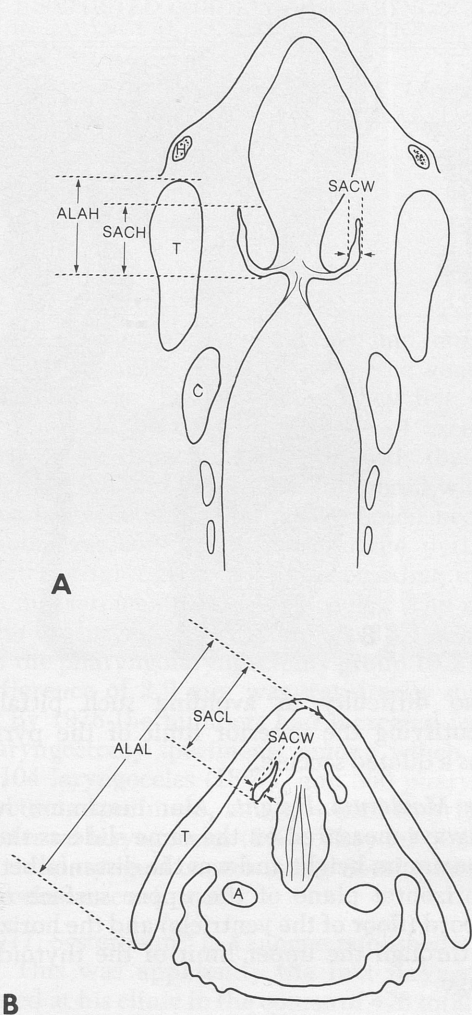


Fig 2. Diagrams showing A) saccule maximum height (SACH), saccule maximum width (SACW), and alar maximum height (ALAH) as measured in coronal specimens. B) Saccule maximum length (SACL), saccule maximum width (SACW), and alar maximum length (ALAL) as measured in horizontal sections. T — thyroid cartilage, C — cricoid cartilage, H — hyoid bone, A — arytenoid cartilage.

in which the saccule appeared. Most of the larynges had been sectioned at 2-mm intervals. If the saccule appeared in only one section, it was given a length of 1 mm. If it appeared in two sections, it was given a length of 2 mm. If it appeared in three sections, it was given a length of 4 mm, if four sections 6 mm, if five sections 8 mm, and so on. Occasionally larynges had been cut at 1-mm intervals, in which case the calculated length was adjusted accordingly. The first 61 larynges had not been cut at accurate intervals, and saccule lengths were not calculated for those.

HORIZONTAL SPECIMENS (FIG 2B)

Saccule Maximum Height. The saccule maximum height was calculated according to the number of sections in which the saccule appeared, using the same method as for the saccule length in the specimens cut coronally.

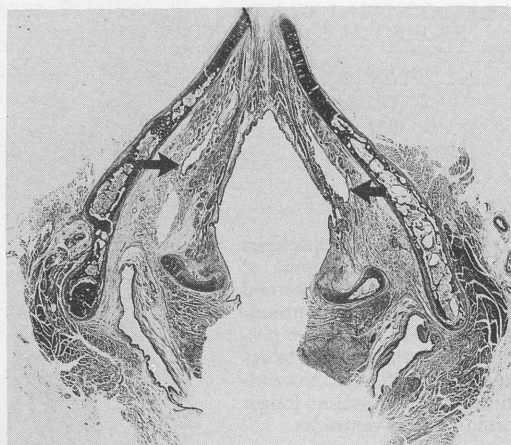


Fig 3. Normal horizontal specimen from patient with carcinoma of upper esophagus invading right pyriform fossa. Section above cord level shows bilateral saccules (arrows).

Saccule Maximum Width. The saccule maximum width was measured as was width in the coronal sections by placing the ruler over the slide at right angles to the plane of measurement of maximum saccule length and recording the greatest clear width between the two walls of the saccule.

Saccule Maximum Length. Saccule maximum length was measured in the long axis of the thyroid alar cartilage and was the greatest distance observed between two lines drawn at right angles to the alar cartilage, the first through the posterior limit of the saccule, and the other through the region of the inner aspect of the junction of the two alar cartilages anteriorly.

Alar Maximum Length. The alar maximum length was measured on the same slide as the saccule maximum length and recorded the distance between the anterior plane used for maximum saccule length and a plane through the posterior limit of the alar cartilage.

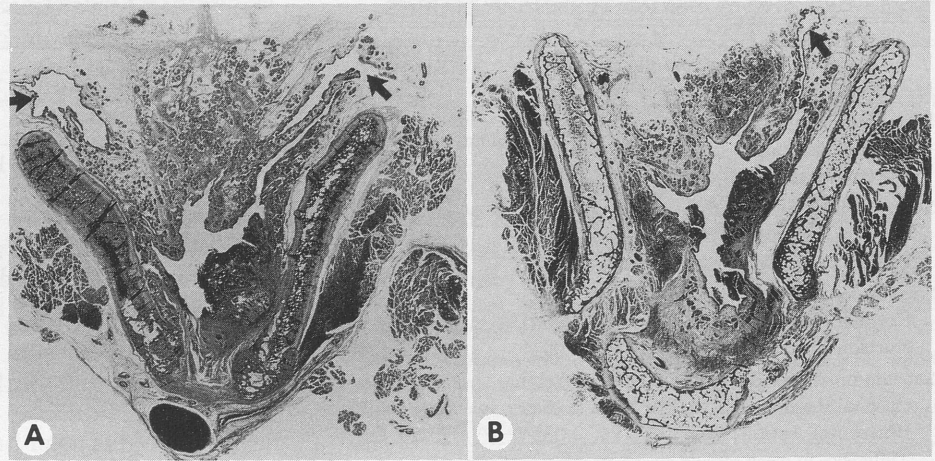
Thus it can be seen that for coronal specimens, maximum saccule height and width and alar height are direct measurements, and saccule length is calculated, while for horizontal specimens, saccule length and width and alar length are direct measurements, and the saccule height is calculated. The heights in the coronal specimens and the lengths in the horizontal specimens are not precise measurements of the saccule itself, the measurements in each case being made from an adjacent, convenient, easily identifiable point.

All measurements were recorded on a data sheet, from which they were extracted, coded where necessary, and entered into the University computer for analysis.

RESULTS

Available for study were 353 larynges, of which 244 had been sectioned coronally and 109 horizon-

Fig 4. Cancerous coronal specimens. A) Carcinoma of right vocal cord with extension to floor of ventricle and subglottis. Large bilateral saccules (arrows) were noted as laryngoceles in pathology report. B) Carcinoma of right vocal cord with subglottic extension. Right saccule (arrow) clearly exceeds alar height, but had not been recorded as laryngocele.



tally. Among coronal specimens, 222 were from men and 22 from women, and the mean age of the patients at laryngectomy was 60.4 years (range 30 to 91 years). Among horizontal specimens, 77 were from men and 32 from women, and the mean age of these patients at laryngectomy was 57.9 years (range 34 to 83 years). Among coronal sections, 213 were cancer specimens and 31 were normal, while among horizontal sections, 29 were cancer specimens and 80 were normal. The normal category included larynges showing no significant invasion, for example, those from patients with carcinoma of the hypopharynx, thyroid, or trachea (Fig 3). The distribution of the specimens with respect to the primary site of disease is given in Table 3. There were 177 glottic, 54 supraglottic, and 11 subglottic primary sites.

LARYNGOCELES

In two cases, the report on the pretreatment

tomographs described an enlarged saccule suggesting a laryngocele. No patient had been diagnosed clinically as having a laryngocele, no laryngoceles had been discovered during the laryngectomy operations, and none was found during the macroscopic examination and drawing of the specimen in the laryngeal laboratory. In 12 cancer specimens, including those showing laryngoceles by radiograph, the comprehensive final report of the pathologist mentioned the presence of a laryngocele as an incidental finding (Fig 4A). The rate at which laryngoceles in association with laryngeal carcinoma had been diagnosed in this population, therefore, was 12 out of 242, or 4.9%. None had been reported in the literature.

SACCULE MEASUREMENTS

In 19 larynges, no saccule was identified. In a further six larynges, no left saccule could be found, and in another 22, no right saccule was evident. In

TABLE 4. RESULTS OF SACCULAR AND ALAR MEASUREMENTS

Measurement	Cancer Specimens		Normal Specimens	
	Coronal Section	Horizontal Section	Coronal Section	Horizontal Section
Saccule max height				
N	180	22	30	74
Mean	9.9 mm	4.32 mm	8.32 mm	3.63 mm
Range	3.0-20.5 mm	1.0-11.0 mm	2.75-16.5 mm	1.0-14.0 mm
SD	4.07	2.7	3.29	2.31
Saccule max width				
N	180	22	30	74
Mean	1.82 mm	1.29 mm	1.51 mm	1.49 mm
Range	0.2-14.0 mm	0.25-2.25 mm	0.5-5.5 mm	0.5-3.0 mm
SD	1.53	0.53	0.93	0.58
Saccule max length				
N	146	22	10	74
Mean	4.15 mm	15.56 mm	3.15 mm	12.87 mm
Range	0.00-11.0 mm	10.5-28.5 mm	2.0-5.0 mm	8.0-21.0 mm
SD	2.25	4.0	1.1	3.04
Saccule max expressed as % of alar max*				
N	180	22	30	74
Mean	66.36%	51.61%	53.58%	41.71%
Range	15.79%-156.96%	33.42%-184.17%	22.96%-122.32%	29.39%-133.83%
SD	30.44	31.79	23.81	13.07

*Measurements in coronal sections are of maximum saccule height as % of maximum alar height. Measurements in horizontal sections are of maximum saccule length as % of maximum alar length.

TABLE 5. STATISTICAL TESTING VARIABLES

Measurements	Student's <i>t</i> Test			Wilcoxon 2 Sample Test	
	<i>t</i>	<i>df</i>	<i>p</i>	<i>z</i>	<i>p</i>
Sacculle maximum height					
Coronal sections	2.02	208	0.042*	2.046	0.041
Horizontal sections	1.18	94	0.238†		
Sacculle maximum width					
Coronal sections	1.08	208	0.283†		
Horizontal sections	1.45	94	0.147†		
Sacculle maximum length					
Coronal sections	1.39	154	0.163†		
Horizontal sections	3.38	94	0.001*	2.719	0.007
Sacculle maximum height as % of alar height					
Coronal sections	2.19	208	0.28*	2.421	0.016
Horizontal sections	2.15	94	0.032*	2.220	0.026

*Difference in mean sacculle measurements was significant.

†Difference in mean sacculle measurements was not significant.

coronal specimens, 10% of saccules from normal larynges (6/56) exceeded 15 mm in height compared with 16% in cancer specimens (59/367). The difference is not statistically significant. (Throughout this paper, statistical significance is assumed where $p < 0.05$.)

The results of the measurement of the sacculle with regard to maximum height, maximum width, and maximum length and with regard to sacculle height expressed as a percentage of the alar height (a maneuver calculated to adjust for variations in the size of the larynx such as variations due to sex) are given in Table 4. The mean measurements in the cancer group are greater than in the normal group, with the single exception of the maximum width in the horizontal sections. The difference in the mean sacculle maximum heights between cancer and normal specimens is statistically significant in coronal sections but not in horizontal sections. Differences in sacculle maximum width are not significant. The difference in the mean sacculle maximum lengths between cancer and normal specimens is statistically significant in horizontal sections but not in coronal sections. The differences in the sacculle maximum heights expressed as a percentage of alar maximum height between cancer and normal specimens in coronal sections, and in sacculle maximum lengths expressed as a percentage of alar maximum length between cancer and normal specimens in horizontal sections, are both statistically significant. The data were not normally distributed in most instances and, therefore, a nonparametric (Wilcoxon 2 sample) test was used to confirm the validity of the *t* test where significant differences were found (Table 5).

A multivariate discriminant analysis was performed on the results from those specimens for which all measurements were available. The purpose of this was to determine the percentage accuracy with which the category of the specimen (cancer versus normal) could be predicted based on the sacculle variables of maximum height, length,

TABLE 6. DISTRIBUTION OF LARGE SACCULES RELATIVE TO PRIMARY SITE

Primary Site	<i>N</i>	Larynges in Which Either or Both Saccules Exceeded Alar Dimensions		% of <i>N</i>
Normal	111	3		2.8
Glottic L	95	20		21.0
Glottic R	75	14		18.7
Glottic B	7	2		28.6
All glottic combined	177	36		20.33
Supraglottic L	22	2		7.4
Supraglottic R	28	4		14.3
Supraglottic B	4	0		0.0
All supraglottic combined	54	6		11.11
Subglottic L	4	0		0.0
Subglottic R	6	1		16.7
Subglottic B	1	0		0.0
All subglottic combined	11	1		9.99
All cancer combined	242	43		17.76
Total	353	46		

Sacculle maximum height in large saccules exceeded 100% of alar maximum height or sacculle maximum length exceeded 100% of alar maximum length.

Difference between normal and all glottic combined is highly significant ($\chi^2 = 16.648$, $df = 1$, $p = 0.0001$).

Difference between normal and all cancer combined is highly significant ($\chi^2 = 13.940$, $df = 1$, $p = 0.0002$).

Difference between normal and all supraglottic combined is not significant ($\chi^2 = 3.483$, $df = 1$, $p = 0.062$).

and width. The computer program rejected as indiscriminant the readings of length and width, while utilization of height correctly predicted cancer versus normal specimens 65% of the time. A 50% prediction would be no better than chance, while the result of 65% indicates a weak tendency toward the laryngeal sacculle having greater height in cancer specimens.

LARGE SACCULES

Further analysis was made to assess the incidence of large saccules. For this purpose, these were defined as those in which sacculle maximum height exceeded alar maximum height in coronal sections, and those in which sacculle maximum length exceeded alar maximum length in horizontal sections (Fig 4B). The distribution of these, relative to primary site, is shown in Table 6.

A χ^2 test was used to compare saccules smaller than alar dimensions with saccules exceeding alar dimensions. The difference observed between normal and glottic carcinoma specimens was highly significant, and the difference between normal and all cancer specimens combined was scarcely less significant. However, the difference between normal and supraglottic specimens did not reach statistical significance (Table 6).

The side of the larynx where large saccules were found, relative to the tumor primary site, is shown in Table 7. In 17 of these 43 specimens, the large sacculle was bilateral, being, therefore, both ipsilateral and contralateral to the tumor in each. In

TABLE 7. SIDE OF ENLARGED SACCULE WITH RESPECT TO PRIMARY SITE OF TUMOR

Saccule Enlarged	N	Tumor Ipsilateral	Tumor Contralateral	Normal
Bilateral	19	17	17	2
Left	14	9	5	0
Right	13	7	5	1
Total	46			

two instances the tumor was itself bilateral. Among the unilateral large saccules, ipsilateral enlargements slightly outnumbered contralateral enlargements.

No significant difference in the numbers of large saccules was found between patients that had been irradiated and those that had not (Table 8).

DISCUSSION

It appears that the hypothesis stated earlier has been justified. The special search mentioned has indeed revealed 12 hitherto unreported instances of laryngoceles coexisting with laryngeal cancer, a rate of 4.9%. The publication of these 12 cases would promote Canada into third place in Table 2 after the study of only 242 larynges, but the number can easily be manipulated by choosing different definitions of laryngocele. The total given here is that in which the diagnosis was recorded in the files and was made, in each instance, by the pathologist, with radiographic confirmation in two cases. On the other hand, DeSanto⁷¹ has expressed the opinion that the term laryngocele should be used only if the patient has symptoms and a lump in the neck, however large the saccule happens to be. On that basis, this study would have found no laryngoceles at all. A further alternative, giving yet another result, would be to accept that a saccule becomes a laryngocele when it exceeds the limit of the alar cartilage. There were 43 such cases here, a laryngocele rate of 17.8%. Clearly, these results would fit almost anywhere in Table 1, depending on the chosen criteria, which, in any case, have not usually been stated by the other authors represented. We do not know if these unmatched groups are truly representative of their country of origin, but one may conclude tentatively that the incidence of large saccules is broadly similar throughout the world and that any attempt to identify a "laryngocele factor," acting only in certain countries and perhaps shedding light on the pathogenesis of laryngeal cancer, would likely be fruitless.

The results of measuring the dimensions of the saccule in this study confirm the findings of Gerard-Marchant et al,⁵⁶ in that there was a significant difference in the mean maximum saccule height between larynges removed for laryngeal cancer and larynges removed for other reasons such as pharyngeal cancer. No additional information was obtained from the measurement of saccule maximum width, nor from the indirect values obtained by

TABLE 8. DISTRIBUTION OF LARGE SACCULES RELATIVE TO IRRADIATION

	N	Larynges in Which Either or Both Saccules Exceeded Alar Dimensions	% of N
Cancer specimens			
No irradiation	74	19	25.6
Irradiation	145	21	14.5
$(\chi^2 = 4.112, df = 1, \text{Fisher's Exact Test [2 Tail]} p = 0.06.)$			
Normal specimens			
No irradiation	53	0	0.0
Irradiation	45	3	6.6
$(\chi^2 = 3.645, df = 1, \text{Fisher's Exact Test [2 Tail]} p = 0.09.)$			

Difference between irradiated and nonirradiated groups is not statistically significant in either cancer or normal groups.

In 36 specimens, radiation status was not clear; these specimens were not included in Table.

counting the number of serial sections in which the saccule appeared (length in coronal sections and height in horizontal sections). However, in horizontal sections, the mean saccule maximum length was significantly greater in the cancer than in the normal specimens. It appears that saccule height in coronal specimens and saccule length in horizontal specimens are useful measurements of saccule size. Cancer and normal specimens were also significantly different when saccule height in coronal specimens and saccule length in horizontal specimens were expressed as a percentage of the alar height and length respectively. According to Scott,⁷² the ratio between alar and saccule height remains the same in smaller female, as in larger male, larynges.

The mean saccule maximum height found here in coronal specimens (cancer: 9.9 mm, normal: 8.32 mm) is less than that reported by Gerard-Marchant et al (cancer: 13.1 mm, normal: 10.2 mm). This is in spite of a possible selection factor that might have produced a tendency in the opposite direction, in that the author included all specimens, while Gerard-Marchant et al excluded any specimen in which they considered a laryngocele was present. These authors do not give their lower measuring point, but it can scarcely have been lower than the present author's choice of the plane of the upper surface of the vocal fold, while had they chosen the upper border of the ventricular recess, as did Scott,⁷² they should have had smaller, rather than greater, readings. The author's material may have shrunk during processing, although this tendency would be resisted by the rigid alar cartilage. Gerard-Marchant et al measured fresh specimens before fixation, and possibly their technique using a graduated stylette allowed each saccule to distort to a slightly greater maximum height.

The finding that 10% of saccules in normal specimens exceeded 15 mm in height is comparable to other published figures, for example 7% by Broyles,⁷³ 7.6% by Scott,⁷² 8% by Iversen,⁷⁴ and 6% by Neumann and William.⁷⁵ Although the percentage exceeding 15 mm in height among the cancer specimens was greater at 16%, the dif-

ference was not statistically significant. However, marked differences between cancer and normal specimens became evident when only large saccules, ie, those exceeding alar dimensions, were compared. This selection of large saccules as abnormal, and therefore suitable for study in this connection, harks back to Virchow's original definition of laryngocele,⁷⁶ which has been regularly supported ever since.^{72,77,78} Researchers have always compared the vertical height of the saccule to the upper border of the thyroid alar cartilage. The author has added the concept that the saccule may be considered abnormally large if it extends more posteriorly than the thyroid alar cartilage when viewed in horizontal sections. Breakdown of the counts of large saccules by primary tumor site provides an interesting point of comparison with the results of Micheau et al,⁶⁷ who found twice the frequency of laryngocele among supraglottic tumor specimens than in all cancer specimens combined, whereas almost the opposite was found here. No immediate explanation for this is apparent.

Virtually all the authors of papers on this topic address the subject of etiology. With regard to laryngocele generally, proposed mechanisms include a steadily enlarging pulsion diverticulum on the one hand, evidence for which is provided by Macfie's demonstration by radiographic techniques of asymptomatic laryngoceles in 56% of 94 bandsmen,⁷⁹ and the chance inflation of a congenitally large saccule on the other, as suggested by Stell and Maran,⁸⁰ who found that in only one out of 139 patients had the laryngocele appeared after many years in a job requiring blowing, while in two others it appeared immediately on taking up a wind instrument. Lindsay,⁸¹ after studying radiographs, had earlier concluded that supraglottic closure is tighter than glottic closure in the face of raised intratracheal pressure, thus providing a mechanism whereby the ventricle, and hence the saccule, may be exposed to raised pressure during such activities as straining, loud shouting, and glass blowing. He suggested that raised intraglottic pressure was the exciting factor in cases of laryngocele, but that "the occurrence of laryngocele in young children and females and the known occurrence of congenitally long appendices of the ventricle suggests a congenital predisposition as a basic factor."

Speculation has also been published regarding the method of development of laryngoceles in association with cancer. Marschik,¹ Cova,⁶ and Meda¹⁵ all suggested that distortion of the neck of the saccule might create a one-way valve and hence inflation of the saccule by retention of air. As Gerlings⁴⁰ points out, however, that does not explain a bilateral laryngocele with a unilateral carcinoma, where it seems easier to postulate that ventricular, and hence saccule pressure, becomes raised due to distortion in the delicate balance of true and false cord closure in the face of raised intratracheal pressure.

If laryngoceles occurred only as a result of random inflation of a congenitally large saccule, without any tendency of the saccule to be "pumped up" to a larger size, the expected finding in this study would be that there were just as many large saccules "waiting to be filled" among the normal larynges as in the cancer group. However, this was clearly not the finding, and therefore the results of this study support the opposite view, that progressive saccule enlargement results from raised ventricular pressure.

Logic, however, admits an alternate possibility, which is that carcinoma might arise preferentially in the lining epithelium of large saccules. Scott⁸² found squamous metaplasia on the ventricular folds and dysplasia on the vocal folds of randomly selected autopsy larynges, but in the saccules he found only inflammation, the degree of which did not correlate with the saccule height. Micheau et al⁶⁷ describe squamous cell carcinoma developing along, and more or less replacing, the epithelium of the laryngocele in 55 out of their 104 specimens in which carcinoma and laryngocele coexisted. The author, who is not a pathologist, does not feel he can address this point with authority in this essay. A further study, jointly with the pathologist involved, is almost complete and has included a detailed histologic examination of all the large saccules and those instances of apparent conjunction of saccule and tumor in other specimens identified in the course of the present study.

CONCLUSIONS

1. The association of laryngeal carcinoma and laryngocele is under-reported unless such cases are sought by special studies.
2. In this series of 242 laryngeal cancer specimens, 12 laryngoceles were recorded as an incidental finding by a pathologist. However, the total number of such larynges in which the saccule exceeded alar cartilage dimensions amounted to 43, or 17.8% of this sample.
3. There is a need to standardize the term laryngocele so that the reported incidence in different centers can be compared. The author recommends that Virchow's original definition, ie, that laryngocele is diagnosed where the saccule extends superior to the alar cartilage, be adopted universally. It is further recommended that a saccule extending posterior to the alar cartilage also be diagnosed as a laryngocele.
4. Mean saccule height is significantly greater in laryngeal cancer specimens than in larynges removed for other reasons when coronally sectioned specimens are measured.
5. Mean saccule length is significantly greater in laryngeal cancer specimens than in larynges removed for other reasons when horizontally sectioned specimens are measured.

6. The frequency with which the saccule exceeds alar cartilage dimensions is significantly greater in laryngeal cancer specimens than in larynges removed for other reasons.
7. These findings might best be explained on the

basis that cancer disturbs the function of true and false cord closure in the face of raised intratracheal pressure and that elevated ventricular pressure is capable, in some instances, of causing gradual inflation of the saccule.

ACKNOWLEDGMENTS — The author thanks the many surgeons who sent laryngectomy specimens to the Charlie Connacher Laryngeal Laboratory and Dr Peter van Nostrand for making the material available. Dr Peter Alberti and Dr Hugh Barber provided constructive criticism for an earlier version of this manuscript. The statistical calculations were performed by Dr John Szalai and Marko Katic in the Department of Biostatistics, Sunnybrook Medical Centre, and their expert help is acknowledged with thanks. Allison MacKay of the Banting Institute photographed many laryngeal specimens, and further assistance with illustrations was provided by the Health Sciences Media Service of Sunnybrook Medical Centre. Finally, this work would not have been ready for presentation without the speedy, accurate, and cheerful contribution of Suzi Langmuir and her word processor.

REFERENCES

1. Marschik R. Sekundäre Laryngocele bei Carcinoma laryngis [Abstract]. Zentralbl Hals-, Nas- Ohrenkrankh 1927;10: 104.
2. Ertl E. Larynxcarcinom mit sekundärer Laryngocele. Monatsschr Ohrenheilkd Laryngo-Rhinol 1932;66:115-6.
3. Zöllner F. Über das Kehlsackempyem. Beitr Anat Physiol Path Therap Ohren 1932;30:274-81.
4. Oreggia JC, Apolo E. Los laryngoceles. Ann Oto-Rino-Laryng Uruguay 1938;8:58-77.
5. Leborgne FE. Tomography and cancer of the larynx. Arch Otolaryngol 1940;31:419-25.
6. Cova PL. Sulla dimostrazione radiologica dell' appendice del ventricolo laringeo del morgagni. Radiol Med (Torino) 1941; 28:313-20.
7. Torchiana L. Laringocele e cancro della laringe. Oto-Rino-Laryngol Ital 1942;12:416-30.
8. Leborgne FE. Cancer de la laringe. Estudio Radiologico. Montevideo: Barreiro y Ramos, 1943:273.
9. Schall LA. Laryngocele — associated with cancer of the larynx. Ann Otol Rhinol Laryngol 1944;53:168-73.
10. Bonandini B. Laringocele e cancro. Osservazioni istopatologiche e cliniche. Valsalva 1946;22:105-15.
11. Caliceti P. Il carcinoma delle laringe. Atti XXXIX Congresso Soc It di Laringol, Caligari 1951: part 1.
12. Casadesus F, Capella G. Laringocele: estudio de quatro casos. Acta Oto-Rino-Laryngol Ibero-Am 1951;2:5-21.
13. Guenzi L. Rilievi anatomo-clinici sul laringocele associato al cancro della laringe. Arch Ital Laringol 1951;59:281-94.
14. Freeman J. Clinical records: three cases of infected laryngocele. J Laryngol Otol 1952;66:409-12.
15. Meda P. Symptomatic laryngocele in cancer of the larynx. Arch Otolaryngol 1952;56:512-20.
16. Cimino A. Laringocele e carcinoma laringeo. Atti Clin Oto-Rino-Laryngoiatr Univ Palermo 1953;5:205-24.
17. Novotny O. Entstehung eines Larynxkarzinoms aus einer Zyste der aryepiglottischen Falte. Monatsschr Ohrenheilkd Laryngo-Rhinol 1954;88:210-2.
18. Pagano A. Laringocele bilaterale e cancro della laringe. Arch Ital Laringol 1954; 62(suppl):57-64.
19. Mattioli V. Il laringocele. Boll Mal Orecch Gola Naso 1955;73:337-41.
20. Carimati A. Il laringocele sintomatico latente (contributo radiologico e clinico). Arch Radiol 1956;4:4.
21. Blavier A. Un cas de cancer du larynx associe a une laryngocele. Acta Oto-Rhino-Laryngol Belg 1957;11:307-12.
22. Gignoux M, Moindrot M. Cancer du larynx et laryngocele. J Fr Oto-Rhino-Laryngol 1957;6:581-5.
23. Leroux-Robert J, Rogeon A. Tumeurs laryngee et laryngoceles. Ann Oto-Laryngol 1957;74:885-903.
24. Matzker J. Über große Zysten und Zelen des Larynx- einganges und seiner Umgebung. Z Laryngol Rhinol Ihre Grenzgeb 1957;36:318-39.
25. Preobraženskij JB. Kehlkopfcarcinom, kompliziert durch doppelseitige Laryngocele [Abstract]. Zbl Hals-, Nas- Ohrenkrankh 1957;58:251.
26. Huizinga E, Stam HC. Sur la planographie dans le cancer du larynx. Acta Oto-Rhino-Laryngol Belg 1958;12:477-8.
27. Agati GL. Adagio: sopra alcuni casi di laringocele sintomatica. Ann Radiol Diagn 1959;32:464-89.
28. Guerrier Y. Les complications des laryngoceles. J Fr Oto-Rhino-Laryngol 1959;8:827-36.
29. Nucci C, Sulseni G. Laringocele e cancro. Oto-Rino-Laryngol Ital 1959;28:477-91.
30. Pietrantoni L, Felisati D, Finzi A. Laryngocele and laryngeal cancer. Ann Otol Rhinol Laryngol 1959;68:100-7.
31. Lund WS. A case of external and internal laryngocele associated with carcinoma of the larynx. J Laryngol Otol 1960;74: 260-5.
32. Gaillard J, Fontvieille J, Gaillard L. Laryngocele interne post-operatoire. J Fr Oto-Rhino-Laryngol 1961;10:265-72.
33. Giraud J-C, Moulouguet LP. Laryngocele au cours d'un cancer du larynx. J Fr Oto-Rhino-Laryngol 1961;10:747-52.
34. Wayoff M, Perrin C. Laryngocele bilaterale et cancer. J Fr Oto-Rhino-Laryngol 1961;10:599-602.
35. Szigeti B. Laryngocele et cancers pharyngo-larynges. Etude Radiologique [Thesis]. Paris, 1961.
36. Montero E, Lopez-Martinez R. Außere Laryngocele mit Klappenbildung. Ann Desarrollo 1962;10:141-51.
37. Schätzle W, Baumert U. Über die Laryngozele. Z Laryngol Rhinol Ihre Grenzgeb 1962;41:270-7.
38. Vertova F. Rilievi anatomo-radiologici sul laringoceli. Riv Radiol 1962;2:88-95.
39. Di Lauro A. Laringocele bilaterale e cancro a stampo delle laringe. Arch Ital Laringol 1963;71:241.
40. Gerlings PG. Cancer of the larynx associated with bilateral laryngocele. Acta Otolaryngol [Suppl] (Stockh) 1963 (suppl 183):55-8.
41. Markovits P, Desprez-Curely J-P, Lanneret J, Cachin Y, Richard J-M, Szigeti B. Laryngoceles et cancers du larynx et du pharyngo-larynx (confrontation anatomo-radiologique: 13 cas). Gaz Med Fr 1963;70:57-74.
42. Alajmo E, Boccuzzi V, Fini-Storchi L. Osservazioni sull'associazione cancro-laringocele. Boll Mal Orecch Gola Naso 1964;82: 671-86.
43. Silvagni C. Rilievi clinici-statistici sull'associazione tra laringocele e cancro della laringe. Valsalva 1965;41:465-79.
44. Flottes L, Riu R, Le Den R, Delpy, Le Mouel C, Laurens. Les masques cliniques des laryngoceles. J Fr Oto-Rhino-Laryngol 1966;15:531-70.
45. Jost G, Legent F, Cotin G. Un cas de laryngocele geante

- coexistent avec un epithelioma du larynx. *Ann Oto-Laryngol* 1966;83:605-7.
46. Sinzinger G. Laryngocele und Larynxcarcinom. *HNO* 1966;14:102-5.
47. Banhidy F. Laryngozele und Karzinom. *Z Laryngol Rhinol Ihre Grenzgeb* 1967;46:619-27.
48. Guerrier Y, Dejean Y. Laryngocele et cancer du larynx. *Gaz Med France* 1967;74:429-37.
49. Rossberg G, Kriegsmann B. Diagnose und Behandlung der Laryngozele. *Z Laryngol Rhinol Ihre Grenzgeb* 1967;46:49-57.
50. Rossi M, Riccioli S. Considerazioni patogenetiche su due casi di associazione cancro-laryngocele. *Clin Otorinolaringoiatr* 1967;19:484-95.
51. Birtual R. Acerca del laryngocele. *Cirug Ginec Urol* 1968;22:35-41.
52. Barcelo-Mesquida B. Laryngocele y cancer. *Acta Oto-Rino-Laringol Ibero-Am* 1969;20:442-9.
53. Black JHA. Cancer of the larynx associated with bilateral external laryngocoele. *J Laryngol Otol* 1969;83:817-25.
54. Cachin Y, Gerard-Marchant R, Micheau C. Epithelioma larynge et laryngocele. II. Une forme anatomo-clinique particuliere. A propos de 7 observations. *Ann Oto-Laryngol* 1969;86:437-42.
55. Delahunty JE, Cherry J. The laryngeal saccule. *J Laryngol Otol* 1969;83:803-15.
56. Gerard-Marchant R, Micheau C, Cachin Y. Epithelioma larynge et laryngocele. I. Etude anatomo-pathologique et statistique. *Ann Oto-Laryngol* 1969;86:431-6.
57. Talavera-Sanchez J, Segra-Coronado E, Sanchez-Hidalgo A. Asociacion laryngocele-leimiosarcoma de la cuerda vocal. *Acta Otorinolaringol Esp* 1969;20:74-85.
58. Calmet L, Fabre L, Chabriat J. Un cas de laryngocele avec cancer du larynx. *J Fr Oto-Rhino-Laryngol* 1970;19:753-6.
59. Gonzales M. Sobre un caso de laryngocele bilateral y cancer larynge. *Acta Oto-Rino-Laringol Ibero-Am* 1971;22:128-38.
60. Scolari R, Castellarin T, Bolla A. Associazione tra laryngocele e cancro larynge. *Ann Laring (Torino)* 1971;70:94-120.
61. Cassidy CL, Mathur AK. Mucocoele of the larynx as a sequel of carcinoma. *Arch Otolaryngol* 1973;98:60-2.
62. Smirnova IN. Sochetanie raka sortani s laringotsele. *Zh Ushn Nos Gorl Bolezn* 1974;89:106-8.
63. Canalis RF. Observations on the simultaneous occurrence of laryngocele and cancer. *J Otolaryngol* 1976;5:207-12.
64. Gonzalez Suarez A, Diaz Montero M, Garcia Soto N. Laryngocele y cancer. *Acta Otorrinolaryngol Esp* 1977;28:41-4.
65. Harrison DFN. Saccular mucocoele and laryngeal cancer. *Arch Otolaryngol* 1977;103:232-4.
66. Sesterhenn K. Laryngozele und Karzinom. *Laryngol Rhinol Otol (Stuttg)* 1977;56:521-8.
67. Micheau C, Luboinski B, Lanchi P, Cachin Y. Relationship between laryngoceles and laryngeal carcinomas. *Laryngoscope* 1978;88:680-8.
68. Grzesiakowska U, Buraczewski J, Dziukowa J. Laryngocele in laryngeal and pharyngeal neoplasms. *Otolaryngol Pol* 1982;36:193-8.
69. Jackson CL. Laryngocele. *Laryngoscope* 1947;57:788-95.
70. Holinger LD, Barnes DR, Smid LJ, Holinger PH. Laryngocele and saccular cysts. *Ann Otol Rhinol Laryngol* 1978;87:675-85.
71. DeSanto LW. Laryngocele, laryngeal mucocoele, large saccules and laryngeal saccular cysts: a developmental spectrum. *Laryngoscope* 1974;84:1291-6.
72. Scott GBD. A morphometric study of the laryngeal saccule and sinus. *Clin Otolaryngol* 1976;1:115-22.
73. Broyles EN. Anatomical observations concerning the laryngeal appendix. *Ann Otol Rhinol Laryngol* 1959;68:461-70.
74. Iversen PB. Sacculus laryngis. *Arch Oto-Rhino-Laryng* 1977;217:189-92.
75. Neumann OG, William H. Untersuchungen über Klinik und Ätiologie menschlicher Laryngocelen anhand von Kunststoffausgußpräparaten. *HNO* 1981;29:339-43.
76. Virchow R. Die krankhaften Geschwulste. Vol 3. Berlin: Hirschwald, 1867:35-40.
77. Keim WF, Livingstone RG. Internal laryngocele. *Ann Otol Rhinol Laryngol* 1951;60:39-50.
78. Burke EN, Golden JL. External ventricular laryngocele. *Am J Roentgenol Radium Ther Nucl Med* 1958;80:49-53.
79. Macfie DD. Asymptomatic laryngoceles in wind-instrument bandmen. *Arch Otolaryngol* 1966;83:270-5.
80. Stell PM, Maran AGD. Laryngocoele. *J Laryngol Otol* 1975;89:915-24.
81. Lindsay JR. Laryngocele ventricularis. *Ann Otol Rhinol Laryngol* 1940;49:661-73.
82. Scott GBD. A quantitative study of microscopical changes in the epithelium and subepithelial tissue of the laryngeal folds, sinus and saccule. *Clin Otolaryngol* 1976;1:257-64.

IMMUNOHISTOCHEMISTRY: HELP IN DIAGNOSIS OF HISTOLOGICALLY AMBIGUOUS LESIONS OF THE HEAD AND NECK

ROBERT C. BONE, MD

JAMES A. ROBB, MD

LA JOLLA, CALIFORNIA

Diagnostically useful antibodies have recently been combined with a glucose oxidase or peroxidase avidin-biotin assay system to provide immunologically specific information. Positive identification in situ of such entities as intracellular keratin, light chain immunoglobulins, and other selected immunologically recognizable entities is now possible. Case examples taken from material at the Scripps Clinic Medical Group during the last several years is presented. Squamous cell carcinoma, large cell lymphoma, and other lesions from the upper aerodigestive regions are included. The addition of this test to conventional, carefully performed microscopic analysis greatly enhances the ability to distinguish among quite different, but histologically similar, processes.

KEY WORDS — cancer classification, glucose oxidase avidin-biotin assay, immunochemical assay, peroxidase avidin-biotin assay.

Now, probably more than ever, the accuracy of histologic diagnosis has assumed a pivotal place in clinical medicine. Critical decisions, clinical, medicolegal, peer review, and quality assurance issues are often based to a large extent, if not entirely, on reports given to the attending physician or surgeon by the pathologist. Thus, we are reminded daily by the pathologist of the need for precise, complete information to accompany the specimen, and we often push pathologists to the limits of discernment for the last detail of information available from an admittedly tiny piece of tissue, often obtained at significant expense and difficulty.

Over the last several years, pathologists, immunologists, and immunopathologists have attempted to use the highly specific characteristics of immune binding in a clinically useful setting. With this technique, specific antigens (eg, proteins or glycoproteins) can be detected and used to classify the type of cancer with a certainty greater than that achieved with routine morphology and nonimmune special stains (Table).¹

GLUCOSE OXIDASE AVIDIN-BIOTIN (GAB) ASSAY

Based on the preceding work of Sternberger² and Hsu et al,³ one of the authors (J.A.R.) has developed an immunohistochemical test that incorporates the high specificity of monoclonal antibodies with the powerful binding affinity of avidin and biotin (one of the strongest known to occur in biochemistry).

Additionally, the avidin-biotin reaction is allowed to successively recur prior to the last phase of the reaction, so that the original site of the immune reaction is, in a sense, visibly "amplified" through creation of a molecular complex, to permit conventional microscopic identification.

The reader is referred elsewhere⁴ for a detailed biochemical description of the assay steps; however, a brief presentation follows. An appropriate cytohistochemical in situ antigen (eg, cytokeratin or CEA) is selected for determination, and a rabbit antibody is produced to create an antigen-antibody binding on the tissue section. Thereafter, a biotinylated goat antirabbit antibody combines with the test material so that the rabbit antibody, earlier bound to the tissue antigen, now also binds to the goat antirabbit antibody as well. The now localized biotin site is next available for linkage to the avidin-biotin complex via attachment to avidin sites. Finally, the lattice is colorized with tetranitroblue tetrazolium to produce a visual marker for the entire antigen-antibody avidin-biotin complex, identifiable by light microscopy.

Peroxidase avidin-biotin complex immunohistochemistry (Vector Labs) is used on formalin-fixed, paraffin-embedded tissues as previously described elsewhere⁵ to detect the presence of specific antigens. The following antibodies are used: rabbit anticallus keratin (J.A.R., 1:200), rabbit antineuroembryonic antigen (Dako, absorbed, 1:1,000), mouse anti-35BH11 cytokeratin (Enzo, ascites, 1:1,000), mouse anti-AE1 cytokeratin (Hybritech, ascites, 1:1,000), rabbit antisalivary amylase (Nordic, 1:600), rabbit antiorosomucoid (Dako, 1:100), mouse antipanleukocyte antigen (Dako, 1:10), mouse antivimentin (Dako, 1:10), rabbit anti-S100 (Dako, 1:500), and rabbit anti- α -fetoprotein (Dako, 1:100). All tissue, except that used for the vimentin assay, is pretreated with 0.1% crude porcine trypsin in pH 7.4 phosphate-buffered saline for 60 minutes at room temperature before addition of primary antisera.

From the Divisions of Head and Neck Surgery and Otolaryngology (Bone) and Anatomic Pathology (Robb), Scripps Clinic and Research Foundation, La Jolla, California.

Presented at the meeting of the American Laryngological Association, Palm Beach, Florida, May 4-5, 1986.

IMMUNOPROFILE OF CANCER TYPES

	Complex Callus	Keratins		CEA	AMY	ORO	PLC	VIM	S100	AFP
		Simple 35BH11	Simple AE1							
Carcinoma	+	+	+	+	+/-/*	+/-/*	0	0	0	0
Lymphoma	0	0	0	0	0	0	+	+	0	0
Sarcoma	0	0	0	0	0	0	0	+	0†	0
Melanoma	0	0	0	0	0	0	0	+§	+	0
Hepatoma	0	+	0	0	0	0	0	0	0	+

Callus — antibody made against callus keratin, 35BH11 — antibody made against keratin, AE1 — antibody made against simple epithelial keratin, CEA — carcinoembryonic antigen, AMY — salivary amylase, ORO — orosomucoid, PLC — panleukocyte antigen, VIM — vimentin, AFP — α -fetoprotein.

*Positive results in head and neck carcinoma support origin from salivary gland, but results have not yet been proven specific for salivary gland origin.

†S100 is positive in sarcomas of neural origin.

§About 50% of malignant melanomas are positive for vimentin.

CASE MATERIAL

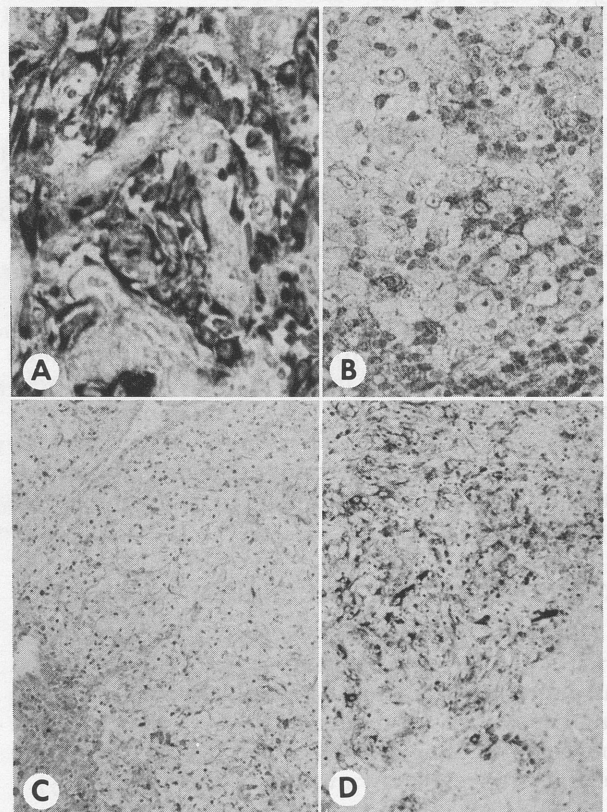
The following four cases are taken from material in the Scripps Clinic Medical Group (SCMG) files from over 2 years. They represent only head and neck disease; of course, the technique is applicable to histologic examination anywhere in the body.

Case 1. A 62-year-old man developed a chronic nonhealing ulcer on the nasal columella approximately 6 months before his examination by the SCMG in 1983. Several biopsies performed by the patient's referring physicians had demonstrated only chronic inflammation without evidence of neoplasia. However, because of clinical suspicion regarding the course of the process, a rebiopsy, which included an immunohistochemical assay, was completed as an initial evaluation. The assay established the presence of cytokeratin-containing cells deep within the connective tissue, and thereby the diagnosis of invasive squamous cell carcinoma (Figure, A). Later, at the time of complete excision, invasive carcinoma identifiable by routine histologic techniques was discovered at the base of the lesion.

Case 2. A 53-year-old woman was seen for the first time 8 weeks after the onset of a swelling in the right tonsil. She was initially treated by her internist with antibiotics for over 2 weeks with no significant improvement. She was then referred to an otolaryngologist, who noted the presence of a 2-cm mass in the superior pole of the right tonsil. Biopsy of the mass at an outside hospital was interpreted by the attending pathologist as most compatible with a poorly differentiated squamous carcinoma.

The patient then sought a second opinion at SCMG, where initial consultation confirmed the physical findings described above. Review of the already obtained tonsillar biopsy raised doubts about the validity of the original histologic diagnosis, however, and to further clarify the situation, a complete unilateral tonsillectomy on the right side was completed to obtain adequate fresh tissue for immunohistochemical diagnosis (Figure, B). The preliminary histologic report from this specimen indicated "a large cell neoplasm in which the differential diagnosis lies between a large cell lymphoma

and an undifferentiated carcinoma." Later GAB assay showed the neoplasm to be "... absolutely negative for keratin with strong staining in the overlying epidermis on two independent assays. ... In the monomorphic portions of the neoplasm, there is no cytoplasmic lambda staining, while there is strong (3+) kappa staining in the cytoplasm of the large



A) (Case 1) Nasal columella biopsy with callus keratin-positive spindled squamous cell carcinoma, previously diagnosed as benign granulation tissue (original x400). B) (Case 2) Tonsil biopsy with panleukocyte-positive large cell lymphoma infiltrating normal lymphocytes, previously diagnosed as poorly differentiated squamous cell carcinoma (original x400). C) (Case 4) Metastatic poorly differentiated carcinoma with absolute negativity for callus keratin, CEA, and 35BH11 cytokeratin (original x100). D) (Case 4) Poorly differentiated carcinoma with only focal AE1 positivity (original x100). This profile strongly suggests renal cell adenocarcinoma.

malignant cells." These immunohistochemical findings were felt to support unequivocally the diagnosis of a diffuse large cell lymphoma of the B cell type with kappa immunoglobulin monoclonality. The absolutely negative keratin and CEA stains further support this diagnosis and exclude the possibility of a poorly differentiated squamous cell carcinoma.

Accordingly, the jaw-neck dissection recommended at the original outside consultation was cancelled and the patient treated by means of the appropriate lymphoma protocol. She has done well and is now tumor free more than 18 months after diagnosis.

Case 3. A 53-year-old man was seen at SCMG for the first time with an 11-year history, during which he was evaluated by an outside physician, diagnosed, and surgically treated for inverting papilloma in the left nasal cavity as the cause of his complaints of unilateral nasal obstruction.

The patient remained symptom free for 10 years, until 1 year prior to being seen at SCMG, when he noted the onset of recurrent ipsilateral nasal obstruction. Rebiopsy was performed in the area of original treatment, but this time a histologic finding of squamous cell carcinoma was noted. The patient was advised to undertake a cancericidal dose of radiotherapy, which was completed without incident.

The patient again remained symptom free for 1 more year, at which time he presented to SCMG with recurrent symptoms of left-sided nasal obstruction; repeat biopsy again demonstrated the presence of squamous cell carcinoma. Associated with this finding, however, were previously unnoted areas of spindle-shaped cells. Routine histologic examination raised the possibility that this population represented one of two entities: first, a transformation to a more malignant variety of carcinoma, a so-called spindle cell carcinoma; or second, a radiation-induced fibrosis or desmoplastic reaction. A distinction was clinically important at this juncture because of the considerably worse prognosis carried by the first diagnosis.

Therefore, a GAB assay was completed on the biopsy material. While the regions of benign hyperplasia (representing the inverting papilloma) showed only focal and weak keratin positivity, there was focally strong (3+ to 4+) positivity in groups of cells in the regions identified as representing squamous cell carcinoma. The concomitant absence of keratin positivity in the spindle cells allowed us to proceed knowing that the chances of these cells representing the more malignant spindle cell carcinoma were quite small and that the surgery proposed, although extensive and possibly mutilating, nonetheless had a reasonable chance of curing the patient. He has remained disease free for 2½ years following surgical ablation.

Case 4. A 55-year-old woman was first seen early in January 1985 for evaluation of a neck mass. The mass was first noted while she was watching television a few weeks before the patient presented to SCMG. Other than its presence, the mass was entirely asymptomatic; further, the patient had no upper airway or digestive tract complaints. She had been a nonsmoker for more than 12 years and was in generally good health.

Pre-endoscopic evaluation, including complete blood count, urinalysis, and chest x-ray examination, were all within normal limits. Triple endoscopy was likewise unrevealing. A frozen section report from an incisional biopsy was nondiagnostic, but on permanent section report, "metastatic large cell carcinoma" was diagnosed. Within several days, a subsequent immunohistochemical (GAB assay) report described the lesion as possessing an immunohistochemical profile strongly suggesting renal origin.

Further work-up a short time later included an intravenous pyelogram that demonstrated a 9-cm mass arising from the inferior pole of the right kidney. A needle biopsy within a few days established the diagnosis of renal cell carcinoma.

COMMENT

Immunohistochemistry is a valuable technique with which the pathologist can help the surgeon and oncologist define the type and origin of a poorly differentiated malignant neoplasm. We routinely use immunohistochemistry to differentiate between carcinoma, lymphoma, melanoma, sarcoma, and hepatoma (Table). As with all biological systems, the staining patterns are not uniform in extent or intensity, either within a single neoplasm or between similar types of neoplasm. A few malignant neoplasms will not stain with any of the antibodies. The techniques that are used on fresh⁶ or formalin-fixed tissues can be applied to cytologic smears and cell block sections from body fluids and fine needle aspirations.

Experience and caution, however, are necessary for the proper interpretation of immunohistochemically stained sections. Pitfalls include nonspecific staining, which can be a major problem in body fluids and necrotic neoplasms; staining of entrapped normal structures, such as bronchi and nerves; and negative staining in tissue with poor fixation or cautery damage. Lymph nodes that are not removed intact, but are torn or crumbled, are very difficult to interpret when a consideration of lymphoma is present. The largest lymph node should always be removed intact and sent fresh, without formalin fixation, to the pathologist to enable the most accurate diagnosis possible.

REFERENCES

1. Falini B, Taylor CR. New developments in immunoperoxidase techniques and their application. *Arch Pathol Lab Med* 1983; 107:105-17.
2. Sternberger LA. *Immunocytochemistry*. Englewood Cliffs, NJ: Prentice-Hall, 1978.
3. Hsu S-M, Raine L, Fanger H. A comparative study of the peroxidase-antiperoxidase method and an avidin-biotin complex method for studying polypeptide hormones with radioimmunoassay antibodies. *Am J Clin Pathol* 1981; 75:734-8.
4. Robb JA. A new enzyme immunoelectin tissue stain. *Diagn Med* 1981; 4:87-95.
5. Robb JA. Diagnostic immunohistochemistry of epithelial neoplasms — practical aspects of technique and interpretation. *J Clin Lab Analysis* 1986 (in press).
6. Robbins BA. Diagnostic immunohistochemistry of lymphoma and related disorders — practical aspects of frozen section technique and interpretation. *J Clin Lab Analysis* 1986 (in press).

CLINICAL AND COMPUTED TOMOGRAPHIC CORRELATIONS OF PHARYNGOLARYNGEAL CANCER WITH WHOLE ORGAN SERIAL SECTIONS IN THE AXIAL PLANE

HISTORADIOGRAPHIC ANALYSIS OF 60 CASES

PATRICK J. GULLANE, MD

TORONTO, CANADA

A. W. P. VAN NOSTRAND, MD

TORONTO, CANADA

TOM E. HAVAS, MB

SYDNEY, AUSTRALIA

IVO BRODARIC, MD

TORONTO, CANADA

ANNE KELLER, MD

TORONTO, CANADA

HARRY S. SHULMAN, MD

TORONTO, CANADA

A retrospective analysis of 60 cases of pharyngolaryngeal cancer comparing the clinical, radiographic, operative, and histologic findings is presented. Computed tomographic scans of the larynges performed prior to surgery were correlated with similar histopathologic sections obtained by whole organ serial sections in the axial plane. Thirty-eight patients were treated primarily with surgery, and the remaining 22 cases were irradiation failures necessitating surgical salvage. Radiographic axial sections at 5-mm intervals or less were directly compared with microscopic sections in the same plane. This enabled us to correlate certain specific parameters such as site of origin of the tumor and its extent, with special emphasis on involvement of the vallecula, preepiglottic space, paraglottic space, and cartilaginous framework of the larynx. Our results indicate that endoscopy with CT is the most reliable method for evaluating pharyngolaryngeal cancer. A combined correlation of clinical evaluation plus CT scan reveals a 92% accuracy at the supraglottic level, 88.6% correlation at the glottic level, and 93.1% correlation in tumors of the hypopharynx. We now feel strongly that sufficient evidence exists for CT to be used as an integral part of the staging protocol.

KEY WORDS — cancer, computed tomography.

INTRODUCTION

The introduction of CT in 1973 made a significant impact in medicine, particularly in determining tumor site, size, and extent in all areas of the body.¹ First mention of this investigational tool in otolaryngology was made by Wortzman and Holgate² in 1976, followed in 1977 by Mancuso et al³ describing the evaluation of laryngeal neoplasms. Comparisons in the accuracy of CT and laryngography were subsequently studied.⁴⁻⁷ Since then, many authors have demonstrated good correlation between gross specimens and histopathologic findings.⁸⁻¹⁰ To our knowledge, no study has compared CT to histopathologic results in the irradiated patient population.

We have reviewed a group of 60 cases of primary carcinoma of the laryngopharynx and attempted to correlate CT scans and clinical findings with whole organ serial sections in the axial plane, both in irradiated and nonirradiated patients. Our investigation has led us to conclude that CT combined with direct fiberoptic endoscopy yields a high degree of correlation when matched with postsurgical whole organ serial sections.

MATERIALS AND METHODS

This series consists of 60 patients with 61 tumors of the laryngopharynx treated at the Toronto General Hospital, Sunnybrook Medical Center, and the

Prince of Wales Hospital, Sydney, Australia (Table 1). Forty-two patients had carcinoma of the larynx; 19 cases involved the hypopharynx. Twenty-one of the laryngeal tumors were supraglottic, 19 glottic, and two primary subglottic. The remaining hypopharyngeal group revealed 13 cases involving primarily the pyriform sinus, four cases of postcricoid tumors, and two cases involving the posterior pharyngeal wall. Twenty-two patients had previous irradiation with 5,000 rad of Cobalt 60 over 4 weeks. Scans were performed on EMI 7070 in four patients, GE 8800 in 41 patients, and GE 9800 in 15 patients. Five-millimeter contiguous axial sections from the oropharynx to the lung apices were obtained following intravenous contrast in 58 of the 60 cases. Additional 1.5-mm contiguous axial sections from the hyoid bone to the cricoid cartilage were obtained in those patients examined on the 9800 scanner. With some variations in total dose, most

TABLE 1. SAMPLE STUDIED

	Irradiation	No Irradiation	Total
Larynx (42 tumors)			
Supraglottic	7	14	21
Glottic	10	9	19
Subglottic	0	2	2
Hypopharynx (19 tumors)			
Pyriform sinus	3	10	13
Postpharyngeal wall	1	1	2
Posterior cricoid	1	3	4

From the Department of Otolaryngology (Gullane, Brodarcic), the Department of Radiology (Keller, Shulman), and the Department of Pathology (van Nostrand), The Connacher Laboratory, Toronto General Hospital, and the University of Toronto. Dr Havas is now at the Department of Otolaryngology, Prince of Wales Hospital, Sydney, Australia.

Presented at the meeting of the American Laryngological Association, Palm Beach, Florida, May 4-5, 1986.

REPRINTS — Patrick J. Gullane, MD, Toronto General Hospital, Eaton North 7-242, 101 College St, Toronto, Ontario, Canada, M5G 1L7.

TABLE 2. POSITIVE CORRELATION

	Irradiation (%)	No Irradiation (%)
Supraglottic		
Radiographic	55.8	80.5
Clinical	79.1	79.1
Clinical and radiographic	88.3	95.8
Glottic		
Radiographic	75.7	80.0
Clinical	72.9	82.9
Clinical and radiographic	88.6	88.6
Hypopharyngeal		
Radiographic	67.8	83.8
Clinical	87.8	85.2
Clinical and radiographic	93.9	92.3

patients received 80 g of bound I2 by bolus and infusion technique. Scanning time was 2 seconds for GE scanners and 3 seconds for the EMI 7070 scans. All 60 patients underwent total laryngectomy and/or laryngopharyngectomy within 4 weeks after the scan. The larynges were submitted for decalcification and sectioning.

The histologic method used in our laboratory for serial sections exploits the advantages of both celloidin and paraffin impregnation by use of a double embedding technique. The resulting sections are thin enough to permit accurate visualization of histologic detail.

The laryngeal specimen is initially fixed in buffered 10% formalin. It is then decalcified in a solution of sodium citrate and formic acid. After dehydration in several alcohol solutions, it is transferred into 3% celloidin in methyl benzoate for the first impregnation. Clearing of the specimen is accomplished with xylol before impregnation with paraffin wax in a vacuum oven. Finally, the specimen is embedded in wax for sectioning in the appropriate plane with a base sledge microtome. Using a

250-mm blade, the microtome gauge is set at 5 μ m, and two sections are cut at each 1-mm interval through the whole larynx, yielding two sets of between 40 and 80 sections. These are mounted on lantern slides and stained with the conventional H & E procedure.

The findings on whole mount histologic sections, CT scans, and clinical evaluation were independently recorded without knowledge of each group's results and tabulated graphically using 20 parameters. These included site of origin of lesion and extent of local spread to the following: tongue, vallecula, hyoid bone, epiglottis, preepiglottic space, aryepiglottic folds, false and true vocal cords, arytenoid cartilages, thyroid cartilage including body and horns, paraglottic space, anterior and posterior commissure, anterior and posterior cricoid cartilages, subglottis, pyriform sinus, and esophagus.

The tumor origin and extent were assessed independently, both clinically and radiographically, and compared with the histologic findings at 20 anatomic levels to determine the percentage of correlation of clinical findings alone, CT alone, and combined clinical and radiographic assessment with the pathologic standard.

RESULTS

Supraglottic Carcinoma. Twenty-one patients had a primary supraglottic carcinoma, and, of these, seven had prior irradiation. Eight of this group had histologically proven tumor in the preepiglottic space. The clinical assessment and radiographic findings on CT revealed 79.1% and 55.8% correlations, respectively, when used alone, but when combined had a correlation of 88.3% in the irradiated population. In the nonirradiated group, the radiographic and clinical correlation was greater: 80.5% and 79.1% alone and 95.8% when combined (Table 2). The combined positive correlations

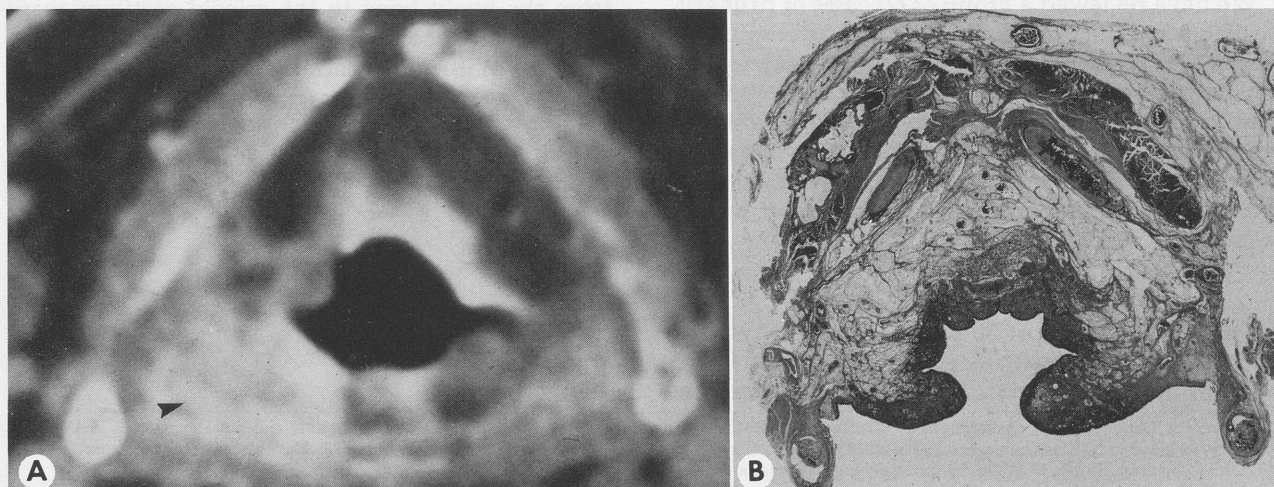


Fig 1. A) Computed tomographic scan at level of preepiglottic space. Area on left (arrow) interpreted as tumor. B) Histopathologic specimen. Edema mimicked tumor and resulted in false positive overcall on CT scan.

TABLE 3. FALSE NEGATIVE CORRELATION IN SUPRAGLOTTIC CASES

	Irradiation (%)	No Irradiation (%)
Radiographic	44.2	19.5
Clinical	20.9	20.9
Clinical and radiographic	11.7	4.2

of CT and endoscopy of 88.3% in the irradiated group and 95.8% in the nonirradiated group are considerably higher than those of radiography or clinical assessment alone. Preoperative irradiation resulted in a dramatic reduction in the ability to detect tumor extension by CT, with failure to differentiate edema from neoplasm in three patients who had prior irradiation (Fig 1).

The combined modalities failed to appreciate malignancy in 11.7% of all anatomic areas surveyed in the irradiated patients, whereas a 4.2% failure was noted in the nonirradiated group (Table 3). Unfortunately, the false negative problem areas for endoscopy were also the problem areas for CT, whether in irradiated or nonirradiated patients: vallecula, thyroid cartilage, paraglottic space, and commissure.

Glottic Carcinoma. Nineteen cases were available for study in this region, and, of these, ten patients had prior irradiation. The clinical correlation of 82.9% in the nonirradiated cases was slightly better than the 72.9% in the irradiated group. There was no noted significant difference in radiographic accuracy in the two groups. The combination of clinical assessment with CT yielded an 88.6% correlation in both the irradiated and nonirradiated groups (Table 2).

The four areas of difficulty in tumor detection were the epiglottis, preepiglottic space, thyroid cartilage, and commissures. At the glottic level (Fig 2),

preoperative irradiation resulted in a high rate (34%) of false positives compared with 20% in the nonirradiated group. Clinical evaluation was not adversely affected by preoperative irradiation, with a false positive rate of 15.7% in the irradiated group versus 17.1% in the nonirradiated group.

The areas of diagnostic difficulty to the endoscopist and the radiologist were the same, namely, the aryepiglottic folds, pyriform sinus, thyroid cartilage, and commissures (Fig 3).

Subglottic Carcinoma. Two cases of primary subglottic carcinoma were diagnosed in this series, and both were nonirradiated. A correlation of 87% was seen clinically, radiographically, and in a combined manner.

Hypopharyngeal Carcinoma. Nineteen cases involved the hypopharynx. Thirteen were primary pyriform sinus neoplasms, two involved the posterior pharyngeal wall, and four involved the postcricoid region. Therefore, we considered all hypopharyngeal lesions as a single unit. Five patients in this group had received prior irradiation, and of these a clinical outcome of 87.8% was superior to the 67.8% radiographic correlation. As in other regions, use of the combined modalities was the best, with a 93.9% correlation. In the 14 nonirradiated patients, a clinical accuracy of 85.2% was similar to that in the irradiated population, but a combined correlation of 92.3% resulted from the CT findings, demonstrating deep cartilaginous extension not evident clinically (Table 2). A false positive rate of 18% was similar in both the irradiated and nonirradiated groups. The lack of preoperative irradiation markedly enhanced the ability of CT to detect tumor, while not affecting clinical evaluation. Endoscopy plus CT failed to detect tumor in 6.1% of sites in irradiated patients and 7.7% in nonirradiated

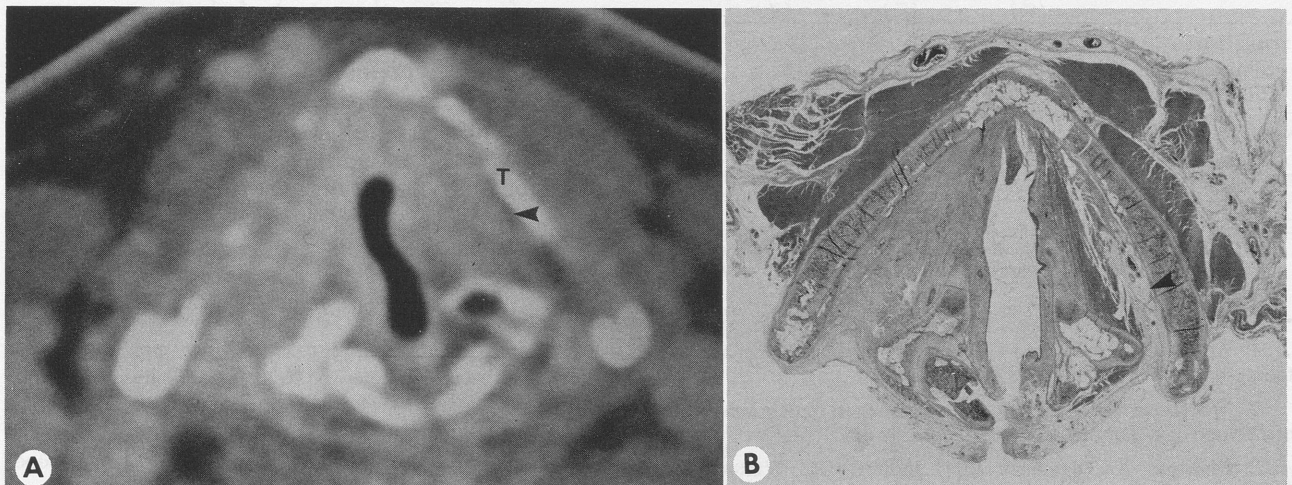


Fig 2. A) Computed tomographic scan at level of true cords showing outline of fat plane on right (arrow), with no tumor or thyroid cartilage involvement. Thyroid cartilage not seen on right with absence of fat plane, interpreted as positive for tumor with cartilage erosion. T — thyroid cartilage. B) Histopathologic section. Confirms accurate CT scan interpretation in right (arrow), with no tumor or cartilage erosion. Lack of ossification of thyroid cartilage on right mimicked cartilage erosion, and irradiation fibrosis of false cord mimicked tumor.

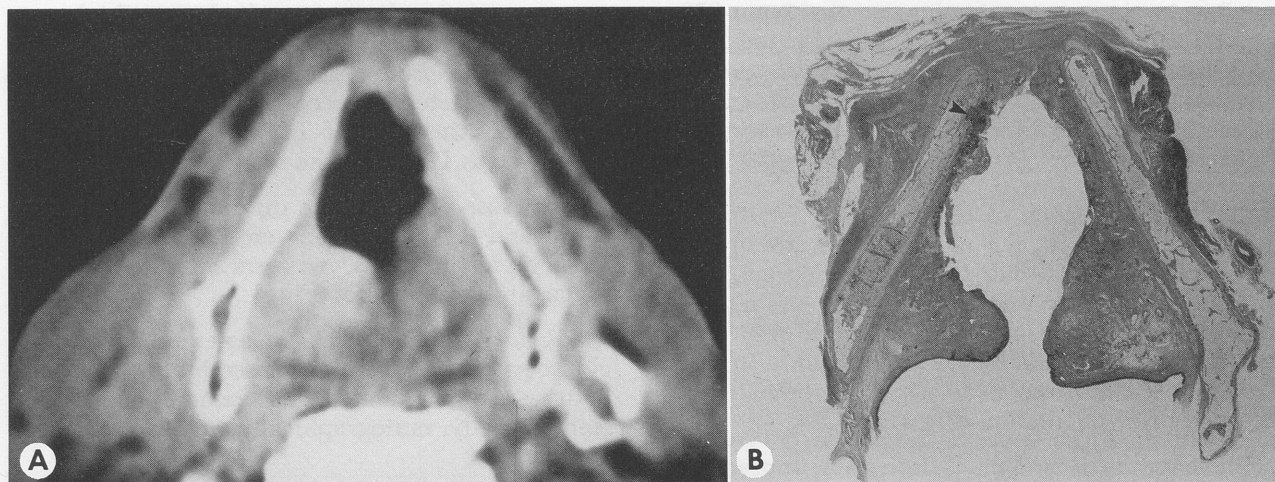


Fig 3. A) Computed tomographic scan at level of floor of ventricle. Irregularity was noted anteriorly on left and right and interpreted as tumor with no cartilage involvement. B) Histopathologic section. Tumor confirmed with thyroid cartilage erosion anteriorly on left (arrow), not detected on CT scan.

ated patients. The thyroid cartilage, paraglottic space, and commissures were the major areas of failure clinically and radiographically in both the irradiated and nonirradiated patients. Radiation edema was often extensive throughout the pharyngolarynx, resulting in a radiographic false positive rate of 20.7% in irradiated patients, as opposed to a rate of 12.3% in nonirradiated patients. Clinical overall of 22.6% and 18.1% in the irradiated and nonirradiated groups, respectively, again demonstrated clinical assessment to be less affected by preoperative radiation.

DISCUSSION

The results of this study indicate a good patho-

TABLE 4. CORRELATION WITH DISEASE SITE

	Supraglottic (%)	Glottic (%)	Hypopharyngeal (%)
Irradiation			
Clinical alone	79.1	72.9	87.8
Clinical and CT	88.3	88.6	93.9
No irradiation			
Clinical alone	79.1	82.9	85.2
Clinical and CT	95.8	88.6	92.3

ACKNOWLEDGMENTS — We thank Drs Derek Birt, Patrick Bridger, and V. S. Dayal for case contributions, Drs Grace and McIlwain for laboratory preparation on whole mount organ sections, Dr Douglas Bryce for continual support and guidance, and Janet Webb for manuscript preparation.

REFERENCES

- Ambrose J, Hounsfield G. Computerized transverse axial tomography. *Br J Radiol* 1973;46:148-9.
- Wortzman G, Holgate RC. Computerized tomography in otolaryngology. *Laryngoscope* 1976;86:1552-62.
- Mancuso AA, Hanafee WN, Juillard GJ, Winter J, Calcaterra TC. The role of computed tomography in the management of the larynx. *Radiology* 1977;124:243-4.
- Ward PH, Hanafee W, Mancuso A, Shallit J, Berci G. Evaluation of computerized tomography, cinelaryngoscopy, and laryngography in determining the extent of laryngeal disease. *Ann Otol Rhinol Laryngol* 1979;88:454-62.
- Gould LV, Cummings CW, Rabuzzi DD, Reed GF, Chung CT. Use of computerized axial tomography of the head and neck region. *Laryngoscope* 1977;87:1270-6.
- Thawley SE, Gado M, Fuller TR. Computerized tomography in the evaluation of head and neck lesions. *Laryngoscope* 1978;88:451-9.
- Mancuso AA, Hanafee WN. A comparative evaluation of computed tomography and laryngography. *Radiology* 1979;133:131-8.
- Archer CR, Sagel SS, Yeager VL, Martin S, Friedman WH. Staging of carcinoma of the larynx: comparative accuracy of

logic correlation in both the irradiated and nonirradiated larynx when a combination of endoscopy and CT was used. The factors that affect accurate interpretation are difficulty in visualizing microscopic disease, differentiation of edema and/or fibrosis from tumor, and pooling of saliva. The four areas that are primarily affected by these factors are the thyroid cartilage, paraglottic space, true cords, and commissures.

In conclusion, endoscopy and thin section CT are necessary for adequate assessment of disease within the pharyngolarynx. The irradiated larynx presents a complex diagnostic problem where there is acute radiation edema or chronic irradiation fibrosis. Despite these difficulties, a clinical overall correlation of 79.1% in the supraglottic region can be improved to 92.1% with the addition of CT. The accuracy of assessing the extent of glottic tumors can be improved from 77.9% to 88.8% using both modalities. In the hypopharyngeal region, an accuracy rate of 86.5% is surpassed by 93.1% when endoscopy is combined with CT (Table 4). We therefore feel that CT is an essential element in the clinical staging of pharyngolaryngeal tumors.

BEDFORD, MASSACHUSETTS

DISCUSSIONS

CARBON DIOXIDE LASER RESECTION OF SUPERFICIAL ORAL CARCINOMA: INDICATIONS, TECHNIQUE, AND RESULTS (p 21)

T. L. GUERRY, MD; S. SILVERMAN, JR, DDS; H. H. DEDO, MD

GEORGE A. SISSON, MD (Chicago): Your experience is pretty much the same as ours. We have had a rather large series using the laser. I must say that the laser has at times been disappointing to me, particularly when I get set and want to use the microscope. It is a laborious and tedious thing. When coming from the old school of sharp dissection, cautery, and even cryosurgery, it seems more rapid. There is no question that the points you made, Dr Dedo, are germane. It is the art of today and probably superior.

BLAIR FEARON, MD (Toronto): I always learn something when Dr Dedo presents a paper at this meeting. I am particularly intrigued by his retractor. With our experiences in children, we don't have vast experience in cancer, but we did have one 12-year-old who had squamous cell carcinoma of the supraglottic larynx that we treated with laser. Our President was there when we first saw this boy. He has survived 7 years now. He had radiation therapy as well, without any problem.

CHARLES W. VAUGHAN, MD (Boston): Dr Dedo's experience using the CO₂ laser in early oral carcinoma mirrors that of ours. When the CO₂ laser is coupled to the operating microscope and supravital staining is used to sharply define the field cancerization, we have a unique system for treating cancer. Because the laser wound is dry and undistorted, and because it is observed under magnification up to 25 times, the surgeon can actually see what he is doing. Muscle, fat, bone, vessels, nerves, and even cancer can be visualized easily. Using this system, tumor removal can be very precise and normal tissue can be spared, thus maximally preserving form and function. A further and very significant advantage of this system is its use in defining the extent of disease. If the attempt at excisional biopsy is unsuccessful in that the margins of the wound reveal further cancer, we have accurately established the extent of the disease (the T stage) and the need for more extensive treatment, which may be carried out without delay.

ANESTHETIC MANAGEMENT FOR TRACHEOBRONCHIAL LASER SURGERY (p 30)

M. RONTAL, MD; E. RONTAL, MD; M. E. WENOKUR, MD; L. ELSON

GEORGE A. SISSON, MD; ROBERT H. OSSOFF, DMD, MD (Chicago): This well-written paper discusses another option for the anesthetic management of patients requiring bronchoscopic laser surgery. The concept of the team approach between the surgeon and anesthesiologist, although not new, is stressed by the authors and is an extremely important aspect of this type of laser surgery. When possible, flexible bronchoscopy should be performed as part of the preoperative workup. Because the authors have emphasized local anesthesia in their approach to this problem, preoperative bronchoscopic examination can be performed immediately before their definitive laser bronchoscopic procedure. We agree with the authors that the rigid bronchoscope is the instrument of choice for bronchoscopic laser surgery whether it be with the carbon dioxide laser or the neodymium-YAG laser. This instrument has been found safer with respect to ventilatory control in the compromised airway and hemostasis. A previously described disadvantage of using the rigid bronchoscope for laser surgery was the need for general anesthesia to provide airway control and patient comfort. Through their technique of local anesthesia, these authors have been able to transform this disadvantage into an advantage. We agree that the use of a video monitor is an excellent idea although not mandatory for each case. While the results achieved by these authors using local anesthesia in the majority of cases are impressive, I would question the completeness of their bronchoscopic resections following photocoagulation, since they brought back six patients in the immediate postoperative period to remove obstructing tumor slough. It is our policy to first photocoagulate and then remove either with the CO₂ laser or the tip of the bronchoscope with a coring action and a biopsy forceps.

Again we congratulate the authors on their successful use of local anesthesia and intravenous sedation to perform the vast ma-

jority of procedures in their series. These results are very good and introduce yet another variable into the choice of techniques for the anesthetic management of patients undergoing bronchoscopic laser surgery. It must be emphasized, however, that previous reports by Dumon who used the rigid bronchoscope and general anesthesia with spontaneous ventilation, by Eisenman et al using general anesthesia with paralysis, and by Shapshay and Beamis utilizing the rigid bronchoscope and jet ventilation as described by Sanders, have demonstrated safety and efficacy. Perhaps the number of choices now available to both the otolaryngologist-head and neck surgeon and the anesthesiologist for the management of patients undergoing bronchoscopic laser surgery implies that there is no one best way to manage the airway in these patients. We appreciate the authors' prejudice for local anesthesia, but must remind the listener and reader of this paper that the implied risks of general anesthesia in our patients (American Society of Anesthesiologists, physical status 3 or 4) have not been found to be significant. The technique ultimately chosen will vary from institution to institution and will depend upon the instrumentation and armamentarium available and the local prejudice of the surgical anesthesia team.

BLAIR FEARON, MD (Toronto): We thank the authors for making their manuscript available well in advance of the presentation and also thank the American Laryngological Association for the opportunity of discussing this outstanding paper.

The information in this presentation is superb in the manner in which it is presented and makes it possible for any well-trained, experienced endoscopist to duplicate the methods described in such explicit detail.

In my humble opinion I believe that this is the manner in which all clinical papers should be written, wherein the information

provided leaves no doubt as to the authors' objectives and the way these objectives are reached. Furthermore the precautionary measures necessary to undertake this type of surgery are very clearly stated.

Although we have used the CO₂ laser to carry out endoscopic surgery for more than 10 years, we have not had the privilege of using the neodymium-YAG laser, and indeed this instrument is not available in our area.

The importance of teamwork in these procedures cannot be overstressed, particularly in peroral endoscopy under local anesthesia. Lack of teamwork can make the difference between a good result and a poor one and, yes, even the unnecessary death of a patient.

We commend highly the authors' preference for local anesthesia for their endoscopic surgery wherever possible. Rigid bronchoscopy under local anesthesia is not such a terrible experience for the patient as many are led to believe. When I did my postgraduate training with the late Dr Gabriel F. Tucker, Sr, virtually all peroral endoscopy was performed under local anesthesia regardless of the patient's age. In fact, the majority of these patients had no analgesia or sedation.

I was continually impressed by the fact that most patients were not reluctant to have repeat endoscopy, and indeed, some would arrive asking to be bronchoscoped.

Unfortunately, since the advent of the flexible fiberbronchoscope, the training in rigid endoscopy has deteriorated to the point where it is no longer possible to acquire the experience that used to be possible when there was a large volume of patients.

We agree wholeheartedly that, wherever possible, general anesthesia with spontaneous breathing is most desirable. This technique is more exacting and requires more care and experience on the part of the anesthesiologist, but it allows for a more exacting technique to carry out the procedures described. A word of caution in the use of Xylocaine in pressurized containers is needed. These units are very convenient, but the propellant in the container is Freon or at least it has been in the past. In our experience this causes a considerable laryngeal reaction in many patients.

Closed circuit anesthesia through the bronchoscope is less difficult to carry out with the patient breathing spontaneously, but I find the attachments very cumbersome, making good endoscopy technique more difficult. The concern of exposing operating room personnel to the anesthetic gases can be overcome by "scavenging" the gas by connecting suction tubing to an Ayers T-piece attached to the proximal end of the bronchoscope. Where a tracheotomy is present, anesthesia is readily administered through the special inner tube we designed and reported before this Association in 1964.

Finally, I wish to commend the authors highly for this fine work and trust that we will hear from them again in the future.

CHARLES W. VAUGHAN, MD (Boston): The paper of Dr Rontal and his colleagues on anesthetic management for laser surgery in the tracheobronchial tree stressed two points. The first, that a cooperative and informed team can develop a safe and effective anesthetic regimen for tracheobronchial laser surgery is very nicely demonstrated by their reported experience. Their rate of complications while managing these often critically ill patients is quite low. Dr Rontal's second point, that local anesthesia should be used for distal tumors was correctly termed in the written paper a "prejudice." It is unproven by their data. We agree that Dr Rontal, following his prejudice, has achieved successful results. However others, such as ourselves at Boston University, following our own prejudice for general anesthesia, have been equally successful in many hundreds of similar procedures. This suggests that the specifics of the method are not as important as is the fact that a skilled and harmonious team should do what it does well.

PETER W. ALBERTI, MB, PhD (Toronto): I had the privilege of reviewing this fascinating and well-written paper with my anesthesiologist colleagues, Drs Gerald Edelist and Joe Mallon and, based on our experience with 74 patients, find many areas of common ground. We agree that this is completely a team procedure with no room for occasional operators and occasional anesthesiologists, and prefer the same team of anesthesiologist and surgeon.

We do not feel that it is proven that local anesthesia is better than general anesthesia for tracheal lesions. We do not use local anesthesia and have had no major problems with hypoxia, hypercarbia, or other signs of inadequate ventilation. We also use the rigid scope and use the fiberoptic scope through it. We have devised a system to give oxygen, nitrogen, and the anesthetic mixture through the side arm of the ventilating bronchoscope while doing either rigid or fiberoptic endoscopy through the rigid scope. We feel we have good control of the patient using this technique. We also use some jet techniques while using the rigid scope alone.

We agree wholeheartedly with use of nebulized lidocaine, propofol, and nitroglycerine for hypertension and the pulse monitor for monitoring oxygen saturation rather than indwelling lines. We are less happy with the outpatient approach. The literature suggests the need for 10% reintubation in 24 hours following discharge from the recovery room, and this we feel is too high to commit patients to the ambulatory experience.

The team must be prepared to adapt. We believe in a rigid bronchoscope and a flexible team for this work. I congratulate the authors on a timely and excellent paper.

IMBRICATION RECONSTRUCTION FOLLOWING PARTIAL LARYNGECTOMY (p 61)

C. LIU, MD; P. H. WARD, MD; L. PLEET, MD

HUGH F. BILLER, MD (New York): This is a very interesting article, and I wish to congratulate Drs Liu and colleagues on a very innovative technique to allow improved voice following vertical partial laryngectomy. The authors do mention in the article that they use this technique for some patients in whom the carcinoma arising on the true vocal cord extends into the undersurface or the lower portion of the false vocal cord, which would make the lesion a transglottic one. The biologic behavior of the transglottic lesion, even the small one, is such that there is submucosal extension and one can have a positive margin at the superior margin of the resection, and many times these lesions also extend and involve the preepiglottic space. Therefore I would anticipate that there would be a higher incidence of local recurrence if this procedure is used for this type of lesion. The classification which the authors use is not the classification that has been adopted by the

American Joint Committee for Cancer Staging and End-Result Reporting, and therefore, it is difficult to assess in what they call T₂ lesions how many of those lesions were indeed transglottic lesions. They had 14 T₂ lesions, and I would like to ask the authors about how many were transglottic lesions, what the follow-up period was for the transglottic lesions, and what the recurrence rate was for transglottic lesions.

BRUCE PEARSON, MD (Rochester, Minn): I found that the data in the paper did show what one would expect. Excision works for the small cancers. By small cancers I mean ones that do not fix the vocal cord. I understand from the paper that if vocal cord fixation is present, this procedure would not be indicated. I wish there was a little more emphasis on margins because I think that this would be a difficult procedure to apply consistently and safely

without the backup and support of the kind of pathologist that Dr Ward has available to him. I expect that the diagrams under-represent the extent of the excision since a narrow strip that was shown could probably be handled by a cordectomy. I think the procedure should produce better voice, as we would expect, if you provided better bulk, and this looks like a very nice technique to do it. It seems simple in concept; it looks reproducible, and the neocord that is produced would be one of the few lined with mucosa, so I think this would help the predictability. I did have a couple of questions for the authors, and they relate to the failures. All three failures had preoperative radiotherapy, so I am interested in knowing how many cases were treated primarily with imbrication laryngoplasty without radiotherapy; and am I right that you have had no local treatment failures when you have used this operation alone and avoided radiotherapy all together; and if that is true, does that expand your indications beyond the ones you have mentioned, that is, the young patients and perhaps the unreliable patients? With regard to the failures, all three had laryngectomies. Were any of these specimens studied by serial section to determine the cause of failure or to look at the histology of the reconstruction? Finally, a couple of technical questions. How does imbrication actually move tissue inward even though that last slide showed two procedures, one where the upper segment is brought in internally to the lower segment and in the other where it is brought externally? I think I understand from the paper that the technique that brings the upper segment to the outside of the lower thyroid remnant has been discarded. It appeared to me that that would be appropriate because I think it would actually take bulk away from the glottis instead of adding to it. You are dealing with postradiated larynges, you strip the outside of the thyroid ala, you cut the top of it, and then you bare the inside of it to achieve that pocket; so doesn't the cartilage sometimes just come

free and act as a free graft? Why don't you release the segment above by cutting the superior cornu, or do you find that this is not necessary? I tried to reproduce this operation on a cadaver and found that that helped.

PAUL H. WARD, MD (Los Angeles): Thank you, Drs Pearson and Biller, for your comments. They are all cogent and important. Regarding the study of the three transglottic lesions, two of them were the ones that recurred. You have an absolutely valid point. This operation is really designed for T1 and T2 lesions in the real sense, it is designed to present a better voice, and it is designed for patients who do not want radiotherapy (and there are patients like this) or who are poor candidates for radiotherapy because they are noncompliant and won't follow through. In answer to some of the other questions, the amount of excision is really about the amount that we pictured. One makes a pocket and imbricates this. It gives tissue to fill out. We did discard the external imbrication, not because it didn't work well but because it didn't give the voice we wanted. The tissue was there for Teflon injection or other material to implant. The overall advantage of this procedure is in the postradiation case in which a hemilaryngectomy may give a very poor voice or edema if one tries it because part of the venous and lymphatic supply has been removed. Dropping down the epiglottic fold and the false cord allows continued lymphatic drainage, and we do not see nearly so much edema in these patients. We don't have the whole organ histology because at that time we did not have it. We now have whole organ fresh histology. We still don't have the type that Dr Bryce and our great speaker, Prof Harrison, use along with Dr Kirchner. The other thing is that we do release this if there is any tension on it at all. We place a large suture in the chin to the chest to flex the head. A week later when the suture is removed the neck remains flexed for another week.

LONG-TERM RESULTS OF CONCURRENT POLYCHEMOTHERAPY AND RADIOTHERAPY IN PATIENTS WITH STOMAL RECURRENCE AFTER TOTAL LARYNGECTOMY (p 66)

A. J. M. BALM, MD, PhD; G. B. SNOW, MD, PhD; A. B. M. F. KARIM, MD, PhD; R. J. J. VERSLUIS, MD; K. H. NJO, MD; R. M. TIWARI, FRCS, PhD

GEORGE A. SISSON, MD (Chicago): It is a pleasure to discuss a topic that has long held my interest. Drs Balm and colleagues have presented a very interesting pilot study whereby the early results on eight patients with stomal recurrence show a remarkable response to polychemotherapy and radiotherapy. They have outlined succinctly the alleged several causes of stomal recurrence that continue to be debatable. I was disappointed that they did not make an attempt to stage the disease, but careful review of the manuscript led me to perceive that the majority of these patients had stage I or II stomal recurrences. This staging system is a personal system that I have outlined and discussed in previous publications. In April 1985, at the International Symposium on Head and Neck Surgery in Tokyo, I presented 75 mediastinal dissections that were performed for stomal recurrence from 1953 to 1984. All of our patients were staged. Ten out of 22, or 45%, of the stage I patients have no evidence of disease and are long-term survivors. All these patients had radiation, and some of the recent ones had our polychemotherapy protocol, which varied from one 5-year interval to another. Five out of 17, or 29%, stage II patients are alive, and ten of 30, or 33%, of the patients who were stage III are alive. One of the six in stage IV survived 3 years. The determinate end result, assuming all patients lost to follow-up died of disease, showed that 26 of 75 patients survived mediastinal dissec-

tion and/or gastric pull-up for an average of 3½ years, an acceptable length of time, and should be considered cured. Recently when we are combining stomach pull-up and pectoralis major flap reconstruction of the mediastinum in patients with stages II and III, our success rate has greatly improved because our complication rate has gone down. At the time of our 1977 report, we did not reconstruct the mediastinum with a pectoralis major flap nor did we add the stomach pull-up for reconstruction of the esophagus when it was involved from stomal recurrence. This, therefore, gives us a survival rate of 35% for mean survival of 3½ years for all patients. These data include the patients of earlier years before improvements in which numerous vessel ruptures were encountered.

It is my contention, at this time, that stomal recurrence should be treated surgically even though adjuvant chemotherapy and radiation do reduce the cancer cell population. Certainly patient 2, as presented, is a motivation to investigate further polychemotherapy for stage IV disease. We are all aware that the occasional remarkable result is observed with these potent drugs, but until there is more evidence, I would recommend we continue to operate on these patients as soon as possible because, I repeat, our results with recent operative technique are showing 45% long-term results.

NEW TECHNIQUE OF SOFT PALATE RECONSTRUCTION USING A HYPOPHARYNGEAL MYOMUCOSAL FLAP (p 130)

Y. MURAKAMI, MD; T. IKARI, MD; S. SAITO, MD; J. ONO, MD

RICHARD T. FARRIOR, MD (Tampa): It is a privilege to have heard Dr Murakami's excellent paper and have this chance to discuss it. I thank Dr Murakami for bringing to this society's attention this versatile and sturdy posterior pharyngeal flap. There are a few points I would like to make with the hope of helping those not using this flap better visualize the area.

First, the length and width of flap may be accomplished through a peroral or transoral approach, and this might avoid the need for the tracheotomy and prolonged hospitalization. Except for some pain, we have not had the trouble he described with some of his patients or the need for prolonged postoperative care. The long hospitalization and the need for tracheotomy create some concern, and perhaps this could be avoided by staying with the peroral approach to avoid also the danger of excessive edema and potential injury to the superior laryngeal or other nerves. With proper positioning, utilizing either the Dott or Dingman mouth gags, one can develop a long flap by the oral route. We have, for some years, used very wide and long flaps extending to the level of the arytenoids, and all were approached by the transoral route.

From longtime experience in cleft palate surgery, it is doubtful that these flaps remain dynamic with healing and contracture, especially as they are separated from the muscle origin and the nerve supply, which enters from lateral. It is probable that the action comes from the preserved levator veli palatini, tensor veli palatini, and palatopharyngeal muscles, as well as other lateral pharyngeal and palatal muscles. The tubed flap generally is conceded to contract and to become static rather than dynamic.

To say the least, musculature and innervation are complex, so totally normal function could not be absolute; however, successful rehabilitation has been demonstrated and is in part due simply to mechanical closure. The anatomy is intricate and the intervention complex for the normal palate and probably as complicated as that for the larynx in the pharyngeal phases of swallowing, breathing, and in speech.

The tubing of the flap, for the oral and nasal surface lining, is a significant technical advance. Because the superiorly based flap is lined on the nasal surface and can be made quite long, it is usually unnecessary to use the nasal flaps described by Cronin, as in a palatal push-back procedure. Should lining on the oral surface be desired, a flap can be developed from the nasal surface of the remaining soft palate. It is, of course, essential to preserve the lateral epithelial lined gutters. The palatal flaps described for additional coverage, saving the neurovascular bundle, can be used either as true axial flaps or even island flaps.

A superiorly based flap can be carried forward well beyond the posterior edge of the hard palate, and the anterior extent of the resection can be made larger. As Dr Murakami has presented this material, certainly the technique of one-staged flap, lined on both sides, is a significant contribution.

As a final statement, speaking in generalities regarding cancer in this area, having this flap in one's armamentarium should increase the margins of resection for these tumors notorious for local recurrence. A word of caution — as with all flaps and tumor re-

section, surgical planning must be made not to limit the resection to fit the planned reconstruction.

It is always a pleasure to see Dr Murakami, and I want to thank Dr Bryce for giving me the opportunity to review this paper.

ROBERT M. BUMSTEAD, MD (Iowa City): I would like to comment on this new technique of soft palate reconstruction. I do admire the authors' attempt to provide an immediate reconstruction of a somewhat difficult defect, the large defect of the soft palate. We have had a lot of experience with these defects since they are very similar to the cleft defects that we routinely repair. I was impressed with the fact that they did use the principle of obtaining mucosal coverage of all surfaces of their pharyngeal flap. I think certain principles of reconstruction of these defects have not been met in this paper, however. One thing, as Dr Farrior mentioned, this operation can be done very easily through a transoral approach, and the lateral pharyngotomy is unnecessary. I think this makes it an excessive operation and probably contributes to the period of time it takes their patients to swallow. The flap elevation should be approximately to the plane of the level of the hard palate. When one thinks of the pathophysiology of velopharyngeal closure, the maximal motion of the sphincter of the velopharyngeal port is in this area, and one wants to have the base of flap in that plane. By starting so low in the neck and extending the flaps only to the posterior margin of the hard palate, one ends up with a low or inferiorly based flap, which was obvious in their postoperative picture. Finally, I think there was a lack of collaborative scientific studies such as evaluation by a competent speech pathologist who is trained in detecting velopharyngeal insufficiency, at least in the paper, but maybe these were performed. If the patients are having this much trouble swallowing, I think they could have used a barium swallow study and some other studies to evaluate these patients, both their successes and lack of success. Without these appropriate studies and collaboration, it is impossible to evaluate the success of this operation, but I do admire their attempt in presenting this study to this society in a one-stage reconstruction.

EMANUEL M. SKOLNIK, MD (Chicago): My Japanese is not as good as Dr Murakami's English is, but I would like to say "arigato" for hearing his paper. This is what I call revisiting a situation. Over 20 years ago, I published a paper in New York on primary reconstruction following resection of the soft palate, and I presented a videotape of my 12 patients. All have done well. In no case was I required to do a lateral pharyngotomy or a tracheotomy. I have to agree with the other two discussers. All of these can be done transorally. One can get down as far as one likes. Oftentimes I will mark out this flap, infiltrate with local anesthesia to reduce the amount of bleeding, get a wide resection, and bring it up with the fascia over the prevertebral muscles so that nothing else has to be done. Bring this flap under the hard palate, make a pocket like a sandwich, and suture it in place. All of these contract enough so that there will be some space on each side for the airway. We still must consider prostheses at times. Not everyone must have primary reconstruction. The prosthetists do a very excellent job. The only time you run into mishaps with the prosthesis is in the patient who has had radiation therapy.

CLINICAL AND COMPUTED TOMOGRAPHIC CORRELATIONS OF PHARYNGOLARYNGEAL CANCER WITH WHOLE ORGAN SERIAL SECTIONS IN THE AXIAL PLANE. HISTORADIOGRAPHIC ANALYSIS OF 60 CASES (p 149)

P. J. GULLANE, MD; T. E. HAVAS, MB; A. KELLER, MD; A. W. P. VAN NOSTRAND, MD; I. BRODARIC, MD; H. S. SHULMAN, MD

DANIEL MILLER, MD (Boston): I haven't seen such beautiful slides in a long time. I congratulate the authors on them. A few

words concerning the correlation of the CT scanning. Eighty-five to 95% correlation is a high rate. This documented report is of

great importance, particularly in monitoring the response to induction chemotherapy. However, the high rate of radiologic overall should be noticed particularly in the previously radiated patient. Likewise, the negative clinical and radiologic overall, although at a lower rate, of 18% false-positive correlation, is of concern particularly in the radiated patients. The reading of a CT scan should be done by a skilled and experienced radiologist, of course, but it is all in the eyes of the beholder. Although we maintain respect for this newly developed CT scan information, let us not downplay the clinical evaluation. None of this correlative work could be done without the skills of the personnel in the highly respected Connacher Laryngeal Laboratory, which was established by our President, Dr Bryce. The ideal discussion is one with a good beginning and a good ending, both of which are very close together. I congratulate the authors on this fine correlative report of confirmation of what most of us have thought from our own experience with classification and staging for tumors of the larynx.

ARNOLD M. NOYEK, MD (Toronto): I compliment you on having put together a nice correlation between routine CT and cancer in the larynx and hypopharynx. I think the most important thing you have shown us is that there are excellent correlations between the CT and the histopathology. Therefore, CT has an absolute, unequivocal role in the pretreatment appropriate staging process. One thing that should not be overlooked is that the images that have been projected are 5-mm contiguous slices and what we are looking at are two-dimensional representations of a three-dimensional situation. Within the 5-mm slice, if we get volume averaging, one loses some of the detail. Although the correlations are 85% to 95%, the imaging capability is really virtually 100% in sophisticated, well set up protocols in which one is try-

ing to provide answers to very specific problems. The clinical direction that Dr Miller mentioned is the most important thing. If you look at sites of predilection for cancer invasion and so forth, one must do thin 1.5-mm sections and maybe one will find the smaller disease. I will comment on three limitations that struck me. The first is the postradiation case. That is going to be a problem with CT because it does not have enough soft tissue range to show differentiation between cancer and adjacent soft tissues, and when one puts edema in the picture, it is more difficult. Magnetic resonance will perhaps have even a 100-fold capability for better soft tissue imaging than CT. So if the decision making is critical for these studies, then that will be the ultimate study for this area. As far as the pyriform sinus is concerned, there is one fault in the manuscript. I believe it is an error to study the pyriform sinus in the axial dimension without doing a modified Valsalva's maneuver like we do on the laryngogram. The argument against it is that the patient will move in the gantry, but not if one has him or her gently blow against a crimped straw. It opens the pyriform sinus so that saliva does not interfere with the soft tissue image. Cartilage destruction can be shown on thin sections if they are set up in retrospective studies and you know at which ones to look. We have a study to be published in the *Archives* next month that shows that we have been able to move from this universal 20% to 30% equivocal or even false-negative rate into finding areas of cartilage destruction using ultrasound as a focus tool, but ultimately it is the CT that tells us that. Now what magnetic resonance imaging tells us about cartilage destruction is uncertain and shows it differently. It doesn't show the hard tissues. It shows the marrow composition, but all of these methods are attempts to see the patient better in a natural situation. I compliment you on what you have shown us.

INCIDENCE OF LARGE SACCULES IN LARYNGECTOMY SPECIMENS (p 135)

D. BIRT, MB, FRCS(C)

JOHN A. KIRCHNER, MD (New Haven): Dr Birt was kind enough to send me a copy of his report well in advance of this meeting. This is a very thorough study, with measurements made in minute detail. The incidence of nearly 18% for laryngoceles in the 353 laryngeal cancer specimens indicates that a laryngeal neoplasm does something to the ventricle that is still hard to explain. I would like to call your attention to two important clinical implications of this work.

If a T1 glottic lesion is to be removed by laser, the surgeon must be able to see the lateral edge of the tumor in order to make a safe cut. If the tumor extends laterally on the upper surface of the true cord, along the floor of the ventricle, it may be difficult or impossible to see the tumor's lateral margin. If the laser cut is made through the ventricular band as shown in this drawing from Carl Silver's book (an excellent book, by the way), the surgeon may miss the lateral edge of the tumor if there is cancer extending into a large saccule such as Dr Birt has described. In a quick survey of my total laryngectomy material last week, I found three such cases.

The other point is illustrated by this laryngectomy specimen shown on the slide being viewed. The patient was referred to me

because of hoarseness and a swollen left ventricular band. The larynx had been biopsied, but no tumor found. By indirect laryngoscopy I was unable to see the vocal cord. Direct examination revealed only a small part of the vocal cord because it was hidden by this large, firm swelling of the ventricular band. My first biopsy failed to show cancer, but a later biopsy with angulated forceps revealed squamous cell carcinoma.

I started a hemilaryngectomy, but I soon saw that the lesion extended far up under the ventricular band. Total laryngectomy showed that the lesion occupied the entire ventricle, under an intact false cord. Even more interesting, the coronal sections showed that the swelling of the false cord was simply due to its being pushed into the lumen by the cancer in the ventricle. So, whether this large ventricle would qualify as a laryngocele or not, it nevertheless illustrates the fact that a smooth swelling of the false cord in a 65-year-old heavy smoker may be concealing a large growth in the underlying saccule.

It would be interesting to know whether Dr Birt observed cancer extending into any of these laryngoceles that he studied, and if so, whether this condition was suspected before the operation.

DIAGNOSIS AND TREATMENT OF SMALL CELL CARCINOMA OF THE LARYNX: A CRITICAL REVIEW (p 84)

A. FERLITO, MD

MURRAY D. MORRISON, MD (Vancouver, Canada): I would like to thank Dr Bryce for forwarding me prior to the meeting a copy of Dr Ferlito's excellent paper on small cell carcinoma of the larynx. In preparing to discuss this paper, I reviewed the recent literature on this topic and note that a significant portion of it has

been written by Dr Ferlito, and it seems clear that he is a current authority on this subject.

Most of the literature reports of these neuroendocrine tumors, or apudomas, appeared during the 1980s, and the first case of one

of these tumors in the larynx was noted in Canada in 1972, and the second by Dr Ferlito in Padua, Italy. Dr Ferlito discusses 14 cases of primary small cell carcinoma from a series of 3,500 primary and secondary laryngeal malignancies, and this incidence is in keeping with other reports similar to the smaller numbers that I reviewed at the Cancer Control Agency of British Columbia in Vancouver. Over a 10-year period between 1970 and 1980, we saw 653 primary laryngeal malignancies and noted two small cell carcinomas, one being an oat cell tumor and the other a small cell combined. My personal experience with the case of oat cell carcinoma of the larynx was in a 40-year-old man who presented in July 1980, with a large neck lump and an extensive supraglottic tumor that on biopsy showed the typical oat cell tumor appearance. Further investigation at that time revealed widespread bony metastases, and although some palliative radiation improved his laryngeal symptoms, he died with widespread disease 6 weeks after admission.

It should be noted that these small cell tumors can occur in the upper aerodigestive tract other than in the larynx, including the oral cavity and esophagus, and the diagnosis and management of these lesions is similar to that outlined by Dr Ferlito. The treatment is generally the same as for the lung oat cell lesions including radiation therapy and chemotherapy, with surgery having little to offer.

DANIEL MILLER, MD (Boston): I enjoyed this paper tremendously. It points out a couple of things that are not too uncommon for those who are doing tumors of the head and neck. One of the points that Dr Ferlito makes is that these patients respond well to chemotherapy. The interesting feature about this is that esthesioneuroblastoma arises from the neural crest and its diagnosis is usually made by electron microscopic demonstration of neurosecretory granules. Since the oat cell carcinomas respond so well to chemotherapy, the esthesioneuroblastomas are now being treated with the same drugs. We have been using Cytosan, Adriamycin, and vincristine sulfate, which have done so well with the few cases of oat cell carcinoma of the larynx. The important thing to recognize is that patients with this tumor should not be treated with laryngectomy because the implication of the staging is not the same as with squamous cell carcinoma. So surgery has very little place in the treatment of oat cell carcinoma unless there is a poor response to the chemotherapy. The relationship to esthesioneuroblastoma is an interesting one and ongoing.

STEPHEN P. BECKER, MD (Chicago): When the pathologist first

sees a tumor like this and proposes the diagnosis of small cell carcinoma, it really means a group of little carcinomatous cells the true identity of which he does not know. Due to the poor differentiation of these small cells, immunochemical methods, histochemical markers, and electron microscopy are all necessary before the pathologist can make an identification.

When the tumor cells of the small cell carcinoma are subjected to these sophisticated tests, they show characteristics such as neurosecretory granules on electron microscopy and neuron-specific enolase and antibodies to neural filaments on immunocytochemistry. These small cell carcinomas are held out as distinct primary neuroendocrine tumors of the larynx. They are not laryngeal carcinoids and are distinguished from carcinoids primarily by the degree of differentiation. The carcinoid shows uniform cuboidal cells, large and numerous neurosecretory granules, and positive argyrophilic methods. The small cell carcinoma has small and relatively infrequent neurosecretory granules and is negative with argyrophilic methods. This tumor is distinguished from small cell squamous carcinoma by the presence of neurosecretory granules in the small cell carcinoma. The syntax and terminology here can lead to a lot of confusion, and to call these small cell neuroendocrine carcinomas a healthy development.

These lesions represent 50% of nonepidermoid laryngeal cancer, so they are a rare but significant group. I do not agree with the separate staging system noted in the paper since there are already too many staging systems, and I think the small cell cancer should be staged as other laryngeal cancers are.

The important point is that the small cell carcinoma must be recognized as a distinct entity due to its aggressive biologic behavior, early invasion, and blood-borne and lymphatic metastases. Due to early widespread dissemination, these lesions appear to represent more of a systemic illness. The best treatment results in this series were obtained with intensive chemotherapy followed by radiation therapy. Chemotherapy is employed first due to early occult metastases and has resulted in some 3- and 6-year survivals instead of the average 12-month survival.

This aggressive tumor is in some series almost uniformly fatal in a short period of time. However, the author derived survival rates in years in a few patients. I am interested in which chemotherapeutic agents he favors and how much radiation he recommends. I would also like to know if there are any favorable situations for local surgery.

DEMONSTRATION OF HUMAN PAPILLOMAVIRUS CAPSID ANTIGEN IN CARCINOMA IN SITU OF THE LARYNX (p 97)

H. KASHIMA, MD; P. MOUNTS, PhD; F. KUHAJDA, MD; M. LOURY, MD

A. W. PETER VAN NOSTRAND, MD (Toronto): The studies Dr Kashima and colleagues have carried out will stimulate a number of prospective studies using gene probe and other techniques requiring fresh tissue to delineate further the relationship between the papilloma virus and the predictability toward the development of invasive carcinoma in premalignant atypia. Using uterine cervical carcinoma in parallel, it has been clearly demonstrated that there is a very definite relationship between previous infection with herpes virus or papilloma virus and the eventual development of carcinoma. The relationship is clearly not just cause and effect, and it is being worked upon very extensively at the present time using exactly the same kind of techniques that Dr

Kashima has applied to his area plus the gene probes to decipher what the exact relationship between the presence of the virus at an earlier stage and the ongoing development of cancer may be. In fact, it may be just the reverse of what Dr Kashima has suggested. In fact, those that are infected with the virus may produce atypia that to the light microscopist may be indistinguishable from premalignant atypia, but these may, in fact, be the reversible ones that do not develop carcinoma. So I would inject a word of caution with respect to interpretation of the cause and effect relationship of the presence of the virus, capsid, or other antigenic portion of the virus, and the eventual development of carcinoma.

ESTROGEN RECEPTOR IN THE LARYNX OF THE AGED BABOON (*PAPIO CYNOCEPHALUS*) (p 102)

G. R. HOLT, MD; T. B. AUFDEMORTE, DDS; P. J. SHERIDAN, PhD

A. W. PETER VAN NOSTRAND, MD (Toronto): This study relating the presence of hormone receptor sites to sex differences in the larynx is interesting. It makes good sense to suggest that the changes in the larynx that separate the sexes take place in the mesenchymal portions, because the major differences in the male and female larynges as we see them in humans are not differences in the epithelium, they are differences in the size and bulk of the

mesenchymal tissues that make up the larynx and its framework. The epithelium just seems to be along for the ride. So I am not at all surprised by the receptor sites being present mainly in the mesenchymal tissue and not in the epithelium. I will look forward to the further studies that are now being carried out on the remainder of that project.


IMMUNOHISTOCHEMISTRY: HELP IN DIAGNOSIS OF HISTOLOGICALLY AMBIGUOUS LESIONS OF THE HEAD AND NECK (p 145)

R. C. BONE, MD; J. A. ROBB, MD

A. W. PETER VAN NOSTRAND, MD (Toronto): Two points I would like to make. The glucose oxidase avidin biotin (GAB) assay that Dr Bone described is but one of numerous refinements in immunoperoxidase staining technique. All of these refinements are designed to make the test more specific. The GAB assay that he has described does make it more specific and more reproducible. One of the reasons why immunoperoxidase did not take off like a rocket when it was first applied was the extreme difficulty in getting reproducible results that were the same in different laboratories around the country. With standardization of the technique and some of the refinements like this one that are now being achieved, you are going to hear a lot more about it. The second point I would like to make has to do with the heterogeneity of tumors. It is becoming more and more clear that tumors that to

the light microscopist appear uniform and homogeneous are not, and this applies not just to the laryngeal squamous cell carcinomas but to tumors of other sites, breast being an obvious example. There are large groups of breast carcinomas that look similar to the light microscopist, but these are now being separated into "good actors" and "bad actors" by hormone receptor studies. The specific reason is that we can show that estrogen receptor site presence in large amounts separates them out as being good behaviors in terms of the current treatment modalities for breast carcinoma. I would predict that the profiles that Dr Bone has described in look-alike tumors both in the larynx and other head and neck sites will in the future allow us to predict the behavior of such tumors and stimulate more aggressive or more specific therapy much earlier than we now do.

MEMORIALS



FRANCIS H. MCGOVERN
1907-1985

Francis Henry McGovern was born in Milwaukee on September 17, 1907. He received a Bachelor of Arts from the University of Wisconsin in 1928 and a Doctorate of Medicine from the University of Pennsylvania in 1932. After an internship at Wisconsin General Hospital in Madison, he entered an eye, ear, nose and throat residency at the University of Virginia in 1933, and thus began a happy association for otolaryngology and the Commonwealth of Virginia that continued until his death on July 9, 1985. Upon completion of residency training in 1935, he entered the private practice of otolaryngology in Danville, Virginia.

He not only acquired a superb grasp of otolaryngology in Charlottesville, Virginia, he also acquired a bride in the person of Rebecca Lee, who was his inspiration and loving companion through the years.

Being a thorough physician and having a winning personality, it wasn't long until Francis had a highly successful practice. For many, this would have been enough, but not for him. He found time to pursue his interest in archeology, history, and the history of medicine. When Danville lacked an ade-

quate library, in the finest Jeffersonian tradition, Francis was instrumental in having one built. He donated a large number of rare books to the University of Virginia Library and substantial sums to the Health Sciences Library annually for more than 25 years. He was instrumental in developing the Danville chapter of the Virginia Museum and served as its first director. He and Rebecca established a scholarship at the Danville Community College, and he made many generous bequests to the Department of Otolaryngology.

He reported on cerebral air embolism following antral irrigation in 1941 and was probably the first to do so. He wrote extensively on congenital choanal atresia, and his contribution of the McGovern nipple saved the lives of many infants. Although he wrote many articles on medical history, he was most interested in facial nerve function and paralysis, and he authored some 27 papers on this subject alone. He was one of the first to be more concerned with the cause than the treatment of facial paralysis, and his theories that allergy or immunological aberrations are the basic cause of Bell's palsy are now gaining increasing acceptance. Scientific data are being amassed to support these theories.


Francis McGovern was a member of all major otolaryngology societies, including the senior societies of the Triological, the American Laryngological Association, and the American Otological Society, Inc. These last two societies are limited to 100 members each.

The group to which Francis belonged that made me most happy was the faculty of the Department of Otolaryngology-Head and Neck Surgery of the University of Virginia. This club is even more exclusive than the Otological or the Laryngological. There are only 21 members. Dr Fitz-Hugh did many fine things while he was chairman, but one of the finest was to convince Francis to join the clinical faculty. He did so in 1953, and Francis faithfully traversed the 130 miles from Danville to Charlottesville twice monthly for 32 years to teach, lecture, and research the facial nerve.

Francis McGovern was an outstanding individual: a fine otolaryngologist, a committed Christian, a gentleman with a sense of personal honor, and a wonderful friend.

He was most generous in his donations to the department, and his great love of books and learning was perpetuated in the Department of Otolaryngology-Head and Neck Surgery's library-conference-audiovisual room, which has been named for him.

R.W.C.



JOHN A. MURTAGH
1905-1986

John A. Murtagh, MD, was born in Webster, Massachusetts, on June 12, 1905. He died January 15, 1986. His career was marked by outstanding professional and personal accomplishments.

After his secondary education at LaSalle Academy in Providence, Rhode Island, he entered Brown University and graduated in 1930 with a BA. He entered the University of Michigan School of Medicine and achieved his MD in 1934. From 1934 to 1935 he held an internship at the Rochester General Hospital. He was a resident in otolaryngology at the Yale-New Haven Hospital from 1935 to 1938, and was an instructor in otolaryngology at the Yale School of Medicine from 1937 to 1938.

In 1938, John married Eleanor Jacot and began his career as Chief of Otolaryngology at the Hitchcock Clinic in Hanover, New Hampshire, which is associated with Dartmouth Medical School. He was certified by the American Board of Otolaryngology in 1940. While practicing otolaryngology at the Hitchcock Clinic, he progressed from Instructor to Professor of Otolaryngology at the Dartmouth Medical School. He served as consultant to the Veterans Administration Hospital in White River Junction, Vermont, and to the Springfield, Vermont hospital.

During his career in Hanover, he authored and coauthored many papers on laryngeal physiology

and disease. This research was done in his leisure time and was financed by donations from his friends. He carried out this research in addition to clinical responsibilities in a busy practice in this well-known medical center. His practice spanned the change in our specialty from the era of infections and sepsis through the years of reconstructive, conservative, antibiotic, corticosteroid, and microsurgical developments, and he kept his skills well adapted to these changes.

John's gentle understanding, his love of his fellow humans, professional expertise, wisdom, and tolerance earned him the Presidency of the New England Otolaryngological Society in 1954. He was Vice-President of the Triological Society in 1955 and Vice-President of the American Laryngological Association in 1968. Besides membership in these societies, he was a member of the American College of Surgeons, the American Medical Association, the American Broncho-Esophagological Association, and his county and state societies.

The warmth and caring that he extended to his friends was given also to his patients. Openness, honesty, and humor sheltered him from any thought of fault or recrimination regardless of the outcome of a case. Thus developed a patient-physician relationship seldom equaled. He treated his house staff with equality and respect, guided and taught them while extending trust and responsibility, but maintained personal control of his patients. Above all he preached and lived by the axiom "do not make the patient worse." *Primum non nocere*.

John served on the councils of the American Broncho-Esophagological Association and the Triological Society. He was a member of the Committee for Laryngeal Research of the American Academy of Ophthalmology and Otolaryngology, and also a member of the Communicative Science Study Section of the National Institutes of Health. In the middle 1960s for 3 years, he was on a panel reviewing National Institutes of Health grant applications in otolaryngology.


In his early years in New Hampshire, John owned and rode fine horses near his home. After retirement in 1970, he moved to Florida and was able to fulfill his love of golf. In late spring, summer, and early fall, however, he returned to old friends and old scenes in New Hampshire to enjoy these particular seasons of the year.

On occasions with friends, John could quote favorite poems and demonstrate his knowledge and enjoyment of classical literature. The beauties of nature were not lost on him. His humor, Irish wit, and concern for others endeared him to many who returned the friendship and affection he offered. He was a beloved physician in his community and enjoyed the personal respect and professional esteem of his peers, patients, and colleagues.

During the illness in his later years, his wife and daughter, to whom he was devoted, sustained and supported him, reflecting the love that he held for them. To those of us who touched his life, he con-

tributed much that will endure. He will be missed by many. John is survived by his wife, Eleanor, and his daughter, Mary Murtagh.

J.P.F.



John P. F. (John P. F.)

After his secondary education at Falmouth, Maine, he attended the University of Maine at Orono, where he received his B.S. degree in 1928. He then attended the University of Maine at Orono, where he received his M.D. degree in 1932. He then attended the University of Maine at Orono, where he received his M.D. degree in 1932.

After his secondary education at Falmouth, Maine, he attended the University of Maine at Orono, where he received his B.S. degree in 1928. He then attended the University of Maine at Orono, where he received his M.D. degree in 1932. He then attended the University of Maine at Orono, where he received his M.D. degree in 1932.

During his career in Hanover, he authored and co-authored many papers on larval physiology. He was a member of the American Society of Zoologists and the American Society of Physiological Zoologists. He was also a member of the American Society of Naturalists and the American Society of Limnology and Oceanography.

He was a member of the American Society of Zoologists and the American Society of Physiological Zoologists. He was also a member of the American Society of Naturalists and the American Society of Limnology and Oceanography.

ROSTER OF FELLOWS 1986

Date indicates year admitted to active fellowship. Attendance at meetings is shown by figures following each name. Asterisk indicates year paper was read. Year and asterisk in parentheses indicates coauthor of paper but not present at meeting.

Active Fellows — 95

- | | |
|--|---|
| <p>1974 Alford, Bobby R., 1200 Moursund Ave, Houston, TX 77025, 1974, '78, '80-'83, '85, '86.</p> <p>1969 Andrews, Albert H. Jr, 122 S Michigan Ave, Chicago, IL 60603, 1970-'74*-'83.</p> <p>1984 Applebaum, Edward L., 1855 W Taylor St, Chicago, IL 60612, 1984-'86.</p> <p>1975 Bailey, Byron J., Dept of Otolaryngol, UTMB, Galveston, TX 77550, 1975, '76*-'78, '81, '82, '84-'86.</p> <p>1970 Ballenger, John J., 723 Elm St, Winnetka, IL 60093, 1971-'86.</p> <p>1963 Baxter, James D., 687 Pine Ave West, Montreal, 112, P.Q. H3A 1A1, Canada 1963, '65*-'74, '76-'80, '82, '85, '86.</p> <p>1975 Biller, Hugh F., Mt Sinai Hosp, 100th St & Fifth Ave, New York, NY 10029, 1975-'77*, '78*, '79*, '80*, '81*, '82*, '83*, '84*, '85, '86*.</p> <p>1977 Blaugrund, Stanley M., 115 E 61st St, New York, NY 10021, 1977-'84*, '85, '86.</p> <p>1975 Boles, Roger, Dept of Otolaryngol, Univ of California, San Francisco, CA 94122, 1975-'82, '84-'86.</p> <p>1984 Bone, Robert C., 10666 N Torrey Pine Rd, La Jolla, CA 92037, 1984, '86*.</p> <p>1959 Brewer, David W., 1100 E Genesee St, Syracuse, NY 13210, 1959, '60*, '61, '62*, '63, '66, '70, '73, '74*, '77, '80, '81, '83, '85.</p> <p>1976 Briant, T. David R., St Michael's Hosp, 30 Bond St, Toronto, Ont M5B 1W8, Canada, 1976, '77, '78, '80-'82, '85, '86.</p> <p>1963 Bryce, Douglas P., O.P.D. Toronto General Hosp, Toronto, Ont M5G 1L7 Canada, 1963*, '64, '66*, '67*, '68*-'79*, '81, '83-'86.</p> <p>1979 Calcaterra, Thomas C., UCLA Med Ctr, Los Angeles, CA 90024, 1979, '85.</p> <p>1985 Canalis, Rinaldo F., 1000 W Carson St, Torrance, CA 90509, 1985.</p> <p>1976 Cantrell, Robert W., Univ of Virginia Med Ctr, Charlottesville, VA 22901, 1976, '77*-'80*-'82-'84*-'86.</p> <p>1968 Chandler, J. Ryan, 1700 NW 10th Ave, Miami, FL 33136, 1968, '69*-'79*-'82-'84*-'86.</p> <p>1985 Chodosh, Paul L., 800 Westminister Ave, Hillside, NJ 07205, 1985, '86.</p> <p>1967 Cocke, Edwin W. Jr, 920 Madison, Memphis, TN 38103, 1967-'70, '72, '74-'78, '80, '82, '84, '86.</p> <p>1964 Cody, Claude C. III, 7777 Southwest Freeway, Houston, TX 77074, 1964, '65, '67, '69, '71, '73, '77-'79, '81, '83-'85.</p> <p>1971 Cohen, Seymour R., 1300 N Vermont Ave, Los Angeles, CA 90027, 1971, '72*, '73*-'75*, '76*-'78*, '80*, '81*, '82*, '83*-'84*-'86*.</p> <p>1984 Crumley, Roger L., 350 Parnassus 501, San Francisco, CA 94117, 1984*, '86.</p> <p>1980 Cummings, Charles W., Dept of Otolaryngology, Univ of Washington, Seattle, WA 98195, 1980-'82*, '83*-'86.</p> | <p>1973 Dedo, Herbert H., Univ of California S.F., School of Med, 3rd and Parnassus, San Francisco, CA 94143, 1973*-'75*, '76*-'79*-'82*-'84*, '86*.</p> <p>1984 DeSanto, Lawrence W., 200 First St, Rochester, MN 55905, 1984.</p> <p>1976 Doyle, Patrick J., 1081 Burrard, Vancouver, BC, V6Z 1Y6, Canada, 1976, '77*, '80*, '81*, '84, '86.</p> <p>1973 Duvall, Arndt J. III, Univ of Minnesota Hosp, A-605 Mayo Memorial Bldg, Minneapolis, MN 55455, 1973*, '75-'78, '80, '81, '84, '86.</p> <p>1968 Farrior, Richard T., 505 DeLeon, Tampa, FL 33606, 1968-'70*, '72, '74, '76-'81, '84-'86.</p> <p>1964 Fearon, Blair, 308 Medical Arts Bldg, Toronto, Ont, M5R 2M8, Canada, 1964, '66-'71*, '72*, '73*, '74*-'78*-'81*, '82-'85*, '86.</p> <p>1982 Fee, Willard E., Jr, Stanford Medical Center, Stanford, CA 94305, 1982-'86.</p> <p>1970 Frazer, John P., 601 Elmwood Ave, Rochester, NY 14642, 1971-'82, '86.</p> <p>1977 Fredrickson, John M., Dept of Otolaryngology, Washington University, St Louis, MO 63110, 1977-'79*, '83-'86.</p> <p>1977 Gacek, Richard R., State Univ Hosp of the Upstate Med Ctr, 750 E Adams St, Syracuse, NY 13210, 1977*-'83*, '84*, '85, '86.</p> <p>1981 Gates, George A., 7703 Floyd Curl Dr, San Antonio, TX 78284, 1981, '82*-'85*, '86.</p> <p>1983 Goldstein, Jerome C., AAO-HNS, 1101 Vermont Ave NW, Washington, DC 20005, 1983-'86.</p> <p>1985 Goode, Richard L., Div of Otolaryngology R-135, Stanford Univ, Stanford, CA 94304.</p> <p>1985 Gross, Charles W., 266 S Cleveland #202, Memphis, TN 38104, 1985, '86.</p> <p>1983 Healy, Gerald B., 300 Longwood, Boston, MA 02115, 1983, '84*, '85*, '86.</p> <p>1983 Hicks, Julius N., 924 S 18th St, Birmingham, AL 35205, 1983, '84*-'86.</p> <p>1986 Holinger, Lauren D., 155 N Michigan Ave, Suite 325, Chicago, IL 60601, 1986.</p> <p>1974 Hudson, William R., Duke Univ Med Ctr, ENT, POP, 3805, Durham, NC 27710, 1974-'78*, '81-'86.</p> <p>1983 Jako, Geza J., 8 Porter St, Melrose, MA 02176, 1983, '85.</p> <p>1983 Johns, Michael E., Dept of Otolaryngology-Head and Neck Surgery, Johns Hopkins Hosp, 600 N Wolfe St, Baltimore, MD 21205, 1983, '84*-'86.</p> <p>1985 Kashima, Haskins K., 5300 St Albans Way, Baltimore, MD 21212, 1985, '86*.</p> <p>1975 Kirchner, Fernando R., 155 S 18th St, Kansas City, KS 66102, 1975*-'77, '79, '82*, '84, '86.</p> <p>1979 Krause, Charles J., Univ Hosp, Ann Arbor, MI 48109, 1979-'82*, '84-'86.</p> <p>1981 Lawson, William, 19 E 98th St, New York, NY 10029, 1981*-'84*, '86*.</p> |
|--|---|

- 1979 LeJeune, Francis E. Jr, 1514 Jefferson Hwy, New Orleans, LA 70121, 1979-'82*, '83*-'86.
- 1966 Lewis, John S., 428 W 59th St, New York, NY 10019, 1966-'69*, '72, '74-'76*, '78-'83*-'86.
- 1976 Lingeman, Raleigh E., Riley Hosp, 702 Barnhill Rd, Indianapolis, IN 46223, 1976, '77*-'82*, '84, '86.
- 1973 Loré, John M. Jr, 2121 Main St, Buffalo, NY 14214, 1974*, '76, '77*, '78*, '81, '85, '86.
- 1978 Lyons, George D., 120 N Jefferson Davis Pkwy, New Orleans, LA 70119, 1978-'80, '82-'84.
- 1966 McCabe, Brian F., Dept of Otolaryngol, Univ Hosp, Iowa City, IA 52242, 1966, '69, '72*, '73, '75*, '76, '79*, '81*, '85, '86*.
- 1976 Miglets, Andrew, 456 Clinic Dr, Rm 4118, Columbus, OH 43210, 1976-'78*, '80, '82, '85.
- 1952 Miller, Alden H., 1407 N Vermont Ave, Los Angeles, CA 90027, 1952, '53*, '55, '57, '58*, '61, '62, '64, '66, '67*-'73*, '74*, '76-'78*, '79, '81, '85.
- 1964 Montgomery, William W., 100 Charles River Plaza, Boston, MA 02114, 1964, '65*, '66*, '68*, '70-'72, '74*-'76*-'78, '80*-'82, '84-'86.
- 1986 Morrison, Murray D., 865 W 10th Ave, Vancouver, BC V5Z 1L7, Canada, 1986.
- 1979 Myers, Eugene N., Dept of Otolaryngol, 230 Lothrop St, Pittsburgh, PA 15213, 1979, '80, '82*-'86.
- 1981 Neel, H. Bryan III, 200 First St, SW, Rochester, MN 55905, 1981, '82*-'85*, '86.
- 1980 Nichols, Richard D., Henry Ford Hosp, 2799 W Grand, Detroit, MI 48202, 1980, '81, '84.
- 1986 Noyek, Arnold M., 99 Avenue Rd, Suite 207, Toronto, Ont M5R 2G5, Canada, 1986.
- 1982 Olson, Nels R., St Joseph Mercy Hospital, P O Box 944, Ann Arbor, MI 48106, 1982, '83*, '85.
- 1972 Pennington, Claude L. Jr, 800 First St, Macon, GA 31201, 1972, '73, '75, '76*, '78, '82-'86.
- 1967 Pratt, Loring W., 325-B Kennedy Memorial Dr, Waterville, ME 04901, 1967-'82, '84*-'86.
- 1963 Reed, George F., 750 E Adams St, Syracuse, NY 13210, 1963, '65*, '66, '68, '69*-'73, '75-'82*-'86.
- 1985 Rice, Dale H., 1245 Wilshire Blvd, #606, Los Angeles, CA 90017, 1985, '86.
- 1974 Ritter, Frank N., 2675 Englave Dr, Ann Arbor, MI 48103, 1974, '75, '77-'79, '81-'86.
- 1982 Rontal, Eugene, 21700 Northwestern Highway, Southfield, MI 48075, 1982, ('83*), '84*, '86*.
- 1981 Sasaki, Clarence T., 333 Cedar St, New Haven, CT 06510, 1981, '83, '85, '86.
- 1964 Saunders, William H., Ohio State Univ, Rm 3110, 456 Clinic Dr, Columbus, OH 43210, 1964-'66, '68*-'70*-'75*-'80, '82*-'84, '86.
- 1984 Schild, Joyce A., Illinois Eye and Ear Inf, 1855 W Taylor St, Chicago, IL 60612, 1985*, '86.
- 1978 Sessions, Donald G., 1960 Grassy Ridge Rd, Kirkwood, MO 63122, 1979*, '80*, '81, '83, '84, '86.
- 1983 Sessions, Roy B., Memorial Sloan-Kettering Cancer Center, 425 E 67th St, New York, NY 10021, 1983*, '86.
- 1979 Shapiro, Myron J., 101 Old Short Hills Rd, West Orange, NJ 07052, 1979-'81, '84, '86.
- 1962 Sisson, George A., Northwestern U Medical School, 303 E Chicago Ave, Chicago, IL 60611, 1962, '63*, '65, '66, '68-'73, '76-'82, '84*, '85*, '86.
- 1964 Skolnik, Emanuel M., 1855 W Taylor St, Chicago, IL 60612, 1964*-'66*-'70*-'73, '75*-'80*-'82*, '85, '86*.
- 1974 Snow, James B. Jr, Univ of Pennsylvania, 3400 Spruce St, Philadelphia, PA 19104, 1974-'75*-'78*, '79, '81-'86.
- 1972 Soboroff, Burton J., 307 N Michigan Ave, Chicago, IL 60601, 1972-'77, '79, '80, '82, '86.
- 1973 Som, Max L., 121 E 60th St, New York, NY 10022, 1973, '74*, '75*-'78*, '79*, '80, '82, ('83*).
- 1979 Spector, Gershon J., Dept of Otolaryngol, 517 S Euclid, St Louis, MO 63110, 1979-'85.
- 1975 Sprinkle, Philip M., West Virginia Univ Med Ctr, Morgantown, WV 26505, 1975-'78*-'82, '84-'86.
- 1975 Strong, M. Stuart, Bedford VA Hosp., 200 Spring St, Bedford, MA 01730, 1975, '76*-'78*, '79*, '81, '82*-'84*-'86*.
- 1963 Tabb, Harold G., Dept of Otolaryngol, Tulane Medical School, New Orleans, LA 70112, 1963, '65-'69, '71, '72, '74, '77-'84, '86.
- 1979 Tardy, M. Eugene, 2913 N Commonwealth, No 430, Chicago, IL 60657, 1979, '82*, '84, '86.
- 1982 Thawley, Stanley E., 517 S Euclid, St Louis, MO 63110, 1982, '83*.
- 1978 Toomey, James M., 101 Tremont St, Suite 805, Boston, MA 02108, 1979*-'81.
- 1970 Tucker, Gabriel F. Jr, The Children's Memorial Hosp, 2300 Children's Plaza, Chicago, IL 60614, 1970*-'73*-'74*-'75*-'77*-'78*-'82*-'85*, '86.
- 1979 Tucker, Harvey M., Dept of Otolaryngol, Cleveland Clinic, Cleveland, OH 44106, 1979, '80*-'82*, '84*, '85*, '86*.
- 1973 Tucker, John A., St Christopher's Hosp, 2600 N Lawrence St, Philadelphia, PA 19133, 1973*, '74*, '75*-'77*, '78*, '80-'85*, '86.
- 1984 Vaughan, Charles W., Veterans Adm Med Center, 150 S Huntington Ave, Boston, MA 02130, 1984-'86.
- 1980 Vrabec, Donald P., Dept of Otolaryngol, Geisinger Med Ctr, Danville, PA 17821, 1980, '81*, '83, '86.
- 1974 Ward, Paul H., UCLA School of Medicine, Los Angeles, CA 90024, 1974*-'77*, '78*, '79*, '81*, '82*, '83*, '84*, '85, '86*.
- 1951 Woodman, DeGraaf, P O Box 560, Easton, MD 21601, 1952-'55*-'76*-'86.
- 1981 Yanagisawa, Eiji, 98 York St, New Haven, CT 06511, 1981, '82*, '83*-'85*.
- 1983 Yarrington, C. Thomas Jr, 1100 9th Ave, POB 900, Seattle, WA 98111, 1983, '84*-'86.

Honorary Fellows — 9

- 1978 (1959) Barretto, Plinio de Mattos, Rua Cons Torres, Homen 371, Sao Paulo, Brazil, 1960, '69, '73, '80.
- 1957 (1925) Clerf, Louis H., 10300 4th St, North, St Petersburg, FL 33702, 1957-'61, '63-'66, '68-'72*-'78.
- 1984 (1957) Conley, John J., 211 Central Park West, New York, NY 10024, 1958*, '60*-'62*, '64, '65, '70, '72, '74*, '75*-'78, '80, '82, ('83*)-'86.
- 1984 (1960) Daly, John F., 16 N Brae Ct, Tenafly, NJ 07670, 1960, '61*, '79*, '81.
- 1986 Gould, Wilbur J., 47 E 77th St, New York, NY 10021.
- 1978 (1971) Harrison, D. F. N., 330/332 Gray's Inn Road, London, WC1X 8EE, United Kingdom, 1971, '77, '81*, '84*-'86*.
- 1984 (1956) Norris, Charles M., 3401 N Broad St, Philadelphia, PA 19140, 1956-'58*-'61*-'64, '66-'68*-'70*-'78*-'86.

- 1966 (1957) Ono, Jo, 6-13, 6-Chome, Roppongi, Minato-Ku, Tokyo, 106, Japan, 1971, ('85*), ('86*).
- 1968 (1957) Ruedi, Prof Dr Luzius, Zollikerstrasse 185, 8008 Zurich, Switzerland, 1957.

Corresponding Fellows — 22

- 1985 Aprigliano, Flavio, Rua Terezina 19, ZC-45 20,000 Rio de Janeiro, Brazil, 1985.
- 1978 Arauz, Juan Carlos, 2150 Cangallo, Buenos Aires, 1040 Argentina, 1980, '85*.
- 1972 Arslan, Prof Michele, Otorinolaringoiatrica dell' Università da Padova, 37 Via Altinate, Padova, Italy, 1972.
- 1959 Bateman, Sir Geoffrey H., Thorney-Graffham, Petworth, West Sussex, GU280EA United Kingdom.
- 1980 Benjamin, Bruce, 229 Macquarie St, Sydney, NSW 2000 Australia, 1980, '81, '83*, '84*, '85*.
- 1964 Cleves, Carlos, Apt 202, Carrea 14, No 44-54, Bogota, Colombia.
- 1984 Evans, John N. G., 5 Lancaster Ave, London SE27, United Kingdom, 1985*.
- 1986 Ferlito, Alfio, Dept of Otolaryngol, Univ of Padua, Padua, Italy, 1986*.
- 1986 Fonseca, Rolando, Rioja 3920, La Lucila, Buenos Aires, Argentina.
- 1970 Halliday, Sir George C., 141 Macquarie St, Sydney, 2000 NSW, Australia.
- 1984 Hirano, Minoru, Dept of Otolaryngol and Head and Neck Surg, Kurume Univ, 67 Asaki-machi, Kurume-shi 830, Japan, 1985*, '86*.
- 1970 Hutcheon, Jack, Morris Towers, 149 Wickham Terrace, Brisbane, 4000 Australia, 1971, '78, '80.
- 1985 Inouye, Tetsuzo, Dept of Otolaryngology, National Defense Med College, Tokorozawa, Saitama, 359, Japan, 1985.
- 1978 Kleinsasser, Oskar, Deutschhausstrasse 3, 355 Marburg (Lahn), Cologne, West Germany, 1982*.
- 1971 Macbeth, Ronald G., Meadow Close, Church Hanborough, Oxford, United Kingdom.
- 1985 Murakami, Yasushi, Keio Univ Sch of Med, 35 Shinanomachi, Shinjuku-Ku, Tokyo, 160, Japan, 1985*, '86*.
- 1968 Nakamura, Fumio, Kyoto Prefectural U Medicine, Kawaramachi 1, Kamikyo-Ku, Kyoto, Japan.
- 1964 Perez, Alfredo C., Instituto Celis Perez, Avenida Montes Deoca, Valencia, Venezuela, 1965.
- 1985 Shaw, Henry J., Royal Marsden Hosp, Fulham Rd, London SW3 6JJ, United Kingdom, 1986.
- 1984 Snow, Gordon B., Dept of Otolaryngology, Free Univ, DeBodolaan 1117, 1007 MB, Amsterdam, Netherlands, 1983*, '85, '86*.
- 1952 Tapia-Acuña, Ricardo, Av Insurgentes, Sur No. 300, Delegación Cuauhtemoc 06700, Mexico 7 DF Mexico, 1953, '57, '60*, '67, '73, '75, '81*.
- 1936 Vialle, Jacques, 27 Rue de France, Nice (Alpes Maritimes), France.
- 1986 (1955) Bordley, John E., John Hopkins Hosp, Baltimore, MD 21205, 1955-'57, '59, '60, '62-'67, '69-'73*-'80, '82, '83, '85*, '86.
- 1986 (1955) Brown, Lester A., 490 Peachtree St, NE, Atlanta, GA 30308, 1955-'59, '61, '63, '65, '68-'73*-'80, '82.
- 1965 (1942) Canfield, Norton, PO Box 1383, Miami, FL 33133, 1982, '84.
- 1977 (1951) Davison, Francis W., Geisinger Med Ctr, Danville, PA 17821, 1951-'53*-'63*-'67*-'69*-'73*-'75, '77, '78*, '79.
- 1985 (1966) Devine, Kenneth D., Mayo Clinic, Rochester, MN 55905, 1966-'68, '72*, '74*, '76*.
- 1980 (1968) DeWeese, David D., 3181 SW Sam Jackson Park Rd, Portland, OR 97202, 1968-'69*, '73-'80, '82.
- 1972 (1962) Erich, John B., Mayo Clinic, 200 Second Ave, Rochester, MN 55905.
- 1982 (1963) Ferguson, Charles R., 5281 Cape Leyte Way, Siesta Key, Sarasota, FL 33581, 1963, '64*, '66, '67*-'69*-'74*-'78*-'82.
- 1983 (1956) Friedberg, Stanton A., 1725 W Harrison St, Chicago, IL 60612, 1956, '57, '65*, '71*, '76*, '78*, '79*, '80, '82, '83*-'85.
- 1985 (1959) Goldman, Joseph L., 55 E 87th St, New York, NY 10028, 1959, '60*-'72*-'78*-'80, '82-'84.
- 1963 (1928) Goodyear, Henry M., 2012 Edgecliff Point, Cincinnati, OH 45206.
- 1980 (1965) Hanckel, Richard W. Jr, 506 E Cleves, Florence, SC 29501, 1965-'67, '69-'74, '77-'80.
- 1978 (1960) Harris, Herbert H., 3457 Meadow Lake Lane, Houston, TX 77027, 1960, '61*-'65*-'75, '77-'79, '81-'84, '86.
- 1968 (1942) Heatley, Clyde A., 2500 East Ave, Rochester, NY 14610, 1942, '46*, '49, '50, '52-'53*-'55, '57, '58, '60, '61, '65.
- 1978 (1959) Henry, G. Arnold, Suite #2, Group Box 24, Lagoon City, RR #1, Brechin, Ont, L0K 1B0, Canada, 1959, '61, '63, '66, '67, '69, '70, '73.
- 1980 (1955) Hilger, Jerome A., 1700 S Lexington, St Paul, MN 55118, 1955-'56*-'60, '62-'66, '68-'71, '75-'78, '80, '82.
- 1977 (1957) Holmes, Edgar M., Graydale Circle, Auburndale, MA 02166, 1957, '59, '61, '63, '68, '70-'72, '74-'76, '80.
- 1985 (1965) King, James T., 1890 W Paces Ferry Rd, Atlanta, GA 30327, 1965-'67, '69-'71, '73-'76, '80, '85.
- 1985 (1963) Kirchner, John A., 333 Cedar St, New Haven, CT 06510, 1963, '65*, '67*-'69*-'71*-'75*, '77, '78, '80*, '82-'84*-'86.
- 1983 (1961) Lewy, Robert B., 25 E Washington, Chicago, IL 60602, 1961, '62*, '63, '65*, '67-'71, '73-'76*, '82, '83*-'86.
- 1974 (1951) McHenry, Lawrence C., 1607 Glenbrook Terrace, Oklahoma City, OK 73116, 1953*, '62-'66, '68, '71.
- 1984 (1965) Miller, Daniel, 110 Francis St, Boston, MA 02215, 1965-'69*-'73*-'77*-'81*-'82*-'86.
- 1985 (1972) Morse, Harry R., The Mooring, MTD #9, Middleboro, MA 02346, 1972, '75, '79-'81.
- 1978 (1957) Munoz-MacCormick, Carlos Eduardo, 71 de Diego, Santurce, PR 00911, 1957-'80, '82-'84.
- 1981 (1958) O'Keefe, John J., 1499 Monk Rd, Gladwyn, PA 19035, 1958-'59*, '60, '62, '64, '67, '71, '73, '75, '78.
- 1984 (1961) Pang, Lup Q., 1374 Nuuanu Ave, Honolulu, HI 96817, 1961, '62*, '64, '66, '67, '69, '71-'73, '75, '77, '79-'82.

Emeritus Fellows — 44

- 1980 (1962) Arnold, Godfrey E., 311 Clinton Blvd, Clinton, MS 39056, 1962, '63*, '64*, '66, '69, '70, '72, '73, '75, '77, '79.
- 1984 (1969) Ausband, John R., Emory Univ, 1365 Clifton Rd, NE, Atlanta, GA 30322, 1970-'73, '75, '78, '81.
- 1973 (1944) Boies, Lawrence R., 410 Cottage Downs, Hopkins, MN 55343, 1944, '46-'48*, '50, '51*, '53-'68*-'69, '71.

- 1984 (1961) Pastore, Peter N., 5503 Riverside Dr, Richmond, VA 23225, 1961, '62*, '64, '66, '67, '69-'76, '78, '80, '82, '86.
- 1976 (1951) Priest, Robert E., 48 Grovecand Terrace, Minneapolis, MN 55403, 1977-'81.
- 1980 (1951) Putney, F. Johnson, 705 Knotty Pine Rd, Charleston, SC 29412, 1951-'53*-'58*-'63*-'64*-'68*-'69*-'70*-'72, '74-'78*, '79*, '82, '86.
- 1972 (1956) Richardson, John R., PO Box 52, Searsport, ME 04974.
- 1981 (1959) Sanders, Sam H., 1286 Peabody Ave, Memphis, TN 38104, 1959-'63, '65, '70-'73, '75, '78, '85.
- 1977 (1958) Simonton, Kinsey M., 951 Holly Ln, Boca Raton, FL 33432, 1958, '59*, '62, '64, '66, '67, '69, '72, '74, '75, '78, '82, '84.
- 1969 (1950) Smith, Austin T., 8401 Roosevelt Bldg, Philadelphia, PA 19152, 1970-'74.
- 1986 (1954) Sooy, Francis A., Univ of California Hosp, 3rd & Parnassus Ave, San Francisco, CA 94122, 1954, '56*, '58, '60, '62-'65*, '67, '68*, '71, '78, '79, '81, '83-'86.
- 1982 (1961) Suehs, Oliver W., 2805 Robbs Run, Austin, TX 78703, 1961, '62*-'64, '66, '68-'72, '74-'78, '80.
- 1983 (1954) Thornell, William C., 2328 Auburn Ave, Cincinnati, OH 45219, 1957, '59, '63, '68, '70, '72, '74, '77, '78, '80.
- 1973 (1963) Tolan, John F., 3419 47th Ave, NE, Seattle, WA 98105, 1963-'67, '69, '71, '73.
- 1961 (1941) Viole, Pierre P., 241 S Windsor, Los Angeles, CA 90004, 1964.
- 1977 (1962) Weaver, Delmar F., Med Professional Bldg, PO Box 862, Culpepper, VA 22701, 1962-'64*, '65, '67*, '69-'70, '72, '74, '76.
- 1983 (1971) Williams, Russell I., 414 E 23rd St, Cheyenne, WY 82001, 1971, '72*-'74, '76-'78*, '80.
- 1975 (1953) Work, Walter P., 172 E Paseo de Golf, Green Valley, AZ 85614, 1953, '54, '56, '58, '59*, '62, '63*, '65, '67-'69, '72, '73, '75, '76, '78*, '79*, '82.

OFFICERS 1986-1987

≈

PRESIDENT

LORING W. PRATT, MD

VICE-PRESIDENT (PRESIDENT-ELECT)

BLAIR FEARON, MD

SECRETARY

EUGENE N. MYERS, MD

TREASURER

JOHN M. FREDRICKSON, MD

HISTORIAN-EDITOR

JAMES B. SNOW, JR, MD

FIRST COUNCILOR

JOHN S. LEWIS, MD

SECOND COUNCILOR

GABRIEL F. TUCKER, JR, MD

THIRD COUNCILOR

DOUGLAS P. BRYCE, MD

COUNCILORS-AT-LARGE

HUGH F. BILLER, MD

JOHN A. TUCKER, MD

INDEX

AUTHORS

A
Alberti PW156
Aufdemorte TB102

B
Balm AJM66
Becker SP160
Biller HF80, 156
Birt D135
Bone RC145
Brito-Filomeno L76
Brodaric I149
Bryce DP12
Bumstead RM158

C
Cohen SR41
Cooper JD76

D
Dankle SK120
Dedo HH21

E
Elson L30

F
Farrior RT158
Fearon B155
Ferlito A84
Fredrickson JM9

G
Gentile RD116
Guerry TL21
Gullane PJ149

H
Harrison DFN35
Havas TE149

Hirano M70
Holt GR102

I
Ikari T130

J
Johns ME8

K
Karim ABMF66
Kashima H97
Keller A149
Kirchner JA159
Kiyokawa K70
Kuhajda F97
Kurita S70

L
Lawson W80
Liu C61
Loury M97
Lusk RP125

M
McCabe BF125
McClead RE120
Miller D158, 160
Miller RH118, 160
Mixon JH125
Morrison MD159
Mounts P97
Murakami Y130
Myers EN8

N
Njo KH66
Noyek AM159

O
Ono J130
Ossoff RH155

P
Pearson B156
Pearson FG76
Pleet L61

R
Robb JA145
Rontal E30
Rontal M30

S
Saito S130
Sato K70
Schuller DE120
Sheridan PJ102
Shulman HS149
Silverman S Jr21
Sisson GA155, 157
Skolnik EE15, 158
Snow GB66
Snow JB Jr8
Strong MS154

T
Thompson JW41
Tiwari RM66
Tucker HM112

V
Van Nostrand AWP95, 160, 161
Vaughan CW155, 156
Versluis RJJ66

W
Ward PH61, 157
Weisberg V80
Wenokur ME30
Woodson GE116

SUBJECTS

A
Aging
 Estrogen receptor in larynx of aged baboon102
Anesthesia
 Anesthetic management for tracheobronchial
 laser surgery30
Annual photograph4
Awards (Casselberry, De Roaldes, Newcomb)11

C
Carcinoma — classification
 Immunocytochemistry: diagnosis of
 histologically ambiguous lesions145
Carcinoma — interferon treatment
 Three-year experience of treating recurrent
 respiratory papilloma with interferon125
Carcinoma — larynx
 Clinical and computed tomographic correlations
 of pharyngolaryngeal cancer with whole
 organ serial sections149

Demonstration of human papillomavirus
 capsid antigen in carcinoma in situ
 of larynx97
Diagnosis and treatment of small cell
 carcinoma of larynx84
Imbrication reconstruction following
 partial laryngectomy61
Incidence of large saccules in laryngectomy
 specimens135
Carcinoma — monoclonal antibodies
 Demonstration of human papillomavirus
 capsid antigen in carcinoma in situ
 of larynx97
 Quiet revolution. Techniques of cell
 biology applied to tissue diagnosis95
Carcinoma — oral cavity
 Carbon dioxide laser resection of superficial
 oral carcinoma21
Chemotherapy
 Long-term results of concurrent
 polychemotherapy and radiotherapy in
 patients with stomal recurrence after

- total laryngectomy 21
- Three-year experience of treating recurrent
respiratory papilloma with interferon 125
- Computed tomography
Clinical and computed tomographic
correlations of pharyngolaryngeal cancer
with whole organ serial sections 149
- D**
- Discussions 155
- E**
- Executive Sessions
Minutes 7
Reports 8
- F**
- Fellows
Registration 5
Roster 165
- G**
- Glottis. *See* Larynx.
- Guest of Honor
Address 15
Introduction 14
- H**
- Human papillomavirus
Demonstration of human papillomavirus
capsid antigen in carcinoma in situ of larynx ... 97
- I**
- Immunocytochemistry — tumors
Demonstration of human papillomavirus
capsid antigen in carcinoma in situ of larynx ... 97
Diagnosis of histologically ambiguous lesions
of head and neck 145
Quiet revolution. Techniques of cell biology
applied to tissue diagnosis 95
- L**
- Larynx
Estrogen receptor in larynx of aged baboon 102
Posterior glottis. Morphological study in
excised human larynges 70
Victor Negus: 57 years later 35
- Larynx — pathology
Incidence of large saccules in laryngectomy
specimens 135
Long-term results of concurrent
polychemotherapy and radiotherapy in
patients with stomal recurrence after
total laryngectomy 66
Lymphangiomas of larynx in infants and
children 41
Risk factors for neonatal acquired subglottic
stenosis 120
Vocal cord paralysis in children 1 year of age
and younger 116
Vocal cord paralysis in small children:
principles in management 112
See also Carcinoma — larynx.
- Larynx — surgical procedures
Experience with partial cricoid resection and
thyrotracheal anastomosis 76
Imbrication reconstruction following
partial laryngectomy 61
Staged repair of extensive tracheal and
laryngotracheal stenoses 80
- Laser, carbon dioxide
Anesthetic management for tracheobronchial
laser surgery 30
Carbon dioxide laser resection of
superficial oral carcinoma 21
- Lymphangioma
Lymphangiomas of larynx in infants and
children 41
- M**
- Memorial Fund, Laryngological Research Fund 11
- Memorials
Francis H. McGovern 162
John A. Murtagh 163
- N**
- Negus, Victor
57 years later 35
- O**
- Officers
1985-1986 5
1986-1987 169
- Oral cavity
Carbon dioxide laser resection of superficial
oral carcinoma 21
- P**
- Presidential Remarks 12
- R**
- Reports
Governor, American College of Surgeons 8
Historian-Editor 8
Secretary 8
Treasurer 9
- Radiotherapy
Long-term results of concurrent
polychemotherapy and radiotherapy in
patients with stomal recurrence after
total laryngectomy 66
- Reconstruction surgery
Experience with partial cricoid resection and
thyrotracheal anastomosis 76
Imbrication reconstruction following partial
laryngectomy 61
New technique of soft palate reconstruction
using a hypopharyngeal myomucosal flap ... 130
Staged repair of extensive tracheal and
laryngotracheal stenoses 80
- S**
- Saccules
Incidence of large saccules in laryngectomy
specimens 135
- Soft palate
New technique of soft palate reconstruction
using a hypopharyngeal myomucosal flap ... 130
- Speech disorder. *See* Vocal fold.
- Stenosis
Endoscopic management of laryngeal stenosis
with carbon dioxide laser (abstract only) 154
Risk factors for neonatal acquired subglottic
stenosis 120
Staged repair of extensive tracheal and
laryngotracheal stenoses 80

T

Trachea

- Anesthetic management for tracheobronchial laser surgery 30
- Experience with partial cricoid resection and thyrotracheal anastomosis 76
- Staged repair of extensive tracheal and laryngotracheal stenoses 80

Tracheostomy

- Long-term results of concurrent polychemotherapy and radiotherapy in patients with stomal recurrence after total laryngectomy 66

V

Vocal fold

- Vocal cord paralysis in children 1 year of age and younger 116
- Vocal cord paralysis in small children 112

iation Vol. 107 (1986)

