TRANSACTIONS

AMERICAN LARYNGOLOGICAL ASSOCIATION

1987

VOLUME ONE HUNDRED EIGHT

"DOCENDO DISCIMUS"

≈

ONE HUNDRED EIGHTH ANNUAL MEETING

FAIRMONT HOTEL

DENVER, COLORADO

APRIL 25 AND 26, 1987

≈

PUBLISHED BY THE ASSOCIATION
ST LOUIS, MISSOURI
JAMES B. SNOW, JR, MD, Editor

CONTENTS

Annual Photograph 4

Officers for 1986-1987 5

Registration of Fellows 5

Minutes of Executive Sessions 6

Reports
- Historian-Editor, James B. Snow, Jr, MD 7
- Governor, American College of Surgeons, Michael E. Johns, MD 7
- Treasurer, John M. Fredrickson, MD 8
- Liaison Director, American Board of Otolaryngology, Eugene N. Myers, MD 9

Recipients of De Roaldes, Casselberry, Newcomb, and Gabriel F. Tucker Awards 11

The Memorial and Laryngological Research Funds 12

Presidential Remarks. Loring W. Pratt, MD 13

Introduction of Guest of Honor John S. Lewis, MD. Loring W. Pratt, MD 18

Guest of Honor Address. John S. Lewis, MD 20

Biography of Gabriel F. Tucker, Sr. John A. Tucker, MD 21

Presentation of Gabriel F. Tucker Award to Seymour R. Cohen, MD. Loring W. Pratt, MD 23

Response of Recipient of Gabriel F. Tucker Award. Seymour R. Cohen, MD 24

SCIENTIFIC SESSIONS

Histochemical Study of Posterior Cricoarytenoid Muscle Reinnervation by a Nerve-Muscle Pedicle in the Cat
Joseph J. Fata, MD; Leslie T. Malmgren, PhD; Richard R. Gacek, MD; Richard Dum, PhD; Peak Woo, MD 29

Acquired Subglottic Stenosis in Children
Francis I. Catlin, MD, ScD; Richard J. H. Smith, MD 38

Phonatory Effects of Thyroid Cartilage Fractures
Robert B. Stanley, Jr, MD, DDS; Donald S. Cooper, PhD; Steven H. Florman, MD 43

Thirteenth Daniel C. Baker, Jr, Memorial Lecture
Monoclonal Antibodies: The Coming Revolution in Diagnosis and Treatment of Human Disease
Brandon J. Price, PhD 47

Congenital Laryngeal Anomalies Associated With Tracheal Agenesis
Lauren D. Holinger, MD; Mark S. Volk, DMD; Gabriel F. Tucker, Jr, MD 55

Adjunctive Measures for Successful Laryngotracheal Reconstruction
Steven Gray, MD; Robert Miller, MD; Charles M. Myer III, MD; Robin T. Cotton, MD 59

Correlation of Tumor Volume With Local Control in Laryngeal Carcinoma Treated by Radiotherapy
Ralph W. Gilbert, MD; Derek Birt, MB; Harry Shulman, MD; Jeremy Freeman, MD; Derek Jenkin, MB; Robert MacKenzie, MD; Charles Smith, MD 64

Cricothyroidotomy: A Decade of Experience in Denver
Barbara A. Esses, MD; Bruce W. Jafek, MD 69

Telescopic Endolaryngeal Surgery
John M. Loré, Jr, MD 75

Unusual Pharyngeal Lesion Causing Dysphagia
Kathryn K. Obana, MD; Willard E. Fee, Jr, MD 77

Vocal Nodules in Children
Bruce Benjamin, FRACS, FAAP; Glen Croxson, FRACS 80

Use of Botulinum Toxin to Lateralize True Vocal Cords: A Biochemical Method to Relieve Bilateral Abductor Vocal Cord Paralysis
Seymour R. Cohen, MS, MD; Jerome W. Thompson, MD 84

Malignant Laryngeal Epithelial Tumors and Lymph Node Involvement: Therapeutic and Prognostic Considerations
Alfio Ferlito, MD 92

Phonatory Airflow Analysis in Patients With Laryngeal Disease
Peak Woo, MD; Raymond H. Colton, PhD; Lee Shangold, MD 99

Laser Resection for Early Oral Cavity Cancer. Results and Complications
Matthew J. Nagorsky, MD; Donald G. Sessions, MD 106

Management of Patients With Long-Term Tracheotomies and Aspiration
Ralph W. Gilbert, MD; Douglas P. Bryce, MD; Jeff C. McIlwain, MD; Ian R. Ross, MD 111

Conradi-Hunerman Syndrome. Case Report
Marcelo Hochman, MD; Willard E. Fee, Jr, MD 115

Selective, Histamine-Mediated Immunosuppression in Laryngeal Cancer
William J. Richtsmeier, MD, PhD; Peter Styczynski; Michael E. Johns, MD 119

Human Speech Development for an Implantable Artificial Larynx
Colin Painter, PhD; Timothy Kaiser, MD; John M. Fredrickson, MD; Roanne Karzon, PhD 123

Selection of Video Cameras for Stroboscopic Videolaryngoscopy
Eiji Yanagisawa, MD; Frederick Godley, MD; Hiroshi Muta, MD 128

Vocal Function Following Hemilaryngectomy
Minoru Hirano, MD; Shigejiro Kurita, MD; Hidetaka Matsuoka, MD 136

Treatment of Spastic Dysphonia Without Nerve Section
Michael Friedman, MD; Dean M. Toriumi, MD; Vytenis Grybauskas, MD;
Edward L. Applebaum, MD 140

Vocal Ligametry. Update
Francis E. LeJeune, Jr, MD 147

Side Effects and Toxicity of Interferon in the Treatment of Recurrent
Respiratory Papillomatosis
Dennis M. Crockett, MD; Brian F. McCabe, MD; Rodney P. Lusk, MD;
Janis Horne Mixon, RN 151

Nasopharyngeal Carcinoma: The Dana-Farber Cancer Institute Experience With 24
Patients Treated With Induction Chemotherapy and Radiotherapy
John R. Clark, MD; Charles M. Norris, Jr, MD; Arnon I. Dreyfuss, MD;
Barbara G. Fallon, MD; Karoly Balogh, MD; Roger F. Anderson, Jr, MD;
John T. Chaffey, MD; Janet W. Andersen, MS; Daniel Miller, MD 158

Technique for External Mobilization of the Vocal Cord With Silastic Implant
J. Ramón Escajadillo, MD 165

Is Chronic Gastroesophageal Reflux a Causative Factor in Glottic Carcinoma
Murray D. Morrison, MD, FRCS(C) 170

Conservation Laryngectomy
Gui-yi Tu, MD 174

Routine Bronchoscopy and Bronchial Cytology for Detection of Occult Pulmonary Cancers in Patients
With Squamous Carcinoma of the Upper Aerodigestive Tract
David B. Hom, MD; Gregory T. Wolf, MD; Theodore F. Beals, MD; Charles J. Krause, MD 177

Laser Surgical Treatment of Chronic Tonsillitis
Geza J. Jako, MD 181

Vocal Tract Electromyographic Abnormalities in Spasmodic Dysphonia. Preliminary Report
Steven Schaefer, MD; Ben Watson, PhD; Frances Freeman, PhD; George Kondraske, PhD;
Kenneth Pool, MD; Lanny Close, MD; Terese Finitzo, PhD 187

New Technique for Diagnosing Movement Disorders of the Larynx: Transmucosal Stimulation
of the Laryngeal Muscles*
I. Sanders, MD; W. Kraus; J. Aviv, MD; Hugh F. Biller, MD

Discussions 197

≈

Memorials
Albert H. Andrews, Jr, MD 202
Lawrence R. Boies, MD 203
Francis W. Davison, MD 204
James T. King, MD 205
Lawrence C. McHenry, MD 206
John J. O'Keefe, MD 207
Francis A. Sooy, MD 208
Gabriel F. Tucker, Jr, MD 210
Pierre Violé, MD 211

Roster of Fellows 1987 212

Officers 1987-1988 216

Index 217

*No manuscript available for publication.

FELLOWS IN ATTENDANCE AT THE ONE HUNDRED EIGHTH ANNUAL MEETING

First Row: Lewy, Yanagisawa, Farrior, Cohen, Woodman, Pratt, Lewis, Fearon, Myers, J. Tucker, D. Sessions, LeJeune, Jako, Loré.
Second Row: Dedo, Hirano, Kashima, Harris, Pennington, Ferlito, J. Kirchner, D. Miller, Hudson, Cody, Morse, Schild, Benjamin, Lucente.
Third Row: Morrison, Olson, Ballenger, Baxter, J. Snow, Fee, Biller, Saunders, Fredrickson, Goldstein, Cocke, H. Tucker, Briant.
Fourth Row: Bryce, Sisson, Alford, R. Miller, Ward, Cantrell, Schuller, Adkins, Strong, Blaugrund, Boles, Work.

OFFICERS 1986-1987

PRESIDENT

LORING W. PRATT, MD

VICE-PRESIDENT (PRESIDENT-ELECT)

BLAIR FEARON, MD

SECRETARY

EUGENE N. MYERS, MD

TREASURER

JOHN M. FREDRICKSON, MD

HISTORIAN-EDITOR

JAMES B. SNOW, JR, MD

FIRST COUNCILOR

JOHN S. LEWIS, MD

SECOND COUNCILOR

GABRIEL F. TUCKER, JR, MD

THIRD COUNCILOR

DOUGLAS P. BRYCE, MD

COUNCILORS-AT-LARGE

HUGH F. BILLER, MD

JOHN A. TUCKER, MD

REGISTRATION OF FELLOWS

ACTIVE

ADKINS, WARREN Y., JR
ALFORD, BOBBY R.
APPLEBAUM, EDWARD L.
BAILEY, BYRON J.
BAKER, SHAN R.
BALLENGER, JOHN J.
BAXTER, JAMES D.
BILLER, HUGH F.
BLAUGRUND, STANLEY M.
BLITZER, ANDREW
BOLES, ROGER
BRIANT, T. DAVID R.
BRYCE, DOUGLAS P.
CALCATERRA, THOMAS C.
CANTRELL, ROBERT W.
CHANDLER, J. RYAN
COCKE, EDWIN W., JR
CODY, CLAUDE C. III
COHEN, SEYMOUR R.
CRUMLEY, ROGER L.
CUMMINGS, CHARLES W.
DEDO, HERBERT H.
DOYLE, PATRICK J.
FARRIOR, RICHARD T.
FEARON, BLAIR
FEE, WILLARD E., JR
FREDRICKSON, JOHN M.
GACEK, RICHARD R.
GATES, GEORGE A.
GOLDSTEIN, JEROME C.
GROSS, CHARLES W.
HAWKINS, DONALD B.
HEALY, GERALD B.
HICKS, JULIUS N.
HOLINGER, LAUREN D.
HUDSON, WILLIAM R.
JAKO, GEZA J.
JOHNS, MICHAEL E.
KASHIMA, HASKINS K.
KRAUSE, CHARLES J.
LEJEUNE, FRANCIS E., JR
LEWIS, JOHN S.
LORÉ, JOHN M., JR
LUCENTE, FRANK E.
MCCABE, BRIAN F.
MILLER, ROBERT H.
MONTGOMERY, WILLIAM W.
MORRISON, MURRAY D.
MYERS, EUGENE N.
NEEL, H. BRYAN III
NICHOLS, RICHARD D.
NOYEK, ARNOLD M.
OLSON, NELS R.
PENNINGTON, CLAUDE L., JR
PRATT, LORING W.
REED, GEORGE F.
RICE, DALE H.
RITTER, FRANK N.
SASAKI, CLARENCE T.
SAUNDERS, WILLIAM H.
SCHILD, JOYCE A.
SCHULLER, DAVID E.
SESSIONS, DONALD G.
SESSIONS, ROY B.
SISSON, GEORGE A.
SNOW, JAMES B., JR
SPRINKLE, PHILIP M.
STRONG, M. STUART
TABB, HAROLD G.
TUCKER, HARVEY M.
TUCKER, JOHN A.
VRABEC, DONALD P.
WARD, PAUL H.
YANAGISAWA, EIJI
YARINGTON, C. THOMAS, JR

EMERITUS

HARRIS, HERBERT H.
KIRCHNER, JOHN A.
LEWY, ROBERT B.
MILLER, DANIEL
MORSE, HARRY R.
WOODMAN, DEGRAAF
WORK, WALTER P.

CORRESPONDING

BENJAMIN, BRUCE
FERLITO, ALFIO
HIRANO, MINORU
INOUYE, TETSUZO
MURAKAMI, YASUSHI
TU, GUI-YI

MINUTES OF THE EXECUTIVE SESSIONS

FIRST SESSION — APRIL 25, 1987

The First Executive Session of the 108th Annual Meeting was convened at 7:30 AM in the Grand Ballroom of the Fairmont Hotel, Denver, Loring W. Pratt, MD, Waterville, Maine, presiding. The following candidates, having been recommended for Fellowship by the Council, were elected to *Active Fellowship*: Warren Y. Adkins, Jr, MD, Charleston, South Carolina; Shan R. Baker, MD, Ann Arbor, Michigan; Andrew Blitzer, MD, New York; Donald B. Hawkins, MD, Los Angeles; Frank E. Lucente, MD, New York; Robert H. Maisel, MD, Minneapolis; Robert H. Miller, MD, New Orleans; David E. Schuller, MD, Columbus, Ohio; to *Emeritus Fellowship*: Alden H. Miller, MD, Los Angeles; DeGraaf Woodman, MD, Easton, Maryland; to *Corresponding Fellowship*: Gui-yi Tu, MD, Beijing, People's Republic of China.

Following their election, Professor Gui-yi Tu and the new Active Fellows were introduced by their sponsors, presented with certificates of fellowship, and welcomed by President Pratt.

President Pratt presented the Award of Merit to Dr DeGraaf Woodman upon his elevation to Emeritus Fellowship.

The following Fellows were elected as members of the Nominating Committee: Paul H. Ward, Chairman; Michael E. Johns, Richard R. Gacek, Stanley M. Blaugrund, and Jerome C. Goldstein.

SECOND SESSION — APRIL 26, 1987

The Second Executive Session was opened by President Pratt at 1:30 PM, and the report of the Nominating Committee was received from the Chairman, Dr Paul H. Ward. The following Fellows were nominated to the Council and elected unanimously: Blair Fearon; Seymour R. Cohen; Eugene N. Myers; John M. Fredrickson; James B. Snow, Jr; Douglas P. Bryce; Loring W. Pratt; Robert W. Cantrell; Charles W. Cummings; and H. Bryan Neel III.

The reports of the Treasurer and Historian-Editor were submitted and accepted. Dr Eugene N. Myers presented the report of the Liaison Member of the American Board of Otolaryngology, and Dr Michael E. Johns presented the report of the Governor of the American College of Surgeons. The meeting was adjourned until the end of the Scientific Session.

At the close of the Scientific Session, the Executive Session was reconvened by President Pratt. At the President's direction, the newly elected members of the Council, acting as Directors of the Association, organized themselves for the year 1987-1988 as follows: President: Blair Fearon, MD; Vice-President (President-Elect): Seymour R. Cohen, MD; Secretary: Eugene N. Myers, MD; Treasurer: John M. Fredrickson, MD; Historian-Editor: James B. Snow, Jr, MD; Second Councilor: Douglas P. Bryce, MD; Third Councilor: Loring W. Pratt, MD; Councilors-at-Large: Robert W. Cantrell, MD; Charles W. Cummings, MD; H. Bryan Neel III, MD. Dr Pratt introduced Dr Blair Fearon as the new President of the Association. Dr Fearon thanked Dr Loring W. Pratt for his outstanding work as President of the Association. The meeting was adjourned.

REPORTS

REPORT OF THE HISTORIAN-EDITOR

I have the sad duty to report the deaths of seven Emeritus Fellows and two Active Fellows. Lawrence R. Boies was elected to Fellowship in 1944 and served the Association as Vice-President in 1966 and as President, presiding at the meeting in 1968. He was elevated to Emeritus Fellowship in 1973. He died on July 5, 1986. Francis W. Davison was elected to Fellowship in 1951 and served the Association as President, presiding at the meeting in 1969. He was elevated to Emeritus Fellowship in 1977. He died on February 5, 1987. James T. King was elected to Fellowship in 1965 and was elevated to Emeritus Fellowship in 1985. He died on July 3, 1986. Lawrence C. McHenry was elected to Fellowship in 1951 and was elevated to Emeritus Fellowship in 1974. He died on June 8, 1985. John J. O'Keefe was elected to Fellowship in 1958 and was elevated to Emeritus Fellowship in 1981. He died on November 8, 1985. Francis A. Sooy was elected to Fellowship in 1954 and was elevated to Emeritus Fellowship in 1986. He died on September 12, 1986. Pierre Violé was elected to Fellowship in 1941 and served the Association as Vice-President in 1957. He was elevated to Emeritus Fellowship in 1961. He died on April 4, 1986. Albert H. Andrews, Jr, was elected to Fellowship in 1969. He died on September 26, 1986. Gabriel F. Tucker, Jr, was elected to Fellowship in 1970 and served the Association as Historian-Editor from 1977 to 1982, as Vice-President in 1983, and as President, presiding at the meeting in 1985. He died on December 8, 1986.

The papers presented at this meeting will be published in the September-October 1987 issue of the *Annals of Otology, Rhinology & Laryngology*.

The library of the Historian-Editor of the Association does not have a copy of the *Transactions* for the years 1879-85, 1888-89, 1891, 1893-97, 1899-1915, 1917, 1920-29, 1932-33, 1939, 1940, 1943, 1955, 1958, 1960, 1970, and 1976. The Association will gratefully receive copies of the missing issues as tax deductible contributions. A complete set from 1879 through 1986 belonging to the Association is maintained in the library of the Eye and Ear Hospital in Pittsburgh.

Issues are available for sale to Fellows of the Association for $2.00 per copy for the years 1918, 1942, 1944-49, 1951, 1953-54, 1958-59, 1962, 1964-69, 1971-75, 1977-86.

Manuscripts for the 1988 meeting should be in the hands of the Editor of the *Annals of Otology, Rhinology & Laryngology* by March 1, 1988.

Respectfully submitted,
James B. Snow, Jr, MD
Historian-Editor

REPORT OF THE GOVERNOR OF THE AMERICAN COLLEGE OF SURGEONS

Your Governor has served the American Laryngological Association over the last year by attending the annual meeting of the Board of Governors of the American College of Surgeons (ACS) on October 19, 1986, the meetings of the Advisory Council of Otorhinolaryngology, and the Maryland chapter of the ACS executive meetings. There are 3,130 members of the ACS who are otolaryngologists-head and neck surgeons and make up nearly 7% of the total membership of the College.

The ACS over the last year has filed an alternative proposal on physician reimbursement to the American Medical Association-Harvard proposal. This effort is a relative value system accounting for fee variations by geography, defining payment units for physician services and other issues of importance to surgery. This has been developed with the help of the consultant firm, Health Policy Alternatives.

The primary issue of concern to surgeons across the nation is professional liability. In response to this issue, the ACS has created a full-time Department of Medical Liability with a full-time medical director, Dr Paul F. Nora. This office will help us take a proactive position in this area.

Other issues of concern that the ACS is addressing include 1) alternate care delivery systems. There is continued and increased frustration regarding the rapidly changing environment in the marketplace. The primary concern is the pressure to join various organizations that require accepting lower fees. 2) Manpower needs. Excessive competition and aggressive advertising with proliferation of outreach clinics is resulting from the physician oversupply. 3) Relations within surgical specialties. There is some concern for the relationship between the surgical specialties over territorial dispute. There is thought to be considerable lack of courtesy and maintenance of ethical standards. 4) Legislative issues in medical care and graduate medical education. Support of graduate medical education and the new "same day admit" present problems for training, both at the medical school level and postgraduate level.

The ACS has now begun to take strong and bold moves particularly in the areas of liability and socioeconomic concerns and hopefully will lead the way for all surgeons in regard to these issues, which have an impact on patient care and on surgeons.

Respectfully submitted,
Michael E. Johns, MD
Governor, American College of Surgeons

REPORT OF THE TREASURER

To the Board of Directors of the
American Laryngological Association

We have compiled the balance sheets of the American Laryngological Association (a not-for-profit corporation) as of March 31, 1987, and 1986, the related statements of activity and changes in fund balance, and additional information for the years then ended, in accordance with standards established by the American Institute of Certified Public Accountants.

A compilation is limited to presenting, in the form of financial statements, information that is the representation of management. We have not audited or reviewed the accompanying financial statements and additional information and, accordingly, do not express an opinion or any other form of assurance on them.

Wolfe, Nilges, Nahorski
Certified Public Accountants

St Louis, Missouri
April 9, 1987

BALANCE SHEETS — MARCH 31, 1987 AND 1986

ASSETS

	1987	1986
Current Assets:		
Cash	$ 60,476	$128,127
Money Market Fund	159,729	5,027
Accounts receivable	2,196	8,442
Deposits	—	508
US Treasury note	—	64,978
Marketable securities:		
Common stocks, at cost (market value $40,815 and $39,255)	19,355	13,980
Total Assets	241,756	221,062

LIABILITIES AND FUND BALANCES

Accounts payable	—	1,762
Prepaid dues income	—	3,450
	—	5,212
Fund Balance	$241,756	$215,850

See accompanying notes to financial statements.

STATEMENTS OF ACTIVITY AND CHANGES IN FUND BALANCE FOR THE YEARS ENDED MARCH 31, 1987 AND 1986

	1987	1986
Revenues:		
Dues	$17,593	$ 17,625
Tickets — annual meeting	8,385	7,650
Tickets — COSM society's distribution	9,680	719
Sale of publications	2,177	2,036
Donations	15,385	125
	53,220	28,155
Expenses:		
Annual meeting and banquet	17,573	12,475
Council travel and expense	3,837	4,919
General and administrative expense	16,513	13,235
Research conference expense	2,250	—
Fund expenses	2,025	3,232
Miscellaneous	20	—
	42,218	33,861
Excess of Revenues over Expenses	11,002	(5,706)
Investment Income	14,904	20,168
Excess of Revenues and Investment Income over Expenses	25,906	14,462
Fund Balance, beginning of year	215,850	201,388
Fund Balance, end of year	$241,756	$215,850

See accompanying notes to financial statements.

SCHEDULE OF MARKETABLE SECURITIES MARCH 31, 1987

		Cost	Market Value
Stocks			
American Telephone & Telegraph	200 shares	$ 3,093	$ 4,725
Ameritech	20 shares	1,122	1,808
Bell Atlantic*	40 shares	1,138	2,700
Bell South	60 shares	1,471	2,385
IBM	40 shares	1,321	6,005
McDonnell Douglas	165 shares	1,194	12,891
McIntyre Mines Ltd	15 shares	675	486
Nynex†	40 shares	1,068	2,646
Pacific Telesis‡	40 shares	897	1,066
Southwestern Bell§	20 shares	1,030	2,343
US Steel (USX)	250 shares	5,375	7,031
US West	40 shares	971	2,200
		$19,355	$46,286

*2 for 1 split, March 12, 1986.

†2 for 1 split, March 20, 1986.

‡2 for 1 split, March 28, 1986.

§2 for 1 split, Feb 7, 1986.

See accompanying notes to financial statements.

SCHEDULE OF INDIVIDUAL TRUST FUNDS FOR THE YEAR ENDED MARCH 31, 1987

	Fund Balance 3/31/86	Receipts			Disbursements	Transfers	Fund Balance 3/31/87
		Revenues	Investment Income	Total			
Daniel C. Baker, Jr, Memorial Fund	$ 34,482	$ —	$ 2,475	$ 2,475	$(2,025)	—	$ 34,932
Casselberry Fund	19,226	—	1,383	1,383	—	—	20,609
Johnston Fund	19,136	—	1,383	1,383	—	—	20,519
De Roaldes Fund	10,816	—	786	786	—	—	11,602
Newcomb Trust Fund	7,508	—	539	539	—	—	8,047
Newcomb Prize Fund	1,746	—	131	131	—	—	1,877
Research Fund	79,197	150	5,719	5,869	—	$ 2,140	87,206
Memorial Fund	29,465	225	2,140	2,365	—	(2,140)	29,690
Gabriel F. Tucker Fund	—	9,635	—	9,635	—	—	9,635
Subtotal	201,576	10,010	14,556	24,566	(2,025)	—	224,117
General Fund	14,274	43,210	348	43,558	(40,193)	—	17,639
Total	$215,850	$53,220	$14,904	$68,124	$(42,218)	$ —	$241,756

See accompanying notes to financial statements.

NOTES TO THE FINANCIAL STATEMENTS — MARCH 31, 1987

1. Organization and summary of significant accounting policies

General. The American Laryngological Association (the Association) is a nonprofit corporation organized for the advancement and promotion of the study of the science of medicine and surgery, devoting special attention to the upper aerodigestive tract, and to engage in and to encourage research with respect thereto. This includes the elevation of standards of the fundamental study and teaching of rhinology and laryngology in the undergraduate and postgraduate medical schools of America, the publishing annually of the proceedings of this Association, and the honoring of those who, by their contributions in the field of rhinology and laryngology, have aided in its advancement.

Method of Accounting. The financial statements have been prepared in accordance with generally accepted accounting principles on the accrual basis.

Investments. The Board's investment in marketable securities (common stocks) is carried at the lower of aggregate cost or quoted market value.

2. Federal income taxes

The Board is exempt from federal income tax under the provisions of section 501(c)(6) of the Internal Revenue code of 1954.

3. Allocation of investment imcome

Interest on US Treasury notes, Certificates of Deposit, Money Markets, as well as dividends on common stock, are credited as income to the Trust Fund. Trust Fund income is further allocated to each individual fund in the ratio each fund bears to the total value of the trust funds at the beginning of the year, except that by action of the Council on January 3, 1976, current income from the Memorial Fund is to be transferred to the fund balance of the Research Fund.

Respectfully submitted,
John M. Fredrickson, MD
Treasurer

REPORT OF THE LIAISON DIRECTOR OF THE AMERICAN BOARD OF OTOLARYNGOLOGY

The following information summarizes the activities and developments of the American Board of Otolaryngology (ABO) for the year 1986.

ELECTION

At the October 1986 business meeting, the Directors of the Board elected Dr H. Bryan Neel III, from Rochester, Minnesota, as a new member of the Board of Directors, replacing Dr Richard R. Gacek who had resigned.

EXAMINATION RESULTS

There were 387 candidates who participated in the September 1986 written examination. Of these candidates, 174 (45%) passed on the basis of the written examination and were certified; 137 (35%) became candidates for the oral examination, and 76 (20%) failed. The oral examination was conducted in Chicago, in March 1987, with 129 candidates being examined; 100 (78%) passed and were certified and 29 (22%) failed. The overall pass/fail rate on the basis of both examinations was 72% passed and were certified and 28% failed. In the previous year the pass/fail rate was 62.7% and 37.3%, respectively.

RECERTIFICATION

Several members of the Board of Directors attended the March Conference on Recertification of the American Board of Medical Specialties (ABMS).

The COCERT committee of the ABO has planned the program for the retreat of the Board to be held in June 1987. This retreat is dedicated to a study of recertification and further development of the Board's posture about recertification.

The ABMS, at its September 1986 meeting, approved in principle the outline for recertification that had been described by the ABO. This was a brief proposal submitted to the ABMS without any explicit definition of the actual process to be adopted, except that time-limited certificates were planned to be issued in 1989 and that the recertification process would occur at an interval of every 7 years thereafter, with the first ABO recertification opportunity to be offered in 1995. The absolute requirements for ABO recertification have not been spelled out.

At this time, it is fair to say that the ABO is completely reassessing its position about recertification. In part, this is due to the disappointment of several members of the Board of Directors concerning what other specialty boards that have adopted recertification processes are doing, and how recertification seems to work and what it really means. Surely one of the major outcomes of the ABO retreat on recertification in June will be a complete reassessment of the ABO position in this regard.

ADDED QUALIFICATIONS

There has been no activity in the added qualifications area. However, the ABO has requested that the Residency Review

Committee for Otolaryngology develop guidelines for fellowship programs that could possibly lead to added qualifications in several areas, if merited.

REDESIGNED CERTIFICATE

As announced in the newsletter, the ABO approved a redesigned certificate at its October meeting. This action and subsequent announcement in the ABO newsletter led to litigation that is pending.

Respectfully submitted,
Eugene N. Myers, MD
Director, American Board of Otolaryngology

RECIPIENTS OF THE DE ROALDES AWARD

1928 Chevalier Jackson
1931 D. Bryson Delavan
1934 Harris P. Mosher
1937 Lee Wallace Dean
1943 Ralph A. Fenton
1949 George M. Coates
1951 Arthur W. Proetz
1954 Louis H. Clerf
1959 Albert C. Furstenberg
1960 Dean M. Lierle
1961 Frederick T. Hill
1966 Paul H. Holinger
1970 Francis E. LeJeune
1973 Lawrence R. Boies
1976 Anderson E. Hilding
1979 Joseph H. Ogura
1982 John J. Conley
1985 John A. Kirchner
1985 Charles M. Norris
1987 Walter P. Work

RECIPIENTS OF THE CASSELBERRY AWARD

1923 George Fetterolf and Herbert Fox
1928 Ralph A. Fenton and O. Larsell
1929 Richard A. Kern and Harry P. Schenck
1929 Edward H. Campbell
1931 Arthur W. Proetz
1934 Anderson C. Hilding
1936 Francis E. LeJeune and Joel J. Pressman
1939 H. Marshall Taylor and Brien T. King
1940 French K. Hansel
1941 Noah D. Fabricant
1946 Paul H. Holinger
1949 Henry B. Orton
1962 Hans von Leden
1966 John A. Kirchner and Barry D. Wyke
1968 Joseph H. Ogura
1985 H. Bryan Neel III
1987 Joseph J. Fata

RECIPIENTS OF THE NEWCOMB AWARD

1941 Burt R. Shurly
1942 Francis R. Packard
1943 George M. Coates
1944 Charles J. Imperatori
1947 Harris P. Mosher
1948 Gordon Berry
1949 Gordon B. New
1950 H. Marshall Taylor
1951 John D. Kernan
1952 William J. McNally
1953 Frederick T. Hill
1954 Henry B. Orton
1955 Thomas C. Galloway
1956 Dean M. Lierle
1957 Gordon F. Harkness
1958 Albert C. Furstenberg
1959 Harry P. Schenck
1960 Joel J. Pressman
1961 Chevalier L. Jackson
1962 Paul H. Holinger
1963 Francis E. LeJeune
1964 Fred W. Dixon
1965 Edwin N. Broyles
1966 Lyman G. Richards
1967 Joseph H. Ogura
1968 Walter P. Work
1969 John A. Kirchner
1970 Louis H. Clerf
1971 Daniel C. Baker, Jr
1972 Alden H. Miller
1973 DeGraaf Woodman
1974 John J. Conley
1975 Francis W. Davison
1976 Joseph L. Goldman
1977 F. Johnson Putney
1978 John F. Daly
1979 Charles F. Ferguson
1980 Charles M. Norris
1981 Stanton A. Friedberg
1982 William M. Trible
1983 Harold G. Tabb
1984 Daniel Miller
1985 M. Stuart Strong
1986 George A. Sisson
1987 John S. Lewis

RECIPIENTS OF THE GABRIEL F. TUCKER AWARD

1987 Seymour R. Cohen

THE MEMORIAL AND LARYNGOLOGICAL RESEARCH FUNDS

The Council earnestly requests that Fellows of the Association give consideration to making a special bequest to these important funds, or to become a Benefactor.

MEMORIAL FUND DONORS

Mrs Daniel C. Baker, Jr
Daniel C. Baker, Jr
John F. Barnhill
August L. Beck
Gordon Berry
William E. Casselberry
Cornelius G. Coakley
Robin T. Cotton
Lee Wallace Dean
Arthur W. De Roaldes
Fred W. Dixon
George Fetterolf
Joseph L. Goodale
William E. Grove
Gordon F. Harkness
Frederick T. Hill
George E. Hourn
Samuel Johnston
James E. Newcomb
Henry B. Orton
Lup Q. Pang
Pediatric Anaesthesia Associates, Ltd, of the Childrens Memorial Hospital of Chicago
Loring W. and Mrs Pratt
Lyman G. Richards
Burt R. Shurly
Lester T. Sunderland
H. Marshall Taylor
Walter H. Theobald
Gabriel F. Tucker, Jr
Francis L. Weille
Eiji Yanagisawa

BENEFACTORS

Mrs Sally Sample-Aall
Mrs Daniel C. Baker, Jr
Edwin N. Broyles
Louis H. Clerf
Seymour R. and Mrs Cohen
John J. Conley
John F. Daly
Francis W. and Mrs. Davison
Stanton A. Friedberg
Thomas C. Galloway
Joseph L. Goldman
Robert L. Goodale
Edley H. Jones
Zelda Radow Weintraub Cancer Fund, Inc
A. P. Marchessini
Francis H. McGovern
Charles M. Norris
Samuel Salinger
Sam H. Sanders
Harry P. Schenck
Karl Storz Endoscopy–America, Inc
Oliver W. Suehs
William M. Trible
DeGraaf Woodman

PRESIDENTIAL REMARKS

FABRICIUS OF AQUAPENDENTE

LORING W. PRATT, MD

BALTIMORE, MARYLAND

Fabricius of Aquapendente was appointed Professor of Anatomy at The University of Padua in 1565 where he taught, did research on the comparative anatomy of the larynx and eye, speech in animals, the development of the chick embryo, the valves of the veins, and other interesting anatomic problems. His work on the venous valves laid the foundation for his student, William Harvey, to solve the riddle of the circulation of blood. His contribution to laryngology was the fine anatomic detail of his comparative anatomic studies and his demonstration of the relationship of form to function.

KEY WORDS — anatomy history, Fabricius of Aquapendente.

Born in 1533, in the small town of "hanging waters" near Orvieto, Italy, and so named for nearby cascades of the turbulent Paglia rushing to join the Tiber on its way to the sea, called Aquapendente, Hieronymus Fabricius (Girolamo Fabrizio) grew up halfway between Rome and Siena (Fig 1).

His was an old and respected family. Although prior to his birth, the family had lost much of its former wealth and station, it was not impecunious and had adequate means for his rearing and educational needs. As a child Fabricius was noted for his extraordinary memory, keen mind, industry, and obedience, as well as his straightforward, candid dealings with others, and his overall amiable good nature.

He studied in Padua — first Greek and Latin and then logic and philosophy. He later entered the School of Medicine in Padua at age 17 and was fortunate to be a student of Gabriele Fallopius (Fig 2) who permitted him to assist in the dissecting room and to accompany him on rounds. (This was the age when the anatomist was also surgeon and physician and divided his time between teaching duties and clinical responsibilities.) He received his degree in medicine and philosophy from the University of Padua in 1559.[1]

Fabricius was enthusiastic in his practice of medicine and surgery and treated many distinguished patients including Cosimo de' Medici II and Galileo, and consulted with many noted physicians, for example, Girolamo Mercuriale (author of the first clinical work on otology) and Gasparo Tagliacozzi (the early plastic surgeon who devised a method to reconstruct the face following amputation of the nose). Fabricius strove to perfect his knowledge of anatomy and asked to assist Fallopius at surgery, where his anatomic knowledge was both essential to and broadened by this work. He was appointed to the Chair of Surgery at Padua on April 10, 1565, 2 years after the death of Fallopius, during which time the Chair had remained vacant. In addition to his surgical duties, he also taught anatomy. He was eventually promoted to the title of Supraordinarius in both surgery and anatomy.

Teaching anatomy in those years was quite different from today. Unembalmed bodies were dissected in a special wooden amphitheater, modeled on the Colosseum in Rome (Fig 3). It was assembled outdoors to house observers of the anatomic dissec-



Fig 1. Hieronymus Fabricius, 1533-1619.[3]

From the Department of Otolaryngology–Head and Neck Surgery, The Johns Hopkins Medical Institutions, Baltimore.

Presented at the meeting of the American Laryngological Association, Denver, April 25-26, 1987.

REPRINTS — Loring W. Pratt, MD, 37 Lawrence Ave, Fairfield, ME 04937.

Fig 2. Gabriele Fallopius, 1523-1562.[4]

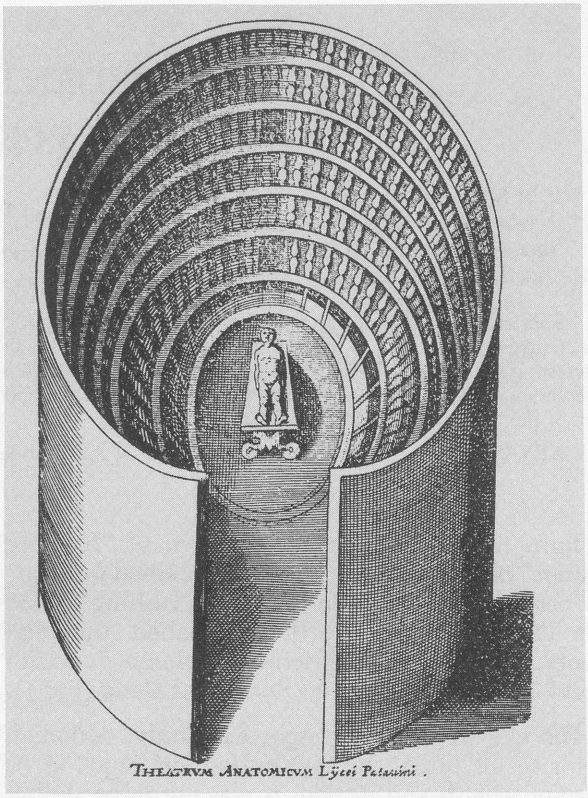

Fig 3. Dissection amphitheater.[3]

tion and make certain that all observers had paid their fees. The theater was disassembled and removed following completion of the course, to be reassembled in time for the next course. In 1583 the anatomy course was moved indoors but was held in the same portable anatomy theater, assembled within a room with dimensions of 25 by 30 ft (7.5 by 9 m) in the medical college. This portable amphitheater provided crowded accommodations for 300 observers standing in six tiers of galleries around a small oval platform that supported the cadaver and the participants in the dissection. Light was provided by two candelabra each bearing three candles and supplemented by eight lamps held and positioned by students. It was not until 1594 that a permanent amphitheater was built and inaugurated by Fabricius to house the anatomic dissections. In honor of the event, free admission to the dissections was offered in the amphitheater that today bears his name.[1,2]

Fabricius was a vigorous worker and from 1563 to 1565 gave private instruction in anatomy. He was somewhat temperamental and at times had to be cajoled into giving the annual anatomy course. On other occasions, especially when competition from Giulio Casserio (whose text shows the first drawings of tracheotomy[3] and who gave private lessons) and others appeared on the scene, he responded in entrepreneurial fashion and carried on above and beyond the call of duty in producing a first-quality course of instruction. He occasionally skipped a year of these performances, especially to the sorrow of new students, who properly felt shortchanged if the course was not given. He was of the era when anatomic knowledge was the most important facet in the training and practice of medicine and he was, like most early anatomists, much interested in the study of comparative anatomy, in which field he did enormous work. He felt that a good understanding of comparative anatomy was essential to proper interpretation of action and function as represented in the anatomic specimen in humans. In truth, he was not nearly as devoted to teaching as to research.[4]

There is an interesting feature of his recorded activity. Although he was appointed Professor of Surgery in 1565 and Professor of Anatomy a short time later and was reported to be an active worker in anatomy for long before that, his first publication was in 1600. One may hypothesize that in those 35 years he dissected, made drawings, and collected the information upon which he was to draw for his writings in later years. Yet it seems strange that a teacher and scientist would not publish in that long period of time and then produce a number of valuable books when he had reached and exceeded the age of 67. This is more understandable when one realizes that attendance at his anatomy instructions might have been somewhat curtailed had he published his work as a young man. The masters in

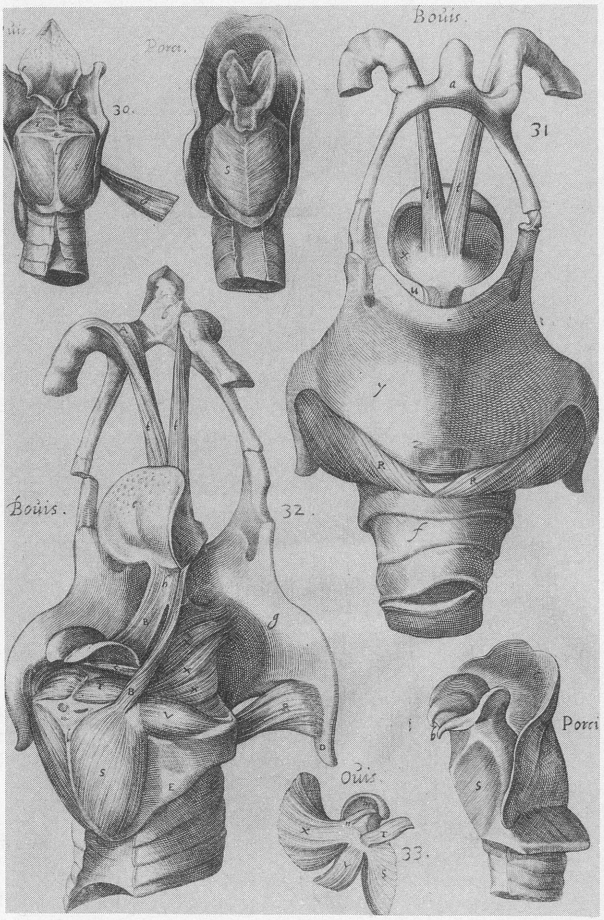

Fig 4. Plate showing dissection of ox, pig, and sheep larynges.[5] (Courtesy of Blocker History of Medicine Collections, Moody Medical Library, The University of Texas Medical Branch, Galveston.)

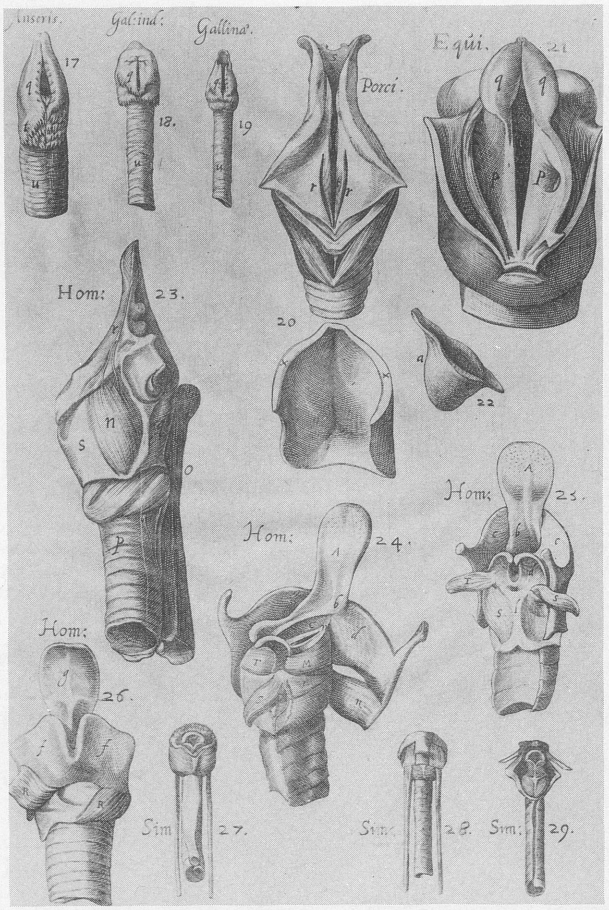

Fig 5. Plate showing drawings of dissections of larynx of human, chicken, pig, and horse.[5] (Courtesy of Blocker History of Medicine Collections, Moody Medical Library, The University of Texas Medical Branch, Galveston.)

those years often published at the end of their careers in a bid for some sort of immortality that would not interfere with the popularity of their teaching sessions.

In the course of dissection, Fabricius made a careful study of the comparative anatomy of the larynges of the human, horse, ox, sheep, and pig (Figs 4-6),[5] and he is credited with being the originator of the concept of comparative anatomy. Although it has been said that he made no real effort to compare the homologous structures from one species to another, it seems unlikely that the beautiful morphologic material he presents in his atlas could have been produced without his awareness of these relationships. The illustrations found in his atlas clearly point out the excellent knowledge he had of the descriptive anatomy of this organ for which our Society is named. His first publication, *De Larynge, Vocis, Instrumento*, was printed in Padua by Laurentius Pasqualus and was published in Venice in 1600 by Jacobus Valegius. The individual sections "*De Voce*," "*De Visione*," and "*De Auditu*" (Fig 7) were each dedicated to one of the senators whose influence in the Venetian senate had helped with the attainment of his title and the appended salary. This volume was followed in 1603 by another volume, *De Brutorum Loquela*,[6] a treatise on phonation of animals, which certainly was a result of his interest in the comparative anatomy of the larynx.

Fabricius's original works were *Pentateuchas Chirurgicum*, published in 1592 and edited by Johann Hartman Berger, without his permission or approval; *De Larynge, Vocis Instrumento* (*De Voce, De Visione, De Auditu*) (1600); *Tabulae Anatomicae* (1600); *De Brutorum Loquela* (1603); *De Venarum Ostiolis* (1603); *De Musculo Artificio, Ossium de Articulationibus* (1614); *De Respiratione et Eius Instrumentis, Libri duo* (1615); *De Gulo, Ventriculo, Intestinis Tractus* (1618); *De Motu Locali Animalis Secundum Totum* (1618); *Hieronymi Senis De Totius Animalis Integumentis Opusculum* (1618); and *Operatives Chirurgicae* (1619), published by Fabricius as an addendum to the *Pentateuchas*.

Fabricius was one of a distinguished group of Paduan teachers and scholars including Alessandro Benedetti, who encouraged dissection by the stu-

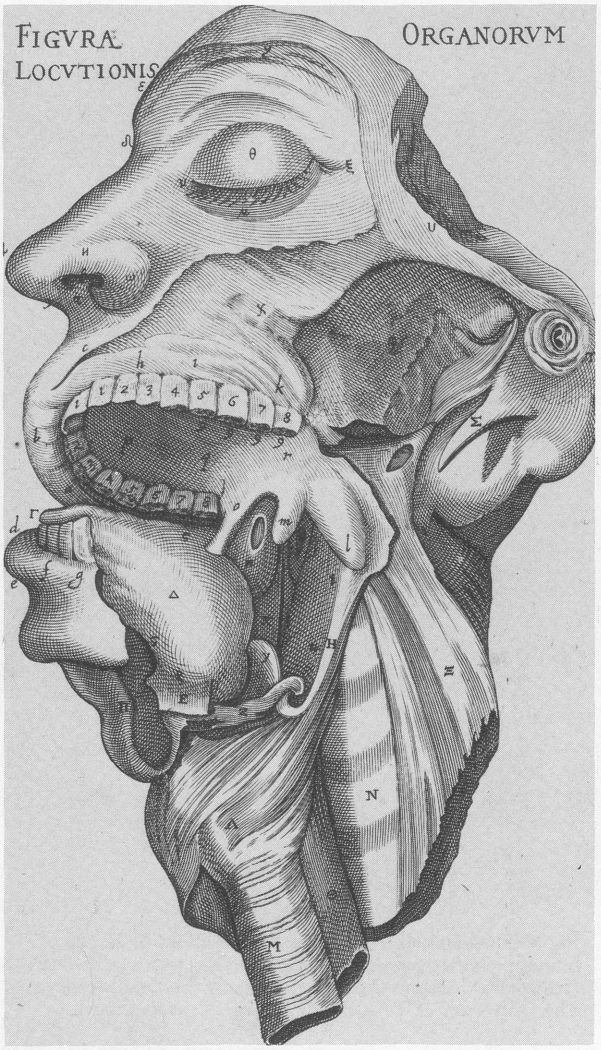

Fig 6. Plate showing dissection of organs of speech.[5] (Courtesy of Blocker History of Medicine Collections, Moody Medical Library, The University of Texas Medical Branch, Galveston.)

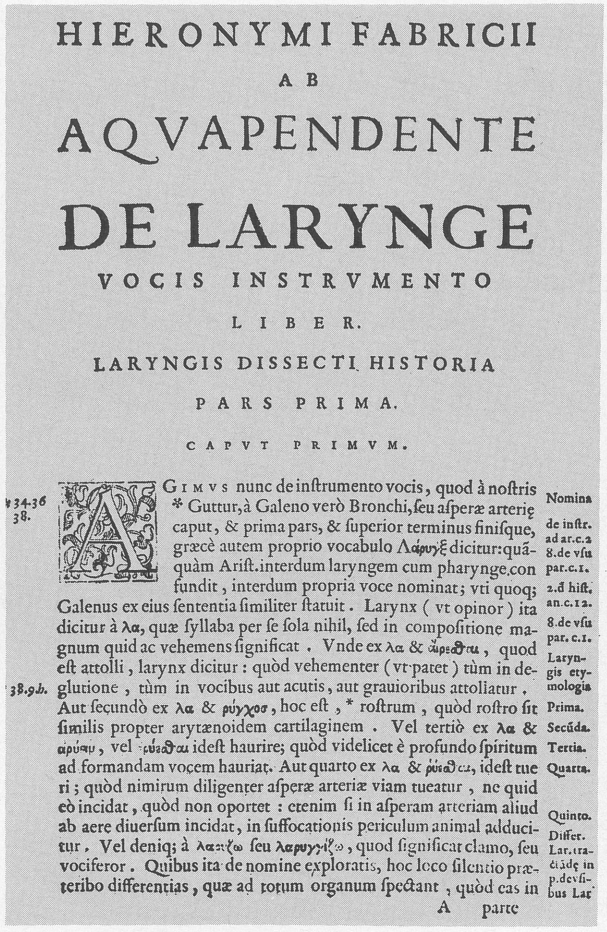

HIERONYMI FABRICII
AB
AQVAPENDENTE
DE LARYNGE
VOCIS INSTRVMENTO
LIBER.
LARYNGIS DISSECTI HISTORIA
PARS PRIMA.
CAPVT PRIMVM.

Nomina

AGimvs nunc de inſtrumento vocis, quod à noſtris * Guttur, à Galeno verò Bronchi, ſeu aſperæ arterię caput, & prima pars, & ſuperior terminus finiſque, græcè autem proprio vocabulo Λάρυγξ dicitur: quã-quàm Ariſt. interdum laryngem cum pharynge confundit, interdum propria voce nominat; vti quoq; Galenus ex eius ſententia ſimiliter ſtatuit. Larynx (vt opinor) ita dicitur à λα, quæ ſyllaba per ſe ſola nihil, ſed in compoſitione magnum quid ac vehemens ſignificat. Vnde ex λα & ἄιρεσθαι, quod eſt attolli, larynx dicitur: quòd vehementer (vt patet) tùm in deglutione, tùm in vocibus aut acutis, aut grauioribus attoliatur. Aut ſecundò ex λα & ῥύγχος, hoc eſt, * roſtrum, quòd roſtro ſit ſimilis propter arytænoidem cartilaginem. Vel tertiò ex λα & ἀρύειν, vel ῥύεσθαι ideſt haurire; quòd videlicet è profundo ſpiritum ad formandam vocem hauriat. Aut quarto ex λα & ῥύεσθαι, ideſt tueri; quòd nimirum diligenter aſperæ arteriæ viam tueatur, ne quid eò incidat, quòd non oportet: etenim ſi in aſperam arteriam aliud ab aere diuerſum incidat, in ſuffocationis periculum animal adducitur. Vel deniq; à λαπτίζω ſeu λαρυγίζω, quod ſignificat clamo, ſeu vociferor. Quibus ita de nomine exploratis, hoc loco ſilentio præteribo differentias, quæ ad totum organum ſpectant, quòd eas in

34-36 38.

38.9.d.

de inſtr. ad ar.c.2
8.de vſu par.c.1.
2.d hiſt. an.c.12.
8.de vſu par. c.1.
Laryngis etymologia
Prima.
Secũda.
Tertia.
Quarta.
Quinto.
Differ. Lar. tra-ctãdę in p.de vſibus Lar.

A parte

Fig 7. First page of Fabricius's treatise on larynx.[5] (Courtesy of Blocker History of Medicine Collections, Moody Medical Library, The University of Texas Medical Branch, Galveston.)

dent, and Andreas Vesalius, who believed that the physician must dissect bodies and who first described the technique of removing the temporal bone for dissection, described the malleus and the incus, and gave them their names.[4] Realdo Columbo, who first described the pulmonary circulation and who believed that on perceiving sound the ossicles are set in motion, and Gabriele Fallopius, who studied the course and ramifications of the acoustic nerve, described the inclination of the tympanic membrane, and discovered that in the fetus the tympanic ring is separated from the temporal bone, were other members of this distinguished company of anatomists and teachers from Padua.

Fabiricius married Violante Vidal and was predeceased by her in 1618. They had no children, but Fabricius had adopted a grandniece, Semida, on the death of her father. Although Fabricius had an illegitimate son who studied medicine and became a doctor, he and his father quarreled and went their separate ways. Fabricius lived quietly in retirement after the loss of his wife and was attended by Semida. He became ill on May 13, 1619, and a few days later died and was buried *sine titulo* in the west cloister of the Franciscan church in Padua on May 23, 1619.

Fabricius was the last of the great anatomists for whom tradition was the controlling factor in his thought. Even though he discovered the valves in the veins, he persisted in upholding Claudius Galen's view that the venous blood moves outward, away from the heart. According to Fabricius, the valves serve to delay or impede the outward movement of the blood, rather than to stop its movement. He published one of his most important writings, *De Venarum Ostiolis* by way of reporting his findings. It was William Harvey, Fabricius's celebrated student who graduated in medicine from Padua in 1602, who solved the riddle of circulation, using Fabricius's work and writings on the veins and their valves as the cornerstone of his work, as he later acknowledged. Scientists always marvel at their predecessors who had the information to unravel a particular problem at their fingertips, yet

failed to do so because of their adherence to traditional thought. We would do well to keep this principle in mind.[2]

In the course of his training with Fabricius, Harvey had also read Galen, who was the master in the development of animal experimentation. Indeed, one of Galen's most celebrated experiments had to do with laryngeal physiology. The ancients believed that speech was the highest manifestation of human intelligence. Although Alexander of Damascus held that control of the voice was under the direction of the heart, Galen was able to demonstrate that this was not true by dissecting and ligating the recurrent laryngeal nerves of a living animal in a public demonstration, thus showing the primacy of the brain in the control of the voice.[7]

Study of the life and work of Fabricius of Aquapendente clearly demonstrates that there is much in medicine that is unchanged from his time. True, our anatomic knowledge is improved, but it exists at least partly as a result of the foundation he built by industry and labor. Teaching was not truly his magnum opus. Even care of the patient was not his prime concern. Research was his consuming interest, and the proper recording of those studies in published volumes was the real reason that his name lives. Without this, his contributions to the art and science of medicine would not have been remembered through the nearly 400 years intervening between his life and our memory of him today. Even then it was publish or perish!

ACKNOWLEDGMENTS — The author acknowledges with gratitude the assistance of Jerome Bylebyl, PhD, of the Institute of the History of Medicine of The Johns Hopkins Medical Institutions and of the Institute of the History of Medicine in allowing access to the original works of Fabricius and reproduction of plates from those volumes in the preparation of this paper. He also acknowledges the help of the Blocker History of Medicine Collection, Moody Medical Library, The University of Texas Medical Branch, Galveston, in permitting use and reproduction of material from their original works of Fabricius.

REFERENCES

1. Adelmann H. The embryological treatises of Hieronymus Fabricius of Aquapendente. The formation of the egg and of the chick (De formatione ovi et pulli); the formed fetus (De formato foetu). Ithaca, NY: Cornell University Press, 1942.

2. Singer C. The evolution of anatomy, a short history of anatomical and physiological discovery to Harvey. New York: Alfred Knopf, 1925.

3. Casserius J. De vocis auditusque organis historia singulari fide methodo ac industria concinnati tractatibus duobus explicata ac variis iconibus aere excusis illustrata. Ferrariae, 122, 1600-1601.

4. Politzer A. History of otology. Milstein S, Portnoff C, Antje Coleman A, trans. Phoenix, Ariz: Columella Press, 1981.

5. Hieronymus Fabrici ab Aquapendente. De larynge vocis instrumento, 1600.

6. Hieronymus Fabrici ab Aquapendente. De brutorum loquela. Francofurti: Typis Hartmanni Palthenij, Sumptibus Jacobi de Zetter, 1604.

7. Bylebyl J. Medicine, philosophy and humanism in Renaissance Italy. In: Shirley JW, Hoeniger FD, eds. Science and the arts in the Renaissance. London: Folger Books, 1985.

INTRODUCTION OF GUEST OF HONOR JOHN S. LEWIS, MD

LORING W. PRATT, MD

Born in Medicine Hat, Alberta, Canada, at that time a town of 8,000 people, which had been distinguished some years before by a visit from Rudyard Kipling, John S. Lewis enjoyed the many advantages of a rural upbringing. While Kipling was visiting this natural gas-producing region, a new well was "brought in" and the escaping gas ignited, sending a flame far into the heavens; Kipling then observed that "Medicine Hat has all Hell for a basement."

It was in this environment that Jack grew up and received his primary education. He went to the University of Alberta and graduated in Medicine in 1943. Immediately following his graduation, he entered the Royal Canadian armed forces and served overseas with the North Nova Scotia Highlanders, a unit that suffered casualties of 60% during World War II. He was stationed in England and on the European continent most of the time and participated in the termination of hostilities from a location in northern Germany.

At the close of the war, he went to the University of Edinburgh where he was trained for 1 year in general surgery. He returned to the University of Alberta for didactic training, then went to Edmonton where he remained for 1 year working in the pathology department. He attended the University of Pennsylvania from 1948 to 1950 as Resident in Otolaryngology under the watchful eye of Harry Schenck, MD.

It was during the period of his residency that he made the most important move of his lifetime, which influenced his entire career most favorably. He married Marion DeLong, a Johns Hopkins's trained dietitian, who has been Jack's willing helpmate and major supporter ever since. In his words, "I don't know how I could ever have gotten along without her."

During the course of his medical training, and especially during residency, he became impressed with the fact that radiation therapy by itself was not enough to cure cancer of the head and neck. He searched in the realm of surgical excision for a technique to prevent the terrible recurrences that plagued patients and doctors alike. With this clearly defined purpose, he became a Special Fellow at the Memorial Hospital in New York City in 1950, and in 1951 he joined the staff as an associate attending physician. Head and neck surgery was under the direction of the world-renowned pioneer, Hayes Martin. At this point, the late Dr Frank Keim had just left Memorial to practice in Newark; Dr Martin needed someone to replace Keim, and John



Lewis was on the scene. He scrubbed with Dr Martin and established a relationship that continued lifelong as a relationship of mutual understanding and respect.

Jack's history of medical affiliations is impressive. He joined the staff of Roosevelt Hospital in 1951 and served as Chief of Otolaryngology from 1967 to 1984. During that time he built the Department of Otolaryngology from nothing to one that had a residency accredited by the Residency Review Committee. During those years he also was Associate Clinical Professor of Otolaryngology at Columbia University. He has been president of most of the important otolaryngologic societies, including the New York Laryngological Association, the New York Otological Association, the Section of Otolaryngology of the New York Academy of Medicine, the American Society for Head and Neck Surgery, and the American Laryngological Association. He served as Vice-President of the Eastern Section of the Triological Society and distinguished himself for his service as Governor of the American College of Surgeons. He humbly says that one of his greatest accomplishments is the he "was never in Lewisburg Penitentiary." A striking example of his humble, self-effacing nature may be taken from a recent appearance in court as an expert witness. The lawyer was trying to establish him as an unusually well-qualified and able physician and he asked, "Is it true, Dr Lewis, that you have been President of

many of the prestigious medical societies?" Jack responded "Yes." "And how do you account for this, Doctor Lewis?" "Just lucky, I guess."

Jack has been one of those remarkable otolaryngologists who entered the specialty when it was at its lowest ebb, the days when sulfonamides and antibiotics had destroyed the need for surgery for septic conditions. He recognized the opportunity to expand the efforts of otolaryngology into fields that were then desperately in need of new concepts upon which ablative surgery with subsequent (and now often simultaneous) reconstruction of the cancer patient is based. Jack picked one of the most formidable of these areas, the temporal bone, and is indeed the world's authority on the management of cancer in this difficult area, having the largest series of cases reported in the English (and probably the world) literature.

By his example and leadership, as one of the founding fathers of the American Society for Head and Neck Surgery, and his diligence in helping others to gain recognition in this field, head and neck surgery is now clearly and universally recognized as the proper province of the otolaryngologist–head and neck surgeon. He has served on committees from both the American Society for Head and Neck Surgery and the Society of Head and Neck Surgeons, helping to develop a fellowship program directed to training superbly qualified head and neck surgeons — most of whom have been otolaryngologists.

Dr John S. Lewis is a fine exemplar of the noblest ideals of the medical profession, and, best of all, he has been my friend for many years. Jack, I salute you!

GUEST OF HONOR ADDRESS

JOHN S. LEWIS, MD

It is a wonderful feeling to be uniquely honored by a Society that I hold in such high esteem. The honor is greatly enhanced by being selected for this tribute by your President, who is revered by all of our societies and has had such a key role in the leadership of our specialty. Our scientific program reflects the considered melding of all facets of laryngology: research, clinical challenges, and the 21st century concept of "flow cytometry." What a wonderful and stimulating annual meeting our president has programmed for us!

When I look down memory lane, the faces of my old chiefs of otolaryngology at the University of Pennsylvania come into focus. What a great triumph it was for Drs Harry Schenck and Edward Campbell to have won the Casselberry Award in 1929 and for Dr Schenck again to win the prestigious Newcomb Award in 1959. These men were great catalysts in my desire to be a part of this elite Society.

The training in laryngology in Philadelphia after World War II was primarily in diagnostic endoscopy using rigid tubes, with the laryngologist involved in laryngoscopy, bronchoscopy, esophagoscopy, and gastroscopy. Occasionally, a laryngectomy would stimulate the surgical appetite. Dr Joseph P. Atkins ran the service at the Hospital of the University of Pennsylvania, Dr Louis H. Clerf at Thomas Jefferson University Hospital, and Dr Chevalier L. Jackson at Temple University Hospital. Cancer of the larynx was treated as a surgical problem, and Dr Clerf was preeminent. All other head and neck cancer was irradiated, most often with dire results. In 1950, I arrived at Memorial Hospital prepared to learn newer approaches to the management of head and neck cancer. It was a heady experience under the direction of Dr Hayes Martin. Not only did one see hundreds of surgical problems, but one was involved in setting up the patients for radiotherapy. I joined the head and neck teaching staff in 1951.

I arrived at Memorial Hospital in 1950 with great expectations. The war had given us great experience with the management of trauma cases. Rapid blood replacement, safe anesthesia, and antibiotics had transformed the entire spectrum of surgical care. Radiotherapy had been the standby for all cancer cases at this large cancer institution for decades. The majority of head and neck surgical procedures such as radical neck dissection, maxillectomy, and laryngectomy had been developed elsewhere. These procedures were modified and used extensively in the treatment of a multiplicity of head and neck cancers. The commando operation was developed at our institution, parotidectomy with facial nerve dissection was popularized, and one-stage subtotal resection of the temporal bone for cancer first was described.

Hayes Martin's office was a veritable mecca for head and neck cases from all over the world. The overflow from his office came to the head and neck clinic, where the younger attending physicians managed their problems. The house staff came from every part of this country and the four corners of the globe. The spin-off from this department included the foremost teachers of oncologic surgery around the world and the formation of the surgical oncologic societies. It was my good fortune to be part of the team that built up a great teaching service and gave the impetus to the operative aspects of head and neck surgery that are used in our specialty today.

Surgery will continue to be the key modality along with more sophisticated radiotherapy in the primary management of head and neck cancers. With the use of routine postoperative radiotherapy, we are curing more primary head and neck cancer but are seeing far more distant metastases than before. Chemotherapy is used widely for advanced cancer, but has a devastating effect on the immune system. An ideal single agent has yet to be found, so that a protocol of multiple agents is frequently used in advanced squamous carcinomas of the head and neck.

Currently we are faced with a perplexing problem of autoimmune deficiency disease transmitted by blood and semen in our homosexual population and intravenous drug abusers. Kaposi's sarcoma presents frequently in the head and neck area and is a strong challenge to the laryngologist and oncologist.

We have overcome the challenges of the past, and we shall overcome the medical challenges of the present. Let us hope that the future generations of laryngologists will maintain the high standards of professional excellence set forth by our Association and forever continue its great traditions.

BIOGRAPHY OF GABRIEL F. TUCKER, SR

JOHN A. TUCKER, MD

Few men have figured as prominently in the founding and development of a medical specialty as has Dr Gabriel F. Tucker, Sr, in the field of bronchology, esophagology, and laryngeal surgery.

Gabriel Tucker, Sr, was born in 1880 on a small island in the Ohio River, at Wheeling, West Virginia, the son of a farmer. His mother died during his infancy of tuberculosis, and he was raised by his grandmother and stepmother. He received his education in Fairmont, West Virginia, and matriculated at the College of Physicians and Surgeons of Baltimore in 1901. In 1903, he returned to West Virginia with an exacerbation of what was considered tuberculosis.

In late 1903, he entered Jefferson Medical College and was a graduate of the class of 1905. He served as a resident in surgery at Mercy Hospital in Pittsburgh for 3 years and became associated with Dr C. Dickenson in otolaryngology and Dr R. Stewart in general surgery.

In 1910 he went into general practice in Cannonsburg, Pennsylvania. It was during these Pittsburgh years that first he contacted Dr Chevalier Jackson on professional consultation.

In 1917 he joined the army with the rank of captain under the command of Colonel G. Snyder, a classmate from Jefferson, who later became President Dwight D. Eisenhower's personal physician. On discharge from the service in 1919, he returned to Philadelphia seeking a surgical specialty. On the advice of Dr Lawrence Flick, Chief of Medicine at the Pennsylvania Hospital and author of a major treatise on tuberculosis, he contacted Dr Chevalier Jackson and an "exciting new specialty." It is interesting to speculate on the similar geographical background and common subjective bond in tuberculosis that may have motivated the association of Dr Jackson and Dr Tucker at Jefferson Medical College and Hospital "in a bronchoscopic clinic in a backroom."

In 1921, a clinic, the first in the world devoted to bronchoesophagology, was established at the Graduate School of Medicine at the University of Pennsylvania Hospital; Dr Tucker became a charter member of the department and a recognized, accomplished, dedicated teacher.

In 1930, he resigned from Jefferson and from that time until 1947 was Professor of Bronchology and Esophagology in the Graduate School of Medicine at the University; in 1932, instruction in laryngeal surgery was added to that in bronchoesophagology. In 1949, an anonymous donor established the Gabriel F. Tucker Chair of Bronchoesophagology and Laryngeal Surgery.

The Gabriel Frederick Tucker Family, Christmas 1930. Standing — Gabriel Frederick, Sr; from left to right — Chevalier Jackson, Gabriel Frederick, Jr, John Anwyl, and Beatrice Jarvis.

Dr Tucker also established bronchoscopic clinics at multiple Philadelphia hospitals including, in 1930, the Children's Hospital of Philadelphia.

Dr Tucker had considerable mechanical ability and contributed a number of original and modified instruments including pediatric endoscopes, twin-lighted endoscopes, endoscopic forceps, pediatric tracheotomy tubes, a valvular talking tracheotomy tube, and Tucker retrograde bougies. The latter was first presented nationally as a candidate's thesis for the Triological Society in 1924, the same year that Gabriel, Jr, was born. The retrograde method of esophageal dilatation in cases of cicatricial esophageal stenosis has found wide application with its safety and efficiency over these many years.

Among Dr Tucker's other outstanding contributions were the recognition of postoperative pulmonary atelectasis and its causes, the popularization of bronchoscopy for the treatment of postoperative atelectasis, along with Doctors I. S. Ravdin, W. E. Lee, and Louis Clerf in 1927, and the pioneering of color cinematography of the larynx in 1936.

In 1923, Dr Tucker married Beatrice Jarvis of Philadelphia. They had three sons, Gabriel, Jr, Chevalier Jackson, and John (see Figure). He died at home in 1958, at the age of 77.

ORIGINAL INSTRUMENTARIUM

Tucker GF. A bronchoscopic tack- and pin-forceps. Laryngoscope, December, 1922.

Tucker GF. A bronchoscopic double point grasping staple forceps. Ann Otol Rhinol Laryngol 1925;34:772-3.

Jackson C, Tucker GF, Clerf LH. Laryngostasis and the laryngostat. Arch Otolaryngol 1925;1:167-9.

Tucker GF. Retrograde laryngoscope. Ann Otol Rhinol Laryngol 1925;34:774-5.

Tucker GF. Bronchoscopic lipiodol instillation tubes. Ann Otol Rhinol Laryngol 1927;36:272-3.

Tucker GF. Technic of bronchoscopic introduction of bismuth subcarbonate and iodized oil, 40 per cent, for pneumonography. Arch Surg 1927;14:175-83.

Tucker GF. An endoscopic dilator for stretching the hiatal esophagus in preventriculosis (so-called cardiospasm). Trans Am Bronchoscopic Soc 1929:13-15.

Tucker GF. An infant bronchoscope. JAMA 1932;99:1899-902.

Tucker GF. An infant esophagoscope and gastroscope. Ann Otol Rhinol Laryngol 1932;41:1269-72.

Tucker GF. A forceps for measuring the larynx. Trans of Section on Laryngol Otol Rhinol of the Am Med Assoc, Philadelphia, 1930.

Tucker GF. Apparatus for treatment of laryngeal stenosis. Trans of Section on Laryngol Otol Rhinol of the Am Med Assoc, Philadelphia, 1930.

Tucker GF. Three laryngeal instruments. Ann Otol Rhinol Laryngol 1934;43:1128-30, 1132.

Tucker GF. A technique for motion picture photography of the larynx in color. Trans Am Laryngol Assoc, 1939.

Tucker GF. (1) A child size esophago-gastroscope; (2) an adult esophago-gastroscope. Ann Otol Rhinol Laryngol 1936;45:1179-80.

Tucker GF. Cardiospasm: a pneumatic-mercury dilator. Ann Otol Rhinol Laryngol 1939;48:808-16.

Tucker GF. A laryngectomy tube screen. Philadelphia.

Tucker GF. A modification of the Mackenty artificial larynx. Trans Am Laryngol Assoc 1941;63:138.

Tucker GF, Lautz V, Tracy JB, Fearon BW. The diagnosis and treatment of benign stenosis of the esophagus, with special reference to treatment by dilatation with the indwelling cannulated bougie. Ann Otol Rhinol Laryngol 1950;59:823-36.

PRESENTATION OF THE GABRIEL F. TUCKER AWARD TO SEYMOUR R. COHEN, MD

LORING W. PRATT, MD

In July 1987, Gabriel F. Tucker, Jr, wrote me that he had set aside $5,000.00 in his will to be paid to the American Laryngological Association after his death for the purpose of establishing an award to be known as the Gabriel F. Tucker Award. The interest money from this gift is to be used by the Association at its discretion to provide an honorarium for a guest speaker at Association meetings on the subject of pediatric laryngology, or to present a medal in any given year to an individual of noted achievement in that field. In his letter Gabriel wrote, "Since pediatric laryngology is something that was close not only to my heart but to my father's heart, I think the simple designation Gabriel F. Tucker Fund will cover it, if this is in accordance with the will of the Council."

Following Gabriel's untimely death, contributions were made in his memory, and the fund now stands at nearly $15,000.00. The Council has accepted these gifts and is ordering a medal struck for this award. Gabriel indicated that he would like to have Seymour R. Cohen be the first recipient of this medal.

Doctor Seymour R. Cohen was born and educated in Chicago, obtaining his BS, MD, and an MS in biochemistry at the University of Chicago. He is a member of Alpha Omega Alpha, a testimony to his excellent educational performance. Only after he had completed his education did he follow Horace Greely's advice and move west to Los Angeles where he took his residency training in otolaryngology.

His participation in the affairs of otolaryngology has led him to memberships in most of the national societies relevant to otolaryngology, and he has been the winner of the Triological Award for the Candidate's Thesis distinguished for its excellence, The John MacKenzie Brown Award for the most outstanding paper of the year, the Silver Medal of the American College of Surgeons for his participation in the Symposium on Spectacular Problems in Surgery, and the Chevalier Jackson Award of the American Broncho-Esophagological Association.

He is a dedicated teacher and has been Clinical Professor of Surgery in Otolaryngology at the University of Southern California Medical School from 1969 to the present.

Seymour has been a prolific writer and lecturer over the years. He is a rather quiet man, and his performances follow an interesting pattern in many cases. It is quite common for someone to present a paper on one or two cases of some unusual problem, and in the discussion Seymour will report on an additional ten or 12 cases of the same problem. He has been a dedicated investigator and teacher, and he has contributed enormously to the care of children suffering from laryngeal disease. Because of his many and continued contributions to this field of laryngology, it is my pleasure to present the first Gabriel F. Tucker Award to Seymour R. Cohen.

RESPONSE OF THE RECIPIENT OF THE GABRIEL F. TUCKER AWARD

A MEMORIAL TO GABRIEL F. TUCKER, SR

SEYMOUR R. COHEN, MD

Dr Pratt, Dr Myers, Dr Lewis, Mary Tucker, Dr John Tucker, members and guests of the Association. To receive the Gabriel F. Tucker Award is a highlight of my career as a pediatric otolaryngologist. I am deeply honored and am very grateful to the Association and the Tucker family. It was Gabe's desire that I present a brief history of pediatric otolaryngology. I accepted this challenge gladly, but found the subject so extensive that it was impossible to cover within the short period of time allotted me. It has, however, stimulated me to write a more detailed review of the field at a later date.

The Tuckers, father and sons, were instrumental in establishing the neophyte subspecialty known as pediatric otolaryngology. Specialization is not new, in fact it dates back to ancient Greek medicine. Over the years, the state of the art has changed tremendously due to the development of new technology. Antibiotics, immunizations, and virtual eradication of diseases such as tuberculosis, syphilis, diphtheria, and poliomyelitis have also occurred. The enormity of the advances in radiographic studies, in surgical techniques including the use of the laser, in diagnosis and treatment of congenital defects, and the development of new procedures for the delivery of anesthesia have all substantially increased the length and depth of training programs. Audiovisual and other photographic documentation methods previously impossible in the study of the child have now become a reality. This subspecialty is the direct result of concerted efforts on the part of physicians who were and are dedicated to the care of the infant and child. It is through such dedication and planning that the efforts of many culminated in the establishment of the American Society of Pediatric Otolaryngology in April 1985. The first annual meeting was held in Santa Barbara, California, in 1986. I am honored to have been elected the society's founding president. Although in its infancy, the society will grow and develop; yet like the young still will remain somewhat dependent on its parent societies, including the important American Laryngological Association. Pediatric otolaryngology has stimulated great interest and has been accepted by the older, more established specialty organizations of otolaryngology.

The name Tucker is indelibly etched in the annals of laryngology, bronchoesophagology, and pediatric otolaryngology, and is known for its many contributions to research in and the development of laryngology. The Tucker bougie, so well designed, safe, and effective, has saved the lives of so many with congenital and acquired stenotic lesions of the esophagus, that this instrument alone will perpetuate the family name.

Pediatric otolaryngology, bronchoesophagology, and laryngology have suffered a great loss with the untimely death of Gabriel F. Tucker, Jr. We who were his friends and colleagues share this loss. We all will miss sorely Gabe's usual pacing in these auditoriums, and John will miss his "pointer."

Pediatric otolaryngology unquestionably had its beginnings in the history of laryngology and bronchoesophagology. This does not mean that during this early period of pediatric medicine, the fields of rhinology and otology and treatment of diseases of the paranasal sinuses, the tonsils and adenoids, and neck infections also were not beginning to expand. In 1941, A. J. Cone presented a paper on diseases of the sinuses in children in which he stressed the emotional aspects of nasal and paranasal sinus disease. Heated discussions followed with suggestions that if emotional causes were of such import, grandmothers should be killed off, fathers could be kept out of the picture, and mothers should be relegated to the bridge club in order to hasten the child's recovery. As you see, the pediatric psychiatrist's viewpoint reared its head some 45 years ago. At the same meeting, Wasson reported the syndrome of bronchosinusitis and revealed his findings that if sinusitis is eradicated, the bronchial disease will subside. Clearly, the causal relationship has been verified today.

The Section on Otology, Rhinology, and Laryngology received independent status in the American Medical Association in 1888. Surprisingly enough, membership was open to all members of the American Medical Association. Early leaders in the development of otolaryngology as a specialty founded institutions for the care of the eye and ear diseases. Other pediatric specialties also developed during this period, and it is strange that there were no specialized arrangements made in these institutions to cooperate with pediatric divisions. While children's hospitals had divisions of otolaryngology, there were no pediatric otolaryngologists as such, and in

From the University of Southern California School of Medicine, Los Angeles.

Presented at the meeting of the American Laryngological Association, Denver, April 25-26, 1987.

REPRINTS — Seymour R. Cohen, MD, 1300 N Vermont Ave, Los Angeles, CA 90027.

some instances, they were considered an unnecessary burden.

R. Pracy in his Semon Lecture in 1980, hosted by the Royal College of Surgery, credited Professor Jan Danielewicz with developing pediatric otolaryngology in Poland around the beginning of World War II. The subspecialty, however, remained confined to the Eastern Block countries. When the Iron Curtain was "lifted," visiting professors and physicians from the West began to travel, and it was during the 1950s that departments of pediatric otolaryngology began to appear in Italy, France, the Federal Republic of Germany, and Scandinavia. A. F. Pushkin in the USSR, in the early 1930s, aroused interest in direct laryngoscopy with his article on intubation under control of sight, in which he referred to tracheotomy as "the bloody one" and intubation as "the bloodless one."

The origin of pediatric otolaryngology and head and neck surgery within the United States and Canada is unknown. The developmental process was disorganized and haphazard. Papers on various problems in the pediatric age group began to appear in the literature and were presented at national medical societies in increasing numbers.

While laryngology dates back to the pre-Jacksonian era, it is Chevalier Jackson who can be considered the father of pediatric bronchoesophagology and laryngology. There were many others before him who pioneered laryngology around the country and in Canada, and who were stimulated by the overwhelming and rampant spread of diphtheria. While intubation had been performed prior to these epidemics, it was this disease that actually gave impetus to intubation for the relief of obstruction and therefore directed efforts toward pediatric endoscopy. The specialty began to flower when Chevalier Jackson moved to Pittsburgh in 1916 and at the age of 35 was elected to the Chair of Laryngology at the Western Pennsylvania Medical College. With his move to Thomas Jefferson University, this strength broadened greatly to include all of laryngology and bronchoesophagology. Patients were referred to him and his associates from all over the world.

Gabriel F. Tucker, Jr, sent me a genealogy of Jackson and associates in 1975 (see Figure). One sees in this outline physicians of great prominence who have impressed medical history through the enormity of their contributions both during and after the Jackson era. It is these men and women who have contributed so much to the foundation of pediatric otolaryngology, even though their practices also included the care of the adult. Notice should be made of Dr Emily Van Loon, who was probably the first full-time academician and pediatric laryngologist in this country. She was placed at the St Christopher's Hospital for Children by Dr Jackson as Director of Pediatric Laryngology.

Of all the Jackson associates, it was Gabriel F. Tucker, Sr, who became Associate in Bronchoesophagology at the University of Pennsylvania and succeeded Dr Jackson as Professor and Head of the Department of the Graduate School of Medicine. He remained in that position until his retirement. Among his innumerable contributions, he created new instruments and methods of measuring the infant larynx, and he was first to suggest endoscopy prior to irradiation of the thymus for the diagnosis of dyspnea of the child.

In the Midwest, Paul H. Holinger advanced the cause of pediatric otolaryngology with his monumental work on the diseases of the air and food passages in the pediatric patient. A chance encounter with Joseph Brubaker in 1945 resulted in the earliest documentation by motion pictures in the field of laryngology and bronchoesophagology.

On the West Coast, in the early 1930s, Simon Jesburg became a force in the development of laryngology and bronchoesophagology. He was innovative and redesigned endoscopes so that less trauma occurred to the delicate structures that were being examined. He opened the Eye and Ear Hospital, which for many years was used by the Children's Hospital of Los Angeles and the Los Angeles County Hospital for specialized endoscopic needs of the child as well as the adult.

Associated with Jesberg was Alden H. Miller, a former President of this Assocation, who while not exclusively a pediatric otolaryngologist, was prominent in pioneering the causes of problems of the child's larynx and airway. His classic paper on epiglottitis caused by *Hemophilus influenza* type b alerted both pediatricians and otolaryngologists to the importance of this highly malignant form of laryngitis.

Contributors to pediatric otolaryngology were as follows. Horace Green, Louis Elsberg, Jacob Solis-Cohen, George M. Lefferts, D. Bryson Delavan, Emil Mayer, and John N. Mackenzie were pioneers of laryngology. St. John Roosa, Blake, Green, Francke H. Bosworth, Deuch, Norval Pierce, and Duel contributed to early otology. In rhinology, Morris J. Asch, Otto T. Freer, William L. Ballenger, Harris P. Mosher, Greenfield Sluder, and Ross H. Skillern all added to our knowledge of the paranasal sinuses. In special training centers away from the Eastern cities, men like Ernest L. Shurly, John Green, Sr, E. Fletcher Ingals, Joseph C. Beck, Arthur W. De Roaldes, Henry Wagner, Adolph Barkan, John C. Barnhill, Robert Levy, Samuel Iglauer, Herbert S. Birkett, and Perry G. Goldsmith all were at the forefront of otolaryngology.

On the North American continent, in the early 1950s, four physicians limited their practices to children. These pioneers in pediatric otolaryngolo-

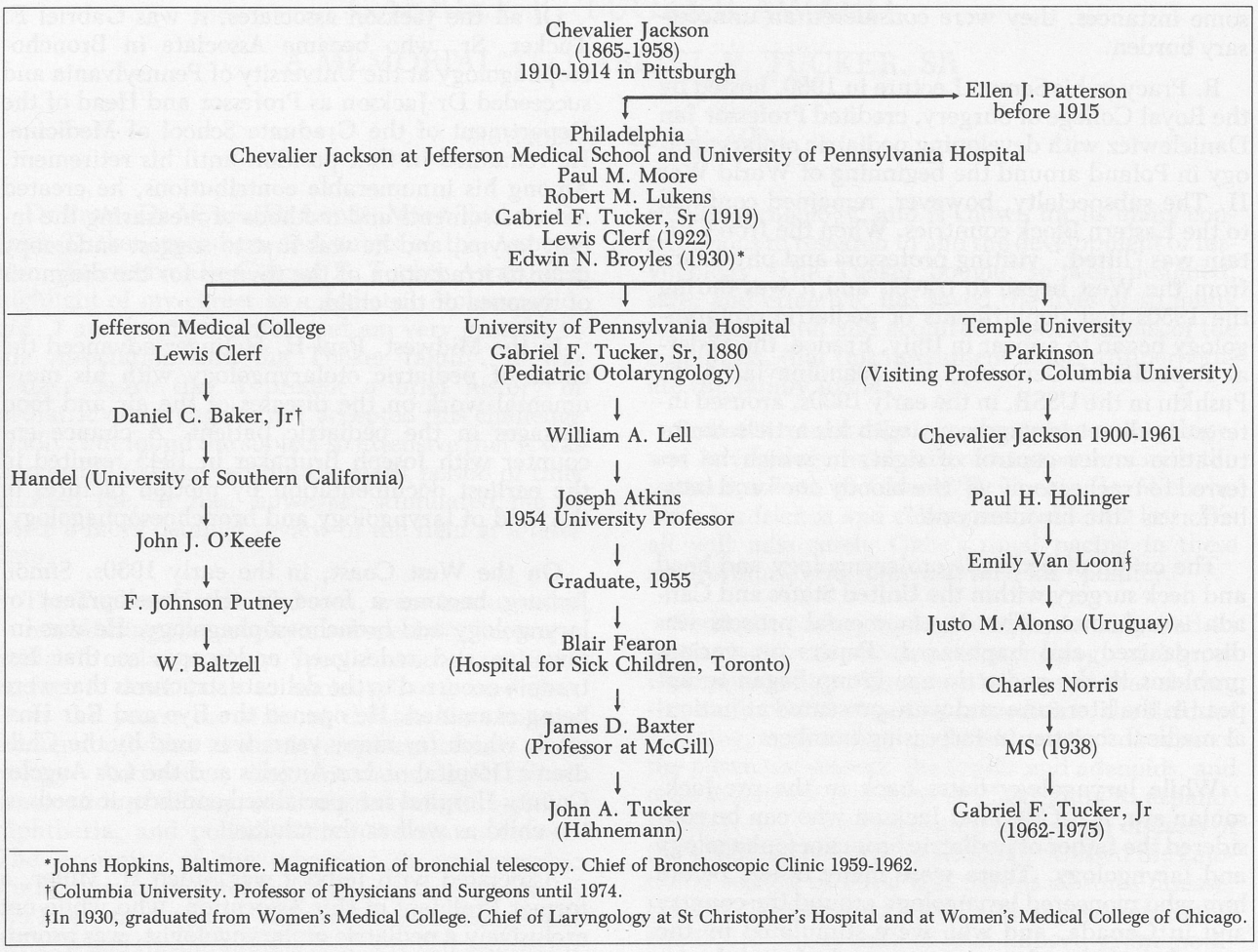

Genealogy of Chevalier Jackson and associates according to Gabriel F. Tucker, Jr.

gy were Charles F. Ferguson, Blair W. Fearon, Herbert G. Birck, and me.

Charles F. Ferguson served for over 34 years at the Children's Hospital Medical Center in Boston. He is the author of 40 or more papers and chapters in medical texts and is the author of a textbook on pediatric otolaryngology published in 1972. He is a past President of this Association.

Blair W. Fearon, at the University of Toronto, had specialty training under Gabriel F. Tucker, Sr, at the University of Pennsylvania. He returned to the Hospital for Sick Children in Toronto and was a pioneer in pediatric otolaryngology. His basic research on the larynx has been responsible for many of the procedures used in the treatment of laryngotracheal stenosis. He is the President-Elect of this Association.

Herbert G. Birck was trained at the Ohio State University Hospital in otolaryngology from 1954 to 1957. In 1962 he limited his practice to pediatric otolaryngology and has been the Chief of the Department of Pediatric Otolaryngology at the Children's Hospital in Columbus, Ohio. While his service does not have fellowships, he has four residents receiving specialized training in pediatric otolaryngology.

In the West, an area once considered backward or lagging in the development of otolaryngology and laryngology, I became interested in the pediatric patient very early in my career. After training at the University of Illinois Medical School, I had my residency at the University of Southern California-Los Angeles County Medical Center under John Mackensie Brown, a Fellow of this Association. After witnessing the tremendous emotional trauma suffered by children and, in fact, their parents also during and after surgery and hospitalization, I decided to direct my attention to resolving what was clearly something heretofore lacking in pediatric practice — the avoidance of reinforcing the separation neurosis in children. Night terrors and regressive behavior such as a return to bed-wetting, thumb-sucking, fear of going to school, and fear of maternal abandonment or disappearance frightened the parent and overwhelmed the switchboard. I saw the critical need to develop a method of preparing child and parent for hospitalization and surgery. The rooming-in of child and parent was made a priority, and with these changes I noted

dramatic and gratifying results. Today, hospitals have tours for preparing the child and the parent, and rooming-in is commonplace. Library shelves are stacked high with books on the subject. This simple beginning was my motivation for becoming a pediatric otolaryngologist.

Around 1973, a few members of the American Academy of Ophthalmology and Otolaryngology interested in pediatric otolaryngology met in Las Vegas and created the organization now known as the Society for Ear, Nose, and Throat Advances in Children (SENTAC). It grew so rapidly, and its base became so broadened, that it overwhelmed its original intent. While ostensibly for pediatric otolaryngologists, the organization became filled with speech therapists and audiologists. Because there still remained an overwhelming need for a physician-oriented pediatric group, the Pediatric Study Group was formed. The first meeting was held under the direction of Charles Bluestone at the Children's Hospital in Pittsburgh, and other meetings were held at major pediatric hospitals with established pediatric otolaryngologists such as Robin Cotton in Cincinnati, Gerald Healy in Boston, and William Potsic in Philadelphia.

By 1977, the Pediatric Study Group became unnecessary with the establishment of a Section on Pediatric Otolaryngology within the American Academy of Pediatrics. This section had its first meeting in 1978 and has served as the main driving force to establish criteria for the needs of the pediatric patient.

Of the children's hospitals in the United States, 50 are general hospitals, two specialize in the care of chronic disorders, 23 are orthopedics-oriented, 15 are of other specialties, 27 are psychiatric, and ten specialize in rehabilitation.

Thirteen hospitals responded to my survey (personal review). Among these, six support pediatric otolaryngology fellowships. Blair Fearon of Toronto and Charles Bluestone at Pittsburgh were the first to initiate pediatric training fellowships in 1975. Training fellowships are available at the University of Cincinnati under Robin Cotton, the Albert Einstein College of Medicine, New York, under Robert Ruben, the Boston Children's Hospital under Gerald Healy, the Children's Hospital in Washington, DC, under Kenneth Grundfast, the Children's Hospital of Detroit, under Walter Belenky, and the Hospital for Children in Montreal under Melvin Schloss.

There are other major children's hospitals that do not have training fellowships as yet. John Tucker has become the Chairman and full-time Head of the Department of Pediatric Otolaryngology at the St Christopher's Hospital for Sick Children in Philadelphia. He succeeds Myles Turtz who was Chief of Otolaryngology at that hospital since 1963. Pediatric otolaryngology has lost an excellent teacher and contributor with the retirement of Myles Turtz from the practice of medicine.

The late Gabriel F. Tucker, Jr, left the Jackson Clinic and became the first full-time Chief of the Department of Otolaryngology at the Memorial Children's Hospital in Chicago in 1975. With his death, his associates, Lauren Holinger and Carol Gerson carry on the administration of his department.

Roland Eavey became the first full-time Chief of the Division of Pediatric Otolaryngology at the Massachusetts Eye and Ear Infirmary in 1980. He is a board-certified pediatrician and otolaryngologist and will be of considerable aid in cementing the relationship of the subspecialty with the pediatric community.

Francis Catlin is the current President of the American Society of Pediatric Otolaryngology. He is also a tremendous force in the establishment of pediatric otolaryngology as a subspecialty.

In the West, Donald Hawkins, Associate Professor of Otolaryngology at the University of Southern California, is Chairman of the Section of Otolaryngology of the American Academy of Pediatrics and is a member of the Board of Directors of the Society of Pediatric Otolaryngology.

We must credit Mark Richardson, who became the full-time Chief of the Department of Otolaryngology at the Orthopedic Hospital for Children in Seattle, for help with the development and creation of the Society of Pediatric Otolaryngology of which he is now the Secretary-Treasurer.

On the West Coast, Jerome Thompson, my associate of 7 years and a dedicated pediatric otolaryngologist, is on the teaching service at the Children's Hospital of Los Angeles and is an Associate Clinical Professor at the University of Southern California School of Medicine. He is a product of Paul Ward's training program at the University of California at Los Angeles, and has an impressive curriculum vitae that shows his abilities in basic and clinical research. To Paul Ward, who has been a major supporter of pediatric otolaryngology, the American Society owes a great debt.

There are many young pediatric otolaryngologists who have not been mentioned. This is by no means an attempt to demean their importance. It is only because of time constraints and space limitations that they have not been introduced to you. Their places in the sun will come at another time.

To the Tucker family and for the world of children, many thanks for this award. I could not help but add a word of thanks to my wife, Dee, for her patience and love in spite of the many hours of absence and delayed dinners. Her support is deeply appreciated and has carried me on for all of these years.

BIBLIOGRAPHY

Cone AJ. Sinus disease in children. Trans Am Acad Ophthalmol Otolaryngol 1941-1942;46:79-94.

Denzer BS, Felshin G. The pre-tonsillectomy clinic. J Pediatr 1943;22:239-49.

Fenton RA. A brief history of otolaryngology in the United States from 1847-1947. Arch Otolaryngol 1947;46:153-62.

Furstenberg AC. A chronicle of 100 years of otolaryngology. Laryngoscope 1947;57:596-615.

Proctor DF. The nose and paranasal sinuses and ears in childhood. Springfield, Ill: Charles C Thomas, 1963:3-17.

Stevenson RS, Guthrie D. A history of otolaryngology. Edinburgh: E & S Livingstone, Ltd, 1949.

Szekely E, Farkas E. Pediatric bronchology. Baltimore, Md: University Park Press, 1978.

Tucker GF. Strictures of the esophagus: diagnosis and treatment. Laryngoscope 1931;41:426-39.

Tucker GF. Obstructive laryngeal dyspnea. Trans Am Laryngol Assoc 1927;33:324-31.

Wright J. A history of otolaryngology and rhinology. 2nd ed. Philadelphia: Lea and Febiger, 1914:320-7.

SCIENTIFIC SESSIONS

HISTOCHEMICAL STUDY OF POSTERIOR CRICOARYTENOID MUSCLE REINNERVATION BY A NERVE-MUSCLE PEDICLE IN THE CAT

JOSEPH J. FATA, MD
LESLIE T. MALMGREN, PHD
RICHARD R. GACEK, MD
RICHARD DUM, PHD
PEAK WOO, MD
SYRACUSE, NEW YORK

Reinnervation of the posterior cricoarytenoid (PCA) muscle with a nerve-muscle pedicle (NMP) has been proposed for patients with bilateral abductor vocal cord paralysis. Since its success has been controversial, a glycogen depletion histochemical technique was used to examine reinnervation. An ansa cervicalis NMP was implanted into the denervated PCA in nine cats. Eight months later, vocal cord activity was evaluated. The NMP nerve was stimulated extensively in seven cats (experimental group). Optical densities of NMP-supplied PCA muscle fibers from experimental and control groups were compared to detect differences in glycogen content. The results demonstrated quantitative evidence of reinnervation in two experimental animals. Electrical stimulation of the NMP produced abduction in one of these two animals, but was never observed during spontaneous respiration or airway occlusion. These observations indicate that reinnervation can occur but abduction requires electrical stimulation. The NMP technique may be more successful with an electrical pacer.

KEY WORDS — glycogen depletion, nerve muscle pedicle, posterior cricoarytenoid muscle.

INTRODUCTION

Bilateral abductor vocal cord paralysis confronts the otolaryngologist with a series of difficult management decisions. A tracheostomy often is required to secure the airway, but it is seldom satisfactory to the patient as a long-term solution. Vocal cord lateralization procedures, such as the Woodman arytenoidectomy,[1] allow decannulation in many patients, but at the expense of transforming a previously acceptable voice into one that is weak and breathy. These procedures also increase the risk of aspiration.

Reanastomosis of the recurrent laryngeal nerve (RLN) usually has been unsuccessful, probably because of the diffuse distribution of abductor and adductor nerve fibers throughout the course of the nerve.[2] This anatomic arrangement results in inappropriate innervation of abductor muscles by adductor nerve fibers, with subsequent paradoxical vocal cord motion.

The concept of selective reinnervation of the posterior cricoarytenoid (PCA) muscle to restore abductor function was proposed first by Doyle et al,[3] who implanted the cut end of the RLN into the PCA muscle. In a later application of this principle, Hengerer and Tucker[4] proposed reinnervation of the PCA muscle using a nerve-muscle pedicle (NMP) based on the innervation of the ansa cervicalis nerve to the strap muscles.

The NMP originally was designed so that its muscle pedicle would incorporate most of the distal nerve fibers, in hope of minimizing the number of cut nerve endings and subsequent neuroma formation.[5] Tucker chose the sternohyoid (and later omohyoid) muscle because of its role as an accessory muscle of respiration, which he believed would provide an appropriately timed neural discharge in the respiratory cycle.

The successful results in the initial animal experiments of Hengerer and Tucker[4] and Lyons and Tucker[6] were based on observed vocal cord motion, electromyographic (EMG) tracings, and histologic sections confirming the presence of nerve fibers. Based on this data, the NMP was applied in humans, and Tucker[7] reported a long-term success rate of 88.8% (40 of 45 patients). The NMP implantation in all cases was delayed, with intervals ranging from 6 months to 50 years; success was determined by improved exercise tolerance, findings on indirect laryngoscopy, and ultimate decannulation.

Other experiments, however, have been unable to confirm Tucker's results. The inability of Crumley,[8] Neal et al,[9] and Rice et al[10] to elicit vocal cord abduction in animal experiments using the NMP, as well as the disappointing clinical results of Biller and Lawson,[11] have curtailed general acceptance of this procedure.

Recently, Anonsen et al[12] have presented convincing data that reinnervation with the NMP is possible, but its functional significance in spontaneous respiration remains in question. Renewed interest

From the Department of Otolaryngology and Communication Sciences, State University of New York, Health Science Center at Syracuse, and the Veterans Administration Medical Center (Gacek, Dum, Woo), Syracuse, New York.

Presented at the meeting of the American Laryngological Association, Denver, April 25-26, 1987. This study received The Casselberry Award.

REPRINTS — Leslie T. Malmgren, PhD, SUNY Health Science Center at Syracuse, Dept of Otolaryngology, 750 E Adams St, 156 Weiskotten Hall, Syracuse, NY 13210.

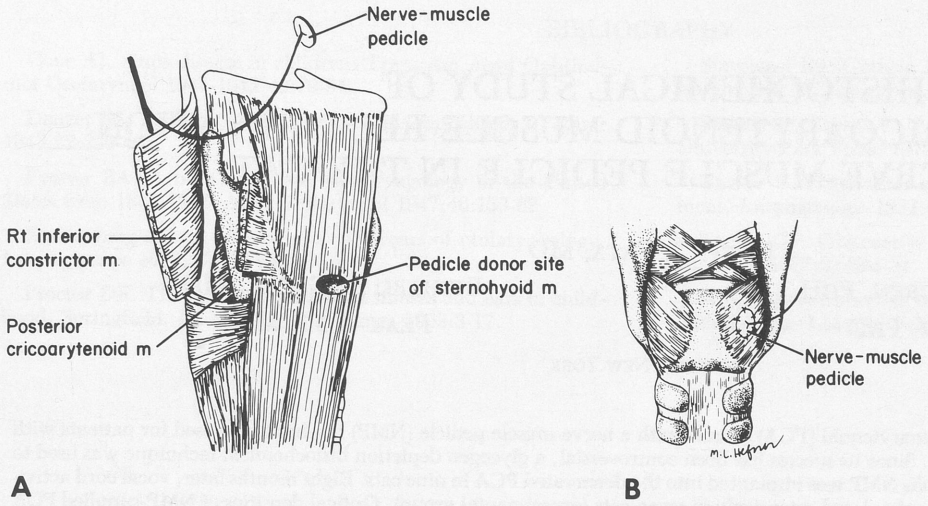

Fig 1. A) Illustration of nerve-muscle pedicle (NMP) harvested from sternohyoid muscle and surgical exposure of posterior cricoarytenoid (PCA) muscle. B) Posterior view of implanted NMP in midportion of PCA muscle.

in the NMP also has been highlighted by the application of electrical pacing by Broniatowski et al[13] with encouraging results.

The purpose of this investigation was to provide evidence for the presence or absence of reinnervation of the PCA muscle with the NMP. For this purpose, we applied the glycogen depletion technique, which is based on the fact that prolonged suprathreshold stimulation of a nerve will deplete glycogen from muscle fibers innervated by that nerve.[14] Originally used to map motor units, depletion of glycogen demonstrates the presence of an intact nerve-muscle pathway, and thus provides direct evidence of reinnervation. The change in glycogen content was determined using quantitative histochemical measurements that were subjected to statistical tests to verify our results. Furthermore, vocal cord activity was observed and recorded under various conditions to correlate with muscle glycogen in selected animals.

MATERIALS AND METHODS

Two normal cats were used to determine the parameters necessary to produce glycogen depletion in the PCA muscle. In each animal, a cuffed electrode was placed around the surgically exposed RLN. Prolonged suprathreshold nerve stimulation was applied (500-ms train of pulses at 40 Hz, delivered once a second at ten times threshold). After the stimulation procedure, a laryngectomy was performed and the larynx was frozen in N-methyl butane cooled to the temperature of dry ice. Serial cross sections 10 mm thick were taken from the midportion of both PCA muscles. The sections were stained for glycogen using a standard PAS technique[15] and then evaluated by light microscopy for evidence of glycogen depletion.

Seven experimental and two control animals then were selected from a group of young adult, colony-bred cats and used for the experimental protocol as follows.

Stage 1. General anesthesia was induced with intravenous (IV) ketamine and nembutal. An NMP was dissected in the right side of the neck. A branch of the ansa cervicalis nerve and the innervated sternohyoid muscle[4,6] comprised the NMP (Fig 1A). The pedicle size varied from 3 to 4 x 2 mm. If this nerve bifurcated close to the muscle, the accessory branch also was dissected free and embedded into the sternomastoid muscle (to avoid any misdirected nerve growth to other muscles of the larynx).

The RLN was identified and transected, and the inferior stump was sutured into the esophageal musculature to prevent regeneration into the laryngeal muscles.

The PCA muscle was exposed by dissecting the hypopharyngeal and pyriform sinus mucosa from the cricoid plate with preservation of the superior laryngeal nerve. The superficial fibers of the midportion of the PCA muscle were incised while maintaining the continuity of the deep fibers. The pedicle was apposed to the prepared fibers of the PCA muscle and secured with two 8.0 nylon sutures (Fig 1B). Incisions were sutured closed, and the procedure was terminated.

Stage 2. After an 8- to 9-month survival period, the animals were studied in stage 2 of the experimental protocol.

Under light general anesthesia using IV ketamine, a tracheostomy was performed, and the trachea was cannulated with a 3.5-mm internal diameter cuffed anode tube.

Direct microlaryngoscopy then was performed using rigid telescopes. Vocal cord motion was observed during spontaneous respiration and after complete occlusion of the anode tube for a period of more than 30 seconds; videotape recordings were made.

The right side of the neck was reexplored, and the nerve to the NMP was dissected free carefully. A 1-

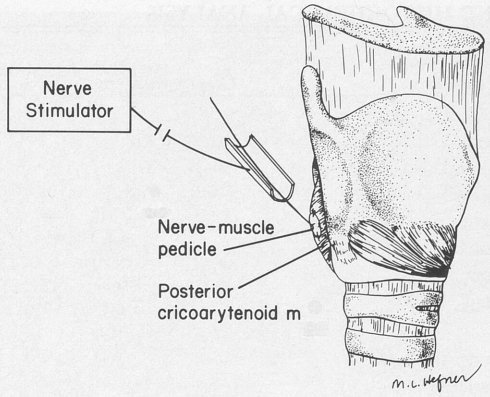

Fig 2. Demonstration of bipolar cuffed electrode in place for electrical stimulation of nerve-muscle pedicle.

cm portion of the NMP nerve was exposed to permit placement of a bipolar insulated cuff electrode (Fig 2).

Direct microlaryngoscopy was repeated. The NMP nerve was stimulated electrically in selected animals using the following parameters: 1) single 0.1-ms square wave pulses at 1.0 and 1.5 V; 2) 40-Hz pulse trains for 2 to 3 seconds at 0.5, 1.0, and 1.5 V.

The animals in the experimental group (E1 to E7) then were prepared for prolonged suprathreshold electrical stimulation to deplete glycogen from successfully reinnervated PCA muscle fibers. Since in some cases the NMP nerve contained branches to the remaining sternohyoid muscle, a pair of EMG electrodes were placed on this muscle to measure twitch thresholds. Electrodes were not placed on the PCA to avoid trauma to the muscle.

Using single square wave pulses, twitch thresholds were established by observing the sternohyoid muscle for visible movement or EMG activity whenever possible. Repetitive nerve stimulation then was performed for a minimum of 1 hour using the following parameters: 1) voltage of ten times threshold (range, 15 to 25 V); 2) 500-ms train of pulses at 40 Hz delivered once a second (effective delivery was 19 to 20 pulses/s). If the EMG amplitude decreased by more than 50% in the first 10 minutes, the train duration was decreased (minimum of 13 pulses/s).

The animals in the control group (C1 and C2) underwent identical procedures, except that suprathreshold nerve stimulation was omitted. A laryngectomy was performed in all nine cats immediately following the last experimental step. The larynx was frozen in N-methyl butane cooled to the temperature of dry ice.

Serial cross sections 10 μm thick at 1-mm intervals were taken through the entire length of the PCA muscle. Periodic acid-Schiff histochemical stains[15] were performed, and each section was evaluated by light microscopy for evidence of glycogen depletion in the NMP-supplied PCA muscle.

Prior studies employing the glycogen depletion technique to map motor units have relied exclusively on judgments regarding the distinction between a depleted fiber and one that has retained its glycogen stores. In this investigation, the standard judgmental technique was supplemented with a quantitative confirmation of depletion in randomly sampled fibers.

Individual muscle fibers were sampled randomly from the experimental animals that demonstrated clusters of glycogen-depleted fibers (after evaluation by four of the authors) and from the two control animals. In the experimental cats, sections exhibiting visible depletion (one level in each animal) were sampled; the contralateral PCA muscle at the same level was sampled to serve as an internal control. The two control animals were sampled at four levels at 1-mm increments on the side containing the NMP.

Muscle Fiber Sampling Technique. One hundred muscle fibers were selected randomly from each section of muscle chosen for analysis in the following manner: the starting point was defined by placing the x and y axes of the microscope lens cross hair at the superior and medial edges of the muscle, respectively. The microscope stage was then moved across the muscle at 0.25-mm increments in both axes in a blind fashion. At each point, the fiber nearest to the cross hair was chosen for analysis.

The optical density (recorded as percent absorption) was measured for each selected fiber using a computer program with a standardized, constant voltage light source. The optical density is directly proportional to the amount of stain picked up by the glycogen molecules and is therefore a quantitative estimate of glycogen content.

Because the optical density was also dependent on the section thickness (which varied considerably), the optical density values were expressed as a percentage of a standardized reference value. The mean optical density of the cartilage matrix, computed separately for each section, was chosen as the reference point because it greatly reduced this variable. A minimum sample size of 30 was used to compute the reference mean for each section, and standard deviations were within acceptable limits.

In addition to our random sampling, we used a nearest neighbor sampling technique. In this technique, whenever the optical density was less than 20% of the mean of the cartilage matrix, we sampled all fibers directly adjacent to this trigger point. If any of the adjacent fibers met the less-than-20% criterion, the nearest neighbor technique was applied again. When none of the adjacent fibers met this criterion, the search was terminated. The purpose of this sampling technique was to demonstrate the marked propensity of depleted fibers to appear in clusters.

TABLE 1. SUMMARY OF MICROLARYNGOSCOPY AND HISTOCHEMICAL ANALYSIS

Animal	*Vocal Cord Abduction*		*Glycogen Depletion*
	Spontaneous	*After Stimulation*	
Experimental			
E1	Absent	Not Tested	No
E2	Absent	Not Tested	NS
E3	Absent	Not Tested	Yes
E4	Absent	Present	Yes
E5	Absent	Present	No
E6	Absent	Absent	No
E7	Absent	Absent	No
Control			
C1	Absent	Present	
C2	Absent	Present	

NS — not statistically significant.

The optical densities of the sampled fibers then were subjected to statistical analysis to verify the significance of differences in glycogen content between the experimental and control groups. This analysis is described in the Results section.

RESULTS

Table 1 summarizes the results of microlaryngoscopy and histochemical analysis of glycogen content in PCA muscle fibers after reinnervation.

Endoscopic evaluation revealed no purposeful vocal cord abduction in any of the animals during spontaneous respiration or after prolonged occlusion of the tracheostomy. A fine quivering of the vocal cord ipsilateral to the NMP-supplied PCA muscle was observed in five of the seven experimental animals and the two controls. This finding was consistent with random firing of small motor units, but also may have resulted from contraction of the cricothyroid muscle or other extrinsic muscles of the larynx. Therefore, we could not accept this observation as evidence of reinnervation.

During spontaneous respiration, the contralateral vocal cord exhibited rhythmic abduction that became more rapid and vigorous after airway occlusion. This observation confirmed that the effects of anesthesia had not suppressed the normal cyclic abduction of the vocal cord during respiration. The response to airway occlusion demonstrated that we had induced adequate hypoxia and hypercapnia for reflex dilatation of the larynx, which, according to Tucker,[7] provides adequate stimulation to the NMP nerve.

The results of single square wave pulsed stimulation (given to E4 through E7, C1, and C2) and trains of pulsed stimulation (given to E5 through E7) were as follows. Animal E4 and the two controls all exhibited a brief but definite vocal cord abduction that was reproducible. During single pulse stimulation, E5 demonstrated a transient cord abduction. When pulsed trains were given, the abduction was sustained for the duration of the stimulus.

Vocal cord abduction in E6 during both single and trained pulse stimulation was inconsistently present. The response ranged from vigorous abduction to inappropriate adduction and, in some instances, no movement. Potential explanations for these findings are reviewed in the Discussion. These endoscopic findings could not be considered supportive of reinnervation.

In E7, the NMP nerve could not be identified. Therefore, the cuffed electrode was placed on the main trunk of the ansa cervicalis nerve. Single pulse stimulation produced artifact secondary to contraction of the strap muscles, and, because of postoperative fibrosis, we could not selectively denervate or divide the strap muscles. Consequently, motion artifact obscured visualization of clear vocal cord abduction.

Histochemical PAS staining intensity for glycogen in the normal PCA muscle in young adult cats varied, with a random distribution of lighter and darker fibers (Fig 3A). Nonstaining PCA muscle fibers were rare, and in no instance did these depleted fibers appear in groups or clusters.

A PAS staining of the PCA muscle in two cats that underwent prolonged suprathreshold stimulation of the intact RLN demonstrated almost complete glycogen depletion. The cat PCA muscle clearly is not completely resistant to the effects of prolonged stimulation.

In the experimental group, clusters of glycogen-depleted muscle fibers (Fig 3B) were found in the NMP-supplied PCA muscle in three of seven animals (E2, E3, and E4). These clusters were located near the midportion of the muscle in all cases. In E2, only one small cluster was found, and its significance could not be supported by statistical analysis. Therefore, statistical data are confined to E3, E4, and the two controls (C1 and C2), with the following results.

The mean muscle fiber optical densities of the NMP-supplied and the contralateral PCA muscle were compared in E3 and E4 (Table 2). The mean

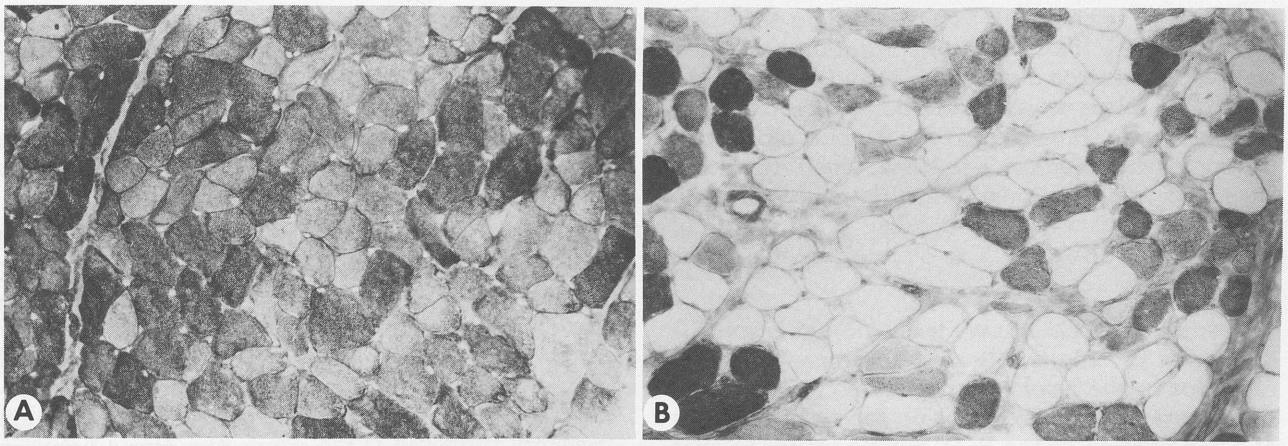

Fig 3. Periodic acid-Schiff glycogen stains (original x50). A) Posterior cricoarytenoid (PCA) muscle of normal cat. Note variable staining intensity, which produces mosaic pattern. B) Nerve-muscle pedicle–supplied PCA muscle in experimental animal E4. Note clustering of glycogen-depleted fibers representing area of successful reinnervation.

optical density for E3 was 0.021 for the NMP-supplied muscle, and 0.049 for the contralateral PCA muscle. The mean optical density for E4 was 0.038 for the NMP-supplied muscle, and 0.056 for the contralateral PCA muscle. Analysis of variance confirmed that the differences in mean values between the paired PCA muscles were statistically significant ($p < .01$) in both animals.

Table 2 also summarizes a comparison of the mean optical densities of the NMP-supplied PCA muscles in the experimental and control animals. The mean optical densities were 0.053 and 0.048 for control animals 1 and 2, respectively. The means of both experimental animals were compared to the mean of each control separately, and in all cases the differences were statistically significant ($p < .01$).

Glycogen depletion in the NMP-supplied PCA muscles of the experimental and control animals were compared further using a frequency distribution of muscle fiber optical densities. All fibers with optical densities of less than 0.05 were grouped into intervals of 0.01. The percentage of fibers falling into each of these intervals was calculated, and the results are seen in Fig 4. The intervals of optical densities of less than 0.020 clearly were dominated by the two experimental animals. Although any cutoff point used to define a depleted fiber is arbitrary, one would expect a partially depleted muscle to have a higher percentage of fibers with optical densities approaching zero. At optical densities of greater than 0.020, the differences in percentages between the experimental and control animals were not as obvious. In the experimental group, they probably represent fibers that were not reinnervated.

DISCUSSION

Nerve-Muscle Physiology. The motor unit is defined as a motor neuron and its set of innervated muscle fibers. The muscle fibers of each motor unit are identical with respect to their histochemical and physiologic profiles. The anatomic arrangement of these fibers, demonstrated by glycogen depletion studies,[16] is one resembling an evenly distributed mosaic pattern. Therefore, any alteration in this mosaic represents a change in the innervation pattern, which can be applied in an assessment of reinnervation.

An important concept in muscle force output is recruitment, defined as the hierarchy of functional response thresholds among motor units under similar conditions. Recruitment is related closely to the subclassification of muscle fibers by Brooke and Kaiser,[17] based on their histochemical and physiologic properties. Burke[18] reviewed several studies addressing this relationship and concluded that type 1 fibers, which are characterized by low tension, slow contraction time, fatigue-resistance, and dependence on aerobic metabolism, have the lowest threshold of recruitment. Type 2B fibers, which are characterized by high tension, fast contraction time, fatigability, and dependence on anaerobic metabolism, have the highest threshold. Type 2A fibers are intermediate in tension, fatigue resistance, and threshold, all consistent with their ability to use both aerobic and anaerobic mechanisms. The properties of type 1 fibers are consistent with their prominent role in muscles that require a low tension and continuous activity, whereas type 2 fibers are generally found in muscles that require short periods of high tension.

The human PCA muscle was shown by Malmgren

TABLE 2. MUSCLE FIBER OPTICAL DENSITY

	Reinnervated PCA		*Contralateral PCA*	
Animal	*Mean*	*SD*	*Mean*	*SD*
Experimental				
E3	0.021	0.013	0.049	0.014
E4	0.038	0.026	0.056	0.019
Control				
C1	0.053	0.022		
C2	0.048	0.018		

Optical density recorded as percent absorption.

and Gacek[19] to consist of 52% type 1 and 48% type 2 (mostly 2A) fibers. This distribution correlates well with its extreme resistance to fatigue, comparable to the soleus muscle in animals,[20,21] and its ability to generate short bursts of high contractile force during airway distress. The enzyme pattern within each fiber type was found to be unusually variable, a finding which may reflect the wide range of motor activity in the PCA muscle previously described by Suzuki and Kirchner.[22]

Overall, the PCA muscle is one of highly specific design for its unique role as the primary laryngeal abductor in the respiratory cycle, both at rest and during exercise. Therefore, any successful attempt at reinnervation of the PCA muscle would require that these histochemical and physiologic characteristics be preserved.

Cross-innervation studies have shown that histochemical and physiologic characteristics of muscle fibers are determined by their nerve supply; these characteristics are capable of a high degree of plasticity and will adapt to a new source of innervation.[23-25] Histochemical studies of cat sternohyoid, sternothyroid, and thyrohyoid muscles have shown a markedly different muscle fiber type distribution compared to the PCA muscle, most notably in the higher percentage of type 2B (fast, fatigable) fibers (Y. Hisa, L. T. Malmgren, R. R. Gacek; unpublished observations). Ultrastructural studies also have shown a high mitochondrial content (necessary for fatigue resistance) in the human PCA muscle compared to the human sternothyroid muscle.[26]

These established observations suggest that reinnervation using an NMP based on the ansa cervicalis may not provide the recruitment sequence or fatigue resistance necessary for normal PCA muscle function. This statement must be qualified, however, by the fact that histochemical data are not available for the omohyoid muscle, the muscle recommended by Tucker for the NMP procedure in humans.[7]

The principle that reinnervation of muscle by a foreign nerve will result in the formation of functioning neuromuscular junctions in denervated muscle, but not in normally innervated muscle, has been well established.[27,28] It also is generally accepted that partial denervation of a muscle will be followed by the recovery of normal tension because of the phenomenon of sprouting (nerve outgrowth from adjacent axons).[29,30] Since denervation studies recently have shown that the growth patterns and rates for foreign nerves and axonal sprouts are very similar,[29] it is likely that reinnervation using the NMP would be governed by the same factors as motor neuron sprouting.

The source of the signal for axonal sprouting is controversial; however, denervated muscle appears to be the best candidate, based on studies that have shown that functional denervation of muscle by chemical agents induces terminal axon sprouting.[31,32] The identity and function of this sprouting mediator has not been elucidated clearly, but the most likely mechanism is felt to be either reduction of a sprouting-inhibitory agent or a denervation product that stimulates nerve growth.[31,32]

Possibly the main limiting factor in terminal sprouting is the maximum growth in the number of muscle fibers in the motor unit. Studies have shown that the maximum growth of the motor unit is four to five times its normal size, which may be related to loss of the sprouting stimulus or a growth limitation of the motor neuron.[33,34] A second limitation recently proposed is the connective tissue between the muscle fascicles, which may act as a physical barrier to nerve growth.[35]

Both the limited motor unit growth and the connective tissue barriers are potential factors limiting the extent of reinnervation by a single NMP, and are consistent with earlier observations by Aitken[27] that reinnervation is optimized by the implantation of multiple axons.

Type grouping is a clustering of muscle fiber subtypes that contrasts the normal mosaic pattern of motor units described above. This pattern represents partial denervation and reinnervation by sprouting of adjacent axons. Histochemical studies of human PCA muscle in elderly patients by Malmgren and Gacek[19] and Teig et al[36] have shown the presence of type grouping, presumably the result of a degenerative, aging process. A study of experimentally reinnervated skeletal muscle also has demonstrated type grouping of motor units using the glycogen depletion technique.[37] Together, these data suggest that the PCA muscle is capable of type grouping, and that any reinnervated fibers in our NMP study identified by glycogen depletion should be found in closely knit clusters.

Experimental Reinnervation. Our experimental results confirm that reinnervation of a denervated PCA muscle using the Tucker NMP can result in the formation of functioning neuromuscular junctions. Using a modification of the glycogen depletion technique, we have demonstrated the presence of a functioning nerve-muscle pathway by our ability to remove glycogen stores from reinnervated PCA muscle fibers through prolonged stimulation of the NMP nerve.

Clusters of glycogen-depleted fibers were observed in three of seven experimental cats, and verified quantitatively using optical density measurements in two of these animals. These two cats will be referred to in the following discussion as the successfully reinnervated animals.

The validity of our results was dependent on the application of strict guidelines regarding glycogen

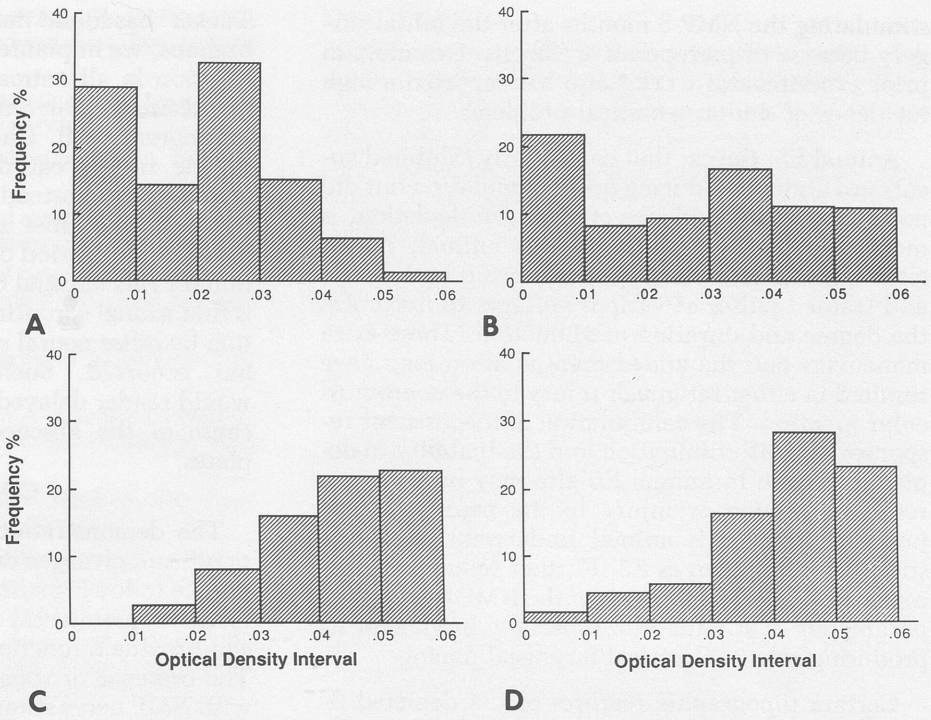

Fig 4. Frequency distribution of glycogen content (optical density, recorded as percent absorption) in reinnervated posterior cricoarytenoid muscle fibers of successfully reinnervated experimental cats and of control group. Note high percentage of depleted fibers (low–optical density intervals) in experimental animals representing areas of known reinnervation. A) Experimental animal E3. B) Experimental animal E4. C) Control animal C1. D) Control animal C2.

histochemistry in the PCA muscle. First, evaluation of the susceptibility of the PCA muscle to glycogen depletion was critical to the credibility of this technique. Successful depletion in two normal cats after prolonged RLN stimulation assured us that the fatigue resistance of the PCA muscle would not impede our later attempts to deplete glycogen through the NMP.

A control group was necessary to assess the effects of denervation and NMP placement on glycogen stores. The two control animals were identical to the experimental group except that prolonged nerve-NMP stimulation for glycogen depletion was omitted. The absence of glycogen depletion in these animals was evidence that loss of glycogen secondary to denervation or placement of the NMP did not occur.

Hengerer and Tucker[4] have noted in animal, and Tucker[5,7] in human studies that although vocal cord abduction after NMP reinnervation may be minimal at rest, occlusion of the trachea will stimulate abduction because of a reflex response to the hypoxia. We did not observe any purposeful motion of the vocal cord ipsilateral to the NMP-supplied PCA muscle, either at rest or after prolonged occlusion of the airway, in any of the nine animals. Histochemical[17] and EMG[38] studies of the sternohyoid muscle suggest that it is not as well suited for the NMP technique as the other strap muscles, which may partially account for the failure to achieve abduction during respiration; however, this muscle was chosen because it was used in the initial animal experiments by Hengerer and Tucker[4] and Lyons and Tucker.[6]

The absence of vocal cord motion in the successfully reinnervated animals is consistent with the data indicating that the ansa cervicalis nerve–sternohyoid muscle system does not possess the appropriate recruitment sequence for adequate function of the PCA muscle. Histochemical and reinnervation studies of the omohyoid muscle will be needed ultimately to determine if it is a more appropriate donor muscle for the NMP.

Another important finding was the vocal cord abduction observed following direct NMP stimulation (performed in one of the two successfully reinnervated animals). The fact that nerve stimulation produced a definite abduction of the ipsilateral vocal cord supports the hypothesis that the glycogen depletion technique is a valid method to assess reinnervation. It also suggests that the recent experiments with laryngeal pacing are a logical direction of pursuit for reinnervation of the PCA muscle.

Using quantitative criteria for successful reinnervation, our experimental results included five failures. The following factors were the most probable reasons for these failures.

The PCA muscles in animals E1, E2, and E7 did not exhibit quantitative evidence of glycogen depletion, and direct nerve stimulation to elicit vocal cord abduction was not performed. Therefore, in these three animals, a functioning NMP–PCA muscle pathway was not established.

Technical errors in the dissection and placement of the NMP into the PCA muscle may have been partially responsible for these failures. Another factor was the difficulty in locating, preserving, and

stimulating the NMP 8 months after the initial surgery because of postoperative fibrosis. Crumley, in prior experimental work,[8] also has reported a high incidence of similar technical problems.

Animal E5, the cat that consistently exhibited vocal cord abduction during nerve stimulation but did not demonstrate evidence of glycogen depletion, is more difficult to explain. In this animal, nerve-NMP stimulation was performed using both single and trained pulses at various voltages to maximize the degree and duration of abduction. These extra maneuvers and the added manipulation may have resulted in either fatigue or injury to the neuromuscular junction. The combination of inconsistent responses to NMP stimulation and the inability to deplete glycogen in animal E6 also may have been a result of fatigue or injury to the neuromuscular junction, since this animal underwent the same stimulation regimen as E5. Further research is necessary to assess the tolerance of the NMP to different parameters of stimulation, especially in view of its promising role in electrical laryngeal pacing.

Certain topographic features of the depleted fibers in the successfully reinnervated animals provided additional information. First, the spatial arrangement of these fibers exhibited certain tendencies. They almost always were arranged in clusters, a finding consistent with the known phenomenon of type grouping in experimentally reinnervated skeletal muscle. Also, they were more concentrated near the superficial surface of the muscle, the site of NMP implantation. This physical proximity would minimize the connective tissue barrier to nerve outgrowth and also favor the sprouting stimulus on the surface of the superficial fibers. Although conclusions regarding the distribution of reinnervated fibers cannot be drawn from this study, the glycogen depletion technique is a potentially useful method to examine this aspect of reinnervation in future experiments.

An impressive feature was the limited extent of reinnervation demonstrated by histochemical analysis. Although technical errors in the prolonged nerve stimulation may have understated our results, studies describing the maximum growth of the motor unit and the physical barriers to nerve growth suggest that the NMP may be capable of only partial reinnervation. The implantation of multiple small NMPs may be a potential solution to this limitation.

Although Lyons and Tucker[6] have stated that reinnervation of the denervated PCA muscle with the NMP can be delayed for up to 6 months in dogs, and Tucker[7] has found that it can be delayed for years in humans, we implanted the NMP at the time of denervation in all animals. This timing was based on unpublished observations (S. E. Schell, L. T. Malmgren, R. R. Gacek) that the denervated PCA muscle in the cat does not undergo progressive atrophy, but instead demonstrates a "reorganization of muscle fiber ultrastructure" 2 to 4 weeks after an initial period of atrophy. A possible explanation for this unusual behavior of denervated muscle is that axonal sprouting and spontaneous reinnervation by other neural systems (autonomic or sensory) has occurred. Such spontaneous reinnervation would render delayed NMP implants ineffective because of the absence of unoccupied motor endplates.

CONCLUSIONS

The demonstration of quantitative, statistically significant glycogen depletion in the denervated PCA muscle following stimulation of the NMP nerve represents experimental evidence that the Tucker NMP can provide a functioning neuromuscular junction. The presence of vocal cord abduction synchronous with NMP nerve stimulation in one of these two animals suggests that this system is potentially capable of providing an adequate airway in bilateral vocal cord paralysis. Several of our observations are not consistent with Tucker's work, however, and we have drawn the following conclusions:

1. Implantation of the Tucker NMP appears to result in only partial reinnervation, possibly because of growth restrictions of the motor unit, physical barriers to nerve growth, or other factors not yet defined.
2. Using the sternohyoid muscle for the NMP technique, vocal cord abduction does not occur under normal physiologic conditions or during total airway obstruction. Experimental histochemical and reinnervation studies of the omohyoid muscle will be needed ultimately to determine if it is a more appropriate donor muscle for the NMP technique.
3. Vocal cord abduction can be elicited by electrical stimulation of the NMP nerve, although our results suggest that this system may be vulnerable to fatigue.
4. Application of the NMP in conjunction with an electrical pacing system, as described by Broniatowski et al,[13] is a promising direction for future research in reinnervation of the paralyzed larynx. Until the technical obstacles of laryngeal pacing can be overcome, however, we cannot support use of the NMP technique in a clinical setting.

ACKNOWLEDGMENTS — The authors thank Joanne Phelan for her help in the preparation of the manuscript, Martha Hefner for the graphic illustrations, and Dr James Brower for his guidance in the statistical analysis.

REFERENCES

1. Woodman DG. A modification of the extralaryngeal approach to arytenoidectomy for bilateral abductor paralysis. Arch Otolaryngol 1946;43:63-5.

2. Malmgren LT, Lyon MJ, Gacek RR. Localization of abductor and adductor fibers in the kitten recurrent laryngeal nerve. Exp Neurol 1977;55:187-98.

3. Doyle PJ, Brummett RE, Everts EC. Results of surgical section and repair of the recurrent laryngeal nerve. Laryngoscope 1967;77:1245-54.

4. Hengerer AS, Tucker HM. Restoration of abduction in the paralyzed canine vocal cord. Arch Otolaryngol 1973;97:247-50.

5. Tucker HM. Human laryngeal reinnervation. Laryngoscope 1976;86:769-99.

6. Lyons RM, Tucker HM. Delayed restoration of abduction in the paralyzed canine larynx. Arch Otolaryngol 1974;100:176-9.

7. Tucker HM. Human laryngeal reinnervation: long-term experience with the nerve-muscle pedicle technique. Laryngoscope 1978;88:598-604.

8. Crumley RL. Experiments in laryngeal reinnervation. Laryngoscope 1982;92(suppl 3).

9. Neal GD, Cummings CW, Sutton D. Delayed reinnervation of unilateral vocal cord paralysis in dogs. Otolaryngol Head Neck Surg 1981;89:608-12.

10. Rice DH, Owens O, Bunnstein F, Verity A. The nerve-muscle pedicle. Arch Otolaryngol 1983;109:233-4.

11. Biller HF, Lawson W. Arytenoidectomy, arytenoidopexy, and the valved tube. In: Snow JB Jr, ed. Controversies in otolaryngology. Philadelphia: WB Saunders, 1980:37-42.

12. Anonsen CK, Patterson HC, Trachy RE, Gordon AM, Cummings CW. Reinnervation of skeletal muscle with a neuromuscular pedicle. Otolaryngol Head Neck Surg 1985;93:48-57.

13. Broniatowski M, Kaneko S, Jacobs G, Nose Y, Tucker HM. Laryngeal pacing: theoretical and practical considerations. In: Baer T, Sasaki C, Harris K, eds. Laryngeal function in phonation and respiration. San Diego: College-Hill Press, 1987:120-30.

14. Edstrom L, Kugelberg E. Histochemical composition, distribution of fibres and fatiguability of single motor units. J Neurol Neurosurg Psychiatry 1968;31:424-33.

15. Dubowitz V, Brook MH, eds. Histological and histochemical stains and reactions. In: Muscle biopsy: a modern approach. Philadelphia: WB Saunders, 1973:28.

16. Levine DN, Tsairis P, Zajac FE. Physiologic types and histochemical profiles in motor units of the cat gastrocnemius. J Physiol (London) 1973;234:723-48.

17. Brooke MH, Kaiser KK. Muscle fiber types: how many and what kind? Arch Neurol 1970;32:369-79.

18. Burke RE. Motor units: anatomy, physiology and functional organization. In: Brookhart JM, Mountcastle VB, Brooks VB, eds. The motor units. 4th ed. Baltimore: Williams & Wilkins, 1981:354-9, 386-90. (Geiger SR, ed. Handbook of physiology; vol 2.)

19. Malmgren LT, Gacek RR. Histochemical characteristics of muscle fiber types in the posterior cricoarytenoid muscle. Ann Otol Rhinol Laryngol 1981;90:423-9.

20. Edstrom L, Lindquist C, Mortensson A. Histochemical properties of intrinsic laryngeal muscle. In: Wyke B, ed. Ventilatory and phonatory control systems. London: Oxford University Press, 1974;392-407.

21. Mortensson A, Skoglund CR. Contractile properties of intrinsic laryngeal muscle. Acta Physiol Scand 1964;60:318-36.

22. Suzuki M, Kirchner JA. The posterior cricoarytenoid as an inspiratory muscle. Ann Otol Rhinol Laryngol 1969;78:849-64.

23. Ellisman MH, Brooke MH, Kaiser KK, Rash JE. Appearance in slow muscle sarcolemma of specializations characteristic of fast muscle after reinnervation by a fast muscle nerve. Exp Neurol 1978;58:59-67.

24. Pearse AGE, McConnell DG. Reversal of the enzyme profiles of muscle fibres in fast and slow muscles by cross-innervation. Nature 1966;5068:1369-70.

25. Buller AJ, Pope R. Plasticity in mammalian skeletal muscle. Philos Trans R Soc Lond [Biol] 1977;278:295-305.

26. Hisa Y, Malmgren LT. Muscle fiber types in the human sternothyroid muscle: a correlated histochemical and ultrastructural morphometric study. In: Baer T, Sasaki C, Harris K, eds. Laryngeal function in phonation and respiration. San Diego: College-Hill Press, 1987:29-44.

27. Aitken JT. Growth of nerve implants in voluntary muscle. J Anat 1950;84:38-49.

28. Aitken JT. Problems of reinnervation of muscle. Prog Brain Res 1965;14:233-62.

29. Brown MC, Holland RL, Hopkins WG. Motor nerve sprouting. Ann Rev Neurosci 1981;4:17-42.

30. Moore RY. Regeneration in the mammalian nervous system. Ann NY Acad Sci 1980;229:102-14.

31. Brown MC, Ironton R. Motor nerve sprouting induced by prolonged tetradotoxin block of nerve action potentials. Nature 1977;265:459-61.

32. Duchen LW, Strich SJ. The effects of botulinim toxin on the pattern of innervation of skeletal muscle in the mouse. Q J Exp Physiol 1968;53:84-9.

33. Brown MC, Ironton R. Variations in the amounts and type of α-motor neuron sprouting following partial denervation of different mouse muscles. J Physiol (Lond) 1978;284:177-8.

34. Thompson W, Janson JKS. The extent of sprouting of remaining motor units in partly denervated immature and adult rat soleus muscles. Neuroscience 1977;2:523-35.

35. Kugelberg L, Edstrom L, Abbruzzese M. Mapping of motor units in experimentally reinnervated rat muscle. J Neurol Neurosurg Psychiatry 1970; 33:319-29.

36. Teig E, Dahl HA, Thorkelsen H. Actomyosin ATPase activity of human laryngeal muscles. Acta Otolaryngol (Stockh) 1978;85:272-81.

37. Edstrom L, Kugelberg E. Histochemical mapping of motor units in experimentally re-innervated skeletal muscle. Experientia 1969;25:1044-5.

38. Ellenbogen BG, Gerber TG, Coon RL, Toohill RJ. Accessory muscle activity and respiration. Otolaryngol Head Neck Surg 1981;89:370-5.

ACQUIRED SUBGLOTTIC STENOSIS IN CHILDREN

FRANCIS I. CATLIN, MD, ScD RICHARD J. H. SMITH, MD

HOUSTON, TEXAS

Subglottic stenosis is a disorder characterized by narrowing of the airway below the glottis or apposing edges of the true vocal cords. In a broad definition, the term may be used to describe airway compromise in the regions of the larynx or the trachea or both. In children, the stenosis is usually due to scar formation secondary to prolonged airway intubation, rather than to external trauma. The location and extent of the stenosis are highly variable; consequently, corrective measures need to be selected to suit the individual problem. In the present series of children, conservative treatment was adequate for lesser degrees of stenosis; those with more severe scarring required external laryngeal surgery. The preoperative evaluation and treatment plans are reviewed.

KEY WORDS — laryngotracheal stenosis, laryngotracheoplasty, subglottic stenosis, tracheotomy.

INTRODUCTION

Laryngotracheal stenosis is a not uncommon complication of disease or trauma in children. Parkin et al[1] have reported that 3% of children in a newborn intensive care unit exhibited subglottic stenosis.

Narrowing of the pediatric airway produces a wide range of signs and symptoms, in proportion to the degree of obstruction. When the obstruction is mild, there may be no more than a slight stridor; when severe, the resulting respiratory fatigue, hypoxia, and risk of asphyxia may require tracheotomy to secure an adequate airway. Unfortunately, tracheotomy in children is associated with significant morbidity and mortality, especially if airway stenosis is severe. In such circumstances, blockage of the tracheotomy tube by mucous plugs or granulations will create a medical emergency for which prompt treatment is needed to avoid asphyxia. At best, the child with a tracheotomy requires constant supervision to monitor the airway. Talking and coughing are more difficult with an open tracheotomy tube, lower respiratory tract infections are more common, and sports activities are limited. Psychological effects of a tracheotomy and tracheotomy dependency are often present, but will not be reviewed here.

Assessment of the extent of the problem and selection of appropriate treatment present significant challenges to the otolaryngologist. The cases reported here indicate that subglottic stenosis is not a single entity; consequently, there is no single therapeutic modality that is appropriate to all. Nevertheless, the ultimate goal remains the same: to produce an adequate, closed airway with a satisfactory voice for communication.

HISTORICAL CONSIDERATIONS

Congenital subglottic stenosis was described by Rossi[2] in 1826. Mackenzie[3] described laryngeal stenosis resulting from trauma and several inflammatory conditions, including syphilis; he tried laryngeal dilation around 1862, but was disappointed in the results. Mackenzie reported that Schroetter[4] of Vienna had tried laryngeal dilation followed by the insertion of vulcanite endolaryngeal tubes, with much discomfort to his patients. In 1915, Jackson recommended intubation dilation for chronic laryngeal stenosis, but noted that "great patience and prolonged treatment, usually a number of years, are necessary for results."[5(p623)] Jackson advocated laryngostomy, an anterior opening of the thyroid cartilage, with incision of the posterior wall of the cricoid cartilage, for severe laryngeal stenosis. A dilating stent was inserted above the tracheotomy tube, and the anterior wound was left open for a period of time, then closed with soft tissue flaps. In 1937, Jackson and Jackson[6] described the use of implanted cartilage flaps for the correction of tracheal stenosis. These cartilages were not applied to the trachea directly because of the lack of asepsis and the unavailability of antimicrobial agents.

Following World War I, a series of patients with traumatic laryngeal stenosis was reported by Rethi.[7] At first, he tried laryngofissure with bilateral division of the cricoid ring at the junction of the posterior and lateral walls. Later, he made a midline sagittal incision in the posterior wall of the cricoid cartilage, with separation of the wall edges until the esophageal muscle fibers were visible. The transverse fibers were removed, and a stent was inserted into the larynx above the tracheostomy until healing occurred.

The correction of upper tracheal defects was also attempted in the 19th century. Koenig[8] used a rib graft to repair a tracheal defect in 1896; von Mangoldt[9] closed a tracheal fistula with costal cartilage in 1900. By 1924, Kindig[10] was reported to have performed six successful tracheoplasties by this tech-

From the Department of Otorhinolaryngology and Communicative Sciences, Baylor College of Medicine, Houston.

Presented at the meeting of the American Laryngological Association, Denver, April 25-26, 1987.

REPRINTS — Francis I. Catlin, MD, Texas Children's Hospital, Box 20269, Houston. TX 77225.

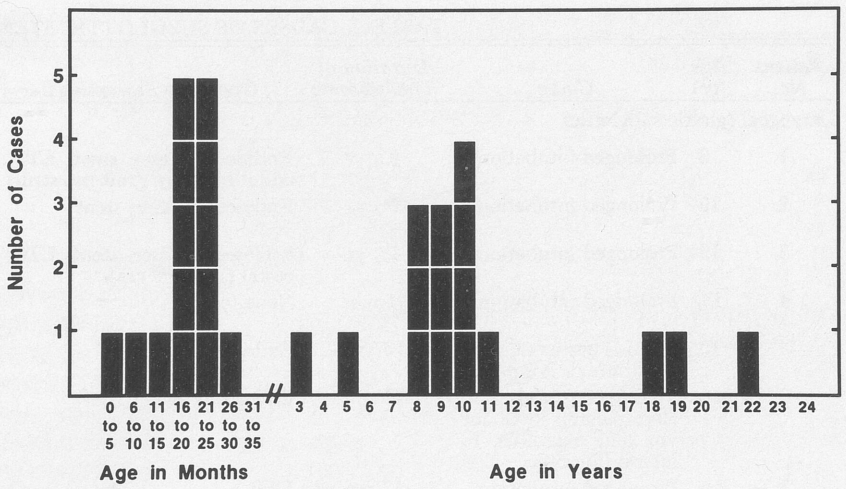

Distribution of cases by age.

nique. In 1927, Fairchild[11] described a multistage skin flap procedure that he attributed to Velpeau[12] (1832). In 1937, Jackson and Jackson[6] described a staged flap procedure in which strips of auricular cartilage were inserted into the tissue that would become the future anterior tracheal wall.

Since these reports, numerous others have entered the medical literature. These range from serial dilation, with or without stenting, to endoscopic removal of stenosis by forceps, electrocautery, carbon dioxide laser, and cryosurgery, as well as open surgical techniques to excise the stenosis and/or widen the airway.

ENDOSCOPIC MANAGEMENT

Conservative endoscopic treatment is effective when the stenosis is slight or when the tissues exhibit an inflammatory reaction rather than severe hard scarring. In 1985, Catlin and Spankus[13] reported a series of 15 children requiring tracheotomy for subglottic stenosis. Of these, four (27%) had a persistent tracheotomy and 11 (73%) were decannulated. Of those decannulated, nine (82%) were treated by dilation and endoscopic removal of airway scars or granulation tissue; two (18%) required open laryngeal surgery (one laryngofissure and one laryngotracheoplasty). The average duration of tracheotomy was 26 months.

A current follow-up of the four children in this series with persistent tracheotomy reveals that two have been decannulated. One of these was treated by serial dilation; the other required endoscopic scar removal by CO_2 laser. A laryngotracheoplasty is planned for the third child. The fourth child, whose laryngeal stenosis is secondary to epidermolysis bullosa, continues to re-form laryngeal scars and is unlikely to be decannulated. Thus, a current follow-up of this series of 15 children shows that 11 (73%) have been decannulated after dilation and/or endoscopic procedures, two (13%) required open laryngeal surgery before decannulation could be done, one child (6.6%) requires a laryngotracheoplasty, and one child (6.6%) will continue to need a tracheotomy.

OPEN SURGICAL MANAGEMENT

Several open procedures to correct laryngeal stenosis have been advocated. Most of these are directed toward glottic and subglottic narrowing. Incision of the thyroid and/or cricoid cartilage has been tried, as in the case of open thyrotomy by Jackson.[5] Others have placed various tissues into the incision to expand the airway: bone, muscle, and cartilage have been tried. Resection of subglottic stenosis with end-to-end anastomosis has also been tried for severe subglottic stricture. In association with these techniques, stenting has been employed by many surgeons, whereas others discourage stents because of their tendency to stimulate granulations. The selection of stent material and the duration of stenting remain unanswered questions. Most stents used today, however, are of the soft, nonirritating type.

When anterior grafting of the cricoid ring provides insufficient increase in the subglottic lumen, sagittal incision of the posterior cricoid cartilage with dilation to expose the esophageal muscle may be performed, as advocated by Rethi[7] or as modified by Grahne.[14]

Narrowing of the trachea by granulation tissue is

TABLE 1. EVALUATION OF LARYNGOTRACHEAL STENOSIS

History
Physical examination
Indirect laryngoscopy
Mirror
Fiberoptic
Neck x-ray study
Xerography
Direct laryngoscopy
Mobility of vocal cords
Tracheoscopy and bronchoscopy
Esophageal swallow study and contrast esophagoscopy
Voice evaluation
Respiratory function tests

TABLE 2. CAUSES OF SUBGLOTTIC STENOSIS

Patient No.	*Age (yr)*	*Cause*	*Duration of Tracheotomy*	*Operative Procedure(s)*	*Procedure(s) Prior to Referral*	*Final Outcome*
Laryngeal (glottic/subglottic)						
1	3	Prolonged intubation	2½ yr	Endoscopy, laser, stent; LTP, costal cartilage graft (no stent)	Dilations	Tracheotomy, treatment in progress
2	10	Prolonged intubation	7½ yr	Endoscopy, laser, stent	Dilations, hyoid interposition	Decannulation
3	19	Prolonged intubation	1½ yr	Endoscopy, laser, stent; LTP, costal cartilage graft	Cordectomy	Decannulation
4	1½	Prolonged intubation	1 mo	None to date	—	Tracheotomy, treatment in progress
5	10	Stenosis postirradiation, mediastinal lymphoma	4 yr	Endoscopy, laser	—	Tracheotomy (glottic scar)
6	2½	Prolonged intubation, cleft palate, small larynx and mandible, bilateral microtia	21 mo	Endoscopy	—	Decannulation
7	1½	Prolonged intubation	17 mo	LTP	Endoscopy	Decannulation
8	10	Prolonged intubation	5 yr	Endoscopy, laser; LTP	Laser	Decannulation
9	8	Head trauma, prolonged intubation	16 mo	Endoscopy, laser	Laser	Tracheotomy, treatment in progress
10	1½	Prolonged intubation, small larynx	11 mo	Endoscopy	Cricoid split	Tracheotomy, treatment in progress
11	3½	Postintubation; respiratory complications	3 yr	Endoscopy	—	Decannulation
12	8	Prolonged intubation	7 yr	LTP, costal cartilage graft, stent	Endoscopy and dilations	Decannulation
13	5 mo	Prolonged intubation	5 mo	Endoscopy	Cricoid split	Tracheotomy, treatment in progress
14	5	Gunshot wound to neck, right vocal cord paralysis, spinal cord injury	1 yr	Endoscopy, removal of subglottic granulomas	—	Tracheotomy, treatment in progress
15	11	Prolonged intubations	NT	Multiple endoscopies, laser	Laser, three times	Asymptomatic
Laryngotracheal (glottic/subglottic/tracheal)						
16	9	Prolonged intubation	NT	Endoscopy, laser	—	Asymptomatic
17	9	Prolonged intubation	8 yr	LTP with costal cartilage graft twice, Rethi procedure once, stent	Dilations	Decannulation
18	8	Motor vehicle accident, prolonged intubation	4½ yr	LTP with costal cartilage graft twice, Rethi procedure once, stent	Dilations, hyoid interposition	Decannulation
Laryngotracheal (subglottic/tracheal)						
19	2	Prolonged intubation	1 yr	LTP, costal cartilage graft, stent	Dilations	Decannulation
20	18	Prolonged intubation	4 mo	LTP, costal cartilage graft, stent	—	Decannulation
21	10	Prolonged intubation	10 mo	LTP, costal cartilage graft, stent	Hyoid interposition	Decannulation
22	9	Prolonged intubation	7 yr	LTP, costal cartilage graft, stent	Dilations	Decannulation
23	22	Prolonged intubation	10 mo	LTP, costal cartilage graft, stent	Laser	Decannulation
24	2	Prolonged intubation	1½ yr	LTP, costal cartilage graft	Dilations	Decannulation
25	2	Prolonged intubation	1½ yr	Endoscopy, removal of granulations	—	Decannulation
26	2	Prolonged intubation	1½ yr	Endoscopy	—	Decannulation
27	1½	Prolonged intubation	1 yr	LTP, costal cartilage graft	—	Decannulation
28	8 mo	Prolonged intubation	4 mo	Endoscopy	—	Tracheotomy, treatment in progress
29	1½	Prolonged intubation	1½ yr	LTP, costal cartilage graft	—	Decannulation
Tracheal						
30	1	Congenital stenosis of trachea	4 mo	Endoscopy	—	Tracheotomy, treatment in progress
31	2	Prolonged intubation, first tracheal ring subluxated beneath cricoid cartilage	2 yr	LTP, costal cartilage graft	—	Tracheotomy, treatment in progress

LTP — laryngotracheoplasty, NT — no tracheotomy.

TABLE 3. SUMMARY OF CAUSES OF SUBGLOTTIC STENOSIS

Cause	*No. Cases*	*%*
Prolonged intubation*	28	90
Congenital stenosis	1	3
Postirradiation scar	1	3
Neck trauma	1	3

Percentages are rounded.
*Two patients also had small larynges.

often seen where erosion of the mucosa has occurred or at the site of the tracheotomy. Such granuloma can be removed easily by cup forceps or by laser. Flattening of the anterior tracheal wall frequently is observed cephalad to the tracheostomy and is felt to be the result of pressure of the curved tracheotomy tube in this region. Such flattening may be corrected by excision of the tracheostomy scar with anterior fixation of the tracheal wall to anterior soft tissues. In contrast, tracheal narrowing secondary to loss of supporting tracheal cartilage seldom responds to conservative therapy. In these situations, more aggressive surgical reconstruction using costal cartilage support is required.

CLINICAL FINDINGS

In the present series of 31 patients, there were 26 males and five females. Their ages ranged from 5 months to 22 years; about half of the patients were under 4 years of age. Their age distribution is shown in the Figure. Most of the patients were 18 to 24 months or 8 to 10 years of age. This bimodal spread deserves comment: in the five 18-month-olds, the average duration of tracheotomy was 13.8 months; in the five 2-year-olds, 18 months. In the older age group, the nine 9- to 10-year-old patients showed a 5-year average duration of tracheotomy. This finding suggests that the conditions that produced the need for tracheotomy occurred most likely after infancy.

The evaluation protocol is shown in Table 1. The initial history and physical examination were supplemented by fiberoptic laryngoscopy in most cases, and by mirror examination in older patients. In many instances, however, tracheotomy was performed for acute respiratory distress or for failure of extubation that was attempted to enable complete evaluation of the airway.

The level and extent of stenosis were determined by direct laryngoscopy and confirmed by lateral x-ray study of the neck or by xerography. During the examination, the type of stenosis and the mobility of the vocal cords were ascertained. Examination of the trachea and bronchi were performed when possible. Patients with symptoms suggesting reflux or obstruction of the esophagus underwent an esophageal swallow study and/or esophagoscopy. Patients with voice problems were evaluated by a speech pathologist. Those with pulmonary disease underwent respiratory function tests.

TABLE 4. LOCATION OF STENOSIS

Location	*No. Cases*	*%*
No tracheotomy		
Glottic/subglottic/tracheal	2	6
With tracheotomy		
Glottic/subglottic	14	45
Glottic/subglottic/tracheal	2	6
Subglottic/tracheal	11	35
Tracheal	2	6

The causes of subglottic stenosis in patients in this study are shown in Table 2. Table 3 summarizes these findings. Twenty-eight cases (91%) were related to prolonged intubation. The parameters of this diagnosis will not be presented at this time. Of the other three patients, one presented with congenital tracheal stenosis, one developed glottic scarring after irradiation of a mediastinal lymphoma, and one sustained a gunshot wound to the neck, larynx, and cervical spine.

The location of stenosis is shown in Table 4. In two cases, tracheotomy was not required. These patients, 9 and 11 years of age, presented with subglottic stenosis and marked stridor. All of the remaining 29 patients required tracheotomy. Of these, 13 (42%) were found to have glottic/subglottic stenosis. The next most common site was subglottic/tracheal stenosis, which occurred in 11 of the patients (35%). Three patients (10%) showed extensive scarring involving the glottis, subglottis, and trachea. Two patients (6%) showed stenosis of the trachea only.

Prior treatment was given to 17 of the patients studied (55%). The six treatment modalities employed thereafter are shown in Table 5. These included: 1) no treatment (except tracheotomy) to date; 2) endoscopic observation; 3) endoscopic dilations; 4) endoscopy with forceps excision of granulomas; 5) endoscopy with CO_2 laser excision of the stenosis; and 6) laryngotracheoplasty with costal cartilage graft to the cricoid ring, with extension of the graft to the anterior upper tracheal rings and thyroid cartilage if needed.

TABLE 5. OUTCOME BY TREATMENT MODALITY

		Current Status	
Treatment	*No. Patients*	*Tracheotomy*	*Decannulation*
No treatment to date	1	1	0
Endoscopic observation	5	2	3
Endoscopic dilation	2	2	0
Endoscopic excision of granulation	2	1	1
Endoscopic CO_2 laser excision	2 no tracheotomy 3 with tracheotomy	1	2
Laryngotracheoplasty	16	2	14*

*Two laryngotracheoplasties were performed in two cases.

TABLE 6. SUMMARY OF OUTCOME

Outcome of Treatment	*No. Cases*	*%*
No tracheotomy/asymptomatic (laser for severe stridor)	2/31	6
Tracheotomy during treatment	29/31	94
Decannulated	19/29	66
Tracheotomy with treatment in progress	9/29	31
Tracheotomy preferred by patient	1/29	3

TABLE 7. DURATION OF TRACHEOTOMY

Mode of Treatment	*Duration (mo)*
Endoscopy +/− laser	33.5
LTP (overall)	35.5
LTP (from date of surgery to decannulation)	3.8

The outcomes of treatment are also shown in Table 5. There were no deaths. One patient, 1 month of age, was tracheotomized and is currently under observation. Five patients received tracheotomies and have been followed by endoscopic observation. Three of these have been decannulated. The others, $2^1/_2$ and $3^1/_2$ years of age, still retain their tracheotomies. Two patients, 5 and 18 months of age, received cricoid split procedures, and have been treated with dilations, but are not ready for decannulation. Two patients, 2 and 5 years of age, were treated by endoscopic excision of their subglottic granulation tissue with forceps; one has been decannulated, and the other continues to have a tracheotomy because of problems with follow-up care.

Five patients were treated with CO_2 laser excision of their stenosis. Two of these did not need tracheotomy. Both exhibited marked stridor secondary to subglottic stenosis, but were asymptomatic after laser therapy. Of the three other laser-treated patients, one still has a tracheotomy and two have been decannulated.

Sixteen patients were treated by laryngotracheoplasty (LTP) with a costal cartilage graft to expand the anterior cricoid ring, plus the anterior upper tracheal rings and thyroid cartilage, if needed. In 12 of these patients, a Teflon stent of the Aboulker type was used. Stents were removed 3 months after surgery. All patients received broad-spectrum antibiotics until the 2-week follow-up examination after stent removal. Two patients required a second LTP to secure an adequate airway. In these patients, a simplified Rethi procedure was used to open the posterior midline of the cricoid cartilage in the sagittal plane. The cartilage was expanded until the sagittal muscle fibers of the esophagus could be clearly seen. At this point the temporary stent was inserted. Both of these patients were decannulated. Fourteen of the 16 patients treated with LTP (88%) were decannulated.

CONCLUSION

The summary of outcomes is shown in Table 6. Twenty-nine of the patients (94%) with subglottic stenosis required a tracheotomy during their course of treatment. Of these 29 patients, 19 (66%) were decannulated. Nine patients (31%) continued to have their tracheotomies while under further treatment. One patient (3%) preferred to keep his tracheotomy.

The duration of tracheotomy for each major treatment modality is shown in Table 7. Of the 12 tracheotomized patients who were treated by endoscopic methods alone, six (50%) have been decannulated. Of the 16 patients treated by LTP, 14 (88%) have been decannulated. The average duration for tracheotomy in the endoscopically treated patients was 33.5 months, and the average duration for tracheotomy for the LTP-treated patients was 35.5 months. The average time to decannulation from the date of LTP in the latter group was 3.8 months.

On the basis of these observations, we conclude that tracheotomy and endoscopic management of patients with milder degrees of stenosis can result in successful decannulation. When the stenosis is severe or complicated, LTP with cartilage graft can significantly shorten the duration of the tracheotomy. Selection of treatment must be individualized, depending upon the clinical problem and the resources for treatment.

REFERENCES

1. Parkin JL, Stevens MH, Jung AL. Acquired and congenital subglottic stenosis in the infant. Ann Otol Rhinol Laryngol 1976;85:573-81.

2. Rossi F. De nonullis monstruositatibus in internis humani corporis partibus. Observationes. Mem R Accad Torino 1826;30: 155.

3. Mackenzie M. Diseases of the pharynx, larynx, and trachea. New York: William Wood & Co, 1880.

4. Schroetter. Monatsschrift für Ohrenheilkunde, etc. No. 12, 1878.

5. Jackson C. Peroral endoscopy and laryngeal surgery. St Louis: Laryngoscope Co Pubs, 1915:623-7.

6. Jackson C, Jackson CL. The larynx and its diseases. Philadelphia: WB Saunders, 1937.

7. Rethi A. An operation for cicatricial stenosis of the larynx. J Laryngol Otol 1956;70:283-93.

8. Koenig F. Berl Klin Wohnschr No. 51, 1896.

9. Von Mangoldt. Die Einpflanzung von Rippenknorpel in den Kehlkopf zur Heilung schwerer Stenosen und Defecte, und Heilung der Sattelnase durch Knorpelübertragung. Archiv für Klin Chiurgie 1900;61:955-69.

10. Kindig GO. Ein Beitrag zur Mangoltschen und Königschen Tracheoplastik und über eine Modifikation der letzeren nach v. Hacker. Archiv für Klin Chiurgie 1924;131:343-52.

11. Fairchild FR. Reconstruction of the trachea. Surg Gynecol Obstet 1927;44:119-122.

12. Velpeau. Nouveaux eléments de médicine opératoire. Paris, 1832.

13. Catlin FI, Spankus EM. Management of subglottic stenosis in children. Otolaryngol Head Neck Surg 1985;93:585-91.

14. Grahne B. Operative treatment of severe chronic traumatic laryngeal stenosis in infants up to three years old. Acta Otolaryngol (Stockh) 1971;72:134-7.

PHONATORY EFFECTS OF THYROID CARTILAGE FRACTURES

ROBERT B. STANLEY, JR, MD, DDS
DONALD S. COOPER, PHD
STEVEN H. FLORMAN, MD
LOS ANGELES, CALIFORNIA

Blunt trauma can cause a wide range of injuries to the cartilaginous framework of the larynx. The severity of injury that is required to cause a permanent disorder of vocal function if left untreated has not been defined. A study using excised canine and human larynges was undertaken to identify the effects of minimal displacement or malalignment in simulated thyroid cartilage fractures on selected voice production measurements. These fractures were found to cause changes in glottal configuration sufficient to affect glottal resistance as well as amplitude and noise content of the voice signal produced by each larynx. Therefore, relatively minor injuries of the thyroid cartilage may cause potentially serious disorders of phonation.

KEY WORDS — phonation, thyroid cartilage fractures.

Blunt trauma to the larynx may cause a wide spectrum of damage to the endolaryngeal soft tissues as well as the underlying cartilaginous skeleton. Management of the injuries is based on the restoration of a properly shaped skeletal framework and an intact epithelial lining so that airway and voice quality are maintained. The extent of surgical manipulation required is dependent on the degree of displacement of the cartilaginous fractures and the severity of the mucosal disruption.[1]

Displaced thyroid cartilage fractures with no overlying mucosal disruption now can be detected by computed tomography.[2] These less severe injuries, even if left untreated, usually do not cause immediate or delayed airway problems.[3] However, the effect of such untreated fractures on vocal function was only theorized until Hirano et al[4] described a displaced midline fracture of the thyroid cartilage in a patient who presented with a limitation in pitch range. They emphasized that vocal function is a multidimensional function, and that disorders of phonation other than the usual chief complaint of hoarseness may occur following blunt laryngeal trauma. The lower limit of displacement or malalignment of a thyroid cartilage fracture that is sufficient to cause such a disorder of phonation has not been defined. Therefore, a study was undertaken to investigate the effects on phonation of a representative series of simulated thyroid cartilage fractures causing minimal displacement or malalignment in excised larynges.

MATERIALS AND METHODS

Unfortunately, the number of available human larynges is limited by the widespread use of endotracheal intubation, which creates permanent postmortem distortion of the vocal folds. However, the resemblance of the canine larynx to those of primates both in shape and physiologic properties makes it an appropriate model for general conclusions regarding the aerodynamics and acoustics of phonation.[5,6] Therefore, the effects of simulated thyroid cartilage fractures were studied in three canine and two human excised larynges.

Each normal larynx was mounted in a specially designed excised larynx apparatus, which has been described fully elsewhere.[7] The larynx was excited by a stream of air warmed to about 37°C and at 100% relative humidity. Before reaching the larynx, the airstream passed through a subglottal resonator designed to act as a pseudolung. Glottal configuration was adjusted by use of calibrated weights connected by sutures to the thyroid cartilage to simulate activity of the cricothyroid muscle and to the muscular processes of the arytenoid cartilages to simulate adductive muscular contraction. Airflow and glottal configuration were adjusted to produce satisfactory phonation for that particular larynx. Average airflow (milliliters per second) was measured with a calibrated spherical float flowmeter, and average subglottal pressure (centimeters H_2O) was measured with a U tube manometer. Realistic levels of airflow (about 110 to 140 mL/s) and subglottal pressure (about 7 to 20 cm H_2O) were maintained for each test situation, based on Hirano's[8] tables of normative values.

Continuous recordings of the acoustic signal were made from a Brüel & Kjaer condenser microphone type 4165 (flat ±1 dB from 20 Hz to 20 kHz), and sound pressure level (SPL) was measured with a microphone amplifier (Brüel & Kjaer model 2003). The recordings were made inside a double-walled sound booth with a background noise level of 24 dB. This noise level required almost no correction of measured sound pressures to remove the contribution of the background. The acoustic signal was fed

From the Department of Otolaryngology–Head and Neck Surgery, University of Southern California School of Medicine, Los Angeles.

Presented at the meeting of the American Laryngological Association, Denver, April 25-26, 1987.

REPRINTS — Robert B. Stanley, Jr, MD, DDS, Los Angeles County–University of Southern California Medical Center, 1200 N State St, Box 795, Los Angeles, CA 90033.

AERODYNAMIC MEASUREMENTS FOR EACH SIMULATED FRACTURE CONDITION*

Larynx	*Fracture Status*	*Condition*	*Subglottal Pressure (cm H2O)*	*Airflow (mL/s)*	*Glottal Resistance (Acoustic Ω)*	*SPL (dB)*
Canine	ML, 1-mm separation	Prefracture	19	136	137	75
		Postfracture	9	142	60	56
Human	ML, 1-mm separation	Prefracture	9	142	65	74
		Postfracture	7	133	51	67
	ML, overlapped	Prefracture	9	142	65	74
		Post/ant	8	118	71	63
		Ant/post	12	137	84	75
Canine	5 mm from ML, overlapped	Prefracture	11	125	91	77
		Post/ant	12	125	98	72
		Ant/post	14	117	120	79
Human	10 mm from ML, overlapped	Prefracture	6	133	47	64
		Post/ant	6	125	48	62
		Ant/post	10	142	71	68
Canine	11 mm from ML, overlapped	Prefracture	8	125	64	72
		Post/ant	6	117	51	67
		Ant/post	9	117	77	70
	Angulated, end-to-end contact maintained	Prefracture	8	125	64	72
		Postfracture	5	125	43	70

ML — midline, Post/ant — posterior segment positioned lateral to anterior segment, Ant/post — reverse positioning.
*Measurements are rounded to nearest unit.

to a waveform-processing digital oscilloscope and recorded on a diskette. Spectral analysis of the sound produced by the larynx permitted observation of the proportion of noise content of the voice signal.

In each experimental condition, one vertical fracture was simulated in the larynx by cutting the thyroid cartilage while the larynx remained suspended in the apparatus. Great care was taken to avoid damage to the endolaryngeal soft tissues, so that all effects on phonation would result from the thyroid cartilage fracture only. Eleven abnormal conditions were investigated using two midline fractures and three fractures of the lateral lamina (see Table). The lateral fractures were approximately 5, 10, and 11 mm from the midline. The last fracture was intended to be more posterior on the lamina, but the position of the larynx in the suspension apparatus prevented this. The species of larynx used for each test was determined only by which larynx was available on the day selected to test a new fracture location.

The abnormal situations were created from the five fractures either by separating the cut edges with a 1-mm thick aluminum strip cemented into the fracture line with cyanoacrylate glue, or by overlapping the anterior and posterior segments by approximately 2 mm and holding them in place with nylon sutures and glue. Airflow was kept as stable as possible, and no adjustments in glottal configuration other than that caused by the fracture itself were performed. All measurements were repeated. Stroboscopic evaluation was accomplished in all but the first larynx tested, the midline fracture in the canine larynx.

RESULTS

It should be noted that final determination of airflow for each larynx was based on the production of satisfactory phonation in that particular larynx. Small variations in pretrauma and posttrauma airflow occurred for each larynx, introducing some extraneous variability into subglottal pressure levels and SPLs. However, the quantity that is compared most appropriately between different larynges and for different conditions in each larynx is average glottal resistance. This is computed from the ratio of the average subglottal pressure to the average airflow and specified in terms of acoustic ohms (1 acoustic $\Omega = 1$ [dyne/cm^2]/[mL/s]). Glottal resistance is an indicator of the efficiency of the larynx in valving air during phonation.[9] More importantly for our study, glottal resistance is determined by glottal configuration, and thus should be affected directly by alterations in the shape of the thyroid cartilage.

The aerodynamic measurements are listed in the Table. It can be seen that a 1-mm separation of the vertical fracture exactly in the midline of a canine larynx produced a 53% decrease in glottal resistance. Similarly, a 1-mm separation of a fracture in a human larynx approximately 1 mm to the right of the midline produced a 21% decrease in glottal resistance. This fracture also was tested with the segments in the overlapped positions. When the anterior segment was overlapped lateral to the posterior segment, a 40% increase in glottal resistance was noted. However, when the overlap was reversed, glottal resistance increased by only 9% relative to the resistance prior to fracture. Similarly, testing of the fractures located more laterally on the thyroid lamina produced increases in glottal resistance of 20% to 50% with the anterior segment lateral to the posterior segment. With the overlaps reversed, glottal resistance increased only slightly for the fractures 5 and 10 mm from the midline, and actually decreased for the fracture 11 mm from the midline. In a final test, the fracture 11 mm from the

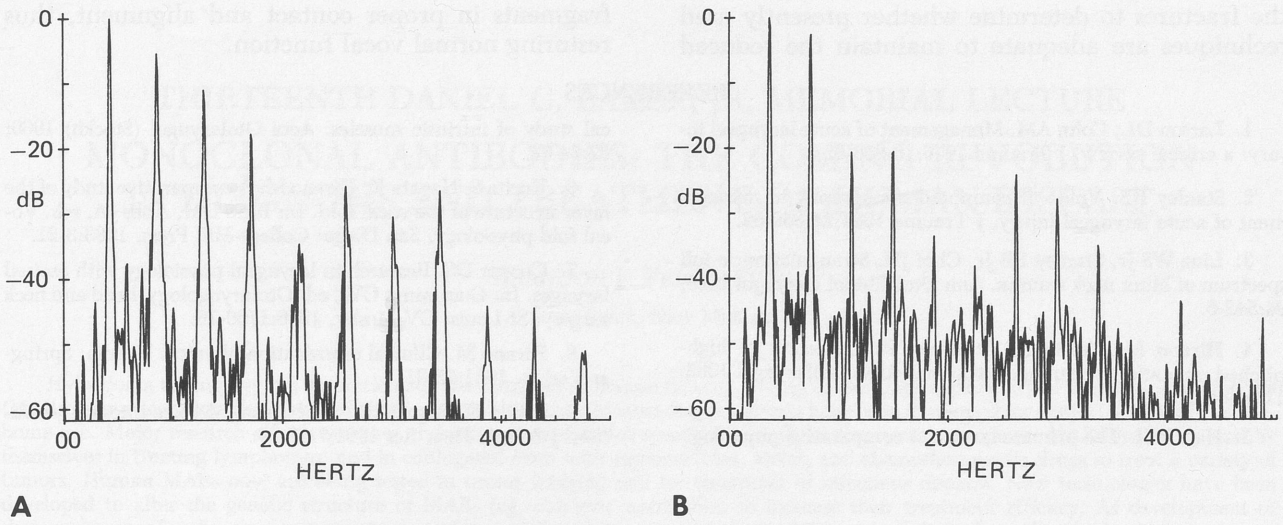

Relative log power spectra of sound from canine larynx with fracture 11 mm from midline. Posterior segment was angulated laterally, but end-to-end contact with anterior segment was maintained. A) Prefracture, B) postfracture. Postfracture spectrum contains more noise.

midline was tested with the posterior segment angled laterally by approximately 30°, but still in end-to-end contact with the anterior segment. A 29% decrease in glottal resistance was found.

Prefracture and postfracture SPLs also are listed in the Table. Noteworthy are the 7- and 19-dB falls in SPL following 1-mm separation of the fractures at or near the midline. Decreases in SPL of 2 to 11 dB were recorded for the overlapped fractures with the posterior segments lateral to the anterior segments. Changes in SPL varied from a 2-dB fall to a 4-dB elevation with the overlap reversed and with the segments placed end-to-end but angulated. However, the changes recorded for the overlapped fractures must be viewed with caution. Each larynx was noted to "sputter" because of irregular vibrations of the vocal cords following creation of the fractures. The minor adjustments in airflow required to achieve satisfactory phonation in these situations make it impossible to attribute the SPL changes entirely to the fractures. The log power spectra of the sound produced by each larynx before and after the fracture demonstrated the increased noise content of the voice signal after injury. A representative spectrum is shown in the Figure.

The mechanical effects of the fractures on vocal cord position during phonation were seen clearly when the larynges were viewed stroboscopically. Separation of the fracture near the anterior commissure produced lateralization of the anterior end of the vocal cord on the involved side, thus keeping the glottis open during phonation. In the overlapped fractures, placing the anterior segment lateral to the posterior segment caused the vocal cord on the side of the trauma to be squeezed medially against the opposing cord. When overlap was reversed in the fracture adjacent to the midline and in the one 5 mm from the midline, the anterior commissure was compressed slightly and the vocal cord was tensed along its entire length. For the fractures 10 mm and 11 mm from the midline, also, the vocal cord was tensed, but it was pulled laterally posterior to the fracture site so as to separate the vocal folds.

DISCUSSION

In the excised larynges, minimally displaced midline and lateral fractures of the thyroid cartilage caused alterations in glottal configuration sufficient to disrupt the normal laryngeal valving mechanisms. Fractures at or near the midline, when separated by only 1 mm, caused a decrease in glottal resistance. Overlapped fractures near the midline or more laterally located on the thyroid lamina caused either an increase or a decrease in glottal resistance, depending on the orientation of the cartilaginous segments. Angulation of a fracture of the lateral lamina produced a decrease in glottal resistance even though the cartilage fragments were in end-to-end contact. Additionally, the amplitude and noise content of the sound produced by each larynx were affected by the simulated injuries. Therefore, relatively minor thyroid cartilage fractures were shown in this experimental model to have the potential to disrupt several aspects of vocal function.

The total effect of less severe injuries of the laryngeal skeleton on phonation remains a complex issue that only partially has been addressed by our study. Although our data in excised larynges showed consistent trends, they did not give definite answers that can be applied yet to treatment planning in clinical situations. A detailed statistical analysis of the exact effects of a particular type of laryngeal fracture and the least amount of displacement or malalignment sufficient to cause a phonatory disturbance will require study of that fracture in multiple larynges. Further studies necessarily will include evaluation of phonation following repair of

the fractures to determine whether presently used techniques are adequate to maintain the reduced fragments in proper contact and alignment, thus restoring normal vocal function.

REFERENCES

1. Larson DL, Cohn AM. Management of acute laryngeal injury: a critical review. J Trauma 1976;16:858-62.

2. Stanley RB. Value of computed tomography in management of acute laryngeal injury. J Trauma 1984;24:359-62.

3. Line WS Jr, Stanley RB Jr, Choi JH. Strangulation: a full spectrum of blunt neck trauma. Ann Otol Rhinol Laryngol 1985; 94:542-6.

4. Hirano M, Kurita S, Terasawa R. Difficulty in high-pitched phonation by laryngeal trauma. Arch Otolaryngol 1985; 111:59-61.

5. Hast MH. The primate larynx. A comparative physiological study of intrinsic muscles. Acta Otolaryngol (Stockh) 1969; 67:84-92.

6. Kurita S, Nagata K, Hirano M. A comparative study of the layer structure of the vocal fold. In: Bless DM, Abbs JA, eds. Vocal fold physiology. San Diego: College-Hill Press, 1983:3-21.

7. Cooper DS. Research in laryngeal physiology with excised larynges. In: Cummings CW, ed. Otolaryngology–head and neck surgery. St Louis: CV Mosby, 1986:1766-76.

8. Hirano M. Clinical examination of voice. Vienna: Springer-Verlag, 1981:25-81.

9. Isshiki N. Regulatory mechanism of voice intensity variation. J Speech Hear Res 1964;7:17-29.

THIRTEENTH DANIEL C. BAKER, JR, MEMORIAL LECTURE

MONOCLONAL ANTIBODIES: THE COMING REVOLUTION IN DIAGNOSIS AND TREATMENT OF HUMAN DISEASE

BRANDON J. PRICE, PHD

ALBUQUERQUE, NEW MEXICO

Hybridoma technology has revolutionized the diagnosis of human disease. Owing to the unique specificity of monoclonal antibodies (MABs) of murine origin, hundreds of highly sensitive, accurate in vitro diagnostic tests have been developed for clinical laboratory and at-home use. Major research efforts are now underway to exploit this specificity for direct therapeutic purposes: MABs are being used by themselves in treating lymphomas, and in conjugated form with radionuclides, toxins, and chemotherapeutic drugs to treat a variety of tumors. Human MABs now are being tested in tumor imaging and for treatment of infectious diseases. New technologies have been developed to alter the genetic structure of MABs (eg, chimeric antibodies) to increase their treatment efficacy. As development of therapeutic uses for these reagents continues and, especially, as they receive approval for general clinical use, hundreds of kilograms per year will have to be produced. This paper reviews some of the recent developments in this area and describes two novel technologies that have been developed for large-scale cultivation of hybridoma cells.

KEY WORDS — hybridoma, mammalian cell culture, monoclonal antibody.

INTRODUCTION

Human health care is beginning to see the first benefits from the techniques and reagents being developed in biotechnology laboratories around the world. Little more than a decade has passed since Köhler and Milstein[1] of the British Medical Research Council Laboratory at Cambridge University published their first paper describing monoclonal antibody (MAB) secretion from fused cells. In this relatively short time, MABs have had an astonishing impact on almost every facet of biology, and several important industries have arisen from their discovery. Commercial applications are being developed in such diverse areas as agriculture,[2] veterinary medicine,[3] immunopurification of biologicals,[4] diagnostic assays,[5] and human therapy.[6]

It is in the diagnosis and treatment of human disease that MABs are likely to make their most significant impact. Already, hundreds of in vitro diagnostic tests have been developed and are being marketed, ranging from detection of HIV-1 antibodies for acquired immune deficiency syndrome to at-home pregnancy determination. In vivo medical imaging will benefit from the unique specificity of MABs. Perhaps the most far-reaching impact will come from use of MABs as carrier molecules to deliver radionuclides, toxins, or chemotherapeutic agents selectively to tumor sites and, as well, to treat infectious disease. Furthermore, it is likely that the antibody molecule itself will be altered genetically to render it more amenable to certain therapeutic and prophylactic applications.

Ultimately, though, as medical applications are developed and begin to gain acceptance, the challenge will be to produce enough purified MAB to meet the projected demand for hundreds of kilograms per year in the 1990s. This paper reviews some of the progress being made in the diagnostic and therapeutic applications of MABs and reports on two innovative techniques that have been developed recently for the large-scale culture of hybridoma cells.

ANTIBODIES: PAST AND PRESENT KNOWLEDGE

Antibodies are the key molecular factors in a remarkably versatile set of adaptive processes, found only in vertebrates, by which animals form specifically reactive proteins (and cells) in response to invasion by foreign substances. Taken collectively, these processes are termed immune responses, and they are the primary means of defense against infection by pathogenic microorganisms and viruses. The notion that persons who recovered from certain diseases could not contract them again has been around for several thousand years. Over 2,500 years ago, the Greeks noted that persons dying of various contagious fevers or plagues could be tended, without ill effect, by others who had contracted the disease previously and survived. The first repeatably successful attempts at inoculating well individuals to protect them from subsequent infection were reported by Jenner in his development of the smallpox vaccination technique. It was not until the late 19th century, however, that the basis for these immune responses was discovered. Numerous investigators found that so-called induced immunity could be transferred from one individual to another by infusions of blood or serum. It was suspected that a factor (or factors) within the serum component of

Presented at the meeting of the American Laryngological Association, Denver, April 25-26, 1987.

REPRINTS — Brandon J. Price, PhD, 341 Big Horn Ridge Rd NE, Albuquerque, NM 87122.

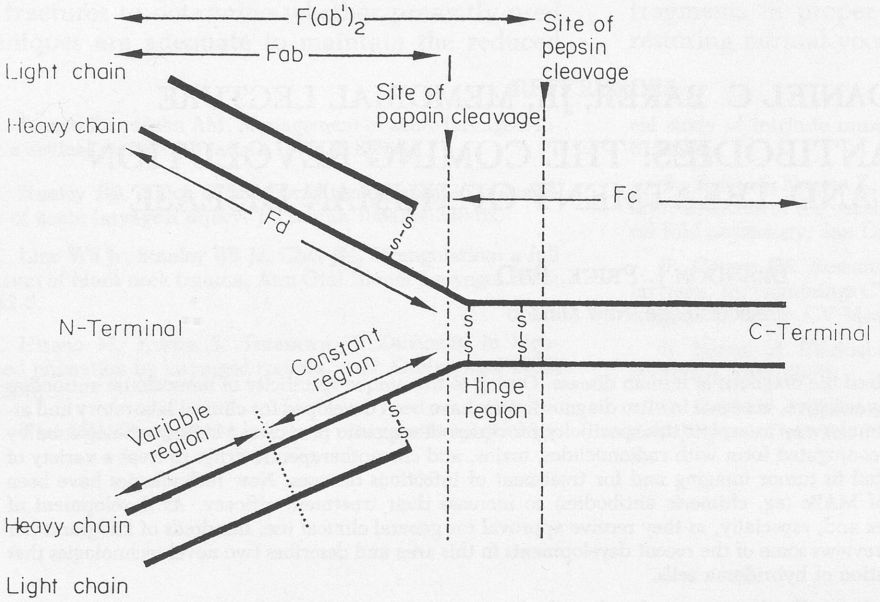

Fig 1. Schematic diagram of immunoglobulin molecule. Heavy chains and light chains are connected by disulfide bridges as indicated. Antibody binding regions (Fab) and constant region (Fc) are shown. F(ab')2 is fragment consisting of both antibody binding sites, obtained by treating antibody molecule with pepsin. Fd is that part of heavy chain within Fab fragment. (Entire light chain is within Fab fragment.)

blood was responsible for conferring immunity. By the beginning of this century, most of the currently known serologic reactions were elucidated, and all were shown to be specific. It was also demonstrated that immune responses could be elicited by introducing nontoxic substances (eg, milk proteins) into the body. The organic molecules responsible for eliciting an immune response were termed antigens, and the antigen-specific neutralizing factors arising in the serum of injected animals were termed antibodies.

It is now well understood that antibodies are, in fact, proteins belonging to a specific class of serum proteins called immunoglobulins (Igs). Antibodies are produced by B-lymphocytes in response to an antigen trigger. An antibody molecule is a glycoprotein made up of high molecular weight polypeptides (heavy chains) and low molecular weight polypeptides (light chains) interconnected in a specific arrangement by sets of disulfide bonds, as schematically depicted in Fig 1. The two antigen-binding portions of the molecule contain the regions of greatest amino acid variation and are referred to as the Fab regions (for *F*ragment: *a*ntibody *b*inding). The "tail end" of the molecule contains relatively constant amino acid sequences and is called the Fc region (for *F*ragment: *c*onstant). Each B-lymphocyte produces antibody molecules of essentially one specificity; that specificity is conferred by the amino acid sequence in each of the two antibody-combining sites formed by the pairing of one light and one heavy chain. The tertiary structure of these molecules has been well established by x-ray crystallographic studies. There are a variety of classes and subclasses of Ig molecules, all with a structure similar to that shown in Fig 1, but differing on the basis of their antigenic properties, amino acid sequences, size of the heavy chain components, and nature of the interchain connections via disulfide bonds. By far the most prevalent class of immunoglobulins in humans is the gamma immunoglobulin (IgG). With an approximate molecular weight of 150,000 daltons, IgGs constitute over 80% of the serum Igs. For an excellent and thorough overview of antibody structure and function, see the book by Eisen.[7]

MONOCLONAL ANTIBODIES

Although individual antibody molecules are highly specific, the reaction of a host to invasion by a foreign substance is relatively nonspecific. If the antigenic agent is sufficiently large (eg, a bacterium or virus), B-lymphocytes will be stimulated to produce antibodies that identify and bind to thousands of different antigens present on the surfaces of the intruding organism. While this polyclonal response can be produced readily by injecting an animal with the antigenic agent and harvesting the product of its immune system, the biochemical complexity of the polyclonal sera makes it virtually impossible to isolate a single antibody that reacts with a specific antigen. Unfortunately, B-lymphocytes cannot be maintained indefinitely in tissue culture. In an ingenious approach developed by Köhler and Milstein,[1] surfactants such as polyethylene glycol can be used to fuse B-lymphocytes with a more stable cultured cell line. In some of the fusion products, the nuclei of each cell type fuse with each other, creating hybrids that can be maintained indefinitely in tissue culture while retaining the ability to produce antibody. The usual procedure is to fuse B-lymphocytes from an immunized animal with a cultured myeloma cell line. Typically, mouse cells are used for this purpose, as mice can be immunized easily (and thus are an excellent source of B-lymphocytes), and several murine myeloma cell lines are readily available. Of the thousands of different hybridomas formed from such a fusion, only a few

are likely to be producing antibodies against the antigen of interest. It is a straightforward (though tedious) process to isolate and clone those few hybridomas. The result is a homogenous cell line in which each hybridoma cell is a duplicate of its sister in culture, and all are producing identical copies of the same Ig. The antibodies so produced are called monoclonal antibodies (MABs). It was only with the advent of Köhler and Milstein's fusion technique in 1975[1] that the enormous diagnostic and therapeutic potential of these highly specific molecules could be assessed and exploited.

DIAGNOSTIC APPLICATIONS

The in vitro detection of agents in blood and other tissue fluids represents the first practical application of MABs in human health care. Among the first laboratory diagnostic applications in the early 1980s was the quantitative measurement of helper (T4) and suppressor (T8) T-lymphocyte ratios in blood for the assessment of immunocompromised individuals.[8] More recently, several companies have begun marketing in vitro diagnostic test kits for pregnancy determination (Monoclonal Antibodies, Mountain View, Calif) and detection of AIDS (Biotech Research Labs, Rockville, Md; Centocor, Malvern, Pa; Genentech, South San Francisco, Calif), cytomegalovirus (Cetus Corp, Emeryville, Calif), and hepatitis B (Centocor; Biogen Corp, Cambridge, Mass; Chiron, Inc, Emeryville, Calif; Integrated Genetics, Framingham, Mass).

Of even greater potential significance is the area of in vivo medical imaging. Monoclonal antibodies can be linked covalently with radionuclides or contrast agents for in vivo use with a nuclear camera or magnetic resonance imaging scanner to precisely localize damaged tissue or cancerous lesions.[9-11] Already available in the European marketplace is an anti-myosin MAB (Centocor) that binds with intracellular cardiac myosin only when that protein is exposed in irreversibly damaged heart cells. Most methods of evaluating necrosis in myocardial infarction are based on functional properties of cardiac tissue and, as such, are not particularly useful for differentiating between irreversible necrosis and severe ischemia. The imaging kit, employing antibody coupled to radioactive technetium 99, already is becoming a useful tool for evaluating the extent of necrosis in the early hours following myocardial infarction.

Although they are not yet on the market, a number of companies (Centocor; Oncogene Science, Inc, Mineola, NY; Xoma Corp, Berkeley, Calif; Cytogen Corp, Princeton, NJ; Hybritech, Inc, San Diego, Calif) are developing in vivo tumor imaging MABs for detection of lymphomas, gastrointestinal cancers, colorectal cancer, renal cell carcinoma, ovarian carcinomas, breast tumors, and lung cancers. An interesting and potentially very useful application of MABs is in assessment of host cell accumulations within tumors. While the functional significance of cellular infiltrates within a primary neoplasm remains obscure, several investigators have noticed a positive correlation between infiltrate intensity and clinical stage.[12] Recently, a panel of MABs against various human lymphocyte subsets and macrophages was used to study discrete subset infiltration within frozen sections from surgical specimens of laryngeal carcinoma.[13] It was found that host cell infiltrates at the tumor periphery were composed of T4 lymphocytes and macrophages, while T8 and natural killer cells appeared to be intermingled with tumor cells further into the tumor. Studies such as these have potential application beyond the tumor studied; for example, the cause of laryngeal cancer is like that of squamous cell bronchial cancer, for which the patient prognosis is decidedly worse. Given the widespread basic and clinical research underway in the United States, Europe, and Japan, it is certain that MABs will be extremely helpful for the detection, monitoring, and staging phases of cancer management programs.

THERAPEUTIC APPLICATIONS

It is likely that the greatest impact of monoclonal antibodies in human health care will be the direct treatment of human infection and other disease. This impact is still farthest away from the marketplace, as strict Food and Drug Administration (FDA) regulations and guidelines must be followed in obtaining clinical trial data showing safety and efficacy. Nonetheless, hundreds of clinical trials are underway in Europe and the United States. Monoclonal antibodies have been developed against bacterial antigens such as tetanus toxoid,[14,15] gram-negative endotoxins,[16] diphtheria toxoid,[17] and *Pneumococcus*[18]; against viral antigens such as cytomegalovirus,[19] measles,[20] and *Varicella zoster*[21]; against malarial parasite antigens[22]; and against antigens involved in autoimmune diseases such as systemic lupus erythematosus[23] and rheumatoid arthritis.[24] Many of the MABs referred to above are already in human clinical trials. In the area of antisepsis treatment, for example, several companies (Centocor; Cetus Corp; Xoma Corp; Hyland Therapeutics Division, Travenol Laboratories, Inc, Duarte, Calif) are engaged in a fierce competitive race to reach the market first. This is due to the potentially large and lucrative market for treatment of postoperative infection in hospitals.

At present, the major clinical research efforts are being put into anti-tumor antibody research and development. The basic notion is quite simple. Surfaces of tumor cells contain a large number and variety of proteins, some of which are specific to the tumor type. Monoclonal antibodies that bind to such tumor-specific antigens then could be used to identify those tumor cells. A number of antibodies

recognizing tumor antigens have been reported.[25] For example, the antibody designated SQM1, directed against the surface membrane of squamous carcinoma cells, has been shown to bind positively to frozen tissue sections of biopsies from head and neck squamous cancer lesions, but to be unreactive with cells of the normal mucosa and stroma.[26] If the tumor antigen were completely specific to all cells in the tumor, then the antibody could be used as a precisely selective targeting vehicle to bring a cell-killing compound directly to the tumor cells. In principle, the problems associated with using nonspecific cytotoxic agents such as chemotherapeutics would be completely eliminated, along with the painful side effects common to cancer therapy. There are a number of approaches being taken in this field. The simplest strategy is to find antibodies that, by themselves, specifically bind to and kill tumor cells. While attractive, this approach may be extremely difficult, as most researchers believe that tumors are composed of heterogeneous cell populations. Also, many solid tumors probably contain semipermeable membranes around portions of the tumor mass, membranes that will not allow the antibody access to the core of the tumor. Nonetheless, some treatments have been promising. In a clinical trial at Stanford University,[27] anti-idiotype antibodies specific for individual patients' B cell lymphomas have been developed, and several dozen patients have been treated to date, with some complete and partial remissions reported.

Conjugating antibodies to cytotoxic agents is a technique beginning to be explored in human clinical trials. Since a great deal already is known about the effects of conventional chemotherapeutic drugs on cancer, these compounds are good candidates for conjugation. Ideally, the conjugation chemistry employed to link the compound to the antibody should be designed so that neither the compound nor the antibody active site is compromised. Also, if the drug were released from the antibody upon binding at the tumor antigen site, the drug would be free to attack neighboring cells, thus circumventing the problem of tumor cell heterogeneity. The first such clinical trial, involving an antibody to adenocarcinomas, has begun at the Scripps Clinic and Research Foundation in La Jolla, Calif. Patients are being treated by a MAB (termed KS 1/4) conjugated to methotrexate, a cell cycle–specific cytotoxic compound. The KS 1/4 antibody is estimated to be reactive with about 65% of all human lung cancers (ie, 97,000 new patients in 1986). Phase 1 clinical trials recently completed indicate that at total dosages of 1 g of antibody, the tumor was saturated with antibody in all 12 patients that were treated.[28]

Conjugating MABs to toxins is another approach to killing tumor cells. The primary advantage of toxins is their concentrated effect: only a few toxin molecules are required to kill a cell. The main problem with this method is that toxins are nonselective. The antibodies should cross-react minimally with normal tissue, and the covalent linkage between toxin and MAB must be strong to avoid decoupling and subsequent destruction of normal cells. There is considerable commercial interest in this approach, and initial clinical trials have begun under FDA regulation (Cetus Corp; Xoma Corp; Hybritech, Inc) in the areas of melanoma treatment, colorectal cancer, breast cancer, and ovarian cancer.

A third conjugation approach is to link radioisotopes to MABs. The advantage of radioactivity is that its killing distance is about 1 cm, thereby overcoming the issue of heterogeneity in tumor cell populations. Of course, this long-distance killing can affect normal cells in the vicinity of antibody-bound tumor cells. Several clinical trials are underway using a variety of radioactive isotopes in treatment of liver, breast, lung, prostate, and colorectal cancers.

Although clinical trials involving MABs injected into humans have been underway for only a few years, there is one antibody that already has been approved for human use by the FDA. It is a T cell–specific antibody that is being used to prevent graft rejection in kidney transplants. Data from the clinical trials indicate well over 90% treatment success with this product.[28]

It is important to note that most of the studies reported above are being conducted with murine MABs, that is, monoclonal antibodies made by hybridomas of murine origin. It is obvious from numerous clinical trials that murine MABs can be administered safely, but many of the patients receiving murine antibodies have had diseases or have been subjected to treatments that reduced their immunocompetence. In some cases, continued administration of murine antibodies has led to anti-mouse titers that neutralized the therapeutic effect.[29,30] It might be possible to minimize the problems associated with murine antibodies by desensitization of patients using high doses of murine antibodies or by immunosuppressive therapy prior to antibody therapy. A logical solution to this problem may lie in the use of human monoclonal antibodies in treatment protocols. The lack of suitable human myeloma–like fusion partners has hampered attempts to generate monoclonal antibodies by methods that had proved useful in the mouse. Attempts at producing human antibody–secreting B cell lines by infection with Epstein-Barr virus or by making mouse/human hybrids have been fruitless, as resulting cell lines either were very poor producers or proved to be chromosomally unstable. More recently, limited success has been achieved using mouse/human heteromyeloma[31,32] and lymphoblastoid fusion partners.[33,34] Limited cell line stability and low antibody secretion levels continue to be problems with these cell lines, however. It is possi-

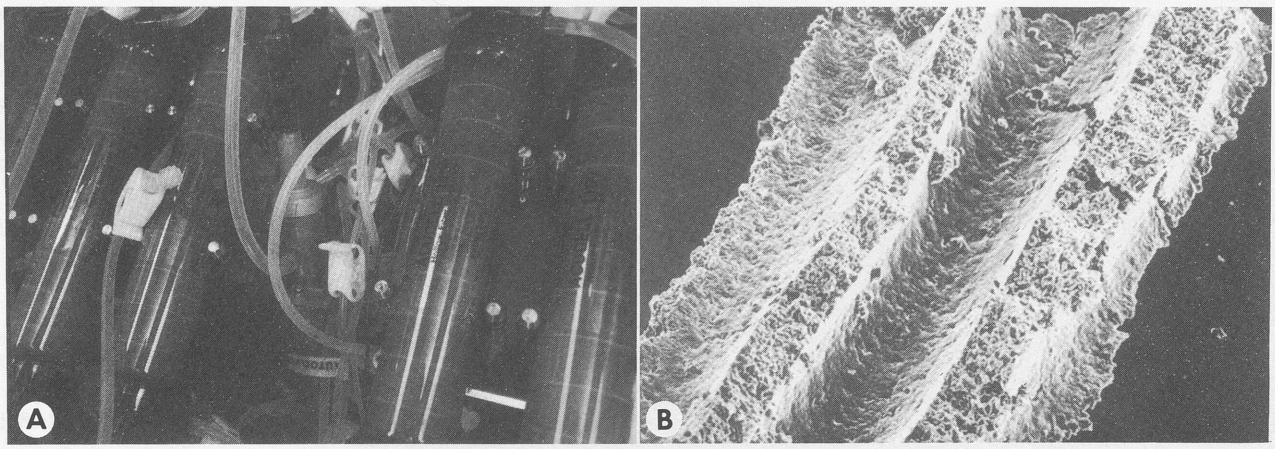

Fig 2. Hollow fiber cartridges. A) Hybridoma cells growing in bioreactors. Each bioreactor contains about 10^{10} cells growing in extracapillary volume among fibers. B) Scanning electron micrograph showing hybridoma cells densely packed between adjacent hollow fibers with fibers removed (original x204). (Photos courtesy of Endotronics, Inc)

ble that continued subcloning of already existing lines may eventually yield productive, stable cell lines. Further out on the horizon, recombinant DNA technology will be used to generate chimeric antibodies (ie, antibodies with Fab and Fc regions of different species origin), or even to "genetically" transplant hypervariable regions of a mouse antibody into the framework region of a human antibody.[35,36] In fact, many human monoclonal antibodies already are being generated for use as probes to study autoimmune and allergic disorders.[37]

ISSUES IN LARGE-SCALE PRODUCTION

Clearly, there has been substantial activity in the past 10 years as a number of diagnostic and therapeutic industries have been formed to exploit the unique specificity properties of MABs. For MABs to realize their full potential, substantial quantities will have to be produced. Currently, production requirements call for amounts ranging from a few micrograms per test, in the case of some in vitro diagnostic test kits, to a few grams per dose, for therapeutic treatment of some cancers. The need for large quantities of MABs has risen quite dramatically since 1981, so much so that an entire contract production industry has arisen just to service the needs of diagnostic and pharmaceutical companies wishing to employ MABs in their products. In 1980, the world's entire production capacity for MABs was estimated to be in the range of 100 mg to 1 g. By 1983, production by all sources probably approached 100 g, and during 1986, something on the order of 20 kg had been produced. This 10,000-fold increase in just 5 years is a testimonial to the impact MABs are having on research and development programs and the marketplace. As MABs begin to be approved as therapeutics, production requirements will increase sharply. For example, in the clinical trial underway at Scripps Clinic and Research Foundation (referred to above), the KS 1/4 antibody is estimated to be reactive with about 65% of all human lung cancers. Given the estimated lung cancer incidence of 149,000 in the United States during 1986, there would be a potential for 97,000 patient treatments. Currently, Phase 2 clinical treatment protocols call for a total dosage of 2 g of methotrexate-conjugated antibody per patient. If this treatment were to demonstrate any reasonable level of clinical efficacy, it undoubtedly would become the treatment of choice, as lung cancer is generally fatal. At a dose rate of 2 g per patient, over 190 kg of MAB product per year would be required to treat this one disease.

Coincident with the research on new medical applications, new technologies have been developed to culture hybridoma cells on a large scale. The most common method of hybridoma culture has been in the peritoneal cavity of mice. While high concentrations of antibody are achievable in ascites fluid (5 to 15 mg/mL), each mouse produces relatively small amounts of antibody, so tens of thousands of mice would be required to produce even 1 kg of MAB. In vitro culture has its own problems, as mammalian cells in general, and hybridoma cells in particular, are quite fragile and have high oxygen and nutrient requirements. Unlike other microorganisms, they cannot be cultured easily in large fermenters. While special fermenters up to 1,000 L in volume have been designed specifically for mammalian cell culture,[38] cells cannot be grown in densities any higher than in T-flask or spinner flask cultures (ie, about 10^6 cells/mL of culture volume).

Within the past 5 years, a novel cell culture technique has been developed that permits mammalian cells to be cultured at densities well above 10^8 cells/mL.[39] The cell growth chamber consists of a mass of hollow fibers packed longitudinally into a cylindrically shaped cartridge. Each fiber is a hollow tube with a 200-μm inner diameter and a semipermeable membrane. Cells are grown in the extracapillary volume among the fibers, and the fibers themselves are used for delivery of cell nutrients. Figure 2A shows hybridoma cells grow-

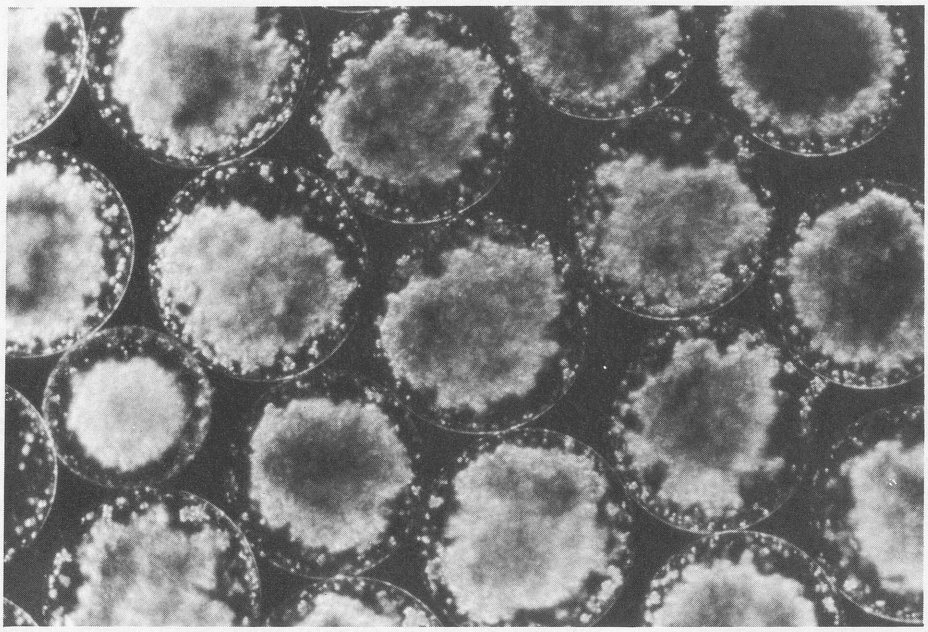

Fig 3. Hybridoma cells growing inside hollow microcapsules with semipermeable membranes. Cells grow to high densities ($>10^8$ cells/mL) within microcapsules. Microcapsule diameters are about 700 μm. (Photo courtesy of Damon Biotech, Inc)

ing in several hollow fiber cartridges. Hybridoma cells grow to high densities in the extracapillary volume while MAB product is continuously harvested in high concentrations (100 to 500 μg/mL) from the spent media. Figure 2B is a scanning electron micrograph of the interior of a hollow fiber cartridge with the fibers stripped out. Cells are packed into the extracapillary volume. Important culture conditions such as pH, dissolved oxygen, and temperature are monitored and controlled via computer. In addition, the computer monitors critical physiologic properties of the cells such as glucose uptake and lactose production[40] to optimize antibody production on a per-cell basis. Using one such commercially available hollow fiber system (the Acusyst-P Cell Culture System, Endotronics, Inc, Coon Rapids, Minn) MAB in reasonably pure form (>50%) can be harvested at a rate of several grams per day from an average-producing hybridoma line.

Another interesting approach to large-scale hybridoma culture is microencapsulation, in which cells are grown in the interior of hollow microcapsules with semipermeable membranes.[41] As with the hollow fibers, the membrane permeability can be tailored to permit free access by nutrient media, but not allow antibody product to cross. In this unique process, the hybridoma cells are contained in liquid microdroplets that are then converted to gelled microspheres. The semipermeable membrane is formed around the gelled microspheres, the gel is reliquified, and the hybridoma cells are now trapped within the hollow microspheres. Cell-containing microspheres then can be placed into specially designed fermenters in which antibody production commences. Figure 3 is a photomicrograph of hybridoma cells growing in microcapsules. Over a period of several weeks, the antibody concentration builds up to over 1 mg/mL within the capsules, which are subsequently broken open to release the antibody for further processing. Antibody production rates with microencapsulation are similar to rates obtained with hollow fiber systems.

SUMMARY AND CONCLUSIONS

It is clear from the foregoing that MABs represent a very special class of molecules. In the decade since hybridoma technology was invented, MABs have become the cornerstone of the emerging biotechnology industry. Hundreds of different in vitro diagnostic tests already have been developed, and the relative ease and low cost with which mouse MABs of high titer and high affinity can be produced in response to a broad range of specific antigens is likely to make them the reagents of choice for most in vitro diagnostic applications. Diagnostic medical imaging applications, however, are likely to become increasingly important, particularly as human MABs become more widely available. The single most important application will be the imaging of malignant tumors by radionuclide-conjugated MABs. Another important imaging application will be the detection of vascular and degenerative lesions, especially acute myocardial infarcts. Finally, radionuclide-labeled MABs against various pathogenic viruses and bacteria will facilitate diagnosis of lesions in internal organs, thus decreasing the need for invasive diagnostic procedures.

It is in the therapeutic arena, however, that MABs are likely to make their biggest impact on human health care. Tumor therapy most likely will become the largest application within the next 5 years. As techniques for creating stable productive human hybridomas are developed, MABs undoubtedly will prove effective in the treatment of infectious disease, particularly for acute viral illnesses

for which presently available antibiotics are known to be ineffective. Treatment effectiveness will be increased by coupling MABs to other cytotoxic agents such as toxins, chemotherapeutics, and radioactive isotopes. Further applications will be found for genetically altered MABs; for example, chimerics.

The above advances have spawned a revolution in our understanding of basic immunologic processes and in the creation of new reagents to study cell-cell interactions. This revolution now is being translated into significant improvements of existing diagnostic tests and development of whole new areas for diagnostic measurement and monitoring. The greatest impact of MAB technology will occur in the treatment of human disease. It is in this area that the revolution has yet to come.

REFERENCES

1. Köhler G, Milstein C. Continuous cultures of fused cells secreting antibody of predefined specificity. Nature 1975;256: 495-7.

2. Wilkinson JM. Monoclonal antibodies in agriculture. Span 1985;28:89-91.

3. Stokes CR. Monoclonal antibodies: the practical aspects as applied to immunology and antisera production. In: Ross DB, Sellers LS, eds. New biotechnology for animal health and production. Association of Veterinarians in Industry. Royal College of Veterinary Surgeons, London, 1984:65.

4. Hill CR, Birch JR, Benton C. Bulk production of monoclonal antibodies in fermenters. In: Bioactive microbial products III — downstream processing. Special publication of the Society for General Microbiology. New York: Academic Press, 1984.

5. Bosch AMG, Stevens W, Schuurs A, Schoenherr OT, Reolefs HWM. Characteristics of monoclonal antibodies against human chorionic gonadotrophin (hCG). In: Peeters H, ed. Peptides of the biological fluids. Proceedings of the 29th Colloquium, Brussels. Oxford: Pergamon Press, 1983:837-42.

6. Miller RA, Maloney DG, Warnke R, Levy R. Treatment of a B-cell lymphoma with monoclonal anti-idiotype antibody. N Engl J Med 1982;306:517-22.

7. Eisen HN. Immunology. 2nd ed. Hagerstown, Md: Harper & Row, 1983:337-80.

8. Hoffman RA. Clinical utility of cell surface antigen detection. Am Biotech Lab 1984;2:38-50.

9. Mach J, Chatal J, Lumbroso J, et al. Tumor localization in patients by radiolabeled monoclonal antibodies. Cancer Res 1983;43:5593-600.

10. Murry J, Rosenblum N, Sobol R, et al. Radioimaging in malignant melanoma with ^{131}I-labeled monoclonal antibody. Cancer Res 1985;45:2376-80.

11. Berger H. Myocardial imaging: new radiotracers aid diagnosis. Diagn Imag 1987;1:78-89.

12. Shimokawara I, Imamura M, Yamanaka N, Ischii Y, Kikuchi K. Identification of lymphocyte subpopulations in human breast cancer tissue and its significance: an immunoperoxidase study with anti-human T and B-cell sera. Cancer 1982; 49: 1456-64.

13. Zeromski J, Szmeja Z, Rewers A, Kruk-Zagajewska A. Immunofluorescent assessment of tumour infiltrating cells in laryngeal carcinoma. Application of monoclonal antibodies. Acta Otolaryngol (Stockh) 1986;102:325-32.

14. Chiorazzi N, Wasserman R, Kendel H. Use of Epstein-Barr virus-transformed B cell lines for the generation of immunoglobulin-producing human B cell hybridomas. J Exp Med 1982; 156:930-5.

15. Burnett K, Leung J, Marinis J. Human monoclonal antibodies to defined antigens. In: Engelman E, Foung S, Larrick J, Raubitschek A, eds. Human hybridomas and monoclonal antibodies. New York: Plenum Press, 1985:113-33.

16. Teng N, Kaplan H, Hebert J, et al. Protection against gram-negative bacteremia and endotoxemia with human monoclonal IgM antibodies. Proc Natl Acad Sci USA 1985;82:1790-4.

17. Hunter K Jr, Fischer G, Hemming V, Wilson S, Hartzmann B, Woody J. Antibacterial activity of a human monoclonal antibody to *Haemophilus influenzae* type B capsular polysaccharide. Lancet 1982;2:798-9.

18. Steinitz M, Tamir S, Goldfarb A. Human anti-pneumococci antibody produced by an Epstein-Barr virus (EBV)-immortalized cell line. J Immunol 1984;132:877-82.

19. Emanual D, Gold J, Colacino J, Lopez C, Hammerling U. A human monoclonal antibody to cytomegalovirus (CMV). J Immunol 1984;133:2202-5.

20. Ritts R Jr, Ruiz-Arguelles A, Weyl K, et al. Establishment and characterization of a human non-secreting plasmacytoid cell line and its hybridization with human B cells. Int J Cancer 1983; 31:133-51.

21. Foung S, Perkins S, Koropchak C, et al. Human monoclonal antibodies neutralizing varicella zoster virus. J Infect Dis 1985;52:280-5.

22. Udomsangpetch R, Lundgren K, Berzins K, et al. Human monoclonal antibodies to Pf155, a major antigen of malaria parasite *Plasmodium falciparum*. Science 1986;231:57-9.

23. Schoenfeld Y, Rauch J, Massicotte H, et al. Polyspecificity of monoclonal lupus autoantibodies produced by human/human hybridomas. N Engl J Med 1983;24:414-20.

24. Haskard D, Archer J. The production of human monoclonal autoantibodies from patients with rheumatoid arthritis by the EBV-hybridoma technique. J Immunol Methods 1984;74: 361-7.

25. Wright GL Jr, ed. Monoclonal antibodies and cancer. New York: Marcel Dekker, 1984.

26. Boeheim K, Schwarzfurtner H, Boeheim C, Frei E III, Bernal SD. Immunohistochemical identification of squamous carcinoma of the head and neck with monoclonal antibody SQM1. Acta Otolaryngol (Stockh) 1986;102:333-40.

27. Meeker TC, Lowder J, Maloney DG, et al. A clinical trial of anti-idiotype therapy for B cell malignancy. Blood 1985; 65:1349-63.

28. Broomby MR, Brown J, Price BJ. Monoclonal antibodies in the United States: a technical and commercial survey of in-vivo applications (trade mission to the United States supported by the Department of Trade and Industry, UK). Report issued by Inveresk Research International, Musselburgh EH21 7UB, Scotland, September 1986.

29. Dillman R, Shawler D, Dillman J, Royston I. Therapy of chronic lymphocytic leukemia and cutaneous T-cell lymphoma with T101 monoclonal antibody. J Clin Oncol 1984;2:881-91.

30. Shawler D, Bartholemew R, Smith L, Dillman R. Human immune response to multiple injections of murine monoclonal IgG1. J Immunol 1985;135:1530-5.

31. Ostberg L, Pursch E. Human X (mouse x human) hybridomas stably producing human antibodies. Hybridoma 1983;2: 361-7.

32. Glassy M, Handley H, Hagiwara H, Royston I. UC-729-6, a human lymphoblastoid B-cell line useful for generating antibody-secreting human/human hybridomas. Proc Natl Acad Sci USA 1983;80:6327-31.

33. Larrick J, Truitt K, Raubitschek A, Senyk G, Wang J.

Characterization of human hybridomas secreting antibody to tetanus toxoid. Proc Natl Acad Sci USA 1983;80:6376-80.

34. Morrison S. Transfectomas provide novel chimaeric antibodies. Science 1985;229:1202-7.

35. Jones PT, Dear PH, Foote J, Neuberger MS, Winter G. Replacing the complementarity-determining regions in a human antibody with those from a mouse. Nature 1986;321:522-5.

36. Chiorazzi N. Human monoclonal antibodies as probes to study autoimmune and allergic disorders. Biotechnology 1986;4: 210-8.

37. Birch JR, Thompson PW, Lambert K, Boraston R. The large scale cultivation of hybridoma cells producing monoclonal antibodies. Abstract of presentation at the meeting of the American Chemical Society, Philadelphia, 1984. Available from Celltech Ltd, 244-250 Bath Rd, Slough, Berkshire SL1 4DY, England.

38. Hopkinson J. Hollow fiber cell culture systems for economical cell-product manufacturing. Biotechnology 1985;3:225-30.

39. Gruenberg ML, Walker RD. A new technique for controlled delivery of biochemical regulatory agents to isolated tissue in culture. BioTechniques 1983;1:87-9.

40. Posillico EG. Microencapsulation technology for large-scale antibody production. Biotechnology 1986;4:114-7.

CONGENITAL LARYNGEAL ANOMALIES ASSOCIATED WITH TRACHEAL AGENESIS

LAUREN D. HOLINGER, MD
CHICAGO, ILLINOIS

MARK S. VOLK, DMD
MAYWOOD, ILLINOIS

GABRIEL F. TUCKER, JR, MD†
CHICAGO, ILLINOIS

Forty-eight cases of tracheal agenesis have been reported to date. Previous authors have studied gross postmortem laryngeal specimens. Of 37 cases wherein laryngeal findings were mentioned, only 14 were reported to be abnormal. This report details two more cases of tracheal agenesis and includes a detailed histopathologic study of the laryngeal anomalies by serial horizontal section. Although one of these specimens appeared normal at autopsy, both were found to have several abnormalities when studied microscopically in horizontal section. Both have an elliptical cricoid cartilage, an abnormality originally discovered by one of us (G.F.T.) using the same technique.

KEY WORDS — cleft larynx, congenital laryngeal anomalies, elliptical cricoid cartilage, tracheal agenesis.

INTRODUCTION

Tracheal agenesis is a rare and universally fatal congenital anomaly. Our report of two newborns with this condition brings the number of reported cases to 50. Other investigators have evaluated this anomaly to clarify the embryology of the upper aerodigestive tract; however, the literature contains only reports of gross pathologic examination of larynges from affected infants. Serial horizontal sectioning of these specimens allows a more detailed and precise investigation, often leading to unanticipated observations, particularly regarding the morphology of the cricoid cartilage.

CASE REPORTS

Case 1. A 2,300-g girl was born to a 42-year-old mother by low forceps delivery. Her Apgar scores were 7 and 8. The infant developed respiratory distress and was given positive pressure ventilation by mask shortly after birth. Multiple attempts at intubation failed, but esophageal placement of an endotracheal tube improved ventilation. Emergency laryngoscopy was carried out immediately upon transfer to The Children's Memorial Hospital in Chicago.

The subglottic larynx was found to end in a blind pouch. An attempted tracheotomy became a neck exploration, but no trachea could be identified. Contrast medium injected into the endotracheal tube showed a communication between the mid-esophagus and both main bronchi. The diagnosis of tracheal agenesis having been made, the chance of long-term survival was recognized to be nil. The decision was made with the family to terminate ventilatory support, and the infant died the next day.

In addition to tracheal agenesis and the laryngeal findings detailed below, autopsy revealed an infant

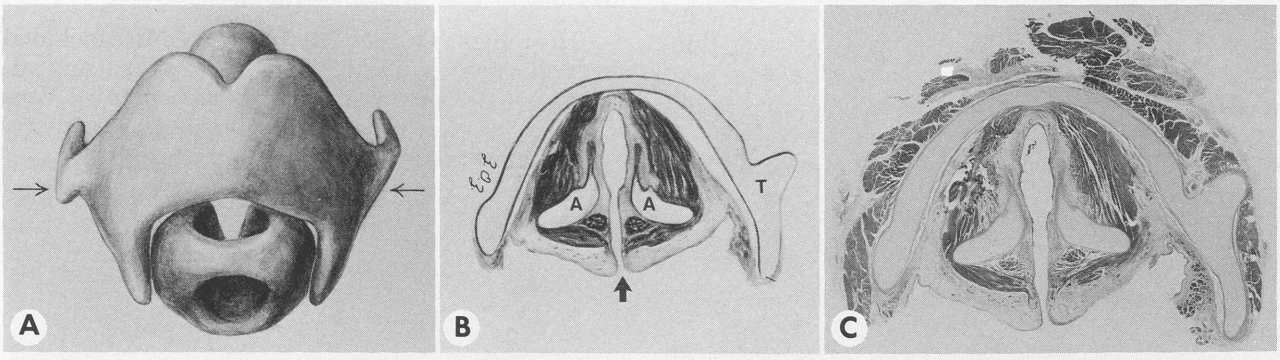

Fig 1. (Case 1) A) Artist's rendering of anterior aspect of larynx. Arrows indicate level of horizontal sections in B and C. B) Horizontal section at level of arytenoid cartilages (A). Arrow — posterior cleft, T — thyroid cartilage. C) Photomicrograph of same section.

From the Division of Otolaryngology/Bronchoesophagology, The Children's Memorial Hospital, and the Department of Otolaryngology and Bronchoesophagology, Rush-Presbyterian-St Luke's Medical Center, Chicago (Holinger); and the Department of Otolaryngology-Head and Neck Surgery, Loyola University Medical Center, Maywood, Illinois (Volk). Work at the Laryngeal Development Laboratory at The Children's Memorial Hospital was supported by a grant from the Lillian S. Wells Foundation, Inc.

†Deceased.

Presented at the meeting of the American Laryngological Association, Denver, April 25-26, 1987.

REPRINTS — Lauren D. Holinger, MD, 155 N Michigan Ave, Chicago, IL 60601.

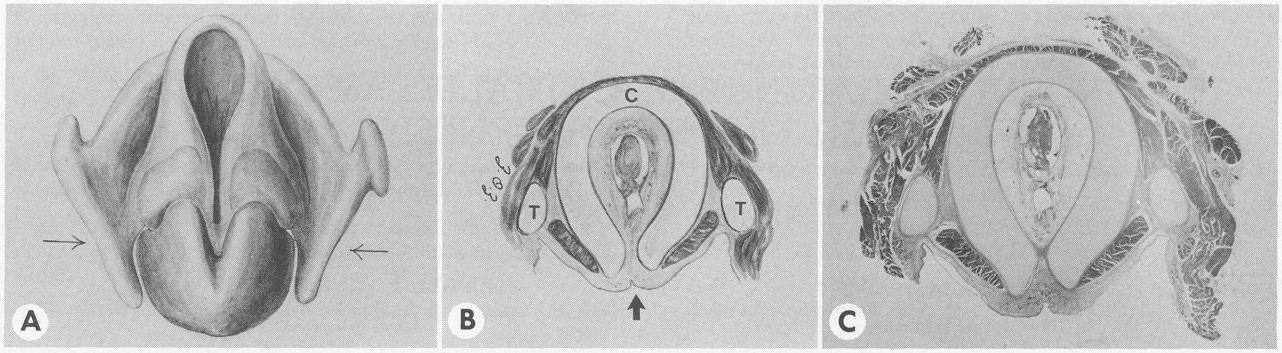

Fig 2. (Case 1) A) Artist's rendering of larynx from posterior aspect. Arrows indicate level of horizontal sections in B and C. B) Horizontal section through larynx at level of cricoid ring. Arrow identifies posterior cleft of cricoid cartilage (C). Soft tissue is intact at this level. T — inferior cornu of thyroid cartilage. C) Photomicrograph of same section.

weighing 1,816 g, measuring 46.5 cm in length, and having a gestational age of 36 weeks. The uterus was rudimentary, and the urethra entered into a blind vaginal pouch. There was a patent foramen ovale and a widely patent ductus arteriosus. The innominate artery was absent.

The larynx was obtained and embedded in pyroxylin (Parolodion) in the usual fashion. It was sectioned at 28 μm in the horizontal plane from top to bottom, and every 20th section was mounted and stained with H & E.

The most striking abnormality is an incomplete posterior laryngeal cleft with an absent posterior cricoarytenoid muscle (Fig 1). The lumen of the cricoid ring is elliptical rather than round (Fig 2). The inferior extent of the cleft is midway through the posterior cricoid lamina (Fig 2). A protuberance or spine is present in the intact posterior-inferior aspect of the cricoid cartilage (Fig 3). There is no atretic plate of cartilage at the inferior margin of the cricoid ring.

From the anterior commissure to the vocal processes of the arytenoid cartilages, the vocal folds measure 5 mm. Because of the laryngeal cleft, the distance between the anterior commissure and the posterior glottic wall could not be measured with accuracy. The anterior-posterior and transverse diameters of the superior cricoid cartilage are 7 mm and 4 mm, respectively. Thickening of the overlying mucous membrane in this area reduced the cricoid lumen to 4 x 2 mm. The anterior-inferior aspect of the cricoid cartilage is dehiscent (Fig 3B,C). The thyroid cartilage, as well as the glottic and supraglottic structures, is relatively normal. These relationships are demonstrated best in the artist's rendering of the larynx (Figs 1A, 2A, and 3A).

Case 2., A 1,400-g boy born to an 18-year-old woman developed respiratory distress immediately after delivery. Positive pressure ventilation by mask was not effective. Multiple unsuccessful intubation attempts were made at the original hospital, as well as at a nearby tertiary care facility. The patient was transferred to The Children's Memorial Hospital in Chicago.

Emergency direct laryngoscopy revealed a blind subglottic pouch. The esophagus was intubated and the patient adequately ventilated. Intraoperative chest radiographs showed bilateral pneumothoraces. Chest tubes were placed and the respiratory status stabilized. Esophagoscopy demonstrated a 1-mm diameter distal bronchoesophageal fistula.

The patient's subsequent hospital course included several episodes of respiratory distress requiring adjustment of the esophageal endotracheal tube. Ventilatory support was discontinued shortly thereafter, and the child died 34 hours after birth.

Fig 3. (Case 1) A) Artist's rendering of left lateral aspect of larynx. Arrows indicate level of horizontal sections in B and C. B) Horizontal section through larynx near inferior extent of cricoid cartilage (C). No atretic plate is present. T — inferior cornu of thyroid cartilage. C) Photomicrograph of same section.

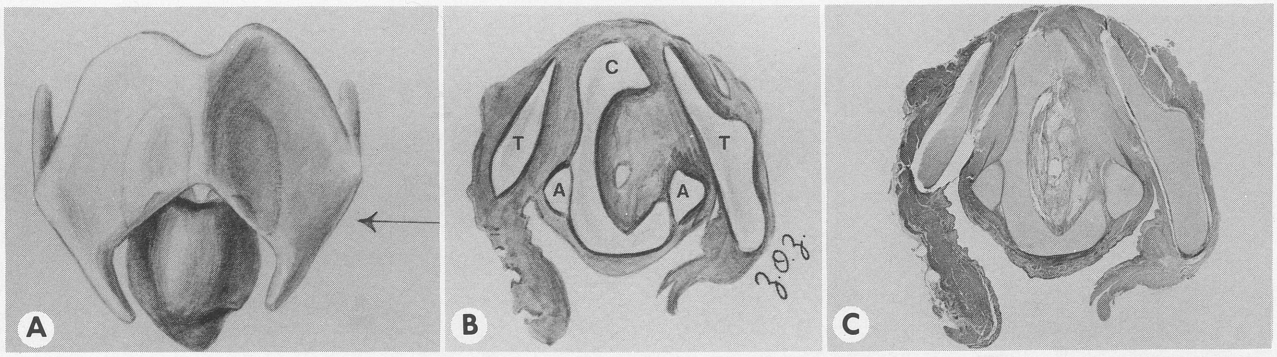

Fig 4. (Case 2) A) Artist's rendering of anterior aspect of larynx. Arrow indicates level of horizontal sections in B and C. B) Horizontal section through larynx at superior end of cricoid cartilage (C). Cricoid is elliptical and extends superiorly to just below vocal folds. A — arytenoid cartilages, T — thyroid cartilage alae. C) Photomicrograph of same section.

At autopsy, the child was determined by examination to be at 36 weeks' gestation. He weighed 1,486 g; was 41.5 cm in length; and had bifid ribs, hemivertebrae, absent right thumb, ovoid shaped pupils, hypoplastic left kidney and ureter, and a 3-mm ventricular septal defect. Examination of the larynx was carried out after decalcification, horizontal sectioning, and staining as described above.

An elliptical cricoid cartilage extends superiorly to just below the vocal folds (Figs 4-6). The cricoid cartilage has an increased rostral-caudal length. The thyroid cartilage extends inferiorly only to the glottic level and therefore is shorter than normal. The vocal folds are 5 mm in length, and the distance between the anterior commissure and the posterior glottic wall is 6 mm. Superiorly, the cricoid cartilage measures 7 mm in the anterior-posterior dimension and 4 mm transversely. The overlying soft tissue is of normal thickness and does not contribute to the subglottic stenosis. Again, no atretic plate is present along the inferior aspect of the cricoid ring (Fig 6).

DISCUSSION

Of the 48 case reports of tracheal agenesis, there are comments on the condition of the larynx in 37.[1-7] Fourteen were reported to be abnormal. The actual number is probably greater. Of the two cases reported here, the only abnormality identified by the pathologist was the laryngeal cleft for case 1. Gross examination revealed no abnormalities in case 2. Prepared by the histopathologic techniques established by Gabriel F. Tucker, Jr, horizontal serial sections of whole larynges have elucidated congenital and acquired conditions that were not readily apparent on endoscopy or routine postmortem examination.[8-10]

Using the same techniques to examine our two specimens, we discovered both larynges to have a number of abnormalities. An elliptical cricoid cartilage was found in both cases. In 1979, Tucker et al first described the elliptical cricoid cartilage.[10] Since then, the condition has been recognized in six living patients.[11]

The glottic dimensions of the two larynges are similar. Measurements of both are within the range of normal established by Schild's data for neonates of 36 weeks' gestation.[12] This finding suggests normal glottic development.

An association between the VATER syndrome (vertebral defects, imperforate anus, tracheoesophageal fistula, and radial and renal dysplasia) and tracheal agenesis has been noted.[13] The structures affected in the VATER syndrome undergo organogenesis during the fourth to seventh postovulatory weeks; this timing coincides with that of laryn-

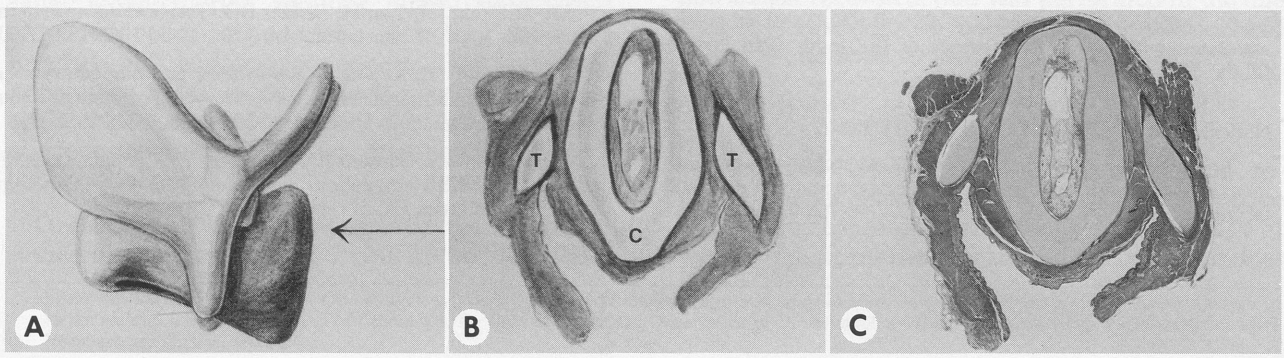

Fig 5. (Case 2) A) Artist's rendering of left lateral aspect of larynx. Arrow indicates level of horizontal sections in B and C. B) Horizontal section at level of cricoid ring (C) demonstrating elliptical shape of cartilage and lumen. T — inferior cornu of thyroid cartilage. C) Photomicrograph of same section.

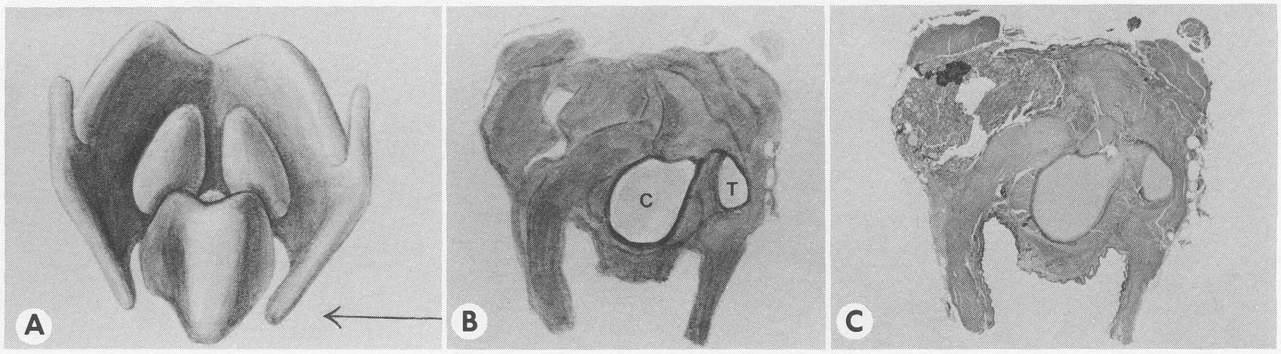

Fig 6. (Case 2) A) Artist's rendering of posterior aspect of larynx. Arrow indicates level of horizontal sections in B and C. B) Horizontal section through inferior aspect of cricoid cartilage (C). No atretic plate or lumen is apparent at this level. T — right inferior cornu of thyroid cartilage. C) Photomicrograph of same section.

geal and tracheal development.[14] Including tracheal agenesis, 31 of the 48 previously described cases have had two or more of the VATER anomalies.[13] This is important, since two-defect combinations occur 11 times more frequently than by chance alone[15]: case 1 has a urethral aberration; case 2, hemivertebrae, bifid ribs, absent thumb, and a hypoplastic kidney and ureter.

SUMMARY

For the first time, larynges from two infants with tracheal agenesis have been studied in detail by the histopathologic technique of serial sectioning of the whole organ in the horizontal plane. An elliptical cricoid cartilage with a relatively normal glottis is present in both specimens. This rare cricoid cartilage anomaly is difficult to diagnose clinically and only recently has been described.[10] Our findings suggest the following conclusions:

1. Congenital laryngeal anomalies, particularly cricoid cartilage deformities, may have been present but unrecognized in previous reports of tracheal agenesis.
2. The abnormalities identified in these two cases support the association of tracheal agenesis with the VATER syndrome.
3. Investigation of congenital laryngeal anomalies, particularly those associated with tracheal agenesis, is best accomplished by careful histopathologic examination, preferably by horizontal serial sectioning of the whole organ.

REFERENCES

1. Warfel KA, Schulz DM. Agenesis of the trachea: report of a case and review of the literature. Arch Pathol Lab Med 1976; 100:357-9.

2. Effman EL, Spackmann TJ, Bendon WE, Kuhn JF, Leonidas JC. Tracheal agenesis. Am J Roentgenol Radium Ther Nucl Med 1975;125:767-81.

3. Donovan TJ, Friedman WH. Aplasia of the trachea. Ear Nose Throat J 1979;58:92-7.

4. Sandison AT. Partial absence of the trachea with live birth. Arch Dis Child 1955;30:475-7.

5. Sakai N, Igarashi M, Miller RH. Temporal bone findings in VATER syndrome. Arch Otolaryngol Head Neck Surg 1968; 112:416-9.

6. Anderson CL, Ahmed G, Caldwell CG. Tracheal atresia associated with congenital absence of the radii. Clin Pediatr (Phila) 1981;20:478-80.

7. Buchino JJ, Meaghr OP, Cox JA. Tracheal agenesis: a clinical approach. J Pediatr Surg 1982;17:132-7.

8. Tucker GF, Tucker JA, Vidic B. Anatomy and development of the cricoid: serial section whole organ study of perinatal larynges. Ann Otol Rhinol Laryngol 1977;86:766-9.

9. Tucker JA, Tucker G, Vidic B. Clinical correlation of anomalies of the supraglottic larynx with the staged sequence of normal human laryngeal development. Ann Otol Rhinol Laryngol 1978;87:636-44.

10. Tucker GF, Ossoff RH, Newman AN, Holinger LD. Histopathology of congenital subglottic stenosis. Laryngoscope 1979; 89:866-77.

11. Schlesinger AE, Tucker GF. Elliptical cricoid cartilage: a unique type of congenital subglottic stenosis. Am J Radiol 1986; 146:1133-6.

12. Schild JA. Relationship of laryngeal dimensions to body size and gestational age in premature neonates and small infants. Laryngoscope 1984;94:1284-92.

13. Millstein JM, Lau M, Bickers RG. Tracheal agenesis in infants with VATER association. Am J Dis Child 1985;139:77-80.

14. O'Rahilly R, Müller F. Respiratory and alimentary relations in staged human embryos: new embryological data and congenital anomalies. Ann Otol Rhinol Laryngol 1984;93:421-9.

15. Khoury MJ, Cordero JF, Greenberg F. A population study of the VACTERL association: evidence for its etiologic heterogenicity. Pediatrics 1983;71:815-20.

ADJUNCTIVE MEASURES FOR SUCCESSFUL LARYNGOTRACHEAL RECONSTRUCTION

STEVEN GRAY, MD
IOWA CITY, IOWA
ROBERT MILLER, MD
CHICAGO, ILLINOIS
CHARLES M. MYER III, MD
CINCINNATI, OHIO
ROBIN T. COTTON, MD
CINCINNATI, OHIO

The field of reconstructive surgery of the laryngotracheal complex has been the object of considerable enthusiasm in recent years. New surgical techniques, better surgical tools, and improved diagnostic skills all have contributed to a more confident approach to severe laryngotracheal stenosis. Just as the surgeon's judgment is crucial for a successful primary laryngotracheal reconstruction, so are his or her skill and judgment vitally important in managing the various problems that frequently are found following reconstructive surgery of the larynx and trachea. These problems, although seemingly minor, may prevent successful decannulation if not managed appropriately. This paper discusses the various problems that have been encountered while achieving decannulation following laryngotracheal reconstruction. An approach to such frustrating problems as suprastomal collapse, granulation tissue, and the inability to decannulate are presented.

KEY WORDS — laryngotracheal reconstruction, laryngotracheal stenosis, subglottic stenosis.

INTRODUCTION

Surgical therapy of the laryngotracheal complex for improvement of the airway has become much more common. Refined techniques for operating on these structures have made it possible for surgeons to perform major reconstructive operations while keeping tracheal and laryngeal scarring to a minimum.[1-5] Ongoing experience with stenting and grafting, better preoperative evaluation, and use of a variety of surgical techniques allow a surgeon to customize the reconstructive procedure to each particular problem. Because of the multiplicity of lesions that may compromise the airway, successful reconstruction requires both creativity and imagination on the part of the surgeon. In a similar fashion, postoperative care of patients following laryngotracheal reconstruction must be individualized.

It is an error to assume that a major reconstructive procedure on the airway, such as laryngotracheal reconstruction, will provide a satisfactory airway without further therapy. Unfortunately, many of our patients and colleagues believe this to be the case. In certain selected situations, this may be true; however, more frequently a successful laryngotracheal reconstruction requires highly skilled and diligent postoperative care, including medical, surgical, and endoscopic therapy. This paper addresses the multiple problems the surgeon faces in achieving a satisfactory airway after laryngotracheal reconstruction and offers therapeutic solutions for the clinician.

Occasionally we have compared the treatment course of these patients to flying an airplane. The takeoff, representing the initial reconstructive operation, is a major step toward completing the journey. But once the plane is in the air, multiple adjustments must be made to keep the flight successfully on course. The same is true with a patient who undergoes laryngotracheal reconstruction. After the laryngotracheal reconstruction has been performed, minor surgical procedures or medical therapy may be needed to assure the success of the operation. Decannulation, which can be compared to landing the airplane, is the last major step and reflects the ultimate success of the mission. To emphasize this concept to our patients, we frequently refer to treatment of these diseases as a course of therapy, thereby reinforcing the point that the treatment necessary for a successful outcome involves more than one step or procedure.

To determine the additional care required for successful decannulation, the 42 patients who experienced a primary laryngotracheal reconstruction from July 1, 1985, to June 30, 1986, were reviewed. These procedures all were performed at the Children's Hospital of Cincinnati. All but one of these patients were tracheotomy-dependent, and laryngotracheal reconstruction was performed in the one patient who did not have a tracheostomy because of severe intolerance to minimal physical activity.

PREOPERATIVE CARE

Successful laryngotracheal reconstruction requires proper patient selection and preoperative evaluation, beginning with deciding on the age at which to perform the procedure. Although this does

From the Division of Pediatric Otolaryngology, Department of Otolaryngology and Maxillofacial Surgery, University of Cincinnati College of Medicine, and Children's Hospital of Cincinnati. Dr Gray is now at the Department of Otolaryngology–Head and Neck Surgery, University of Iowa Hospitals and Clinics, Iowa City.

Presented at the meeting of the American Laryngological Association, Denver, April 25-26, 1987.

REPRINTS — Robin T. Cotton, MD, Dept of Pediatric Otolaryngology and Maxillofacial Surgery, Children's Hospital Medical Center, Elland and Bethesda Aves, Cincinnati, OH 45229-2899.

not become an issue for the adult patient with laryngotracheal stenosis, the physician who cares for pediatric patients is asked this question frequently. Though the answer depends on many conditions, most laryngotracheal reconstructions can be performed successfully by the time a child is 1 to 1½ years of age and weighs approximately 10 kg. In selected instances, we have performed successful laryngotracheal reconstruction on infants who were less than 1 year of age. Our earliest laryngotracheal reconstruction was performed in a 9-month-old. It has been our experience that performing this operation earlier makes the surgery more difficult technically and that the postoperative endoscopic care is also more challenging. One should remember that a cricoid split may be an acceptable therapeutic alternative to laryngotracheal reconstruction in some patients with a limited anterior subglottic stenosis.[6]

Many pediatric patients with laryngotracheal stenosis have concomitant pulmonary disease, the most common being bronchopulmonary dysplasia. Correction and stabilization of pulmonary and cardiovascular disease should be done before laryngotracheal reconstruction. There are a number of reasons for this. The harvesting of rib grafts for laryngotracheal grafting can compromise the pulmonary system postoperatively and places the patient at risk for a pneumothorax. Laryngotracheal reconstruction and the stents that may be used in such a procedure can lead to postoperative aspiration that would compound the difficulties experienced in postoperative care of a patient with pulmonary compromise. Additionally, even if the procedure is successful, a patient who has severe pulmonary disease may require further ventilatory support that precludes decannulation. For similar reasons, a laryngotracheal reconstruction should be delayed if it appears that other operations or anesthetics will be required in the near future. In this way, unnecessary trauma to an abnormal larynx is avoided.

Other medical problems that should be addressed preoperatively include nutritional status, gastroesophageal reflux (GER), and proper evaluation of the primary insult that caused the laryngotracheal injury. As head and neck surgeons, we are acutely aware of the postoperative complications that can develop in patients who are malnourished.[7,8] The infant who undergoes laryngotracheal reconstruction is no exception.

Gastroesophageal reflux is a condition that is frequently overlooked. It has been our impression that patients with uncontrolled GER have a higher rate of failure in laryngotracheal reconstruction and also require more postoperative procedures, especially if a laryngeal stent is present. When GER occurs with a stent in place, prime conditions exist for formation of excessive granulation tissue and scarring.

Recently, we have become much more aware of the important effect this may have on successful decannulation. Several infants have failed decannulation following an apparently successful laryngotracheal reconstruction because of apnea and laryngospasm associated with GER.[9] Correction of the GER subsequently allowed decannulation. It is our routine for every patient undergoing laryngotracheal reconstruction to have a preoperative nuclear medicine scan to evaluate for GER.

Laryngotracheal reconstruction should be delayed if the stenosis is not mature or if the condition causing the stenosis, such as an infectious or inflammatory disease, is not controlled. An immature stenosis at times still may be treated by conservative methods. Waiting until the stenosis matures allows the surgeon to recognize preoperatively the full extent of the stenosis. In rare cases, the condition causing the stenosis may never be controlled. This is demonstrated well in those patients who have an inherent cartilage abnormality such as spondyloepiphyseal dysplasia.[10]

Finally, proper preoperative evaluation of the larynx should include flexible laryngoscopy to assess the motion of the vocal cords and the supraglottic region. Obviously, successful decannulation may be delayed if the vocal cords are paralyzed or the arytenoid cartilages are fixed. Unfortunately, accurate assessment of glottic and supraglottic function may be impossible in a child with subglottic stenosis and a tracheotomy. Patients need to be informed of these conditions preoperatively so that expectations are realistic. Finally, the physician should insure that proper education of parents has taken place and that they demonstrate proficiency in tracheotomy care and cardiopulmonary resuscitation.

OPERATIVE MEASURES

There are many successful surgical methods that may be used to correct laryngotracheal stenosis. Since each method has inherent advantages and disadvantages, it is up to the surgeon to determine which reconstructive procedure would provide the optimal result for the problem at hand. It is not the purpose of this paper to discuss the indications for each method; however, there are standard principles and techniques that can optimize the postoperative result. The first is prophylactic perioperative antimicrobial agents.[11] Nearly all of these patients have an indwelling tracheotomy at the time of the surgery, and, although this represents a contaminated site, surprisingly few serious infections result from this contamination. It is reasonable, however, to assume that perioperative antimicrobial agents reduce the postoperative wound infection rate. In our series of laryngotracheal reconstructions, we have experienced no severe postoperative wound infections causing dissolution of the cartilage graft.

Surgical access to the area of upper laryngeal or tracheal stenosis is generally not a problem. In cer-



Fig 1. Cross section of cricoid cartilage with anterior and posterior grafts in place. T configuration of anterior graft prevents prolapse. Grafts should be lined up evenly with tracheal edges or slightly outward, so that mucosa healing over graft will be level.

tain cases, however, a tracheal lesion such as complete tracheal rings or a distal tracheal stenosis requires access to the region of the carina. A sternotomy is required, and there may be difficulty with ventilation when the trachea is open from the level of the cricoid to the carina. In such cases, we employ cardiopulmonary bypass in order to maintain satisfactory oxygenation. Because a sternotomy is required for exposure of the defect, there is some additional morbidity. This allows unparalleled exposure to the entire laryngotracheal tree and avoids the competition the surgeon frequently encounters with the anesthesiologist in attempting to maintain ventilation without compromising surgical access and visualization. Following the actual reconstructive procedure and termination of cardiopulmonary bypass, ventilation may be continued by an endotracheal tube placed intraoperatively; if a long-term stent is needed, this may be placed in combination with a tracheotomy tube.

As improvement in airway symptoms in children occurs with only millimeters of change in the diameter of the trachea and larynx, surgery of the airway demands commensurate attention to detail. Mucosal and cartilage edges must be lined up precisely for optimal results. Care should be taken to remove any redundant tissue or folded remnants of cartilage at the tracheotomy site when performing a laryngotracheal reconstruction. Corresponding attention should be paid to the sites of grafting or anastomosis so that redundancies or folds of tissue are not present. When cartilage grafting is used, optimal placement of the graft is positioned slightly outward as shown in Fig 1.[12]

The use of stents in laryngotracheal reconstruction is an important method of maintaining a lumen while healing occurs. Nevertheless, because it represents a foreign object, a stent occasionally provokes an inflammatory reaction in the larynx or trachea. It appears this response is very individualized, and some people are able to accommodate a stent for a long period of time. A frequently overlooked site of irritation for stents is in the glottis. If a laryngeal stent is at the level of the vocal cords or in the supraglottic region at the level of the false vocal cords, the additional motion caused by the vocal cords against the stent can be quite irritating. As a result, one may encounter severe scarring and granulation tissue in the glottis or supraglottic region from such stents. It appears that the majority of these reactions are caused by the true vocal cords or false vocal cords trying to close over the stent, and if the stent is placed through both the false and true vocal cords, closure cannot be achieved and irritation and inflammation are kept to a minimum. Total glottic obstruction from scarring may result from a stent placed up to the vocal cords but not through them. The same phenomenon can result in a blind pouch in the supraglottic region at the level of the false vocal cords. Because of these potential complications, we recommend placement of long-term stents through both the true and false vocal cords. The position of the stents should be checked endoscopically both intraoperatively and postoperatively.

POSTOPERATIVE CARE

It does not appear that prolonged use of antimicrobial agents for weeks or months while a stent is in position has any significant benefit in reducing the occurrence of granulation tissue. The only advantage of long-term antibiotics from a patient's perspective is that they frequently will reduce the occasional annoying odor associated with long-term stenting. Therefore, postoperative antimicrobial agents are used as needed when appropriate indications exist.

Postoperatively, the patients are observed in the recovery room for the first 12 to 24 hours and then are transferred to the intensive care unit. During their recovery room stay, the patients generally are not allowed to eat or drink. By the first or second day after surgery, the patients are started on an oral diet. The amount of dysphagia and aspiration present in the immediate postoperative period frequently is related to whether or not a posterior cricoid split has been done during the procedure and whether or not any supraglottic reconstruction has been done that would result in significant supraglottic edema. The major determinant of the degree of dysphagia and aspiration appears to be the presence or absence of a stent; the individuals with a stent seem to have more dysphagia postoperatively. Since at least a mild amount of dysphagia seems to be a universal problem after laryngotracheal reconstruction, all patients are initially started on a diet of foods with the consistency of applesauce or mashed potatoes. Fluids are given by mouth as tolerated. By the third or fourth postoperative day, most patients are taking oral fluids successfully. Sig-

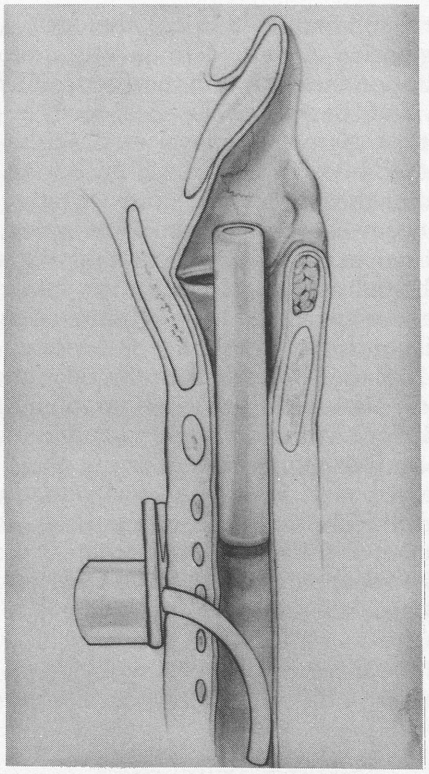

Fig 2. Diagram of position of stent in supraglottic region, where it prevents false vocal cord closure. Gap between stent and tracheotomy tube is potential site for granulation tissue.

nificant dysphagia occasionally will last 7 to 10 days, but not longer.

When the stent is wired to the tracheotomy tube, there is generally very little problem with the suprastomal region in regard to granulation tissue formation or suprastomal collapse. Occasionally in the preoperative evaluation of patients for laryngotracheal reconstruction, a long area of normal trachea is found between the laryngeal defect and the tracheostoma. In this type of patient, a stent frequently is anchored with a large Prolene suture through the cricoid region. The result is a gap between the lower end of the stent and the tracheotomy (Fig 2). The advantages of this type of stenting are significant, in that the tracheotomy tube can be removed in an emergency situation and the patient is safer in the postoperative period. The major disadvantage, however, is that granulation tissue may form at the lower end of the stent if the stent is not removed within a relatively short period of time (ie, 3 weeks) after implantation. If the stent is left longer than 4 weeks, there is a significant danger of circumferential granulation tissue at the lower end of the stent.

Granulation tissue in the larynx and trachea after intubation, tracheotomy, or laryngotracheal reconstruction is frequently a troubling problem and can affect significantly the ease of decannulation. Granulation tissue following laryngotracheal reconstruction is found around the cartilage graft sites generally only when a stent has been used; however, the most frequently involved area is the suprastomal region. Several endoscopic procedures may be required prior to attempts at decannulation. The suprastomal granulations may result from pooled secretions that can be reduced or eliminated with the use of a fenestrated tracheotomy tube in patients under 2 years old following stent removal. The tubes are fenestrated at the time of bronchoscopy so that the position of the fenestration can be checked directly from above. When a fenestrated tube is used, special tracheotomy care instructions need to be given to the parents, particularly regarding suctioning. The parents are instructed to pull the tube out of the neck on a daily basis until the fenestration is seen in the suprastomal region and then reinsert the tube. This can be done without loosening the tracheotomy tapes and helps prevent crusting in the trachea.

When significant amounts of granulation tissue are found in the glottic, subglottic, or tracheal regions, the use of topical steroids is often helpful. Generally, significant granulation tissue is found only if a stent has been used. Decadron is given by aerosal technique in a hospitalized patient or, in a patient old enough to cooperate, by mouth with a Vanceril inhaler. The response to these topical medications is frequently dramatic. The major disadvantage is the well-known potential for adrenocortical suppression, which may require gradual tapering of the doses at the end of the treatment period.

Suprastomal collapse in the postoperative laryngotracheal reconstruction patient is less likely to occur when the stent is wired to the tracheotomy tube, thereby eliminating the gap between the stent and the stoma. When this problem is found, however, it is frequently related to a long tracheotomy tract that is epithelialized. When the patient is otherwise ready for decannulation, the tract can be excised completely and the anterior tracheal wall or soft tissue closed externally.[13] The patient then is left overnight in intensive care with a nasotracheal tube prior to extubation. Occasionally, significant weakness in the anterior tracheal wall may require insertion of another cartilage graft in the region.

Laryngeal dilations are used only sparingly as a treatment for subglottic or tracheal stenosis following laryngotracheal reconstruction. In a tight, thick stenosis, these multiple procedures probably cause more damage to the region than benefit. A thin shelf or web occasionally is present below the glottis and can be dilated effectively with one or two procedures without causing significant trauma to the framework of the airway.

Because of the potential for disaster when a patient is decannulated inappropriately, evaluation of the entire airway from the nose to the carina is a

necessity. Microscopic laryngoscopy and bronchoscopy always are done prior to attempts at decannulation. In addition, the airway assessment also should include an evaluation of true vocal cord motion. The tracheotomy tube is plugged initially in an intensive care unit setting with pulse oximeter monitoring whenever the patient is asleep or in bed for any reason. If the patient tolerates plugging of the tracheotomy tube for two nights, then the tube is removed. The decannulation always is done in an intensive care unit environment and never is done on a weekend when unit staffing problems could occur.[14] Occasionally, despite thorough evaluation of the patient's airway, the plugging of the tracheostomy tube is tolerated poorly. In some patients, there is flaccidity of the tracheal wall that can be exacerbated by hypertrophic tonsils and adenoids, thus causing airway obstruction. In these situations, a tonsillectomy and adenoidectomy may be needed to facilitate successful decannulation.

DISCUSSION

The 42 patients reviewed required a total of 138 procedures following primary laryngotracheal reconstruction. Included are the endoscopies required to remove laryngeal stents and endoscopic evaluations for decannulation. Laryngoscopies and bronchoscopies accounted for 125 of these 138. This yields an average of three endoscopic procedures per patient following the primary reconstruction. Tracheal or laryngeal granulation tissue was the operative indication for the majority of these endoscopies. Removal of stents and evaluation of the larynx and trachea just prior to decannulation accounted for most of the remaining endoscopies.

Four of the 42 patients required open revision of the laryngotracheal reconstruction. Three of the 42 patients needed adenoidectomy, with or without tonsillectomy, after which decannulation was accomplished. One patient developed anterior glottic webbing, which was treated with an umbrella keel, and the patient was decannulated successfully. Three patients required laryngeal dilations; one, repair of a chest wound; and one, scar revision.

Thirty-four of the 42 patients were decannulated successfully. Three patients still have long-term stents that were placed at the original operation for severe laryngotracheal disease. These stents will be removed in the next few months. The remaining five patients still are requiring additional endoscopic procedures to prepare the airway better for decannulation. Because of this, the average number of endoscopic procedures per patient eventually will be slightly higher than three.

SUMMARY

The purpose of this paper is to focus on the preoperative, intraoperative, and postoperative care that is required for successful laryngotracheal reconstruction regardless of the primary surgical reconstructive procedure used. Caution should be exercised not to interpret this study as a report regarding the rate of successful decannulation following laryngotracheal reconstruction, as the course of therapy in some of these patients is not yet complete. Rather, study of this group of patients serves to illustrate that the treatment plan of these diseases requires intensive, diligent, and at times patient and prolonged care before success is achieved.

REFERENCES

1. Cotton RT, Evans JNG. Laryngotracheal reconstruction in children. Five-year follow-up. Ann Otol Rhinol Laryngol 1981;90:516-20.

2. Strong MS, Healy GB, Vaughan CW, Fried MP, Shapshay S. Endoscopic management of laryngotracheal stenosis. Otolaryngol Clin North Am 1979;12:797-805.

3. Eliachar I, Marovich A, Har Shai Y. Rotary door flap in laryngotracheal reconstruction. Arch Otolaryngol 1984;110:585-90.

4. Alonso WA, Druck NS, Ogura JH. Clinical experiences in hyoid arch transposition. Laryngoscope 1976;86:617-24.

5. Montgomery WW. The surgical management of supraglottic and subglottic stenosis. Ann Otol Rhinol Laryngol 1968; 77:534-46.

6. Cotton RT, Seid AB. Management of the extubation problem in the premature child. Anterior cricoid split as an alternative to tracheotomy. Ann Otol Rhinol Laryngol 1980;89: 508-11.

7. Busby GP, Mullen JL, Matthews DC, Hobbs CL, Rosato EF. Prognostic nutritional index in gastrointestinal surgery. Am J Surg 1980;139:160-7.

8. Hooley R, Levine H, Flores TC, Wheeler T, Steiger E. Predicting postoperative head and neck complications using nutritional assessment. Arch Otolaryngol 1983;109:83-5.

9. Menon AP, Schefft GL, Thach BT. Apnea associated with regurgitation in infants. J Pediatr 1985;106:625-9.

10. Myer CM, Cotton RT. Laryngotracheal stenosis in spondyloepiphyseal dysplasia. Laryngoscope 1985;95:3-5.

11. Johnson JT, Myers EN, Thearle PB, Sigler BA, Schramm VL Jr. Antimicrobial prophylaxis for contaminated head and neck surgery. Laryngoscope 1984;94:46-51.

12. Zalzal GH, Cotton RT. A new way of carving cartilage grafts to avoid prolapse into the tracheal lumen when used in subglottic reconstruction. Laryngoscope 1986;96:1039.

13. Friedberg J. Tracheotomy revision to facilitate extubation and correction of aphonia in tracheotomized infants. Presented at the meeting of the Society of Ear, Nose, and Throat Advances in Children, Inc (SENTAC), Philadelphia, Dec 4-7, 1986.

14. Willis R, Myer C, Miller R, Cotton RT. Tracheotomy decannulation in the pediatric patient. Laryngoscope (in press).

CORRELATION OF TUMOR VOLUME WITH LOCAL CONTROL IN LARYNGEAL CARCINOMA TREATED BY RADIOTHERAPY

RALPH W. GILBERT, MD
LINKOPING, SWEDEN

DEREK BIRT, MB
TORONTO, CANADA

HARRY SHULMAN, MD
TORONTO, CANADA

JEREMY FREEMAN, MD
TORONTO, CANADA

DEREK JENKIN, MB
TORONTO, CANADA

ROBERT MACKENZIE, MD
TORONTO, CANADA

CHARLES SMITH, MD
TORONTO, CANADA

An analysis of 37 patients with laryngeal carcinoma (T2 or greater) treated with radical radiotherapy, with surgery reserved for failure, was performed to determine if tumor volume, alone or in association with other prognostic factors, accurately predicted the probability of local control. Patient records were reviewed retrospectively and the following data extracted: age, sex, laryngeal region and number of sites involved by tumor, T and N categories, and success or failure of radiotherapy. Tumor volume for each patient was calculated from pretreatment computed tomograms by summing the products of the cross-sectional tumor area on each CT cut and the interval in millimeters between sequential CT cuts. The mean tumor volume for patients failing radiotherapy was 21.8 cm^3, and the mean volume for patients primarily controlled by radiotherapy was 8.86 cm^3. Tumor volume significantly predicted disease-free interval ($p = .045$) and outcome with radiotherapy ($p = .02$). The study suggests that tumor volume is a significant factor in determining the outcome of primary radiotherapy in advanced laryngeal carcinoma.

KEY WORDS — laryngeal carcinoma, radiotherapy, tumor volume.

INTRODUCTION

It is well established that radiotherapy with surgery held in reserve for failure is efficacious treatment for early laryngeal carcinoma.[1,2] Furthermore, it is widely held that even extensive tumors are handled well by this treatment, provided the vocal cord remains mobile. Controversy, however, persists over the appropriate management of patients with a fixed vocal cord or tumor extension outside the larynx.

Proponents of radiotherapy with surgery held in reserve for failure contend that the survival of patients treated in this way for advanced disease is not significantly different from survival in those treated with primary surgery, and that there is the added benefit of sparing the larynx in those patients treated by irradiation alone.[1,3,4] Proponents of primary radical surgery contend that it affords a better opportunity for survival and better rehabilitation of voice and deglutition than does the salvage of patients who experience radiation failure.[5]

There is little doubt that patients who are treated successfully with radiation alone have a significantly better quality of life than those who undergo primary laryngectomy; however, the patient who fails radiation has borne the burden of a prolonged and apparently unnecessary treatment. In addition, the patient who fails radiation must face the increase in morbidity inherent in surgery following radiation therapy.

The ideal approach to treatment of advanced laryngeal cancers would be to determine those patient and tumor factors that could predict a given patient's likelihood of primary control with radiation and subsequently to direct the patient to the most appropriate therapy.

Recently, a number of authors have published retrospective analyses evaluating a variety of prognostic factors for the success of radiation in laryngeal carcinoma. Important patient features appear to be sex,[2,6] age,[7] and pretreatment hemoglobin.[6] Important tumor features appear to be tumor size,[6] nodal status,[8,9] morphologic grading,[10,11] ploidy,[12-14] and tumor thickness.[15]

Until recently, the only prognostic factor regularly considered was the TNM stage. The T category in laryngeal carcinoma takes into account anatomic features (eg, extension to other regions, cord fixation) that can predict relatively accurately the likelihood of deep extension and tumor size, and it is clear that T category in all laryngeal regions has a relationship with the likelihood of primary control by irradiation. In spite of this information, T staging has limitations, and more accurate methods of measuring the extent of laryngeal tumors would be useful.

From the Departments of Otolaryngology (Birt) and Radiology (Shulman), Sunnybrook Medical Centre, Toronto, and the Departments of Otolaryngology (Gilbert, Freeman) and Oncology (Jenkin, MacKenzie), The Toronto-Bayview Regional Cancer Centre, University of Toronto; and the Department of Pathology, The Hospital for Sick Children (Smith), Toronto. Dr Gilbert is temporarily at the Department of Otolaryngology, University Hospital, Linkoping, Sweden.

Presented at the meeting of the American Laryngological Association, Denver, April 25-26, 1987.

REPRINTS — B. D. Birt, MB, Sunnybrook Medical Centre, 2075 Bayview Ave. Toronto, Ontario M4N 3M5, Canada.

TABLE 1. DISTRIBUTION OF PATIENTS BY REGION AND T AND N CATEGORIES

	Glottic Tumors			*Supraglottic Tumors*		
	T2	*T3*	*T4*	*T2*	*T3*	*T4*
N0	7	6	2	2	3	8
N1	0	0	0	1	0	5
N2	0	0	0	0	0	1
N3	0	0	0	0	1	1

The purpose of this paper is to determine if the volume of a given tumor as measured by computed tomography, either as a single variable or associated with other tumor and patient variables, can predict control by irradiation.

METHODS

The Toronto-Bayview Regional Cancer Centre of the Ontario Cancer Treatment and Research Foundation is located at the Sunnybrook Medical Centre in Toronto. The center was established in 1981, and between its inception and December 1985, 169 new patients with all stages of laryngeal cancer have been seen. The treatment for all patients with laryngeal carcinoma has been radical radiotherapy, with surgery reserved for radiotherapy failures.

For the purpose of this study, 62 patients were identified with laryngeal carcinoma graded T2 or greater. All patients were staged clinically according to the UICC classification (1978)[16]; radiologic investigations included either CT scan or laryngeal tomography. Patients were excluded from the analysis if the intent of radiotherapy was palliative (two patients), if the patient failed to complete the intended course of treatment (one patient), or if the patient had not undergone a pretreatment enhanced CT scan (22 patients). After these exclusions, 37 patients remained and provided the material for this study.

The patients' charts were reviewed retrospectively, and information retrieved from each chart included age, sex, tumor region (supraglottic, glottic, subglottic), tumor sites (eg, vocal cord, anterior commissure, epiglottis), radiation treatment (dose, fractionation, method of delivery), outcome (failure defined as failure at the primary site after irradiation), duration of survival, and surgical treatment. Follow-up was complete on all patients and ranged from 15 months to 4 years 6 months or to death (mean, 26.9 months).

Radiotherapy at the center has been relatively uniform, with some changes introduced in the past 3 years. Twenty patients received 50 Gy in 20 fractions, five patients received 64 Gy in 32 fractions, three patients received 66 Gy in 33 fractions, and five patients received 70 Gy in 35 fractions. All were treated with a ^{60}Co unit. Mean field size was 100 cm^2, with a range of 39 to 200 cm^2 for the parallel pair fields used to irradiate the primary tumor. Twenty-two patients had radiation delivered by a parallel pair technique, and 15 by parallel pair and anterior split techniques.

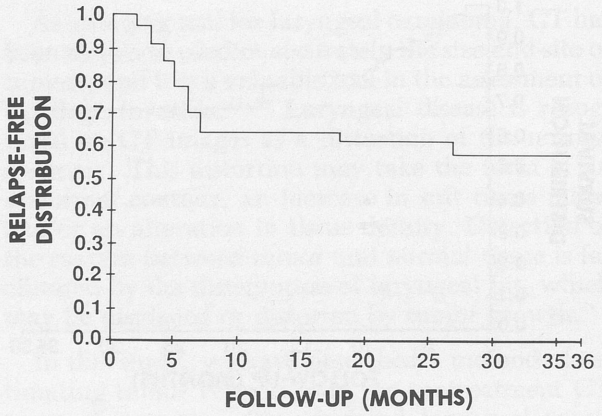

Fig 1. Actuarial local relapse-free rate for 37 patients studied. The 24- and 36-month relapse-free rates were 61% and 58%, respectively.

The CT scans for each patient were evaluated blindly by one of the authors (H.S.), an experienced laryngeal radiologist. The tumor on each cut was outlined with a wax pencil, with the sections being marked at the bulkiest cut, proceeding in a cephalad and then caudad direction. The tumor areas from serial CT scans were determined using an IBAS II interactive image analyzer (Carl Zeiss, Oberkochen, Federal Republic of Germany). Each scan was redigitized from the hard copy image (512 x 512 pixel array) and scaled, and the tumor was reoutlined according to the wax pencil markings. The area was determined by algorithms within the IBAS array processor. Two area measurements were made for each cut, and the mean was determined to be the cross-sectional area of the tumor.

Tumor volume was calculated as the sum of the volumes of the cuts in which tumor was identified. The volume of each cut was the measured tumor area times the section thickness. The following assumptions were made in making the volume calculations: 1) that cross-sectional area of the tumor was constant throughout the vertical height of the section and 2) that the thickness of each section was equal to the distance in millimeters from the cut being evaluated to the next caudad cut.

Statistical analyses included actuarial analysis of local relapse-free rate and survival rate. The role of sex, age, T and N categories, laryngeal region, number of sites, and volume in predicting relapse-free status was assessed using Cox's and logistic regression analyses with backward stepwise elimination of the prognostic factors.

RESULTS

Patient and Site Data. In the group of 37 patients selected for this study, 33 were men and four were women, a ratio of 8.2:1. The ages of patients ranged from 37 to 82 years, with a mean of 63

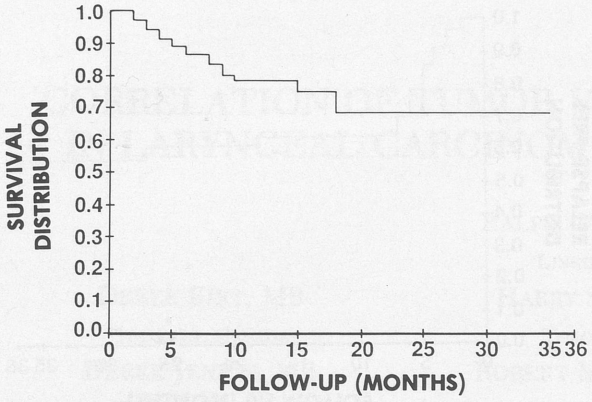

Fig 2. Actuarial survival for 37 patients studied. The 24- and 36-month survival rates were 68% and 61%, respectively.

years. Fifteen patients had tumors staged as glottic, and all were clinically NO. Twenty-two patients had tumors staged as supraglottic, with nine of these patients having clinically evident neck disease at presentation (Table 1).

Radiation and Survival Data. The overall actuarial local relapse-free rate for the patients studied appears in Fig 1, with 58% of the patients relapse free and maintaining an intact and functioning larynx at 36 months. The actuarial survival is illustrated in Fig 2, with a 36-month survival of 61%.

Volume Data. The crude results of the volume determinations are illustrated in Fig 3, which is a linear distribution of the volumes for patients controlled primarily by irradiation and for those who failed radiation. The mean volume for patients who failed radiation was 21.8 cm^3, with a median of 10.8 cm^3 and standard deviation of 25.9 cm^3. For patients who were cured by radiotherapy, the mean volume was 8.86 cm^3, with a median of 6.81 cm^3 and standard deviation of 8.0 cm^3.

Volumes for individual patients were evaluated in relation to their clinical T category, and it is clear

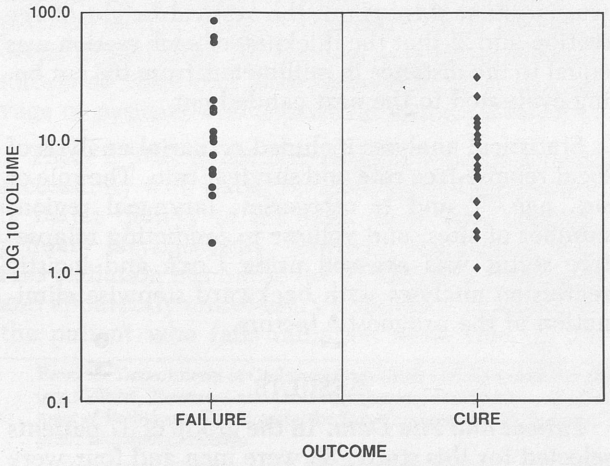

Fig 3. Crude results for volume determination in cm^3, differentiated by success or failure of radiation (log10 scale).

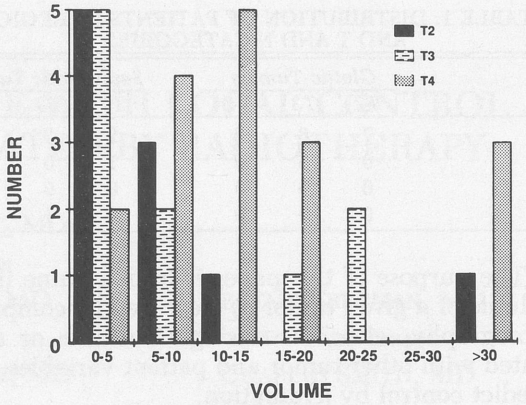

Fig 4. Frequency histogram of volume cm^3 by T stage.

that in general, T category correlated with tumor volume except in a few instances. Several small tumors were staged as T4, and one large tumor was staged as T2 (Fig 4).

A Cox's regression analysis using a backward elimination of the prognostic variables sex, age, T and N categories, laryngeal region (supraglottic or glottic), number of sites (eg, vocal cord, anterior commissure), and volume resulted in a final model ($\chi^2 = 4.61$, $p = .03$), with tumor volume emerging as the strongest prognostic factor. Disease-free time (survival without recurrence) was used as the dependent variable, and outcome (success or failure) was used as the censoring variable. Table 2 illustrates the ranking of the variables in the initial step of the analysis, based on the hypothesis that all seven variables are predictive of disease-free time (p values are indicative of ranking, but not significance). Analysis incorporating all seven variables did not achieve a level of significance.

A logistic regression using the backward elimination procedure on the prognostic variables predicting relapses (previously outlined) also yielded a significant model ($\chi^2 = 4.97$, $p = .03$) containing only tumor volume as a prognostic factor.

A plot of the predicted probability of radiation failure versus tumor volume with 95% confidence limits was produced from the output of the logistic regression model containing tumor volume (Fig 5). A near-linear relationship exists between volume and probability of failure between 3.0 and 30 cm^3.

TABLE 2. RANKING OF PROGNOSTIC VARIABLES IN ORDER OF SIGNIFICANCE

Prognostic Factor	*Probability Value*
Volume	.0018
N category	.0213
Sex	.0436
Age	.1714
Laryngeal region	.1848
Number of sites	.5188
T category	.9207

Cox's regression analysis, general hazards procedure. Probability values do not indicate statistical significance.

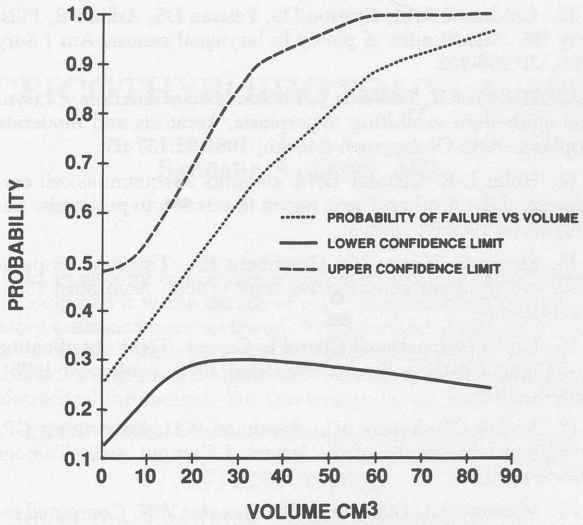

Fig 5. Predicted probability plot of likelihood of radiation failure by volume cm^3.

Special note needs to be made of the wide confidence limits for volumes greater than 20 cm^3. The wide confidence limits are probably due to the small number of observations and the considerable overlap in the tumor volumes for the two outcome groups (Fig 3).

DISCUSSION

Ideally, patients with laryngeal carcinoma would be treated by a protocol that optimized their chance of maintenance of voice, yet selected those patients with a high probability of radiation failure for primary surgical therapy. Such an approach would reduce the morbidity of an inevitable surgical procedure and might increase the chance of survival. In order to attain this goal, prognostic factors that can predict a given patient's likelihood of radiation failure need to be established. The literature to date has identified a number of patient and tumor variables other than TNM stage that seem predictive, and these were discussed earlier. Overgaard et al[6] have demonstrated that tumor size is a significant predictor of a given patient's potential for cure by radiation therapy. This finding is not surprising, as it has been demonstrated for many tumor sites, is part of the current staging systems for upper aerodigestive tract malignancies, and is consistent with established radiobiologic principles.

The larynx poses a problem for the clinical evaluation of tumor size or volume, as it is not directly accessible, and measurements made during endoscopy are difficult because of the intricate and undulating anatomy of the larynx.

As a staging tool for laryngeal carcinoma, CT has been shown to predict accurately the size and site of tumors, and it is a valuable tool in the assessment of cartilage invasion.[17-20] Laryngeal disease is recognized on CT images as a distortion of the normal anatomy. This distortion may take the form of an abnormal contour, an increase in soft tissue mass, and/or an alteration in tissue density. Detection of the margin between tumor and normal tissue is facilitated by the distribution of laryngeal fat, which may be displaced or distorted by tumor growth.

In this study, we have described a method of estimating tumor volume from the pretreatment CT scans of patients with advanced laryngeal carcinoma. The tumor volumes, both alone and in combination with other patient and tumor variables, have been correlated with the patients' responses to radiotherapy. Tumor volume was shown to be a significant prognostic factor in predicting the outcome of radiation therapy, and was of greater significance than age, sex, T and N categories, tumor region, or the number of laryngeal sites involved.

Several comments need to be made regarding the interpretation of these data. First, the interpretation of the size of a tumor on a CT scan involves subjective evaluation, and it requires a radiologist with a great deal of experience in the interpretation of laryngeal radiographs. In addition, there is likely to be a certain amount of interobserver variability, and in this paper we have not evaluated how great this variability may be.

Second, this review was retrospective and the number of patients was small, making interpretation of the statistical analysis difficult and subject to uncertainty.

This investigation was intended as a pilot study to ascertain the value of CT scan–derived tumor volumes as a predictive factor for tumor control by irradiation. The results suggest that tumor volume may be an important factor, and a prospective study with a larger number of patients is under consideration.

Finally, it is evident that any approach to the selection of patients for different treatment modalities will require the consideration of multiple patient and tumor prognostic factors, each with a varying influence on outcome. It is apparent that tumor volume is a significant predictor of a given patient's likelihood of response to radiotherapy, and it likely will be incorporated into a predictive model.

ACKNOWLEDGMENTS — The authors thank the personnel of the Department of Biostatistics at Sunnybrook Medical Centre, and in particular Dr John Szalai and Marko Katic. In addition, the authors thank the personnel of the Health Records Department at the Toronto Bayview Regional Cancer Centre for their assistance in providing the patient charts.

REFERENCES

1. Harwood AR. Cancer of the larynx. J Otolaryngol 1982; 11(suppl 11):3-21.

2. Wang CC. Factors influencing the success of radiation therapy for T2 and T3 glottic carcinomas. Am J Clin Oncol 1986;

9:517-20.

3. Harwood AR, Bryce DP, Rider WD. Management of T3 glottic cancer. Arch Otolaryngol 1980;106:697-9.

4. Harwood AR, Hawkins NV, Rider WD, Bryce DP. Management of advanced glottic cancer: a ten year review of the Toronto experience. Int J Radiat Oncol Biol Phys 1979;5:899-904.

5. DeSanto LW. T3 glottic cancer: options and consequences of the options. Laryngoscope 1984;94:1311-5.

6. Overgaard J, Hansen HS, Jørgenson K, Hansen HM. Primary radiotherapy of the larynx and pharynx carcinoma — an analysis of some factors influencing local control and survival. Int J Radiat Oncol Biol Phys 1986;12:515-21.

7. Harwood AR, DeBoer G, Kazim F. Prognostic factors in T3 glottic cancer. Cancer 1981;47:367-72.

8. Pera E, Moreno A, Galindo L. Prognostic factors in laryngeal carcinoma. Cancer 1986;58:928-34.

9. Schuller D, McGuirt W, McCabe B, Young D. The prognostic significance of metastatic cervical lymph nodes. Laryngoscope 1980;90:557-70.

10. Jacobsson P, Killander D, Moberger G, Mårtensson B. Histologic classification and grading of malignancy in carcinoma of the larynx. Acta Radiol Ther Phys Biol 1973;12:1-8.

11. Holm L-E, Lundquist P-G, Silfverswärd C, Sobin A. Histological grading of malignancy in squamous cell carcinoma of the oral tongue. Acta Otolaryngol (Stockh) 1982;94:185-92.

12. Goldsmith MM, Cresson DS, Postma DS, Askin FB, Pillsbury HC. Significance of ploidy in laryngeal cancer. Am J Surg 1986;152:396-402.

13. Hellquist H, Olofsson J. Photometric evaluation of laryngeal epithelium exhibiting hyperplasia, keratosis and moderate dysplasia. Acta Otolaryngol (Stockh) 1981;92:157-65.

14. Holm L-E. Cellular DNA amounts of squamous cell carcinomas of the head and neck region in relation to prognosis. Laryngoscope 1982;92:1064-9.

15. Moore C, Kuhns JG, Greenberg RA. Thickness as prognostic aid in upper aerodigestive tract cancer. Arch Surg 1986; 121:1410-4.

16. Union International Contre le Cancer. TNM classification of malignant tumors (larynx, classified 1972, confirmed 1978). Geneva, 1978.

17. Archer CR, Yeager VL, Friedman WH, Katsantonis GP. Computed tomography of the larynx. J Comput Assist Tomogr 1978;2:404-11.

18. Mancuso AA, Calcaterra TC, Hanafee WN. Computed tomography of the larynx. Radiol Clin North Am 1978;16:195-208.

19. Gregor RT, Lloyd GAS, Michaels L. Computed tomography of the larynx: a clinical and pathologic study. Head Neck Surg 1981;3:284-96.

20. Sokjer H, Olofsson J. Computed tomography in carcinoma of the larynx and pyriform sinus. Clin Otolaryngol 1981;6:335-43.

CRICOTHYROIDOTOMY: A DECADE OF EXPERIENCE IN DENVER

BARBARA A. ESSES, MD BRUCE W. JAFEK, MD

DENVER, COLORADO

In an attempt to evaluate cricothyroidotomy as described by Brantigan and Grow in 1976, the authors have reviewed the literature and compared it to the decade of experience following Brantigan and Grow's report. The records of over 1,000 patients requiring ventilatory assistance were reviewed. A comparison of this experience with Brantigan and Grow's original series and subsequent reports was used to establish the criteria and technique for cricothyroidotomy. It appears that while cricothyroidotomy has specific advantages, it also has disadvantages and a higher incidence of airway stenosis than either of the procedures it was designed to replace (low tracheotomy or endotracheal intubation). For this reason, its use has been severely restricted in Colorado, where it was popularized.

KEY WORDS — airway obstruction, laryngeal cartilages, larynx, tracheotomy.

INTRODUCTION

Since the favorable report of Brantigan and Grow[1] on cricothyroidotomy in 1976, controversy over the role of this procedure has pervaded the literature. Numerous articles have appeared in support and equally numerous ones in condemnation of the technique. In an attempt to resolve the question "cricothyroidotomy: if, when, and how," we have reviewed the literature and compared it to the decade of experience following Brantigan and Grow's report.

We then turned our attention to what is being done in Denver, where Brantigan popularized the technique. We reviewed the records of over 1,000 patients requiring airway management and compared them with Brantigan and Grow's original series and subsequent reports in order to establish the criteria and technique for cricothyroidotomy.

LITERATURE REVIEW

The practice of performing cricothyroidotomy has become a subject of great controversy. The matter apparently had been laid to rest by Chevalier Jackson's landmark paper on high tracheotomies in 1921.[2] A high tracheotomy is defined as a tracheotomy through the larynx or first tracheal ring. Currently, the most commonly performed high tracheotomy is the cricothyroidotomy, ie, opening the airway at the cricothyroid membrane. Identification of landmarks is essential for proper placement of the cricothyroidotomy. One should first palpate the thyroid notch — the midline prominence of the thyroid cartilage. Approximately 2 to 3 cm inferior to this, the cricothyroid membrane is palpable as a space between the thyroid and cricoid cartilages. On the average, this membrane is 10 mm in height. It should be noted that the vocal folds lie 1.5 to 2 cm above the cricothyroid membrane (Fig 1A). Most authors advocate a transverse skin incision over the cricothyroid membrane, while others claim a vertical incision gives better exposure and less bleeding. In nonemergency situations, a transverse incision is preferred for a more cosmetically pleasing result. Once the cricothyroid membrane is reached, a horizontal incision is made in the membrane itself, maintaining a caudal direction on the blade to protect the vocal cords (Fig 1B). At this point, the tracheal spreaders or a hook can be used to open the airway. The tracheotomy tube is inserted; its outside diameter should be no greater than 10 mm to avoid excessive laryngeal trauma (Fig 1C). The tube is secured with sutures or ties.

In his paper, Jackson described 200 patients, many of them children, referred to him for chronic laryngeal stenosis. Of these 200, he felt that 158 cases were due to the practice of high tracheotomies and improper tracheostomy care. Jackson reasoned that the incidence of stenosis was high in the high tracheotomies because of several factors:

1. The larynx is the narrowest portion of the laryngotracheal airway.
2. Subglottic tissues in children are intolerant of contact.
3. Division of the cricothyroid membrane and cricoid cartilage results in loss of the only complete ringlike support of the airway.

He concluded that "there should be taught only one tracheotomy and that should be 'low'."[2,(p397)] He also stated that if high tracheotomy has been performed, it should be converted rapidly to the standard low tracheotomy.

In 1976, Brantigan and Grow[1] questioned what had by that time become professional dogma. In a landmark paper of their own, they reviewed 655 cases of cricothyroidotomy and discovered a complication rate of 6.1% (40 patients). These complications included bleeding (intraoperative, immedi-

From the Department of Otolaryngology/Head and Neck Surgery, University of Colorado School of Medicine, Denver.

Presented at the meeting of the American Laryngological Association, Denver, April 25-26, 1987.

REPRINTS — Bruce W. Jafek, MD, Dept of Otolaryngology/Head and Neck Surgery, University of Colorado School of Medicine, 4200 E Ninth Ave, Box B210, Denver, CO 80262.

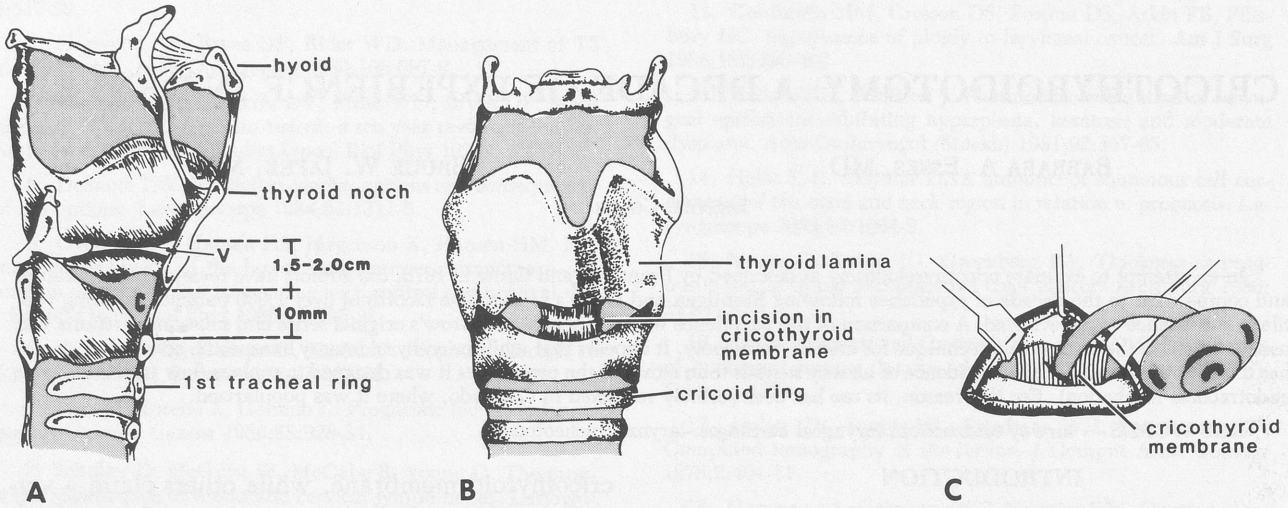

Fig 1. Schematic drawings of larynx. A) Sagittal section of larynx and trachea. Note distance between vocal fold (V) and cricothyroid membrane (C). B) Placement of incision on cricothyroid membrane. Note that incision is horizontally placed. C) Cricothyroidotomy tube placement.

ately postoperative, and delayed), abscess, cellulitis, subcutaneous emphysema, voice changes, globus sensation, persistent stoma, and laryngeal obstruction. Eight patients suffered from airway obstruction in their series. Five of these required tracheal resection; two patients had subglottic granulation tissue that had to be removed endoscopically. Brantigan and Grow reported no cases of chronic subglottic stenosis in their initial report. They concluded that the cricothyroidotomy was not significantly associated with subglottic stenosis and that it held such advantages as being faster, being performable by nonsurgeons, having a low complication rate, and being isolated from the median sternotomy. These findings, which differed from Jackson's, were felt to be attributable to the fact that the tracheotomies were no longer being performed routinely for acute infectious and inflammatory conditions as in Jackson's time, but rather for respiratory failure, control of secretions, and mechanical ventilation.

Over the past decade, the literature has seen a renewed interest in cricothyroidotomy. Several clinical studies have supported the findings of Brantigan and Grow. Boyd et al[3] studied 147 patients undergoing cricothyroidotomies. Of their original 147 patients, there were 105 long-term survivors, ten of whom developed complications. These included stomal bleeding, hoarseness, and improper tube placement. There were two cases of subglottic and glottic stenosis in patients who were intubated endotracheally more than 7 days prior to cricothyroidotomy. Boyd et al concluded that patients who have had endotracheal tubes in place for more than 7 days should not undergo cricothyroidotomy.

Sise et al[4] carried out a prospective study on 76 patients undergoing cricothyroidotomy. Five of their patients developed subglottic stenosis. There was one death due to loss of airway during the procedure, and one case of subglottic granulation tissue, which was treated successfully with oral steroids. Of the 39 patients who died, all underwent autopsies; 28% were found to have pathologic changes, ulceration, or hematoma at the cuff site. Sise et al found no significant difference in morbidity or mortality with prolonged prior intubation or steroid or antibiotic usage. They advocated the use of cricothyroidotomy except in children or adolescents, in whom rapid conversion to tracheotomy is advised. They noted, however, that "subglottic stenosis is the most frequently reported major complication after cricothyroidotomy, but is rare after tracheostomy."[4(p17)]

Smaller clinical series, such as those reported by Griesz and coworkers,[5] McDowell,[6] and O'Connor et al,[7] also found similar favorable results with respect to subglottic stenosis. Griesz et al[5] provided additional information with autopsy studies: in 20 patients, 11 displayed pathologic changes. They observed superficial ulcerations of the trachea, ulcers on the false and true vocal cords, and erosion of laryngeal cartilages. McDowell's[6] series of 43 patients reported no cases of subglottic stenosis, but there was one death attributable to a plugged cricothyroidotomy tube. The series of O'Connor et al[7] of 49 patients included three patients who developed tracheal stenosis, two of whom required tracheal resection. They noted, however, that these lesions all were found at the level of the original endotracheal balloon.

Morain,[8] reviewing a series of 16 cases, described additional advantages of cricothyroidotomy, including isolation of the airway entrance (cricothyroidotomy) from the operative site (radical neck dissection), improved cosmesis of the resultant scar, enhanced safety with suspected cervical spine injury, and ease in patients with cervical kyphosis. He noted no examples of subglottic stenosis and con-

cluded, "we see a diminishing role for the 'standard' tracheostomy."[8(p428)]

In 1982, Brantigan and Grow[9] reviewed several cases of subglottic stenosis found in their series and others. They identified three predisposing factors in this group: 1) prolonged endotracheal intubation, 2) paralyzed vocal cords, and 3) laryngeal trauma. Those patients suffering from subglottic granulation tissue were found to have the same predisposing factors, although in two cases reviewed there were no apparent predisposing factors. It was felt that ulcerations caused by endotracheal tubes on the vocal cords and subglottic area, as demonstrated by others, constituted contaminated wounds due to colonization of the tubes. They recommended laryngoscopic examinations prior to cricothyroidotomy in chronically intubated patients.

There have likewise been reports in the past decade that do not view cricothyroidotomy in the same favorable light. Kennedy[10] reported two cases, one of true vocal cord fixation and one of total glottic and subglottic stenosis, both following cricothyroidotomy. He reasoned that since the average width of the cricothyroid membrane is 9 mm and the outside diameter of most Shiley tubes is 10 mm, this could lead to necrosis secondary to pressure and thus scarring. Kennedy has cautioned against a procedure that causes damage to the larynx and risks such a devastating, although infrequent, complication as subglottic stenosis.

In a report by Weymuller and Cummings,[11] four cases of 19 were found to have subglottic granulation. These cases all were handled with endoscopic removal of the granulation tissue and steroid injections. All cases occurred in patients who previously had been endotracheally intubated 7 days or longer. The study was, in fact, discontinued because of the alarmingly high rate of airway obstruction secondary to subglottic granulation. Weymuller and Cummings concluded in accordance with the previous findings of Boyd,

> The presence of an endotracheal tube must be considered a source of acute laryngeal inflammation and mucosal ulceration, and therefore a predisposing factor to complications from cricothyroidotomy.[11(p438)]

Gleeson[12] investigated one complication of cricothyroidotomy that had been somewhat minimized — voice changes. Of eight patients studied, six had subjective voice changes. These changes included loss of volume, deeper pitch, and extreme huskiness in one woman. Three patients were amateur singers who were unable to perform because of limited vocal ranges and a tendency to fall off key, especially on high notes. These subjective complaints were confirmed with objective data. Three patients were found, on indirect laryngoscopy, to have distortion secondary to scarring at the anterior commissure. All of the patients describing a voice change had abnormal laryngographs with pathologic narrowing of the fundamental vocal range and a distribution favoring the lower frequencies. These changes were probably secondary to damage to either the cartilages or the cricothyroid muscle, as postulated by Kennedy[10] and Caparosa and Zavatsky.[13]

Since the original paper of Brantigan and Grow[1] involved primarily nonemergency cricothyroidotomies, we were interested to see the results of McGill et al[14] on 38 emergency cricothyroidotomies. They demonstrated a complication rate of 32%, greater than five times the complication rate originally reported by Brantigan and Grow. These complications included tubes in the thyrohyoid membrane and trachea, execution time greater than 3 minutes, unsuccessful placements, and hemorrhage. Their series also included one long-term complication of a longitudinal fracture of the thyroid cartilage secondary to forceful placement of an oversized tube. This led to a permanent dysphonia in this patient. McGill et al recommended in their summary that a vertical incision be used for adequate visualization of the anatomy, and that a No. 4 Shiley catheter with an 8.5-mm external diameter be used in emergency care.

Finally, animal studies have been performed to demonstrate the pathologic effects, if any, of cricothyroidotomy. Romita et al[15] studied 32 dogs divided into four groups and compared healing with duration of intubation (0 to 7 days), incision of the anterior cricoid cartilage, and excision of a 1-cm segment of anterior cricoid cartilage. In the group with anterior cricoid cartilage excision, there was excessive scarring at the subglottic level. All other groups had complete healing at 6 weeks without stenosis. Koopman et al[16] studied the effects of trauma to laryngeal mucosa (scraping) and the effect of antibiotics. They found no significant differences in dogs treated with antibiotics or in dogs with laryngeal trauma.

In light of the controversy, one must compare cricothyroidotomies with other methods of controlling the airway, namely, tracheotomy and endotracheal intubation. We are fortunate to have at our disposal a study from the Denver area that facilitates comparison. Stauffer et al[17] performed a prospective study of the complications of endotracheal intubation and tracheotomy. They discovered an alarmingly high rate of complications of 62% with endotracheal intubation and 66% with tracheotomy. The most common complications are listed in Table 1.

In the survivors, tomograms of the larynx and trachea were obtained to evaluate tracheal stenosis. They defined stenosis as "a reduction in the transverse air column diameter of the trachea greater than 10% in a distinct short segment of the trachea."[17(p70)] They found these conditions in five of 27 patients (19%) who were endotracheally intu-

TABLE 1. COMPLICATIONS OF TRACHEOTOMY AND ENDOTRACHEAL INTUBATION

	Tracheotomy (% of Pts)	*Endotracheal Intubation (% of Pts)*
Excessive cuff pressure	23	19
Self-extubation		13
Inability to seal airway		19
Stomal infection	36	
Stomal bleeding	36	
Subcutaneous emphysema or pneumomediastinum	13	

From Stauffer et al.[17]

bated. Two of these five had subglottic stenosis. Of the patients with tracheotomies, 11 of 17 (65%) met this criterion. It should be noted that cricothyroidotomies were considered tracheotomies in their study. Of the 17 tracheotomies, two were cricothyroidotomies, and both of these resulted in stenosis, one subglottic. Therefore, the stenosis rate with cricothyroidotomy was 100%, compared to 19% of those endotracheally intubated and 60% (nine of 15) of those with tracheotomies. In the discussion that followed, it was noted that those patients with tracheotomies were intubated for a much longer period of time than those with endotracheal tubes.

MATERIALS AND METHODS

We reviewed the hospital records of 1,069 patients who were classified under the International Classification of Disease as having undergone either permanent or temporary procedures for airway access during the period January 1976 through December 1985. Forty-three of these patients were excluded from the study because they had procedures other than tracheotomy or cricothyroidotomy performed (eg, transtracheal aspiration, tracheal resection, endotracheal intubation). This left a total of 1,026 patient records reviewed in the study. The records studied were drawn from University Hospital, located at the University of Colorado Health Sciences Center (tertiary care/referral center), Denver General Hospital (city hospital/major trauma center), and the Denver Veterans Administration Hospital (tertiary care center). The number of procedures, type and nature of procedure, and patient data are presented in Tables 2 and 3, which are divided according to hospitals because of the diversity of the patient populations and its effect on the statistics.

TABLE 2. PATIENT DATA BY HOSPITAL

	University Hospital	*Denver VA Hospital*	*Denver General Hospital*
No. procedures*	550	190	286
Cricothyroidotomy No. (%)	23 (4)	7 (4)	48 (17)
Average age (yr)	50.4	66.6	46.0
Age range (yr)	7 to 80	45 to 79	12 to 90
Male:female	3:1	All male	2.5:1

*Tracheotomy or cricothyroidotomy.

TABLE 3. MORTALITY FOLLOWING ELECTIVE VERSUS EMERGENCY CRICOTHYROIDOTOMY BY HOSPITAL

	Mortality
Elective	
University Hospital	8 of 10 (80%)
Denver VA Hospital	5 of 7 (71%)
Denver General Hospital	7 of 16 (44%)
Emergency	
University Hospital	4 of 13 (31%)
Denver VA Hospital (none performed)	
Denver General Hospital	8 of 32 (25%)

RESULTS

Of a total 1,026 procedures performed, only 78 were cricothyroidotomies — or 7.6% of all procedures. The remaining cases were all various forms of tracheotomies (inferior flap, open window, etc). Of the 78 cricothyroidotomies, there were 32 deaths, for a mortality rate of 41%. The reported complications that were felt to be attributable to the cricothyroidotomy are listed in Table 4. There were 22 complications in 78 procedures, leading to a complication rate of 28%. Most notable are two cases of subglottic stenosis. This gives an incidence of 2.6% of subglottic stenosis in our series.

The reasons that cricothyroidotomy was performed are presented in Table 5. These included 15 cases in which cricothyroidotomy was performed as an alternate procedure when tracheotomy and endotracheal intubation were deemed inappropriate (eg, anatomic variations, inability to intubate in the operating room).

Three cases of subglottic stenosis following cricothyroidotomy are presented in detail. These patients are presented to illustrate the devastating long-term effects of this complication. Although the third patient also suffered subglottic stenosis secondary to cricothyroidotomy, the cricothyroidotomy was performed at another institution and the patient received treatment for stenosis at University Hospital. Therefore, this case is considered among those that received tracheotomies in the data presented, since that was the procedure performed in our institution.

TABLE 4. COMPLICATIONS OF CRICOTHYROIDOTOMY

Complications	*Number*
Subglottic stenosis	2
Vocal cord paralysis or paresis	3
Pneumothorax	4
Granulation at cuff site	1
Self-extubation	2
Infected stoma	1
Hoarseness	1
Plugging of tube	2
Persistent stoma	1
Difficulty ventilating	2
Pneumomediastinum	1
Subcutaneous emphysema	1
Bleeding	1
Total	22

TABLE 5. REASONS FOR CRICOTHYROIDOTOMY (N = 78)

	No. Patients
Alternative to tracheotomy	8
Alternative to endotracheal intubation	7
Elective airway management	25
Emergency airway management	38

Case 1. A 43-year-old woman was admitted in hepatic coma with a pneumococcal pneumonia. This patient underwent a bedside cricothyroidotomy with a No. 11 Portex tube after 5 days of endotracheal intubation. The patient was extubated 7 days later following improvement of her respiratory status, but had a persistent laryngocutaneous stoma and hoarseness. The patient had a direct laryngoscopic examination at 27 days postextubation, which revealed left true vocal cord paresis and anterior subglottic granulation tissue. Subsequent air laryngograms revealed approximately 3 cm of subglottic stenosis with circumferential narrowing of the airway, the right side being affected more than the left. The patient has since undergone repeated dilatations, steroid injections, insertion of a Montgomery® Safe-T-Tube, and, ultimately, laryngofissure with hyoid interposition. The patient was extubated following the hyoid interposition, but has now developed an esophageal stricture, which still requires dilatation every 6 weeks.

Case 2. A 35-year-old man suffered multiple stab wounds to the abdomen and chest with laceration of the aorta and right adrenal artery. The patient underwent exploratory laparotomy and thoracotomy, from which he recovered fully except for the complication of a left subclavian vein thrombosis. The patient was given heparin for anticoagulation and was discharged on a regimen of Coumadin. Two months after discharge, he presented to the emergency room with bleeding from multiple sites secondary to Coumadin overdose. On the day of admission, the patient developed upper airway obstruction secondary to hematoma formation in the oropharynx and nasopharynx. A cricothyroidotomy was performed in the operating room using local anesthesia and placement of a No. 7 Portex tube. The patient tolerated the procedure well and was extubated on the sixth postoperative day. Over the next 3 months, the patient experienced hoarseness and increasing shortness of breath. He was admitted 3 months after the cricothyroidotomy in respiratory distress. Laryngoscopy revealed a paralyzed left vocal cord and a subglottic stenosis on the left with approximately 30% airway narrowing. The patient underwent tracheotomy and multiple dilatations and steroid injections. When last seen at our facilities 2 years later, the patient was still intubated.

Case 3. A 32-year-old woman was involved in a motor vehicle accident in which she sustained multiple injuries. She presented to another facility at the time of the accident and underwent emergency cricothyroidotomy for airway control. The details regarding length of intubation, tube size, etc, are not available. She presented to our institution 5 months after the accident complaining of hoarseness and difficulty breathing. Examination at that time revealed an anterior web that compromised approximately the anterior half of the glottic chink. She has since undergone tracheotomy, laser excision of the anterior glottic web, and laryngofissure with stent placement (Fig 2). The patient is presently extubated and has continued hoarseness and recurrent anterior laryngeal webbing.

DISCUSSION

Since Brantigan and Grow[1] reported their large series of cricothyroidotomies in 1976, it has not become a routine procedure for elective airway management in the Denver area. This is evidenced by the fact that only 7.6% of all airway procedures were cricothyroidotomies at our multicenter institution. Nor is cricothyroidotomy a benign procedure. A 28% complication rate was observed at our facilities in comparison to Brantigan and Grow's 6.1%. We also experienced a 2.6% incidence of

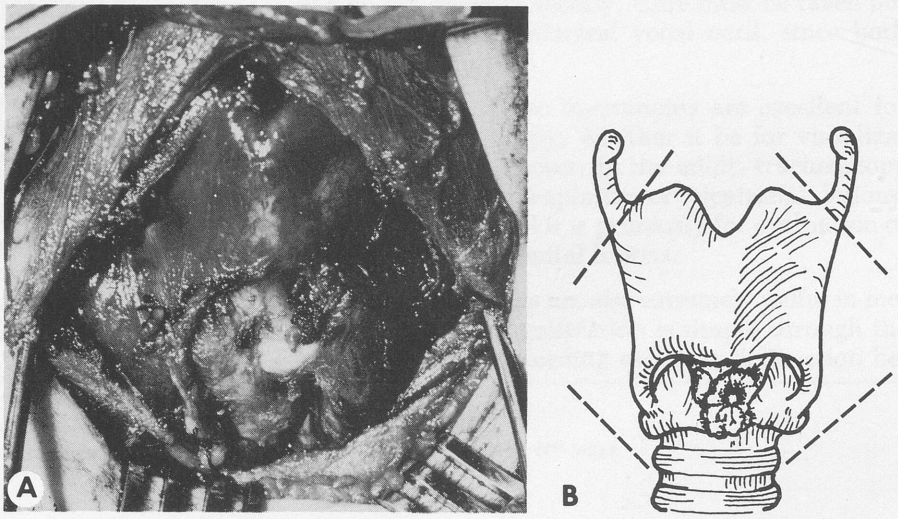

Fig 2. (Case 3) Subglottic stenosis. A) Operative approach. Note extensive damage to anterior cricoid plate and cricothyroid membrane. B) Schematic drawing.

subglottic stenosis: in practical terms, at this rate, almost three patients out of every 100 will suffer chronic airway obstruction and/or a voice disorder following cricothyroidotomy.

An interesting finding is that the mortality rate is higher in elective cases (Table 3). This fact suggests that when cricothyroidotomy is performed for elective airway management, it is used on seriously or terminally ill patients for palliation, rather than long-term therapy.

Based upon our clinical series and literature review, cricothyroidotomy may be applicable in the following situations:

1. In emergency situations (rapid conversion to standard tracheotomy is still advised if there is prolonged need for airway control)
2. For palliation therapy (ie, respiratory hygiene in terminally ill patients)
3. In the presence of anatomic variations that prohibit tracheotomy (these cases are actually very rare).

Cricothyroidotomy is not recommended in the following situations:

1. For pediatric patients
2. When an endotracheal tube has been in place more than 7 days
3. In the presence of laryngeal inflammation or infection.

Unless more convincing evidence is presented, the prudent surgeon should exercise very strict guidelines for performing cricothyroidotomy and altering the laryngeal structure.

REFERENCES

1. Brantigan CO, Grow JB Sr. Cricothyroidotomy: elective use in respiratory problems requiring tracheotomy. J Thorac Cardiovasc Surg 1976;71:72-81.

2. Jackson C. High tracheostomy and other errors, the chief causes of chronic laryngeal stenosis. Surg Gynecol Obstet 1921;32:292-398.

3. Boyd AD, Romita MC, Conlan AA, Fink SD, Spencer FC. A clinical evaluation of cricothyroidotomy. Surg Gynecol Obstet 1979;149:365-8.

4. Sise MJ, Shacksord SR, Cruickshank JC, Murphy G, Fridlund PH. Cricothyroidotomy for long term tracheal access. Ann Surg 1984;200:13-7.

5. Griesz H, Qvarnström O, Willen R. Elective cricothyroidotomy: a clinical and histopathological study. Crit Care Med 1982;10:387-9.

6. McDowell DE. Cricothyroidostomy for airway access. South Med J 1982;75:282-4.

7. O'Connor JV, Reddy K, Ergin MA, Griepp RB. Cricothyroidotomy for prolonged ventilatory support after cardiac operations. Ann Thorac Surg 1985;39:353-4.

8. Morain WD. Cricothyroidotomy in head and neck surgery. Plast Reconstr Surg 1979;65:424-8.

9. Brantigan CO, Grow JB. Subglottic stenosis after cricothyroidotomy. Surgery 1982;91:217-21.

10. Kennedy TL. Epiglottic reconstruction of laryngeal stenosis secondary to cricothyroidotomy. Laryngoscope 1980;90: 1130-6.

11. Weymuller EA Jr, Cummings CW. Cricothyroidotomy: the impact of antecedent endotracheal intubation. Ann Otol Rhinol Laryngol 1982;91:437-9.

12. Gleeson MJ. Cricothyroidotomy: a satisfactory alternative to tracheostomy? Clin Otolaryngol 1984;9:1-2.

13. Caparosa RJ, Zavatsky AB. Practical aspects of the cricothyroid space. Laryngoscope 1957;67:577-91.

14. McGill J, Clinton JE, Ruiz E. Cricothyroidotomy in the emergency department. Ann Emerg Med 1982;11:361-4.

15. Romita MC, Colvin SB, Boyd AD. Cricothyroidotomy: its healing and complications. Surg Forum 1977;28:174-5.

16. Koopman CF Jr, Feld RA, Coulthard SW. Effects of antibiotics and injury of cricothyroidotomy. Surg Forum 1979; 30:507-8.

17. Stauffer JL, Olson DE, Petty TL. Complications and consequences of endotracheal intubation and tracheotomy. Am J Med 1981;70:65-76.

TELESCOPIC ENDOLARYNGEAL SURGERY

JOHN M. LORÉ, JR, MD
BUFFALO, NEW YORK

Magnification for endolaryngeal visualization, biopsy, and removal of benign lesions and carcinoma in situ is achieved using a telescope inserted in stripping type forceps. The combined telescope and forceps are passed easily through any standard laryngoscope with a holder. Excellent visualization is achieved through the telescope, which can be provided with 0°, 30°, or 70° optics. In most circumstances, these instruments obviate the use of the operating microscope, being simpler and just as exact. The field of vision, however, is smaller. The instruments are also ideal for cervical tracheoscopy and mediastinoscopy.

KEY WORDS — laryngoscopy, telescopic endolaryngeal surgery.

Magnified visualization of the larynx can be achieved by the use of a microscope or either a rigid or flexible telescope. These instruments are further adaptable to endolaryngeal surgery, except that the flexible telescope has had very limited application to the larynx. Kleinsasser[1] has designed rigid telescopes for use via his laryngoscope, mainly for visualization and photography. Endolaryngeal surgery would then require a separate set of instruments.

Combination of telescopes within forceps (Figure) simplifies the surgery and is not new. Years ago such instruments were designed for lung biopsy purposes. Later on, this concept of combining telescopes and forceps was used in nasopharyngeal biopsy forceps (Loré-Storz),[2] nasal endoscopic surgical instruments (Messerklinger-Storz),[3] and urologic and other instruments.

Using the combination principle, endolaryngeal telescopes with forceps were designed with the cooperation of Karl Storz Endoscopy-America Inc, (Culver City, Calif) for use with almost any standard type of laryngoscope. A wide lumen laryngoscope and the operating microscope are not necessary. These instruments were first manufactured with 0° and 70° telescopes and, later on, a 30° angle optical system. The forceps are a modification of the right and left Loré stripping instruments[4] designed primarily for deepithelialization of the surface or free edge of a vocal cord.[5] The original forceps were based on the Imperatori subglottic forceps. The forceps currently used through the telescope are universal — right or left — with both blades hinged. The original nontelescopic instruments had one blade hinged and the other blade fixed for one vocal cord, and vice versa for the other vocal cord. The fixed blade was placed on the medial side of the vocal cord to be stripped. Another modification is the use of adult and child sizes, in which the angulated blade is longer for the adult and shorter for the child. All these original forceps could be used via a laryngoscope, with or without the use of the microscope. The problems in using the microscope involve the usual necessity of a larger lumen laryngoscope with imminent danger to dentition and the adjustment and alignment of the microscope. The telescopic laryngeal instruments, although requiring a laryngoscope, use virtually any standard laryngoscope with a Lewy or similar laryngoscopic holder.

The current combination of telescope with forceps eliminates the microscope and affords precise visualization during the surgical procedure, whether it be for biopsy purposes, stripping a vocal cord, or removal of a benign lesion or carcinoma in situ.

TECHNIQUE

The telescope alone is used for visualization and is then removed and inserted into the channel in the forceps for definitive surgery. This permits careful scrutiny of not only the usual presenting surface of the larynx, but also the walls of the ventricle and infraglottic and subglottic space by using the 30° and 70° telescope. For the surgical procedure, either the 0° or the 30° telescope is ideal. The exact extent and depth of the excision are clearly visualized. The 70° telescope requires some practice to become oriented to the visual field, whereas the 0° and 30° telescopes are oriented readily. Care must be taken not to grasp the contralateral vocal cord, since both blades are hinged.

In addition, these instruments are excellent for cervical tracheoscopy, whether it be for visualization or biopsy purposes. In the adult, tracheoscopy is primarily for neoplastic or cicatricial lesions, whereas in the child it is primarily for evaluation of cicatricial or congenital lesions.

These instruments are also extremely useful in mediastinoscopy. Magnification is simple through the telescope alone, affording excellent delineation be-

From the Department of Otolaryngology, State University of New York at Buffalo.

Presented at the meeting of the American Laryngological Association, Denver, April 25-26, 1987.

REPRINTS — John M. Loré, Jr, MD, Dept of Otolaryngology, SUNY at Buffalo, 2121 Main St, Buffalo, NY 14214.

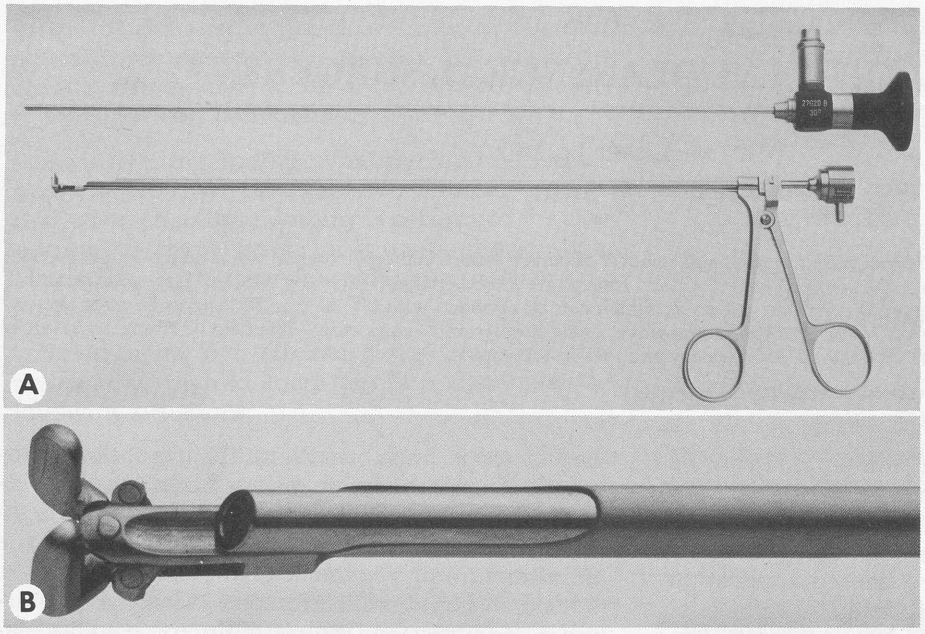

Thirty-degree telescope and stripping forceps. A) Separated. B) Telescope inserted in stripping forceps. Blades of stripping forceps are both hinged and depicted in open position. (From Loré JM Jr. An Atlas of Head and Neck Surgery, 3rd ed. Philadelphia: WB Saunders, 1987. Reprinted with permission.)

tween lymph nodes and vessels. The telescope then is inserted in the forceps and used under the magnified vision.

SUMMARY

Telescopic endolaryngeal instruments with 0°, 30°, and 70° optics and stripping forceps are described. These instruments provide magnification for visualization and, with the forceps, are used for biopsy and definitive surgical procedures. They also are used for cervical tracheoscopy and for mediastinoscopy. Other types of forceps could be manufactured for other purposes.

REFERENCES

1. Kleinsasser O. Microlaryngoscopy and endolaryngeal microsurgery. Philadelphia: WB Saunders, 1968.

2. Loré JM Jr. Optical nasopharyngeal biopsy forceps. Arch Otolaryngol 1978;104:167.

3. Messerklinger W. Recurring rhinosinusitis, endoscopic diagnosis and surgery. Presented at the 13th World Congress of Otorhinolaryngology, Miami, May 26-31, 1985.

4. Loré JM Jr. A set of instruments designed for stripping the vocal cords. Arch Otolaryngol 1954;59:604-5.

5. Loré JM. Stripping of the vocal cords. Laryngoscope 1934; 44:803-16.

UNUSUAL PHARYNGEAL LESION CAUSING DYSPHAGIA

KATHRYN K. OBANA, MD WILLARD E. FEE, JR, MD

STANFORD, CALIFORNIA

A 58-year-old man was evaluated for a 42-year complaint of a pharyngeal foreign body sensation whenever he ate. Examination revealed normal anatomy at rest but diffuse hypopharyngeal distension with Valsalva's maneuver. His past history was remarkable for an infectious illness, possibly diphtheria. We speculate that this unusual case most likely represents a postdiphtheritic selective pharyngeal paralysis and present his case, radiographic findings, and a discussion of the differential diagnosis.

KEY WORDS — diphtheria, dysphagia.

INTRODUCTION

The differential diagnosis of dysphagia is long and varied and includes benign and malignant tumors, diverticula, mural lesions, infections, webs, spasm, extrinsic compression on the pharynx or esophagus, metabolic causes, foreign bodies, tracheoesophageal fistula, neurologic disorders, myopathic disorders, and psychologic disorders. Uncommon causes of dysphagia include several of the rare degenerative neurologic and myopathic syndromes, pharyngocele, and the infectious diseases rabies, tetanus, poliomyelitis, and diphtheria. We present a patient with dysphagia due to an unusual cause and discuss the differential diagnosis of uncommon causes of dysphagia.

CASE REPORT

In July 1983, we were asked to see a 58-year-old man in the emergency room for a suspected esophageal foreign body. By the time we arrived, the foreign body sensation had passed. He had been scheduled for a Zenker's diverticulectomy at another institution, but had cancelled the appointment.

The patient had had chronic difficulty in swallowing since 1941, following an infectious illness that he called encephalitis. Evidently, one physician had diagnosed him as having diphtheria; however, a second physician had dismissed this diagnosis. This infectious illness was characterized by a sudden complete inability to swallow, necessitating nasogastric feedings for 3 days, fever to 40°C, diplopia, and paralysis of the palatal muscles. He was treated with Prontosil (one of the original sulfa antibiotics) and recovered uneventfully from the illness, except for the sequelae of persistent palatal weakness and an annoying foreign body sensation whenever he ate.

On physical examination, the patient appeared to be well and was in no distress. He had normal laryngeal and pharyngeal anatomy and function at rest, except for a minimal symmetric palatal weakness. When asked to perform Valsalva's maneuver, his entire hypopharynx from the level of the hyoid cartilage to the level of the pyriform sinuses ballooned out in smooth symmetric fashion.

Cine-esophagrams (Figs 1 and 2) revealed a normal hypopharynx and esophagus at rest but great distensibility of the hypopharynx with Valsalva's maneuver. Cricopharyngeal function was normal. The patient was given some barium-soaked bread to eat. When he swallowed, the bread lodged in the area of his left pyriform sinus, creating a foreign body sensation. We suggested that the patient turn his head to the right, whereupon the bread readily passed. Turning the head to the right occludes the right hypopharynx and enlarges the left hypopharynx. Using this maneuver, the patient was able to dislodge the bread and was relieved of the foreign body sensation. Four years later, he continues to be able to relieve this sensation with the same maneuver.

DISCUSSION

This case illustrates an interesting lesion producing dysphagia and a simple solution to the problem. The unusual causes of dysphagia in the differential diagnosis of this lesion include, but are not limited to, several of the degenerative neurologic and myopathic syndromes, pharyngocele, and infectious diseases such as rabies, tetanus, poliomyelitis, and diphtheria.

While many of the neuromuscular disorders are characterized by dysphagia, it usually constitutes but one of many neuromuscular problems from which the patient suffers. A careful history and physical examination will reveal other neuromuscular abnormalities that characterize the various disease processes. In general, neuromuscular diseases are progressive, not focal or self-limiting as is the process discussed here.

From the Division of Otolaryngology–Head and Neck Surgery, Stanford University Medical Center, Stanford, California.

Presented at the meeting of the American Laryngological Association, Denver, April 25-26, 1987.

REPRINTS — Willard E. Fee, Jr, MD, Division of Otolaryngology–Head and Neck Surgery, Stanford University Medical Center, Stanford, CA 94305-5328.

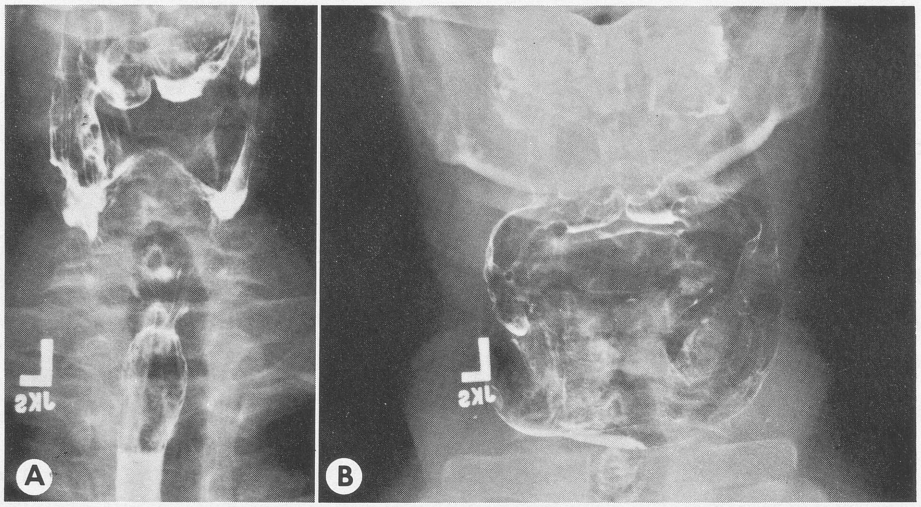

Fig 1. Anteroposterior cineradiographic view of patient's hypopharynx A) at rest and B) during Valsalva's maneuver.

Pharyngocele is an unusual cause of dysphagia, and until 1979, only 18 well-documented cases were reported in the literature.[1] A pharyngocele is produced by herniation of the mucous membrane through anatomically weak areas of the pharyngeal wall (usually at the base of tongue or pyriform sinus regions). These are discrete pouches with luminal apertures,[2] and normally increase in size with Valsalva's maneuver. This lesion presents most commonly with symptoms of dysphagia and a sensation of food lodging in the throat.[1] Diagnosis is made by radiographic examination and by endoscopy. If warranted, the treatment is surgical excision. While the lesion we studied shared certain similarities to a pharyngocele, eg, a change in configuration with Valsalva's maneuver, it was a diffuse symmetric hypopharyngeal distension rather than a discrete pouch.

Rabies, tetanus, poliomyelitis, and diphtheria are rare causes of dysphagia today, but were quite common in 1941 when our patient experienced his infectious illness.

Rabies occurs almost exclusively following a bite by an infected animal. A 2- to 10-day prodrome ensues, characterized by fatigue, anorexia, fever, sore throat, malaise, and nausea. An acute neuropathic period follows, during which the patient manifests anxiety, irritability, insomnia, and depression. Painful pharyngeal spasms occur during this phase. Characteristic drooling occurs, since swallowing is extremely painful. Only three cases of human survival of rabies have been documented.[3]

Tetanus presenting with dysphagia has been the subject of at least two recent case reports.[4,5] It presents most commonly with symptoms of trismus and dysphagia. As more muscles become involved, a generalized rigidity ensues. Infection usually is transmitted through an open wound. Treatment consists of surgical debridement of the wound, antibiotics (usually penicillin), administration of tetanus antitoxin, and supportive care.

Poliomyelitis constitutes an unusual cause of dysphagia at the present time in the United States because of the widespread use of the polio vaccine. Polio is well known to cause bulbar paralysis with resulting laryngeal and pharyngeal involvement. Isolated bulbar paralysis is unusual, but may be seen occasionally in children. Dysphagia, in this disease, results from viral invasion of the nucleus ambiguus with production of nerve cell injury and inflammation. The degree of clinical manifestation is a reflection of the number of cells within the nucleus ambiguus that are damaged.[6] It is therefore possible, but not common, to see a primarily pharyngeal paralysis with minimal or no laryngeal involvement.

There is a recent case report in which a unilateral palatopharyngeal paralysis without laryngeal paralysis is reported as a sequela of bulbar polio.[7] It is hypothetically conceivable that the symmetric pharyngeal paralysis of our patient resulted from selective nerve destruction within the nucleus ambiguus by polio.

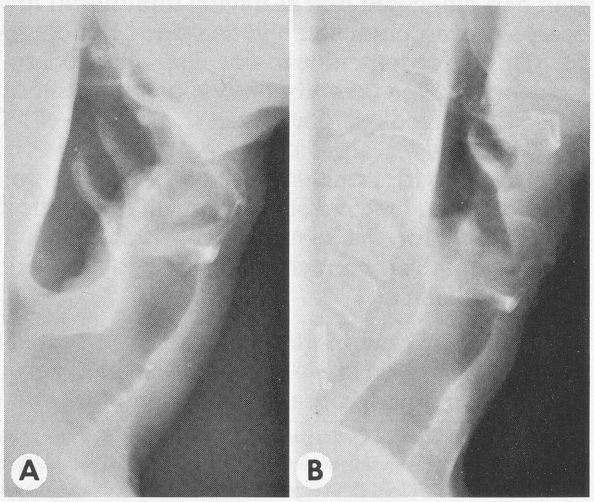

Fig 2. Lateral cineradiographic views of patient's hypopharynx A) during Valsalva's maneuver and B) at rest.

Our best hypothesis, given the possible history of diphtheria, is that of a postdiphtheritic selective pharyngeal paralysis. Diphtheria was a common entity in 1941, with diphtheritic pharyngotonsillitis occurring in 48% to 61% of diphtheria cases.[8] In a series of 1,433 patients, pharyngeal paralysis was found to occur in 42 people.[9] As experienced by our patient, the early stage of paralysis often is heralded by difficulty swallowing, with either unilateral or bilateral paralysis of the soft palate and pharyngeal muscles. The early stage of paralysis also commonly is accompanied by paresis of accommodation,[9] which may manifest in the symptom of diplopia, which the patient described as occurring during his infectious illness.

Diphtheria creates a demyelination with preservation of axonal continuity. While the most common site of involvement is at the neural ganglia, more peripheral involvement can occur as well. It has been proposed recently that focal neuropathies may occur in faucial diphtheria as a result of local toxic effects.[10] The only factor mitigating against a diagnosis of diphtheria is the time course reported by the patient. Palatal and pharyngeal paresis typically occur during the third to fourth week of the illness, rather than as the initial presenting symptom of the illness.

We have presented an unusual lesion causing dysphagia and a simple solution to the problem. A 4-year follow-up of the patient reveals that he is eating well using this method of turning his head to the right when he swallows.

REFERENCES

1. Norris CW. Pharyngocoeles of the hypopharynx. Laryngoscope 1979;89:1788-807.

2. Ward PH, Fredrickson JM, Strandjord NM, Valvassori GE. Laryngeal and pharyngeal pouches. Laryngoscope 1963;73: 564-82.

3. Morrison AJ, Wenzel RP. Rabies: a review and current approach for the clinician. South Med J 1985;78:1211-8.

4. Wang L, Karmody CS. Dysphagia as a presenting symptom of tetanus. Arch Otolaryngol 1985;111:342-3.

5. Watanabe H, Makishima K. Dynamics of swallowing in tetanus. J Laryngol Otol 1984;98:953-6.

6. Adams RD, Victor M. Principles of neurology. 3rd ed. New York: McGraw-Hill, 1985:547-51.

7. Rubin AM, Blair RL, Alberti PW. Near drowning, scuba diving: an unusual late sequela of bulbar polio. J Laryngol Otol 1984;98:733-6.

8. Naiditen MJ, Bower AG. Diphtheria: a study of 1433 cases observed during a ten year period at Los Angeles County Hospital. Am J Med 1954;17:229-45.

9. Scheid W. Diphtherial paralysis: an analysis of 2292 cases of diphtheria which include 174 cases of polyneuritis. J Nerv Ment Dis 1952;116:1095-101.

10. Dyck RT, Thomas PK. Peripheral neuropathy. 2nd ed. Philadelphia: WB Saunders, 1984:2010-7.

VOCAL NODULES IN CHILDREN

BRUCE BENJAMIN, FRACS, FAAP GLEN CROXSON, FRACS

SYDNEY, AUSTRALIA

We reviewed 27 pediatric patients who had vocal nodules removed surgically in a 5-year period. Age of operation, duration of symptoms, indications for operation, and the results of removal are analyzed. The techniques of laryngoscopic assessment with telescopes and of microsurgical removal are described in detail. The 27 children had 53 nodules removed. Almost all had normal or improved voices as judged by the parents' answers to a written questionnaire. From the results of this series, microsurgical removal of vocal nodules in children is justified in selected patients.

KEY WORDS — hoarseness, microlaryngoscopy, vocal nodules.

INTRODUCTION

Morell MacKenzie first described vocal nodules and their frequency in the 1880s.[1] Now, 100 years later, it is documented that vocal nodules are the commonest cause of hoarseness in children.[2-7] They may be called screamer's nodules or singer's nodules in adults.

The incidence of chronic hoarseness in children is estimated at from 2%[8] to 23.4%.[4] The cause of the hoarseness in one study was found to be vocal nodules in 38%,[9] whereas in another study it was found in 78%.[4] Nodules are the most common voice disorder in school-age children, although they are not common in teenagers.[2]

Wilson[8] emphasized the reeducation of children to eliminate vocal abuse; to encourage training in pitch, loudness, and speech quality; and to make the new speech characteristics habitual. In 1962 Arnold[10] stated, "surgical ablation of simple vocal nodules in children is unnecessary, senseless and potentially harmful." In 1985 Von Leyden[7] warned, "surgical manipulations of the pediatric larynx are more difficult because of its size and structure and the larynx is easily traumatised." He added "the removal of nodules will be followed by prompt recurrence unless the etiologic factors have been eliminated."

Removal of vocal nodules in adults is acknowledged as an effective treatment for persistent nodules in selected patients, especially when speech therapy has not been beneficial. Surgical treatment is not so readily accepted in children; despite a literature search, we cannot find support for surgical removal of vocal nodules in children. This paper is a retrospective review of pediatric patients whose vocal nodules were removed and assesses the effect of the operation.

MATERIALS AND METHOD

We reviewed the records of 27 consecutive patients under the age of 15 years who had surgical removal of vocal nodules during the 5 years 1981 through 1986 at the Royal Alexandra Hospital for Children, Sydney. Data collected included age, sex, symptoms, duration of symptoms, age at operation, methods of endoscopic evaluation and surgical removal, and recurrence rate. Further data were obtained from a questionnaire sent by mail to parents in September 1986. It asked about preoperative duration of hoarseness; whether speech therapy was given and how many sessions and whether it was beneficial; whether the child's voice was "worse," "the same," "improved," or "normal" after complete healing; and whether the voice remained the same or became bad again.

Endoscopic evaluation of the vocal nodules and surgical removal were performed using a standardized technique of general anesthesia,[11] laryngoscopy with telescopic magnification (Fig 1), and microsurgery.[12] The operations were performed as day surgical procedures.

Anesthesia was an inhalational technique with spontaneous respiration using oxygen, nitrous ox-

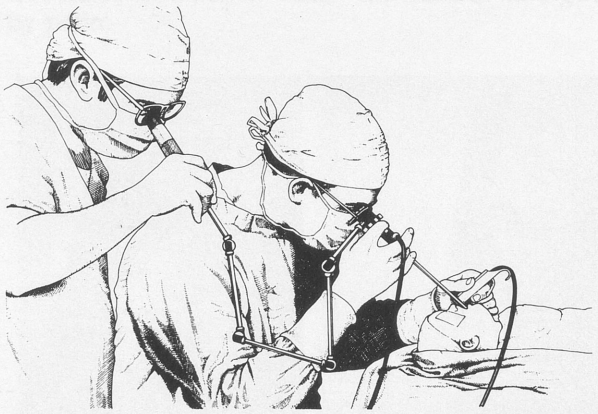

Fig 1. Direct laryngoscopy using rigid rod lens telescope in child under general anesthesia. Assistant using Wittmoser optical teaching arm has similar clear view to that of surgeon.

From the Royal Alexandra Hospital for Children, Sydney, Australia.

Presented at the meeting of the American Laryngological Association, Denver, April 25-26, 1987.

Fig 2. Histologic section of vocal nodule. There are areas of epithelial hyperplasia, marked submucosal edema, and minimal inflammatory changes.

ide, halothane, and methoxyflurane. No endotracheal tube was used. General anesthesia was supplemented by topical lidocaine up to 5 mg/kg.

Preliminary direct laryngoscopy was performed with a hand-held laryngoscope. This was followed by laryngoscopy using rigid rod lens Hopkins telescopes, 0° to 30°, to give a clear magnified view and allow photography.

We used the operating microscope during suspension laryngoscopy for microlaryngeal surgery. The Benjamin[13] pediatric microlaryngoscope (Karl Storz, Germany) was maintained in position by a modified Reicker-Kleinsasser laryngoscope holder (Karl Storz), which rested on a height-adjustable platform mounted on the operating table.

The edge and undersurface of the vocal cord and the vocal nodule itself were readily displayed by external finger pressure on the neck on one or the other side of the larynx, or by gentle use of a suction tip or blunt instrument to evert the vocal cord. The nodule was grasped with the edge of cup-shaped forceps, usually up-cupped forceps, 2 mm in diameter, and drawn toward the midline. This method of traction emphasized the wide base. Next, curved or up-cutting scissors were used to excise the nodule and a small cuff of surrounding edematous mucosa. After excision, the defect had an elongated oval shape on the edge and undersurface of the vocal cord. In most cases a small amount of the vocal cord mucosa remained intact anterior to the site of removal toward the anterior commissure; occasionally removal resulted in stripping of the cord edge up to the anterior commissure. The right and left nodules were deliberately not removed at the same operation to eliminate the chance of postsurgical adhesion. All nodules were examined histologically (Fig 2).

The children were observed postoperatively for several hours in the recovery ward. Steroids, antibiotics, and humidified air were not used. The patients were advised to use their voices quietly for 7

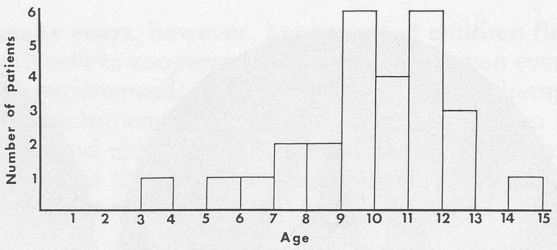

Fig 3. Age distribution of 27 patients who had removal of vocal cord nodules.

to 10 days postoperatively, but there was no instruction for complete voice rest. Removal of the contralateral nodule was performed 4 weeks later. Postoperative evaluation was performed at 4 weeks and then at 12 months thereafter.

RESULTS

Twenty-seven patients were operated on between 1981 and 1986 by the principal author (B.B.). There were 22 boys and five girls. The age range at operation was from 3 to 14 years, with a mean age of 9.4 years (Fig 3). All 27 patients had hoarse voices. Three also had periods of loss of voice, and two others had noticeable voice fatigue. The age of onset of symptoms showed a wide scatter from infancy to 11 years. The mean duration of symptoms before operation was 4.1 years.

The 27 children had 53 nodule removals. Twenty-four children had bilateral nodules, all with staged removal. One child had a unilateral nodule removed. One child had bilateral nodules, but did not have the second operation. One child had a repeat operation in 1985 for recurrence on one side, having had bilateral nodules removed in 1981.

The period of postoperative follow-up was from 3 months to 3 years 9 months, with a mean time of 1 year 5 months. Twenty-five of the 27 patients responded to the questionnaire. Fifteen reported a "normal" voice and ten reported "improvement;" of these ten there were three who reported improvement but fluctuation with voice abuse. None reported the voice as being "the same" or "worse." Five patients received preoperative speech therapy. The parents assessed this as of no value in three cases, little value in one, and worthwhile in one. There were no complications of anesthesia or surgery.

DISCUSSION

The age, sex, and clinical features in this series are similar to those of previously reported series.[2-7]

In a child with a persistent husky voice, it is essential to exclude laryngeal papillomata. At indirect laryngoscopy, mucus on the edge of the vocal cord can sometimes mimic nodules, but the mucus clears after coughing. If the larynx cannot be seen with a mirror, diagnostic endoscopy under general anes-

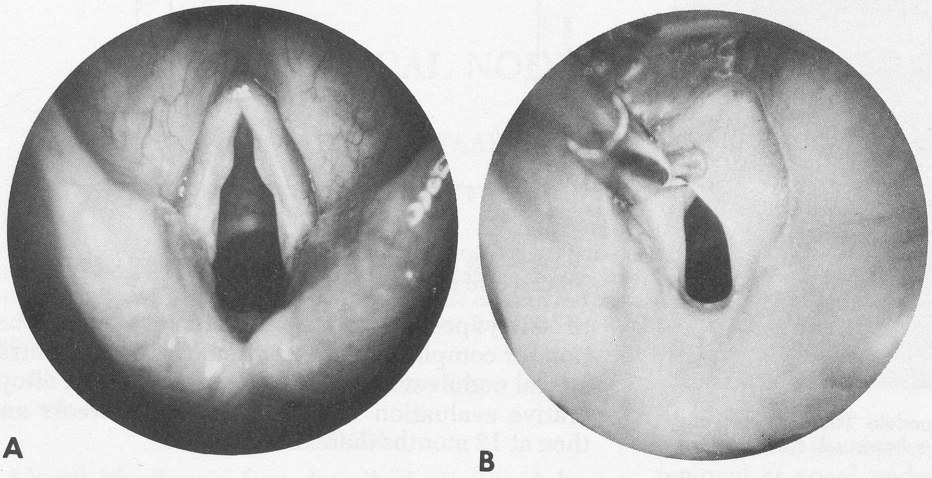

Fig 4. Removal of vocal nodules. A) Appearance at direct laryngoscopy photographed using rigid telescope. B) Nodule is grasped by cup-shaped forceps and retracted to emphasize longitudinal extension of edema. Scissors are used to remove focal nodularity and area of perinodular edema.

thesia is justified.

Not all children with vocal nodules are recommended for operation. On the contrary, most are evaluated by indirect laryngoscopy and reassessed during the next year. The indications for operation are firm and include a long history for several years without improvement, the voice becoming worse, and severe hoarseness or loss of voice sufficient to cause embarrassment in everyday conversation or reading in class. Sometimes the symptoms are sufficient for the child to be teased or ridiculed. A deliberate recommendation for operation is seldom made before the age of 8 years, although children who undergo diagnostic laryngoscopy may have nodule removal at an earlier age. It generally is contended that vocal nodules are self-limiting and resolve in the teenage years. Although there is no study to prove this view, the possibility of natural remission, given sufficient time, should be considered when advising that removal is necessary.

Our experience with nodules in general, and with the patients in this series in particular, lead us to certain conclusions. The obvious abnormality in vocal nodules is the nodularity and focal thickening at the site classically described on the edge of the vocal cord at the junction of the anterior third and posterior two thirds, but there is also surrounding longitudinal edema in the submucosal space (Fig 4A). The most prominent swelling is on the edge and undersurface of the vocal fold. There may be a difference in the appearance at indirect laryngoscopy and the appearance under general anesthesia using telescopes or the microscope. A nodule seen prominently in the laryngeal mirror may be less obvious under anesthesia; it will be found just under the edge of the vocal fold.

There is a spectrum of appearances in vocal nodules. In simple nodules there is a localized, fusiform thickening of the mucosal surface of the edge of the vocal cord. In larger nodules there is prominent irregular focal nodularity with extensive chronic surrounding longitudinal edema, and sometimes also secondary edema in the anterior subcommissure. The nodule can be seen clearly on the edge and undersurface by everting the vocal fold using a suction tip or a blunt instrument to gently displace the ventricle downward and roll the vocal fold. The nodule and the surrounding edema are emphasized and made more prominent[14] by grasping the center of the nodule with the edge of cup-shaped forceps and retracting it toward the midline (Fig 4B). Surgical removal using curved or up-cutting scissors must remove not only the focal nodularity but also, at the same time and in one piece, the area of perinodular edema. The vocal cord mucosa near the anterior commissure should be kept intact. If preservation of the mucosal edge could be achieved with certainty there would be no danger to the anterior commissure and staged removal would not be necessary. In our patients removal of the contralateral nodule was staged 4 weeks later to eliminate the possibility of an adhesion, possibly an overcautious approach.

We found some years ago that cup-shaped forceps and scissors give a more satisfactory and accurate removal than laser removal. In particular, the forceps and scissors technique allows removal of the nodule and the area of surrounding edema in the submucosal layer without injury to the vocalis muscle or the vocal ligament. The resultant surgical defect has a very shallow, elongated oval shape.

We have observed rapid healing, lack of reaction, absence of complications, and a low rate of recurrence. We conclude that children's vocal cords are not delicate and that with modern, precise, gentle microsurgical techniques vocal nodule removal is a relatively safe, justifiable, and effective procedure that can be performed on an outpatient basis.

We realize that objective evaluation of a voice disorder is difficult, unreliable, and prone to observer error.[6,15] The criterion used for voice improvement in this series was the parents' opinions of the postoperative voice, which, although subjective, may be as reliable as other available parameters such as stroboscopy, videoendoscopy, or com-

puter analysis of speech, which are difficult to apply in all children.

The operation cannot be regarded as curative in all cases. All the patients were improved; only three had fluctuation of symptoms with voice abuse. The underlying abnormality of voice production may persist even though the quality of the voice is improved. Speech therapy was considered and attempted in some, although results in the past were disappointing. It may be that appropriate preoperative and postoperative speech therapy would further improve the voice results. Our impression over many years, however, has been that children find it difficult to cooperate with the advice given even by an experienced, skilled, pediatric speech therapist, that interpersonal conflicts can arise between parents and children with regard to use of the voice, and that the possible beneficial effect is no longer apparent when therapy ceases.

In this series the good results, the rarity of recurrence, and the relative safety of the procedure indicate that microsurgical removal of vocal nodules is justified in children selected according to the indications outlined above.

REFERENCES

1. MacKenzie M. Diseases of the pharynx, larynx and trachea. William Wood and Company, 1880:218-32.

2. Strong MS, Vaughan CW. Vocal nodules and polyps — the role of surgical treatment. Laryngoscope 1971;81:911-23.

3. Shearer WM. Diagnosis and treatment of voice disorders in school children. J Speech Hear Disord 1972;37:215-21.

4. Silverman E-M, Zimmer CH. Incidence of chronic hoarseness among school age children. J Speech Hear Disord 1975; 40:211-5.

5. Pont C. Hoarseness in children. West Mich Univ J Speech Ther 1965;2:6-8.

6. Baynes RA. An incidence study of chronic hoarseness among children. J Speech Hear Disord 1965;13:172-6.

7. Von Leyden H. Vocal nodules in children. Ear Nose Throat J 1985;64:29-41.

8. Wilson DK. Children with vocal nodules. J Speech Hear Disord 1961;26:19-25.

9. Senturia BH, Wilson FB. Otorhinolaryngic findings in children with voice deviations. Preliminary report. Ann Otol Rhinol Laryngol 1968;77:1027-41.

10. Arnold GE. Vocal nodules and polyps: laryngeal tissue reaction to habitual hyperkinetic dysphonia. J Speech Hear Disord 1962;27:205-17.

11. Benjamin B. Anesthesia for laryngoscopy. Ann Otol Rhinol Laryngol 1984;93:338-42.

12. Benjamin B. Laryngoscopy. In: Gans SL, ed. Pediatric endoscopy. New York: Grune & Stratton, 1983:17-36.

13. Benjamin B. A new pediatric microlaryngoscope. Ann Otol Rhinol Laryngol 1984;93:468.

14. Lehmann W, Pidoux J-M, Widmann J-J. Pseudotumours-nodules. In: Larynx. Microlaryngoscopie et histopathologie. Geneva: Inpharzam Medical Publications: 68-75.

15. Onslow M, Ingham R. Speech quality measurement and the management of stuttering [Thesis]. Sydney, Australia: Cumberland College of Health Sciences, 1980.

USE OF BOTULINUM TOXIN TO LATERALIZE TRUE VOCAL CORDS: A BIOCHEMICAL METHOD TO RELIEVE BILATERAL ABDUCTOR VOCAL CORD PARALYSIS

SEYMOUR R. COHEN, MS, MD JEROME W. THOMPSON, MD

LOS ANGELES, CALIFORNIA

Using the mongrel dog as an animal model, we studied the effectiveness of botulinum toxin (Oculinum) to lateralize the true vocal cord. This experiment was undertaken in order to determine whether the toxin can improve the airway in subjects with bilateral abductor vocal cord paralysis. The toxin was injected into the cricothyroid muscle to block neuromuscular transmission at the motor end-plate. Paralysis of the cricothyroid muscle was achieved and documented by electromyography and videotaped endoscopy. Paralysis of the cricothyroid muscle decreases the tension of the true vocal cord and allows the cord to take a more lateral position. In this preliminary report, the literature is reviewed, the effect of and action of the toxin are discussed, and the results of the experimental protocol, establishment of dose-response curves, and techniques of injection are presented. Preliminary data suggest that there is an increase in the airway by lateralizing the true vocal cord with this biologic substance, and that this method may have many applications in clinical medicine for the otolaryngologist–head and neck surgeon.

KEY WORDS — airway obstruction, botulinum toxin, cricothyroid muscle, laryngeal paralysis, lateralization, true vocal cord.

INTRODUCTION

The search for a simpler and better method to rehabilitate the paralyzed larynx has been persistent and elusive. We report the preliminary results of a basic science research project wherein botulinum toxin is injected into the cricothyroid muscle of a mongrel dog to attain lateralization of the true vocal cord and thereby to improve the airway. This study has been in progress for approximately 2 years.

A review of the literature reveals that chemical or biochemical methods have not been used to relieve the situation of the patient with a neurologically crippled larynx. This project was undertaken to study the effects of botulinum toxin in order to relieve the obstructive phenomenon resulting from bilateral abductor paralysis of the larynx and thus eliminate the need for an artificial airway. Botulinum toxin (Oculinum) has been used to temporarily paralyze selected muscles or muscle groups to relieve patients of the effects of the following diseases: 1) strabismus, 2) blepharospasm, 3) hemifacial spasm, and 4) torticollis. We believe this is the first report of the use of this toxin in the treatment of neurologic diseases of the larynx.

The possibility that botulinum toxin could relieve the devastating effects of laryngeal bilateral abductor paralysis stimulated us to attempt this trial study. Also encouraging to us were the facts that this form of treatment is not permanent, does not derange the normal anatomy of the larynx, has an almost immediate response, has no systemic toxicity when locally injected, and reduces the morbidity so common after all surgical procedures to a minimum. Because the effect of the drug is temporary, its use in some patients with spontaneous reversible bilateral abductor vocal cord paralysis would be ideal.

HISTORICAL REVIEW OF TREATMENT OF LARYNGEAL PARALYSIS

The surgical methods used to treat laryngeal paralysis have been controversial and often disappointing. While many techniques have been proposed and modified, perfect return of function of the larynx has not been attained as yet. While a high success rate has been reported for many of the procedures that eliminate the need for an artificial airway, restriction of exercise tolerance and the resultant voice defects still plague both patient and surgeon.

Arytenoidectomy, the surgical management first developed by King[1] in 1939, was modified by Orton[2] in 1944, and improved to its final form by Woodman[3] in 1946. In 1953, Woodman,[4] who avoided invasion of the thyroid cartilage, achieved some good results but no guarantee of an airway adequate for normal activity without challenge to voice quality.

In 1932, New and Childrey[5] reported a questionnaire response of 969 patients who had arytenoidectomy procedures; the success rate was less than 50% in patients who were operated upon previously and 91% in those who had no previous surgery. The

From the University of Southern California School of Medicine, Los Angeles. This research is funded by a grant from the Seymour R. Cohen and Odelia A. Cohen Medical Foundation and the Seymour R. Cohen and Burton Borman Otolaryngology Fund.

Presented at the meeting of the American Laryngological Association, Denver, April 25-26, 1987.

REPRINTS — Seymour R. Cohen, MD, 1300 N Vermont Ave, Los Angeles, CA 90027.

voice was a difficult factor to analyze accurately, but 5% of patients had poor voice, eight patients had aphonia, 20% had good to excellent voice, and 75% had adequate voice. In 1952 Thornell[6] suggested translaryngeal arytenoidectomy. Hoover[7] in 1932 used midline thyrotomy and submucosal resection of the vocal cord for improvement of the airway.

Fraser[8] in 1924 and Lahey[9] in 1928 attempted end-to-end anastomosis of the recurrent laryngeal nerve but failed, with uniformly poor results. Other techniques, such as the use of spinal accessory nerve, hypoglossal nerve, and phrenic and facial nerve hookups, resulted in such varying degrees of success that many of these procedures have been abandoned. Kleinsasser[10] in 1968 suggested a microlaryngeal surgical approach to arytenoidectomy, with a submucosal thinning of the true vocal cord. In 1976 laryngeal reinnervation was proposed and advanced by Tucker,[11] who reported relief of obstruction and the return of vocal function in the first five patients who underwent the procedure. Newman and Work[12] in 1976 stated a preference for the Woodman procedure and reported a 75% success rate. In 1978 Tucker[13] reported using the nerve pedicle graft in 45 patients ranging from 2 to 84 years of age. Return of function was noted within 6 to 12 weeks, with a primary success rate of 91.1% and a long-term success rate of 88.8%. Laser arytenoidectomy was performed on mongrel dogs and was introduced in 1983 by Eskew and Bailey.[14] Kleinsasser and Nolte[15] in 1981 reported 116 patients treated with microlaryngeal laser arytenoidectomy and indicated that all were decannulated between the 16th and 40th days, with satisfactory voices. Most recently, Sanders et al[16] reported a method of controlling true vocal cord position by transcutaneous electrical stimulation of the recurrent laryngeal nerve.

Baldissera et al[17] in 1986 attempted to reinnervate the paralyzed larynx using the phrenic nerve to reinnervate the posterior cricoarytenoid muscle. They anastomosed the right recurrent laryngeal nerve with the upper branch of the phrenic nerve, and reported success in 100% of the cats thus studied. Otto et al[18] in 1985 reported a study in which electrodes were placed into the posterior cricoarytenoid muscle and diaphragm muscles of five tracheotomized dogs. They used a sensor that selectively detected diaphragmatic electromyographic (EMG) activity, which served as a trigger to stimulate the posterior cricoarytenoid muscle. Otto and Davis[19] in 1986 reported another functional pacing of the vocal cord abduction with respirations. They used the negative intrathoracic pressure changes during inspiration, which were detected by a tracheal transducer, and stimulated the cricoarytenoid muscle by an implantable electrode. This study was performed in dogs, and showed abduction of the true vocal cords paced with normal respirations.

Broniatowski et al[20] in 1986 suggested electrical pacing of reinnervated strap muscles in the dog. The experiments were said to be the first attempt to pace a nerve-muscle pedicle by means of triggering information obtained through a strain gauge linked directly to tracheal motion during respirations. Freije et al[21] in 1986 examined motor end-plate distribution in the human lateral cricoarytenoid muscle. They used histochemical techniques and computer graphics to determine the three-dimensional distribution of the motor end-plates in the human lateral cricoarytenoid muscle. Their results indicated that the end-plates in human thyroarytenoid, cricothyroid, and posterior cricoarytenoid muscles have diffusely distributed end-plates, whereas in the lateral cricoarytenoid muscle, they are generally distributed along a broad band at the midlength of this muscle.

According to Tschiassny,[22] stimulation of the cricothyroid muscle approximates the cricoid ring to the lower border of the thyroid. Unilateral stimulation of the cricothyroid muscle effects elevation and deviation of the ring toward the stimulated side. These factors cause elongation of the vocal cord and approximation of the vocal processes to each other. This author[22] credits Hooper for first explaining that the upward movement of the cricoid cartilage onto the thyroid cartilage is caused by the pressure of air expelled from the chest, a process called the Hooper phenomenon.[23] This phenomenon is directly proportional to the force with which air is expelled from the chest. It is believed to be a centrally controlled expiratory action, occurs even after complete separation of the larynx from the trachea, and is not due to recoil after release of increased tracheal traction during inspiration. The phenomenon disappears in deeply anesthetized animals.

In 1957 Tschiassny[24] stated that excision of the cricothyroid muscle is effective in lateralizing the vocal cords when performed experimentally, but is associated with therapeutic failure with few exceptions when performed experimentally. He indicated that there are additional nerve supplies from the internal branch of the superior laryngeal nerve that supply the arytenoid muscles to produce adduction of the arytenoid and thus close the cartilaginous part of the glottis. This is a highly controversial view. Tschaissny pointed out that the rationale of therapeutic cricothyroid muscle elimination is to abolish the tension produced by this muscle, thus changing the vocal cord from the midline to the cadaveric position. Prerequisites for success are normal joint and elastic conditions of the larynx and the presence of a functioning cricothyroid muscle. Thompson et al[25] in 1984 did experimental studies in the dog for the correction of superior laryngeal

nerve paralysis by fusion of the thyroid to the cricoid cartilages. Their surgical procedure was used to correct the mechanical deficit caused by the disruption of the superior laryngeal nerve.

PHARMACOLOGY OF BOTULINUM TOXIN

According to Simpson,[26] *Clostridium botulinum* produces a very powerful neurotoxin of which there are numerous antigenically identifiable strains, classified according to the type of toxin they produce. Scott[27] and Simpson[26] indicate that while these strains are named A, B, Cα, Cβ, D, E, F, and G, the type A botulinum toxin is the only one of the eight that has been crystallized in stable form. Botulinum toxin A has powerful paralytic effects on the human muscle. The toxin, which has a molecular weight (mol wt) of 900,000 daltons, has been demonstrated to have neurotoxic as well as hemagglutinin (red cell) activity. The purer neurotoxin, mol wt 150,000 daltons, is three to five times as toxic as the crystalline toxin-hemagglutinin. Studies[28] suggest that all eight botulinum neurotoxins are proteins of equal molecular weights, and that the type A crystalline molecule is a simple protein composed of ordinary amino acids. The toxin is felt to be a single polypeptide chain without prosthetic group. Its toxicity is dependent upon maintaining the integrity of its tertiary structure.[27,28]

The complex of toxin-hemagglutinin is probably too large to penetrate the intestinal wall, and it is the toxin (150,000 daltons) that is found in the bloodstream. There is no evidence that the toxin penetrates the blood-brain barrier, except possibly in massive doses.

ACTION OF BOTULINUM TOXIN

It is appropriate to review the normal physiology at the neuromuscular junction to better understand the effects of the toxin. "The invasion of a nerve terminal by an action potential opens voltage-dependent calcium channels transiently. The brief influx of calcium rapidly stimulates release of a quanta of transmitter which in turn produces post synaptic change in conductance. Hopefully the biochemical basis of transmitted release will be unravelled by recent developments in membrane biochemistry."[29] The complex nature of the biochemistry of neurotransmitter release is reported by Kelly et al.[29] To summarize, exocytotic release of the neurotransmitter involves the apposition and fusion of vesicle membranes with the nerve terminal plasma membrane. Anatomic studies point to the presence of large intramembranous particles that are associated with synaptic vesicles at rest, with plasma membrane during exocytosis, and with coated vesicles during endocytosis.[30] The most characteristic feature of the nerve terminal is the synaptic vesicle, which corresponds to the quantum of transmitter release. The synaptic vesicles are not distributed uniformly in the nerve terminal, but are clustered around dense projections at the presynaptic plasma membrane.[31]

The toxin binds firmly to the muscle.[27] When injected locally into the muscle, the toxin will act locally for a prolonged period of time. Thus in low doses injected into eye muscles, for instance, little remaining toxin is left to pass into the general circulation. Safety of the toxin, used appropriately, is thereby assured. Also, type A toxin is rapidly fixed at the terminal nerve fibers and other tissue-binding loci. One estimate of a parenteral lethal dose (LD) for a grown man was seven mouse LDs. Scott[27] injected 26 mouse LD/50 into an eye muscle without any systemic effect. In the human the estimated LD/50 dose would be 2 mg given intravenously (IV).

Botulinum toxin interferes with the release of acetylcholine from the nerve ending, but it does not interfere with its storage within the synaptic vesicle. The release of acetylcholine from the nerve terminal requires an alteration in calcium ion metabolism with which botulinum toxin interferes. This interference with calcium metabolism blocks the release of acetylcholine, and thus functionally denervates the muscle fibers for weeks and even months. The toxin apparently acts upon individual motor nerve terminals. Boroff and Das Gupta[32] suggested that botulinum toxin antagonizes calcium ion transport by serotonin and upon calcium ion depletion. The end-plate does not release acetylcholine and the muscle fiber fails to contract. The toxin does not block propagation of the nerve impulse, and neither the nerve nor the muscle suffers impairment of electrical excitability or conductivity. Long-term exposure to the toxin will cause atrophy of the muscle. Botulinum toxin treatment of skeletal muscles produces the same effect as that of denervation.

METHODS

SUBJECT GROUPS

Twelve mongrel dogs were selected for long-term survivability. They then were assigned randomly to control or treatment groups. Each animal served as its own internal control for normal, preintervention vocal cord position. The larynx of each dog was videotaped at the beginning of the study and in each stage to document the angle of the vocal cords at the three defined cord positions: resting, maximum abduction, and maximum adduction. The techniques will be described in greater detail.

At the conclusion of the project, all animal groups will undergo needle biopsies of the cricothyroid muscles and be placed for adoption.

Group 1. To insure that all the fluid actually was injected into the cricothyroid muscle, the injection was done under direct vision via an open neck dissection of the muscles. As a control of the effect of

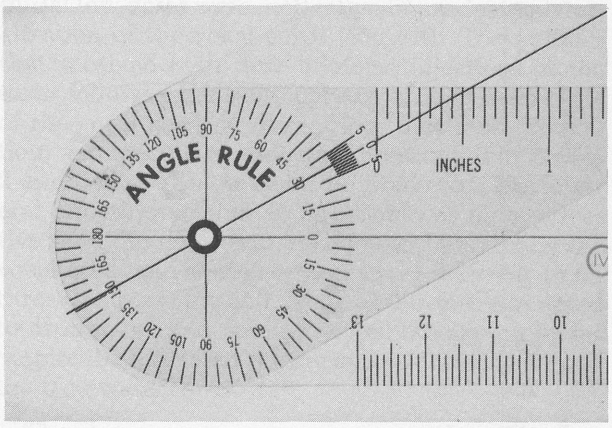

Fig 1. Goniometer with vernier scale used to measure angle formed by vocal cords using anterior commissure as axis of rotation.

injecting the standard treatment volume of 1 mL of fluid into the muscle, three animals were injected bilaterally with 1 mL of normal saline directly into each cricothyroid muscle. Preinjection and postinjection videotapes were obtained.

Group 2. This group had the standard volume of botulinum toxin injected into the right cricothyroid muscle. Because the dosage to be used in the dog was unknown, based on other animal studies, a low dose of 0.1 U/0.45 kg (1 lb) was initially used and was increased in increments in each subsequent dog so as to establish a dose-response curve. Each animal was videotaped preoperatively, immediately postoperatively, and at intervals of 4 weeks.

Group 3. The standard volume of botulinum toxin was injected into one cricothyroid muscle of each of two dogs that had a previous segmental resection of one recurrent laryngeal nerve. In one animal, the injection was ipsilateral, in the other animal the injection was contralateral. The same videotaping patterns and techniques were used.

Group 4. Botulinum toxin was injected into both right and left cricothyroid muscles of this group. Again, progressive increments in drug dosage were used to establish a dose-response curve. When both cricothyroid muscles were injected, the animals received twice as much toxin as those in which a unilateral injection was given.

SURGICAL METHODS

Preoperative penicillin was administered intramuscularly (IM). Each dog was sedated by an injection of 6 mg IM of acetyl promazine and 0.24 mg IM of atropine sulfate, followed by an injection of 0.1 mg/0.45 kg IV of a 0.5% solution of thiopental. The dog was then positioned and restrained on the operating table in a supine position and a mouth gag was placed. The larynx was visualized on the television monitor with a rigid fiberoptic fixed telescope and video camera combination. The status of the larynx was recorded on videotape (½ in). Continuous videotaping of the excursion of the vocal cords during breathing and vocalization and at rest were obtained. Once preoperative videotapes were completed, the animal was given an additional dose of thiopental to produce a surgical level of anesthesia.

VOCAL CORD MEASUREMENTS

Group	*Cord Position*	*Measurements (Angle in Degrees)*			
1	Resting	25	27	28	20.0
	Maximum adduction	0	0	0	0.0
	Maximum abduction	47	47	49	49.0
2	Resting	26	32	30	30.0
	Maximum adduction	0	3	2	0.6
	Maximum abduction	38	46	42	41.0
3	Resting	25	32	31	31.0
	Maximum adduction	2	11	10	9.0
	Maximum abduction	33	42	44	42.0
4A	Resting	26	30	32	34.0
	Maximum adduction	0	8	5	5.0
	Maximum abduction	60	54	55	54.0
4B	Resting	22	32	33	33.0
	Maximum adduction	0	9	9	11.0
	Maximum abduction	40	50	46	46.0

The surgical site in the neck was shaved, prepared, and draped in usual fashion for a sterile surgical procedure. An incision was made vertically along the midline over the cricoid cartilage. Self-retaining retractors were placed and the strap muscles were separated so that the cricothyroid muscle could be visualized. One milliliter of a specified concentration of botulinum toxin was injected through a monopolar needle attached to an EMG amplifier. The EMG signals could thus be heard and were used to guide the needle placement. An attached EMG recorder provided permanent records. Each muscle was probed with a needle electrode until the site of maximum electrical discharge was located, which was assumed to be the site of the highest concentration of motor end-plates. It was here that the injection of the toxin was performed. The wound was flushed with saline and closed with chromic suture. The operative site was drained and a dressing was applied. The dogs were reexamined when awake, then they were taken to a recovery cage. Vital signs were closely monitored. In the animals in which a nerve resection was done, a 1-cm segment of the recurrent laryngeal nerve was removed at the level of the midcervical trachea 1 month prior to muscle injection. All drains were removed on the fourth postoperative day.

Measurements. The angles of the cords in the control and experimental groups were measured in three positions: resting, maximum abduction, and maximum adduction. This was accomplished using the anterior commissure as the center of rotation of an arc created by the vocal cords. The degrees of arc in which the cords rested or to which they moved were measured using a goniometer with a vernier scale (Fig 1). To simplify the measurements, prints

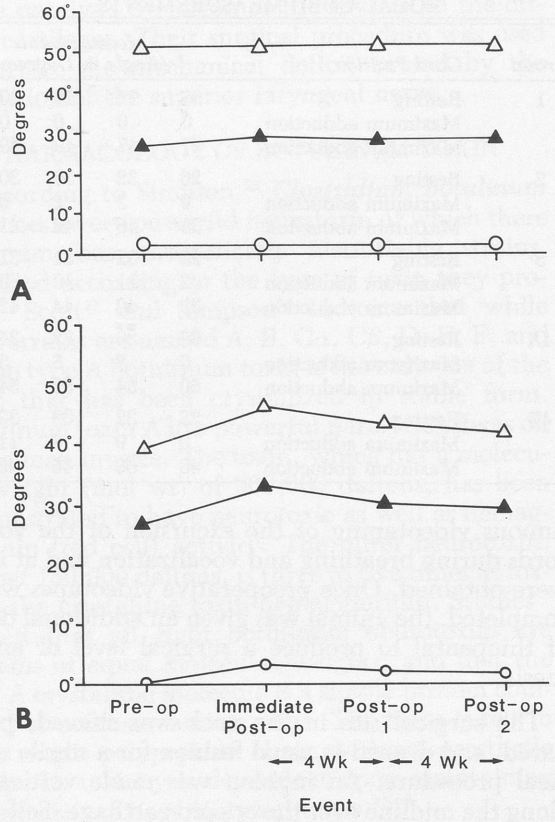

Fig 2. Vocal cord positions. A) Group 1. Lack of effect on mean true vocal cord angle when saline is injected as control into cricothyroid muscle. Angle is changed from preoperative for all three positions. B) Group 2. Slight increase in mean true vocal cord angle for all three cord positions after unilateral injection of toxin into cricothyroid muscle. ○ — maximum adduction, ▲ — resting, △ — maximum abduction.

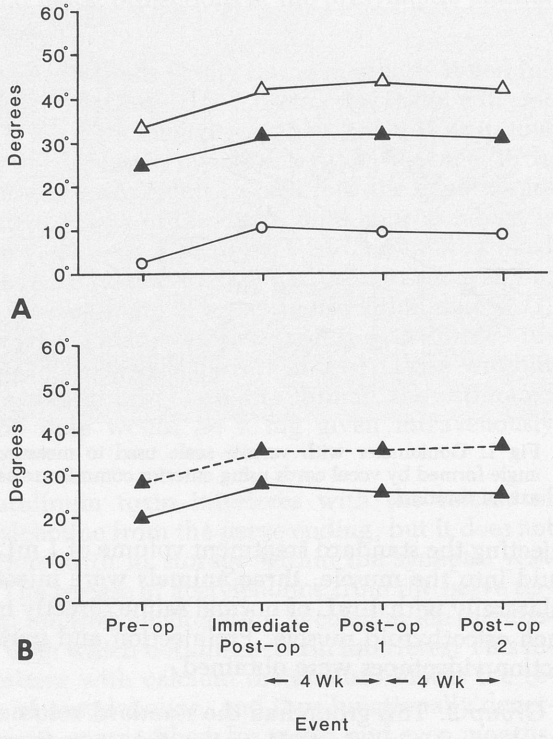

Fig 3. Group 3. Unilateral injection of toxin into subjects with right true vocal cord paralysis. A) Mean angle increase of true vocal cords for three specified positions. ○ — maximum adduction, ▲ — resting, △ — maximum abduction. B) Comparison of ipsilateral (----) and contralateral (——) injections of toxin. Ipsilateral injection is more effective in increasing angle. ▲ — resting angle.

of the laryngeal image were obtained on a video display printer. While the number of animals used in this preliminary study is small, there appears to be a definite trend as a result of the use of botulinum toxin injected into the cricothyroid muscle.

RESULTS

All 12 animals did well with no intraoperative or postoperative complications, morbidity, or deaths. Cinelaryngoscopy with video documentation was performed in the immediate postoperative period and 4 weeks thereafter. Recovery from anesthesia was rapid, with ambulation and normal feedings within 2 hours after the surgical procedure. None of the animals experienced dysphagia, aspiration, postoperative infection, or toxic reaction to the drug injection. The mean values for each group of vocal cord angle were calculated for each of the three vocal cord positions and were plotted on graphs. See the Table for data.

Group 1. There were three animals in this group in which bilateral saline control injections were given. The mean angle of the vocal cords after injection of saline in all three positions was no different from the preoperative values. Therefore, injection of normal saline into each cricothyroid muscle had no effect on vocal cord position (Fig 2A).

Group 2. In the three animals that received unilateral injections of botulinum toxin, the mean angles of the vocal cords at rest, maximum abduction, and maximum adduction were larger after the injections and appeared to drift slowly back toward the preoperative values after several months. This indicates that the botulinum toxin temporarily lateralizes the vocal cords (Fig 2B).

Group 3. In the two animals that had previous unilateral recurrent nerve sections and received unilateral injections of the toxin, the preoperative cord positions were altered by the unilateral paralysis, as was expected. The overall mean effect of the toxin was the same as that in group 2, in which there was an apparent increase in all the angles at the specified positions (Fig 3A). In the unilateral paralyzed larynx, the injection in the same side as the recurrent laryngeal paralysis clearly was far more effective in lateralizing the cords than the contralateral normal side injection (Fig 3B). Therefore, by injecting the contralateral side, effective opening of the larynx was not as good.

Group 4. This group of four animals was divided into those with high and low dose injections. The

initial low doses were ineffective in producing lateralization of the vocal cords (Fig 4A). The animals that received high dose bilateral injections of the toxin followed the same pattern of increased angle of the vocal cords at the resting, maximum abduction, and maximum adduction positions as in groups 2 and 3 (Fig 4B). As could be predicted, the bilateral cricothyroid muscle injection was more effective than the unilateral injection in lateralizing the vocal cords and thus provided a larger airway in all three positions (Fig 4C). None of the dogs was noted to aspirate or had feeding or pulmonary problems despite the increased resting and adduction angle of the true vocal cords.

The dose-response curves suggest that the most effective dose of the toxin as yet may not have been reached. The jump in effectiveness of the toxin between 0.7 U/0.45 kg and 0.9 U/0.45 kg may be an artifact. If the values at 0.6 and 0.7 U/0.45 kg are disregarded as variations between animals and only the 0.1, 0.5, 0.9, and 1.1 values are used, a best-fit line gives a fairly linear dose-response curve, which suggests that a dose plateau actually has not been reached (Fig 5). At this point in the preliminary study it is impossible to determine an accurate dose-versus-duration curve. This is due to the long duration of the higher dosage and the short period of this study.

DISCUSSION

The severe and devastating effects of midline paralysis of the larynx are well documented, its morbidity is extensive, and its cost to patient and society is well known. The literature is replete with many forms of therapy that have been related in the literature review, and the search for better methods of relief of these symptoms continues. The most consistent successes have been with arytenoidectomy performed by many techniques.

Prior to this study, chemical and biochemical methods were not used in the treatment of laryngeal disease of neurologic origin. The continued search for a better method represents dissatisfaction with the current treatment of midline paralysis of the larynx.

The primary premise for the use of a neurotoxin injected locally to produce muscle paralysis is based on the anatomy and function of the cricothyroid muscle. When stimulated, the cricothyroid muscle, served by the external branch of the superior laryngeal nerve, produces the following effects upon the larynx: 1) it approximates the cricoid ring to the lower border of the thyroid cartilage, 2) it effects elevation and deviation of the cricoid ring toward the stimulated side, and 3) it elongates the vocal cord and approximates the vocal processes.

Cutting the external division of the superior laryngeal nerve or removing the cricothyroid muscle produces gradual lateral bowing of the ipsilateral vocal cord and thereby opens the airway. The rationale for eliminating the cricothyroid muscle is to abolish the tension of the vocal cord produced by this muscle and thus to change it from the midline to a more lateral position. The prerequisites for this

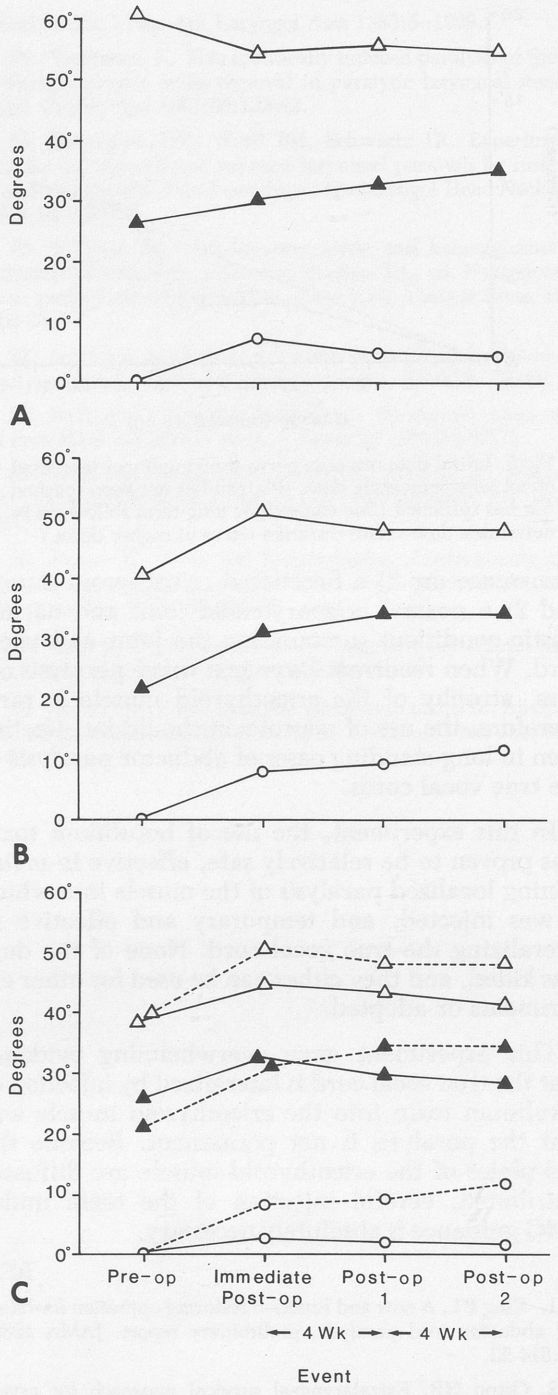

Fig 4. Group 4. Bilateral injection of toxin into cricothyroid muscle. A) Equivocal effects of early low dose (7 U/0.45 kg). B) Dramatic increase in true vocal cord angle for injection of higher dose toxin (mean 65 U/0.45 kg). C) Comparison of dramatic difference between bilateral (----) injection and unilateral (——) injection. Bilateral injection appears to produce larger airway. ○ — maximum adduction, ▲ — resting, △ — maximum abduction.

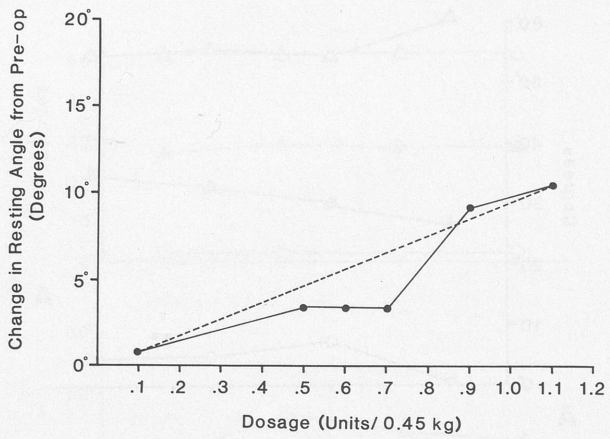

Fig 5. Initial dose response curve showing linear increased effect with increasing dose. (Plateau has not been reached nor has sufficient time elapsed for long-term follow-up to determine dose-versus-duration curve of higher doses.)

occurrence are 1) a functional cricothyroid muscle and 2) a normal cricoarytenoid joint and normal elastic conditions surrounding the joint and vocal cord. When recurrent laryngeal nerve paralysis occurs, atrophy of the cricothyroid muscle is rare; therefore, the use of neurotoxin should be effective even in long-standing cases of abductor paralysis of the true vocal cords.

In this experiment, the use of botulinum toxin was proven to be relatively safe, effective in maintaining localized paralysis of the muscle into which it was injected, and temporary and effective in lateralizing the true vocal cord. None of the dogs was killed, and they either can be used for other experiments or adopted.

This experiment gave overwhelming evidence that the true vocal cord is lateralized by injection of botulinum toxin into the cricothyroid muscle and that the paralysis is not permanent. Because the end-plates of the cricothyroid muscle are diffusely distributed, careful injection of the toxin under EMG guidance is absolutely necessary.

It is important to note that the dog's larynx most closely resembles that of the human. However, dosage requirements of the toxin are higher because the dog probably has antibodies to this toxin. These experiments attempted to establish the dosage of toxin levels required in the dog.

For the otolaryngologist, this experimental study opens a number of possibilities for the use of neurotoxins and other chemicals or drugs to correct the deficiencies and crippling effects of many neuropathic lesions of the head and neck. It is encouraging to contemplate how these neurotoxic drugs or chemicals, not yet tried, can reverse the morbidity of neurologic disorders so commonly seen by the otolaryngologist. These drugs can be used without changing the normal anatomy of the organ and thus can avoid or reduce the morbidity of the disease and/or the surgical procedures used for its correction. It is also encouraging that the use of these drugs is temporary and possibly reversible.

Voice quality cannot be evaluated in dog experiments. It is likely that voice changes in patients treated with botulinum toxin will be variable depending upon vocal cord position and may be significant only in professional singers.

Botulinum toxin can change laryngomechanics, at least for a defined period of time. The extent of this change is probably dose-related. Prolonged effects can be achieved by multiple injections of the toxin. While the open surgical procedure was used in this experiment, percutaneous injection of the toxin with EMG guidance has been proven effective for other muscle groups.

The effectiveness of injection of botulinum toxin to correct the obstructive phenomenon of bilateral abductor laryngeal paralysis under all types of activity and stress must await clinical trials. Botulinum toxin may be valuable in further experimentation on neuropathies of the larynx.

REFERENCES

1. King BT. A new and function restoring operation for bilateral abductor cord paralysis, preliminary report. JAMA 1939; 112:814-23.

2. Orton HB. Extralaryngeal surgical approach for arytenoidectomy: bilateral abductor paralysis of the larynx. Ann Otol Rhinol Laryngol 1944;53:302-7.

3. Woodman D. A modification of the extralaryngeal approach to arytenoidectomy for bilateral abductor paralysis. Arch Otolaryngol 1946;43:63-5.

4. Woodman D. Bilateral abductor paralysis, a survey of 521 cases of arytenoidectomy via the open approach as reported by ninety surgeons. Arch Otolaryngol 1953;58:150-3.

5. New G, Childrey J. Paralysis of the vocal cords. Arch Otolaryngol 1932;16:143-52.

6. Thornell WC. Intralaryngeal arytenoidectomy in bilateral abductor vocal cord paralysis. Surg Gynecol Obstet 1952;95:63-6.

7. Hoover WB. Bilateral abductor paralysis; operative treatment by submucous resection of the vocal cords. Arch Otolaryngol 1932;15:339-55.

8. Fraser CH. The treatment of paralysis of the recurrent nerve by nerve anastomosis. Ann Surg 1924;79:161-71.

9. Lahey FH. Suture of the recurrent laryngeal nerve for bilateral abductor paralysis. Ann Surg 1928;87:481-4.

10. Kleinsasser O. Microlaryngoscopy and endolaryngeal microsurgery. Philadelphia: WB Saunders Co, 1968:120-7.

11. Tucker HM. Human laryngeal reinnervation. Laryngoscope 1976;86:769-79.

12. Newman MH, Work WP. Arytenoidectomy revisited. Laryngoscope 1976;86:840-9.

13. Tucker HM. Human laryngeal reinnervation; long-term experience with the nerve-muscle pedicle technique. Laryngoscope 1978;88:598-604.

14. Eskew JR, Bailey BJ. Laser arytenoidectomy for bilateral vocal cord paralysis. Otolaryngol Head Neck Surg 1983;91:294-8.

15. Kleinsasser O, Nolte E. Endolaryngeale Arytaenoidektom-

ie und submukose partielle Chordektomie bei bilateralen Stimmlippenlahmungen. Laryngol Rhinol Otol (Stuttg) 1981;60:397-401.

16. Sanders I, Aviv J, Biller HF. Transcutaneous electrical stimulation of the recurrent laryngeal nerve; a method of controlling vocal cord position. Otolaryngol Head Neck Surg 1986; 96:152-7.

17. Baldissera F, Cantarella G, Marini G, Ottaviani F. Restoring abduction of paralyzed vocal cords in the cat using selective laryngeal reinnervation by phrenic motoneurons. Laryngoscope 1986;96:1399-404.

18. Otto RA, Templer J, Davis W, Homeyer D, Stroble M. Coordinated electrical pacing of vocal cord abductors in recurrent laryngeal nerve paralysis. Otolaryngol Head Neck Surg 1985;93: 634-8.

19. Otto RA, Davis W. Functional electrical stimulation for the treatment of bilateral recurrent laryngeal nerve paralysis. Otolaryngol Head Neck Surg 1986;95:47-51.

20. Broniatowski M, Tucker HM, Kaneko S, Jacobs G, Nose Y. Laryngeal pacemaker part I. Electronic pacing of reinnervated strap muscles in the dog. Otolaryngol Head Neck Surg 1986;94: 41-4.

21. Freije J, Malmgren LT, Gacek RE. Motor end-plate distribution in the human lateral cricoarytenoid muscle. Arch Otolaryngol Head Neck Surg 1986;112:176-9.

22. Tschiassny K. Studies concerning the action of the musculus cricothyroideus. Laryngoscope 1944;54:589-604.

23. Hooper FH. Experimental researches on the tension of the vocal bands. Trans Am Laryngol Assn 1883;5::1929.

24. Tschiassny K. Therapeutically induced paralysis of the cricothyroid muscle or its removal in paralytic laryngeal stenosis. Arch Otolaryngol 1957;65:133-42.

25. Thompson JW, Ward PH, Schwartz IR. Experimental studies for correction of superior laryngeal paralysis by fusion of the thyroid to the cricoid cartilages. Otolaryngol Head Neck Surg 1984;92:498-508.

26. Simpson LL. The neuroparalytic and hemagglutinating activities of botulinum toxin. In: Simpson LL, ed. Neuropoisons: their pathophysiological actions. New York: Plenum Press, 1971: 303-24.

27. Scott AB. Botulinum toxin injection of eye muscles to correct strabismus. Trans Am Ophthalmol Soc 1981;79:735-69.

28. Stefanye D, Schantz EJ, Spero L. Aminoacid composition of crystalline botulinum toxin. J Bacteriol 1967;94:277-8.

29. Kelly RB, Deutsch JW, Carlson SS, Wagner JH. Biochemistry of neurotransmitter release. Ann Rev Neurosci 1979;2:398-446.

30. Heuser JE, Reese TS. Redistribution of intramembranous particles from synaptic vesicles; direct evidence of vesicle recycling. Anat Rec 1975;181:374-82.

31. Katz B. The release of neurotransmitter substances. Liverpool, England: University Press, 1969.

32. Boroff DA, Das Gupta BR. Botulinum toxin. In: Aii SJ, ed. Microbial toxins. Vol 2A. New York: Academic Press Inc, 1971: 1-68.

MALIGNANT LARYNGEAL EPITHELIAL TUMORS AND LYMPH NODE INVOLVEMENT: THERAPEUTIC AND PROGNOSTIC CONSIDERATIONS

ALFIO FERLITO, MD

PADUA, ITALY

The relationship among various malignant epithelial tumors of the larynx, with or without their respective lymph node and visceral metastases, is discussed. The tumors considered include squamous cell carcinoma, verrucous squamous cell carcinoma, spindle cell squamous carcinoma, small cell carcinoma, atypical carcinoma, mucoepidermoid carcinoma, adenoid cystic carcinoma, and primary malignant melanoma. Other, rarer, malignant epithelial neoplasms of the larynx are only mentioned. The choice of therapy should be determined by tumor stage, oncotype, and patient status.

KEY WORDS — laryngeal metastases, lymphogenous and hematogenous metastases, malignant laryngeal cancers.

The presence of cervical lymph node metastases is the most important factor in the choice and success of treatment in cancer of the larynx.

Malignant laryngeal neoplasms may spread by direct infiltration or by the lymphatic or blood systems. Tumor dissemination may be affected by various factors, such as the site of the primary tumor, the oncotype, the degree of cellular differentiation, the presence or absence of certain barriers, and biologic factors related to the tumor-host relationship, which may act independently or jointly in cancer patients.[1]

Direct infiltration is self-explanatory: the tumor extends directly into the adjacent normal structures and may infiltrate the glossoepiglottic valleculae, the hypopharynx, the thyroid, and the trachea. Occasionally, the cancer may invade the prelaryngeal muscles, subcutaneous tissues, and the overlying skin.

Metastatic spread, however, usually occurs via either the lymphatic or blood systems. The pattern of the spread varies with the histologic type of the primary malignancy. Clinical studies have shown that malignant laryngeal tumors frequently show definite metastatic patterns. This tendency for tumors of a particular histologic type to metastasize to specific structures is also a characteristic of experimental animal tumor systems. Some neoplasms metastasize through the lymphatic system whereas others do not, and in some malignancies blood and lymphatic metastatic spread occur with almost equal frequency. A careful histologic diagnosis, therefore, is an important element in evaluating the spread of the cancer. Often, all cancers of the larynx are treated in the same way, regardless of their histologic characteristics. The diagnosis of cancer must be based on histologic study of the tumor, and the cellular type of the lesion should be recorded. The biologic behavior varies from one type of cancer to another, and therefore only similar types should be compared with one another. Furthermore, neoplasms are not always composed of a uniform population of cells, but may consist of various cell subpopulations and show evidence of clonal heterogeneity. This fact explains variations in their biologic behavior and response to therapy.

SQUAMOUS CELL CARCINOMA

Squamous cell carcinoma has a high tendency to metastasize to the cervical lymph nodes in the form of emboli. In the great majority of cases, few lymph nodes are involved. Generally, there is a relationship between the degree of structural differentiation and the incidence of lymph node metastasis.[2] Poorly differentiated carcinomas show a greater aggressiveness than well-differentiated or moderately differentiated neoplasms.[3] The grade of differentiation of a neoplasm should not be confused with the histologic grading. Factors allowing for a better assessment of the histologic grading of malignancies are the following: 1) degree of structural differentiation, 2) cellular anaplasia or pleomorphism, 3) mitotic activity (frequency and abnormality of mitotic figures), 4) expansive or infiltrative growth, 5) necrosis, and 6) invasion (lymphatic and vascular).

The grade of morphologic differentiation represents only one biologic manifestation of the cancer, and in order to achieve a complete evaluation of the biologic behavior of the tumor, the oncotype with its histologic grade should be considered in conjunction with other important prognostic factors, such as the site and size of the primary neoplasm, the extension of the neoplasm, the nature of the tumor margins (infiltrating or pushing), the growth rate of the neoplasm, the performance status, the immuno-

From the Department of Otolaryngology, University of Padua, Padua, Italy.

Presented at the meeting of the American Laryngological Association, Denver, April 25-26, 1987.

REPRINTS — A. Ferlito, MD, Dept of Otolaryngology, University of Padua, Nuovo Policlinico, Via Giustiniani, 2, 35100 Padua, Italy.

Fig 1. Verrucous squamous cell carcinoma of larynx (H & E, original x16). Note abundance of inflammatory cells surrounding pushing margins of neoplasm.

competence of the host, and the patient's age. Another important factor that may influence survival is the presence of synchronous or metachronous primary cancers in the head and neck area or elsewhere, especially in the esophagus, lung, and oral cavity. The presence of nonneoplastic diseases may also influence survival.

With regard to lymph node metastases, the prognosis depends more on the presence of extracapsular spread, with the resulting increased possibility of distant metastases, than the number of the involved lymph nodes with an intact capsula. Patients with extracapsular spread should be treated with postoperative radiation therapy. Combined therapy may allow the long-term control or cure of these metastases. The level of node involvement is also important. Metastases to lymph nodes in the anterior inferior and posterior inferior cervical triangles are associated with a poor prognosis.[4]

Bloodstream metastases may occur in the later stages of the disease, and cervical lymph nodes are always involved in all cases showing widespread dissemination. The organs and structures most commonly involved are the lungs, liver, bones, brain, skin, and mediastinal lymph nodes.

The lymph most frequently provides the means for metastatic spread in squamous cell carcinoma. Neck dissection is indicated in the presence, whether suspected or proved, of a metastatic tumor involving the cervical lymph nodes.

In a patient with laryngeal cancer, the suspected presence of a lung metastasis, without cervical lymph node metastases, probably indicates the presence of another primary tumor.[5]

Sometimes, the presence of cervical lymph node metastases is not connected with laryngeal cancer, but with other malignant neoplasms arising in the thyroid gland or other structures. In rare cases, one or several lymph nodes may simultaneously contain laryngeal and thyroid metastases. Very rarely, metastases from laryngeal cancer to cervical lymph nodes that are also affected by chronic lymphocytic leukemia are reported.[6]

VERRUCOUS SQUAMOUS CELL CARCINOMA

Verrucous squamous cell carcinoma is an unusual, distinct, pathologic and clinical variant of well-differentiated squamous cell carcinoma (Fig 1).[7-10] It is difficult to assess the true frequency of this lesion, since it is often classified with squamous carcinoma. In my experience, the incidence is about 3% to 4% of all laryngeal malignant neoplasms. Multifocal occurrence may be seen at times. Mitoses are rare. Cytologic criteria of malignancy are lacking, but the nuclei of the cells of this tumor have abnormal quantities of nucleic acid.[11] It is characterized by a local invasiveness, nonmetastatic behavior, and a favorable prognosis, when adequate surgical treatment is received early enough.[12]

The transformation of a verrucous carcinoma to an anaplastic cancer following radiation therapy is a rare but possible complication in this as in other sites. Also, radiation therapy may cause a change in the character of the tumor, which may metastasize.[13] Abramson et al[14] believe that radiotherapy should not be given to patients with verrucous carcinoma of the larynx unless the potential consequences are fully explained, because of its potential to activate or alter human papillomavirus-16–related DNA sequences. The most important contraindication for radiation therapy appears to be the lack of local control of the tumor, in particular when it is large and has a high recurrence rate.[12]

The selection of treatment should be made on the basis of the effectiveness of the modality, and therefore surgery is the treatment of choice of this tumor, although some authors[15-18] have reported the effectiveness of radiotherapy.

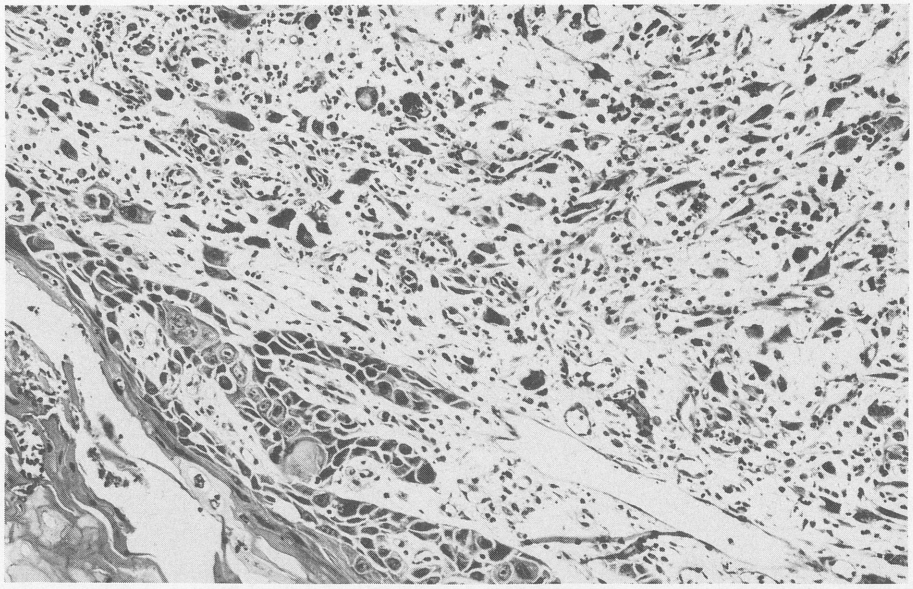

Fig 2. Spindle cell squamous carcinoma of larynx (H & E, original x40). Carcinomatous component is surrounded by atypical spindle cells.

The involvement of regional lymph nodes and the presence of distant metastases in cases of pure laryngeal verrucous squamous cell carcinoma have not been reported to date. Therefore, elective or radical neck dissection is not indicated in this tumor, even in the presence of enlarged and tender lymph nodes. In fact, biopsy and surgical specimens after neck dissection in these cases have revealed only an intense inflammatory reaction.

SPINDLE CELL SQUAMOUS CARCINOMA

Spindle cell squamous carcinoma is an unusual, controversial, biphasic variant of squamous cell carcinoma (Fig 2). In my experience the incidence of this lesion is about 1%. I suspect that most neoplasms classified as primary laryngeal sarcomas in the past were, in fact, spindle cell squamous carcinomas showing multiform features and occasionally an osseous or chondroid metaplasia. Metastases may consist of epithelial, sarcomatous, or mixed patterns, and are not less common than those of the most common squamous cell carcinoma.[19] The first metastases occur in the cervical lymph nodes, whereas later distant metastases occur in several organs (eg, lungs, liver, bones, kidneys, heart).

Laryngectomy, either partial or total, appears to be the treatment of choice. A high recurrence rate is associated with radiation therapy. The spindle cell squamous carcinoma cannot be considered a "favorable" type of tumor.

SMALL CELL CARCINOMA

Small cell carcinoma is an uncommon neuroendocrine tumor associated with frequent, early, widespread metastases and a rapid clinical course.[20-22] The most common sites of metastatic spread are the cervical lymph nodes, liver (Fig 3), lung, bone, and bone marrow. Metastases to the CNS are rare and

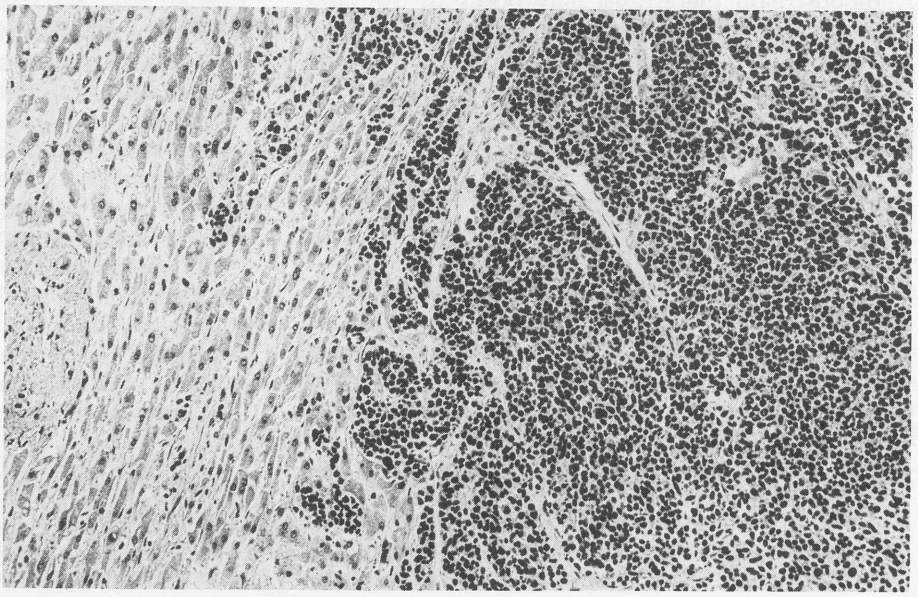

Fig 3. Metastatic deposit in liver of small cell carcinoma of larynx (H & E, original x40). Note hyperchromatic nuclei.

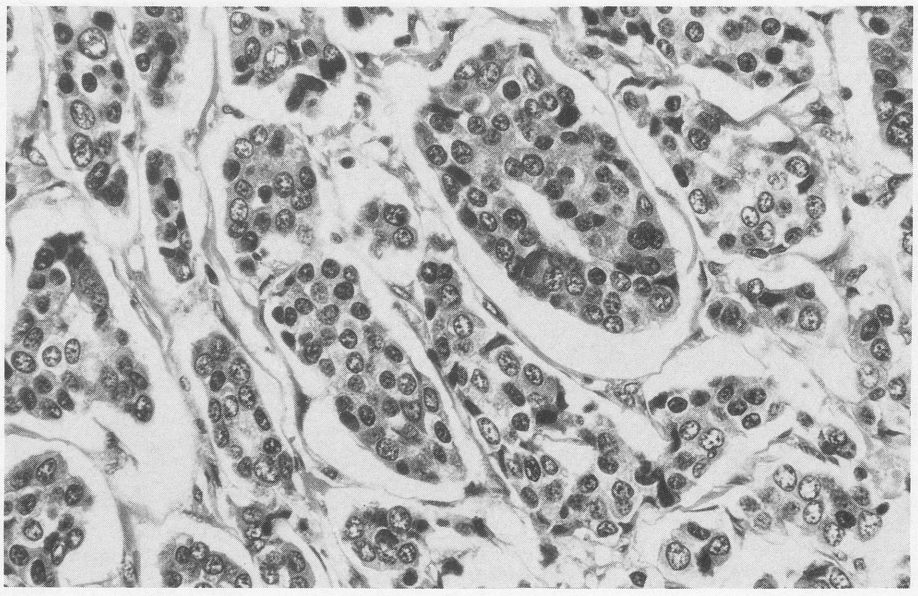

Fig 4. Atypical carcinoid tumor of larynx (H & E, original x100). Nuclear structure is unlike that of small cell carcinoma.

occur as a preterminal event. Tumor staging is therefore mandatory for therapeutic and prognostic reasons, and also to reveal occult metastases. It should include the following: chest radiographs, computed tomography of the lungs, panendoscopy, bone scintigraphy, liver echotomography, iliac crest bone marrow aspiration and biopsy, CT of the brain, and laboratory investigations.

A combination of systemic chemotherapy and radiation therapy appears to offer the least disabling and most efficacious form of current therapy.[23] Prophylactic cranial irradiation is not indicated. The survival of patients treated in this way may be significantly improved, and some patients may be cured.[24]

The extent of the disease at the time of diagnosis and the performance status of the patients are the most important factors in survival. The biologic characteristics of the neoplastic cells themselves may play a role in the response to therapy.

CARCINOID TUMORS

Carcinoid tumors are distinguished from other neoplasms of the larynx by their various histologic features, histochemical findings of argyrophilic and, rarely, argentaffinic granules, and by electron microscopic demonstration of neurosecretory granules. I know of about 40 cases of these tumors in the larynx, of which only five were typical.

Atypical carcinoids (Fig 4), also called neuroendocrine carcinomas, usually exhibit aggressive behavior and have a poor prognosis. Cervical lymph node metastases are very common. Other sites of metastases include skin, subcutaneous tissues, distant lymph nodes, lungs, mediastinum, bones, liver, heart, and pancreas.

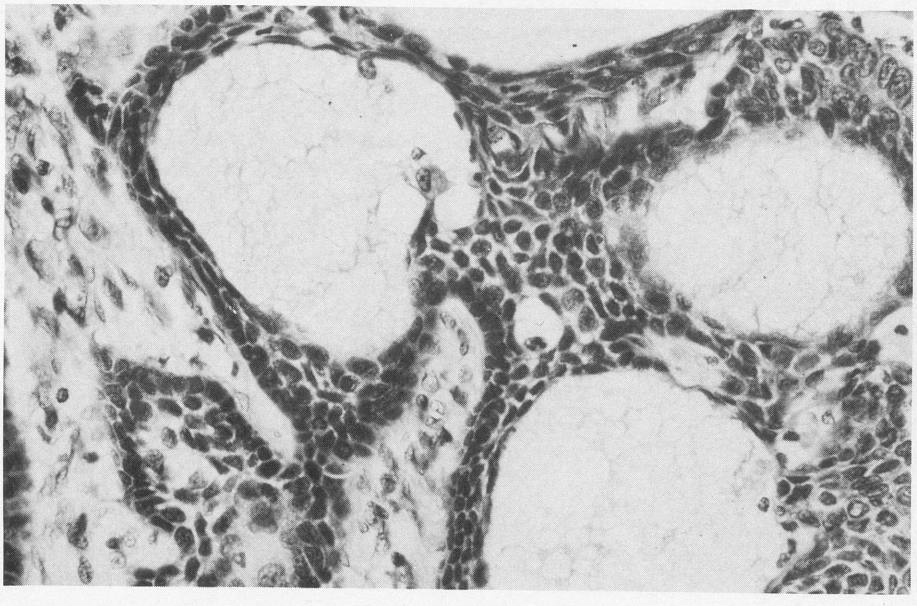

Fig 5. Mucoepidermoid carcinoma of larynx (H & E, original x100). Tumor shows nests of squamous epithelium and glandular structures containing mucous secretion.

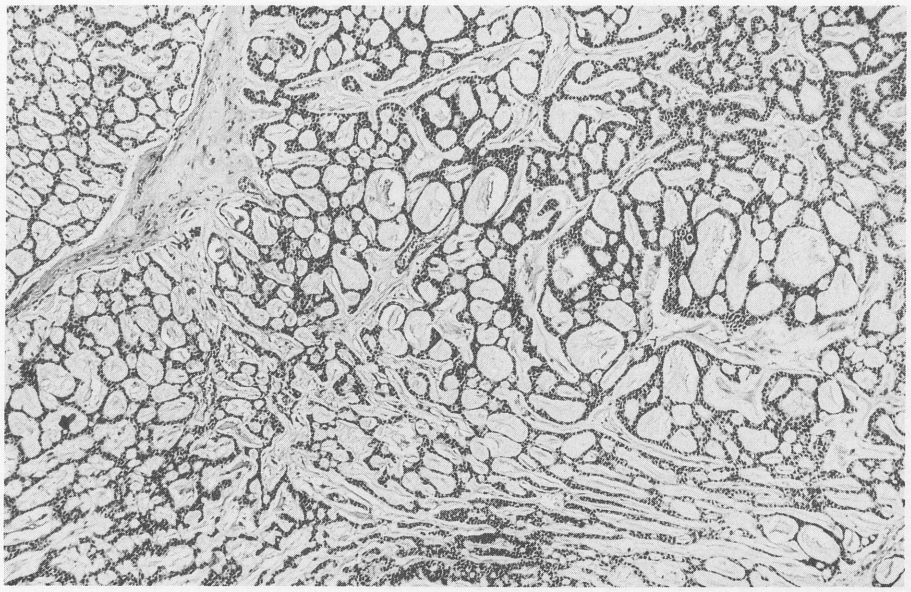

Fig 6. Adenoid cystic carcinoma of larynx (H & E, original x16). Note cribriform pattern of tumor.

These neoplasms should be treated surgically.[25-27] Usually they are radioresistant. Neck dissection is indicated, because of the high likelihood of cervical lymph node metastases.

MUCOEPIDERMOID CARCINOMA

Mucoepidermoid carcinoma is the most common malignant neoplasm of the laryngeal seromucinous glands (Fig 5). The tumor may metastasize to the cervical lymph nodes, and visceral metastases may also occur, in particular in the lungs. The primary mode of treatment for these tumors is complete surgical removal of the primary lesion.[28] Neck dissection would appear justified only if clinically palpable metastases are present at the time of surgery. These tumors are only moderately responsive to radiotherapy.

ADENOID CYSTIC CARCINOMA

Adenoid cystic carcinoma is a rare neoplasm of the larynx (Fig 6), and I have observed only two cases. The prognosis is better than for common squamous cell carcinoma or for other adenocarcinomas. Acceptable and well-documented cases of laryngeal adenoid cystic carcinoma with cervical lymph nodes have not been reported. This neoplasm has a remarkable capacity for local recurrence and hematogenous spread, which rarely occurs in laryngeal adenoid cystic carcinoma. The lungs, bones, brain, and liver are the most common sites of visceral metastases.[29] This lesion, therefore, metastasizes more like a sarcoma than a carcinoma. Metastases are often a late phenomenon and are often heralded by severe local recurrences of the primary lesion. A peculiar feature of this tumor is the great tendency to show perineural and neural infiltration. The tumor may be confused with salivary duct carcinoma (Fig 7), which may produce a pseudocribriform pattern.[30]

Partial or total laryngectomy remains the treat-

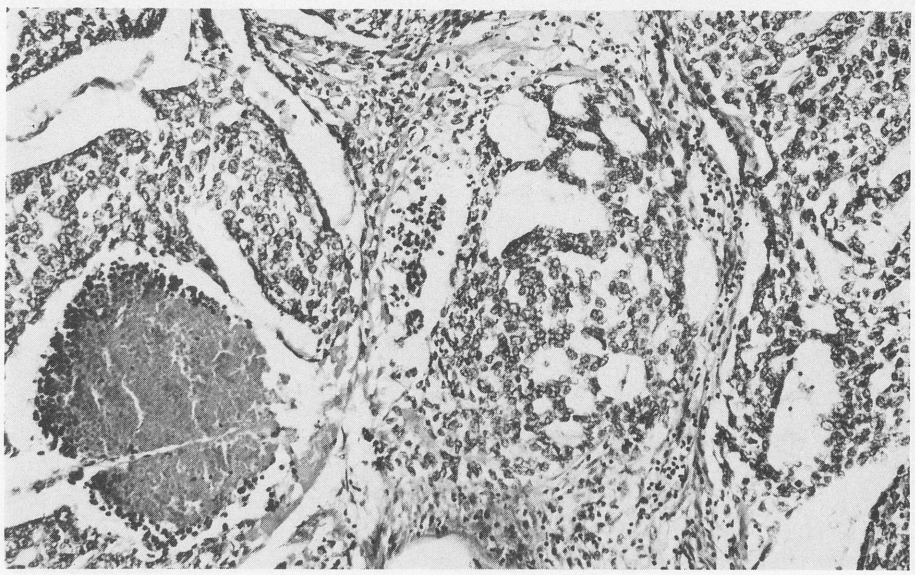

Fig 7. Salivary duct carcinoma of larynx (H & E, original x40). Note papillary, cribriform, and comedo patterns. This neoplasm may be misdiagnosed as adenoid cystic carcinoma.

TABLE 1. NECK DISSECTION ACCORDING TO ONCOTYPE

Laryngeal Epithelial Tumor	*Neck Dissection May Be Performed*
Squamous cell carcinoma	Yes
Spindle cell squamous carcinoma	Yes
Atypical carcinoid	Yes
Mucoepidermoid carcinoma	Yes
Primary malignant melanoma	Yes
Verrucous squamous cell carcinoma	No
Small cell carcinoma	No
Adenoid cystic carcinoma	No

ment of choice at present. The presence of lung metastases need not discourage surgical treatment of the primary lesion, as single or multiple lung metastases may remain silent even for a decade or more. Resection of a solitary pulmonary metastasis may be justified. Neck dissection is not indicated in laryngeal adenoid cystic carcinoma, because the neoplasm does not metastasize to the cervical lymph nodes. Regional lymph node spread by direct local extension was recorded in these tumors when the submandibular gland was involved. Radiation therapy may produce temporary regression, but does not cure the disease.

The success of the treatment and final prognosis cannot be evaluated in 5-year terms, but only after 15 or 20 years. It is important to emphasize that the presence or absence of the tumor at the surgical margins is an important prognostic factor.

MELANOMA

Primary melanoma of the larynx is a well-documented but rare entity.[31,32] Atypical junctional changes are usually seen. Before diagnosing a lesion as a primary melanoma of the larynx, a metastatic melanoma should always be considered. Also, although the exact incidence of primary and metastatic melanomas involving the larynx is difficult to assess, secondary laryngeal melanomas are more frequent than primary ones. We have recorded about 50 cases of melanoma metastasizing to the larynx (A. Ferlito, G. Caruso, and G. Recher, unpublished observations).

Radical surgery is recommended as the primary method in the absence of distant metastases, with or without adjuvant radiotherapy or chemotherapy. Therapeutic neck dissection is indicated for patients with no evidence of distant metastatic disease. Unfortunately, lymph node metastases usually indicate an advanced and uncontrolled or uncontrollable neoplasm.

OTHER MALIGNANT TUMORS

Other malignant tumors have been reported in the larynx, ie, lymphoepithelioma,[33,34] giant cell carcinoma,[35,36] clear cell carcinoma,[37] adenosquamous carcinoma,[38,39] malignant mixed carcinoma,[19] acinic cell carcinoma,[40,41] salivary duct carcinoma,[30] and malignant paraganglioma.[42] Because these tumors are extremely rare and have been segregated only recently as separate types, we do not know their biologic behavior.

TABLE 2. MOST COMMON METASTATIC SITES OF LARYNGEAL EPITHELIAL TUMORS

Histologic Type	*Metastatic Sites*
Squamous cell carcinoma	Lymph nodes, lungs, liver, bones
Verrucous squamous cell carcinoma	Nonmetastatic behavior
Spindle cell squamous carcinoma	Lymph nodes, lungs, liver, bones
Small cell carcinoma	Lymph nodes, liver, lungs, bones
Atypical carcinoid	Lymph nodes, skin, subcutaneous tissues, lungs, bones, liver
Mucoepidermoid carcinoma	Lymph nodes, lungs
Adenoid cystic carcinoma	Lungs, bones, brain, liver
Primary malignant melanoma	Lymph nodes, bones, lungs, liver

CONCLUSIONS

The laryngeal epithelia give rise to a wide range of histologically diverse neoplasms. The different oncotypes are associated with unpredictable patterns of clinical behavior, and they constitute, together with other factors, discriminatory elements in the choice of treatment. Their recognition is of paramount importance, because it influences the selection of therapy. All patients with laryngeal cancer are often considered wrongly to have the same disease. In fact, each tumor is a distinct entity, and treatment depends upon a correct diagnosis. The oncotype should be considered a guide to treatment selection. It is understood, for instance, that the elective treatment for laryngeal verrucous carcinoma is surgery, whereas the same treatment may be harmful or ineffective in other tumors. Neck dissection may be performed in some malignant epithelial tumors of the larynx (Table 1), whereas it is not indicated in others, such as verrucous squamous cell carcinoma and adenoid cystic carcinoma, in which the neoplasm usually does not metastasize to cervical lymph nodes (Table 2).

In conclusion, the treatment and the prognosis of laryngeal cancer depend upon several factors and cannot be based solely upon the site and extent of the lesion. The oncotype is an important factor in deciding on the most suitable and satisfactory treatment. The biologic behavior of each oncotype is different, and the appropriate therapy varies accordingly. Therapy decisions should be made after careful assessment of the morphologic characteristics of the lesion and the status of the patients, while bearing in mind the lesion's responsiveness to each possible therapy.

REFERENCES

1. Ferlito A. Spread of cancer of the larynx. In: Ferlito A, ed. Cancer of the larynx. Vol 2. Boca Raton, Fla: CRC Press, 1985: 109-41.

2. McGavran MH, Bauer WC, Ogura JH. The incidence of cervical lymph node metastases from epidermoid carcinoma of the larynx and their relationship to certain characteristics of the

primary tumor. A study based on the clinical and pathological findings in 96 patients treated by primary en bloc laryngectomy and radical neck dissection. Cancer 1961;14:55-66.

3. Ferlito A. Histological classification of larynx and hypopharynx cancers and their clinical implications. Pathologic aspects of 2,052 malignant neoplasms diagnosed at the ORL Department of Padua University from 1966 to 1976. Acta Otolaryngol [Suppl] (Stockh) 1976:suppl 342.

4. Sessions DG. Surgical pathology of cancer of the larynx and hypopharynx. Laryngoscope 1976;86:814-39.

5. Ferlito A, Di Bonito L. Primary cancer of the larynx associated with primary lung cancer. Report of 21 cases, 14 with autopsy findings and 7 biopsies. ORL J Otorhinolaryngol Relat Spec 1976;38:230-45.

6. Ferlito A, Recher G, Visonà A. Laryngeal cancer metastatic to lymph nodes with lymphocytic leukaemia. J Laryngol Otol 1986;100:233-7.

7. Kraus FT, Perez-Mesa C. Verrucous carcinoma: clinical and pathologic study of 105 cases involving oral cavity, larynx and genitalia. Cancer 1966;19:26-38.

8. Van Nostrand AWP, Olofsson J. Verrucous carcinoma of the larynx. A clinical and pathologic study of 10 cases. Cancer 1972;30:691-702.

9. Batsakis JG, Hybels R, Crissman JD, Rice DH. The pathology of head and neck tumors: verrucous carcinoma. Head Neck Surg 1982;5:29-38.

10. Biller HF, Ogura JH, Bauer WC. Verrucous cancer of the larynx. Laryngoscope 1971;81:1323-9.

11. Ferlito A, Antonutto G, Silvestri F. Histological appearances and nuclear DNA content of verrucous squamous cell carcinoma of the larynx. ORL J Otorhinolaryngol Relat Spec 1976;38: 65-85.

12. Ferlito A, Recher G. Ackerman's tumor (verrucous carcinoma) of the larynx. A clinicopathologic study of 77 cases. Cancer 1980;46:1617-30.

13. Smith RRL, Kuhajda FP, Harris AE. Anaplastic transformation of verrucous carcinoma following radiotherapy. Am J Otolaryngol 1985;6:448-52.

14. Abramson AL, Brandsma J, Steinberg B, Winkler B. Verrucous carcinoma of the larynx. Possible human papillomavirus etiology. Arch Otolaryngol 1985;111:709-15.

15. Schwade JG, Wara WM, Dedo HH, Phillips TL. Radiotherapy for verrucous carcinoma. Radiology 1976;120:677-9.

16. Burns HP, van Nostrand AWP, Bryce DP. Verrucous carcinoma of the larynx: management by radiotherapy and surgery. Ann Otol Rhinol Laryngol 1976;85:538-43.

17. Rider WD. Toronto experience of verrucous carcinoma of the larynx. Can J Otolaryngol 1975;4:278-9.

18. Wang CC. Radiation therapy of laryngeal tumors. In: Thawley SE, Panje WR, Batsakis JG, Lindberg RD, eds. Comprehensive management of head and neck tumors. Vol 1. Philadelphia: WB Saunders, 1987:906-19.

19. Ferlito A. Malignant epithelial tumors of the larynx. In: Ferlito A, ed. Cancer of the larynx. Vol 1. Boca Raton, Fla: CRC Press, 1985:91-196.

20. Gnepp DR, Ferlito A, Hyams V. Primary anaplastic small cell (oat cell) carcinoma of the larynx. Review of the literature and report of 18 cases. Cancer 1983;51:1731-45.

21. Ferlito A, Recher G, Caruso G. Primary combined small cell carcinoma of the larynx. Am J Otolaryngol 1985;6:302-8.

22. Ferlito A. Diagnosis and treatment of small cell carcinoma of the larynx: a critical review. Ann Otol Rhinol Laryngol 1986; 95:590-600.

23. Baugh RF, Wolf GT, Beals TF, Krause CJ, Forastiere A. Small cell carcinoma of the larynx: results of therapy. Laryngoscope 1986;96:1283-90.

24. Ferlito A, Pesavento G, Recher G, et al. Long-term survival in response to chemotherapy and radiotherapy in laryngeal small cell carcinoma. Auris Nasus Larynx 1986;13:113-23.

25. Snyderman C, Johnson JT, Barnes L. Carcinoid tumor of the larynx: case report and review of the world literature. Otolaryngol Head Neck Surg 1986;95:158-64.

26. Stanley RJ, DeSanto LW, Weiland LH. Oncocytic and oncocytoid carcinoid tumors (well-differentiated neuroendocrine carcinomas) of the larynx. Arch Otolaryngol 1986;112:529-35.

27. Goldman NC, Katibah GM, Medina J. Carcinoid tumors of the larynx. Ear Nose Throat J 1985;64:130-4.

28. Ferlito A, Recher G, Bottin F. Mucoepidermoid carcinoma of the larynx. A clinicopathological study of 11 cases with review of the literature. ORL J Otorhinolaryngol Relat Spec 1981;43:280-99.

29. Ferlito A, Caruso G. Biological behaviour of laryngeal adenoid cystic carcinoma. Therapeutic considerations. ORL J Otorhinolaryngol Relat Spec 1983;45:245-56.

30. Ferlito A, Gale N, Hvala H. Laryngeal salivary duct carcinoma. A light and electron microscopic study. J Laryngol Otol 1981;95:731-8.

31. Reuter VE, Woodruff JM. Melanoma of the larynx. Laryngoscope 1986;94:389-93.

32. Kim H, Park C. Primary malignant laryngeal melanoma. Report of a case with review of literature. Yonsei Med J 1982; 23:118-22.

33. Ferlito A, Primary lymphoepithelial carcinoma of the hypopharynx. J Laryngol Otol 1977;91:361-7.

34. Stanley RJ, Weiland LH, DeSanto LW, Neel HB III. Lymphoepithelioma (undifferentiated carcinoma) of the laryngohypopharynx. Laryngoscope 1985;95:1077-81.

35. Ferlito A. Primary anaplastic giant cell adenocarcinoma of the larynx. J Laryngol Otol 1976;90:1053-60.

36. Ferlito A, Friedmann I, Recher G. Primary giant cell carcinoma of the larynx. A clinicopathological study of four cases. ORL J Otorhinolaryngol Relat Spec 1985;47:105-12.

37. Pesavento G, Ferlito A, Recher G. Primary clear cell carcinoma of the larynx. J Clin Pathol 1980;33:1160-4.

38. Gerughty RM, Hennigar GR, Brown FM. Adenosquamous carcinoma of the nasal, oral and laryngeal cavities. A clinicopathologic survery of ten cases. Cancer 1968;22:1140-55.

39. Ferlito A. Adenosquamous carcinoma of the larynx. A clinical and pathologic study. Report of four cases and review of the literature. Acta Otorhinolaryngol Belg 1976;30:379-89.

40. Crissman JD, Rosenblatt A. Acinous cell carcinoma of the larynx. Arch Pathol Lab Med 1978;102:233-6.

41. Ferlito A. Acinic cell carcinoma of the minor salivary glands. Histopathology 1980;4:331-43.

42. Hanna GS, Ali MH. Chemodectoma of the larynx. J Laryngol Otol 1986;100:1081-7.

PHONATORY AIRFLOW ANALYSIS IN PATIENTS WITH LARYNGEAL DISEASE

PEAK WOO, MD

RAYMOND H. COLTON, PHD LEE SHANGOLD, MD

SYRACUSE, NEW YORK

Phonatory airflow was recorded in 150 patients with various laryngeal diseases and in 60 persons with normal voices. All subjects produced several sustained vowels at different loudness levels. Disturbances of voice due to laryngeal disease may be manifested as variations of mean flow (DC), alternating flow (AC), or as a variation in the amplitude of the frequency components of the airflow signal (frequency spectra). The quantification of airflow characteristics is important if the clinician is to have a better understanding of laryngeal disease. Furthermore, preoperative and postoperative analysis can serve to document therapeutic effectiveness.

KEY WORDS — frequency spectra, laryngeal disease, phonatory airflow.

INTRODUCTION

During normal phonation, airflow is converted from a steady flow source from the lungs (DC) into a flow source with a rapidly changing component (AC) by vocal fold vibration. This flow signal can be recorded at the oral cavity noninvasively using a flow meter. As Isshiki et al[1,2] proposed, the ratio of the rapidly changing component to the mean flow (AC/DC ratio) measured by a constant temperature hot wire anemometer (CTHWA) may be a good measure of vocal efficiency. His work in normal and disordered states has been substantiated by others.[3-5] Most often, the presence of a laryngeal disorder produces an airflow waveform that shows an increase in turbulence.[6] This variation of airflow waveform is attributed to the loss of the vocal folds' ability to sustain periodic vibration. The measurement of phonatory airflow may be a clinically useful tool for analyzing vocal dysfunction and may lead to a better understanding of laryngeal disorders. Serial measurements may be used to follow patients undergoing surgery. In this report, phonatory airflow and sound pressure were studied in patients with various laryngeal disorders and compared to those of patients with normal voices. In addition to a mean flow rate (MFR) analysis, analysis of the data included estimates of phonatory efficiency (AC/DC ratio) and frequency analysis of the phonatory airflow waveform.

MATERIAL AND METHODS

Patient Selection. One hundred fifty patients with laryngeal disorders were selected for study. All patients had clinically obvious dysphonia and were examined to identify and confirm the diagnosis. All patients with paralysis, polyps, or damage due to trauma were previously untreated. Patients with laryngitis were all untreated, except for two with radiation-induced laryngitis. Cancer patients were studied prior to biopsy, except for two who had prior biopsy and radiation therapy. If a diagnosis was changed postoperatively, ie, from chronic laryngitis to carcinoma, the patient was reassigned based on disorder criteria. Sixty subjects (30 men and 30 women) with normal voices in their second, third, and fourth decades of life served as normal controls (Table 1).

Equipment Set-up and Calibration. A single channel constant temperature anemometry unit and power supply were operated in a linearized mode (TSI 1054, 1051, 1056, 1055). Calibration of the probe and unit for linear output was done by the manufacturer at 0 to 9 m/s (0 to 10 yards/s) for 0 to 10 V of output. The operating temperature was set at 250°C with a bridge ratio of 5 to 1. With its frequency response set at maximal, a TSI 1210-20 probe was used to record all airflows. Before patient testing, the system was calibrated using a constant, steady, humidified flow source at 36°C and a Wright spirometer.

The frequency response of the system was tested using a sine wave flow source at 512 Hz and 1,024 Hz. Constant flow rates from 30 mL/s to 1,000 mL/s (100 mV to 2.2 V) were used at room temperature combined with oscillating flows, and the frequency response was analyzed using frequency analysis. The frequency response for the system used was greater than 1 kHz at MFRs above 50 mL/s. Distortion was less than −40 dB at MFRs above 30 mL/s.

The DC voltage from the anemometry circuit is read off the DC voltmeter (TSI 1051-1) and is defined here as MFR. The AC voltage is read off a root mean squared voltmeter (Hewlett Packard 400 GL) and is defined here as fluctuant flow. The AC/DC

From the Department of Otolaryngology and Communication Sciences, SUNY Health Science Center at Syracuse, Syracuse, New York. This work was supported in part by IA grant 93026 from the Hendricks Fund for Medical Research and UUP-PDQWL New Faculty Development Award 22001112.

Presented at the meeting of the American Laryngological Association, Denver, April 25-26, 1987.

REPRINTS — Peak Woo, MD, Dept of Otolaryngology, SUNY Health Science Center, 750 E Adams St, Syracuse, NY 13210.

TABLE 1. DATA SUMMARY

Grouping by Disorder	*No. Subjects*	*Modal "ee"**		
		Mean Flow Rate (DC, mL/s)	*AC/DC Ratio*	*Intensity (dB)*
Normal men and women, ages 20 to 50	M = 30 F = 30	144 (58)	.39 (.09)	78 (5)
Unilateral and bilateral paralysis of recurrent laryngeal nerve	M = 10 F = 7	469 (271)	.31 (.07)	73 (6)
Vocal nodules, polyps (unilateral and bilateral)	M = 14 F = 18	265 (100)	.29 (.08)	76 (5)
Carcinoma of glottis, T1 to T4	M = 16 F = 10	269 (120)	.30 (.10)	76 (6)
Postintubation trauma, blunt laryngeal trauma	M = 4 F = 9	327 (222)	.28 (.09)	72 (6)
Acute, chronic, and radiation laryngitis	M = 7 F = 11	222 (105)	.29 (.11)	75 (5)
Other	M = 33 F = 11	155 (59)	.38 (.14)	77 (5)
Total of all disorder groups	M = 84 F = 66	276 (174)	.30 (.10)	74 (5)

*Standard deviations in parentheses.

ratio is calculated based on AC and DC voltage readings. All voltage readings were converted to volume velocity using calibration curves established for each probe.

Patient Recording. The patient was seated comfortably in a room with a background noise of less than 58 dB. A short, disposable rigid paper cylinder was placed orally to serve as a conduit for phonatory airflow and to reduce oral cavity and lip influences on airflow. The flow transducer was placed at the level of the lips inside a short cylinder coupled to the paper tube (radius, 0.9 cm). A condenser microphone (Brüel & Kjaer type 4134) was placed at 20 cm away from the lips and led to a measuring amplifier (Brüel & Kjaer type 2610) for recording of sound pressures. The patient was asked to phonate the vowel "ee," respectively, at a steady fundamental frequency, at a very low fundamental frequency without vocal fry, at a very high fundamental frequency without falsetto, and at the loudest level the patient could sustain. Each condition was produced three times. Direct meter readings of the DC, AC, and decibel values were recorded for each condition and the average recorded.

Signal Analysis. Digital sampling was carried out with computers and signal analysis software (Nicolet Med-80, IBM-PC) with 12-bit accuracy. Initially, signal sampling at 15 kHz was done with and without a low pass filter set at 8 kHz (Krone Hite 3750, 12 dB/octave falloff). This allowed high resolution but a short time window. After the first 100 patients, the signal was also sampled at a 1-kHz sampling rate after band pass filtering from 2 to 500 Hz. This was done because it was found that little high frequency energy was present above 500 Hz, and using a lower sampling resolution permitted acquisition of 8 seconds of phonation. Using the data of 8 seconds of phonation at the 1-kHz sampling rate, the data block was divided into 125-ms epochs and transformed into a frequency domain. Sixty-four epochs of sequential power spectra were plotted from the 8-second sample in a compressed spectral array for hard copy record. Total power at each frequency was then summated to give a graphic output of the average power spectrum.

RESULTS

Table 1 summarizes the patient groups and statistics for modal "ee" in terms of MFR, AC/DC value, and decibel output. The results are summarized below in terms of 1) mean flow, 2) AC/DC ratio, and 3) frequency analysis for the normal and patient groups.

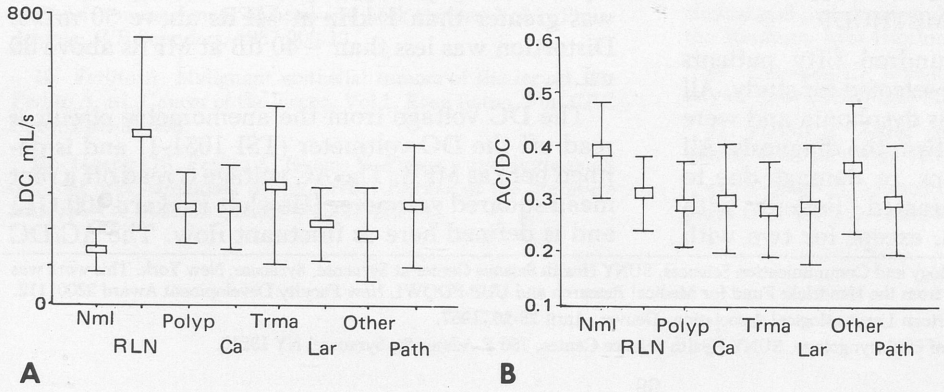

Fig 1. Sustained modal "ee" in normal subjects and patients. Nml — normal, RLN — recurrent laryngeal nerve paralysis, Polyp — vocal nodules and polyps, Ca — carcinoma, Lar — laryngitis, Trma — trauma, Other — other groups, Path — all patients with laryngeal disorders. See Table 1 for explanation of grouping by disorder. A) Mean phonatory airflow. DC — mean flow volume velocity in mL/s. B) AD/DC ratio. AC — rapidly changing airflow component produced by vocal fold vibration, DC — steady flow source from lungs.

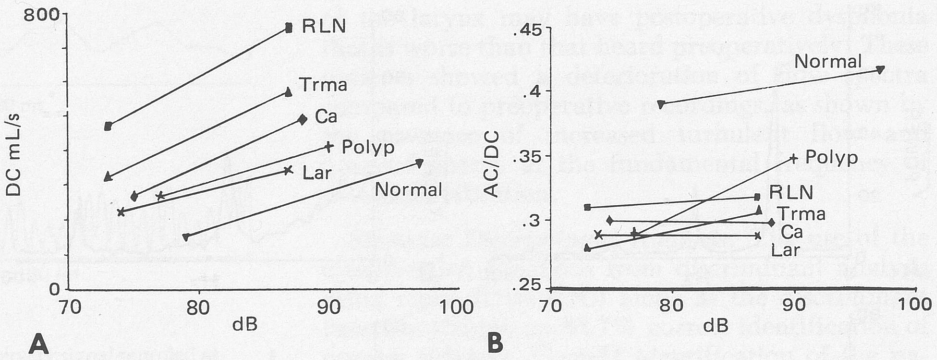

Fig 2. Modal "ee" for conditions of easy phonation and loud sustained phonation for various groups. See Table 1 for explanation of grouping by disorder. A) Mean flow (DC) versus dB. B) AC/DC ratio. For definitions, see Fig 1 legend.

Mean Flow Rates. Figure 1A graphically displays the mean phonatory airflow for the normal subjects and patients. The values for the normal group agreed with those reported in the literature on studies using other transducers.[7-9] In the patient groups, there were many differences from normal subjects and from each other. Not unexpectedly, maximal airflows were seen in paralysis and trauma patients. This is attributable to poor glottic closure and leakage. The higher-than-normal MFR in polyps and cancer patients also agrees well with previously reported data.[7,8,10] The data provide further evidence that MFR in patients with laryngitis is either similiar to that in normal speakers or slightly elevated.[11] The only group to have little difference in MFR is the group labeled "other." This is a disparate group that included esophageal speakers and patients with Blom-Singer valves, partial laryngectomies, subglottic stenosis, and spasmodic dysphonia. These were included in the "other" group because of the low number of patients. The combination of small numbers and large variability may possibly account for the MFR values recorded.

Figure 2A displays the change in MFR with increased loudness. The MFR rises with increased loudness, primarily because of the increase of subglottic pressure. Normal subjects and patients both increase MFR with effort phonation. Maximal loudness is decreased in patients compared to the normal group, whereas MFR at loud phonation in patients is elevated compared to that of the normal group. The slope of increasing MFR with increasing loudness is the same in the control group, patients with polyps, and patients with laryngitis, whereas groups with paralysis, trauma, or carcinoma showed a slightly steeper slope. If it can be assumed that both control and patient groups are using maximal input power, MFR during loud "ee" appeared to be on a continuum from low in normal subjects to high in patients with recurrent nerve paralysis. A similar relationship can be seen during production of modal "ee."

AC/DC Ratio Analysis. Figure 1B displays the AC/DC ratio of the control and patient groups. The patient groups all had lower than normal AC/DC ratios. Our AC/DC ratio for the normal group is less than that reported by others,[3] but this may be due to our usage of an RMS AC voltmeter, which would be expected to give lower values than a peak-to-peak AC voltmeter. Whereas AC/DC ratios are similar among different patient groups, AC values were very large for patients with recurrent laryngeal nerve paralysis compared to other groups. A possible explanation is the lack of vocal fold tension in this group. This would result in large vibratory amplitude of the vocal folds during phonation, thus resulting in increased AC values. A better group separation between normal and disordered states may be obtained by plotting the AC/DC ratio versus decibel output (Fig 2B). For normal subjects, a higher AC/DC ratio accompanies a louder "ee" then a modal "ee." The increase of laryngeal efficiency, as measured by AC/DC ratios, is also seen in the group with polyps, but not in the groups with paralysis, trauma, carcinoma, or laryngitis. An increase in laryngeal efficiency at loud "ee" in the group with polyps may be due to increased vocal fold tension, which is used to overcome the loading of the mass (polyp) on the vibration of the vocal folds. Such a maneuver may result in vibration of the normal mucous membrane. In laryngitis, increased inflammatory edema maintains the vocal folds in a swollen, tense state. Further increases in input power and vocal fold tension with effort phonation are ineffective in producing better laryngeal vibration, and no improvement in laryngeal efficiency is seen. The lower AC/DC ratios seen in the various disorders in this study may be used as an index of the effectiveness of treatment. In patients with acute laryngitis but normal MFR, spontaneous improvement results in improved AC/DC ratios. Patients with vocal cord polyps may have MFRs also in the normal range, but may show a decrease in AC/DC ratios. The AC/DC ratio may become normal after laser surgery to remove mass lesions. Although the number of patients studied is small, patients with spasmodic dysphonia or hyperfunction seem to have normal to slightly elevated AC/DC ratios during modal "ee." This finding, along with their high decibel output for modal "ee," suggests that these patients are operating toward the high end of their phonatory ability, contributing to vocal fatigue. Further studies using such an approach may be useful in voice therapy.

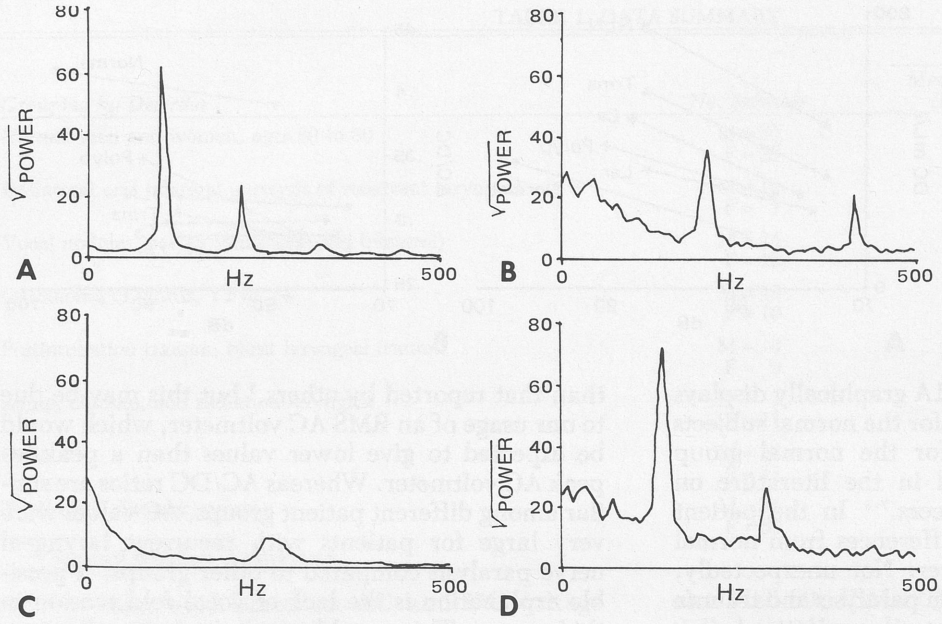

Fig 3. Average power spectra for four subjects. x axis — frequency, 0 to 500 Hz, y axis — square root of power. Note increase in low frequency energy and interharmonic energy in laryngeal disorder. Severe dysphonia is correlated with low frequency energy's being greater than periodic energy. A) Normal subject, B) patient with vocal polyps, C) patient with T2 laryngeal carcinoma, D) patient with vocal cord paralysis.

Frequency Analysis. Analysis of the average power spectrum of the phonatory airflow signal is presented in Fig 3. It includes a normal subject and patients with T2 laryngeal carcinoma, bilateral vocal cord paralysis, and vocal cord polyps. The spectral array for each of the 125-ms epochs in the 8-second sample for each of the cases is presented in Fig 4. The normal phonatory airflow signal is dominated by energy at the fundamental frequency of vocal fold vibration, with some energy at the first and second harmonics and little interharmonic or noise energy (Fig 4A). Normal phonatory airflow is periodic. With laryngeal lesions (Figs 3 and 4B-D), the periodic vibratory capacity of the vocal folds is disturbed and appears as decreased power at the fundamental frequency and/or as presence of increased interharmonic energy or increased low frequency energy. Low frequency energy is defined as that energy present in frequencies below the fundamental frequency of laryngeal vibration. This

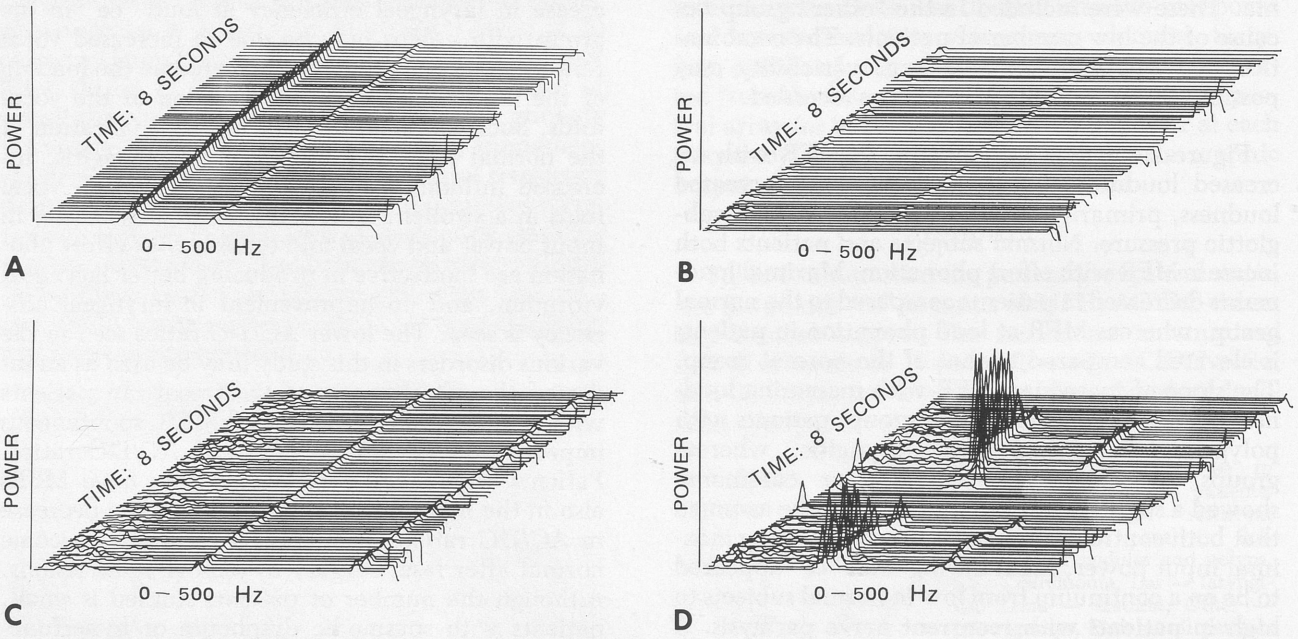

Fig 4. Compressed spectral arrays. Each line = 125 ms. A) Normal man. Note peak energy at fundamental frequency, stability over time in amplitude of peak power, and lack of interharmonic energy and low frequency energy. DC = 130 mL/s, AC/DC ratio = 0.4. B) Man with cancer. Note loss of energy at fundamental frequency, elevation of fundamental frequency as patient uses more effort to phonate, low AC value resulting in flat compressed spectral array plot, and presence of low frequency energy signals. DC = 210 mL/s, AC/DC ratio = 0.18. C) Woman with vocal polyp. Note preservation of fundamental frequency of vibration and its harmonics and presence of low frequency turbulence. DC = 200 mL/s, AC/DC ratio = 0.34. D) Man with vocal cord paralysis. Note patient's maximum phonation time < 4 seconds along z axis, no vocal fold vibration or AC signal during respiration, and large signal component during phonation because of flaccid vocal fold vibration. DC = 400 mL/s, AC/DC ratio = 0.4.

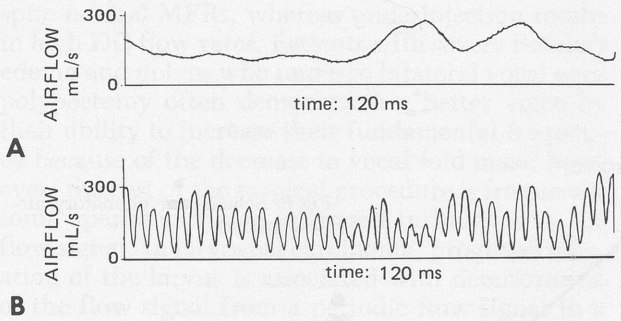

Fig 5. Phonatory airflow volume velocity signal sampled at high frequency resolution (15 kHz) for woman with papilloma of larynx. A) Preoperative, B) postoperative.

characteristic presence of wide energy distribution in mass lesions represents random low frequency phonatory airflow that contributes to the AC signal but contributes little to the periodic component of vocal fold vibration.

The presence of random flow signals that correspond to turbulence in mass lesions may also be an important aspect of laryngeal function not measured with AC/DC flow ratios alone. In patients with advanced carcinoma of the larynx and in patients with severe glottic insufficiency in which little vocal fold vibration is observed, the airflow spectrum deteriorates to a completely random flow spectrum in which energy is distributed over all frequencies. This is characteristic of turbulent flow[12] (Figs 3 and 4D).

The recording of airflows before and after Teflon injection shows restoration of phonatory airflow vibrations in successful injections. In patients who underwent surgical excision of mass lesions, return of laryngeal vocal fold vibration is documented by increased fundamental frequency and decreased turbulent energy. Figure 5 is a recording of airflow in a patient with papilloma of the larynx before and after surgery. The preoperative airflow signal shows a small AC component, but a normal to slightly elevated MFR. There is little periodic energy. Postoperatively, the vocal folds vibrate normally, the airflow signal shows a high AC component that is quasiperiodic, and there is very little air leakage. These altered aerodynamic characteristics are consistent with symptomatic improvement in vocal ability and voice. Similarly, recordings of patients who undergo laser cordectomy for small carcinomas of the larynx may have postoperative dysphonia that is worse than that heard preoperatively. These patients showed a deterioration of flow spectra compared to preoperative recordings, as shown by the presence of increased turbulent flow and lowered energy at the fundamental frequency of vocal fold vibration.

Stepwise Discriminant Analysis. The use of the classification functions from discriminant analysis using mean flows (DC) alone as the discriminant function yielded an 86.7% correct identification of normal subjects. Correct identification of the patient group, however, was a poor 49.3%, with an overall 60.0% correct. The addition of AC/DC ratio improved discrimination of the patient group from normal subjects to 77.5%, with an overall improvement in discrimination to 78.8% (Table 2).

The ability to correctly distinguish between the various disorders was also tested, using MFR, AC/DC ratio, and decibel values as discriminant functions. This analysis yielded poor discriminant ability among the eight groups, with the best overall correct identification of 40% using mean flow (DC), fluctuant flow (AC), AC/DC ratio, and decibel values as the discriminant functions.

DISCUSSION

Acoustic analysis of phonation in patients with laryngeal disorders has been performed by many investigators.[13-17] Although such an acoustic approach may differentiate disorders, it bears only indirectly on laryngeal pathophysiology. Investigators of vocal fold vibratory capability have used techniques such as stroboscopy, high speed motion pictures, electroglottography, photoglottography, and inverse filtering of pressure waveforms. All have some limitations and advantages. To decide on a clinically useful instrument for assessment of laryngeal function, the criteria discussed by Kakita[5] may be useful: 1) the method of measurement should be noninvasive, 2) the method should measure observed quantities that reflect some aspect of glottal function, and 3) the basis of measurement should be clear as a physical entity. The method must be reliable and repeatable and should require little adjustment on the part of the operator. The use of a CTHWA for metering airflow at the oral cavity satisfies many of the above criteria.

TABLE 2. STEPWISE DISCRIMINANT ANALYSIS

	Normal	*Disordered*		*Normal*	*Disordered*
Variable:			Variable:		
Mean flow (DC)	0.00629	0.01205	Mean flow (DC)	0.00617	0.01264
			AC/DC ratio	43.45730	33.06190
Constant	− 1.147	− 2.357	Constant	− 9.511	− 7.380
% Correct	86.7	49.3	% Correct	87.7	77.5
Total (%)		60.0	Total (%)		78.8

Stepwise discriminant analysis was carried out using BMDP program P7M to calculate functions to discriminate between normal and disordered phonatory airflows using mean flow (DC), and mean flow (DC) plus AC/DC ratio as the available variables.

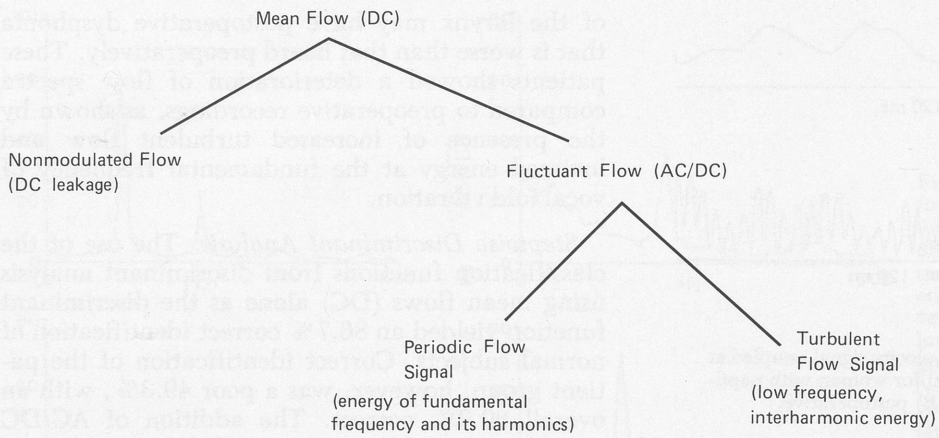

Fig 6. Schema for phonatory airflow analysis.

With improvements in the frequency response of the CTHWA, the rapid component of phonatory airflow due to vibration of the vocal folds can be measured using an AC meter. With the advent of inexpensive computers, it is easier to perform frequency analysis of the airflow signal. As each level of analysis has become practical, it seems to help separate the normal from disordered groups (Fig 6). This has resulted in better quantifiable parameters for assessment of laryngeal function. Laryngeal control of phonatory airflow may be thought of as having two components that make up MFRs: 1) flow that passes through the glottis unmodulated and 2) flow that is fluctuant because of vocal fold vibration (AC). In addition, it is possible to analyze the fluctuant component of the flow signal using frequency analysis to assess laryngeal vibratory function. We find that the normal phonatory airflow signal has typical spectral properties that are restricted to frequencies below 1 kHz. The spectral energy is dominated by the fundamental frequency component of laryngeal vibration and its first three to four harmonics. Disturbance of the airflow signal seems to correspond well to qualitative assessment of laryngeal vibratory capability using laryngoscopy or laryngostroboscopy. In order to arrive at an estimate of aerodynamic power during phonation, it would be necessary to record both flow and subglottic pressure[18]; we did not measure subglottic pressure in this study. Realistically, it is difficult to obtain these measurements in a clinically noninvasive way, although data have been collected experimentally.[19] Despite not being able to measure aerodynamic power, the measurement and analysis of the airflow alone have been useful.

Mean flow measurements give little indication of the laryngeal efficiency of flow conversion from DC to AC flow. The AC/DC ratio serves as a convenient means to judge the extent to which airflow is modulated by the larynx. If laryngeal disorder results in flow leakage, the AC/DC ratio is decreased because of an elevated DC value. If the larynx's vibratory ability is diminished because of inflammation or mass loading, the decrease in the AC component may be the primary contributor to a decreased AC/DC ratio. Combination changes can occur; however, with laryngeal lesions that result in dysphonia, a decreased AC/DC ratio is seen. By the measurement of AC and DC values, it can be determined if decreased vocal efficiency is due to excessive DC leakage, decreased laryngeal vibration, or both. The analysis of the AC signal using frequency analysis helps to further differentiate the vocal folds' vibratory capacity. In normal voices, airflow energy is largely limited to the fundamental frequency of vocal fold vibration and its first few harmonics. With laryngeal lesions, the quasiperiodic waveform is disturbed and changed to a more random, turbulent flow pattern.

Because the recording is done at the level of the oral cavity, tongue and pharyngeal oscillations during sustained phonation will affect the flow signal. These contributors, however, are of low frequency and may be removed through filtering of the airflow signal.

The advantages of airflow analysis in the clinical applications has been primarily demonstrated in two areas. One is in better understanding of underlying pathophysiology and the other is in serial recordings of patients undergoing therapy. Analysis of airflow using the above criteria helps to determine if the pathophysiology of phonatory airflow is due to problems with vibration, laryngeal efficiency, or MFR. The calculation of periodic energy in relationship to noise or nonperiodic energy may help to better differentiate a rough quality of voice from other qualities such as breathiness, aperiodicity, and hyperfunction. Further correlation of the airflow signal to the quality of sound is needed. In patients undergoing laryngeal microsurgery, analysis of airflow has helped to clarify changes in laryngeal function due to surgery. In patients with recurrent laryngeal nerve paralysis who are hoarse despite "adequate" injection of Teflon, analysis of their airflow may help to differentiate a voice problem due to overinjection from one due to underinjection. In our limited experience, overinjection results in a stiff vocal fold that is unable to vibrate de-

spite normal MFRs, whereas underinjection results in high DC flow rates. Patients with severe Reinke's edema and polyps who undergo bilateral vocal cord polypectomy often demonstrate a better voice by their ability to increase their fundamental frequency because of the decrease in vocal fold mass; however, the cost of the surgical procedure is frequently some aperiodicity and increased turbulence in the flow signal. In laryngeal carcinoma, progressive fixation of the larynx is associated with deterioration of the flow signal from a periodic flow signal to a random turbulent flow signal. It is our impression that signal properties of airflow are the first to change, followed by changes in the AC/DC ratios and, finally, MFR. Whether this observation can be used to clinical advantage in assessment of laryngeal function in carcinoma has yet to be demonstrated.

If analysis of phonatory airflow is to be useful to the clinician, improvements must be made in the ability to distinguish normal from disordered voices. In our series, using MFR as the only criterion yielded a poor 60% overall correct classification. The addition of a single AC/DC ratio improved correct identification to 78.8%. This method, however, is still inadequate if it is to be useful of and by itself. Improvements in predictive value may reside in further analysis of the airflow data in terms of frequency components. One possible addition for achieving better separation may be to analyze the airflow signal for the periodic-to-noise signal ratio using spectrum analysis. Efforts to identify possible parameters to use are being made in our institution.

In summary, the phonatory airflow signal may be useful in the clinical assessment of laryngeal function. This study proposes three levels of analysis for phonatory airflow. These are 1) mean flow (DC), 2) flow efficiency (AC/DC), and 3) frequency analysis of the phonatory airflow. The combined analysis of all of the above has been useful in the study of laryngeal dysfunction. More specific clinical applications await further study.

REFERENCES

1. Isshiki N, Yanagihara N, Morimoto M. Approach to the objective diagnosis of hoarseness. Folia Phoniatr (Basel) 1966; 18:393-400.

2. Isshiki N. Vocal efficiency index. In: Stevens KN, Hirano M, eds. Vocal fold physiology. Tokyo: University Press, 1981: 193-207.

3. Kitajima K. Airflow study of pathologic larynges using a hot wire flowmeter. Ann Otol Rhinol Laryngol 1985;94:195-7.

4. Kitajima I, Isshiki N, Tanabe M. Use of hotwire flow meter in the study of laryngeal function. Studia Phonolog 1978; 12:25-30.

5. Kakita Y. Measures and displays representing phonatory ability. In: Baer T, Sasaki C, Hannis K, eds. Laryngeal function in phonation and respiration. Boston: Little, Brown, 1987:448-62.

6. Woo P. Phonatory volume velocity recording by use of hot film anemometry and signal analysis. Otolaryngol Head Neck Surg 1986;95:312-8.

7. Isshiki N, von Leden H. Hoarseness in aerodynamic studies. Arch Otolaryngol 1964;80:206-13.

8. Hirano M, Koike Y, von Leden H. Maximum phonation time and air usage during phonation. Folia Phoniatr (Basel) 1968;20:185-201.

9. Yoshioka H, Sawashima M, Hirose H, Ushijima T, Honda K. Clinical evaluation of air usage during phonation. Jpn J Logopedics Phoniatr 1977;18:87-93.

10. Iwata S, Esaki T, Iwami K, Minura Y. Laryngeal function in patients with laryngeal polyps after laryngomicrosurgery. Pract Otol (Kyoto) 1976;69:499-506.

11. Hirano M. Clinical examination of the voice. Disorders of communication. New York: Springer-Verlag, 1981:25-34.

12. Tennekes H, Lumley JL. A first course in turbulence. Cambridge, Mass: MIT Press, 1983.

13. Koike Y, Markel J. Application of inverse filtering for detecting laryngeal pathology. Ann Otol Rhinol Laryngol 1975;84: 117-24.

14. Davis S. Acoustic characteristics of normal and pathological voices. In: Ludlow C, Hart M, eds. NIH conference on assessment of vocal pathology. ASHA Report 11; 1979:97-115.

15. Flanagan JC. Speech analysis, synthesis and perception. New York: Springer-Verlag, 1972.

16. Iwata S, von Leden H. Periodicities of pitch perturbations in normal and pathologic larynges. Laryngoscope 1972;82:87-96.

17. Muta H, Muraoka T, Wagatsuma K, et al. Analysis of hoarse voices using the LPC method. In: Baer T, Sasaki C, Hannis K, eds. Laryngeal function in phonation and respiration. Boston: Little, Brown, 1987:463-74.

18. Van der Berg JW. Direct and indirect determination of the mean subglottic pressure. Folia Phoniatr (Basel) 1956;8:1-24.

19. Tanaka S, Gould WJ. Vocal efficiency and aerodynamic aspects in voice disorders. Ann Otol Rhinol Laryngol 1985;94: 29-33.

LASER RESECTION FOR EARLY ORAL CAVITY CANCER

RESULTS AND COMPLICATIONS

MATTHEW J. NAGORSKY, MD DONALD G. SESSIONS, MD

ST LOUIS, MISSOURI

Laser excision of early selected cancers of the oral cavity and pharynx is a well accepted and reported treatment. Postoperative radiation therapy is employed in patients with unfavorable pathologic findings and in patients expected to have a high recurrence and metastatic rate. In most patients the combination of laser excision and postoperative radiation therapy is well tolerated and results in satisfactory healing, excellent tumor control, and high-level posttreatment function. This report discusses the treatment and results in 28 patients treated for early cancer of the oral cavity and pharynx. The local control rate of 77% compares favorably with the reported results following either conventional or laser excision of these lesions. The overall complication rate was 39%, with a 25% rate for patients not receiving postoperative radiation therapy, and a 58% complication rate for patients treated with postoperative radiation.

KEY WORDS — carbon dioxide laser excision, oral cavity, pharynx.

INTRODUCTION

The introduction of laser laryngeal surgery by Strong and Jako in 1972[1] created a new technology for the head and neck surgeon. Since that initial article, the carbon dioxide laser has found increased usage for treating head and neck tumors including the transoral excision of carcinoma. In 1979 Strong et al[2] reported their experience with 57 such resections. They concluded that laser excision of localized oral cavity carcinoma was a practical, sound method of treatment producing acceptable cure rates with few complications and low morbidity. Additional investigators[3,4] have corroborated these results. They have reported local control rates of 60% to 80% and noted that this was comparable to control following conventional surgery and radiation. It has been claimed that excision with the laser, including the resection of periosteum, results in wounds that heal quickly without the need for primary closure or reconstruction.[2,4,5]

The laser has been used classically for the wide local excision of small superficial cancers, including early recurrent or persistent tumors, in various oral cavity sites. It has been claimed that the general advantage of the laser is that its meticulous and precise use under microscopic control results in minimal operative blood loss and few complications. The transoral approach precludes the need for a transcutaneous neck approach. The use of the microscope theoretically allows for increased local control by decreasing positive surgical margins in a group of patients where resection margins are a major issue. The laser is used as a cutting tool for the resection and not for destruction or vaporization of the lesion and a pathology specimen always is available for examination.

The specifically claimed advantage of using the laser in treating oral cavity cancer concerns patients with lesions overlying the mandible. These lesions include small primary tumors involving the mucosa over the edentulous mandible and tumors with secondary extension to the mandibular surface from the floor of the mouth, retromolar trigone, anterior tonsillar pillar, soft palate, and buccal mucosa. These lesions, including periosteum, presumably could be excised widely. According to the literature, these wounds would heal spontaneously, leaving the mandible intact, without the necessity of complicated primary closure with local or distant flaps.

In order to see the results of laser treatment of early oral cavity cancer, a series of patients treated with laser resection is reported.

MATERIAL AND METHODS

From 1981 through 1985, 28 patients with oral cavity epidermoid cancer were treated with a total of 31 transoral laser excisions. Patient ages ranged from 43 to 83 years with a mean age of 64 years. There were 12 men and 16 women. These patients had 22 primary cancers and nine recurrent tumors involving various oral cavity sites (Table 1). Nine patients with recurrent tumors had been treated previously: conventional surgery (four), radiation therapy (three), or combined surgery and radiation (two). The staging of these lesions according to the American Joint Committee on Cancer[6] is shown in Table 2. None of the patients had any regional or distant metastasis at the time of initial laser resection.

The treatment of these cancer patients was con-

From the Department of Otolaryngology–Head and Neck Surgery, Washington University School of Medicine, St Louis.

Presented at the meeting of the American Laryngological Association, Denver, April 25-26, 1987. Funding for this study was made available through a research grant by Jack Minton.

REPRINTS — Donald G. Sessions, MD, Dept of Otolaryngology–Head and Neck Surgery, Washington University School of Medicine, 517 S Euclid Ave, St Louis, MO 63110.

TABLE 1. SITE OF LESION

	Primary	*Recurrence*	*Total*
Tongue	6	6	12
Buccal mucosa	2	1	3
Retromolar trigone	2	1	3
Floor of mouth	8*	1	9
Palate	2†	—	2
Alveolus	2†	—	2
Total	22	9	31

*Includes two second primary lesions.
†Includes one second primary lesion.

TABLE 2. SITE OF LESION BY TUMOR STAGE

	T1	*T2*	*T3*	*Total*
Tongue	7	4	1	12
Buccal mucosa	—	2	1	3
Retromolar trigone	—	3	—	3
Floor of mouth	5	3	1	9
Palate	1	1	—	2
Alveolus	—	1	1	2
Total	13	14	4	31

No T4 lesions were found.

ventional in that following wide local excision of the tumors, postoperative radiation was given under certain conditions. These conditions included pathology specimens showing tumor invasion of blood vessels or lymphatics or tumors recurrent at the time of excision. Specific patients with microscopic tumors at the burn margins of the pathology specimens were treated with postoperative radiation. In most patients, therapy consisted of external beam treatments of 5,000 to 6,000 rad if prior radiation had not been given. In those patients who had received prior irradiation, iridium 192 interstitial implants were performed delivering up to 5,000 rad. One patient with a recurrent T2 floor of mouth cancer was treated with a primary cesium implant delivering 6,500 rad, followed by laser excision.

The laser excisions were accomplished using a 50-W power setting delivered continuously by a Cavitron CO_2 laser mounted on an operating microscope. If the tumor appeared fixed superficially to the mandible then an appropriate portion of the mandible was excised en bloc using a high-speed air drill. A minimum margin of 2 cm of uninvolved oral cavity tissue was excised around the lesion. This margin was initially marked with methylene blue using a 2-cm cut plastic measuring stick. Larger margins were taken if tumor became apparent under the operating microscope. For questionable margins, frozen sections of the remaining oral cavity resection defect were taken at the operating table, and more tissue was excised where appropriate. The laser was used as a cutting tool and no lesion was destroyed or vaporized. Hemostasis was accomplished with laser coagulation, electrocautery, or suture ligature. Specimens were sent to the pathology department for examination in all patients. Two of 31 operative wounds were closed primarily with chromic sutures. All other wounds were allowed to heal spontaneously.

All patients were followed for a minimum of 2 years and no patients were lost to follow-up. They were evaluated for tumor control, healing status including fibrosis, ulceration, necrosis, or exposed mandible, and speech and deglutition function.

RESULTS

All patients tolerated the operative procedure well without the need for tracheotomy, transfusion, or prolonged hospitalization. The only operative laser mishap consisted of a 1-mm lip burn, which healed without permanent residual injury. One patient required operative suture ligation of a bleeding artery on the mobile tongue on the sixth postoperative day.

TUMOR CONTROL

Local Control. Local control of cancer was achieved following 24 (77%) of the 31 laser excisions. Table 3 indicates 81% local control of tumor in previously untreated patients treated for primary cancer of the oral cavity. Table 3 also shows 67% local control of tumors in previously treated patients with recurrent cancer of the oral cavity.

Regional Control. None of the patients presented with regional nodal metastasis. Four patients, all with tongue primary lesions, developed subsequent neck nodal disease an average of 6 months following initial treatment. One of these patients (T2 tongue cancer) was salvaged with a radical neck dissection 5 months after initial laser excision and presently shows no evidence of disease more than 5 years after treatment. The other three patients with nodal disease died an average of 21 months after primary treatment despite all conventional measures.

SURGICAL MARGINS

Histopathologic examinations of the resected specimens revealed cancer at one or more margins in 12 of the 31 excisions (39%). Positive margins were noted in specimens from the floor of the mouth (four), tongue (six), and retromolar trigone (two). Nine of these patients (75%) have shown no evidence of disease following either careful follow-up (no further treatment), another laser resection, or postoperative radiation therapy. Eight patients with positive margins were treated with postoperative radiation therapy. Five of these patients have achieved long-term control. Three patients with positive margins in the initial specimen (T1 tongue [one], T3 tongue [one], and T3 floor of mouth [one]) developed locally recurrent cancer despite postoperative radiation therapy and died of disease an average of 17 months following laser excision. Four patients with positive margins were followed closely without receiving any further therapy. Three of these patients (T1 tongue [two], T2 floor of mouth [one]) have shown no evidence of disease. The

TABLE 3. LOCAL CONTROL BY SITE

Site	Laser Resection			Laser Resection and Postoperative Radiation		
	Control	Failure	Total Control	Control	Failure	Total Control
Previously untreated carcinoma (n = 22)						
Tongue*	1	2*	2/3	1	2	1/3
Buccal mucosa	—	—	—	2	—	2/2
Retromolar trigone	—	—	—	2	—	2/2
Floor of mouth	5		5/5	2	1	2/3
Palate	2		2/2	—	—	—
Alveolus	2†		2/2	—	—	—
Total	10	2	11/12	7	3	7/10
Recurrent carcinoma (n = 9)						
Tongue	3	1	3/4	1	1	1/2
Buccal mucosa	—	1	0/1	—	—	—
Retromolar trigone	1	—	1/1	—	—	—
Floor of mouth	1	—	1/1	—	—	—
Total	5	2	5/7	1	1	1/2

*One patient (T1 anterior tongue) salvaged with second laser excision.

†One patient died of local disease at second primary site following laser excision.

fourth patient (T1 tongue) developed locally recurrent tumor and is now free of disease after a repeat laser excision.

COMPLICATIONS

Eleven patients (39%) suffered a total of 17 complications necessitating 31 additional operative procedures and three courses of hyperbaric oxygen treatment. Exposed mandible (six) and trismus (three) often resulted in severe disability. Other complications included nonhealing ulcer/necrosis (five), orocutaneous fistula (two), and nasopharyngeal stenosis (one). Table 4 indicates the complications by site in relation to postoperative radiation therapy. Of the 16 patients who did not receive postoperative radiation therapy, four (25%) had a serious complication while seven (58%) of 12 patients who had postoperative radiation experienced a severe complication.

Exposed Mandible. Six patients had an exposed section of mandible for at least 4 months following laser excision of lesions of the tongue (three), floor of the mouth (two), and retromolar trigone (one). Three patients in this group did not have postoperative radiation. One developed local recurrence 13 months after initial resection and died of disease. The other two patients responded to office debridement of the local wound and are healed and free of disease. The three patients with exposed mandible who received radiation therapy developed osteonecrosis of that portion of the mandible. Two of these patients developed small orocutaneous fistulas. They required excision of a portion of the mandible and complex wound closure with multistaged local and distant flaps. The third patient with osteonecrosis was treated with multiple debridements and hyperbaric oxygen and finally healed. She recently had reconstruction of the area with a scapular microvascular free flap. All of the five survivors have had no recurrent disease and are healed, eating by mouth, and talking satisfactorily.

Ulceration and Necrosis. Five patients had persistent ulceration and necrosis lasting more than 4 months following laser excision of cancer of the floor of the mouth (three), tongue (one), and buccal mucosa (one). Four patients with this problem had received postoperative radiation therapy. Three of these five patients healed spontaneously over a 10-month period. One patient developed necrosis in the infratemporal fossa necessitating debridement via a Caldwell-Luc approach and healed after hyperbaric oxygen treatments. The final patient in this group had an ulcerated area that progressed to exposed mandible before the completion of radiation therapy and to osteonecrosis requiring partial mandibulectomy and complex flap closure.

Trismus and Ankylosis. Three patients developed debilitating trismus and some degree of mandibular ankylosis following laser excision of a surface lesion of the buccal mucosa (two) or retromolar trigone (one). All had received postoperative radiation therapy and their mandibles were intact. All three of these patients have been cured of cancer for a long time. None can chew or wear dentures. All three can speak and swallow satisfactorily and are

TABLE 4. COMPLICATIONS BY SITE AS INFLUENCED BY POSTOPERATIVE RADIATION THERAPY

Site	Postoperative Radiation Therapy	No Postoperative Radiation Therapy	Total
	No. Pts With Complications	No. Pts With Complications	
Tongue	2/5	1/5	3/10
Buccal mucosa	2/2	0/1	2/3
Retromolar trigone	1/2	0/1	1/3
Floor of mouth	2/3	3/6*	5/9
Palate	—	1/2*	1/2
Alveolus	—	0/2	0/2
Total	7/12 (58%)	4/16 (25%)	11/28 (39%)

*One patient with two separate primary lesions had complication following treatment at each site.

maintaining their weight. One patient (retromolar trigone primary lesion) has healed after local debridement and hyperbaric oxygen treatment and has temporomandibular joint ankylosis with minimal movement and an intraincisor opening of 22 mm. A second patient (buccal mucosa primary lesion) underwent unsuccessful gap arthroplasty and presently has very painful trismus with an intraincisor opening of 9 mm. The third patient developed severe wound breakdown with fistula and osteonecrosis following elective intraoral excision of the coronoid process for her trismus. She required hyperbaric oxygen treatments, multiple transoral debridements, and eventually hemimandibulectomy. She still has painful trismus on the opposite side as well as ipsilateral pain and is unable to chew.

Nasopharyngeal Stenosis. Nasopharyngeal stenosis developed in one patient following full-thickness laser resection of an uvula–soft palate cancer. The posterior wall was not incised by the laser and the stenosis was from the lateral bands. Operative correction on two separate occasions has resolved the problem without permanent residual injury.

DISCUSSION

Use of the laser has become popular for the transoral excision of oral cavity cancers. For selected, favorable, small, superficial lesions, resection with the laser as a cutting tool should result in little or no blood loss and minimal morbidity. Use of the microscope with the laser results in an increase in operative time to do the resection. There are no data to suggest, however, that there is any increase in morbidity related to this. It is important to state that the CO_2 laser is not a treatment modality itself, but rather a valuable tool to aid in the treatment of these tumors.

Patients in this series had superficial cancer of the oral cavity that was accessible for laser excision. Not all patients had extremely small lesions. Many of the tumors were T2 and some were superficial T3. The local control rate of 77% compares favorably with the reported results following either conventional or laser excision of these lesions. Patients with primary lesions demonstrated a local control rate of 81% while laser excision of recurrent lesions resulted in a 67% local control rate.

None of the patients in the series had neck disease at the time they were initially treated. The only patients to develop subsequent neck metastasis had primary tongue cancer origin. One patient developed neck nodal metastasis without local recurrence. The other three patients developed both local and neck nodal disease.

The issue of positive burn margins in laser-resected patients remains unclear. The question is whether or not to treat all patients with positive resection margins with postoperative radiation therapy. The overall positive margin rate of 39% certainly indicates that 2-cm gross margins are not adequate to encompass all microscopic margins in these patients. It is apparent that lesions involving the floor of the mouth, tongue, and retromolar trigone require larger margins. The use of frozen sections at the operating table has not been entirely helpful in obtaining negative margins. Perhaps more frozen sections or Moh's technique should be done in this regard. Some reliable patients with positive margins from resected lesions that are pathologically favorable and whose tumor defect is easily accessible for examination may be followed expectantly. These patients may be spared the added morbidity of radiation therapy or an additional operative procedure.

A specific advantage of using the laser for resection of these tumors is that the removal of lesions over the mandible, including the excision of mandibular periosteum, is reported to heal primarily without difficult or debilitating reconstruction. Some patients in this series did heal in this manner. When prompt primary healing did not occur, however, the results were especially catastrophic. All three patients with exposed mandible given postoperative radiation developed severe osteonecrosis.

Another claimed specific advantage of using the laser is that the mandible can be left intact even when treating small superficial cancers of the buccal mucosa and retromolar trigone overlying the mandible. This series has shown that dissection of tumor from over the pterygoid muscles in patients with intact mandibles who are then given postoperative radiation results in the particularly incapacitating problems of painful trismus and ankylosis of the mandible. None of these patients can chew or wear dentures. Therapy for this posttreatment condition remains problematic.

CONCLUSIONS

Based on our study of this group of patients, the following conclusions are made. Transoral laser excision of small, superficial, accessible cancers of the oral cavity results in satisfactory tumor control. Greater than 2 cm of gross-cut tumor margin may be necessary to obtain microsurgically clear margins in treating tumors of the tongue, floor of the mouth, and retromolar trigone. Most patients with tongue tumors should have postoperative radiation to the neck because of the probability of neck nodal disease. All patients with nonhealing ulcers or exposed mandible should be treated aggressively with full-thickness reconstructive coverage prior to radiation therapy. Painful trismus and ankylosis may be unavoidable in patients with an intact mandible who have had dissection over the pterygoid musculature and postoperative radiation therapy. The treatment of this latter condition remains a difficult problem without any clearly optimal treatment.

REFERENCES

1. Strong MS, Jako GJ. Laser surgery in the larynx. Early clinical experience with continuous CO_2 laser. Ann Otol Rhinol Laryngol 1972;81:791-8.

2. Strong MS, Vaughan CW, Healy GB, Shapshay SM, Jako GJ. Transoral management of localized carcinoma of the oral cavity using the CO_2 laser. Laryngoscope 1979;89:897-905.

3. Guerry TL, Silverman S, Dedo HH. Carbon dioxide laser resection of superficial oral carcinoma: indications, technique, and results. Ann Otol Rhinol Laryngol 1986;95:547-55.

4. McDonald GA, Simpson GT. Transoral resection of lesions of the oral cavity with the carbon dioxide laser. Otolaryngol Clin North Am 1983;16:839-47.

5. Strong MS, Vaughan CW, Jako GJ, Polanyi T. Transoral resection of cancer of the oral cavity: the role of the CO_2 laser. Otolaryngol Clin North Am 1979;12:207-18.

6. American Joint Committee on Cancer. Beahrs OH, Myers MH, eds. Manual for staging of cancer. Ed 2. Philadelphia: JB Lippincott Co, 1983.

MANAGEMENT OF PATIENTS WITH LONG-TERM TRACHEOTOMIES AND ASPIRATION

RALPH W. GILBERT, MD
LINKOPING, SWEDEN
JEFF C. MCILWAIN, MD
TORONTO, CANADA
DOUGLAS P. BRYCE, MD
TORONTO, CANADA
IAN R. ROSS, MD
TORONTO, CANADA

The purpose of this study was to develop a management protocol for patients with long-term tracheotomies and aspiration, in order to develop clinical criteria for extubation and reduction of aspiration-related complications. We studied 39 patients with tracheotomies in place for over 3 months, 28 of whom completed management. Patients were classified according to degree of impairment and managed with the aims of avoiding aspiration and performing extubation whenever feasible. Criteria for choosing various management strategies are presented.

KEY WORDS — aspiration, gastrostomy tube, nasogastric tube, tracheotomy.

INTRODUCTION

It is not unusual for an otolaryngologist to be faced with the problem of managing a neurologically impaired patient with a tracheotomy and nasogastric tube. He or she must face the clinical questions of whether the patient can be extubated and how a tendency toward aspiration can be managed.

The process of normal deglutition is complex, requiring a high degree of integration of sensory and motor functions. It involves four basic stages: 1) velopharyngeal closure to prevent nasal reflux, 2) pharyngeal peristalsis to propel the bolus into the pharynx, 3) airway protection by elevation and closure of the larynx, and 4) cricopharyngeal or upper esophageal sphincter relaxation to allow passage of the bolus.

The patient with brain stem or major cerebrocortical injuries often is left with various neurologic defects. Superimposed on these deficits are the direct effects of tracheotomy and nasogastric tubes. Tracheotomy tube effects include impairment of laryngeal elevation during deglutition and decompression of the normal subglottic pressure maintained during swallowing, resulting in an increased risk of aspiration.[1,2] Nasogastric tubes contribute to aspiration locally, by direct effects on the cricoid cartilage and the cricopharyngeus muscle, or distally, by interference with the normal function of the lower esophageal sphincter allowing reflux of gastric contents.[1-10]

The Queen Elizabeth Hospital is a major institution providing rehabilitation and chronic care in metropolitan Toronto. A significant proportion of the patients in this institution suffer from a variety of neurologic and other physical impairments. Some of these patients have received severe neurologic insults and present with a tracheotomy and nasogastric feeding tube as the end stage of acute care management. We intended to develop a management protocol for such patients, with the aim of developing clinical criteria for extubation and reduction of aspiration-related complications.

METHODS

From July 1984 to July 1986, 39 patients were identified who had had a tracheotomy in place for more than 3 months. No other criteria were used for patient selection. Patients were assessed clinically with a detailed history including documentation of airway-related complications, eg, pneumonia, hemoptysis, stomal infection. Physical examination included a detailed neurologic examination, flexible nasolaryngoscopy, and limited bronchoscopy. Special radiologic investigations of dynamic aerodigestive function were used infrequently, as the general state and neurologic status of the patients would not allow an adequate study.

Patient assessment was based primarily on the findings at nasolaryngoscopy, with particular emphasis placed on degree of aspiration, laryngeal protective function, and sensation. Aspiration was graded as absent when no aspiration was seen at nasolaryngoscopy, mild when small amounts of pharyngeal contents intermittently penetrated the larynx, moderate when greater volumes of pharyngeal contents persistently penetrated the larynx, and severe when there was free flow of pharyngeal contents into the airway. Laryngeal protective function was assessed as normal when closure and elevation were normal, near normal when the glottis did not close completely but coordinated motor

From the Department of Otolaryngology–Head and Neck Surgery (Gilbert, Bryce, McIlwain) University of Toronto, and Queen Elizabeth Hospital (Ross), Toronto. Dr Gilbert is now at the Department of Otolaryngology, University Hospital, Linkoping, Sweden.

Presented at the meeting of the American Laryngological Association, Denver, April 25-26, 1987.

REPRINTS — Douglas P. Bryce, MD, 7 Eaton Wing N, Room 228, Toronto General Hospital, 200 Elizabeth St, Toronto, Ontario, Canada M5G 1L7.

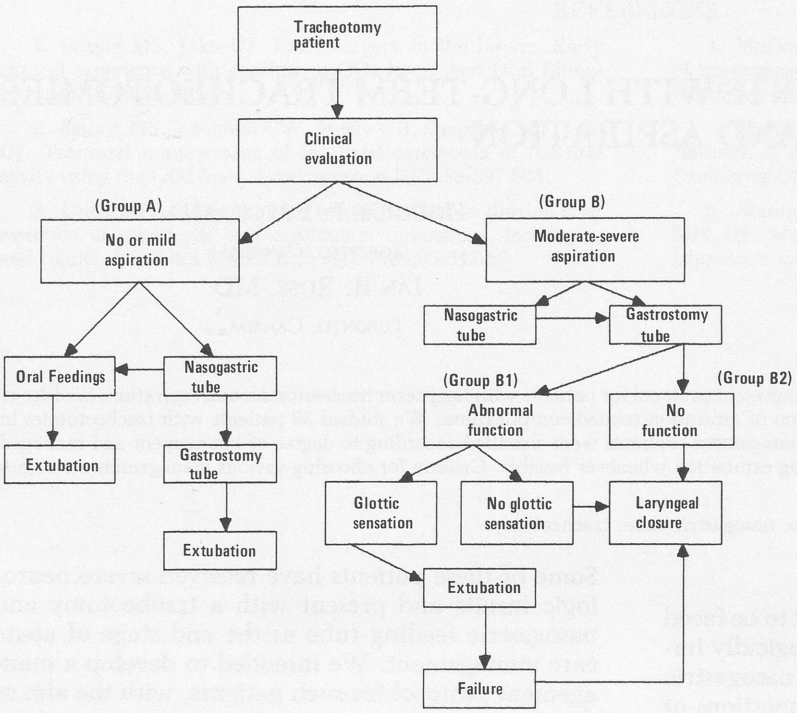

Fig 1. Management protocol.

activity was observed during the normal phase of deglutition, abnormal when the glottis closed incompletely and out of sequence with normal deglutition, and no function when no glottic activity was observed. In the final category, most patients maintained the glottis in full abduction with little or no observed movement. Glottic sensation was observed as present or absent based on the patient's response to mucosal stimulation with the flexible nasopharyngoscope. Basic demographic information was retrieved regarding age, sex, and principal neurologic diagnosis.

A management protocol was developed on an empiric basis from early observations of a small number of patients and a review of the literature. In developing the protocol, we assumed that 1) nasogastric tubes are a significant risk factor for aspiration and 2) extubation is a desirable end point in patient management. The protocol, outlined in Fig 1, is based on an initial evaluation of aspiration, with patients divided into two large groups, those with no or mild aspiration (group A) and those with moderate to severe aspiration (group B).

Group A patients are fed either orally or by nasogastric tube. Those fed orally with normal laryngeal function are extubated, provided there are no medical contraindications. Those patients fed by nasogastric tube undergo placement of a percutaneous gastrostomy tube and are considered for extubation provided there are no medical contraindications. Patients with laryngeal stenosis or airway problems that would preclude extubation are referred for surgical correction and subsequently reconsidered for extubation.

Group B patients are fed by either nasogastric or percutaneous gastrostomy tube at presentation. For those patients with nasogastric tubes, feeding by gastrostomy tubes is tried, and all patients are reevaluated and based on laryngeal function divided into two groups. Group B1 patients are those with abnormal protective function, and group B2 patients are those with no laryngeal protective function. Patients in group B are unlikely to have normal or near-normal glottic function because of the severe nature of their neurologic injuries. Group B2 patients, because of their high risk for aspiration-related complications, are referred for surgical closure of the larynx by a modification of the technique described by Baron and Dedo.[11] Group B1 patients without laryngeal sensation are referred for surgical laryngeal closure, and those with sensation are considered for extubation provided there are no medical or airway-related contraindications. Should the latter group fail extubation, ie, require repeat tracheotomy, laryngeal closure is considered.

Results at the end of this 2-year study are reported in an incomplete form, as only 28 of the 39 patients completed management. The families of five patients either did not wish further intervention or preferred to defer a decision on management, and six patients had not completed the protocol at the completion of the study. Follow-up of patients ranged from 3 months to 2 years.

RESULTS

In the group of patients reviewed, 18 were men and ten were women. Their ages ranged from 24 to 71 years, with a mean of 45 years (Fig 2). Principal neurologic diagnoses of the original 39 patients are listed in Table 1. Trauma and cerebrovascular disorders predominate.

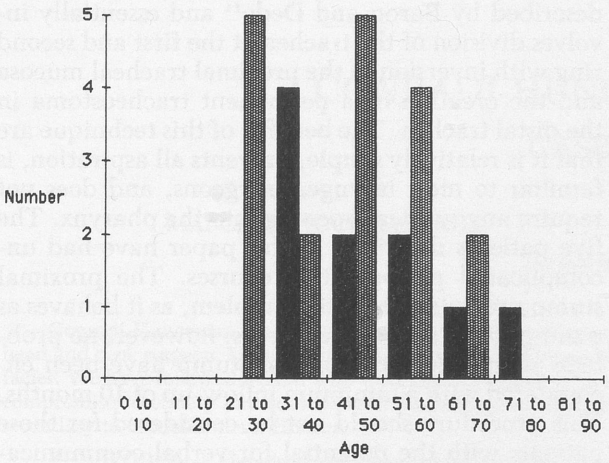

Fig 2. Ages of 28 patients reviewed. Range is 24 to 71 years, mean is 45. Light bars — men, dark bars — women.

There were 18 patients in group A. Results for this group are presented in Table 2, which shows that 14 of the 18 patients have been extubated without complication. One patient with quadriparesis at the C-3 level requires nocturnal ventilation and did not undergo extubation. Three patients have not tolerated attempts at extubation: one has persisting subglottic stenosis, one has pulmonary complications as a result of aspiration, and one has had more severe aspiration since a laryngoplasty was performed to improve the airway. Four of the 18 patients in this group receive all nutrition orally, and the remainder are fed by gastrostomy tube.

Ten patients were in group B (Table 3); five of these were subclassified into group B1 and five into group B2. Two of the patients in group B1 were extubated following placement of a percutaneous feeding gastrostomy tube and have had no complications, and one patient died of pneumonia 6 months after extubation. One patient with a severe seizure disorder requires a tracheotomy for airway protection during seizures, and the last patient underwent laryngeal closure without complications.

Four of the five patients in group B2 have undergone laryngeal closure. One of the four died as a result of underlying disease, and the other three patients are functioning well. One patient is a poor surgical risk and remains tracheotomized.

DISCUSSION

This study presents and evaluates an approach to the management of the chronically neurologically disabled patient with a long-term tracheotomy and nasogastric tube with or without aspiration.

TABLE 1. NEUROLOGIC DIAGNOSES (N = 39)

	No. Patients
Intracerebral hemorrhage	13
Cerebral contusion	9
Anoxic brain injury	7
Subdural hematoma	5
Quadriparesis	2
Tuberculous meningitis	1
Cerebellar degeneration	1
Epilepsy	1

TABLE 2. RESULTS FOR GROUP A PATIENTS (N = 18)

	No. Patients
Extubation	14
No or failed extubation	4*
Oral intake	14
Gastrostomy tube	4

*One patient requires nocturnal ventilation, one has subglottic stenosis, two failed because of aspiration.

The patients reviewed in this paper for the most part were severely disabled and required intensive nursing management, with many in a permanent vegetative state. One might wonder what purpose such an assessment of chronically disabled patients would achieve. It was hoped that this evaluation would produce a clinical protocol for management of chronic aspiration and define criteria for undertaking extubation. These aims were based on the assumption that decreasing the severity and frequency of aspiration, and removal of tracheotomies in patients who could function without them, would improve the quality of life for the patient and decrease the intensity of nursing care. Also, it was hoped that the knowledge gained in this evaluation might benefit those with less profound neurologic injuries.

The type of patients reviewed in this study presented difficulties in examination by routine clinical laryngologic techniques, as most were unable to cooperate or were in a fixed supine position. The use of the flexible fiberoptic nasopharyngoscope greatly facilitated the evaluation of such patients, as the larynx could be viewed from above or below and the amount of aspiration and quality of laryngeal function could be assessed. The grading scales developed for nasopharyngoscopic evaluation of aspiration and laryngeal function are obviously imperfect, as a certain amount of subjective evaluation is required for this grading. We were aware of this problem, but did not feel that any other system would produce a simple and relatively reproducible method of evaluation.

Based on our early experience with a small number of patients, it became apparent that patients could be divided into two large groups, those with mild to no aspiration and those with moderate

TABLE 3. RESULTS FOR GROUP B PATIENTS (N = 10)

	B1	*B2*
Extubation	2	0
Laryngeal closure	1	4
No or failed extubation	2*	1†
Oral intake	1	0
Gastrostomy tube	4	5

*One patient died of aspiration pneumonia; one with seizure disorder requires airway protection.

†Poor surgical risk.

to severe aspiration. The former group most often have normal or near-normal laryngeal function, and once the local influences of the nasogastric tube have been removed by either tube removal or placement of a permanent gastrostomy tube, then the majority of these patients may be extubated.

Patients with moderate to severe aspiration present a more difficult challenge, as many have minimal laryngeal protective function and little glottic or supraglottic sensation and have had numerous aspiration-related complications. Generally these patients are vegetative, with no potential for verbal communication, and in the majority of cases require intensive pulmonary toilet. It is our view that all patients in this group should be considered for placement of feeding gastrostomy tubes as the initial step in management. Those patients with laryngeal sensation and a degree of laryngeal motor function should be considered subsequently for a trial of extubation, as they may have adequate protective laryngeal reflexes. Those patients who fail extubation, and patients with little or no laryngeal function, in our view are managed best surgically by the technique of subglottic laryngeal closure.

The technique of subglottic laryngeal closure advocated by the authors is a modification of that described by Baron and Dedo[11] and essentially involves division of the trachea at the first and second ring with inversion of the proximal tracheal mucosa and the creation of a permanent tracheostoma in the distal trachea. The benefits of this technique are that it is relatively simple, prevents all aspiration, is familiar to most laryngeal surgeons, and does not require any surgical opening into the pharynx. The five patients described in this paper have had uncomplicated postoperative courses. The proximal stump presents a theoretic problem, as it behaves as a sump for pharyngeal contents; however, no problems related to the proximal stump have been encountered with a minimum follow-up of 10 months. This procedure should not be considered for those patients with the potential for verbal communication, as the procedure has not been demonstrated to be reversible.

Finally, this paper has outlined a protocol for management of the chronically ill patient with a long-term tracheotomy. The system presented, although simple, allows patients to be classified according to severity of aspiration and laryngeal function. The evaluation of this protocol has indicated that it reduces the risks and incidence of aspiration and its complications and that it predicts those patients amenable to extubation.

REFERENCES

1. Cameron JL, Reynolds J, Zuidema GD. Aspiration in patients with tracheotomies. Surg Gynecol Obstet 1973;136:68-70.

2. Arms RA, Dines DA, Tintsman TC. Aspiration pneumonia. Chest 1974;65:136-9.

3. Dines DA, Titus JL, Sessler AD. Aspiration pneumonia. Mayo Clin Proc 1970;45:347-60.

4. Holinger PH, Loeb WJ. Feeding tube stenosis of the larynx. Surg Gynecol Obstet 1946;83:253-8.

5. Wolff AP, Kessler S. Iatrogenic injury to the hypopharynx and cervical esophagus: an autopsy study. Ann Otol Rhinol Laryngol 1973;82:778-83.

6. Nagler R, Spiro HM. Persistent gastroesophageal reflux induced during prolonged gastric intubation. N Engl J Med 1963; 269:495-500.

7. Foster CA, Meyerhoff WL. Cricoid chondritis. Ear Nose Throat J 1980;59:28-31.

8. Sofferman RA, Hubbell RN. Laryngeal complications of nasogastric tubes. Ann Otol Rhinol Laryngol 1981;90:465-8.

9. Friedman M, Baim H, Shelton V, et al. Laryngeal injuries secondary to nasogastric tubes. Ann Otol Rhinol Laryngol 1981; 90:469-74.

10. Alessi DM, Berci G. Aspiration and nasogastric intubation. Otolaryngol Head Neck Surg 1986;94:486-9.

11. Baron BC, Dedo HH. Separation of the larynx and trachea for intractable aspiration. Laryngoscope 1980;90:1927-32.

CONRADI-HUNERMAN SYNDROME

CASE REPORT

MARCELO HOCHMAN, MD WILLARD E. FEE, JR, MD

STANFORD, CALIFORNIA

Conradi-Hunerman syndrome, a variant of chondrodysplasia punctata, rarely presents with primary manifestations relevant to the head and neck surgeon. Usually, the disease is evidenced by malformation of the extremities, cataracts, cutaneous lesions, and an unusual facies. We have followed a child with Conradi-Hunerman syndrome for 7 years whose primary manifestation of the disease is respiratory compromise secondary to calcification of the laryngotracheobronchial tree. In addition, he has a conductive hearing loss thought to be secondary to ossicular chain fixation.

KEY WORDS — chondrodysplasia punctata, Conradi-Hunerman syndrome.

INTRODUCTION

Chondrodysplasia punctata is the term used to describe a group of bone disorders characterized by the presence of punctate epiphyseal calcifications. Children affected with this group of disorders rarely present with manifestations relevant to the head and neck surgeon. The purpose of this paper is to present a 7-year follow-up on a patient with Conradi-Hunerman syndrome, a variant of chondrodysplasia punctata, whose primary manifestation is respiratory embarrassment secondary to calcification of his laryngotracheobronchial tree. The patient also has a conductive hearing loss thought to be due to ossicular chain fixation.

CASE REPORT

This child was born at another institution, the 3.03-kg product of a 40-week pregnancy complicated by a maternal grand mal seizure at 5 months of gestation. The mother had a history of encephalitis as an infant and had her first seizure approximately 1 year prior to the pregnancy. For the remainder of the pregnancy, she was treated with phenobarbital. No other seizures, medications (including Dilantin or warfarin), or illnesses were reported. Labor and delivery were uncomplicated. Apgar scores are not available. Shortly after birth, the child was noted to have heavy breathing; however, he did well and was discharged from the hospital 2 days later. Increasing stridor precipitated a physical examination and genetic, metabolic, and radiologic workup at 3 weeks of age. Radiographs revealed symmetric stippled calcifications of the proximal femoral epiphyses, lumbar vertebrae, and pelvis, as well as calcification of the larynx, trachea, and bronchial cartilages (Fig 1). Hand x-ray films showed distal phalangeal hypoplasia. Based on these findings, along with an unusual facies characterized by a severely hypoplastic nose and frontal bossing, the diagnosis of chondrodysplasia punctata, Conradi-Hunerman type, was determined.

The child had repeated episodes of pneumonia until at 19 months of age (May 1980) he presented at Stanford University Hospital with severe airway distress and a subsequent respiratory arrest with bradycardia. Although difficult, intubation was accomplished with a 3-mm endotracheal tube. Extubation attempts failed, and a tracheostomy tube was placed (Shiley No. 00). Direct laryngoscopy and bronchoscopy at the time showed a narrowed tracheal lumen (approximately 70% to 80% stenosis) and stenosis of the main stem bronchi, worse in the left lung than in the right.

The patient's subsequent medical course was marked with repeated episodes of respiratory infections and pneumonias with varying degrees of airway distress. Between May 1980 (19 months of age) and January 1987 (8 years 3 months), he underwent 12 endoscopies to evaluate the airway. Over this period of time, the calcifications disappeared on x-ray examination (Fig 2), the tracheal lumen grew less than 2 mm in diameter, and the main stem bronchi remained essentially unchanged since the initial bronchoscopy.

The larynx, though slightly small, is normal and not the site of airway obstruction. Currently, the patient wears a snug-fitting No. 9 Montgomery® Safe-T-Tube, which he maintains unplugged. His overall growth and development have been somewhat slow, but currently he is in the 75th percentile for height and 50th percentile for weight. Mentally, he performs a few grade levels below what is expected in a regular school. In addition to his unusual physical appearance and airway problems, he has a progressive conductive hearing loss thought to be due to ossicular chain fixation and intermittent serous otitis

From the Division of Otolaryngology/Head and Neck Surgery, Stanford University Medical Center, Stanford, California.

Presented at the meeting of the American Laryngological Association, Denver, April 25-26, 1987.

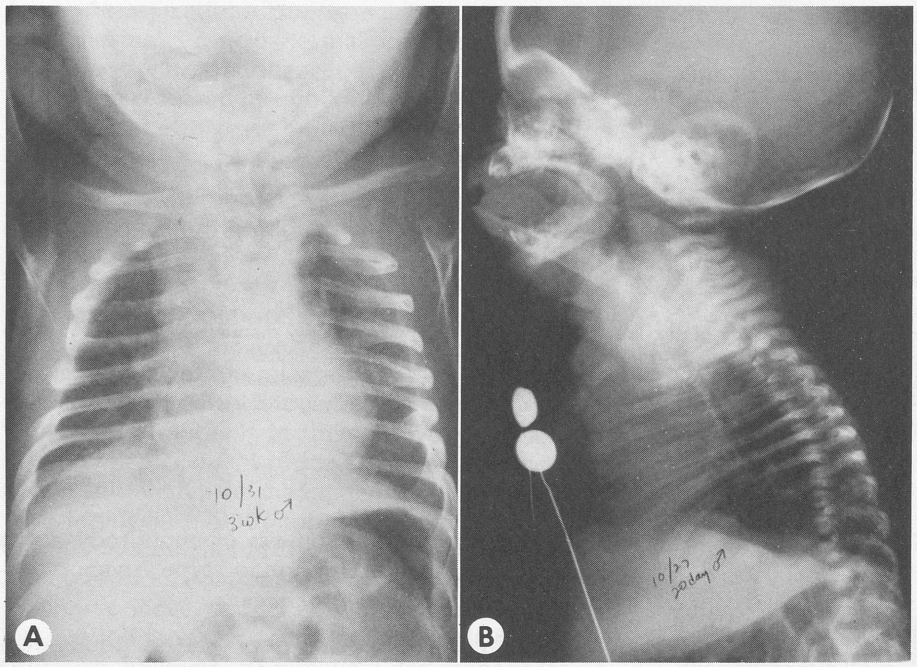

Fig 1. Chest radiographs taken at time of initial presentation with respiratory distress. Calcifications of laryngotracheobronchial tree are readily visible. Right upper lobe pneumonia is also evident. A) Anteroposterior, B) lateral.

media. He wears hearing aids with good results, and his parents have declined exploratory tympanotomy.

The results of tests for disorders of calcium metabolism, including serum calcium, phosphorus, and parathyroid hormone levels, were normal, and the patient has no orthopedic, ophthalmologic, dermatologic, or cardiac abnormalities. Based on the child's clinical picture and an extensive family workup including detailed physical and radiologic examination of the parents, chromosomal analyses, and delineation of the family pedigree, we believe that this represents a sporadic case (spontaneous mutation) of chondrodysplasia punctata, Conradi-Hunerman type (Fig 3).

DISCUSSION

Conradi-Hunerman syndrome is a variant of chondrodysplasia punctata, a heterogeneous group of rare bone dysplasias characterized by punctate epiphyseal calcifications. These calcifications are evanescent and usually disappear by the third year of life. Numerous additional clinical features have been associated with this basic disturbance, most notably saddle nose deformity, micromelia, rhizomelia, short stature, flexion contractures, and dermatoses, among others. Calcification of the laryngotracheobronchial tree has been reported in patients with this syndrome, but more commonly as an isolated rarity. Its presence is not always associated with respiratory embarrassment, nor does its disappearance signify recovery, as this case demonstrates.

Since Conradi's initial description in 1914,[1] this group of disorders has been reported under a variety of synonyms: chondrodystrophia epiphysialis punctata, stippled epiphysis disease, dysplasia epiphysialis punctata, chondroangiopathia calcarea punctata, Conradi's disease, and others. The preferred terminology now is chondrodysplasia punctata.[2] In retrospect, some cases reported as chondrodysplasia punctata are probably other, now-established entities.[3-5]

There are four described phenotypes of chondrodysplasia punctata. Many cases that do not fit into these four groups are thought to be evidence for a continuum of one disease process with varied expression rather than different disease processes.

Conradi-Hunerman syndrome is the most common type of chondrodysplasia punctata and the most varied in presentation. According to Spranger et al,[5] some patients have cataracts (17%), ichthy-

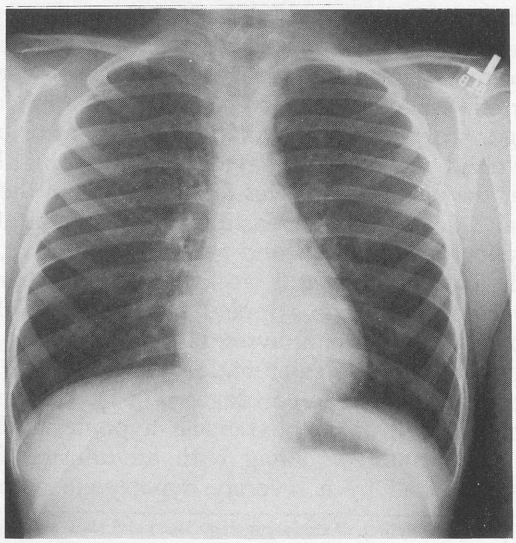

Fig 2. Posteroanterior chest radiograph of patient at 8 years of age, without evidence of airway calcification.

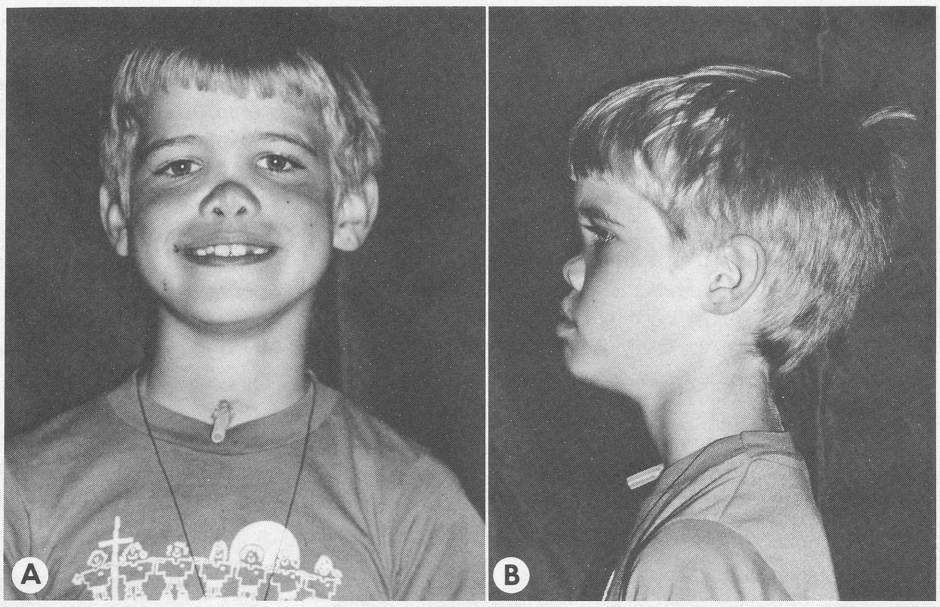

Fig 3. Patient at 8 years 3 months of age. Note characteristic frontal bossing and hypoplastic nasal dorsum. He is wearing a No. 8 Montgomery® Safe-T-Tube. A) Front view, B) profile.

otic skin changes (28%), and scoliosis, while others have only the characteristic facies. The dermatologic findings (atrophoderma follicularis) may be the only diagnostic features in those patients with mild expression who live to adulthood. The majority of cases are sporadic mutations, although some cases in the literature appear to conform to the autosomal dominant pattern of inheritance.[6] Phenocopies of the Conradi-Hunerman type are known to be produced by warfarin and Dilantin taken during pregnancy.[7-9] Histologic studies of the involved epiphyseal cartilages show mucoid degeneration, cyst formation, calcification, and fibrous tissue formation with neovascularization. Normal columnization of cartilage cells is observed in some growth plates, and failure of orientation in others.[10] Some investigators have felt that the same process occurs in the ocular lens, which like cartilage has a high mucopolysaccharide content, thus accounting for the relatively common occurrence of cataracts in these patients.[11] Since the clinical picture of the Conradi-Hunerman type is so varied, there is no one set of criteria for diagnosis. Rather, a complete workup (physical examination and genetic, metabolic, and radiologic workup) is in order to exclude the other versions of the disease.

The rhizomelic type is associated with severe symmetric proximal shortening of the extremities, vertebral body clefts (100%), high incidence of cataracts (72%) and contractures (61%), and death in early infancy.[5] Evidence for transmission of this type by the homozygous state of an autosomal gene (autosomal recessive trait) is its frequent association with parental consanguinity and recurrences in siblings.[12]

An X-linked dominant form has been reported with presumed lethality in affected male fetuses, since it has been documented only in female patients.[13,14] It is associated with linear skin lesions, cataracts, and markedly asymmetric skeletal involvement.

The most recently described type of chondrodysplasia punctata is an X-linked recessive one resulting from an inherited deletion of the short arm of the X chromosome (Xp).[15] The most noteworthy clinical difference between this type and the Conradi-Hunerman type is the consistent presence of mental retardation in the recessive type. Symmetric skeletal involvement and distal phalangeal hypoplasia are common features. Prenatal diagnosis of the X-linked recessive type of chondrodysplasia punctata or verification in an apparently sporadic case may be possible by detection of reduced activity of steroid sulfatase, since the loci coding for this enzyme system is located at the distal tip of Xp. Cytogenetic studies by amniocentesis or routine chromosomal smears also may be used.

The most remarkable finding in the patient presented is the calcification of the larynx, trachea, and bronchi. Among the many abnormalities associated with congenital stridor, premature calcification of the airway is one of the rarest. Normally, one does not see calcification of these cartilages before the third decade of life, except in the body and greater horn of the hyoid, where it may be present from the fifth month of fetal life.[16] The prognostic significance of the tracheobronchial calcifications is unclear. Reversal of the calcifications in the early years of life was once thought to be an encouraging sign. In effect, it is a trait of the disorder for these to disappear. Patients in the literature with complete disappearance of the calcifications on x-ray examination and normal airways contrast with some who continued to require a tracheostomy with obvious arrest in tracheal growth, and others whose airways are smaller than normal yet show no evidence of respiratory embarrassment or developmental retardation.[17-21] At least one other report

presents an intant with evanescent calcifications of the airway who never had stridor.[22] The calcifications themselves are unexplained. So far as is known, calcification of cartilage in the adult respiratory tract is a degenerative phenomenon similar to that occurring in the cartilaginous portion of the ribs and has no clinical significance. It is difficult to prove a causal relationship between the calcifications, stridor, and tracheal and bronchial growth arrest in children affected with chondrodysplasia punctata, but intuitively there seems to be one. Whether the same process is the cause of the progressive conductive hearing loss in our patient is speculative.

The main finding on repeated diagnostic endoscopies of this patient was tracheal and bronchial stenosis with markedly retarded airway growth over time. There were no abnormal ridges or masses reminiscent of the ossified features seen in adults affected with tracheopathia osteoplastica. Histologic examinations have not shown ossification in patients with Conradi-Hunerman syndrome; therefore, these entities do not seem to be related.

This patient currently is limited markedly in terms of exercise tolerance and has a limited airway reserve that is easily compromised by infection. The life-limiting factor for him and other children with the disease seems to be stenosis of the airway at the level of the trachea and proximal bronchi. At this point, observation and supportive care during the episodes of acute airway compromise are all that can be offered. He soon will require surgical correction of his bilateral proximal bronchial stenoses.

REFERENCES

1. Conradi E. Vortzeitges Auftreten von Knochen — und eigenartigen Verkalkungskernen bei Chondrodystrophia foetalis hypoplastica. J Kinderheilkd 1914;80:86-97.

2. Maroteaux P, Langer LO, Silverman FN, Sauvegrain J, Scott J, Spranger J. International nomenclature on bone dysplasias. Ann Radiol (Paris) 1970;13:455-64.

3. Jan JE, Hardwick DF, Lowry RB, McCormick AQ. Cerebro-hepato-renal syndrome of Zellweger. Am J Dis Child 1970; 119:274-7.

4. Valdmanis A, Wilson JR, Mann JD, Pearson G, Shaw MW. Subglottic pseudotumor, laryngeal dysplasia and chondrodysplasia calcificans congenita with a t(D;B) chromosomal translocation. Ann Genet (Paris) 1967;10:55-9.

5. Spranger JW, Opitz JM, Bidder U. Heterogeneity of chondrodysplasia punctata. Humangenetik 1971;11:190-212.

6. Silengo MC, Luzzatti L, Silverman FN. Clinical and genetic aspects of Conradi-Hunerman disease. J Pediatr 1980; 97:911-7.

7. Becker MH, Genieser NB, Feingold M, Miranda D, Spackman T. Chondrodysplasia punctata: is maternal warfarin therapy a factor? Am J Dis Child 1975;129:356-9.

8. Pettifor JM, Benson R. Congenital malformations with the administration of oral anticoagulants during pregnancy. J Pediatr 1975;86:459-62.

9. Mountain KR, Hirsh J, Gallus AS. Neonatal coagulation defect due to anticonvulsant treatment in pregnancy. Lancet 1970;1:265-8.

10. Karlen AG, Cameron JAP. Dysplasia epiphysialis punctata. J Bone Joint Surg [Br] 1957;39:293.

11. Yakovac WC. Calcareous chondropathies in the newborn infant. Arch Pathol 1954;57:62-79.

12. Gilbert EF, Opitz JM, Spranger JW, Langer LO Jr, Wolfson JJ, Viseskul C. Chondrodysplasia punctata — rhizomelic form: pathologic and radiologic studies of three infants. Eur J Pediatr 1976;123:89-109.

13. Happle R. X-linked dominant chondrodysplasia punctata: review of literature and report of a case. Hum Genet 1979;53: 65-73.

14. Manzke H, Christophers E, Wiedemann H-R. Dominant sex-linked inherited chondrodysplasia punctata: a distinct type of chondrodysplasia punctata. Clin Genet 1980;17:97-107.

15. Curry CJR, Magenis RE, Brown M, et al. Inherited chondrodysplasia punctata due to a deletion of the terminal short arm on an X chromosome. N Engl J Med 1984;311:1010-5.

16. Caffey J. Pediatric x-ray diagnosis, 7th ed. Chicago: Year Book Publishers, 1978:263-4.

17. Narcy P, Baculard J, Manac'h Y, Sterkers O, Bobin S. Stenose laryngo-tracheale chez des enfants atteints de maladies des epiphyses ponctuees. Ann Otolaryngol Chir Cervicofac 1979;96:905-12.

18. Goldbloom RB, Scott DJ. Calcification of cartilage in the trachea and larynx in infancy associated with congenital stridor. Pediatrics 1960;26:669-73.

19. Nabarro S. Calcification of the laryngeal and tracheal cartilages associated with congenital stridor in an infant. Arch Dis Child 1952;27:185-6.

20. Russo PE, Coin CG. Calcification of the hyoid, thyroid and tracheal cartilages in infancy. Am J Roentgenol 1958;80: 440-2.

21. Kaufmann HJ, Mahboubi S, Spackman TJ, Capitanio MA, Kirkpatrick J. Tracheal stenosis as a complication of chondrodysplasia punctata. Ann Radiol (Paris) 1976;19:203-9.

22. Marchal G, Baert L, van der Hauwaert L. Calcification of larynx and trachea in infancy. Br J Radiol 1974;47:896-7.

SELECTIVE, HISTAMINE-MEDIATED IMMUNOSUPPRESSION IN LARYNGEAL CANCER

WILLIAM J. RICHTSMEIER, MD, PHD
PETER STYCZYNSKI MICHAEL E. JOHNS, MD
BALTIMORE, MARYLAND

Immunosuppression observed even in the earliest laryngeal cancers can be, in part, reversed with H2 histamine antagonists. In an effort to explain this, we tested whether histamine could evoke changes in endogenous antitumor lymphokine production using tonsil lymphocytes as test cells. We have observed that lymphocytes, treated in vitro with histamine, display a significant suppression of lymphokine production and mixed lymphocyte proliferation response following galactose oxidase treatment. Interferon gamma production was reduced to less than 2% of control value in the presence of histamine. In contrast, the lymphokine-activated killer cell activity induced by purified, natural interleukin-2 was not affected by similar concentrations of histamine. Histamine appears to exert its inhibitory effect by stimulating the production of a substance released by suppressor T cells. The suppressive effects observed could be reversed by concomitant or sequential treatment with cimetidine or ranitidine and not by H1 histamine antagonists, indicating that it occurs through an H2 histamine receptor. These experiments suggest that histamine may have a profound suppressive effect on the lymphocyte population studied.

KEY WORDS — cimetidine, H2 histamine antagonists, histamine, interferon gamma, interleukin-2, ranitidine.

INTRODUCTION

Histamine continues to be of interest to otolaryngologists in its role as a mediator of allergy, as a therapeutic agent in otology, and as a modulator of the cellular immune response.[1-5] We have investigated the mechanisms by which immunomodulators affect delayed hypersensitivity reaction in head and neck cancer. Laryngeal cancers are of particular interest among the head and neck cancers, since they are among the earliest recognizable cancers in the head and neck. Even small laryngeal cancers may be associated with significant immunosuppression (unpublished results). Previously, reversal of skin test anergy in laryngeal cancer patients during treatment with cimetidine or ranitidine has been demonstrated. The in vivo effects of the H2 histamine antagonist implicates a role for histamine as a significant suppressor of lymphocyte function. A remarkable sensitivity of laryngeal cancer cells in vitro to the action of recombinant human interferon gamma (rHuIFN-γ) also has been observed (unpublished results). Because of these two observations, we investigated the effect that histamine might have on the production of interferon gamma (IFN-γ) in vitro. Previous experience has shown that the induction of IFN-γ by galactose oxidase (GO) or periodate involves cell-to-cell interactions in mixed lymphocyte preparations.[6] The purpose of the present investigation was to identify immunologic tests that could explain the above in vivo observations. We chose tonsil lymphocytes, since they are head and neck lymphoid tissues that are accessible for evaluation and would allow investigation of such cell-to-cell interactions.

MATERIALS AND METHODS

Tonsil lymphocytes were prepared as previously described[7] and maintained in RPMI-1640 media with fetal bovine serum (10%). Histamine (Sigma) was prepared in serum-free medium, frozen and thawed for each experiment; cimetidine for intravenous (IV) administration (Smith, Kline & French), powdered ranitidine (Dr R. T. Brittain, Glaxo Group Research Limited, Great Britain), and diphenhydramine for IV administration (Parke-Davis) were prepared similarly and frozen.

Production of IFN-γ was measured by the vesicular stomatitis virus cytopathogenic effect reduction assay in trisomy 21 fibroblasts.[8] Recombinant human IFN-γ (Hoffman LaRoche) was used as a laboratory reference reagent and standardized by the National Institutes of Health HuIFN standard (G-023901-530).

Following initial preparation, lymphocytes were incubated with control media or media containing the indicated concentrations of histamine and/or drugs overnight (20 hours). Cultures then were in-

EFFECT OF 10^{-4} *M* HISTAMINE ON IFN-γ PRODUCTION IN TONSIL LYMPHOCYTES

*Treatment**	*Mean IFN-γ Yield/mL*	*% Control*
Control media	650	100
Histamine 0-20 h	90	14
Histamine 0-44 h	72	11

IFN-γ — interferon gamma.

*Cells were incubated for 20 hours with or without histamine, washed, and then treated with galactose oxidase. Then cells were re-treated immediately with histamine or given control media for 24 hours, after which time supernatants were harvested for IFN-γ determination.

From the Department of Otolaryngology–Head and Neck Surgery, The Johns Hopkins School of Medicine, Baltimore. This work was funded in part by the Traylor Research Fund of The Johns Hopkins School of Medicine and performed while Dr Richtsmeier was the recipient of the American Cancer Society Clinical Oncology Career Development Award.

Presented at the meeting of the American Laryngological Association, Denver, April 25-26, 1987.

REPRINTS — William J. Richtsmeier, MD, PhD, Johns Hopkins School of Medicine, 600 N Wolfe St, Carnegie 469, Baltimore, MD 21205.

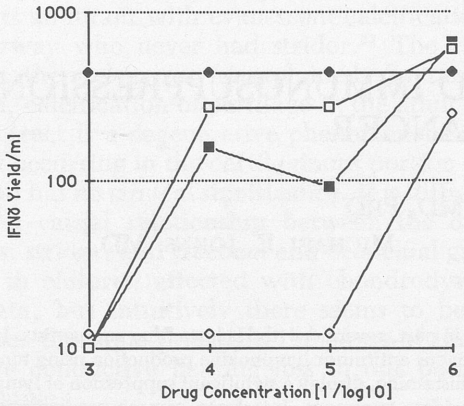

Fig 1. Dose response of histamine and combined histamine–H2 histamine receptor antagonist on interferon production. Tonsil lymphocytes were treated with drugs at concentrations indicated for 24 hours before induction with galactose oxidase. Supernatants were harvested 48 hours later. Mean yield of IFN-γ (units/mL) is plotted against molar concentration of various compounds employed. Solid diamonds — mean control yield; open diamonds — histamine; solid squares — histamine plus ranitidine; open squares — histamine plus cimetidine.

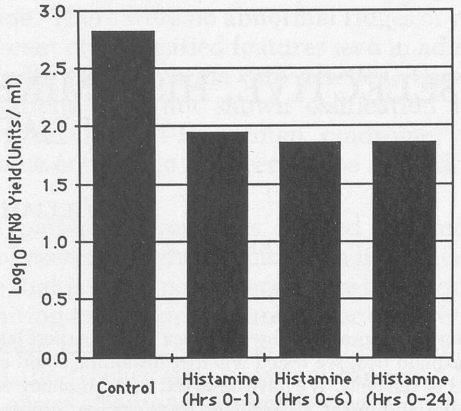

Fig 2. Effect of time of exposure to histamine on IFN-γ production. Interferon gamma yield following galactose oxidase induction of human tonsil lymphocytes is shown for cultures treated with histamine for various lengths of time as indicated. Cells were treated with histamine for 1 or 6 hours, then washed and incubated with control media up to 24 hours or kept on continual exposure for 24 hours before being washed and induced with galactose oxidase.

duced to produce IFN-γ with GO 9 units/mL (Sigma), and 24 hours later supernatants were collected and frozen at −80°C until assayed. Each sample was titrated in three separate dilution series. A different tonsil preparation was used for each experiment, and therefore, the experiment sampled the response of many individual lymphocyte donors. Neither histamine nor any of its receptor antagonists had any effect on the assay of IFN-γ.

Laryngeal cancer tissue cultures designated JH-011-SCC-L-P, JH-020-SCC-L-P, and JH-022-SCC-L-N were derived in our laboratory from laryngeal primary tumor or nodal metastasis as designated by the last letter of the cell name. All cells stained positive for pemphigus antibody in an indirect immunofluorescence assay. Each cell line produced tumors in nude mice that appeared to be squamous cell carcinoma, and all lines were sensitive to human interferons in tissue culture.

A killer cell assay was performed with K562 cells as the target after 4 days of incubation in media containing 10^4 units/mL of purified natural interleukin-2 (IL-2) (Electro Nucleonics, Silver Spring, Md). Cells were washed and incubated at a responder target ratio of 200 to 1 in five sequential twofold dilutions.

RESULTS

Previous reports indicate that histamine must be present prior to assay for the suppressor effect to be evident. We chose a 20-hour exposure to allow for the induction of the effect. To see if the inhibitory effect would last through the period of IFN-γ induction, cells were treated from time 0 to 20 hours with histamine and then were re-treated with histamine or received control media for the 24 hours after GO induction. The Table shows little difference between the cells in continuous histamine cultures and those treated pre–IFN induction only. This was consistent with preliminary observations that simultaneous histamine and IFN-γ induction gave inconsistent suppression. An inhibition in cell proliferation determined by cell counts also was observed, but was not as dramatic since control cell growth increased only twofold to threefold during the period of observation.

We then examined the dose ranges of histamine that would induce suppression in our assay. Figure 1 demonstrates the inducible IFN-γ titers over a 4 log10 range. Suppression of IFN-γ (to undetectable levels) was observed in concentrations down to 10^{-5} *M* histamine. Concomitant histamine-antihistamine treatment also was studied in this experiment. Significant reversal of suppression was observed with either of the H2 antagonists cimetidine or ranitidine at concentrations of 10^{-4} *M* or above, but none was observed with the H1 antagonist diphenhydramine at the same concentrations. In other experiments, ranitidine (Fig 2) appeared to be more effective in reversing the effect of 10^{-4} *M* histamine.

To determine more clearly the length of time necessary for histamine exposure, cells were treated for various periods of time up to 24 hours, then washed and induced with GO. We used 10^{-4} *M* histamine throughout the subsequent experiments because it gave reproducible results that were reversible by H2 receptor antagonists. Maximum suppression occurred by 6 hours, and near-maximum suppression was reached by 1 hour (Fig 2).

Figure 3 shows the results of an experiment designed to test whether the histamine-inducible suppression was reversible. Cells treated with histamine 10^{-4} *M* for 24 hours were treated sequentially with the same molar concentrations of H2 antago-

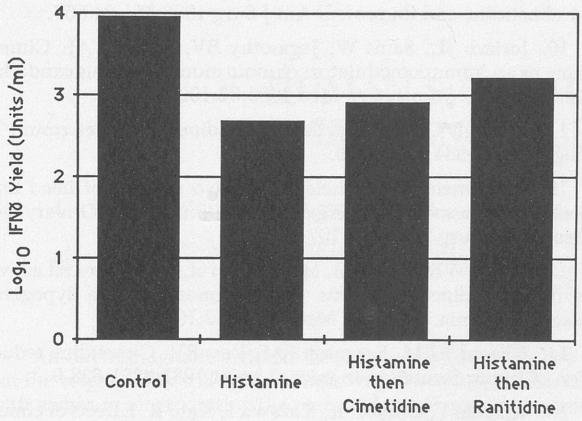

Fig 3. Reversal of histamine-induced suppression of IFN-γ production with sequential H2 histamine antagonists. Mean IFN-γ yield following galactose oxidase induction of human tonsil lymphocytes is plotted as indicated. All drugs were present at 10^{-4} *M*. Following initial treatment with control or histamine-containing media, cultures were treated with cimetidine or ranitidine at time of galactose oxidase induction.

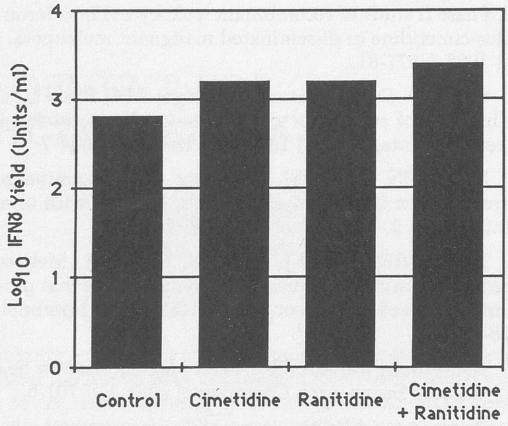

Fig 4. Enhanced IFN-γ production in presence of H2 histamine receptor antagonists. Cells were treated with control media or cimetidine, ranitidine, or both for 24 hours prior to galactose oxidase induction. Mean IFN-γ yield is shown for each test culture.

nists at the time of GO induction. A reversal of IFN production can be observed in the histamine-then-ranitidine cultures. This observation, combined with an occasional lack of detectable IFN-γ production in some specimens, led us to test for supraproduction of IFN-γ in ranitidine control cultures. In another aspect of this experiment, IFN-γ was measured after treatment with 10^{-4} *M* H2 antagonists alone or in combination (Fig 4). The increased IFN-γ production in the treated cultures of this individual suggests that the lymphocytes arrive in our cultures with a measurable degree of suppression.

To test the direct effect of laryngeal cancer cells on the production of IFN-γ, we added equal numbers of viable laryngeal cancer cells harvested from monolayer tissue culture by trypsinization to tonsil lymphocytes prior to GO induction. No decrease in IFN-γ was observed for any of the three laryngeal cancer cell–treated lymphocyte cultures.

DISCUSSION

We have observed up to fiftyfold suppression of IFN-γ production in tonsil lymphocytes in the presence of histamine. This effect can be reversed by the H2 histamine inhibitors cimetidine or ranitidine, either concomitantly or sequentially; however, this effect is not observed with the H1 histamine inhibitor diphenhydramine.

Other work has demonstrated the clinical effectiveness of H2 histamine antagonists in several clinical settings.[2,9-13] The H2 histamine antagonists also have improved the survival of tumor-bearing mice.[14,15] The significance of such immunosuppression in cancer is evident by its effect on the production of an antitumor such as IFN-γ.

We used serum in our experiments; however, the presence of histaminase may have necessitated the relatively large doses of histamine necessary for the observed effect.[16] Whether physiologic doses of histamine actually can suppress IFN-γ production in a patient is unknown, but we suspect that this type of immunosuppression indeed does occur since we have observed both in vivo delayed hypersensitivity skin reaction changes and in vitro supraproduction of IFN-γ in the presence of ranitidine.

Our killer cell assay largely measures lymphokine-activated killer (LAK) cells and does not differentiate contributions by natural killer (NK) cells. Though NK cell activity can be controlled by suppressor cells, LAK cells cannot. Our observation of a lack of suppressive effect of histamine on LAK cells is consistent with earlier reports.[16] It also helps place in perspective the spectrum of immunosuppression seen in laryngeal cancer.

The mechanism by which laryngeal cancer can induce histamine receptor–mediated immunosuppression is not known. Our results of coculture would suggest that it is not a direct effect of the cells similar to immunosecretory products of other tumor cells.[14,17]

There are several theoretic mechanisms that could account for this immunosuppressive effect: inflammatory response to the tumor, inflammatory response to microorganisms involving a tumor-mucosal barrier, other direct or indirect tumor products, or mechanical trauma. Further work on the mechanism by which this immunosuppression occurs is in progress.

REFERENCES

1. Carlsson R, Dohlstein M, Sjogren HO. Histamine modulates the production of interferon-γ and interleukin-2 by mitogen-activated human mononuclear blood cells. Cell Immunol 1985;96:104-12.

2. Creagan ET, Ahmann DL, Green SJ, Long HF, Frytak S,

Itri L. Phase II study of recombinant leukocyte A interferon (IFN-rA) plus cimetidine in disseminated malignant melanoma. J Clin Oncol 1985;3:977-81.

3. Griswold DE, Salvatore A, Badger AM, Poste G, Hanna N. Inhibition of suppressor cell expression by histamine type 2 (H_2) receptor antagonists. J Immunol 1984;132:3054-7.

4. Nair MPN, Cilik JM, Schwartz SA. Histamine-induced suppressor factor inhibition of NK cells: reversal with interferon and interleukin 2. J Immunol 1986;136:2456-62.

5. Rocklin RE, Breard J, Gupta S, Good RA, Melmon KA. Characterization of the human blood lymphocytes that produce a histamine-induced suppressor factor (HSF). Cell Immunol 1980; 51:226-37.

6. Richtsmeier WJ. Dendritic cell identification in head and neck lymphoid tissue. Arch Otolaryngol 1984;110:701-6.

7. Richtsmeier WJ. Human interferon production in tonsil and adenoid tissue cultures. Am J Otolaryngol 1983;4:325-33.

8. Armstrong JA. Cytopathic effect inhibition assay for interferon: microculture plate assay. Methods Enzymol 1981;78: 381-6.

9. Hansbrough JF, Zapta-Sirvent RL, Bender EM. Prevention of alterations in post-operative lymphocyte subpopulations by cimetidine and ibuprofen. Am J Surg 1986;151:249-55.

10. Jorizzo JL, Sams W, Jegasothy BV, Alansky AJ. Cimetidine as an immunomodulator: chronic mucocutaneous candidiasis as a model. Ann Intern Med 1980;92:192-5.

11. Mavligit GM, Talpaz M. Cimetidine for herpes zoster. N Engl J Med 1984;310:318-9.

12. Richtsmeier WJ, Eisele D. In vivo reversal of head and neck cancer associated anergy by cimetidine. Arch Otolaryngol Head Neck Surg 1986;112:1074-7.

13. White WB, Ballow B. Modulation of suppressor-cell activity by cimetidine in patients with common variable hypogammaglobulinemia. N Engl J Med 1985;312:198-202.

14. Gifford RRM, Ferguson RM, Voss BV. Cimetidine reduction of tumor formation in mice. Lancet 1981;8221:638-9.

15. Kikuchi Y, Oamori K, Kazawa I, Kato K. Effects of cimetidine on tumor growth and immune function in nude mice bearing human ovarian carcinoma. J Nat Cancer Inst 1985;74:495-8.

16. Osband ME. Successful tumor immunotherapy with cimetidine in mice. Lancet 1981;8221:636-7.

17. Roth JA, Grimm EA, Osborne BA, Putnam JB, Davidson DD, Ames RS. Suppressive immunoregulatory factors produced by tumors. Lymphokine Res 1983;2:67-73.

HUMAN SPEECH DEVELOPMENT FOR AN IMPLANTABLE ARTIFICIAL LARYNX

COLIN PAINTER, PHD
JOHN M. FREDRICKSON, MD
TIMOTHY KAISER, MD
ROANNE KARZON, PHD

ST LOUIS, MISSOURI

An electromagnetic artificial larynx was implanted in two volunteer laryngectomees. Both patients were able to communicate well, but the voice quality still needed improving. Therefore, in this investigation, listener judgments were obtained of 22 different sound sources with a view to incorporating the preferred speech sound in a new version of the device. Electroglottograms were used as sound sources in a speech synthesizer and sentences were produced with different voice qualities for judgmental tests. The results of the listening tests showed a distinct preference for waveforms corresponding to a long completely open phase, a very brief completely closed phase, and an abrupt closing gesture. The optimum acoustic characteristics for the device will be used by electrical engineers to manufacture a new version of the artificial larynx with an improved voice quality.

KEY WORDS — implant, laryngectomee, larynx, listening tests, voice quality.

BACKGROUND

No method of speech rehabilitation following laryngectomy has proved entirely satisfactory.[1,2] The best results from all procedures are acceptable, but most patients cannot achieve good esophageal speech, the extracervical electrolarynx has poor voice quality, and tracheoesophageal puncture is often inconvenient and not always successful. It was hypothesized, therefore, that a large number of patients might find an implantable electromagnetic device to be the solution of choice for them. Our intention was, and still is, to produce a device that 1) results in a more natural voice than other methods, partly because of the nature of the sound source and partly because of the built-in intonation contours,[3] 2) delivers sound within the vocal tract to provide a much better signal-to-noise ratio than the extracervical electromagnetic device, 3) is as loud as normal voice, 4) is capable of being adjusted in many ways outside the body, 5) needs no cleaning or maintenance, 6) does not have to be held in the hand, 7) is easy to use, and 8) is biocompatible.

To this end, an early version of the electromagnetic artificial larynx was implanted in two volunteer laryngectomees.[4-6] Tissue reaction was minimal and both patients were able to communicate well though the voice still sounded mechanical. It was felt, therefore, that the results justified further research focusing on improving voice quality and reducing the size of the device.

The investigation reported here addressed the issue of voice quality and compared listener judgments on 22 different sound sources that could be used in a new version of the device. The most favored ones will later be examined from the perspective of speech intelligibility.

SURGICAL ASPECTS

There are two primary objectives in the placement of the implantable electrolarynx. The device must not interfere with deglutition and must adequately drive the column of air in the pharynx, causing it to resonate.

The device (Fig 1) was placed in the prevertebral space opposite C2-3 through an incision made along the anterior border of the sternocleidomastoid muscle. Blunt dissection was used to create a pocket posterior to the pharyngeal constrictor muscles that was of sufficient size to contain the implant. Closure was performed in standard fashion. The microstructure of the surface of the device itself was such as to promote bonding to the surrounding tissue.[4]

The disk-shaped device was relatively thick, being 1 cm in the anteroposterior dimension.[4] This problem has been corrected in a newer version that is much thinner (Fig 2), and we hope eventually to reduce it to the point where it can be placed subcutaneously in the anterior neck in front of the pharyngeal air column. The surgical procedure will thus be easier and can be done under local anesthesia.

SPEECH SCIENCE ASPECTS

The acoustic theory of speech production (Table) treats the speech mechanism as a power supply (respiration), a vibrating sound source (phonation), a complex resonating system (articulation), and an output (the acoustic product as captured by a microphone beyond the lips).

Given appropriate laryngeal muscle settings and a flow of air from the lungs, the vocal folds will vibrate and produce an on/off airflow as input into the supraglottal vocal tract.

From the Department of Otolaryngology, Washington University School of Medicine, St Louis.
Presented at the meeting of the American Laryngological Association, Denver, April 25-26, 1987.

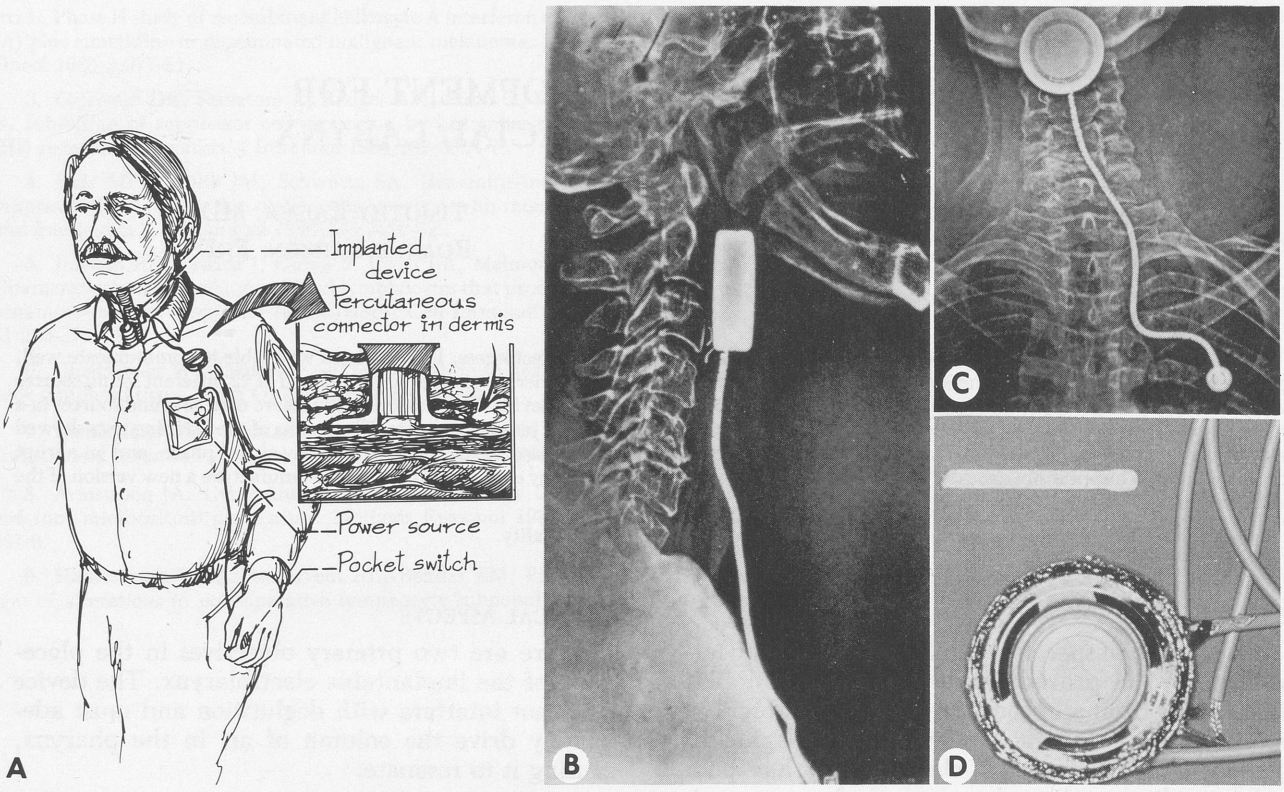

Fig 1. Implantable artificial larynx. A) Drawing of device in position. (Reprinted with permission.[5]) B,C) X-ray films of device in position. Lead seen terminates at percutaneous biocarbon button. (Reprinted with permission.[4]) D) Original version of device.

The glottal sound source (Fig 3) has an intensity/frequency spectrum that is triangular in shape, with its greatest amplitudes at the lowest frequencies falling off at 12 dB/octave to an effective zero at 5 kHz. The supraglottal vocal tract amplifies some of these frequency components and damps out others so that beyond the lips the output has a spectrum that is no longer triangular but categorized by several energy peaks (called vowel formants) separated by valleys with little acoustic energy. Each vowel in a language has a different set of formant frequency values corresponding to the different vocal tract configurations. One should, therefore, make a clear distinction between 1) formant frequency, a supraglottal resonance phenomenon; 2) fundamental frequency, a laryngeal phenomenon — pitch — the number of times per second the vocal folds vibrate; and 3) voice quality, which includes a second laryngeal phenomenon associated with the mode of vibration of the vocal folds.

We make the general assumption that, for a laryngectomee, respiration and articulation are largely unaffected and that the larynx has to be replaced by a device that is a good internal driving source.

SOUND SOURCES

What form should the artificial sound source take? It is impossible to record the output from the larynx directly because disturbances to the air in the vocal tract are reflected back to the larynx from the boundary between the lips and the outside air. However, we know from experiments on excised larynges that the waveforms for airflow at the lips, inverse filtering of the latter, and electroglottography are all good representations of the human glottal sound source.

The electroglottograph[7] is an instrument in the form of an impedance collar that gives data on vocal fold contact area across time. Electroglottograms (Fig 4A) have the following forms: 1) all waveforms show a closing gesture (stage 3) and an opening gesture (stage 5), 2) some waveforms show



Fig 2. Photograph of present version of device. Belt pack is at top, artificial larynx itself is bottom right, and subcutaneous radio receiver is bottom left.

INPUT, RESPONSE, AND OUTPUT FOR SEVERAL ACOUSTIC SYSTEMS

	Input	*Response*	*Output*
Organ Bellows	→ Vibrating reed →	Air column in a pipe	→ Music output
Normal speech Respiration	→ Phonation →	Articulation	→ Speech output
Synthetic speech Electric power	→ Pulse train →	Selected resonators	→ Synthetic speech
Implant Battery	→ Implant →	Supraglottal vocal tract	→ Speech output

a bimodal closing gesture that begins gently (stage 2) and ends steeply, 3) some waveforms show a bimodal opening gesture that begins steeply and ends gently (stage 6), 4) some waveforms have a horizontal closed plateau (stage 4), and 5) some have a horizontal open valley (stage 1).

When the six stages are permutated we see 16 possible waveform types (Fig 4B), each of which may be subclassified by the open/closed ratio. At the bottom of Fig 4B we see that all 16 types have stages 3 and 5 (+3, +5). Waveform types 1 to 4 in column 1 have neither a stage 1 nor a stage 4 (−1, −4), whereas types 13 to 16 in column 4 have both (+1, +4). Waveform types 1, 5, 9, and 13 in horizontal row 1 have neither a stage 2 nor a stage 6 (−2, −6), whereas types 4, 8, 12, and 16 have both (+2, +6). The middle of the illustration shows what the waveforms look like, with vocal folds together (closed glottis) at the top and vocal folds apart (open glottis) at the bottom of each tracing. The top of the illustration shows how each waveform type may be subclassified by closed/open ratio, ie, the percentage of each cycle during which the vocal folds are together divided by the time they are apart.

These 16 human waveform types and, in addition, an electroglottogram from a diplophonic speaker, the original sound source of the Klatt synthesizer, a pseudosinusoidal wave (henceforth called a sine wave), a triangular wave, a sawtooth wave, and a square wave were used as sound sources in a speech synthesizer to produce sentences for judgmental tests. The Klatt Massachusetts Institute of Technology speech synthesis program[8] was modified by Kaiser and Painter (unpublished) to allow any waveform to be used as a sound source, and 22 versions of the sentence "It's a baby" were generated, two of which may be seen in Fig 5. All 22 were identical except for the voice quality associated with the sound source.

LISTENING TESTS

Each utterance was then paired with every other one, each pair occurring twice with the members of the pair in different positions. The order of presentation of the pairs was then randomized and an audiotape was prepared containing these 462 pairs of utterances with a 1-second pause between utterances and a 5-second pause between pairs. Ten listeners seated in the sound field of an Industrial Acoustics Corporation sound-treated booth were then presented with the pairs of stimuli and asked to choose the member of the pair that "sounded the best," ie, "would be the most pleasant to listen to." There were no further instructions or practice sessions. The listening sessions took 1 hour with a short break between half-hour sessions.

In general listeners preferred human glottal waveforms to geometric ones (Fig 6). Particularly low on the list of choices were the square, sawtooth, and triangular waves. Interestingly, however, listeners preferred the sine wave as a sound source, followed by the standard excitation of the original Klatt synthesizer and waveforms 10, 11, 17, 7, and 3, all of which scored over 60%.

Waveforms with a stage 1 but no stage 4 (Fig 4B) and those with a stage 6 but no stage 2 scored especially well. Waveforms with a stage 1 and a

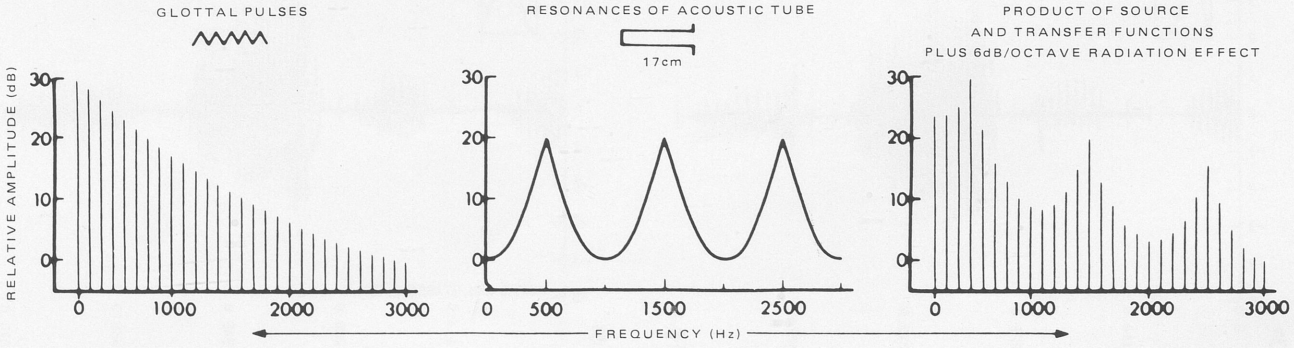

Fig 3. Input, response, and output amplitude/frequency spectra. (Reprinted with permission from Borden G, Harris K. Speech science primer. Baltimore: Williams and Wilkins, 1980.)

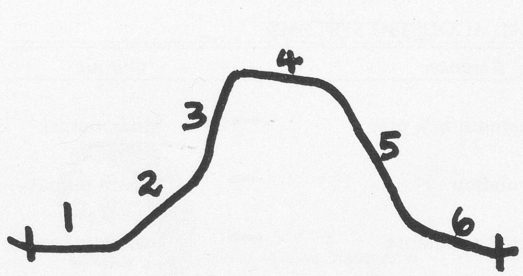

A

For each waveform type # 1 - 16:
Subclassify by closed/open ratio:

	closed %	
A	0-25	= less than a 1:3 ratio
B	26-35	= a 1:2 ratio
C	36-45	= a 2:3 ratio
D	46-55	= a 1:1 ratio
E	56-65	= a 3:2 ratio
F	66-75	= a 2:1 or 3:1 ratio
G	76-100	= more than a 3:1 ratio

EXAMPLES

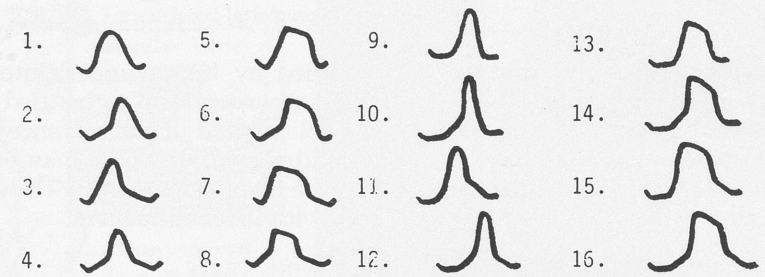

All 16 types have +3 and +5

		-1 -4		-1 +4		+1 -4		+1 +4	
-6	-2	1.	35	5.	345	9.	1 35	13.	1 345
-6	+2	2.	235	6.	2345	10.	1235	14.	12345
+6	-2	3.	356	7.	3456	11.	1 356	15.	1 3456
+6	+2	4.	2356	8.	23456	12.	12356	16.	123456

B

Fig 4. Electroglottograms. A) Stages. 1 — fully open, 2 — closing (elastic recoil), 3 — closing (Bernoulli), 4 — fully closed, 5 — opening (explosion), 6 — opening (further lateral displacement). B) Waveform types.

stage 4 and those with a stage 6 and a stage 2 scored badly. There was, therefore, a distinct preference for waveforms corresponding to a long, completely open phase, a very brief completely closed phase, and an abrupt closing gesture. This is not surprising given the low ratings for the square, sawtooth, and triangular waves.

Waveforms 10, 11, and 9 were scored highly — it would appear that the mode of vibration of the vocal folds appropriate for breathy voice constitutes a good sound source when unaccompanied by the normally associated local turbulence. Waveform 17 was also well scored — it would appear that the mode of vibration appropriate for diplophonia is a good sound source when unaccompanied by the normally associated jitter.

ENGINEERING ASPECTS

Electrical engineers will use the results of the listening tests to manufacture a new version of the device with a voice quality better than that of the previous model. The biggest problem is to produce a woofer the size of a tweeter, ie, a small loudspeaker that responds well to low frequencies. Most of the acoustic energy in speech is below 2,500 Hz and small diaphragms do not respond well below 1,000 Hz. The task of the engineer is to take the op-

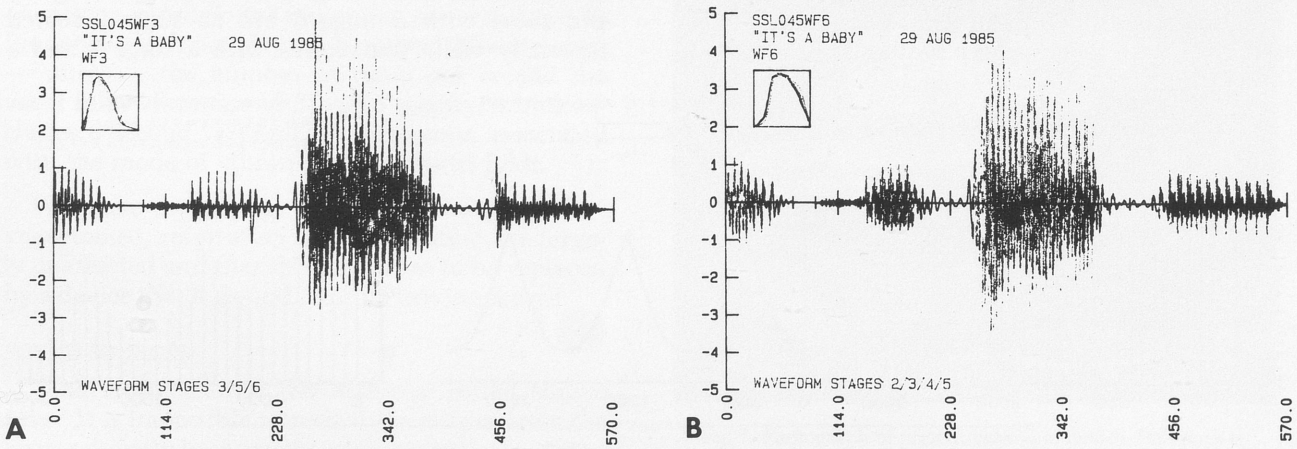

Fig 5. Amplitude/time spectrum of synthesized sentence. A) Waveform 3 as sound source, B) waveform 6 as sound source.

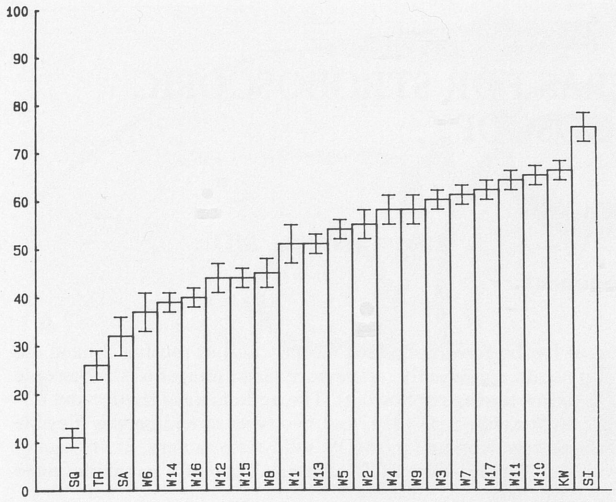

Fig 6. Results of listening tests showing percent waveform preference of 462 utterance pairs. W1-W16 — waveform types 1 to 16, W17 — diplophonia, SQ — square wave, TR — triangular wave, SA — sawtooth wave, KW — Klatt sound source, SI — sine wave, I — standard error.

timum acoustic characteristics of the device and produce a diaphragm with an output that best approximates it. Recent and ongoing advances in loudspeaker and headphone design make it likely that the approximation will be very close.

The present version of the implant (Fig 2) has a subcutaneous radio receiver just below the clavicle connected by an internal sealed wire to the retropharyngeal artificial larynx. A radio transmitter is placed on the surface skin above the receiver and is driven from a pack measuring 2.5 x 7.5 x 12.5 cm fixed to the patient's belt. The driver unit can be adjusted by the technician to control the overall loudness, pitch range, highness or lowness of the pitch, intonation contours, and voice quality itself by changing the circuitry. The device is turned on and off at the belt or by a switch in the pocket (Fig 1A).

The original artificial larynx (Fig 1D) measured 2.5 cm x 1 cm, weighed 75 g, and was encased in No. 316 stainless steel. The porousness of the surface allowed for tissue ingrowth, and the lead was of low-resistance silver coaxial cable coated with Silastic.[4] The current artificial larynx (Fig 2) is 0.5 cm thick and has been designed to provide adequate output using a transcutaneous driving source. It is encased in titanium with the exception of the Teflon-sealed diaphragm itself. An even smaller version has been bench-tested. The company responsible for the production of the device considers that, given the economics of scale, it can be manufactured at an acceptable cost.

FUTURE WORK

Once we have produced a new version of the device with improved voice quality and reduced size, we plan a limited clinical investigation with six volunteer patients to test the clinical utility of the implant.

REFERENCES

1. Sekey A, ed. Electroacoustic analysis and enhancement of alaryngeal speech. Springfield, Ill: Charles C Thomas, 1982.

2. Weinberg B, ed. Readings in speech following total laryngectomy. Baltimore: University Park Press, 1980.

3. Painter C. The pitch range of tonal units in Gwa. Z Phon Sprach Kommun 1979;32:272-81.

4. Charles DA, Fredrickson JM, Bryce DP. An implantable electromagnetic sound source: preliminary results of human implantation. In: Shedd DP, Weinberg B, eds. Surgical and prosthetic approaches to speech rehabilitation. Boston: GK Hall Medical Publishers, 1980:247-57.

5. Frederickson JM, Charles DA, Painter C. Laryngeal research. In: Bailey B, Biller H, eds. Surgery of the larynx. Philadelphia: WB Saunders Co, 1985:451-9.

6. Maruzzo B, Fredrickson J, Painter C. A new implantable electrolarynx. Digest of the 34th conference on engineering medicine and biology, Houston, 1981.

7. Painter C. Xeroradiographic, laryngoscopic, spectrographic and glottographic indicators of laryngeal function. In: Cummings C, Fredrickson JM, Harker LA, Krause CJ, Schuller DE, eds. Otolaryngology–head and neck surgery. 4 vols. St Louis: CV Mosby Co, 1986:1816-23.

8. Klatt DH. Software for a cascade/parallel formant synthesizer. J Acoust Soc Am 1980;67:971-95.

SELECTION OF VIDEO CAMERAS FOR STROBOSCOPIC VIDEOLARYNGOSCOPY

EIJI YANAGISAWA, MD

FREDERICK GODLEY, MD HIROSHI MUTA, MD

NEW HAVEN, CONNECTICUT

Stroboscopic evaluation for the analysis of laryngeal function and disease has been reemphasized recently and its routine clinical use recommended. Many have found, however, that it is not always possible to obtain consistently satisfactory video images of stroboscopic laryngoscopy. The problem is related to the low intensity of the xenon light source during stroboscopy. The authors have tried many different video cameras available, along with the Brüel & Kjaer Rhino-Larynx Stroboscope type 4914, and two types of endoscopes (flexible and rigid). The cameras included 1) single tube camera, 2) single chip metal oxide semiconductors (MOS) solid-state camera, 3) single chip charge-coupled devices (CCD) solid-state camera, 4) three-tube camera, and 5) three-chip CCD camera. Currently available video cameras and their adaptability for stroboscopic videolaryngoscopy are discussed.

KEY WORDS — stroboscopic videolaryngoscopy.

Since the early stroboscopic examination of the human vocal cords by Oertel in 1895,[1] many investigators have emphasized the value of stroboscopic laryngoscopy.[2-19] Von Leden et al,[6,7] Hirano et al,[14,17] Kitzing[18] and other proponents[8,9] have pointed out the advantages of stroboscopic laryngoscopy and recommended its routine use in laryngeal examination.

Recent advances in the technology of video cameras have improved our ability to visualize and to document vocal cord vibration dramatically. In 1978, Kittel described the use of a microtelevision lens to provide an enlargement of the stroboscopic laryngeal examination on a screen.[11] In 1979, Yoshida et al[13] reported their design of a videotape system that recorded the strobotelescopic images of the larynx. Since these early reports there has been rapid development of electronic and fiberoptic equipment that can be applied to stroboscopic videolaryngoscopy. On the one hand, the wealth of the new products has produced affordable systems for more otolaryngologists, but, on the other hand, it has made the choice among products more difficult.

In an attempt to find a suitable video camera for stroboscopic videolaryngoscopy, we have sampled nine cameras from the broad range of equipment available. Using the Brüel & Kjaer Rhino-Larynx Stroboscope we tested the following video cameras with both flexible and rigid endoscopes: 1) single tube camera, 2) single chip metal oxide semiconductors (MOS) solid-state camera, 3) single chip charge-coupled devices (CCD) solid-state camera, 4) three-tube camera, and 5) three-chip CCD camera.

EQUIPMENT

The following equipment was used for this study:

RHINO-LARYNX STROBOSCOPE TYPE 4914 (BRÜEL & KJAER)

This stroboscope is simple to operate and is equipped with a stethoscope-type laryngeal microphone that is placed over the lateral aspect of the subject's neck to provide the frequency input to the stroboscope (Fig 1). The operator then controls two functions of the stroboscope with a foot pedal. When the foot pedal is depressed all the way, a fixed light source provides excellent illumination for direct examination as well as video recording of the anatomy and the function of the larynx. The fixed light is a 150-W halogen lamp. When the foot pedal is pressed lightly, it changes to the stroboscopic mode. The stroboscopic light has two operating modes: the first is the phase delay, which varies between 0° and 360°, and the second mode is a fixed frequency (1.4 Hz) slow motion stroboscope light. The light source of the stroboscope is a xenon-filled flash tube. The stroboscope unit measures 177 mm



Fig 1. Brüel & Kjaer Rhino-Larynx Stroboscope type 4914.

From the Section of Otolaryngology, Department of Surgery, Yale-New Haven Hospital (Yanagisawa, Godley) and Yale University School of Medicine (Yanagisawa); the Section of Otolaryngology, Department of Surgery, Hospital of Saint Raphael (Yanagisawa); and Haskins Laboratories (Muta), New Haven, Connecticut.

Presented at the meeting of the American Laryngological Association, Denver, April 25-26, 1987.

REPRINTS — Eiji Yanagisawa, MD, 98 York St, New Haven, CT 06511.

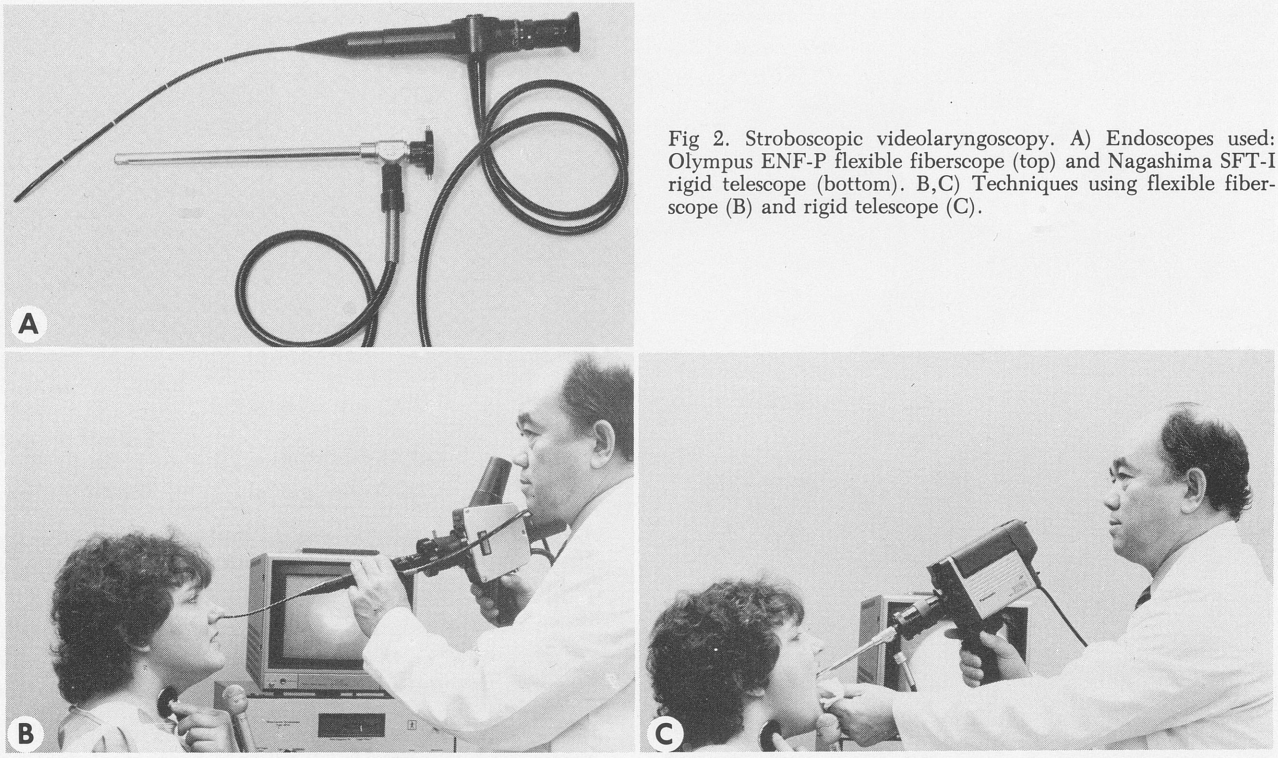

Fig 2. Stroboscopic videolaryngoscopy. A) Endoscopes used: Olympus ENF-P flexible fiberscope (top) and Nagashima SFT-I rigid telescope (bottom). B,C) Techniques using flexible fiberscope (B) and rigid telescope (C).

(7 in) x 430 mm (16.9 in) x 320 mm (12.6 in). It costs approximately $13,000.

ENDOSCOPES

Flexible Fiberscope
Olympus ENF-P 3.7 mm diameter (Olympus Corp) (Fig 2A, top; and 2B)

Rigid Telescope
Nagashima SFT-I (Kelleher Medical, Richmond, Va) (Fig 2A, bottom; and 2C)

VIDEO CAMERAS

Single Tube Cameras
Panasonic PK-973
JVC GX-N8U (Fig 3B)
Hitachi DK-3000

Three-Tube Cameras
Hitachi DK-5050 (Fig 3A) and DK-5053

Single Chip MOS Solid-State Camera
Hitachi VK C2000

Single Chip CCD Solid-State Camera
Karl Storz 9000
Panasonic WV-3260/8AF (Fig 3C)
Olympus Movie 8 VX-801-KU

Three-Chip CCD Camera
Sony DXC-3000P

TECHNIQUE

Each video camera was tested with both the Olympus ENF-P flexible fiberscope and the Nagashima SFT-I rigid telescope.

The flexible fiberscope was passed transnasally after the application of 3% ephedrine and 4% lidocaine (Xylocaine) to the nasal and nasopharyngeal mucosa (Fig 2B). The rigid telescope was introduced transorally after the topical application of 4% lidocaine to the soft palate, the pharynx, and the posterior half of the tongue (Fig 2C). For the telescopic examination, the examiner held the video camera in one hand and inserted the telescope into the mouth while holding the subject's tongue with the other hand. When the desired image appeared on the monitor screen, the laryngeal image was centered on the screen using the television monitor or the viewfinder of the camera.

The larynx first was examined using the standard illumination of the Brüel & Kjaer stroboscope during respiration and phonation. The stroboscopic examination was carried out using the xenon light source of the stroboscope while the stethoscope-type laryngeal microphone was pressed against the lateral aspect of the thyroid cartilage of the neck. A separate microphone rather than the built-in microphone of the camera was held in front of the mouth to obtain high quality voice recording. For each test, the subject produced sustained vowels repeatedly at low, normal, and high pitch. The same subject was used under the same conditions for all the cameras tested.

RESULTS

All recorded material produced by different cameras was reviewed and judged by a panel of three otolaryngologists (present authors) and one audiovisual specialist. The performance of each



Fig 3. Video cameras. A) Hitachi DK-5050 three-tube color camera, B) JVC GX-N8U single tube home video camera, and C) Panasonic WV-3260 single chip CCD home video camera.

video camera was graded as poor, fair, good, or excellent in terms of its sensitivity, color, and resolution of stroboscopic images with both the Olympus ENF-P fiberscope and the Nagashima SFT-I rigid telescope. We also observed some of the technical problems encountered with these cameras. The summary of our findings is shown in the Table.

The Panasonic PK-973 (minimal illumination 30 lux) produced an excellent view of enlarged stroboscopic images of the larynx with the telescope. However, the image obtained by the fiberscope was fair. The Nagashima video adapter F-60mm was used for the telescope while the Karl Storz 35- to 70-mm zoom lens adapter was used for the fiberscope.

The JVC GX-N8U camera (minimal illumination 10 lux) (Fig 3B) produced surprisingly good images of both the fiberscopic and telescopic stroboscopy (Fig 4G-L). The brightness and color retention were very good to excellent with the telescope. The mucosal waves were very well shown. The camera is equipped with a convenient viewfinder that greatly facilitated in positioning the vocal cords in the center of the screen during the examination. To attach the endoscope to the front of the camera lens, the Karl Storz quick-connect adapter was used for the fiberscope while the Machida adapter was used for the telescope.

The Hitachi DK-3000 (minimal illumination 25 lux) was not quite as light-sensitive as the JVC GX-N8U home video camera although the resolution appeared to be better. With the fiberscope, the image was fair to good. With the telescope, it produced a large full-screen size picture, but the resolution was not satisfactory. The Karl Storz zoom lens adapter was used for the fiberscope while the Nagashima adapter was used for the telescope.

The Hitachi DK-5050 (Fig 3A) is a high performance three-tube color video camera specifically designed for medical use. This camera produced the best quality images by far for both fiberscopic and telescopic stroboscopic laryngoscopy in terms of color, sensitivity, and resolution (Fig 4A-F). Special adapters made for the Nagashima telescope and the Olympus fiberscope by the Hitachi Company were used.

The control unit of the Hitachi DK-5050 is equipped with a special sensitivity switch. When the stroboscopic image with the fiberscope is dark, the sensitivity of the camera is increased by turning the sensitivity switch to the + 9-dB or + 18-dB positions. This results in considerably brighter fiberscopic images.

We also used the Hitachi DK-5053, which is a somewhat simplified model of the Hitachi DK-5050 and costs considerably less. We have found that this camera performed exactly the same as the DK-5050 for stroboscopic videolaryngoscopy.

The Karl Storz single chip CCD camera 9000 (minimal illumination 30 lux) was an amazingly small, lightweight camera (55 g [1.77 oz]). When used with the Karl Storz zoom lens adapter, the camera was not sensitive enough to produce a satisfactory fiberscopic image. In contrast, it did have a

COMPARISON OF VIDEO CAMERAS

Video Camera	*Pickup Device*	*Minimal Illumination (lux)*	*Horizontal Resolution*	*Fiberscope*		
				Brightness	*Color*	*Resolution*
Panasonic PK-973	2/3 in single tube (Newvicon)	30	300 lines	Good	Fair	Fair
JVC GX-N8U	1/2 in single tube (Newvicon)	10	300 lines	Good	Fair	Good
Hitachi DK-3000	2/3 in single tube (Newvicon)	25	350 lines	Fair	Fair	Poor
Hitachi DK-5050	2/3 in three tube (Chalnicon)	16 (actually much lower than listed)	550 lines	Very good	Very good	Very good
Hitachi VK C2000	2/3 in single chip MOS	100	260 lines	Poor	Poor	Poor
Karl Storz 9000	2/3 in single chip CCD	30	360 lines	Poor	Fair	Fair
Panasonic WV-3260/ 8AF	2/3 in single chip CCD	7	380 lines	Good	Good	Good
Olympus Movie 8 VX-801-KU	1/2 in single chip CCD	7	Not listed	Good	Fair	Good
Sony DXC-3000P	2/3 in three chip CCD	30	520 lines	Fair	Fair	Fair

full screen size and adequately bright stroboscopic images for the telescopic examination when used with the Nagashima adapter. The mucosal waves were very well visualized although the resolution was not as fine as one would want. There were no horizontal lines or stripes with this camera.

The Panasonic WV-3260/8AF home video camera (minimal illumination 7 lux) (Fig 3C) was very light-sensitive and produced adequately bright images (Fig 4M-R). However, the images were grainy, particularly with the fiberscope. It retained color very well. There was a great deal of flickering of the images that interfered with the observation of the mucosal waves.

The Olympus Movie 8 VX-901-KU is a new compact, lightweight, home video camera equipped with a built-in 8-mm recorder. This had an excellent sensitivity of 7 lux. The images obtained by the fiberscope were fair to good. The images obtained by the telescope were amazingly good for the size and the cost of the camera. The mucosal waves of the vocal fold motion were shown very well.

The Sony DXC-3000, a three-tube color camera (professional use), is relatively lightweight, but the size was considerably larger than any other cameras used. It had to be used with a tripod. The picture obtained appeared to be quite good but, since the camera was equipped with a bayonet-type, not C-mount, coupler, it required a specifically designed cine-adapter. These problems make it unsuitable for stroboscopic videolaryngoscopy.

DISCUSSION

All video cameras use one of two fundamentally different image pickup devices: 1) conventional vacuum tube pickups and 2) newer, solid-state image sensors (Fig 5). Each of these systems converts light intensity to an electrical signal that can then be converted to a video signal. This video signal can be displayed then on a video monitor or stored on a magnetic tape.

COMPARISON OF VIDEO CAMERAS (continued)

Video Camera	*Telescope*			*Problems*			*Weight*	*Price*
	Brightness	*Color*	*Resolution*	*Horizontal Stripes*	*Flickering*	*Moiré Effect*		
Panasonic PK-973	Excellent	Good	Very good	+ +	—	+	2.7 kg (6 lb) with lens	$900 (1985)
JVC GX-N8U	Excellent	Excellent	Very good	+ +	—	+	1.06 kg (2.3 lb)	Approx $800 (1986)
Hitachi DK-3000	Good	Good	Good	+ +	—	—	0.37 kg (0.8 lb)	Approx $5200 (1987)
Hitachi DK-5050	Excellent	Excellent	Excellent	+	—	—	1.1 kg (2.4 lb)	Approx $24,000 (1987)
Hitachi VK C2000	Poor	Poor	Poor	+ + +	—	+ +	1.7 kg (3.74 lb)	$2,000 (1986)
Karl Storz 9000	Good	Good	Good	—	+	+	55 g (1.77 oz)	$12,000 (1986)
Panasonic WV-3260/ 8AF	Very good	Very good	Very good	—	+ + +	+ +	3.06 kg (6.8 lb) includes lens view finder	$1,300 (1987)
Olympus Movie 8 VX-801-KU	Very good	Very good	Very good	—	+ +	+	1.3 kg (2.9 lb)	Approx $1,600 (1987)
Sony DXC-3000P	Very good	Very good	Very good	—	+ + +	—	3.3 kg (7 lb 4 oz)	$6,000 (1986)

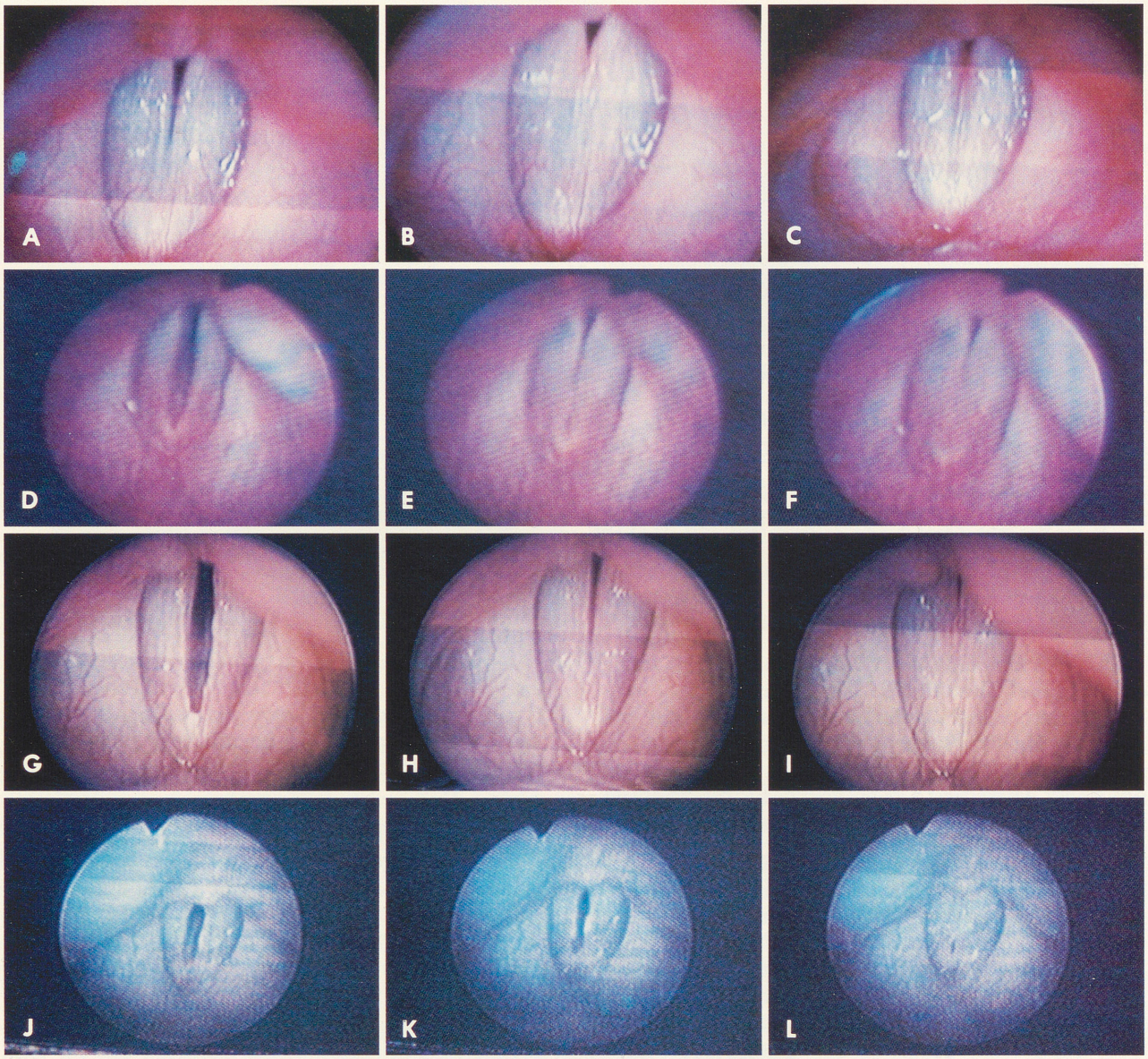

Fig 4. Stroboscopic images produced by different video cameras. A-F) Images with Hitachi DK-5050: telescopic view (A-C); fiberscopic view (D-F). G-L) Images with JVC GX-N8U: telescopic view (G-I); fiberscopic view (J-L).

The conventional pickup tubes create video images with electron beam scanning, which horizontally scans a photoconductive surface to convert light intensity to an electrical signal. At present, the major advantages of the pickup tube video cameras are their high resolution and better sensitivity (Fig 4A-I). Therefore, they function well under the low-light conditions of laryngostroboscopy. Unfortunately, the vacuum tube is fragile mechanically and easily damaged permanently by overexposure to light. Finally, with the electron beam scanning system, the stroboscopic light creates horizontal line artifact corresponding to each strobe flash (Fig 4A-C,G-J). A light streaking or "comet tail" effect is a usual disadvantage of tube pickup cameras, but with stroboscopic imaging, this afterimage helps to reduce the artifact of horizontal lines.

The solid-state pickup technology that utilizes silicon chips and integrated circuits is a rapidly evolving area of video imaging. The solid-state cameras have the obvious advantages of better shock resistance and miniaturization. The solid-state pickups are classified into 1) MOS type and 2) CCD type, among others (Fig 5). The CCD system is the most popular at present. By their method of reading the light-intensity data from the photoconductive elements, the MOS is also called an X-Y addressing type, and the CCD a data transfer type. Pickups of the X-Y addressing type generate the image signal by accessing selectively and reading the light intensity of a photoconductive element of each pixel similar to accessing the memory bits in computers. Pickups of the data transfer type store the data of light intensity of each pixel into the analog

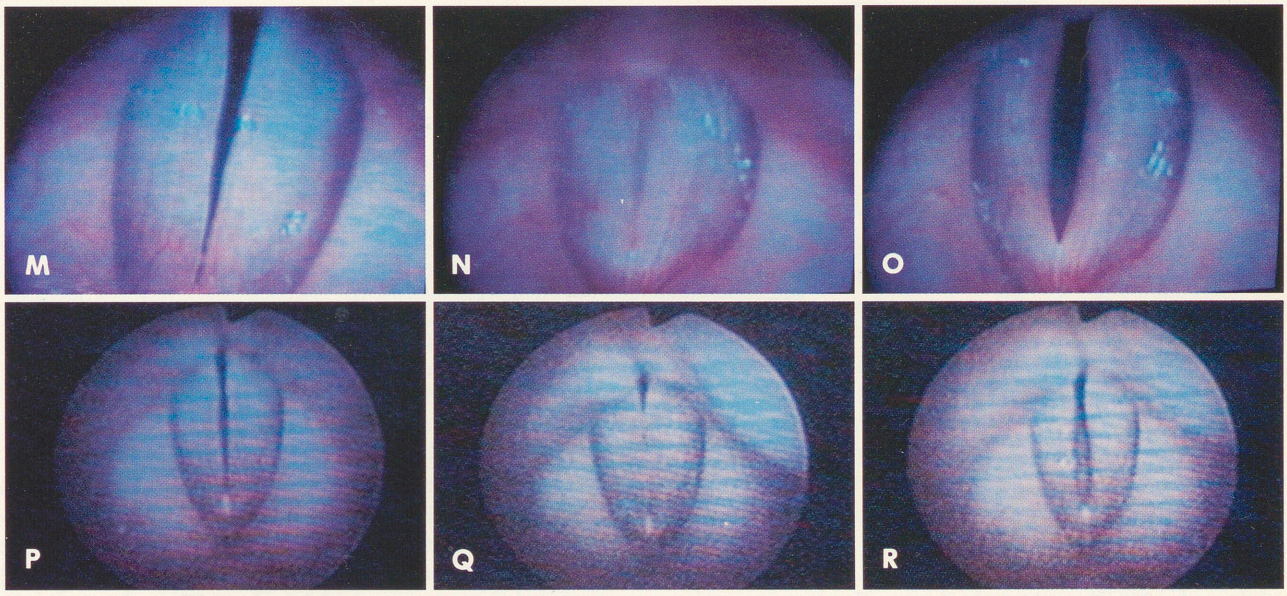

Fig 4 (continued). M-R) Images with Panasonic WV-3260/8AF: telescopic view (M-O); fiberscopic view (P-R).

memory elements that are located next to each photoconductive element. The image signal is generated by transferring the data from analog memory, one after another.[20,21]

While the pickup tubes form video images by successive electron beam scanning, the CCD system forms video images by simultaneously accumulating light intensity from all of the picture elements that cover the pickup surface. This system correlates with the method of storing pictures on a movie film.

The advantage of the CCD system is that it is not associated with the artifact of horizontal lines (Fig 4M-O). Unfortunately, CCD cameras create the artifact of flickering. When an unequal number of strobe flashes fall on successive frames, the video image appears to flicker. This occurs when the fundamental frequency of vocal fold vibration is not a multiple of the video frame frequency — 30 frames/s in the United States. The CCD systems are manufactured with two exposure speeds: $^1/_{30}$-second exposure (frame integration mode) and $^1/_{60}$-second exposure (field integration mode). A CCD system of frame integration mode accumulates light intensity over $^1/_{30}$ second, which is twice as long as the one field period ($^1/_{60}$ second), in order to form an image for each video field. On the other hand, a CCD system of field integration mode accumulates light intensity over $^1/_{60}$ second for each field, which is the same as the one field period. The effect of accumulation time for a video frame is the same as that of exposure speed for still photographs. Generally, higher exposure speed is better for moving objects; however, slower exposure speed is advantageous for videostroboscopy because of low association with the flicker phenomenon. The effect of exposure speed is independent of the frame rate. A CCD system that uses a $^1/_{30}$-second exposure time has a low association with the flicker phenomenon. This is because the longer the exposure time, the more nearly equal will be the amount of light falling on each frame.

There are several ways to improve the stroboscopic video image common to both the tube and solid-state systems. The first is to increase the number of pickups. The three-pickup systems improve both the sensitivity and resolution of the image. Furthermore, these systems minimize the moiré effect (Fig 4D-F). This electronic artifact appears as any abnormal color pattern on the video monitor, more commonly as a colored strip. The moiré effect is a disadvantage common to both types of single pickup color cameras when used with a flexible fiberscope (Fig 4J-L,P-R). This problem is created by the interface between the individual fiberoptic fibers and the color separation filter array of the video pickup device. Some of the major drawbacks of three-tube cameras at present are that 1) they cost significantly more than single pickup cameras, 2) they are shaped awkwardly and are difficult to handle, and 3) they have a bayonet-type coupler and require their own adapters, which are costly. They are not available as home video cameras yet.

The second way to improve the stroboscopic video image is to use a high sensitivity single pickup video camera. Video cameras each have a minimal illumination, or lux. This is a measure of how much better the camera's light sensitivity is; cameras with a low lux produce a brighter image with better color saturation. There are two generalizations to be made: 1) pickup tube cameras have lower lux numbers than the CCD cameras, but this trend is now changing; and 2) for the best images with a fiberscope, the minimal illumination of a single tube or chip camera should be below 7 lux.

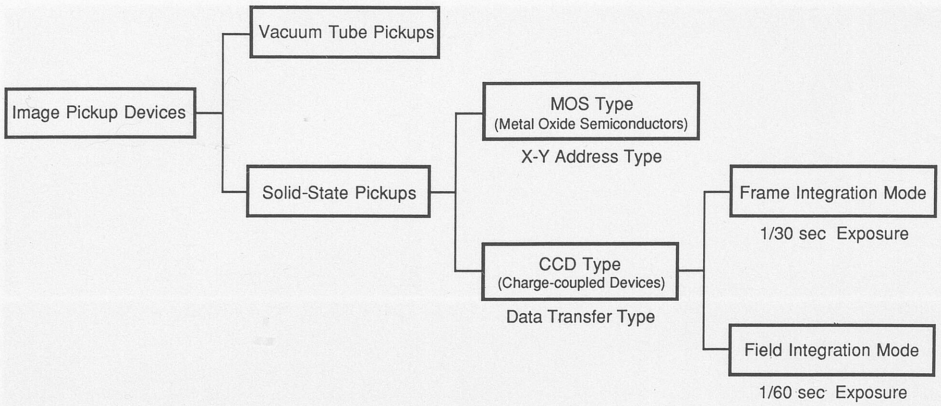

Fig 5. Types of image pickup devices.

The use of a video camera with a smaller diameter pickup device is another way to improve the stroboscopic video image. The difference in size of the pickup device will affect the final results of video images on the monitor screen. The smaller the pickup device diameter, the larger the image on the video screen. For example, the image obtained by a $^1/_2$ in image device may fill the entire monitor screen while the image produced by a $^2/_3$ in image device will occupy about half of the screen (Fig 6). This ratio of the diameter is 3:4. The image obtained by a $^1/_2$ in pickup device is about 33% larger in diameter than that obtained by a $^2/_3$ in pickup device, provided that the same adapter with the same focal length of the camera is used. This means that the size of the image obtained by a $^1/_2$ in device is about 80% larger in area. When the size of the image obtained by a $^1/_2$ in device is decreased by using a shorter focal length of the camera or the adapter, a much brighter image on the monitor screen can be obtained. This is important in stroboscopic videolaryngoscopy because the amount of light produced by a stroboscope is fixed.

Finally, the selection of a video camera for stroboscopic videolaryngoscopy depends greatly on which type of endoscope is used. Since the diameter of the telescope is generally larger than that of a fiberscope and the telescope transmits more light, it produces a much brighter and clearer stroboscopic image. If the telescope alone is used, therefore, many cameras available today are adequate for stroboscopic videolaryngoscopy. In our study, all video cameras tested except for the Hitachi VK C2000 (a $^2/_3$ in single chip MOS) produced adequate stroboscopic images with a telescope.

If the fiberscope is used exclusively for stroboscopic videolaryngoscopy, a much more light-sensitive video camera is required. Only the Hitachi DK-5050 and DK-5053 produced consistently reliable high quality stroboscopic images with a fiberscope. Hirano et al[17] emphasized the advantages of fiberscopic videostroboscopy over telescopic videostroboscopy, citing application for children, patients with an omega-shaped or infantile epiglottis, and patients with a supraglottic mass or swelling. They also emphasized that the fiberscopic examination allows the patient to phonate in the normal head position, thus producing habitual or more normal speech during the examination. For telescopic videolaryngoscopy, patients have to phonate while maintaining an unusual head position. In order to achieve high quality, closeup stroboscopic video images with a fiberscope, we recommend the use of a three-tube camera, a wider diameter flexible fiberscope such as Olympus ENF-L (4.4 mm), and appropriate topical anesthesia of the laryngeal surface.

CONCLUSION

The three-tube camera such as the Hitachi DK-5050 or its simplified model DK-5053 (considerably less expensive) has produced the best stroboscopic images of the larynx. We highly recommend these three-tube cameras for those investigators who wish to obtain high quality stro-

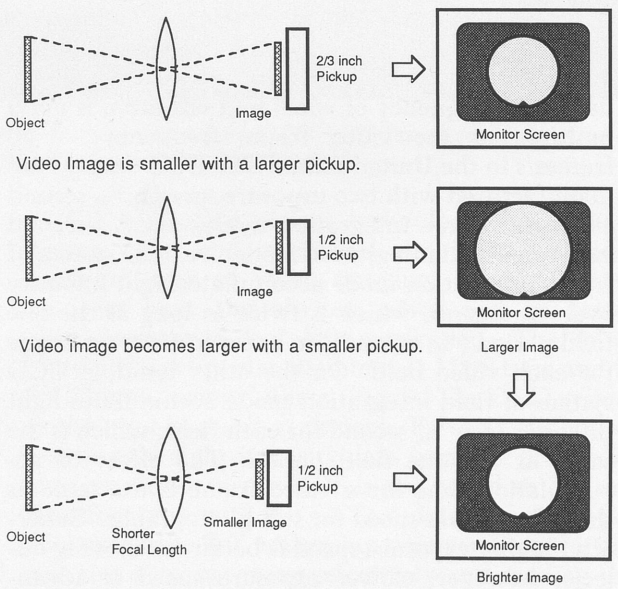

Fig 6. Effect of video images on monitor screen by different size pickup devices.

boscopic video images for both a fiberscope and a telescope.

The ideal single pickup device (either tube or chip) for stroboscopic videolaryngoscopy is one with high light sensitivity (low lux), a smaller diameter (1/2 in rather than 2/3 in) pickup device, a zoom lens capability, and one that remains compact, lightweight, and affordable. In our opinion, the minimal illumination of the video camera for stroboscopic videolaryngoscopy should be below 10 lux.

The JVC GX-N8U (10 lux, 1/2 in single tube) fulfilled most of the above-mentioned requirements and produced very satisfactory results (this was our choice among low-cost video cameras). The Panasonic WV-3260 (7 lux, 2/3 in single chip CCD) provided adequately bright images but produced more flickering and moiré effect. The newer Olympus Movie 8 compact camcorder (7 lux, 1/2 in single chip CCD) produced surprisingly bright stroboscopic images. For these low-budget video cameras, we recommend the use of a telescope rather than a fiberscope for stroboscopic videolaryngoscopy.

Flickering, moiré effect (abnormal color lines), and horizontal stripes were some of the problems encountered during stroboscopy and made the interpretation of the stroboscopic images of the larynx difficult in some instances. The single CCD cameras had a tendency to produce more noticeable flickering and moiré effect when used with a fiberscope. The chief advantage of a CCD camera was an absence of horizontal stripes almost always noted during videostroboscopy with a pickup tube camera. No or little flickering was noted with the pickup tube camera.

REFERENCES

1. Oertel MJ. Das Laryngo-Stroboskop und die Laryngo-Stroboskopische Untersuchung. Arch Laryngol Rhinol 1895;3:1.

2. Kallen IA. Laryngostroboscopy in the practice of otolaryngology. Arch Otolaryngol 1932;16:791-807.

3. Timcke R, von Leden H, Moore T. Laryngeal vibrations: measurements of the glottic wave. I. The normal vibratory cycle. Arch Otolaryngol 1958;68:1-19.

4. Timcke R, von Leden H, Moore P. Laryngeal vibrations: measurements of the glottic wave. II. Physiologic vibrations. Arch Otolaryngol 1959;69:438-44.

5. Schonharl E. Die Stroboskopie in der praktischen Laryngologie. Stuttgart: Georg Thieme Verlag, 1960.

6. Von Leden H, Moore P, Timcke R. Laryngeal vibrations: measurements of the glottic wave. III. The pathologic larynx. Arch Otolaryngol 1960;71:16-35.

7. Von Leden H. The electronic synchron-stroboscope: its value for the practicing laryngologist. Ann Otol Rhinol Laryngol 1961;70:881-93.

8. Padovan IF, Christman MT, Hamilton LH. Indirect microlaryngostroboscopy. Laryngoscope 1973;83:2035-41.

9. Saito S, Fukuda H, Kitahara S. Stroboscopic microsurgery of the larynx. Arch Otolaryngol 1975;101:196-201.

10. Alberti PW. The diagnostic role of laryngeal stroboscopy. Otolaryngol Clin North Am 1978;11:347-54.

11. Kittel G. Lupen-Mikro-TV-Farbstroboskopie mit Amplituden-bestimmungsmoglichkeiten. HNO 1978;26:94-6.

12. Gould WJ, Kojima H, Lambiase A. A technique for stroboscopic examination of the vocal folds using fiberoptics. Arch Otolaryngol 1979;105:285.

13. Yoshida Y, Hirano M, Nakajima T. A videotape recording system for laryngostroboscopy. J Jpn Bronchoesophagol Soc 1979;30:1-5.

14. Hirano M. Clinical examination of voice. Wien-New York: Springer-Verlag, 1981.

15. Monday LA, Cornut G, Bouchayer M, Roch JB, Loire T. Diagnosis and treatment of intracordal cysts. J Otolaryngol 1981; 10:363-70.

16. Monday LA, Bouchayer M, Cornut G, Roch JB. Epidermoid cysts of the vocal cords. Ann Otol Rhinol Laryngol 1983; 92:124-7.

17. Hirano M, Yoshida Y, Yoshida T, Tateishi O. Strobofiberscopic video recording of vocal fold vibration. Ann Otol Rhinol Laryngol 1985;94:588-90.

18. Kitzing P. Stroboscopy — a pertinent laryngological examination. Otolaryngology 1985;14:3:151-7.

19. Watanabe H, Shin T, Matsuo K, Oda M, Fudaura J. A new computer-analyzing system for clinical use with a strobovideoscope. Arch Otolaryngol Head Neck Surg 1986;112:978-81.

20. Uya S, Harada N, Hayashimoto Y, et al. A high resolution CCD image sensor overlaid with a a-Si:H photoconductor layer. Abstract of the 16th International Conference on Solid State Devices and Materials 1984;325-8.

21. Takemura Y. Interline transfer CCD. Electronics Magazine 1986;31:31-6.

VOCAL FUNCTION FOLLOWING HEMILARYNGECTOMY

MINORU HIRANO, MD
SHIGEJIRO KURITA, MD HIDETAKA MATSUOKA, MD
KURUME, JAPAN

Vocal function following hemilaryngectomy was investigated in 54 cases in which a superiorly based sternohyoid muscle flap was used for glottic reconstruction. Four types of material were employed for covering the muscle flap: hypopharyngeal mucosa, lip mucosa, thyroid perichondrium, and island cervical skin flap. The vocal function varied greatly from individual to individual; however, the following tendencies were observed in many cases: 1) the glottis did not close completely; 2) supraglottic structures (false fold, arytenoid region, and epiglottis) were hyperfunctional and vibrated instead of or together with the unaffected vocal fold; 3) vibrations of the laryngeal structures were irregular; 4) maximum phonation time was short; 5) mean airflow rate was high; 6) fundamental frequency and intensity ranges of phonation were limited; 7) the voice was rough, breathy, and/or strained; and 8) cases with poor vocal function were most frequent in the skin flap group and least frequent in the lip mucosa group.

KEY WORDS — hemilaryngectomy, vocal function.

In 1976, one of the present authors (M.H.) reported a technique of glottic reconstruction following hemilaryngectomy and its preliminary functional results.[1] This technique employed a superiorly based sternohyoid muscle flap covered with hypopharyngeal mucosa or a free graft of lip mucosa. We have been using this technique since 1971 and followed up the patients for functional evaluations as well as for oncologic results. This paper describes postoperative vocal function and discusses several issues related to glottic reconstruction following hemilaryngectomy.

SUBJECTS AND METHODS

A total of 54 patients were investigated in this study. All patients had previously undergone hemilaryngectomy followed by glottic reconstruction. Of the 54, 53 were men and one was a woman. Their ages at surgery ranged from 34 to 92 years, with an average of 64 years. The surgery was conducted for carcinoma of the larynx in 52 patients, for extensive papilloma in one, and for extensive primary amyloid tumor in one.

Since the surgical technique was previously reported in detail,[1] only a brief explanation will be given here. The lesion was removed basically with the extended frontolateral laryngectomy technique. The glottis was reconstructed with a superiorly based sternohyoid muscle flap. The muscular bulge was covered by hypopharyngeal mucosa or a free graft of lip mucosa in the early period of use. The outer perichondrium of the thyroid cartilage was used for a time and, more recently, island cervical skin flap[2] was employed to cover the muscular bulge. In the present series, hypopharyngeal mucosa was used in 16 cases, lip mucosa in 15, perichondrium in two, and island skin flap in 21.

Vocal function was evaluated by means of the following tests: 1) maximum phonation time (MPT); 2) mean airflow rate (MFR) during phonation; 3) fundamental frequency range (F0 range) of phonation; 4) intensity range of phonation; 5) strobofiberscopy of the larynx during phonation; and 6) psychoacoustic evaluation with the use of the GRBAS scale. The details of these tests have been described elsewhere.[3-5]

The evaluation of vocal function was conducted 1 month to 13 years 10 months (average, 2 years 11 months) after surgery. In the majority of the cases (48 of 54), the interval from the surgery to the tests was 6 months or longer, and in 37 cases, 1 year or more. In some cases, some of the tests could not be conducted. No voice therapy was given to any patient.

RESULTS

MAXIMUM PHONATION TIME

Table 1 shows MPT for each material used for covering the muscle flap. There were great individual variations in MPT in each group. In most patients, MPT was shorter than the normal average value (approximately 25 seconds). Values of less than 10 seconds, which are abnormally short,[3] were observed most frequently for island skin flap (12 of 21) and least frequently for lip mucosa (1 of 14). Maximum phonation time was not related to the interval after the surgery in the present series.

MEAN AIRFLOW RATE

Table 1 presents MFR by the material employed for covering. Again, there were great individual

From the Department of Otolaryngology–Head and Neck Surgery, Kurume University School of Medicine, Kurume, Japan. This investigation was supported in part by a Grant-in-Aid for Scientific Research (No. 60480386), the Ministry of Education, Science and Culture, Japan.

Presented at the meeting of the American Laryngological Association, Denver, April 25-26, 1987.

REPRINTS — Minoru Hirano, MD, Dept of Otolaryngology–Head and Neck Surgery, Kurume University School of Medicine, 67 Asahi-machi, Kurume-shi, 830 Japan.

TABLE 1. MAXIMUM PHONATION TIME AND MEAN AIRFLOW RATE

	Hypo-pharynx (N = 16)	*Lip (N = 15)*	*Peri-chondrium (N = 2)*	*Skin (N = 21)*
Maximum phonation time(s)				
Average	12.1	15.4	18.6	9.3
Minimum	4.0	6.0	6.7	2.1
First quartile	8.3	12.2	—	5.8
Median	11.7	15.4	18.6	9.6
Third quartile	14.2	18.1	—	12.1
Maximum	21.2	22.7	30.4	16.6
Mean airflow rate (mL/s)				
Average	271	249	287	293
Minimum	115	60	161	100
First quartile	189	208	—	159
Median	260	236	287	278
Third quartile	335	288	—	376
Maximum	513	590	413	566

TABLE 2. FUNDAMENTAL FREQUENCY AND INTENSITY RANGES

	Hypo-pharynx (N = 9)	*Lip (N = 6)*	*Peri-chondrium (N = 2)*	*Skin (N = 20)*
Fundamental frequency range (semitones)				
Average	17	19	18	20
Minimum	7	9	15	10
First quartile	14	15	—	13
Median	15	19	18	21
Third quartile	21	27	—	24
Maximum	26	29	21	35
Intensity range (dB SPL)				
Average	24	23	19	20
Minimum	15	16	18	6
First quartile	20	16	—	16
Median	22	20	19	20
Third quartile	28	25	—	24
Maximum	32	41	19	31

differences in MFR in each group. In most patients, MFR was greater than the normal average value (100 to 150 mL/s). The rate of occurrence of abnormally high MFR, ie, more than 200 mL/s,[3] did not differ significantly among the material groups. Very high MFRs of more than 300 mL/s were least frequent for lip mucosa (1 of 15). There was no relationship between MFR and the interval from the surgery.

FUNDAMENTAL FREQUENCY RANGE OF PHONATION

Fundamental frequency range for each group is shown in Table 2. Data were available for 37 patients. The F0 range varied greatly from individual to individual in each group, and it was abnormally small in many cases. Ranges of 24 semitones (two octaves) or greater, which fall in the normal range,[3] were observed in only eight cases. The rate of occurrence of a normal F0 range did not differ significantly among the groups.

INTENSITY RANGE OF PHONATION

Table 2 shows the intensity range of phonation for each group. Data were available for 37 patients. There were great individual differences in intensity range in each group except for the perichondrium group. There are no normative values reported for the intensity range. We measured the intensity range in 11 age-matched normal subjects. The values ranged from 30 to 35 dB in nine of the 11 subjects. In most patients (32 of 37) of the present series, the intensity range was less than 30 dB.

STROBOSCOPIC FINDINGS

Stroboscopic examinations were conducted in 42 patients.

Vibrating Structure. The most striking finding was the fact that the unaffected vocal fold did not vibrate in many cases. Some other structures vibrated instead, in order to produce vocal sound. Table 3 shows the vibrating structures in each group. On the operated side, no structures vibrated during phonation in 25 of the 42 cases (60%). The reconstructed bulge at the glottis vibrated in 5 of the 13 hypopharyngeal mucosa cases and two of the nine lip mucosa cases, but in none of the perichondrium and skin flap cases. The bulge in the latter groups was stiff. Two patients in the skin flap group showed vibrations of the mucosa of a small upper portion of the false vocal fold. The major portion of the false fold had been previously removed. In a total of ten patients, the mucosa of the arytenoid region vibrated. Two patients in the hypopharyngeal mucosa group showed vibrations of both the bulge and the arytenoid region.

On the unaffected side, the vocal fold displayed vibration in seven of the 13 hypopharyngeal mucosa cases, six of the nine lip mucosa cases, one of the two perichondrium cases, and three of the 18 skin flap cases. The occurrence of vocal fold vibration was less frequent for the skin flap group. The false fold vibrated in a total of 23 of the 42 patients (55%). The incidence of false vocal fold vibration was almost the same for every group. Vibration of the arytenoid region was frequently observed in the

TABLE 3. VIBRATING STRUCTURES

	Hypo-pharynx (N = 13)	*Lip (N = 9)*	*Peri-chondrium (N = 2)*	*Skin (N = 18)*
Operated side				
Bulge	5	2	0	0
False vocal fold*	0	0	0	2
Arytenoid	3	2	0	5
None	7	5	2	11
Unaffected side				
Vocal fold	7	6	1	3
False vocal fold	8	5	1	9
Arytenoid	1	2	0	10
None	0	0	0	1
Epiglottis	1	0	0	1
Mucus only	0	0	0	1

In some cases, there were two or more vibrating structures on one or both sides of larynx.

*Small upper portion of false vocal cord. Major portion had been removed.

TABLE 4. REGULARITY OF VIBRATION AND DEGREE OF GLOTTIC CLOSURE

	Hypo-pharynx (N = 13)	*Lip (N = 9)*	*Peri-chondrium (N = 2)*	*Skin (N = 18)*
Regularity of vibration				
Regular	4	4	0	2
Irregular	9	5	2	16
Glottic closure				
Complete	4	3	0	1
Incomplete	9	6	2	17

skin flap cases. In one case of the skin flap group, no laryngeal structures showed vibration. Only mucus on the constricted supraglottis displayed irregular vibration, generating a friction sound. In some cases, two or more structures on the unaffected side vibrated during phonation.

In two cases, the mucosa of the epiglottis facing the vibrating arytenoid region was involved in vibration.

Regularity of Vibration. Successive vibrations during phonation were irregular or aperiodic in 32 of the 42 patients (76%; Table 4). Irregular vibrations were more frequently observed in the perichondrium and skin flap groups than in the pharyngeal and lip mucosa groups.

Glottic Closure. During vibratory cycles, the glottis failed to close completely in 34 of the 42 patients (81%; Table 4). Incomplete glottic closure was more frequently observed for the perichondrium and skin flap groups than for the pharyngeal and lip mucosa groups. The glottic gap was particularly wide in many cases of the skin flap group during phonation.

PSYCHOACOUSTIC EVALUATION OF VOICE

The voice was hoarse in all patients, except for one in the lip mucosa group. Table 5 shows the results of psychoacoustic evaluation of the hoarse voice by means of the GRBAS scale. A high-grade (G3) hoarseness was found more frequently in the skin flap group than in the other groups. The voice quality was rough, breathy, and/or strained in almost all cases. Asthenic voice was rare.

TABLE 5. PSYCHOACOUSTIC EVALUATION WITH GRBAS SCALE

		Hypo-pharynx (N = 13)	*Lip (N = 10)*	*Peri-chondrium (N = 2)*	*Skin (N = 18)*
Grade (G)	0	0	1	0	0
	1	2	3	1	2
	2	9	4	1	8
	3	2	2	0	8
Rough (R)	0	2	2	1	1
	1	6	3	1	5
	2	5	4	0	10
	3	0	1	0	2
Breathy (B)	0	1	1	0	3
	1	5	5	1	4
	2	6	2	1	7
	3	1	2	0	4
Asthenic (A)	0	13	9	2	17
	1	0	1	0	0
	2	0	0	0	1
	3	0	0	0	0
Strained (S)	0	4	4	0	3
	1	5	2	2	4
	2	3	3	0	6
	3	1	1	0	5

COMMENTS

The results of the present study are summarized as follows. The vocal function following hemilaryngectomy was inferior to that in normal persons. The voice was hoarse in all cases except one. Roughness, breathiness, and strain were frequently noted in the voice quality. Roughness appears to have been caused by irregular vibrations, breathiness by incomplete glottic closure, and strain by hyperfunctional supraglottic structures. In many cases, MPT was short and MFR was high, reflecting chiefly the glottic incompetence. The F0 and intensity ranges of phonation were limited in many cases, and can be attributed to the lack of muscular control on one side of the larynx. Among the four types of material used for covering the bulge, lip mucosa tended to result in a relatively good vocal function, whereas island skin flap was likely to cause a poor function.

One of the problems with the present reconstructive technique is that the muscle flap becomes atrophied to a certain extent.[6,7] Therefore, the bulge should be made larger in size in anticipation of the atrophy that will take place. We follow this principle whenever we use the pharyngeal or lip mucosa or the thyroid perichondrium. As a result, the airway is temporarily narrowed and the patients have to have a tracheostoma open for a fairly long time.[1] When an island skin flap is used, the muscular bulge does not protrude beyond the midsagittal plane because the skin flap is stretched. As a result, the tracheostoma can be closed earlier. Furthermore, the surgical procedure is simpler than when mucosa is used for covering.[2] The present study, however, demonstrated that the vocal function tended to be inferior when island skin flap was used, compared to the two types of mucosa. The greatest problem with the free graft of lip mucosa is occasional necrosis.[1]

Reports on vocal function following hemilaryngectomy are limited.[1,2,6,8-11] Nevertheless, there are some common findings. The glottis does not completely close in many cases.[1,2,6,9] Supraglottic structures including the false fold, arytenoid region(s), and epiglottis are hyperfunctional in order to compensate for the glottic incompetence.[1,6,8,9,11] These supraglottic structures vibrate instead of or together with the unaffected vocal fold.[6,8,9,11] Vibrations of the supraglottic structure are irregular,[6,9] resulting in a rough quality of voice. The glottic incompetence causes a short MPT and high MFR.[2,6,9,11] The ability to regulate F0 and vocal intensity is limited.[2,11]

It should be noted that there are great individual differences in vocal function even after the same surgical procedure conducted by the same surgeon. In other words, precise functional results are not predictable. This may be attributed to individual differences in changes of the reconstructed structure[7] and in compensatory behavior. Development of surgical techniques that assure predictable functional results is necessary.

Comparisons of vocal function among the different surgical techniques are not possible, because there are no internationally standardized methods for evaluation of vocal function. Establishment of such methods would permit comparison of various surgical techniques across institutions. We have reported on vocal function following laser surgery for glottic carcinoma,[12] which was superior to that following hemilaryngectomy in the present study.

REFERENCES

1. Hirano M. Technique for glottic reconstruction following vertical partial laryngectomy: a preliminary report. Ann Otol Rhinol Laryngol 1976;85:25-31.

2. Hirano M, Kurita S, Tateishi M, Matsuoka H. A modified Hirano technique for glottic reconstruction following hemilaryngectomy. Otolaryngology (Tokyo) 1987;59:49-54.

3. Hirano M. Clinical examination of voice. Vienna: Springer-Verlag, 1981.

4. Hirano M, Yoshida Y, Yoshida T, Tateishi O. Strobofiberscopic video recording of vocal fold vibration. Ann Otol Rhinol Laryngol 1985;96:588-90.

5. Hirano M, Hartmann HG. Aspects of videostroboscopy in practice (videotape). Kurume: Kurume University, 1986.

6. Mihashi K. Investigations of phonatory function following vertical partial laryngectomy. Otol Fukuoka 1977;23:786-806.

7. Hirano M, Shin T, Ohnishi Y. Repair and healing process of surgical injuries of the larynx. An animal model for reconstruction following hemilaryngectomy. In: Ruben RW, Van de Water TR, Rubel EW, eds. The biology of change in otolaryngology. Proceedings of the 9th ARO Mid-Winter Research Meeting, Clearwater Beach, Fla, February 1986. Amsterdam: Elsevier Science Publishers, 1986:383-94.

8. Hirano M. Phonatory function after glottal reconstruction. J Jpn Bronchoesophagol Soc 1972;23:87-93.

9. Hirano M. Phonosurgery. Basic and clinical investigations. Otol Fukuoka 1975;21:239-442.

10. Kobayashi S. Glottal vibration after Hirano's reconstruction following hemilaryngectomy. An ultra-high-speed cinematographic investigation. Otol Fukuoka 1978;24:831-49.

11. Blaugrund SM, Gould WJ, Haji T, Meltzer J, Bloch C, Baer T. Voice analysis of the partially ablated larynx. A preliminary report. Ann Otol Rhinol Laryngol 1984;93:311-7.

12. Hirano M, Hirade Y, Kawasaki H. Vocal function following carbon dioxide laser surgery for glottic carcinoma. Ann Otol Rhinol Laryngol 1985;94:232-5.

TREATMENT OF SPASTIC DYSPHONIA WITHOUT NERVE SECTION

MICHAEL FRIEDMAN, MD
VYTENIS GRYBAUSKAS, MD
DEAN M. TORIUMI, MD
EDWARD L. APPLEBAUM, MD
CHICAGO, ILLINOIS

Spastic dysphonia is a disorder characterized by strained, constricted phonation with excessively adducted vocal cords. Despite initial success with recurrent laryngeal nerve section, the search for other treatment continues. Our clinical study involved inserting a needle electrode percutaneously into the region of the recurrent laryngeal nerve in five patients with spastic dysphonia. Electrical stimulation resulted in dramatic improvement in three patients and minimal improvement in two. Our experimental study was designed to create an animal model for an implantable nerve stimulator to be used on a long-term basis. A Medtronic spinal cord stimulation system was implanted into a dog, and a cuff electrode was positioned around the recurrent laryngeal nerve. Vocal cord position could be altered by varying the stimulus frequency. Long-term stimulation of the recurrent laryngeal nerve was relatively safe and effective. Eventually, we plan to implant nerve stimulators into spastic dysphonia patients who respond well to percutaneous stimulation.

KEY WORDS — recurrent laryngeal nerve, spastic dysphonia.

INTRODUCTION

Spastic (spasmodic) dysphonia is a disorder characterized by a strained, hoarse, jerky, tight, staccato voice.[1] Patients with spastic dysphonia often exhibit facial grimacing and frowning in addition to a constricted, high-pitched voice. The spasticity of the voice results from hyperadduction of the true and false vocal cords with simultaneous elevation of the larynx.[1] The disorder has a female preponderance and usually manifests itself during the fourth or fifth decades of life. Very few cases have been reported in patients younger than 16 years of age. An accurate incidence of the disease is not known, but it has been reported that as many as 4% of all patients with functional voice disorders have spastic dysphonia.[2] Spastic dysphonia is clearly a rare disease, but its incidence may be higher than statistics indicate because many patients are misdiagnosed.

There are discordant views as to the pathophysiology of the disease. Spastic dysphonia first was thought of as a voice disorder of psychogenic origin or a form of conversion hysteria.[2] In 1960, Robe et al[3] found abnormal electroencephalographic patterns in 90% of their patients with spastic dysphonia. Aronson et al[1] further advocated the neurologic aspects of the disease, implicating the extrapyramidal tracts as the possible site of lesion. Recent reports have attributed spastic dysphonia to several possible sources: 1) central nervous system diseases involving movement disorders that hyperstimulate or disinhibit centers that control laryngeal closure and 2) acute or chronic emotional stress that can increase laryngeal musculoskeletal tension or conversion reaction.[4] Spastic dysphonia is considered idiopathic if no etiologic factor can be identified.[4]

Diagnosing spastic dysphonia is often very difficult and involves the subjective evaluation of a patient's speech and phonation with a trained ear.[5] Laryngoscopy, acoustic analysis, glottography, cinefluoroscopy, and electromyography are not diagnostic. Laryngostroboscopy can help to identify vocal cord shudder or tremor with tight glottic closure, but requires specialized equipment and is costly. The symptoms of spastic dysphonia can be quite variable and can be mistaken for those of benign essential voice tremor (neurologic cause) or oral stuttering. Patients with benign essential voice tremor may or may not have a component of spastic dysphonia. Furthermore, patients with spastic dysphonia are diagnosed not infrequently as malingerers, voice abusers, or emotionally unstable.

The treatment of spastic dysphonia has included voice-speech therapy, respiratory therapy, psychotherapy, biofeedback, electroshock therapy, hypnosis, acupuncture, meditation, muscle relaxants, tranquilizers, and vitamins.[5] The results of these therapies have been poor. Patients often become frustrated with their lack of improvement and develop exacerbation of symptoms. Mysoline has been used to treat benign essential voice tremor, but has been shown to be ineffective in the treatment of spastic dysphonia.[6]

In 1976, Dedo[7] introduced recurrent laryngeal nerve section, currently thought to be the single most effective treatment for intractable adductor spastic dysphonia. After a 3-year follow-up, Dedo and Izdebski[5,8] reported a 10% to 15% recurrence rate. They found that recurrences were for the most part less severe than the symptoms prior to nerve section.

From the Department of Otolaryngology–Head and Neck Surgery, University of Illinois College of Medicine (Friedman, Grybauskas, Applebaum), the Department of Otolaryngology–Head and Neck Surgery, Illinois Masonic Medical Center (Friedman, Grybauskas); and the Department of Otolaryngology–Head and Neck Surgery, Northwestern University Medical School (Toriumi), Chicago.

Presented at the meeting of the American Laryngological Association, Denver, April 25-26, 1987.

REPRINTS — Michael Friedman, MD, University of Illinois Eye and Ear Infirmary, Dept of Otolaryngology–Head and Neck Surgery, 1855 W Taylor St, Chicago, IL 60611.

Dedo and Izdebski[8] and Dedo and Shipp[9] stated that the failure is from a reduced glottic space and suggested postoperative voice therapy to avoid pushing or tensing the cords to increase volume.

For cases in which recurrent nerve section and voice therapy fail, Dedo and Izdebski[10] suggested vocal fold thinning under direct laryngoscopy, preferably with the carbon dioxide laser. This acts to pull the edge of the vocal fold away from the midline, thereby decreasing resistance to transglottic airflow. Despite such modifications of recurrent nerve section, there is a relatively high incidence of failure.

Aronson and DeSanto[4] reported an initial success rate of 97% at 6 months for recurrent nerve section, but at 3 years their success rate dropped to 36%; of the 64% that failed at 3 years, 48% were worse than before the nerve section. Patients that fail nerve section have a strained, hoarse voice in addition to the symptoms of iatrogenic vocal cord paralysis. Furthermore, Aronson and DeSanto[4] noted that failure is due to gradual overadduction of the intact vocal fold against the paralyzed vocal fold.

Aronson and DeSanto[4] suggested that the majority of the patients that they treated with recurrent nerve section probably had essential voice tremor (neurologic cause). They interpreted surgical failures as being due to the natural progression of the patient's neurologic condition that occurred regardless of the treatment. Other patients were believed to have a psychogenic spastic dysphonia that could be treated with voice therapy and psychotherapy.[4] Aronson and DeSanto[4] concluded that the effectiveness of unilateral recurrent laryngeal nerve section for the treatment of adductor spastic dysphonia decreases with time and results in permanent cord paralysis and treatment failure in a high number of patients.

In 1979, Biller et al[11] introduced laryngeal nerve crush for spastic dysphonia in an attempt to avoid sectioning the nerve. All of their patients had initial improvement with the nerve crush, but only 13% had continued improvement after 3 years.[11,12]

We have attempted to develop a means of recurrent laryngeal nerve stimulation that may help patients with spastic dysphonia without the need for permanent nerve section. We performed a clinical and experimental study that involved direct variable frequency electrical stimulation of the recurrent laryngeal nerve to produce an alteration in the neurophysiologic state of the ipsilateral vocal cord. In the clinical study, a fine needle electrode was passed through the skin into the region of the recurrent laryngeal nerve. This permitted stimulation of the nerve without surgical intervention. In the experimental study, a self-contained nerve stimulator was implanted into a dog, with a cuffed electrode nontraumatically placed around a recurrent laryngeal nerve.

Clinically, we were able to alter the neurophysiologic state of the recurrent laryngeal nerve in such a manner that dramatic improvement in voice quality occurred in some patients with spastic dysphonia. In the dog, we were able to position the ipsilateral vocal cord selectively by varying the frequency of the nerve stimulus. Our goal in these studies of electrical stimulation of the recurrent laryngeal nerve was twofold: 1) to demonstrate that direct electrical stimulation of the recurrent laryngeal nerve effectively can improve the voice of patients with spastic dysphonia and 2) to produce an animal model for an implantable nerve stimulator that can be used relatively safely to stimulate the recurrent laryngeal nerve for a long time period without permanent nerve damage.

MATERIALS AND METHODS

CLINICAL STUDY

Five patients with intractable spastic dysphonia were treated with unilateral percutaneous electrical stimulation of the recurrent laryngeal nerve. Three were women and two were men. Their ages ranged from 44 to 53 years. The response of each patient to the procedure was evaluated by a minimum of two speech pathologists experienced in the diagnosis of spastic dysphonia, two experienced otolaryngologists, and the patient. A 27-gauge needle (3.8 cm long) was used as the percutaneous electrode. A multifunction, solid-state, square wave stimulator (Grass Instrument Co, Quincy, Mass) was used. The percutaneous needle insertion was made at the inferolateral aspect of the cricoid cartilage in the region adjacent to the right tracheoesophageal groove. The skin was prepared with an antiseptic solution and then anesthetized with 1% lidocaine with 1:100,000 epinephrine injected superficially. Recurrent laryngeal nerve function was confirmed to rule out inadvertent infiltration. When the needle was inserted, the inferolateral aspect of the cricoid cartilage could be palpated with the needle point. The depth of needle insertion was varied depending on the thickness of the patient's neck.

With the needle in position, the square wave stimulator was set at a frequency of 300 pulses/s (range, 30 to 300 pulses/s) and a voltage of 5 to 15. These variables were manipulated to obtain maximal improvement in voice character. The patient was not informed of the initiation or discontinuation of the stimulation, to prevent a false response. The vocal cords were visualized with a flexible fiberoptic laryngoscope before, during, and after the stimulation trial. Voice recordings were made before, during, and after each stimulation trial. A cardiac monitor also was used.

Nerve stimulation was continued long enough for the patient to read the first 98 words of the Rainbow Passage.[13] After the trial was completed, the



Fig 1. Medtronic nerve stimulator transmitter with antenna and implantable receiver with cuff electrode.

electrode was removed and light pressure applied over the insertion site for 5 minutes.

The response to the percutaneous nerve stimulation was evaluated by two otolaryngologists, two speech pathologists, and the patient. The criteria for improvement were 1) reduced strained hoarseness, 2) fewer episodes of phonatory struggle or effort, 3) smooth voice flow, 4) less breathiness, 5) relaxed facial expression, and 6) increased volume. Each of these criteria were evaluated to compile a final rating of 1) worse, 2) no change, 3) improvement, or 4) marked improvement. Each patient's scores were averaged.

EXPERIMENTAL STUDY

A single mongrel dog underwent implantation of a subcutaneous, variable frequency, Medtronic nerve stimulator (model 3422, Minneapolis) for recurrent laryngeal nerve stimulation.

Anesthesia was induced using sodium pentobarbital (30 mg/kg) intravenously, and the dog was placed in the supine position with the neck shaved from mandible to xiphoid process. A straight blade laryngoscope was used to visualize the larynx and stabilize the epiglottis. Initially, transcutaneous stimulation of the left recurrent laryngeal nerve was performed by the technique of Sanders et al.[14] To demonstrate good vocal cord mobility, cord position was manipulated by altering the frequency of the nerve stimulus as described by Sanders et al.[14,15]

Using sterile technique, a midline incision was made from the hyoid bone down to the fourth tracheal ring. The strap muscles were divided in the midline. The left recurrent laryngeal nerve was identified near the left tracheoesophageal groove. A cuff of surrounding fascia was left on the nerve. The Medtronic spinal cord stimulation system was used (Fig 1). The cuffed electrode was wrapped loosely around the nerve and stabilized to surrounding tissue using nonabsorbable sutures (Fig 2). Then the implantable receiver was placed in a subcutaneous pocket over the left anterior chest wall.

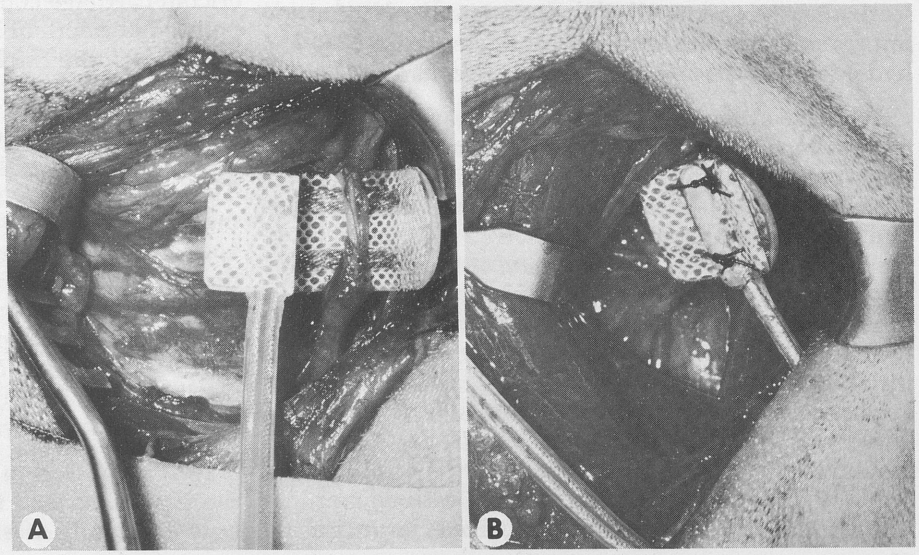

Fig 2. Canine recurrent laryngeal nerve in tracheoesophageal groove. A) Cuff electrode is adjacent to trachea. B) Cuff electrode encloses nerve and is secured to soft tissue.

Before surgical wound closure, the external transmitter and antenna were activated to test the nerve for ability to be stimulated. While altering the current and frequency, vocal cord mobility was visualized using a straight blade laryngoscope for exposure and a 0° fiberoptic telescope for photographing cord position. When it was established that the unit functioned well, the wound was closed in two layers. Penicillin was administered intramuscularly for 14 days postoperatively.

The stimulator was left in place for 6 months, and recurrent laryngeal nerve stimulation was performed every other day for the entire period. The stimulation settings ranged from 2 to 10 mA, and frequencies were varied from 10 to 100 Hz in 10-Hz increments. The duration of stimulation was 15 to 20 minutes. The stimulus is a balanced square wave with a pulse duration of 0.75 ms.

On three separate trials, the dog was fully anesthetized with sodium pentobarbital so that the position of the vocal cords could be photographed and videotaped under direct visualization. The vocal cord positions were recorded during respiration and at stimulation settings of 2 to 10 mA and at frequencies ranging from 10 to 100 Hz in 10-Hz increments. During periods of nerve stimulation, constant cardiac and respiratory monitoring was done.

After 6 months, the animal was killed and the neck examined. The segment of recurrent laryngeal nerve that was surrounded by the electrode was harvested, histologically examined, and compared with the contralateral nerve.

RESULTS

CLINICAL STUDY

Phonatory Changes. During the period of unilateral percutaneous electrical stimulation of the recurrent laryngeal nerve, all five patients had improvement in their voice characteristics. After the stimulus was terminated, their voices immediately returned to the pretreatment status. Three patients had such dramatic improvement that their voices were considered by all observers and themselves to be almost normal. The other two patients had minimal improvement. The major improvement in their speech was in the marked decrease in strain and hoarseness accompanied by a smoother voice flow and greatly improved volume. One patient had a dramatic improvement in his pronounced facial grimacing, but it returned immediately after nerve stimulation was terminated. No patient's symptoms were rated as worse. The Table shows the response of each patient based on our subjective criteria.

Observation of the vocal cords during percutaneous stimulation did not reveal any obvious change in vocal cord position. During vocalization, observation of the fine movement of the vocal cords was very difficult. Since no topical laryngeal anesthesia was used to avoid altering the results of electrical stimulation, the flexible laryngoscope could not be positioned easily just above the vocal cords. It was clear, however, that the stimulation did not cause vocal cord paralysis.

RESPONSE OF PATIENTS TO ELECTRICAL STIMULATION AS SUBJECTIVELY DETERMINED BY TWO OTOLARYNGOLOGISTS, TWO SPEECH PATHOLOGISTS, AND PATIENT

Patient No.	Otolaryngologists' Scores		Speech Pathologists' Scores		Patient's Response	Average
	1	2	1	2		
1	4	3	4	3	4	3.6
2	4	4	4	3	4	3.8
3	3	2	2	3	2	2.4
4	3	3	2	3	2	2.6
5	4	4	4	4	4	4.0

4 — marked improvement, 3 — improvement, 2 — no change, (1 — worse).

Cardiopulmonary Status. Throughout all five trials of percutaneous recurrent laryngeal nerve stimulation, there were no arrhythmias or significant changes in heart rate or respiratory pattern. No patients had chest pain, flushing, or vasovagal responses. Continuous electrocardiographic recordings were unchanged throughout periods of electrical stimulation.

Test Tolerance. The only discomfort experienced by the patients was slight pain at the ground electrode site on the forearm if the voltage was increased above 15 during trials. There was no neck discomfort, adjacent muscle twitching, or delayed sequelae.

Complications. There was no evidence of infection, hematoma, or soft tissue damage at the percutaneous puncture site. After the stimulation trials, indirect examination of the larynx did not reveal any evidence of recurrent laryngeal nerve paresis or paralysis.

EXPERIMENTAL STUDY

Vocal Cord Position. During observation of the dog's larynx, recurrent laryngeal nerve stimulation revealed initial abduction followed by adduction of the ipsilateral vocal cord as the frequency was increased from 10 to 100 Hz. The current was held at 5 or 6 mA. At the low frequencies (10 to 20 Hz), nerve stimulation resulted in oscillation of the vocal cord from the resting position to the partially abducted position. As the frequency was increased, the cord movement became finer and oscillation became less noticeable, with movement toward maximal abduction at 40 Hz. At frequencies greater than 50 Hz, the vocal cord was noted to adduct, with near-complete adduction at 70 Hz. With the cords in the adducted position, further increases in frequency resulted in further closure of the glottis and eventual onset of stridor. Optimal cord motion was noted at 5 to 6 mA. Current greater than 7 mA resulted in adjacent muscle stimulation and discom-



Fig 3. Harvested canine recurrent laryngeal nerve after 6 months of electrical stimulation showing cuff of scar tissue.

fort to the animal.

Cardiorespiratory Status. The dog was connected to a cardiac and respiratory monitor throughout the entire period of nerve stimulation. There were no episodes of arrhythmia or marked changes in heart or respiratory rates. There was a slight increase in heart and respiratory rates when the current was greater than 8 mA or when the frequency was greater than 80 Hz (glottic closure with stridor).

Recurrent Laryngeal Nerve Function. Prior to killing of the animal, the larynx was visualized while the animal was breathing spontaneously. Both vocal cords moved well without evidence of paresis, paralysis, or any asymmetry.

Histopathology of Recurrent Laryngeal Nerve. Upon opening the neck, scar tissue was noted around the electrode site. The electrode and receiver were removed without difficulty. The segments of recurrent laryngeal nerve that were surrounded by the electrode were excised, as well as the corresponding contralateral segment of recurrent laryngeal nerve. The recurrent laryngeal nerve itself was intact, but there was a cuff of scar tissue surrounding the nerve at the site of the electrode (Fig 3). The nerve sheath was intact, with no evidence of damage to the nerve despite its being enclosed by an electrode cuff with persistent, long-term nerve stimulation. There was no granulation tissue, inflammation, or other surrounding tissue damage.

Histologic comparison between the ipsilateral and contralateral recurrent laryngeal nerves revealed primarily perineural and epineural fibrosis with slight endoneural fibrosis of the stimulated nerve (Fig 4).

DISCUSSION

In our preliminary studies, unilateral percutaneous electrical stimulation of the recurrent laryngeal nerve dramatically improved the voice quality of patients with spastic dysphonia. The improved voice quality lasts only as long as the needle electrode is transmitting current to the nerve. The exact mechanism by which this electrical stimulation helps these patients is unknown. The magnitude of current is relatively low, and there is no observable change in cord position. Perhaps we are altering the neurophysiologic state of the recurrent laryngeal nerve in a way that hinders or masks abnormal impulses from a central source. Many of these patients actually may have essential voice tremor for which the current alters the hypertonic signals from the brain stem or extrapyramidal tracts. The mechanism may be similar to that theorized of electrotherapy for severe tinnitus and hemifacial spasm.[16,17] The stimulation may inhibit the excessive impulses causing hyperadduction of the vocal cords and, at the same time, rectify the irregularity of the transmission of impulses by a regular interval of stimulation.[16,17]

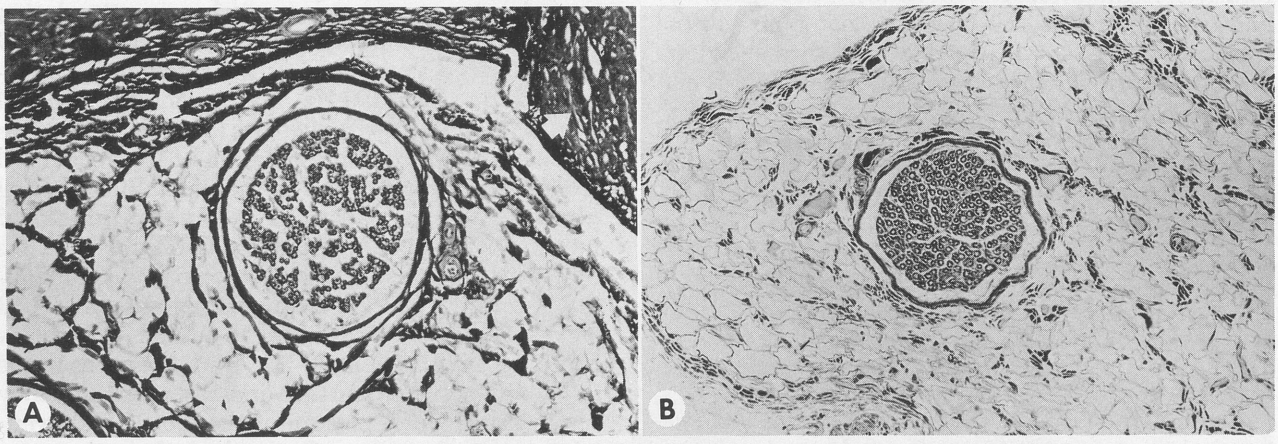

Fig 4. Histologic sections of canine recurrent laryngeal nerve using trichrome stain. A) Dense perineural fibrous tissue surrounds intact nerve trunk with negligible endoneural fibrosis. Arrows point to fibrotic scar tissue. B) Contralateral normal recurrent laryngeal nerve.

Percutaneous stimulation of the recurrent laryngeal nerve is not a precise method of nerve stimulation, because the insertion of the needle electrode only approximates the position of the recurrent laryngeal nerve. Exact placement of an implanted electrode permitting direct stimulation undoubtedly will yield superior, reproducible results.

There were no cardiovascular or respiratory alterations noted with percutaneous electrical stimulation of the recurrent laryngeal nerve. The current and voltage were small and did not result in any discomfort or adjacent muscle stimulation. Such information is important because of the proximity of the stimulus to the vagus nerve, superior laryngeal nerve, nerve branches to the carotid sinus, and possible aortic baroreceptor pathways in the recurrent laryngeal nerve itself.[15]

The success of percutaneous electrical stimulation of the recurrent laryngeal nerve in the treatment of spastic dysphonia may enable us to treat the disease without permanent nerve paralysis. If percutaneous nerve stimulation is effective in a patient, the next step is to implant a self-contained unit that could stimulate the recurrent laryngeal nerve for as long as needed. The patient could initiate the stimulation whenever he or she begins to speak. The electrode would be positioned around the nerve and the receiver implanted into a subcutaneous pocket over the chest wall. The transmitter and antenna could be worn on the belt or kept in a pocket.

We intend to implant the nerve stimulator in patients with spastic dysphonia to stimulate the recurrent laryngeal nerve directly. The criteria for implantation will include improvement of symptoms of spastic dysphonia during unilateral percutaneous electrical stimulation. In our experimental study, the recurrent laryngeal nerve remained undamaged after 6 months of direct electrical stimulation. If the nerve stimulation is not helpful or fails with time, the unit can be removed and the nerve should be left intact.

Our experimental study demonstrated that a self-contained, subcutaneous nerve stimulator could be used relatively safely without damaging the recurrent laryngeal nerve. An electrode cuff encircled the nerve and permitted direct stimulation from a receiver unit placed in a subcutaneous pocket. A similar silicone rubber electrode cuff is employed with a phrenic nerve stimulator for diaphragmatic pacing to treat respiratory insufficiency.[18] Histopathologic studies of human phrenic nerves that were stimulated with the electrode cuff for up to 4 years occasionally revealed focal areas of demyelination with some axonal loss.[19] The nerves of some patients stimulated for approximately 2 years showed no changes.[19] This suggests that injury was not caused by the electrical stimulation, but by the technique and improper nerve fixation.[19] Animal studies with vagus[20] or splanchnic nerves[21] showed no microscopic abnormalities after long-term electrical stimulation. After 6 months of direct stimulation, there was no evidence of damage to the recurrent laryngeal nerve. The study demonstrated the effectiveness and safety of the nerve stimulator and that it could be implanted and removed without any recurrent laryngeal nerve deficit.

We also will perform extensive laryngeal studies including laryngostroboscopy in an effort to identify how we are altering recurrent laryngeal nerve function to produce improvement in spastic dysphonia. Further studies of this type may reveal the true pathophysiology causing spastic dysphonia.

CONCLUSION

We have introduced a technique of unilateral percutaneous electrical stimulation of the recurrent laryngeal nerve that improves the voice of patients with spastic dysphonia. An experimental study demonstrated the ease, relative safety, and effectiveness of an implantable electrode and receiver for direct electrical stimulation of the recurrent laryngeal nerve. Implantation of nerve stimulators in patients with spastic dysphonia may improve voice quality without need for permanent recurrent laryngeal nerve section. Although this procedure does not represent a cure for spastic dysphonia, it seems to offer effective, reversible treatment until a cure is found.

ACKNOWLEDGMENTS — The authors thank Bonnie E. Smith, PhD, Assistant Professor, Department of Otolaryngology–Head and Neck Surgery, University of Illinois College of Medicine, for patient speech evaluations; Chet Childs, Scientific Photographer, University of Illinois, for outstanding audiovisual management; Dr Thomas Chilis, Illinois Masonic Medical Center, for the pathologic study; and Terri Strorigl, RN, for laboratory and editorial assistance.

REFERENCES

1. Aronson AE, Brown JR, Litting EM, Pearson JS. Spastic dysphonia II: comparison with essential voice tremor and other neurologic and psychogenic dysphonias. J Speech Hear Disord 1968;33:219-31.

2. Brodnitz FS. Spastic dysphonia. Ann Otol Rhinol Laryngol 1976;85:210-4.

3. Robe E, Brumlik J, Moore P. A study of spastic dysphonia: neurologic and electroencephalographic abnormalities. Laryngoscope 1960;70:219-45.

4. Aronson AE, DeSanto LW. Adductor spastic dysphonia: three years after recurrent laryngeal nerve section. Laryngoscope 1983;93:1-8.

5. Dedo HH, Izdebski K. Immediate results of 306 recurrent laryngeal nerve sections for spastic dysphonia. Laryngoscope 1983;93:9-16.

6. Hartman DE, Vishwanat B. Spastic dysphonia and essential (voice) tremor treated with primidone. Arch Otolaryngol 1984;110:394-7.

7. Dedo HH. Recurrent laryngeal nerve section for spastic dysphonia. Ann Otol Rhinol Laryngol 1976;85:451-9.

8. Dedo HH, Izdebski K. Problems with surgical (RLN section) treatment of spastic dysphonia. Laryngoscope 1983;93: 268-71.

9. Dedo HH, Shipp T. Spastic dysphonia: a surgical and voice therapy program. Houston: College-Hill, 1980:1-17.

10. Dedo HH, Izdebski K. Surgical treatment of spastic dysphonia. Contemp Surg 1981;19:75-90.

11. Biller HF, Som ML, Lawson W. Laryngeal nerve crush for spastic dysphonia. Ann Otol Rhinol Laryngol 1979;88:531-2.

12. Biller HF, Som ML, Lawson W. Laryngeal nerve crush for spastic dysphonia. Ann Otol Rhinol Laryngol 1983;92:469.

13. Fairbanks G. Voice and articulation drillbook. New York: Harper, 1960.

14. Sanders I, Aviv J, Biller HF. Transcutaneous electrical stimulation of the recurrent laryngeal nerve: a method of controlling vocal cord position. Otolaryngol Head Neck Surg 1986;95: 152-7.

15. Sanders I, Aviv J, Kraus WM, Racenstein MM, Biller HF. Transcutaneous electrical stimulation of the recurrent laryngeal nerve in monkeys. Ann Otol Rhinol Laryngol 1987;96:38-42.

16. Chouard CH, Myers B, Maridat D. Transcutaneous electrotherapy for severe tinnitus. Acta Otolaryngol (Stockh) 1981;91: 415-22.

17. Yamamoto E, Nishimura H. Treatment of hemifacial spasm with transcutaneous electrical stimulation. Laryngoscope 1987;97:458-60.

18. Fodstad H, Anderson G, Blom S, Linderholm H. Phrenic nerve stimulation (diaphragm pacing) in respiratory paralysis. Appl Neurophysiol 1985;48:351-7.

19. Kim JH, Manuelidis EE, Glen WW, Kaneyuki T. Diaphragm pacing: histologic changes in the phrenic nerve following long-term electrical stimulation. J Thorac Cardiovasc Surg 1976; 72:602-8.

20. Bourde J, Robinson LA, Suda Y, White TT. Vagal stimulation. I. A technique for repeated stimulation of the vagus on conscious dogs. Ann Surg 1970;171:352-6.

21. Palti Y. Stimulation of internal organs by means of externally applied electrodes. J Appl Physiol 1966;21:1619-24.

VOCAL LIGAMETRY
UPDATE

FRANCIS E. LEJEUNE, JR, MD
NEW ORLEANS, LOUISIANA

In 1983, a report was made concerning experience with a technique of vocal ligament tightening in certain cases of dysphonia due to the ligament's stretching or lengthening. Since that time, efforts to measure the relative slackness or loss of tension of the vocal ligament have been partially successful. This report addresses the topics of consent forms; review of the local board of human procedures; and technical problems of instrument design, fabrication, and calibration. A large data base will be needed before true usefulness can be derived from these efforts. The author hopes to stimulate other workers in the field of phonosurgery to parallel these efforts and explore a field that is still relatively uncharted.

KEY WORDS — vocal ligament tightening, vocal ligametry.

INTRODUCTION

In 1983, we reported our experience with five cases of severe hoarseness that were improved by means of tightening the vocal ligament.[1] The surgical correction was accomplished by advancing the anterior commissure of the thyroid cartilage several millimeters, estimating the distance necessary to tighten the vocal ligament effectively. Tucker[2] and Koufman[3] subsequently reported favorable experiences with the procedure, each introducing modifications.

Before the technique could gain wide use, however, we felt that a more reliable means of patient selection and of objective assessment of the corrective effort was needed. This involved measurement of the vocal (thyroarytenoid) ligament by direct contact with a calibrated device. This, of course, required elimination of the cough reflex and also of any muscle tightness due to breathing, breath holding, or phonation.

METHODS

General anesthesia is administered via a small endotracheal tube, combined with topical anesthesia and a curare-like medication to eliminate muscle spasm. The glottis is exposed with a fairly large laryngoscope, and then it is suspended. A caliper is introduced through the laryngoscope to embrace the vocal cord with three stainless steel pins (Fig 1A). The two fixed pins are placed on the superior surface of the vocal cord; the single pin is extended beneath the cord by squeezing the trigger and then is allowed to travel upward by the pull of a light spring (Fig 1B). The single pin pulls up a loop of vocal cord into the 3-mm gate between the two fixed pins (Fig 1C). The amount of travel the single pin makes is related directly to the relative length of the vocal ligament. Thus, a normal vocal ligament will allow a limited amount of pin travel. A stretched or long vocal ligament will allow a greater amount of pin travel. An overly taut or short vocal ligament will allow much less pin travel. The technical steps in measuring the ligament are as follows:

1. Administering general and topical anesthesia, using the smallest endotracheal tube considered safe for the patient (6 mm or less inside diameter, 8 mm outside diameter)
2. Performing suspension laryngoscopy using a laryngoscope large enough to admit the 5 x 5-mm tip of the caliper
3. Drying the vocal cord epithelium to lessen the slippery quality of the surface (cotton applicators may be used)
4. Placing the pins to embrace the true vocal cords — two pins above, one below; proximal magnification (3x) is required (Wolf G4205.20)
5. Maintaining the proper amount of lateral pressure with the tip of the caliper for the 10 seconds or more that is required for the pin to stabilize
6. Recognizing the end point — that point at which the indicator needle almost stops moving
7. Reading the dial indicator (Starrett 25-881J), which is actually a fine measure of distance, in millimeters and 0.01 mm (must be done by an assistant on the command, "Start," and 10 seconds later, "Stop")
8. Calibrating the light spring (every 6 months)

A potential problem in measuring the ligament is laceration of a vocal cord. This could occur if the center pin were extracted forcibly in the lateral position while the patient was in laryngospasm. Should laryngospasm occur, the operator should squeeze the trigger immediately, extending the single pin; the instrument then is rotated toward the midline and extracted from the glottis.

From the Department of Otolaryngology, Ochsner Clinic and Alton Ochsner Medical Foundation, New Orleans.
Presented at the meeting of the American Laryngological Association, Denver, April 25-26, 1987.
REPRINTS — Francis E. LeJeune, MD, Ochsner Clinic, 1514 Jefferson Highway, New Orleans, LA 70121.

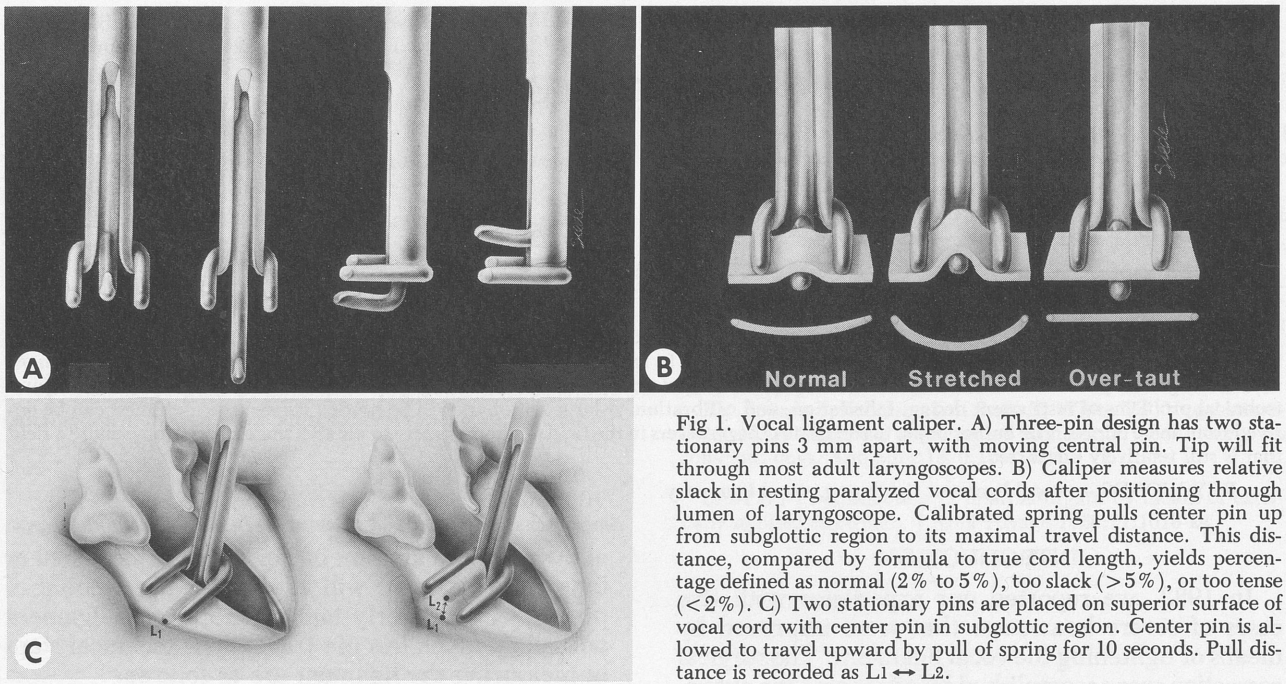

Fig 1. Vocal ligament caliper. A) Three-pin design has two stationary pins 3 mm apart, with moving central pin. Tip will fit through most adult laryngoscopes. B) Caliper measures relative slack in resting paralyzed vocal cords after positioning through lumen of laryngoscope. Calibrated spring pulls center pin up from subglottic region to its maximal travel distance. This distance, compared by formula to true cord length, yields percentage defined as normal (2% to 5%), too slack (>5%), or too tense (<2%). C) Two stationary pins are placed on superior surface of vocal cord with center pin in subglottic region. Center pin is allowed to travel upward by pull of spring for 10 seconds. Pull distance is recorded as L1 ↔ L2.

RESULTS

Three readings are taken and averaged. The mathematic equation of the measurement of the vocal ligament is as follows.

$$\text{ligament stretch index (LSI)} = \frac{(\sqrt{(\text{pin travel}^2 + 2.25)} \times 2) - 3}{\text{ideal vocal cord length}}$$

(Ideal vocal cord length is obtained by x-ray study or direct measurement: the distance from the thyroid notch to the inferior border of the thyroid cartilage, midline, is approximately the same as the length of the vocal cord.)

Our current estimates are as follows: normal vocal ligament, LSI = 2% to 5%; clinically stretched vocal ligament, LSI = 5% to 10%; clinically overtaut, high pitched ligament, LSI = 0% to 2%.

Our efforts so far must be considered to be only a pilot study, as these estimates are based on experience with only 22 patients, some of whose measurements were considered valid, others invalid because of difficulty in recognizing the end point. More data will be needed before these estimates can be confirmed.

In addition, some nontechnical problems of this study may be even more difficult to resolve. A full study and review by the Clinical Investigations Committee of my medical institution was required of me before a relevant operative permit form could be approved.

The opinion of our legal counsel is that at this time it would be very hazardous for me to give, loan, or otherwise dispense or distribute any of the vocal ligament caliper units to fellow clinicians who are interested in vocal ligametry. Presumably, these might be used on humans in a manner that might damage a vocal cord and therefore provide a claim against the institution or against me for failing to foresee such a problem. An indemnity agreement from such physicians indemnifying my institution and myself against any suits or losses for using the device, whether on humans or animals, would be needed. Also, we would need an agreement stating that the device would not be used on humans. Should the device gain approval by the Food and Drug Administration under the Devices Act, then such agreements might not be needed.

DISCUSSION

The mechanism of the tightening of the vocal bands has been of long and enduring interest to the American Laryngological Association (ALA). At the fifth annual meeting of the ALA in 1883 held in New York, Dr F. H. Hooper[4] of Boston described his experimental research on the tension of the vocal bands. His studies of canine and human cadaver larynges demonstrated that the cricothyroid muscle and the inflation factor of increased subglottic pressure both serve to increase the tension of the vocal bands.

Isshiki's[5] studies on the regulatory mechanism of the pitch and volume of the voice in 1959 and his many studies since have added to our knowledge of laryngeal dynamics. Tanaka and Gould[6] and, more recently, Tanaka and Tanabe[7] have helped to refine our knowledge of the mechanism for adjustment of the glottis to regulate vocal intensity. Their conclusion was that cordal adduction, as a function of the lateral cricoarytenoid muscle and other muscles, and changes in cordal shape and stiffness as a func-

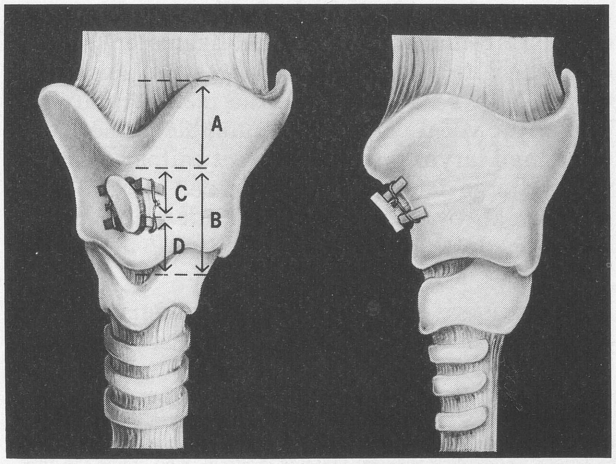

Fig 2. Thyroplasty type 2. Advancement of anterior commissure to increase tension of vocal ligaments currently is performed by completely mobilizing midline segment of cartilage and inserting metal strip both above and below point of ligament insertion. Distance B (as defined by Gould et al[9]) is used as estimate of vocal cord length and can be measured directly or by x-ray study.

tion of the thyroarytenoid muscle were responsible for the minute changes in vocal intensity. In 1883, Hooper[4] said that a singer with a three-octave range had as many as 2,100 changes in pitch, each representing successive changes in the length of the vibrating edges of the vocal bands in successive proportions of one seventeen-thousandth of an inch (0.00149 mm).

In 1974, Isshiki et al[8] described thyroplasty as a new phonosurgical technique and made reference to altering the tension of the vocal ligament by altering the anterior commissure. Gould et al[9] have described techniques for increasing the tension of one vocal ligament by dividing one thyroid ala vertically and inserting a plug to distract the edges. Since our report on early experience with vocal ligament tightening[1] by advancing the anterior commissure, which contains the insertion of the vocal ligaments, Tucker[2] and Koufman[3] have reported successful use and modification of the anterior advancement technique. Our current technique of anterior commissure advancement (Fig 2) uses a metal strip above and below the ligament insertion.

In Japan, Isshiki's[9] success with local anesthesia of several hours' duration for the adjustment of vocal ligament position and tension is undeniable. I believe, however, that greater acceptance in this country would be achieved if the procedure could be performed under general anesthesia.

For this reason, we have tried to develop an objective method of evaluation and selection of patients who might be in need of adjustment of vocal ligament tension. This would be a measurement of the ligament performed while the patient was anesthetized for suspension laryngoscopy. The adjustment of the ligament tension could be done at that time or at a later time.

Direct measurements of the vocal ligament made under general anesthesia must be made with the realization that the ligament is totally relaxed and that the arytenoids are in the abducted position, held there by the presence of the endotracheal tube. The amount of slack or gatherable ligament is measured (Fig 1C). A similarity exists to an auto mechanic's palpating the alternator belt while the engine is at rest to judge the adequacy of its tension.

The three-pin design (Fig 3A) was considered to be the simplest mechanical tool for assessing the amount of linear slack in the resting ligament. A hy-

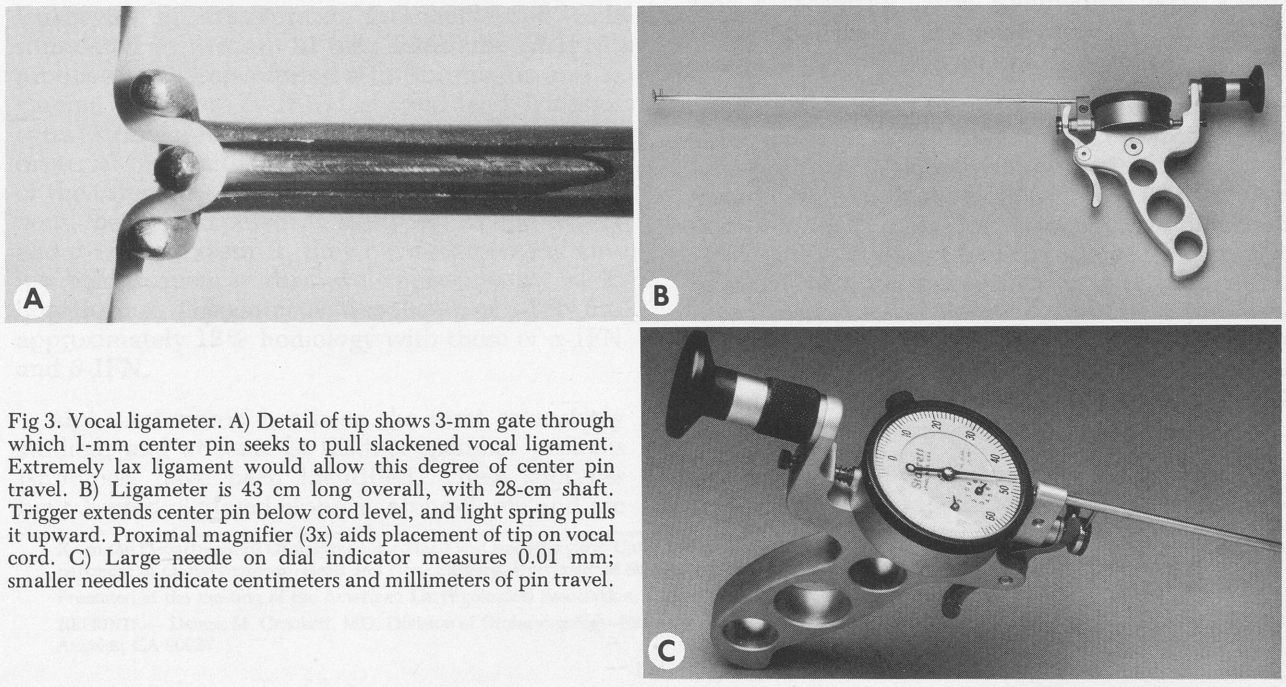

Fig 3. Vocal ligameter. A) Detail of tip shows 3-mm gate through which 1-mm center pin seeks to pull slackened vocal ligament. Extremely lax ligament would allow this degree of center pin travel. B) Ligameter is 43 cm long overall, with 28-cm shaft. Trigger extends center pin below cord level, and light spring pulls it upward. Proximal magnifier (3x) aids placement of tip on vocal cord. C) Large needle on dial indicator measures 0.01 mm; smaller needles indicate centimeters and millimeters of pin travel.

draulic inflatable cuff and a miniature torsion bar were rejected as being too difficult to read. Since ligaments distort or stretch gradually under a constant force, there is a gradual elongation as the pin presses against the undersurface of the vocal ligament. If the pin were left in position too long, the cord and ligament would travel laterally and slide off its tip. Therefore, a time limit of 10 seconds is placed on this phase of the measurement. An assistant is instructed to read the dial indicator (Fig 3B,C) on the command "Start," and again 10 seconds later at the command "Stop."

The laryngoscope used for exposure of the ligament must be wide enough to allow ready passage of the 5 x 5-mm tip of the vocal ligameter. The endotracheal tube chosen must be small enough so that it allows easy access to the membranous portion of the vocal cord. We are unable to measure a very small larynx with the current caliper. Furthermore, a large data base will be needed before a range for normal, overslack, and overtaut values can be determined.

In summary, objective vocal ligametry is a step closer than it was 4 years ago, but real success is at least several years away.

ACKNOWLEDGMENTS — I would like to thank Mark Duvoisin, formerly of Tulane University School of Engineering, currently with NASA at the Kennedy Space Center, who assisted me in the design of the caliper; Nicholas Fisher, president of Fisher Machine Shop in New Orleans, who assisted in the fabrication of the instruments; and Dr Mack Cheney and other members of the Tulane University Residency Training Program, who, under the direction of Department Chairman Harold G. Tabb, MD, assisted in the collection of data while on rotation at Ochsner Foundation Hospital.

REFERENCES

1. LeJeune FE Jr, Guice CE, Samuels PM. Early experiences with vocal ligament tightening. Ann Otol Rhinol Laryngol 1983; 92:475-7.

2. Tucker HM. Anterior commissure laryngoplasty for adjustment of vocal fold tension. Ann Otol Rhinol Laryngol 1985; 94:547-9.

3. Koufman JA. Laryngoplasty for vocal cord medialization: an alternative to Teflon®. Laryngoscope 1986;96:726-31.

4. Hooper FH. Experimental researches on the tension of the vocal bands. Transactions of the fifth annual meeting of the American Laryngological Association. New York: Putnam Press, 1883:118-40.

5. Isshiki N. Regulatory mechanism of the pitch and volume control of voice. Practica Otol (Kyoto) 1959;52:1065-94.

6. Tanaka S, Gould WJ. Relationships between vocal intensity and noninvasively obtained aerodynamic parameters in normal subjects. J Acoust Soc Am 1983;73:1316-21.

7. Tanaka S, Tanabe M. Glottal adjustment for regulating vocal intensity — experimental study. Acta Otolaryngol (Stockh) 1986;102:315-24.

8. Isshiki N, Morita H, Okamura H, Hiramoto M. Thyroplasty as a new phonosurgical technique. Acta Otolaryngol (Stockh) 1974;78:451-7.

9. Gould WJ, Lawrence VL, Isshiki N. Surgical care of voice disorders. New York: Springer-Verlag, 1984:78-9.

SIDE EFFECTS AND TOXICITY OF INTERFERON IN THE TREATMENT OF RECURRENT RESPIRATORY PAPILLOMATOSIS

DENNIS M. CROCKETT, MD
LOS ANGELES, CALIFORNIA
RODNEY P. LUSK, MD
ST LOUIS, MISSOURI
BRIAN F. MCCABE, MD
IOWA CITY, IOWA
JANIS HORNE MIXON, RN
IOWA CITY, IOWA

Twenty-six patients with recurrent respiratory papillomatosis have received interferon administered according to one or more of five experimental protocols currently ongoing or completed at the University of Iowa. Short-term side effects following interferon administration were common and included fever, headache, chills, fatigue, myalgias, and nausea. Two patients experienced neurotoxicity manifested as somnolence, confusion, or petit mal type or grand mal type seizures. Preliminary data show evidence for some growth retardation in patients receiving long-term interferon therapy. Laboratory evidence of toxicity in the form of decreased WBC, RBC, and platelet counts occurred in five patients, and increased liver enzymes occurred in 16 patients. Neither cardiovascular nor renal toxicity was noted.

KEY WORDS — interferon side effects, interferon toxicity, recurrent respiratory papillomatosis.

INTRODUCTION

The term interferon was introduced approximately 30 years ago to describe an antigenic inducible cellular factor that by some mechanism protected eukaryotic cells from infection by influenza virus.[1] During the past decade, investigators have directed much effort toward a better understanding of the structure and complex functions of the interferons so that the most effective therapeutic applications of these agents may be realized. Interferons are natural proteins manufactured by eukaryotic cells in response to viral and nonviral stimuli (eg, mitogens, allogeneic cells, bacterial and viral antigens, or other polynucleotide antigens). Three major antigenic classes of interferon have been delineated based on their cells of origin: 1) alpha interferon (α-IFN), derived from cultures of normal leukocytes or transformed lymphoblastoid cells stimulated by viruses; 2) beta interferon (β-IFN), produced by virus-infected skin fibroblasts; and 3) gamma interferon (γ-IFN), secreted by T-lymphocytes stimulated by certain specific mitogens, bacterial or viral antigens, or allogeneic cells.[2] All of the three major types of interferon are heterogenous, being composed of subtypes. While α-IFN and β-IFN are distinct, they have segments of amino acid sequences that are approximately 40% homologous. The amino acid sequence of γ-IFN has approximately 12% homology with those of α-IFN and β-IFN.

Alpha interferon has been the most extensively studied, and at least 14 distinct member proteins (subtypes) have been identified. These subtypes have been designated alpha-1, alpha-2, etc and are composed of approximately 166 amino acids each and share at least 75% amino acid homology. The α-IFNs have been classified further according to World Health Organization nomenclature depending on the method of production and, in the case of recombinant DNA α-IFN, on the amino acid sequence in the interferon molecule (eg, alfa-2a, alfa-2b, alfa-2c, alfa-N1).[3] The designation alfa is used rather than alpha to denote the international spelling. Most major pharmaceutical companies in the United States have used one of two methods to produce α-IFN: 1) isolation from supernatants of cultures of human lymphoblastoid cells subjected to viral stimulation (eg, IFN alfa-N1, Wellferon, Burroughs Wellcome Co, Research Triangle Park, NC); or 2) expression of certain gene loci in bacteria using recombinant DNA techniques (eg, IFN alfa-2b, Intron A, Schering Corp, Kenilworth, NJ).[4] Use of recombinant DNA technology has allowed production of highly purified interferon proteins.

The mechanisms of action of the interferons involve antiviral, antineoplastic, and immunomodulatory effects.[5] The antiviral properties of the interferons involve induction of enzymes within eukaryotic cells that block viral replication of RNA and DNA and alteration of eukaryotic cell membranes to make them less susceptible to viral penetration. Interferon selectively inhibits growth and proliferation of neoplastic cells by unknown mechanisms. Immunoregulatory effects involving mediation of both the humoral and cellular pathways of the immune system are understood poorly.

A number of investigators have shown that interferon retards the growth of respiratory papilloma-

From the Department of Otolaryngology–Head and Neck Surgery, University of Iowa Hospitals and Clinics, Iowa City. Dr Crockett is now at the Department of Otolaryngology–Head and Neck Surgery, University of Southern California School of Medicine, Los Angeles.

Presented at the meeting of the American Laryngological Association, Denver, April 25-26, 1987.

REPRINTS — Dennis M. Crockett, MD, Division of Otolaryngology–Head and Neck Surgery, Children's Hospital of Los Angeles, 4650 Sunset Blvd, Los Angeles, CA 90027.

TYPE OF INTERFERON, DURATION OF THERAPY, DOSAGE, AND CURRENT STATUS

Patient	Interferon Type	Duration of Therapy (wk)	Dosage (megaunits/ m^2)	Current Status re: Interferon
1	BW	19; 31	5; 1-1.5	On BW
2	NYBC	151	1-3	Off
3	BW	35	5	Off
4	NYBC	227	3-4	On S
	S	27	3	
5	NYBC	261	3-5	On NYBC
6	NYBC	52	1-3	Off
7	NYBC	192	3-7	On S
	S	36	3-4	
8	BW	224	3-5	On BW
9	BW	54	2	Off
10	NYBC	34	1-2	On S
	S	3; 168	3; 3	
11	BW	153	4	Off
12	NYBC	194	3-5	On S
	S	26	3	
13	NYBC	53	3	Off
14	NYBC	62	2	Off
15	BW	49; 27	4; 4	On BW
16	NYBC	52	7	On S
	S	34	3	
17	NYBC	36	3-7	Off
18	BW	65	5	Deceased
19	NYBC	119	3	On S
	S	64	5	
20	S	32	3	On S
21	NYBC	52	3-5	Off
22	NYBC	263	2-3	On NYBC
23	NYBC	56	3	Off
24	NYBC	84	3	Off
25	NYBC	45	3-5	Off
26	NYBC	26	3	Off

NYBC — New York Blood Center interferon, BW — Burroughs Wellcome Co interferon, S — Schering Corp interferon.

tosis and thereby reduces the frequency of surgical procedures.[6-9] A more recent investigation has shown only transient retardation of papilloma growth and is not as encouraging as earlier reports (G. B. Healy; personal communication). Interferon is not a benign agent, and the potential benefits of administration of the drug to each patient must be weighed against the potential side effects and toxicity. Many reports in the internal medicine literature have discussed the signs and symptoms of side effects and general toxicity of interferon in the treatment of various malignant neoplasms. Previous reports from our institution reporting the efficacy of interferon in the treatment of recurrent respiratory papillomatosis have briefly outlined the side effects that occurred secondary to the drug.[8,9] Since that time, additional toxic effects and side effects have been observed and studied. An updated retrospective analysis of side effects and toxicity secondary to interferon in the treatment of recurrent respiratory papillomatosis forms the basis for this report. The report updates the practicing otolaryngologist on the possible side effects and toxicity of interferon, as release of interferon from its investigational status by the Food and Drug Administration is expected in the near future.

MATERIALS AND METHODS

Twenty-six patients were included in the study group. The type of interferon each patient received, the total duration of therapy, the approximate dosage, and current status regarding interferon administration are shown in the Table. Fifteen patients had brief interruptions of interferon therapy (less than 8 weeks at a time) for reasons that will be described in the Results section. Three patients (Nos. 1, 10, and 15) had prolonged interruption of interferon therapy (more than 8 weeks), indicated in the Table by the two numbers in the column showing duration of therapy. The patient group consisted of 25 children, with a present mean age of 7.5 years, and one 47-year-old man (No. 16).

The 26 patients received interferon from three sources. Early in our experience, all patients received a partially purified polyclonal mixture of α-IFN produced from cultures of human leukocytes by the New York Blood Center, Inc (NYBC). Recently, new patients and some previous patients receiving NYBC interferon have received either 1) interferon alfa-N1 (Wellferon), which is purified from supernatants of cultures of human lymphoblastoid cells stimulated by Sendai virus; or 2) interferon alfa-2b (Intron A), which is produced by *Escherichia coli* in recombinant DNA technology. Interferon alfa-2b is the product of a single gene and is purified to homogeneity, unlike the other two interferons.

The interferon preparations were injected either subcutaneously (Intron A, Wellferon) or intramuscularly (NYBC interferon) according to dosage schedules set up by the various study protocols (the Table lists dosages). Depending on the particular protocol for the individual patient, interferon was administered either three times per week or every other day. Beginning dosages were calculated based on the patient's body surface area in square meters (m^2). The biologic activity of the α-IFNs is expressed in international units of antiviral activity per milligram of protein or in megaunits.[5] One megaunit is equal to 10^6 IU. Biologic activity of α-IFN is based on the minimum dilution of interferon required to protect 50% of eukaryotic cells exposed to a particular viral strain.

Our experience with the efficacy of NYBC interferon in retarding the growth of respiratory papillomatosis has been reported in detail previously.[8,9] A pilot study involving Intron A is currently ongoing at our center and will be reported in the future. Wellferon is being administered at our center as part of a multi-institutional study, with The Johns Hopkins Medical Institutions serving as the study center.

RESULTS

ACUTE TOXICITY

An acute febrile reaction following the initial in-

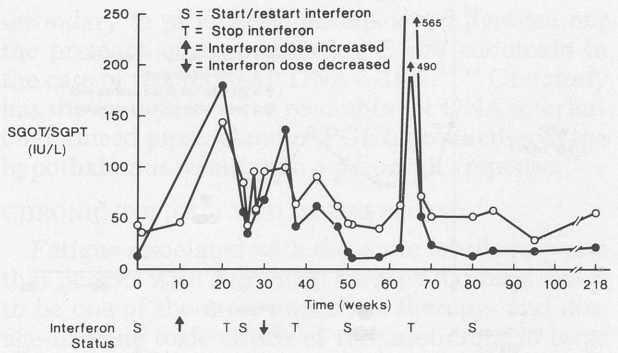

Fig 1. Elevation of SGOT (open circles) and SGPT (closed circles) in response to administration of interferon.

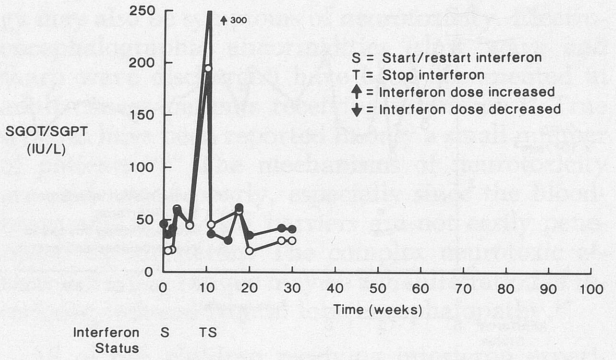

Fig 2. Rapid elevation of SGOT/SGPT in response to interferon administration.

jection of interferon was common, occurring in 24 patients (92%). The febrile reaction occurred for all three types of interferon, typically occurring within 4 to 6 hours of administration, reaching 38°C to 40°C, and lasting 8 to 12 hours if untreated. Elevated temperatures resolved in those patients given acetaminophen. In all cases, the febrile reaction was accompanied by symptoms consistent with a generalized influenza-like syndrome: chills, headache, fatigue, myalgias, and mild nausea. Significant elevation or depression of systolic and diastolic blood pressures was not observed in any of our patients following the initial interferon injections. One patient experienced a severe temperature spike to 41°C, extreme myalgias and lower extremity arthralgias, rigors, and severe nausea and vomiting following the initial interferon injection. The severe reaction persisted following subsequent injections and resolved when the dosage was decreased.

In general, the acute febrile and toxic response to interferon administration persisted with subsequent drug injections, but became less severe and resolved completely in all patients after 10 to 15 weeks. Several patients experienced sporadic febrile responses following interferon injection many months after initiation of therapy. All the patients suffered some degree of fatigue that was highly variable. As the majority of our patients were children, fatigue was manifested as daytime somnolence and various degrees of withdrawal from social interaction with playmates and classmates. Many parents and teachers noted decreased academic performance, although this was not measured objectively.

CHRONIC TOXICITY AND SIDE EFFECTS

Exteme chronic impairment of physical activities and school performance did not occur, and the symptoms of fatigue tended to lessen with time. After several months, the children acquired a tolerance to interferon and returned to normal play and school activity. Parents correlated the difficulty in physical activity and school performance with the frequency of laser microlaryngoscopy procedures rather than the interferon therapy itself.

Three of the authors (R.P.L., B.F.M., J.H.M.; unpublished observations) have evaluated growth rates of ten patients receiving interferon in terms of linear height gain compared to published longitudinal standards[10] for height and weight velocity for North American children. For nine patients, the rate of growth in terms of height velocity during the treatment interval with interferon was significantly less than that predicted from standard growth charts. Following cessation of interferon therapy, the patients' growth in terms of height velocity tended to increase, approaching normal.

ORGAN SYSTEM TOXICITY AND SIDE EFFECTS

Nervous System. Symptomatology consistent with neurotoxicity occurred in two patients. The first patient experienced several episodes of generalized convulsions (grand mal type) within 12 hours of administration of an interferon dose. He had a mild increased temperature (37.5°C) at the time and had been on interferon for the previous 9 months without prior episodes. Twenty-four hours later, he was noted to have an episode of loss of consciousness lasting a few seconds and clonic contractions of the extremities. This was felt to be consistent with a petit mal type seizure. The interferon was stopped and restarted 1 week later. He again experienced several grand mal type seizures 1 week following reinitiation of therapy. This time there was a concomitant fever spike, and the interferon was discontinued again. The patient continued to have severe laryngeal and tracheal disease requiring rescue laryngoscopies on a weekly basis. Carbamazepine in a maintenance dose was administered, and interferon therapy was resumed shortly thereafter. He has continued receiving interferon without further seizure episodes during the past 18 months. The second patient experienced a single brief episode of marked confusion and a grand mal type seizure associated with a febrile response (39.5°C) following interferon administration.

Gastrointestinal-Hepatic System. Mild to moderate nausea was noted in approximately 25% of the patients and was associated with the initial influenza-like syndrome. Significant vomiting was uncommon and required antiemetic medication in

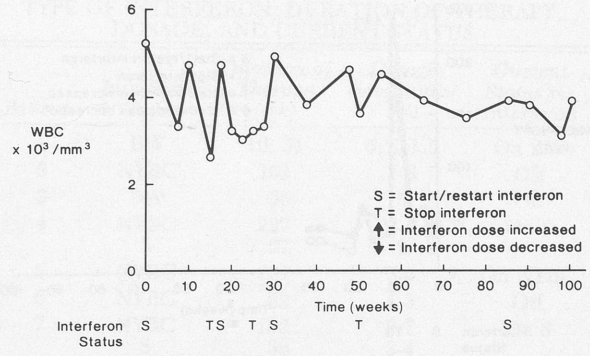

Fig 3. Several rapid leukopenic responses following interferon administration.

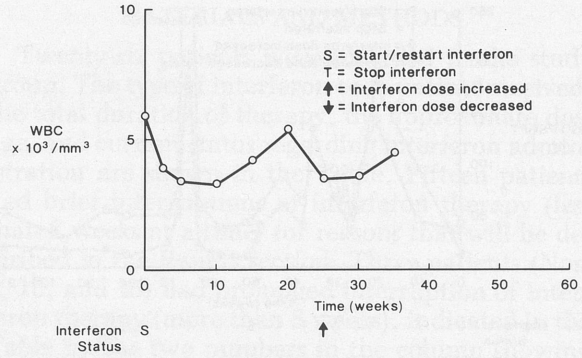

Fig 4. Gradual leukopenic response following interferon administration.

only two patients. Five children experienced anorexia that lasted several months and eventually resolved.

Hepatotoxicity manifesting as elevation of transaminase levels occurred on one or more occasions in 16 patients. Three had elevation of SGPT and SGOT in the 150- to 500-IU/L range (Figs 1 and 2). Three experienced milder elevations in the 100- to 150-IU/L range. The remaining ten patients had one or two sporadic transaminase elevations in the 50- to 100-IU/L range. In general, increase in transaminase levels usually corresponded to the initiation of therapy or an increase in the dosage of interferon and was reversed following rest periods off interferon.

Hematopoietic System. Hematologic effects involving WBCs were noted in five patients. Three experienced rapid leukopenic responses to administration of interferon that required discontinuing therapy for several weeks at a time to allow the WBC count to return to normal (Fig 3). Two additional patients exhibited gradual leukopenic responses over the first 5 to 10 weeks of interferon therapy that tended to plateau and stabilize at a lower total WBC count (Fig 4). A persistent normochromic normocytic anemia was noted in only one case.

One patient experienced rapid thrombocytopenia shortly following administration of interferon requiring three rest periods off therapy to allow the total platelet count to increase (Fig 5). No bleeding problems were noted at any time.

Cutaneous System. Partial alopecia has occurred in two children and has persisted following completion of interferon therapy. Four children experienced tenderness, erythema, and induration at injection sites several hours to days following intramuscular administration. Two patients experienced eruption of maculopapular rashes during the febrile response following initial administration. Persistent dry skin and generalized pruritis occurred in four patients intermittently during their courses of treatment.

DISCUSSION

In general, observed side effects and toxicities were distributed equally among the three different types of interferon used in this study. A special note should be made that it is not the purpose of this paper to make comparisons or draw conclusions concerning drug superiority with respect to toxicity.

ACUTE TOXICITY

The acute febrile response and influenza-like syndrome associated with the initial injections of interferon have been well described in adults with cancer receiving interferon.[11] In the case of adult patients, the febrile response and accompanying symptoms usually disappear within 1 to 2 weeks. This contrasts with our experience with children with recurrent respiratory papillomatosis, whose febrile response tended to persist for 10 to 15 weeks during the initial interferon injections. The one adult patient (No. 16) receiving interferon experienced disappearance of fever at 2 weeks into therapy.

Our experience is in accord with the observations of others[11-13] that all types of interferon induce fever, including highly purified recombinant α-IFN. This suggests that the interferon molecule itself is responsible for the febrile response and associated influenza-like symptoms. The exact mechanism by which interferon produces fever is not well understood. Fever production does not appear to be

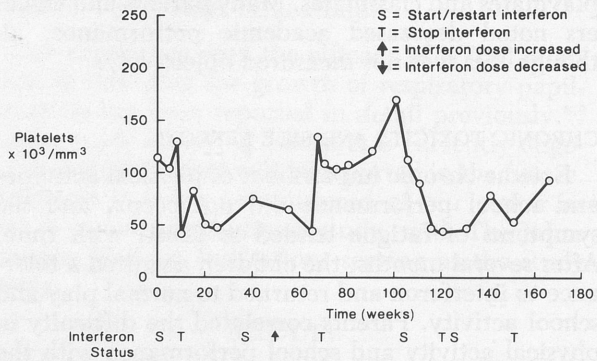

Fig 5. Thrombocytopenia occurring with interferon administration.

secondary to production of leukocytic pyrogen nor the presence of contaminating *E coli* endotoxin in the case of recombinant DNA α-IFN.[12,13] One study has shown evidence for recombinant DNA interferon–induced prostaglandin (PGE2) production in the hypothalamus resulting in a pyrogenic response.[13]

CHRONIC TOXICITY AND SIDE EFFECTS

Fatigue associated with the acute febrile response that persists with continued therapy has been noted to be one of the most important therapy- and dosage-limiting toxic effects of the interferons in large groups of adult patients with cancer.[14,15] Fatigue appears to be dosage-related, and decreased dosages are often necessary to continue therapy. While all of our patients experienced significant fatigue during the initial weeks of interferon therapy, the majority of our children adjusted with time and returned to normal activities for age. This may be due to the relatively smaller interferon dosages administered as set up by the individual protocols, unlike the high dosages (greater than 20 megaunits) often required for adult cancer patients. Recently, we have instructed parents to administer interferon at bedtime or during the evening hours so that the child may sleep through the febrile response. It may be helpful for teachers, counselors, and other professionals who are in contact with children on interferon therapy to be educated about the possible toxic effects of the drug during the first few weeks of therapy.

Short-term weight loss in adult cancer patients receiving interferon has been well documented and is probably secondary to anorexia and other gastrointestinal side effects such as nausea, vomiting, and diarrhea.[16] There is little data available on the effect of interferon on growth in children and adolescents. One study has shown decreased average daily rate of weight gain during the treatment period in four of five infants receiving interferon to treat cytomegalovirus infections.[17] The study of growth in terms of linear height gain in ten children receiving interferon from our institution is retrospective and small with regard to sample size, but does indicate that interferon may have an effect on growth. The apparent growth suppression occurring during the interferon treatment period is an important factor that needs consideration when treating children. Future studies involving interferon should include evaluation of growth in terms of linear height gain in a randomized and prospective manner.

ORGAN SYSTEM TOXICITY AND SIDE EFFECTS

Nervous System. Both specific and nonspecific CNS effects have been noted in adult cancer patients receiving interferon, and a complex neurotoxic syndrome secondary to interferon has been described.[15] The fatigue experienced by patients may be one of the manifestations of the interferon neurotoxicity. Confusion, somnolence, and lethargy may also be symptoms of neurotoxicity. Electroencephalographic abnormalities (slow wave and sharp wave discharges) have been documented in adult cancer patients receiving interferon.[18] True seizures have been reported in only a small number of patients.[14,19] The mechanisms of neurotoxicity are understood poorly, especially since the blood-brain and brain-CSF barriers are not easily penetrated by interferon. The complex neurotoxic effects including fatigue may be a manifestation of interferon-induced frontal lobe encephalopathy.[15]

All of our children receiving interferon experienced fatigue that resolved 1 to 3 months following initiation of therapy. In the patient who experienced grand mal and petit mal type seizures, we cannot state with certainty that this represents a manifestation of interferon neurotoxicity. While his temperature at the time of the initial seizure was elevated only moderately and he had no antecedent or family history of seizure disorders, he had been receiving interferon during the previous 9 months without incident. He did, however, experience a second grand mal seizure after stopping and restarting interferon 1 week later that was associated with an elevated temperature. A high fever, rather than a direct CNS toxicity due to interferon, may explain the confusion and seizure experienced by the second patient.

Gastrointestinal-Hepatic System. Gastrointestinal toxicity manifested as anorexia, nausea, and vomiting usually occurs early in the interferon course and is probably part of the influenza-like syndrome. None of our patients experienced significant diarrhea as described in adult cancer patients[11] receiving interferon.

Hepatotoxicity in the form of elevated transaminase levels has been observed in as high as 80% of patients receiving interferon, depending on the dosage and frequency.[14] The mechanism of interferon hepatotoxicity is understood poorly. Elevation of alkaline phosphatase and lactic dehydrogenase have been observed less frequently. Elevation of transaminase levels can be frightening, especially in children, but our experience has confirmed that reported in adult cancer patients,[11] in that transaminase levels rapidly return to pretreatment levels following rest periods off the drug.

Hematopoietic System. The exact mechanism of suppression of RBC, WBC, and platelet cell lines by interferon is debated and may involve true myelosuppression of myeloid progenitor cells, simple vascular redistribution of circulating leukocytes in the case of WBCs, and immune-mediated thrombocytopenia in the case of platelets.[14,20-22]

Anemia that is normocytic and normochromic and occurs gradually over weeks to months is typical of adult cancer patients, although this was observed in only one of our patients. Leukopenia usu-

ally occurs more rapidly after the first few weeks of interferon administration and tends to plateau and stabilize at a lowered total WBC count with continued therapy. Although an increased propensity for infection has not been observed, we feel interferon therapy should be discontinued if the total WBC count approaches 2,500/mm^3. Recovery is usually brisk following cessation of therapy. Rapid and devastating pancytopenia has been reported in a few patients.[14,20]

Cutaneous System. The mechanism of partial alopecia is unknown. Curiously, excessive growth of eyelashes has been observed in a few patients.[23] The significance of the maculopapular skin eruptions occurring in two patients during the initial febrile response is not clear, and whether or not these eruptions are related to the interferon is not certain.

ORGAN SYSTEM TOXICITIES AND SIDE EFFECTS NOT OBSERVED IN OUR PATIENT GROUP

Tachycardia; atrial and, less commonly, ventricular arrhythmias; congestive heart failure; and myocardial infarction have been reported infrequently in adult cancer patients receiving interferon.[24] In general, most of these patients have been older, and a significant number of them had predisposing cardiac risk factors prior to initiation of therapy. None of these complications were observed in our patients.

Acute renal failure and nephrotic syndrome have been reported in a small number of adult cancer patients receiving interferon.[14] Proteinuria is relatively common (15% to 20%), but is usually mild and transient. None of our patients have exhibited protein in the urine with performance of regular urinalyses. Serial creatinine levels have been normal in all patients studied thus far.

Thyroid dysfunction in the form of hypothyroidism was described recently.[25] Because of this finding, we initiated drawing of thyroid hormone panels as part of the regular workup for our patients receiving interferon. This included the two patients with partial alopecia, which may be a manifestation of hypothyroidism. Thus far, we have found normal levels of thyroid hormone in the 12 patients for whom results have been obtained.

Other objective laboratory abnormalities observed in adult cancer patients receiving interferon and not observed in our study group have included hyperkalemia, hypercalcemia, and decreased blood levels of estrogen, progesterone, and high density lipoproteins.[11] Antibodies to α-IFN have not been detected thus far in patients receiving NYBC interferon or Intron A. Results of antibody studies for patients receiving Wellferon are pending.

SUMMARY

The fact that interferon results in toxicity and side effects involving multiple organ systems is not surprising in light of its extreme range of antiviral, antineoplastic, and immunomodulatory effects. The side effects and toxicities observed in our patients receiving interferon have in general been tolerable, controllable, and reversible. A potential problem with growth in children receiving interferon has been identified, and more studies are needed. Although trials regarding the efficacy of the drug in retarding the growth of papillomas need to be completed, we have demonstrated that interferon has been of benefit to our patients.[8,9] Because the side effects and toxicities are tolerable, the experimental use of interferon to treat patients with recurrent respiratory papillomatosis should continue.

REFERENCES

1. Isaacs A, Lindenmann J. Virus interference. Proc R Soc Lond [Biol] 1957;147:258-67.

2. Krown SE. Interferons and interferon inducers in cancer treatment. Semin Oncol 1986;13:207-17.

3. World Health Organization. International Laboratory for Biological Standards, National Biological Standard Building, London, England.

4. Warren SL. Interferon review and clinical experience. Immunol Allerg Pract 1986;8:115-28.

5. Balmer CM. The new alpha interferons. Drug Intell Clin Pharm 1985;19:887-93.

6. Haglund S, Lundquist P, Cantell K, Strander H. Interferon therapy in juvenile laryngeal papillomatosis. Arch Otolaryngol 1981;107:327-32.

7. Goepfert H, Sessions RB, Gutterman JU, Cangir A, Dichtel WJ, Sulek M. Leukocyte interferon in patients with juvenile laryngeal papillomatosis. Ann Otol Rhinol Laryngol 1982;91:431-6.

8. McCabe BF, Clark KF. Interferon and laryngeal papillomatosis. The Iowa experience. Ann Otol Rhinol Laryngol 1983;92:2-7.

9. Lusk RP, McCabe BF, Mixon JH. Three-year experience of treating recurrent respiratory papilloma with interferon. Ann Otol Rhinol Laryngol 1987;96:158-62.

10. Tanner J, Davies P. Clinical longitudinal standards for height and height velocity for North American children. J Pediatr 1985;107:317-29.

11. Scott GM. The toxic effects of interferon in man. In: Gesser I, ed. Interferon. Vol 5. Orlando, Fla: Academic Press, 1983:86-114.

12. Ackerman SK, Hochstein HD, Zoon K, Browne W, Rivera E, Elisberg B. Interferon fever: absence of human leukocytic pyrogen response to recombinant alpha interferon. J Leukocyte Biol 1984;36:17-25.

13. Dinarello CA, Bernheim HA, Duff GW, et al. Mechanisms of fever induced by recombinant human interferon. J Clin Invest 1984;74:906-13.

14. Quesada JR, Talpaz M, Rios A, Kurzrock R, Gutterman JV. Clinical toxicity of interferons in cancer patients: a review. J Clin Oncol 1986;4:234-43.

15. Adams F, Quesada JR, Gutterman JV. Neuropsychiatric manifestations of human leukocyte interferon therapy in patients with cancer. JAMA 1984;252:938-41.

16. Mayer D, Hetrick K, Riggs C, Sherwin S. Weight loss in patients receiving recombinant leukocyte A interferon (IFLrA): a brief report. Can Nurs 1984(Feb):53-6.

17. Arvin AM, Yeager AS, Merigan TC. Effect of leukocyte interferon in urinary excretion of cytomegalovirus by infants. J Infect Dis 1976;133:A205-10.

18. Suter CC, Westmoreland BF, Sharbrough FW, Hermann RC. Electroencephalographic abnormalities in interferon encephalopathy: a preliminary report. Mayo Clin Proc 1984;59:847-50.

19. Dierckx RA, Michotte A, Schmedding E, Ebinger G, Degeeter T, van Camp B. Unilateral seizures in a patient with hairy cell leukemia treated with interferon. Clin Neurol Neurosurg 1985;87:209-12.

20. Mangan KF, Zidar B, Shadduck RK, Zeigler Z, Winkelstein A. Interferon-induced aplasia: evidence for T-cell-mediated suppression of hematopoiesis and recovery after treatment with horse antihuman thymocyte globulin. Am J Hematol 1985;19: 401-13.

21. Holdener EE, Schnell P, Spieler P, Senn H. In vitro effect of interferon alpha on human granulocyte/macrophage progenitor cells and human clonogenic tumor cells. Recent Results Cancer Res 1984;94:206-19.

22. McLaughlin P, Talpaz M, Quesada JR, Saleem A, Barlogie B, Gutterman JV. Immune thrombocytopenia following alpha-interferon therapy in patients with cancer. JAMA 1985;254: 1353-4.

23. Foon KA, Dougher G. Increased growth of eyelashes in a patient given leukocyte A interferon. N Engl J Med 1984;311: 1259.

24. Oldham R. Toxic effects of interferon. Science 1982;902: 219.

25. Fentiman IS, Thomas BS, Balkwill FR, Rubens RD, Hayward JL. Primary hypothyroidism associated with interferon therapy of breast cancer. Lancet 1985;2:1166.

NASOPHARYNGEAL CARCINOMA: THE DANA-FARBER CANCER INSTITUTE EXPERIENCE WITH 24 PATIENTS TREATED WITH INDUCTION CHEMOTHERAPY AND RADIOTHERAPY

JOHN R. CLARK, MD
BARBARA G. FALLON, MD
JOHN T. CHAFFEY, MD
CHARLES M. NORRIS, JR, MD
KAROLY BALOGH, MD
JANET W. ANDERSEN, MS
ARNON I. DREYFUSS, MD
ROGER F. ANDERSON, JR, MD
DANIEL MILLER, MD
BOSTON, MASSACHUSETTS

Nasopharyngeal carcinoma traditionally has been treated with radiotherapy alone. Although the probability of cure for patients with stage I and II nasopharyngeal carcinoma is high, the probability of cure for patients with stage III and IV disease is poor because of a higher rate of local-regional and distant failure. Between February 1981 and August 1986, 24 patients with previously untreated, stage IV nasopharyngeal carcinoma were treated with two to four monthly courses of cisplatin-based combination chemotherapy prior to radiotherapy. A response to induction chemotherapy was recorded in 75% of patients (29% complete response and 46% partial) prior to radiotherapy. By actuarial estimate with a median follow-up of 42 months, the 2-year failure-free survival for all patients was 57%. In conclusion, induction chemotherapy has significant activity in nasopharyngeal carcinoma. The toxicity of this approach, as well as the influence of initial histopathology and response to chemotherapy on survival, will be discussed.

KEY WORDS — chemotherapy, nasopharyngeal carcinoma, radiotherapy.

INTRODUCTION

The role of induction chemotherapy in the multidisciplinary treatment of patients with advanced squamous cell carcinoma of the head and neck (SCCHN) remains controversial. Numerous uncontrolled studies have reported high response rates to combination chemotherapy prior to local treatment, an association between a response to induction chemotherapy and survival after local treatment, and most importantly, an improved survival compared with historical controls.[1-8] Unfortunately, a survival advantage was not associated with the use of induction combination chemotherapy in any of the five published randomized trials that contained a control group of patients treated with conventional surgery or radiotherapy alone.[9-13] Although the results from these randomized trials may have been compromised by the frequent use of combination chemotherapy of a limited duration (≤ 4 weeks in three of five studies), inadequate patient accrual, or suboptimal local treatment, the use of chemotherapy prior to surgery or radiotherapy remains an investigational treatment modality of uncertain benefit.

Several recent reviews have critically analyzed the use of chemotherapy in the multidisciplinary treatment of patients with advanced SCCHN and provided direction for future research activities.[14,15] Continued progress in the medical treatment of SCCHN awaits the creation of more active regimens of induction chemotherapy and an increase in the rate of complete response (CR) to systemic treatment, clarification of the extent of local treatment required for adequate local-regional control after a response to chemotherapy, knowledge of which patient subgroups have the most to gain from multidisciplinary treatment with chemotherapy, and ultimately a new generation of randomized trials using a control group of conventionally treated patients.

To this end, several studies of induction chemotherapy for patients with advanced SCCHN have evaluated the impact of primary tumor site on response to chemotherapy or survival. Three studies of patients with advanced but potentially curable (M0) SCCHN have recently suggested that patients with nasopharyngeal tumors have a high rate of response to induction chemotherapy and an improved survival in comparison with patients whose primary tumors arose from other head and neck sites.[8,16,17] This observation provided the stimulus for an analysis of the Dana-Farber Cancer Institute's experience with induction chemotherapy and radiotherapy in the treatment of advanced nasopharyngeal tumors. The objectives of this analysis

TABLE 1. STAGING DIAGRAM FOR 24 PATIENTS

	N0	*N1*	*N2*	*N3*
T1	—	—	3	3
T2	—	—	4	1
T3	—	—	1	2
T4	1	2	5	2

From the Divisions of Medicine (Clark, Dreyfuss, Fallon) and Biostatistics (Andersen), Dana-Farber Cancer Institute; the Departments of Surgery (Norris, Miller) and Pathology (Balogh), New England Deaconess Hospital; and the Joint Center for Radiation Therapy (Andersen, Chaffey), Harvard Medical School, Boston. This work was supported by an American Cancer Society Clinical Oncology Career Development Award.

Presented at the meeting of the American Laryngological Association, Denver, April 25-26, 1987.

REPRINTS — John Ross Clark, MD, Dana-Farber Cancer Institute, 44 Binney St, Boston, MA 02115.

TABLE 2. PATIENT CHARACTERISTICS

	Total	Primary Tumor Histology		
		Group 1	Group 2	Group 3
Patients	24	11	6	7
Male:female	19:5	6:5	6:0	7:0
Median age (range)	56 (9-73)	57 (9-73)	43 (12-48)	59 (47-69)
T stage				
T1, 2	11	5	1	5
T3, 4	13	6	5	2
N stage				
N0, 1	3	1	2	—
N2, 3	21	10	4	7

were to define the rate of antitumor response to induction combination chemotherapy and survival after local treatment, and to determine the impact of T stage, N stage, and pretreatment histologic differentiation on treatment outcome.

METHODS

Between February 1981 and August 1986, 180 patients with advanced, previously untreated, stage III and IV SCCHN were entered into one of three Dana-Farber protocol studies of induction chemotherapy followed by conventional surgery or radiotherapy. All 180 patients had histologically confirmed carcinomas of epithelial origin and were evaluable for response, toxicity, or survival. Patients with multiple primary carcinomas or distant metastases at presentation were excluded from these studies, as were patients whose tumors represented a second primary carcinoma.

From these 180 patients, 24 (13%) with carcinomas of nasopharyngeal origin were identified (Tables 1 and 2). All 24 patients had stage IV disease at presentation as defined by criteria of the American Joint Committee for Cancer Staging.[18] Of the 24 patients, 13 were enrolled in protocol A, seven in protocol B, and four in protocol C (Table 3). All patients had a pretreatment performance status of 0 to 2, adequate renal function with a creatinine clearance of ≥ 50 mL/min, a leukocyte count of $\geq 4{,}000/mm^3$, and a platelet count of $\geq 100{,}000/m^3$. Patients who received bleomycin as part of their induction treatment in protocols A or B underwent monthly pulmonary function testing while on therapy to ensure a total lung capacity and residual volume greater than 60% of normal and a carbon monoxide diffusion capacity at least 55% of normal.

All patients were evaluated prior to study entry for initial staging and treatment planning by a surgeon, a radiotherapist, and a medical oncologist in a multidisciplinary clinic. Written informed consent was obtained and treatment begun with one of the three combinations of induction chemotherapy according to the schedules shown in Table 3. Cisplatin was administered as intermittent intravenous boluses in protocols A and B, and by 24-hour continuous infusion in protocol C. Three liters of normal saline were administered daily as hydration, either in split doses before and after cisplatin (protocols A and B), or as a 24-hour continuous infusion (protocol C). Bleomycin and 5-fluorouracil were administered as 24-hour continuous infusions at the doses shown for 5 consecutive days. Midcycle methotrexate with oral calcium leucovorin rescue was delivered in protocols A and C. Standard antiemetic regimens were prescribed for prophylactic control of nausea and vomiting.

The patient population consisted of 19 male (79%) and five female (21%) patients (Table 2). Only two patients were of Asian ancestry. Patient age ranged from 9 years to 73 years, with a median age of 56 years. Pretreatment primary tumor biopsy specimens were reviewed retrospectively by a panel of three pathologists and classified according to the recommendations of the World Health Organization.[19] Histologically, 11 lesions (46%) represented undifferentiated carcinomas of nasopharyngeal type including lymphoepitheliomas (group 1), six (25%) were nonkeratinizing epithelial carcinomas (group 2), and seven (29%) were keratinizing squamous cell carcinomas (group 3). The T-stage and N-stage characteristics of the 24 study patients are recorded in Table 2 before and after stratification into these three histologic groups.

Patients were reevaluated monthly during treatment. At the end of induction chemotherapy, responses were quantified by clinical and radiographic examinations. Epstein-Barr viral antigen titers

TABLE 3. CHEMOTHERAPY SCHEDULE

	Protocol A (2 Courses)	Protocol B (2-4 Courses)		Protocol C (2-4 Courses)
Patients	13	7 (randomized trial)		4
		3 patients	4 patients	
Cisplatin	20 mg/m²/d IVB d 1-5	Same as protocol A	20 mg/m²/d IVB d 1-6	25 mg/m²/d 24-h infusion, d 1-5
Bleomycin	10 mg/m²/d 24-h infusion, d 3-7			
5-Fluorouracil			1,000 mg/m²/d 24-h infusion, d 2-6	800 mg/m²/d 24-h infusion, d 1-5
Methotrexate	200 mg/m² IVB d 15, 22			200 mg/m² IVB d 15, 22
Leucovorin	20 mg po q6h d 16-18, 23-25			20 mg po q6h d 16-18, 23-25

IVB — by intravenous bolus, po — orally.

TABLE 4. RESPONSE TO INDUCTION CHEMOTHERAPY

Histologic Group	*Patients*	*CR (%)*	*PR*	*NR*
Group 1	11	5 (45)	3	3*
Group 2	6	1 (17)	4	1
Group 3	7	1 (14)	4	2
Total	24	7 (29)	11	6*

CR — complete response, PR — partial response, NR — no response.
*Includes one death during induction chemotherapy.

were not routinely assessed. Primary site and lymph node responses to chemotherapy were scored separately. A patient's overall response to chemotherapy was determined by the least-responding tumor site — primary or lymph node. A CR was defined as the disappearance of all clinically or radiographically evident tumor. A partial response (PR) was defined as a >50% reduction in the product of two perpendicular diameters of all measurable tumor — primary or nodal. No response (NR) was defined as any response less than PR, stable disease, or progression of disease while on chemotherapy.

Local treatment consisted of radiotherapy with additional neck dissections in four patients. Radiotherapy was administered to fields that were determined by the extent of disease prior to chemotherapy. A tumor dose of at least 60 Gy/30 fractions/6 wk was planned to cover the nasopharynx and upper neck in all patients, with appropriate spinal cord shielding. Small additional fields of external beam radiotherapy or local implants (three patients) were used to provide an additional 5 to 10 Gy to the primary tumor or to residual areas of disease in the neck. Patients without palpable disease in the neck generally received 4.5 to 5.5 Gy in 5 weeks to this region. Radiotherapy was administered with cobalt 60 or linear accelerator beams, sometimes supplemented with electron beam therapy to superficial sites. A radical neck dissection was performed after radiotherapy in three patients with localized residual neck disease. A fourth patient received a radical neck dissection after radiotherapy for management of a neck that had been violated prior to treatment with a diagnostic lymph node excision.

TABLE 5. PRIMARY SITE (T STAGE) AND LYMPH NODE (N STAGE) RESPONSES TO CHEMOTHERAPY

Stage	*Patients*	*CR (%)*	*PR*	*NR*
T1	6	5 (83)	1	—
T2	5	2 (40)	2	1
T3	3	1 (33)	2	—
T4	10	3 (30)	4	3*
Total	24	11 (46)	9	4*
N1	2	2 (100)	—	—
N2	12†	6 (46)	4	2*
N3	8	2 (25)	4	2
Total	22	10 (45)	8	4*

CR — complete response, PR — partial response, NR — no response.
*Includes one death during induction chemotherapy.
†Excludes one patient who received diagnostic excision of N2a lymph node prior to therapy.

TABLE 6. EFFECT OF RESPONSE TO INDUCTION CHEMOTHERAPY AND HISTOLOGIC GROUP ON LOCAL-REGIONAL CONTROL OF DISEASE AND SURVIVAL

	Patients	*NED After Local Treatment*	*Total Failure LR/Distant*	*Alive NED*
Response				
CR	7	7	1/0	5*
PR	10	8	3/1	6
NR	5	2	2/2	1
Histologic group				
1	9	8	1/2	5
2	6	5	2/0	4
3	7	4	3/1	3
Total	22	17	6/3	12

NED — no evidence of disease, LR — local-regional.
*Excludes one death due to ovarian cancer while NED for nasopharyngeal carcinoma.

RESULTS

Of the 24 patients, a complete remission with induction chemotherapy alone was achieved with seven patients (29%) and a partial remission in 11 patients (46%)) for a total response rate of 75% (Table 4). The CR rate for patients with undifferentiated tumors was 45% (five of 11 patients), which was greater than the CR rates for patients with nonkeratinizing epidermoid tumors (17% CR) or keratinizing squamous tumors (14% CR); however, the observed difference in the incidence of CR between histologic groups was not significant ($p = .18$, Fisher Exact Test).

The influence of primary tumor size or extent of regional adenopathy on response to chemotherapy is shown in Table 5. As noted, a primary site CR to induction chemotherapy was noted in 83% of patients with T1 primary lesions, but in only 30% of patients with T4 lesions ($p = .04$, Wilcoxon Mid-Rank Test). A similar trend in the rate of CR was apparent in the 22 patients with measurable regional adenopathy ($p = .06$, Wilcoxon Mid-Rank Test).

Twenty-two of the 24 patients treated with chemotherapy completed local treatment and were evaluable for an analysis of local-regional control of disease and failure. Table 6 records these data with a median follow-up of 3½ years from study entry (range, 6 months to 7 years 1 month). Seventeen of the 22 patients (77%) were disease-free after local treatment. Upon stratification by response to induction chemotherapy, a significant difference was apparent in the proportion of patients who were disease-free after local treatment ($p = .02$, Wilcoxon Mid-Rank Test). Eighty-eight percent (15 of 17) of patients with a response to induction chemotherapy were disease-free after local treatment, whereas only 40% of patients (two of five) with no response to initial chemotherapy achieved a similar disease-free state. To date, nine of the 22 patients who completed local treatment have had either recurrent disease or progression of persistent disease (three

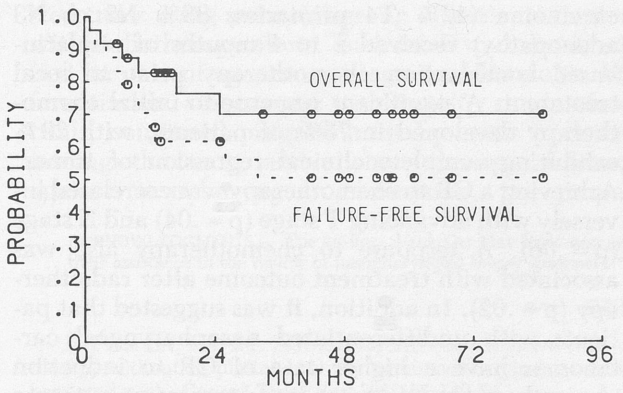

Fig 1. Overall and failure-free survival by actuarial estimate for 24 study patients. Eighteen patients remain alive (2-yr survival, 71%). Thirteen patients remain failure-free (2-yr survival, 57%).

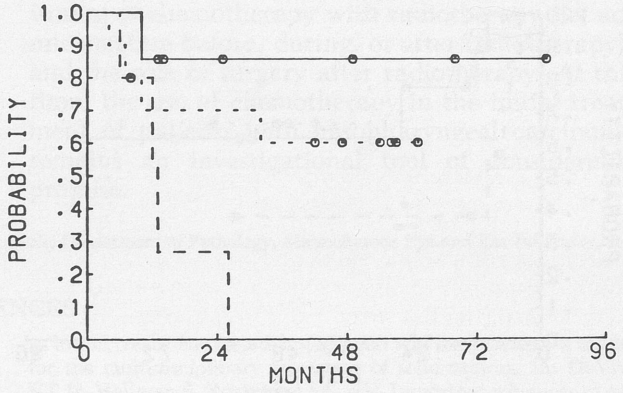

Fig 2. Failure-free survival by response to induction chemotherapy for 22 patients who completed local treatment. Complete response (solid line), six of seven patients remain failure-free; partial response (short-dashed line), six of ten patients remain failure-free; no response (long-dashed line), one of five patients remain failure-free.

local, three regional, three distant relapses). Considering only the 17 patients who were disease-free after local treatment, four (24%) have developed recurrent disease, including one of seven patients with a complete response to induction chemotherapy (local relapse), two of eight patients with a partial response (local and distant relapse), and one of two patients with no response to initial chemotherapy (distant relapse). Upon stratification by histologic group, eight of nine evaluable patients (89%) with undifferentiated nasopharyngeal tumors were disease-free after local treatment, whereas only four of seven patients (57%) with keratinizing squamous tumors were disease-free after local treatment; but this difference was not statistically significant.

Salvage treatment with curative intent was offered to three patients who relapsed after disease-free intervals of 10 months, 10 months, and 2 years 4 months, respectively. One local recurrence was controlled for 2 months with 30 Gy radiotherapy by an intracavitary cesium implant. An upper neck recurrence was resected, leaving close margins at the base of the skull. This patient remains clinically disease-free 5 months after surgery, but is considered alive with disease. The third recurrence involved the upper neck with extension to the lateral oropharyngeal wall and the base of the skull. This recurrence was unresectable and managed with sequential chemotherapy and 20 Gy external beam and 50 Gy ^{198}Au seed implant radiotherapy, which led to partial tumor regression. The latter patient remains alive with regional disease 2 years 3 months after relapse.

Actuarial estimates of survival for all 24 patients have been calculated using the technique of Kaplan and Meier (Fig 1).[20] At present, 18 of 24 patients (75%) are alive, although six are alive with recurrent or persistent disease. The overall survival by actuarial estimate 2 years from study entry is 71%. Given the number of patients who are alive with disease and their relatively short follow-up, failure-free survival may be a more appropriate estimate of treatment outcome. By actuarial estimate, the 2-year failure-free survival is 57%, with no relapses noted in the nine patients remaining failure-free after 2 years 4 months.

Failure-free survival for the 22 patients who completed local treatment was considered separately. Upon stratification by response to induction chemotherapy (Fig 2) or histologic group (Fig 3), trends were apparent suggesting improved survival for those patients with a response to induction chemotherapy or a tumor of the undifferentiated or nonkeratinizing type.

The toxicity of this approach was generally acceptable, with mild to moderate nausea in most patients that was effectively controlled with prophylactic antiemetic medications. No significant renal, bone marrow, or respiratory toxicities to chemotherapy developed during this study. Mild, transient, drug-induced mucositis was recorded in two of eight patients treated with 5-fluorouracil chemotherapy combinations. One death during treatment occurred in a patient receiving protocol A chemotherapy. This patient died of an outpatient myocardial infarction in the setting of normal blood counts 1 week following hospital discharge from the first inpatient cycle of chemotherapy. Twenty-two of 24 patients completed radiotherapy, excluding the one patient who died during induction chemotherapy and one patient who refused local treatment. Radiation-associated toxicity consisted of mild to moderate mucositis in most patients and severe mucositis in four patients that was managed with brief (1 week) radiation treatment breaks. One patient with T4N3b disease and multiple cranial neuropathies at presentation did not respond to induction chemotherapy and developed severe weight loss and inanition during treatment. Despite minimal mucositis, this patient required multiple treatment breaks during a 10-week course of radiotherapy and was never disease-free. No surgical compli-

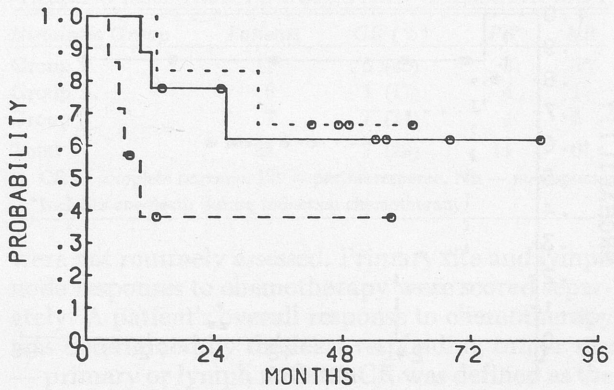

Fig 3. Failure-free survival by histologic group for 22 patients who completed local treatment. Group 1 (solid line), six of nine patients remain failure-free; group 2 (short-dashed line), four of six patients remain failure-free; group 3 (long-dashed line), three of seven patients remain failure-free.

cations developed in the four patients who underwent planned neck dissections after radiotherapy.

DISCUSSION

Nasopharyngeal carcinoma is a relatively uncommon malignancy in North America that is characterized by an epidemiologic association with Epstein-Barr viral infection[21-27] and a remarkable tendency for early regional and distant metastatic spread.[28-31] The traditional treatment for this disease has been radiotherapy alone because of a reported sensitivity to radiotherapy and the technical inability to resect either primary site disease or contiguous lymph node chains. While the probability of cure for patients with stage I and II nasopharyngeal cancer is high, the probability of cure for patients with stage III and IV (M0) disease is poor because of a higher rate of local-regional and distant failure. From large series of Chinese patients with advanced nasopharyngeal carcinoma (non-AJC stage III and IV), the 5- and 10-year survival rates are 10% to 45% and 0% to 30%, respectively.[24,32-35] The North American experience with nasopharyngeal carcinoma is more limited, but a 2-year survival of only 35% to 50% has been reported for patients with advanced disease.[36-40] While local-regional relapse remains the principal cause of treatment failure and death, the incidence of clinically significant distant metastases is 20% to 40%[28-30,34,35] and is thus higher than the incidence of distant metastases from squamous cell carcinomas originating in other head and neck sites.

The use of chemotherapy prior to the local treatment of advanced nasopharyngeal carcinomas represents an investigative approach that offers the potential of initial macroscopic tumor reduction and enhancement of local-regional control by subsequent radiotherapy, as well as the early systemic treatment of microscopic metastatic disease. In this study, 24 patients with stage IV nasopharyngeal carcinoma (42% T4 primaries, 88% N2 or N3 adenopathy) received 2 to 4 months of cisplatin-based combination chemotherapy prior to local treatment. A significant response to initial chemotherapy developed in 75% of patients, with 29% exhibiting complete clinical regression of tumor. Achieving a CR to chemotherapy was correlated inversely with advancing T stage ($p = .04$) and N stage ($p = .06$). A response to chemotherapy also was associated with treatment outcome after radiotherapy ($p = .02$). In addition, it was suggested that patients with undifferentiated nasopharyngeal carcinomas have a higher rate of CR to induction chemotherapy and an improved treatment outcome when compared to patients with keratinizing nasopharyngeal carcinomas. The apparent sensitivity of nasopharyngeal carcinomas to chemotherapy has been published previously.[41-43] The data in this report, however, represent the first evidence that histologic differentiation of nasopharyngeal carcinomas influences response to chemotherapy.

Several of these findings parallel those from studies of induction chemotherapy for previously untreated, advanced carcinomas of other head and neck sites. In these studies, CR rates of 20% to 50% have been recorded and correlated with pretreatment tumor extent and survival after local treatment;[2,5,7,8,10,44] however, a response to induction chemotherapy may not be associated with an improved survival independent of other prognostic factors such as T stage and N stage. A multivariate analysis can evaluate this problem, and when performed, such an analysis has shown that a response to chemotherapy is associated with an improved survival independent of initial tumor volume.[8] The number of patients in the present study was too small to perform such an analysis.

The principal question is whether the use of induction chemotherapy for patients with nasopharyngeal carcinoma leads to an improved survival compared to that achieved with radiotherapy alone. Certainly the 2-year failure-free survival of 57% noted in this series of patients with stage IV disease compares favorably with the cited North American experience. The value of comparisons with historical controls from other institutions is limited, however, given frequent differences in patient composition, tumor histology, methods of pretreatment staging, and local treatment. The use of historical controls within a single institution lessens these differences, and when used, two studies suggested an improved survival with chemotherapy,[45,46] whereas a third study[47] did not report a survival advantage with chemotherapy in the initial treatment of patients with advanced nasopharyngeal carcinoma.

The role of chemotherapy in the management of patients with nasopharyngeal carcinoma will ultimately be defined by large, prospective, random-

ized trials using a control group of patients treated with radiotherapy alone. Such trials must be stratified for patient age, tumor stage, and histologic differentiation. Concurrent with ongoing randomized trials, continued progress must be made in determining the most active chemotherapy regimen against nasopharyngeal carcinomas, the proper timing of chemotherapy with radiotherapy (ie, administration before, during, or after radiotherapy), and the role of surgery after radiotherapy. At this time, the use of chemotherapy in the initial treatment of patients with nasopharyngeal carcinoma remains an investigational tool of considerable promise.

ACKNOWLEDGMENTS — The authors thank Drs Max Goodman and Ben Pilch, Department of Pathology, Massachusetts Eye and Ear Infirmary, for their assistance in the review of nasopharyngeal biopsy specimens.

REFERENCES

1. Price LA, Hill BT. Safe and effective combination chemotherapy without cis-platinum for squamous cell carcinomas of the head and neck. Cancer Treat Rep 1981;65:149-54.

2. Pennacchio JL, Hong WK, Shapshay S, et al. Combination of cis-platinum and bleomycin prior to surgery and/or radiotherapy compared with radiotherapy alone for the treatment of advanced squamous cell carcinoma of the head and neck. Cancer 1982;50:2795-801.

3. Weaver A, Flemming S, Kish J, et al. Cis-platinum and 5-fluorouracil as induction therapy for advanced head and neck cancer. Am J Surg 1982;144:445-8.

4. Spaulding MB, Kahn A, De Los Santos R, Klotch D, Loré JM Jr. Adjuvant chemotherapy in advanced head and neck cancer: an update. Cancer Treat Rep 1982;144:432-6.

5. Hill BT, Price LA, Busby E, Macrae K, Shaw HJ. Positive impact of initial 24-hour combination chemotherapy without cisplatinum on 6-year survival figures in advanced squamous cell carcinomas of the head and neck. In: Jones SE, Salmon SE, eds. Adjuvant therapy of cancer IV. Orlando, Fla: Grune & Stratton, 1984:97-106.

6. Amrein PC, Weitzman SA. Treatment of squamous cell carcinoma of the head and neck with cisplatin and 5-fluorouracil. J Clin Oncol 1985;3:1632-9.

7. Rooney M, Kish J, Jacobs J, et al. Improved complete response rate and survival in advanced head and neck cancer after three-course induction therapy with 120-hour 5-FU infusion and cisplatin. Cancer 1985;55:1123-8.

8. Ervin TJ, Clark JC, Weichselbaum RR, et al. An analysis of induction and adjuvant chemotherapy in the multidisciplinary treatment of squamous-cell carcinoma of the head and neck. J Clin Oncol 1987;5:10-20.

9. Stell PM, Dalby JE, Strickland P, et al. Sequential chemotherapy and radiotherapy in advanced head and neck cancer. Clin Radiol 1983;34:463-7.

10. Jacobs C, Wolf GT, Makuch RW, Vikram B. Adjuvant chemotherapy for head and neck squamous carcinomas [Abstract]. Proc Am Soc Clin Oncol 1984;3:182.

11. Schuller DE, Wilson H, Hodgson S, Mattox D. Preoperative reductive chemotherapy for stage III or IV operative epidermoid carcinoma of the oral cavity, oropharynx, hypopharynx, or larynx, Phase III. A Southwest Oncology Group study [Abstract 185]. Presented at the International Conference on Head and Neck Cancer, Baltimore, July 1984.

12. Holoye PY, Grossman TW, Toohill RJ, et al. Randomized study of adjuvant chemotherapy for head and neck. Otolaryngol Head Neck Surg 1985;93:712-7.

13. Haas C, Byhardt R, Cox J, et al. Randomized study of 5-fluorouracil and cis-platinum as initial therapy of locally advanced squamous carcinoma of the head and neck [Abstract]. Proc Am Soc Clin Oncol 1983;4:143.

14. Tannock IF, Browman G. Lack of evidence for a role of chemotherapy in the routine management of locally advanced head and neck cancer. J Clin Oncol 1986;4:1121-6.

15. Clark JC, Fallon BG, Frei E III. Induction chemotherapy as initial treatment for advanced head and neck cancer: a model for the multidisciplinary treatment of solid tumors. In: DeVita VT Jr, Hellman S, Rosenberg SA, eds. Important advances in oncology. Philadelphia: JB Lippincott, 1987:175-95.

16. Price LA, Hill BT. Safe and effective 24 hour combination chemotherapy without cisplatin as initial treatment in head and neck cancer: improved survival at 5 years [Abstract]. Proc Am Soc Clin Oncol 1982;1:202.

17. Kuten A, Zidan G, Cohen Y, Robinson E. Progress report on the treatment of advanced squamous cancer of the head and neck by bleomycin, methotrexate and cisplatin (BMP) followed by radiotherapy: superior survival in complete responders and in nasopharyngeal carcinoma [Abstract]. Proc Am Soc Clin Oncol 1986;5:491.

18. American Joint Committee for Cancer Staging and End-Results Reporting. Manual for Staging of Cancer 1978. Chicago: AJC, 1978.

19. Shanmugaratnam K, Sobin L. Histological typing of upper respiratory tract tumors. In: International histological typing of tumors. Vol 19. Geneva: World Health Organization, 1978:32-7.

20. Kaplan EL, Meier P. Nonparametric estimation from incomplete observations. J Am Stat Assoc 1958;53:457-81.

21. Lin TM, Yang CS, Chiou JF, et al. Seroepidemiological studies on carcinoma of the nasopharynx. Cancer Res 1973;33:2603-8.

22. Schryver AD, Klein G, Henle W, Henle G. EB virus-associated antibodies in caucasian patients with carcinoma of the nasopharynx and in long-term survivors after treatment. Int J Cancer 1974;13:319-25.

23. Miller D. The etiology of nasopharyngeal cancer and its management. Otolaryngol Clin North Am 1980;13:467-75.

24. Shanmugaratnam K, Chan SH, De-The G, et al. Histopathology of nasopharyngeal carcinoma: correlations with epidemiology, survival rates and other biological characteristics. Cancer 1979;44:1029-44.

25. Sprinkle PM, Veltri RW. Epstein-Barr virus infection and neoplasia. Otolaryngol Head Neck Surg 1981;89:542-4.

26. Naegele RF, Champion J, Murphy S, Henle G, Henle W. Nasopharyngeal carcinoma in American children: Epstein-Barr virus-specific antibody titers and prognosis. Int J Cancer 1982;29:209-12.

27. Fedder M, Gonzalez MF. Nasopharyngeal carcinoma: brief review. Am J Med 1985;79:365-9.

28. Meyer JE, Wang CC. Carcinoma of the nasopharynx: factors influencing results of therapy. Radiology 1971;100:385-8.

29. Hoppe RT, Williams J, Warnke R, Goffinet DR, Bagshaw MA. Carcinoma of the nasopharynx — the significance of histology. Int J Radiat Oncol Biol Phys 1978;4:199-205.

30. Applebaum EL, Mantravadi P, Haas R. Lymphoepithelioma of the nasopharynx. Laryngoscope 1982;92:510-4.

31. Vikram B, Mishra UB, Strong EW, Manolatos S. Patterns of failure in carcinoma of the nasopharynx: failure at distant sites. Head Neck Surg 1986;8:276-9.

32. Ho JHC. An epidemiologic and clinical study of nasopharyngeal carcinoma. Int J Radiat Oncol Biol Phys 1978;4:183-98.

33. Huang SC. Nasopharyngeal cancer: a review of 1605 patients treated radically with cobalt 60. Int J Radiat Oncol Biol Phys 1980;6:401-7.

34. Huang SC, Chu GL. Nasopharyngeal cancer: study II. Int J Radiat Oncol Biol Phys 1981;7:713-6.

35. Hsu MM, Tu SM. Nasopharyngeal carcinoma in Taiwan: clinical manifestations and results of therapy. Cancer 1983;52: 362-8.

36. Bedwinek JM, Perez CA, Keys DJ. Analysis of failures after definitive irradiation for epidermoid carcinoma of the nasopharynx. Cancer 1980;45:2725-9.

37. Petrovich Z, Kuisk H, Jose L, Barton RT. Advanced carcinoma of the nasopharynx: treatment results. Acta Radiol [Oncol] 1981;20:245-51.

38. Mesic JB, Fletcher GH, Goepfert H. Megavoltage irradiation of epithelial tumors of the nasopharynx. Int J Radiat Oncol Biol Phys 1981;7:447-53.

39. Baker SR, Wolfe RA. Prognostic factors of nasopharyngeal malignancy. Cancer 1982;49:163-9.

40. Petrovich Z, Cox JD, Roswit B, et al. Advanced carcinoma of the nasopharynx. Radiology 1982;144:905-8.

41. Holoye PY, Byers RM, Gard DA, Goepfert H, Guillamondegui OM, Jesse RH. Combination chemotherapy of head and neck cancer. Cancer 1978;42:1661-9.

42. Galligioni E, Carbone A, Tirelli U, et al. Combined chemotherapy with doxorubicin, bleomycin, vinblastine, dacarbazine, and radiotherapy for advanced lymphoepithelioma. Cancer Treat Rep 1982;66:1207-10.

43. Decker DA, Drelichman A, Al-Sarraf M, Crissman J, Reed ML. Chemotherapy for nasopharyngeal carcinoma: a ten-year experience. Cancer 1983;52:602-5.

44. Jacobs C, Goffinet D, Fee W, Goffinet L, Hopp M. Chemotherapy as a substitute for surgery in the treatment of advanced operable head and neck cancer: an NCOG pilot [Abstract]. Proc Am Soc Clin Oncol 1985;4:137.

45. Chatani M, Teshima T, Inoue T, et al. Radiation therapy for nasopharyngeal carcinoma: retrospective review of 105 patients based on a survey of Kansai Cancer Therapist Group. Cancer 1986;57:2267-71.

46. Rahima M, Rakowsky E, Barzilay J, Sidi J. Carcinoma of the nasopharynx: an analysis of 91 cases and a comparison of differing treatment approaches. Cancer 1986;58:843-9.

47. Tannock I, Payne D, Cummings B, Hewitt K, Panzarella T, The Princess Margaret Hospital Head and Neck Cancer Group. Sequential chemotherapy and radiation for nasopharyngeal cancer: absence of long-term benefit despite a high rate of tumor response to chemotherapy. J Clin Oncol 1987;5:629-34.

TECHNIQUE FOR EXTERNAL REPOSITIONING OF THE PARALYZED VOCAL CORD WITH SILASTIC IMPLANT

J. RAMÓN ESCAJADILLO, MD

IMPERIAL BEACH, CALIFORNIA

A technique is introduced for vocal cord mobilization in which a tunnel is made through the inner perichondrium of the thyroid cartilage and a medical grade silicone is placed from the upper part of the thyroid cartilage and pulled out over the cricothyroid membrane. This technique was performed on six dogs, and results were compared to those of a modified laryngoplasty performed on another six dogs. The technique was refined on 20 cadavers and finally performed on five adult patients with more than 1 year of vocal cord paralysis. Results of this technique suggest that it constitutes a good alternative to Teflon injection; morbidity was minimal.

KEY WORDS — Silastic implant, vocal cord paralysis.

INTRODUCTION

Phonosurgery is a growing subspeciality in otolaryngology–head and neck surgery and involves a great number of applications, such as voice rehabilitation after ablative surgery of the larynx, management of the flaccid larynx, treatment for atrophy of the vocal cords, surgery for modification of vocal pitch, and treatment for vocal cord paralysis.

Until now, there have been several alternatives for the treatment of symptomatic vocal cord paralysis.[1-8] In 1915, Payr[9] used a tilted U-shaped incision on the thyroid ala to make a pedicled cartilage flap, which was depressed inward in order to shift the vocal cord medially. This constituted the first attempt at external mobilization of the vocal cord. In 1952, Meurman[10] used a cartilage implant taken from the costal rib and inserted between the thyroid cartilage (TC) and the inner perichondrium. In 1955, Opheim[11] used an incised segment of the TC, which was inserted into the inner perichondrium at the level of the vocal cord. This produced severe postoperative edema, which required tracheotomy. In 1968, Sawashima et al[12] inserted an incised segment of TC between the thyroid ala and inner perichondrium, with excellent results for the voice.

Isshiki et al[13,14] reported a thyroplasty for dysphonia due to vocal cord paralysis or atrophy as an alternative to intracordal Teflon injection, which is the most frequently performed procedure. Their technique consists of a rectangular incision over the thyroid ala, approximately 10 x 3 mm, the upper margin of which should be at the level of the vocal cord. A wedge of TC is inserted between the rectangular fragment and the remaining frame of the TC to enhance the compression effect on the vocal cord.

In 1986, Koufman[15] reported a modification of the medialization laryngoplasty of Isshiki et al that involves using a Silastic implant, which is custom fitted for each patient in order to obtain the best possible functional results. The present paper discusses Koufman's modified procedure and introduces another technique for vocal cord medialization, in which an incision over the external perichondrium of the medial upper part of the TC is performed and, as in a septoplasty, a tunnel is made through the inner perichondrium until the cricothyroid membrane is reached. A medical grade silicone is placed on the superior part of the TC and pulled out over the cricothyroid membrane. We report our results in dogs, cadaver specimens, and five patients, and compare this technique with Koufman's.

MATERIAL AND METHODS

Twelve adult mongrel dogs were used for the experiment. The dogs were divided into two groups. In the first experiment, five dogs were anesthesized with an intraperitoneal injection of pentobarbital sodium. After draping, shaving, and cleaning the neck, a vertical midline incision was performed in order to expose the larynx and left recurrent laryngeal nerve, which was sectioned, and a 2-cm sample of the nerve was taken after verifying normal vocal cord mobility through direct laryngoscopy.

The midline raphe of the strap muscles was incised, and these were reflected laterally, exposing the entire TC on the left side. The external perichondrium of the medial upper part of the TC was incised, and as in a septoplasty, a tunnel was made with the aid of a Freer dissector through the inner perichondrium until the cricothyroid membrane was reached. Here, a careful dissection was performed to avoid luxation of the cricothyroid joint and laceration of the mucosa in the subglottic region. Then a medical grade silicone in the form of a cylinder 4 mm in diameter, previously designed according to the cadaver larynx studies, was placed from the superior part of the TC and pulled out

From the Hospital Fray Junípero Serra, Autonomous University of Baja California, Tijuana, Mexico.

Presented at the meeting of the American Laryngological Association, Denver, April 25-26, 1987.

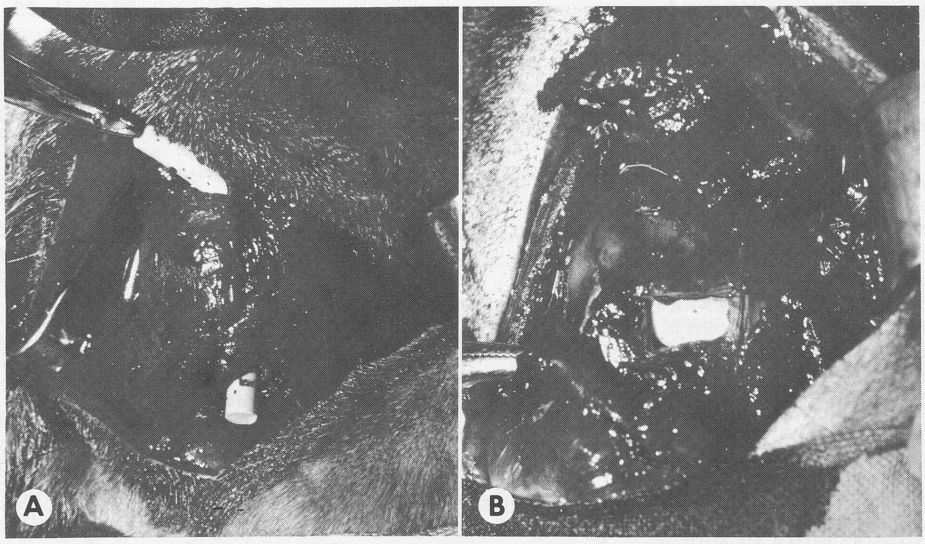

Fig 1. Photographs of cylindrical Silastic implants in dogs A) from upper part of thyroid cartilage to cricothyroid membrane (tunnel technique) and B) inside previously made window, over ala of thyroid cartilage.

over the cricothyroid membrane (Fig 1A). The Silastic was fixed with nonabsorbable sutures to prelaryngeal muscles. The wound was closed in layers. Perioperative antibiotics were administered to the animals.

The second experiment also was performed on five dogs. The preoperative procedures were basically the same, and the left recurrent laryngeal nerve was sectioned. In this group, Koufman's modification of the laryngoplasty devised by Isshiki et al was performed. A rectangular incision was made over the left thyroid ala according to Koufman's formula.[15] The upper margin of the incision was at the level of the vocal cord. The window of cartilage was cut with a No. 11 blade without perforating the inner perichondrium. A Cottle elevator was used to raise the inner perichondrium until the window of cartilage was free of the alar cartilage. Then a medical grade Silastic implant was positioned horizontally, pressing and medializing the cartilage window (Fig 1B). The wound was closed in layers.

The dogs were killed 1 week (two dogs), 2 weeks (two dogs), 3 weeks (two dogs), 6 weeks (two dogs), and 8 weeks (four dogs) postoperatively. Their larynges were removed, fixed in formalin, and stained with hematoxylin and eosin for light microscopic study.

In two additional dogs, one belonging to the first group and one to the second, the recurrent laryngeal nerve was not cut. Both were killed at 8 weeks postoperatively.

The dogs' barking was recorded on a cassette tape for evaluation before and after the operative procedure. The results were described as excellent (normal barking), good (nearly normal barking), and poor (dysphonia).

The second part of this study refers to the anatomic dimensions (Fig 2) of 20 adult human larynges (16 from males and four from females; age range, 20 to 64 years; mean, 30 years) from which the following mean measurements were obtained: 1) height of the central portion of the TC (20 mm); 2) height of the left thyroid ala (28.8 mm), 2A) height of the right thyroid ala (29.1 mm); 3) width of the left thyroid ala (36.3 mm), 3A) width of the right thyroid ala (36.4 mm); 4) distance between the true vocal cords and the inferior border of the TC (10.2 mm); 5) distance between the true vocal cords and the superior border of the TC (9.9 mm); 6) length of the vocal cords (20.2 mm); 7) distance between the posterior cricoid and the anterior commissure (30.2 mm); 8) height of the arytenoids (18.2 mm); 9) width of the interior larynx, taken from one external thyroarytenoid muscle to the other (19.6 mm); 10) width of the glottic lumen, with (4.2 mm) and without (7.0 mm) an implant; 11) width of the subglottic lumen, with (12.7 mm) and without (13.5 mm) an implant.

The surgical technique for external mobilization of the vocal cord was performed on all the larynges, and the glottic and subglottic lumens were measured with calipers before and after the introduction of the Silastic implant (4 mm). The larynges were fixed in formalin and stained with hematoxylin and eosin for light microscopic study (Fig 3A,B).

RESULTS

All the dogs tolerated the procedure well, and the fibrotic reaction around the silicone material was minimal (Fig 3C).

The group in which the tunnel technique was performed showed good compensation (lateralization) of the vocal cord. One dog developed a granuloma in the region of the anterior commissure. The barking recorded on a cassette tape showed excellent results (normal barking) in two dogs, good (slight loss of air) in two others, and poor (evident dysphonia) in one.

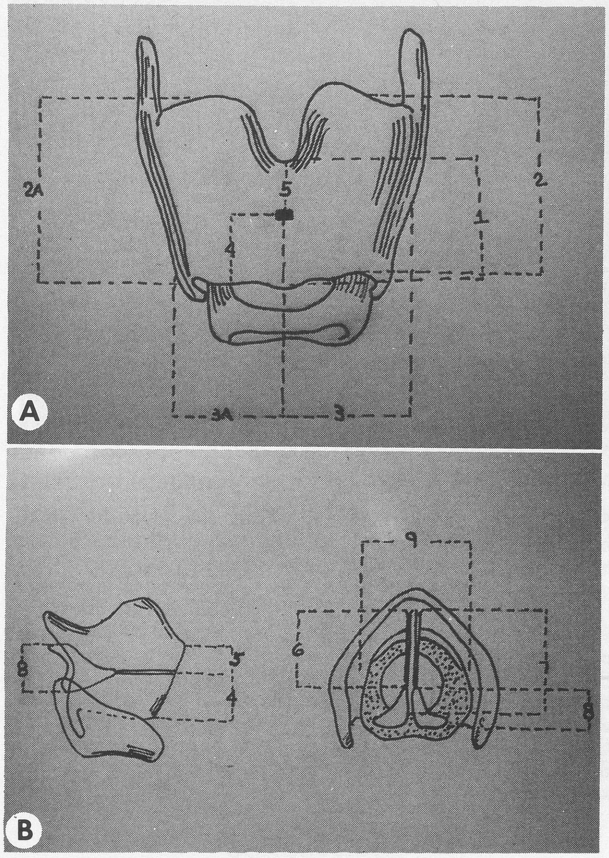

Fig 2. Views of larynx. A) Frontal view. 1 — height of central portion of thyroid cartilage (TC), 2 — height of left thyroid ala, 2A — height of right thyroid ala, 3 — width of left thyroid ala, 3A — width of right thyroid ala, 4 — distance between true vocal cords and inferior border of TC, 5 — distance between true vocal cords and superior border of TC. B) Lateral and coronal views. 4 — distance between true vocal cords and inferior border of TC, 5 — distance between true vocal cords and superior border of TC, 6 — length of vocal cords, 7 — distance between posterior cricoid and anterior commissure, 8 — height of arytenoids, 9 — width of interior larynx, taken from one external thyroarytenoid muscle to other.

In the second group, none of the dogs developed a granuloma. In one case, an abscess formed in the wound, compromising the results, and the prosthesis was removed. The implant was also well tolerated, with minimal reaction. Barking was excellent in two dogs, good in two, and poor in one (the one with the infection).

Concerning the two dogs in which the recurrent laryngeal nerve was not cut, one developed a granuloma of the anterior third of the medialized vocal cord.

The results of the anatomic measurements performed on the human larynges seem to indicate that the tunnel technique shortens the subglottic space, whereas the Koufman laryngoplasty does not. This effect did not seem to produce any functional deficit in the dogs, at least during the period of follow-up, and no diplophony was noticed.

It was evident that the thyroarytenoid muscles moved toward the midline after the introduction of the implants. This goal is reached in a similar way with both techniques.

CASE REPORTS

Case 1. A 27-year-old man had progressive idiopathic hoarseness, which had started when he was 13 years of age. A Teflon injection on the left vocal cord was performed when he was 20 years of age, with apparent early good results, but after several months the hoarseness became worse. When we first examined the patient, he had severe dysphonia, and indirect laryngoscopy revealed atrophy of the left vocal cord, which was lateralized. A direct laryngoscopy confirmed these findings. The vocal cord had an irregular shape and a stone-hard consistency. The patient did not have aspiration problems, and he was scheduled for vocal cord mobilization under local anesthesia via an external approach using Koufman's modification of the procedure of Isshiki et al. Several different sizes of Silastic implant were tried, and it was finally decided to leave two struts. The external perichondrium was used to seal the defect. The postoperative period was unremarkable and the patient's dysphonia improved, but a normal voice was not obtained. However, we consider this a successful procedure, because of the preoperative condition of the larynx.

Case 2. A 51-year-old woman underwent a section of the right recurrent laryngeal nerve after excision of a thyroid carcinoma. She developed a moderate dysphonia with minimal aspiration. Direct laryngoscopy showed a paramedian right vocal cord paralysis. A Koufman technique was performed, using the external thyroid perichondrium to seal the defect. She obtained a normal voice, but the aspiration was the same at her 10-month follow-up.

Case 3. A 60-year-old man developed an idiopathic left vocal cord paralysis with severe dysphonia and moderate aspiration. Direct laryngoscopy showed a lateralized left vocal cord. He underwent surgical medialization of the vocal cord with the tunnel technique, after which he obtained a nearly normal voice without aspiration on an 11-month follow-up (Fig 4A).

Case 4. A 70-year-old man developed severe dysphonia and aspiration after a cerebrovascular accident. Direct laryngoscopy revealed a lateralized left vocal cord paralysis. The tunnel surgical technique was performed, after which he obtained a nearly normal voice without aspiration on a 12-month follow-up.

Case 5. A 48-year-old woman developed aphonia and moderate aspiration secondary to lung carcinoma. Direct laryngoscopy revealed a paramedian left vocal cord paralysis. She underwent a tunnel

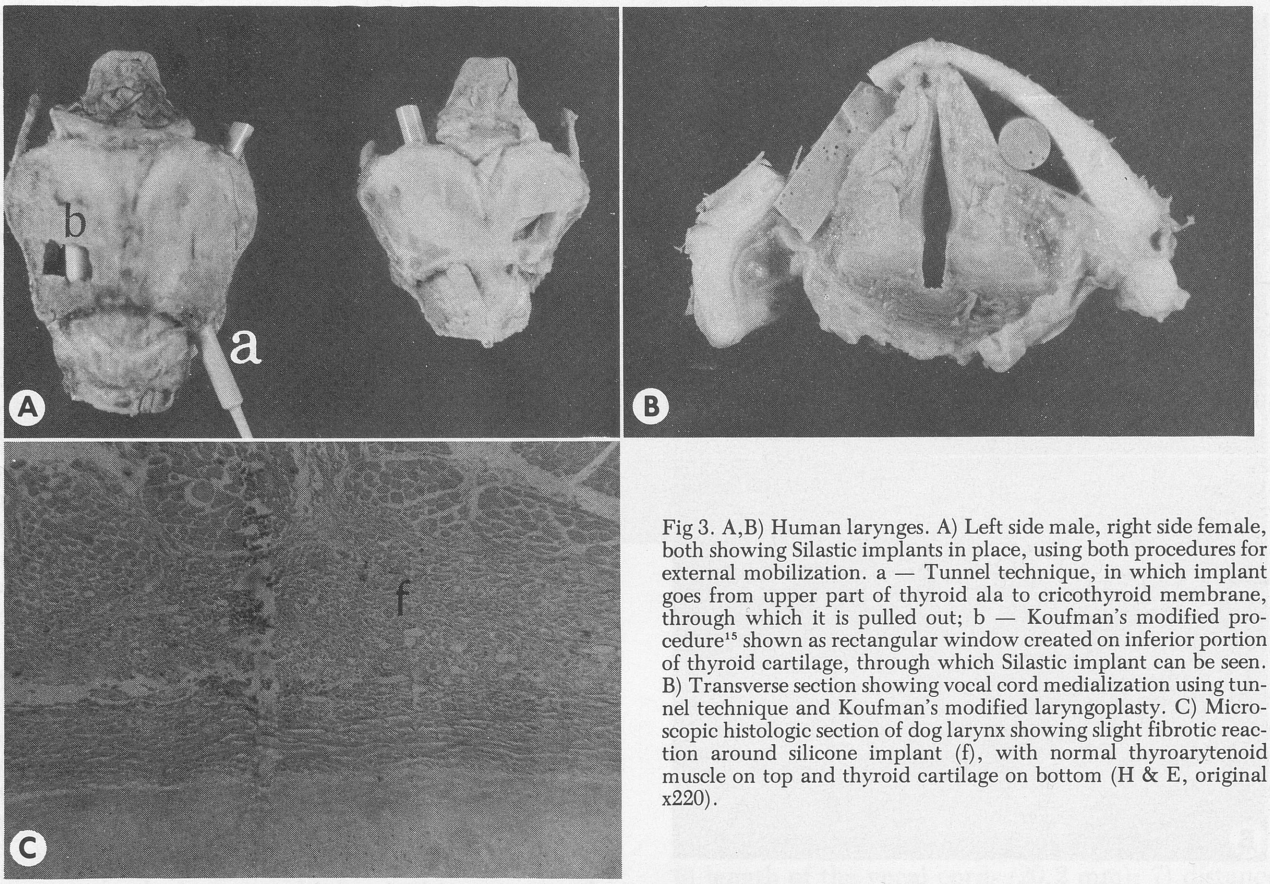

Fig 3. A,B) Human larynges. A) Left side male, right side female, both showing Silastic implants in place, using both procedures for external mobilization. a — Tunnel technique, in which implant goes from upper part of thyroid ala to cricothyroid membrane, through which it is pulled out; b — Koufman's modified procedure[15] shown as rectangular window created on inferior portion of thyroid cartilage, through which Silastic implant can be seen. B) Transverse section showing vocal cord medialization using tunnel technique and Koufman's modified laryngoplasty. C) Microscopic histologic section of dog larynx showing slight fibrotic reaction around silicone implant (f), with normal thyroarytenoid muscle on top and thyroid cartilage on bottom (H & E, original x220).

surgical technique for medialization of the vocal cord. Postoperatively she obtained a nearly normal voice, with minimal aspiration, which was the same on her 12-month follow-up.

DISCUSSION

Various techniques exist to alter vocal cord position surgically, with intracordal Teflon injection being the most popular.[16] However, as Koufman has pointed out, it has several disadvantages: 1) the need for patient cooperation under local topical anesthesia during direct laryngoscopy; 2) the need to be sure that motor function will not return to the injected vocal cord; and 3) the fact that the technique is not suggested in status postcordectomy, in the presence of atrophy and bowing of the vocal cord, or after laryngeal trauma causing a loss of soft tissue.

Case 1 suggests that patients with deficient soft tissue and scarring of the vocal cord can benefit from external medialization of the vocal cord. It seems that the tunnel technique can provide relief of aspiration in patients with paralysis due to central lesions, who often have concomitant superior laryngeal nerve and pharyngeal dysfunction, as well as in patients who have a lateralized vocal cord paralysis. This can be related to the slight reduction in the subglottic lumen produced by the implant (Fig 4B), which was found also in the cadaver dissections. Three of the patients in whom the tunnel technique was performed had clinical improvement of their aspiration. Both techniques of external medialization gave good functional results, and four of the five patients obtained a normal or nearly normal postoperative voice.

The granuloma formation in the anterior commissure in one of the dogs probably is related to an excessive medialization of the vocal cord. We did not observe the development of diplophonia, which might have occurred with the tunnel technique, in either the dogs or the five patients. There was no damage of the subglottic mucosa or cricothyroid joint luxation.

This study clearly shows how these techniques work. The Silastic produced a minimal fibrotic reaction, and its easy removal after a 2-month period is additional evidence that these external procedures are reversible. The degree of lateral compression may be adjusted better by using Koufman's technique than by the tunnel method, and the former is ideal for medialization of the vocal cord after a peripheral nerve lesion. The use of perichondrium of the TC to seal the defect created on it will help stabilize the implant and prevent early extrusions.

Both techniques may be used in conjunction with the procedure of vocal ligament tightening popularized by Isshiki et al,[14] LeJeune et al,[17] and Tuck-

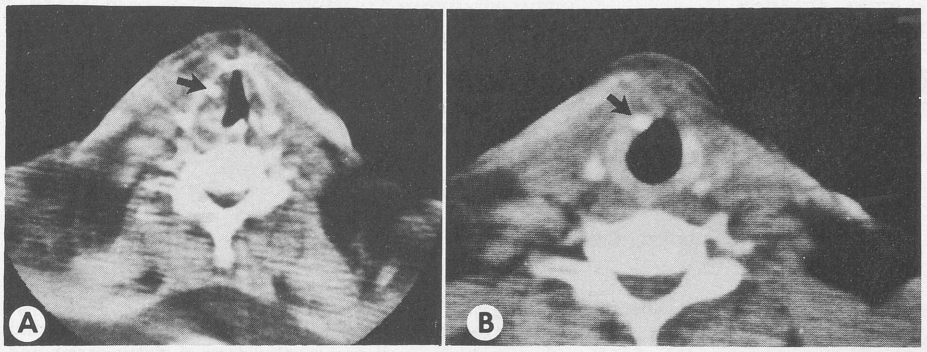

Fig 4. (Case 3) Computed tomographic scans. A) Scan showing Silastic implant after tunnel technique was performed on left side of larynx in order to medialize vocal cord (arrow). Following procedure, patient obtained nearly normal voice. B) Scan at level of subglottic region, showing slight reduction of lumen secondary to Silastic implant (arrow). There is no damage to mucosa or emphysema around implant.

er[18] for management of flaccid larynges or for patients who desire a modification of basic vocal pitch. Laryngeal reinnervation techniques such as the ansa hypoglossi–recurrent laryngeal nerve anastomosis[5] can be used as well, thanks to the reversibility of the procedure, and may offer the patient a more physiologic method of restoring vocal cord movement after unilateral paralysis. Once vocal cord mobility is regained, the laryngeal implant will be removed in order to avoid secondary problems.

It seems that external medialization of the vocal cord overcomes some of the inconveniences of Teflon injection and offers a new area for research in phonosurgery.

CONCLUSIONS

1. A new technique for vocal cord medialization is presented, using medical grade Silastic in a pocket created in the inner perichondrium of the TC (tunnel technique).
2. Early experiences have been promising in patients with paralysis due to central lesions, as well as in patients with lateralized vocal cord paralysis. Aspiration can be improved, and this constitutes an advantage over Koufman's procedure.
3. A modification of Koufman's laryngoplasty technique is presented, using the external perichondrium of the TC to keep the Silastic implant in place over the previously formed window. Experience has shown that several pieces of Silastic were needed in order to get voice improvement.
4. These techniques of external mobilization have a low morbidity. They are reversible and may be used in combination with other techniques of rehabilitation of the movement of the vocal cords, such as the ansa hypoglossi–recurrent laryngeal nerve anastomosis.
5. External mobilization of the vocal cord constitutes a good alternative to the Teflon injection method.

REFERENCES

1. Rubin HJ. Pitfalls in treatment of dysphonias by intracordal injection of synthetics. Laryngoscope 1965;75:1381-97.

2. Arnold GE. Vocal rehabilitation of paralytic dysphonia. Arch Otolaryngol 1962;76:358-68.

3. Ford CN, Bless DM. Clinical experience with injectable collagen for vocal fold augmentation. Laryngoscope 1986;96: 863-9.

4. Lewy RB. Teflon injection of the vocal cord: complications, errors, and precautions. Ann Otol Rhinol Laryngol 1983; 92:473-4.

5. Crumley RL, Izdebski K. Voice quality following laryngeal reinnervation by ansa hypoglossi transfer. Laryngoscope 1986;96:611-6.

6. Crumley RL. Phrenic nerve graft for bilateral vocal cord paralysis. Laryngoscope 1983;93:425-8.

7. Tucker HM, Rusnov M. Laryngeal reinnervation for unilateral vocal cord paralysis: long-term results. Ann Otol Rhinol Laryngol 1981;90:457-9.

8. Dedo HH, Urrea RD, Lawson L. Intracordal injection of Teflon® in the treatment of 135 patients with dysphonia. Ann Otol Rhinol Laryngol 1973;82:661-7.

9. Payr A. Plastik am Schildknorpel zur Behebung der folgen einseitiger Stimmbandlahmung. Dtsch Med Wochenschr 1915; 43:1265-7.

10. Meurman Y. Operative mediofixation of the vocal cord in complete unilateral paralysis. Arch Otolaryngol 1952;55:544-9.

11. Opheim O. Unilateral paralysis of the vocal cord. Operative treatment. Acta Otolaryngol (Stockh) 1955;45:226-31.

12. Sawashima M, Totsuka G, Kobayashi T, Hirose H. Surgery for hoarseness due to unilateral vocal cord paralysis. Arch Otolaryngol 1968;87:289-94.

13. Isshiki N, Morita H, Okamura H, Hiramoto M. Thyroplasty as a new phonosurgical technique. Acta Otolaryngol (Stockh) 1974;78:451-7.

14. Isshiki N, Okamura H, Ishikawa T. Thyroplasty type I (lateral compression) for dysphonia due to vocal cord paralysis or atrophy. Acta Otolaryngol (Stockh) 1975;80:465-73.

15. Koufman JA. Laryngoplasty for vocal cord medialization: an alternative to Teflon. Laryngoscope 1986;96:726-31.

16. Arnold GE. Vocal rehabilitation of paralytic dysphonia. IX. Technique of intracordal injection. Arch Otolaryngol 1962; 76:358-68.

17. LeJeune FE, Guice CE, Samuels PM. Early experiences with vocal ligament tightening. Ann Otol Rhinol Laryngol 1983; 92:475-7.

18. Tucker HM. Anterior commissure laryngoplasty for adjustment of vocal fold tension. Ann Otol Rhinol Laryngol 1985;94: 547-9.

IS CHRONIC GASTROESOPHAGEAL REFLUX A CAUSATIVE FACTOR IN GLOTTIC CARCINOMA?

MURRAY D. MORRISON, MD, FRCS(C)

VANCOUVER, CANADA

Several forms of laryngeal dysfunction can be attributed to the effects of chronic gastric reflux through direct acid irritation, by a reflex alteration in voluntary muscle tone or vagally referred sensation. It is widely accepted that contact ulcers and granulomata over the medial aspects of the arytenoid cartilages are associated with gastric reflux, but there have not been well-documented cases of glottic carcinoma that are reflux-related. This paper presents five cases of glottic carcinoma, all with T1 lesions of the anterior two thirds of the vocal cord. All the patients were lifetime nonsmokers and had no ailments other than moderately severe chronic gastroesophageal reflux. Clinical details from the study of these patients strongly indicate that the reflux may have been a factor in the development of the disease. In addition, review of 21 lifetime nonsmokers with glottic carcinoma presenting over a 10-year period at the Cancer Control Agency of British Columbia revealed 48% likely to have been suffering from reflux, compared to 16% in a group that had stopped smoking 10 or more years previously. While this small number of cases cannot be said to prove the causative relationship between reflux and glottic carcinoma, it is important for the otolaryngologic community to be aware of the possible clinical relationship.

KEY WORDS — gastric reflux, laryngeal cancer.

The title of this presentation is in the form of a question, and for the time being the question will remain unanswered. I present several cases of glottic carcinoma in lifetime nonsmokers that may have been reflux-induced, at least in part, and also offer some circumstantial evidence from a review of 10 years of experience with glottic cancer from the Cancer Control Agency of British Columbia that supports chronic gastroesophageal reflux as a possible causative factor in this disease.

When an otolaryngologist sees a patient with a carcinoma of the glottic larynx, it is assumed routinely that the patient has been a heavy smoker for most of his or her life. One is surprised when it turns out that the patient is a nonsmoker of many years, or has never smoked in his or her life.

Five patients with glottic carcinoma who were lifetime nonsmokers presented over a relatively brief period, during which time the author was interested in the manifestations of chronic gastroesophageal reflux on the larynx. Much of our study of pharyngolaryngeal manifestations of reflux has been directed toward the common throat symptoms of globus sensation, postnasal drip, and habitual throat clearing, as well as the more usual heartburn and postprandial discomfort with nighttime coughing spells and throat problems in the morning. It became apparent that these nonsmoking patients with glottic carcinoma had an abundance of these symptoms, so attention turned to their reflux status.

CASE REPORTS

Case 1. An overweight man 46 years of age had been having lifetime problems with recurrent upper respiratory tract problems attributed to chronic sinusitis and postnasal discharge. He eventually developed nighttime asthma attacks that would wake him. He also developed nasal polyps, for which allergy to aspirin was ruled out as a cause. Examination of the larynx showed a diffusely reddened posterior glottic mucosa with a white polypoid mass in the middle third of the right vocal cord, which biopsy confirmed to be a moderately differentiated squamous cell carcinoma. This was treated with radiation therapy and responded well, but during the follow-up period over the next few years, he continued to have difficulty with his nighttime coughing spells and with postnasal drip and globus sensation. A barium swallow study showed a hiatus hernia, and his symptoms cleared on antireflux management.

Neither he nor anyone in his family had ever been tobacco smokers, nor had he had any known exposure to other potential carcinogens.

Case 2. A woman 56 years of age had throat complaints of less than 1 year consisting of postnasal drip that was often metallic or acid-tasting, habitual throat clearing, heartburn after meals, and a dry, irritated throat in the mornings. Her voice became squeaky and higher-pitched, so that she was unable to sing in the church choir.

Laryngoscopy showed a rather fleshy and granular pinkish ovoid mass occupying the middle third of the right vocal cord. Biopsy at microlaryngoscopy showed an invasive well-differentiated squamous cell carcinoma. This patient had never smoked a cigarette in her life; neither did anyone else in her family. She was otherwise well and on no medications.

From the University of British Columbia Division of Otolaryngology, Vancouver General Hospital, and the Cancer Control Agency of British Columbia, Vancouver, Canada.

Presented at the meeting of the American Laryngological Association, Denver, April 25-26, 1987.

TABLE 1. SMOKING HISTORY IN 458 PATIENTS WITH GLOTTIC CARCINOMA

Smoking History	*Patients*	
	No.	*%*
Never smoked	21	4.6
Stopped >9 yr	44	9.6
Stopped <10 yr	52	11.4
Light	34	7.4
Moderate	132	28.8
Heavy	148	32.3
Pipe smoker	11	2.4
Unknown	16	3.5

This patient's carcinoma responded well to radiation therapy; however, she developed bilateral contact granulomata over the arytenoids as the radiation reaction settled down. These, as well as her presenting symptoms, eventually were alleviated with antireflux measures.

Case 3. For 2 years this 55-year-old man had been having throat symptoms consisting of the need to clear his throat because of a constant feeling of congestion and of the inability to sing or project his voice. He was found to have a large hiatus hernia and to have had trouble with gastric reflux for the previous 15 years. He was unable to drink coffee without its causing heartburn, throat clearing, postnasal drip, and globus sensation. He had never smoked cigarettes and used alcohol only minimally. Laryngoscopy showed a diffuse hyperkeratotic appearance at the anterior end of the left vocal cord that seemed to extend to the anterior right vocal cord as well. Laryngoscopy and biopsy confirmed in situ squamous cell carcinoma, which was treated with local laser ablation. Postsurgically, the throat symptoms related to the radiographically demonstrated massive reflux could be controlled only by the most stringent antireflux measures. One year later, his larynx remains healthy in appearance, and he remains on careful follow-up with videolaryngostroboscopy.

Case 4. A 72-year-old man has been an amateur singer much of his life, but for many years had been having problems with postnasal drip, nighttime heartburn, and irritation of his throat, particularly in the morning. Over the preceding few years, he had developed several keratotic lesions in the larynx that had been removed and had shown only benign keratosis. Eventually, a microlaryngoscopy and excisional biopsy of a recurrent keratotic lesion showed a distinct carcinoma in situ. Because of his history of reflux, a barium swallow study was obtained that showed a moderately large sliding hiatus hernia with reflux. The carcinoma in situ was controlled with carbon dioxide laser excision, and his symptoms are controlled with antireflux measures. Regular follow-up for 2 years has shown no suggestion of recurrence.

Case 5. A woman 28 years of age had been complaining of throat clearing and postnasal discharge for 4 years that was bothering her first thing in the morning and was associated with globus sensation. Her health generally had been good, and she had been moderately vocally active in gymnastics coaching and looking after her three children. She had never smoked, and no one else in the family was a smoker.

TABLE 2. AGES OF NONSMOKERS VERSUS FORMER SMOKERS

Age	*Never Smoked*	*Stopped >9 Years Before Diagnosis*
<50	4	1
50-59	2	5
60-69	6	15
70-79	6	11
80-89	3	12
Total	21	44

Laryngologic examination showed a reddish granular lesion along the full length of the superior surface of the right vocal cord and a smaller but similar-appearing lesion on the superior surface of the left vocal cord. Microlaryngoscopy and biopsy revealed these to be squamous cell carcinomata in situ, and they were removed totally with the CO_2 laser.

Gastroesophageal reflux was confirmed on barium swallow study. Her symptoms have been alleviated with antireflux measures, and at regular follow-up videolaryngoscopy and stroboscopy there is no suggestion of recurrence.

Comment. These five patients all came for treatment in the early and middle 1980s. Since the author had participated in the study of all laryngeal carcinomas presenting to the Cancer Control Agency of British Columbia between 1970 and 1980, it was decided to review patients from that series who were nonsmokers in an attempt to determine whether or not gastroesophageal reflux disease may have been a concomitant feature.

MATERIALS AND METHODS

The clinical records of 458 patients were reviewed. As shown in Table 1, 21 patients, or 4.6%, had been recorded as never having smoked, while 44 were noted to have stopped smoking more than 9 years previously. It was decided to look closely at the records of these two groups, ie, the "never smoked" group and the "stopped smokers" group, to determine whether or not there might be any evidence of chronic gastroesophageal reflux disease.

Criteria for arriving at a presumptive reflux diagnosis are as follows. A definitive diagnosis required a radiographic, manometric, or esophagoscopic proof that gastroesophageal reflux was present. A probable reflux diagnosis was made if the patient was being treated for this condition, such as with bed elevation, antacids, or cimetidine. A possible reflux diagnosis was entertained when the symptoms strongly

TABLE 3. TUMOR LOCATION IN GLOTTIS

Location	*Never Smoked*	*Stopped >9 Years Before Diagnosis*
Anterior	5	17
Middle	8	13
Posterior	2	3
Full	6	11

suggested that reflux was present. As discussed in the case presentations, these symptoms include globus sensation, postnasal drip, habitual throat clearing, acid taste in the throat, symptoms worse in the morning, nighttime coughing or choking spells, and heartburn or postprandial indigestion.

RESULTS

The ages of the two groups are shown in Table 2. Those developing glottic cancer who had never smoked were a slightly younger group, but the difference was not statistically significant.

The sex difference is, however, statistically significant ($p = .001$). All 44 of those patients developing glottic cancer who had been previous smokers were men, and of the never-smoked group, 15 were men and six women.

It is recognized in the literature[1] that laryngeal disease of a benign nature secondary to chronic gastroesophageal reflux usually affects the posterior glottis. This includes such things as contact ulcers, granulomata, and posterior glottic stenosis. It was interesting to note that in our five cases of glottic carcinoma that may have been reflux-induced, all of the tumors were at the middle of the cord or in the anterior commissure. Review of the 65 Cancer Agency patients confirms the pattern, in that the majority of tumors are in the middle of the cord or anterior, as is shown in Table 3. There was a slight preponderance of bilateral disease (five patients) as compared to unilateral disease (16 patients) in the group that had never smoked; in the group that had quit smoking 9 or more years earlier, seven had bilateral disease and 37 had unilateral disease.

Reflux Diagnosis. It is somewhat dangerous to go back to a series of charts of patients with glottic cancer and try to deduce from them whether or not the patient was suffering the effects of chronic gastroesophageal reflux. On the other hand, in a number of these patients, the reflux diagnosis was very clear. Results of this detective work are shown in Table 4. In those patients who had never smoked, reflux diagnosis was possible, probable, or definite in ten for an incidence of 47.6%, while in the stopped-smoking group there were seven, or 16%, possible diagnoses of reflux. This difference is statistically significant ($p = .016$). If we include only those patients with a probable or definite diagnosis of gastroesophageal reflux, seven of 21 of the nonsmokers had reflux compared to three of 44 of patients who had stopped smoking more than 9 years previously. This difference is also significant ($p = .016$).

TABLE 4. REFLUX DIAGNOSIS

	Never Smoked	*Stopped >9 Years Before Diagnosis*
Definite	3	2
Probable	4	1
Possible	3	4
Absent	11	37
Total	21	44

$p = .016$.

DISCUSSION

Every author who writes about the cause of cancer of the larynx highlights cigarette smoking as the prime cause. Cann et al[2] recently have done an exhaustive review of this issue and combined the findings of 122 studies of epidemiology of squamous cell cancer in the head and neck. In addition to smoking, they discuss the well-known apparent synergism between tobacco and alcohol, but it is widely recognized that this interrelationship is not as strong with glottic cancer as with supraglottic tumors. It should be noted that the five patients in the present study were all very light alcohol users or abstainers.

In this review of laryngeal cancer patients, we compared lifetime nonsmokers with those patients who had stopped smoking 10 or more years prior to diagnosis. Wynder and Stellman[3] have shown that age- and race-adjusted relative risk of laryngeal cancer in men decreased from 14.3%, relative to nonsmokers, to 2.5% at 16 years after quitting smoking. Using this group of stopped smokers to compare to the nonsmoking group gave a population of roughly comparable size and also provided patients that would not be having other tobacco-related symptoms. But it did remain our contention that the previous cigarette smoking, which in many patients was quite heavy, still was related to the onset of their laryngeal cancer, as suggested by the above statistic. In addition, other possible occupational exposures such as contact with asbestos or leather working, nickel refining, or textile fiber processing that have been variably implicated in the literature were not present in any of these patients.

I have not been able to find any previous reports or references to suggest that chronic gastroesophageal reflux might be a causative factor in development of glottic carcinoma. I also do not blithely claim that the glottic cancers that developed in the five nonsmoking patients were caused by their proven gastroesophageal reflux disease, but this association is very difficult to ignore. The fact that a known or highly likely diagnosis of reflux was statistically more prevalent among lifetime nonsmokers with glottic cancer than among a group that had smoked previously also lends circumstantial evidence. As otolaryngologists become more aware of the effects

of reflux on the larynx, I suspect other reports such as this will appear and perhaps help to answer our original question. This will, of course, beg the question of pathogenesis.

ACKNOWLEDGMENTS — The author thanks the Cancer Control Agency of British Columbia for assistance in record review and Dr Albino Flores for help and advice.

REFERENCES

1. Olsen NR. The problem of gastroesophageal reflux. Otolaryngol Clin North Am 1986;20:119-33.

2. Cann CI, Fried MP, Rothman PH. Epidemiology of squamous cell cancer of the head and neck. Otolaryngol Clin North Am 1985;18:367-88.

3. Wynder EL, Stellman SD. Comparative epidemiology of tobacco-related cancers. Cancer Res 1977;37:4608-22.

CONSERVATION LARYNGECTOMY

GUI-YI TU, MD

BEIJING, PEOPLE'S REPUBLIC OF CHINA

During the past 10 years in China, there has been an increasing trend toward conservation laryngectomy for laryngeal cancer. Repair at the Cancer Hospital in Beijing has been made by using an osteomuscular flap fashioned from hyoid bone and strap muscles. This flap can be used in cases of three-fourths resection and in cases following extended vertical laryngectomy for T3 disease. The 5-year cure rate in this series of 123 patients is 78%.

KEY WORDS — conservation laryngectomy, osteomuscular flap.

A major goal of ablative cancer surgery today is maintenance of a meaningful quality of life. The idea of conservation surgery that permits the laryngeal cancer patient to retain the functions of breathing, phonation, and swallowing is not new. Shortly after Billroth had introduced total laryngectomy, he worked on developing partial laryngectomy.[1] The technique evolved slowly during this century until now the rationale for conservation procedures is soundly based anatomically, histologically, and clinically. Laryngeal surgery has come into a new era in which the proportion of laryngeal patients treated conservatively is a measure of the quality of an oncology service. In the Cancer Hospital of the Chinese Academy of Medical Sciences, the percentage of conservation laryngectomies has risen from 10% in the 1950s to 57% in recent years.

METHODS

Between 1958 and 1981, 123 patients were treated with conservation surgery, 79 for supraglottic cancer and 44 for glottic cancer. The age of the patients ranged from 22 to 72 years. Seventy-one patients were men and 52 were women, and all had squamous cell carcinoma.

For cases of supraglottic cancer with vocal cord involvement (T2) and fixed arytenoid cartilage (T3), we performed a three-fourths resection or partial laryngectomy (Table 1), originally described by Ogura and Dedo.[2] After removing tumor-bearing tissue, only one vocal cord (or part of one) and a single arytenoid cartilage remained. In these cases we used the hyoid bone and strap muscle for reconstruction, as will be described. For bilateral vocal cord lesions without much supraglottic and subglottic extension, we performed a horizontal glottal resection. Ventricular mucosa was anastomosed to tracheal mucosa. For T3 glottic lesions in which the vocal cord was fixed, an extended vertical partial laryngectomy that included the cricoarytenoid articulation and a part of the cricoid rostrum was performed. The defect may also be repaired with an osteomuscular flap.

Osteomuscular Flap. Building on the work of earlier surgeons who repaired the laryngeal surgical defect with a piece of thyroid cartilage and used a segment of thyroid cartilage to fill the gap remaining after arytenoid cartilage removal,[3] we developed a technique using a piece of hyoid bone and a strip of thyrohyoid muscle to repair the resected half of the laryngeal cavity (Fig 1). The osteomus-

TABLE 1. TREATMENT OF LARYNGEAL CANCER

Site of Carcinoma	*Staging*	*Treatment*
Supraglottic area	T1	Supraglottic laryngectomy (horizontal)
	T2	Partial laryngectomy (vertical), three-fourths laryngectomy (horizontal-vertical)
	T3	Supraglottic laryngectomy (horizontal) for preepiglottic space invasion, three-fourths laryngectomy for arytenoid fixation
	T4	Supraglottic laryngectomy (horizontal) for pharyngoepiglottic fold invasion or involvement of medial wall of pyriform sinus, three-fourths resection with one-sided glottic invasion, or total laryngectomy
Glottis	T1	Irradiation or cordectomy
	T2	Partial laryngectomy (vertical) or frontolateral laryngectomy, glottal resection (horizontal) for bilateral vocal cord lesions
	T3	Extended partial laryngectomy (vertical) including excision of arytenoid cartilage and cricoarytenoid articulation, or total laryngectomy
	T4	Total laryngectomy
Neck	N0	"Wait and see" for glottic cases, elective ipsilateral upper neck dissection for supraglottic cases
	N1	Radical neck dissection
	N2	Radical neck dissection
	N3	Preoperative irradiation and radical neck dissection

From the Cancer Hospital, Chinese Academy of Medical Sciences, Beijing, People's Republic of China.

Presented at the meeting of the American Laryngological Association, Denver, April 25-26, 1987.

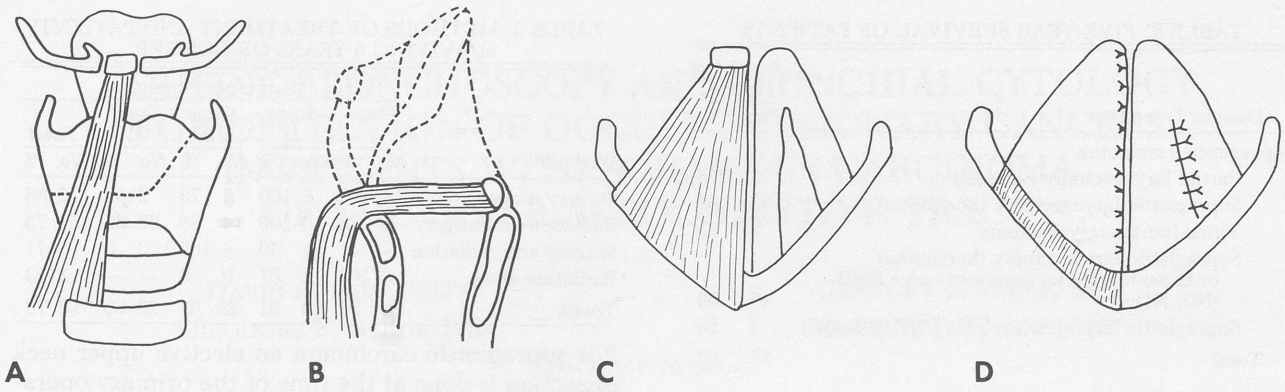

Fig 1. Technique of creating osteomuscular flap. A) Segment of hyoid bone is incised and left attached to thyrohyoid muscle. B) Lateral view of flap in defect. C) Superior view of flap in defect. D) Completed repair of glottis with hypopharyngeal mucous membrane.

cular flap is turned into the laryngeal cavity (Fig 2) at a right angle. The hyoid bone is fixed at the site where the arytenoid cartilage was removed. The hypopharyngeal mucosa is then advanced to cover the superior raw surface of the flap. The underlying raw surface facing the trachea is left to heal by secondary intention.

DISCUSSION

Over the past hundred years the practice of radical surgery for the majority of laryngeal cancers has changed. Today the emphasis is on individual assessment and conservation of function within the context of radical surgery. Whole organs are not routinely resected. The survival rates in this series strongly support the concept of conservation laryngectomy, even for late-stage disease (Tables 2 and 3).

The popularity of conservation laryngectomy has brought the problem of reconstruction to the foreground. When the surgeon is able to reconstruct a partial larynx, the approach is wide resection. The osteomuscular flap is versatile and useful in this situation.

Controversy remains with respect to management of neck nodes especially when the cancer is N0 with potential microscopic metastatic foci. Because of the high incidence of neck metastases in supraglottic cancer, some surgeons advocate an elective

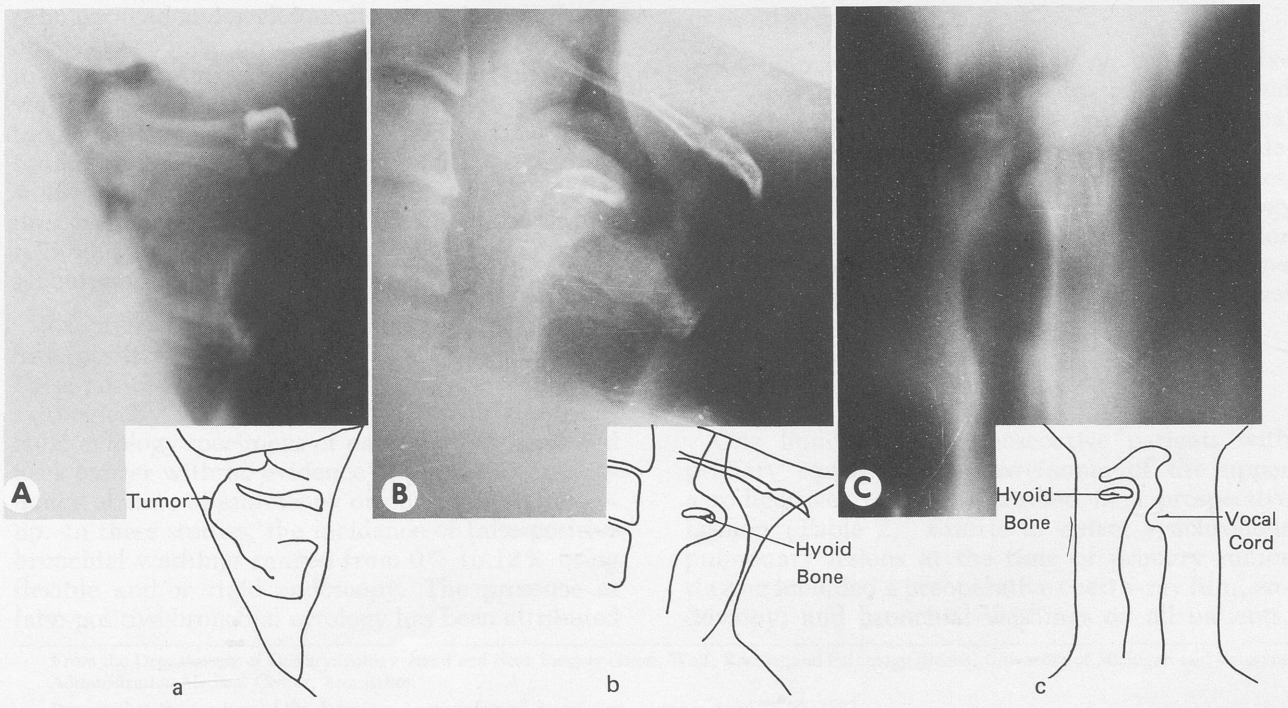

Fig 2. A) Lateral radiograph of larynx shows supraglottic lesion; a) corresponding line drawing. B) Lateral radiograph of larynx shows repair with hyoid osteomuscular flap; b) corresponding line drawing. C) Anterior-posterior tomogram of larynx shows repair with right hyoid osteomuscular flap; c) corresponding line drawing.

TABLE 2. FIVE-YEAR SURVIVAL OF PATIENTS

Disease/Treatment	*Surviving Patients* No.	%
Supraglottic carcinoma		
Partial laryngectomy (vertical)	3	75
Supraglottic laryngectomy (horizontal)	33	87
Three-fourths laryngectomy	7	88
Supraglottic laryngectomy (horizontal) or three-fourths laryngectomy plus RND (N0, N1)	13	54
Supraglottic laryngectomy plus RND (N2, N3)	1	20
Total	57	72
Glottic carcinoma		
Cordectomy	4	100
Partial laryngectomy (vertical)	18	95
Glottic laryngectomy (horizontal)	1	100
Extended laryngectomy (vertical) including RND in 2 cases	16	80
Total	39	89

RND — radical neck dissection.

neck dissection for N0 cases. In this series we adopted a "wait and see" policy for glottic cases.

TABLE 3. METHODS OF TREATMENT AND PATIENTS SURVIVING 5 YEARS OR LONGER

	Surviving Patients									
	Stage I		*Stage II*		*Stage III*		*Stage IV*		*Total*	
Methods	No.	%	No.	%	No.	%	No.	%	No.	%
Surgery alone	14	100	8	100	8	73	2	50	32	86
Radiation and surgery	5	83	9	100	14	88	23	62	51	75
Surgery and radiation	—	—	1	50	4	100	0	0	5	71
Radiation alone	6	100	2	67	0	0	—	—	8	73
Totals	25	96	20	91	26	79	25	60	96	78

For supraglottic carcinoma an elective upper neck dissection is done at the time of the primary operation. Radical neck dissection is required if the node is positive.

Since the 1940s, surgery has been playing an increasing role in the management of cancer; resection of the whole organ, when invaded by cancer, was the method of choice. Today the extent and nature of cancer surgery is determined individually, and surgeons routinely leave adequate tissue for repair and restoration of organ function.

REFERENCES

1. Stell PM. The first laryngectomy for carcinoma [Editorial]. Arch Otolaryngol 1973;98:293.

2. Ogura JH, Dedo HH. Glottic reconstruction following subtotal glottic-supraglottic laryngectomy. Laryngoscope 1965;75:865-78.

3. Blaugrund SM, Kurland SR. Replacement of the arytenoid following vertical hemilaryngectomy. Laryngoscope 1975;85: 935-41.

ROUTINE BRONCHOSCOPY AND BRONCHIAL CYTOLOGY FOR DETECTION OF OCCULT PULMONARY CANCERS IN PATIENTS WITH SQUAMOUS CARCINOMA OF THE UPPER AERODIGESTIVE TRACT

DAVID B. HOM, MD
THEODORE F. BEALS, MD
GREGORY T. WOLF, MD
CHARLES J. KRAUSE, MD

ANN ARBOR, MICHIGAN

Patients with squamous cell carcinoma of the upper aerodigestive tract are at high risk of developing synchronous and metachronous second primary neoplasms. Controversy exists as to the usefulness of bronchoscopy and bronchial cytology at time of staging endoscopy for the detection of synchronous pulmonary malignancies. A prospective study of 103 high risk patients with documented squamous carcinoma of the primary upper aerodigestive tract was undertaken to determine the effectiveness of routine bronchial cytology in detecting occult pulmonary cancers. The incidence of false-positive cytologies (7.8%) in this prospective study is higher than the reported in prior studies (3.8%) and suggests that routine bronchial washings are of limited usefulness because of low sensitivity (25%) and a high rate of false positives among all positives (80%).

KEY WORDS — bronchogenic carcinoma, bronchoscopy, head and neck neoplasms.

INTRODUCTION

Patients with squamous cell carcinoma of the upper aerodigestive tract are at high risk for developing synchronous (4% to 14%) and metachronous (12% to 19%) second primary malignancies.[1-4] A synchronous lesion is defined as a second primary lesion within 6 months of the original primary cancer, and a metachronous lesion is defined as one found anytime after 6 months. Primary bronchogenic carcinoma is the most common non–head and neck second primary malignancy associated with primary head and neck squamous carcinoma. These observations have prompted a number of surgeons to perform routine bronchoscopy and bronchial washings as screening measures to detect occult lung malignancies in patients with head and neck squamous cell cancer. Despite a number of prior studies of bronchoscopy in patients with head and neck squamous cell cancer,[4-7] the effectiveness and reliability of bronchial cytology for detecting occult synchronous lung malignancy remains unclear.

Six prior studies have reported varying rates of false-positive bronchial cytologies (Table 1).[6-11] False-positive bronchial washings were defined as cytologically malignant cells present in the bronchial cytology specimens of patients with head and neck cancer with no evidence of pulmonary malignancy at time of endoscopy or during close follow-up. In these studies, the incidence of false-positive bronchial washings ranged from 0% to 12% using flexible and/or rigid endoscopy. The presence of false-positive bronchial cytology has been attributed to contamination of exfoliated malignant cells from the primary upper aerodigestive tract tumor.

Studies by Garfinkle et al[11] and Denneny and Weisman[10] reported that contamination of bronchial washings from more proximal desquamated neoplastic cells in patients with aerodigestive tract cancers occurred in up to 12% of their cases. This occurrence was especially evident when the bronchoscope was passed beside the endotracheal tube. Other studies suggested that bronchial washing contamination giving false-positive cytology was an unusual event.[6,8,9]

To help resolve this controversy, a prospective study was undertaken in 103 patients with head and neck squamous carcinoma to determine the clinical usefulness and accuracy of bronchial cytology in detecting synchronous occult pulmonary malignancies. Rates of true- and false-positive bronchial cytology were determined by subsequent patient evaluation and follow-up. The relationship of false-positive rates to primary tumor site and extent also was analyzed.

METHODS

One hundred three consecutive patients with primary squamous cell carcinoma of the upper aerodigestive tract were studied in a prospective fashion (Table 2). Efforts to detect synchronous pulmonary lesions at the time of primary tumor staging included a preoperative chest x-ray film, endoscopy, and bronchial washings on all patients.

From the Departments of Otolaryngology–Head and Neck Surgery (Hom, Wolf, Krause) and Pathology (Beals), University of Michigan and Veterans Administration Medical Center, Ann Arbor.

Presented at the meeting of the American Laryngological Association, Denver, April 25-26, 1987.

REPRINTS — G. T. Wolf, MD, Dept of Otolaryngology–Head and Neck Surgery, 1904 H Taubman, University Hospitals, 1500 E Medical Center Dr, Ann Arbor, MI 48109.

TABLE 1. INCIDENCE OF FALSE-POSITIVE BRONCHIAL WASHINGS

Study	*N*	*% False Positives*	*Type of Bronchoscope*
Dellon et al[8]	18	0.0	Flexible
Johnson et al[9]	100	1.0	Rigid
Leipzig et al[7]	275	2.2	Rigid and flexible
Leipzig[6]	98	3.1	Rigid and flexible
Denneny and Weisman[10]	65	3.1	Flexible
Garfinkle et al[11]	107	12.1	Flexible
Total	663	Mean 3.8	

Bronchoscopy and bronchial washings were performed under general anesthesia using a rigid ventilating bronchoscope. Five milliliters of normal saline was instilled in each main stem bronchus, and the specimens from each side were collected in separate Leukens trap containers. Each container was labeled individually for cytologic analysis. In processing the specimens, standard cytologic techniques were followed. Four slides were prepared from each specimen by smearing the collected fluid onto frosted glass microscopic slides. Slides then were fixed in 95% ethanol and subsequently stained for the Papanicolaou test. Smears were screened thoroughly by a cytopathologist. The cytologic findings were classified as either negative for malignant cells, atypical (abnormal benign cells present), suspicious (cells with malignant cytologic features present but definite diagnosis of malignancy not made), or positive (malignant cells definitely identified).

Each patient was followed for a minimum of 6 months (except for those patients who expired within 6 months) to determine if a synchronous pulmonary malignancy appeared (follow-up range, 3 months to 8 years 4 months). Retrospectively, all positive bronchial washings were reviewed again in a blinded fashion by the pathologist (T.F.B.) to determine if the source of tumor cells could be distinguished cytologically as upper versus lower airway.

RESULTS

Of the 103 high risk patients with documented primary upper aerodigestive tract neoplasms, ten had bronchial washings that were either strongly suspicious or positive for malignancy (Table 3). Eight of these ten patients had no evidence of pulmonary malignancy at the time of endoscopy or during close follow-up (mean, 1 year; range, 3 months to 2 years 10 months). Two of these eight patients expired at 3 and 4 months postendoscopy from non-tumor-related causes with no evidence of pulmonary carcinoma.

TABLE 2. STUDY POPULATION BY CANCER STAGE AND SITE

Site	*T1*	*T2*	*T3*	*T4*	*Tx*	*Total*
Oral cavity	1	7	7	2	—	17
Oral pharynx	8	11	13	2	—	34
Hypopharynx	4	5	2	1	—	12
Larynx	8	10	7	8	—	33
Esophagus	1	—	2	—	—	3
Nasopharynx	—	1	—	—	—	1
Unknown primary	—	—	—	—	3	3
Total	22	34	31	13	3	103

TABLE 3. NUMBER OF PATIENTS BY CYTOLOGY RESULTS AND PRIMARY TUMOR CLASSIFICATION

Class	*No. Pts*	*Normal*	*Atypical*	*Suspicious*	*Positive*
T1	22	19	2	1	—
T2	34	24	5	2	3
T3	31	22	6	1	2
T4	13	9	3	—	1
Tx	3	3	—	—	—
Total	103	77	16	4	6

Of the ten patients with suspicious or positive bronchial washings, only two were found to have bronchogenic carcinoma (true positives). The bronchial cytology of one of these patients was classified as suspicious, while the other patient's cytology was classified as positive. In both of these patients, a lung lesion also was evident on the chest x-ray film at the time of endoscopy.

In the remaining 93 patients with negative bronchial cytologies (follow-up range, 3 months to 8 years 4 months), six developed pulmonary malignancies within 3 months and in one, bronchogenic carcinoma was detected within 14 months. Occult pulmonary cancer was not detected by bronchial washings in any patients with normal chest x-ray results. Thus, of the eight patients who had synchronous lung malignancies, only two had positive bronchial washings, and both of these patients had abnormal chest x-ray results at the time of endoscopy. Once a chest x-ray film suggested a malignant pulmonary process, a tissue diagnosis was established by needle biopsy or bronchial biopsy.

The primary tumor site most frequently associated with false-positive bronchial cytology was the hypopharynx (17%), followed by the larynx (12%). False-positive bronchial cytology occurred with both large and small tumors, with no apparent association with tumor size (Table 4).

Bronchial washing sensitivity as a screen for bronchial carcinoma was only 25%, with a specificity of 92%. The false-positive detection rate (rate of false positives among all positives) was high (80%). Thus, the incidence of false-positive bronchial washings was four times greater than that of true-positive (Table 5).

TABLE 4. NUMBER OF PATIENTS WITH FALSE-POSITIVE BRONCHIAL CYTOLOGY ACCORDING TO PRIMARY TUMOR SITE AND T CLASSIFICATION

Site	*No. Pts*	*T1*	*T2*	*T3*	*T4*	*Total*	*(%)*
Oral cavity	17	—	—	—	—	0	(0)
Oral pharynx	34	—	1	1	—	2	(6)
Hypopharynx	12	1	1	—	—	2	(17)
Larynx	33	—	2	1	1	4	(12)

TABLE 5. CLINICAL RESULTS OF BRONCHIAL CYTOLOGY SPECIMENS

Bronchial Cytology	*No. Pts*	*Clinical Result*	
		Positive for Lung Neoplasm	*Negative for Lung Neoplasm*
Positive	10	2 (True+)	8 (False+)
Negative	93	6 (False−)	87 (True−)
Total	103	8	95

To determine if the source of positive cells (upper versus lower airway) in bronchial washings could be distinguished cytologically, all positive cytologies were reevaluated by the pathologist (T.F.B.) in a blinded retrospective fashion. In neither the original nor rereviewed cytologic specimens was it possible to determine whether the malignant cells were from the lower versus the upper airway. Thus, false positives could not be distinguished from true positives on the basis of the cytomorphology of the malignant cells.

DISCUSSION

A major finding in this study was the high rate of false-positive bronchial washings in patients with primary head and neck cancers. These findings confirm and extend similar results by other investigators[6,7,9-11] and suggest that bronchial washings are not useful in screening for synchronous lung cancer in this patient population. The fact that the incidence of false-positive cytologies in this prospective study (7.8%) was higher than that reported in several prior studies[6-9] may be due to several causes.

Rigid endoscopy was used exclusively in this study, and the majority of prior studies included flexible endoscopy. The use of a rigid endoscope may make contamination of bronchial washings more likely. However, in the study by Johnson et al[9] in which the rigid endoscope was used exclusively, the incidence of false-positive bronchial washings was low (1%).

Passing the bronchoscope along the side of the endotracheal tube may encourage shedding of tumor cells more distally. This possibility is supported by past studies[10,11] that have indicated that bronchial washings can be contaminated with exfoliated malignant cells from upper aerodigestive tract cancers. Garfinkle et al[11] demonstrated that the risk of false-positive bronchial cytology increased more than 300% when a flexible bronchoscope was passed adjacent to an endotracheal tube rather than through it. Denneny and Weisman[10] also found that when the outside of an endotracheal tube from a patient with an upper airway carcinoma is washed, 15 of 67 cytology specimens were suggestive or positive for malignancy. Other means by which contamination of bronchial washings theoretically could occur include spontaneous tumor cell shedding by the patient or contamination by positive pressure ventilation techniques during general anesthesia induction. It is well recognized that epithelial cells from the upper airways often are found in bronchial washings. It is also known that bronchial washings are less sensitive than sputum cytologies in detecting occult bronchogenic carcinoma.[12]

This study included a large number of hypopharyngeal and laryngeal lesions, giving a high probability of endoscopic instrumentation. In five prior studies,[6,7,9-11] 15 of 25 false-positive bronchial cytologies (60%) were from patients with primary tumors arising from laryngeal or hypopharyngeal sites. In our study, six of eight patients with false-positive bronchial cytologies (75%) had primary tumors at laryngeal or hypopharyngeal sites. In the study by Johnson et al,[9] however, in which almost 50% of the lesions were laryngeal, a high incidence of false positives was not observed.

The cytopathologic interpretation and classification of bronchial washings may vary among different institutions and pathologists. It is important to note that the diagnostic threshold criteria are different for squamous cell carcinomas of the upper and lower airways. For upper airway squamous cell carcinomas, a diagnosis of malignancy is made on more stringent cytologic criteria than for lower airway cancers. Severe atypia not related to malignancy is seen more commonly in the upper airway from benign chronic inflammatory processes. In analyzing lower airway cytologies, severe squamous atypia is a less frequent observation and is more likely to be associated with neoplasia. Thus, the cytologic interpretation of cellular atypia without knowing the source of the cells (upper versus lower airway) can be difficult. This factor is especially important when performing routine bronchial washings in high risk populations who have a high incidence of long-term smoking and alcohol usage that may cause atypical changes in the upper and lower aerodigestive tract. Because of differences in interpretation of cytologic thresholds, the incidence of false-positive bronchial washings may differ by institution. In this study, over 95% of the patients were long-term smokers and at least moderate users of alcohol.

The effectiveness of bronchial washings in detecting pulmonary malignancies was lower in this study than in previous reports. Dellon et al[8] demonstrated that among 17 patients with known simultaneous bronchogenic carcinoma who underwent flexible endoscopy, 14 patients (82%) had tumor cells in their bronchial washings. This may have been due, in part, to the use of flexible endoscopy in obtaining the bronchial washings, since flexible endoscopy may be more sensitive in detecting peripheral lung lesions than is rigid bronchoscopy. Furthermore, in that study bronchial washings were obtained when a known pulmonary malignancy concurrently existed (simultaneous primary lesion). In our prospective study, it would be unlikely that bronchial washings could detect lung cancer developing more than 6 months postendoscopy.

In this study, no occult endobronchial malignancies were detected by bronchoscopy when the chest x-ray results were normal; however, this study cannot address specifically the usefulness of routine bronchoscopy alone in patients with head and neck cancer. In one retrospective study, Maisel and Vermeersch[4] reported that the preoperative chest x-ray study was more useful than bronchoscopy for detecting occult pulmonary malignancies in patients with head and neck cancer. In their study, 17 of 449 patients had synchronous lung primary lesions, and all 17 had abnormal chest x-ray results. Their study suggested that bronchoscopy should not be included in routine diagnostic measures in head and neck cancer patients who have normal chest x-ray results. Nevertheless, two separate prospective studies advocate routine bronchoscopy for screening patients with head and neck cancer, since a 1% to 3% incidence was found of unsuspected synchronous pulmonary tumors that were not evident on chest x-ray films.[5,6] Our findings do not support the use of routine bronchoscopy or bronchial washings in patients with normal chest x-ray results. Bronchoscopy continues to be indicated in the evaluation of subglottic tumor extension in selected laryngeal cancers; however, bronchial washings are not effective in screening such patients for occult lung cancers. If screening in addition to a routine chest x-ray study is warranted, computed tomography of the chest may be more accurate than and as cost-effective as bronchoscopy and bronchial washing.

CONCLUSION

Routine bronchial cytology was of limited usefulness for detecting synchronous pulmonary malignancies in patients with squamous carcinoma of the upper aerodigestive tract. Despite careful rigid bronchoscopic technique, contamination of bronchial washings with exfoliated cells from upper airway cancers apparently does occur, resulting in a high rate of false-positive bronchial cytologies.

The primary tumor sites most often associated with false-positive bronchial cytology were the larynx and hypopharynx. The size of the primary tumor did not appear to be a factor contributing to false-positive bronchial washings. True-positive bronchial cytology was rare, and simultaneous occult pulmonary lesions in patients with head and neck cancer usually can be detected by a preoperative chest x-ray study. Occult synchronous pulmonary cancer in this study was never detected by bronchial washings in patients with normal chest x-ray results.

REFERENCES

1. Vrabec DP. Multiple primary malignancies of the upper aerodigestive system. Ann Otol Rhinol Laryngol 1979;88:846-54.

2. Gluckman JL. Synchronous multiple primary lesions of the upper aerodigestive system. Arch Otolaryngol 1979;105:597-8.

3. Shapshay SM, Hong WK, Fried MP, Sismanis A, Vaughan CW, Strong MS. Simultaneous carcinomas of the esophagus and upper aerodigestive tract. Otolaryngol Head Neck Surg 1980; 88:373-7.

4. Maisel RH, Vermeersch H. Panendoscopy for second primaries in head and neck cancer. Ann Otol Rhinol Laryngol 1981; 90:460-4.

5. McGuirt WF. Panendoscopy as a screening examination for simultaneous primary tumors in head and neck cancer: a prospective sequential study and review of the literature. Laryngoscope 1982;92:569-76.

6. Leipzig B. Bronchoscopy in the staging and evaluation of head and neck carcinoma. Ann Otol Rhinol Laryngol 1983;92: 373-6.

7. Leipzig B, Zellmer JE, Klug D, The Panendoscopy Study Group. The role of endoscopy in evaluating patients with head and neck cancer. A multi-institutional prospective study. Arch Otolaryngol 1985;101:589-94.

8. Dellon AL, Chu EW, Hall CA, Chretien PB. Cytology of bronchial washings. Arch Otolaryngol 1975;101:465-6.

9. Johnson JT, Turner J, Dekker A, Myers EN. Significance of positive bronchial cytology in presence of squamous cell carcinoma of upper aerodigestive tract. Ann Otol Rhinol Laryngol 1981;90:454-6.

10. Denneny JC, Weisman RA. A prospective study of endotracheal tube cytology in head and neck cancer patients. Otolaryngol Head Neck Surg 1985;93:75-8.

11. Garfinkle TJ, Weisman RA, Denneny JC III. Flexible fiberoptic bronchoscopy and pulmonary cytology in the evaluation of patients with head and neck malignancies. Ann Otol Rhinol Laryngol 1981;90:351-3.

12. Koss LG. Diagnostic cytology and its histopathological basis. 3rd ed. Philadelphia: JB Lippincott, 1979:551,1177.

LASER SURGICAL TREATMENT OF CHRONIC TONSILLITIS

GEZA J. JAKO, MD
BOSTON, MASSACHUSETTS

This preliminary report describes a pilot study for a potential alternative for treatment and prevention of chronic tonsillitis and its associated sequelae. Less radical than conventional removal, carbon dioxide laser microsurgery appears to restore normal tonsillar function and is almost free of complications. The anterior tonsillar pillar is removed, blocked crypts are drilled open, and new crypts are created with the CO_2 laser beam. Postoperatively, the patients had less pain than they would have had with tonsillectomy, and no hemorrhages necessitating intervention occurred. All the patients experienced lasting cures during the follow-up period. Although only adult patients were treated, the treatment potentially could be used in the pediatric group.

KEY WORDS — chronic tonsillitis, laser surgery.

INTRODUCTION

Acute and chronic pharyngitis and tonsillitis are frequent illnesses, necessitating over 40 million patient visits per year in the United States.[1] In those patients who still have their tonsils, acute and chronic tonsillar disease accounts for a considerable number of these visits.[2]

In the preantibiotic era, prophylactic tonsillectomy became an accepted modality to avoid or prevent numerous secondary diseases that were attributed to acute and chronic diseases of the tonsils. By the 1950s, over 1 million tonsillectomies were performed annually in the United States,[3] and several million were performed worldwide. Since the mid-1970s, new pharmacologic options and scientific knowledge regarding infectious diseases, immunology, and epidemiology have led to more conservative treatment of tonsillar disease. In many instances, medical treatment has replaced the radical surgical procedure, ie, removal of the tonsils.

It generally is accepted that recurrent acute inflammation caused by bacteria, viruses, or both can lead to the irreversible changes causing chronic tonsillitis. A considerable portion of these irreversible changes now can be prevented by the early administration of antibiotics. In some cases, however, the pathologic bacteria are resistant to the antibiotics, or local antibiotic concentrations are inadequate. In these cases, irreversible changes may develop, leading to chronic tonsillitis.

RATIONALE FOR CONSERVATIVE TREATMENT

In the past two decades, an increasing number of authors have investigated the tonsils and have found that they may have several important functions. It was shown that the epithelium of the normal crypt is suitable for antigen uptake.[4] Antoni and Staub state, "There is no doubt that the tonsils play an important role in both the local control of antigen invasion and the development of the systemic immune response by supplying first hand immunologic information for the immune apparatus."[5(p161)] They also found that a subpopulation of tonsillar lymphocytes produces lysozyme. Based on their studies, Yamanaka et al[6] concluded that the tonsil has a dual role as both an immune organ and an infectious organ.

CHRONIC TONSILLITIS

When the delicate balance between the dual function of the tonsil as an immunologic antigen provider and infectious organ shifts toward the infectious side, and this cannot be rebalanced by medical treatment, irreversible changes can result that can lead to chronic tonsillitis.

The signs and symptoms of these changes, as well as the histopathologic features, are well known to laryngologists and have been described by many.[7,8] The changes are caused by the long-lasting irreversible dysfunction of the cryptal epithelium. In most cases, the cryptal flow is damaged and disturbed by mechanical blockage[9] (Fig 1). According to Osborn and Roydhouse,[10] these obstructions can develop if early, adequate, and effective antibiotic treatment is not administered. It long has been observed that buried (submerged) or retracted tonsils in adults more frequently cause local symptoms and secondary ailments.[11-13] These tonsils are generally small and appear even smaller since the anterior pillar obstructs their view. In this case, the muscles of the anterior and posterior pillars can form a constricting muscular ring, and pressure by this ring can squeeze crypt material inward rather than outward (Fig 2A,B).

In my observations in children with large hypertrophied tonsils, the contour of the anterior pillar appears to be concave. In adults with submerged tonsils, the anterior pillar appears to be straight

From the Department of Otolaryngology, Boston University School of Medicine.
Presented at the meeting of the American Laryngological Association, Denver, April 25-26, 1987.
REPRINTS — Geza J. Jako, MD, 169 E Emerson St, Melrose, MA 02176.

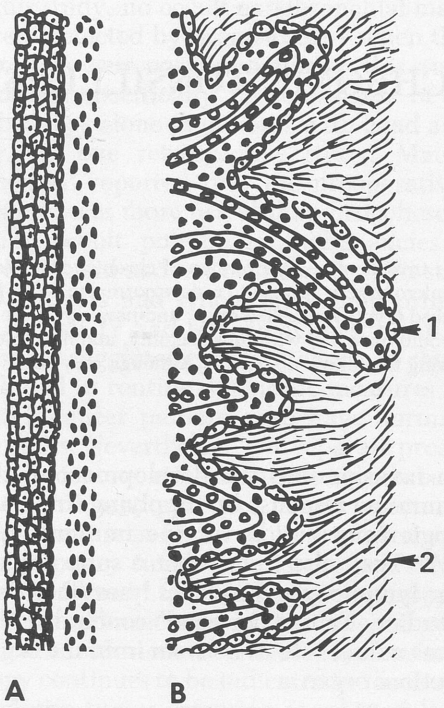

Fig 1. Tonsillar crypts. A) Full thickness squamous epithelium of normal crypt. B) Diseased crypt. 1 — obstructing cryptal valve, 2 — cryptal debris. (Modified after Osborn and Roydhouse.[10])

(Fig 2C,D). It is frequently bulky and obstructs most of the anterior surface of the tonsil. Others have observed also that the anterior pillar can be adherent to the anterior surface of the tonsil, contributing to the blockage of numerous crypts.[14] In this case, the anterior pillar is infected because of the underlying periodic infection in the blocked crypts.

CRYPTS

The macroscopic and microscopic anatomy of the crypts have been studied in subjects of all ages. In both children and adults, there are about ten to 20 crypts in each tonsil, the number, shapes, and sizes of which can change during life. Rarely, blocked crypts may marsupialize to the surface or anastomose with other crypts. More frequently, cysts containing infected material are formed. With aging, the number of crypts usually decreases sometimes to as few as one, and multiple infected cysts can form[15] (Fig 3).

The large hypertrophied tonsils found in children undergo an involution and may even sink laterally deeper into the tonsillar fossa, causing the concave-appearing and stretched anterior pillar to become straighter and bulkier. The upper pole of the tonsil frequently is covered by the supratonsillar (semilunar) plica, which blocks the four to six crypts that normally would empty into the throat directly. The triangular plica, which contains lymphoid elements and glands, can swell or change position and block crypts at the lower pole.

These predisposing anatomic abnormalities may be a major factor in the pathogenesis of chronic tonsillitis. In my personal observations, about three fourths of the young adult and adult patients having symptoms of chronic tonsillitis have the submerged type of tonsils with blocked crypts. Thus, I felt that a rational treatment of chronic tonsillitis would be to remove the anterior pillar and reopen the blocked crypts. Based on my previous developmental work and experience, carbon dioxide laser microsurgery was the obvious answer.[16,17]

TECHNIQUE

The patient is placed under general anesthesia and put in Rose's position. The endotracheal tube is protected by metal foil. Aluminum foil is wrapped around the lips and teeth before the mouth gag and self-retaining tongue depressor are inserted. The aluminum foil prevents laser injury to the lips or teeth. The newly developed CO_2 laser operating microscope is brought into position (Fig 4A). Color photographs are taken for documentation. First, a U-shaped incision is made, starting superiorly from the uvula to the lateral border of the tonsil, turning inferiorly, and at the inferior border of the tonsil turning medially (Fig 4B). Then the upper edge of the anterior pillar is held with a curved hemostat and the pillar is peeled bloodlessly off the anterior surface of the tonsil (Fig 4C). A small front surface

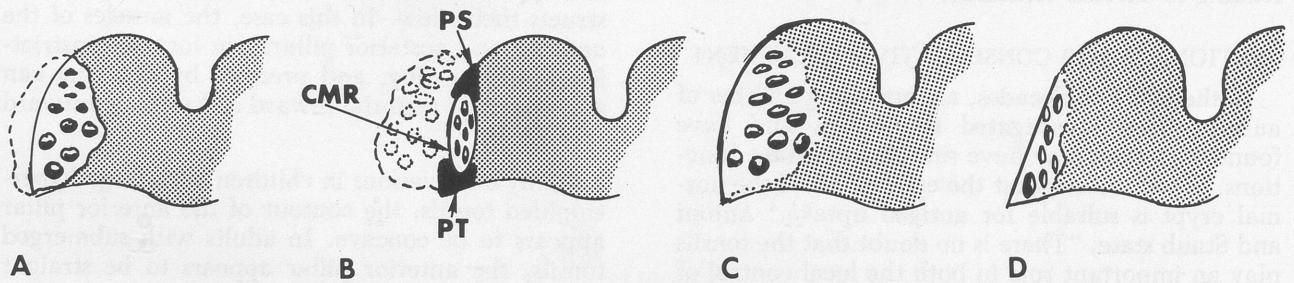

Fig 2. Examples of tonsils. A) Normal or moderately hypertrophied. Crypts are open directly into throat. Muscular contractions of anterior and posterior pillars facilitate cryptal drainage into throat. B) Submerged. Many of crypt openings are blocked by anterior pillar, which with plica triangularis (PT), plica semilunaris (PS), and edge of posterior pillars forms constricting muscular ring (CMR) around submerged tonsil. C) Contour of anterior pillar in children with large hypertrophied tonsils appears concave. D) In adults with smaller or submerged tonsils, contour of anterior pillar appears straight.

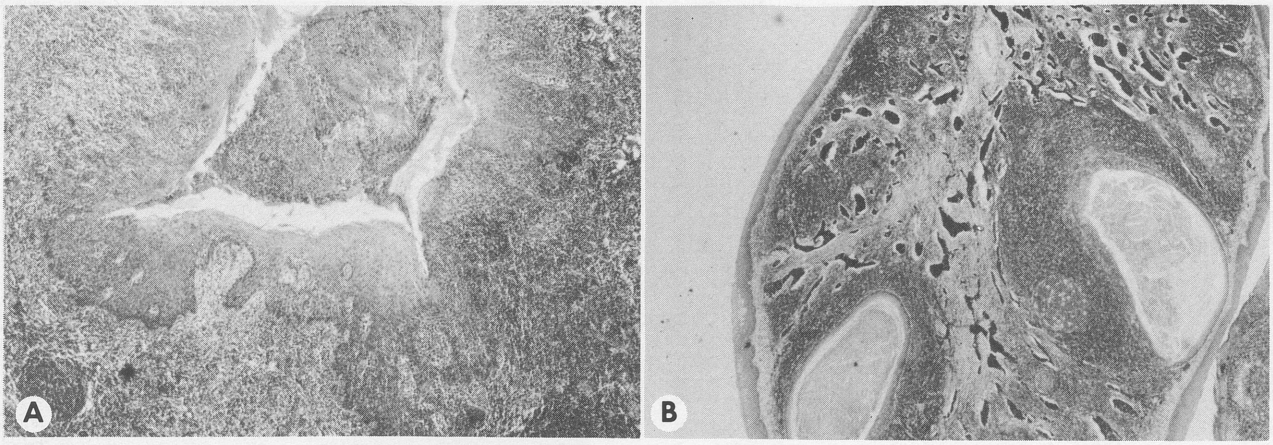

Fig 3. Tonsillar crypts. A) Dilated and filled with debris, and B) blocked and enlarged, showing cystic appearance.

dental mirror is sometimes helpful to direct the laser beam at an angle. Superiorly, the plica semilunaris and, inferiorly, the plica triangularis are removed by peeling and evaporation. Laterally, the tonsil is released slightly by pulling the tonsil toward the midline and separating the capsule from the tissue of the tonsillar fossa. This cut is made only superficially and stopped above the tonsillar artery. Then the anterior surface of the tonsil with partially or totally blocked crypts is inspected under the microscope. A plan is made to drill open the blocked crypts on the anterior and medial surface of the tonsil with a 1.5-mm diameter CO_2 laser beam. The purpose is to create new crypts by drilling, marsupialize the old crypts, and connect crypts (Fig 4D). Debris or pus is frequently found and can be cultured and then removed or evaporated.

The procedure is done under magnification with minimal trauma. Forceful pulling of tissues should be avoided, in which case most of the procedure is usually bloodless. Small bleeding vessels can be stopped easily with 6.5-cm^2 (1 sq in) epinephrine-soaked surgical pads and laser coagulation. Larger arteries could require needle electrocoagulation with the aid of suction. During laser drilling, care is taken not to burn tonsillar tissue unnecessarily. This can be avoided by step-by-step drilling and applying saline-soaked pads to the drilled area. The plica triangularis is peeled off, or part of it is evaporated, and the tonsillar area underneath also is drilled. Generally, seven to 12 drillings are made, stopping before the tonsillar capsule. Before proceeding to the opposite side, all bleeding is controlled. Then the mouth gag, tongue retractor, and endotracheal

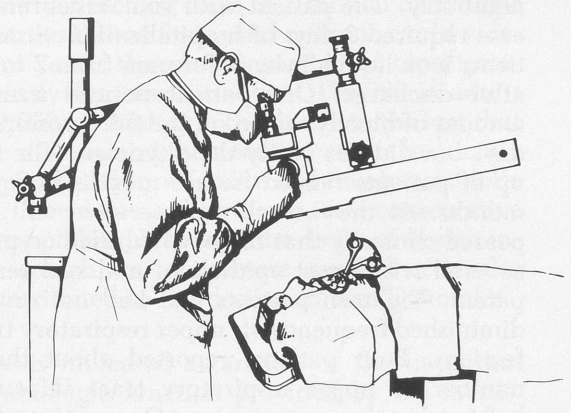

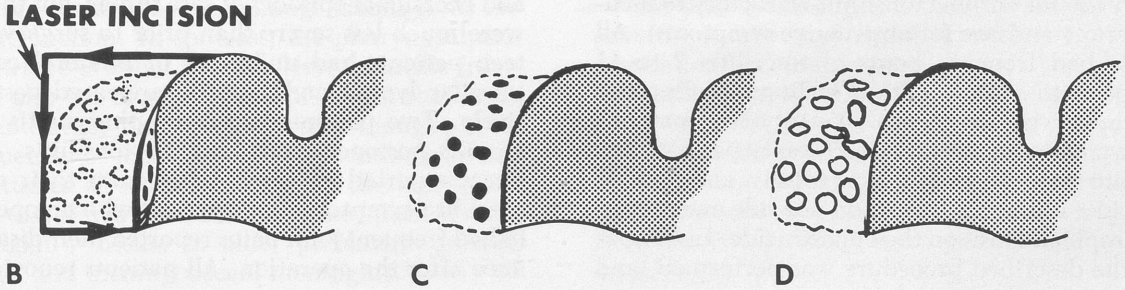

Fig 4. Operative technique. A) Jako carbon dioxide laser operating microscope. Patient is in Rose's position and tonsillar exposure is attained by use of mouth gag and self-retaining tongue retractor. Aluminum foil is used to shield lips and teeth. B) Laser incision for removal of anterior pillar. C) Anterior pillar is removed and blocked crypts are visible under microscope. D) Blocked crypts are drilled open and new crypts are created with CO_2 laser beam.

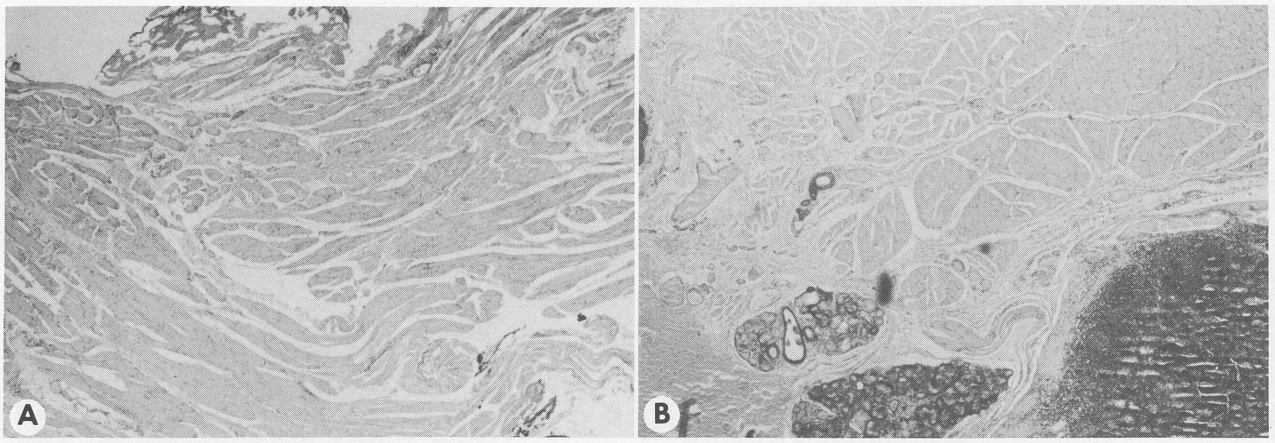

Fig 5. Anterior pillars. A) Cross section showing laser excision and muscle fibers. B) Removed from 55-year-old woman; shows pillar's structures with adherent lymphoid tissue.

tube are repositioned, and the procedure is completed on the other tonsil.

During the operation, care is taken to protect the endotracheal tube by positioning it toward the other side. The surrounding tissues are protected by wet pads and the patient's face by wet towels. The smoke and vapor have to be aspirated carefully. The eyes of the operating room personnel are protected by safety goggles. At the completion of the procedure, the appearance of the operated tonsils is documented by color photography (Fig 5). It is estimated that the drilling will remove approximately 10% of the tonsil mass.

POSTOPERATIVE CARE AND MORBIDITY

The patients generally are kept in the recovery room for 1 to 2 hours. Depending on their postanesthesia condition, they may be discharged in 6 to 8 hours. Postoperative pain depends on the patient's individual sensitivity and on the degree of surgical trauma. Some patients require Demerol in the hospital. For others, acetaminophin with codeine is sufficent, and some patients request no pain medication. The first postoperative days are generally considerably less painful than after tonsillectomy. Diet is similar to the post-tonsillectomy diet. Patients are seen 1, 3, and 8 weeks postoperatively.

RESULTS

Twenty-seven patients were operated on by the author. All were unequivocal candidates for tonsillectomy (26 for chronic tonsillitis refractory to medical therapy and one for obstructive symptoms). All patients had frequent bouts of tonsillitis 2 to 11 years prior to surgery with a feeling of fullness in the oropharynx or tonsils. Twenty-two patients were available for evaluation. Twenty patients had moderate size, submerged type tonsils, and one patient had a submerged tonsil on one side and a large hypertrophied tonsil on the opposite side. In this patient, the described procedure was performed, and the large hypertrophied tonsil was partially resected with the laser beam. One 33-year-old man who had grade 4+ hypertrophied tonsils and requested removal because of heavy snoring had laser resection (tonsillotomy) and removal of the anterior pillars. This patient had von Willebrand's disease, and for this reason, the laser procedure was chosen instead of tonsillectomy. This patient had postoperative bleeding, which was controlled with the administration of frozen plasma.

Four patients had bad breath (fetor oris) of tonsillar origin, which was eliminated with the treatment. There were 18 female and four male patients. In this group of patients, the youngest patient was 14 and the oldest was 42. Four patients were discharged on the day of surgery, and 18 after an overnight stay. The patient with von Willebrand's disease required 3 days of hospitalization. Sixteen patients took liquid Tylenol for pain from 2 to 6 days after discharge. One patient noticed a minimal amount of bloody mucus on the third postoperative day, but did not notify the physician. The follow-up of patients ranged from 6 months to 6 years 8 months. At the 8-week postoperative visit, it appeared clinically that the newly drilled crypts were covered with crypt epithelium and had remained patent. Eighteen patients had had no, or greatly diminished frequency of, upper respiratory tract infections. Four patients reported about the same number of upper respiratory tract infections as before, but less severe ones. One patient had an acute follicular tonsillitis 6 months postoperatively and occasional episodes of sore throat, but the latter were much less severe than prior to surgery. Eighteen patients had unilateral or bilateral cervical-tonsillar lymph nodes. All disappeared postoperatively. Two patients had acute pharyngitis several months postoperatively, but no tonsillitis. All patients reported excellent relief from their chronic tonsillitis symptoms. One patient who preoperatively had frequent joint pains reported their disappearance after the operation. All patients reported that

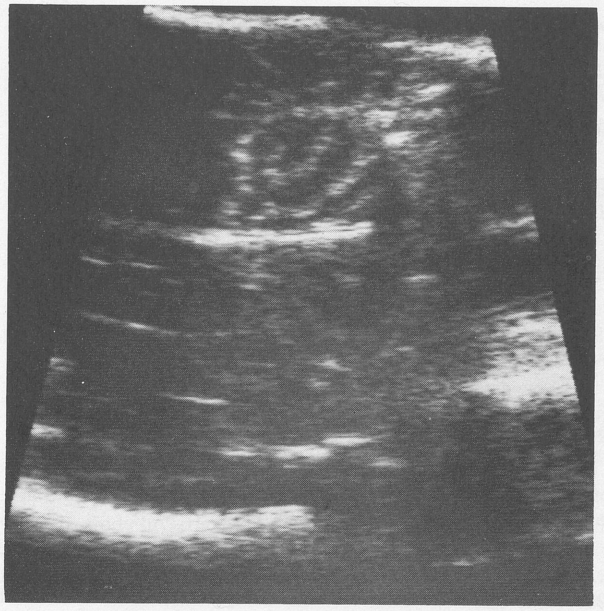

Fig 6. Ultrasonic scan picture demonstrating removed tonsil and its internal structure; taken with 10-MHz thyroid transducer.

their lives changed for the better after the surgery, and no patients felt that the surgery was not helpful.

DISCUSSION

Until now, the definitive treatment of chronic tonsillitis in adults and children necessitated a radical surgical procedure, tonsillectomy. Preventive tonsillectomy also was practiced for decades in this century, reaching close to 2 million operations yearly in the United States and millions worldwide. In recent years, the annual number of tonsillectomies greatly decreased, to about 175,000 in adults and 300,000 in children.[3] This is due to the fact that tonsillar diseases and their complications frequently can be prevented by effective and timely antibiotic therapy. The decreased birthrate, new conservative treatment philosophies, and the desire of health insurance companies to decrease surgical costs also have contributed to the decline in tonsillectomies.

There is increased awareness of the important immunobiologic function provided by the tonsils. The surface area of the normal cryptal epithelium can be as large as 300 cm^2 (600 cm^2 for both tonsils). This large surface for interchange attests to its important function. In contrast, the pharyngeal mucosal surface is about 60 cm^2. New scientific information also has changed concepts about rheumatic fever and other diseases previously thought to be consequences of focal infection. Epidemiologic and other studies also seem to indicate the increase of certain diseases in the tonsillectomized patient, such as Hodgkin's disease in older patients,[18] prostate cancer,[19] and meningococcal meningitis.[20]

On the other hand, irreversibly damaged crypt function creates local symptoms: sore throat, fetor oris,[21] enlarged cervical lymph nodes, and a feeling of fullness in the tonsils. Focal tonsillar disease is associated with decreased immunoglobulins and secondary diseases such as glomerulonephritis, arthritis, pustulosis palmaris,[22] and other diseases. Markedly increased pathologic bacterial counts have been found in chronically diseased tonsils.[23] Pathogenic, aerobic and anaerobic antibiotic-resistant bacteria are commonly isolated from tonsils.[24] Bacteria and bacterial toxins can enter the lymphatic system, causing enlargement of the tonsillar (subtonsillar) lymph node. In a study by Sasaki and Koss,[23] 80% of patients with chronic tonsillitis were found to have cervical adenopathy. Direct spread of bacteria into the blood also can take place. This may lead to a new realization of the importance of the chronically infected tonsil. This is especially relevant in light of the expected increase in the incidence of chronic tonsillitis now that fewer tonsillectomies are performed in childhood.

The present work was directed to young adult and adult patients. The rationale of the operation and the satisfactory results in adults make the extension of this treatment into certain childhood groups feasible. Partial resection of a large obstructive tonsil by laser aided by electrosurgery, and the removal of the anterior pillar and creation of new crypts by laser drillings, appears to be practical.

It is conceivable that this less traumatic, reconstructive treatment will spur more research activity in the pathomechanism of chronic tonsillitis. Future histologic studies, both experimental and clinical, need to be performed for us to better understand crypt formation by laser drilling. One also can foresee, with new biotechnologic developments, the potential utilization of the tonsillar lymphocytes for new diagnostic studies of tonsillar diseases and other benign and malignant diseases. Ultrasonic techniques potentially may be used for imaging the changes induced by chronic tonsillar disease. Preliminary ultrasonic studies of removed tonsils have permitted the visualization of structural changes (Fig 6).

CONCLUSIONS

This pilot study suggests that laser treatment may provide a new and effective alternative for the prevention and treatment of chronic tonsillitis and associated diseases. The procedure is simple and appears relatively free of complications. It is hoped that this study will spur new scientific and clinical investigations. Since chronic tonsillitis affects millions of people around the world, this new procedure potentially could have major significance in health care.

ACKNOWLEDGMENT — I am indebted to Howard Herman, a senior medical student at Boston University, for his contributions to this paper.

REFERENCES

1. Cypress BK. Office visits for diseases of the respiratory system. Hyattsville, Md: Department of Health, Education and Welfare, 1979:18.

2. State of the art and current problems. In: Workshop on tonsillectomy and adenoidectomy. Ann Otol Rhinol Laryngol 1975; 84(suppl 19):8-14.

3. Bluestone CD. Status of tonsillectomy and adenoidectomy: 1977. Laryngoscope 1977;87:1233-43.

4. Surjan L Jr. Reduced lymphocyte activation in repeatedly inflamed human tonsils. Acta Otolaryngol (Stockh) 1980;89: 187-94.

5. Antoni F, Staub M, eds. Tonsils: structure, immunology and biochemistry. Budapest: Hungarian Academic Press, 1978.

6. Yamanaka N, Sambe S, Kataura A. Conceptual understanding of pustulosis palmaris et plantaris as an immune complex disease due to focal tonsillar infections. Acta Otolaryngol [Suppl] (Stockh) 1983(suppl 401):31-5.

7. Pratt LW. Infections of the lymphoid tissue. In: English GM, ed. Otolaryngology. Chapter 27. Philadelphia: Harper & Row, 1980.

8. Kornblut AD. Non-neoplastic diseases of the tonsils and adenoids. In: Paparella MM, Shumrick DA, eds. Otolaryngology. Vol 3. Philadelphia: WB Saunders, 1980:2263-81.

9. Ballenger WL, Ballenger HC. Diseases of the nose, throat and ear: medical and surgical. Philadelphia: Lea and Febiger, 1930.

10. Osborn GR, Roydhouse N. The tonsillitis habit. Auckland, New Zealand: WP Roydhouse, 1976.

11. Mithoefer W. The submerged tonsil. Lancet Clinic 1909; 102:572-5.

12. Shambaugh GE. The faucial tonsils as a focus for systemic infection. Ann Otol Rhinol Laryngol 1913;22:659-65.

13. Hill FT. What is wrong with the tonsil operation? Ann Otol Rhinol Laryngol 1926;35:913-36.

14. Gibb JS. Some observations upon the complete extirpation of the diseased faucial tonsil. Trans Am Laryngol Assoc 1909; 31:191-209.

15. Kelemen G. The palatine tonsil in the sixth decade. Ann Otol Rhinol Laryngol 1943;52:419-43.

16. Jako GJ. Laser surgery of the vocal cords. An experimental study with carbon dioxide lasers on dogs. Laryngoscope 1972; 82:2204-16.

17. Strong MS, Jako GJ. Laser surgery in the larynx. Early clinical experience with the continuous CO_2 laser. Ann Otol Rhinol Laryngol 1972;81:791-8.

18. Mueller H, Swanson GM, Hsich CC, Cole P. Tonsillectomy and Hodgkin's disease: results from companion population-based studies. J Natl Cancer Inst 1987;78:1-5.

19. Whittmore AS, Paffenbarger RF Jr. Early precursors of site specific cancer in college men and women. J Natl Cancer Inst 1985;74:43-51.

20. Kristiansen BE, Elverland H, Hannestad K. Increased meningococcal carrier rate after tonsillectomy. Br Med J [Clin Res] 1984;288:974.

21. Castellani A, Florence MD. Fetor oris of tonsillar origin and certain bacilli causing it. Lancet 1930;1:623-4.

22. Tabata T. Preface. Symposium on pustulosis palmaris et plantaris and tonsil-focus. Acta Otolaryngol [Suppl] (Stockh) 1983(suppl 401):5.

23. Sasaki CT, Koss N. Chronic bacterial tonsillitis: fact or fiction. Otolaryngology 1978;86:858-64.

24. Brook I, Yocum P. Bacteriology of chronic tonsillitis in young adults. Arch Otolaryngol 1984;110:803-5.

VOCAL TRACT ELECTROMYGRAPHIC ABNORMALITIES IN SPASMODIC DYSPHONIA

PRELIMINARY REPORT

STEVEN SCHAEFER, MD
DALLAS, TEXAS

BEN WATSON, PHD
DALLAS, TEXAS

FRANCES FREEMAN, PHD
DALLAS, TEXAS

GEORGE KONDRASKE, PHD
ARLINGTON, TEXAS

KENNETH POOL, MD
DALLAS, TEXAS

LANNY CLOSE, MD
DALLAS, TEXAS

TERESE FINITZO, PHD
DALLAS, TEXAS

This study investigates peripheral neuromotor manifestations of spasmodic dysphonia (SD) in terms of two broad questions. 1) What are their salient characteristics? 2) What is the extent of vocal tract involvement? Using an experimental protocol designed to address these questions, electromyographic (EMG) signals were recorded from three subjects with adductor SD, one subject with abductor SD, and three normal control subjects. Simultaneous recordings were obtained from multiple vocal tract muscles, using indwelling hooked-wire electrodes, while subjects performed vegetative, paralinguistic, and linguistic tasks. Herein, we report preliminary qualitative and quantitative analyses of EMG data that both demonstrate the potential of multichannel vocal tract EMG in addressing the questions posed and enhance our understanding of the neurophysiology of pathologic speech.

KEY WORDS — laryngeal electromyography, spasmodic dysphonia, vocal motor control.

INTRODUCTION

Spasmodic dysphonia (SD) is a voice disorder of unknown cause with variable clinical presentation and response to treatment. Recently, measures of neural function have implicated the CNS in etiologic models of the disorder.[1-10] Cortical and subcortical structure and function have been assessed via magnetic resonance imaging, single photon emission computed tomography, brain electrical activity mapping, and auditory brain stem response.[1-4,7,8] Peripheral manifestations of CNS activity have been characterized by acoustic/perceptual voice analyses, visceral vagal testing, and laryngeal electromyography (EMG).[5,6,11-17] These studies support the concept that SD is a neurogenic disorder predominately localized above the brain stem (ie, upper motor neuron), involving perhaps cortical or subcortical structures.

The majority of measures of neuromotor function in SD have involved acoustic/perceptual analyses because such measures are noninvasive and data are obtained easily for large numbers of subjects. Using information obtained from acoustic/perceptual analyses, we and others have attempted categorical differential diagnosis of SD subjects.[9,10,18-21] However, intrasubject variability in vocal characteristics introduced reliability problems. We attempted to overcome reliability problems by increasing the number of tasks, the number of diagnostic sessions, the specificity of instructions given subjects, and the methods of analyzing data. This increased observed performance variability and exacerbated problems of reliability.

Vocal performance in SD is task-dependent.[1,9,10,19-21] Some tasks result in improved vocal performance for most subjects with SD, while others result in performance decrements. Further, certain vocal characteristics tend to be present (or acoustically measurable) in some tasks, and absent (or acoustically unmeasurable) in others. Finally, vocal characteristics of subjects with SD can be manipulated systematically by instructions, and these manipulations can produce similar responses across large numbers of subjects with SD. Thus, initial intrasubject variability problems yielded findings of systematic intersubject patterns.[9]

These findings led to the conclusion that variability in vocal performance is not a random phenomenon. Consequently, our goal has become that of defining the underlying rules of this phenomenon. This objective is based on two assumptions. First, understanding the rules will clarify the nature of the underlying motor control deficit(s) and possibly the neuropathophysiologic basis of the disorder. Second, such understanding will guide behavioral

From the Department of Otorhinolaryngology, University of Texas Health Science Center at Dallas (Schaefer, Close), the Callier Center for Communication Disorders, University of Texas at Dallas (Watson, Freeman, Finitzo), the Biomedical Engineering Program, University of Texas at Arlington (Kondraske), Dallas Neuroscience Associates (Pool), and the Dallas Center for Vocal Motor Control. Supported in part by National Institute of Neurological and Communicative Disorders and Stroke grant 18276-04 awarded to the University of Texas at Dallas.

Presented at the meeting of the American Laryngological Association, Denver, April 25-26, 1987.

REPRINTS — Steven D. Schaefer, MD, Dept of Otorhinolaryngology, University of Texas Health Science Center at Dallas, 5323 Harry Hines Blvd, Dallas, TX 75235.

TABLE 1. SUMMARY OF PREVIOUS ELECTROMYOGRAPHIC FINDINGS IN PATIENTS WITH SPASTIC DYSPHONIA

Investigator(s)	*Population*	*Muscles Sampled*	*Tasks*	*Findings*	*Comments*
Tarasch[11]	9	Surface electrodes on neck, tongue	Phonatory	Asymmetric spasms	Psychosomatic illness related to organic illness
Rabuzzi and McCall[12]	Several	Intrinsic laryngeal muscles	Avocal contractions	—	SD suggested as organic disorder
Blair et al[13]	6	TA, CT	Phonatory	Normal activity	—
Hirose[14]	28	TA, CT	Phonatory	Grouping of voltages in adductors	Little information on EMG findings in SD
Fritzell et al[15]	3-4	TA, CT	Phonatory	Bursts of activity on vocalization	Partial reinnervation shown after RLN section
Shipp et al[16]	1	PCA, IA, TA, CT (bilateral)	Phonatory, nonphonatory	Normal PCA activity during breath holding; irregular IA and TA activity on voicing (bursts of activity immediately prior to vocal arrests); sporadic CT activity at normal pitch, steady activity at falsetto	Eradication of contralateral abnormal adductor activity by unilateral RLN paralysis
Blitzer et al[17]	14	TA, CT (bilateral)	Phonatory, swallowing	Abnormal activity in TA and CT (polyphasic potentials, R/L amplitude disparities, asynchronous activity, bursts) in 7 of 14 subjects	No patterns consistent with spasticity

TA — thyroarytenoid muscle, CT — cricothyroid muscle, PCA — posterior cricoarytenoid muscle, IA — interarytenoid muscle, RLN — recurrent laryngeal nerve.

management (voice therapy) and medical therapy for rehabilitating individuals with SD. At its conclusion, this work should provide insights into whether SD is 1) a unitary disorder with symptom continua, 2) a unitary disorder with subgroups categorizable by symptoms, or 3) two or more disorders with similar symptoms.

Levels of data acquisition used in most studies (eg, perceptual, acoustic, and fiberoptic visualization) are not adequate to evaluate these three alternatives.[9,10,18-21] These levels are too far removed from the neuromotor breakdown for generation of valid inferences about an underlying neuropathophysiologic disorder. Instead, we need information at the neuromuscular level, that is, EMG recordings.

Table 1 summarizes several studies reporting EMG findings in SD patients.[11-17] With respect to evaluating the alternatives outlined above, these studies have several methodologic limitations. For example, when multiple muscles were studied simultaneously, a small number of subjects were used. When larger numbers of subjects were studied, only one or two muscles were investigated. More importantly, all of the previous EMG work used a limited sample of vocal tasks. If vocal performance is task-specific, then only an experimental design incorporating a variety of tasks will elicit a spectrum of behavioral and associated electrophysiologic responses.[9,21]

The goal of this preliminary report is twofold. First, we explore the utility of EMG as a technique to address two questions regarding neuromotor abnormalities in vocal motor control in SD. 1) What are their salient characteristics? 2) What is the extent of vocal tract involvement? Second, we use qualitative and quantitative observations to generate additional questions regarding the nature of underlying motor control deficits and to provide guidance for in-depth study of larger numbers of subjects. To this end, we report selected examples of EMG signals recorded from multiple insertion sites within the vocal tract during tasks representing continua of increasing motoric and linguistic complexity. These examples illustrate gross neuromuscular behavior during primarily steady state activation. This focus differs from other clinical uses of EMG such as detection of peripheral neuropathy or specific myopathy.

METHODOLOGY

Subjects. Simultaneous recordings of acoustic and EMG signals were obtained from three men and one woman with SD and three age- and sex-matched normal controls. Table 2 summarizes relevant characteristics of SD and control subjects. Diagnoses of SD were confirmed by two otolaryngologists and two speech/language pathologists. None of these subjects evidenced movement disorders. Subject SD2 had visual-spatial deficits subsequent to the closed head injury noted in Table 2. Subject SD3 had a paternal history of hand tremor. These subjects were selected from a larger population of SD patients that have been evaluated by the authors over the past 6 years.[1-10,20] Prior to initiating EMG studies, informed consent was obtained from all subjects in accordance with regulations of the Institutional Review Board of the University of Texas Health Science Center at Dallas.

Muscle Selection. Table 2 summarizes muscles from which verifiable EMG signals were recorded

TABLE 2. SUBJECT PROFILES

Subject	*Sex*	*Age (yr)*	*Presumed Cause of SD*	*Fiberoptic Findings*	*Perceptual Vocal Characteristics*	*Duration of Symptoms*	*Muscles Sampled*
SD1	M	41	Unknown	Normal	Adductor, no tremor	14 yr	TA, CT, LP, IT
SD2	M	47	Closed head injury	Hyperactive adduction laryngeal tremor	Adductor, with tremor	4½ yr	Both CT, LP, IT
SD3	M	44	Unknown	Normal	Adductor, no tremor	3 yr	TA, CT, LP, IT
SD4	F	43	Unknown	Intermittent incomplete laryngeal closure	Abductor, with tremor	3 yr	TA, strap, LP, GGP
C1	M	40		Normal	Normal		CT, strap, LP, IT
C2	M	41		Normal	Normal		CT, strap, LP, IT
C3	F	46		Normal	Normal		CT, strap, TA, IT

CT — cricothyroid muscle, LP — levator veli palatini muscle, GGP — posterior genioglossus muscle, TA — thyroarytenoid muscle, IT — intrinsic tongue muscle (general term used because in development of experimental procedures we did not record from same IT in all subjects. All IT insertions were anterior and relatively superficial and showed activity for tongue tip elevation and advancement and for speech gestures such as /pʌtʌkʌ/).

from each subject. Given individual subjects' ability to tolerate this invasive procedure and our current facility limitations of four-channel EMG recording, preliminary experiments were designed to obtain as much data as possible from each subject. To accomplish this goal, the ideal session recorded EMG signals from hooked-wire electrodes inserted within the thyroarytenoid muscle (TA), the ipsilateral cricothyroid muscle (CT), the levator veli palatini muscle (LP), and an intrinsic tongue muscle (IT). This permitted assessment of muscles innervated by two divisions of the vagus nerve at the level of the larynx (innervating the CT and TA) and the pharyngeal plexus, which includes the vagus (innervating the LP) and the hypoglossal nerve (innervating the IT). In the worst case condition, the LP, an IT, and both CTs (or one CT and one strap muscle) were sampled. This allowed assessment of muscles innervated by the pharyngeal plexus, the hypoglossal nerve, and the superior laryngeal nerve. Overall, our approach was designed to focus on the larynx, but also allowed evaluation of nonvagal neuromotor activity.

Electrode Insertion, Verification, and Recording Procedures. Before electrode insertion, examination of the vocal folds was performed using either an Olympus flexible nasolaryngoscope (type L) or a rigid endoscope coupled to a Wolf 5011 Stroboskop generator with simultaneous video recording. Superficial skin or mucous membrane at each insertion site was anesthetized with 1% Xylocaine or 4% cocaine, respectively.

Bipolar hooked-wire electrodes, either 0.05-mm (0.002 in) coated platinum wire (Semiconductor Packaging Materials, Inc) or 80-μm coated copper wire (Wolf model 8296.02), were inserted either perorally or percutaneously. The exposed or recording surface of all electrodes was approximately 1 mm in length (as recommended by Shipp et al[22] and Basmajian[23]). Output from each of four electrode pairs was routed to separate EEG amplifiers (Grass Instruments model 7P511). Amplifier filters were set at a bandwidth of 100 Hz to 3 kHz. The impedance at each input terminal of the preamplifiers was 20 MΩ. Sensitivity varied from 5 to 20 μV/mm depending on the electrode configuration (eg, bipolar or monopolar). Verification of insertions followed procedures developed at Haskins Laboratories and was based on appropriateness of electrical activity for a given muscle during specific maneuvers.[24-26]

Speech acoustic and EMG signals were monitored on the CRT of a four-channel EMG (TECA model TE4) during experimental sessions and recorded on ¼-in tape (Vetter Instrumentation Recorder) for subsequent review and computer analysis. At the completion of all the experimental tasks, free ends of each pair of hooked-wire electrodes were joined to form four monopolar electrodes. A reference electrode was placed over a neutral muscle and the entire task sequence was repeated. This provided two advantages. First, a broader recording field was available for comparison with the bipolar condition. Second, useful information could be obtained from shorted bipolar electrodes converted to monopolar mode.

Experimental Tasks. Acoustic and EMG signals were recorded while subjects produced multiple repetitions of the 23 tasks summarized in Table 3. These tasks were chosen to meet several criteria. First, tasks ranged from vegetative nonvocal through cognitive-linguistic, thus involving different levels of subcortical and cortical neuromotor control. Second, tasks varied from simple to complex in terms of temporal constraints and/or motor organization. Third, as illustrated in Fig 1, we included tasks presumed to be controlled primarily by the right or left brain hemisphere in order to investigate the cortical laterality of neuromotor control deficits in SD. Finally, we included tasks requiring temporal coordination of antagonistic or synergistic muscle groups. As a preliminary communication, we report selected, mainly steady state tasks that highlight the potential utility of a multitask research design, are easily quantified in terms of integrated average activity, and begin to address the questions posed in the Introduction.

Data Analysis. Electromyographic and acoustic signals, as well as 50-μV calibration signals recorded during each experimental session, were low pass fil-

TABLE 3. TEST CONDITIONS

Task No. and Task		*Approximate Task Duration*	*Major Vocal Tract Components*
Vegetative nonvocal			
1	Inspiration-expiration	15 s @ 16 breaths/min rate	Larynx
2	Breath holding	As long as possible, 3 times	Larynx
3	Swallowing	3 times	Tongue, velum, larynx, pharynx
Vegetative vocal			
4	Sigh	5 times	Larynx
Vocalization, affective			
5*	Repeated laughing	5 s	Larynx
6*	Repeated growl	5 s	Larynx
Vocalization, paralinguistic exclamations			
7	Phonation of /i/ at "normal" intensity and modal pitch	As long as possible	Larynx
8	Phonation of /i/ ascending/descending scale	5 s	Larynx
9	Phonation of /s/ and /z/	As long as possible	Tongue, larynx
10	Phonation of /m/	As long as possible	Velum, tongue, larynx
11	Saying "uh-oh" (oops)	5 times	Tongue, larynx
12	Saying "aha"	5 times	Larynx
13	Saying "mm . . . uh" (uncertainty)	5 times	Velum, larynx
14	Saying "uh-uh" (no)	5 times	Velum, larynx
15	Slow and fast production of syllable triplets /pʌtʌkʌ/ and /bʌdʌgʌ/	15 s	Lips, tongue, velum, larynx
16	Humming "Old McDonald's Farm," low volume	30 s	Larynx
Linguistic, automatic			
17	Counting 1 to 10	1 time	Vocal tract
18	Days of week	1 time	Vocal tract
19	Months of year	1 time	Vocal tract
Linguistic, propositional			
20	Singing "Old McDonald's Farm"	30 s	Vocal tract
21	Reading "Old McDonald's Farm"	30 s	Vocal tract
22	Answering questions (President, Vice President, day of week, first President)	45 s	Vocal tract
23	Reaction time for production of /i/ on visual cue	180 s	Vocal tract

*Since these tasks may dislodge electrodes, they are performed last. Task sequence is repeated at least twice during session.

tered and digitized at a 4-kHz sampling rate (12-bit analog-to-digital resolution) on an LSI 11/73 laboratory computer. Electromyographic signals were low pass filtered at 700 Hz to eliminate tape recorder noise above this frequency. The acoustic signal was low pass filtered at 1.8 kHz. Hard copy plots of time-synchronous EMG and speech acoustic signals were produced on a Hewlett-Packard plotter and constitute the preliminary qualitative data reported in this paper.

Digitized EMG signals were rectified (ie, absolute value was computed) and then processed to determine mean, standard deviation, and minimum and maximum values in analog-to-digital units for each task. Percentage change in average activity relative to a reference task also was computed for each muscle. Reference tasks were selected as representing theoretic maxima of muscle activity. This percent change value was used to indicate differences in activity across tasks for a given muscle for each subject.[27] This value has the advantage of being independent of calibration factors (gains or attenuations) associated with the electrode configuration, amplifier, and recording system, since these factors represent constants that multiply both the numerator and denominator and cancel each other out when the percentage is computed.

RESULTS

We begin by addressing the first question posed in the Introduction: "What are the salient characteristics of the neuromotor abnormality in SD?" The diversity of tasks employed and muscles sampled in our experimental design permits consideration of this question from several different perspectives. We limit this report to findings regarding 1) the relationship between neuromotor abnormalities, as represented in EMG signals, and acoustic/perceptual characteristics of vocal performance; and 2) changes in activity levels in specific muscles as a function of experimental task.

Thyroarytenoid Muscle. The TA, the medial portion of which is typically referred to as the vocalis muscle, forms the muscular basis of the vocal folds. For this reason it might be considered the prototyp-

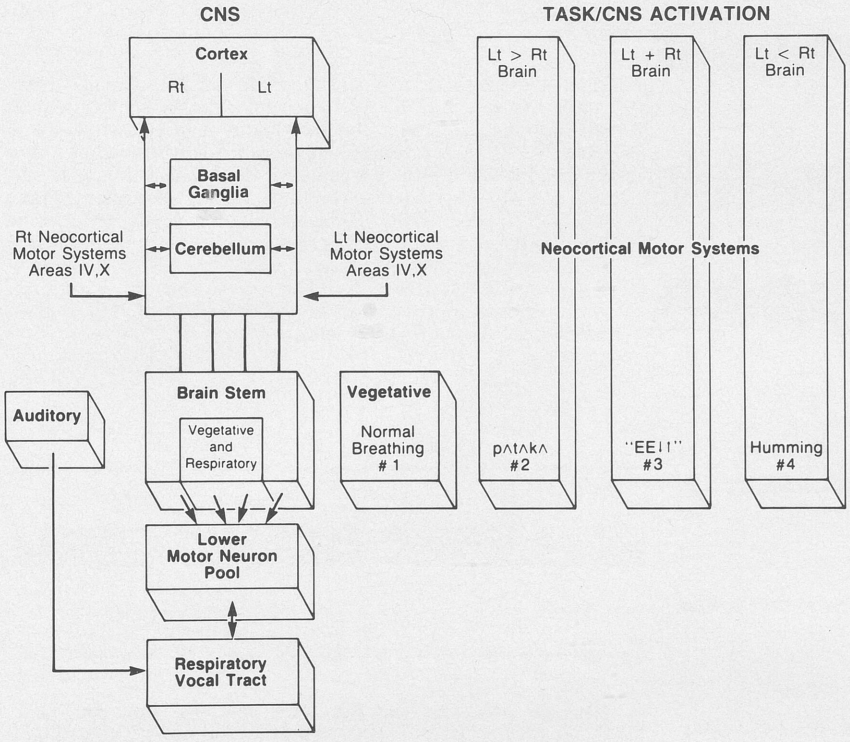

Fig 1. Schematic diagram of possible CNS organization with reference to experimental tasks.

ical muscle of interest in a disorder affecting vocalization. In a disorder such as adductor SD, one might assume that abnormal activity of the TA could produce vocal spasms (eg, hyperadduction) perceptually characterized by disrupted phonation. Further, one might assume TA involvement in perceived instances of either frequency or amplitude tremor. Finally, in a simplistic dichotomy between abductor SD and adductor SD, one might expect abnormal TA activity in the adductor form, but not in the abductor form. Acoustic and EMG data are presented to address characteristics of TA function in SD.

Intrasubject perceptual/acoustic variability referred to in the Introduction is illustrated in Fig 2A. Waveforms are presented for sustained /s/, /m/, and /i/ produced by a subject with adductor SD (subject SD1). Perceptually, tremor is not obvious in /s/ or /m/, but is readily apparent in /i/. There is clear acoustic evidence of regular amplitude perturbation in /i/, and of less dramatic and less regular amplitude perturbation in /m/. The arrow marks a complete phonatory break in the sustained vowel.

Figure 2B shows TA EMG activity accompanying the productions illustrated in Fig 2A. In the lower trace of Fig 2B, the arrow marks the phonatory break identified by the arrow in Fig 2A. This break immediately follows a rather bizarre spike in the EMG tracing of TA activity. The characteristics of this spike suggest that it is some form of artifact, possibly induced by a sudden movement of the electrodes or the muscle in which the electrodes are inserted. Therefore, we do not feel that the spike should be interpreted as causing the phonatory break. Rather, both the spike and the break may result from an extremely forceful movement of the vocal folds, possibly produced by contraction(s) of muscles(s) not monitored. The clear abnormality in TA during the sustained /i/ is shown by the regularly occurring periods of rapid onset, high amplitude activity (cluster bursts). These cluster bursts appear to occur at a rate of approximately 6 to 7 Hz, be superimposed on background TA activity, and be synchronous with amplitude modulations (tremor) in the acoustic waveform. While less dramatic, similar cluster bursts (at the same frequency) are present in TA activity accompanying the production of sustained /m/. Thus, the acoustic amplitude modulation apparent in these productions is accompanied by TA cluster bursts of a similar frequency. Interpretation of TA activity accompanying the /s/ production is less clear. While the acoustic waveform shows no evidence of amplitude modulation, the EMG signal shows some evidence of what may be low amplitude cluster bursts in the 6- to 7-Hz frequency range.

The presence of cluster bursts, or at least our ability to detect this abnormal EMG pattern, appears related to the increasing TA activity demonstrated by this subject across these three speech tasks. Lower overall levels of TA activity are observed for the voiceless obstruent /s/ as compared to the nasal /m/, and for /m/ as compared to the vowel /i/. This expected pattern also is demonstrated by our normal controls. At the higher levels of TA activity accompanying production of /i/, both the cluster bursts and the acoustic amplitude modulations are exacerbated.

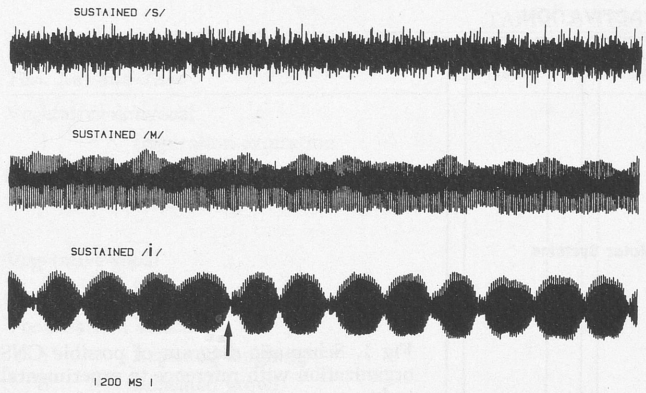

A

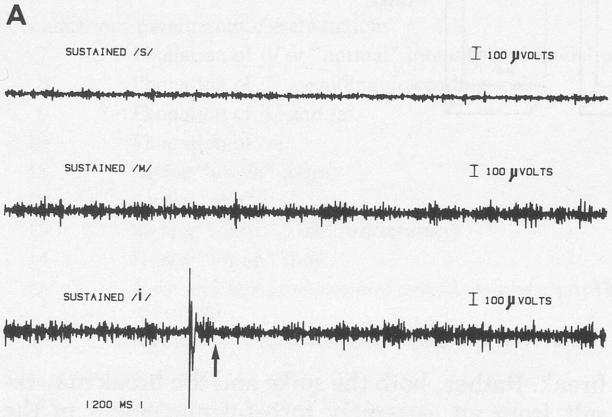

B

Fig 2. (Subject SD1) Acoustic waveforms of 2-s segments of sustained /s/, /m/, and /i/. A) These and all other acoustic signals were low pass filtered at 1.8 kHz before digitizing at sampling rate of 4 kHz. Arrow marks phonatory break perceived by listeners as adductor spasm. Listeners perceived vocal tremor in sustained /i/. B) Thyroarytenoid muscle activity accompanying /s/, /m/, and /i/ productions. These and all other EMG signals were low pass filtered at 700 Hz before digitizing at sampling rate of 4 kHz. Arrow identifies vocal spasm marked by identical arrow in A. C) Levator veli palatini EMG activity and acoustic waveforms for 2-s segments of sustained /m/ (top two traces) and /i/ (bottom two traces). Arrow marks voicing break perceived by listeners as spasm.

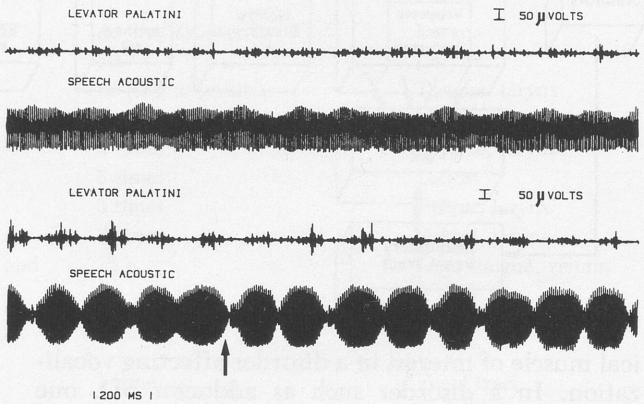

C

Figure 3A shows acoustic waveforms and accompanying TA EMGs for two tokens of sustained /i/ produced by subject SD3 under two speaking conditions. The upper signals were recorded while the subject applied techniques learned in voice therapy. The lower signals were recorded without use of these techniques. As might be expected, given differences evident in the acoustic records, these productions differed dramatically in perceived quality. Without therapy controls, this subject's voice had a strained/strangled quality, evidenced as a partial phonatory break (spasm) and a following complete break. With therapy controls, this subject's voice was slightly but not unpleasantly breathy and did not evidence any perceptually clear vocal breaks. Thyroarytenoid muscle activity accompanying both utterances is of relatively high amplitude. There is some regular modulation, but background levels make clear identification of cluster bursts difficult. The most dramatic difference between the two TA patterns is the occurrence, in the third trace, of an exceedingly high amplitude 200-ms burst preceding the complete vocal break in the acoustic waveform (fourth trace). This difference is typical of other comparisons made of this patient speaking with and without therapy techniques. In general, techniques learned in voice therapy appear to inhibit the occurrence of these high amplitude, relatively long duration bursts. This inhibition correlates with improved perceptual vocal quality and reduction in the frequency and duration of voicing breaks.

The acoustic waveform in Fig 3B illustrates a vocal pattern quite different from those in Figs 2A and 3A. This sustained /i/, produced by a subject with abductor SD (subject SD4), was extremely aspirate (almost completely whispered), with minimal vocal fold vibration. Given the minimal voicing observed, the high levels of TA activity are somewhat surprising. Indeed, this TA recording is remarkably similar to those of subject SD3, illustrated in Fig 3A. High levels of continuous activity make identification of cluster burst activity difficult.

When considering each of the preceding examples in isolation, a conclusion of overall abnormality of TA activity cannot be reached. The remaining question is whether the apparently high levels of TA activity illustrated in these selected examples represent deviant function in this muscle. Since intersubject comparisons of EMG activity are neither valid nor reliable for recordings obtained from indwelling hooked-wire electrodes, this question can be addressed only by intrasubject comparisons across selected experimental tasks.

Thyroarytenoid muscle activity is known to vary systematically across several of the tasks employed in this experiment. As an example, in the vegetative task of swallow, TA normally demonstrates high levels of activity associated with a maximal, protective closure gesture. In contrast, for the production of a voiceless /s/, TA activity in normal speakers is minimal. Between these two extremes, normal

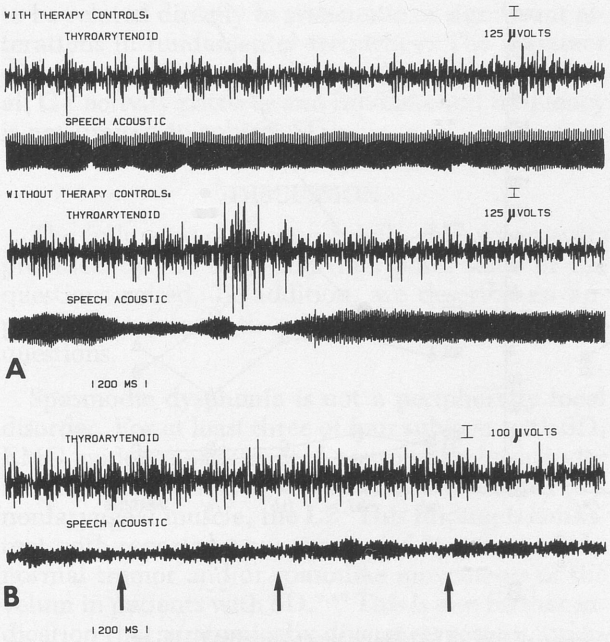

Fig 3. Thyroarytenoid muscle activity and acoustic waveforms for three 2-s tokens of sustained /i/. A) Subject SD3 speaking with and without techniques mastered in therapy. Listeners perceived two vocal spasms in "without therapy controls" condition. B) Utterance of subject SD4 (abductor SD) was perceived as extremely aspirate; little acoustic evidence of vocal fold vibration is present. Arrows indicate points in acoustic waveform at which decreases in amplitude occurred. Listeners perceived these events as abductor spasms.

speakers will show TA level differences (such as those illustrated in Fig 2B) associated with production of various speech sounds. Since none of our subjects (control subjects or subjects with SD) evidenced laryngeal insufficiency in swallow (ie, history of aspirating saliva, liquids, or solids), comparisons illustrated in Fig 4A were based on each subject's integrated average TA activity during swallow. Based on the assumption that this average value represented a relatively high (near presumed physiologic maximum) level of TA activity for each subject, average levels of activity during production of speech sounds were expressed as percentages of EMG activity during a swallow. Thus, in Fig 4A the level of TA activity during swallow represents 0% for each subject. Positive percentages indicate average levels of activity exceeding that occurring during swallow, and negative percentages represent levels below that accompanying swallow.

The expected normal pattern of TA activity is illustrated by subject C3. Production of /i/ required 70% less TA activity than did a swallow. Further, productions of sustained /m/, /z/, and /s/ required even lower levels of TA activity. In contrast, levels of TA activity demonstrated by the subjects with SD while producing these sustained speech sounds frequently equaled or exceeded their levels accompanying swallow. Two subjects with adductor SD showed higher levels for /i/ than for /m/, /z/, and /s/, while the subject with abductor SD showed a converse pattern, with higher levels for the consonants than for the vowel. It is tempting to consider this as evidence of different physiologic forms of the disorder. However, the number of subjects is too small to warrant such a conclusion.

Levator Veli Palatini Muscle. Having documented abnormal patterns of activity in an intrinsic laryngeal muscle (eg, TA) in these subjects with SD, we addressed the question of nonlaryngeal muscle abnormality in SD. If SD is a laryngeal problem, then LP activity should be normal. However, if SD is a disorder affecting all speech muscles, or at least all muscles innervated by the vagus nerve, then LP should demonstrate abnormality. Figure 2C shows acoustic waveforms and LP EMG activity for sustained /m/ and sustained /i/ produced by subject SD1. These acoustic waveforms are repeated from Fig 2A, and the TA activity for these utterances is presented in Fig 2B. Cluster bursts with a frequency of 6 to 7 Hz are apparent in both LP traces. These bursts appear to be temporally synchronous with similar cluster bursts in TA as well as with amplitude modulations in the acoustic signals. The cluster bursts accompanying /m/ production are more clearly apparent in LP tracings than in TA tracings because background LP activity is very low (as is appropriate for production of a nasal sound such as /m/).

In comparing levels of LP activity across subjects, a strategy similar to that used for the TA was adopted. During swallow, high levels of LP contraction assure closure of the velopharyngeal port and prevent liquids from being forced into the nasal passages. In contrast, during quiet breathing relatively low levels of LP activity occur, since the velopharyngeal port is open to allow air passage. In speech, production of a sustained obstruent such as /s/ requires LP activity in order to maintain intraoral air pressure, while production of a nasal such as /m/ is facilitated by decreased or suppressed LP activity to assure an open nasal passage. Therefore, the maximal vegetative gesture, swallow, was used as a basis for comparison. Activity levels for speech tasks and breathing were expressed as percentages of average LP activity during a swallow.

In Fig 4B, the level of LP activity during swallow represents 0% for each subject. Positive values represent average levels of activity exceeding that occurring during swallow. Negative values represent levels below that accompanying swallow. The normal pattern, illustrated by subject C1, shows that velopharyngeal closure necessitated by increased intraoral airflow for /s/ required 70% less LP activity than did a swallow. Productions of speech sounds that require lower levels of intraoral air pressure showed even lower levels of LP activity. Subject SD2 demonstrated an LP activity pattern similar to that of subject C1. Subject SD1, whose LP activity

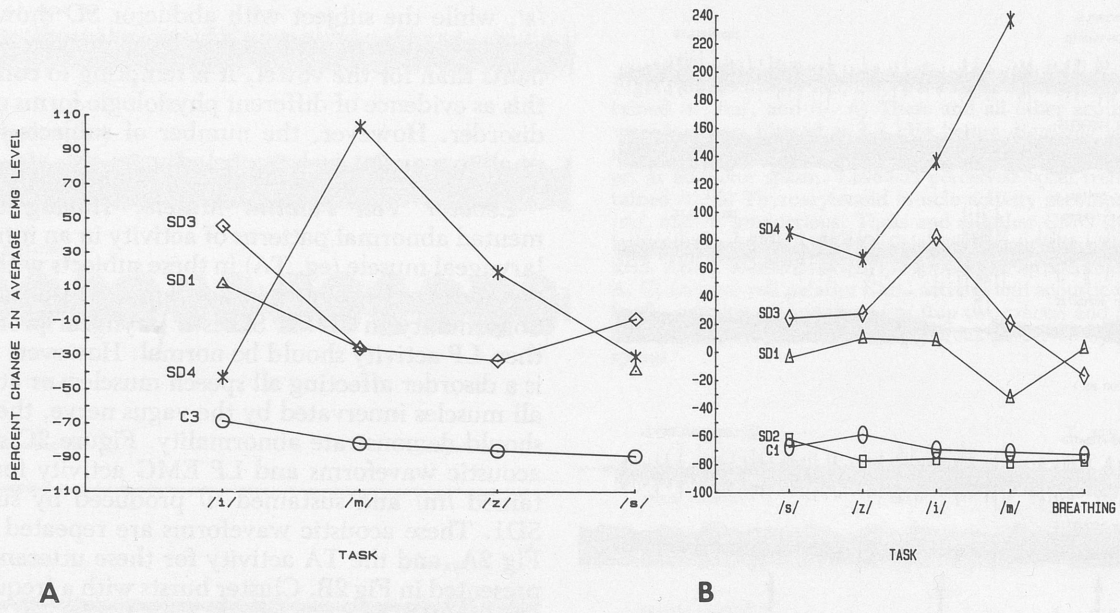

Fig 4. Relative change in average levels of EMG activity as function of task. A) Thyroarytenoid muscle EMG activity. For each subject, average level of activity during swallow (reflexive, protective laryngeal closure) is defined as 0%, and levels of activity for speech tasks are expressed as positive or negative percentages of that level. B) Levator veli palatini EMG activity. For each subject, average level of activity during swallow (reflexive closure of nasopharyngeal port) is defined as 0%, and levels of activity for other tasks are expressed as positive or negative percentages of that level.

patterns are illustrated in Fig 2C, showed an elevated baseline but a relatively normal pattern, including the expected drop in activity associated with nasal production. All oral speech sound productions were accompanied by LP levels that equaled or exceeded the level observed during a swallow. For subjects SD3 and SD4, LP activity levels for all speech tasks exceeded those for swallow. While the high LP levels accompanying subject SD4's productions of /s/, /z/, and /i/ might be explained by the high airflows accompanying the extremely aspirate (breathy) vocalizations, this explanation does not account for the 240% increase associated with this subject's /m/ production.

Cricothyroid Muscle. As have previous investigators, we found evidence of abnormal CT activity in our subjects with SD. However, these abnormalities were more puzzling than elucidating.[16] Figure 5 illustrates the perplexing nature of such findings. As shown in the lower trace (speech acoustic waveform), subject SD1 produced three iterations of the utterance /pʌtʌkʌ/. Perceptually, all three can be described as having the strained/strangled quality typical of this and many other subjects with adductor SD. Further, the three iterations are not perceptually or acoustically different from one another. Levator veli palatini activity for all three iterations appears normal (ie, bursts are associated with each of the stop closures). Nor can any gross abnormality of patterning be identified in the TA tracing. Indeed, nothing clearly abnormal can be identified in CT activity accompanying the first iteration. However, the CT activity temporally associated with the second and, to a lesser extent, third iterations can only be described as bizarre. This CT pattern is not, however, atypical for this subject. It occurs sporadically throughout his speech recordings. Careful consideration and reconsideration of all insertion validation criteria and recordings for this CT insertion revealed that this was a good CT recording (ie, there was no evidence of activity during head turning or jaw movements). If this activity represents artifact associated with movements of the laryngeal cartilages rather than elevated levels of CT contraction, it is a violent and relatively long-lasting movement.

Whether CT contraction or dramatic structural movement affecting the CT or its attaching cartilages, these bizarre electrical events do not appear

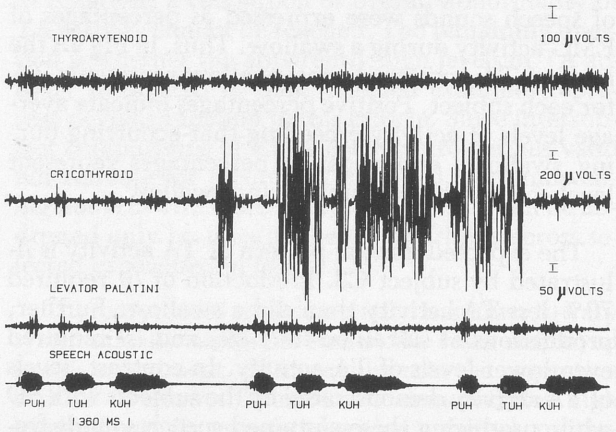

Fig 5. (Subject SD1) Electromyographic activity in thyroarytenoid muscle, cricothyroid muscle, and levator veli palatini, and acoustic waveform for three iterations of /pʌtʌkʌ/.

to be related directly to systematic or significant alterations in fundamental frequency. The apparent disassociation between abnormal, or at least unusual, CT activity patterns and fundamental frequency is not limited to subject SD1.

DISCUSSION

The following discussion briefly reviews answers provided by the data and then poses some of the questions raised. In addition, we describe an approach we intend to pursue in addressing these questions.

Spasmodic dysphonia is not a peripherally focal disorder. For at least three of four subjects with SD, EMG evidence of disrupted neuromuscular activity is not limited to laryngeal muscles, but extends to a nonlaryngeal muscle, the LP. This finding is consistent with reports by our group and by others of abnormal tremor and/or spasmlike movements of the velum in patients with SD.[9,10] This is also further indication that anatomically diverse structures innervated by the vagus nerve demonstrate abnormal function in SD.[6] Electromyographic studies of nonvagal speech muscles and of nonspeech muscles will be required to elucidate these results. While vocal abnormality is clearly a defining characteristic of SD, the underlying disorder appears to be nonspecific to laryngeal motor control. Instead, these findings suggest that abnormalities exist at higher levels of speech motor control.

Spasmodic dysphonia is probably a symptomatically unitary disorder. Previous work has demonstrated that perceptual ratings of vocal performance and acoustic analyses can be used to differentiate two groups of patients with SD (abductor and adductor). However, Cannito and Johnson[18] described a patient with mixed abductor and adductor characteristics, suggesting that vocal symptoms represent a continuum rather than a dichotomy. The subject in the present study with abductor SD showed abnormal activity in both the TA (an adductor muscle) and LP (a nonlaryngeal muscle). In addition, this subject showed higher relative levels of TA EMG activity for speech than did the three subjects with adductor SD. Thus, our data refute the simplistic assumption that a subject with abductor SD would demonstrate normal neuromotor activity in adductor muscles and abnormal activity only in the vocal fold abductor (posterior cricoarytenoid muscle). Additional subjects and muscles must be studied before the meaningfulness of these differences can be assessed.

Behavioral therapeutic intervention appears to be viable. Electromyographic results from a single subject treated by voice therapy indicate that therapy-related alterations in perceptual vocal quality occur in conjunction with alterations in the underlying EMG pattern. That is, voice therapy can effect changes in neuromotor control patterns in patients with SD. Understanding the effects of therapy at the level of neuromuscular control is thus a valid goal of future EMG research.

To the question "What is the level of neuromotor abnormality in SD?" data reported here offer part of the answer. Specifically, they support the notion that peripheral neuromotor manifestations, such as cluster bursts, reflect an upper motor neuron disorder. This interpretation is consistent with observed differences in levels of EMG activity as a function of task. Such reproducible, task-dependent differences would not be expected in a disorder limited to the lower motor neurons.

Data reported in this study do not permit further delineation of the locus or characteristics of the suspected upper motor neuron disorder. However, several aspects of our experimental protocol are designed to optimize efforts toward this end. Specifically, the 23 tasks listed in Table 3 provide differential activation of several vocal tract muscles along presumably different motor pathways. Differential activation of a muscle may represent changes in the overall amplitude of activity required for a task, in predominant hemispheric contribution, and/or in task-specific constraints on temporal patterning (ie, motor complexity). Effects of changes in overall amplitude of EMG activity required for a task are exemplified by data presented in this report (eg, exacerbation of cluster bursts). The implication of this finding is that neuromotor abnormality may frequently be present to some extent in the motor system, but that peripheral manifestation of this abnormality is contingent upon muscle activation beyond some threshold. Furthermore, the magnitude of this threshold may differ across individual muscles, patterns of muscle activation, subjects, or all three. Threshold variability could contribute to frequently reported intersubject and intrasubject variability in acoustic/perceptual characteristics of vocal performance as a function of task. Effects of predominant hemispheric contribution may be reflected also in differential activation of a muscle. As illustrated in Fig 1, certain of the tasks summarized in Table 3 may activate different subcortical and/or cortical regions preferentially. In-depth analyses of patterns of EMG activity within and between these tasks may facilitate identification of loci of upper motor neuron disease. Effects of constraints on temporal patterning may be resolved by a comparison of EMG patterns during steady state versus dynamic vocal tasks. With one exception, data presented here represented relatively steady state activation of a muscle. These patterns were informative in our understanding of relationships between neuromotor and acoustic/perceptual characteristics of vocal performance and permitted quantified comparisons between subjects across tasks. Conversely, the one example of muscle activity during a dynamic vocal task (CT during /pʌtʌkʌ/) illustrates gross qualitative abnormality. It is not yet clear whether quan-

tifiable abnormalities also exist in other muscles. We believe further discriminating power can be achieved by simultaneous analysis of all EMG signals during discrete temporal intervals within a response. Such signal processing should permit better resolution of timing and coordination measures as the dynamics of the vocal task change over the course of the response.[28]

Conclusions drawn from preliminary analyses of EMG data highlight future directions of our research. We plan to use information provided by EMG to continue pursuing several fundamental issues. For example, SD has been referred to as a focal dystonia.[17] Our mapping of EMG signals at multiple levels within the vocal tract has established that the focus extends beyond the larynx. In future studies, we will investigate the extent of vocal tract involvement and the validity of the label dystonia. As another example, our technique enables us to continue addressing the question of symptom heterogeneity in a larger number of SD subjects. We also will continue our search to identify the rules underlying the patterns(s) of task-related electrophysiologic abnormalities in SD. In a narrow scope, this work provides insight into causation and treatment. In a broader scope, the search may contribute to our understanding of 1) basic principles relating vocal motor control to task complexity and organization, 2) basic principles of central control of vocalization and/or speech, or 3) both, since the two may indeed be the same.

ACKNOWLEDGMENTS — Additional authors include Dr Michael Devous, Dr Sandra Chapman, James Dembowski, and Mehdi Jafari.

REFERENCES

1. Schaefer SD, Finitzo-Hieber T, Gerling IJ, Freeman FJ. Brainstem conduction abnormalities in spasmodic dysphonia. Ann Otol Rhinol Laryngol 1983;92:59-64.

2. Finitzo-Hieber T, Freeman FJ, Gerling IJ, Dobson L, Schaefer SD. Auditory brainstem response abnormalities in adductor spasmodic dysphonia. Am J Otolaryngol 1982;3:26-30.

3. Schaefer S, Freeman F, Finitzo T, et al. Magnetic resonance imaging findings and correlations in spasmodic dysphonia patients. Ann Otol Rhinol Laryngol 1985;94:595-601.

4. Pool K, Freeman FJ, Finitzo T. Brain electrical activity mapping applications to vocal motor control disorders. In: Peters H, Hulstijn W, eds. Speech motor dynamics in stuttering. New York: Springer Press, 1987.

5. Schaefer SD. Neuropathology of spasmodic dysphonia. Laryngoscope 1983;93:1183-204.

6. Feldman M, Nixon JY, Finitzo-Hieber T, Freeman FJ. Abnormal parasympathetic vagal function in patients with spasmodic dysphonia. Ann Intern Med 1984;100:491-5.

7. Cannito MP, Pool K, Freeman FJ, Finitzo T. Brain electrical activity mapping in adductor spasmodic dysphonia. J Acoust Soc Am 1985;75(suppl 1):S87.

8. Cannito M, Freeman FJ, Kondraske G, Pool K, Schaefer SD, Fintizo T. Spasmodic dysphonia: a dysarthria? Presented at the Third Biennial Clinical Dysarthria Conference, Tucson, Ariz, April 1986.

9. Freeman FJ, Cannito M, Finitzo T. Classification of spasmodic dysphonia by visual, perceptual and acoustic means. In: Gates G, ed. Spastic dysphonia: state of the art. New York: The Voice Foundation, 1985.

10. Freeman FJ, Schaefer SD. Theory and research in voice disorders. In: Lawrence Y, ed. The Proceedings of the Eleventh Symposium on the Care of the Professional Voice. New York: The Voice Foundation, 1982.

11. Tarasch H. Muscle spasticity in functional aphonia and dysphonia. Med Woman's J 1946;53:25-33.

12. Rabuzzi DD, McCall GN. Spasmodic dysphonia. Trans Am Acad Ophthalmol Otolaryngol 1972;76:724-8.

13. Blair RL, Berry H, Briant TD. Laryngeal electromyography: techniques and application. Otolaryngol Clin North Am 1978;11:325-46.

14. Hirose H. Electromyography of the larynx and other speech organs. In: Sawashima M, ed. Dynamic aspects of speech production. Tokyo: University of Tokyo Press, 1981.

15. Fritzell B, Feuer E, Haglund S, Knutsson E, Schiratzki H. Experience with recurrent laryngeal nerve section for spastic dysphonia. Folia Phoniatr (Basel) 1982;34:160-7.

16. Shipp T, Izdebski K, Reed C, Morrissey P. Intrinsic laryngeal muscle activity in a spastic dysphonia patient. J Speech Hear Disord 1985;50:54-9.

17. Blitzer A, Lovelace RE, Brin MF, Fahn S, Fink ME. Electromyographic findings in focal laryngeal dystonia (spastic dysphonia). Ann Otol Rhinol Laryngol 1985;94:591-4.

18. Cannito M, Johnson J. Spastic dysphonia: a continuum disorder. J Commun Dis 1981;14:215-23.

19. Schaefer SD, Freeman FJ. Spasmodic dysphonia. Otolaryngol Clin North Am 1987;20:161-78.

20. Freeman FJ, Schaefer SD, Finitzo-Hieber T. Fiberoptic studies of spasmodic dysphonia, a fifty minute video production. Presented at the Annual Conference of the American Speech/Language and Hearing Association, Cincinnati, November 1983.

21. Bloch CS, Hirano M, Gould WJ. Symptom improvement of spastic dysphonia in response to phonatory tasks. Ann Otol Rhinol Laryngol 1985;94:51-4.

22. Shipp T, Deatsch WW, Robertson K. A technique for electromyographic assessment of deep neck muscle activity. Laryngoscope 1968;78:418-32.

23. Basmajian JV. Simple method to improve performance of fine-wire electrodes. Am J Phys Med 1974;53:269-70.

24. Gay T, Hirose H, Strome M, Sawashima M. Electromyography of the intrinsic laryngeal muscles during phonation. Ann Otol Rhinol Laryngol 1972;81:401-9.

25. Hirano M, Ohala J. Use of hooked-wire electrodes for electromyography of the intrinsic laryngeal muscles. J Speech Hear Res 1969;12:362-73.

26. Freeman FJ, Ushijima T. Laryngeal activity during stuttering. J Speech Hear Res 1978;21:538-62.

27. O'Dwyer NJ, Quinn PT, Guitar BE, Andrews G, Neilson PT. Procedures for verification of electrode placement in EMG studies of orofacial and mandibular muscles. J Speech Hear Res 1981;24:273-88.

28. Stulen FB, DeLuca CJ. Frequency parameters of the myoelectric signal as a measure of muscle conduction velocity. IEEE Trans Biomed Eng 1981;28:515-23.

DISCUSSIONS

CONRADI-HUNERMAN SYNDROME. CASE REPORT (p 115)

M. HOCHMAN, MD; W. E. FEE, JR, MD

SEYMOUR R. COHEN, MD (Los Angeles): I would like to congratulate Dr Fee and Dr Hochman. This Conradi syndrome is a very rare disease. I have only seen one patient, and I think this child is the one whom I saw when he was only 1 or 2 months of age. The diagnosis was obviously made with radiographic studies. The problem in these children happens to be the airway. There is a new technique, and it has been developed by Gabriel F. Tucker, Jr, and his group at Children's Memorial Hospital in Chicago. Children with the so-called stovepipe trachea or concentric entire rings were uniformly dead before 1 month of age or so. Their airways have not been able to be kept patent because of the tremendous narrowing that has occurred, which in some cases has been entirely bronchial. What Dr Idriss and Gabriel Tucker and his group have done is to use a pericardial graft after splitting the trachea anteriorly and posteriorly. The patients have done extremely well. We recently had a child almost on his deathbed who had this operation and 3 months later is doing very well. Another report from Denver describes using cartilage grafts to enlarge the trachea. Since the child with the Conradi-Hunerman syndrome has a much better prognosis as he or she gets older, the thing to do is to protect the airway and to consider doing one of these procedures.

HISTOCHEMICAL STUDY OF POSTERIOR CRICOARYTENOID MUSCLE REINNERVATION BY A NERVE-MUSCLE PEDICLE IN THE CAT (p 29)

J. J. FATA, MD; L. T. MALMGREN, PHD; R. R. GACEK, MD; R. DUM, PHD; P. WOO, MD

ROBERT B. LEWY, MD (Chicago): This is a beautiful paper — very well designed and very well put together. There are, however, two areas to which I would like to refer: first, the author uses the word "controversy" relative to the neuromuscular transplant. This has no doubt been true, and I will not go through the whole controversy. I would suggest the following. I cannot move my omohyoid muscle except under circumstances of extreme stress after vigorous exercise. I submit that most people cannot move their omohyoid muscles. If they cannot do this, is it reasonable to expect that a neuromuscular transplant of the ansa including part of the omohyoid muscle would then be effectively volitional when put into the larynx? The clinical results have not been sufficient in the hands of many of us to justify that conclusion. The second point is the question of glycogen depletion, which was the essential argument of the paper. If I remember the author's slide correctly, there were two controls. Neither of the two controls showed any glycogen depletion. A minority, not a majority, showed some glycogen depletion. It may well be that this will ultimately prove to be a very excellent measure of neuromuscular transplantation, but if so, it seems to me that more work must be done in which the majority of the cases prove to have glycogen depletion.

ROGER L. CRUMLEY, MD (San Francisco): In experimental protocols for laryngeal reinnervation, it is imperative that chronic denervation of the posterior cricoarytenoid muscle be achieved and confirmed. This is critical because it is known that adjacent nerves and muscles, as well as the recurrent laryngeal nerve, may regenerate back to the posterior cricoarytenoid and produce reinnervation. The nerve or muscle transplant may in fact have nothing to do with such reinnervation. This study leaves that issue unclear, since the neuromuscular pedicle is growing axons toward the muscle, at the same time as all the other local regenerative sources are. We know that ligation of the recurrent laryngeal nerve in animals will not preclude recurrent nerve regeneration. I think these issues are cloudy here in terms of which nerve actually reinnervated the posterior cricoarytenoid muscle.

JOHN A. KIRCHNER, MD (New Haven, Conn): I think this is an excellent paper. I think that the workers have brought this nerve-muscle pedicle graft up to the next stage beyond what we knew before. The stimulation certainly showed glycogen depletion. I think the next stage in investigating this technique would be to put an electrode into the muscle to see if there is activity of the abductor muscles during inspiration. Because you do or do not see abduction on inspiration does not mean that the muscle is not working. There is just enough contraction of the posterior cricoarytenoid muscle ordinarily to stabilize the vocal cord against abduction by the Bernoulli effect and to prevent the stridor that would otherwise occur. If one looks at the vocal cord under these conditions, one does not necessarily see abduction; therefore, we may be underestimating this technique. The work from now on should include an electromyographic recording from the muscle.

JOSEPH J. FATA, MD (Syracuse, NY): Dr Lewy, the control animals did not show glycogen depletion because the nerve-muscle pedicle (NMP) was not subjected to suprathreshold stimulation. This demonstrated that glycogen depletion in the experimental animals was produced by stimulation of the NMP rather than by some other process such as the denervation procedure.

There are several possible explanations for the inconsistency of glycogen depletion in the posterior cricoarytenoid muscle (PCA) following NMP stimulation in the experimental animals: 1) disruption of the neural connections between the NMP and the PCA produced by the technical difficulties associated with surgical exposure of the small NMP in a field obliterated with fibrosis; 2) fatigue of the neuromuscular junctions of the NMP-PCA complex secondary to excessive electrical stimulation; and 3) unsuccessful reinnervation by the NMP due to factors such as degeneration of the NMP as a result of ischemia, unfavorable location to the end plates in the PCA, and fibrosis.

Dr Crumley's suggestions regarding reinnervation of the denervated PCA by the transected recurrent laryngeal nerve (RLN) or other nearby neural systems are pertinent and were addressed in the experimental design. The proximal end of the transected RLN was embedded into a pocket formed in the lower cervical esophageal wall and sealed with nonabsorbable suture. The chance for reinnervation by this source is extremely remote. Previous work in our laboratory (Schell, Malmgren, Gacek) presented a few years ago to this society, demonstrated that in the cat, the denervated PCA initially shows muscle degeneration but undergoes spontaneous reorganization 2 to 4 weeks after the denervation procedure. This reorganization, which is indistinguishable from the normal PCA several months later, strongly suggests spontaneous reinnervation by other nearby neural systems such as autonomic nerve fibers or sensory components of the vagus nerve. This phenomenon indicates that reinnervation procedures applied to the chronically denervated PCA are destined to failure. Therefore, the NMP or other reinnervation attempts must be employed

within a short time period following denervation. The present study, using the glycogen depletion principle, which is a cornerstone in muscle physiology research, presents the first unequivocal evidence that the NMP can reinnervate the denervated PCA.

HARVEY M. TUCKER, MD (Cleveland): First, let me say that Dr Kirchner's comments are well placed. Work has been done repeatedly in which electromyographic activity in acute and chronic preparations has been detected from electrical stimulation applied to the transplanted nerve in an organ isolated so that it could not possibly be from any other source. One can detect appropriate potentials and activity in the muscle at some distance from the nerve-muscle pedicle that has been transposed. This has also been done in spontaneous activity without electrical stimulation.

The omohyoid muscle is under voluntary control. It is true that many of us cannot voluntarily contract the omohyoid muscle on any ongoing basis, but during hypoxia it has been demonstrated clearly that activity in all of the strap muscles including the omohyoid muscle increases dramatically. It is the electrical activity that we are seeking and not contraction of the muscle. The nerve-muscle pedicle is not transposed to provide muscle to make the vocal cord move; it is to provide a nerve supply to the muscle that is already there, the posterior cricoarytenoid muscle. We must not lose sight of the fact that a denervated larynx does not behave like a normal larynx, and it does not take a great deal of activity to stabilize or abduct the vocal fold when it is unopposed by any other electrical activity or muscular activity. All of this notwithstanding, the controversy goes on. I have to agree at this point with the statement made by the Casselberry essayist (and I also commend him for this nice piece of work) that the probable long-term future of nerve-muscle reinnervation of the larynx will lie in electrical stimulation by pacing. I am pleased that we will be presenting a paper today along these lines. There have been reports in the literature from Europe and the United States recently showing that pacing via a transposed nerve-muscle pedicle does in fact work in the acute experiment, and now chronic experiments need to be done.

SEYMOUR R. COHEN, MD (Los Angeles): I just have a feeling in going over the literature and reading about all of the techniques of vocal cord reinnervation that we have lost one of the most important aspects of what all of the research is about. This is to try to undo something that laryngeal paralysis does. In the treatment of neuropathies of the larynx certainly that issue has not been settled. I have not seen any responses as good, even in the child, as that which we get with the Woodman procedure. I think that we should not forget that that procedure can be done even in children when done appropriately. I have heard people talk about what happens histologically, that we know that glycogen storage is reduced or depleted. I have heard people say that histologically we can see all of these nice changes and we know that the pedicle takes, but what has it done to the patient? Has it really done enough to the patient to cause a complete recovery of the problem? To that I can't see that the answer has been "yes." There is no reason to believe that about laryngeal muscles that have so many motor end-plates. Each muscle has motor end-plates that are different from the motor end-plates of other muscles on the larynx. Some are broad-banded, some are smaller. To put a small pedicle into one muscle of the larynx does not mean, because it has histologically taken and does its work, that it will fire each and every one of these end-plates. Therein, I think, lies the real distress that I feel about small pedicles in an attempt to replace motor innervation.

VOCAL LIGAMETRY. UPDATE (p 147)

F. E. LEJEUNE, JR, MD

ROBERT B. LEWY, MD (Chicago): I am fascinated by Dr LeJeune's paper, and I would like to introduce a peculiar type of word of warning. It is my belief that he uses the detachable laryngoscope holder for suspension of my design, which includes a star gear up against a rotary gear. This is extremely powerful. We have had to instruct our residents carefully that the placement of the tip of the laryngoscope and the amount of tension placed against the vocal cords must be just right in order to do a good job relative to injecting Teflon. It would seem to me that if the tip is in too tight and if it is not placed just right, then perhaps his measurement of the vocal cord might suffer in some degree in its accuracy.

LASER RESECTION FOR EARLY ORAL CAVITY CANCER. RESULTS AND COMPLICATIONS (p 106)

M. J. NAGORSKY, MD; D. G. SESSIONS, MD

DONALD G. SESSIONS, MD (St Louis): I would like to make a comment on my paper because one could say that these complications are complications of treating cancer rather than those from the laser therapy. It is reported in the literature that one may excise periosteum and large amounts of soft tissue with the laser and the wound will heal. That is exactly what happened when we began to use the laser for oral cavity cancer, but in patients who needed postoperative radiation therapy before the periosteum healed we had catastrophic results. All of these patients developed osteoradionecrosis. We feel strongly that those patients who need radiation therapy for cure need to have full-thickness coverage. The second thing that happens with the laser is that often one can take out small lesions that in the past would have required removal of the mandible, particularly in the retromolar trigone, soft palate, and buccal area. When one takes out large lesions in that area, even though one gets around them, and leaves the mandible in, one cannot help but have some problem with mandible movement, especially trismus. Not having thought about that until it happened, it became a very serious problem. I brought this up also to see what people do with patients who have had high-dose radiation therapy with their mandibles in and who have trismus, because we have not come upon a satisfactory treatment for that situation yet.

M. STUART STRONG, MD (Boston): After your comments, Dr Sessions, I almost decided to withdraw mine, but I couldn't restrain myself. Congratulations to you both for bringing this work to us. I think you have pressed the laser to the ultimate limit in the oral cavity. You took over where we left off, as it were. Our early presentation showed one could do it and nothing bad happens; we soon found it to be most useful in the early lesions. Now, T3, a bulky tumor, is not a very early tumor in my view. I speak of early disease as the spreaders, the brush fires, the multicentric, the little patches of erythroplasia. One doesn't know whether the disease is invasive, in-situ, or maybe less than that. The rationale for using the laser for these is to do an excisional biopsy. One knows roughly where the tumor is, but its margins can be exaggerated with stain. Then one cuts around it to take off the surface

layer including a little muscle as well, but not much more than that. The floor of the mouth, the palate, the undersurface of the tongue are convenient places to do this expeditiously. If the tumor has bulk, I think the laser has no advantage. I think one should go to it in the old-fashioned way, according to one's preference. One knows perfectly well if the patients live for 3 years, it is likely that there will be a recurrence of their diathesis. The idea is to hold back on the use of radiation until the time comes when one has to use it. I have irradiated a couple of undersurface-of-the-tongue tumors and nothing untoward happened. I haven't irradiated the exposed mandible; however, I have exposed the mandible in a person who was a radiation failure and gotten away with it, so that is a bit of a paradox. Please, Dr Sessions, don't lose sight of the disease and don't be seduced by the laser. It is only a tool, use it only when you think it will be a real advantage and then you won't have any regrets about its use. You have told us how far you can go, and now we have to retreat a bit. In so doing you have served us well.

DANIEL MILLER, MD (Boston): A couple of comments, if I may. I am a little concerned, if I am correct in what I heard, that 29% of the patients had already had recurrences when the laser was used. If this is so, it raises the question of selectivity of patients for this destructive tool that you use and how you use it. I didn't hear much about frozen sections at the time of laser removal, and I think that the old-fashioned way is still good. The laser is a destructive tool in the proper hands, but the selective nature of the tool for the disease seems to me to be paramount in making the laser more effective.

DR SESSIONS: The laser is not used as a destructive tool. It is used merely as a cutting tool, and that distinction was very difficult for me until I started using it in the oral cavity as a cutting tool.

TECHNIQUE FOR EXTERNAL MOBILIZATION OF THE VOCAL CORD WITH SILASTIC IMPLANT (p 165)

J. R. ESCAJADILLO, MD

HARVEY M. TUCKER, MD (Cleveland): The statement was made that one of the advantages of this technique is that it would be reversible. I think it is fair to say that one could remove the Silastic as the author stated it, but I am not sure that that makes the procedure reversible. If this is being recommended for consideration in people in whom spontaneous return of function can be expected, I would still strongly recommend, as stated in the literature by most essayists, that irreversible procedures for vocal cord paralysis should not be carried out until a reasonable period of time (and that period may vary from 6 months to 1 year) has gone by so that there is no hope of recovery. I think it is likely that if this Silastic were removed a year later because the vocal folds are working or too much adduction had been achieved, there is no reason to think that the mobilized vocal cord will go back to where it came from.

ROBERT B. LEWY, MD (Chicago): I agree completely with what Dr Tucker said. I was distressed by this paper for two reasons. One is that implants of that nature have been used for years. I thought that we were beyond that implant stage when, after 25 years of experience and thousands of cases, we were running a batting average of greater than 90% success with a far simpler operation, the injection of Teflon. I don't see the rationale for using a very complex operation when a far simpler operation has been functioning well for a quarter of a century.

USE OF BOTULINUM TOXIN TO LATERALIZE TRUE VOCAL CORDS: A BIOCHEMICAL METHOD TO RELIEVE BILATERAL ABDUCTOR VOCAL CORD PARALYSIS (p 84)

S. R. COHEN, MS, MD; J. W. THOMPSON, MD

ROBERT H. MILLER, MD (New Orleans): When I was in Houston, we had the opportunity to inject botulinum toxin in two patients who had severe spasmodic dysphonia. We used a percutaneous electromyographic needle technique and got excellent results in both patients. One of the patients has been injected three times and each time has responded very nicely. It has been a very useful technique for these patients.

HERBERT H. DEDO, MD (San Francisco): I an delighted to see that more people are deciding that paralysis of the vocal cord can be useful for spastic dysphonia, but I think there are two difficulties with the botulinum toxin. One, Dr Miller said it has been successful and then went on to say it had been done three times. The beauty of doing an open surgical section, since we are using techniques that thyroid surgeons perfected in the past, is that it does not have to be repeated. One puts a ligature on the proximal stump, and it is permanent. I am astonished at the lengths people will go to try to avoid doing a relatively minor, open surgical procedure; it is about as serious as a tracheotomy. The second disadvantage of botulinum toxin injection is that the injection needs to be done along the side of the cricoid cartilage, and in this area it is difficult to avoid paralyzing the superior laryngeal nerve and ending up with more breathiness and lateralization of the vocal cord than you want in some of the patients.

CORRELATION OF TUMOR VOLUME WITH LOCAL CONTROL IN LARYNGEAL CARCINOMA TREATED BY RADIOTHERAPY (p 64)

R. W. GILBERT, MD; D. BIRT, MB; H. SHULMAN, MD; J. FREEMAN, MD; D. JENKIN, MB; R. MACKENZIE, MD; C. SMITH, MD

JOHN A. KIRCHNER, MD (New Haven, Conn): It seems to me that there are two types of tumor volume: one large tumor might be large because it invades the deep structures of the larynx such as the thyroarytenoid muscle, and another type of bulk might be

due to the fact that it is just a large exophytic tumor like a verrucous carcinoma. We have all had the experience that the latter type of tumor has a better prognosis than one that is deeply invasive. Have the authors had the opportunity to compare the exophytic lesions with the deeply infiltrative lesions?

DEREK BIRT MB (Toronto): The short answer is "no." A more expanded answer might refer to the work that is being increasingly published on the thickness of tumors. A lot have not been laryngeal tumors but oral cavity tumors. The authors here who are studying them are quite concerned about the depth into tissues that the tumors penetrate. The authors usually have said that they have been unable to apply the techniques of measuring thickness to the larynx. We haven't studied the matter that Dr Kirchner questioned. We simply set out to see that, if we measured the volume of apparent tumor from computed tomographic scans, did it have any value, and as I said earlier, we think it may.

VOCAL NODULES IN INFANTS AND CHILDREN (p 80)

B. BENJAMIN, FRACS, FAAP; G. CROXSON, FRACS

CHARLES N. FORD, MD (Madison, Wis): First, I would like to commend the authors on their excellent results. I don't think I have seen such tremendous results in that particular disease — 100% relative success; about three fifths of the patients with "normal voices." I am a little suspicious of those results based on some of the real disasters that I have seen in patients with vocal nodules surgically removed and the principle that any time one removes tissue on the vocal fold, one introduces some damage to the vibratory mechanism. I suggest that we should be looking at the vibratory characteristics, and should this kind of study be repeated, it would be very nice to see videostroboscopic studies to assess exactly what is happening. For example, in the patients with so-called improved but not normal voices, it may well be that these improvements are improvements in terms of breathiness, but there may be persistent raspiness and severe impairment of vibration due to scarring.

BRUCE BENJAMIN, MD (Sydney, Australia): I would like to thank you for the comments. We, of course, do not claim 100% success; that was made clear and you echo it in your comments. I agree that the removal of vocal nodules in children is controversial. It is not for all children; it is for carefully selected children. I agree that judging the quality of the voice is difficult. There are very many parameters that could be used; the one we used was the parent's opinion of the child's voice. Now that microlaryngeal surgery is so precise, the results we obtained can be obtained by anybody performing the surgery carefully. Clumsy or unskilled surgery obviously will produce poor results, but those of us who are skilled in microsurgery in the middle and inner ear realize that microsurgery in the child's larynx is really, if you like to think of it, gross surgery compared to the microsurgery in the middle ear. I make no excuses for advocating the removal of vocal nodules in children in selected cases.

CONSERVATION LARYNGECTOMY (p 174)

GUI-YI TU, MD

EUGENE N. MYERS, MD (Pittsburgh): I was very interested in hearing Dr Tu's discussion about the approach in China, at least his approach in Beijing, to laryngeal cancer. I was intrigued by the type of reconstructive efforts that he has carried out, particularly with the osteomuscular pedicle. I wonder if there is anyone in the audience who has experience with that technique or related techniques and would like to comment. It is always challenging to try to do some type of reconstruction after this type of extensive partial laryngeal surgery.

DONALD G. SESSIONS, MD (St Louis): I think one of the problems that comes up and becomes more important as the world gets smaller is: What is a three-quarter laryngectomy? The type of operation that Dr Pearson calls a three-quarter laryngectomy certainly is different from what Dr Ogura was very clear and concise about. He called a three-quarter laryngectomy a supraglottic partial laryngectomy for a patient in whom the superior surface of one vocal cord was involved. Although it was a tumor that had crossed the ventricle, he was very precise that it did not affect the mobility of the vocal cord. Therefore, he only took a small portion of the top of one vocal cord. The results from that surgery were good in terms of cure rate because the patients were highly selected. The functional results in regard to swallowing from doing that procedure, which I have had the opportunity to watch through the years, and those of tumors that involved the vallecula, the so-called extended supraglottic laryngectomy, were the poorest swallowing results of all conservation laryngeal surgery. The cases that I have had in which a supraglottic laryngectomy is done, including a hemilaryngectomy on one side, were difficult reconstructive processes; they involved bringing in muscle pedicles for reconstruction when there was no pyriform sinus left because that kind of tumor often involved the pyriform sinus. It is hard to raise a pedicle that is still attached without taking the nerve supply to it. When that is done, one is going to get atrophy, in my experience. We have dealt with that problem by markedly overcorrecting. One patient with overcorrection was fine for a year and then had the usual swallowing problems. I don't have the answer to that problem. I think that the American Laryngological Association should start to be very precise and meticulous about the presentations in terms of what procedure was done, what the size of the lesion was, and where exactly the lesion was. I don't believe that such precision has been obtained yet.

BRUCE PEARSON, MD (Jacksonville, Fla): First of all, I think we all feel a kinship with Dr Tu. His personal story before the presentation was as impressive as the presentation. I don't use the term three-quarter laryngectomy in the hopes of avoiding the difficulties in understanding to which Dr Sessions alluded, and I agree that anatomical precision in describing what we are doing is vital to understanding this work. I believe he is referring to the near-total laryngectomy, which is a larger operation and for larger cases than Dr Tu is describing.

There are some technical questions I have about the pedicle. There were no wires seen in the postoperative x-ray films. We were wondering how the bone was anchored posteriorly in the larynx. Were the pedicles covered with mucosa, or was it not possible to do so? Was mucosa used only in instances in which the lower circumferential ring of the cricoid cartilage was preserved, in other words, wherever just the upper portion was resected?

GUI-YI TU, MD (Beijing): First, in the supraglottic T2 lesions in which the tumor crosses the ventricle and in the supraglottic T3 lesions in which the arytenoid cartilage is fixed, the problem is a fixed vocal cord. Either the vocal cord is fixed by tumor or by involvement of the aryepiglottic fold. It is hard to predict. Approximately one half of our patients have received preoperative ir-

radiation. Before treatment we have a meeting of our coordinating group of radiation therapists and surgeons to consult on treatment and to determine the staging. Once the staging is determined it is not changed. For supraglottic T2 and T3 lesions, we do a three-fourths resection, which is a horizontal supraglottic plus vertical partial laryngectomy. Only one vocal cord and one arytenoid remains. For that case we use the osteomuscular flap to cover the resected half of the larynx. Postoperatively that half of the larynx is stationary in the midline, and the normal vocal cord approximates with it. Therefore, in every case in my hospital, we have no problem with postoperative swallowing or aspiration. We had two cases of postoperative aspiration pneumonia, but they healed later with no problems.

Sometimes it took 1 to 2 months of practice in swallowing semisolid food before the patient could resume a normal intake of food and could be decannulated. Every patient in this series can take normal food by mouth. For T3 glottic cases, we resect the arytenoid cartilage together with part of the cricoid rostrum, not the whole cricoid cartilage. In that case, we place the osteomuscular flap. The idea of the osteomuscular flap was inspired by Dr Ogura, and I read Dr Blaugrund's paper about use of part of the thyroid cartilage to fill the gap that remained after removal of the arytenoid cartilage. We use a part of the hyoid bone to fill the defect and a strap muscle to cover the half larynx so as to avoid aspiration of food into the trachea. As for mucosal covering, the postarytenoid and pyriform sinus mucosa is used whenever possible. In case there is not enough hypopharyngeal mucosa, we try to cover the bony surface and leave the transplanted muscle with its investing fascia bare. It heals well and the epithelium covers the raw surface by secondary intention.

EUGENE N. MYERS, MD (Pittsburgh): One of the other questions is "How do you fix the hyoid bone when you bring it down?"

DR GUI-YI TU: I remember that Dr Ogura's method was to use wire. We leave a little of the suprahyoid muscle attached to the hyoid bone and suture it to the soft tissue where the arytenoid had been. We do not use interosseous wiring.

PAUL H. WARD, MD (Los Angeles): Does the patient get any movement? The patient should. The muscle is innervated.

DR GUI-YI TU: No movement. No innervation.

FRANK E. LUCENTE, MD (New York): I can't let the discussion finish without making a comment about the paper that prompted much of this by Dr Seymour R. Cohen in response to Dr Gabriel F. Tucker, Jr's request that the history of pediatric laryngology be presented. This discussion we have just heard for the last 20 minutes tells us that there is much to be learned from a careful study of history; that many of the mistakes that are propagated have been resolved in the past and that every investigator must do a very thorough study of the history of what has preceded us. There is no need to repeat problems that have been solved before. I think it is also a challenge to those who have many clinical experiences who do not share them at these professional meetings to present them so we can all learn from what should be a living history and not just a recitation of names. I hope we all have a living history here.

MEMORIALS



ALBERT H. ANDREWS, JR
1907-1986

Albert H. Andrews, Jr, MD, Professor Emeritus of Otolaryngology-Head and Neck Surgery at the University of Illinois, Chicago, died on September 26, 1986, at 79 years of age. Dr Andrews was appointed as a clinical instructor in the University of Illinois College of Medicine in 1939 and retained academic affiliations with the Department of Otolaryngology-Head and Neck Surgery continuously until his death. He achieved the rank of Clinical Professor in 1963 and was head of the department from 1968 until 1975 at which time he became Professor Emeritus. Dr Andrews's retirement hardly diminished his activities at the university. He continued to participate in teaching, patient care, and research on a part-time basis. During these retirement years, Dr Andrews continued his work with the laser and coauthored a book in 1982 entitled *Microscopic and Endoscopic Surgery with the CO_2 Laser*.

Dr Andrews was a pioneer in laser surgery. He was one of the first to apply this new surgical tool to diseases of the larynx. Dr Andrews brought one of the first clinical lasers to the University of Illinois where, in addition to animal experiments, he operated on hundreds of patients using the laser. Dr Andrews helped surgeons in other specialties learn the technique so that they could apply it to their own practices. Because of his interest in the surgical laser and his idea that its application to patients would be improved by cooperation among various specialists in different institutions, Dr Andrews helped found the Midwest Bio-Laser Institute. This multidisciplinary organization, of which Dr Andrews had been president, has fostered laser research and clinical application.

Throughout Dr Andrews's career, he was an innovator and leader. During World War II, he served in the Navy where he helped set oxygen standards for naval flyers and encouraged the use of helicopters for rescue missions and on hospital ships.

Following military service, Dr Andrews returned to Chicago where he helped develop the special high humidity-saturated room at Children's Memorial Hospital. Rooms of this type, and later croup tents, were of great help to children in respiratory distress. Dr Andrews's interest in the respiratory tract was also reflected in membership in the American College of Chest Physicians, of which he was president from 1972 to 1973. He was very active in the American Association for Respiratory Therapy and the American Registry of Ventilation Therapists in which he was president of the board of trustees. He was an active member of the American Laryngological Association from 1969. In 1981, Dr Andrews received the Chevalier Jackson Award of the American Broncho-Esophagological Association. In addition to his many academic and professional society interests, Dr Andrews maintained a private practice in several Chicago hospitals.

Dr Andrews will be remember with fondness by many colleagues. His many past accomplishments and his productivity since his retirement in 1975 will continue to inspire his former students, residents, and colleagues.

E.L.A.

LAWRENCE R. BOIES
1898-1986

Lawrence R. Boies was born on November 7, 1898, in Renville, Minnesota, and soon moved to Wisconsin where his father made cheese. Dr Boies served in the US Army in World War I as a corpsman. He received his BA from the University of Wisconsin in 1922 and his MA from the same institution in 1923. For a short time between college and medical school, he was an English teacher. He graduated from Columbia University College of Physicians and Surgeons in 1926.

Love of the English language never left him. Unlike so many educated Americans, he wrote concisely and well, which may account for the success of *Boies' Fundamentals of Otolaryngology*. Under his authorship through four editions, it has been the most popular textbook in otolaryngology for medical students in the western world.

Dr Boies was in general practice from 1927 to 1929 during which time he was the team physician for the Minneapolis Millers baseball team. He played sandlot baseball as a young man, and this sport was a lifelong love.

Dr Boies received his specialty training between 1929 and 1931 at the Massachusetts Eye and Ear Infirmary under Harris P. Mosher. He went to the University of Minnesota as a clinical instructor in 1931 and became the Director of the Department of Otolaryngology in 1941. He was Professor and Head of the Department of Otolaryngology from 1945 until 1967, the year of his retirement from the practice of medicine. Besides being an active clinician and department head, he was a diligent contributor to local, regional, and national organizations. He was president of most of our national societies. He served as President of the American Laryngological Association in 1967. His contributions as President of the American Board of Otolaryngology from 1964 to 1968 were very great.

Following his retirement, Dr Boies was Director of Medical Affairs for the Deafness Research Foundation from 1967 until 1971. He was the president of the organization from 1970 to 1971.

Dr Boies married Louise in 1928, and they had three sons. Dr Boies died on July 5, 1986, in Minneapolis. He is survived by his wife, two sons, Lawrence R. Boies, Jr, MD, and David, a lawyer, and three grandchildren.

Dr Boies will be remembered with affection by his many students for his diligent teaching and the twinkle in his eyes, and throughout our country by his colleagues for his many years of work to advance otolaryngology within organized medicine.

A.J.D.



FRANCIS W. DAVISON
1903-1987

Dr Francis W. Davison died February 5, 1987, at the Geisinger Medical Center, Danville, Pennsylvania, where he had been a staff member for more than 55 years. He was 84 years of age.

A 1928 graduate of the University of Pennsylvania School of Medicine, Dr Davison served both his internship and residency at what was then the George F. Geisinger Memorial Hospital. In 1936, he was named Director of the Department of Otolaryngology and Bronchoesophagology at the Geisinger Medical Center, Danville, a position he held until 1964. Since that time, he had been a senior consultant in the Department of Otolaryngology-Head and Neck Surgery.

The author of some 75 scientific papers, Dr Davison had distinguished himself in leadership roles throughout his career. In 1955, he served as Chairman of the Section of Laryngology, Otology and Rhinology of the American Medical Association. He was President of the American Broncho-Esophagological Association in 1959 and was President of the American Laryngological, Rhinological and Otological Society in 1966. In 1969, he was elected President of the American Laryngological Association.

Dr Davison was a life member of the American Academy of Otolaryngology-Head and Neck Surgery, a Meritorious Member of the Pennsylvania Academy of Ophthalmology and Otolaryngology, and an Honorary Member of the American Academy of Otolaryngic Allergy. He was named the recipient of the Chevalier Jackson Award of the American Broncho-Esophagological Association in 1977, the Newcomb Award of the American Laryngological Association in 1975, the Philadelphia Laryngological Society Award in 1969, and the Award for Distinguished Services from the American Academy of Ophthalmologic and Otolaryngologic Allergy in 1970, and was twice named the Guest of Honor at the Pennsylvania Academy of Ophthalmology and Otolaryngology.

The F. W. Davison Library and Conference Room at the Geisinger Medical Center in Danville is named in his honor.

Dr Davison is survived by his wife of 58 years, the former Margaret Vaughan Smith, four granddaughters, and three greatgrandsons. His daughter, Dr Joan Dudley Davison died in 1961, and his son, Dr Richard Alvin Davison, a colonel in the US Air Force Medical Corps, died in 1974.

D.P.V.



JAMES T. KING
1912-1986

James T. King died July 3, 1986, at his home in Atlanta after a long illness.

He was born in Quitman, Georgia, on March 24, 1912. He received his undergraduate degree from Emory University in 1932 and subsequently graduated from the Medical College of Georgia in 1936. He completed his internship and otolaryngologic residency training at Grady Memorial Hospital in Atlanta in 1939. For a little over a year, he practiced otolaryngology in Valdosta, Georgia, but in 1940 he joined the US Army in which he served until 1945. Two and one-half years of his military service were spent in the Southwest Pacific Theater.

In 1945 he returned to Atlanta, to the private practice of otolaryngology and was appointed Assistant Professor of Surgery and Assistant Professor in Otolaryngology at Emory University, which position he held until his death. He was certified by the American Board of Otolaryngololgy in 1946. He was injured in an automobile accident in February 1972, which resulted in a paralyzed left shoulder and prevented his continuation in active practice.

Dr King was a member of numerous medical societies including the American Laryngological Association and the American Laryngological, Rhinological and Otological Society, of which he was Vice-President of the Southern Section in 1958 and Secretary from 1961 to 1965. He was also Secretary from 1961 to 1964, and in 1964 to 1965 he was President of the Georgia Society of Ophthalmology and Otolaryngology. He was Chief of Ear, Nose, and Throat (1968), Chairman, Executive Committee (1971-1972), and Chief of Staff (1971-1972) of the Atlanta Hospital. Dr King served on the active staff of Georgia Baptist, Atlanta, Doctors' Memorial, West Paces Ferry, Metropolitan Eye and Ear, Clayton General, Grady, and Crawford W. Long hospitals in Atlanta.

Dr King made numerous contributions to the medical literature in otolaryngology and was recognized as an authority on techniques of tonsillectomy and adenoidectomy and the management of the complications of this surgery. He gave courses at the American Academy of Ophthalmology and Otolaryngology's annual meetings for a number of years and was a guest lecturer for the New England Society of Otolaryngology and other regional societies.

Dr King was a member of the Trinity Presbyterian Church in Atlanta. He traveled extensively in Europe and was an authority on the wines of France, Italy, and Germany. His hobbies included photography, jogging, bicycling, and mechanical maintenance of his Rolls Royce automobile.

He is survived by his wife, the former Lavonia Foster of Atlanta; two children, James T. King, Jr, of Portland, Oregon, and Sue King Ellsworth of Atlanta, six grandchildren, and a brother, Raymond P. King of Tampa, Florida.

C.L.P.

LAWRENCE C. McHENRY
1901-1985

Lawrence C. McHenry was born on August 23, 1901, in Princeton, Missouri. His early education was completed in Oklahoma City. Dr McHenry earned an AB degree from DePauw University, Greencastle, Indiana. He graduated from Harvard Medical School in 1925 and took a 2-year rotating internship at the Brooklyn Hospital. He studied at the University of Pennsylvania Graduate School of Medicine and the Chevalier Jackson Bronchoscopic Clinics from 1927 to 1928. He was a Diplomate of the American Board of Otolaryngology.

Dr McHenry practiced in Oklahoma City from 1929 to 1970. He was a member of the medical staffs of the St Anthony's Hospital, Wesley (later Presbyterian Hospital), and Mercy Hospital. Throughout his career he was active in the teaching program of the Department of Otorhinolaryngology of the University of Oklahoma Health Sciences Center. Dr McHenry was a dedicated physician and a good teacher; he was promoted to Professor in the 1950s. Integrity was one of his outstanding characteristics. He exerted a great deal of influence on the teaching program at the University of Oklahoma, was instrumental in the founding of the Oklahoma Medical Research Foundation, and served on the Board of Directors of the Oklahoma Blue Cross/Blue Shield for many years.

Chester McHenry's leadership was recognized widely. He served as President of the Oklahoma City Academy of Medicine and the Oklahoma State Medical Association and as Vice-President of the Middle Section of the Triological Society. He was a Fellow of the American College of Surgeons and a member of the American Broncho-Esophagological Association.

Dr McHenry was married in 1923 in North Conway, New Hampshire, and had a son, Larry, who was named for him. In 1933, his wife died, and in 1934 he married Maryellen Childers in Homewood, Illinois. A son, Patrick Earl McHenry, was born of this union. Lawrence C. McHenry, Jr, became a distinguished neurologist and died several months before his father's death. Mrs McHenry died several months after Dr McHenry's death, which occurred on June 8, 1985, in Oklahoma City. He is survived by Patrick and his sister, Florence Mee, of Oklahoma City.

Chester McHenry will be remembered by all of his colleagues as a devoted and loyal friend.

E.A.W.

JOHN J. O'KEEFE
1909-1985

John J. O'Keefe died on November 8, 1985, at the age of 76. A native Philadelphian, his undergraduate education was obtained at St Joseph's College. His entire professional career was spent at Jefferson Medical College of Thomas Jefferson University except for service in the European Theatre in World War II from 1942 to 1945 as a major in the medical corps of the US Army Air Force. He joined the faculty of Thomas Jefferson University in 1941 and advanced academically through the ranks until he was named Professor in 1968 and Chairman of the Department of Otolaryngology from 1973 to 1975.

He received the first Ross V. Patterson Fellowship in Bronchoesophagology, 1939-1940, and then became an assistant to Dr Louis H. Clerf, whose influence he cherished throughout his lifetime.

A keen clinician, he maintained an active private practice concerned primarily with laryngology and bronchoesophagology. Along with his duties at Jefferson, he was also busy as consultant in laryngology and bronchoesophagology at Nazareth, Misericordia, and St Joseph's Hospitals in Philadelphia, Our Lady of Lourdes Hospital in Camden, New Jersey, and the Veteran's Administration hospitals in Coatesville, Pennsylvania, and Wilmington, Delaware.

He was a frequent contributor to the medical literature with 35 articles and 22 chapters in books. His national society affiliations included the American Academy of Otolaryngology-Head and Neck Surgery, American Broncho-Esophagological Association, American College of Chest Physicians, American College of Surgeons, American Laryngological, Rhinological and Otological Society, American Thoracic Society, and the American Laryngological Association.

Long membership on the executive committee of the alumni association of Jefferson Medical College was highlighted by acting as agent of his class of 1937 for the annual giving fund.

In vacation periods and summers, he enjoyed the south New Jersey seashore, and his favorite activities were boating and offshore fishing.

His wife, Virginia, predeceased him by just several months. Surviving are twin sons and three other children.

F.J.P.



FRANCIS A. SOOY
1915-1986

One of our most honored otolaryngologists, Francis A. Sooy, MD, died in a private plane crash on Sept 12, 1986, in the small Sacramento–San Joaquin River delta town of Rio Vista. It was an untimely death for this accomplished, adventuresome, and busy man. At age 71, he was in excellent health and had a boundless schedule of activities, including a busy otological practice, regular attendance at clinics at San Francisco General Hospital and at the University of California Hospital, the assembly of a mid-1930 replica of an Auburn speedster in his basement, the maintenance and riding of a stable of antique motorcycles that he had restored in previous years, the antique World War II Stearman biplane that he had restored to museum-piece specifications and that he frequently flew, season tickets for the football games of his beloved University of California Bears, fund raising and administrative consulting roles for the University of California, and his family life with his wife, Betty, and his five children, all of whom live in the Bay area. On the other hand, Dr Sooy loved flying and he loved machinery; he knew the risks and limitations of both and discussed these freely and prophetically with his friends and colleagues on many occasions. Dr Sooy was both a realist and a dreamer. Very few of us will dream such magnificent dreams nor will we make as many of them happen as did Frank Sooy. And very few of us his age or younger will pass from this earth with a busier agenda than he had.

Dr Sooy was a Californian first, last, and always, except for 2 years of active duty and combat service with the Navy during WW II and his years of otolaryngology residency at Washington University in St Louis in the 1940s. He was born in 1915 in the little southern San Joaquin valley town of Coalinga in the heyday of the early discovery and development of oil in the Bakersfield–Kern County area.

His father, an engineer, was graduated from the University of California at Berkeley, worked for the Standard Oil Company of California, and died of tuberculosis when Dr Sooy was only 3 years old, leaving Mrs Sooy, who returned to teaching school, to raise Frank and his younger brother through the difficult Depression years. Despite these hardships, Dr Sooy went on to become a Phi Beta Kappa member at the University of California at Berkeley, and subsequently at the University of California at San Francisco School of Medicine he was elected to Alpha Omega Alpha. His younger brother graduated from the US Naval Academy at Annapolis and died in action during WW II.

Following duty with the Navy in WW II, Dr Sooy entered private practice in San Francisco and joined the clinical faculty of the University of California at San Francisco. In 1958 he succeeded Lewis Morrison, MD, as Chairman of the Division of Otolaryngology at UCSF. Shortly thereafter he joined the full-time faculty at UCSF and moved his practice to the university campus. In 1967, he successfully petitioned for independent departmental status for otolaryngology at UCSF. During his tenure as program chairman, Dr Sooy built the program of his dreams by installing a full-time research laboratory service, a full-time speech and hearing science PhD program, and a clinical otolaryngology department that was broadly based in the modern aspects of the field.

During these same years Dr Sooy had great dreams for the university. The "turbulent 1960s" were difficult times for the university with much student and general public unrest. As Dr Sooy became increasingly involved in faculty and university committees and governance, his skills and credibility as an arbitrator, administrator, and leader became widely recognized, and in 1969 he was elected Chairman of the Assembly of the Academic Senate of the combined faculties of all campuses of the university. His quietly effective and mature manner in this role brought greater stability to the faculty and its relationship with the university leadership and legislature, and led to his becoming the overwhelming choice of the Regents in 1972 as the Chancellor of the UCSF campus.

During his 10 years as chancellor, Dr Sooy was responsible for a major expansion and modernization of the physical facilities including a new School of Dentistry and a major new hospital addition. During these same 10 years, UCSF achieved preem-

inence as a health science research institution. Dr Sooy also made great strides at weaving the university into the social, economic, and political fabric of the greater San Francisco community.

Throughout his remarkable academic and professional career, Dr Sooy's first love was always the specialty of otolaryngology. Even when he was chancellor of the UCSF campus, he maintained office hours and a regular surgical schedule, working Saturday mornings in the office and Saturday afternoons in the operating room to minimize any interference his practice might have upon his weekday responsibilities as chancellor. He was a superb otologist and a model physician. His patients loved him and his colleagues had the utmost respect for his skill and judgment. Dr Sooy was a member of most of our major specialty societies and was president of many, including the Triological Society, the American Otological Society, the Society of University Otolaryngologists, and the Collegium Oto-Rhino-Laryngologicum Amicitiae Sacrum. He served as a member of the Board of Directors of the American Board of Otolaryngology for many years.

Frank Sooy has been referred to as a Renaissance man and a man for all seasons. He did indeed have many interests and many talents. He gave greatly of himself to his patients, to his students, to otolaryngology, and to his alma mater in ways that very few are privileged to serve. He will be missed by all who were fortunate enough to know him.

R.B.



GABRIEL F. TUCKER, JR
1924-1986

Gabriel F. Tucker, Jr, a Fellow and Past President of the American Laryngological Association, died in Chicago on December 8, 1986, following a prolonged illness that terminated a distinguished and diverse career.

His early education was at Waldron Academy and Haverford School. College years at Princeton were interrupted by service as a line officer in the Navy from 1943 to 1946. After graduating from Princeton in 1947, he enrolled at Johns Hopkins School of Medicine, where he graduated in 1951. Internship and residency training were at the Graduate Hospital of the University of Pennsylvania, where his father, Gabriel F. Tucker, Sr, a distinguished longtime associate of Chevalier Jackson, had succeeded Dr Jackson as Chairman of the Department of Broncho-Esophagology and Laryngeal Surgery. He also trained at the Children's Hospital in Philadelphia and The Johns Hopkins Hospital.

Following 3 years at the University of North Carolina in the Departments of Surgery and Otolaryngology, he returned to Johns Hopkins as Assistant Professor of Laryngology and Otology; here he was associated with Edwin Broyles and assisted in the further development of the Broncho-Esophagology Clinic.

Dr Tucker joined the Department of Broncho-Esophagology and Laryngology (Chevalier Jackson Clinic) at Temple University in 1962. Having modified techniques for serial section of the temporal bone for application to the larynx, he became a pioneer in coronal section research relating to the spread of cancer of the larynx; the same techniques were applied to embryologic and developmental aspects of laryngeal anatomy. In addition to clinical work at Temple, he supervised the pediatric division of the Chevalier Jackson Clinic at St Christopher's Hospital and collaborated in the intensive postgraduate courses in bronchoesophagology at the Jackson Clinic. In 1975 he was invited to be Head of the Division of Otolaryngology and Department of Communication Disorders at Children's Memorial Hospital in Chicago and Professor of Otolaryngology and Maxillofacial Surgery at Northwestern University, positions which he retained until his death.

Dr Tucker was active in all of our societies and served with distinction in official capacities in many of them. Having been Historian-Editor of the American Laryngological Association for 7 years, he was President from 1984 to 1985. He was President of the American Council of Otolaryngology (1974-1975) and of the American Broncho-Esophagological Association (1973-1974), Executive Secretary-Treasurer of the International Broncho-Esophagological Society beginning in 1983, and a Founding Fellow of the Section on Otolaryngology and Broncho-Esophagology of the American Academy of Pediatrics. He was an Honorary Member of the Irish Otolaryngology Society, the Australian Otolaryngology Society, the Columbian Otorhinolaryngological Society, and a Fellow of the Royal Society of Medicine, London.

As a productive author, he contributed much to the basic as well as the clinical science of the speciality, especially in the fields of cancer of the larynx and pediatric endoscopy. Skilled in his clinical work, diligent in his research, and dedicated in his teaching, Gabriel also had the personal qualities of tolerance, patience, and sympathy.

Devoted to family as well as to his profession, he shared with Mary the joys and responsibilities of six fine children. His philosophical acceptance of the inevitable and his courage in facing the relentless progression of his disease enabled him to continue his work until nearly the end. We are all enriched by the legacy of his life and accomplishments.

C.M.N.



PIERRE P. VIOLÉ
1896-1986

Pierre P. Violé was born in Los Angeles in 1896. He was the grandson of the first English-speaking physician in Los Angeles. He graduated from Los Angeles High School in 1914 and served in the Army Medical Corps during World War I. He completed his medical studies at Los Angeles College of Physicians and Surgeons, which later became the University of Southern California School of Medicine. Dr Violé took his internship at Los Angeles County Hospital and his residency in otolaryngology at Bellevue Hospital in New York.

He returned to Los Angeles in 1924 and began his practice; he retired 37 years later in 1961. During his long practice, he became a clinical professor of otolaryngology at the University of Southern California School of Medicine and was continuously on the attending staff at the Los Angeles County Hospital and the Los Angeles Children's Hospital. Dr Violé served as Chief of Staff at the French Hospital in Los Angeles. He was a founding member and President of the Research Study Club of Los Angeles and President of the Los Angeles Oto-Ophthalmological Society. Dr Violé became a member of the Triological Society in 1932. He was elected to active Fellowship in the American Laryngological Association in 1941.

Dr Violé contributed to our literature on the surgical treatment of deafness; the treatment of streptococcal infection; and the causes and surgical treatment of facial paralysis, carotid body tumors, and schwannomas of the pharynx.

Dr Violé died on April 4, 1986, at 90 years of age. He will be remembered as a fine, charming man and a distinguished physician. He is survived by his wife, Edith Taix Violé; a son and physician, Armand Violé; a daughter and professor of medical history at the University of California at Los Angeles, Ynez Violé O'Neill, and a sister, Andrea Violé Floyd.

J.B.S.

ROSTER OF FELLOWS
1987

Date indicates year admitted to active fellowship. Attendance at meetings is shown by figures following each name. Asterisk indicates year paper was read. Year and asterisk in parentheses indicates coauthor of paper but not present at meeting.

Active Fellows — 99

1987 Adkins, Warren Y., Jr, Med Univ of SC, 171 Ashley Ave, Charleston, SC 29425, 1987.

1974 Alford, Bobby R., 1200 Moursund Ave, Houston, TX 77025, 1974, '78, '80-'83, '85-87.

1984 Applebaum, Edward L., 1855 W Taylor St, Chicago, IL 60612, 1984-'87*.

1975 Bailey, Byron J., Dept of Otolaryngol, UTMB, Galveston, TX 77550, 1975, '76*-'78, '81, '82, '84-'87.

1987 Baker, Shan R., Univ of Mich Hosp, 1405 E Ann St, Ann Arbor, MI 48109, 1987.

1970 Ballenger, John J., 723 Elm St, Winnetka, IL 60093, 1971-'87.

1963 Baxter, James D., 687 Pine Ave West, Montreal, 112, P.Q. H3A 1A1, Canada, 1963, '65*-'74, '76-'80, '82, '85-'87.

1975 Biller, Hugh F., Mt Sinai Hosp, 100th St & Fifth Ave, New York, NY 10029, 1975-'77*, '78*, '79*, '80*, '81*, '82*, '83*, '84*, '85, '86*, '87*.

1977 Blaugrund, Stanley M., 115 E 61st St, New York, NY 10021, 1977-'84*, '85-'87.

1987 Blitzer, Andrew, Columbia Univ, 630 W 168th St, New York, NY 10032, 1987.

1975 Boles, Roger, Dept of Otolaryngol, Univ of California, San Francisco, CA 94122, 1975-'82, '84-'87.

1984 Bone, Robert C., 10666 N Torrey Pine Rd, La Jolla, CA 92037, 1984, '86*.

1959 Brewer, David W., 1100 E Genesee St, Syracuse, NY 13210, 1959, '60*, '61, '62*, '63, '66, '70, '73, '74*, '77, '80, '81, '83, '85.

1976 Briant, T. David R., St Michael's Hosp, 30 Bond St, Toronto, Ont M5B 1W8, Canada, 1976, '77, '78, '80-'82, '85-'87.

1963 Bryce, Douglas P., O.P.D. Toronto General Hosp, Toronto, Ont M5G 1L7 Canada, 1963*, '64, '66*, '67*, '68*-'79*, '81, '83-'87*.

1979 Calcaterra, Thomas C., UCLA Med Ctr, Los Angeles, CA 90024, 1979, '85, '87.

1985 Canalis, Rinaldo F., UCLA Head and Neck Surg, 10833 LeConte, Los Angeles, CA 90024, 1985.

1976 Cantrell, Robert W., Univ of Virginia Med Ctr, Charlottesville, VA 22901, 1976, '77*-'80*-'82-'84*-'87.

1968 Chandler, J. Ryan, 1700 NW 10th Ave, Miami, FL 33136, 1968, '69*-'79*-'82-'84*-'87.

1985 Chodosh, Paul L., 800 Westminister Ave, Hillside, NJ 07205, 1985, '86.

1967 Cocke, Edwin W., Jr, 920 Madison, Memphis, TN 38103, 1967-'70, '72, '74-'78, '80, '82, '84, '86, '87.

1964 Cody, Claude C. III, 529 E Friar Tuck, Houston, TX 77024, 1964, '65, '67, '69, '71, '73, '77-'79, '81, '83-'85, '87.

1971 Cohen, Seymour R., 1300 N Vermont Ave, Los Angeles, CA 90027, 1971, '72*, '73*-'75*, '76*-'78*, '80*, '81*, '82*, '83*, '84-'86*, '87*.

1984 Crumley, Roger L., 350 Parnassus 501, San Francisco, CA 94117, 1984*, '86, '87.

1980 Cummings, Charles W., Dept of Otolaryngol, Univ of Washington, Seattle, WA 98195, 1980-'82*, '83*-'87.

1973 Dedo, Herbert H., Univ of California S.F., School of Med, 3rd and Parnassus, San Francisco, CA 94143, 1973*-'75*, '76*-'79*-'82*-'84*, '86*, '87.

1984 DeSanto, Lawrence W., 200 First St, Rochester, MN 55905, 1984.

1976 Doyle, Patrick J., 1081 Burrard, Vancouver, BC, V6Z 1Y6, Canada, 1976, '77*, '80*, '81*, '84, '86, '87.

1973 Duvall, Arndt J. III, Univ of Minnesota Hosp, 8-264 Phillips Wagensteen Bldg, Minneapolis, MN 55455, 1973*, '75-'78, '80, '81, '84, '86.

1968 Farrior, Richard T., 505 DeLeon, Tampa, FL 33606, 1968-'70*, '72, '74, '76-'81, '84-'87.

1964 Fearon, Blair, 308 Medical Arts Bldg, Toronto, Ont, M5R 2M8, Canada, 1964, '66-'71*, '72*, '73*, '74*-'78*-'81*, '82-'85*-'87.

1982 Fee, Willard E., Jr, Stanford Medical Center, Stanford, CA 94305, 1982-'87*.

1970 Frazer, John P., 601 Elmwood Ave, Rochester, NY 14642, 1971-'82, '86.

1977 Fredrickson, John M., Dept of Otolaryngol, Washington University, St Louis, MO 63110, 1977-'79*, '83-'87*.

1977 Gacek, Richard R., State Univ Hosp of the Upstate Med Ctr, 750 E Adams St, Syracuse, NY 13210, 1977*-'83*, '84*-'87*.

1981 Gates, George A., 7703 Floyd Curl Dr, San Antonio, TX 78284, 1981, '82*-'85*-'87.

1983 Goldstein, Jerome C., AAO-HNS, 1101 Vermont Ave NW, Washington, DC 20005, 1983-'87.

1985 Goode, Richard L., Div of Otolaryngol, R-135, Stanford Univ, Stanford, CA 94304.

1985 Gross, Charles W., 266 S Cleveland #202, Memphis, TN 38104, 1985-'87.

1987 Hawkins, Donald B., 1200 N State St, Los Angeles, CA 90033, 1987.

1983 Healy, Gerald B., 300 Longwood Ave, Boston, MA 02115, 1983, '84*, '85*-'87.

1983 Hicks, Julius N., 924 S 18th St, Birmingham, AL 35205, 1983, '84*-'87.

1986 Holinger, Lauren D., 155 N Michigan Ave, Suite 325, Chicago, IL 60601, 1986, '87*.

1974 Hudson, William R., Duke Univ Med Ctr, ENT, POP, 3805, Durham, NC 27710, 1974-'78*, '81-'87.

1983 Jako, Geza J., 8 Porter St, Melrose, MA 02176, 1983, '85, '87*.

1983 Johns, Michael E., Dept of Otolaryngol-Head and Neck Surg, Johns Hopkins Hosp, 600 N Wolfe St, Baltimore, MD 21205, 1983, '84*-'87*.

1985 Kashima, Haskins K., Johns Hopkins Hosp, Osler 425, Baltimore, MD 21205, 1985, '86*, '87.

1975 Kirchner, Fernando R., 155 S 18th St, Kansas City, KS 66102, 1975*-'77, '79, '82*, '84, '86.

1979 Krause, Charles J., Univ Hosp, Ann Arbor, MI 48109, 1979-'82*, '84-'87*.

1981 Lawson, William, 19 E 98th St, New York, NY 10029, 1981*-'84*, '86*.

1979 LeJeune, Francis E., Jr, 1514 Jefferson Hwy, New Orleans, LA 70121, 1979-'82*, '83*-'87*.

1966 Lewis, John S., 3 E 71st St, New York, NY 10021, 1966-'69*, '72, '74-'76*, '78-'83*-'87*.

1976 Lingeman, Raleigh E., Riley Hosp, 702 Barnhill Rd, Indianapolis, IN 46223, 1976, '77*-'82*, '84, '86.

1973 Loré, John M., Jr, 2121 Main St, Buffalo, NY 14214, 1974*, '76, '77*, '78*, '81, '85, '86, '87*.

1987 Lucente, Frank E., 310 E 14th St, New York, NY 10003, 1987.

1978 Lyons, George D., 1542 Tulane Ave, New Orleans, LA 70112, 1978-'80, '82-'84.

1966 McCabe, Brian F., Dept of Otolaryngol, Univ Hosp, Iowa City, IA 52242, 1966, '69, '72*, '73, '75*, '76, '79*, '81*, '85, '86*, '87*.

1987 Maisel, Robert H., 701 Park Ave S, Minneapolis, MN 55415.

1976 Miglets, Andrew, 456 Clinic Dr, Rm 4118, Columbus, OH 43210, 1976-'78*, '80, '82, '85.

1987 Miller, Robert H., Dept of Otolaryngol, Tulane Med Sch, New Orleans, LA 70112, 1987.

1964 Montgomery, William W., 100 Charles River Plaza, Boston, MA 02114, 1964, '65*, '66*, '68*, '70-'72, '74*-'76*-'78, '80*-'82, '84-'87.

1986 Morrison, Murray D., 865 W 10th Ave, Vancouver, BC V5Z IL7, Canada, 1986, '87*.

1979 Myers, Eugene N., Dept of Otolaryngol, 230 Lothrop St, Pittsburgh, PA 15213, 1979, '80, '82*-'87.

1981 Neel, H. Bryan III, 200 First St, SW, Rochester, MN 55905, 1981, '82*-'85*-'87.

1980 Nichols, Richard D., Henry Ford Hosp, 2799 W Grand, Detroit, MI 48202, 1980, '81, '84, '87.

1986 Noyek, Arnold M., 99 Avenue Rd, Suite 207, Toronto, Ont M5R 2G5, Canada, 1986, '87.

1982 Olson, Nels R., St Joseph Mercy Hospital, PO Box 944, Ann Arbor, MI 48106, 1982, '83*, '85, '87.

1972 Pennington, Claude L., Jr, 800 First St, Macon, GA 31201, 1972, '73, '75, '76*, '78, '82-'87.

1967 Pratt, Loring W., 37 Lawrence Ave, Fairfield, ME 04937, 1967-'82, '84*-'87*.

1963 Reed, George F., 750 E Adams St, Syracuse, NY 13210, 1963, '65*, '66, '68, '69*-'73, '75-'82*-'87.

1985 Rice, Dale H., 1300 N Vermont Ave, #508, Los Angeles, CA 90027, 1985-'87.

1974 Ritter, Frank N., 2675 Englave Dr, Ann Arbor, MI 48103, 1974, '75, '77-'79, '81-'87.

1982 Rontal, Eugene, 21700 Northwestern Highway, Southfield, MI 48075, 1982, ('83*), '84*, '86*.

1981 Sasaki, Clarence T., 333 Cedar St, New Haven, CT 06510, 1981, '83, '85-'87.

1964 Saunders, William H., Ohio State Univ, Rm 3110, 456 Clinic Dr, Columbus, OH 43210, 1964-'66, '68*-'70*-'75*-'80, '82*-'84, '86, '87.

1984 Schild, Joyce A., Illinois Eye and Ear Inf, 1855 W Taylor St, Chicago, IL 60612, 1985*-'87.

1987 Schuller, David E., 456 Clinic Dr, Columbus, OH 43210, 1987.

1978 Sessions, Donald G., 1960 Grassy Ridge Rd, Kirkwood, MO 63122, 1979*, '80*, '81, '83, '84, '86, '87*.

1983 Sessions, Roy B., Memorial Sloan-Kettering Cancer Center, 425 E 67th St, New York, NY 10021, 1983*, '86, '87.

1979 Shapiro, Myron J., 101 Old Short Hills Rd, West Orange, NJ 07052, 1979-'81, '84, '86.

1962 Sisson, George A., Northwestern Univ Med Sch, 303 E Chicago Ave, Chicago, IL 60611, 1962, '63*, '65, '66, '68-'73, '76-'82, '84*, '85*-'87.

1964 Skolnik, Emanuel M., 1855 W Taylor St, Chicago, IL 60612, 1964*-'66*-'70*-'73, '75*-'80*-'82*, '85, '86*.

1974 Snow, James B., Jr, Univ of Pennsylvania, 3400 Spruce St, Philadelphia, PA 19104, 1974-'75*-'78*, '79, '81-'87.

1972 Soboroff, Burton J., 307 N Michigan Ave, Chicago, IL 60601, 1972-'77, '79, '80, '82, '86.

1973 Som, Max L., 121 E 60th St, New York, NY 10022, 1973, '74*, '75*-'78*, '79*, '80, '82, ('83*).

1979 Spector, Gershon J., Dept of Otolaryngol, Washington Univ, 517 S Euclid Ave, St Louis, MO 63110, 1979-'85.

1975 Sprinkle, Philip M., 125 N 6th St, Clarksburg, WV 26301, 1975-'78*-'82, '84-'87.

1975 Strong, M. Stuart, Bedford VA Hosp, 200 Spring St, Bedford, MA 01730, 1975, '76*-'78*, '79*, '81, '82*-'84*-'86*, '87.

1963 Tabb, Harold G., Dept of Otolaryngol, Tulane Med Sch, New Orleans, LA 70112, 1963, '65-'69, '71, '72, '74, '77-'84, '86, '87.

1979 Tardy, M. Eugene, 2913 N Commonwealth, No 430, Chicago, IL 60657, 1979, '82*, '84, '86.

1982 Thawley, Stanley E., Dept of Otolaryngol, Washington Univ, 517 S Euclid Ave, St Louis, MO 63110, 1982, '83*.

1978 Toomey, James M., 2 Broad Alley, Boston, MA 02113, 1979*-'81.

1979 Tucker, Harvey M., Dept of Otolaryngol, Cleveland Clinic, Cleveland, OH 44106, 1979, '80*-'82*, '84*, '85*, '86*, '87*.

1973 Tucker, John A., St Christopher's Hosp, 2600 N Lawrence St, Philadelphia, PA 19133, 1973*, '74*, '75*-'77*, '78*, '80-'85*-'87.

1984 Vaughan, Charles W., Veterans Adm Med Center, 150 S Huntington Ave, Boston, MA 02130, 1984-'86.

1980 Vrabec, Donald P., Dept of Otolaryngol, Geisinger Med Ctr, Danville, PA 17821, 1980, '81*, '83, '86, '87.

1974 Ward, Paul H., UCLA School of Medicine, Los Angeles, CA 90024, 1974*-'77*, '78*, '79*, '81*, '82*, '83*, '84*, '85, '86*, '87.

1981 Yanagisawa, Eiji, 98 York St, New Haven, CT 06511, 1981, '82*, '83*-'85*, '87*.

1983 Yarington, C. Thomas, Jr, 1100 9th Ave, POB 900, Seattle, WA 98111, 1983, '84*-'87.

Honorary Fellows — 9

1978 (1959) Barretto, Plinio de Mattos, Rua Cons Torres, Homen 371, Sao Paulo, Brazil, 1960, '69, '73, '80.

1957 (1925) Clerf, Louis H., 10300 4th St, North, St Petersburg, FL 33702, 1957-'61, '63-'66, '68-'72*-'78.

1984 (1957) Conley, John J., 211 Central Park West, New York, NY 10024, 1958*, '60*-'62*, '64, '65, '70, '72, '74*, '75*-'78, '80, '82, ('83*)-'86.

1984 (1960) Daly, John F., 16 N Brae Ct, Tenafly, NJ 07670, 1960, '61*, '79*, '81.

1986 Gould, Wilbur J., 47 E 77th St, New York, NY 10021.

1978 (1971) Harrison, D. F. N., 330/332 Gray's Inn Road, London, WCIX 8EE, United Kingdom, 1971, '77, '81*, '84*-'86*.

1984 (1956) Norris, Charles M., 3401 N Broad St, Philadelphia, PA 19140, 1956-'58*-'61*-'64, '66-'68*-'70*-'78*-'86.

1966 (1957) Ono, Jo, 6-13, 6-Chome, Roppongi, Minato-Ku, Tokyo, 106, Japan, 1971, ('85*), ('86*).

1968 (1957) Ruedi, Prof Dr Luzius, Zollikerstrasse 185, 8008 Zurich, Switzerland, 1957.

Corresponding Fellows — 23

1985 Aprigliano, Flavio, Rua Terezina 19, ZC-45 20,000 Rio de Janeiro, Brazil, 1985.

1978 Arauz, Juan Carlos, 2150 Cangallo, Buenos Aires, 1040 Argentina, 1980, '85*.

1972 Arslan, Prof Michele, Otorinolaringoiatrica dell' Universita da Padova, 37 Via Altinate, Padova, Italy, 1972.

1959 Bateman, Sir Geoffrey H., Thorney-Graffham, Petworth, West Sussex, GU280EA United Kingdom.

1980 Benjamin, Bruce, 229 Macquarie St, Sydney, NSW 2000 Australia, 1980, '81, '83*, '84*, '85*, '87*.

1964 Cleves, Carlos, Carrea 12, No 20-69, Bogota, Colombia.

1984 Evans, John N. G., 5 Lancaster Ave, London SE27, United Kingdom, 1985*.

1986 Ferlito, Alfio, Dept of Otolaryngol, Univ of Padua, Padua, Italy, 1986*, '87*.

1986 Fonseca, Rolando, Rioja 3920, La Lucila, Buenos Aires, Argentina.

1970 Halliday, Sir George C., 143 Macquarie St, Sydney, NSW 2000 Australia.

1984 Hirano, Minoru, Dept of Otolaryngol-Head and Neck Surg, Kurume Univ, 67 Asaki-machi, Kurume-shi 830, Japan, 1985*, '86*, '87*.

1970 Hutcheon, Jack, Morris Towers, 149 Wickham Terrace, Brisbane, 4000 Australia, 1971, '78, '80.

1985 Inouye, Tetsuzo, Dept of Otolaryngol, National Defense Med College, Tokorozawa, Saitama, 359, Japan, 1985, '87.

1978 Kleinsasser, Oskar, Deutschhausstrasse 3, 355 Marburg (Lahn), Cologne, West Germany, 1982*.

1971 Macbeth, Ronald G., Meadow Close, Church Hanborough, Oxford, United Kingdom.

1985 Murakami, Yasushi, Keio Univ Sch of Med, 35 Shinanomachi, Shinjuku-Ku, Tokyo, 160, Japan, 1985*, '86*, '87.

1968 Nakamura, Fumio, Kyoto Prefectural Univ Medicine, Kawara-Mach 1, Kamikyo-Ku, Kyoto, Japan.

1964 Perez, Alfredo C., Instituto Celis Perez, Avenida Montes Deoca, Valencia, Venezuela, 1965.

1985 Shaw, Henry J., Royal Marsden Hosp, Fulham Rd, London SW3 6JJ, United Kingdom, 1986.

1984 Snow, Gordon B., Dept of Otolaryngol, Free Univ, DeBodelaan 1117, 1007 MB, Amsterdam, The Netherlands, 1983*, '85, '86*.

1952 Tapia-Acuña, Ricardo, Av Insurgentes, Sur No. 300, Delegacion Cuauhtemoc 06700, Mexico 7 DF Mexico, 1953, '57, '60*, '67, '73, '75, '81*.

1987 Tu, Gui-yi, Dept of Head and Neck Surg, Cancer Hosp, Chinese Acad of Med Sciences, Pan Jia Yao, Chaoyang Qu, Beijing, People's Republic of China, 1987*.

1936 Vialle, Jacques, 27 Rue de France, Nice (Alpes Maritimes), France.

Emeritus Fellows — 39

1980 (1962) Arnold, Godfrey E., 543 C Hwy 80 W, Clinton, MS 39056, 1962, '63*, '64*, '66, '69, '70, '72, '73, '75, '77, '79.

1984 (1969) Ausband, John R., Emory Univ, 1365 Clifton Rd, NE, Atlanta, GA 30322, 1970-'73, '75, '78, '81.

1986 (1955) Bordley, John E., John Hopkins Hosp, Baltimore, MD 21205, 1955-'57, '59, '60, '62-'67, '69-'73*-'80, '82, '83, '85*, '86.

1986 (1955) Brown, Lester A., PO Box 98261, Atlanta, GA 30329, 1955-'59, '61, '63, '65, '68-'73*-'80, '82.

1965 (1942) Canfield, Norton, PO Box 1383, Miami, FL 33133, 1982, '84.

1985 (1966) Devine, Kenneth D., Mayo Clinic, Rochester, MN 55905, 1966-'68, '72*, '74*, '76*.

1980 (1968) DeWeese, David D., 3181 SW Sam Jackson Park Rd, Portland, OR 97202, 1968-'69*, '73-'80, '82.

1972 (1962) Erich, John B., Mayo Clinic, 200 Second Ave SW, Rochester, MN 55905.

1982 (1963) Ferguson, Charles F., 5281 Cape Leyte Way, Siesta Key, Sarasota, FL 33581, 1963, '64*, '66, '67*-'69*-'74*-'78*-'82.

1983 (1956) Friedberg, Stanton A., 5730 Kenwood Ave, Chicago, IL 60637, 1956, '57, '65*, '71*, '76*, '78*, '79*, '80, '82, '83*-'85.

1985 (1959) Goldman, Joseph L., 55 E 87th St, New York, NY 10028, 1959, '60*-'72*-'78*-'80, '82-'84.

1963 (1928) Goodyear, Henry M., 2012 Edgecliff Point, Cincinnati, OH 45206.

1980 (1965) Hanckel, Richard W., Jr, 1167 S Sherwood Dr, Florence, SC 29501, 1965-'67, '69-'74, '77-'80.

1978 (1960) Harris, Herbert H., 3457 Meadow Lake Lane, Houston, TX 77027, 1960, '61*-'65*-'75, '77-'79, '81-'84, '86, '87.

1968 (1942) Heatley, Clyde A., 1570 East Ave, Apt. 412, Rochester, NY 14610, 1942, '46*, '49, '50, '52-'53*-'55, '57, '58, '60, '61, '65.

1978 (1959) Henry, G. Arnold, Suite #2, Group Box 24, Lagoon City, RR #1, Brechin, Ont, L0K 1B0, Canada, 1959, '61, '63, '66, '67, '69, '70, '73.

1980 (1955) Hilger, Jerome A., 1700 S Lexington, St Paul, MN 55118, 1955-'56*-'60, '62-'66, '68-'71, '75-'78, '80, '82.

1977 (1957) Holmes, Edgar M., Graydale Circle, Auburndale, MA 02166, 1957, '59, '61, '63, '68, '70-'72, '74-'76, '80.

1985 (1963) Kirchner, John A., 333 Cedar St, New Haven, CT 06510, 1963, '65*, '67*-'69*-'71*-'75*, '77, '78, '80*, '82-'84*-'87.

1983 (1961) Lewy, Robert B., 25 E Washington, Chicago, IL 60602, 1961, '62*, '63, '65*, '67-'71, '73-'76*, '82, '83*-'87.

1987 (1952) Miller, Alden H., 1705 Rancho Ave, Glendale, CA 91201, 1952, '53*, '55, '57, '58*, '61, '62, '64, '66, '67-'73*, '74*, '76-'78*, '79, '81, '85.

1984 (1965) Miller, Daniel, 110 Francis St, Boston, MA 02215, 1965-'69*-'73*-'77*-'81*-'82*-'87*.

1985 (1972) Morse, Harry R., The Mooring, MTD #9, Middleboro, MA 02346, 1972, '75, '79-'81, '87.

1978 (1957) Munoz-MacCormick, Carlos Eduardo, 71 de Diego, Santurce, PR 00911, 1957-'80, '82-'84.

1984 (1961) Pang, Lup Q., 1374 Nuuanu Ave, Honolulu, HI 96817, 1961, '62*, '64, '66, '67, '69, '71-'73, '75, '77, '79-'82.

1984 (1961) Pastore, Peter N., 5503 Riverside Dr, Richmond, VA 23225, 1961, '62*, '64, '66, '67, '69-'76, '78, '80, '82, '86.

1976 (1951) Priest, Robert E., 322 Medical Arts Bldg, Minneapolis, MN 55402, 1977-'81.

1980 (1951) Putney, F. Johnson, 705 Knotty Pine Rd, Charleston, SC 29412, 1951-'53*-'58*-'63*-'64*-'68*-'69*-'70*-'72, '74-'78*, '79*, '82, '86.

1972 (1956) Richardson, John R., PO Box 52, Searsport, ME 04974.

1981 (1959) Sanders, Sam H., 1286 Peabody Ave, Memphis, TN 38104, 1959-'63, '65, '70-'73, '75, '78, '85.

1977 (1958) Simonton, Kinsey M., 951 Holly Ln, Boca Raton, FL 33432, 1958, '59*, '62, '64, '66, '67, '69, '72, '74, '75, '78, '82, '84.

1969 (1950) Smith, Austin T., 8401 Roosevelt Bldg, Philadelphia, PA 19152, 1970-'74.

1982 (1961) Suehs, Oliver W., 2805 Robbs Run, Austin, TX 78703, 1961, '62*-'64, '66, '68-'72, '74-'78, '80.

1983 (1954) Thornell, William C., 2328 Auburn Ave, Cincinnati, OH 45219, 1957, '59, '63, '68, '70, '72, '74, '77, '78, '80.

1973 (1963) Tolan, John F., 3419 47th Ave, NE, Seattle, WA 98105, 1963-'67, '69, '71, '73.

1977 (1962) Weaver, Delmar F., Medical Professional Bldg, PO Box 862, Culpepper, VA 22701, 1962-'64*, '65, '67*, '69-'70, '72, '74, '76.

1983 (1971) Williams, Russell I., 414 E 23rd St, Cheyenne, WY 82001, 1971, '72*-'74, '76-'78*, '80.

1987 (1951) Woodman, DeGraaf, PO Box 560, Easton, MD 21601, 1952-'55*-'76*-'87.

1975 (1953) Work, Walter P., 172 E Paseo de Golf, Green Valley, AZ 85614, 1953, '54, '56, '58, '59*, '62, '63*, '65, '67-'69, '72, '73, '75, '76, '78*, '79*, '82, '87.

OFFICERS 1987-1988

≈

PRESIDENT
BLAIR FEARON, MD

VICE-PRESIDENT (PRESIDENT-ELECT)
SEYMOUR R. COHEN, MD

SECRETARY
EUGENE N. MYERS, MD

TREASURER
JOHN M. FREDRICKSON, MD

HISTORIAN-EDITOR
JAMES B. SNOW, JR, MD

SECOND COUNCILOR
DOUGLAS P. BRYCE, MD

THIRD COUNCILOR
LORING W. PRATT, MD

COUNCILORS-AT-LARGE
ROBERT W. CANTRELL, MD
CHARLES W. CUMMINGS, MD
H. BRYAN NEEL III, MD

INDEX

AUTHORS

A

Andersen JW 158
Anderson RF Jr 158
Applebaum EL 140

B

Balogh K 158
Beals TF 177
Benjamin B 80, 200
Birt D 64, 200
Bryce DP 111

C

Catlin FI 38
Chaffey JT 158
Clark JR 158
Close L 187
Cohen SR 24, 84, 197, 198
Colton RH 99
Cooper DS 43
Cotton RT 59
Crockett DM 151
Croxson G 80
Crumley RL 197

D

Dedo HH 199
Dreyfuss AI 158
Dum R 29

E

Escajadillo JR 165
Esses BA 69

F

Fallon BG 158
Fata JJ 29, 197
Fee WE Jr 72, 115
Ferlito A 92
Finitzo T 187
Florman SH 43
Ford CN 200
Fredrickson JM 8, 123
Freeman F 187
Freeman J 64
Friedman M 140

G

Gacek RR 29
Gilbert RW 64, 111
Godley F 128
Gray S 59
Grybauskas V 140

H

Hirano M 136
Hochman M 115
Holinger LD 55
Hom DB 177

J

Jafek BW 69
Jako GJ 181
Jenkin D 64
Johns ME 7, 119

K

Kaiser T 123
Karzon R 123
Kirchner JA 197, 199
Kondraske G 187
Krause CJ 177
Kurita S 136

L

LeJeune FE Jr 147
Lewis JS 20
Lewy RB 197, 198, 199
Loré JM Jr 75
Lucente FE 201
Lusk RP 151

M

MacKenzie R 64
Malmgren LT 29
Matsuoka H 136
McCabe BF 151
McIlwain JC 111
Miller D 158, 199
Miller RH 159, 199
Mixon JH 151
Morrison MR 170
Muta H 128
Myer CM III 59
Myers EN 9, 200, 201

N

Nagorsky MJ 106
Norris CM Jr 158

O

Obana KK 77

P

Painter C 123
Pearson B 200
Pool K 187
Pratt LW 13, 18, 23
Price BJ 47

R

Richtsmeier WJ 119
Ross IR 111

S

Schaefer S 187
Sessions DG 106, 198, 199, 200
Shangold L 99
Shulman H 64
Smith C 64
Smith RJH 38
Snow JB Jr 7
Stanley RB Jr 43
Strong MS 198
Styczynski P 119

T

Thompson JW 84
Toriumi DM 140
Tu G-y 174, 200, 201
Tucker GF Jr 55
Tucker HM 198, 199
Tucker JA 21

V

Volk MS 55

W

Ward PH 201
Watson B 187
Wolf GT 177
Woo P 29, 99

Y

Yanagisawa E 128

SUBJECTS

A

Annual photograph 4

Aspiration
- Management of patients with long-term tracheotomies and aspiration 111

Awards
- Casselberry, De Roaldes, Newcomb, Gabriel F. Tucker 11

B

Bronchoscopy
- Routine, and bronchial cytology for detection of occult pulmonary cancers in patients with squamous carcinoma of upper aerodigestive tract 177

C

Carcinoma
- Nasopharyngeal carcinoma: Dana-Farber Cancer Institute experience with 24 patients treated with induction chemotherapy and radiotherapy 158

Carcinoma — aerodigestive tract
- Routine bronchoscopy and bronchial cytology for detection of occult pulmonary cancers in patients with squamous carcinoma of upper aerodigestive tract 177

Carcinoma — glottis
Chronic gastroesophageal reflux as causative factor in ... 170

Carcinoma — larynx
Correlation of tumor volume with local control in laryngeal carcinoma treated by radiotherapy ... 64
Malignant laryngeal epithelial tumors and lymph node involvement: therapeutic and prognostic considerations ... 92
Selective, histamine-mediated immunosuppression in laryngeal cancer ... 119

Carcinoma — oral cavity
Laser resection for early oral cavity cancer. Results and complications ... 106

Chemotherapy
Nasopharyngeal carcinoma: Dana-Farber Cancer Institute experience with 24 patients treated with induction chemotherapy and radiotherapy ... 158

Conradi-Hunerman syndrome
Conradi-Hunerman syndrome. Case report ... 115

Cricothyroidotomy
Cricothyroidotomy: decade of experience in Denver ... 68

D

Daniel C. Baker, Jr, Memorial Lecture ... 47

Deglutition
Unusual pharyngeal lesion causing dysphagia ... 77

Diagnosis
Thirteenth Daniel C. Baker, Jr, Memorial Lecture. Monoclonal antibodies: coming revolution in diagnosis and treatment of human disease ... 47

Discussions ... 197

Dysphagia
Unusual pharyngeal lesion causing dysphagia ... 77

E

Electromyography
Vocal tract electromyographic abnormalities in spasmodic dysphonia: preliminary report ... 187

Endoscopy
Selection of video cameras for stroboscopic videolaryngoscopy ... 128
Telescopic endolaryngeal surgery ... 75

Executive Sessions
Minutes ... 6
Reports ... 7

F

Fellows
Registration ... 5
Roster ... 212

G

Gabriel F. Tucker
Biography of Gabriel F. Tucker, Sr ... 21
Presentation of Gabriel F. Tucker Award ... 23
Recipients of Gabriel F. Tucker Award ... 11
Response of recipient of Gabriel F. Tucker Award ... 24

Gastroesophageal reflux
Chronic, as causative factor in glottic carcinoma ... 170

Guest of Honor
Address ... 20
Introduction ... 18

I

Immunology
Selective, histamine-mediated immunosuppression in laryngeal cancer ... 119

Interferon
Side effects of toxicity of interferon in treatment of recurrent respiratory papillomatosis ... 151

L

Larynx
Vocal ligametry. Update ... 147

Larynx — pathology
Congenital laryngeal anomalies associated with tracheal agenesis ... 55
Correlation of tumor volume with local control in laryngeal carcinoma treated by radiotherapy ... 64
Malignant laryngeal epithelial tumors and lymph node involvement: therapeutic and prognostic considerations ... 92
Phonatory airflow analysis in patients with laryngeal disease ... 99
Use of botulinum toxin to lateralize true vocal cords: biochemical method ... 84
Vocal function following hemilaryngectomy ... 136

Larynx — surgery
Adjunctive measures for successful laryngotracheal reconstruction ... 59
Conservation laryngectomy ... 174
Telescopic endolaryngeal surgery ... 75

Laser surgery
Laser resection for early oral cavity cancer. Results and complications ... 106
Laser surgical treatment of chronic tonsillitis ... 181

M

Memorial Fund, Laryngological Research Fund ... 12

Memorials
Albert H. Andrews, Jr, MD ... 202
Lawrence R. Boies, MD ... 203
Francis W. Davison, MD ... 204
James T. King, MD ... 205
Lawrence C. McHenry, MD ... 206
John J. O'Keefe, MD ... 207
Francis A. Sooy, MD ... 208
Gabriel F. Tucker, Jr, MD ... 210
Pierre Violé, MD ... 211

Monoclonal antibodies
Thirteenth Daniel C. Baker, Jr, Memorial Lecture. Monoclonal antibodies: coming revolution in diagnosis and treatment of human disease ... 47

N

Nerve implantation
Histochemical study of posterior cricoarytenoid muscle reinnervation by nerve-muscle pedicle in cat ... 29

Neuromuscular pedicle transfer
Histochemical study of posterior cricoarytenoid muscle reinnervation by nerve-muscle pedicle in cat ... 29

O

Officers
1986-1987 ... 5
1987-1988 ... 216

Osteomuscular pedicle
Use in conservation laryngectomy 174

P

Papilloma
Side effects and toxicity of interferon in treatment of recurrent respiratory papillomatosis 151
Pharynx
Unusual pharyngeal lesion causing dysphagia 77
Presidential Remarks 13
Prosthesis
Human speech development for implantable artificial larynx 123

R

Radiotherapy
Nasopharyngeal carcinoma: Dana-Farber Cancer Institute experience with 24 patients treated with induction chemotherapy and radiotherapy 158
Reconstruction surgery
Adjunctive measures for successful laryngotracheal reconstruction 59
Reports
Governor, American College of Surgeons 7
Historian-Editor 7
Liaison Director, American Board of Otolaryngology 9
Treasurer 8

S

Silastic implant
Technique for external mobilization of vocal cord with Silastic implant 165
Spastic dysphonia
Treatment of spastic dysphonia without nerve section 140
Vocal tract electromyographic abnormalities in spasmodic dysphonia: preliminary report 187
Speech
Human speech development for implantable artificial larynx 123
Stenosis
Acquired subglottic stenosis in children 38
Stroboscopic laryngoscopy
Selection of video cameras for stroboscopic videolaryngoscopy 128

T

Thyroid
Phonatory effects of thyroid cartilage fractures ... 43
Tonsillitis
Laser surgical treatment of chronic tonsillitis 181
Trachea
Acquired subglottic stenosis in children 38
Adjunctive measures for successful laryngotracheal reconstruction 59
Congenital laryngeal anomalies associated with tracheal agenesis 55
Cricothyroidotomy: decade of experience in Denver 69
Management of patients with long-term tracheotomies and aspiration 111
Tracheostomy
Conradi-Hunerman syndrome. Case report 115

V

Videolaryngoscopy
Selection of video cameras for stroboscopic videolaryngoscopy 128
Vocal fold
Technique for external mobilization of vocal cord with Silastic implant 165
Use of botulinum toxin to lateralize true vocal cords 84
Vocal ligament
Vocal ligametry. Update 147
Vocal nodules
Vocal nodules in children 80
Voice
Phonatory airflow analysis in patients with laryngeal disease 99
Phonatory effects of thyroid cartilage fractures ... 43
Vocal function following hemilaryngectomy 136
Voice disorders
Treatment of spastic dysphonia without nerve section 140
Vocal nodules in children 80



Vol. 108 (1987)