TRANSACTIONS

AMERICAN LARYNGOLOGICAL ASSOCIATION

1991

VOLUME ONE HUNDRED TWELVE

"DOCENDO DISCIMUS"

ONE HUNDRED TWELFTH ANNUAL MEETING

HYATT REGENCY WAIKOLOA HOTEL

WAIKOLOA, HAWAII

MAY 4-5, 1991

PUBLISHED BY THE ASSOCIATION
ST LOUIS, MISSOURI
PAUL H. WARD, MD, EDITOR

CONTENTS

Annual Photograph 5

Officers for 1990-1991 6

Registration of Fellows 6

Minutes of the Executive Sessions 7

Reports

Secretary, H. Bryan Neel III, MD, PhD 8

Historian-Editor, Paul H. Ward, MD 8

Representative to the Board of Governors of the American Academy of Otolaryngology–Head and Neck Surgery, William R. Hudson, MD 8

Governor, American College of Surgeons, Michael E. Johns, MD 9

Liaison Director, American Board of Otolaryngology, Eugene N. Myers, MD 9

Treasurer, Robert W. Cantrell, MD 10

Recipients of the De Roaldes, Casselberry, Newcomb, Gabriel F. Tucker, American Laryngological Association, Resident Research, and Young Faculty Research Awards 13

Memorial and Laryngological Research Funds 14

Presidential Remarks. Mission and Priorities of the National Institute on Deafness and Other Communication Disorders. James B. Snow, Jr, MD 15

Introduction of Guest of Honor Douglas P. Bryce, MD. James B. Snow, Jr, MD 19

Guest of Honor Address. The Golden Years. Douglas P. Bryce, MD 20

Presentation of the American Laryngological Association Award to Arnold E. Aronson, PhD. James B. Snow, Jr, MD 22

Response of the Recipient of the American Laryngological Association Award. Arnold E. Aronson, PhD 23

Presentation of the Gabriel F. Tucker Award to John A. Tucker, MD. William R. Hudson, MD 24

Response of the Recipient of the Gabriel F. Tucker Award. John A. Tucker, MD 25

Presentation of the De Roaldes Award to William W. Montgomery, MD. James B. Snow, Jr, MD 26

Introduction of the 17th Daniel C. Baker, Jr, Lecturer, Charles W. Cummings, MD. James B. Snow, Jr, MD 27

Seventeenth Daniel C. Baker, Jr, Memorial Lecture

Otolaryngology–Head and Neck Surgery: A Model Specialty for the Future

Charles W. Cummings, MD 28

SCIENTIFIC SESSIONS

Clinical Staging for Primary Malignancies of the Supraglottic Larynx

Rene L. Zamora, MD; Edward L. Spitznagel, Jr, PhD; Donald G. Sessions, MD; Joseph E. Harvey, PhD 32

Preepiglottic Space Invasion in "Early" Epiglottic Cancer

Steven M. Zeitels, MD; Charles W. Vaughan, MD 41

Prognostic Significance of Tumor Site, Extension, and Mobility in Glottic Cancer

Murray D. Morrison, MD; Albino D. Flores, MD; Ashley Sikand, MD; J. Scott Durham, MD 45

Meta-Analysis of Second Malignant Tumors in Head and Neck Cancer: The Case for an Endoscopic Screening Protocol

Bruce H. Haughey, MBChB, FRACS; George A. Gates, MD; Cynthia L. Arfken, PhD; Joseph Harvey, PhD 51

Head and Neck Surveillance Program for Factory Personnel Exposed to Asbestos

Steven M. Parnes, MD; Malcolm Sherman, PhD 59

Carcinoma In Situ and Microinvasive Squamous Cell Carcinoma of the Vocal Cords

Robert E. Rothfield, MD; Eugene N. Myers, MD; Jonas T. Johnson, MD 65

Congenital Lack of Olfactory Ability

Donald A. Leopold, MD; David E. Hornung, PhD; James E. Schwob, MD, PhD 69

In Situ Hybridization and Laryngeal Papillomas
Frank Rimell, MD; Robert Maisel, MD; Vannesa Dayton, MD 77

Collagen in the Developing Larynx. Preliminary Study
Seymour R. Cohen, MS, MD; David T. Cheung, PhD; Marcel E. Nimni, PhD;
Vladimir Mahnovski, MD; Grace Lian, MD; Natasha Perelman; Alfonzo P. Carranza, MD 85

Strobovideolaryngoscopy: Results and Clinical Value
Robert T. Sataloff, MD; Joseph R. Spiegel, MD; Mary J. Hawkshaw, RN 90

Videostroboscopy of Human Vocal Fold Paralysis
Joel A. Sercarz, MD; Gerald S. Berke, MD; Ye Ming, MD; Bruce R. Gerratt, PhD;
Manuel Natividad 93

Bilateral Vocal Fold Motion Impairment: Pathophysiology and Management by Transverse Cordotomy
Haskins K. Kashima, MD 104

Stroboscopy for Glottic T1A Carcinomas: Its Role in Diagnosis
Minoru Hirano, MD; Rongxiang Zhao, MD; Shinzo Tanaka, MD;
Kiminori Sato, MD 109

Open Slope Quotient: An Estimator of Glottic Resistance
David H. Slavit, MD; Thomas V. McCaffrey, MD, PhD 114

Thyroarytenoid Intramuscular Pressures
Donald S. Cooper, PhD; Eric Pinczower, MD; Dale H. Rice, MD 122

Multichannel Electromyographic Observations in Spasmodic Dysphonia Patients and Normal Control Subjects
Steven D. Schaefer, MD; Rick M. Roark, PhD; Ben C. Watson, PhD; George V. Kondraske, PhD;
Frances J. Freeman, PhD; Robert W. Butsch, MS; John Pohl 131

Voluntary Control of the Soft Palate in Phonation
Eiji Yanagisawa, MD; Jo Estill; Lawrence Mambrino, MD; David Talkin 140

Noninvasive Technique for Estimating Subglottic Pressure and Laryngeal Efficiency
Michael C. Bard, MD; David H. Slavit, MD; Thomas V. McCaffrey, MD, PhD;
Richard J. Lipton, MD 148

Stable Internal Fixation of Fractures of the Partially Mineralized Thyroid Cartilage
John R. Austin, MD; Robert B. Stanley, MD, DDS; Donald S. Cooper, PhD 153

Free Jejunal Graft: Effects of Longitudinal Myotomy
Bruce H. Haughey, MBChB, FRACS; James W. Forsen, MD 158

Effect of Blood on the Incendiary Properties of Endotracheal Tubes Irradiated With the Carbon Dioxide Laser
Robert H. Ossoff, DMD, MD; Debra A. Gonzalez, MD 164

Point-Touch Technique of Botulinum Toxin Injection for the Treatment of Spasmodic Dysphonia
David C. Green, MD; Gerald S. Berke, MD; Paul H. Ward, MD; Bruce R. Gerratt, PhD 172

Physiologic Assessment of Arytenoid Adduction
David H. Slavit, MD; Nicolas E. Maragos, MD 177

Role of Injectable Collagen in the Treatment of Glottic Insufficiency: A Study of 119 Patients
Charles N. Ford, MD; Diane M. Bless, PhD; Jean M. Loftus, MD 184

Surgical Anatomy of the Pharyngeal Plexus
Mark I. Singer, MD 195

Lidocaine Effects on the Laryngeal Chemoreflex, Mechanoreflex, and Afferent Electrical Stimulation Reflex
Timothy M. McCulloch, MD; Paul W. Flint, MD; Mark A. Richardson, MD;
Michael J. Bishop, MD 199

Laryngeal Synkinesis Following Reinnervation in the Rat. Neuroanatomic and Physiologic Study Using Retrograde Fluorescent Tracers and Electromyography
Paul W. Flint, MD; Daniel H. Downs, MD; Marc D. Coltrera, MD 206

Characteristics of Late Responses to Superior Laryngeal Nerve Stimulation in Humans
Christy L. Ludlow, PhD; Frederick Van Pelt, MD; Junji Koda, ScD 216

Electrophysiologic Investigation of Lower Cranial Nerve Diseases by Means of Magnetically Stimulated Neuromyography of the Larynx
W. F. Thumfart, MD; C. Pototschnig, MD; P. Zorowka, MD; H. E. Eckel, MD 224

The Three Bellies of the Canine Cricothyroid Muscle
Lauren S. Zaretsky, MD; Ira Sanders, MD 230

Management of Airway Obstruction in Patients With Congenital Heart Defects
Deborah A. Davis, MD; John A. Tucker, MD; Pierantonio Russo, MD 244

Acquired Laryngomalacia: Epiglottis Prolapse as a Cause of Airway Obstruction
Peak Woo, MD 248

Special Instruments for Laryngeal Framework Surgery
Nobuhiko Isshiki, MD; Hisayoshi Kojima, MD; Masaki Sawada, MD 255

Injection and Removal of Teflon for Unilateral Vocal Cord Paralysis
Herbert H. Dedo, MD 258

Ethmoid Surgery Complications and Their Avoidance
Alan Sogg, MD; Berkley Eichel, MD 264

Irradiation-Induced Atherosclerosis: A Factor in Therapeutic Planning
W. Frederick McGuirt, MD; Robert S. Feehs, MD; Gene Bond, PhD; Harriet L. Strickland, DVM; William M. McKinney, MD 267

Microvascularization of the Laryngeal Cartilages and Its Oncologic Importance [Abstract]
Prof Mario Andrea 274

Medialization Laryngoplasty and the Arytenoid Adduction Procedure: Which and When? [Abstract]
James A. Koufman, MD 274

Discussions 275

Memorials
Lup Q. Pang, MD 282
Peter N. Pastore, MD 283
Sam H. Sanders, MD 285

Officers 1879-1990 286

Deceased Fellows 289

Roster of Fellows 1991 293

Officers 1991-1992 298

Index 299



FELLOWS IN ATTENDANCE AT THE ONE HUNDRED TWELFTH ANNUAL MEETING

First Row: Maisel, Maniglia, Hirano, Ward, D. Miller, Cantrell, Bryce, Snow, Fredrickson, Myers, Neel, Gross, Weymuller, Crumley.
Second Row: Calcaterra, Pratt, Ford, Blaugrund, Montgomery, Applebaum, Strong, Koufman, Cocke, Sisson, Hicks, Thumfart, Cohen.
Third Row: Goldstein, Loré, Lewis, Fearon, Andrea, Holinger, Morrison, Schild, Kim, Murakami, Yanagisawa, Tucker.
Fourth Row: Lucente, Kashima, Rice, Gullane, R. Miller, Canalis, Hawkins, Alford, Isshiki, Strome, Cummings, Hudson, Sessions.

OFFICERS 1990-1991

PRESIDENT

JAMES B. SNOW, JR, MD

VICE-PRESIDENT (PRESIDENT-ELECT)

JOHN M. FREDRICKSON, MD

SECRETARY

H. BRYAN NEEL III, MD, PHD

TREASURER

ROBERT W. CANTRELL, MD

HISTORIAN-EDITOR

PAUL H. WARD, MD

FIRST COUNCILOR

BLAIR FEARON, MD

SECOND COUNCILOR

SEYMOUR R. COHEN, MD

THIRD COUNCILOR

EUGENE N. MYERS, MD

COUNCILORS-AT-LARGE

BYRON J. BAILEY, MD
WILLIAM R. HUDSON, MD

REGISTRATION OF FELLOWS

ACTIVE

ADKINS, WARREN
ALFORD, BOBBY
APPLEBAUM, EDWARD L.
BLAUGRUND, STANLEY M.
BLITZER, ANDREW
CALCATERRA, THOMAS C.
CANALIS, RINALDO
CANTRELL, ROBERT W.
COHEN, SEYMOUR R.
CRUMLEY, ROGER L.
CUMMINGS, CHARLES W.
DEDO, HERBERT H.
DOYLE, PATRICK J.
FEARON, BLAIR
FEE, WILLARD E., JR
FORD, CHARLES N.
FREDRICKSON, JOHN M.
GACEK, RICHARD R.
GOLDSTEIN, JEROME C.
GROSS, CHARLES W.
GULLANE, PATRICK J.
HAWKINS, DONALD B.
HEALY, GERALD B.
HICKS, JULIUS N.
HIRANO, MINORU
HOLINGER, LAUREN D.
HUDSON, WILLIAM R.
ISSHIKI, NOBUHIKO
JOHNS, MICHAEL E.
JOHNSON, JONAS T.
KASHIMA, HASKINS K.
KOUFMAN, JAMES
KRAUSE, CHARLES J.
LEWIS, JOHN S.
LUCENTE, FRANK E.
MANIGLIA, ANTHONY J.
MAISEL, ROBERT H.
MARSH, BERNARD R.
MCGUIRT, WILLIAM F.
MILLER, ROBERT H.
MORRISON, MURRAY D.
MYERS, EUGENE N.
NEEL, H. BRYAN III
OSSOFF, ROBERT H.
PRATT, LORING W.
RICE, DALE H.
RITTER, FRANK N.
SCHILD, JOYCE A.
SCHULLER, DAVID E.
SESSIONS, DONALD G.
SHAPSHAY, STANLEY M.
SINGER, MARK I.
SNOW, JAMES B., JR
STROME, MARSHALL
TUCKER, JOHN A.
WARD, PAUL H.
WEYMULLER, ERNEST A.
YANAGISAWA, EIJI

EMERITUS

BALLENGER, JOHN J.
BRYCE, DOUGLAS P.
CHANDLER, J. RYAN
COCKE, EDWIN W., JR
CODY, CLAUDE C. III
LORÉ, JOHN M.
MILLER, DANIEL
MONTGOMERY, WILLIAM W.
SISSON, GEORGE A.
SOBOROFF, BURTON J.
STRONG, M. STUART

CORRESPONDING

ANDREA, MARIO
ISSHIKI, NOBUHIKO

MINUTES OF THE EXECUTIVE SESSIONS

FIRST SESSION — MAY 4, 1991

The First Executive Session of the 112th Annual Meeting was convened at 7:00 AM in the Monarchy Room of the Hyatt Regency Waikoloa Hotel, Waikoloa, Hawaii, James B. Snow, Jr, MD, Gaithersburg, Maryland, presiding.

A Nominating Committee consisting of Drs John S. Lewis, Charles W. Cummings, John A. Tucker, and Stanley M. Blaugrund was elected; Dr M. Stuart Strong was appointed Chairman.

The following candidates, having been recommended for Fellowship by the Council, were elected to *Active Fellowship*: Jack L. Gluckman, MD, Cincinnati, Ohio; Patrick J. Gullane, MD, Toronto, Canada; James A. Koufman, MD, Winston-Salem, North Carolina; Marshall Strome, MD, Boston, Massachusetts; Edward C. Weisberger, MD, Indianapolis, Indiana; to *Emeritus Fellowship*: Fernando R. Kirchner, MD, Tucson, Arizona; John S. Lewis, MD, New York, New York; Andrew W. Miglets, MD, Columbus, Ohio; Loring W. Pratt, MD, Fairfield, Maine; to *Corresponding Fellowship*: Professor Mario Andrea, Lisbon, Portugal; Patrick Bradley, MD, Nottingham, England; Yasuo Hisa, MD, Kyoto, Japan; Walter Franz Thumfart, MD, Cologne, Germany; to *Honorary Fellowship*: John A. Kirchner, MD, New Haven, Connecticut.

Following their election, the Active Fellows were introduced by their sponsors and welcomed by President Snow.

SECOND SESSION — MAY 5, 1991

The Second Executive Session was opened by President Snow at 1:30 PM, and the report of the Nominating Committee was received from Dr M. Stuart Strong. The following Fellows were nominated and unanimously elected to the Council: John M. Fredrickson; William R. Hudson; H. Bryan Neel III; Robert W. Cantrell; Paul H. Ward; Seymour R. Cohen; Eugene N. Myers; James B. Snow, Jr; Byron J. Bailey; and Charles J. Krause.

The reports of the Secretary, the Treasurer, and the Historian-Editor were submitted and accepted. The report of the Governor of the American College of Surgeons was given by Dr Michael E. Johns. The report of the Liaison Director of the American Board of Otolaryngology was given by Dr Eugene N. Myers.

At the President's direction, the newly elected members of the Council, acting as Directors of the Association, organized themselves for the year 1991-1992 as follows: President, John M. Fredrickson, MD; Vice-President (President-Elect), William R. Hudson, MD; Secretary, H. Bryan Neel III, MD; Treasurer, Robert W. Cantrell, MD; Historian-Editor, Paul H. Ward, MD; First Councilor, Seymour R. Cohen, MD; Second Councilor, Eugene N. Myers, MD; Third Councilor, James B. Snow, Jr, MD; Councilors-at-Large, Byron J. Bailey, MD, and Charles J. Krause, MD.

At the close of the Scientific Session, the Executive Session was reconvened by President Snow, who introduced Dr John M. Fredrickson as the new President of the Association. The meeting was adjourned.

REPORTS

REPORT OF THE SECRETARY

The membership prior to this annual meeting consisted of 98 Active members, 52 Emeritus members, 24 Corresponding members, and 8 Honorary members, for a total of 182 members. At the present time, after this year's elections, the membership now consists of 99 Active Members, 56 Emeritus members, 28 Corresponding members, and 9 Honorary members, for a total of 192 members.

There were 35 requests for applications and 14 formal submissions for the new American Laryngological Association Grant. The Laryngeal Research Fund Committee evaluated the grants and selected the best one for the $15,000 award. Already there have been several requests for applications in 1991.

The Accreditation Council for Continuing Medical Education reviewed the Association in 1990 and approved reaccreditation for 4 years. The Association will be due for routine resurvey in 1994.

The next meeting of the American Laryngological Association will be held at the Marriott Desert Springs Resort in Palm Desert, California, in conjunction with the 1992 Combined Otolaryngological Spring Meetings.

The next meeting of the Council — the First Council Meeting — of the American Laryngological Association will be held in conjunction with the Western Section of the Triological Society at the LaQuinta Hotel, LaQuinta, California.

Respectfully submitted,
H. Bryan Neel III, MD, PhD
Secretary

REPORT OF THE HISTORIAN-EDITOR

I have the sad duty to report the deaths of three Emeritus Fellows. Dr Lup Q. Pang was elected to Fellowship in 1961 and was elevated to Emeritus status in 1984. He died on July 28, 1990. Dr Peter N. Pastore was elected to Fellowship in 1961 and was elevated to Emeritus status in 1984. He died on September 16, 1989. Dr Sam H. Sanders was elected to active Fellowship in 1959 and was elevated to Emeritus status in 1981. He died on March 14, 1991. Would you please stand for a moment of silence.

Again, I call your attention to the fact that the Library of the Historian-Editor of the Association does not have a copy of the *Transactions* for the years 1879-85, 1888-89, 1891, 1893-97, 1899-1915, 1917, 1920-29, 1932-33, 1939-40, 1943, 1955, 1958, 1960, 1970, and 1976. The Association will gratefully receive copies of the missing issues as tax deductible contributions. A complete set from 1879 through 1991, belonging to the Association, is maintained in the library of the Eye and Ear Hospital in Pittsburgh, Pennsylvania.

Issues are available for sale to Fellows of the Association for $2.00 per copy for the years 1918, 1942, 1944-49, 1951, 1954, 1958-59, 1962, 1964-69, 1971-75, and 1977-89.

Manuscripts for the 1992 meeting should be in the hands of the Editor of the *Annals of Otology, Rhinology & Laryngology* by March 1, 1992. In the future, failure to follow instructions and not present a complete manuscript to the Editor-Historian will result in denial of presentation by Council action.

Respectfully submitted,
Paul H. Ward, MD
Historian-Editor

REPORT OF THE REPRESENTATIVE TO THE BOARD OF GOVERNORS OF THE AMERICAN ACADEMY OF OTOLARYNGOLOGY–HEAD AND NECK SURGERY

The Board of Governors of the American Academy of Otolaryngology–Head and Neck Surgery met twice during 1990: at the meeting of the American Laryngological, Rhinological and Otological Society, Inc, in Palm Beach, Florida, and at the Academy meeting in San Diego, California. Your representative attended both of these meetings. This report will combine the discussions of the meetings.

Both meetings were preceded by remarks from the President and the Executive Vice-President of the Academy. Their remarks related to the importance of the Board of Governors in determining the role of the Academy. The new building was discussed, particularly in relation to the Greater Academy Campaign.

Further discussion of the Greater Academy Campaign was presented by Drs Philip Sprinkle and William Moran. The need to identify well-to-do otolaryngologists and corporate sponsors was emphasized. Packets of promotional material are to be distributed to each Governor, and prospective donors will be identified.

Dr Gerald Healy expressed concern about the decline in the number of applications to medical schools. He suggested we approach our medical societies and try to do a better job in recruiting young people into medicine.

Recredentialing continues to be a hot topic. Dr Richard Farrior commented that recertification is not currently an issue. The Board of Governors is advocating a continuing education approach, with a requirement of 150 hours over a 5-year period.

Dr Robert Ruben presented the activities of the Legislative Key Docs program. Seventeen states have been identified that have attempted to restrict advertisements.

The most recent survey of members of the Board of Governors identified the most important concerns: 1 — reimbursement, 2 — turf wars, 3 — malpractice, 4 — medical education, 5 — recertification, and 6 — intrusion of government into medicine.

Questions for the nominees were finalized. These questions related to the nominees' opinions about added qualifications, efficient use of Academy resources, and the advisability of Academy involvement in establishing practice guidelines.

Finally, one member of the Board of Governors from the floor commented how the Through With Chew campaign had resulted in his discontinuing the habit. He then discussed his concerns about alcohol and alcohol-related injuries. He recommended alcohol-free Academy social functions to set an example to the public of our commitment to a drug-free society. The silence was deafening.

Respectfully submitted,
William R. Hudson, MD
Representative to the Board of Governors of the American Academy of Otolaryngology–Head and Neck Surgery

REPORT OF THE GOVERNOR OF THE AMERICAN COLLEGE OF SURGEONS

Your Governor attended the American College of Surgeons 1990 Board of Governors Meeting in San Francisco, California. In addition, he has participated in the State of Maryland functions. A detailed report of the activities of the 1990 Board of Governors and the College of Surgeons meeting has been submitted to the Association office for review.

The Board of Governors of the American College of Surgeons has eight major areas of concern.

Physician Reimbursement. The physician Medicare fee schedule required by the Omnibus Budget Reconciliation Act of 1989 has caused considerable concern among the Fellowship. It is hopeful that the College's lobbying efforts in Washington, DC, will have some effect in softening the thrust of the current legislative efforts to reduce fees for surgical service under Medicare.

Professional Liability and Malpractice. Professional liability and malpractice remains the second concern of the Governors. They indicate that the number of malpractice suits is down but that the awards are higher in those cases in which the plaintiff prevails. The number of cases won by the defense is remaining constant or even increasing in percentage. It is noted that premium rates seem to be temporarily stabilized, but there has been little progress in tort reform within most states.

Government and Third Party Intervention. The Governors have expressed increased frustration and a sense of helplessness in their efforts to preserve quality care for their patients. Surgeons are feeling pressure from outside sources to ration health care and compromise the quality of care, with no sharing of responsibility for outcome as a result of this rationing. There is increasing harassment of physicians by third party payors with attempts to dictate preoperative admission policies, length of stay, use of antibiotics, etc, that may result in deterioration in the quality of care.

Relations With Surgical and Medical Specialties. Many Fellows express concern about issues they perceive as encroachment within their sphere of activity. The problem is not unique to general surgery but encompasses other areas as well. The complaint of the various specialties is that procedures and activities that previously have been done almost exclusively by one specialty are now being encroached upon by other specialties. There is concern that general surgery as a specialty is seriously threatened.

Education, Credentialing, and New Technology. Another area of concern is in the area of education, credentialing, and new technology. Reports emphasize that the content and process of undergraduate medical education has become a focus of more frequent attacks. Because imperfections of the process have been identified and issues such as resident working hours have been publicly challenged, educational changes have been proposed giving little or no consideration for potential impact upon the end product of surgical training. There is universal agreement that 100-hour work-weeks are undesirable. However, changes must be made in a thoughtful manner so as to improve upon the overall educational experience.

The increasing costs of high-tech medicine in surgery are forcing rationing in several different ways around the country and forcing hospital budgets to the breaking point. Serious concerns are expressed about the reduction in federal support for health care education including training of residents and reduction of federal research support.

New surgical techniques outside the area of academic surgery with corresponding limited peer review is of concern to many surgeons. Practicing surgeons are in some instances dismayed at the cost for enrolling in those courses offered and the cost and delay in obtaining the equipment needed to perform the procedure.

Acquired Immune Deficiency Syndrome (AIDS). The Governors remain concerned about AIDS. Surgeons are concerned with their inability to order testing without elaborate permission, and red tape seems no less irrational than it did a year ago. The surgical community is concerned with the added expense of treating the AIDS patient.

Peer Review. Peer review continues as a major concern of the Governors. The concern of most is that the Peer Review Organizations will continue to establish regulations placing physicians in a defensive position.

Trauma. The Governors are primarily concerned with the lack of a method of funding for trauma care in the United States. There is growing concern that nonsurgeons have taken a leadership role in critical care units in North America, sometimes to the point of excluding surgeons from management of their own patients.

The specialty of otorhinolaryngology now accounts for 7.17% of the American College of Surgeons membership as the fourth largest group after general surgery, urology, and orthopedic surgery.

Respectfully submitted,
Michael E. Johns, MD
Governor, American College of Surgeons

REPORT OF THE LIAISON DIRECTOR OF THE AMERICAN BOARD OF OTOLARYNGOLOGY

The American Board of Otolaryngology (ABO) has met twice since our last Winter Council Meeting. At the meeting held in Chicago, Illinois, on March 17, 1990, a moment of silence was held for Dr David DeWeese, a former ABO Director, who died late in February. Dr Bobby R. Alford and Dr James B. Snow, Jr, were elevated to Senior Councilor status after many years of dedicated service to the ABO. They were honored at a special dinner on Monday, March 19, 1990. Dr Robert J. Ruben, Bronx, New York, and Dr Robert H. Miller, New Orleans, Louisiana, were elected to the Board of Directors. The financial condition of

the ABO was reported to be healthy.

Ninety-two candidates took the oral examination on March 18 and 19, 1990. Sixty (65%) of the candidates passed and 32 (35%) failed. On September 16, 1990, 340 candidates took the written examination. Two hundred thirty-eight (68%) of the candidates passed, 51 (15%) failed, and 60 (17%) became candidates for the oral examination.

A retreat for the ABO was held early in June in Charlottesville, Virginia, at which time a decision was made to separate the written and oral examinations. Beginning in 1991, the written examination will be taken by all candidates. Those who pass will be eligible to take the oral examination. It is necessary to pass both examinations in order to become certified by the ABO.

At a meeting held in Chicago, Illinois, on November 2, a very ambitious long range plan was presented in detail to the ABO by Dr Michael Johns and his Long Range Planning Committee. This was unanimously accepted by the Board of Directors, and plans were made for implementation of these suggestions.

At the same meeting, it was decided to move ahead with added qualifications in cosmetic facial surgery.

Respectfully submitted,
Eugene N. Myers, MD
Liaison Director
American Board of Otolaryngology

REPORT OF THE TREASURER

To the Board of Directors of the
American Laryngological Association

We have compiled the accompanying balance sheet of the American Laryngological Association as of March 31, 1991, and 1990, and the related statements of revenues, expenses, and changes in fund balances and cash flows for the years then ended, and the accompanying supplementary information presented only for supplementary analysis purposes, in accordance with standards established by the American Institute of Certified Public Accountants.

A compilation is limited to presenting, in the form of financial statements and supplementary schedules, information that is the representation of the management. We have not audited or reviewed the accompanying financial statements and, accordingly, do not express an opinion or any other form of assurance on them.

Respectfully submitted,
Deane and Fulton, Ltd

Charlottesville, Virginia
April 24, 1991

STATEMENT OF ASSETS, LIABILITIES, AND FUND BALANCES FOR THE YEARS ENDED MARCH 31, 1991, AND FEB 28, 1990

ASSETS

Current Assets:	*1991*	*1990*
Cash — checking	$ 60,293	$ 27,966
Certificate of deposit	100,000	99,000
Money Market Funds	2,384	201,750
Accounts receivable — dues	5,400	400
Accounts receivable — banquet	3,940	1,750
Accrued interest receivable	563	0
Total Current Assets	$172,580	$330,866
Long-term Investments:		
Marketable securities — stocks	12,786	85,953
US Treasury obligations	244,281	0
Total Assets	$429,647	$416,819

LIABILITIES AND FUND BALANCES

Liabilities:		
Unearned dues	$ 0	$ 7,400
Fund Balances (Deficit):		
General Fund	($ 9,151)	318
Trust Fund	438,798	409,101
Total Liabilities and Fund Balance	$429,647	$416,819

See Accountants' Compilation Report and Notes to Financial Statements.

STATEMENT OF REVENUES, EXPENSES, AND CHANGES IN FUND BALANCES FOR THE YEARS ENDED MARCH 31, 1991, AND FEB 28, 1990

Revenues:	*1991*	*1990*
Dues	$ 19,000	$ 15,200
COSM registration	21,654	7,700
Sale of publications	1,830	1,755
Donations	3,310	104,335
Annual meeting	14,140	19,715
Gain (loss) on sale of securities	(1,423)	18,543
Total revenues	$ 58,511	$167,248
Expenses:		
Annual meeting and banquet	$ 32,538	$ 34,771
Council travel and expenses	14,812	11,126
Printing, postage and supplies	12,942	16,474
Professional fees	1,212	4,460
Research awards/donations	15,200	500
Clerical	1,560	2,400
Administration	1,380	0
Other trust expenses	382	398
Miscellaneous	226	842
Total expenditures	$ 80,252	$ 70,971
Excess (deficit) of Revenues over Expenditures	($ 21,741)	$ 96,277
Investment Income	41,969	41,168
Excess of Revenues and Investment Income over Expenses	$ 20,228	$137,445
Fund Balances, beginning of year	409,419	271,974
Fund Balances, end of year	$429,647	$409,419

See Accountants' Compilation Report and Notes to Financial Statements.

STATEMENT OF CASH FLOWS FOR THE YEARS ENDED MARCH 31, 1991, AND FEBRUARY 28, 1990

Cash Flows From Operating Activities:	*Year Ended March 31, 1991*	*Year Ended Feb 28, 1990*
Excess of revenues and investment income over expenditures	$ 20,228	$137,445
Adjustment to reconcile with net cash provided:		
(Gain) Loss on sale of securities	1,423	(18,543)
Increase in accounts receivable — dues	(5,000)	(400)
(Increase) Decrease in accounts receivable — banquet	(2,190)	19,485
Increase in accrued interest receivable	(563)	0
Decrease in unearned revenues	(7,400)	0
Net Cash Provided by Operating Activities	$ 6,498	$137,987
Cash Flows From Investing Activities:		
Proceeds from sale of marketable securities	$ 76,466	$ 45,048
Payments to acquire marketable securities	(4,722)	(119,142)
Payments to acquire US Treasury obligations	(244,281)	0
Net Cash Used by Investing Activities	($172,537)	($74,094)
Net Increase (Decrease) in Cash and Cash Equivalents	($166,039)	$ 63,893
Cash and Cash Equivalents, beginning of year	328,716	264,823
Cash and Cash Equivalents, end of year	$ 162,677	$328,716

See Accountants' Compilation Report and Notes to Financial Statements.

SCHEDULE OF LONG-TERM INVESTMENTS MARCH 31, 1991

Stocks	*Shares*	*Cost*	*Market Value*
Ameritech	60	$ 1,122	$ 4,020
American Telephone & Telegraph	200	3,093	6,850
Bell Atlantic	40	1,138	4,110
Bell South	90	1,471	4,793
Falcon Bridge Gold	2	675	4
IBM	40	1,321	4,555
Nynex	40	1,068	2,900
Pacific Telesis	80	897	3,440
Southwestern Bell	60	1,030	3,367
US West	80	971	3,130
		$ 12,786	$ 37,169
US Treasury Obligations:			
$75,000 Treasury Bill due August 1, 1991, at par		$ 73,391	$ 73,391
$75,000 Treasury Bill due February 13, 1992, at par		$ 71,111	$ 71,111
$100,000 6 3/4% Treasury Note due February 28, 1993; interest paid semiannually in August and February		$ 99,779	$ 99,779
		$244,281	$244,281

See Accountants' Compilation Report and Notes to Financial Statements.

SCHEDULE OF INDIVIDUAL TRUST FUNDS FOR THE YEAR ENDED MARCH 31, 1991

	Fund Balance 02/28/90	*Revenues*	*Income*	*Disbursements*	*Transfers*	*Fund Balance 03/31/91*
Daniel C. Baker, Jr, Memorial Fund	$ 42,272	$	$ 4,337	$	$	$ 46,609
Casselberry Fund	26,258		2,694			28,952
Johnston Fund	26,152		2,683			28,835
De Roaldes Fund	14,955		1,534			16,489
Newcomb Trust Fund	10,404		1,067			11,471
Newcomb Prize Fund	2,603		267			2,870
Research Fund	233,651	$2,500	23,970	($15,200)	$3,317	248,238
Memorial Fund	31,592	810	3,241		(3,317)	32,326
Gabriel F. Tucker Fund	20,489		2,102	(382)		22,209
Dr Louis H. Clerf	725		74			799
	$409,101	$3,310	$41,969	($15,582)	$ 0	$438,798

See Accountants' Compilation Report and Notes to Financial Statements.

NOTES TO FINANCIAL STATEMENTS — MARCH 31, 1991

1. Summary of significant accounting policies

This summary of significant accounting policies of the American Laryngological Association (the Association) is presented to assist in understanding the Association's financial statements. The financial statements and notes are representations of the Association's managing council, which is responsible for their integrity and objectivity.

General. The Association is a nonprofit corporation organized for the advancement and promotion of the study of the science of medicine and surgery, devoting special attention to the upper aerodigestive tract, and to engage in and to encourage research with respect thereto. This includes the elevation of standards of the fundamental study and teaching of rhinology and laryngology in the undergraduate and postgraduate medical schools of America, the publishing annually of the proceedings of this Association, and the honoring of those who, by their contributions in the field of rhinology and laryngology, have aided in its advancement.

Method of Accounting. The financial statements have been prepared in accordance with generally accepted accounting principles on the accrual basis.

Accounts Receivable. The Association follows the practice of writing off uncollectible accounts as they are incurred. There is no allowance for uncollectible accounts reflected in the balance sheet. Management is of the opinion that no allowance is necessary.

Investments. The Association's investment in marketable securities (common stocks) is carried at the lower of aggregate cost or quoted market value.

2. Federal income tax

The Association is exempt from federal income tax under the provisions of Section 501(c)(6) of the Internal Revenue Code.

3. Allocation of investment income

Interest on US Treasury notes, Certificates of Deposit, Money Markets, as well as dividends on common stock, are credited as income to the Trust Fund. Trust Fund income is further allocated to each individual fund in the ratio each fund bears to the total value of the trust funds at the beginning of the year, except that by action of the Council on January 3, 1976, current income from the Memorial Fund is to be transferred to the fund balance of the Research Fund.

4. Arthur W. Proetz Trust Fund

On November 9, 1987, the American Laryngological Association was named the conditional beneficiary of a Trust under the will of Arthur W. Proetz. The entire net income derived from the Trust is paid quarterly to the Association to be used for research, education, or scientific activities related to the science of rhinology or laryngology. The Association is an income beneficiary only of this Trust and, as such, has no claim to the principal assets held by the Trust. Accordingly, the Trust's assets, which are managed by Boatmen's Trust Company, are not a part of the Association's balance sheet. The net income received from the Trust is included in investment income.

5. Cash flows

For purposes of the statement of cash flows, the Association considers all deposit accounts and money market funds to be cash and cash equivalents.

Respectfully submitted,
Robert W. Cantrell, MD
Treasurer

RECIPIENTS OF THE DE ROALDES AWARD

1928	Chevalier Jackson
1931	D. Bryson Delavan
1934	Harris P. Mosher
1937	Lee Wallace Dean
1943	Ralph A. Fenton
1949	George M. Coates
1951	Arthur W. Proetz
1954	Louis H. Clerf
1959	Albert C. Furstenberg
1960	Dean M. Lierle
1961	Frederick T. Hill
1966	Paul H. Holinger
1970	Francis E. LeJeune
1973	Lawrence R. Boies
1976	Anderson E. Hilding
1979	Joseph H. Ogura
1982	John J. Conley
1985	John A. Kirchner
1985	Charles M. Norris
1987	Walter P. Work
1988	DeGraaf Woodman
1989	John F. Daly
1990	Joseph L. Goldman
1991	William W. Montgomery

RECIPIENTS OF THE CASSELBERRY AWARD

1923	George Fetterolf and Herbert Fox
1928	Ralph A. Fenton and O. Larsell
1929	Richard A. Kern and Harry P. Schenck
1929	Edward H. Campbell
1931	Arthur W. Proetz
1934	Anderson C. Hilding
1936	Francis E. LeJeune and Joel J. Pressman
1939	H. Marshall Taylor and Brien T. King
1940	French K. Hansel
1941	Noah D. Fabricant
1946	Paul H. Holinger
1949	Henry B. Orton
1962	Hans von Leden
1966	John A. Kirchner and Barry D. Wyke
1968	Joseph H. Ogura
1985	H. Bryan Neel III
1987	Joseph J. Fata
1991	James L. Koufman

RECIPIENTS OF THE NEWCOMB AWARD

1941	Burt R. Shurly
1942	Francis R. Packard
1943	George M. Coates
1944	Charles J. Imperatori
1947	Harris P. Mosher
1948	Gordon Berry
1949	Gordon B. New
1950	H. Marshall Taylor
1951	John D. Kernan
1952	William J. McNally
1953	Frederick T. Hill
1954	Henry B. Orton
1955	Thomas C. Galloway
1956	Dean M. Lierle
1957	Gordon F. Harkness
1958	Albert C. Furstenberg
1959	Harry P. Schenck
1960	Joel J. Pressman
1961	Chevalier L. Jackson
1962	Paul H. Holinger
1963	Francis E. LeJeune
1964	Fred W. Dixon
1965	Edwin N. Broyles
1966	Lyman G. Richards
1967	Joseph H. Ogura
1968	Walter P. Work
1969	John A. Kirchner
1970	Louis H. Clerf
1971	Daniel C. Baker, Jr
1972	Alden H. Miller
1973	DeGraaf Woodman
1974	John J. Conley
1975	Francis W. Davison
1976	Joseph L. Goldman
1977	F. Johnson Putney
1978	John F. Daly
1979	Charles F. Ferguson
1980	Charles M. Norris
1981	Stanton A. Friedberg
1982	William M. Trible
1983	Harold G. Tabb
1984	Daniel Miller
1985	M. Stuart Strong
1986	George A. Sisson
1987	John S. Lewis
1988	Douglas P. Bryce
1989	Loring W. Pratt
1990	William W. Montgomery
1991	Seymour R. Cohen

RECIPIENTS OF THE GABRIEL F. TUCKER AWARD

1987	Seymour R. Cohen
1988	Charles F. Ferguson
1989	Blair Fearon
1990	Gerald B. Healy
1991	John A. Tucker

RECIPIENTS OF THE AMERICAN LARYNGOLOGICAL ASSOCIATION AWARD

1988	Frank Netter
1989	Shigeto Ikeda
1990	Hans Littmann
1991	Arnold E. Aronson

RECIPIENTS OF THE AMERICAN LARYNGOLOGICAL ASSOCIATION RESIDENT RESEARCH AWARD

1990	David C. Green
1991	Timothy M. McCulloch

RECIPIENT OF THE AMERICAN LARYNGOLOGICAL ASSOCIATION YOUNG FACULTY RESEARCH AWARD

1991	Paul W. Flint

THE MEMORIAL AND LARYNGOLOGICAL RESEARCH FUNDS

The Council earnestly requests that Fellows of the Association give consideration to making a special bequest to these important funds, or to becoming a Benefactor.

MEMORIAL FUND DONORS

Mrs Daniel C. Baker, Jr
Daniel C. Baker, Jr
John F. Barnhill
August L. Beck
Gordon Berry
William E. Casselberry
Cornelius G. Coakley
Robin T. Cotton
Lee Wallace Dean
Arthur W. De Roaldes
Fred W. Dixon
George Fetterolf
Joseph L. Goodale
William E. Grove
Gordon F. Harkness
Frederick T. Hill
George E. Hourn
Samuel Johnston
James E. Newcomb
Henry B. Orton
Lup Q. Pang
Pediatric Anaesthsia Associates, Ltd, of the Childrens Memorial Hospital of Chicago
Loring W. And Mrs Pratt
Lyman G. Richards
Burt R. Shurly
Lester T. Sunderland
H. Marshall Taylor
Walter H. Theobald
Gabriel F. Tucker, Jr
Francis L. Weille
Eiji Yanagisawa

BENEFACTORS

Mrs Sally Sample-Aall
Mrs Daniel C. Baker, Jr
Edwin N. Broyles
Louis H. Clerf
Seymour R. and Mrs Cohen
John J. Conley
John F. Daly
Francis W. and Mrs Davison
Stanton A. Friedberg
Thomas C. Galloway
Joseph L. Goldman
Robert L. Goodale
Edley H. Jones
Zelda Radow Weintraub Cancer Fund, Inc
A. P. Marchessini
Francis H. McGovern
Charles M. Norris
Samuel Salinger
Sam H. Sanders
Harry P. Schenck
Karl Storz Endoscopy–America, Inc
Oliver W. Suehs
William M. Trible
DeGraaf Woodman

PRESIDENTIAL REMARKS

MISSION AND PRIORITIES OF THE NATIONAL INSTITUTE ON DEAFNESS AND OTHER COMMUNICATION DISORDERS

JAMES B. SNOW, JR, MD

I thank the American Laryngological Association for the honor and privilege of serving as its President. It has been a rewarding experience to work with your Council and the membership in tending to the affairs of the Association and in preparing for its 112th annual meeting.

We live in a pluralistic society in which the decision-making process results from disparate views from many groups and individuals and from compromise and consensus. In public matters of science and health, physicians have a special responsibility because of their knowledge and experience. In health matters, physicians must be advocates for certain forms of governmental activity to serve the needs of their patients. This responsibility is particularly evident in health-related research. This 112th annual meeting of the American Laryngological Association is a gathering of scientifically oriented physicians. I use the term scientifically oriented physician to mean one who applies the principles of scientific logic to his or her decision-making process, who recognizes that there are varying degrees of validity in any data, and who readily incorporates new information into his or her daily practice. Physicians such as these are the backbone of our profession, and they have an abiding interest in research. Very little of what well-experienced clinicians do today was known at the time of their residencies. From today's research will come the knowledge, skills, and techniques with which physicians of tomorrow will improve the quality of the lives of their patients.

I am delighted to have this opportunity to tell you about the mission and priorities of the National Institute on Deafness and Other Communication Disorders (NIDCD), because at this time there are unprecedented opportunities for research in rhinology and laryngology.

The NIDCD is one of the 13 institutes of the National Institutes of Health (NIH) in Bethesda, Maryland. The NIDCD is responsible for research and research training related to both normal and disordered hearing, balance, smell, taste, voice, speech, and language. The NIDCD accomplishes its mission through research performed in its own laboratories and a program of research grants, career development awards, individual and institutional research training awards, and center grants and contracts to private and public research institutions and organizations. You will have an opportunity to learn more about the work conducted in the NIDCD intramural program when Dr Christy Ludlow, one of the NIDCD's distinguished scientists, presents the paper "Characteristics of Late Responses to Superior Laryngeal Nerve Stimulation in Humans."

The Institute also conducts and supports research and research training in disease prevention and health promotion. The NIDCD is concerned with the special biomedical and behavioral problems associated with people who have communication impairments and disorders.

The Institute is also supporting efforts to create devices that will substitute for lost and impaired communication functions. These devices include cochlear implants, hearing aids, vibrotactile aids, speech prostheses, voice prostheses, and laryngeal pacers, and perhaps in the future, swallowing prostheses. The NIDCD is pleased to have received an unprecedented commitment of the nation's financial resources to support research and research training in hearing, balance, smell, taste, voice, speech, and language. The Institute's budget was $117,283,000

BUDGET MECHANISM

	FY 1991 Appropriation		*FY 1992 Estimate*		*Increase Over FY 1991 (%)*
Research					
Research projects		$94,178		$103,577	10
Research centers		17,562		18,006	3
Other research					
Careers	3,053		3,053		—
MBRS	316		333		5
Other	825		825		—
Subtotal		4,194		4,211	0.4
Total		115,934		125,794	9
Training					
Individual	968		987		2
Institutional	3,017		3,047		1
Total		3,985		4,034	1
R & D contracts		2,930		3,027	3
Intramural		6,117		6,590	8
RM & S		5,969		6,876	15
Total		134,935		146,321	8

Dollars are given in thousands.

FY — fiscal year, MBRS — minority biomedical research support, R & D — research and development, RM & S — research management and support.

for fiscal year (FY) 1990 and was increased 15% to $134,935,000 for FY 1991 (see Table). The President's budget for the Institute for FY 1992 is $146,321,000, an 8.44% increase compared to an increase of 6% for all of the NIH. Eighty-five percent of these dollars will go toward supporting investigator-initiated research projects, 3% for research training, 2% for research and development contracts for things such as cochlear implants, 5% for the intramural research program, and 5% for research support and management or overhead.

The NIDCD was able to fund 97 new and competing renewal grants in FY 1989 ($16,973,000), 130 in FY 1990 ($22,476,000), and an estimated 138 in FY 1991 ($25,557,000). The NIDCD's success rate of applications, that is, percentage of applications received that are funded, was 37.1% in FY 1990; this percentage is second to that of the National Eye Institute and compares to 24% for all of the NIH. At the level of the President's budget for 1992, only 118 new and competing renewal grants can be funded. The scientific community has responded to the creation of this Institute by providing an increasing number of high quality applications: 254 in FY 1989, 350 in FY 1990, and 472 in FY 1991. It is conservatively estimated that 546 applications will be received in FY 1992 — a more than 100% increase since 1989. At the level of the President's budget for FY 1992, the success rate is estimated to be 21.6% for the NIDCD and compares to 26% for all of the NIH.

Fifty-nine percent of our grant portfolio is in hearing research, 3% in vestibular research, 15% in the chemical senses, 7% each in voice and speech, and 9% in language. Approximately one third of our total portfolio is in neurobiology, including investigations related to neural regeneration, auditory perception, and voice and language disorders. With this substantial interest in the neural basis of disorders such as aphasia, the Institute is pleased to be a part of the NIH institutes involved in the "Decade of the Brain."

In January 1989 the NIDCD brought together 100 distinguished scientists and clinicians charged with writing both a 3-year and a long-range research plan for deafness and other communication disorders that became the National Strategic Research Plan (NSRP). This document provides a guide to the goals and priorities of the Institute. The language and vestibular system sections of the NSRP were updated in January 1991. Next year the hearing and voice sections will be updated, and in 1993 the chemical senses and the speech sections will be updated. By repeating this cycle every 3 years, no part of the NSRP will be more than 3 years old.

The first three National Multipurpose Research and Training Centers have been established. The one at Boys Town in Omaha, Nebraska, under the leadership of Patrick Brookhouser, addresses hearing loss in children. The one at Johns Hopkins University, Baltimore, Maryland, deals with basic and applied studies of the auditory and vestibular systems and is under the direction of Murray Sachs. The one at The University of Iowa, Iowa City, Iowa, is concerned with voice and speech disorders, and is under the guidance of Ingo Titze. The research training compo-

nents of these centers will increase the numbers and broaden the capabilities of investigators in the communication sciences. Continuing education for health professionals will be provided, and these programs will disseminate research results to physicians, other health professionals, patients, and the public.

The NIDCD will continue to support minority-related research and minority scientists. In several of its clinical trials on otitis media, specific attention has been devoted to minority populations such as American Indians and Native Alaskans. Although those involved in clinical trials supported by the NIDCD include both males and females, recent findings in diseases affecting women differentially have occurred in Meniere's disease, otosclerosis, and voice tremor. The scientific community has become increasingly alert to the unique needs of each of these groups, and the NIDCD is committed to continued attention to the needs of these populations.

The NIDCD employs several mechanisms to nurture applications in areas of science that either are not receiving sufficient attention or are particularly promising for discovery. These initiatives comprise the Implementation Plan for each FY and include requests for application for grants, requests for proposals for contracts, program announcements, and workshops and conferences. Among initiatives in the Implementation Plan for FY 1991, and of interest to those in rhinology and laryngology, is a request for applications on the nasal chemosensory nerves as portals to the brain. Among the program announcements is one on the assessment of speech and voice production, and among the conferences is one on the growth and senescence of sensory receptors of smell and taste. Among the program announcements for FY 1992 is one on the assessment of speech and voice production and its clinical application, and one on chemosensory disorders and altered nutrient intake. The workshops and conferences for FY 1992 include one on the integration of smell, taste, and touch in the central nervous system.

An example of important progress being made is our understanding of the regeneration of sensory cells, ie, unlocking the way to accelerate their repair and return to normal function. This progress depends upon the study of auditory and vestibular hair cells and olfactory neuroepithelium. The olfactory neuroepithelium is known to have the remarkable capability of regenerating olfactory receptor neurons from stem cells throughout life. Recently scientists have discovered that this neuroepithelium produces another type of cell that migrates into the brain during adult life. Using both transplantations in intact brains and explants in tissue culture, scientists now identify the characteristics of these cells by defining the limits of their migration and by studying the interactions between cells that normally do not contact each other. The olfactory neuroepithelium is not only a source of olfactory receptor neurons, which have a powerful trophic effect on the brain, but may also be a direct source of additional cells for the brain.

The NIDCD uses several grant mechanisms to support studies in hearing, balance, smell, taste, voice, speech, and language.

R03, Small Grant Program. This program provides support for pilot research or especially innovative or high-risk research to determine the feasibility of a subsequent research project. For example, the pilot research may involve development of tests of new techniques or a small basic, clinical, or epidemiologic research project. This program is designed primarily to support investigators changing their areas of research, especially those coming into communication disorders research for the first time from another area, and clinicians with limited research experience. Participation in the program by investigators at minority institutions is encouraged.

K08, Clinical Investigator Development Award. The purpose of this mechanism is to recruit and prepare clinically trained individuals for research and teaching careers in the areas of medical science related to communication sciences and disorders. By supporting individuals with an interest in academic research careers, this award bridges the gap between the initial period of postdoctoral study and a secure academic appointment, or it supports the completion of the development of research capabilities of someone who may have had minimal research experience.

R29, First Independent Research Support and Transition Award (FIRST). The objective of the FIRST award is to provide, at a domestic institution, a sufficient period of research support for newly independent investigators to initiate their research and demonstrate the merit of their own research ideas. These grants are intended to underwrite the first independent investigative efforts of an individual; to provide a reasonable opportunity to demonstrate creativity, productivity, and further promise; and to help in the transition to traditional types of research project grants.

R01, Research Project Grant. Investigator-initiated research grants make up the largest single category of support provided by both the NIDCD and the NIH as a whole. This mechanism is the most traditional grant activity. These grants are awarded to an organization on behalf of an individual principal investigator to facilitate pursuit of a research objec-

tive in an area of the investigator's research interests and competence.

News from the Institute would not be complete without mentioning the new Director of the NIH, Dr Bernadine Healy. Dr Healy is a Vassar and Harvard Medical School graduate and a distinguished cardiologist. From 1977 to 1984 she was the Director of the Coronary Care Unit at The Johns Hopkins University; from 1984 until her confirmation last month, Dr Healy was Director of Clinical Research at the Cleveland Clinic Foundation, Cleveland, Ohio. Under her leadership, there is heightened expectation that the nation will commit increased resources to opportunities for biomedical and behavioral research.

The NIDCD is currently supporting research across the entire biomedical spectrum from basic research to applied clinical trials, prevention, and rehabilitation. This is the first time in history that the opportunities for research in rhinology and laryngology have had this funding support. Now that the Institute exists, we must make the most of this propitious convergence of scientific opportunity and research support to prepare a better future for those who have disorders of human communication.

INTRODUCTION OF GUEST OF HONOR DOUGLAS P. BRYCE, MD

JAMES B. SNOW, JR, MD

It is again our privilege to have among us Douglas P. Bryce. It is my great pleasure to introduce him as the Guest of Honor of the American Laryngological Association. This ardent worker in laryngology and in this Association is not a guest but a pillar of this discipline and this Association. Dr Bryce served the American Laryngological Association in 1985 as President, and he received the Newcomb Award of this Association in 1988.

Dr Bryce's contributions to the field are legion: through research and the presentation and publication of many articles on the treatment of laryngeal carcinoma; through education as the Chairman of the preeminent Department of Otolaryngology at the University of Toronto from 1966 to 1982; through encouragement of philanthropy in raising over $3,500,000 for the Charlie Conacher Laryngeal Laboratory for laryngeal histopathology; and in organized medicine in the formation of the Canadian Society of Otolaryngology, in accreditation of training programs as chairman of the Royal College's committee, and in certification of otolaryngologists through the American Board of Otolaryngology.

In all of these activities Douglas Bryce has been the steady and carefully reasoned advocate and foremost champion of conservation of laryngeal function in treatment of patients with carcinoma of the larynx. It is principally for this leadership that we honor him at this meeting. Nowhere was this leadership better expressed than in the Centennial Conference on Cancer of the Larynx organized by Dr Bryce and held in Toronto in 1974.

Honors are not new to this Sir Felix Semon, Sir William Wilde, Harris, Lamberson and Hoople lecturer, recipient of an honorary doctorate from the University of Linkoping, holder of honorary fellowships from the Royal Colleges of Edinburgh and Ireland, and member of the Collegium Otorhinolaryngologicum Amicitiae Sacrum. In addition he has been honored by Spain, Italy, South Africa, and Egypt.

Elizabeth and Douglas Bryce are citizens of the world and contribute to the culture and quality of life of their community. We salute them both!

Dr Strong and Dr Cohen, will you please escort Dr Bryce to the podium so we may again hear from him.

GUEST OF HONOR ADDRESS
THE GOLDEN YEARS

DOUGLAS P. BRYCE, MD

Mr President, Mr Secretary, special guests, and my friends of the American Laryngological Association: It seems just a step from the nervous young man who first stood before this august and terrifying Association to give a paper at Hollywood Beach, Florida, in 1961 to the older but still slightly nervous one who has the unique privilege to be your Guest of Honor today.

The larynx has fascinated me all my professional life and I continue my interest through the resources of the Conacher Laryngeal Laboratory in Toronto. Thus to be the honored guest of this primary and most prestigious association of laryngologists in the world is a crowning achievement of my career.

I have known and worked with your President Jim Snow for more than 30 years. My great admiration for his integrity, ability, and dedication to the specialty makes this honor still more warmly appreciated. My wife, Elizabeth, and I and Jim and Sally have had many happy times together. I wish to associate Elizabeth with this distinction you have awarded me as she has served the Association with great generosity and skill throughout these years.

Thirty years ago, there was no doubt in my mind that my task was to educate the members of this Association and as many others as I could reach about the larynx and its diseases and especially, of course, as to the management of malignant laryngeal disease. The course that I outlined to the laryngologists of that day was to say the least not the most popular one but I felt that with patience I could encourage them to change their direction as is illustrated in this humorous naval exchange.

Two battleships assigned to the training squadron had been at sea on manoeuvres in heavy weather for several days. The visibility was poor with patchy fog, so the captain remained on the bridge.

Shortly after dark, the lookout on the wing of the bridge reported, "Steady light, bearing on the starboard bow Captain."

The captain called to the signalman, "Signal that ship: We are on a collision course, advise you change course 20 degrees."

Back came a signal, "Advisable for you to change course 20 degrees."

The captain said, "Send I'm a captain, change course 20 degrees."

"I'm a seaman second class," came the reply. "You had better change course 20 degrees."

By that time, the captain was furious. He spat out, "Send I'm a battleship. Change course 20 degrees." Back came the flashing light, "I'm a lighthouse."

We changed course.

I have entitled my address "The Golden Years" because it occurred to me that I have been associated with this specialty for more than 40 years, and in that time there has been a dynamic ongoing revolution that has affected and changed every aspect of the specialty of otolaryngology — even to its name!

From a dying discipline made unnecessary by the discovery of antibiotics after World War II, it has become a giant bursting at its seams and a major role player in the national and international health organizations and important areas of health care.

Just before this revolution became apparent in my senior Fellowship year, I toured the United States and Canada to see the institutions and men who were the leaders in the field. At that time I visited Montreal, Boston, Philadelphia, Ann Arbor, Chicago, Baltimore, New Orleans, St Louis, and New York. I met the leaders of the day familiar to you all: McNally, Mosher, Jackson, Tucker, Work, Lederer, Holinger, Bordley, Miller, and LeJeune. Of course, this list is not complete. These cities were the germinal centers and the men there provided the wisdom and guidance for the explosion of energy and enthusiasm just beginning in this specialty.

While in Boston, I met a famous otolaryngologist who said, "If anyone is going to cure the effects of otosclerosis, it will not be the surgeon." Almost immediately the operating microscope was developed for clinical use, and in Lempert's famous institute in New York, fenestrations were being done by the thousands and a whole new surgical field was born. It was only about 30 years from the first hesitant approach to the stapes to the insertion of electrodes into the cochlea.

The basic foundation of the strength of this new discipline was the certification of specialists in this country by the American Board of Otolaryngology and in Canada by the Royal College. The disciplinary bodies in Canada developed more slowly; I was one of the two who sat for the first examination for Fellowship in the Royal College in Otolaryngology in 1949. These certifying bodies and their committees controlled the scope of the specialty, gave authority to its expansions, and recognized qualified training centers throughout North America. They in fact controlled and legitimized the revolution.

The struggle for dominance in head and neck surgery by surgeons with basic training in otolaryngology was initiated by a small group who formed the American Society for Head and Neck Surgery and carved for the specialty a section in the American College of Surgeons. The programs of the American College were eventually dominated in the head and neck field by the influence and energy of these men. The American Society for Head and Neck Surgery was immensely successful, and later in a gesture to reduce friction, almost but not quite married the sister Society of Head and Neck Surgeons. Joint meetings did occur, however, and most importantly a joint council was formed to develop and certify special programs for young surgeons training in the specialty of head and neck. This was a great achievement and continues today.

During the 30 years I was involved with the administrative bodies and boards of this specialty, the battle for jurisdiction in the field of head and neck surgery has appeared on the agenda of almost every meeting. The competition in this struggle has led to better training for our young men and women, and has stimulated and encouraged new surgical techniques in the field.

The young men and women trained in head and neck surgery and certified by the American Board of Otolaryngology–Head and Neck Surgery now dominate the full range of regional surgery throughout this country and to a growing extent throughout the western world. The Committee for Recognition of specialty training centers in otolaryngology in Great Britain was the direct result of the influence and strength of the American Board.

There is, of course, another large aspect of otolaryngology in which changes in surgical techniques and management protocols have been perhaps most remarkable of all, and that is in the management of malignant disease and particularly cancer of the larynx. Although the survival of patients with cancer has not greatly changed, we have improved immensely the quality of life for our patients with cancer.

The revolution in this field did not come quickly, but the concept of the "team" approach to malignant disease has now almost universally been recognized. The optimum results of treatment both for survival and quality of life can only be reached when all the associated and essential disciplines are applied to its management. Diagnostic radiology, radiotherapy, surgery, medical statistics, and basic laboratory backup are essential. The Centennial Conference on Laryngeal Cancer in Toronto 20 years ago was designed to bring these participating disciplines to meet face to face, to exchange views, and to appreciate the role of each in the development of treatment protocols. No immediate harmony was realized, which would have been too much to ask, but in retrospect I believe it was a landmark along the way.

One final area of great interest is the treatment of laryngeal cancer itself. The challenge of cancer of the larynx is that it is a relatively benign condition and therefore conservation of laryngeal function must be considered. By the "team" approach, maximum survival can be achieved with maximum functional preservation.

The greatest advance is that there are now far fewer total laryngectomies necessary. This is the main reason for the disappearance of the "Lost Cord Clubs." Also, there is the amazing story of the development of tracheopharyngeal or esophageal speech. Dr Asai must be given the credit, I believe, for beginning this surgical circus, and in the past 30 years hundreds of techniques and devices have been proposed to make the laryngectomized patient speak again. We are fairly settled at the moment with the most recent Blom-Singer tubes, but the surgical principle is that when many techniques are offered for the same disease, the perfect one has not yet been found. Moreover, there remain about 30% of the laryngectomized who are not well enough or energetic enough to be capable of mastering any device or technique to achieve speech.

PRESENTATION OF THE AMERICAN LARYNGOLOGICAL ASSOCIATION AWARD TO ARNOLD E. ARONSON, PHD

JAMES B. SNOW, JR, MD

The American Laryngological Association Award is a mark of recognition and esteem for outstanding achievement that has contributed importantly to laryngology or rhinology. Today we make the fourth American Laryngological Association Award to Dr Arnold E. Aronson, one of the foremost exponents of our sister discipline, speech-language pathology. Dr Aronson is Head of the Section of Speech Pathology in the Department of Neurology of the Mayo Medical Center and Professor in the Mayo Medical School. He has contributed over 50 major presentations and articles on psychogenic and neurogenic voice disorders. His contributions to the management of speech motor disorders and spastic dysphonia have consistently involved the application of the newest technology. He is the author of the highly regarded text entitled *Clinical Voice Disorders*, which is in its third edition. His ability to interpret the tenets of speech-language pathology to physicians is unsurpassed. Dr Aronson, we salute you as an internationally recognized authority on the management of voice disorders and take pride in presenting the American Laryngological Association Award to you.

RESPONSE OF RECIPIENT OF AMERICAN LARYNGOLOGICAL ASSOCIATION AWARD

ARNOLD E. ARONSON, PHD

President Snow, members of the American Laryngological Association: I accept this award with deep gratitude, not only for myself but as a representative of my profession, speech and language pathology.

This award encompasses many meanings to me. It signifies otolaryngology's official recognition of the speech and language pathologist's clinical and research importance to the practice of otolaryngology and to the advancement of its science. It represents a milestone in otolaryngology's development of its interests in communicative disorders, and it reinforces the growing allied health and public perception of otolaryngology as a specialty that now concerns itself with the importance of communication to the quality of life beyond its biological survival.

However, and I say this with major portent for the future of my profession, this award is a reflection of your essential openness and collegiality, embracing us and sharing your lives with us in a spirit of professional democracy. There is no doubt in my mind that I would not be in this room today had you not trusted, taught, and consulted me about your patients with diagnostically and therapeutically difficult voice problems. You gave me the most precious commodity any aspiring professional could hope for: the opportunity to learn. For this opportunity, and for this award, I am deeply grateful.

PRESENTATION OF THE GABRIEL F. TUCKER AWARD TO JOHN A. TUCKER, MD

WILLIAM R. HUDSON, MD

Nineteen-sixty was a momentous year in otolaryngology for me. I was a research fellow in Dr Bordley's program at Johns Hopkins, working with Bob Ruben and Ugo Fisch. Gabe Tucker was a newly minted assistant professor there. He and I became fast friends and together we went to the International Meeting in Paris. Our friendship continued until his untimely death. Gabe's contributions to our specialty and to the American Laryngological Association are well known. My memories of Gabe are much more personal — his visits to Duke, a train trip to Montreal with Gabe and Mary, the Princeton Club in New York (Gabe has his Princeton tie on, it must be Friday), visits in his home — so many memories. I do miss him.

This Association was very special to Gabe. In 1988, through his will, he provided a sum of money to recognize outstanding contributions in the area of his primary interest, pediatric laryngology. One should note the award is the Gabriel F. Tucker Award, honoring both Gabe and his distinguished father. Well-deserved awards have previously been presented to Seymour Cohen, Charles Ferguson, Blair Fearon, and Gerald Healy. Today it is my privilege to add another name to this illustrious group.

The recipient of the 1991 Gabriel F. Tucker Award is a member of one of the first families of otolaryngology. His father and his brother made outstanding contributions to our specialty and to this Association. The recipient has created his own niche, adding luster to the family name. Of course, I refer to the Tuckers of Philadelphia, Gabriel Senior, Gabe, and our honoree, John.

John Anwyl Tucker is a graduate of the University of Pennsylvania, the Johns Hopkins School of Medicine, and of the residency program of the Hospital of the University of Pennsylvania. Except for a couple of years in Atlanta, John has spent his professional life in Philadelphia, rising through the academic ranks at the University of Pennsylvania, culminating in his appointment as Professor and Chairman of the Department of Otorhinolaryngology, Hahnemann University, and serving as chairman from 1973 until 1984. He continues his appointments as a clinical professor in the Departments of Otolaryngology at Hahnemann, Temple, and Pennsylvania, and is Director of the William Glasgow Reynolds Voice and Whole Organ Laryngeal Section Laboratory, St Christopher's Hospital for Children.

John's extensive bibliography covers a variety of subjects in our specialty, although his primary interest and his major contributions have been in the field of developmental anatomy of the human larynx. In 1970 John presented an instructional course on the infant larynx at the Academy. Subsequently, he has enlarged on this theme with use of whole organ sections to demonstrate laryngeal embryology. We have come to expect almost yearly presentations of his well-prepared and beautifully illustrated studies. His most recent paper, "The Ontogeny of the Human Cricoid Cartilage," was read at the 1990 meeting of this Association. In should be noted that a number of these papers were prepared in collaboration with Gabe.

His many honors and awards include the Silver Medal Award from the Academy, the Hektoen Silver Medal from the AMA, the Seymour R. Cohen Award for Pediatric Laryngology and Bronchoesophagology from the American Broncho-Esophagological Association, and Honored Guest recognition in Japan, Australia, and Canada, as well as many visiting professorships.

The American Laryngological Association is pleased to present the 1991 Gabriel F. Tucker Award to John Anwyl Tucker.

RESPONSE OF THE RECIPIENT OF THE GABRIEL F. TUCKER AWARD

JOHN A. TUCKER, MD



I thank the Council and the Association for this especially meaningful award. I am greatly honored to be included with the distinguished previous recipients.

This award represents a completion and fulfillment in my life. I know my father would be pleased, my brothers would be pleased, but, most of all, my mother would be pleased. I thank you again.

PRESENTATION OF THE DE ROALDES AWARD TO WILLIAM W. MONTGOMERY, MD

JAMES B. SNOW, JR, MD

Arthur W. De Roaldes was President of the American Laryngological Association in 1906. The De Roaldes is the highest award of the Association. It is not given regularly, only when an individual's contribution in laryngology and rhinology is sufficiently outstanding to deserve this most special recognition.

On behalf of the American Laryngological Association, it is my privilege to present the De Roaldes Award to William W. Montgomery. Bill is Vermont's gift to American otolaryngology–head and neck surgery. He was a wounded medical officer of the Korean War. He is a selfless and favorite teacher of two generations of young otolaryngologist–head and neck surgeons, master of precise conceptualization of operations, gifted sculptor, and mover and shaker of our field through writings and teaching of his personal contributions.

William Montgomery's keen observation and daily practice of the belief that "I can do this operation better today than yesterday" have given this field and the patients who benefit from it a wealth of innovations.

With this award, Bill, goes the hope for a career of many more years and a challenge to make them as fruitful as your distinguished past. Here it is, the De Roaldes Award, richly deserved.

INTRODUCTION OF THE 17TH DANIEL C. BAKER, JR, LECTURER, CHARLES W. CUMMINGS, MD

JAMES B. SNOW, JR, MD

We now come to the part of our program in which we remember and honor Daniel C. Baker, Jr, beloved and generous leader in the field of otolaryngology–head and neck surgery. As most of you know, Daniel Baker was Professor and Chairman of the Department of Otolaryngology at Columbia University. We are appalled by the tragic and incomprehensible death of our esteemed colleague, Maxwell Abramson, who succeeded Dr Baker as Professor and Chairman of the Department at Columbia.

It is indeed fitting that this year's lecturer, Dr Charles W. Cummings, is endowed with a similarly warm and engaging personality. Dr Cummings led the distinguished Department of Otolaryngology–Head and Neck Surgery at the University of Washington from 1978 to 1990. In that position, basic and clinical research in the voice flourished through wise leadership, effective interdisciplinary collaboration, and the encouragement of outstanding young investigators. These developments, particularly in laryngeal neurophysiology, occurred at the same time that the outstanding auditory research in that department expanded and attained new heights. It is for this reason that Dr Cummings was chosen to give the Baker Lecture. In the meanwhile, Johns Hopkins University has chosen him to be their Professor and Chairman of the Department of Otolaryngology–Head and Neck Surgery, but let it be remembered that our committee chose him first.

Dr Cummings is the first author of the highly authoritative four-volume comprehensive text *Otolaryngology–Head & Neck Surgery*. As did Dr Baker, Charles Cummings has exercised leadership in many roles in organized otolaryngology–head and neck surgery. With this leadership in mind, we will now hear his address "Otolaryngology–Head and Neck Surgery: A Model Specialty for the Future."

SEVENTEENTH DANIEL C. BAKER, JR, MEMORIAL LECTURE

OTOLARYNGOLOGY–HEAD AND NECK SURGERY: A MODEL SPECIALTY FOR THE FUTURE

CHARLES W. CUMMINGS, MD

BALTIMORE, MARYLAND

I first met Dr Daniel Baker at the Spring Meeting in 1967, and I was delighted to have the opportunity to meet one of the specialty leaders while I was in my residency training. My next encounter was more traumatic, taking place in the poorly lit Palmer House during a Board oral examination. My recollection was that we talked otolaryngology for a short time, and talked about nonmedical matters for the remaining period. What struck me about Dr Baker was that he did not create a barrier between the candidate and the examiner. That was my last meeting with Dr Baker; however, I did have the opportunity to show his son Dan around the Massachusetts Eye and Ear Infirmary as he was in the process of deciding whether to pursue otolaryngology or plastic surgery as a professional career. As you know, he chose to go the plastic surgery route. That choice has some relevance to the content of this talk.



When Dr Baker was in his prime, the specialty of otolaryngology–head and neck surgery was substantially different than it is now. More physicians focused on paranasal sinus disease, otology, and airway problems; cosmetic surgery, major head and neck surgery, and reconstruction were not components of the specialty. Dr Baker contributed to the introduction of head and neck surgery to the specialty of otolaryngology.

Chemotherapeutics, technological innovations, and plenty of difficult confrontations with the traditional surgical establishment have brought the specialty to its current, tremendously expanded, state. With this change has come the redefinition of "specialty" and, as a material consequence, new turf issues. Otology and paranasal sinus disease remain an unchallenged component of our specialty, yet the new components of our specialty are objects of desire and, in fact, are coveted by other disciplines. Head and neck surgery is a rekindled component of "the basic general surgical curriculum." Reconstructive and cosmetic surgery have been the brass rings so much sought after by a generation or more of plastic surgeons as they wage war with our otolaryngology–head and neck colleagues who have similar interests. Endoscopy has in part slipped away to the pulmonologist and the gastroenterologist. Allergy has added a new definition to the words orthodox and unorthodox. Now skull base surgery is in the process of being defined with respect to disciplinary domain. Obviously the breadth of our specialty is far different from that when Dr Baker was the director of a successful residency training program. Today we have the additional challenge of subspecialization within our parent specialty. Some would say this is fragmentation or fractionation. There is no question that we are witnessing intraspecialty strife at the leadership level

From the Department of Otolaryngology–Head and Neck Surgery, Johns Hopkins School of Medicine, Baltimore, Maryland.

Presented at the meeting of the American Laryngological Association, Waikoloa, Hawaii, May 4-5, 1991.

REPRINTS — Charles W. Cummings, MD, PO Box 41402, Baltimore, MD 21203-6402.

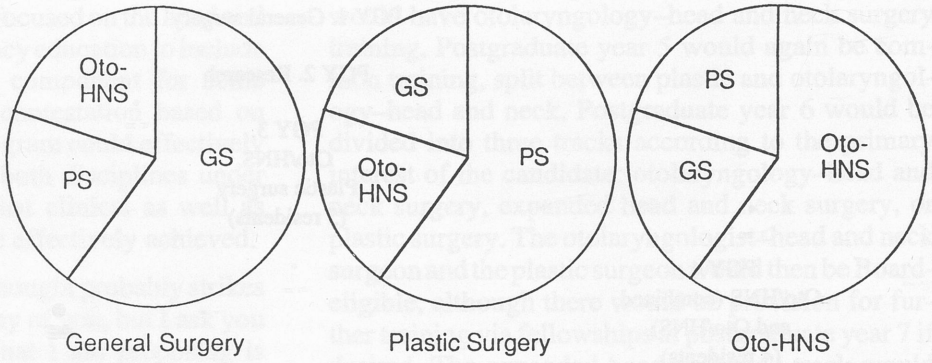

Fig 1. Head and neck perspective of involved specialty surgery.

of our specialty as each component of our discipline strives to establish recognition and certification. This phenomenon did not exist in the Baker era.

Interspecialty strife and conflict is nothing new. The polarity which has evolved from years of conflict with plastic surgery and general surgery is promulgated today. Frequently, I have heard remarks derogatory of my specialty ascribed to an "old guard" member of one of these disciplines. I am struck that the old guard has the capability to replicate. The foundations for opinion are most definitely shaped by perspective. Each discipline views the components of head and neck surgery differently (Fig 1). General surgery is obviously heavily weighted toward general surgery — similarly with plastic surgery. Our specialty biases hopefully more approximate the current relationships.

What drives this phenomenon and gives it energy is T.U.R.F. Turf issues stoke the fire in the engine room of old guardism. Territory Ultimately Rekindles Friction.

I have not mentioned a new claimant to our turf. An allied profession, oral surgery, has chosen to expand its parameters now to include the head and neck. Cosmetic surgery and cancer management have been established as central to their cause. On the surface, in fact, to the core, this is most disquieting and upsetting. Territorial definitions aside, our concerns for the best patient care elicit reasoned protestation. This new addition to the fray may indeed help to reshape the mindset of our most militant surgical colleagues. Collaboration may, in fact, replace confrontation.

With this background, what are the potential scenarios for our future as a specialty and as well what are the potential formats for the residency training programs of tomorrow?

Otolaryngology–head and neck surgery could very well remain as is — the status quo, with continued intraspecialty friction associated with spurts of activity toward subspecialty independence and self-governance. My concern about this pocket warfare is that

OTOLARYNGOLOGY–HEAD AND NECK SURGERY
Otology/otoneurology
Bronchoesophagology
Laryngology
Paranasal sinus disease

Head and neck surgery
Base of skull surgery
(for neoplasm)

PLASTIC SURGERY
Non–head and neck cosmetic surgery
Cutaneous lesions
Burns

Congenital (ie, urological,
hand and extremities)

Reconstruction (general)

Cleft palate and craniofacial

AREA OF OVERLAP
Facial cosmetic surgery
Head and neck reconstruction
(including free tissue transfer)

Trauma head and neck

Cutaneous malignancy head and neck

Fig 2. Scope of otolaryngology–head and neck surgery and plastic surgery and overlap.

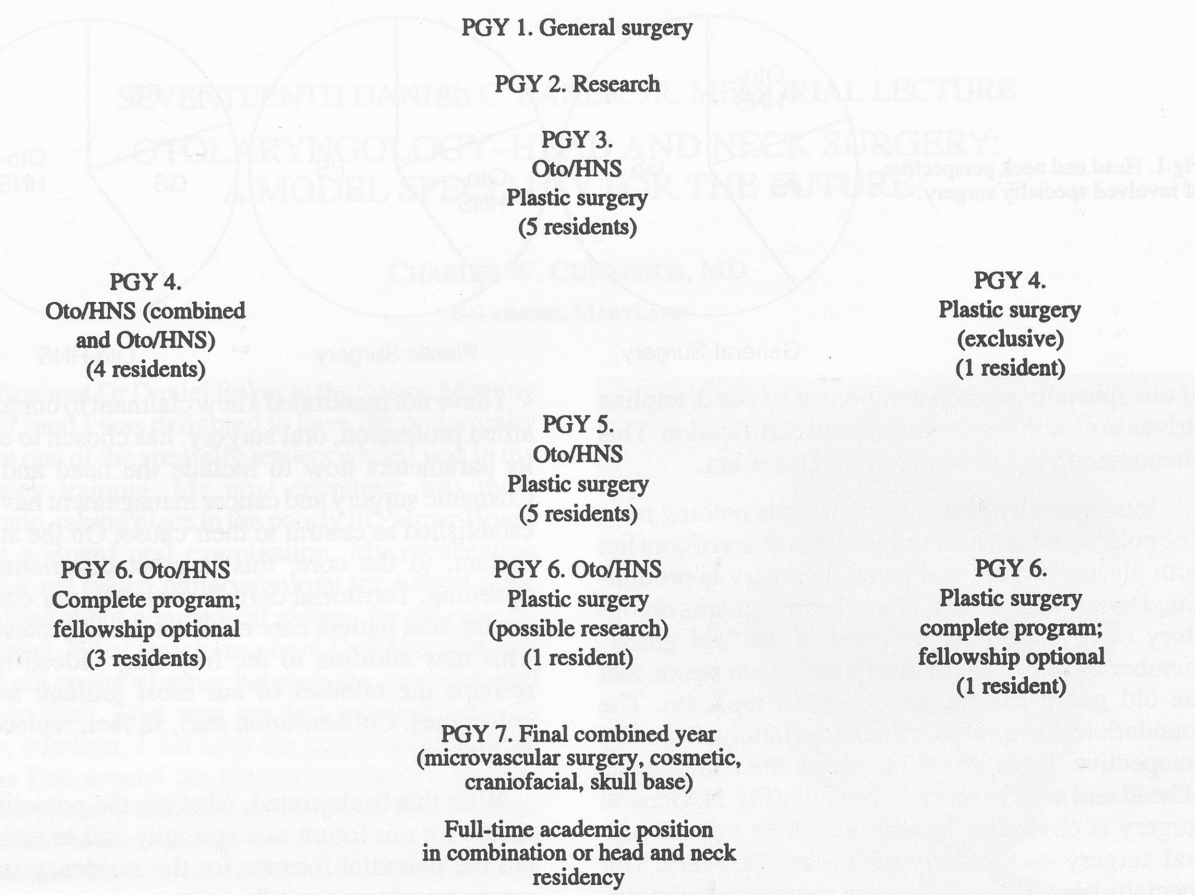

Fig 3. Ideal residency for five residents.

it might lead to autodigestion and erosion of the skeleton that has made us a formidable gatekeeper of our turf. The strength of collaboration might well dissipate, reducing us to "easy prey." The strength of unification is powerful and should not be underestimated. The outcome of recent litigation at the American Board of Medical Specialties level with respect to our Board certificate more than validates otolaryngology–head and neck surgery as it now exists as more potent than the numbers in our specialty of medicine might convey.

Another course might be that our specialty sees wisdom in fractionation so that otology or otoneurology stands apart from the mainstream. This situation exists as well with cosmetic and facial plastic surgery. The subspecialty, represented by the American Academy of Facial Plastic and Reconstructive Surgery, has a large membership, but I suspect that most of its members are not exclusively facial plastic surgeons. To contest turf boundaries with reduced personnel (ie, if our Academy is not involved in the fray) most assuredly reduces chances for success of our quest for specialty identity. If we permit each of our components to withdraw into itself, we will seriously affect the chances of specialty survival.

We might, as a specialty, elect to consolidate rather than fractionate and eliminate turf issues by amputating them or assigning them to other disciplines. For instance, we might pass major reconstruction and microvascular surgery to plastic surgery; refer endocrine surgery (thyroid primarily) back to the general surgeons; reduce our menu of cosmetic surgical procedures to rhinoplasty alone; and forsake the expansion that has come to our specialty through aggressive and demanding training. What I am describing is a direction for the future that would emasculate our character and alter forever the very essence of the modern day and future otolaryngologist–head and neck surgeon. No one with pride in his or her specialty could endorse this picture, certainly not Daniel Baker.

I feel that we must change to stay strong; further, I think that these changes must evolve from the crucible of surgical education. A reshaping of resident training and education is the natural vehicle to affect the future. Nonmedical higher education has exercised this principle for generations. It just might be possible to redefine the scope of surgical training so that otolaryngology–head and neck surgery might become a major component of a broader training

program that is anatomically focused on the head and neck. By restructuring residency education to include plastic surgery as an equal component for some would ultimately eliminate contestation based on turf. A combined training program could effectively incorporate the strengths of both disciplines under one administrative roof so that clinical as well as research goals might be more effectively achieved.

The image created by this thought probably strikes fear, even revulsion, into many of you, but I ask you to give it an open mind. What I am proposing is merely that, a proposal for consideration. My goals are as yours: reason for pride in my specialty, the ability to respond to challenges and changes from the outside, and the best, most successful and humane care for our patients. Let me explain my thoughts.

Let us look first at the scope of our specialty and that of plastic surgery and where there is overlap (Fig 2). Most assuredly otology, bronchoesophagology, laryngology, and treatment of paranasal sinus disorders belong to otolaryngology–head and neck surgery just as non–head and neck cosmetic surgery, congenital defects of extremities, burns, and major cutaneous lesions belong to plastic surgery. Surgery for tumors of the head and neck and base of skull is more closely allied to otolaryngology–head and neck surgery, but there is some overlap. Facial plastic surgery, major head and neck reconstruction including free flaps, head and neck trauma, and cutaneous lesions of the head and neck are all areas of common turf. There is much of both specialties that, depending on the geographic region and the historical background, overlaps.

It seems to me that the best solution to this problem is to inextricably combine the training process into three tracks so that the end product (the graduate) of one of the tracks would be Board-eligible for both specialties simultaneously and have equal allegiances to both. Further, graduates of this process would be expected to go forward to other training institutions with the intention of establishing similar programs. The structure of this ideal training program is three-faceted, each track leading toward a specific Board-certifiable goal: otolaryngology–head and neck surgery, combined head and neck surgery and plastic surgery, and plastic surgery alone. Obviously, this schema is not practical in programs of modest size or those with marginal clinical material.

The schema for such a training process is as follows (Fig 3). The initial 3 years of training would be the same for each pathway (a core platform). Year 4 would split so that the plastic track would have 1 year of plastic surgery training and the other two tracks would have otolaryngology–head and neck surgery training. Postgraduate year 5 would again be common training, split between plastic and otolaryngology–head and neck. Postgraduate year 6 would be divided into three tracks according to the primary interest of the candidate: otolaryngology–head and neck surgery, expanded head and neck surgery, or plastic surgery. The otolaryngologist–head and neck surgeon and the plastic surgeon would then be Board-eligible, although there would be provision for further training via fellowships at postgraduate year 7 if desired. The expanded head and neck track would then enter a postgraduate year 7 that would focus on major reconstruction, microvascular surgery, facial plastic surgery, and skull base surgery.

Now what does this achieve? Essentially, this proposal has the potential to resolve age-old turf battles by amalgamation of the training process of specialties heretofore frequently at odds. Obviously, both disciplines would have to purchase the concept. Better, more uniform care for our patients might evolve from such a consolidation of the two disciplines. This combined training process would not dilute the uniqueness of either specialty as it now exists, but through the creation of a third combined track, a much closer liaison could be established. In addition, despite a mandatory year of research, the combined training concept shortens the overall process by 1 year.

The potential downside is not insignificant from the risk standpoint. Although this plan does not alter our specialty as we know it, a perception will surface that the parameters of otolaryngology–head and neck surgery will be redefined and perhaps down-scaled. A potential alliance with a warring discipline is disquieting. What our predecessors have so arduously fought for, an expanded definition of the specialty, will be put on the line. Our very identity may be challenged, certainly modified. I see no consolidation of specialty, merely the formulation of a separate track that centers on major free-tissue transfer and cosmetic surgery.

What is proposed here is that we consider a change in the training process in order to enhance the scope of expertise and enhancement of the environment for those focused on major reconstructive head and neck surgery and cosmetic surgery by amalgamation of the training structures of both otolaryngology–head and neck surgery and plastic surgery. The disciplines of otolaryngology–head and neck surgery and plastic surgery should remain essentially unchanged. A new definition of global head and neck surgery, however, may evolve from this coalescence of training.

CLINICAL STAGING FOR PRIMARY MALIGNANCIES OF THE SUPRAGLOTTIC LARYNX

RENE L. ZAMORA, MD
DONALD G. SESSIONS, MD
EDWARD L. SPITZNAGEL, JR, PHD
JOSEPH E. HARVEY, PHD
ST LOUIS, MISSOURI

A study of 520 patients with primary supraglottic cancers was carried out. The tumors were staged according to the 1983 and 1988 American Joint Committee on Cancer T and N stage definitions. There were 293 early-stage (T1 or T2) tumors, 227 advanced-stage (T3 or T4) tumors, and 428 early nodal disease (N0 or N1) tumors in both systems. In the 1983 N staging, there were 44 N2 and 48 N3 lesions; in the 1988 N staging, there were 62 N2 and 30 N3 lesions. Cox regression showed that the 1983 and 1988 T stage (T1 to T4) definitions successfully prognosticated survival when patients were without neck nodes. In contrast, when neck nodes were present, the N stage (N0 to N3) of the disease prognosticated survival better than T stage. Further analyses showed that the 1988 N stage definition provided a better separation between N2 and N3 lesions compared to the 1983 version. Combined-modality treatment significantly improved survival compared to single-modality treatment in patients with T4 lesions and when patients progressed from N0 to N3 neck disease but not when patients advanced from T1 to T3. We conclude that the 1988 T and N stage definitions successfully prognosticate survival according to T stage (T1 to T4) and N stage (N0 to N3), with better separation of N2 and N3 lesions compared to the 1983 version.

KEY WORDS — Cox regression, neck nodes, staging, supraglottic cancers.

INTRODUCTION

Supraglottic cancers present in a patient population that is elderly and often debilitated by long use of alcohol and tobacco and inattentive to early symptoms of the disease. Because of the extent of the primary lesion and the profuse capillary and lymphatic drainage, neck nodes are frequently involved at presentation. Despite these factors, primary supraglottic malignancies may be curable. It is therefore one of the few areas in oncology in which early diagnoses and several treatment techniques may produce good cure rates and optimal preservation of function.[1] Preoperative evaluation of patients with cancer of the larynx has been standardized.[2,3] This has allowed for the development of advanced diagnostic techniques that identify the extent of local and regional spread of disease at the time of clinical presentation. Because the latter ultimately predicts the prognosis, accurate clinical staging will determine if increasingly satisfactory survival rates can be achieved.

The purposes of establishing a clinical staging system are fourfold. First, it should be clearly defined in order to allow clinicians to compare and contrast similar experiences. Second, it should accurately reflect prognosis and thus provide guidelines for the nature of therapeutic regimens. Third, it should provide a data base in which pertinent clinical factors such as various treatment techniques, recurrence, complications, and survival can be analyzed. Finally, it should be convenient to use and update.

One of the major issues in the clinical staging of primary cancers of the larynx is the inadequate definition of what constitutes the boundaries of the larynx. The 1983 and 1988 American Joint Committee on Cancer (AJCC) staging systems attempt to solve this problem by defining the primary site of origin.[4,5] The anterior limit is composed of the anterior lingual surface of the suprahyoid epiglottis, the thyrohyoid membrane, the anterior commissure, and the anterior wall of the subglottic region (the thyroid cartilage, cricothyroid membrane, and anterior arch of the cricoid cartilage). The posterior and lateral limits include the aryepiglottic folds, the arytenoid region, the interarytenoid space, and the posterior surface of the subglottic space (mucous membrane covering the cricoid cartilage). The superolateral limits are composed of the tip and lateral borders of the epiglottis. The inferior limits are made up of the plane passing through the inferior edge of the cricoid cartilage (Fig 1). With these anatomic boundaries in mind, the larynx can be divided into the three regions shown in Fig 1: supraglottis, glottis, and subglottis. The supraglottis is further subdivided into different sites: epiglottis, aryepiglottic folds, arytenoids, and ventricular bands (false vocal cords). It is important to note that in the past staging systems, tumors originating from the aryepiglottic folds were excluded from the T stage definitions and termed "marginal" tumors. The current classification schemes avoid this exclusion. The inferior boundary is a horizontal plane of the supraglottis passing through the apex of the ventricle. The glottis is composed of the true vocal cords, including the anterior and posterior commissures. The lower boundary is the horizontal plane 1 cm below the apex of the ventricle. The subglottis is the region extending from the lower boundary of the glottis to the lower margin of the cricoid cartilage (Fig 1).

From the Departments of Otolaryngology (Zamora, Sessions, Harvey) and Biostatistics (Spitznagel), Washington University School of Medicine, St Louis, Missouri.

Presented at the meeting of the American Laryngological Association, Waikoloa, Hawaii, May 4-5, 1991.

REPRINTS — Donald G. Sessions, MD, Dept of Otolaryngology, Washington University School of Medicine, 517 S Euclid Ave, St Louis, MO 63110.

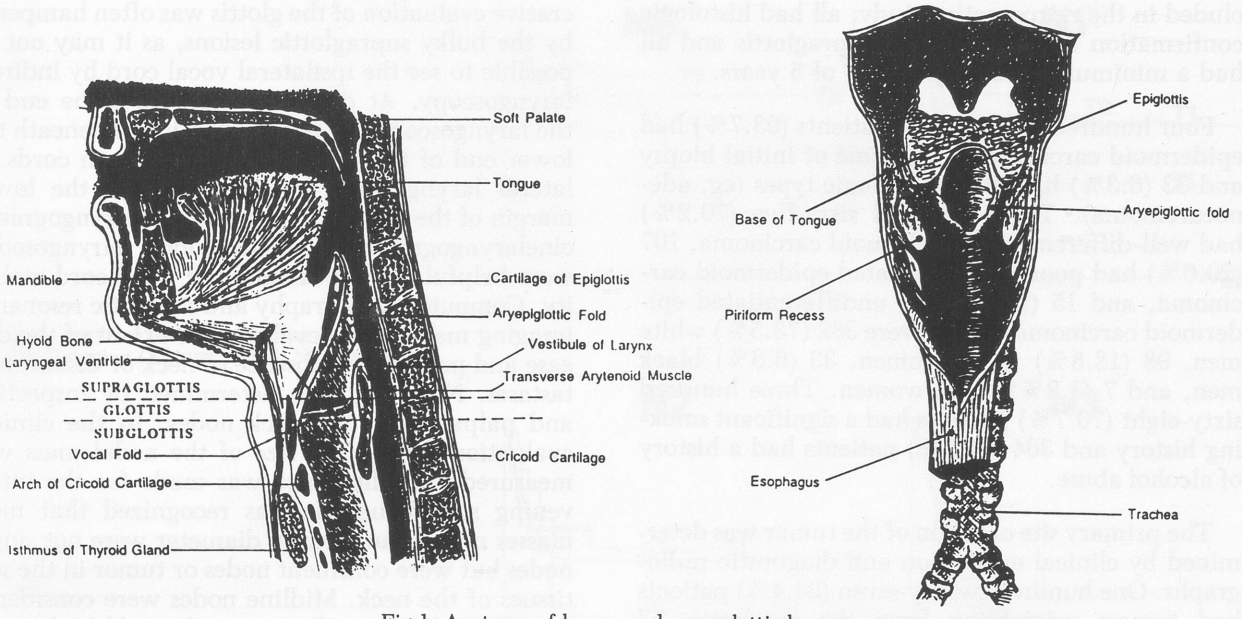

Fig 1. Anatomy of larynx and supraglottic larynx.

The purpose of this study is to assess the prognostic power of the 1983 and 1988 AJCC clinical T and N staging for supraglottic primaries. The T definitions and N0 and N1 definitions remain the same; the definitions for stages N2 and N3 are shown in Table 1. The only difference occurs in patients presenting with bilateral or contralateral nodes between 3 cm and 6 cm in diameter; the 1983 definition stages this condition N3, while the 1988 system stages it N2. The number of patients down-staged from N3 to N2 is also shown in Table 1.

MATERIALS AND METHODS

Five hundred twenty patients with primary supraglottic tumors of the larynx presented to Washington University Department of Otolaryngology between 1952 and 1985. The average age at the time of diagnosis was 59 years old, with a minimum age of 27 and a maximum age of 88 years old. One hundred seventeen patients (22.5%) presented with a T1 lesion, 176 (33.8%) with a T2 lesion, 137 (26.4%) with a T3 lesion, and 90 (17.3%) with a T4 lesion staged according to the 1983 and 1988 T staging definitions. Three hundred forty-nine patients (67.0%) were without evidence of neck nodes; 79 (15.2%) were N1 by both 1983 and 1988 definitions. By the 1983 N staging definition, 44 (8.5%) presented with N2 lesions and 48 (9.2%) presented with N3 lesions. With the 1988 N staging, 62 (12.0%) presented with N2 lesions and 30 (5.8%) presented with N3 lesions. None of the patients had clinical and/or radiographic evidence of distant metastases at time of diagnosis. All patients were in-

TABLE 1. 1983 AND 1988 AJCC T AND N STAGING DEFINITIONS

Site	Supraglottis
Subsites	False vocal cords Arytenoids Suprahyoid epiglottis (epilarynx) Infrahyoid epiglottis Aryepiglottic folds (marginal zone)

T1. Limited to supraglottis. One subsite without fixation.
T2. Limited to supraglottis. More than one subsite *or* invasion of glottis without fixation.
T3. Invasion of glottis with fixation *or* beyond supraglottis, postcricoid area, medial wall pyriform sinus, preepiglottic space.
T4. Beyond supraglottis. Oropharynx, soft tissues of neck, *or* destruction of thyroid cartilage.

N Stage	*1983 AJCC N Staging*	*1988 AJCC N Staging*	*This Study*
N1	1 ipsilateral node (N<3)	1 ipsilateral node (N<3)	
N2	1 ipsilateral node (3<N<6) *or* Multiple ipsilateral nodes (N<6)	1 ipsilateral node (3<N<6) *or* Multiple ipsilateral nodes (N<6) *or* Bilateral or contralateral nodes (N<6)	18 patients down-staged and statistically significant (p<.001)
N3	Ipsilateral node *or* Bilateral or contralateral nodes	Any positive node (N>6)	

N — estimated diameter of palpable node in centimeters.

cluded in the retrospective study; all had histologic confirmation of cancer of the supraglottis and all had a minimum follow-up period of 5 years.

Four hundred eighty-seven patients (93.7%) had epidermoid carcinoma at the time of initial biopsy and 33 (6.3%) had other histologic types (eg, adenocarcinoma). Three hundred sixty-five (70.2%) had well-differentiated epidermoid carcinoma, 107 (20.6%) had poorly differentiated epidermoid carcinoma, and 15 (2.9%) had undifferentiated epidermoid carcinoma. There were 382 (73.5%) white men, 98 (18.8%) white women, 33 (6.3%) black men, and 7 (1.3%) black women. Three hundred sixty-eight (70.7%) patients had a significant smoking history and 304 (58.5%) patients had a history of alcohol abuse.

The primary site of origin of the tumor was determined by clinical evaluation and diagnostic radiographs. One hundred twenty-seven (24.4%) patients had tumors originating from the epiglottis; 77 (14.8%) from the false vocal cords; 3 (0.6%) from the ventricles; 8 (1.5%) from the arytenoids; 148 (28.5%) from the epiglottis and the false vocal cords; 35 (6.7%) from the epiglottis, false vocal cords, and ventricles; 78 (15.0%) from the epiglottis, false vocal cords, ventricles, and arytenoids; 23 (4.4%) from the false vocal cords and ventricle; and 21 (4.0%) from the false vocal cords, ventricle, and arytenoids.

Only patients undergoing primary treatment for carcinoma of the supraglottis at Washington University Medical Center were considered. Primary treatment modalities included subtotal supraglottic laryngectomy (SSL) plus or minus radical neck dissection (RND), total laryngectomy (TL) plus or minus RND, and full-course radiotherapy. Seventy-five patients (14.4%) underwent full-course radiotherapy without surgery, 189 (36%) had SSL minus RND, 69 (13.2%) had SSL plus RND, 115 (22%) had TL minus RND, and 72 (14%) had TL plus RND. One hundred forty-six (28.1%) patients had surgery alone, 75 (14.4%) had radiotherapy alone, 78 (15%) had postoperative radiotherapy, and 221 (42.5%) had preoperative radiotherapy. There were 203 (39%) patients who had no neck nodes but received combined-modality treatment: 67 (33%) had T2 lesions, 92 (45%) had T3 lesions, and 44 (22%) had T4 lesions. The T1 and T2 lesions were all treated with SSL plus or minus RND; T3 and T4 lesions were treated with TL plus or minus RND. Radiotherapy was delivered to the primary site and the neck was included in the irradiation field when nodal disease was present. A tumoricidal dose was delivered in all cases treated for cure.

The rules of staging were the following. The larynx can be assessed by inspection using indirect mirror examinations or direct laryngoscopy. Preoperative evaluation of the glottis was often hampered by the bulky supraglottic lesions, as it may not be possible to see the ipsilateral vocal cord by indirect laryngoscopy. At direct laryngoscopy, the end of the laryngoscope can usually be slipped beneath the lower end of the tumor to visualize both cords. A lateral laryngogram may demonstrate the lower margin of the tumor. Posteroanterior laryngograms, cinelaryngography, and fiberoptic laryngoscopy were helpful in the evaluation of vocal cord mobility. Computed tomography and magnetic resonance imaging may help to evaluate the extent of the disease and presence or absence of neck or distant metastases. N staging was determined by inspection and palpation of the neck nodes. In the clinical evaluation, the actual size of the nodal mass was measured and allowance was made for the intervening soft tissues. It was recognized that most masses more than 3 cm in diameter were not single nodes but were confluent nodes or tumor in the soft tissues of the neck. Midline nodes were considered homolateral nodes. All were confirmed histologically at the time of initial biopsy prior to primary treatment. Each patient was restaged according to the 1983 and 1988 T stage and N stage definitions on the basis of the drawings and descriptions of the consulting surgeons and radiotherapists at presentation.

Analysis of Results. Survival curves were constructed according to the Kaplan-Meier method.[6] The y-axis is survival probability (range, 0% to 100% per period of time) and the x-axis is time of follow-up (range, 0 to 5 years). Time zero was defined as the date of the patient's initial diagnosis. Survival rates only changed when a death in a particular group occurred. Death was defined as caused by any disease related to the primary malignancy. Any patient who died of other causes such as treatment complications, second primary cancer, or intercurrent disease was treated as censored at the time of death.[6] Cox regression analysis was then applied to test if there were statistically significant differences between each of the survival curves.[6] This statistical test compares the effects of independent variables (or covariates) such as height, age, weight, sex, race, tumor stage, regional node disease, and treatment modality on the prediction of a binary or dichotomous dependent variable, death. If the associated probability was $<5\%$ then the differences were considered statistically significant. Cox regression analysis for each of the independent variables results in the determination of the hazard function coefficient (HF coefficient).[6] The greater the magnitude of the coefficient, the greater the probability that the dependent variable (death) will occur in the near future, ie, a positive HF coefficient for an independent variable implies that it increases the risk of death, while a negative coefficient implies it decreases the risk of death.

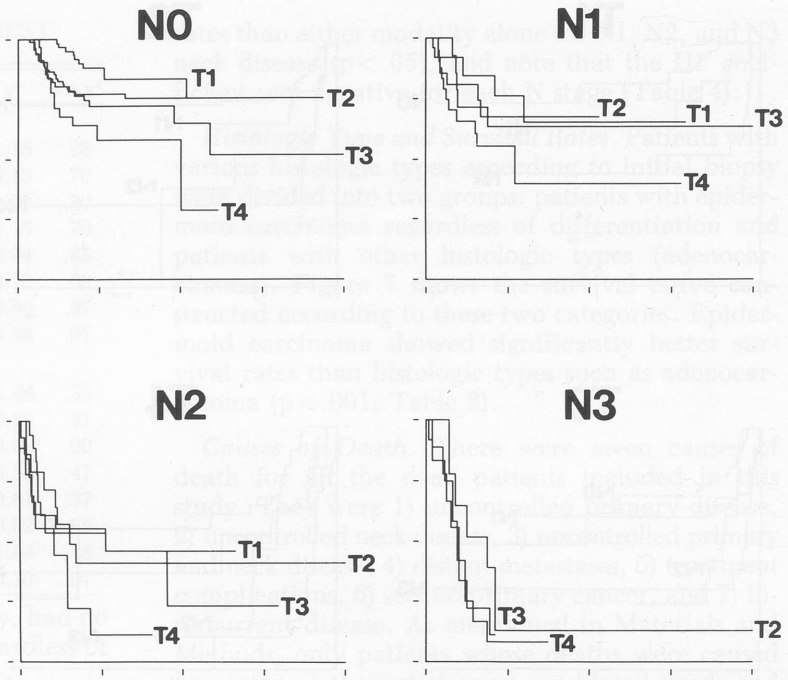

Fig 2. Survival curves according to 1983 and 1988 T staging (T stage varied, N stage fixed).

RESULTS

Comparison of 1983 and 1988 AJCC T Staging Systems. There were no differences in T staging definitions between the 1983 and 1988 AJCC systems. Therefore, both systems were referred to when the survival curves were constructed. The prognostic power of clinical staging was assessed over a minimum follow-up period of 5 years. Survival curves were calculated by varying T stage for each N stage, and statistical difference was determined by using Cox regression. Results show that T3 and T4 cases (advanced) were significantly different from T1 and T2 cases (early) when the N stage was N0 ($p < .05$; Fig 2 and Table 2). Note that the HF coefficient becomes increasingly positive as a patient progresses from T2 to T4 for each N stage (Table 2). The treatment modality did not significantly contribute to survival when included as a covariate in the Cox regression analysis; however, a negative HF coefficient was calculated (Table 2). In contrast, when the N stage was N1, N2, or N3, differences among survival curves were not statistically significant (Fig 2 and Table 2). Note that when N stage was N2, a p value of .05 was calculated, but this was not considered significant because our cutoff was less than 5%.

Comparison of 1983 and 1988 AJCC N Staging Systems. Survival curves for patients presenting with neck nodes were also constructed. Since the 1983 and 1988 N stage definitions showed differences in the N2 and N3 definitions, two sets of survival curves were calculated for each version. Figure 3 shows the survival curve for the 1983 N staging definitions, varying N stage with respect to T stage. Cox regression on the four curves (ie, one curve for each N stage) showed statistically significant differences between the survival curves for patients presenting with N2 or N3 disease relative to N0 or N1 disease independent of T stage ($p < .05$ for N0, $p < .01$ for N1 and N2, $p < .001$ for N3; Fig 3 and Table 2). Note that the HF coefficient for treatment modality was negative, but increasingly positive values were obtained when the patient progressed from N1 to N3 (Table 2). The contribution

TABLE 2. COX REGRESSION ANALYSES OF 1983 AND 1988 STAGING SYSTEMS

				Hazard Function Coefficient			
	N	χ^2	*p*	*Rx*	*T2*	*T3*	*T4*
T varied, N fixed							
N0	349	11.00	.03	0.06	0.62	0.90	1.31
N1	79	7.41	.17	−0.79	0.33	0.13	0.87
N2	62	9.30	.05	−1.0	−0.26	−0.11	0.45
N3	30	7.43	.11	−1.04	−0.86	0.0	0.0
				Rx	*N1*	*N2*	*N3*
T fixed, 1983 N varied							
T1	117	11.21	.011	−0.70	0.97	1.9	0.0
T2	176	18.40	.001	−0.32	0.55	1.37	1.45
T3	137	17.29	.002	−0.38	0.25	1.45	1.56
T4	90	31.00	.000	−0.97	0.72	1.47	2.19
T fixed, 1988 N varied							
T1	117	11.21	.011	−0.70	0.97	1.9	0.0
T2	176	21.32	.0003	−0.23	0.54	1.14	2.04
T3	137	25.96	.000	−0.27	0.25	0.98	2.61
T4	90	31.71	.000	−0.92	0.71	1.52	2.32
1983 N2 vs N3 definition							
	92	2.25	.13				0.40
1988 N2 vs N3 definition							
	92	14.48	.0001				1.10
Epidermoid carcinoma vs adenocarcinoma*							
	520	22.52	.000				

Rx — treatment.

*Hazard function coefficient for epidermoid carcinoma, −1.30.

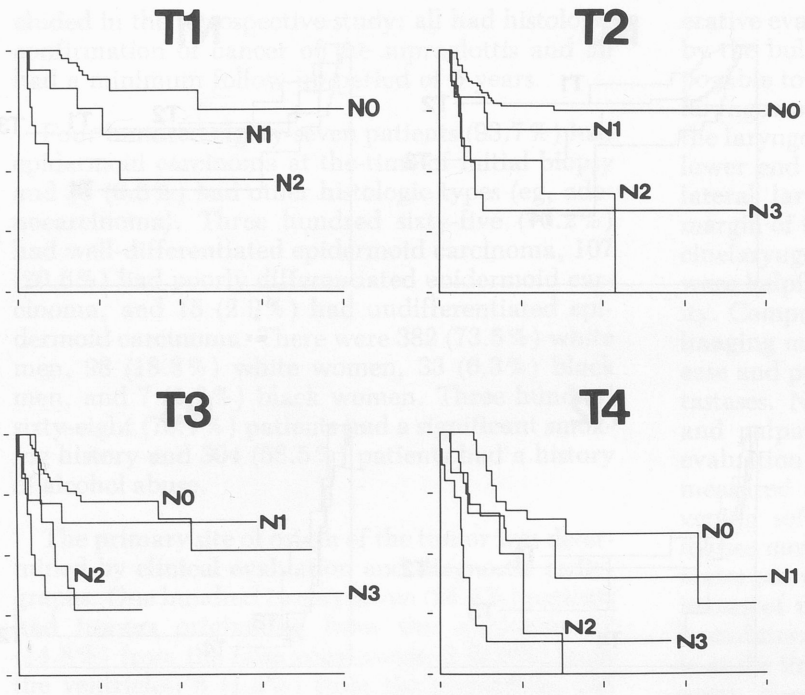

Fig 3. Survival curves according to 1983 N staging (T stage fixed, N stage varied).

of treatment modality to survival when included as a covariate was not statistically significant ($p > .05$; Table 2). Further Cox regression to test separation between N2 and N3 disease showed no statistically significant difference ($p > .05$; Table 2).

Survival curves were constructed in a like manner for the 1988 N stage definition. T stage was kept constant and N stage varied (Fig 4). Cox regression showed a statistically significant difference between patients presenting with N2 or N3 disease relative to N0 or N1 ($p < .05$ for N0; $p < .001$ for N1, N2, and N3; Table 2). The contribution of treatment modality to survival was not significant ($p > .05$; Table 2). Further Cox regression showed a statistically significant separation between N2 and N3 better than the 1983 N stage definition ($p < .001$; Table 2).

Comparison of Treatment Modalities. The patients were divided into two groups. The first group was composed of patients who received either surgery alone or radiotherapy alone, both for cure as a primary form of treatment, and there was no significant difference between the two groups for each T and N stage ($p > .05$; Table 3). The second group was composed of patients who received combined-modality treatment in the form of surgery and radiotherapy. The manner in which radiotherapy was

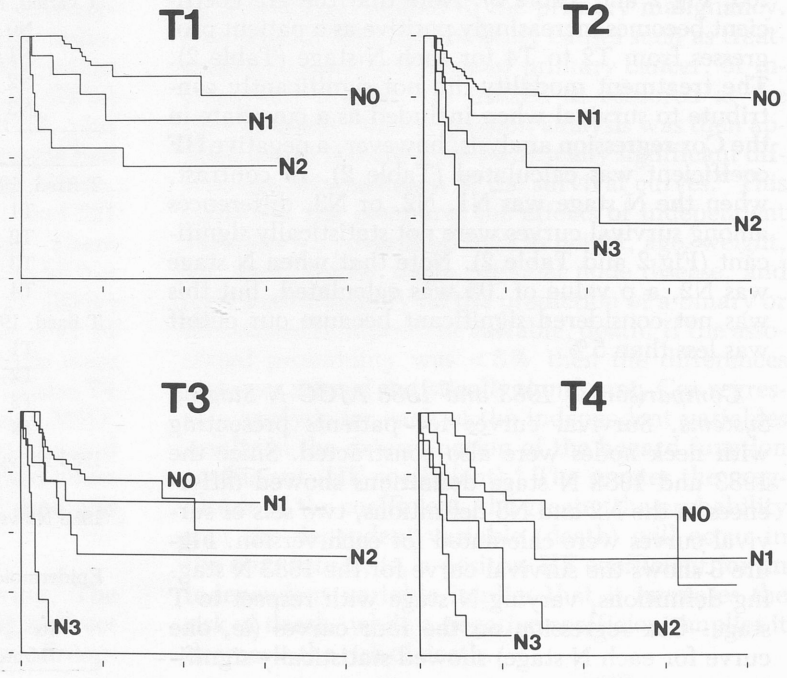

Fig 4. Survival curves according to 1988 N staging (T stage fixed, N stage varied).

TABLE 3. COX REGRESSION OF TREATMENT MODALITIES

	N	χ^2	$p>\chi^2$
Surgery vs radiotherapy alone			
T1	46	1.15	.28
T2	67	0.15	.70
T3	58	1.07	.30
T4	50	0.15	.70
N0	146	0.04	.85
N1	34	3.13	.08
N2	22	0.80	.37
N3	19	3.28	.07
Preoperative vs postoperative radiotherapy			
T1	71	0.96	.33
T2	109	0.81	.37
T3	79	0.02	.90
T4	40	0.52	.47
N0	203	0.81	.37
N1	45	0.02	.88
N2	40	1.84	.76
N3	11	3.30	.07

given, ie, preoperatively or postoperatively, had no significant difference in survival rates regardless of T and N stage ($p>.05$; Table 3).

Two sets of survival cures were constructed. First, the T stage was kept constant and treatment modality was varied (Fig 5). For stages T1 to T3, there were no significant differences among the two groups of patients (Table 4). For stage T4, the Cox regression was significant ($p<.05$) and the HF coefficient was negative (Table 4). Second, the N stage was kept constant and treatment modality was varied (Fig 6). The definition of N stage used in the construction of the survival curves was from the 1988 AJCC version because it was shown to provide better separation than the 1983 AJCC definition (Table 2). In contrast to T stage, combined-modality treatment showed significantly better survival rates than either modality alone for N1, N2, and N3 neck disease ($p<.05$), and note that the HF coefficient was negative for each N stage (Table 4).

Histologic Type and Survival Rates. Patients with various histologic types according to initial biopsy were divided into two groups: patients with epidermoid carcinoma regardless of differentiation and patients with other histologic types (adenocarcinoma). Figure 7 shows the survival curve constructed according to these two categories. Epidermoid carcinoma showed significantly better survival rates than histologic types such as adenocarcinoma ($p<.001$; Table 2).

Causes of Death. There were seven causes of death for all the dead patients included in this study. They were 1) uncontrolled primary disease, 2) uncontrolled neck disease, 3) uncontrolled primary and neck disease, 4) distant metastases, 5) treatment complications, 6) second primary cancer, and 7) intercurrent disease. As mentioned in Materials and Methods, only patients whose deaths were caused by reasons 1 through 4 were considered dead, and patients who died because of reasons 5 through 7 were censored at the time of death. The number of patients dying according to the above causes relative to 1988 T stage and 1988 N stage are shown (Table 5).

DISCUSSION

There were five significant findings in this study on the clinical staging for supraglottic laryngeal tumors. First, the 1983 and 1988 versions of the AJCC showed no difference in T stage definitions (Table 1). When applied to patients presenting with primary supraglottic tumors without clinical and

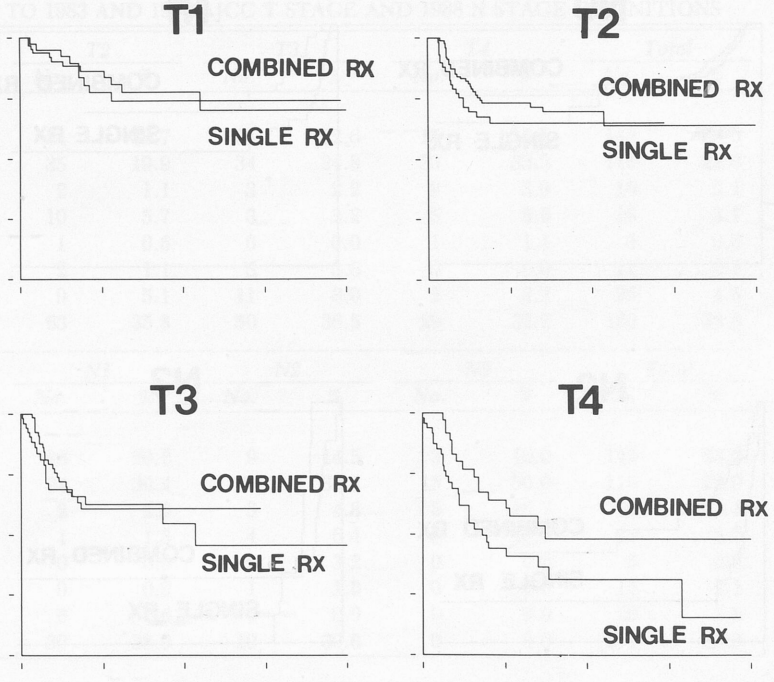

Fig 5. Survival curves according to treatment modality (1983 and 1988 T stage fixed, treatment [RX] varied).

TABLE 4. COX REGRESSION OF COMBINED- VERSUS SINGLE-MODALITY TREATMENT

	N	χ^2	p	Hazard Function Coefficient: Combined Therapy	Hazard Function Coefficient: T Stage
T fixed, treatment varied					
T1	117	0.03	.85	−0.08	
T2	176	0.96	.33	−0.29	
T3	137	0.28	.59	−0.17	
T4	90	4.24	.04	−0.63	
N fixed, treatment varied					
N0	349	0.00	.97	0.01	0.0
N1	79	6.45	.04	−0.75	0.28
N2	62	7.98	.02	−0.93	0.17
N3	30	6.52	.04	−0.96	0.39

radiographic evidence of neck nodes and/or metastases, stages T1 to T4 reliably prognosticate survival (Fig 2 and Table 2).

Second, if patients present with palpable neck nodes, survival is more reliably predicted by the N stage of the disease rather than the T stage. This finding is based on the following observations. When the survival curves were constructed by keeping the N stage of the disease constant for each T stage, differences in survival rates were not statistically significant for N1 to N3 (Table 2). If the converse calculation was done, ie, T stage kept constant and N stage varied, differences in survival rates were statistically significant (Fig 4 and Table 2). This implies that although the size and extent of the tumor as reflected by T stage are important factors in determining prognosis, when regional nodes are present, they become the more important determinant of prognosis, independent of T stage. Hahn et al[7] have concluded that nodal status predominates over T stage as a prognostic determinant for supraglottic cancers. Furthermore, they conclude that T stage has a prognostic value only when the patient has early lymph node involvement (N0 and N1) and there are statistically significant differences in survival between patients with early neck disease (N0 and N1) and advanced neck lesions (N2 and N3) regardless of T stage. They inferred from these data that when a patient presents with advanced neck disease (N2 and N3), the disease is more aggressive with regard to primary recurrence, neck recurrence, and distant metastases irrespective of the extensiveness of the primary lesion. With the above factors, they recommend a more aggressive approach for patients with advanced neck disease and thus recommend combined treatment (radiotherapy and surgery).[7] In a separate study by Wall et al,[8] the relationship between lymph node status and primary tumor control probability was examined. They observed that for early (T1 and T2) and advanced (T3 and T4) disease, primary tumor control at 5-year follow-up decreased progressively with neck nodal disease, independent of the modality of neck treatment. They attributed the finding to the increased probability of local recurrence, treatment failure, and distant metastases when there were palpable nodes at the time of presentation.[8] Lymph node metastases occur with significant frequency in supraglottic carcinoma. McGavran et al[9] reported a 33% incidence of cervical metastases, and Som[10] noted a 32% incidence of lymph node metastases, half of which were palpable preoperatively. In 14 of Som's patients with palpable positive nodes greater than or equal to 2 cm who underwent contralateral neck dissection, there was a 42% incidence of contralateral microscopically positive nodes. Recurrent cervical node metastasis was the most frequent cause of death (15%) in his series.[10]

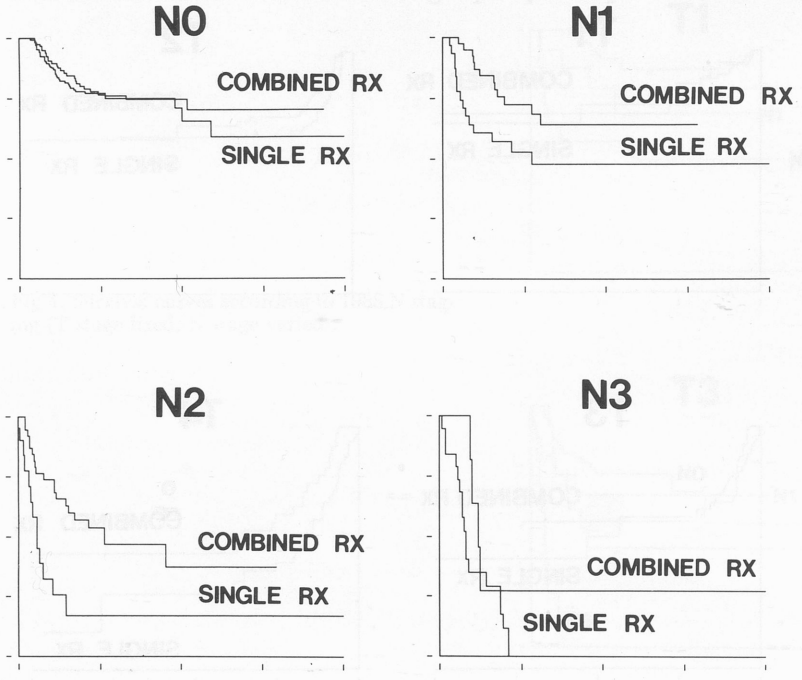

Fig 6. Survival curves according to treatment modality (1988 N stage fixed, treatment varied).

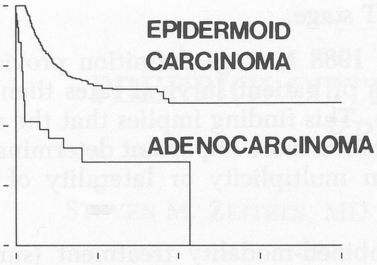

Fig 7. Survival curves according to histologic type.

Third, the 1983 and 1988 AJCC definitions differed in one way: patients with multiple ipsilateral or bilateral or contralateral nodes less than 6 cm in estimated diameter were up-staged to N2 in the 1988 system, whereas in the 1983 version, they were staged N3 regardless of size. The 1988 N stage version showed statistically detectable separation of survival rates compared to the 1983 N stage version (Table 2). This finding implies that size is a more important determinant of survival for supraglottic primaries than multiplicity, bilaterality, or contralaterality of the neck nodes. This finding confirms and agrees with the results of Taylor and Nathanson,[11] who stated that enlargement or palpability of nodes was the most dependable guide to the presence of metastases, which in turn significantly decreases survival. McGavran et al[9] reported that the overall metastatic rate for patients with clinical nodes was 71%. More specifically, they noted that patients with supraglottic cancers with palpable nodes had a metastatic rate of 89%.[9] Bocca et al[12] confirmed this high incidence of neck metastases by reporting that 83% of neck dissection specimens were positive for patients who had clinically suspected metastases. However, it is important to note that there have been studies that emphasized the importance of contralateral metastases. The authors, however, note that the contralateral metastases occur in a delayed and microscopic fashion rather than early in the disease; hence, they are an unsuitable criterion for clinical staging purposes.[13-15]

Fourth, treatment regimens when compared with fixed T staging and varied N staging showed no detectable difference in survival (Fig 5 and Table 4). In contrast, combined surgery and radiotherapy showed significantly better survival than either one alone when patients presented with N1, N2, or N3 neck disease according to the 1988 N definition (Fig 6 and Table 4). This is consistent with previous findings that combined-modality treatment is more effective in improving survival than either modality alone when patients present with suspected metastases preoperatively.[16,17] Preoperative irradiation has resulted in increased cure rates in patients with supraglottic cancer with clinically positive nodes.[18] There was, however, no evidence in the present study that preoperative radiotherapy significantly improved survival relative to postoperative radiotherapy (Table 3); similarly, there was no difference in survival rates when irradiation and surgery alone were compared ($p > .05$; Table 3).

Last, the histologic type of the primary tumor also contributed to survival. This result confirmed previous findings that epidermoid carcinoma had a better prognosis than other histologic types such as adenocarcinoma (Fig 7 and Table 2). More than 90% of laryngeal epithelial malignancies are squamous cell carcinomas and most of these are at least moderately well differentiated.[19] Prognosis of laryngeal cancer is generally related to T stage rather than differentiation, although more poorly differentiated lesions tend to present in more advanced stages.[20] Adenocarcinoma is rare, accounting for

TABLE 5. CAUSES OF DEATH ACCORDING TO 1983 AND 1988 AJCC T STAGE AND 1988 N STAGE DEFINITIONS

	T1		*T2*		*T3*		*T4*		*Total*	
	No.	*%*	*No.*	*%*	*No.*	*%*	*No.*	*%*	*No.*	*%*
1983 and 1988										
Alive	45	38.5	54	30.7	31	22.6	15	16.7	145	28.0
Primary disease	16	14.0	35	19.9	34	24.8	30	33.3	115	22.0
Neck metastases	3	2.6	2	1.1	3	2.2	8	8.9	16	3.1
Distant metastases	1	0.9	10	5.7	3	2.2	5	5.6	19	3.7
Primary and neck metastases	1	0.9	1	0.6	0	0.0	1	1.1	3	0.6
Treatment complications	4	3.4	2	1.1	5	3.6	0	0.0	11	2.1
Second primary	3	2.6	9	5.1	11	8.0	2	2.2	25	4.8
Intercurrent disease	44	37.6	63	35.8	50	36.5	29	32.2	186	35.8
	N0		*N1*		*N2*		*N3*		*Total*	
	No.	*%*	*No.*	*%*	*No.*	*%*	*No.*	*%*	*No.*	*%*
1988										
Alive	117	33.5	16	20.2	9	14.5	3	10.0	145	28.0
Primary disease	52	14.9	24	30.4	24	38.7	15	50.0	115	22.0
Neck metastases	6	1.7	2	2.5	3	4.8	5	16.7	16	3.1
Distant metastases	8	2.3	1	1.3	4	6.4	6	20.0	19	3.7
Primary and neck metastases	1	0.3	0	0.0	2	3.2	0	0.0	3	0.6
Treatment complications	10	2.9	0	0.0	1	1.6	0	0.0	11	2.1
Second primary	19	5.4	6	7.6	0	0.0	0	0.0	25	4.8
Intercurrent disease	136	39.0	30	38.0	19	30.6	0	0.0	186	35.8

0.5% to 5% of laryngeal cancers.[20] The most common adenocarcinoma is adenoid cystic carcinoma. They are locally aggressive and slow-growing. Late recurrences are common and the ultimate prognosis is poor.[21]

In summary, the 1983 and 1988 T staging definition successfully prognosticates survival for patients with supraglottic primaries, with better separation of regional nodes in the 1988 N stage definition than in the 1983 definition.

CONCLUSIONS

1. The 1983 and 1988 AJCC T stage definitions successfully prognosticate survival of patients with supraglottic primaries, provided they present without clinical evidence of neck nodes and/or metastases.

2. When a patient with a supraglottic primary presents with neck nodes, the N stage of the disease becomes a more important predictor of survival than the T stage.

3. The 1988 N stage definition provides better separation of patient survival rates than the 1983 definition. This finding implies that the size of the neck nodes is a more important determinant of survival than multiplicity or laterality of the neck nodes.

4. Combined-modality treatment (surgery and radiotherapy) showed significantly better survival rates than either modality alone in patients with supraglottic primaries and positive neck nodes. There was also a significant difference between combined-modality and single-modality treatment in the T4 stage.

5. There was no significant difference in survival when preoperative and postoperative radiotherapeutic regimens were compared.

6. Squamous cell carcinoma had a significantly better prognosis than rare histologic types such as adenocarcinoma.

ACKNOWLEDGMENT — Ahmed F. Ghouri, Department of Anesthesiology, Washington University School of Medicine, provided the technical drawings of the larynx.

REFERENCES

1. Robbins KT, Davidson W, Peters LJ, Goepfert H. Conservation surgery for T2 and T3 carcinomas of the supraglottic larynx. Arch Otolaryngol Head Neck Surg 1988;114:421-6.

2. Lee NK, Goepfert H, Wendt CD. Supraglottic laryngectomy for intermediate-stage cancer: U.T. M.D. Anderson Cancer Center experience with combined therapy. Laryngoscope 1990; 100:831-6.

3. Maceri DR, Lampe HB, Makielski KH, Passamani PP, Krause CJ. Conservation laryngeal surgery. A critical analysis. Arch Otolaryngol 1985;111:361-5.

4. American Joint Committee on Cancer. Manual for staging of cancer. 2nd ed. Philadelphia, Pa: JB Lippincott, 1983:13-42.

5. American Joint Committee on Cancer. Manual for staging of cancer. 3rd ed. Philadelphia, Pa: JB Lippincott, 1988:39-43.

6. DeSanto LW, Magrina C, O'Fallon WM. The "second" side of the neck in supraglottic cancer. Otolaryngol Head Neck Surg 1990;102:351-61.

7. Hahn SS, Spaulding CA, Kim J, Constable WC. The prognostic significance of lymph node involvement in pyriform sinus and supraglottic cancers. Int J Radiat Oncol Biol Phys 1987; 13:1143-7.

8. Wall TJ, Peters LJ, Brown BW, Oswald MJ, Milas L. Relationship between lymph nodal status and primary tumor control probability in tumors of the supraglottic larynx. Int J Radiat Oncol Biol Phys 1985;11:1895-902.

9. McGavran MH, Bauer WC, Ogura JH. The incidence of cervical lymph node metastases from epidermoid carcinoma of the larynx and their relationships to certain characteristics of the primary tumor. Cancer 1961;14:55-66.

10. Som ML. Conservation surgery for carcinoma of the supraglottis. J Laryngol Otol 1970;84:655-78.

11. Taylor CW, Nathanson IT. Lymph node metastases. New York, NY: Oxford University Press, 1972.

12. Bocca E, Pignataro O, Oldini C, Cappa C. Functional neck dissection: an evaluation and review of 843 cases. Laryngoscope 1984;94:942-5.

13. Levendag P, Vikram B. The problem of neck relapse in early stage supraglottic cancer — results of different treatment modalities for the clinically negative neck. Int J Radiat Oncol Biol Phys 1987;13:1621-4.

14. DeSanto LW. Early supraglottic cancer. Ann Otol Rhinol Laryngol 1990;99:593-7.

15. Lutz CK, Johnson JT, Wagner RL, Myers EN. Supraglottic carcinoma: patterns of recurrence. Ann Otol Rhinol Laryngol 1990;99:12-7.

16. Wang CC. Radiation therapy for head and neck neoplasms. 2nd ed. Chicago, Ill: Year Book Medical Publishers, 1983:9-11, 160-95.

17. Kramer S, Marcial VA, Pajak TT, MacLean CJ, Davis LW. Prognostic factors for loco/regional control and metastases and the impact on survival. Int J Radiat Oncol Biol Phys 1986; 12:573-8.

18. Spaulding CA, Constable WC, Levine PA, Cantrell RW. Partial laryngectomy and radiotherapy for supraglottic cancer: a conservative approach. Ann Otol Rhinol Laryngol 1989;98:125-9.

19. Batsakis JG. Tumors of the head and neck. Clinical and pathological considerations. 2nd ed. Baltimore, Md: Williams & Wilkins, 1979:202-4.

20. Lawson W, Biller HF. In: Suen JY, Myers EN, eds. Cancer in the head and neck. New York, NY: Churchill Livingstone, 1981:434-99.

21. Gadamski SP, Zwillenberg DA. Adenocarcinoma of the larynx. Trans Pa Acad Ophthalmol Otolaryngol 1985;37:259-62.

PREEPIGLOTTIC SPACE INVASION IN "EARLY" EPIGLOTTIC CANCER

STEVEN M. ZEITELS, MD CHARLES W. VAUGHAN, MD

BOSTON, MASSACHUSETTS

The tendency of epiglottic cancer to invade the preepiglottic space and the significance of this invasion was evaluated in 36 surgical specimens of epiglottic carcinoma originally staged T1 or T2. None of the 9 lesions originating above the hyoepiglottic ligament invaded the preepiglottic space. Twenty-four of the 27 (89%) lesions originating below the hyoepiglottic ligament showed invasion of the preepiglottic space and were clinically understaged. Of the 3 infrahyoid lesions showing no invasion of the preepiglottic space, 1 was a verrucous carcinoma and another was a mucoepidermoid carcinoma arising on the petiole. All other lesions were squamous cell carcinoma. In 12 of the 24 patients (50%) with preepiglottic space invasion, cervical node metastasis was present despite the preoperative staging of T1 or T2.

KEY WORDS — cancer, epiglottis, larynx, preepiglottic space, staging, supraglottis.

INTRODUCTION

From his analysis of whole-mount laryngeal sections in 1936, Leroux-Robert[1] described the difficulty in clinically assessing the depth of invasion of lower epiglottic and ventricular fold cancers. He also explained that these cancers were predisposed to invade the preepiglottic space. In 1940, Clerf[2] reinforced these concepts and in 1944 he further stated that lymphatic drainage from the base of the epiglottis is carried across the preepiglottic space through the thyrohyoid membrane to the upper deep cervical nodes.[3]

Using dye injections in 1956, Pressman et al[4] demonstrated horizontal lymphatic communications between the lateral paraglottic spaces via the preepiglottic space. In 1962, Tucker and Smith[5] used the whole-organ section technique for studying laryngeal cancer and in 1963 Tucker[6] showed residual cancer in the preepiglottic space after radiotherapy. Bocca et al[7] described the high incidence of preepiglottic space invasion in supraglottic cancer and stressed the importance of the preepiglottic space as a prognosticator of cervical metastasis. Using serial sections, Kirchner[8] and Kirchner and Som[9] found a high incidence of preepiglottic space invasion in epiglottic cancer. Also from serially sectioned specimens, McDonald et al[10] reported that 33 of 40 supraglottic cancers had preepiglottic space invasion. These tumors were confined to the supraglottis but were not exclusively epiglottic primaries. The anatomic definition and prognostic significance of the preepiglottic space were debated at the Centennial Conference on Laryngeal Cancer[11] in 1974. The consensus was that preepiglottic space invasion predisposed to cervical metastasis and a worse prognosis. Partly as a result, the staging system[12,13] was modified in 1977, with preepiglottic space invasion being designated T3. However, the endoscopist still faces the difficulty of assessing an invisible third dimension, invasion of the preepiglottic space, whether by inspection and palpation or by imaging methods.[11] Zeitels et al[14] studied 22 supraglottic cancer specimens originally staged T1 and T2 and found preepiglottic space invasion in 7. This invasion had not been identified by computed tomography.

In a series of 105 patients, Nadol[15] reported cervical metastasis in 3 of 19 (16%) suprahyoid epiglottic cancers and in 28 of 86 infrahyoid lesions (33%) based upon pretreatment clinical staging. In that series, he concluded that the increased incidence of cervical metastasis with infrahyoid lesions resulted in a poorer 5-year survival: 56% in infrahyoid lesions and 79% in suprahyoid.

MATERIALS AND METHODS

To determine the incidence of preepiglottic space invasion and cervical node metastasis in a series of T1 and T2 epiglottic lesions, a study of 36 specimens resected by total or partial laryngectomy was undertaken. Infrahyoid lesions (27) outnumbered suprahyoid lesions (9). Whole-organ sections were used to evaluate 26 laryngectomy specimens at the Yale–New Haven Medical Center, and 10 epiglottectomy specimens at the Boston Veterans Affairs Medical Center were studied by histopathology. Tumor volume was not quantified. Cervical lymph node metastasis was established in 14 cases either by neck dissection or by the appearance of metastatic disease in the cervical nodes during the follow-up period.

RESULTS

Six of the 12 T1 and 18 of the 24 T2 epiglottic le-

From the Massachusetts Eye and Ear Infirmary and the Department of Otology and Laryngology, Harvard Medical School (Zeitels), and Boston University School of Medicine and the Otolaryngology Section, Boston Veterans Affairs Medical Center (both authors), Boston, Massachusetts. Supported by US Public Health Service grant 2-R01-CA 22101-11.

Presented at the meeting of the American Laryngological Association, Waikoloa, Hawaii, May 4-5, 1991.

REPRINTS — Steven M. Zeitels, MD, Dept of Otology and Laryngology, Massachusetts Eye and Ear Infirmary, 243 Charles St, Boston, MA 02114.

sions had unrecognized preepiglottic space invasion (see Figure, A). None of the 9 suprahyoid lesions showed preepiglottic space invasion, whereas 24 of the 27 infrahyoid lesions showed some degree of invasion. Of the 3 infrahyoid cancers without preepiglottic space invasion, 1 was a verrucous carcinoma and another was a mucoepidermoid carcinoma located at the petiole. The third was a squamous cell carcinoma (see Figure, B).

Cervical metastasis occurred in 12 of 24 patients with preepiglottic space invasion. Two of the 24 had been treated by therapeutic neck dissections, and metastatic carcinoma was confirmed pathologically. Elective neck dissection was performed in 14 of the 24 patients with preepiglottic invasion. Seven of the 14 (50%) patients who underwent elective neck dissection had cervical metastasis on pathologic examination. Eight other patients with preepiglottic space invasion and clinically negative necks were treated with radiotherapy. In 3 of these patients, cervical node metastasis eventually developed.

Two of the nine patients with cancer in the suprahyoid epiglottis presented with cervical lymphadenopathy, and metastatic disease was confirmed at neck dissection in both cases. However, both surgical specimens revealed occult invasion of the tongue base. Two other patients with suprahyoid lesions and clinically negative necks underwent neck dissection. Neither had extension outside the larynx or cervical metastatic disease on pathologic examination. Of the remaining five undissected necks in patients with suprahyoid lesions without preepiglottic space invasion, three received radiotherapy to the cervical lymph nodes. None of the five patients has developed metastatic disease during a follow-up period of at least 3 years.

DISCUSSION

The natural fenestrae of the epiglottis below the level of the hyoepiglottic ligament predispose to early preepiglottic space invasion by anterior cancer penetration (see Figure, A).[1,6,8,10,14-17] Clinical assessment of the preepiglottic space is difficult for several reasons. Direct laryngoscopic view of the lower epiglottis is largely two-dimensional and tangential. Instrumental and digital palpation of the vallecula above the hyoepiglottic ligament (the roof of the preepiglottic space) is usually unrevealing unless there is extensive invasion of this space. Radiographic imaging does not provide sufficient resolution for identifying a small volume of tumor (see Figure, A).[14,15,18]

The data generated from this review justify a high level of suspicion that preepiglottic space invasion has occurred with infrahyoid cancer, even with those lesions in an early clinical stage. Twenty-four of the 27 infrahyoid T1 and T2 lesions (89%) had preepiglottic space invasion. However, of the 3 infrahyoid lesions without preepiglottic space invasion, 1 was a verrucous carcinoma and 1 was a mucoepidermoid carcinoma. All the other lesions were squamous cell carcinoma, and 24 of the 25 (96%) exhibited invasion of the preepiglottic space (see Figure, C) and had therefore been understaged. In the present study none of the 9 lesions of the suprahyoid epiglottis invaded the preepiglottic space.

The control rates for treating cancer of the infrahyoid epiglottis by radiotherapy have not equaled those for surgery.[19,20] This may be due in part to the poor blood supply in the preepiglottic tissue, and in part to the difficulty in clinical assessment after radiotherapy. Once the surface has healed, detection of recurrent or residual disease is often delayed, even with deep biopsies.[19]

The preepiglottic space contains no lymph nodes, but it does contain lymphatic channels that allow cervical metastasis.[1,3,4,21,22] The occurrence of cervical metastasis with preepiglottic space invasion has been previously noted by Ogura,[23] Bocca et al,[7] and DeSanto.[24]

In the present study, 1 of the 10 patients with cancer confined to the epiglottic mucosa had metastasis to the neck. This patient had a high-grade mucoepidermoid carcinoma on the petiole. Cervical metastasis often occurred with preepiglottic space invasion (12 of 24) or with tongue base invasion (2 of 2). It is possible that some of the 5 patients with preepiglottic space invasion and clinically negative necks treated by full-course radiotherapy may have had occult cervical node metastasis, so that the incidence of cervical metastasis may be understated. Similarly, in the suprahyoid group there could have been occult cervical metastasis in those necks that were irradiated. Since the neck is usually the site of failure in supraglottic cancer,[11,24-29] aggressive regional management is prudent with any infrahyoid epiglottic carcinoma.

The present study does not determine whether the incidence of cervical metastasis depends on the volume of tumor within the preepiglottic space. For this reason, further study of this group of surgical specimens is being made in an effort to correlate tumor volume and metastatic rates.

CONCLUSIONS

1. Preepiglottic space invasion by squamous cell carcinoma involving the epiglottis inferior to the hyoepiglottic ligament is usual, even in those lesions without clinical evidence of invasion.

2. Invasion of the preepiglottic space by squamous cell carcinoma limited to the epiglottis above the hyoepiglottic ligament did not occur in any of the nine specimens in this study; this finding suggests that such invasion from T1 or T2 lesions rarely occurs.

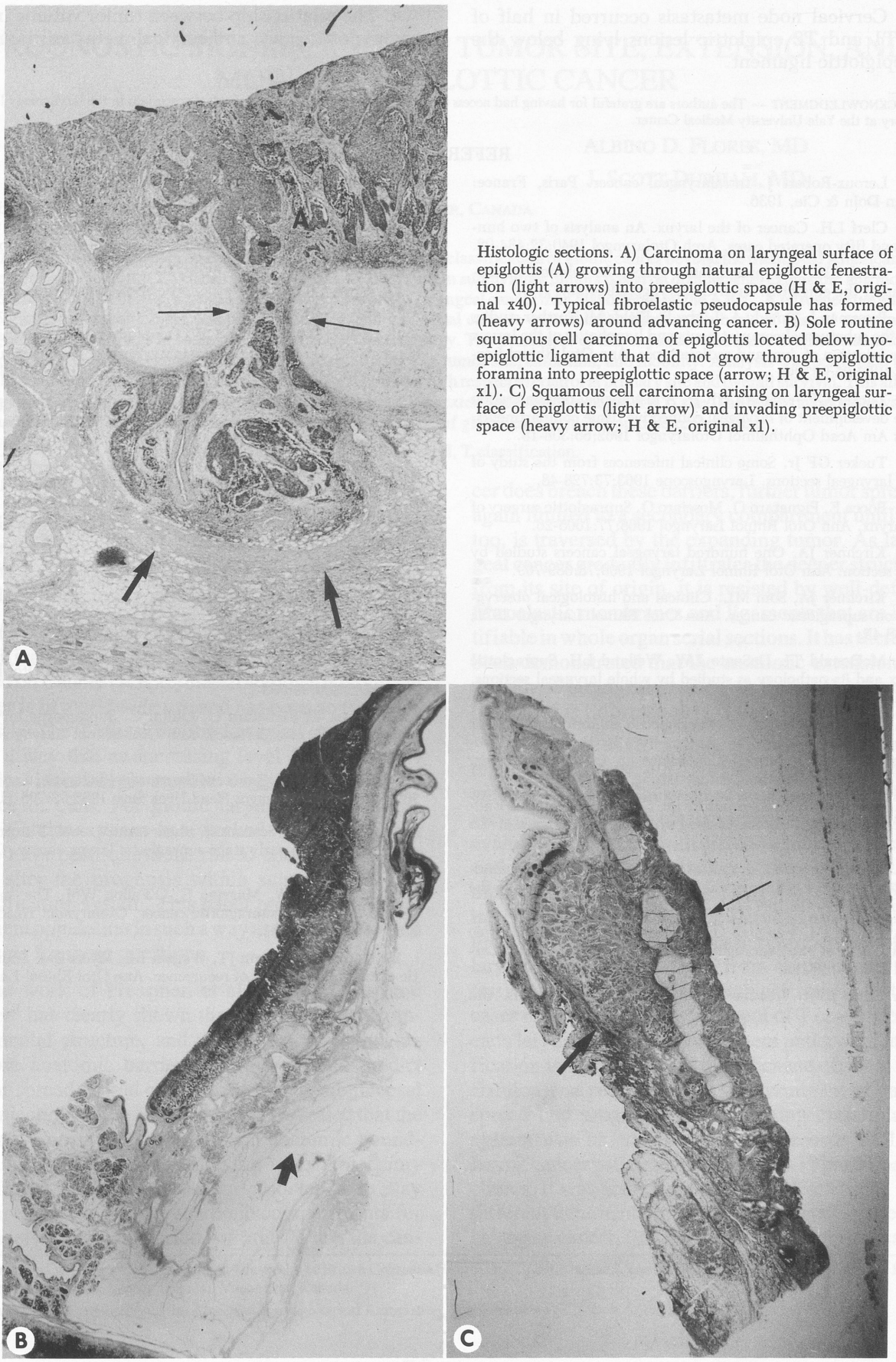

Histologic sections. A) Carcinoma on laryngeal surface of epiglottis (A) growing through natural epiglottic fenestration (light arrows) into preepiglottic space (H & E, original x40). Typical fibroelastic pseudocapsule has formed (heavy arrows) around advancing cancer. B) Sole routine squamous cell carcinoma of epiglottis located below hyoepiglottic ligament that did not grow through epiglottic foramina into preepiglottic space (arrow; H & E, original x1). C) Squamous cell carcinoma arising on laryngeal surface of epiglottis (light arrow) and invading preepiglottic space (heavy arrow; H & E, original x1).

3. Cervical node metastasis occurred in half of the T1 and T2 epiglottic lesions lying below the hyoepiglottic ligament.

4. The relationship between tumor volume in the preepiglottic space and cervical metastasis is still to be determined.

ACKNOWLEDGMENT — The authors are grateful for having had access to the collection of whole-organ surgical specimens in the laryngology laboratory at the Yale University Medical Center.

REFERENCES

1. Leroux-Robert J. Intralaryngeal cancer. Paris, France: Gaston Doin & Cie, 1936.

2. Clerf LH. Cancer of the larynx. An analysis of two hundred and fifty operated cases. Arch Otolaryngol 1940;32:484-98.

3. Clerf LH. The preepiglottic space. Its relation to carcinoma of the epiglottis. Arch Otolaryngol 1944;40:177-9.

4. Pressman J, Dowdy A, Libby R, Fields M. Further studies upon the submucosal compartments and lymphatics of the larynx by the injection of dyes and radioisotopes. Ann Otol Rhinol Laryngol 1956;65:963-80.

5. Tucker GF Jr, Smith HR Jr. A histological demonstration of the development of laryngeal connective tissue compartments. Trans Am Acad Ophthalmol Otolaryngol 1962;66:308-18.

6. Tucker GF Jr. Some clinical inferences from the study of serial laryngeal sections. Laryngoscope 1963;73:728-48.

7. Bocca E, Pignataro O, Mosciaro O. Supraglottic surgery of the larynx. Ann Otol Rhinol Laryngol 1968;77:1005-26.

8. Kirchner JA. One hundred laryngeal cancers studied by serial section. Ann Otol Rhinol Laryngol 1969;78:689-709.

9. Kirchner JA, Som ML. Clinical and histological observations on supraglottic cancer. Ann Otol Rhinol Laryngol 1971; 80:638-45.

10. McDonald TJ, DeSanto LW, Weiland LH. Supraglottic larynx and its pathology as studied by whole laryngeal sections. Laryngoscope 1976;86:635-48.

11. Maguire A, Dayal VS. Supraglottic anatomy: the pre- or the peri-epiglottic space. In: Alberti PW, Bryce DP, eds. Proceedings of the Centennial Conference on Laryngeal Cancer. New York, NY: Appleton-Century-Crofts, 1976:26-39.

12. American Joint Committee for Cancer Staging and End-Results Reporting. Clinical staging system for carcinoma of the larynx. Chicago, Ill: 1972.

13. American Joint Committee for Cancer Staging and End-Results Reporting. Clinical staging system for carcinoma of the larynx. Chicago, Ill: 1977.

14. Zeitels SM, Vaughan CW, Domanowski GF. Endoscopic management of early supraglottic cancer. Ann Otol Rhinol Laryngol 1990;99:951-6.

15. Nadol JB Jr. Treatment of carcinoma of the epiglottis. Ann Otol Rhinol Laryngol 1981;90:442-8.

16. Olofsson J, Van Nostrand AWP. Growth and spread of laryngeal and hypopharyngeal carcinoma with reflections on the effect of preoperative irradiation: 139 cases studied. Acta Otolaryngol [Suppl] (Stockh) 1973(suppl 308).

17. Gregor RT. The preepiglottic space revisited: is it significant? Am J Otolaryngol 1990;11:161-4.

18. Zeitels SM, Vaughan CW, Domanowski GF, Fuleihan NS, Simpson GT II. Laser epiglottectomy: endoscopic technique and indications. Otolaryngol Head Neck Surg 1990;103:337-43.

19. Kirchner JA. What have whole organ sections contributed to the treatment of laryngeal cancer? Ann Otol Rhinol Laryngol 1989;98:661-7.

20. Kirchner JA, Carter D. Intralaryngeal barriers to the spread of cancer. Acta Otolaryngol (Stockh) 1987;103:503-13.

21. Dayal VS, Bahri H, Stone PC. Preepiglottic space. An anatomic study. Arch Otolaryngol 1972;95:130-3.

22. Lam KH, Wong J. The preepiglottic and paraglottic spaces in relation to spread of carcinoma of the larynx. Am J Otolaryngol 1983;4:81-91.

23. Ogura JH. Surgical pathology of cancer of the larynx. Laryngoscope 1955;65:867-926.

24. DeSanto LW. Early supraglottic cancer. Ann Otol Rhinol Laryngol 1990;99:593-7.

25. Bocca E, Pignataro O, Oldini C. Supraglottic laryngectomy: 30 years of experience. Ann Otol Rhinol Laryngol 1983; 92:14-8.

26. DeSanto LW. Cancer of the supragottic larynx: a review of 260 patients. Otolaryngol Head Neck Surg 1985;93:705-11.

27. Levendag P, Sessions R, Bhadrasain V, et al. The problem of neck relapse in early stage supraglottic larynx cancer. Cancer 1989;63:345-8.

28. DeSanto LW, Magrina C, O'Fallon WM. The "second" side of the neck in supraglottic cancer. Otolaryngol Head Neck Surg 1990;102:351-61.

29. Lutz CK, Johnson JT, Wagner RL, Myers EM. Supraglottic carcinoma: patterns of recurrence. Ann Otol Rhinol Laryngol 1990;99:12-7.

PROGNOSTIC SIGNIFICANCE OF TUMOR SITE, EXTENSION, AND MOBILITY IN GLOTTIC CANCER

MURRAY D. MORRISON, MD
ALBINO D. FLORES, MD
ASHLEY SIKAND, MD
J. SCOTT DURHAM, MD
VANCOUVER, CANADA

This study was designed to analyze the value of an anatomic subclassification of glottic cancer beyond the traditional American Joint Committee on Cancer (AJCC) classification. A classification system subdividing tumors based on detailed site, extension, and mobility was developed that permitted a more accurate categorization of laryngeal cancer than that offered by the AJCC. A retrospective analysis of 345 glottic laryngeal tumors was then undertaken, and individual cancers were subclassified on the basis of clinical examination, laryngeal video recordings in some cases, endoscopy, and radiology. The usefulness of this expanded and more detailed classification system was assessed by evaluating the prognostic significance of tumor site, extension, and mobility. Analysis was performed to test for statistically significant differences between tumor subgroups with respect to control at primary site and overall survival. This allowed a comparison of treatment outcome for laryngeal tumors of various extensions within a single AJCC site. The results support the validity of the current AJCC and did not identify any particular subgroup of glottic cancer that should be reclassified.

KEY WORDS — laryngeal cancer, subsite treatment, survival, T classification.

INTRODUCTION

The development of a classification system for the staging of laryngeal cancer had its origin in 1952, when Pierre Denoix first conceived the TNM system for classifying malignant tumors.

The International Union Against Cancer (UICC) classification and the combined American Joint Committee on Cancer (AJCC) classification for laryngeal cancer is in worldwide use and has been so for many years.[1,2] The T classification has been structured in such a way that an increasing level from T1 to T4 implies increasingly severe disease and reduced chance of cure. For glottic laryngeal cancers this classification system has worked well for us, but there have been questions raised about factors that may alter the prognosis within subgroups of this classification system. This paper presents data from a patient population in such a way as to attempt to find answers for these questions.

The work of Pressman et al[3] and Kirchner and Carter[4] has clearly shown that the larynx is a compartmental structure, and that these compartments impose anatomic barriers that govern and predict tumor spread. Initial experiments using submucosal dye injections into cadaver larynges revealed that the dye stays confined within certain anatomic boundaries. Histopathologic evaluation of laryngectomy specimens reveals that cancer also tends to stay confined to these same anatomic compartments for relatively prolonged periods of time. When the cancer does breach these barriers, further tumor spread is again limited to a secondary compartment until this, too, is traversed by the expanding tumor. As laryngeal cancer gradually infiltrates the deeper structures from its site of origin, it is resisted by well-defined fibroelastic membranes and ligaments that are identifiable in whole organ serial sections. It has therefore been demonstrated that the anatomic extension and growth of laryngeal cancer can be predicted on the basis of this information.

In addition to information regarding theoretic patterns of tumor growth and knowledge of laryngeal anatomy, the development of a clinically useful and verifiable system of classifying cancer requires the evaluation of tumors with different sites of origin and various degrees of extension with respect to treatment outcome and survival. The 1962 "Clinical Staging System for Cancer of the Larynx" as put forth by the AJCC was based on a retrospective review of 600 laryngeal cancers collected from seven cancer centers.[2] An analysis of the treatment results of these cases resulted in the development of T categories for each laryngeal region. This system underwent modification in 1972, after the significance of vocal cord fixation was recognized as a determinant of cancer spread and prognosis. The resulting classification system was based on a study of records of 1,645 larynx cancer patients collected from 19 participating clinics. It was acknowledged that these clinics used different treatment protocols in their management of laryngeal cancer. Revisions to the 1972 classification

From the Division of Otolaryngology, University of British Columbia (Morrison, Sikand, Durham), and the Division of Radiation Oncology, British Columbia Cancer Agency (Flores), Vancouver, Canada.

Presented at the meeting of the American Laryngological Association, Waikoloa, Hawaii, May 4-5, 1991.

were made in 1976, during the Centennial Conference on Laryngeal Cancer in Toronto. These modifications primarily involved defining anatomic boundaries and descriptions of T classes. The resulting classification system has been used up to the present time and is essentially the same as that described by the UICC.

T1 glottic carcinoma consists of a tumor that is limited to the vocal cords and that does not alter mobility. It may extend to involve the entire glottic region, including both vocal cords, as well as anterior and posterior commissures. Concern has been raised in the past about T1 carcinomas involving the commissures, particularly the anterior commissure.[5] It was felt that these may be less curable, possibly because of early invasion into the cartilage at the anterior commissure because of ligamentous insertions there, or more difficulty in aiming and controlling radiotherapy. Another possibility for difficulty would be the added complexities of surgical treatment around the anterior commissure.

For a laryngeal glottic carcinoma to be classified as T2, it must start in the glottis, but it may extend to adjacent supraglottic structures, to the subglottis, or both. Additionally, the tumor may limit mobility of the vocal cord, but not to the extent of fixation. Are some of these factors more important than others? Does extension to supraglottic adjacent structures carry a lesser or greater risk than subglottic extension? Or is extension in one or both directions more or less important than the limitation of mobility? Does the tumor limited to the vocal cord, but with reduced mobility, carry a worse prognosis than a T2 carcinoma that extends to supraglottic and subglottic structures, but with mobility maintained?

Mårtensson et al[6] noted the relationship between reduced cord mobility and survival in 1967, and this led to the suggestion that T2 tumors should be subclassified as T2a if they are T2 by reason of extension only, and T2b if they have reduced mobility. Studies by Harwood et al,[7] Wang,[8] and Wiggenraad et al[9] have led to the conclusion by some[10] that the presence of reduced mobility significantly diminishes the chance of disease control by irradiation. Others[11-13] have not been able to support this difference.

To be classified as T3, the glottic carcinoma must produce fixation within the larynx irrespective of extension. Does supraglottic or subglottic extension alter the prognosis of the T3 carcinoma so that it should be looked at differently than the more deeply invading tumor that is restricted to the vocal cord itself? Another way of looking at this question is to ask whether or not the addition of fixation over and above the T2 extension factors accounts for all of the loss of curability.

A T4 glottic tumor implies cartilage invasion, extension beyond the larynx to neck tissue, or extension from the larynx to adjacent internal structures such as the hypopharynx. Do any of these factors mean a worse prognosis than the others? Unfortunately, our small number of cases of T4 glottic cancer will not provide us answers from this study.

METHODS

A subsite classification system for the larynx was developed for both glottic and supraglottic regions. This system took into account the specific site of tumor origin and patterns of extension to surrounding areas, as well as functional impairments that suggested deeper invasion of tumor.

A broadly based retrospective review was conducted on 486 cases of laryngeal cancer registered at the British Columbia Cancer Agency between 1980 and 1986. The time frame used provided the possibility for 5-year survival statistics. This review collected a large body of data about demographics, clinical presentation, evaluation, and treatment that is not encompassable here, but that will surface in other presentations. From this group, 345 (71%) patients had glottic cancer, and this study evaluates the importance of subsite extension, vocal cord mobility, and combinations thereof on overall disease-specific survival rate.

After examination of referring otolaryngologist reports, oncologist consultation reports, operating room reports, tomographic x-ray or computed tomography reports, video recordings, and treatment staging diagrams, the chart reviewer assigned the case to 1 of 27 subclasses of glottic cancer based on the details of tumor site, extent, and mobility. The status of nodal and distant metastases was, needless to say, included.

The 11 subsites for T1 lesions are listed in Table 1, and the 11 subgroups of T2 and 4 subsites of T3 are listed in Table 2. As there were only nine T4 glottic cancers, these were left in one group together.

As it was noted that some subsites collected only a small number of cases, we decided to cluster them in various combinations in order to help answer the questions asked in the Introduction. The T1 cancers were subgrouped according to size, monofocal versus multifocal disease, and involvement of commissures (Table 1).

The T2 cases were subgrouped by 1) presence or

TABLE 1. T1 GLOTTIS BY REGIONAL SUBGROUPS

T1 Subgroups	*T1 Subsites Studied*	*No. of Cases*	*No. of Deaths*	*% Survival (5-y)*
Tis monofocal	1	21	0	100
Tis multifocal	2	12	0	100
T1 mid-cord	3	63	0	100
T1 commissures	4 (anterior commissure) 5 (anterior commissure and one cord) 6 (anterior commissure and two cords) 7 (vocal process) 8 (posterior commissure)	34	1	97
T1 entire cord	9 (entire cord) 11 (subglottic <5 mm)	24	0	100
T1 bilateral	10	13	0	100
Total		167	1	99

absence of impaired mobility, 2) minimal extent versus bulky tumor, 3) transglottic versus nontransglottic disease, and 4) subglottic versus supraglottic extension. The T3 tumors were then looked at in reference to supraglottic extension, subglottic extension, or both, in combination with the T2 tumors. As only 3 of 50 T3 tumors were confined to the primary site, a meaningful comparison of this aspect could not be made. The numbers associated with all of the above T2 and T3 subgroupings are listed in Tables 3 through 6. Nodal status was recorded.

TABLE 2. CARCINOMA OF GLOTTIS (T2, T3, T4)

	No. of Cases	*Alive, Free of Disease*	*Dead of Disease or Alive With Disease*
T2 (normal mobility) by extension to			
Ventricle	44	32	0
False cord	8	5	1
Arytenoid and/or ae fold	1	1	0
Subglottis >5 mm	13	8	3
Transglottic	3	1	0
T2 with impaired mobility			
Confined to site	16	9	1
With extension			
To ventricle	19	14	1
To false cord	5	2	1
To arytenoid and/or ae fold	1	0	0
To subglottis >5 mm	6	3	0
Transglottic	3	2	0
T3 (fixation)			
Confined to site	3	2	0
Extension to supraglottis	24	13	10
Extension to subglottis	4	2	2
Extension transglottic	19	7	9
T4 through thyroid cartilage and/or beyond larynx	9	2	5

ae — aryepiglottic.

The treatment policies for patients with glottic cancer at our center can be generalized as follows.

1. Endoscopic laser excision of localized in situ lesions.
2. Radiotherapy, usually 60 Gy in 25 fractions over 5 weeks, with surgery for salvage for T1, T2, and most T3 tumors.
3. Combined irradiation and surgery for extensive disease. Surgery may precede irradiation when the airway is compromised or when the chances of saving the larynx are minimal.

Treatment modalities for the 345 glottic tumors reviewed are summarized in Table 7.

RESULTS

Table 8 itemizes the number of cases in each T classification and, in combination with the disease-specific survival curves shown in the Figure, demonstrates the very high rate of disease control for T1 and T2 tumors. This grouping by traditional T class constitutes the data to which the subgroups below are compared.

Table 1 presents data for T1 glottic cancer subgroups. Since only 1 of the 167 patients actually died of laryngeal disease, it is clear that the subsite class system for T1 lesions does not add useful prognostic information. A look at Table 7 will reveal that 160 Tis and T1 cancers were treated with irradiation. One hundred forty-seven, or 92%, were controlled by this treatment, and 13 required salvage surgery.

TABLE 3. IMPAIRED VERSUS NORMAL MOBILITY IN T2 GLOTTIS

	No. of Cases	*Deaths*	*% Survival*
Normal	69	4	94
Impaired	50	2	96

No differences; overall $\chi^2 = 0.20$ on 1 df, and $p = .6634$; χ^2 for trend = 0.00 on 1 df, and $p = .9713$.

TABLE 4. MINIMAL EXTENT VERSUS BULKY TUMOR IN T2 GLOTTIS

	No. of Cases	Deaths	% Survival
T2 minimal extent	98	4	96
T2 bulky tumor	21	2	90

No differences; overall $\chi^2 = 1.17$ on 1 df, and $p = .279$; χ^2 for trend = 0.29 on 1 df, and $p = .5919$.

Table 2 lists the number of cases in each subsite for T2, T3, and T4 tumors, the number that are alive and free of their cancer at 5 years, and the number that have died because of laryngeal carcinoma or are still alive with the disease. Note that there are no differences in disease control rates among the four T3 subgroupings.

Table 3 compares those T2 glottic lesions with normal mobility with those having impaired mobility. The 5-year disease-specific survival rates for these two groups are virtually identical.

Table 4 lists 98 tumors that have been clustered together because of minimal extent of tumor. Among this disease-specific group there were two deaths, for an overall survival of 96%. The T2 tumors that were clustered as being bulky in their extent numbered 21, and these had a somewhat less but still not significantly different 90% disease-specific survival rate.

Table 5 examines those cases in which T2 glottic carcinoma spread to the supraglottis, to the subglottis, or to both. Seventy-eight patients had supraglottic extension, with three deaths and 96% survival. Of the 19 patients with subglottic extension, there were three deaths, with a disease-specific survival rate of 84%. Even though this is a 12% drop in survival, the p value was not significant. Interestingly, there were no deaths among those 6 patients presenting with T2 lesions extending both subglottically and supraglottically.

A breakdown of all the T2 and T3 carcinomas by subglottic and supraglottic extension is shown in Table 6, and there is a highly significant difference. There are 23 patients with subglottic extension and 102 patients with supraglottic extension. These patients have 83% and 88% disease-specific survivals, respectively, indicating no difference. However, when the tumor extension went in both directions, as it did

TABLE 5. T2 SUBGLOTTIC VERSUS SUPRAGLOTTIC EXTENSION

	No. of Cases	Deaths	% Survival
Subglottic	19	3	84
Supraglottic	78	3	96
Both	6	0	100

No differences; $\chi^2 = 4.46$ on 2 df, and $p = .1074$.

TABLE 6. T2 AND T3 SUBGLOTTIC VERSUS SUPRAGLOTTIC EXTENSION

	No. of Cases	Deaths	% Survival
Subglottic	23	4	83
Supraglottic	102	12	88
Both	25	9	64

Highly significant differences and trend; $\chi^2 = 12.55$ on 2 df, and $p = .0019$; χ^2 for trend = 10.39 on 1 df, and $p = .0013$.

in 25 patients, there were nine deaths, for a disease-specific survival rate of 64% that is significant to a p value of .0019. Since none of the 6 patients shown in Table 5 with both subglottic and supraglottic extension in T2 carcinoma died, then the nine deaths because of spread both ways in Table 6 were T3 patients. The difference in percent survival then represents the fact that the T3 carcinomas were the ones accounting for the worsening of the prognosis; this finding brings us back to the validity of our original differences by traditional T classification (Table 8).

Almost all glottic cancer patients presented without nodal metastatic disease. Only 8 of the 345 patients had nodes, but this group had a much worse prognosis ($p < .001$).

Table 7 indicates the manner in which the 345 patients with glottic carcinoma were treated at our institution. They are broken down by T classification and by rather coarse treatment groupings including 1) surgery alone, 2) irradiation alone, 3) surgery followed by irradiation, and 4) irradiation followed by surgery. Surgical treatment alone was used in only 12 cases, with seven endoscopic treatments of very early disease, and five total laryngectomies for advanced T3 lesions. The vast majority, 271 cases, received radiotherapy as the sole modality of treatment. A few patients had surgical treatment followed by radiotherapy. In the T1 and T2 groups this consisted of surgical resection followed by radiotherapy because of an inability to control disease, and in the more advanced T3 and T4 tumors, laryngectomy with postoperative radiotherapy. However, most cases of combined treatment entailed preoperative radiotherapy, either as a planned combined treatment, or

TABLE 7. TREATMENT FOR GLOTTIC CANCER AT BRITISH COLUMBIA CANCER AGENCY, 1980 TO 1985

	Surg	Rad	Surg → Rad	Rad → Surg	Total
Tis	5	26	1	1	33
T1	2	115	5	12	134
T2	0	98	4	17	119
T3	5	28	1	16	50
T4	0	4	2	3	9
Total	12	271	13	49	345
%	3	79	4	14	

Surg — surgery, Rad — irradiation, arrow — followed by.

TABLE 8. GLOTTIS BY AJCC CLASSIFICATION

	No. of Cases	*%*	*Deaths*	*% Survival (5-y)*
Tis	33	9	0	100
T1	134	39	1	99
T2	119	34	6	95
T3	50	15	19	62
T4	9	3	5	44
Total	345	100	31	91

with surgery for salvage of irradiation failure.

Table 9 compares irradiation control with final disease control in the various T2 glottic cancer subgroupings. It demonstrates the high level of effectiveness of radiotherapy for the cure of this disease. There are no significant differences between the groups.

DISCUSSION

Our data would indicate that the current AJCC classification is working well in predicting response to therapy. Since T1 tumors are so curable and no particular subsite stands out as having a less good prognosis, they will not be discussed further except to say that anterior commissure lesions fare no worse than other glottic lesions.

The presence or absence of limitation of vocal cord mobility in T2 lesions has not been shown to be of any significance in our patients. However, limited mobility, as distinct from fixation, is a very subjective finding and may be misleading. For example, in our case reviews, it was occasionally observed that the referring otolaryngologist reported normal mobility, whereas subsequent evaluation at the cancer agency described movement restriction. Might this have been caused by postbiopsy inflammation? Whose opinion should be taken? Movement asymmetries may also be seen in larynges without cancer. In any event, we do not find any reason to suggest that T2 tumors with limited mobility should be given a separate classification category.

There is a suggestion from our data that tumors spreading to the subglottis present a less favorable prognosis than those with supraglottic extension. However, the differences are not significant until the T2 and T3 cancers are combined. In this situation, it is shown that glottic tumors going to the subglottis, or

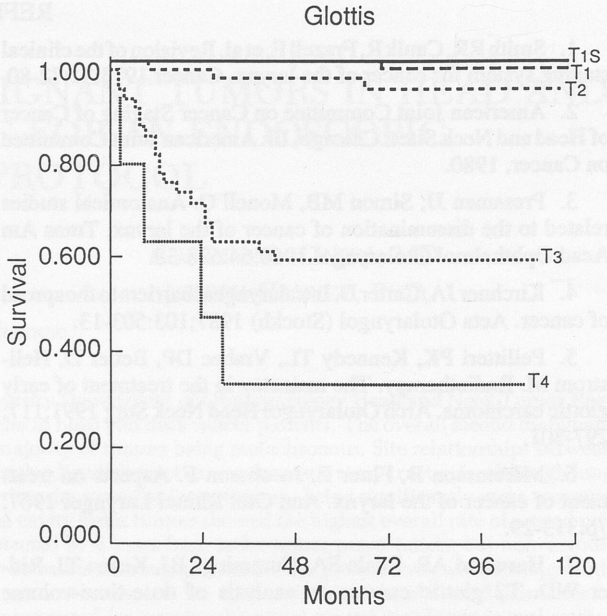

Disease-specific survival curves ($p < .001$) for 345 cases of glottic cancer by T classification, treated at the British Columbia Cancer Agency, 1980 to 1985.

that are transglottic, are more difficult to control than those with only supraglottic spread. This is more significant when the cord is fixed, ie, T3, implying that the deeply invading subglottic extension is the dangerous element. This is logical, particularly in light of Kirchner and Carter's[4] demonstration of tumor exit pathways.

In order to accrue 5-year survival information, the data presented here were from patients treated between 1980 and 1985. Routine pretreatment computed tomography scanning was not employed until toward the end of this time, and the scan quality was poor. We were therefore unable to compare measurements of tumor bulk with other parameters, but the addition of this, together with more precise documentation of tumor extent and mobility such as afforded by video endoscopic recordings, will allow us to present even stronger data in the future.

We will continue to collect data about tumor extension and cord mobility so that as time passes the potential value of subsite classification may emerge. For now, it would appear that the current AJCC classification system is adequate for our prognostic needs.

TABLE 9. IRRADIATION CONTROL AND FINAL CONTROL BY EXTENT AND MOBILITY IN T2 GLOTTIC CANCER

	Normal Mobility			*Impaired Mobility*			
T2 Glottis	*Supra*	*Sub*	*Both*	*Supra*	*Sub*	*Both*	*Localized*
No. of patients	53	13	3	25	6	3	16
% Irradiation control	83	77	100	84	100	100	94
% Final control	98	77	100	92	100	100	94

Supra — supraglottic, Sub — subglottic.

REFERENCES

1. Smith RR, Caulk R, Frazell E, et al. Revision of the clinical staging system for cancer of the larynx. Cancer 1973;31:72-80.

2. American Joint Committee on Cancer Staging of Cancer of Head and Neck Sites. Chicago, Ill: American Joint Committee on Cancer, 1980.

3. Pressman JJ, Simon MB, Monell C. Anatomical studies related to the dissemination of cancer of the larynx. Trans Am Acad Ophthalmol Otolaryngol 1960;64:628-38.

4. Kirchner JA, Carter D. Intralaryngeal barriers to the spread of cancer. Acta Otolaryngol (Stockh) 1987;103:503-13.

5. Pellitteri PK, Kennedy TL, Vrabec DP, Beiler D, Hellstrom M. Radiotherapy. The mainstay in the treatment of early glottic carcinoma. Arch Otolaryngol Head Neck Surg 1991;117: 297-301.

6. Mårtensson B, Fluur E, Jacobsson F. Aspects on treatment of cancer of the larynx. Ann Otol Rhinol Laryngol 1967; 76:313-29.

7. Harwood AR, Beale FA, Cummings BJ, Keane TJ, Rider WD. T2 glottic cancer: an analysis of dose-time-volume factors. Int J Radiat Oncol Biol Phys 1981;7:1501-5.

8. Wang CC. Factors influencing the success of radiation therapy for T2 and T3 glottic carcinomas. Am J Clin Oncol 1986;96:517-20.

9. Wiggenraad RG, Terhaard CH, Horidijk GJ, Ravasz LA. The importance of vocal cord mobility in T2 laryngeal cancer. Radiother Oncol 1990;18:321-7.

10. Ang KK, Peters LJ. Vocal cord cancer: 2B worse than not 2B? Radiother Oncol 1990;18:365-6.

11. Van den Bogaert W, Ostyn F, van der Schueren E. The significance of extension and impaired mobility in cancer of the vocal cord. Int J Radiat Oncol Biol Phys 1983;9:181-4.

12. Karim ABMF, Kralendonk JH, Yap LY, et al. Heterogeneity of stage II glottic carcinoma and its therapeutic implications. Int J Radiat Oncol Biol Phys 1987;13:313-7.

13. Howell-Burke D, Peters LJ, Goepfert H, Oswald MJ. T2 glottic cancer. Recurrence, salvage, and survival after definitive radiotherapy. Arch Otolaryngol Head Neck Surg 1990; 116:830-5.

META-ANALYSIS OF SECOND MALIGNANT TUMORS IN HEAD AND NECK CANCER: THE CASE FOR AN ENDOSCOPIC SCREENING PROTOCOL

BRUCE H. HAUGHEY, MBChB, FRACS
GEORGE A. GATES, MD
CYNTHIA L. ARFKEN, PhD
JOSEPH HARVEY, PhD
ST LOUIS, MISSOURI

A meta-analysis was performed on data from the Washington University Department of Otolaryngology Head and Neck Tumor Registry and 24 studies reporting synchronous and metachronous malignancies in head and neck cancer patients. The overall second malignant tumor (second primary) prevalence was 14.2% in 40,287 patients, the majority of tumors being metachronous. Site relationships between index tumors and second primaries revealed significantly high risks along the digestive tract axis or the respiratory tract axis, although lung second primaries were prevalent in all groups. Head and neck second primaries were the largest group, being significantly more common in the oral cavity, oropharynx, and hypopharynx than in the larynx. Oral cavity index tumors showed the highest overall rate of second primary formation. Half of all aerodigestive tract second primaries are detected by 2 years from index tumor presentation, but non–aerodigestive tract tumors are common beyond 5 years. A significantly higher detection rate was proven for the prospective panendoscopy studies. We recommend routine interval endoscopic intervention within 2 years of treatment for optimum detection of second primaries in head and neck cancer patients. Also, a lifetime of clinical surveillance is suggested for aerodigestive tract second neoplasms in oral cavity, oropharynx, and hypopharynx cancer patients and for lung and non–aerodigestive tract neoplasms in larynx cancer patients.

KEY WORDS — endoscopy, head and neck cancer, metachrony, screening, synchrony.

INTRODUCTION

Detailed review of treatment outcomes in head and neck cancer reveals a large patient group who survive their first tumor only to succumb to a second.[1] From 10% to 40% may develop a subsequent primary tumor,[2] the early-stage patients being at particularly high risk.[3,4] Earlier presentation of patients and greater treatment successes may even increase the proportion who develop second malignancies. While endoscopic screening for simultaneous malignancies in the head and neck and upper aerodigestive tract is considered routine,[5] few centers adopt a systematic endoscopic approach to detection of subsequent metachronous malignancies. M. Savary of Lausanne, Switzerland, however, demonstrated a 29% tumor yield from endoscopy and toluidine blue staining conducted 2 years after initial treatment for the index head and neck tumor. Over half the patients were asymptomatic with a negative clinical examination, chest x-ray study, and cytology (unpublished data, 1990).

We conducted a retrospective review of patients entered into Washington University's Department of Otolaryngology Head and Neck Tumor Registry and patient data from other selected series, totaling 41,830 patients with index squamous carcinoma of the head and neck. The overall prevalence, the site specificity, and the time to development of second primaries was analyzed to determine 1) the prevalence of new tumors, 2) where in the body to screen for second primaries, and 3) when to screen endoscopically for second primaries.

METHODS

WASHINGTON UNIVERSITY REGISTRY STUDY

This retrospective study was based on records of 5,246 patients treated for head and neck cancer between 1961 and 1989 in the Department of Otolaryngology at Washington University School of Medicine, St Louis, Mo. Eight hundred two patients were found to have second primaries. However, the study was then narrowed to 4,181 patients with index squamous carcinoma of the oral cavity, oropharynx, hypopharynx, or larynx. Nasopharyngeal and sinus index tumor patients were excluded because of their low risk for second primaries.[6] However, only 3,706 of these 4,181 patients had suitable follow-up data in the registry. These 3,706 patients, therefore, represented the total population at risk for second primaries with index tumors at the above four head and neck sites. This group contained 475 patients with two or more subsequent tumors. Third, fourth, and subsequent primaries were counted and included in the site and time analyses.

Treatments received by these patients represented a mix of primary surgery, primary radiotherapy, planned combined irradiation and surgery, and chemotherapy. All patients since the 1960s had undergone rigid endoscopy, chest radiography, and barium swallow studies for staging and detection of

From the Department of Otolaryngology–Head and Neck Surgery (Haughey, Gates, Harvey) and the Division of Biostatistics (Arfken), Washington University School of Medicine, St Louis, Missouri.

Presented at the meeting of the American Laryngological Association, Waikoloa, Hawaii, May 4-5, 1991.

REPRINTS — Bruce H. Haughey, MBChB, FRACS, Dept of Otolaryngology–Head and Neck Surgery, Washington University School of Medicine, 4932 Forest Park Blvd, St Louis, MO 63108.

simultaneous primary tumors in the upper aerodigestive tract. Bronchoscopy has not been routine. Data were then analyzed for overall incidence, site relationships between index and second primaries, and the time course of detection of second primaries from the presentation of the index tumor. The criteria of Warren and Gates[7] were used for definitions of newly discovered tumors as distinct primaries versus recurrences. Second primaries were defined as synchronous if discovered simultaneously with the index head and neck tumor or within 6 months of it. Second primaries discovered any time after 6 months were defined as metachronous. The site analysis used the principle of reciprocal associations,[8] in which occurrences in two primary sites, eg, oral cavity and lung, were considered valid in whatever order they occurred because of their potential biologic association. Similarly, in analyzing the time of appearance for second primaries, patients who had a documented malignancy prior to presentation with their head and neck tumor at Washington University were included in the study. In these cases the presenting tumor was considered the second primary. No allowance was made for patients lost to follow-up. Mortality from either uncontrolled index tumor or unrelated causes was considered to be a constant factor in any mixed group of head and neck cancer patients that would cause attrition of the population at risk for second primaries. The mean follow-up period for patients in the Washington University registry was 6.3 years, with a range of 1 to 30 years. A possible source of bias exists because of the 11.4% incomplete follow-up rate in the registry.

META-ANALYSIS STUDY

This phase began with a comprehensive literature review in which published material was included according to the following criteria.

1. The primary topic of the paper was second malignancies in head and neck cancer patients.

2. Data were available for synchronous, metachronous, or overall rate of second primary formation.

3. Warren and Gates's[7] definitions of second primaries were used.

4. The second primaries, both synchronous and metachronous, were identified by site, including both aerodigestive tract and distant locations. The head and neck sites could be grouped or separated into the four principal regions. The index tumor had to be identifiable as being from the larynx, oropharynx, hypopharynx, or oral cavity. Nasopharyngeal and sinus cancers were again excluded.

5. For time course analysis, the number of second primaries appearing by 1 year (including synchronous tumors), 2 years, and more than 5 years had to be available and calculable as percentages of total second primaries detected.

The data from 24 previous studies, spanning the 12 years from 1979 to 1990, were found appropriate for inclusion. In the overall prevalence analysis, study locations were a variety of centers worldwide (Table 1[4-6,9-24]). Five of the 24 were prospective panendoscopy studies, analyzed separately for incidence. The literature survey data and the Washington University registry data give a total of 25 series with 41,830 head and neck cancer patients. Of these cases, 2,938 reported in 4 series were exclusively laryngeal cancer.

In the site analysis, there were 18 studies analyzable for laryngeal cancer (19,159 patients), 13 studies for oral cavity cancer (10,641 patients), 8 studies for oropharyngeal cancer (4,504 patients), and 9 studies for hypopharyngeal cancer (4,550 patients).

In the time course analysis, eight studies contained sufficient data to qualify for inclusion under criterion 5 above. Three other studies reported the time to appearance of second primaries as the mode, median, or mean (in years); and one other study, the only to screen prospectively for metachronous tumors, reported a 2-year posttreatment yield for panendoscopy.

STATISTICS

The statistical analysis was done in the Division of Biostatistics. The analysis consisted of comparing site-specific rates within each study and across studies. To do this we corrected for sample size by using both weighted and unweighted analyses. The Wilcoxon rank test was used to compare rates across studies, thus avoiding parametric distributional assumptions. We also used repeated-measures analysis of variance (MANOVA) on rank-transformed data by using Van der Waerden scores for comparing rates within studies. The reported p value from the repeated-measures analysis corresponds to Wilks' Λ multivariate test assessing within-study effects. All analyses were run in SAS.

RESULTS

WASHINGTON UNIVERSITY REGISTRY STUDY

Prevalence. Second primaries were detected in 475 of the 3,706 patients with index tumors of the oral cavity, oropharynx, hypopharynx, and larynx for a prevalence of 12.8%. Four hundred forty-four patients (12.0%) had one second primary, while 31 (0.8%) had two or more second primaries. The 475 patients manifested a total of 528 second primaries for an overall subsequent tumor prevalence of 14.2%. Of these cancers, 107 (20%) were synchronous and the remaining 421 (80%) were metachronous.

Site Analysis. Table 2 outlines the number of second primaries found in the lung, esophagus, larynx, oral cavity, oropharynx, hypopharynx, and other, non–aerodigestive tract sites by each index primary. Of the 528 second primaries overall, 47% were in

TABLE 1. INDIVIDUAL STUDIES USED FOR PREVALENCE

Series	*Re or Pr*	*Year*	*Location*	*Index Tumor Cases*	*Synchronous Second Primaries*	*Metachronous Second Primaries*	*Total Second Primaries*
Weichert and Shumrick[9]	Re	1979	Cincinnati	825	19	35	54 (6.5%)
Vrabec[10]	Re	1979	Pennsylvania	1,518	37	138	175 (11.5%)
Cohn and Peppard[11]*	Re	1980	Michigan	267	25	19	44 (17%)
Shapshay et al[12]	Re	1980	Boston	150	21	7	28 (19%)
Maisel and Vermeersch[13]	Pr	1981	Minnesota	449	36	44	80 (17.8%)
Deviri et al[14]*	Re	1982	Israel	1,660	14	70	84 (5%)
McGuirt[15]†	Pr	1982	North Carolina	100	18	Unknown	Unknown
Black et al[16]	Re	1983	Cincinnati	577	36	85	121 (20.9%)
Black et al[16]	Re	1983	Cincinnati	5,337	270	466	736 (13.8%)
Black et al[16]†	Pr	1983	Cincinnati	645	58	Unknown	Unknown
Hordijk and deJong[17]	Re	1983	Holland	1,148	36	165	201 (17.5%)
Hordijk and deJong[17]†	Pr	1983	Holland	100	2	Unknown	Unknown
Fitzpatrick et al[18]	Re	1984	Toronto	6,203	239	409	648 (10.4%)
Savary (unpublished data)	Re	1984	Lausanne	1,091	92	88	180 (16.5%)
Savary (unpublished data)†	Pr	1984	Lausanne	100	Unknown	19	Unknown*
Leipzig et al[5]†	Re	1985	Colorado	384	34	Unknown	Unknown
DeVries and Snow[19]*	Re	1986	Holland	748	8	96	104 (14%)
Lundgren and Olofsson[20]*	Re	1986	Sweden	295	4	28	32 (10.8%)
Shikhani et al[6]	Re	1986	Baltimore	1,961	89	101	190 (9.7%)
Masaki et al[21]§	Re	1987	Osaka	3,162	37	145	182 (5.8%)
Cooper et al[4]	Re	1989	Multi-institutional (USA)	991	63	110	173 (17.5%)
McDonald et al[22]*	Re	1989	New York	235	7	54	61 (26%)
Panosetti et al[23]	Re	1989	France	9,089	350	480	830 (9.1%)
Larson et al[24]	Re	1990	Minneapolis	875	72	135	207 (24%)
Washington University	Re	1991	St Louis	3,706	96	379	475 (12.8%)

Re — retrospective, Pr — prospective.

*Larynx index tumors only.

†Panendoscopy studies.

§Excludes prior cancers now presenting with head and neck primaries.

the head and neck, 30% at other, distant sites, 20% in the lung, and 3% in the esophagus.

The likelihood of any second primary's being found in the head and neck, when considered by site of index tumor, was 67% for oropharynx, 53% for oral cavity, 43% for hypopharynx, and 30% for larynx. By contrast, the likelihood of any second primary's being a lung cancer by site was almost the reverse, with the highest rate in laryngeal tumors and the lowest in oropharyngeal index cancers, ie, larynx 27%, hypopharynx 23%, oral cavity 17%, and oropharynx 11%. The likelihood of a second primary's being in other, non-aerodigestive tract sites was proportionally highest for larynx, the rank being larynx 40%, oral cavity 26%, hypopharynx 24%, and oropharynx 20%. In this review, esophageal second primaries were uncommon (less than 5%) for any index primary site.

Time Course. These data are summarized in Table 3. Over one third of second primaries, inclusive of simultaneous tumors, have appeared by 1 year from diagnosis of their index tumor. By 2 years from

TABLE 2. SECOND PRIMARY SITE BY INDEX TUMOR IN WASHINGTON UNIVERSITY REGISTRY DATA

Index Tumor	*Lung*	*Esophagus*	*Larynx*	*Oral Cavity*	*Oropharynx*	*Hypopharynx*	*Other*	*Total*
Larynx (N = 1,864)	55	5	19	16	26	1	84	206 (11%)
Oral cavity (N = 728)	21	6	18	18	19	12	33	127 (17.4%)
Oropharynx (N = 523)	13	3	21	20	22	17	24	120 (23%)
Hypopharynx (N = 591)	17	3	5	17	13	2	18	75 (12.7%)
Total (N = 3,706)	106	17	63	71	80	32	159	528 (14.2%)

TABLE 3. TIME TO DEVELOP SECOND PRIMARY IN WASHINGTON UNIVERSITY REGISTRY DATA

Index Tumor	*<6 mo*	*6 mo to 1 y*	*2 y*	*3 y*	*4 y*	*>5 y*	*Total*
Larynx (N = 1,864)	39	27	9	18	16	97	206
Oral cavity (N = 728)	28	26	11	2	11	49	127
Oropharynx (N = 523)	23	13	15	6	13	50	120
Hypopharynx (N = 591)	17	13	4	8	6	27	75
Total (N = 3,706)	107	79	39	34	46	223	528
Cumulative %	20%	35%	42%	49%	58%	100%	100%

diagnosis, slightly more metachronous tumors have appeared than were detected at synchronous endoscopy. However, fully 40% remained to be diagnosed at the 5-year point or beyond. The range, by site, at 2 years for the cumulative rate of second primary development was between 51% for oral cavity tumors and 36% for laryngeal. Oropharyngeal and hypopharyngeal index tumors yielded second primary development rates of 43% and 45%, respectively, at 2 years.

In relating the site of the second primary to time of discovery beyond the index tumor, the following was observed. For head and neck, lung, and especially esophageal second primaries, the majority were detected within 2 to 3 years of the index primary. By contrast, non–aerodigestive tract malignancies were a steadily increasing proportion of the second primaries discovered annually as time extended from the original diagnosis. In the laryngeal index group, other sites comprised 50% of all second primaries found beyond 5 years, but in other index sites they ranged from 14% to 28%.

META-ANALYSIS STUDY

Prevalence. Table 4 summarizes the overall prevalence data. This Table is derived from the 25 studies outlined in Table 1. The highest synchronous rate was in a study by McGuirt,[15] in which prospective panendoscopy by a specialist head and neck surgeon was used for screening. The lowest was in the study of Masaki et al,[21] based on patients treated primarily with radiotherapy in the Department of Radiology, Osaka University Medical School, Osaka, Japan.

Metachronous second primary rates also manifested a wide range of detection. The lowest was a laryngeal index tumor study from Israel.[14] Here the predominant ethnic group was European Jewish immigrants who were followed up for a maximum of 28 years. The highest was in the study of Larson et al,[24] in which a mixed-site group of head and neck cancer patients treated at a Veterans Administration hospital in Minnesota was followed up for a maximum of 15 years.

TABLE 4. META-ANALYSIS: SYNCHRONOUS, METACHRONOUS, AND TOTAL RATES OF SECOND PRIMARY FORMATION

Parameter	*Synchronous*	*Metachronous*	*Overall*
Mean (weighted)	6% (4%)	9.7% (7.6%)	14.2% (11.4%)
Median	4.5%	9.1%	13.8%
Range	0.8% - 18%	4.2% - 23%	5% - 26%
N (studies)	24	22	20
N (patients)	1,677	3,143	40,287

The overall ranges were from 5% in the Israeli study[14] to 26% in the study of Larson et al.[24] Another study with a high detection rate was that of Cooper et al,[4] a Radiation Therapy Oncology Group study that revealed a 23% rate at 8 years. This study was based on a general mix of head and neck cancer patients entered into multi-institutional protocols.

Prospective Panendoscopy Studies. Separate analysis of the five prospective studies conducted either by individuals (four) or across institutions (one) revealed a median yield for second primaries of 9%. When compared with the group median for synchronous second primaries (3.9%), this was statistically significantly higher as measured by a Wilcoxon rank test (p = .04).

Site Analysis. The total numbers and site distribution of second primaries occurring at the four primary index tumor sites (38,856 patients) are summarized in Table 5. Although 25 studies were included, there were 47 instances in those studies in which index sites were clearly related to second primary sites.

Although the total median rates for second primaries at the four index sites were variable, ie, oral cavity 17.3%, oropharynx 13.7%, hypopharynx 13.4%, and larynx 10.9%, the trend toward a higher rate for oral cavity versus other sites only approached significance as assessed by a Wilcoxon rank test (p = .11). However, within sites for laryngeal, hypopharyngeal, and oral cavity index tumors, the different median rates of second primary formation by site (lung, esophagus, head and neck, and other) were statistically significant as judged by a MANOVA test performed on transformed, nonparametric data. In laryngeal primaries, therefore, there were significant differences (p = .0003), with

TABLE 5. SECOND MALIGNANT TUMOR SITE ANALYSIS BY INDEX TUMOR SITE

Index Site	*No. of Studies*	*Index Primaries (Patients)*	*Total Second Primaries*	*Second Primaries by Site*			
				Head and Neck	*Lung*	*Esophagus*	*Other*
Larynx	18	19,159	1,909	337	678	106	788
Oral cavity	13	10,643	1,503	723	250	175	355
Oropharynx	7	4,504	559	291	82	72	114
Hypopharynx	9	4,550	652	266	128	75	183
Total	47	38,856	4,623	1,617	1,138	428	1,440

lung being most common, followed by head and neck and esophagus, among the aerodigestive tract sites (Fig 1). Similarly, for the hypopharynx, there was a significant predominance of head and neck second primaries ($p = .0006$), followed by lung, other, and esophagus. In the oral cavity, the differences were again significant ($p = .02$), with head and neck (median 6.5%) being ahead of lung (3.2%), other (2.5%), and esophagus (1.7%). For oropharyngeal index tumors, there were no significant differences despite an absolute predominance for head and neck (Fig 1).

Figure 2 illustrates the distribution of the 4,623 second primaries according to site of appearance in this mixed head and neck cancer group. The rate differences in the sites of second primary formation within each study's second primary site report, regardless of index tumor, are statistically significant by MANOVA ($p = .0001$). This nonparametric test corrects for different sample sizes by analyzing rate difference *within* studies.

It is also noticeable from Table 5 that the distributions of second primary formation sites varies by index site — eg, in laryngeal cancer, head and neck second primaries comprise 17.7% of all second primaries for the primary site, but in the oral cavity it is 48%, in the oropharynx 52%, and in the hypopharynx 40%. Figure 3 summarizes these relationships by index tumor site. The difference in median rates of formation of head and neck second primaries for each index tumor site is statistically significant ($p = .0001$, Wilcoxon rank test). Significance also holds for second primaries at the esophageal site ($p = .02$), but not for lung ($p = .43$) or other second primary sites ($p = .62$).

There were 12 instances in which the head and neck *subsites* of second primary formation were given in a total of 5,973 laryngeal, 3,237 oral cavity, 2,556 oropharyngeal, and 1,911 hypopharyngeal index tumors. If the primary site is ignored, but we maintain a within-study paradigm, the difference in rates of second primary formation at the four head and neck subsites (oral cavity 1.9%, oropharynx 1.9%, hypopharynx 1.1%, and larynx 0.7%) was statistically significant according to a

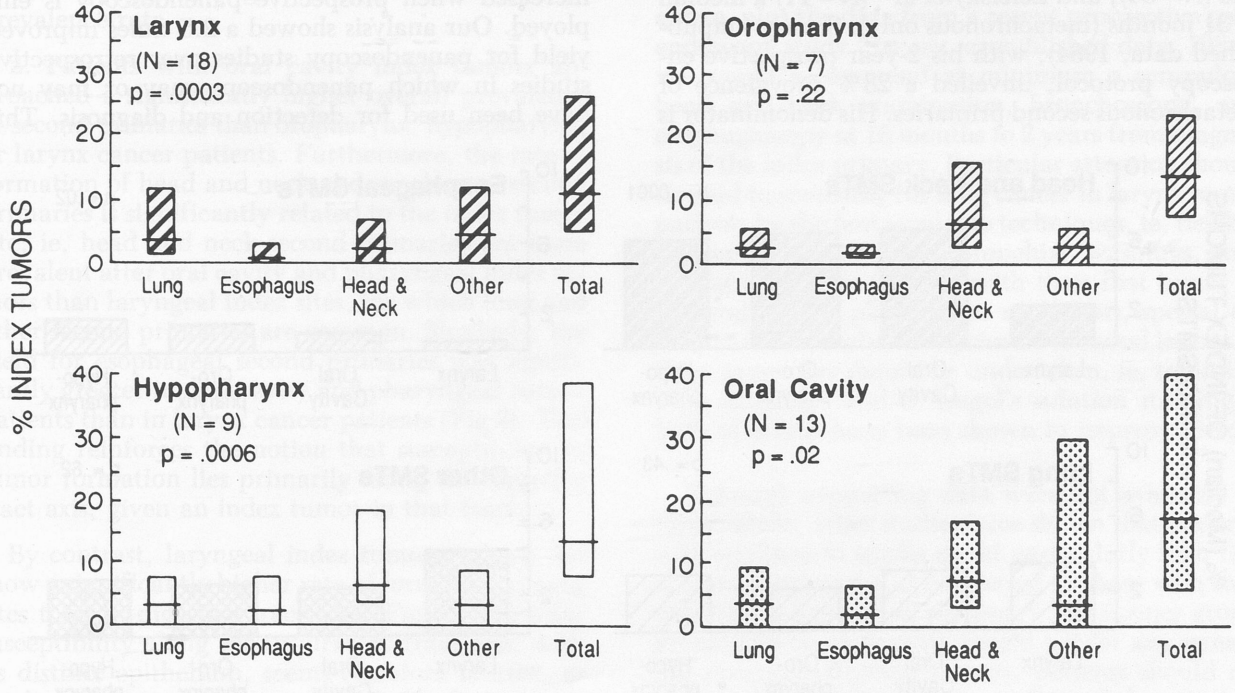

Fig 1. Median percent of index tumors of larynx (18 studies), oropharynx (7 studies), hypopharynx (9 studies), and oral cavity (13 studies) associated with second primaries in lung, esophagus, head and neck, and other, non–aerodigestive tract sites, plus total. Within index sites, rates of second primary formation at different sites are statistically significant for larynx, hypopharynx, and oral cavity.

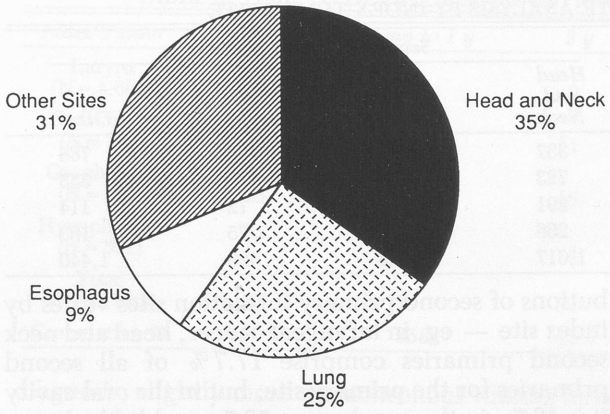

Fig 2. Site distribution (p = .0001) of 4,623 second primaries in 38,856 head and neck cancer patients. Index sites are limited to oral cavity, oropharynx, hypopharynx, and larynx.

MANOVA (p = .0002).

Time Course Data. A summary of the eight studies yielding comparable data regarding intervals to detection for second primaries is found in Table 6.[6,10,11,14,17,25,26] The cumulative range of second primaries appearing by 1 year is 23% to 59% and by 2 years is 30% to 74%. At 5 years or beyond, between 7% and 42% of second primaries remained to be detected.

Other authors reported their time data as follows: Larson et al[3] found a mode of 1.5 years in time to appearance of their 207 second primaries, Weichert and Shumrick[9] a mean of 4 years (8 months to 24 years) for metachronous-only second primaries (N = 54), and Zelefsky et al[27] (N = 11) a median of 31 months (metachronous only). Savary (unpublished data, 1984), with his 2-year prospective endoscopy protocol, unveiled a 28% prevalence of metachronous second primaries. His denominator is the total at-risk population, not the total of second primaries to be discovered in a longitudinal study.

DISCUSSION

Second malignant tumors in head and neck cancer patients carry serious consequences. The reasons include the poor individual prognosis for some sites (lung, esophagus), late diagnosis, and the potential difficulty in applying optimum therapy to two sites at the same time.[4,23,28]

The population at risk for synchronous or metachronous new primaries is "captive," ie, usually accessible for regular evaluation as well as highly selected by virtue of their index tumor formation. The cost-effectiveness, therefore, of screening is likely to be maximal because of an enhanced yield. In addition, the majority of tumors detected by aggressive screening are early-stage (Savary, unpublished data, 1984), and asymptomatic patients in whom tumors are discovered have a significantly better survival than the symptomatic group.[29]

The wide range of reported rates for synchronous, metachronous, and total second primaries and the potential for identifying significant trends to enhance screening selectivity encouraged us to search the literature with a view to meta-analysis of these data. This led to a number of interesting observations.

1. The overall mean prevalence of 14.2% suggests a sufficiently large yield to make screening worthwhile. Furthermore, the yield is significantly increased when prospective panendoscopy is employed. Our analysis showed a 2.5 times improved yield for panendoscopy studies over retrospective studies in which panendoscopy may or may not have been used for detection and diagnosis. This

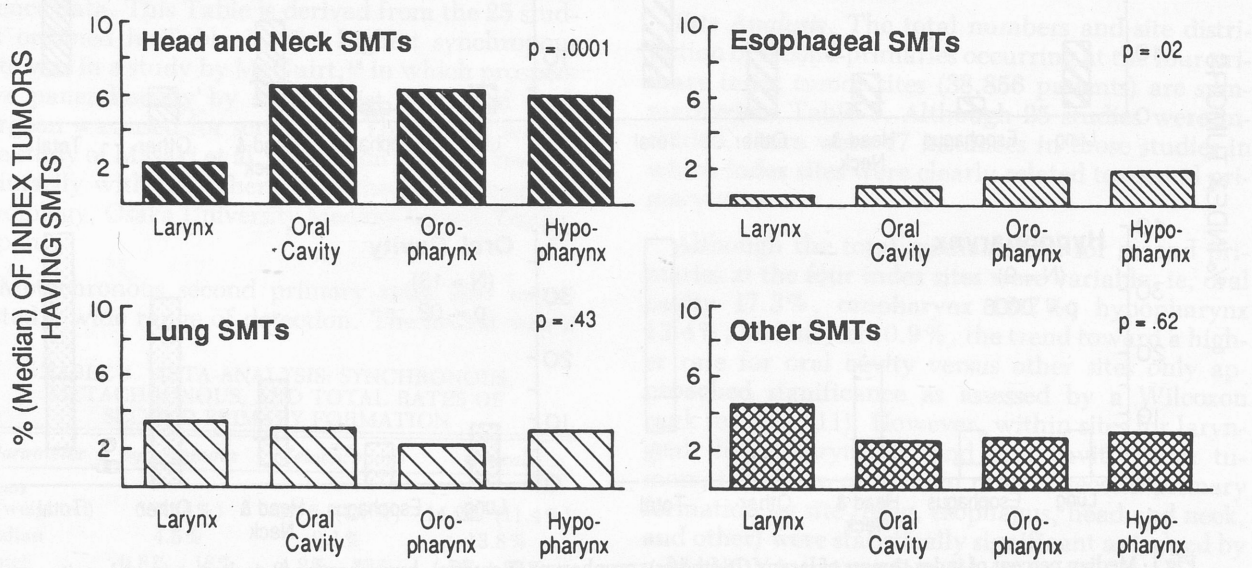

Fig 3. Index tumor site associations with second primaries in head and neck, esophagus, lung, and other, non–aerodigestive tract sites. Differences between index sites are significant for head and neck (p = .0001) and esophageal (p = .02) second primaries. SMTs — second malignant tumors.

TABLE 6. YEARS FROM INDEX TUMOR TO APPEARANCE OF SECOND PRIMARY

Study	*1 y Cumulative*	*2 y Cumulative*	*≥5 y Absolute*
Hordijk and deJong[17] (N = 294)	25%	50%	30%
Vrabec[10]* (N = 114)	45%	60%	22%
Shikhani et al[6] (N = 190)	59%	74%	7%
Parker and Enstrom[25] (N = 39)	44%	62%	15%
Shons and McQuarrie[26]* (N = 52)	25%	48%	23%
Deviri et al[14]† (N = 84)	23%	30%	38%
Cohn and Peppard[11] (N = 47)	57%	72%	11%
Washington University (N = 528)	35%	42%	42%

*Aerodigestive tract only.

†Laryngeal index tumors only.

was proven in synchronous tumors but would apply equally to metachronous. A possible source of bias in the overall prevalence calculation may have been the inclusion of several larynx cancer studies. This index site consistently has been shown to have a lower rate of second primary formation than other head and neck sites. This phenomenon pertains to radiotherapy studies in which the larynx is conserved, as well as surgical studies. This factor, plus the likelihood of a higher yield by prospective management, suggests that the yield for an ongoing screening program might be higher than our mean prevalence rate.

2. Patients with oral cavity index tumors approached a significantly higher overall prevalence of second primaries than oropharynx, hypopharynx, or larynx cancer patients. Furthermore, the rate of formation of head and neck and esophageal second primaries is significantly related to the index tumor site; ie, head and neck second primaries are more prevalent after oral cavity and pharyngeal index tumors than laryngeal index sites, for which lung and other second primaries are common. Similarly, the yield for esophageal second primaries was significantly greater in oral cavity and pharyngeal cancer patients than in larynx cancer patients (Fig 3). This finding reinforces the notion that susceptibility to tumor formation lies primarily along the digestive tract axis, given an index tumor in that tract.

By contrast, laryngeal index tumor patients did show a significantly higher rate of formation at lung sites than at digestive tract sites (Fig 3). A similar susceptibility along the respiratory tract axis, with its distinct epithelium, seems therefore to exist, as has been previously documented.[30] The larynx is also a significantly lower site of second primary formation than other head and neck sites. These site association data on a large number of head and neck cancer patients are an exciting new application of meta-analysis. Formal statistics have shown here a significant trend toward clustering of index and second primaries in the digestive tract. New information on the natural history of head and neck cancer patients, therefore, is made available by analyzing large numbers, whereas individual studies were inconclusive on this question.

3. The majority of series with time course data show that at least half the second primaries have developed by 2 years from treatment of the index primary. Although a significant proportion of patients also form their second primary at 5 years and beyond, especially in laryngeal cancer, these late second primaries seem to be most frequent in non–aerodigestive tract sites. In the Washington University study, however, half of the head and neck primaries were to develop at 5 years or beyond, perhaps because of the long duration of follow-up (up to 30 years). Esophageal second primaries were clustered bimodally at or before 2 years and at or after 5 years. It is noteworthy in the Washington University and other studies that considerably more new malignancies have appeared by 2 years postdiagnosis than were discovered simultaneously with the index tumor — hence the potential importance of a routine "second-look" endoscopy at or near this posttreatment stage. This would not replace, but complement, clinical and radiographic follow-up by virtue of greater sensitivity.

4. Combining the impressions from 1, 2, and 3 above, plus the data from a recent prospective panendoscopy study (Savary, unpublished data, 1984), we would recommend at minimum a scrupulous head and neck examination, bronchoscopy, and esophagoscopy at 18 months to 2 years from diagnosis of the index primary. Particular attention should be paid to screening for lung cancer in larynx tumor patients by the best available techniques, ie, flexible fiberoptic examination, bronchial washings, and radiography. For patients with their first tumor in the oral cavity, pharynx, or esophagus, special efforts to detect early, new primary mucosal lesions in these same sites should be undertaken, ie, toluidine blue staining[31] and/or Lugol's solution staining,[32] both of which have been shown to improve yields.

Although supporting data were not available in this analysis, other studies have shown that patients who continue to smoke are at particularly high risk of second primaries as compared to those who stop smoking or have never smoked.[33] The former group should also be strenuously sought out for any screening program. Beyond 2 years, patients should receive triple endoscopy as indicated by clinical symptoms or signs; but regular follow-up, directed at second primary detection, should continue beyond 5 years.

It is anticipated, on the basis of these findings, that future reporting of data generated by a prospective screening protocol will justify its widespread inception. Furthermore, monitoring of chemoprevention,[4] a promising new therapeutic approach to second primaries, will be facilitated.

ACKNOWLEDGMENT — The authors would like to acknowledge Dr M. Savary, ENT Surgeon, University Hospital in Lausanne, Switzerland, who shared his unpublished data regarding prospective evaluation of second malignancies in head and neck cancer.

REFERENCES

1. Vikram B. Changing patterns of failure in advanced head and neck cancer. Arch Otolaryngol 1984;110:564-5.

2. Hong WK, Bromer RH, Amato DA, et al. Patterns of relapse in locally advanced head and neck cancer patients who achieved complete remission after combined modality therapy. Cancer 1985;56:1242-5.

3. Larson TJ, Adams GL, Fatah HA. Survival statistics for multiple primaries in head and neck cancer. Otolaryngol Head Neck Surg 1990;103:14-24.

4. Cooper JS, Pajak TF, Rubin P, et al. Second malignancies in patients who have head and neck cancer: incidence, effect on survival and implications based on the RTOG experience. Int J Radiat Oncol Biol Phys 1989;17:449-56.

5. Leipzig B, Zellmer JE, Klug D, and The Panendoscopy Study Group. The role of endoscopy in evaluating patients with head and neck cancer. A multi-institutional prospective study. Arch Otolaryngol 1985;111:589-94.

6. Shikhani AH, Matanoski GM, Jones MM, Kashima HK, Johns ME. Multiple primary malignancies in head and neck cancer. Arch Otolaryngol Head Neck Surg 1986;112:1172-9.

7. Warren S, Gates O. Multiple malignant tumors: a survey of literature and statistical study. Am J Cancer 1932;51:1358-414.

8. Berg JW, Schottenfield D, Ritter F. Incidence of multiple primary cancers III. Cancers of the respiratory and upper digestive system as multiple primary cancers. J Natl Cancer Inst 1970; 44:263-74.

9. Weichert KA, Shumrick D. Multiple malignancies in patients with primary carcinomas of the head and neck. Laryngoscope 1979;89:988-91.

10. Vrabec DP. Multiple primary malignancies of the upper aerodigestive system. Ann Otol Rhinol Laryngol 1979;88:846-54.

11. Cohn AM, Peppard SB. Multiple primary malignant tumors of the head and neck. Am J Otolaryngol 1980;1:411-7.

12. Shapshay SM, Hong WK, Fried MP, Sismanis A, Vaughan CW, Strong MS. Simultaneous carcinomas of the esophagus and upper aerodigestive tract. Otolaryngol Head Neck Surg 1980;88: 373-7.

13. Maisel RH, Vermeersch H. Panendoscopy for second primaries in head and neck cancer. Ann Otol Rhinol Laryngol 1981; 90:460-4.

14. Deviri E, Bartal A, Goldsher M, Eliachar I, Steinitz R, Robinson E. Occurrence of additional primary neoplasms in patients with laryngeal carcinoma in Israel (1960-1976). Ann Otol Rhinol Laryngol 1982;91:261-5.

15. McGuirt WF. Panendoscopy as a screening examination for simultaneous primary tumors in head and neck cancer: a prospective sequential study and review of the literature. Laryngoscope 1982;92:569-76.

16. Black RJ, Gluckman JL, Shumrick DA. Multiple primary tumours of the upper aerodigestive tract. Clin Otolaryngol 1983; 8:277-81.

17. Hordijk GJ, deJong JMA. Synchronous and metachronous tumours in patients with head and neck cancer. J Laryngol Otol 1983;97:619-21.

18. Fitzpatrick PJ, Tepperman BS, DeBoer G. Multiple primary squamous cell carcinoma in the upper aerodigestive tract. Int J Radiat Oncol Biol Phys 1984;10:2273-9.

19. DeVries E, Snow CB. Multiple primary tumours in laryngeal cancer. J Laryngol Otol 1986;100:915-8.

20. Lundgren J, Olofsson J. Multiple primary malignancies in patients treated for laryngeal carcinoma. J Otolaryngol 1986;15: 145-50.

21. Masaki N, Hashimoto T, Ikeda H, Inoue T, Kozuka T. Multiple primary malignancies in patients with head and neck cancer. Jpn J Clin Oncol 1987;7:303-7.

22. McDonald S, Haie C, Rubin P, Nelson D, Divers LD. Second malignant tumors in patients with laryngeal carcinoma: diagnosis, treatment, and prevention. Int J Radiat Oncol Biol Phys 1989;17:457-65.

23. Panosetti E, Luboinski B, Mamelle G, Richard J-M. Multiple synchronous and metachronous cancers of the upper aerodigestive tract: a nine-year study. Laryngoscope 1989;99:1267-73.

24. Larson J, Adams G, Abdel H. Survival statistics for multiple primaries in head and neck cancer. Otolaryngol Head Neck Surg 1990;103:14-24.

25. Parker R, Enstrom J. Second primary cancers of the head and neck following treatment of initial primary head and neck cancers. Int J Radiat Oncol Biol Phys 1988;14:561-4.

26. Shons A, McQuarrie D. Multiple primary epidermoid carcinomas of the upper aerodigestive tract. Arch Surg 1985;120: 1007-9.

27. Zelefsky M, Harrison L, Fass D, et al. Postoperative radiotherapy for oral cavity cancers: impact of anatomic subsite on treatment outcome. Head Neck Surg 1990;12:470-5.

28. Gluckman JL, Crissman JD. Survival rates in 548 patients with multiple neoplasms of the upper aerodigestive tract. Laryngoscope 1983;93:71-4.

29. Stalpers LJA, van Viersen PBJ, Brouns JJA, et al. The role of yearly chest radiography in the early detection of lung cancer following oral cancer. Int J Oral Maxillofac Surg 1989;18:99-103.

30. Strigenz MA, Toohill RJ, Grossman TW. Association of laryngeal and pulmonary malignancies: a continuing challenge. Ann Otol Rhinol Laryngol 1987;96:621-4.

31. Mashberg A. Re-evaluation of toluidine blue application as a diagnostic adjunct in the detection of asymptomatic oral squamous cell carcinoma. Cancer 1980;46:758-63.

32. Shiozaki H, Tahara H, Kobayashi K, et al. Endoscopic screening of early esophageal cancer with the Lugol dye method in patients with head and neck cancers. Cancer 1990;66:2068-71.

33. Silverman S Jr, Greenspan D, Gorsky M. Tobacco usage in patients with head and neck carcinomas: a follow-up study on habit changes and second primary oral/oropharyngeal cancers. J Am Dent Assoc 1983;106:33-5.

HEAD AND NECK SURVEILLANCE PROGRAM FOR FACTORY PERSONNEL EXPOSED TO ASBESTOS

STEVEN M. PARNES, MD MALCOLM SHERMAN, PHD

ALBANY, NEW YORK

Personnel at a local factory that manufactures brake linings and discs in which asbestos is a major component were requested to participate in an on-site surveillance program to detect head and neck abnormalities, specifically cancer. Demographic data included smoking histories and job descriptions that could be delineated into high- and low-asbestos exposure groups. In the first year, 322 factory workers had no cancer identified but 15% had laryngeal abnormalities, mostly laryngitis. Ninety-seven percent of those workers with abnormal findings were smokers, but there were a significant number in the high-asbestos group irrespective of smoking histories. From this report, high-risk individuals were identified and requested to continue in the program for monitoring. In the subsequent 3 years, these individuals and new personnel were examined. Similar results were obtained in that laryngitis was noted in 24% (95% of whom were smokers) with a stronger statistical association with the high-asbestos group. More important, one person previously identified as high-risk was noted to have stage I squamous cell carcinoma and was treated with radiotherapy. The results of this program suggest that individuals at high risk for the development of head and neck cancer can be identified and that such surveillance programs should be implemented in similar arenas.

KEY WORDS — asbestos, head and neck cancer, surveillance programs.

INTRODUCTION

Exposure to asbestos evokes a morbid fear of cancer and permanent disability. There has been an explosive growth of asbestos identification and removal companies as a result of the mandate by the Environmental Protection Agency and the Asbestos Hazard Emergency Response Act. To comply with these regulations will cost industry and the public approximately $53 billion and perhaps as high as $100 to $150 billion.[1] Despite these policies, the exact risk of disease from this exposure remains unclear.

It has been well established that in workers having direct contact with asbestos, there is an increased occurrence of diseases, particularly cancer of the lung, mesothelioma, and asbestosis.[2-8] The relationship of cancer of the larynx to asbestos exposure remains extremely controversial. There have been a number of studies on this subject with extensive review of data from the literature. In evaluating the same data bases and cohort studies, the authors have reported conflicting results and interpretations.[9-16] This is due in part to the fact that cancer of the larynx has a relatively small fatality rate in contrast to lung cancer; thus, the large-cohort mortality studies do not provide a satisfactory way of investigating this entity. The advantage is, however, that the types of fibers and degree of exposure in terms of duration are known. Unfortunately, smoking and drinking habits have often been omitted. As an alternative, the case control studies have been more attractive, since they focus on laryngeal cancer. However, they also suffer from potential difficulties, since precise exposure histories are lacking and there is the investigators' potential bias to the patient population they are evaluating. The type of asbestos can be critical, since a preponderance of evidence seems to point to the increased risks and hazards associated with the amphibole type of asbestos as compared to the far more prevalent chrysotile type.

There have been a few studies[16-18] in which the investigators used cross-sectional methods to examine the individuals at risk from asbestos exposure. Two studies[16,18] performed on-site head and neck examinations to determine the effects of asbestos on the head and neck areas. Both reported similar findings. The workers with high asbestos exposure had significantly increased findings of alterations in the laryngeal mucosa, but in neither case was carcinoma of the larynx identified.

This investigation and a previous one[16] were motivated by the discovery of three cases of cancer of the larynx over a period of 10 years among the employees in a single plant that uses asbestos. Initially, a large number of personnel were noted to have laryngeal disease, mostly laryngitis, which had a significant association with exposure to asbestos. This study represents a 3-year follow-up with continued monitoring of individuals who were initially considered at high risk. It further evaluates the relationship between exposure to asbestos and laryngitis.

METHOD

A head and neck surveillance program was de-

From the Division of Otolaryngology–Head and Neck Surgery, The Albany Medical College (Parnes), and the Department of Biometry and Statistics–School of Public Health, State University of New York at Albany (Sherman), Albany, New York. Supported by a grant from Allied Chemical, Inc.

Presented at the meeting of the American Laryngological Association, Waikoloa, Hawaii, May 4-5, 1991.

REPRINTS — Steven M. Parnes, MD, Division of Otolaryngology–Head and Neck Surgery, A-41, The Albany Medical College, 47 New Scotland Ave, Albany, NY 12208.

signed and implemented for a local factory that manufactures brake linings and discs in which chrysotile asbestos is a major component. Data were obtained from the safety personnel regarding various levels of asbestos at different locations. In addition, information from safety reports regarding other potential contaminants was obtained. Occupations were categorized as low-risk (less than 0.1 fiber per cubic centimeter) and high-risk (greater than or equal to 0.1 fiber per cubic centimeter). These categories were dependent upon location within the building as well as peculiarities of the individual occupation. In general, low-risk exposure included all office workers, executives, and professional employees who had minimal contact with the asbestos and are comparable to the normal population. All other personnel (those who worked in the building in which asbestos was prevalent) were identified as the high-risk group. Initially, the program was made available to all personnel on a volunteer basis. The senior author approached the factory workers through formal presentations to indicate the purpose and logistics of the program, particularly in reference to early detection of cancer of the head and the larynx. Of the approximately 500 employees, 322 (65%) agreed to the examination and signed formal consent forms to participate in the study. Each individual had a complete head and neck examination, including the nose, oral cavity, oropharynx, nasal pharynx, larynx, and neck, performed by the senior author (90%) or other otolaryngologists. Just prior to each examination, the individual filled out a questionnaire designed to elicit the following symptoms: hemoptysis, dysphagia, loss of weight, neck mass, cough, and hoarseness. Also obtained were smoking and alcohol histories, occupation, date of birth, sex, race, and length of employment. Any positive responses were discussed during the head and neck examination. This information was tabulated and incorporated into a data base on a personal computer and has been previously reported.[16] Through analysis of the original data, high-risk groups were identified. These included all subjects with positive findings and alterations of laryngeal mucosa as well as those who were smokers. These individuals were then requested to participate in continued monitoring in the subsequent 2 years. New personnel were also permitted to participate. These results were also tabulated and then analyzed independently and in combination with the original reported series.

STATISTICAL ANALYSIS

Observed incidence of laryngitis or other laryngeal disease was related to asbestos exposure, allowing for the effects of smoking and checking on the relevance of other potential explanatory factors, including alcohol use, age, race, sex, and employment years. Data were analyzed with SAS software on a mainframe computer.

The potential relationship between probability of laryngitis and asbestos was investigated by means of a standard logit model to relate probability p of laryngitis, and a quantified measure of smoking, asbestos exposure, and some other factors, including age and years of working at the plant. Logit (p) is defined as the natural logarithm of the odds ratio $(p/1-p)$, which is assumed to be a linear function of other variables. Thus, one model investigated is

$$\text{Logit (p)} = \log p/1-p = A + B \times \text{smoking index} + C \times \text{asbestos level} \quad (1)$$

If the fitted values of B and C are positive and if the probability that the true values are zero or negative can be ruled out statistically, then the model states that as smoking increases, so does the incidence of laryngitis and there is a greater probability of laryngitis at asbestos level 1 (high exposure) than at level zero (low exposure). Since the subjects studied were selected precisely because of presumed elevated risk, the overall incidence of laryngitis should be higher than it would be for all workers at this type of plant. Even though the value of the constant A is presumably greater than for a sample of all workers in the plant, the constants B and C should still indicate the magnitude of the effect of smoking and the magnitude of the effect, if any, associated with asbestos exposure.

A variable, smoking index (Smkindex), is used as a measure of smoking risk in the present study. It is defined in terms of two other variables, lifetime pack-years (PY) and years elapsed since smoking was given up (NS). Thus, if a subject smoked 1.5 packs per day for 20 years but gave up smoking 5 years before the examination, the value of PY would be $30 = 20 \times 1.5$ and NS = 5. Smoking index (Smkindex) is defined as PY times an attenuation factor that reduces risk for persons who gave up smoking. The actual formula is

$$\text{Smkindex} = \text{PY} \exp[-2\,\text{NS}/(\text{PY} + 2\text{NS})] \quad (2)$$

($\text{Exp}[a] = e^a$, where $e = 2.71828$ is the base of natural logarithms.) Thus, in the example, $\text{Smkindex} = 30 \exp[-10/(30+10)] = 30 \times 0.779 = 23.4$. For someone who smoked briefly and gave up smoking long ago, the attenuation factor will be not much more than about $e^{-1} = 0.368$, so that such a person has the same risk factor as a present smoker who had smoked only about 40% as much. The attenuation factor is, of course, equal to 1 for current smokers. For nonsmokers, Smkindex is equal to zero. For those who smoke cigars or a pipe but not cigarettes, PY is defined as one tenth the product of the number of years of smoking times either the number of cigars per day or the number of times per day the pipe is smoked.

RESULTS

There were 212 employees who participated in

TABLE 1. PERSONNEL

Asbestos Exposure	*No. of Cases*	*Smokers*	*Laryngitis*	*% With Laryngitis Who Smoked*
High	144	122	43	98
Low	96	48	14	86
Total	240	170	57	95

the follow-up examination, 63 of whom had been examined previously, and 28 were subsequently seen twice. One hundred seventy-five examinations took place between November 1987 and February 1988, while the remaining 65 were conducted in January and February 1990. The participants ranged in age from 22 to 66 (average, 43), with 210 men and 170 smokers (66 had quit). As noted in Table 1, 43 of the 144 employees in the high-exposure group had laryngitis, of whom 98% smoked. In the low-asbestos exposure group (96), there were 14 patients who had laryngitis, of whom 86% smoked.

Normal examination results were noted in 123 employees (51%) (Table 2). There were 139 abnormalities noted, of which the most common was deviated nasal septum (60 cases or 25%), followed by laryngitis defined by either erythema or edema (57 cases or 24%), one of which proved to be a squamous cell carcinoma. Three employees required some type of operative intervention. One was a direct laryngoscopy and biopsy and, as noted, the lesion proved to be a stage I squamous cell carcinoma of the larynx. This patient received full-course irradiation and remains disease-free after 1 year. The second had a neck node biopsy that showed the node to be benign and the third had removal of a lesion of the oral cavity, pathologically demonstrating a papilloma.

The incidence of laryngitis was then analyzed in reference to the low- and high-asbestos groups with smoking accounted for (Table 3). At both levels, the number of cases of laryngitis increased with smoking, although the effect is much clearer at the higher-asbestos level. Smoking exposure is defined as none for nonsmokers, low for those in whom the Smkindex is between 0 and 15, medium for those from whom the Smkindex is between 15 and 35, and high for those from whom the Smkindex is above 35. The statistical analysis was based on 212 employees, using data for the second visit on the 28 that were examined twice. The Smkindex was found to have a higher correlation with laryngitis than did PY.

If the logit curves for the low- and high-asbestos groups are parallel, fitted values for the model give the following formula.

$$\text{Logit (p)} = -2.4105 + 0.90304 \text{ x (asbestos)} + 0.03281 \text{ x (Smkindex)} \quad (3)$$

The coefficient of Smkindex is highly significant (p = .0018). Similarly, the coefficient of asbestos

TABLE 2. PHYSICAL EXAMINATION RESULTS

	No. of Cases	*% of Patients*
Normal	123	51.0
Deviated nasal septum	60	25.0
Laryngitis	57	24.0
Neck node or mass	5	2.1
Carcinoma of larynx	1	0.4
Other	16	6.6

was significant, with a p value of .024. The fact that the coefficient of asbestos groups is not zero means that there are differences in probability of laryngitis that are associated with asbestos level (and not, for example, with any tendency for the group with greater asbestos exposure to smoke more). These estimates have a high substantial margin of sampling error, and it is probably not likely that the curves behave in a parallel manner, but rather that the high- and low-asbestos populations do differ significantly with respect to asbestos, even taking smoking into account. The model then is determined separately for each group. The formula for the low group would be

$$\text{Logit (p)} = -2.2333 + .02168 \text{ x (Smkindex)} \quad (4)$$

The formula for the high group would be

$$\text{Logit (p)} = -1.6047 + .03829 \text{ x (Smkindex)} \quad (5)$$

In the low-asbestos group, the coefficient of Smkindex is not statistically different from zero (p = .247). Among the high group the coefficient is highly significant (p = .0034) (Fig 1). According to this model, a nonsmoker in the low group has an odds ratio for laryngitis of 0.110, which corresponds to a probability of .099, while a nonsmoker in the high group has an odds ratio of 0.187 and a probability of .158. Thus, in this model asbestos is associated with higher risk — a risk difference that increases with increasing levels of smoking and probably invalidates the assumption that the logits were parallel (ie, that the difference in logs of odds ratio was independent from smoking).

TABLE 3. INCIDENCE OF LARYNGITIS BY ASBESTOS EXPOSURE AND SMOKING

Asbestos Level	*Smoke Exposure*	*Normal*	*Laryngitis*	*Total*
Low	None	42	2	44
	Low	11	2	13
	Medium	11	5	16
	High	9	2	11
	Total	73	11	84
High	None	19	1	20
	Low	44	12	56
	Medium	24	17	41
	High	6	5	11
	Total	93	35	128
Total	None	61	3	64
	Low	55	14	69
	Medium	35	22	57
	High	15	7	22
	Total	166	46	212

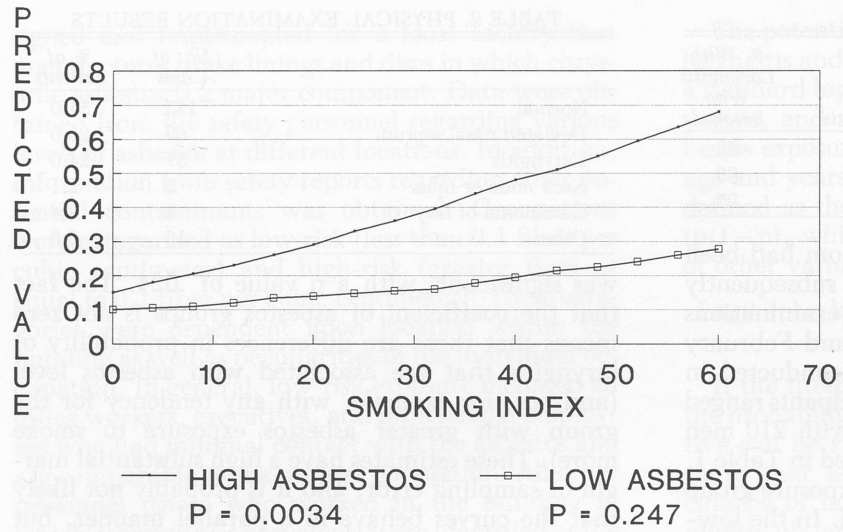

Fig 1. Probability of laryngitis at two asbestos levels (new data).

A similar pattern emerges from combining this data base with that from the previously reported study.[16] A total of 467 individuals were examined, with a total of 562 encounters. A tabulation of the incidence of laryngitis, asbestos exposure, and smoking appears in Table 4. There was an overall incidence of laryngitis of 19 of 240 in the low-asbestos group and 43 of 227 in the high-asbestos group. The fitted values for this model gave the following formula for the low group.

$$\text{Logit}(p) = -2.7289 + .01868 \times (\text{Smkindex}) \quad (6)$$

In the high-exposure group the formula was

$$\text{Logit}(p) = -2.2303 + .040837 \times (\text{Smkindex}) \quad (7)$$

The coefficient for Smkindex is not statistically different from zero in the low group ($p = .130$), while it is highly significant ($p = .0001$) in the high group (Fig 2). Thus, there exists a significant positive association of asbestos level with laryngitis, accounting for relatively large changes in the observed incidence of laryngitis.

One other interesting finding was the difference in laryngitis between men and women. Of the 29 women most recently examined, 15 were in the low-asbestos group and 14 in the high-asbestos group. Only 1 had laryngitis, while 25% of the men had laryngitis. While the women were a bit younger and somewhat less likely to smoke, these differences were not large enough to explain a disparity of this magnitude. The single woman with laryngitis smoked an average of one pack a day for the previous 7 years and did work in the high-exposure group for less than 1 year. While the sample sizes for women were too small to give reliable correlations, the evidence as a whole suggests the possibility that associations between asbestos and laryngitis may differ for men and women.

DISCUSSION

Asbestos is a broad commercial term for a group of naturally occurring hydrated silicates that crystallize into a fibrous form. The family of asbestos minerals can be subdivided into serpentine and amphibole fibers. Chrysotile, a serpentine type, is the most common asbestos fiber, accounting for 90% of the world's production, whereas the amphibole is a diverse group of less industrially important minerals including crocidolite, amosite, anthophyllite, actinolite, and tremolite asbestos.[15] In this factory in which this head and neck surveillance occurred, chrysotile was the only type of asbestos used. There are other chemicals in the plant, but according to the safety personnel, these were all within safety standards set by the Occupational Safety and Health Administration. It is extremely important to distinguish among the different types of asbestos, since mortality appears to be highest among those workers who work with amphibole alone, lower for those who work with mixtures, and lower still among those who work with chrysotile alone.[15,19,20]

One factory worker, a heavy smoker, was found to have a stage I carcinoma of the larynx. No con-

TABLE 4. INCIDENCE OF LARYNGITIS BY ASBESTOS EXPOSURE AND SMOKING (COMBINED DATA)

Asbestos Level	*Smoke Exposure*	*Normal*	*Laryngitis*	*Total*
Low	None	84	3	87
	Low	64	4	68
	Medium	47	9	56
	High	26	3	29
	Total	221	19	240
High	None	43	1	44
	Low	70	12	82
	Medium	49	21	70
	High	22	9	31
	Total	184	43	227
Total	None	127	4	131
	Low	134	16	150
	Medium	96	30	126
	High	48	12	60
	Total	405	62	467

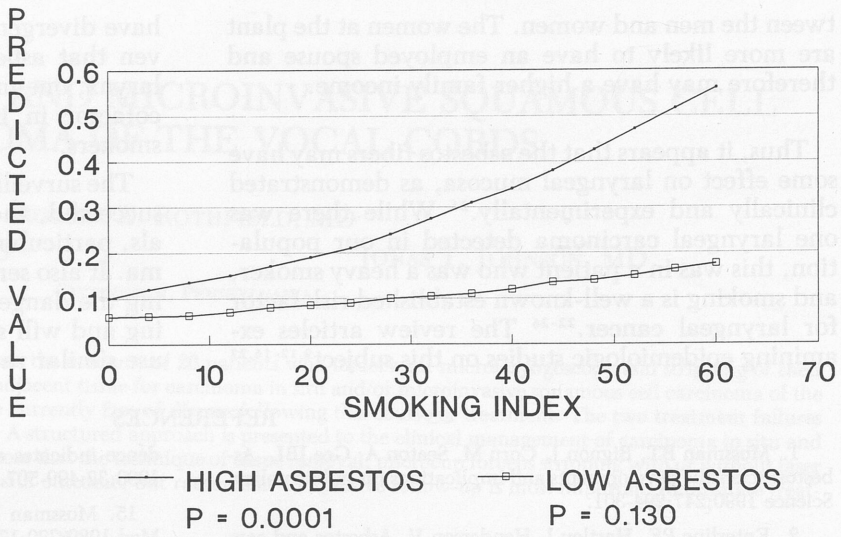

Fig 2. Probability of laryngitis at two asbestos levels (combined data).

clusions can be inferred from this one case. In one study,[21] human laryngeal carcinoma cells were exposed to small chrysotile asbestos fibers. These fibers did penetrate the cell's cytosome and were translocated in proximity to the nucleus. They could also be found inside the nucleus of the interface cells. Findings suggested that after fiber penetration, a rearrangement of the cytoskeletal apparatus did occur and thus can play a role in asbestos intercytoplasmic translocation in epithelial cells. The data also suggested an interaction occurring between the asbestos fibers in the normal mitotic process. Perhaps the disturbance of the cell cytoskeleton causing morphologic contact between asbestos fibers and the cell's nuclear region was important in explaining the carcinogenic effects of the asbestos mineral fibers.

This report also demonstrates that of the employees in this factory, personnel in the high-asbestos group had a significant increase in laryngitis. This statistically significant positive association, however, is weaker than that demonstrated between smoking and laryngitis. Even if asbestos is a cause of laryngitis, it would appear to be a weak cause among nonsmokers. Several years ago, substantial reductions in asbestos level were achieved in the plant, so that even if past asbestos levels are a factor in the present incidence of laryngitis, it does not follow that further reductions in asbestos would reduce the future incidence of laryngitis. It should be emphasized that if asbestos exposure is a contributing cause of laryngitis, it does not follow that asbestos is a cause of cancer of the larynx. A statistical association does not prove the existence of a causal relationship. The present investigation is an observational study, which means that observed associations may be due to uncontrollable confounding factors. To effectively eliminate this possibility would require that subjects be randomly assigned to work in high- or low-asbestos areas, which in this case would not be feasible. In addition, the observed statistical relationship noted may well result from confounding of asbestos exposure with other sociologic or physical factors. High-exposure jobs are factory jobs, while most of the low-exposure jobs are office jobs. There could well be off-the-job behavioral differences among these occupational groups that are related to laryngitis. For example, it is possible that factory workers drink more hard liquor and beer than office workers. Alcohol use has been found in numerous studies to act as a throat irritant. In the earlier study,[16] workers were asked about alcohol consumption, but self-reported alcohol usage did not appear to be related to the incidence of laryngitis. However, it seems most likely that workers would be hesitant to report large, off-the-job alcohol consumption to an examining doctor whose investigation is sponsored by the employer. Although the literature suggests that alcohol should be a cause of laryngitis and of other throat irritations, a failure to detect a relationship between alcohol and laryngitis is probably due to the tendency of workers to deny or minimize their drinking.

There could be differences in work air quality that are unrelated to asbestos that account for the differences in laryngitis between factory workers and office workers. While air quality at the plant is now quite good, even the cleanest factory is presumably dustier than an office. There might also be differences in ambient noise levels between factory jobs and office jobs so that factory workers are more likely to strain their voices in conversation. Such differences might contribute to the observed incidence of laryngitis among factory workers.

The noted difference between sexes is difficult to explain. The asbestos may be confounded with other causes, or perhaps one can speculate on the possible causes of such sex disparity. For example, alcohol consumption could be an important factor, since men tend to drink more than women. There may also be other socioeconomic differences be-

tween the men and women. The women at the plant are more likely to have an employed spouse and therefore may have a higher family income.

Thus, it appears that the asbestos fibers may have some effect on laryngeal mucosa, as demonstrated clinically and experimentally.[21] While there was one laryngeal carcinoma detected in our population, this was in a patient who was a heavy smoker, and smoking is a well-known established risk factor for laryngeal cancer.[22-26] The review articles examining epidemiologic studies on this subject[9,12-16,27] have divergent conclusions. Although it is not proven that asbestos exposure leads to cancer of the larynx, one must be concerned that it may act as a cofactor in individuals already at high risk, ie, smokers.

The surveillance program in this plant has proven successful, then, in identifying high-risk individuals, particularly the employee with stage I carcinoma. It also served to educate the personnel concerning the dangers of smoking. This program is ongoing and will serve as a model for other plants that use similar raw materials.

REFERENCES

1. Mossman BT, Bignon J, Corn M, Seaton A, Gee JBL. Asbestos: scientific developments and implications for public policy. Science 1990;247:294-301.

2. Enterline PE, Hartley J, Henderson V. Asbestos and cancer: a cohort followed up to death. Br J Ind Med 1987;44:396-401.

3. Peto J, Doll R, Hermon C, Binns W, Clayton R, Goffe T. Relationship of mortality to measures of environmental asbestos pollution in an asbestos textile factory. Ann Occup Hyg 1985;29: 305-55.

4. Liddell FDK, Thomas DC, Gibbs GW, McDonald JC. Fibre exposure and mortality from pneumoconiosis, respiratory and abdominal malignancies and chrysotile production in Quebec, 1926-75. Ann Acad Med Singapore 1984;13:340-4.

5. Hüskonen MS. Asbestos and cancer. Eur J Respir Dis [Suppl] 1982;63(suppl 123):145-52.

6. Finkelstein MM. Mortality rates among employees potentially exposed to chrysotile asbestos at two automotive parts factories. Can Med Assoc 1989;141:125-30.

7. Armstrong BK, De Klerc NH, Musk AW, Hobbs MST. Mortality in miners and millers of crocidolite in western Australia. Br J Ind Med 1988;45:5-13.

8. McDonald A, Fry J, Wooley A, McDonald J. Dust exposure and mortality in an American chrysotile textile plant. Br J Ind Med 1983;40:361-7.

9. Liddell FDK. Laryngeal cancer and asbestos. Br J Ind Med 1990;47:289-91.

10. Kern DG, Christiani DG, Kelsey KT, et al. Letter to editor. N Engl J Med 1991;324:195-6.

11. Mossman BT, Gee J. Letter to editor. N Engl J Med 1991; 324:196-7.

12. Chan K, Gee J. Exposure and laryngeal cancer: an analysis of the epidemiological evidence. J Occup Med 1988;30:23-7.

13. Edelman DA. Laryngeal cancer and occupational exposure to asbestos. Int Arch Occup Environ Health 1989;61:223-7.

14. Smith AH, Handley MA, Wood R. Epidemiological evidence indicates asbestos causes laryngeal cancer. J Occup Med 1990;32:499-507.

15. Mossman BT, Gee J. Asbestos related diseases. N Engl J Med 1989;320:1721-30.

16. Parnes SM. Asbestos and cancer of the larynx: is there a relationship? Laryngoscope 1990;100:254-60.

17. Lillis R, Daum S, Anderson H, Sirota M, Andrews G, Selikoff I. Asbestos disease in maintenance workers in the chemical industry. Ann NY Acad Sci 1979;330:127-35.

18. Kambic V, Radsell Z, Gale N. Alterations in the laryngeal mucosa after exposure to asbestos. Br J Ind Med 1989;46:717-23.

19. McDonald JC. Epidemiology of malignant mesothelioma. In: Mantmin K, Aisner J, eds. Asbestos related malignancy. Orlando, Fla: Grune & Stratton, 1987:31-56.

20. Churg A, Wiggs B. Fiber size and number of workers exposed to processed chrysotile asbestos, chrysotile miners and the general population. Am J Ind Med 1986;9:143-52.

21. Mallorni W, Iosi F, Falchi N, Donelli G. On the mechanism of cell internalization of chrysotile fibres: immunocytal chemical and ultrastructural study. Environ Res 1990;52:164-77.

22. Maier H, Deitz A, Zielinski D, Junemann K, Heller W. Risk factors associated with squamous epitheliomas of the mouth, oropharynx, hypopharynx and larynx. Dtsch Med Wochenschr 1990;115:843-50.

23. Cann CI, Fried MP. Determinants and prognosis of laryngeal cancer. Otolaryngol Clin North Am 1984;17:139-50.

24. Decker J, Goldstein JC. Current concepts in otolaryngology: risk factors in head and neck cancer. N Engl J Med 1982;306: 1151-5.

25. Rothman KJ. Epidemiology of head and neck cancer. Laryngoscope 1978;88:435-8.

26. Wynder EL, Bross IJ, Day E. A study of environmental factors in cancer of the larynx. Cancer 1956;9:86-110.

27. Cowles SR. Cancer of the larynx: occupational and environmental associations. South Med J 1983;76:894-8.

CARCINOMA IN SITU AND MICROINVASIVE SQUAMOUS CELL CARCINOMA OF THE VOCAL CORDS

ROBERT E. ROTHFIELD, MD
EUGENE N. MYERS, MD JONAS T. JOHNSON, MD
PITTSBURGH, PENNSYLVANIA

A retrospective study was undertaken to assess the outcome of 20 patients who underwent microlaryngoscopy and stripping of their vocal cord(s) with and without laser ablation of adjacent tissue for carcinoma in situ and/or microinvasive squamous cell carcinoma of the glottic larynx. Eighteen of 20 (90%) patients are currently free of disease following this course of treatment. The two treatment failures were in patients who had been lost to follow-up. A structured approach is presented to the clinical management of carcinoma in situ and microinvasive squamous cell carcinoma. We propose that the technique of tissue removal, microcup forceps stripping with or without laser ablation, is not the critical determinant of successful outcome, but rather that compulsive follow-up is most important to ultimate treatment success.

KEY WORDS — carcinoma in situ, squamous cell carcinoma, vocal cords.

INTRODUCTION

Carcinoma in situ and microinvasive squamous cell carcinoma (SCCA) of the vocal cords have generated much discussion in the last quarter century. As the biologic nature of these lesions has become better understood, their management has evolved. Yet, because these relatively infrequent lesions are initially treated successfully with a multitude of ablative techniques, including vocal cord stripping, laser excision, and radiotherapy, the best approach to their management is often not clear.

A retrospective study was undertaken to assess the outcome in 20 patients who underwent microlaryngoscopy and stripping of their vocal cord(s) with and without laser ablation of adjacent tissue for carcinoma in situ and/or microinvasive SCCA of the glottic larynx. On the basis of the experience at our institution with this spectrum of disease, we propose that the technique of tissue removal, microcup forceps stripping with or without laser ablation, is not the critical determinant of successful outcome, but rather that compulsive follow-up is most important to long-term treatment success. In addition, a structured approach is presented for the clinical management of carcinoma in situ and microinvasive SCCA.

PATIENTS, METHODS, AND MATERIALS

The medical charts of patients who had undergone microlaryngoscopy at the Eye and Ear Hospital of Pittsburgh between January 1, 1983, and December 31, 1987, were reviewed. The study population consisted of those patients with the diagnosis of carcinoma in situ or microinvasive SCCA of the glottis.

Carcinoma in situ was defined as the presence of full-thickness epithelial disarray and atypia associated with an intact basement membrane. Microinvasive SCCA was defined as full-thickness epithelial disarray and atypia associated with discrete foci of invasion through the basement membrane.

Standard suspension laryngoscopy was performed by using either Jako or Dedo wide-bore laryngoscopes. Microcup forceps were used to strip the mucosa off the vocal fold, leaving the underlying vocalis muscle undisturbed. If adjacent mucosa or underlying muscle was suspect for superficial invasion, the carbon dioxide laser was employed to vaporize these areas.

RESULTS

Two hundred fifty-seven patients were identified who had undergone microlaryngoscopy during the course of the study period. Diagnoses of glottic carcinoma in situ in 13 patients and glottic microinvasive SCCA in 7 patients were determined. Follow-up ranged from 27.3 months to 69.3 months, with an average of 46.9 months. Sixteen patients were men and 4 were women.

Eighteen of 20 patients (90%) were treated endoscopically with ultimate disease control. The laser was used in 12 of 20 patients. Two patients developed invasive SCCA, both of whom were lost to follow-up after biopsy-proven disease-free intervals of 16 and 28 months. One patient developed a contralateral T1 SCCA 64 months after his initial presentation with carcinoma in situ and was treated with radiotherapy. The other patient developed an ipsilateral T3 SCCA 65 months after his initial presentation with carcinoma in situ and was suc-

From the Department of Otolaryngology (all authors) and the Division of Head and Neck Oncology and Immunology (Johnson), University of Pittsburgh School of Medicine, Pittsburgh, Pennsylvania.

Presented at the meeting of the American Laryngological Association, Waikoloa, Hawaii, May 4-5, 1991.

REPRINTS — Eugene N. Myers, MD, Dept of Otolaryngology, Eye and Ear Institute, Suite 500, 203 Lothrop St, Pittsburgh, PA 15213.

cessfully salvaged with a total laryngectomy. The laser was not used in the treatment of either patient.

Recurrent carcinoma in situ or microinvasive SCCA developed in an additional four patients after a biopsy-proven minimum disease-free interval of 22 months. Two patients developed ipsilateral recurrence and two patients developed contralateral recurrence. The laser was used in the endoscopic treatment of all four patients. All four patients remain free of disease after further endoscopic treatment.

The time interval between the biopsy-proven absence of carcinoma in situ or microinvasive SCCA and the development of recurrent carcinoma in situ, microinvasive SCCA, or invasive SCCA ranged between 22 and 37 months, with an average of 29 months. The average number of procedures required by patients following the initial microlaryngoscopy was 2.25, with a range of 1 to 5. Nineteen of 20 patients were smokers, with an average tobacco-smoking history of 43.6 pack-years.

DISCUSSION

Great strides have been made in understanding the biology of carcinoma in situ and microinvasive SCCA over the last 20 years. Following the 1974 Centennial Conference on Laryngeal Cancer, a general consensus was agreed upon as to the basic histologic definitions of carcinoma in situ and microinvasive SCCA.[1] However, as Barnes[2] has noted, because of the marked subjectivity in interpreting vocal cord biopsies, the diagnosis is often not straightforward. This has led to incidences of isolated glottic carcinoma in situ and microinvasive SCCA that vary anywhere between 1% and 13% of all laryngeal carcinomas.[2] Our incidence of 6% (20 of 330) falls within the range of reported values.[3-6] As such, isolated glottic carcinoma in situ and microinvasive SCCA are relatively rare lesions.

With the recognition of carcinoma in situ and microinvasive SCCA as distinct entities along a spectrum of diseases, ranging between dysplasia and invasive SCCA, treatment programs have matured. Open neck procedures, and to a lesser extent radiotherapy, have largely given way to endoscopic techniques to control isolated glottic carcinoma in situ and microinvasive SCCA. The varied endoscopic methods have been embraced not only because they offer good control of disease while preserving voice, but because, just as important, they do not preclude further treatment options. As early as 1960, McCabe and Magielski[7] advocated the efficacy of limited laryngoscopic techniques. The studies of Fisher and Miller[8] and Miller[9] over a 25-year period also demonstrated that endoscopic procedures could be used with good success in isolated vocal cord carcinoma in situ. These studies also highlighted the potentially serious nature of the disease, as more than 10% of those patients treated endoscopically went on to develop invasive SCCA. Som[10] further elucidated the management of carcinoma in situ by using repeated vocal cord strippings successfully in 20 of 24 patients. The same technique was similarly employed by Bailey[11] with success in 22 of 25 patients with microinvasive SCCA. DeSanto,[3] while recognizing the utility of vocal cord stripping, pointed out that the term was often a misnomer, when in fact the procedure might also have included cordectomy, surgical diathermy, electrocoagulation, cryonecrosis, or even laser ablation. In recent years, the laser has been used with good success in these superficial vocal cord lesions.[3] Good control of disease has, in fact, been accomplished in almost all of the variations of endoscopic techniques, with perhaps the exception of simple biopsy.[12-20] Because of the relative rarity of isolated vocal cord carcinoma in situ and microinvasive SCCA, and because so many treatment modalities have proven successful, there has been no uniformity in treatment regimens. Ferlito et al[21] documented this lack of uniformity in an international survey of head and neck surgeons in 1981. It is interesting that in this survey the majority of respondents still treated isolated glottic carcinoma in situ with radiotherapy.

In the present study, control of disease was accomplished endoscopically in 18 of 20 patients. One patient with a T1 SCCA was salvaged with radiotherapy, and the other patient with a T3 SCCA was salvaged with a total laryngectomy. No differences were noted among those patients treated with the laser and stripping versus stripping alone, either in the recurrence of carcinoma in situ or microinvasive SCCA or in the development of invasive SCCA.

The concept of field disease is important in understanding vocal cord disease and the spectrum of disease ranging from dysplasia to carcinoma in situ or microinvasive SCCA to invasive SCCA. This progression generally represents the sequelae of long-term insults (usually tobacco smoke) to the vocal cord epithelium. Removal of a lesion does not guarantee that additional lesions will not appear at some later date on the same or opposite vocal cord, even if the inciting insult is removed. Similarly, whereas individual lesions are curable with radiotherapy, the irradiated field cannot be sterilized long-term from a tumor or dysplasia standpoint.[22] The only sure guarantee against further dysplasia and malignant change is organ removal, clearly not a treatment option. Many authors have demonstrated the development of second and third vocal cord carcinomas in situ, microinvasive SCCAs, and invasive SCCAs years after initial treatment with endoscopic or radiotherapeutic methods.[10,13,14,23] The present study confirms these observations, as 6 of 20 patients (30%) developed new vocal cord carcinoma in situ, microinvasive SCCA, or invasive SCCA after biopsy-proven disease-free intervals of

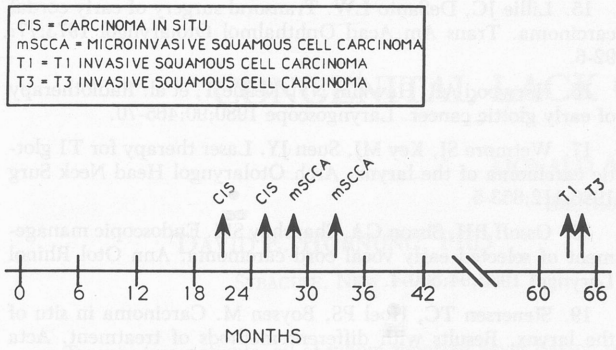

Fig 1. New-onset carcinoma in situ, microinvasive squamous cell carcinoma, and invasive squamous cell carcinoma.

at least 22 months (Fig 1). This potential for further dysplasia, even after definitive therapy, has been one of the strongest arguments against the use of radiotherapy for carcinoma in situ and microinvasive SCCA.

Recognition of the need for compulsive patient follow-up has been fundamental to the success of endoscopic techniques. The admonition of McGavran et al[24] that "therapeutic opportunism, social instability, doctor hopping and the patient's wish for an absolute, quick and guaranteed cure are inimical to the conservative management of [carcinoma in situ and] superficially invasive carcinoma of the vocal cord" remains true today. The present study powerfully demonstrates the need for long-term patient surveillance, as the only treatment failures were in the two patients who were lost to follow-up. These patients had shown no evidence of disease for 16 to 28 months, respectively, before being lost to follow-up, but developed invasive SCCA more than 5 years after their initial procedures. The four patients who had adequate follow-up and subsequently developed recurrent carcinoma in situ or microinvasive SCCA did so after disease-free intervals of at least 22 months and were all successfully managed with further endoscopic techniques (stripping with or without an adjunctive carbon dioxide laser).

Our treatment protocol for carcinoma in situ and microinvasive SCCA (Fig 2) is predicated upon close follow-up. Patients are strongly encouraged to abstain from smoking. Suspicious lesions noted at office examination are further investigated under microlaryngoscopy and stripped or submitted to biopsy as necessary. If a lesion does not strip well off the underlying vocalis muscle, the laser is often employed to ablate any suspicious adjacent or underlying tissue. Pathologic diagnosis of keratosis or dysplasia requires only follow-up examination in 3 months. If invasive SCCA is demonstrated, the patient is scheduled for conservation laryngeal surgery or radiotherapy. A diagnosis of carcinoma in situ or microinvasive SCCA requires repeat examination, microlaryngoscopy, and stripping in 6 weeks. Repeat stripping done prematurely can make pathologic examination considerably more difficult.[13] If no further carcinoma in situ or microinvasive SCCA is demonstrated in the pathologic specimen, the patient is examined again in 6 weeks. If this examination yields normal findings, the patient is seen in 3 months and then biannually thereafter if all examinations have normal findings.

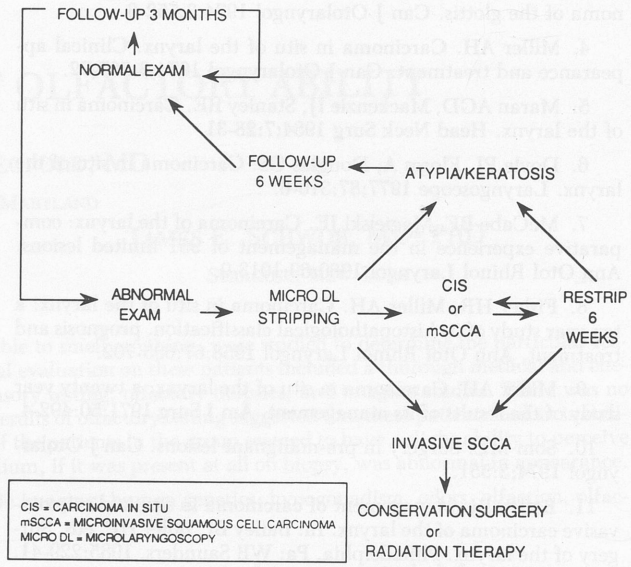

Fig 2. Management algorithm.

Relative contraindications to this approach include patients medically unable to undergo general anesthesia, patients unable to be followed up regularly, and patients in whom laryngeal examination, even under anesthesia, is not adequate. These subgroups of patients would be directed toward radiotherapy.

These data confirm multiple other reports that endoscopic excision of carcinoma in situ and microinvasive SCCA of the vocal cords is efficacious. It does not, however, demonstrate an advantage in use of the laser over microcup forceps stripping alone. Both techniques alone or in combination work well. Most important, the current data demonstrate that carcinoma in situ and microinvasive SCCA of the vocal cords represent a field disease with the potential for further dysplasia and metaplasia years after initial adequate treatment. Long-term patient surveillance is therefore essential.

REFERENCES

1. Miller AH, Batsakis JG. Premalignant laryngeal lesions, carcinoma in situ, superficial carcinoma — definition and management. In: Centennial Conference on Laryngeal Cancer. Can J Otolaryngol 1974;3:573-5.

2. Barnes L. Surgical pathology of the head and neck. New York, NY: Marcel Dekker, 1985:159-60.

3. DeSanto LW. Selection of in situ and early invasive carci-

noma of the glottis. Can J Otolaryngol 1974;3:552-6.

4. Miller AH. Carcinoma in situ of the larynx. Clinical appearance and treatment. Can J Otolaryngol 1974;3:567-72.

5. Maran AGD, Mackenzie IJ, Stanley RE. Carcinoma in situ of the larynx. Head Neck Surg 1984;7:28-31.

6. Doyle PJ, Flores A, Douglas GS. Carcinoma in situ of the larynx. Laryngoscope 1977;87:310-6.

7. McCabe BF, Magielski JE. Carcinoma of the larynx: comparative experience in the management of 951 limited lesions. Ann Otol Rhinol Laryngol 1960;69:1013-9.

8. Fisher HR, Miller AH. Carcinoma in situ of the larynx: a ten year study of its histopathological classification, prognosis and treatment. Ann Otol Rhinol Laryngol 1958;67:695-702.

9. Miller AH. Carcinoma in situ of the larynx: a twenty year study of the results of its management. Am J Surg 1971;50:492-4.

10. Som ML. Surgery in pre-malignant lesions. Can J Otolaryngol 1974;3:551.

11. Bailey BJ. Management of carcinoma in situ and microinvasive carcinoma of the larynx. In: Bailey BJ, Biller HF, eds. Surgery of the larynx. Philadelphia, Pa: WB Saunders, 1985:229-41.

12. Hellquist H, Lundgren J, Olofsson J. Hyperplasia, keratosis, dysplasia and carcinoma in situ of the vocal cords. A follow-up study. Clin Otolaryngol 1982;7:11-27.

13. Stutsman AC, McGavran MH. Ultraconservative management of superficially invasive epidermoid carcinoma of the vocal cord. Ann Otol Rhinol Laryngol 1971;80:507-12.

14. Pene F, Fletcher GH. Results of irradiation of the in situ carcinomas of the vocal cords. Cancer 1976;37:2586-90.

15. Lillie JC, DeSanto LW. Transoral surgery of early cordal carcinoma. Trans Am Acad Ophthalmol Otolaryngol 1973;77:92-6.

16. Harwood AR, Hawkins NV, Keane T, et al. Radiotherapy of early glottic cancer. Laryngoscope 1980;90:465-70.

17. Wetmore SJ, Key MJ, Suen JY. Laser therapy for T1 glottic carcinoma of the larynx. Arch Otolaryngol Head Neck Surg 1986;112:853-5.

18. Ossoff RH, Sisson GA, Shapshay SM. Endoscopic management of selected early vocal cord carcinoma. Ann Otol Rhinol Laryngol 1985;94:560-4.

19. Stenersen TC, Hoel PS, Boysen M. Carcinoma in situ of the larynx. Results with different methods of treatment. Acta Otolaryngol [Suppl] (Stockh) 1988(suppl 449):131-3.

20. Hinz BL, Kagon AR, Nussbaum H, Rao AR, Chan PYM, Miles J. A watchful waiting policy for in situ carcinoma of the vocal cords. Arch Otolaryngol 1981;107:746-51.

21. Ferlito A, Polidoro F, Rossi M. Pathological basis and clinical aspects of treatment policy in carcinoma-in-situ of the larynx. J Laryngol Otol 1981;95:141-54.

22. Gillis TM, Incze J, Strong MS, Vaughan CW, Simpson GT. The natural history and management of keratosis, atypia, carcinoma in situ and microinvasive carcinoma of the larynx. Am J Surg 1983;146:512-6.

23. Crissman JD. Laryngeal keratosis and subsequent carcinoma. Head Neck Surg 1979;1:386-91.

24. McGavran MH, Stutsman AC, Ogura JH. Superficially invasive epidermoid carcinoma of the true vocal cord. Can J Otolaryngol 1974;3:526-7.

CONGENITAL LACK OF OLFACTORY ABILITY

DONALD A. LEOPOLD, MD
BALTIMORE, MARYLAND

DAVID E. HORNUNG, PHD
SYRACUSE, NEW YORK

JAMES E. SCHWOB, MD, PHD
SYRACUSE, NEW YORK

Twenty-two patients, all of whom reported never having been able to smell anything, were studied to determine the particular features that distinguish individuals with congenital anosmia. The clinical evaluation on these patients included a thorough medical and chemosensory history, physical examination, nasal endoscopy, chemosensory testing, olfactory biopsies, and imaging studies. There was no evidence to indicate that these patients ever had a sense of smell. The results of olfactory testing suggested that these patients had an inability to detect both olfactory and trigeminal odorants; however, many of the patients in the group seemed to have a slight ability to perceive at least some component of trigeminal odorants. The olfactory epithelium, if it was present at all on biopsy, was abnormal in appearance.

KEY WORDS — choanal atresia, congenital anosmia, diagnostic imaging, human genetics, hypogonadism, odors, olfaction, olfactory bulb, olfactory mucosa, smell.

Among patients who complain of a poor sense of smell, there is a small but discrete group who say that they have never smelled anything. Because these patients have never experienced an odor sensation, they are said to have a congenital lack of olfactory ability. These individuals have a difficult time understanding the concept of odor and have developed alternate mechanisms for dealing with food, fragrances, and volatile chemicals.

Congenital anosmia is a poorly understood entity from the standpoint of categorization, heredity, or pathophysiology. For purposes of discussion, two broad categories are often considered: congenital anosmia that occurs in concert with other anomalies, and congenital anosmia that occurs as an isolated condition. Congenital anosmia that occurs in association with other anomalies has been recognized for many years. Perhaps the most notable example is Kallmann's syndrome — hypogonadotropic hypogonadism accompanied by total anosmia. Congenital anosmia has also been associated with premature baldness and vascular headaches,[1] choanal atresia,[2] alopecia universalis,[3] ichthyosis and hypogonadism,[4,5] and congenital insensitivity to pain.[6]

The purpose of this paper is to describe the clinical presentation of these patients, discuss how their chemosensory status can be evaluated, illustrate the histopathologic changes in their olfactory mucosa, and determine if the absent olfactory ability is accompanied by other anomalies. Methods of management of patients who have a congenital lack of olfactory ability will also be discussed, as will strategies as to how patients might use nonolfactory cues to cope with this congenital defect.

MATERIALS AND METHODS

The material for the present report comes from 22 patients (14 female, mean age 34 years, range 14 to 58; 8 male, mean age 22, range 14 to 35) with a congenital lack of olfactory ability. These patients were evaluated at the Clinical Olfactory Research Center of the SUNY Health Science Center in Syracuse, New York, from 1984 through 1990. As described below, a detailed history of these patients' chemosensory status was obtained. A head and neck physical examination was then performed, with special attention to the patency of the upper nasal cavities and character of the nasal mucosa. In 18 of these patients, the nasal and sinus cavities were imaged by computed tomography (CT). The olfactory abilities were measured in 19 of the patients, and in 5 of the patients, biopsy specimens of the olfactory epithelium were obtained by using the techniques originally described by Lovell et al.[7]

History. Since there is no known method of positively identifying someone as having a congenital lack of olfactory ability (eg, with a blood test or biopsy), the diagnosis must be made from the patient's history and the lack of any alternative explanation for the anosmia based on the physical examination. Because congenital anosmia is to some extent a diagnosis of exclusion, it was essential that each patient's history be explored in an orderly fashion, with a careful physical examination including all of the features that are discussed below.

The diagnosis of a congenital lack of olfactory ability was suggested when the patient indicated

From the Departments of Otolaryngology (Leopold), Physiology (Hornung), and Anatomy and Cell Biology (Schwob) and the Clinical Olfactory Research Center (all authors), State University of New York Health Science Center, Syracuse, New York. Supported by National Institutes of Health/National Institute on Deafness and Other Communication Disorders grant 9-P01 DC00220.

Presented at the meeting of the American Laryngological Association, Waikoloa, Hawaii, May 4-5, 1991.

REPRINTS — Donald A. Leopold, MD, Johns Hopkins Dept of Otolaryngology–Head and Neck Surgery, Francis Scott Key Medical Center, 4940 Eastern Ave, Baltimore, MD 21224.

that he or she had never had a sense of smell.[8,9] However, even with this admission, it was necessary to eliminate other causes for the olfactory deficit by asking questions about head trauma, nasal disease, upper respiratory tract infections, etc. Because patients who have lost their olfactory abilities before the age of 6 often do not remember ever having had a sense of smell, they and their parents (if possible) were thoroughly questioned about any head trauma or major respiratory tract infections that might have occurred during early childhood. Since virtually everyone has upper respiratory tract infections as a child, and since childhood trauma is also a relatively common event, eliminating these as causative agents for the olfactory deficit was difficult. A behavioral or eating pattern change that followed a head injury or respiratory infection suggested the possibility of an olfactory sense that was lost during early childhood, and therefore these patients were not classified as congenitally anosmic. In addition, the knowledge that occipital blows are more likely to cause olfactory loss helped in this judgment.

To evaluate for the endocrinologic problems that are sometimes associated with a congenital lack of olfactory ability (such as hypogonadotropic hypogonadism), inquiries were made regarding sexual development. In both sexes, questions regarding adult body development, the distribution of axillary and pubic hair, and fertility were particularly important.

Between the ages of 5 and 10, many patients with a congenital lack of olfactory ability began to realize that friends and family members perceived something called odors, which they could not perceive. Commonly cited odorants that were not perceived included freshly prepared popcorn or a recently discovered skunk. The patients soon learned to "play along," and acted as if the odor could be recognized so that they would not be thought of as being different. With the maturity that accompanies the mid-teen years, patients usually began to discuss this problem with family members or close friends. In many instances, the nature and severity of the problem were not appreciated or understood. Consultation with physician(s) usually resulted in laboratory or imaging studies; however, abnormalities are infrequently found and a satisfactory understanding of the reason for the poor olfactory ability was often not obtained.

Patients with this congenital lack of olfactory ability usually discovered that they could successfully function in the olfactory world by fastidiously cleaning themselves and their surroundings. They used little or no fragrance for fear of applying too much. Freshly opened foods were labeled and discarded after a few days to avoid the possibility of spoilage. It was soon learned that lumpy milk and green bologna resulted in gastrointestinal discomfort. Many solicited the assistance of friends or family members in matters of smell.

Since these patients could not detect the aroma of food, they often emphasized factors such as texture, color, and the presence of only a sweet, sour, salty, or bitter taste when describing what they ate. For example, to appreciate the crispness of the flakes, some patients ate cereal without milk. Similarly, foods with a soft texture, such as guacamole and tapioca pudding, were often disliked.

Physical Examinations, Imaging Studies, and Biopsies. The physical examination for a patient with congenital anosmia is important in identifying abnormalities such as nasal disease, which could change the patient's diagnosis and treatment. Accordingly, during the examination, the patency of the nasal airways in the region leading up to the olfactory clefts was determined. Although this was most easily accomplished with the aid of an endoscope, conditions like choanal atresia were diagnosed with the aid of a CT scan. To completely eliminate the possibility that the olfactory deficit occurred as a result of nasal obstructive disease, it was necessary that the nasal cavity be patent the day the olfactory testing was performed.

The physical examination is also important in identifying anomalies that are sometimes associated with congenital anosmia and that may need treatment. For example, it was essential to check for the presence of endocrinologic problems,[2] midline facial defects,[10] alopecia,[3] vascular headaches,[1] ichthyosis,[4,5] and congenital insensitivity to pain.[6]

Chemosensory Testing. The olfactory ability was assessed by the patient's performance on the Odorant Confusion Matrix (OCM).[11] In this test, 10 single chemical odorants were presented to the patient in random order. After smelling each odorant, the patient chose a word from a closed set of 10 words that best described the odor that was smelled. The block of 10 odorants, in random order, was then repeated 9 more times until 10 blocks had been presented. These 100 presentations and responses were then recorded in a matrix (Table 1) that showed not only the correct responses along the diagonal, but also the pattern of incorrect substitutions. Since the subject had 10 choices for each stimulus, the chance performance level for this test was 10% correct.

From a preliminary analysis of the OCM results, it became apparent that the olfactory ability of the congenitally anosmic patients was poor at best, approaching chance performance in many patients. Because of this olfactory deficit, there was at least the possibility that patients would respond with the same word to a number of different odorants. This response bias could confound an odor-by-odor analysis of the OCM percent correct score. At the extreme, consider a patient who responded with "rose" to each of the 100 stimuli. Since rose was cor-

TABLE 1. ODORANT CONFUSION MATRIX SHOWING NUMBER OF RESPONSES

	Ammonia	*Cinnamon*	*Licorice*	*Mint*	*Mothballs*	*Orange*	*Rose*	*Rubbing Alcohol*	*Vanilla*	*Vinegar*
Ammonia	1	1	1	—	1	2	1	1	—	2
Cinnamon	—	1	—	1	1	2	—	—	5	—
Licorice	—	1	—	1	1	—	1	1	5	—
Mint	—	—	1	2	—	1	1	—	5	—
Mothballs	1	—	1	3	1	—	—	1	3	—
Orange	—	2	—	—	2	—	1	1	3	1
Rose	—	—	1	1	—	—	2	1	5	—
Rubbing alcohol	—	—	1	2	—	—	—	3	4	—
Vanilla	—	1	1	—	1	—	—	2	5	—
Vinegar	5	—	—	—	—	—	—	1	—	4
Column totals	7	6	6	10	7	5	6	11	35	7

This matrix shows olfactory test results on one congenitally anosmic patient. Odorant stimuli are listed along left side, and patient's responses are in columns under appropriate odorant name. For 10 vinegar trials, this patient responded with name "ammonia" 5 times, "rubbing alcohol" once, and "vinegar" 4 times. Since this patient correctly identified vinegar 4 out of 10 times, odorant confusion matrix score for vinegar was 40% correct. Diagonal from upper left to lower right contains number of correct responses for each stimulus. Diagonal total for all 10 odorants was 19; thus, for 100 presented odorants, this patient scored 19% correct. Column totals represent number of times patient chose each odorant name. Notice large number of times (35) patient responded with word "vanilla."

rectly identified all 10 times it was presented, the percent correct for rose would be 100%. On the other hand, the percent correct for the other 9 odorants on the OCM would be zero. Clearly, in this example the percent correct for rose is inflated by the response bias of the patient. Although this is an extreme example, one of the congenitally anosmic patients described in the present study responded with the name "vanilla" 80 of 100 times, and another responded with the name "mint" 78 times.

To compensate for the possibility of a response bias, a ratio of the number of correct responses to the number of times chosen was calculated for each odorant. An analysis of variance for both percent correct and the above-noted ratio was calculated to determine if different odorants affected the percent correct on the OCM or the ratio differently. Because it is a routine part of the chemosensory evaluation, an assessment of gustatory ability was also performed.[12]

RESULTS

History. Six of the 22 patients related instances in which they had had difficulty in the early detection of the smoke from a fire. All these patients denied ever having had a sense of smell, and the concept of an odor was difficult for them to understand. None of these patients had a history that suggested that the olfactory deficit could have occurred as a result of an upper respiratory tract infection, nasal disease, toxic exposure, aging, or head trauma. Eight of the patients in the group reported a family history of a similar congenital olfactory problem in grandparents, parents, siblings, or offspring children (Fig 1).

A 27-year-old man in this group was diagnosed as having Kallmann's syndrome (hypogonadotropic hypogonadism) and a 24-year-old woman had reproductive and growth disturbances. None of the other patients had a history of endocrinologic problems; all had gone through puberty and showed signs of adult development (males with facial hair and/or male pattern baldness; females with regular menstruation and many with children).

Physical Examination, Imaging Studies, and Biopsies. The physical examination findings for the patients without associated anomalies were generally normal. The CT scans were reviewed for bony and mucosal abnormalities in the upper nasal and sinus cavities. Two of the 18 patients had unilateral choanal narrowing, 1 with a mild stenosis and 1 with an atresia. The olfactory clefts in these 2 patients appeared to be normal. Six patients had a minor degree of mucosal thickening in the paranasal sinuses, but the airways were patent. The CT scans of the remaining 10 patients were read as normal.

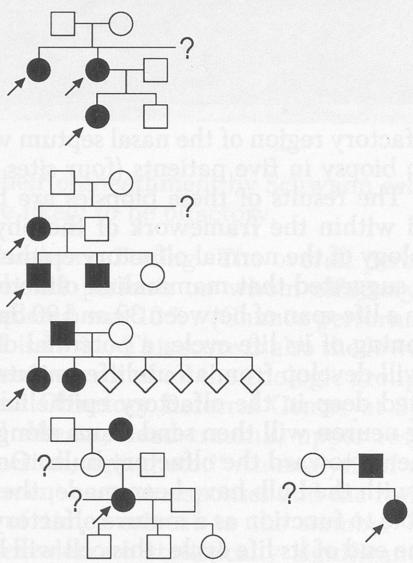

Fig 1. Pedigrees from patients who had congenital anosmia. Although only some of congenitally anosmic relatives received olfactory testing, all were said to have never had sense of smell. Dark symbols — congenitally anosmic individuals, squares — males, circles — females, diamonds — known offspring of unknown gender, question marks — unknown offspring, arrows — patients in present study.

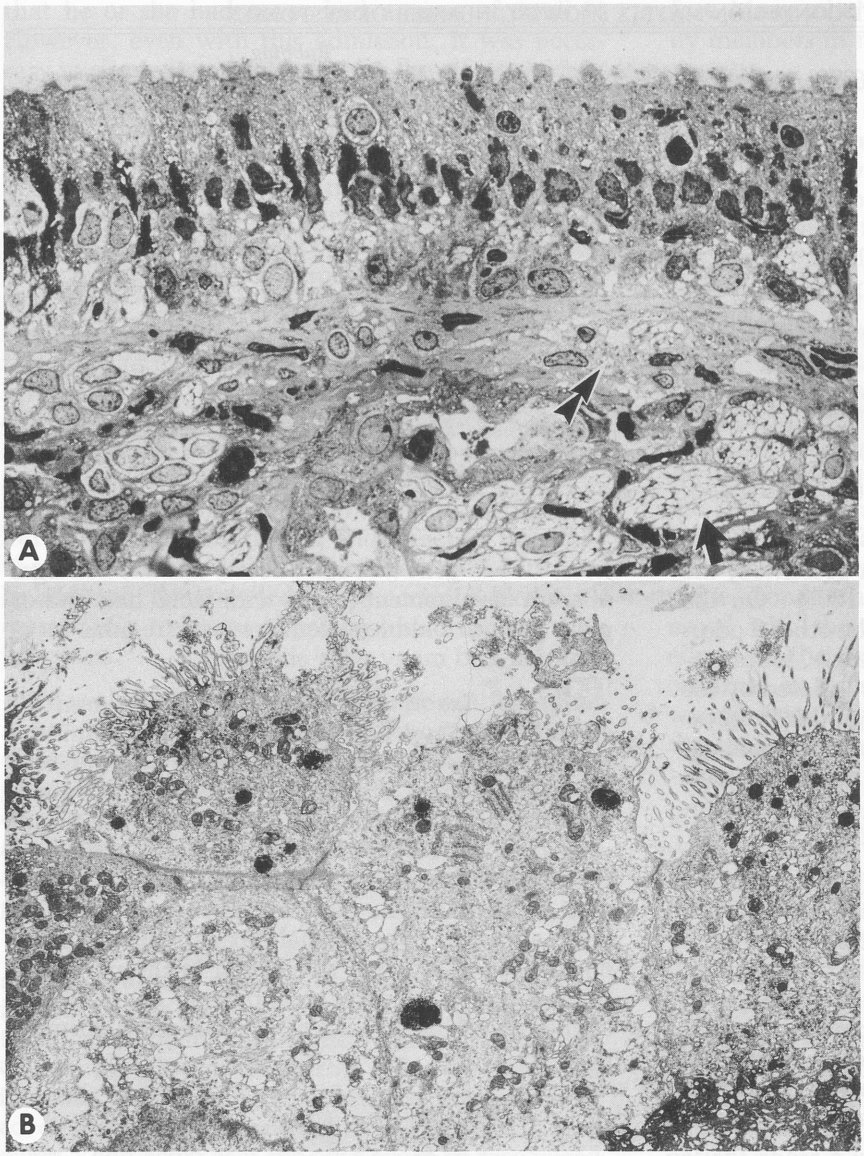

Fig 2. Olfactory mucosa, including both epithelium and lamina propria, harvested from 42-year-old woman with isolated congenital anosmia. A) Light micrograph illustrating presence of supporting cells and basal cells; there is no evidence of neurons in this particular field, although immature neurons were observed in other areas of biopsy specimen (original x720). Arrow — small fascicle of olfactory nerve containing swollen axons (comparable to area in Fig 3A), double arrowheads — swollen axons loose in lamina propria (comparable to area in Fig 3B). B) Electron micrograph of apical surface of epithelium showing typical microvillar-capped supporting cells and absence of olfactory knobs in this field (original x7,000).

The olfactory region of the nasal septum was submitted to biopsy in five patients (four sites in each patient). The results of these biopsies are best appreciated within the framework of the physiology and histology of the normal olfactory epithelium. It has been suggested that mammalian olfactory neurons have a life span of between 30 and 90 days.[13] At the beginning of its life cycle, a potential olfactory neuron will develop from an undifferentiated basal cell located deep in the olfactory epithelium. This emerging neuron will then send axons along the olfactory nerve toward the olfactory bulb. Once connections with the bulb have been made, the neuron will be able to function as a mature olfactory receptor. At the end of its life cycle, this cell will begin to degenerate and the connections with the olfactory bulb will be broken. The process of developing another olfactory receptor will then begin. If the neuron fails to make synaptic connections with the olfactory bulb, it will die before reaching the normal limit of its life span.[14]

Biopsies of the olfactory area usually show the presence of several different types of cells, including basal cells, supporting cells, and olfactory neurons at various stages of maturity. In the lamina propria, most of the axons seen are ensheathed by Schwann cells into fascicles, with each fascicle containing many axons. The mature axons are normally small, unmyelinated fibers that are fairly uniform in diameter.[15]

In three of the patients, no olfactory epithelium was found; instead, normal-appearing respiratory epithelium was identified. This result is consistent with the results of Jafek et al,[8] who recently found only respiratory epithelium in seven congenitally anosmic patients. In two of our patients — one the 27-year-old man with Kallmann's syndrome and the other a 42-year-old woman with isolated congenital anosmia — olfactory epithelium could be identified, but was highly abnormal in appearance. In both cases, the histopathology of the olfactory

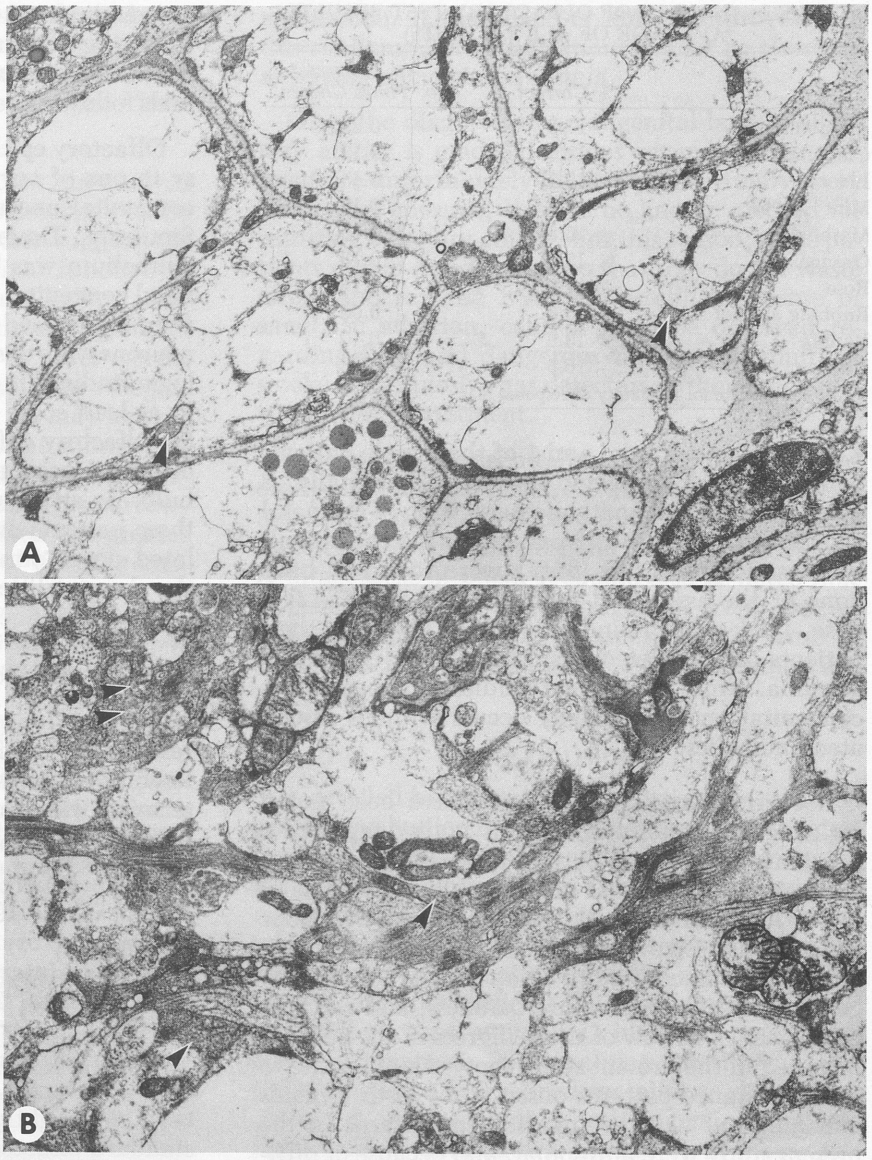

Fig 3. Same area of olfactory mucosa as shown in Fig 2. A) Electron micrograph illustrating fascicle of olfactory axons partitioned by tongues of Schwann cell cytoplasm (original x10,500). Vast majority of axons are swollen and their surface membranes are fragmented. However, some normal-appearing olfactory axons are seen (arrowheads). B) Electron micrograph of lamina propria illustrating disorganized knot of olfactory axons loose in connective tissue (original x15,500). Many axons are very swollen and fragmented, but some look normal (arrowheads) and others are intermediate in appearance.

epithelium was similar: supporting cells capped with microvilli and basal cells were present. Occasionally, immature olfactory neurons, identified by the absence of cilia on the olfactory knob, were also observed. However, there were no mature olfactory sensory neurons in these patches of epithelium (Fig 2). In the lamina propria deep to the epithelium, axons were abundant. They were found ensheathed by Schwann cells into fascicles, each fascicle containing many axons (Fig 3A). Other axons were found loose in the surrounding connective tissue or in dense neuromalike knots (Fig 3B). Most of these axons, irrespective of location, were swollen or broken open — an appearance that is indicative of axonal degeneration. Since some axons that were smaller and more normal in appearance were intermingled with the swollen atypical axons, it is unlikely that the observed axonal abnormalities are artifactual. On the basis of their abundance, their location throughout the lamina propria, and the nature of their ensheathment by Schwann cells, these axons are likely to be olfactory.

Chemosensory Testing. The overall percent correct of the 19 patients on whom olfactory testing was completed was 13%. (Chance performance for the OCM is 10%.) This score is also the lowest average percent correct of all the etiologic groups classified at the Olfactory Referral Center at Syracuse, eg, nasal disease, head trauma, upper respiratory tract infection, aging, etc.[16] An analysis of variance of the percent correct responses and the ratio of the number of times correct to the number of times chosen revealed no statistically significant difference across the 10 odorants. The mean percent correct and the mean ratio are shown by odorant in Table 2.

DISCUSSION

In the present study, 1 of the male patients had

TABLE 2. ANALYSIS OF OLFACTORY TEST RESULTS (AVERAGE OF ALL PATIENTS)

	% Correct	No. Correct/ No. Times Chosen*
Ammonia	17.8	0.23
Cinnamon	11.0	0.12
Licorice	13.7	0.15
Mint	13.7	0.10
Mothballs	6.8	0.16
Orange	12.6	0.18
Rose	17.9	0.16
Rubbing alcohol	5.4	0.06
Vanilla	13.6	0.10
Vinegar	16.5	0.23

*To compensate for possibility of response bias.

Kallmann's syndrome, and 1 of the female patients had other endocrinologic defects. Additionally, 2 other patients had anatomic narrowing of the nasal choanae. Thus, of the 22 patients in the congenitally anosmic group, 18 (82%) were found to have none of the associated defects listed above. Likewise, Jafek et al[8] found that 6 of 7 (86%) of their patients had no defects associated with congenital anosmia. From both these studies it appears that congenital anosmia usually occurs without associated anomalies.

Recurring familial tendencies have been noted for congenital anosmia.[1,8,17-19] Lygonis[17] reported a dominant inheritance pattern that affected females approximately twice as often as males (19 females and 9 males in a family of 52 members over four generations). Likewise, Singh et al[1] reported a dominant inheritance pattern in an association of congenital anosmia, premature baldness, and vascular headaches. A review of the pedigrees of the patients included in the present study showed similarities to the inheritance patterns observed by both Lygonis and Singh et al. The inheritance patterns in the present study were autosomal, and because of difficulties in the identification and reporting of congenital anosmia in other family members, likely dominant. Moreover, we observed a female predominance of approximately 2 to 1.

Little is known of the pathophysiologic basis for congenital anosmia with or without associated anomalies. In Kallmann's syndrome, the olfactory bulbs are reportedly absent.[20] Similarly, midline facial defects can be associated with congenital anosmia and absence of the olfactory bulbs.[10] The presence of olfactory epithelium in our patient with Kallmann's syndrome is an indication, therefore, that absence of the olfactory bulbs is not necessarily associated with the failure of formation of the olfactory epithelium. Indeed, our observations of immature olfactory neurons in association with dilated, degenerating olfactory axons indicate that olfactory neurons are present in the mucosal lining and still send out axons in an attempt to contact the bulb. These degenerative changes in the olfactory axons are reminiscent of alterations observed in anosmia following head trauma[21] (also J. E. Schwob, unpublished observations, 1990) and in experimental animals following removal of the olfactory bulbs.[14]

Olfactory epithelium was also identified by biopsy in one of our patients who was judged to have congenital anosmia without associated anomalies. Similarly, Douek et al[22] reported that olfactory epithelium was harvested from a patient with isolated congenital anosmia. In both cases, axonal abnormalities and the absence of mature olfactory neurons were observed. Considering the histopathologic findings in these cases, we think that perhaps in at least some patients with congenital anosmia, the olfactory deficit may be due to a failure of the olfactory neurons to contact an existing olfactory bulb. As another possibility, the olfactory bulbs in these patients may be absent, representing an isolated developmental abnormality. In either case, the abnormalities observed in the olfactory epithelium would reflect the inability of olfactory neurons to contact the bulb and the enhanced neuronal turnover that would occur as a consequence.[14]

Klingmuller et al[23] recently developed magnetic resonance techniques to image the olfactory sulcus. It will be interesting to use these techniques to determine which congenitally anosmic patients lack normal olfactory sulci.

Thirteen percent was the mean overall percent correct of the 19 congenitally anosmic patients on whom olfactory testing was completed. The 95% confidence interval for this mean is 10 to 16, suggesting that 13% is not significantly different from the 10% chance level. This observation is consistent with the results of both Jafek et al[8] and Davidson et al,[24] who report that congenitally anosmic patients test only slightly above the chance level on other standard olfactory tests.

An analysis of variance of the percent correct and the ratio of the number of times correct to the number of times an item was chosen revealed no statistically significant difference across the 10 odorants ($p > .05$). Given the nature of the odorants in the OCM, this result is somewhat surprising. The 10 odorants of the OCM include some odorants that stimulate mostly the trigeminal nerve (ammonia and vinegar) and others that stimulate mostly the olfactory nerve (rose and vanilla). The other 6 odors in the test are mixed stimulators, affecting both the trigeminal and olfactory nerves. Since no statistically significant difference was found in the identifiability of the 10 odorants on the OCM, the results of the present study suggest that congenitally anosmic patients can detect neither olfactory nor trigeminal chemosensory signals.

However, some caution must be exercised in suggesting this conclusion. It should be recalled that the OCM is an identification test. It is possible that

at least some of the chemosensory signals are being detected, but the patients cannot make the proper identification. That is, patients might know that something is there but not be able to give the stimulus the correct name.

Although not statistically significant, an analysis by odorant of the ratio of the number correct to the number of times an odorant was chosen suggests the possibility of at least some trigeminal function in many of the patients. As can be seen in Table 1, ammonia and vinegar (the two strongest trigeminal stimulators) had the highest ratio. In other words, when subjects indicated either ammonia or vinegar, they were more likely to be correct. It may be that these patients felt "something" from the stimulation of the trigeminal nerve, and so limited their responses to either ammonia or vinegar. This narrowing of choices might then have resulted in a greater likelihood of correct identification of the odorants.

However, for several of the patients in this study there is no evidence of either trigeminal or olfactory function. Perhaps, as Jafek et al[8] suggest, the problem with some congenital anosmics may be central. Thus, no airborne stimuli are likely to be detected.

Results of tests of gustatory function in the present study were all normal — an observation that is consistent with the experience of Jafek et al.[8] The presence of functional taste buds should be pointed out to the patient as a positive factor for improving his or her eating experience.

Imaging studies using CT scanning were useful in separating patients who had obstructive nasal inflammatory disease from those with congenital olfactory deficits. As noted above, several of the patients with congenital deficits did have some thickening of the membranes of the nasal cavity and sinuses. However, in all cases, the passageway to the olfactory receptors in the olfactory cleft was patent.

As Jafek et al[8] suggest, another aid to the diagnosis of congenital anosmia is a trial of oral steroid medication. If the olfactory ability improves with this challenge, then the patient cannot be classified as having congenital anosmia.

Once the diagnosis of a congenital lack of olfactory ability is made, decisions regarding management are unfortunately limited. For virtually every congenital anosmic, there is no known method for restoring olfactory ability. For this reason, these patients should be counseled so that they do not waste effort and expense trying to establish a sense of smell. In addition, caution must be observed regarding fires and dangerous fumes, and multiple smoke and explosive gas detectors in the home are a worthwhile investment.

Fortunately, congenitally anosmic patients generally do not consume sweet and salty foods in an unhealthy manner — an eating pattern that is sometimes seen in patients who have lost a previously intact sense of smell. It should also be noted that in general, patients in the congenital group are not unhappy, since they never experienced a sense of smell and therefore do not realize what they are missing.

CONCLUSION

A detailed history, physical examination, chemosensory evaluation, olfactory biopsies, and imaging studies were conducted on patients with a congenital lack of olfactory ability. These patients reported never having smelled anything, and the concept of odor was difficult for them to understand. Although the physical examination findings were generally normal, in a few patients the anosmia was accompanied by other anomalies, including endocrine and nasal anatomic abnormalities. Results from the OCM suggest a generalized inability to detect airborne odorants, including both trigeminal and olfactory nerve stimulators. However, in many patients there was at least a suggestion of some trigeminal function. Biopsy showed the presence of olfactory epithelium in some of the patients, but it was abnormal in appearance.

REFERENCES

1. Singh N, Grewal MS, Austin JH. Familial anosmia. Arch Neurol 1970;22:40-4.

2. Klein VR, Friedman JM, Brookshire GS, Brown OE, Edman CD. Kallmann syndrome association with choanal atresia. Clin Genet 1987;31:224-7.

3. Monk B. Alopecia universalis and Kallmann's syndrome [Letter]. Dermatologica 1973;173:101-2.

4. Sunohara N, Sakuragawa N, Satoyoshi E, Tanae A, Shapiro LJ. A new syndrome of anosmia, ichthyosis, hypogonadism and various neurological manifestations with deficiency of steroid sulfatase and arylsulfatase C. Ann Neurol 1986;19:174-81.

5. Bick D, Curry CJR, McGill JR, Schorderet DF, Bux RC, Moore CM. Male infant with ichthyosis, Kallman syndrome, chondrodysplasia punctata, and an Xp chromosome deletion. Am J Med Genet 1989;33:100-7.

6. Losa M, Scheier H, Rohner P, et al. Long-term course in congenital analgesia [in German; English abstract]. Schweiz Med Wochenschr 1989;119:1303-8.

7. Lovell MA, Jafek BW, Moran DT, Rowley JC III. Biopsy of human olfactory mucosa. An instrument and a technique. Arch Otolaryngol 1982;108:247-9.

8. Jafek BW, Gordon AS, Moran DT, Eller PM. Congenital anosmia. Ear Nose Throat J 1990;69:331-7.

9. Paik SI, Seiden AM, Duncan HJ, Smith DV. Olfactory mucosal biopsy in patients with congenital anosmia. Chemical Senses (in press).

10. Cohen MM Jr. Perspectives on holoprosencephaly: part I. Epidemiology, genetics, and syndromology. Teratology 1989;40:211-35.

11. Wright HN. Characterization of olfactory dysfunction. Arch Otolaryngol Head Neck Surg 1987;113:163-8.

12. Bartoshuk L. Clinical evaluation of the sense of taste. Ear Nose Throat J 1989;68:331-7.

13. Costanzo RM, Graziadei PPC. Development and plasticity of the olfactory system. In: Finger TE, Silver WL, eds. Neurobiology of taste and smell. New York, NY: John Wiley & Sons, 1987:233-50.

14. Schwob JE. The biochemistry of olfactory neurons: stages of differentiation and neuronal subsets. In: Serby ML, Chodor LL, eds. The science of olfaction. Berlin, Germany: Springer-Verlag (in press).

15. Jafek BW. Ultrastructure of human nasal mucosa. Laryngoscope 1983;93:1576-99.

16. Leopold DA. Physiology of olfaction. In: Cummings C, ed. Otolaryngology–head and neck surgery. 2nd ed. St Louis, Mo: Mosby-Year Book, Inc (in press).

17. Lygonis CS. Familiar absence of olfaction. Hereditas 1969; 61:413-6.

18. Chaussain JL, Toublanc JE, Feingold J, Naud C, Vassal J, Job JC. Mode of inheritance in familial cases of primary gonadotropic deficiency. Horm Res 1988;29:202-6.

19. Meitinger T, Heye B, Petit C, et al. Definitive localization of X-linked Kallman syndrome (hypogonadotropic hypogonadism and anosmia) to Xp22.3: close linkage to the hypervariable repeat sequence CRI-S232. Am J Hum Genet 1990;47:664-9.

20. Gauthier G. La dysplasia olfacto-genitale (agenesie des lobes olfactifs avec absence de development gonadique a la puberte). Acta Neuroveg 1960;21:345-94.

21. Jafek BW, Eller PM, Esses BA, Moran DT. Post-traumatic anosmia. Arch Neurol 1989;46:300-4.

22. Douek E, Bannister LH, Dodson HC. Recent advances in the pathology of olfaction. Proc R Soc Med 1975;68:467-70.

23. Klingmuller D, Dewes W, Krahe T, Brecht G, Schweikert H-U. Magnetic resonance imaging of the brain in patients with anosmia and hypothalamic hypogonadism (Kallmann's syndrome). J Clin Endocrinol Metab 1987;65:581-4.

24. Davidson TM, Jalowayski A, Murphy C, Jacobs RD. Evaluation and treatment of smell dysfunction. West J Med 1987;146: 434-8.

IN SITU HYBRIDIZATION AND LARYNGEAL PAPILLOMAS

FRANK RIMELL, MD
ROBERT MAISEL, MD
VANNESA DAYTON, MD
MINNEAPOLIS, MINNESOTA

The technique of in situ hybridization with biotin-labeled probes was applied to 20 patients with laryngeal papillomatosis (9 with adult-onset disease and 11 with juvenile-onset). Ten patients were noted for epithelial transformation of their laryngeal disease. All patients, regardless of their clinical outcome, tested positive for human papillomavirus group 6/11. The biotin method of in situ hybridization proved to be a sensitive method in this study, identifying the infecting viral group in 23 of 24 samples. This study also tested for group 16/18 and is the first to test for the presence of group 31/33/35 in the larynx. These viruses or members of related groups have been reported in malignancies of the head and neck as well as the uterine cervix. They have yet, however, to be identified in benign laryngeal papillomas or laryngeal papillomas that have undergone epithelial transformation.

KEY WORDS — epithelial atypia, human papillomavirus, in situ hybridization, larynx.

INTRODUCTION

The search for the cause of laryngeal papillomas began with Ullman,[1] who in 1923 reported on the successful transfer of an agent from human laryngeal papillomas to the vagina of a dog and to his own arm. Some 50 years later, Boyle et al[2] identified papova viral particles with the electron microscope. In 1982, papilloma viral DNA was identified in the larynx of both adult and juvenile patients with the technique of Southern blot DNA hybridization.[3] The technique at this time was limited to fresh tissue biopsy samples that were quickly frozen and could identify only human papillomavirus (HPV) 6. Recently, the ability to identify the papillomavirus from paraffin-embedded archival material has been developed with the use of the in situ hybridization technique. Along with this new ability has come a series of recent articles that have identified HPV 16 and HPV 30 in carcinomas of the larynx and other regions of the head and neck.[4-8]

As of 1990, 13 different viral types have been isolated from the human genital tract. These viral types can be further classified into groupings based on their genetic makeup. An arbitrary figure of 50% is set so that if a new papillomavirus is isolated and has a DNA structure that has 50% or greater homology with a virus already isolated, it will be grouped with that virus.[9] If less than 50% of the DNA is homologous with any preexisting papillomavirus, it is placed into a new group. For example, HPV 6 and HPV 11 share approximately 85% of their genetic structure and are placed into one typing group. In contrast, HPV 16 and HPV 18 share greater than 50% of their genetic structure with each other, but less than 50% with group 6/11, and form a second typing group. The HPV groups 6/11, 16/18, and 31/33/35 are the most prevalent typing groups in the uterine cervix. There is one exception to this classification system at this time: HPV 16 and 31 appear to be more homologous than originally recognized.[10] However, HPV 16 shares little homology with other members of the group (HPV 33 and 35) and therefore remains in a separate group with HPV 18.

Much of our knowledge concerning the clinical behavior of the papillomavirus comes from its association with uterine cervical epithelium, in which the virus appears to be most prevalent. This higher prevalence in the uterine cervix has also been suggested as one mode of transmission of the virus to the larynx.[11] This higher prevalence rate has been the source of many studies that have made the identification of the infecting papilloma group a useful tool in predicting which patients are at higher risk of atypical or malignant epithelial transformation.[12] Presently, HPV group 16/18 is considered to be of high risk because of its association with uterine cervical epithelial transformations to severe cellular atypia or malignancy.[10,13-15] Group 31/33/35 is considered of intermediate risk and group 6/11 is of low risk.[14-16] These risks were deduced from the fact that HPV group 16/18 is the major type of viral DNA found in cervical carcinomas and are reinforced by the demonstration of HPV group 16/18 in 75% of the established cell lines originating from human cervical cancers.[17,18] Group 31/33/35 is likely to be present in cervical intraepithelial neoplasias demonstrating high grades of cellular atypia, while HPV group 6/11 is typically associated with low-grade intraepithelial neoplasia or benign papillomatosis.[16] The described differences in the genetic sequences between papillomavirus groupings may explain why some papilloma typing groups have greater transforming or oncogenic capabilities than others.[10]

In laryngeal papillomatosis, the majority of pa-

From the Departments of Otolaryngology (Rimell, Maisel) and Laboratory Medicine and Pathology (Dayton), University of Minnesota, Minneapolis, Minnesota. Funded by a grant from the Minneapolis Medical Research Foundation.

Presented at the meeting of the American Laryngological Association, Waikoloa, Hawaii, May 4-5, 1991.

tients display a self-limited and benign course. Certain patients, as in disease of the uterine cervix, will display a more aggressive form manifested by various degrees of cellular atypia and, rarely, a transformation to a carcinoma. Many in the past have considered variance in clinical and pathologic outcome of laryngeal papillomatosis to be host-related or environmentally related (ie, irradiation and smoking).[19,20] The objective of the present study was to determine if variance of the infecting HPV viral group was also a factor related to the clinical and pathologic outcome in patients with laryngeal disease as it is in cervical disease. We were particularly interested in those patients whom we considered to suffer from an atypical course of laryngeal papillomatosis and who underwent epithelial transformation of their disease.

MATERIALS AND METHODS

Twenty patients with a diagnosis of laryngeal papillomas were selected from the records of the University of Minnesota Affiliated Hospitals and Clinics. The study group comprised 9 patients with adult onset and 11 patients with juvenile onset. Patients were excluded if there was a history of radiotherapy prior to a malignant transformation. The adult-onset group, as defined by Corbitt et al,[21] consisted of patients presenting with laryngeal disease past the age of 16. Juvenile-onset patients were those presenting prior to the age of 16 with disease. The patients were selected in a nonrandom manner and emphasis was placed on including those patients thought to suffer from severe or atypical laryngeal disease. Hence, this was not a truly representative sample of our papilloma population.

The clinical records of each patient were reviewed and pertinent data abstracted. Hematoxylin and eosin–stained slides of infected laryngeal epithelium were reviewed and histologically categorized as benign or atypical on the basis of cellular aberrations such as dyskeratosis, increased nucleus-cytoplasm ratios, nuclear enlargement, nuclear hyperchromatism, loss of transepithelial maturation, and abnormal mitotic figures. The diagnosis of mild, moderate, or severe atypia was made by the reviewing pathologist at the University of Minnesota.

Tissue samples for in situ hybridization had been previously fixed in 15% formalin and embedded in paraffin. One sample from each patient underwent in situ hybridization. The sample selected represented that patient's most atypical epithelial change. Patients 5, 8, and 17 had a second sample analyzed representing their benign laryngeal disease prior to its conversion to carcinoma in situ (CIS) or squamous cell carcinoma. Patient 14 also had a second specimen analyzed from an esophageal biopsy. In total, 24 samples were analyzed.

In Situ Hybridization. The method used is similar to that previously described by Unger et al.[22] Sections 3 millimicrons thick were cut from paraffin tissue blocks and placed onto beveled glass slides pretreated with 3-aminopropyltriethoxysilane. The slides were then air-dried at room temperature and placed on a heating block and baked at 58°C overnight to allow the paraffin to melt and the cells to adhere to the slides. Slides the next day were cooled to room temperature, dewaxed by two 5-minute incubations in xylene followed by two 5-minute incubations in absolute alcohol, and then air-dried for 10 minutes. Then the slides were exposed to pronase and incubated at 37°C for 15 minutes to allow for proteolytic digestion and to facilitate efficient intracellular penetration of the hybridization probe. Slides were then washed in TRIS-saline for 1 minute, dehydrated in 95% alcohol for 1 minute, and air-dried for 10 minutes.

Hybridization was carried out with plasmid pBR322 containing HPV group 6/11, 16/18, or 31/33/35. A probe for HPV 30 was not available at our institution. These probes had previously undergone nick translation and were labeled with biotin-11-dUTP. Forty microliters of probe reagent was placed on the slide, which was then covered with an 18 x 18-mm coverslip and incubated for 2 hours at 37°C. Slides were then washed in 2x SSC three times each for 3 minutes at 37°C.

Detection of the viral DNA, now hybridized to the probe, was accomplished by the addition of 40 μL of streptavidin-biotinylated alkaline phosphatase to each slide and incubation at 37°C for 20 minutes. Slides were then washed in TRIS-saline and incubated again in a solution containing 5-bromo-4-chloro-3-indolylphosphate dye and nitroblue tetrazolium dye at 37°C for 60 minutes. Slides were washed again, counterstained with nuclear-fast red, and mounted. Known control human anogenital tissue as well as a negative control was prepared along with the above samples to ensure accuracy. The biotin-labeled plasmid probe, the streptavidin detection reagent, and all dyes were purchased from Life Technologies, Inc (Gaithersburg, Md).

CASE STUDIES

Adult-Onset Group. This group comprised nine men with age at presentation ranging from 20 to 78 years (Table 1). Five of the nine patients (2, 3, 4, 6, and 7) had no epithelial changes on biopsies and were noted to undergo clinical remission after 1 to 3 years of disease. We felt these five patients to be representative of a typical course of adult laryngeal papillomatosis.

Patient 9, although never undergoing epithelial transformation, did undergo tracheobronchial spread of his laryngeal disease 5 months following presentation. This patient, who was found to have stage IV chronic lymphocytic leukemia 2 years prior

TABLE 1. ADULT-ONSET PATIENTS

Patient	*Age at Onset*	*Age at Biopsy*	*No. of Surgical Procedures*	*Tracheotomy*	*No. of Lesions*	*Pathologic Findings*
1	62	64	6	–	Multiple	SA
2	53	53	2	–	Single	Benign
3	29	30	5	–	Multiple	Benign
4	61	63	2	–	Single	Benign
5	73	74	8	–	Multiple	CIS
6	20	23	4	–	Multiple	Benign
7	78	80	4	–	Multiple	Benign
8	28	64	?	+	Multiple	CIS
9	44	45	4	–	Multiple	Benign

SA — severe atypia, CIS — carcinoma in situ.

TABLE 2. JUVENILE-ONSET PATIENTS

Patient	*Age at Onset*	*Age at Biopsy*	*No. of Surgical Procedures*	*Tracheotomy*	*Disease as Adult*	*Pathologic Findings*
10	1.5	20	>120	+	+	SA
11	3	32	>120	+	+	SA
12	1	1	2	–	–	Benign
13	1.5	3	11	–	–	Benign
14	2	13	>70	+	+	MIA
15	2	17	>90	+	+	MIA
16	2	7	13	–	–	Benign
17	7	28	25	+	+	MOA
18	3	52	>30	–	+	SCCA
19	2	19	>90	+	+	MIA
20	3	3	4	–	–	Benign

SA — severe atypia, MIA — mild atypia, MOA — moderate atypia, SCCA — squamous cell carcinoma.

to the onset of laryngeal papillomas, had eventual obstruction of the right lower lobe of his lung by papillomas.

Three patients (1, 5, and 8) were noted for epithelial transformation. Patient 8 in addition developed severe tracheobronchial spread of his papillomatosis. Patient 1 has had unusually severe disease for an adult, to the extent that he twice presented with partial airway obstruction and underwent emergent endoscopic removal of disease. This patient was receiving steroid therapy for chronic obstructive pulmonary disease and consequently had developed invasive candidiasis of the larynx along with his papillomas. The patient's epithelium at this point has transformed into severe atypia.

Patient 5 presented with bilateral benign laryngeal papillomas (see Figure; A,B). Ten months later he developed severe atypia (see Figure, C). Twelve months following the initial biopsy, the epithelium of the left true vocal cord transformed to CIS (see Figure; D,E). Fifteen months from presentation the patient's right true vocal cord also transformed to CIS. He was treated with sequential mucosal strippings and continues to be followed up with laryngeal biopsies that reveal severe atypia.

Patient 8 presented at age 28 and has had disease over 40 years with several tracheotomies. He currently has diffuse laryngeal and tracheal involvement that has led to frequent pneumonias and near-death by suffocation. He has had two recent laryngeal biopsies revealing CIS with microinvasion.

Juvenile-Onset Group. This group comprised two male and nine female patients with age at onset of laryngeal disease ranging from 1.5 to 7 years old (Table 2). Four patients (12, 13, 16, and 20) had laryngeal disease that disappeared before puberty, fewer than 15 operative procedures per patient, and no history of tracheotomy. We considered these four patients representative of benign juvenile laryngeal papillomatosis.

Six patients, five female and one male (10, 11, 14, 15, 17, and 19), had disease that persisted without remission into adulthood, multiple surgical procedures, placement of a tracheotomy at some point during their clinical course, and epithelial transformation on more than two occasions. These patients represent a significant subgroup at our institution and have been labeled as having aggressive juvenile laryngeal papillomatosis. Each patient of this subgroup, except for patient 17, had more than 70 surgical procedures. Patient 17 had 21 surgical procedures and then at the age of 16 underwent a tracheotomy at another institution. Initially she was noted to undergo tracheobronchial spread of her disease but then her clinical follow-up ceased. She presented to us 12 years later, tracheotomy in place, with extensive glottic and subglottic disease but without tracheobronchial disease. She has since undergone 4 additional surgical procedures in an attempt at decannulation and has had biopsies revealing moderate atypia.

Patient 10 has had over 120 surgical procedures, including 50 procedures by the time she was 8 years old. She has been treated with transfer factor, gamma globulin, and interferon in the past. Tracheal spread to the carina was first noted at age 10 but did not require tracheotomy until age 17, when the patient became pregnant. Several laryngeal and tracheal biopsies have shown severe atypia. She continues tracheotomy-dependent at age 22 with monthly removal of disease.

Patient 11 has a similar history, with over 120 surgical procedures, the majority done at other institutions. She underwent her first tracheotomy at the age of 5, with decannulation at age 13. A few years later, she underwent a second tracheotomy, with decannulation after 7 years at the age of 23. She first presented to us at the age of 39, pregnant and with obstructive distal disease of the left main stem bronchus. Two biopsies revealed severe atypia of the larynx.

Patient 14 underwent tracheotomy at an outside institution at the age of 3. She has had more than 70 surgical procedures and treatment in the past with

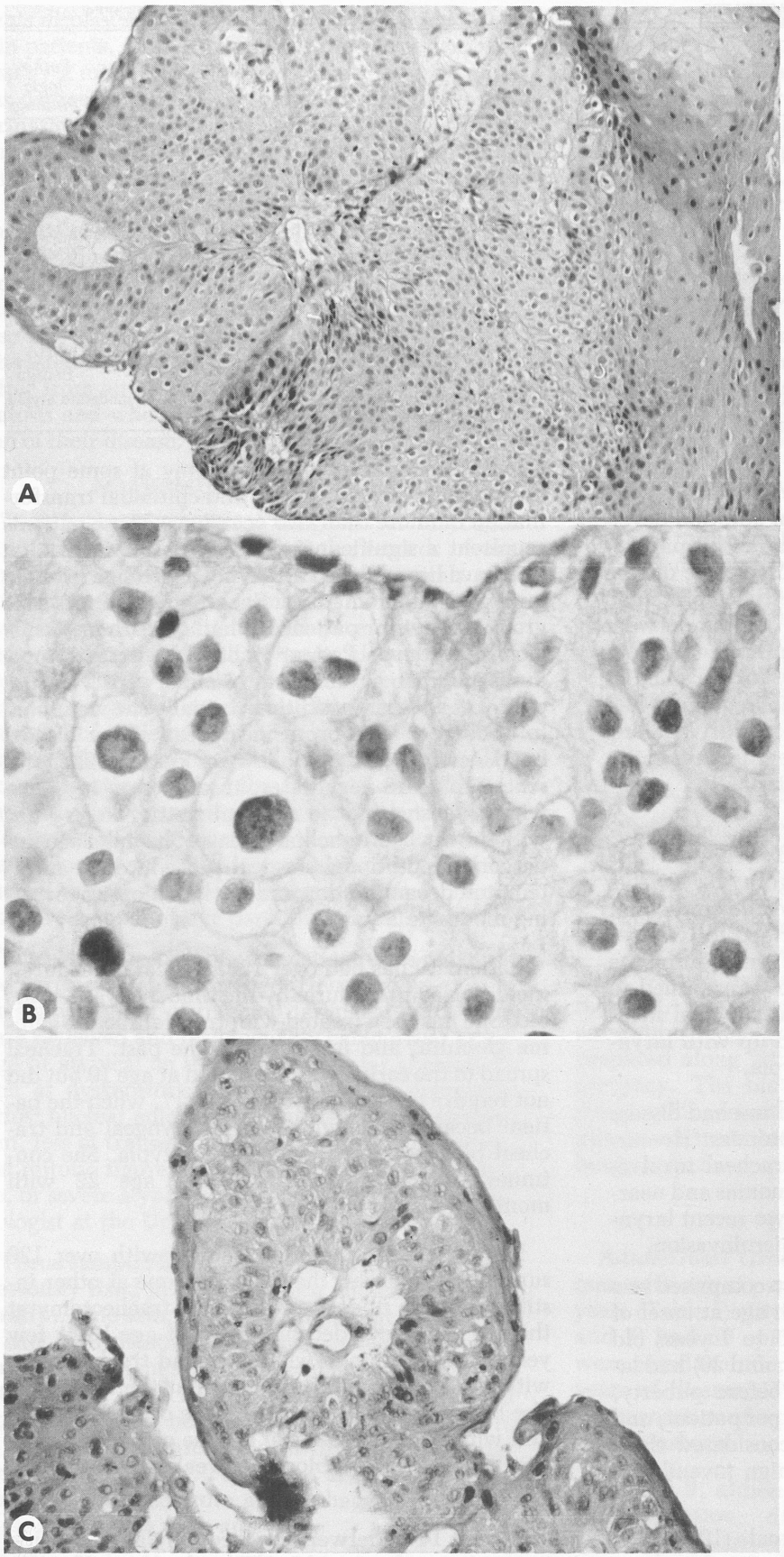

(Patient 5) Photomicrographs of laryngeal biopsies over 1 year. A) Initial biopsy reveals squamous papilloma characterized by multilayering of squamous epithelial cells around fibrovascular core with normal transepithelial maturation and nuclear polarity (H & E, original x40). B) High-power view of A revealing marked koilocytosis associated with virally infected epithelium (H & E, original x256). C) Biopsy 10 months later reveals continued papillary configuration as well as koilocytic changes; however, there is increase in nucleus-cytoplasm ratio, loss of cellular maturation toward surface, and marked presence of mitotic figures consistent with findings of severe atypia (H & E, original x64). (Continued on next page.)

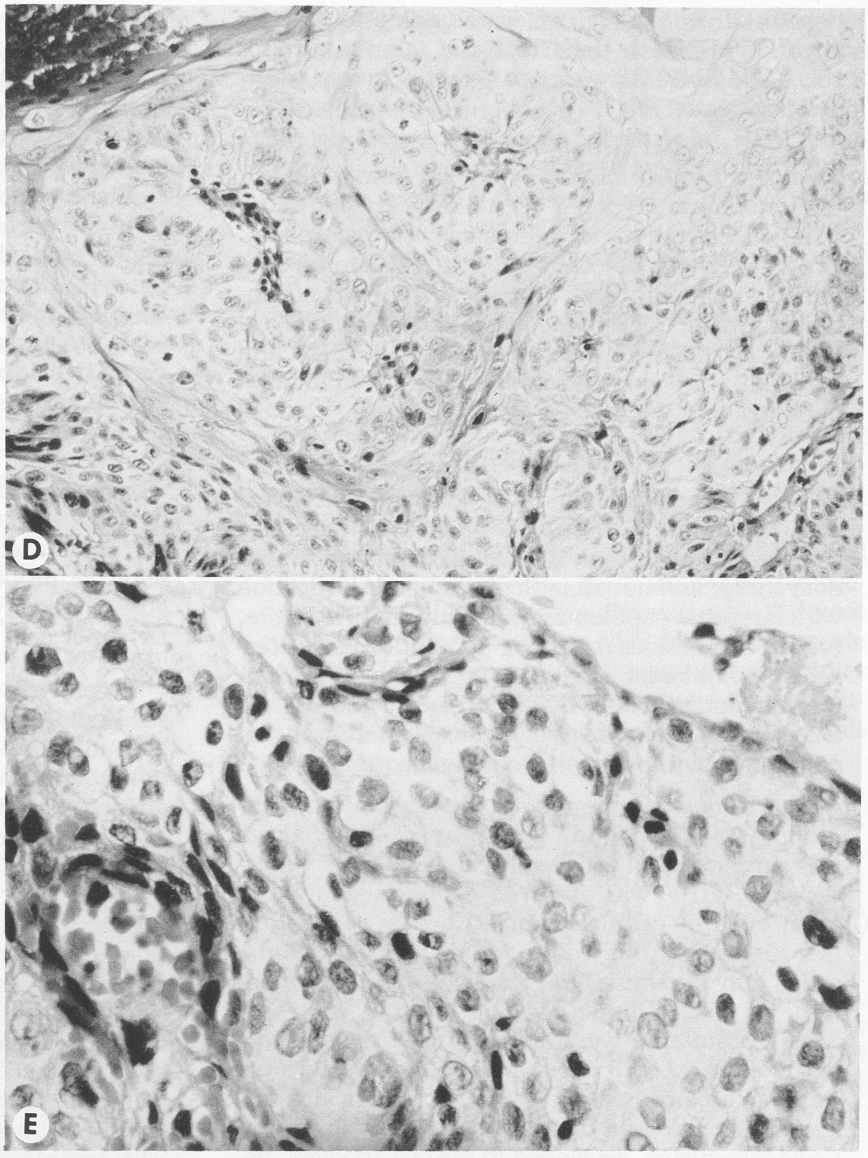

(Continued.) D,E) Biopsy 12 months following initial presentation. There is continued presence of papillary configurations with koilocytic changes; however, there is now complete loss of transepithelial maturation as well as loss of nuclear polarity consistent with carcinoma in situ. D) Low-power view (H & E, original x64). E) High-power view (H & E, original x200).

gamma globulin. She had diffuse low tracheal involvement further complicated by staphylococcal pneumonias secondary to bronchial obstruction by papillomas. At the age of 10 she complained of solid food dysphagia and was noted to have papillomas in the esophagus that were confirmed on biopsies. Three years later they disappeared without further treatment. Laryngeal and tracheal biopsies have shown mild focal atypia. She was decannulated 3 years ago and has persistent laryngeal papillomas.

Patients 15 and 19 have similar histories of extremely resistant disease. Both patients were treated with interferon in the past and both have had tracheotomies. Both patients appear to be in a state of clinical remission, are decannulated, and have mild laryngeal disease. Several biopsies in the past were noted for areas of mild atypia.

Patient 18 presented at the age of 3 with laryngeal disease that initially required frequent removal. The patient's further clinical history is quite different, however, from that of the above six patients, and she is not considered part of the group with aggressive juvenile laryngeal papillomatosis. It appears that after the onset of puberty her disease was markedly reduced in severity but persistent, and she required excision every 1 to 2 years as an adult. At the age of 52, she developed a T1N0 squamous cell carcinoma of the larynx, confirmed on two separate biopsies. This was treated with radiotherapy in 1988. At present, she continues with occasional benign laryngeal papillomas.

RESULTS

Adult-Onset Group. Of the nine patients, three had epithelial transformation. One patient developed severe atypia, while two patients developed CIS. In situ hybridization revealed the presence of HPV group 6/11 in every sample except for the CIS tissue of patient 5. Group 6/11 was detected in the tissue of patient 5 prior to his epithelial transforma-

tion to CIS; however, we were unable to identify any HPV DNA in the CIS tissue sample. Groups 16/18 and 31/33/35 were not detected in any adult-onset patients.

Juvenile-Onset Group. Of the 11 patients, 7 had epithelial transformation — 3 with mild atypia, 1 with moderate atypia, 2 with severe atypia, and 1 with a conversion to squamous cell carcinoma. Group 6/11 was detected in all tissue samples submitted, including that of patient 18, which contained squamous cell carcinoma, and the esophageal biopsy specimen of patient 14. Groups 16/18 and 31/33/35 were not detected in any juvenile-onset patients.

DISCUSSION

This study consisted of 20 patients with laryngeal papillomatosis, 10 of whom underwent epithelial transformation of their disease. This was not a random study, and not all patients from our institution with laryngeal papillomas were included. Therefore, further conclusions regarding population characteristics cannot be inferred from these data. It is of interest to note, though, that 2 patients (9 and 10) had tracheobronchial spread of their original laryngeal papillomas without a previous tracheotomy.

There are several reports in the literature of papilloma viral detection in both laryngeal papillomas and carcinomas of the head and neck.[4-8,21,23-30] Historically, HPV was observed by microscopy, and manifested by cellular changes such as koilocytosis (see Figure, B), but this histologic change within a cell is only circumstantial evidence of a viral infection. In 1923 Ullman,[1] in an attempt to satisfy Koch's postulates, was able to transfer the etiologic agent of laryngeal papillomas in vivo. However, growth and multiplication of HPV using in vitro tissue culture has been relatively unsuccessful. Immunocytochemistry, developed in the last 10 years, depends on antibodies against the capsid antigens of HPV or mature HPV virions for viral detection. A positive reaction to immunocytochemistry, however, may require several hundred virions per cell and hence the procedure is not very sensitive.

In 1975 Southern[31] developed a method to test DNA homology using a principle that two complementary DNAs with 50% or more homology will form a pair. The original method required fresh tissue and extraction of all DNA from the cells before the presence of viral DNA could be detected. When the tissue consisted of more than one cell type or more than one lesion, the localization of HPV was unknown. Furthermore, HPV DNA is easily diluted in this method and undetected when the tissue sample is small. Even with these limitations, however, the Southern technique still remains the gold standard to which all other methods are compared for their accuracy and sensitivity.

In the early 1980s a technique called in situ hybridization was developed that allowed for the identification of papilloma DNA within cells.[32] This is in contrast to the method of Southern, which required DNA extraction from the cell before identification. An advantage of in situ hybridization is that it can be performed on archival material that is fixed and embedded in paraffin. The cells, once removed from the paraffin, are mounted on slides with glue and treated with enzymes to expose the DNA within the cell. The cells are then heated as in the original Southern method to allow the DNA to separate into unpaired chains. The now-separated DNA may undergo hybridization by pairing with an introduced known and radioactive-labeled DNA papilloma sequence (probe). Unhybridized probes are removed and successful hybridization is identified by autoradiographic methods. Sensitivity of successful probe hybridization varies with the type of radioactive label used in autoradiographic detection. The most sensitive probe is a tritiated labeled probe that is able to identify as few as three to five copies of viral DNA per cell.

Recently, a second technique for identification of successfully hybridized probes has been introduced. This method involves labeling various probes with nonradioactive biotin (vitamin B12) and then taking advantage of the specific and tenacious interaction between biotin and enzyme-labeled avidin (a product of egg whites). In this case, the enzyme-labeled avidin becomes attached to biotin and then signals a successful hybridization with the enzymatic formation of a colored dye product. The technique is faster and easier than autoradiography and is thought to be sensitive to 10 to 15 copies of DNA per cell. This simplification allows for wider use of papilloma identification, since it does not require specialized equipment for the manufacturing of radiolabeled probes or equipment for autoradiography. This technique proved to be sensitive in this study, with the identification of viral DNA in 23 of the 24 samples submitted for analysis.

Specific trends of HPV infection have been established by applying the techniques of viral identification to genital lesions. Studies have shown that HPV group 16/18 detected in uterine cervical epithelium is more than likely to be associated with changes of severe nuclear atypia and squamous cell carcinoma and may prognosticate the epithelial transformation to more aggressive biologic behavior.[13-15,17] Group 31/33/35 is also associated with high grades of epithelial atypia in the female genital tract and is overall intermediate in risk for malignant transformation, while group 6/11 appears to be associated with benign disease or low-grade atypia of the uterine cervix.[14-16] Therefore, advanced viral typing of cervical lesions with in situ hybridization presents a useful tool to determine those patients at higher risk for epithelial transformation to high grades of atypia or carcinoma.

In reviewing the otolaryngologic literature, HPV group 6/11 has been found in benign laryngeal papillomas, while HPV group 16/18 has been isolated from various carcinomas of the head and neck.[4-7,21,23-30] Human papillomavirus 30 was isolated once from a laryngeal squamous cell carcinoma.[8] No previous study to our knowledge has tested for the presence of HPV 31/33/35 in the larynx. An HPV 30 probe was not available at our institution and therefore was not used in this study. It was anticipated that if HPV 30 was present in the laryngeal biopsies it would be recognized by its cross-reactivity to the 31/33/35 group probe.

The literature cites just 4 patients (2 adult and 2 juvenile), to our knowledge, without a previous history of radiotherapy who have undergone epithelial transformation of their laryngeal papillomas and have had successful identification of their infecting viral type.[24-26] Two patients (juvenile-onset) developed squamous cell carcinoma, and 2 others (both adult-onset) had mild dysplasia. This study adds an additional 10 patients with epithelial transformation of their laryngeal disease without previous radiotherapy. All 14 patients were infected by HPV group 6/11, the same infecting viral group seen in patients without epithelial transformation of their laryngeal disease.[3,21,26,27]

It has been suggested that one mode of transmission of the papillomavirus to the larynx is through the birth canal. This was demonstrated by an earlier study from this institution, with a reported high prevalence of genital condylomata in mothers of children with benign juvenile laryngeal papillomatosis.[11] If this theory is true, it would be expected that HPV group 16/18 or HPV group 31/33/35 would be identified in some laryngeal papillomas because of the fairly high prevalence of these viral groups in the uterine cervix, particularly HPV group 16/18.[15,33] From reviewing the literature, we know of 18 additional patients who were tested for the presence of both HPV groups 6/11 and 16/18.[21,25,26] These 18 patients along with the 20 patients from this study have all proven negative for HPV group 16/18. To our knowledge there are no reports in the literature revealing the identification of HPV group 16/18 or HPV group 31/33/35 in laryngeal papillomas. Therefore, at this time we feel the theory of birth canal transmission is unproven, since it would seem likely that HPV group 16/18 would have been detected in 1 of these 38 patients with laryngeal papillomatosis.

At this point, it appears as though the infecting HPV group has little influence on the clinical outcome in patients with laryngeal papillomatosis. This is in direct contrast to uterine cervical infections by the papillomavirus. Although HPV 6 and HPV 11 are approximately 85% similar in their genetic structure, it is possible that a slightly different strain from this viral group with greater oncogenic potential is responsible for the greater morbidity seen in certain patients with laryngeal disease. Future studies may need to look specifically at this possibility.

We conclude, first, that the in situ hybridization technique employing biotin-labeled probes is a sensitive method to detect viral DNA in laryngeal biopsy specimens. Second, HPV 6/11 is associated with severe nuclear atypia, CIS, and squamous cell carcinomas in patients with laryngeal papillomas, but in this study clinical outcome of disease in the larynx is not influenced by the infecting viral group as seen in the uterine cervix. Groups 16/18 and 31/33/35 have not been found to be associated with laryngeal papillomas or papillomas that have undergone epithelial transformation.

REFERENCES

1. Ullman EV. On the etiology of the laryngeal papilloma. Acta Otolaryngol (Stockh) 1923;5:317-38.

2. Boyle WF, Riggs JL, Oshiro LS, Lennette EH. Electron microscopic identification of papova virus in laryngeal papilloma. Laryngoscope 1973;83:1102-8.

3. Mounts P, Shah KV, Kashima H. Viral etiology of juvenile and adult onset squamous papilloma of the larynx. Proc Natl Acad Sci USA 1982;79:5425-9.

4. Hoshikawa T, Nakajima T, Uhara H, et al. Detection of human papillomavirus DNA in laryngeal squamous cell carcinomas by polymerase chain reaction. Laryngoscope 1990;100:647-50.

5. Dekmezian RH, Batsakis JG, Goepfert H. In situ hybridization of papillomavirus DNA in head and neck squamous cell carcinomas. Arch Otolaryngol Head Neck Surg 1987;113:819-21.

6. Ishibashi T, Matsushima S, Tsunokawa Y, et al. Human papillomavirus DNA in squamous cell carcinoma of the upper aerodigestive tract. Arch Otolaryngol Head Neck Surg 1990;116: 294-8.

7. Abramson AL, Brandsma J, Steinberg B, Winkler B. Verrucous carcinoma of the larynx. Possible human papillomavirus etiology. Arch Otolaryngol 1985;111:709-15.

8. Kahn T, Schwarz E, zur Hausen H. Molecular cloning and characterization of the DNA of a new human papillomavirus (HPV 30) from a laryngeal carcinoma. Int J Cancer 1986;37:61-5.

9. Singer A, Campion MJ, McCance DJ. Human papillomavirus. Br J Hosp Med 1985;34:104-8.

10. Pfister H. Human papillomavirus and genital cancer. Adv Cancer Res 1987;48:113-47.

11. Quick CA, Watts SL, Krzyzek RA, Faras AJ. Relationship between condylomata and laryngeal papillomata. Clinical and molecular virological evidence. Ann Otol Rhinol Laryngol 1980; 89:467-71.

12. Barnes W, Delgado G, Kurman RJ, et al. Possible prognostic significance of human papillomavirus type in cervical cancer. Gynecol Oncol 1988;29:267-73.

13. Fuchs PG, Girardi F, Pfister H. Human papillomavirus DNA in normal, metaplastic, preneoplastic and neoplastic epithelia of the cervix uteri. Int J Cancer 1988;41:41-5.

14. Lorincz AT, Temple GF, Kurman RJ, Jensen AB, Lancaster WD. Oncogenic association of specific human papillomavirus types with cervical neoplasia. J Natl Cancer Inst 1987;79:671-6.

15. Reid R, Greenberg M, Jensen AB, et al. Sexually transmitted papillomavirus infections. Am J Obstet Gynecol 1987;156: 212-22.

16. Meanwell CA, Blackledge G, Cox MF, Maitland NJ. HPV 16 DNA in normal and malignant cervical epithelium: implications for the aetiology and behaviour of cervical neoplasia. Lancet 1987;1:703-7.

17. Durst M, Gissmann L, Ikenberg H, zur Hausen H. A papillomavirus DNA from a cervical carcinoma and its prevalence in cancer biopsy samples from different geographic regions. Proc Natl Acad Sci USA 1983;80:3812-5.

18. Boshart M, Gissmann L, Ikenberg H, Kleinheinz A, Scheurlen W, zur Hausen H. A new type of papillomavirus DNA, its presence in genital cancer biopsies and in cell lines derived from cervical cancer. EMBO J 1984;3:1151-7.

19. Majoros M, Devine KD, Parkhill EM. Malignant transformation of benign laryngeal papillomas in children after radiation therapy. Surg Clin North Am 1963;43:1049-61.

20. Toso G. Epithelial papillomas — benign or malignant? Interesting findings in laryngeal papilloma. Laryngoscope 1971; 81:1524-31.

21. Corbitt G, Zarod AP, Arrand JR, Longson M, Farrington WT. Human papillomavirus genotypes associated with laryngeal papilloma. J Clin Pathol 1988;41:284-8.

22. Unger ER, Budgeon LR, Myerson D, Brigati DJ. Viral diagnosis by in situ hybridization. Am J Surg Pathol 1986;10:1-8.

23. Kashima H, Wu T-C, Mounts P, Heffner D, Cachay A, Hyams V. Carcinoma ex-papilloma: histologic and virologic studies in whole-organ sections of the larynx. Laryngoscope 1988;98: 619-24.

24. Byrne JC, Ming-Sound T, Fraser RS, Howley PM. Human papillomavirus-11 DNA in a patient with chronic laryngotracheobronchial papillomatosis and metastatic squamous-cell carcinoma of the lung. N Engl J Med 1987;317:873-8.

25. Lindeberg H, Syrjanen S, Karja J, Syrjanen K. Human papillomavirus type 11 DNA in squamous cell carcinomas and preexisting multiple laryngeal papillomas. Acta Otolaryngol (Stockh) 1989;107:141-9.

26. Duggan MA, Lim M, Gill MJ, Masafumi I. HPV DNA typing of adult-onset respiratory papillomatosis. Laryngoscope 1990;100:639-42.

27. Quiney RE, Wells M, Lewis FA, Terry RM, Michaels L, Croft CB. Laryngeal papillomatosis: correlation between severity of disease and presence of HPV 6 and 11 detected by in situ DNA hybridization. J Clin Pathol 1989;42:694-8.

28. Tsutsumi K, Nakajima T, Gotoh M, et al. In situ hybridization and immunohistochemical study of human papillomavirus infection in adult laryngeal papillomas. Laryngoscope 1989;99: 80-5.

29. Kerley SW, Buchon-Zalles C, Moran J, Fishback JL. Chronic cavitary respiratory papillomatosis. Arch Pathol Lab Med 1989;113:1166-9.

30. Schnadig VJ, Clark WD, Clegg TJ, Yao CS. Invasive papillomatosis and squamous carcinoma complicating juvenile laryngeal papillomatosis. Arch Otolaryngol Head Neck Surg 1986;112: 966-71.

31. Southern EM. Detection of specific sequences among DNA fragments separated by gel electrophoresis. J Mol Biol 1975;98: 503-20.

32. Wagner D, Ikenberg H, Boehm N, Gissman L. Identification of human papillomavirus in cervical swabs by deoxyribonucleic acid in situ hybridization. Obstet Gynecol 1984;64:767-72.

33. Tidy JA, Parry GCN, Ward P, et al. High rate of human papillomavirus type 16 infection in cytologically normal cervices [Letter]. Lancet 1989;1:434.

COLLAGEN IN THE DEVELOPING LARYNX
PRELIMINARY STUDY

SEYMOUR R. COHEN, MS, MD
LOS ANGELES, CALIFORNIA

DAVID T. CHEUNG, PHD
LOS ANGELES, CALIFORNIA

MARCEL E. NIMNI, PHD
LOS ANGELES, CALIFORNIA

VLADIMIR MAHNOVSKI, MD
LOS ANGELES, CALIFORNIA

GRACE LIAN, MD
LOS ANGELES, CALIFORNIA

NATASHA PERELMAN
LOS ANGELES, CALIFORNIA

ALFONZO P. CARRANZA, MD
SAN JOSE, COSTA RICA

The primary purpose of this study was to determine the types of collagen in the developing human larynx that contribute to the structural framework and function of various components of this organ. The infant larynx is much more than a mere miniature of the adult "voice box." There are many age-related differences that occur in the larynx from the newborn period to the adult period of life. While collagen has been studied in numerous tissues, both normal and diseased, there have been no studies of the whole organ content, types, and/or changes of collagen in the developing human larynx that may account for many of the clinical findings. This study may at least in part explain whether collagen differences may account for the structural changes and responses that are seen in clinical practice.

KEY WORDS — cartilage, collagen, connective tissue, development, larynx.

INTRODUCTION

The cellular histology of the adult human larynx has been well documented. Greater interest has been shown in the epithelial structures than in the other laryngeal connective tissues. Little has been reported regarding the biochemistry of the supporting laryngeal cartilaginous and soft tissue framework. Further, little has been written about the biochemical changes in these tissues during the growth and development of the larynx.

There is a paucity of knowledge about the true cause of changes in the response of the infant larynx to trauma and disease as compared to the changes found in the maturing larynx. Still remaining to be explained is why these responses subside and why an anomaly such as laryngomalacia reverts to normal with growth and development.

The purpose of this preliminary study is to evaluate the collagen content of selected cartilages of the normal developing human laryngeal framework as to type and quantity. An understanding of the normal biochemical makeup of laryngeal connective tissue may be essential in order to prevent and treat the devastating effects of trauma and other diseases on the larynx.

Collagen is extremely important in the growth, development, repair, regeneration, and structural integrity of the laryngeal framework. Collagen is very distinctive in that it forms insoluble fibers with a very high tensile strength. It is the most common and abundant mammalian protein and accounts for 30% of all proteins in the body.[1]

The term collagen is derived from Greek words meaning "to produce glue," and collagen is present in all organs of the body. It serves as a scaffolding that holds cells together. Connective tissues form the architectural framework of the vertebrate body. As a major fibrous element of skin, bone, cartilage, blood vessels, and teeth, collagen has been extensively studied. However, whole organ studies have not been common and there are no studies reported of this connective tissue element in the larynx, which depends upon this protein substance for the integrity of its cartilaginous framework. The high tensile strength of most organs (eg, skin) is due to the presence of collagen, a fibrous protein.

Histologically, cartilages of the larynx have been determined to be hyaline, except for the epiglottis, which is elastic fibrocartilage.

In the last two decades it has become apparent that not all collagen molecules are alike. Type II collagen, which is the sole component of hyaline cartilage, was

From the Departments of Otolaryngology (Cohen) and Pathology (Mahnovski), Children's Hospital of Los Angeles, and the Departments of Biochemistry (Cheung, Nimni, Lian, Perelman) and Pathology (Mahnovski), University of Southern California, Los Angeles, California, and the Department of Pathology, National Children's Hospital, San Jose, Costa Rica (Carranza). This research was funded by a grant from the Seymour R. and Odelia A. Cohen Medical Foundation.

Presented at the meeting of the American Laryngological Association, Waikoloa, Hawaii, May 4-5, 1991.

REPRINTS — Seymour R. Cohen, MS, MD, 4301 Cromwell Ave, Los Angeles, CA 90027.

the first tissue-specific collagen to be described. In contrast to the more ubiquitous type I collagen, present in bone, skin, and most organs, it contains three identical polypeptide chains that are highly glycosylated. Since then, around 14 different types of collagens have been described in human tissues. Fibrocartilage, in contrast with hyaline cartilage, contains type I collagen.

BIOCHEMISTRY OF COLLAGEN

One of the functions of protein is its structural role.[1,2] Since disease is associated with excessive accumulation of collagen leading to various forms of fibrosis, an understanding of the normal collagen content and typing is essential.

Each collagen seems to have a specific purpose, although this has not yet been completely elucidated. The extracellular matrix was thought to serve mainly as a relatively inert scaffolding that stabilizes the physical structure of tissues. It is now clear that the matrix plays a more active and complex role in regulating the behavior of the cells that contact it.[3,4] The extracellular matrix is composed primarily of fibrous proteins embedded in a hydrated polysaccharide gel. In most connective tissues these macromolecules are secreted largely by fibroblasts. There are two more classes of extracellular macromolecules that make up the matrix: 1) polysaccharide glycosaminoglycans and 2) fibrous proteins. Of the proteins, collagen and elastin are mainly structural, and fibronectic and laminin are mainly adhesive.[2-4] This study deals only with collagen, the major protein of the extracellular matrix.

Collagen is a family of highly characteristic fibrous proteins found in all multicellular animals.[1,3,4] The collagen molecules are stiff, triple-stranded helical structures. Three collagen polypeptide chains called α chains (each about 1,000 amino acids long) are wound around one another in a regular superhelix to generate a ropelike collagen molecule about 300 nm long and 1.5 nm in diameter. The collagens are rich in proline, hydroxyproline, and glycine, which are very important in the formation of a triple-stranded helix. Glycine is the smallest amino acid, regularly spaced at every third residue. Proline and hydroxyproline, because of their ring structures, stabilize a left-handed helical conformation in each α chain, with three amino acid residues per turn. Throughout the central region of the α chain, proline allows the three helical α chains to pack tightly together to form the final collagen superhelix.

As mentioned, many distinct collagen α chains have been identified, each encoded by a separate gene. Different combinations of these genes are expressed in different tissues. To date, about 14 types of collagen have been recognized, each a distinct protein product from one or more genes.[3,4] The best-defined of the collagen types and the most relevant to these studies are types I, II, III, and IV.

Types I, II, and III are the fibrillar collagens and are the main types found in connective tissue. Type I collagen is the most common by far and is found in skin, tendon, bone, ligaments, cornea, and internal organs. It comprises about 90% of body collagen. Type II collagen is found in hyaline cartilage, the intervertebral disc, the notochord, and the vitreous body of the eye. Type III collagen is found in skin, blood vessels, and internal organs. Type IV collagen (a nonfibrillar type) is found in the basal lamina. It is important that the organization of collagen fibrils in the extracellular matrix is adapted to the needs of the tissue.[2]

TYPES OF COLLAGEN

Type I collagen is the most prevalent type in the vertebrate organism. The major molecular species of type I collagen is a heterotrimer consisting of two identical α1 chains and a simple α2 chain. Electron immunohistochemical localization of type I collagen in a variety of tissues typically shows cross-banded fibers with an average diameter of 40 to 60 nm and characteristic cross banding at 67-nm intervals. Type I collagen is often found associated with other types of collagen (types III, V, and VI), as well as other noncollagenous proteins in several major non-cartilaginous connective tissues.[5]

Type II collagen is the cartilaginous counterpart to type I collagen and is the predominant collagen found in hyaline cartilage. The type II collagen molecule is a homotrimer consisting of three α chains. The type II collagen molecule interacts with other cartilage proteins (proteoglycans, structural glycoproteins, and type IX, X, and XI collagens) to form the cartilage matrix. Type II collagen also forms fibrous elements in other tissues such as the notocord, the nucleus pulposus, and the vitreous humor of the eye.[5]

Type III collagen is found in association with larger type I fibers in the more distensible connective tissues such as the dermis and arteries.

Type IV collagen is localized to all basement membranes and is known as the basement membrane collagen. Aggregates of this type of collagen form a loose network, rather than fibers, because of the presence of nonhelical domains.

MATERIALS AND METHODS

Tritium-labeled sodium borohydride (^{3}H-NaBH4;

9.5 Ci/mmol) was purchased from Amersham (Arlington Heights, Ill), and sequenal grade dimethylformamide was purchased from Pierce Chemical Co (Rockford, Ill).

Selection and Identification of Tissue Samples. Whole organ autopsy specimens of the larynx were collected, including, whenever available, portions of the body of the hyoid and the attached upper three tracheal rings. The specimen was wrapped to prevent potential drying and immediately frozen and stored at −70°C. The age of the patient at the time of death, regardless of cause, was documented. After defrosting, the specimens were immediately and carefully dissected to remove all external musculature so as to anatomically outline the cartilaginous framework of the larynx, and in some instances the hyoid and upper tracheal cartilages. Each structure was then sampled for biopsy: a sliver of cartilage was removed and immediately placed into a vial containing chloroform-methanol (50/50, vol/vol), and the specimens were refrigerated at temperatures of 2°C to 6°C pending transfer to the biochemical laboratory. In each specimen the sliver of cartilage was obtained as follows.

1. From the epiglottis at its superior tip by a transverse cut.
2. From the thyroid lamina at its most lateral margin.
3. From the cricoid by a sliver taken from the lamina.
4. From the arytenoid by removing a portion of its muscular process.

The remaining structures — the trachea, true vocal cord, false vocal cord, and center of the body of the hyoid — were all stored for further studies.

Preparation of Tissues. The tissues (10 to 20 mg wet weight) were extracted with chloroform-methanol (50/50, vol/vol) to remove fat. The tissues were then washed with methanol to remove the chloroform, and saline was used to remove the methanol. The tissues were then extracted with 4 mol/L guanidine to remove proteoglycans. The extracted tissues, consisting mainly of collagen, were then washed with saline to remove the guanidine before cyanogen bromide (CNBr) digestion.

CNBr Digestion. The procedure used was that of Miller.[6] Samples (10 mg wet weight) were digested in 0.8 mL of nitrogen-purged formic acid containing 40 mg CNBr for 4 hours at 30°C. The mixtures were diluted tenfold with water by volume and lyophilized twice at the end of the digestion to remove excess CNBr.

^{3}H-NaBH4/Dimethylformamide Labeling of CNBr Peptides. The method used to label proteins with ^{3}H by methylation of amino acid groups was modified by a procedure previously described by Cheung et al.[7] The CNBr derived from defatted tissues or purified collagen preparation (25 mg dry weight) was lyophilized to dryness and suspended in 0.2 to 0.5 mL of sequenal-grade dimethylformamide. A 0.02-mL aliquot of ^{3}H-NaBH4 (100 mCi/mL, in dimethylformamide) was added to each sample, which was vigorously mixed and then allowed to stand for 2 hours. The labeling reaction was terminated by adding 0.5 mL of 0.5 mol/L acetic acid. The free label was removed by desalting on a Bio-gel P-2 column with 0.1 mol/L acetic acid (column volume, 30 mL; fraction volume, 0.5 mL). The void volume peak containing radioactive peptides was collected and lyophilized.

Mercaptoethanol Reduction of CNBr Peptides and Second CNBr Digestion. Radioactively labeled CNBr peptides were subjected to overnight reduction at 55°C in the presence of 25% mercaptoethanol in 0.1 mol/L ammonium carbonate. Samples were then diluted with a fourfold volume of water (final mercaptoethanol concentration, 5%). The mercaptoethanol was then removed by desalting the diluted samples on a P-2 column as described above.

2-D Isoelectric Focusing and NaDodSO4 Electrophoresis Mapping of ^{3}H-NaBH4 CNBr Peptides. The technique was described by Benya.[8] The CNBr peptide samples that were dissolved in urea and amphiline containing sample buffer were subjected to isoelectric focusing in polyacrylamide focusing tube gels. The first dimensional gel was then removed from the tube and cast on top of the second dimensional slab gel and electrophoresed in the presence of sodium dodecosulfate. The resulting maps were either stained with a copper sulfate containing Coomassie blue and then destained with 35% methanol, or processed for fluorography.[8]

Quantitative Analysis of Fluorographs From Two-Dimensional Maps. Some x-ray films were preexposed to yield a background of 0.15 optical density at 600 nm after being developed. These films were then exposed to processed two-dimensional (2-D) maps for various lengths of time at −70°C. The films were developed in a Kodak X-omatic developer and then scanned on a Bioimage Visage-60 2-D densitometer-integrator.

RESULTS

We analyzed the distributions of type I, II, and III collagens by 2-D CNBr peptide mapping in the thyroid lamina, cricoid cartilage, arytenoid, and epiglottis of the developing larynges obtained at autopsy from subjects 1 day, 9 days, 1 month, 7 months, 18

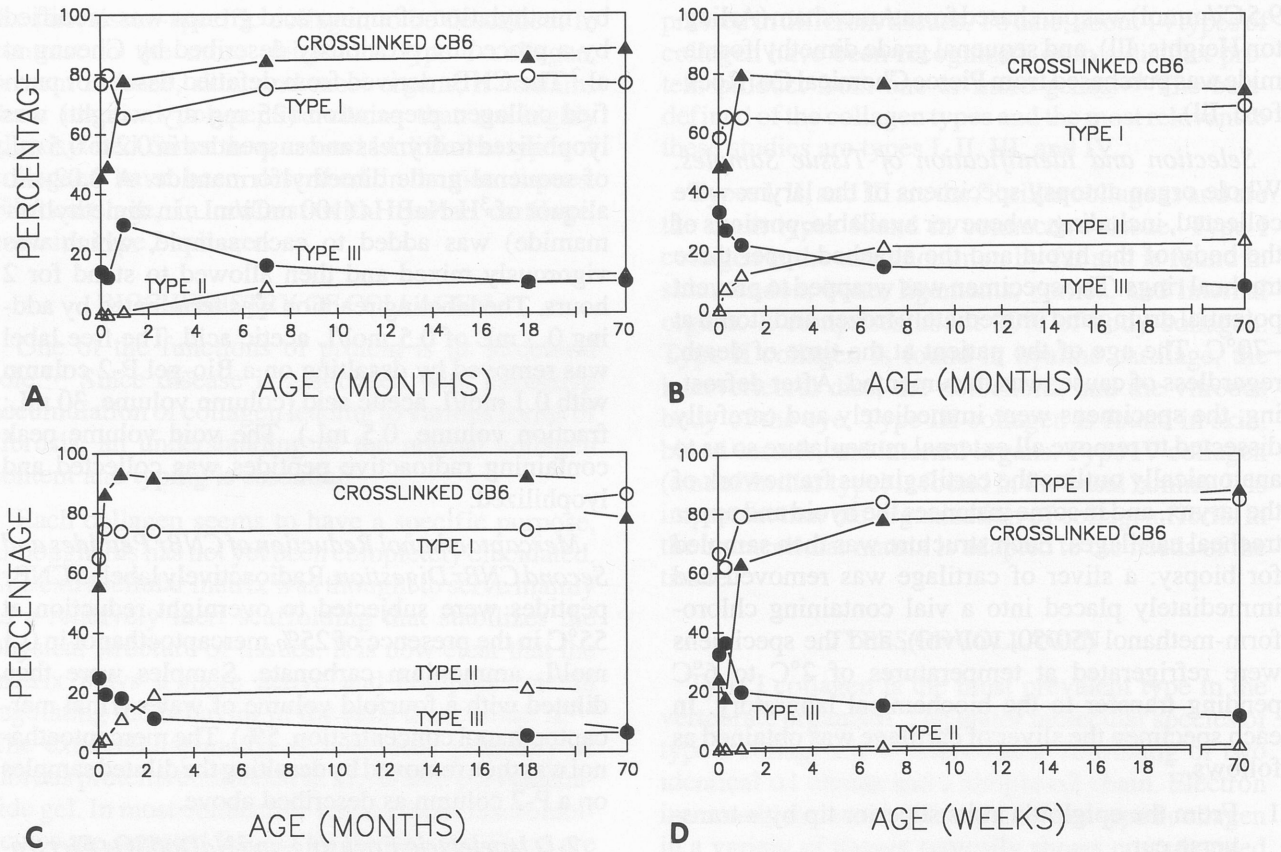

Distributions of collagen types and collagen cross-linking at ages studied. A) Epiglottis. B) Cricoid cartilage. C) Thyroid lamina. D) Arytenoid.

months, and 70 months old. The degree of collagen cross-linking was also analyzed by measuring the amount of non–cross-linked type I C-terminal CNBr peptide α1-CB6 in each sample.

Epiglottis. The changes of the distributions of type I, II, and III collagens during early development in this tissue are shown in the Figure, A. Type I, a major collagen type in most connective tissues except cartilages, was found to be the major type of collagen in the epiglottis at birth, and this percentage was maintained at levels of 70% and 80% throughout the first 70 months of life. Type II collagen, the major collagen type found in articular and hyaline cartilage, was absent in the epiglottis at birth. This collagen (type II) first appeared at 1 month of age and gradually increased to about 12% at 70 months of age. At birth, type III collagen (a type present in higher amounts in fetal as well as vascular tissues) was present in levels of 15%, but increased to about 30%, following which it gradually diminished to about 10% at 70 months of age. At birth, approximately 45% of type I α1 chains were cross-linked at the C-terminal end, since only 55% of the free peptide was observed in the 2-D maps. Cross-linking increased rapidly after birth, and about 80% of the α1 chains were cross-linked after 1 month of age.

Cricoid Cartilage. Distributions of type I, II, and III collagens in the cricoid cartilage from specimens at the various ages studied are shown in the Figure, B. Type I collagen was also found to be the major collagen type (between 60% ad 65%) from 1 day to 70 months, but at a lower level than that found in the epiglottis. At birth, type II collagen was absent and there was about 34% of type III collagen. Type II collagen appeared soon after birth (7.5% at 9 days of age) and increased rapidly during the first month, after which it reached 21.6% at 7 months of age. Type III collagen was present at levels of 33% at birth in this tissue, but decreased rapidly to 22% at 1 month of age. This percentage continued to drop to 10% at 70 months of age. The rapid loss of α1-CB6 of type I collagen in this tissue also indicates that cross-linking of collagen occurs quickly after birth.

Thyroid Lamina. The distributions of type I, II, and III collagens in the thyroid lamina during early development are shown in the Figure, C. Type I collagen was, again, found to be the major collagen type, with increases from 64% to 84% throughout the early neonatal development of the thyroid lamina. Type II collagen was present at a very low level (4%) at birth, but increased to about 20% at 2 months of age. This level was maintained until 18 months of age, but

dropped to about 8% at 70 months of age. Type III collagen decreased from 25% at birth to 7% at 7 months of age. Cross-linking of collagen was also found to occur rapidly during the first month of life.

Arytenoid. The changes in distributions of type I, II, and III collagens in the arytenoid during the early development of the larynx are shown in the Figure, D. Unlike the other tissues described above, type II collagen was not found in the arytenoid from birth to 70 months of age. However, type I collagen increased from 65% to 80% during the first month of life and was maintained at this level up to the age of 70 months. Type III collagen was present at birth at levels of 35%, decreased to 20% rapidly during the first month of age, and continued to drop to 12% at 70 months of age. Cross-linking of collagen was also found to occur rapidly during the first month of life in this tissue.

SUMMARY

Type I collagen was the major component found in all four cartilaginous structures analyzed. However, a small percentage of type II collagen was found in the thyroid lamina. Type II collagen was absent at birth in all laryngeal cartilages analyzed. Type III collagen was found in concentrations of 15% to 35% in all of the laryngeal cartilages at birth. It is also evident that significant amounts of collagen are already cross-linked at birth.

A dynamic change in the distribution of the different types of collagen and an increase of cross-linking of type I collagen occur within the first month of life in all four components of the larynx analyzed. Cross-linking is a part of the maturation process of collagen and is very important to the stability and mechanical properties of the collagenous tissues. No significant amount of type II collagen is present in the arytenoid cartilage. While type II collagen increases in concentration to 20% in both the cricoid cartilage and the thyroid lamina at 7 months of age, it was found to remain at this level in the cricoid cartilage for up to 70 months of age. However, type II collagen drops to 8% within the thyroid lamina. Type III collagen decreases to levels below 10% as the larynx passes its neonatal development.

CONCLUSIONS

This preliminary study establishes the types and quantities of fibrillar collagens present during the early growth and development of the laryngeal cartilaginous framework. The study does not attempt to correlate these findings with any clinical aspects of laryngeal disease. It is obvious from these studies that collagen is in a constant state of flux during laryngeal growth and development.

In progress are studies that will include information regarding 1) sex variations, if any; 2) hormonal changes at puberty; 3) trauma; 4) infection; 5) congenital anomalies; 6) autoimmune disease; 7) the aging process; and 8) tissue distribution and localization by using immunohistochemical methods.

Also in progress and soon to be completed are evaluations of the collagen content of the tracheal rings, hyoid bone, true vocal cords, false vocal cords, and the aryepiglottic folds. Also in progress are electron microscopy and immunochemistry studies.

Histologically, the laryngeal cartilages are considered hyaline-type cartilage, yet biochemically these cartilages do not have the type II collagen commonly associated with this type of cartilage.

REFERENCES

1. Nimni M. Collagen: structure, function and metabolism in normal and fibrotic tissues. Semin Arthritis Rheum 1983;13:1-30.

2. Alberts B, Bray D, Lewis J, Raff M, Roberts K, Watson JD. Molecular biology of the cell. 2nd ed. New York, NY: Garland, 1989:808-34.

3. Nimni ME, Cheung D, Strates B, Cheikh K. Biochemistry, biomechanics and biotechnology. In: Nimni ME, ed. Bioprosthesis derived from cross-linked and chemically modified collagenous tissues in collagen. Boca Raton, Fla: CRC Press, 1988:1-38. (Collagen; vol 1.)

4. Stewart TE, Gay RE, Gay S. The collagens. In: Lindh E, Thorell JI, eds. Clinical impact of bone and connective tissue markers. New York, NY: Harcourt Brace Jovanovich, 1989: 3-12.

5. Eyre DR, Muir H. Quantitative analysis of types I and II collagens in human intervertebrate discs at various ages. Biochim Biophys Acta 1977;492:29-42.

6. Miller EJ. Isolation and characterization of cyanogen bromide peptides from the alpha (1) (II) chain of chick cartilage collagen. Biochemistry 1971;10:3030-5.

7. Cheung DT, Benya PD, Gorn A, Nimni ME. An efficient method for in vitro labelling proteins to high specific radioactivity using ^{3}H-NaBH4 in dimethylformamide. Anal Biochem 1981;116:69-74.

8. Benya PD. Two dimensional CNBr peptide patterns of collagen types I, II and III. Coll Relat Res 1981;1:17-26.

STROBOVIDEOLARYNGOSCOPY: RESULTS AND CLINICAL VALUE

ROBERT T. SATALOFF, MD
JOSEPH R. SPIEGEL, MD MARY J. HAWKSHAW, RN
PHILADELPHIA, PENNSYLVANIA

Strobovideolaryngoscopy is a valuable addition to the diagnostic armamentarium because it allows the otolaryngologist to perform a detailed physical examination of the vibratory margin of the vocal fold. From 1985 through 1989, we performed 1,876 strobovideolaryngoscopy procedures, the majority on professional voice users. Previously, we reported findings on our first 486 strobovideolaryngoscopy procedures. Stroboscopic information influenced diagnosis or treatment in approximately one third. The present study was undertaken to determine whether additional experience had altered the clinical usefulness of the procedure. Diagnoses were noted before and after stroboscopy prospectively for 377 strobovideolaryngoscopy procedures performed during the calendar year 1989. In 53% of the procedures, strobovideolaryngoscopy resulted in no change in diagnosis. In 29%, preprocedure impressions were confirmed and additional diagnoses were made. In 18%, preprocedure diagnoses were found to be incorrect. The procedure has proven very helpful in caring for voice patients, modifying diagnoses in 47%, and confirming uncertain diagnoses in many of the other patients studied.

KEY WORDS — stroboscopy, strobovideolaryngoscopy, voice.

Complex motion of the vibratory margin of the vocal folds is essential for normal voice. Because the vocal folds open and close between about 60 and 1,500 times per second depending upon the pitch of phonation, valid, reliable physical examination of the vibratory margin cannot be accomplished by using continuous light and a laryngeal mirror. High-speed photography permits slow-motion evaluation of vocal fold vibration, but it is cumbersome. It also permits evaluation of only relatively short samples of phonation. High-speed video is not widely available and shares many disadvantages with high-speed photography. Strobovideolaryngoscopy is currently the most convenient technique permitting the otolaryngologist to perform a detailed assessment of the vibratory margin of the vocal fold. From 1985 through 1989, we performed 1,876 strobovideolaryngoscopy procedures. All strobovideolaryngoscopic examinations were performed by an otolaryngologist, usually with the assistance of a nurse, speech-language pathologist, and/or singing voice specialist. The majority were on professional voice users. Previously, we reported findings on our first 486 strobovideolaryngoscopy procedures.[1] Stroboscopic information influenced diagnosis or treatment in approximately one third of cases. The present study was undertaken to determine whether additional experience had altered the clinical usefulness of the procedure.

MATERIALS AND METHODS

Three hundred seventy-seven strobovideolaryngoscopy procedures were performed on 352 patients between January 1, 1989, and December 31, 1989. During that period, we saw 583 voice patients for a total of 1,180 voice-related visits. The 377 visits during which strobovideolaryngoscopy was performed comprised approximately 32% of voice patient visits, and stroboscopy was performed on 60% of the patients seen during that period. All patients were selected because of the presence or suspicion of a structural or neurologic abnormality, or to prove the absence of such a lesion. Of the 352 patients who underwent strobovideolaryngoscopy, the majority were professional voice users, and 129 of these were singers. The other patients also sought medical attention specifically for voice complaints.

All stroboscopic examinations were performed with a Bruel and Kjaer rhinolarynx stroboscope type 4914, with the patient seated. An Olympus flexible nasolaryngoscope and a magnifying telescope were used in virtually all cases. Initially, examinations were performed while looking directly into the laryngoscope before connecting it to the video system. In some cases, the laryngoscope was also connected to a Zeiss operating microscope using a custom-made adaptor, before strobovideolaryngoscopy. This technique provides high-quality magnification, which is especially helpful in those few patients who will not tolerate the laryngeal telescope. The flexible laryngoscope permits observation of vocal fold function under continuous and stroboscopic light during a variety of phonatory tasks, with relatively undistorted vocal tract anatomy. The magnification and high optical quality provided by a rigid laryngeal telescope are invaluable and obviate the need for magnification with an operating microscope in most cases. However, they permit vocal fold evaluation only during relatively awkward vocal tract positions and tasks. Simultaneous synchronized electroglottography was also performed, and the electroglottographic waveform

From the Department of Otolaryngology, Thomas Jefferson University (Sataloff, Spiegel), and the American Institute for Voice and Ear Research (Hawkshaw), Philadelphia, Pennsylvania.

Presented at the meeting of the American Laryngological Association, Waikoloa, Hawaii, May 4-5, 1991.

REPRINTS — Robert T. Sataloff, MD, 1721 Pine St, Philadelphia, PA 19103.

TABLE 1. FORTY ENTITIES OBSERVED DURING 377 STROBOVIDEOLARYNGOSCOPIC PROCEDURES

Diagnosis	*No. of Procedures*	*No. of Patients*
Arytenoid dislocation	2	2
Cancer	4	3
Cricothyroid fusion	1	1
Cysts	10	8
Dysarthria	1	1
Dysphonia	50	45
Dysphonia plica ventricularis	8	5
Functional dysphonia	9	9
Foreign body	1	1
Granuloma	3	3
Hemorrhage	30	26
Histoplasmosis	1	1
Hoarseness	2	2
Laryngeal spasm	7	2
Laryngitis	21	18
Leukoplakia	2	1
Lymphoid hyperplasia	2	1
Mass	87	86
Mucosal tear	6	6
Myasthenia gravis	3	3
Nerve paralysis or paresis	66	59
Nodules	34	32
Normal	7	5
Parkinson's disease	1	1
Polyp	6	4
Presbyphonia	12	10
Reflux laryngitis	186	165
Reinke's edema	10	4
Respiratory dysfunction	1	1
Sarcoidosis	1	1
Scar with stiffness	59	32
Subglottic stenosis	1	1
Temporomandibular joint syndrome	1	1
Tonsillitis	1	1
Trauma	4	3
Ulcer	1	1
Upper respiratory tract infection	1	1
Varicosity	11	10
Voice abuse*	133	126
Web	5	5

*Includes hypofunctional and hyperfunctional voice abuse, muscular tension dysphonia, and improper singing or speaking technique.

was superimposed on the laryngeal image. Electroglottography provides an assessment of each vibratory event. This is a valuable adjunct because the stroboscope only simulates slow motion by imaging fragments of successive vibratory cycles. All examinations were recorded on videotape and stored. Duplicates were made routinely for the referring physician, speech-language pathologist, singing teacher, or patient. Black and white and color video printers are also connected to the system for documentation and patient education.

Our videostroboscopy protocol involves speaking at various frequencies and intensities, pitch sliding, sniffing, whistling, rapid repetition of syllables, singing, sustained vowel phonation, and other selected tasks. Observations are recorded about voice quality, laryngeal color, vocal fold motion, vibratory margin motion, structural abnormalities, supraglottic muscle function, and other findings. Symmetry, periodicity, glottic closure, amplitudes, waveforms, and nonvibrating segments are assessed by using a modification of the format proposed by Hirano.[2] In all cases, prior to strobovideolaryngoscopy diagnoses were recorded based on clinical examination using a laryngeal mirror, and examination of the singing voice when appropriate. Diagnoses based on the strobovideolaryngoscopic examination were compared with preprocedure diagnoses to determine whether strobovideolaryngoscopy was helpful clinically in establishing diagnoses or treatment strategies. We were also interested in determining whether additional clinical and teaching experience since the time of our original report in 1988 had altered the usefulness of strobovideolaryngoscopy in our practice.

TABLE 2. NUMBER OF PROCEDURES EXPERIENCED BY INDIVIDUAL PATIENTS

No. of Procedures per Patient	*Patients*	
	No.	*%*
1	326	93
2	23	6.5
3	1	< 1
4	2	< 1

RESULTS

Three hundred seventy-seven strobovideolaryngoscopic examinations were performed on 352 patients. Forty entities were diagnosed (Table 1). Many patients had more than one diagnosis, although some had their second, third, or fourth diagnosis established at separate office visits during the 12-month period. For example, a patient with voice abuse and a varicosity on one visit may have returned with a vocal fold hemorrhage. Table 1 lists each diagnosis every time it was observed during strobovideolaryngoscopy, even if it was present on several examinations in the same patient. Table 1 also lists the number of patients who had each diagnosis at any time during the 12-month period. Seven percent of patients underwent more than one strobovideolaryngoscopic procedure (Table 2). Most of the patients who underwent two or more procedures had vocal fold hemorrhage, vocal nodules, or unrelated problems on different occasions during the 12-month period. In 110 procedures (29%), stroboscopy confirmed the clinical diagnosis and permitted detection of additional diagnoses. In 67 procedures (18%), the clinical diagnosis was found to be incorrect. Thus, during 177 procedures (47%) strobovideolaryngoscopy provided additional diagnostic information. In 55 cases, the additional findings did not alter medical management. The 122 cases (32.4% of procedures) in which clinically significant findings were detected only following strobovideolaryngoscopy are summarized in Table 3. These examples include cases of small recurrent carcinoma, cases of delayed resolution of vocal fold hemorrhage, cases of recurrent laryngeal nerve pa-

TABLE 3. CASES IN WHICH STROBOSCOPY MADE SIGNIFICANT DIFFERENCE IN DIAGNOSIS AND/OR TREATMENT

Lesion	No. of Procedures
Carcinoma	1
Cricothyroid fusion	2
Cyst	7
Cyst and contact nodule	4
Granuloma	2
Hemorrhage	10
Mass	12
Mucosal tear	5
Myasthenia gravis	2
Nodules	8
Normal larynx with functional dysphonia	3
Polyp	2
Recurrent laryngeal nerve paresis	10
Scar	32
Superior laryngeal nerve paresis or paralysis	16
Varicosity	3
Web	3

resis initially thought to have been paralysis, cases in which vocal fold scar was detected unexpectedly in the presence of other vocal fold disorders such as nodules or cysts, and other conditions. Stroboscopy allowed diagnosis of vocal fold cysts with contralateral reactive nodules in several cases that had been misdiagnosed as bilateral vocal nodules. Accurate stroboscopic diagnosis in these cases altered the treatment plan and decreased the amount of time spent in voice therapy prior to surgical intervention. Stroboscopy is also helpful in documenting normal vocal fold function in cases of psychogenic dysphonia or malingering. Malingering is increasingly common as the number of lawsuits following surgical procedures continues to increase.

DISCUSSION

Use of stroboscopic light to evaluate the larynx was first reported in 1895.[3] Since that time, more than 90 articles have recommended the technique, and numerous equipment designs have been proposed, as cited previously.[1] Recent improvements in laryngeal stroboscopes have provided instrumentation that is practical for clinical use. The technique has proven helpful in evaluating many patients with voice complaints, providing rapid assessment of vibratory function. This permits diagnosis of structural lesions that are often missed altogether without stroboscopy. In comparing our current findings with those reported in our 1988 study, we were somewhat surprised to note a 12% increase in the percentage of voice visits during which stroboscopy was performed. We believe this is due not to expanded indications for stroboscopy, but rather to the increasing percentage of our patients referred by otolaryngologists for complex medical or legal consultation. In our previous investigation, we reported that stroboscopy provided clinically valuable information in 31.2% of the procedures performed. In our present study, there were additional findings in 47% of procedures, but important diagnostic changes in only 32.4%. These remarkably consistent findings confirm the conclusions put forth in our previous report. Strobovideolaryngoscopy provides valuable information that alters diagnosis and/or treatment in about one third of patients for whom the procedure is indicated. It is helpful in confirming clinical impressions in many additional patients. Once skill has been acquired in performing and interpreting strobovideolaryngoscopy, extensive experience does not appear to alter its clinical value. Stroboscopic findings routinely result in changes in diagnosis that alter treatment strategies. We have found the technique invaluable in daily practice and essential for valid, reliable diagnosis of voice disorders.

REFERENCES

1. Sataloff RT, Siegel JR, Carroll LM, Schiebel BR, Darby KS, Rulnick RK. Strobovideolaryngoscopy in professional voice users: results and clinical value. J Voice 1988;1:359-64.

2. Hirano M. Phonosurgery: basic and clinical investigations. Otologia (Fukuoka) 1975;21:239-442.

3. Oertel MJ. Das Laryngoskopische Untersuchung. Arch Laryngol Rhinol (Berl) 1895;3:1-16.

VIDEOSTROBOSCOPY OF HUMAN VOCAL FOLD PARALYSIS

JOEL A. SERCARZ, MD
GERALD S. BERKE, MD
YE MING, MD
BRUCE R. GERRATT, PHD
MANUEL NATIVIDAD
LOS ANGELES, CALIFORNIA

Previous stroboscopic studies of human vocal cord paralysis have been infrequent and have lacked documentation of the site of lesion. In order to study human laryngeal paralysis, the recurrent and superior laryngeal nerves were infiltrated unilaterally with lidocaine hydrochloride in three human volunteers. Vagal paralysis was simulated by combined (superior and recurrent) infiltration in one volunteer. Additionally, 20 patients with untreated laryngeal paralysis were studied from the voice laboratory at UCLA. In addition to videostroboscopic analysis, photoglottography and electroglottography were performed and synchronized with the stroboscopic images. The most significant finding in stroboscopy of the paralyzed larynx was the asymmetry of traveling wave motion. The traveling wave on the normal vocal fold had a faster wave velocity that created a phase difference in the vibration of the two folds. The wave also traversed a greater distance along the vocal fold mucosa on the normal side. No patient or volunteer with untreated laryngeal paralysis had a symmetric traveling wave, either in superior or recurrent laryngeal nerve paralysis. Synchronization with glottography indicated that the differentiated electroglottographic waveform provides useful information about the timing of glottic opening and closure in states of asymmetric laryngeal vibration. Implications for future studies and for the diagnosis of laryngeal paralysis are discussed.

KEY WORDS — laryngeal paralysis, larynx, mucosal wave, stroboscopy, voice disorders.

INTRODUCTION

Stroboscopy has provided valuable insights into laryngeal vibration and mucosal motion. However, few studies have systematically assessed the findings of stroboscopic analysis in laryngeal paralysis. Stroboscopy has a long history of clinical use in laryngology. Oertel is credited with the first clinical examination of the larynx with a stroboscope in 1878.[1] His primitive system employed a rotating perforated disc and laryngeal mirror to intermittently illuminate the glottis. Modern stroboscopes, while expensive, are considerably less cumbersome and have gained widespread use, particularly in Japan and Europe.[2]

Much of the behavior of the vibrating vocal folds is not visible through indirect laryngoscopy. Because an image on the human retina persists for approximately 0.2 seconds, the vibrating vocal folds appear as a blur along their medial edge. Stroboscopy creates the illusion of slow motion by generating light flashes at a rate slightly out of synchrony (approximately 2 Hz) with the fundamental frequency of phonation. This transforms the duration of a typical laryngeal cycle from 5 milliseconds to somewhere between 0.25 and 1 second. The "cycle" therefore represents a montage of many laryngeal cycles, rather than documentation of a single cycle as in high-speed photography.

Stroboscopic analysis was instrumental in the development of the cover-body theory of Hirano and Kakita,[3] which proposes that the stiff underlying body formed primarily by the vocalis muscle is responsible for the transverse movements of the vocal folds, while the looser mucosal cover vibrates primarily in the vertical dimension and forms a traveling mucosal wave.[3] As confirmed through supraglottic and subglottic videostroboscopy, the vocal folds vibrate as an upper and a lower margin during phonation. The lower margins separate first, forming a subglottic vault filled with a small volume of air, which is released as a puff into the vocal tract. The lower margins then return to the midline, and a gradual closing of the upper margin follows. In unilateral paralysis, there is a loss of stiffness of the underlying body, reducing the distinction between the upper and lower margins and creating a diminution or loss of the traveling wave.[4]

In addition to its research value, stroboscopy has been used for decades in clinical laryngology. Von Leden[5] emphasized the usefulness of stroboscopy in differentiating functional from anatomic laryngeal lesions, and for the early detection of invasive cancers of the vocal folds. However, stroboscopy is limited when aperiodicity, severe hoarseness, or breathiness impairs its ability to synchronize the flashes accurately.[2]

From the Division of Head and Neck Surgery, University of California–Los Angeles Medical Center (Sercarz, Berke, Natividad), and the Division of Head and Neck Surgery, West Los Angeles Veterans Administration Medical Center (Ming, Gerratt), Los Angeles, California.

Presented at the meeting of the American Laryngological Association, Waikoloa, Hawaii, May 4-5, 1991.

REPRINTS — Gerald S. Berke, MD, Division of Head and Neck Surgery, UCLA School of Medicine, Los Angeles, CA 90024.

Previous research supported the widespread view that laryngeal paralysis is accompanied by a loss of the mucosal traveling wave on the paralyzed fold.[2] Schoenharl[6] studied laryngeal paralysis with stroboscopy and found that in 55 of 62 cases the traveling wave was absent. The presence of the mucosal wave in patients with a paralyzed fold was interpreted as a sign of some degree of reinnervation, suggesting an improved prognosis for eventual complete recovery.[2,7] Fex[7] published a study in 1970 on the stroboscopy of laryngeal paralysis. He agreed with previous authors that in acute recurrent laryngeal nerve (RLN) paralysis the glottic wave is absent. The mucosal traveling wave was found to be an accurate reflection of thyroarytenoid muscle tonus, and its return indicated recovery of RLN function even when vocal fold abduction could not be detected.[7] The possibility that the return of the traveling wave was promoted by vocal cord fibrosis was not discussed.

Isshiki et al[8] published a detailed account of the effects of asymmetric vocal fold extension, using excised larynges and a computer model to assess the effect of unilateral changes of cricothyroid (CT) contraction and subsequent vocal fold stiffness. According to Isshiki et al, the vibratory findings produced by asymmetric laryngeal tension depend on the degree of glottic closure. They found that in simulated superior laryngeal nerve (SLN) paralysis the true vocal folds vibrated at the same frequency but out of phase, with the more tense fold (active CT) preceding the less tense one. This finding was later confirmed by Isshiki's group in a study performed on live dogs.[9]

Another study of canine laryngeal paralysis was performed by Moore et al[4] employing videostroboscopy. The authors found that canine RLN paralysis produces a difference in the timing of the onset of vocal fold lateral displacement and loss of the normal two-mass laryngeal vibration. The mucosal wave was markedly diminished but not lost in RLN paralysis.[4]

The morphological findings in laryngeal paralysis, including the Wagner-Grossman theory of vocal fold position in RLN and vagal paralysis, can be appreciated through indirect laryngoscopy alone and will not be the focus of this research.

The purpose of this study is to update earlier analyses of asymmetric laryngeal vibration by using videostroboscopy. First, it will describe the stroboscopic appearance of the larynx in paralysis. Previous reports of vibrational findings in laryngeal paralysis have been limited by the difficulty in defining the actual type of paralysis. Temporary induced paralysis was used in this study and provides a known site of lesion and the ability to compare laryngeal vibration before and after paralysis. Second, videostroboscopic images were synchronized with glottographic waveforms to more accurately assess the timing of glottic opening and closure on the glottographic waveforms. Third, an analysis of a clinical series of patients with various types of vocal fold paralysis was performed to verify that the findings noted in induced paralyses are similar to those in a typical laryngology practice. Finally, asymmetric vibration of the laryngeal mucosa provides an opportunity to utilize recently developed techniques for the objective analysis of videostroboscopic images for the degree of vocal fold symmetry.

MATERIALS AND METHODS

Method of Paralysis Induction. Three adult male volunteers with a mean age of 36 years were studied in this experiment. The volunteers appeared normal on laryngeal examination and had no history of laryngeal disorders. Vocal fold paralysis was induced by infiltrating 2% lidocaine hydrochloride with a 25-gauge needle into the expected location of the nerve. The left RLN was infiltrated in the tracheoesophageal groove approximately 2 cm inferior to the cricoid cartilage. The left SLN was infiltrated as described by Abelson and Tucker.[10] Ten cubic centimeters were necessary, with injection both at the posterior edge of the thyroid ala and inferiorly near its passage posterior to the thyrohyoid muscle. To create a combined ("vagal") paralysis, an SLN injection was performed, verified by stroboscopy, and immediately followed by an RLN injection. Subject 1 had SLN, RLN, and combined paralysis induced with lidocaine. Subject 2 had the RLN only injected, and subject 3 had the SLN only injected.

Videostroboscopic Analysis. The method of videostroboscopic analysis was modified from previous reports by Bless et al[1] and Kitzing.[2] Emphasis was placed in the analysis on the characteristics of the traveling mucosal wave. The onset, extent, and velocity of the traveling wave were analyzed and estimated by advancing the videotape frame by frame. Phase differences were noted in cases of asymmetric vibration. Other characteristics included the degree of glottic closure, the lateral excursion of the fold during vibration (termed amplitude by Bless et al[1]), and the regularity of glottic cycles, reflecting the presence or absence of severe frequency perturbation.

Stroboscopy. The experimental equipment required for these studies is depicted in Fig 1. Stroboscopy was performed with a Bruel & Kjaer 4914A (Orange, Calif) stroboscope. A microphone (Sennheiser MD

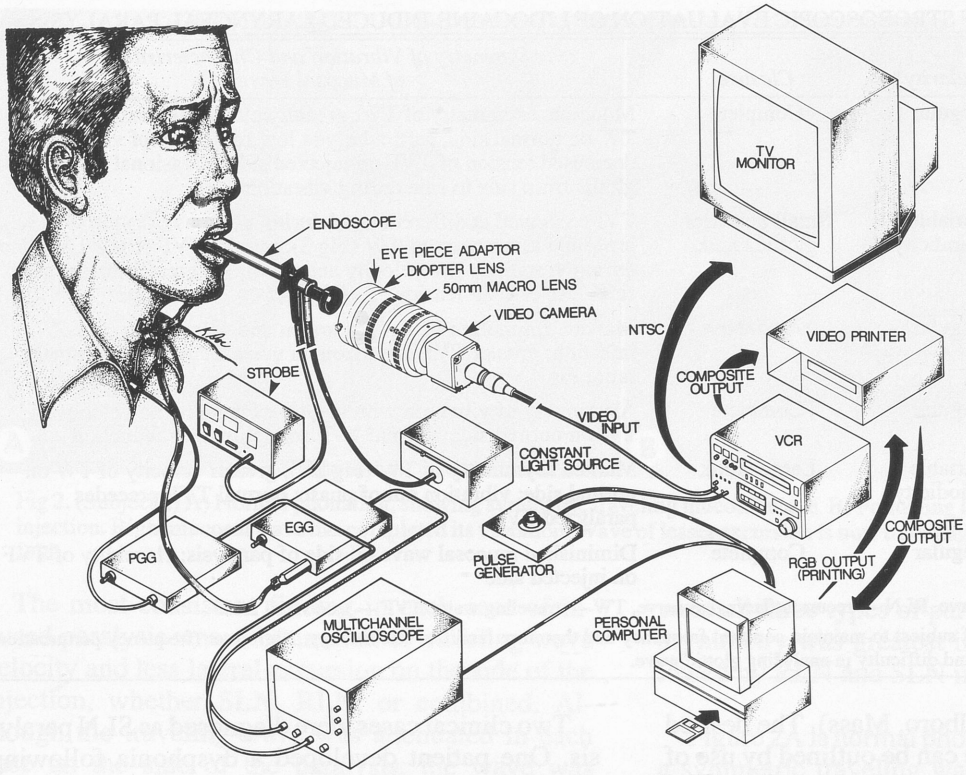

Fig 1. Experimental setup for recording of videostroboscopic images and concurrent glottographic waveforms. Computer includes Frame Grabber hardware, which allows digitization of videostroboscopic images, and Image Pro software for analysis of images.

4026) transduced the speech signal to allow synchronization with the video images. A Toshiba Charge Coupled Device (CCD) color video camera (model 1K-C30A, Buffalo Grove, Ill) imaged the glottis. The images were recorded onto a 3/4-in professional videocassette recorder (Sony VO-9850, Teaneck, NJ) equipped with a time coder. Still images from the videotape were made with a color video printer (Sony Mavigraph, Teaneck, NJ).

Glottography. Videostroboscopy and glottography were performed simultaneously during phonation of the vowel /i/ produced at a constant pitch and loudness. Transduction of photoglottography (PGG) waveforms required constant illumination of the larynx with a miniature light source (Karl Storz 481-C, Culver City, Calif) in addition to the stroboscopic light source. A 90° telescope (Wolfe, Rosemont, Ill) with two light inputs was used to visualize the glottis. Light transmission for PGG waveforms was transduced with a photosensor (Centronics OSD 50-2, Mountainside, NJ) held in position on the skin overlying the CT membrane. Electroglottography (EGG) recording electrodes were strapped into position onto the subject's neck, overlying the thyroid lamina at the level of the true vocal folds. A Synchrovoice electroglottograph (Harrison, NJ) recorded the EGG waveforms.

Synchronization. Videostroboscopic images were correlated with glottographic signals to provide preliminary information about the timing of events in laryngeal paralysis. Further details about the synchronization method are being published in a separate report from this laboratory.[11] Briefly, a 5-millisecond square wave pulse was digitized and simultaneously recorded on the audio channel by the videotape recorder. By correlating the 5-millisecond square wave pulse with the vertical synchronization trace of the video signal, the position on the glottographic waveform could be precisely correlated with individual video images. A Hitachi oscilloscope (model V-1050 F, Torrance, Calif) was used to extract the vertical trace of the video signal for recording.

Electroglottography, photoglottography, synchronizing pulse and vertical trace of the video signal were digitized via a Labmaster 12-bit analog-to-digital board housed in an IBM compatible computer. The EGG and PGG signals were verified on a Tektronix 5116 (Beaverton, Ore) storage oscilloscope prior to recording. The waveforms were analyzed by using a commercially available software package for the PC system (C-Speech, Paul Milenkovic, University of Wisconsin, Madison, Wis).

Videostroboscopic Image Evaluation. Images were analyzed by using an image processing software package previously described[12] (Image Pro II, Media Cybernetics, Silver Spring, Md). The hardware necessary for image analysis included a Frame Grabber to digitize and analyze video images (Data Transla-

TABLE 1. SUMMARY OF STROBOSCOPIC EVALUATION OF LIDOCAINE-INDUCED LARYNGEAL PARALYSIS

Subject	*Site*	*Regularity**	*Closure*	*Symmetry of Vibration and Characteristics of Mucosal Wave*
1	SLN	Regular	Complete	Moderate asymmetry of TW; greater velocity and excursion of TW on normal side, particularly at low frequency of vibration; decreased tension of TVF on injected side; occasional shifting of glottis from side to side during vibration
1	SLN + RLN	Variable aperiodicity	Small posterior glottic chink	TVFs vibrated at different level during portions of cycle (Fig 3C); profound asymmetry of TW (Fig 3); normal TVF crossed midline during vibration; TW velocity and excursion greater on normal side; loss of TVF tension; TVF higher on normal side
1	RLN	Regular	Variable	Marked diminution of TW excursion and velocity on side of injection; greater TVF excursion on normal side (see symmetry ratio, Fig 4A)
1	RLN paresis	Regular	Complete	Asymmetry of vibration with greater excursion and velocity of TW on normal side; normal TVF adduction and abduction
2	RLN	Variable aperiodicity	Large chink	Marked asymmetry of TW (Fig 2B); greater velocity of TW on normal side; vibration out of phase; normal TVF precedes paralyzed TVF
3	SLN	Regular	Complete	Diminished mucosal wave on side of paralysis; flaccidity of TVF on injected side

SLN — superior laryngeal nerve, RLN — recurrent laryngeal nerve, TW — traveling wave, TVF — true vocal fold.

*Regularity indicates ability of subject to maintain constant frequency and therefore facilitate stroboscopy. High jitter (frequency perturbation) results in irregular vibration and difficulty in analyzing glottic wave.

tion, DT-2853 60SQ, Marlboro, Mass). The desired portion of the video image can be outlined by use of a pointing device, and then the area of the trace or the length of a line is calculated by and expressed in pixel units by the software.

Images were digitized from the most closed and most open portions of the vocal cycle, and the width of the vocal folds was measured during these intervals. A measure was then computed of the symmetry ratio, which expresses the excursion of one vocal fold in proportion to that of the other fold. Symmetric vibratory movement is marked by an equal excursion of both vocal folds from the midline during phonation. When the lateral motion of one fold is markedly reduced, as in unilateral RLN paralysis, the symmetry ratio approaches zero. Further details regarding the objective analysis of videostroboscopic images have been recently published by Sercarz et al.[12]

Chronic Paralysis Study. We reviewed the videotapes and clinical files of all patients with a diagnosis of vocal fold paralysis evaluated in the UCLA Voice Laboratory during the years 1988 to 1991. Patients were excluded if the paralyses had been previously treated or if inadequate videotape or clinical information was available. All patients underwent stroboscopy and glottographic (PGG and EGG) recordings. In each case, medical records were analyzed to determine the probable site of the paralysis. Three cases of vagal paralysis had documented sites of lesion. Two patients had laryngeal paralysis following penetrating trauma to the skull base and subsequent high vagal paralysis. The third had undergone a tumor with sacrifice of cranial nerve X at the skull base.

Two clinical cases were diagnosed as SLN paralysis. One patient developed a dysphonia following thyroid surgery marked by a reduced ability to modulate pitch and vocal fatigue. Later exploration revealed a lack of function of the SLN on direct nerve stimulation. Another patient suffered neck trauma and developed a dysphonia marked by abnormal laryngeal vibration and normal vocal fold abduction and adduction. In the latter patient, there was a rotation of the posterior commissure in the direction of the paralysis side.

Fifteen additional patients received diagnoses of unilateral RLN paralysis based on history and indirect laryngeal examination.

RESULTS

Induced Paralysis. The three subjects underwent stroboscopy prior to induction of paralysis. In each case, vibration was normal with equivalent velocity and excursion of the traveling wave and symmetric tension of the vocal folds bilaterally. Closure was complete in each case.

In each case of SLN paralysis, the volunteer reported anesthesia of the larynx and an inability to sing at a high pitch in addition to the findings described.

Table 1 summarizes the videostroboscopic findings in induced vocal fold paralysis. Following RLN injection, the vocal process on the paralyzed side remained in the paramedian position. There was no rotation of the posterior glottis that was appreciable in any of the induced paralysis states.

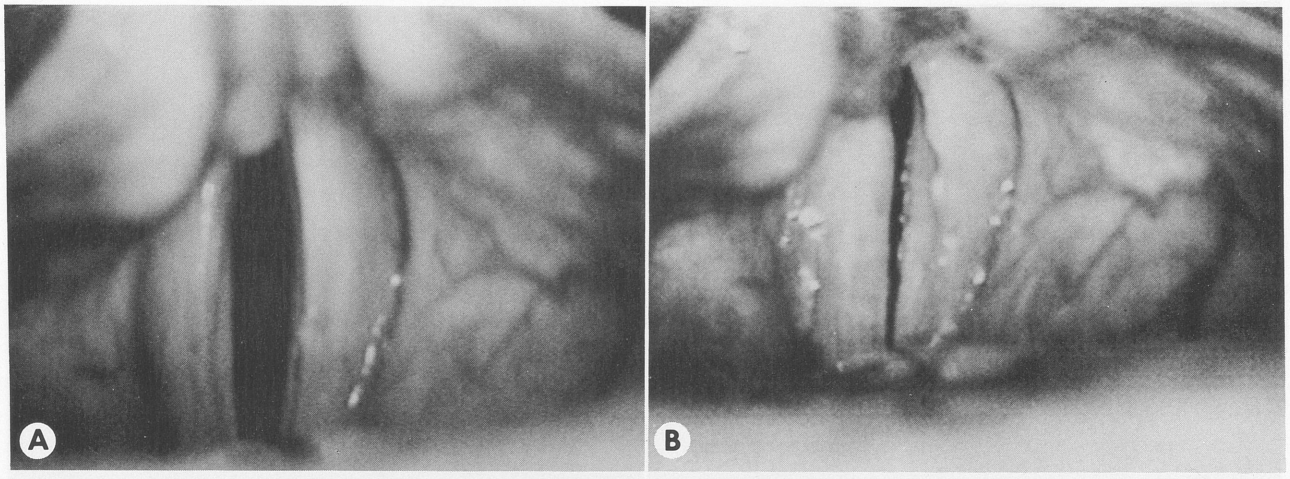

Fig 2. (Subject 2) A) Normal phonation, showing symmetric traveling mucosal wave. B) Following left recurrent laryngeal nerve injection. Right mucosal wave has completed its vibration. Wave of lesser excursion is now traveling along left (paralyzed) vocal fold.

The most consistent finding in each case of induced paralysis was a diminution of traveling wave velocity and less lateral excursion on the side of the injection, whether SLN, RLN, or combined. Although the traveling wave was attenuated in each case on the side of the paralysis, the wave was observed during each trial. For subject 1, who underwent all three types of paralysis, the traveling wave asymmetry was greatest in the vagal paralysis, followed by RLN and SLN in that order.

Figure 2A is normal phonation from subject 2 with a symmetric traveling wave. Figure 2B, following left RLN injection, demonstrates asymmetric vibra-

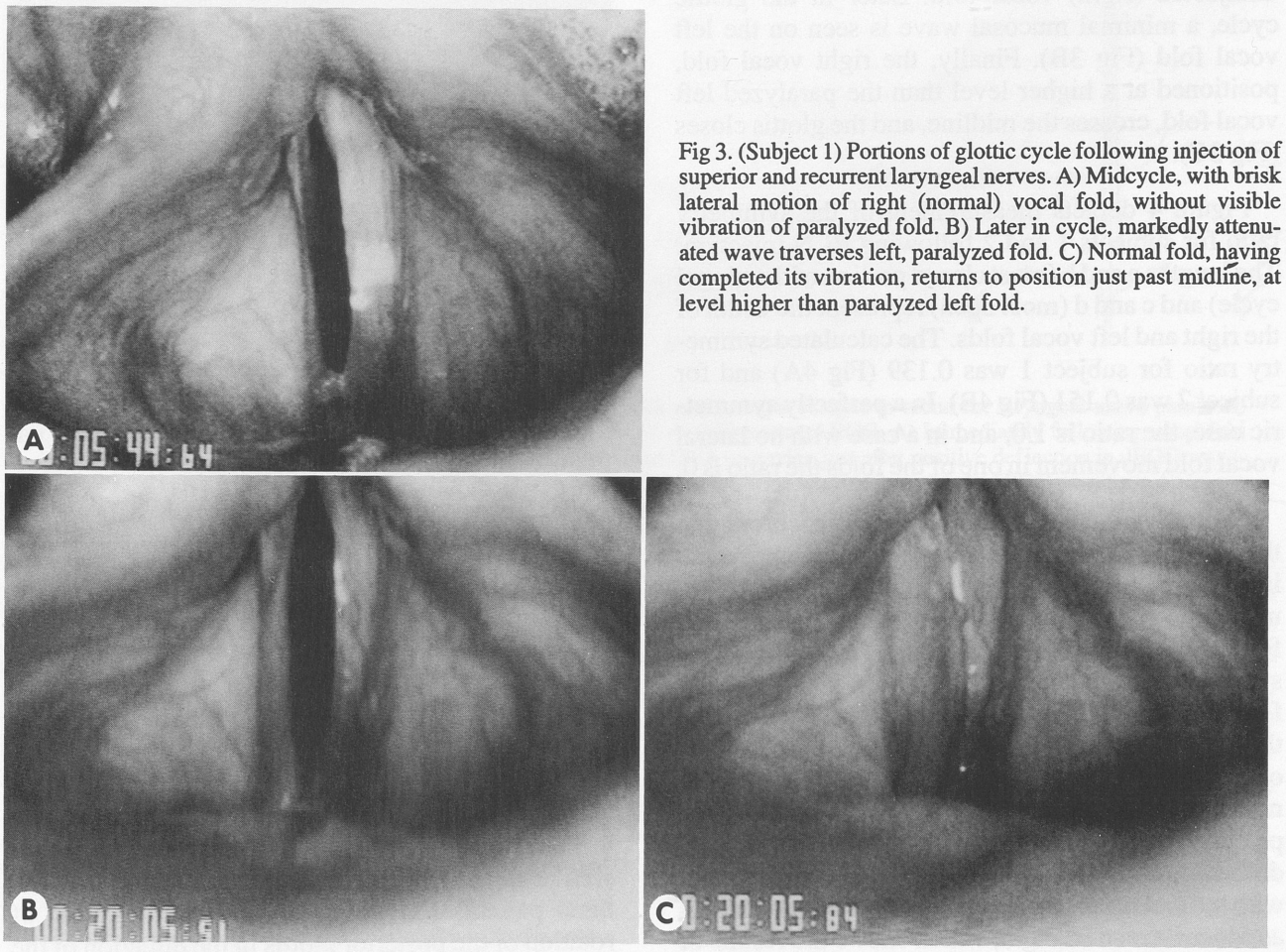

Fig 3. (Subject 1) Portions of glottic cycle following injection of superior and recurrent laryngeal nerves. A) Midcycle, with brisk lateral motion of right (normal) vocal fold, without visible vibration of paralyzed fold. B) Later in cycle, markedly attenuated wave traverses left, paralyzed fold. C) Normal fold, having completed its vibration, returns to position just past midline, at level higher than paralyzed left fold.

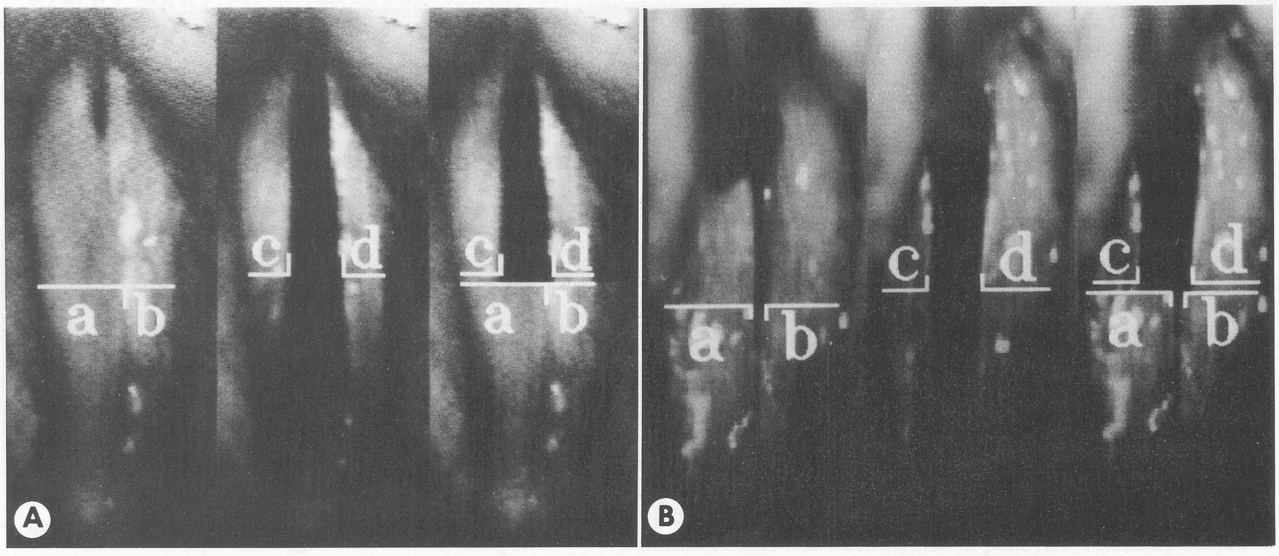

Fig 4. Symmetry ratio for two volunteers with induced recurrent laryngeal nerve paralysis (see text). A) Subject 1. B) Subject 2.

tion. The normal (right) vocal fold has completed its vibration, and the paralyzed (left) fold is shown with an attenuated traveling wave. Figure 3 is a series of still video frames from subject 1 with a left combined RLN and SLN paralysis. Figure 3A is early in the glottic cycle, with a vigorous excursion of the uninjected (right) vocal fold. Later in the glottic cycle, a minimal mucosal wave is seen on the left vocal fold (Fig 3B). Finally, the right vocal fold, positioned at a higher level than the paralyzed left vocal fold, crosses the midline, and the glottis closes (Fig 3C).

Figure 4 depicts measurement of the symmetry ratio for subjects 1 and 2 following RLN injection. The lengths a and b (most closed portion of the glottal cycle) and c and d (most open) represent the width of the right and left vocal folds. The calculated symmetry ratio for subject 1 was 0.139 (Fig 4A) and for subject 2 was 0.151 (Fig 4B). In a perfectly symmetric case, the ratio is 1.0, and in a case with no lateral vocal fold movement in one of the folds the ratio is 0.

Figure 5 demonstrates the results of synchronizing the glottographic signal to the videostroboscopic image from subject 1 following RLN injection. Figure 5A is a stroboscopic image taken immediately following opening of the glottis. Figure 5B is the synchronized glottography. There is an upward deflection in the differentiated EGG (dEGG) waveform that correlates well with the onset of vocal fold opening. Figure 5C,D is synchronized from a point at midcycle. Figure 5E,F is from an image immediately preceding the point of glottic closure. The downward deflection in the dEGG waveform closely correlated with the instant of laryngeal closure. Similar findings are documented in Fig 6, which shows the results of synchronizing strobe images and glottography in subject 1 with SLN paralysis at the moment of opening (Fig 6A,B) and closure (Fig 6C,D). Again, the timing of opening and closure of the vocal folds is predicted by the dEGG waveform.

Clinical Cases. The results of a series of 20 consecutive patients analyzed at the UCLA Voice Laboratory will now be described. Of the 15 RLN patients, 3 could not be included because aperiodic vibration or a large glottic gap prevented analysis of the mucosal traveling wave. The results of the 12 remaining patients with unilateral RLN paralysis and adequate stroboscopy are summarized in Table 2. Ten of 12 patients had a mucosal wave present on the paralysis side. The wave asymmetry was similar to that observed in the induced paralysis: the normal wave had a greater velocity and traveled farther along the vocal fold mucosa. There was a phase shift, with the normal side vibrating sooner than the side of the paralysis. The asymmetry was marked in the majority of patients with unilateral RLN paralysis.

The findings in the two patients with SLN paralysis parallel those in the group with induced paralysis. There was normal abduction and adduction of the vocal folds in both cases. Glottic closure and regularity (lack of noticeable frequency perturbation) were normal. Analysis of the mucosal wave revealed mild to moderate asymmetry of the traveling wave. On the normal (nonparalysis) side, the wave appeared earlier, had a greater velocity, and traveled farther along the surface of the vocal cord mucosa.

The mucosal wave findings in vagal paralysis are similar to those in RLN paralysis. Only one of the three patients had the frequently cited finding of rotation of the posterior glottis in the direction of the

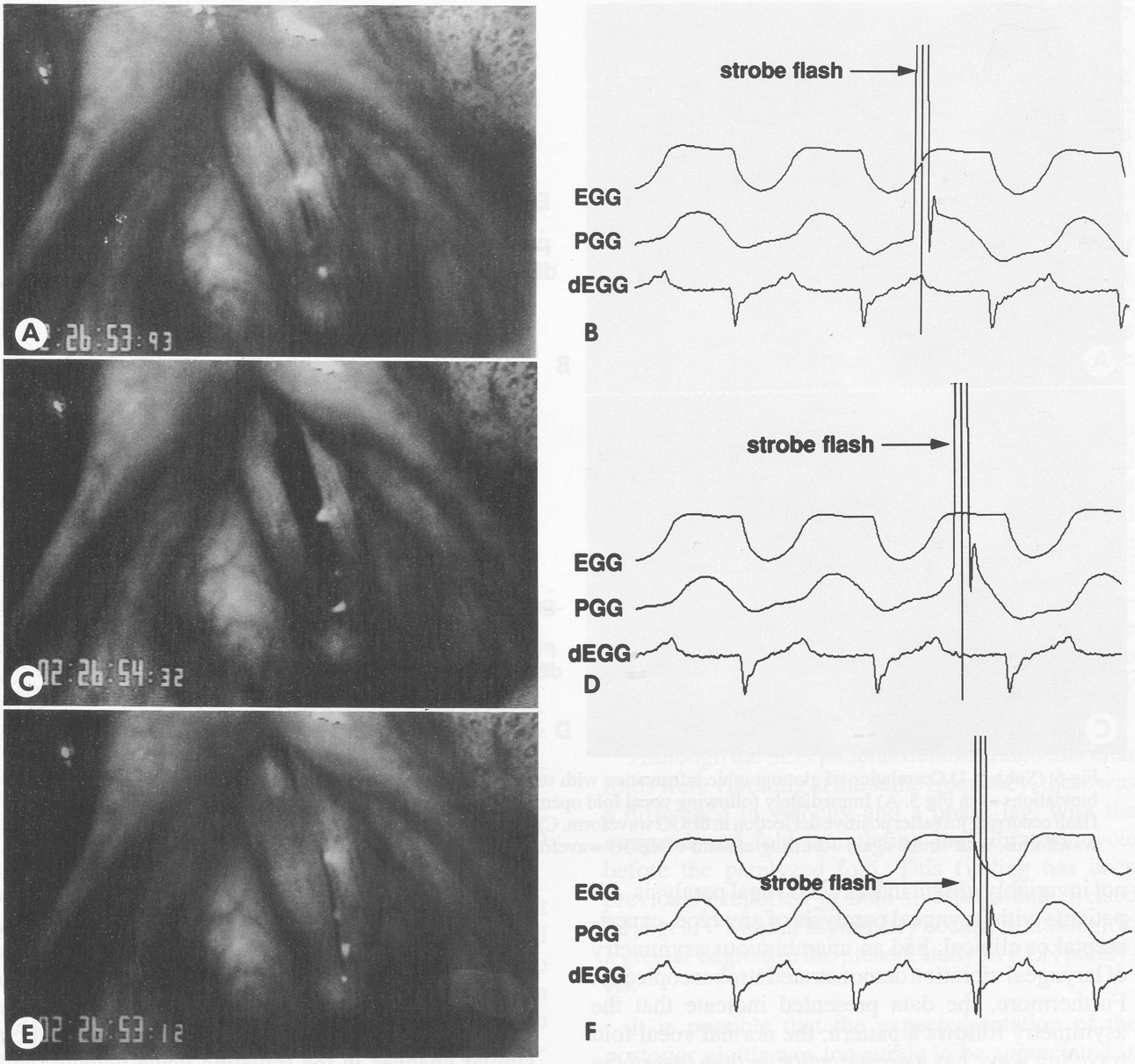

Fig 5. (Subject 1) Correlation of glottographic information with stroboscopic images in recurrent laryngeal nerve paralysis. EGG — electroglottography, PGG — photoglottography, dEGG — differentiated EGG. A) Immediately following vocal fold opening. B) Corresponding glottographic waveforms, with strobe flash occurring just after positive deflection in dEGG waveform. C) Later in cycle, at mid-opening. D) Glottographic waveforms, with strobe occurring near peak of PGG waveform. E) Image of glottis at point of closure. F) Corresponding waveforms; nadir of dEGG waveform corresponds to strobe flash.

paralysis. In one of the patients with vagal paralysis, the glottic gap was wide throughout the cycle and there was very irregular vibration of the mucosal wave bilaterally. The other two patients had marked asymmetry of the traveling wave, vibration out of phase, and differences in the velocity and excursion of the traveling wave similar to those found with induced vagal paralysis in this study.

DISCUSSION

There are several advantages of studying induced vocal fold paralysis stroboscopically. Temporary chemical paralysis allows comparison with normal stroboscopy in the same individual. It also provides an opportunity to study recovering RLN weakness and observe the gradual recovery of symmetry, as in the study of vocal fold paresis in subject 1. Before discussing the stroboscopic findings in particular paralytic states, we will review the overall relationship between tension of the vocal fold and vibratory characteristics.

Unlike previous studies[2,6,7,13] of stroboscopy in vocal cord paralysis, the data in the present report indicate that the mucosal wave is always *affected* but

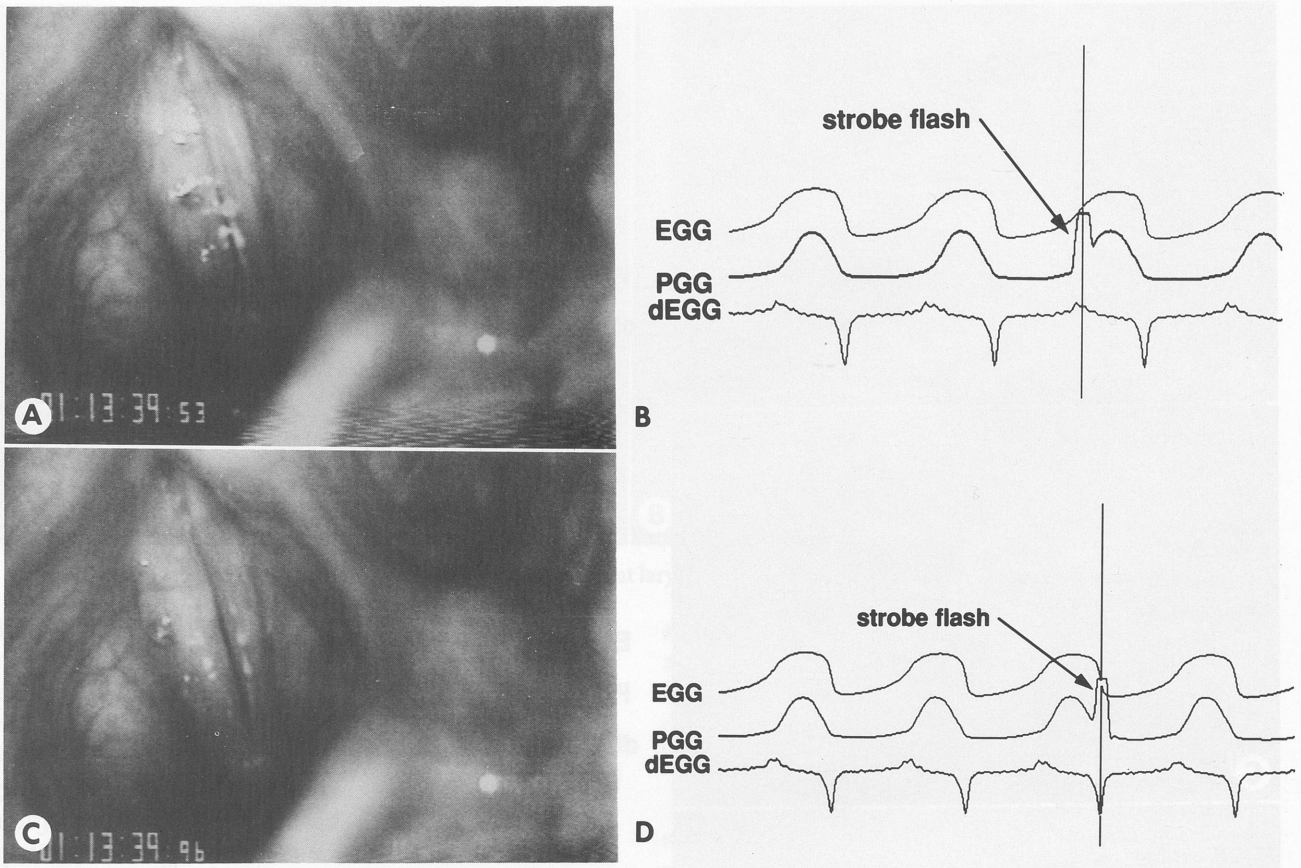

Fig 6. (Subject 1) Correlation of glottographic information with stroboscopic images in superior laryngeal nerve paralysis. Abbreviations as in Fig 5. A) Immediately following vocal fold opening. B) Corresponding glottographic waveforms, with strobe flash occurring just after positive deflection in dEGG waveform. C) At point of closure of glottis. D) Corresponding glottographic waveforms, with strobe again occurring at nadir of dEGG waveform.

not invariably *absent* in RLN and vagal paralysis. All patients with laryngeal paralysis of any type, experimental or clinical, had an unambiguous asymmetry of laryngeal vibration demonstrated stroboscopically. Furthermore, the data presented indicate that the asymmetry follows a pattern: the normal vocal fold traveling wave has a greater velocity than that of the paralyzed fold, is observed earlier in the glottic cycle, and traverses farther over the surface of the vocal fold mucosa. The symmetry ratio data were presented to document the greater excursion of the vocal fold margin on the nonparalyzed side during the most open portion of the cycle in unilateral RLN paralysis.

The findings described here are similar to those reported by Tanabe et al[9] in a report on asymmetric glottic vibration studied in canine larynges. It is not surprising that there was a visible difference in the velocity of the traveling waves on two vocal folds. Basic research on the propagation of waves in elastic media have indicated that there is a direct relationship between the stiffness of the material or reactance to deformation and the velocity of a harmonic traveling wave.[14] The lack of thyroarytenoid stiffness and/or CT contraction is probably the central cause of the vibratory differences in laryngeal paralysis. In a morphologic study of the vocal fold as a vibrator, Hirano[15] stated that the CT and thyroarytenoid muscles had the greatest effect on the stiffness relationship between the body and the cover of the vocal fold; this finding may explain why either muscle may elicit similar changes in the traveling wave velocity and excursion.

For the two patients with absent glottic waves, each had poor glottic closure that reduced the degree of vocal fold contact. This tended to decrease the ability of stroboscopy to detect the very subtle mucosal wave that generally occurs on the paralyzed vocal fold.

Because of its sensitivity in demonstrating slight differences in vocal fold vibration, stroboscopy is particularly useful in the study of laryngeal paralysis. In subtle cases, such as RLN paresis or isolated SLN paralysis, an abnormality of traveling wave motion may be the easiest finding to elicit. The results of this study suggest that traveling wave asymmetry may be one of the most salient observations to make in suspected paralysis, because traveling wave asymmetry

TABLE 2. RESULTS OF PATIENTS WITH RECURRENT LARYNGEAL NERVE PARALYSIS

	No. of Patients
Glottic closure	
Complete	2
Mild to moderate incomplete closure	5
Severely incomplete closure	5
Glottic wave: extent of wave excursion along vocal fold mucosa	
Symmetric	0
Mild to moderate asymmetry	2
Marked asymmetry	8
Absent on paralysis side	2
Glottic wave: estimated speed of glottic wave	
Symmetric	0
Greater velocity (earlier wave) on normal side	10
Greater velocity on paralyzed side	0
Absent wave on paralyzed side	2
Vocal fold lateral displacement during vibration*	
Equivalent	0
Mild to moderate asymmetry	4
Marked asymmetry	8

Of 15 patients with clinical diagnosis of recurrent laryngeal nerve paralysis, 12 had adequate regularity of vibration for suitable stroboscopy. Their results are presented here.

*Lateral motion during vibration was invariably greater on side opposite paralysis (normal side). See Fig 4, showing symmetry ratio in induced paralysis.

is a consistent finding in untreated laryngeal paralysis. In subject 1, traveling wave asymmetry was also identified in RLN paresis.

Despite this consistency, there is a significant variability of findings among different patients and even within the same individual phonating at two different fundamental frequencies. For example, in RLN paralysis, CT muscle contraction at high pitch adds vocal fold stiffness and tends to reduce the degree of asymmetry. One patient in the study developed RLN paralysis following thyroid surgery 20 years before the examination; the paralysis is still largely uncompensated. He apparently compensates with CT tension, producing speech at a high pitch level (paralytic falsetto) that provides glottic closure and only moderately asymmetric traveling wave motion.

Both RLN paralysis and combined SLN and RLN paralysis produced the above changes in the traveling wave. Although the combined paralysis was characterized by a greater degree of asymmetry and a more flaccid or "wavy" paralyzed cord, it is doubtful from our data whether stroboscopy alone can be of significant assistance in differentiating vagal from RLN paralysis.

Isolated SLN paralysis is a rarely noted clinical entity that probably often goes undetected.[10,16,17] The SLN provides sensation to the supraglottic larynx through its internal branch and motor fibers to the CT muscle via its external branch. The motor branch is in close proximity to the superior thyroid vessels and is therefore vulnerable to injury during thyroid surgery. According to Ward et al[17] and other authors,[10] paralysis of the CT muscle causes 1) lack of longitudinal tension of the true vocal folds, 2) a tilt of the larynx because of the downward motion of the contralateral intact CT muscle, and 3) a rotation of the posterior glottis toward the side of the paralysis because of the unopposed CT muscle's pulling the anterior thyroid cartilage toward the intact side.

Unfortunately for the clinician, as stated by Dedo in his study on experimental and clinical vocal fold paralysis, the expected findings in SLN paralysis "...are not consistent or obvious enough to be useful in clinically diagnosing superior laryngeal nerve paralysis."[16(p1503)] Neither of the two volunteers undergoing SLN injection for this study had an unequivocal rotation of the posterior glottis toward the paralyzed side, as described in the literature. The asymmetry of the traveling wave, however, was easy to observe stroboscopically.

Although the SLN patients demonstrated that their folds were vibrating at the same frequency, there was a difference in velocity and a phase lag, with the nonparalyzed fold completing the vibratory cycle before the paralyzed fold. This finding has been previously reported in both live dogs and excised larynges.[8,9] Similar asymmetry occurred, although to a greater degree, in the present study in RLN paralysis.

It is possible that the expected rotation of the posterior glottis was too subtle to be appreciated in these patients. In a canine study, the glottic rotation following unilateral CT paralysis was only 3.5° to 17°.[9] At the lower end of this range, the rotation probably is imperceptible.

Following SLN injection, the asymmetric vibration and morphology, supraglottic anesthesia, and inability to sing at a high pitch produced a constellation of findings consistent only with SLN paralysis, in the opinion of the authors. It is difficult to prove complete SLN paralysis, however, even if a loss of CT activity is documented on electromyography. It is possible, but unlikely, that there is another explanation for the stroboscopic findings.

Clinical correlation is required in the diagnosis of an isolated SLN paralysis with stroboscopy. Other possible causes of asymmetric laryngeal vibration should be considered, including scarring or a submu-

cosal mass, which could rarely produce a similar stroboscopic picture.[2,18] In the setting of suspected SLN injury — for example, a postthyroidectomy patient with a loss of the ability to sing or modulate pitch in continuous speech — an asymmetric mucosal traveling wave or asymmetric vocal fold excursion suggests SLN paralysis, even if other characteristics such as posterior glottic rotation or tension asymmetry are not observed on indirect laryngoscopy alone. In such a situation, laryngeal electromyography provides a sensitive method to verify the presence of a paralysis.[19]

A method of synchronizing glottographic waveforms with videostroboscopic images has recently been developed in our laboratory.[11] Figures 5 and 6 indicate that in studies of patients with asymmetric laryngeal vibration, the first derivative of the EGG waveform provides information about the timing of laryngeal opening and closure, provided that adequate vocal fold contact occurs during phonation. The upward deflection in the EGG first-derivative waveform is a good indicator of the moment of opening, whether in normal patients or in those with asymmetric vibration. The nadir of the dEGG waveform has previously been shown to closely correspond to the moment of laryngeal closure.[20,21] The largest positive peak in the dEGG waveform has been shown to correlate with opening.[20] Our data from synchronizing the videostroboscopic images with glottographic waveforms (Figs 5 and 6) indicate that a similar relationship exists in both RLN and SLN paralyses. Childers et al[20] noted that there was a significant variation in dEGG waveforms dependent on the experimental conditions, such as frequency, which somewhat limits the accuracy of estimating glottic events based on dEGG.

Computerized digital analysis of stroboscopic images holds the promise for quantifying traveling wave abnormalities associated with laryngeal disorders. Figure 4 demonstrates the symmetry ratio applied to laryngeal paralysis. The ratios can provide an objective measure, allowing interpatient and intrapatient comparisons of asymmetry.

Although this study did not report data describing the results of reinnervation or treatment on videostroboscopic findings in RLN paralysis, stroboscopy can document a return of normal symmetry of laryngeal vibration, particularly when the thyroarytenoid muscle is reinnervated. Crumley[22] recently updated his experience with ansa hypoglossi nerve transfer for the treatment of unilateral vocal fold paralysis. He used stroboscopic analysis to document reinnervation, observing return to symmetric vibration in four of five patients assessed following reinnervation.[22]

In conclusion, stroboscopy is a useful tool in the evaluation of patients with suspected laryngeal paralysis. Paralysis of the SLN, RLN, or both results in asymmetric laryngeal vibration that is easily identified even by inexperienced observers. The mucosal wave has a greater velocity and travels further along the mucosa on the normal fold. The probable cause of these vibratory findings is the reduced stiffness in the paralyzed cord, which reduces the velocity and extent of the traveling mucosal wave. Stroboscopy can identify abnormal vibration in patients with otherwise normal findings on indirect examination. Our early experience suggests that stroboscopy cannot reliably distinguish RLN paralysis from vagal paralysis. Studies are being planned in the canine model to better quantify the traveling wave findings in laryngeal paralysis.

REFERENCES

1. Bless DM, Hirano M, Feder RJ. Videostroboscopic evaluation of the larynx. Ear Nose Throat J 1987;66:48-58.

2. Kitzing P. Stroboscopy — a pertinent laryngeal examination. J Otolaryngol 1985;14:151-7.

3. Hirano M, Kakita Y. Cover-body theory of vocal fold vibration. In: Daniloff RG, ed. Speech science. San Diego, Calif: College-Hill Press, 1985:1-46.

4. Moore DM, Berke GS, Hanson DG, Ward PH. Videostroboscopy of the canine larynx: the effects of asymmetric laryngeal tension. Laryngoscope 1987;97:543-53.

5. Von Leden H. The electronic synchron-stroboscope. Its value for the practicing laryngologist. Ann Otol Rhinol Laryngol 1961;70:881-93.

6. Schoenharl E. Die Stroboskopie in der Praktischen Laryngologie. Stuttgart, Germany: Georg Thieme Verlag, 1960.

7. Fex S. Judging the movements of vocal cords in larynx paralysis. Acta Otolaryngol [Suppl] (Stockh) 1970(suppl 263): 82-3.

8. Isshiki N, Tanabe M, Ishizaka K, Broad D. Clinical significance of asymmetrical vocal cord tension. Ann Otol Rhinol Laryngol 1977;86:58-66.

9. Tanabe M, Isshiki N, Kitajima N. Vibratory pattern of the vocal cord in unilateral paralysis of the cricothyroid muscle. An experimental study. Acta Otolaryngol (Stockh) 1972;74:339-45.

10. Abelson TI, Tucker HM. Laryngeal findings in superior laryngeal nerve paralysis: a controversy. Otolaryngol Head Neck Surg 1981;89:463-70.

11. Sercarz JA, Berke GS, Ming Y, Gerratt BR, Kreiman J, Natividad M. Synchronizing videostroboscopic images of human laryngeal vibration with physiologic signals. Am J Otolaryngol (in press).

12. Sercarz JA, Berke GS, Arnstein D, Gerratt B, Natividad M. A new technique for quantitative measurement of laryngeal videostroboscopic images. Arch Otolaryngol Head Neck Surg 1991;117:871-5.

13. Fex S, Elmqvist D. Endemic recurrent laryngeal nerve

paresis. Correlation between EMG and stroboscopic findings. Acta Otolaryngol (Stockh) 1973;75:368-9.

14. Achenbach JD. Wave propagation in elastic solids. Amsterdam, the Netherlands: Elsevier Science Publications, 1987.

15. Hirano M. Morphological structure of the vocal cord as a vibrator and its variations. Folia Phoniatr (Basel) 1974;26:89-94.

16. Dedo HH. The paralyzed larynx: an electromyographic study in dogs and humans. Laryngoscope 1970;80:1455-517.

17. Ward PH, Berci G, Calcaterra TC. Superior laryngeal nerve paralysis: an often overlooked entity. Trans Am Acad Ophthalmol Otolaryngol 1977;84:78-89.

18. Hirano M. Clinical examination of voice. New York, NY: Springer-Verlag, 1981.

19. Blair RL, Berry H, Briant TDR. Laryngeal electromyography: techniques and application. Otolaryngol Clin North Am 1978;11:325-46.

20. Childers DG, Hicks DM, Moore GP, Eskenazi L, Lalwani AL. Electroglottography and vocal fold physiology. J Speech Hear Res 1990;33:245-54.

21. Gerratt BR, Hanson DG, Berke GS. Glottographic measures of laryngeal function in individuals with abnormal motor control. In: Baer T, ed. Proceedings of the 4th International Conference on Vocal Fold Physiology. San Diego, Calif: College-Hill Press, 1986:521-32.

22. Crumley R. Update: ansa cervicalis to recurrent laryngeal nerve anastomosis for unilateral laryngeal paralysis. Laryngoscope 1991;101:384-8.

BILATERAL VOCAL FOLD MOTION IMPAIRMENT: PATHOPHYSIOLOGY AND MANAGEMENT BY TRANSVERSE CORDOTOMY

HASKINS K. KASHIMA, MD

BALTIMORE, MARYLAND

Although bilateral vocal fold paralysis (BVFP) is an uncommon disorder, bilateral vocal fold motion impairment (BVFMI) resulting from a variety of laryngeal derangements is encountered with increasing frequency. Moreover, pure BVFP accounts for only a small proportion of BVFMI. When antecedent factors associated with BVFP are absent, recognition of BVFMI is often delayed and frequently overlooked. The requirements for assessment and successful management of BVFMI are 1) recognition of its presence, 2) identification of the constituent factors restricting vocal fold motion, 3) objective assessment of airway patency, and 4) selection of a reliable management plan. More often than not, two or more BVFMI-causing factors are present; only rarely is BVFMI attributable to a single vocal fold motion–limiting cause. The clinical and endoscopic examinations should evaluate the relative contributions of vocal fold paralysis, cricoarytenoid joint fixation, infiltrative disorders, and webs and synechiae that cause restricted vocal fold motion. The flow-volume loop examination documents airflow rate and volume and the site, nature, and severity of the obstructing lesion(s). This presentation describes the evaluation and rationale for management in BVFMI. The surgical techniques currently used to address BVFMI are compared to determine their respective merits and drawbacks, depending upon the constituent factors causing vocal fold motion limitation.

KEY WORDS — arytenoidectomy, bilateral vocal fold paralysis, cordotomy, cricoarytenoid arthrodesis, infiltrative lesions of vocal folds, laryngeal web.

INTRODUCTION

Bilateral vocal fold paralysis (BVFP), encountered most often after thyroidectomy, is occurring with diminishing frequency. It constitutes a subset of bilateral vocal fold motion impairment (BVFMI), a syndrome that is encountered with increasing frequency in the contemporary medical care setting and that arises from a broad range of circumstances ranging from blunt or endoscopic laryngeal trauma to arthritis. Bilateral vocal fold motion impairment is often the solitary residual after successful treatment of an unrelated principal medical or surgical disorder. Moreover, because the index of suspicion is not high, diagnosis of BVFMI is frequently overlooked.

BILATERAL VOCAL FOLD MOTION IMPAIRMENT

The principal symptoms of BVFMI are dyspnea and voice impairment. Vocal fold flaccidity results in inward vocal cord displacement on forced inspiration, airway collapse, and flow rate limitation. Outward displacement of the vocal folds on expiration causes air wastage and light-headedness. The hypotonic vocal folds appose incompletely on phonation and produce a voice with reduced loudness and limited pitch range. These symptoms can be of variable severity depending, in part, upon degree of paralysis, whether complete or partial. The resulting chronic dyspnea and easy fatigability may masquerade as chronic fatigue syndrome.

There are four principal categories of BVFMI: 1) vocal fold paralysis, 2) cricoarytenoid joint fixation (CAJF), 3) vocal fold infiltrative lesions (VFIL), and 4) cicatricial webs. The foregoing categories occur singularly or in combination and either may result from a primary disorder (such as bulbar palsy causing paralysis, rheumatoid arthritis causing CAJF, amyloidosis causing VFIL, and mucosal pemphigoid causing cicatricial webs) or may have an iatrogenic basis such as after surgical dissection, endotracheal intubation and endoscopic instrumentation, laser dissection, infection, bleeding, and resultant fibrosis (Table 1).

TABLE 1. CATEGORIES AND CAUSES OF BILATERAL VOCAL FOLD MOTION IMPAIRMENT

Bilateral vocal fold paralysis
Thyroidectomy
Parathyroidectomy
Neurologic disorders
Midbrain stroke
Amyotrophic lateral sclerosis
Cricoarytenoid joint fixation
Rheumatoid arthritis
Blunt neck injury
Vocal fold infiltrative lesions
Sarcoid
Amyloid
Postirradiation fibrosis
Wegener's granulomatosis
Lipoid granulomatosis
Idiopathic fibrosis
Posterior glottic web
Prolonged endotracheal intubation
Cicatricial pemphigoid

From the Department of Otolaryngology–Head and Neck Surgery, The Johns Hopkins Medical Institutions, Baltimore, Maryland.

Presented at the meeting of the American Laryngological Association, Waikoloa, Hawaii, May 4-5, 1991.

REPRINTS — Haskins K. Kashima, MD, Dept of Otolaryngology–Head and Neck Surgery, The Johns Hopkins Medical Institutions, 600 N Wolfe St, Carnegie Building Room 469, Baltimore, MD 21205.

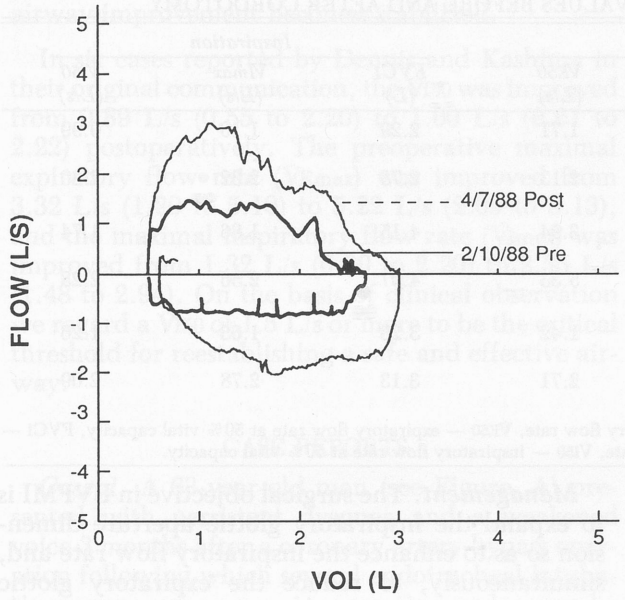

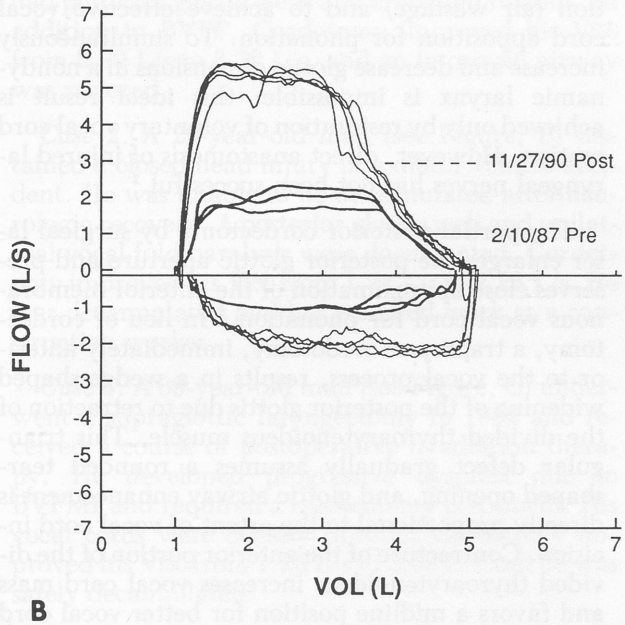

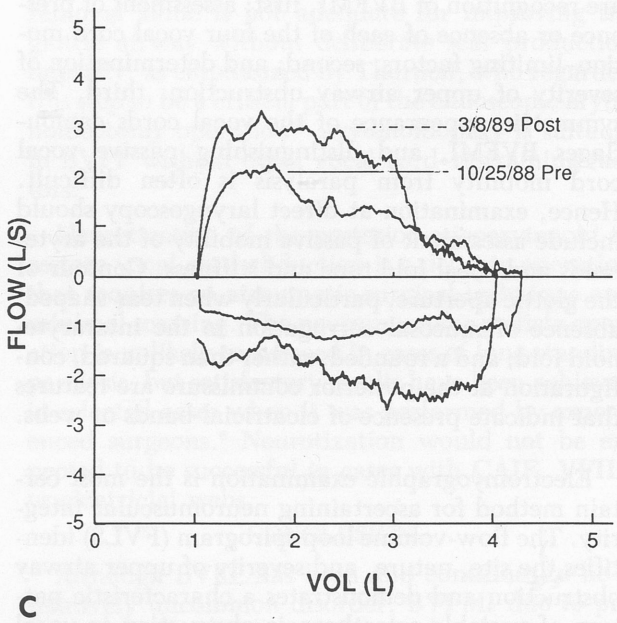

Flow-volume loop spirograms in patients with bilateral vocal fold motion impairment. Pre — before cordotomy, Post — after cordotomy. A) (Case 1) 63-year-old man who had coronary artery bypass, with bilateral vocal fold paralysis and cicatricial web. B) (Case 2) 29-year-old man who sustained closed head injury, with cricoarytenoid joint fixation and cicatricial webbing. C) (Case 3) 69-year-old man who had post–supraglottic laryngectomy fibrosis, with cricoarytenoid joint fixation, vocal fold infiltrative lesions, and cicatricial webbing.

Cricoarytenoid joint fixation immobilizes the arytenoid cartilage, through which the action of the adducting and abducting muscles is transmitted. Passive mobility of the vocal cords is preserved, and passive mobility of the aryepiglottic folds, normally stabilized by the arytenoid, may be exaggerated; hence, inspiratory stridor tends to be conspicuous and voice impairment is less severe.

Infiltrative disorders such as amyloid, sarcoid, or fibrosis in the vocal folds abolish abduction and adduction in spite of intact neuromuscular function; vocal cord rigidity disallows passive displacement. Airway limitation and voice compromise tend to be severe.

Cicatricial webs inhibit abduction more than adduction so that airway compromise is more severe and voice impairment is usually minimal. Pure laryngeal paralysis abolishes voluntary abduction and/or adduction. Passive displacement of the vocal folds is greater than with CAJF, VFIL, or cicatricial webs; in paralysis of long standing, passive vocal cord excursion is exaggerated because of muscle atrophy. The above features are compounded when one or more inhibiting lesions coexist — a common occurrence. Postinflammatory reactive infiltration and cicatricial webs can be sequelae to laryngeal instrumentation and/or endotracheal intubation; such iatrogenic aftereffects compound the nature and severity of BVFMI.

Irrespective of the underlying dysfunction, BVFMI presents with a near-indistinguishable clinical picture. Differentiating the four categories of BVFMI

TABLE 2. FLOW-VOLUME LOOP SPIROGRAM VALUES BEFORE AND AFTER CORDOTOMY

		Expiration			*Inspiration*		
Patient	*Date*	*FVCE (L)*	*V̇Emax (L/s)*	*V̇E50 (L/s)*	*FVCI (L)*	*V̇Imax (L/s)*	*V̇I50 (L/s)*
1	Preoperative (2/10/88)	2.29	1.86	1.71	2.29	1.10	0.99
	Postoperative (4/7/88)	2.90	3.47	2.13	2.78	2.32	2.30
2	Preoperative (2/10/87)	4.54	4.08	3.94	4.15	1.86	1.74
	Postoperative (11/27/90)	4.33	5.92	5.33	4.07	2.56	2.28
3	Preoperative (10/25/88)	3.39	2.34	1.42	3.28	1.63	1.26
	Postoperative (3/8/89)	3.13	3.48	2.71	3.13	2.78	2.09

FVCE — forced vital capacity on expiration, V̇Emax — maximal expiratory flow rate, V̇E50 — expiratory flow rate at 50% vital capacity, FVCI — forced vital capacity on inspiration, V̇Imax — maximal inspiratory flow rate, V̇I50 — inspiratory flow rate at 50% vital capacity.

is important in selecting the optimum treatment method (eg, whether vocal fold lateralization or nerve-muscle pedicle).

Evaluation. The objectives in clinical evaluation are recognition of BVFMI, first; assessment of presence or absence of each of the four vocal cord motion–limiting factors, second; and determination of severity of upper airway obstruction, third. The symmetric appearance of the vocal cords camouflages BVFMI, and distinguishing passive vocal cord mobility from paralysis is often difficult. Hence, examination at direct laryngoscopy should include assessment of passive mobility of the arytenoids and vocal fold tone and stiffness. Contour of the glottic aperture, particularly when tear-shaped; absence of mucosal corrugation in the interarytenoid fold; and a rounded, rather than squared, configuration at the posterior commissure are features that indicate presence of cicatricial bands or webs.

Electromyographic examination is the most certain method for ascertaining neuromuscular integrity. The flow-volume loop spirogram (FVLS) identifies the site, nature, and severity of upper airway obstruction and demonstrates a characteristic pattern of variable extrathoracic obstruction in vocal cord paralysis, unilateral and bilateral.[1] Two distinct FVLS patterns are observed in upper airway obstruction due to BVFMI. When flow rate limitation occurs during both inspiration and expiration, the FVLS pattern is termed fixed; this pattern is observed in cases of VFIL (see Figure, C and Table 2). An FVLS pattern with selective inspiratory flow rate limitation and normal expiratory flow rate is termed variable extrathoracic obstruction (VEO; see Figure; A,B and Table 2). The VEO pattern is observed in BVFP, CAJF, and cicatricial webs. The FVLS examination, serially performed, objectively documents improvement or progression in respiratory flow rates and is an ideal reference standard for determining airway adequacy. A mid–vital capacity flow rate (V̇I50) of 1.5 L/s is the necessary threshold for moderate activity in most adults.

Management. The surgical objective in BVFMI is to expand the inspiratory glottic aperture dimension so as to enhance the inspiratory flow rate and, simultaneously, to reduce the expiratory glottic aperture to minimize excessive airflow on expiration (air wastage) and to achieve effective vocal cord apposition for phonation. To simultaneously increase and decrease glottic dimensions in a nondynamic larynx is impossible; this ideal result is achieved only by restoration of voluntary vocal cord motion. However, direct anastomosis of injured laryngeal nerves has not been successful.[2]

The partial posterior cordectomy by surgical laser enlarges the posterior glottic aperture and preserves close approximation of the anterior membranous vocal cord for phonation.[3] In lieu of cordectomy, a transverse cordotomy, immediately anterior to the vocal process, results in a wedge-shaped widening of the posterior glottis due to retraction of the divided thyroarytenoideus muscle. This triangular defect gradually assumes a rounded tear-shaped opening, and glottic airway enhancement is directly proportional to the extent of vocal cord incision. Contracture of the anterior portion of the divided thyroarytenoideus increases vocal cord mass and favors a midline position for better vocal cord apposition and effective voice production. This transverse cordotomy operation offers the advantages of simplicity, minimal trauma, and a predictable degree of airway enhancement. When additional airway enlargement is necessary, a revision operation with further transverse division of the ipsilateral or contralateral vocal cord is performed. Neither cricoarytenoid joint fixation nor glottic web nor infiltrative disorders and fibrosis of the vocal cords limits effectiveness of this operation to achieve airway improvement.

Dennis and Kashima, who conceived the posterior cordectomy operation, have reported that this operation can be relatively safely performed without preliminary tracheotomy.[3] Virtually all of our patients present with a tracheostomy, which we vent for several weeks postoperatively until the final

airway improvement becomes stabilized.

In six cases reported by Dennis and Kashima in their original communication, the $\dot{V}_{I50}$ was improved from 0.89 L/s (0.55 to 2.20) to 1.60 L/s (0.61 to 2.22) postoperatively. The preoperative maximal expiratory flow rate ($\dot{V}_{Emax}$) was improved from 3.32 L/s (1.20 to 5.10) to 5.22 L/s (2.09 to 8.13), and the maximal inspiratory flow rate ($\dot{V}_{Imax}$) was improved from 1.32 L/s (0.80 to 2.20) to 2.35 L/s (1.48 to 2.94). On the basis of clinical observation we regard a $\dot{V}_{I50}$ of 1.5 L/s or more to be the critical threshold for reestablishing a safe and effective airway.

CASE REPORTS

Case 1. A 63-year-old man (see Figure, A) presented with persistent dyspnea and a weakened voice 3 months after a coronary artery bypass operation following which several endotracheal intubations were necessary. At operative endoscopy he had posterior glottic webs and arytenoid fixation, in addition to BVFP. Cordotomy improved his $\dot{V}_{I50}$ from 0.99 L/s to 2.30 L/s, and an improved airway was restored.

Case 2. A 29-year-old man (see Figure, B) sustained a closed head injury in a motor vehicle accident. He was unable to be decannulated after neurologic recovery. A posterior glottic web and unilateral vocal fold paralysis were documented. Cordotomy improved his $\dot{V}_{I50}$ from 1.74 L/s to 2.28 L/s. He was decannulated and has resumed work as a construction worker.

Case 3. A 69-year-old man (see Figure, C) underwent a supraglottic laryngectomy in 1982 and received a course of postoperative irradiation therapy. He developed progressive dyspnea due to BVFMI and required a tracheotomy placement. His vocal cords were densely fibrotic. Cordotomy improved his $\dot{V}_{I50}$ from 1.26 L/s to 2.09 L/s and he was safely decannulated.

DISCUSSION

Tracheotomy with use of a valved tracheotomy tube is a management choice of high reliability and minimal morbidity. It is particularly well suited for individuals with severe comorbidities and airway instability. Voice quality is preserved.

The objective in subtotal cordectomy operations is air passage enlargement by reduction of a vocal cord mass. The final airway caliber is not precisely predictable and the voice result is imperfect. Use of the surgical laser has improved precision of vocal cord excisions, and novel techniques for reduction of vocal cord mass with preservation of mucosa will likely be developed.

The arytenoid cartilage, by virtue of its crucial relationship to the lateral and posterior cricoarytenoid, interarytenoid, and thyroarytenoid muscles, logically has long been the focus of surgical interest to achieve vocal cord lateralization. Although numerous surgical techniques have been described in minute detail, exposure of the arytenoid is difficult and usually suboptimal; the necessary muscle detachments are more readily achieved in textbook diagrams than in the operative field. Moreover, in CAJF with infiltrative or fibrotic lesions of the vocal fold, lateralization of the arytenoids and vocal cords is difficult to achieve, and in the presence of webs, the opposite vocal cord is drawn toward the repositioned arytenoid, minimizing the intended enlargement of the posterior glottic aperture. In spite of these limitations, a high proportion of successful rehabilitation in bilateral vocal fold "paralysis" has been achieved by experienced surgeons.[4] Arytenoid removal alone is not adequate for improving the glottic airway without deliberate scar production laterally, as emphasized by Thornell, who regarded this step to be a critical part of the endoscopic arytenoidectomy operation.[5] Arytenoidopexy is suitable in BVFP without other vocal cord–restraining factors.

Neurotization of the posterior cricoarytenoid to restore vocal cord abduction is a delicate operation that requires an atraumatic surgical technique and minimal scarring. The neuromuscular pedicle operation is unlikely to succeed in cases of long-standing paralysis, but satisfactory results have been achieved in selected cases when it was performed by experienced surgeons.[6] Neurotization would not be expected to be successful in cases with CAJF, VFIL, or cicatricial webs.

CONCLUSION

Although BVFP has been and continues to be a relatively uncommon disorder, BVFMI due to paralysis, CAJF, VFIL, or cicatricial webs is encountered with increasing frequency in the current era of complex medical treatments. This presentation suggests that distinguishing these BVFMI subgroups and recognizing their unique features will lead to improved results in their management.

The patient with BVFMI syndrome is plagued by a precarious airway, often in the presence of one or more serious comorbidities. In such settings, a straightforward and reliable airway restoration is of paramount importance. Transverse cordotomy by carbon dioxide laser appears ideally suited to achieve this goal.

REFERENCES

1. Kashima HK. Documentation of upper airway obstruction in unilateral vocal cord paralysis: flow-volume loop studies in 43 subjects. Laryngoscope 1984;94:923-37.

2. Tucker HM. Vocal cord paralysis — 1979: etiology and management. Laryngoscope 1980;90:585-90.

3. Dennis DP, Kashima H. Carbon dioxide laser posterior cordectomy for treatment of bilateral vocal cord paralysis. Ann Otol Rhinol Laryngol 1989;98:930-4.

4. Woodman D, Pennington CL. Bilateral abductor paralysis. 30 years experience with arytenoidectomy. Ann Otol Rhinol Laryngol 1976;85:437-9.

5. Thornell WC. Transoral intralaryngeal approach for arytenoidectomy in the treatment of bilateral abductor vocal cord paralysis. In: Jackson CL, ed. Diseases of the nose, throat and ear. Philadelphia, Pa: WB Saunders, 1959:647-50.

6. Tucker HM. Long-term results of nerve-muscle pedicle reinnervation for laryngeal paralysis. Ann Otol Rhinol Laryngol 1989;98:674-6.

STROBOSCOPY FOR GLOTTIC T1A CARCINOMAS: ITS ROLE IN DIAGNOSIS

MINORU HIRANO, MD
SHINZO TANAKA, MD
RONGXIANG ZHAO, MD
KIMINORI SATO, MD

KURUME, JAPAN

Video stroboscopy was conducted in 34 patients with glottic T1a carcinoma. Four stroboscopic parameters were investigated: amplitude of vibration (AMP) of the entire vocal fold (AMPE) and the lesion (AMPL) and mucosal wave (WAV) of the entire vocal fold (WAVE) and the lesion (WAVL). The stroboscopic findings were related to the extent of the lesion and to the clinical diagnosis. In addition, the role of stroboscopy in differentiating carcinoma and epithelial hyperplasia/dysplasia was investigated by comparing the stroboscopic findings of the 34 patients with those of 72 vocal folds with epithelial hyperplasia/dysplasia. The WAVL was zero in all patients and AMPE, AMPL, and WAVE were small or zero in all but one patient. WAVE was negatively related to the extent of the lesion. Both AMPE and AMPL were negatively related to the extent of the lesion in nonexophytic lesions. Compared with fiberscopy under ordinary light, stroboscopy increased the rate of correct clinical diagnosis by 29%. In three false-negative cases under ordinary light, stroboscopy indicated a possibility of malignancy. Stroboscopy was useful in differentiating carcinoma and epithelial hyperplasia/dysplasia in 21 of the 39 cases in which clinical diagnosis was undetermined under ordinary light.

KEY WORDS — diagnosis, epithelial hyperplasia, glottic carcinoma, stroboscopy, vocal fold vibration.

The usefulness of laryngeal stroboscopy in detecting early glottic carcinomas has been emphasized by many investigators.[1-6] The most significant stroboscopic manifestation of carcinoma has been reported to be an absence of mucosal wave and lack of vibratory movements at the affected portion of the vocal fold. On the other hand, well-trained laryngologists empirically know that in some or even many cases, early glottic carcinomas can be detected simply by means of laryngeal mirror or fiberscopic examination with ordinary light. Under ordinary light, however, differentiation of early glottic carcinoma from epithelial hyperplasia/dysplasia (EH) is occasionally difficult. Other benign disorders can be clinically differentiated from glottic carcinoma more frequently under ordinary light.

There have been few reports that give answers to the following questions. What percentage of early glottic carcinomas can be clinically diagnosed without stroboscopy? What percentage of early glottic carcinomas calls for stroboscopy for clinical diagnosis? What percentage of early glottic carcinomas cannot be clinically diagnosed even with stroboscopy? What are the important stroboscopic parameters for clinical diagnosis of early glottic carcinomas? Is the extent of disease related to stroboscopic findings? To what extent is stroboscopy useful in differentiating early glottic carcinoma from EH? The purpose of this study was to find some answers to these questions.

SUBJECTS AND METHODS

The subjects of this study were 34 adult patients (33 men and 1 woman) with previously untreated glottic T1a carcinoma who underwent a pretherapeutic video fiberstroboscopy and microendoscopic biopsy from 1984 to 1989 at the Department of Otolaryngology–Head and Neck Surgery, Kurume University Hospital. Their ages ranged from 45 to 81 years with a mean of 65 years.

Video fiberstroboscopy was conducted under surface anesthesia of the pharyngeal and laryngeal mucosa. The tip of the fiberscope was placed close to the vocal fold so that the structure and vibratory behavior of the vocal fold could be observed in detail. The image of the vocal folds occupied about a half or more of the vertical dimension of the television screen in most cases. In the video fiberstroboscopy, the amplitude of vibration (AMP) and the mucosal wave (WAV) were evaluated and they were categorized into four groups: great, normal, small, and zero. Thus, AMP and WAV were determined for the entire vocal fold (AMPE, WAVE) and for the affected portion or the lesion (AMPL, WAVL). In contrast, AMPE and WAVE were determined at the location where the vibratory amplitude and mucosal wave, respectively, were greatest. Other stroboscopic parameters, including symmetry of vibratory movements of the two vocal folds, regularity of successive vibrations, and glottic closure, were also investigated, but they were not important for the diagnosis of carcinoma. Therefore, they were not included in this paper.

For the purpose of quantifying the extent of the lesion, a relative area of the lesion (AR) was determined. It was defined as a ratio of the area of the le-

From the Department of Otolaryngology–Head and Neck Surgery, Kurume University, Kurume, Japan. This investigation was supported in part by a Grant-in-Aid for Scientific Research (No. 04254399) from the Japanese Ministry of Education, Science and Culture.

Presented at the meeting of the American Laryngological Association, Waikoloa, Hawaii, May 4-5, 1991.

REPRINTS — Minoru Hirano, MD, Dept of Otolaryngology–Head and Neck Surgery, Kurume University, 67 Asahi-machi, Kurume 830, Japan.

TABLE 1. AMPLITUDE OF VIBRATION AND MUCOSAL WAVE IN 34 PATIENTS WITH GLOTTIC T1A CARCINOMA

	AMPE	*AMPL*	*WAVE*	*WAVL*
Normal	1 (3%)*	0	1 (3%)*	0
Small	20 (59%)	17 (50%)	8 (24%)	0
Zero	13 (38%)	17 (50%)	25 (74%)	34 (100%)

AMPE — amplitude of vibration of entire vocal fold, AMPL — amplitude of vibration of lesion, WAVE — mucosal wave of entire vocal fold, WAVL — mucosal wave of lesion.

*Exophytic lesion located chiefly at posterior glottis.

sion to the area of the entire membranous vocal fold. The measurements were performed on the video images of the vocal fold. The extent of the lesion was related to the stroboscopic categorization.

The clinical diagnosis based on fiberscopy with an ordinary light and that based on video fiberstroboscopy were reviewed on the patients' charts and they were checked and confirmed by reviewing the videotapes repeatedly. The clinical diagnosis under ordinary light and that under stroboscopic light depended on the visual judgment of well-trained laryngologists. The intra-examiner and inter-examiner reliabilities of this diagnostic procedure were high, being 90% or greater. The relationships of the clinical diagnosis to the stroboscopic parameters and AR were investigated.

In order to determine the significance of stroboscopy in differentiating carcinoma and EH, the relationship of the stroboscopic findings to the clinical diagnosis in this study was compared to that obtained from 72 vocal folds with EH in 53 patients. Details of stroboscopic findings of the EH cases and their relationship to the extent of lesion have been reported in a separate paper.[7] In the separate paper, however, relationships between the clinical diagnosis and stroboscopic findings were not investigated. In the present study, the clinical diagnosis for the 72 vocal folds with EH was reviewed and checked in the same way as that for the carcinoma cases. The clinical diagnosis was related to the stroboscopic findings.

RESULTS

Stroboscopic Findings. Table 1 shows the results of the stroboscopic examination. In all but one case, AMP and WAV were limited. The limitation was more marked in mucosal wave than in amplitude and it was more marked for the affected portion than for the entire vocal fold. No mucosal wave was observed at the lesion in all cases (zero WAVL). The exceptional case that presented a normal AMPE and WAVE had an exophytic lesion located chiefly at the posterior glottis. Only a posterior portion of the membranous vocal fold was involved.

Extent of Lesion Versus Stroboscopic Findings. The Figure depicts a scatterplot of AR values as a function of the category of AMPE, AMPL, WAVE, and WAVL for individual cases. The numbers at the bottom portion show the mean value and standard deviation of AR in each category. The statistical significance of the difference in mean value of AR between categories (t test) is also indicated in the bottom part of the Figure.

The amplitude of vibration evaluated for the entire vocal fold (AMPE) and for the lesion (AMPL) did not depend on the extent of the lesion (AR) for the entire cases. It should be noted, however, that exophytic lesions (crosses in the Figure) tended to show less limitation of AMP. Most cases with an exophyt-

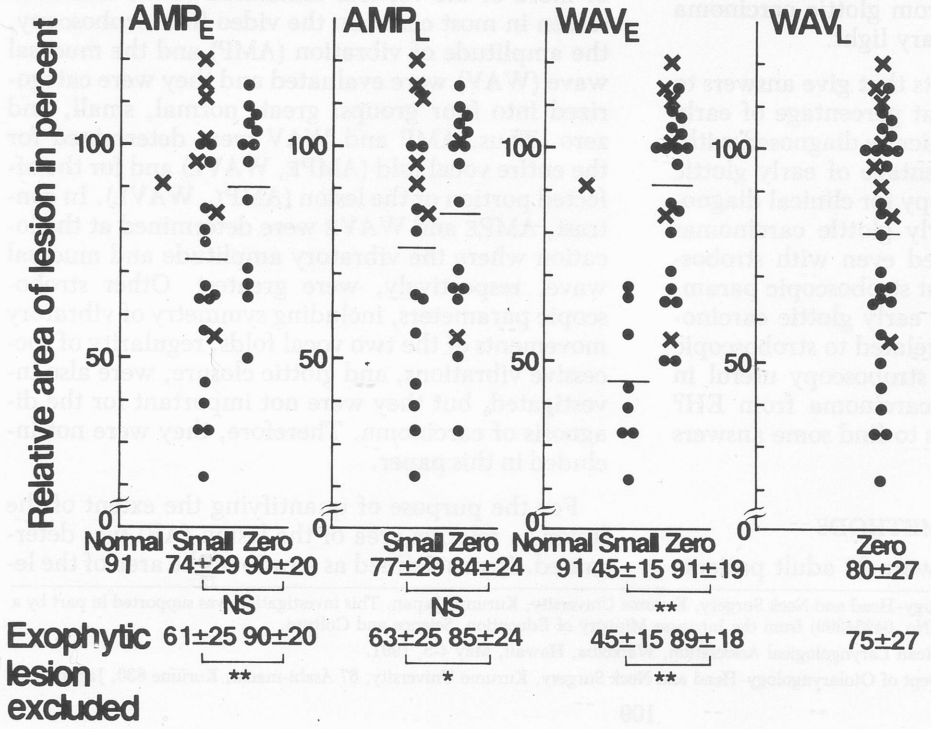

Scatterplot of extent of lesion values as function of size of amplitude of vibration (AMP) and mucosal wave (WAV) for individual patients (E — entire, L — lesion only). Crosses — exophytic lesion, bullets — nonexophytic lesion, numbers at bottom portion — mean and SD, ** — $p<.01$, * — $p<.05$, NS — $p>.05$.

TABLE 2. RELATIONSHIP OF CLINICAL DIAGNOSIS TO STROBOSCOPIC FINDINGS

Stroboscopic Findings	*Clinical Diagnosis*		
	OL Ca, Strob Ca (n = 21)	*OL ?, Strob Ca (n = 10)*	*OL Benign, Strob ? (n = 3)*
AMPE			
Normal	1*		
Small	10	7	3
Zero	10	3	
AMPL			
Small	8	6	3
Zero	13	4	
WAVE			
Normal	1*		
Small	2	3	2
Zero	18	7	1
WAVL			
Zero	21	10	3

OL — ordinary light, Strob — stroboscopic light, Ca — carcinoma, ? — not determined. Other abbreviations as in Table 1.

*Lesion located chiefly at posterior glottis.

ic lesion presented with a high AR value but a small (not zero) AMPE and AMPL. This was in contrast to the majority of cases with a nonexophytic lesion (bullets in the Figure), which had a comparable value of AR and presented a zero AMPE and AMPL. Among the cases with nonexophytic lesions, the mean AR was significantly greater for zero AMPE and AMPL than for small AMPE and AMPL, respectively, as indicated at the bottom of the Figure.

The mucosal wave evaluated for the entire vocal fold (WAVE) was negatively related to AR. No mucosal wave was observed on the lesion in all cases, regardless of the extent of the lesion.

Ordinary Light Versus Stroboscopic Light in Clinical Diagnosis. In 21 of the 34 patients, the clinical diagnosis of glottic carcinoma was correctly made under fiberoscopy with ordinary light, and this was assured under stroboscopic light. In 10 patients, it was undetermined under ordinary light whether the lesion was malignant or benign, and the clinical diagnosis of glottic carcinoma was correctly determined by means of stroboscopy. One case was diagnosed as a polyp under ordinary light, but with the use of stroboscopic light, the diagnosis was undetermined because a possibility of carcinoma was suggested. In two cases, the clinical diagnosis under ordinary light was epithelial hyperplasia, but a possibility of carcinoma was indicated under stroboscopic light. Thus, the diagnosis under ordinary light was correct in 21 patients (62%), undetermined in 10 (29%), and false-negative in 3 (9%). The diagnosis by means of stroboscopy was correct in 31 patients (91%) and undetermined in 3 (9%). There were no false-negative cases under stroboscopy. Stroboscopy was also useful, in many cases, in estimating the extent of subepithelial invasion. Limitation of mucosal wave was the landmark for subepithelial extension.

The relationship of clinical diagnosis to stroboscopic findings is shown in Table 2. As described earlier, no mucosal wave was observed at the lesion (zero WAVL) in all cases, regardless of clinical diagnosis. Those patients in whom a diagnosis of carcinoma was correctly made under ordinary light frequently (18/21) presented a lack of mucosal wave on the entire vocal fold (zero WAVE), indicating that the superficial layer of the lamina propria or Reinke's space was stiffened. All cases of zero AMPE and those with zero AMPL were correctly diagnosed as carcinoma under stroboscopic light. All but one of the cases of zero WAVE were also stroboscopically diagnosed as carcinoma. The exception was a case in which a thin and partly hyperkeratotic lesion occupied 100% of the area of the membranous vocal fold. In this patient with zero WAVE, the am-

TABLE 3. STROBOSCOPIC FINDINGS IN CARCINOMA AND EPITHELIAL HYPERPLASIA/DYSPLASIA

Stroboscopic Findings				*Clinical Diagnosis for 34 Ca Patients*			*Clinical Diagnosis for 72 EH Vocal Folds*					
AMPE	*AMPL*	*WAVE*	*WAVL*	*OL Ca, Strob Ca (n = 21)*	*OL ?, Strob Ca (n = 10)*	*OL Benign, Strob ? (n = 3)*	*OL EH, Strob EH (n = 35)*	*OL ?, Strob EH (n = 11)*	*OL EH, Strob ? (n = 4)*	*OL ?, Strob ? (n = 17)*	*OL ?, Strob Ca (n = 1)*	*OL Ca, Strob Ca (n = 4)*
N	N	N	N				11					
N	N	N	S				1					
N	N	N	Z					1				
N	N	S	S				3					
N	N	S	Z				1					
N	S	N	S				1					
N	S	N	Z	1*				1				
S	S	N	N				1					
S	S	N	Z				1					
S	S	S	S				8	1		1		
S	S	S	Z	1	3	2	5	2	4	6		
S	S	Z	Z	6	3	1	3	6		7		1
S	Z	S	Z	1						2		1
S	Z	Z	Z	2	1					1		
Z	Z	Z	Z	10	3						1	2

EH — epithelial hyperplasia/dysplasia, N — normal, S — small, Z — zero. Other abbreviations as in Tables 1 and 2.

*Lesion located chiefly at posterior glottis.

plitude of vibration was smaller than normal but not very limited.

Clinical Diagnosis Versus Extent of Lesion. The mean AR value and SD were 87.2% ± 22.4% for the 21 patients in whom the diagnosis was correctly made under ordinary light, 73.0% ± 28.2% for the 10 patients in whom the correct diagnosis was made only under stroboscopic light, and 57.3% ± 30.3% for the 3 patients in whom diagnosis was undetermined under stroboscopy. The difference in mean AR value among the three groups was not statistically significant.

Stroboscopy in Differentiating Carcinoma and Epithelial Hyperplasia/Dysplasia. Table 3 compares stroboscopic findings of carcinoma cases in the present series with those of 72 vocal folds with EH in 53 patients and relates the stroboscopic findings to clinical diagnosis. Stroboscopic findings are presented as combinations of the categories, ie, normal, small, or zero, for the four parameters, ie, AMPE, AMPL, WAVE, and WAVL.

Of the 72 cases of EH, 35 were correctly diagnosed as EH under ordinary light and the diagnosis was stroboscopically confirmed. For 11 vocal folds, the diagnosis was not determined under ordinary light but stroboscopy yielded a diagnosis of EH. In 4 vocal folds, the lesion was diagnosed as EH under ordinary light but stroboscopic diagnosis was undetermined, indicating a possibility of carcinoma. In 17 vocal folds, clinical diagnosis was not determined under both ordinary and stroboscopic light. Stroboscopy was false-positive in 5 vocal folds, and in 4 of the 5 the clinical diagnosis under ordinary light was also false-positive. Thus, clinical diagnosis under ordinary light was correct in 39 vocal folds (54%), false-positive in 4 (6%), and undetermined in 29 (40%). Stroboscopic diagnosis was correct in 46 (64%), false-positive in 5 (7%), and undetermined in 21 (29%).

As shown in Table 3, stroboscopic diagnosis for carcinoma and EH did not simply depend on the normal/small/zero categorization of the four parameters, ie, AMPE, AMPL, WAVE, and WAVL. No simple, straightforward relationships were found between the stroboscopic findings and clinical diagnosis. Nevertheless, the following points can be made.

1. When a mucosal wave was observed at the lesion (normal or small WAVL), the disorder was EH and the clinical diagnosis was correctly made under stroboscopy.

2. When AMPE, AMPL, and/or WAVE was normal, the disorder was EH, except in one case in which a carcinomatous lesion was located chiefly at the posterior glottis. The clinical diagnosis was correct in all these cases.

3. When all four parameters were categorized as zero — in other words, when the affected vocal fold was completely still during phonation — the stroboscopic diagnosis was carcinoma. Sixteen vocal folds fell in this group. Of the 16, however, 3 were false-positive.

4. When WAVL was zero and none of the other three parameters were normal, the stroboscopic diagnosis varied. The diagnosis depended not only on the four stroboscopic parameters investigated, but also on some other clinical findings, including the color, surface texture, shape, and ulceration of the lesion.

COMMENTS

Several questions were presented earlier in this paper. Some answers were obtained from the results of this study.

What percentage of early glottic carcinomas can be clinically diagnosed without stroboscopy? The answer obtained from this study was 62%. What percentage of early glottic carcinomas calls for stroboscopy for clinical diagnosis? The answer from this study was 29%. What percentage of early glottic carcinoma cannot be clinically diagnosed even with stroboscopy? The answer was 9%. What are the important stroboscopic parameters for clinical diagnosis of early glottic carcinomas? The answer was that the important parameters were first, the mucosal wave (WAV), and second, the amplitude of vibration (AMP). They should have been evaluated for the affected portion of the vocal fold and for the entire vocal fold. Carcinomas presented no WAV at the affected portion. The next question was, Is the extent of disease related to stroboscopic findings? The answer was yes, for nonexophytic lesions. The greater the extent of lesion was, the more limited WAV and AMP tended to be.

The final question proposed earlier was, To what extent is stroboscopy useful in differentiating early glottic carcinoma from EH? The answer could not be given by a single number or percentage. Among the 106 lesions in Table 3, the clinical diagnosis was not determined under ordinary light in 39 (10 of carcinoma and 29 of EH). Stroboscopy yielded a correct diagnosis in 21 of the 39 (54%), ie, in all 10 with carcinoma and 11 of the 29 with EH. Stroboscopy could not yield a diagnosis in 17 of the 39, and it gave a false-positive diagnosis in the other 1. It should be noted that there were no false-negative cases in the stroboscopic examination. Under ordinary light, there were 3 false-negative cases. Stroboscopy indicated the possibility of malignancy in these 3 cases, although it could not determine correct clinical diagnosis.

The final diagnosis of carcinoma and that of EH usually depend on a histopathologic study. The accuracy of clinical diagnosis is particularly important in determining how soon a biopsy for histo-

pathologic study should be made, as well as in determining the treatment modality. Epithelial hyperplasia/dysplasia occasionally disappears following cessation of cigarette smoking. An accurate clinical diagnosis of EH can occasionally prevent a biopsy procedure under general anesthesia.

The results of this study indicate that laryngeal stroboscopy plays an important role in the clinical diagnosis of early glottic carcinomas and in the differential diagnosis of carcinoma and EH of the vocal fold. It should also be mentioned that stroboscopy is useful in estimating the extent of subepithelial invasion. A correct estimation of the subepithelial invasion is particularly demanded when laser surgery is conducted.

Finally, a technical suggestion will be given. In order to make a correct stroboscopic diagnosis, it is absolutely necessary to obtain magnified and clear images of the vocal fold. Video stroboscopy seems to have been becoming more and more popular in laryngologic practice over the past several years. This is an epoch-making development in laryngology and it has greatly improved the quality of laryngologic practice. However, the value of video stroboscopy cannot be high when the stroboscopic images are poor. One of the keys to obtaining good images is to place the tip of the fiberscope close to the vocal folds.

Patients with glottic carcinoma frequently tend to narrow the supraglottic cavity when they phonate. This prevents good images from being obtained. We recommend the following technique. Surface anesthesia is given down to the upper trachea. A fiberscope is first inserted into the upper trachea. It is then pulled gradually while one is examining the upper trachea, subglottis, anterior commissure, posterior glottis, and vocal folds under ordinary light. When the fiberscope is located immediately above the glottis, the patient is asked to phonate. In many patients, the larynx moves downward during phonation and, therefore, the fiberscope located immediately above the glottis during respiration often catches images of the entire vocal fold during phonation. The location of the fiberscope is adjusted according to the location of the vocal folds during phonation. When good images are obtained the ordinary light is switched to a stroboscopic light. The entire procedure is recorded on a videotape.

In conclusion, video stroboscopy is a useful clinical tool in diagnosis of early glottic carcinoma when it is conducted with an adequate technique.

REFERENCES

1. Schönhärl E. Die Stroboskopie in der praktischen Laryngologie. Stuttgart, Federal Republic of Germany: Georg Thieme, 1960.

2. Von Leden H. The electronic synchron-stroboscope. Its value for the practicing laryngologist. Ann Otol Rhinol Laryngol 1961;70:881-93.

3. Alberti PW. The diagnostic role of laryngeal stroboscopy. Otolaryngol Clin North Am 1978;11:347-54.

4. Hirano M. Clinical examination of voice. New York, NY: Springer-Verlag, 1981.

5. Kitzing P. Stroboscopy — a pertinent laryngological examination. J Otolaryngol 1985;14:151-7.

6. Hirano M. Objective evaluation of the human voice: clinical aspects. Folia Phoniatr (Basel) 1989;41:89-144.

7. Zhao R, Hirano M, Tanaka S, Sato K. Vocal fold epithelial hyperplasia: vibratory behavior vs extent of lesion. Arch Otolaryngol Head Neck Surg 1991;117:1015-8.

OPEN SLOPE QUOTIENT: AN ESTIMATOR OF GLOTTIC RESISTANCE

DAVID H. SLAVIT, MD
BROOKLYN, NEW YORK

THOMAS V. MCCAFFREY, MD, PHD
ROCHESTER, MINNESOTA

This study introduces a new objective measurement of the vibratory pattern termed the open slope quotient, based on the maximum slope of the photoglottographic waveform during glottic opening. By using an excised canine larynx model, the electroglottographic and photoglottographic waveforms, sound intensity, and subglottic pressure were recorded while vocal fold tension, glottic width, and airflow rate were systematically varied. Multiple regression analysis of the data from nine larynges revealed the open slope quotient to be inversely related to glottic width ($p < .001$) and vocal fold tension ($p < .001$) and directly related to glottic resistance ($p < .001$) and subglottic pressure ($p < .001$). The open slope quotient was better correlated with glottic width, subglottic pressure, and glottic resistance than the speed quotient. The open quotient was directly related to longitudinal vocal fold tension ($p < .01$) and glottic efficiency ($p < .001$). Similar results were found in pilot data in humans. The open slope quotient appears to be an estimator of glottic width and laryngeal resistance, while the open quotient reflects changes in vocal fold tension and glottic efficiency.

KEY WORDS — electroglottography, glottic resistance, open slope quotient, phonation, photoglottography, vocal fold vibration.

INTRODUCTION

The development of valid and reliable measurements of vocal fold vibration during phonation continues to be a goal of research in laryngeal physiology. New phonosurgical techniques have been proposed, including laryngeal framework procedures,[1] collagen vocal fold injections,[2] and microlaryngeal surgery[3]; however, objective assessment of these procedures has been limited. Tests have been developed to study the acoustic signal and aerodynamic parameters,[4,5] yet techniques to objectively study the actual vibratory patterns of the vocal folds have been limited.

Video laryngostroboscopy is limited in that the images represent a composite of events obtained from several vibratory cycles. Stroboscopy, therefore, does not show fine details of each vibratory cycle, and the composite image cannot show fine variations from cycle to cycle. High-speed photography, on the other hand, does provide continuous monitoring of the vocal folds during phonation; however, this technique is cumbersome, expensive, and clinically impractical because voice samples are limited to a second or two of phonation, and the time necessary to develop the film negates on-line monitoring of phonation.

Glottographic techniques, in particular electroglottography (EGG) and photoglottography (PGG), provide electrical signals that reflect the vibratory nature of the vocal folds for each cycle of vibration. Electroglottography[6,7] measures impedance to a low current flow across the neck at the level of the vocal folds and provides an estimate of the vocal fold contact during the glottic cycle. Photoglottography[8] measures the amount of light transmitted through the vocal folds during phonation. The photosensor placed on the neck below the vocal folds measures the transillumination of light through the glottis, reflecting the changes in the glottic area during phonation. Identification of events related to opening and closing of the glottis can be made on the basis of the PGG and EGG waveforms.[9]

Two measures of glottic cycle, calculated from the PGG and EGG waveforms, with potential clinical application are the open quotient (OQ) and the speed quotient (SQ). The OQ is defined as the fraction of time the folds are open during the glottic cycle, and the SQ is defined as the duration of time the folds are opening divided by the duration of time the folds are closing (Fig 1). Studies in humans have shown that the SQ can reflect the nature of vocal fold paralysis, distinguishing between vocal fold paralyses due to recurrent laryngeal nerve injury, superior laryngeal nerve injury, and high vagal nerve injury.[10] The OQ could distinguish pathologic phonation from normal but could not separate the different lesions.[10]

Nevertheless, few significant applications have

From the Department of Otorhinolaryngology, Mayo Clinic and Mayo Foundation, Rochester, Minnesota. Dr Slavit is currently at the Department of Otolaryngology, State University of New York at Brooklyn, Brooklyn, New York. This study was performed in accordance with the PHS Policy on Humane Care and Use of Laboratory Animals, the NIH *Guide for the Care and Use of Laboratory Animals*, and the Animal Welfare Act (7 U.S.C. et seq.); the animal use protocol was approved by the Institutional Animal Care and Use Committee (IACUC) of Mayo Clinic.

Presented at the meeting of the American Laryngological Association, Waikoloa, Hawaii, May 4-5, 1991.

REPRINTS — Thomas V. McCaffrey, MD, PhD, Dept of Otorhinolaryngology, Mayo Clinic, 200 First St SW, Rochester, MN 55905.

$$OSQ = \frac{\text{Maximum opening slope}}{\text{Amplitude signal x frequency signal}} = \frac{O}{H \times (1/P)} = \frac{MOS}{H \times (1/P)}$$

$$CSQ = \frac{|\text{Maximum closing slope}|}{\text{Amplitude signal x frequency signal}} = \frac{|C|}{H \times (1/P)} = \frac{MCS}{H \times (1/P)}$$

$$SRQ = \frac{\text{Maximum opening slope}}{|\text{Maximum closing slope}|} = \frac{O}{|C|} = \frac{MOS}{MCS}$$

$$OQ = \frac{\text{Open phase}}{P}$$

$$SQ = \frac{\text{Opening phase}}{\text{Closing phase}}$$

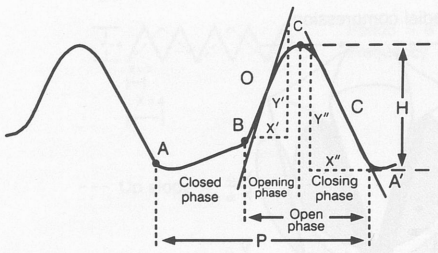

O = maximum opening slope = $\frac{Y'}{X'}$

C = maximum closing slope = $\frac{Y''}{X''}$

H = amplitude of PGG waveform

P = period waveform = A-A'

mayo
CG-138502B-3A

Fig 1. Photoglottographic waveform and glottographic quotients. Period of vibratory cycle can be divided into open and closed portions, with open portion further divided into opening and closing phases. Open quotient (OQ) is ratio of open phase to period of vibratory cycle (P). Speed quotient (SQ) is opening phase divided by closing phase. Maximum opening slope (O) and maximum closing slope (C) of vibratory cycle can be determined along with amplitude of waveform (H). Maximum opening slope (MOS) and absolute value of maximum closing slope (MCS) can be adjusted to control for frequency and amplitude of signal. Open slope quotient (OSQ) is MOS divided by amplitude (H) and frequency (1/P) of photoglottographic waveform. Closed slope quotient (CSQ) is MCS divided by amplitude (H) and frequency (1/P) of signal. Slope ratio quotient (SRQ) is absolute value of ratio of MOS to MCS. A,A´ — points of initial glottic closure as lower margins of vocal folds come together, B — point of initial opening of glottis as upper margins of vocal folds separate, D — point of maximum glottic aperture.

been made to clinical patient care, because waveform descriptors have not been shown to correlate with normal and pathologic conditions in systematic studies aimed at establishing normative data and patterns for underlying vocal fold pathophysiology. If descriptors can be shown to correlate with specific pathologic conditions, then such patterns could be used to diagnose phonatory disorders and monitor treatment. Both the OQ and SQ are based on ratios of time periods or average slopes, specifically looking at opening, closing, and closed times. The current study involved analysis of EGG and PGG waveforms to investigate new parameters that can be calculated from the glottographic waveforms on the basis of the maximum slope of the waveforms. An excised canine larynx mode of phonation was used to assess the effect of variation of a number of parameters, including airflow, longitudinal vocal fold tension, and glottic width, on the EGG and PGG waveforms. The glottographic parameters evaluated were OQ, SQ, maximum opening slope (MOS) of the PGG waveform, maximum closing slope (MCS) of the PGG waveform, ratio of the MOS to the MCS of the PGG waveform (slope ratio quotient [SRQ]), and maximum opening and closing slopes controlled for the amplitude and frequency of the signal (open slope quotient [OSQ] and closed slope quotient [CSQ], respectively; Fig 1).

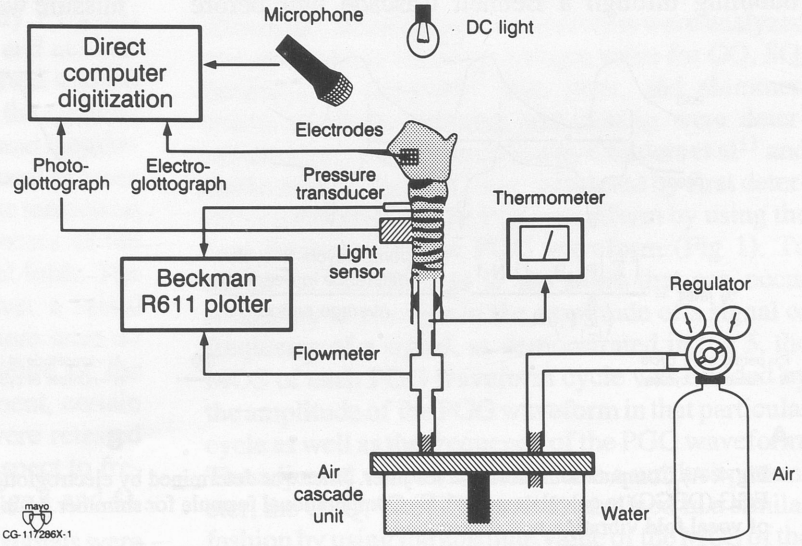

mayo
CG-117286X-1

Fig 2. Schematic representation of experimental setup for excised laryngeal preparation.[11]

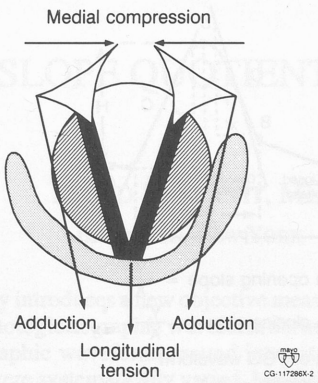

Fig 3. Longitudinal anteroposterior force on vocal folds simulates action of cricothyroid muscle. Adduction by lateral cricoarytenoid muscles is simulated by medioventrocaudal force on muscular process of arytenoids. Medial compression of posterior aspect of arytenoids simulates interarytenoid muscle.[11]

METHODS

Subjects. The larynges were obtained from nine healthy mongrel dogs immediately after they were painlessly killed for organ procurement. These dogs had normal larynges on direct examination and had not undergone any previous experimental studies. The trachea was transected 14 cm below the level of the cricoid cartilage. Superiorly, the excision was between the thyroid cartilage and hyoid bone, with the soft parts cranial to the level of the ventricular folds removed. The larynges were studied immediately after procurement.

Preparation and Experimental Design. Figure 2[11] illustrates the experimental setup. The excised larynx model used has been previously described in detail.[11] Briefly, a tracheotomy tube was positioned in the trachea with the cuff inflated to form a seal, the tip lying 10 cm below the vocal folds and pointed rostrally. Air from a compressed air canister was heated to 37°C and humidified to >95% relative humidity by bubbling through a Bennett Cascade unit before being passed through the larynx. Airflow rate was controlled with a valve and measured by a pneumotachograph. The airflow meter was calibrated before every experiment with a Lab-Crest Flowmeter. To measure subglottic pressure, a catheter tip pressure transducer was placed into the trachea between the cricoid cartilage and the first tracheal ring with its tip 2 cm below the vocal folds. Calibration of the Celestone pressure transducer to 60 and 120 mm H20 was performed before every experiment by using a pressure gauge. A temperature probe was positioned at the caudal end of the trachea to confirm that the temperature of the air was maintained at 37°C.

Electroglottography and PGG confirmed that the vocal folds were vibrating in a pattern consistent with the modal register as opposed to falsetto or strohbass (vocal fry).[11] Recording electrodes for the EGG (Synchrovoice) were sutured on each side of the thyroid cartilage, symmetrically placed. The ground electrode was secured to adjacent strap muscles. A DC light source was placed above the larynx and a Centronics OSD-2 phototransducer was fixed against the trachea just below the cricoid cartilage to record the PGG signal. The microphone for the Larson-Davis 800B sound intensity meter was mounted a radial distance of 30 cm above the glottis and off-axis to prevent direct exposure to conductive airflow. The C-scale of the sound intensity meter was used to provide a flat frequency response in the phonation spectrum with suppression of some low-frequency background noise (below 30 Hz).

The effects of muscular contractions of the cricothyroid muscle, lateral cricoarytenoid muscles, and interarytenoid muscle were simulated by means of surgical silk sutures (Fig 3[11]). To simulate the effect of the cricothyroid muscle, a small rectangular segment of thyroid cartilage overlying the anterior commissure was isolated by making horizontal and ver-

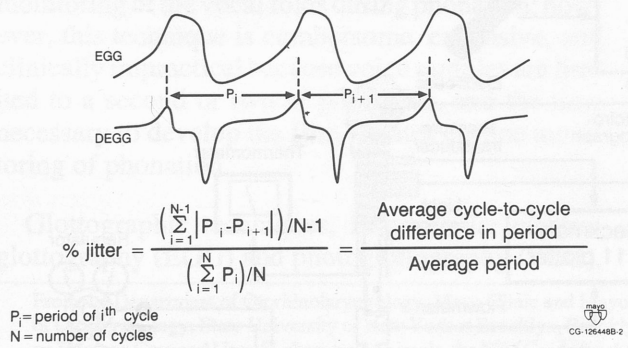

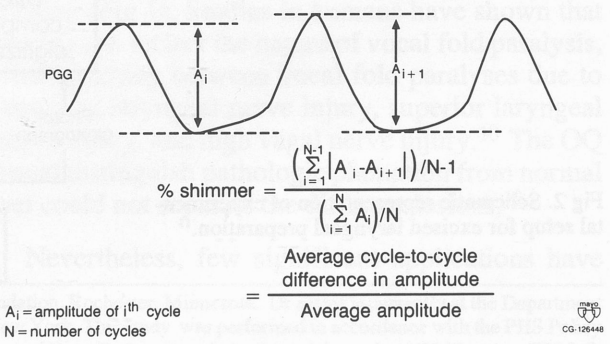

A B

Fig 4. A) Computational formula for jitter. Jitter was determined by electroglottographic (EGG) signal using first derivative of EGG (DEGG) to calculate period. B) Computational formula for shimmer. Using photoglottographic (PGG) signal, amplitude of vocal fold vibration was determined.

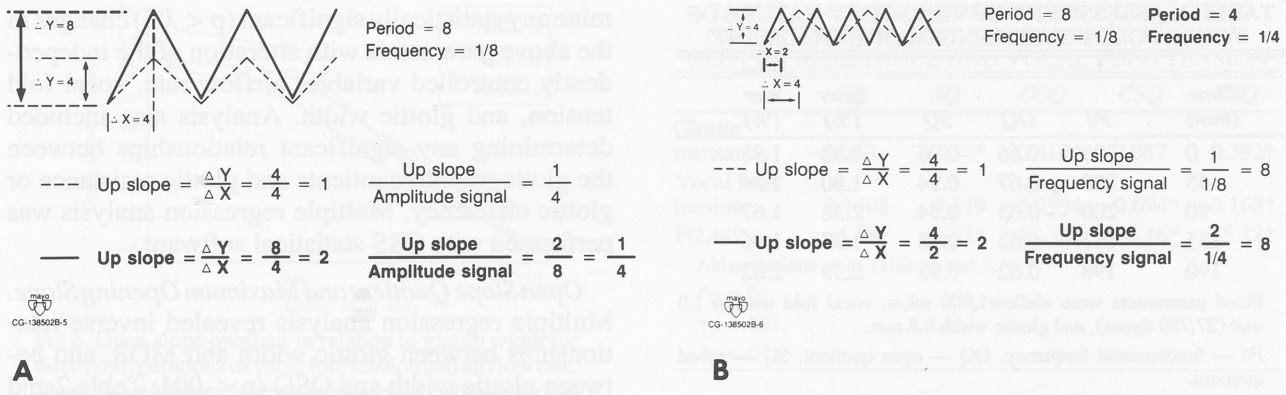

Fig 5. A) Slope of waveform can be altered by merely changing amplitude of signal. When amplitude is doubled, maximum up slope goes from 1 to 2. If up slope is controlled for amplitude of signal by dividing slope by amplitude, both waveforms have same value of one fourth. B) Alterations in frequency of waveform can alter slope of signal. When frequency is doubled from one eighth to one fourth, up slope increases from 1 to 2. Controlling for changes in frequency by dividing up slope by frequency of signal, both waveforms have value of 8.

tical cuts through the cartilage. A surgical silk was then sutured at one end to the anterior commissure and the incised section of thyroid cartilage, and at the other end the silk was attached to a force transducer (Grass FT03D). The length and longitudinal tension of the vocal folds were altered by applying tension to the suture in the plane of the vocal folds. The adducting force of the lateral cricoarytenoid muscles was simulated by attaching a surgical silk to the muscular process of the arytenoid cartilage and applying force in the medioventrocaudal direction.[11] A surgical silk placed through the posterior aspect of the body of the arytenoids simulated the adduction action of the interarytenoid muscle. To help form the body of the vocal fold, a technique similar to a type I thyroplasty[1] was used with a piece of Silastic placed through a window in the thyroid cartilage, displacing the thyroarytenoid muscle and adding bulk.

The experiments were initiated immediately after obtaining a larynx and were completed within 3 hours. The glottographic signals, subglottic pressure, and sound intensity were simultaneously recorded while vocal fold tension, glottic width, and airflow rate were systematically varied. Vocal fold tension was altered by changing the tension on the surgical silk attached to the anterior commissure and measuring the force. Glottic width across the vocal process of the arytenoids was varied by altering the tension on the sutures attached to the muscular process of the arytenoid, causing adduction of the vocal folds. The vocal fold vibrations were recorded over a broad range of frequencies. To confirm that there were no significant changes in the vibratory nature of the vocal folds over the time of the experiment, certain specific configurations of the larynx were retested every 45 minutes and evaluated with respect to frequency, OQ, SQ, jitter, and shimmer (Figs 1 and 4).

Data Acquisition. The PGG and EGG signals were amplified to the ±5-V range and band-pass-filtered with five-pole Butterworth filters at 1.0 Hz and 2.5 kHz. The EGG and PGG signals were then digitized at 10,000 Hz. An AST 20868 microcomputer with an 80287 mathematic co-processor and ASYSTANT software (ASYST Technologies) for high-speed data acquisition and analysis was used. One second of waveform data was stored onto the hard disk of the microcomputer for later analysis. The signals were also monitored on a Tektronix oscilloscope (model 5111) to confirm modal register.[11,12]

Vocal fold longitudinal tension, airflow rate, subglottic pressure, and sound intensity were recorded simultaneously on a Beckman R611 recorder. The vocal fold length from the anterior commissure to the vocal process of the arytenoid and the width of the glottis at the vocal process of the arytenoid were measured with calipers with the aid of magnification and recorded manually.

Analysis of Data. Within each trial of simulated phonation, 20 consecutive waveforms were analyzed and averaged to calculate a single value for OQ, SQ, fundamental frequency (F0), jitter, and shimmer. Points of glottic opening and closing were determined as previously described by Childers et al[13] and Berke et al.[14] The OSQ was calculated by first determining the MOS of the PGG waveform by using the first derivative of the PGG waveform (Fig 1). To adjust for the changes in the slope that can occur secondary to changes in the amplitude of a signal or frequency of a signal, as demonstrated in Fig 5, the MOS of each PGG waveform cycle was divided by the amplitude of the PGG waveform in that particular cycle as well as the frequency of the PGG waveform. The adjusted value for the MOS is a unitless parameter, the OSQ. The CSQ was determined in a similar fashion by using the absolute value of the MCS of the

TABLE 1. ASSESSMENT OF VIBRATORY NATURE OF VOCAL FOLDS OVER LENGTH OF EXPERIMENT

Time (min)	*F0*	*OQ*	*SQ*	*Jitter (%)*	*Shimmer (%)*
0	205	0.66	0.96	1.38	1.91
45	202	0.67	0.94	1.80	1.84
90	200	0.63	0.94	2.36	1.67
135	197	0.63	0.98	1.97	1.96
190	198	0.62	0.93	2.39	2.02

Fixed parameters were airflow1,000 mL/s, vocal fold tension 1.0 unit (27,759 dynes), and glottic width 0.8 mm.

F0 — fundamental frequency, OQ — open quotient, SQ — speed quotient.

PGG waveform and controlling for amplitude and frequency of the signal. The SRQ was determined by taking the ratio of the MOS of the PGG signal to the absolute value of the MCS. Within the 1 second of waveform data that was recorded and stored on the hard disk, 20 consecutive PGG waveforms were analyzed and averaged to calculate a single value for MOS, OSQ, MCS, CSQ, and SRQ. The glottic resistance was calculated by dividing subglottic pressure by airflow rate. Vocal efficiency was calculated as the ratio of radiated acoustic power to aerodynamic power supplied to the larynx.[15] Data analysis and processing were performed with ASYSTANT software.

RESULTS

Nine excised larynges were studied under 50 different combinations of airflow rate, vocal fold tension, and glottic width that produced phonation in the canine modal register. Based on the consistency of the vibratory pattern as measured by F0, jitter (frequency perturbation), shimmer (amplitude perturbation), and the glottographic OQ and SQ for the specific conditions retested every 45 minutes, the vibratory nature of the vocal folds appeared to be constant throughout the experiment (Table 1).

The OQ, SQ, F0, MOS, OSQ, MCS, CSQ, and SRQ were calculated for all experimental conditions. Multiple regression analysis was performed to determine any statistically significant ($p < .05$) changes in the above parameters with alteration of the independently controlled variables airflow rate, vocal fold tension, and glottic width. Analysis also included determining any significant relationships between the glottographic quotients and glottic resistance or glottic efficiency. Multiple regression analysis was performed with CSS statistical software.

Open Slope Quotient and Maximum Opening Slope. Multiple regression analysis revealed inverse relationships between glottic width and MOS, and between glottic width and OSQ ($p < .001$; Table 2 and Fig 6). The OSQ also had statistically significant relationships with subglottic pressure ($p < .001$) and glottic resistance ($p < .001$; Tables 3 and 4). As the subglottic pressure and glottic resistance increased with glottic narrowing, there was a significant rise in the OSQ. With an increase in vocal fold tension there was a rise in F0 ($p < .001$) but no significant changes in MOS. The tension, however, was inversely related to OSQ, which is the MOS controlling for the amplitude and frequency of the signal ($p < .001$) because of the direct relationship between tension and F0. Although the OSQ was significantly related to a number of variables, the strongest relationship existed with glottic resistance. Glottic resistance was inversely related to glottic width but was not altered by changes in vocal fold tension (Table 5 and Figs 7 and 8).

Closed Slope Quotient and Maximum Closing Slope. The glottic width had a statistically significant inverse relationship with the MCS ($p < .001$), yet with the adjustment for amplitude and frequency of the glottographic signal, there was no significant relationship between glottic width and the CSQ (Table 2). There were also no significant relationships between vocal fold tension, subglottic pressure, glottic resistance, glottic efficiency, or sound intensity and the CSQ (Tables 2-4).

Slope Ratio Quotient. Regression of vocal fold tension and glottic width on SRQ revealed significant inverse relationships ($F[2,449] = 6.49$, $p < .01$; Table 2). The inverse relationships that glottic width and

TABLE 2. MULTIPLE REGRESSION COEFFICIENT (BETA) FOR VIBRATORY PARAMETERS VERSUS GLOTTIC WIDTH AND VOCAL FOLD TENSION

Independent Variables	*Dependent Variables*							
	F0	*OQ*	*SQ*	*MOS*	*OSQ*	*MCS*	*CSQ*	*SRQ*
Glottic width	−0.031	0.093*	−0.09*	−0.373§	−0.225§	−0.318§	−0.004	−0.114*
Vocal fold tension	0.520§	0.155†	0.088	0.020†	−0.309§	0.001	−0.104	−0.150†
F[2,449]	86.67§	6.10†	4.26*	37.57§	32.55§	25.32§	2.43	6.49†

MOS — maximum opening slope, OSQ — open slope quotient, MCS — maximum closing slope, CSQ — closed slope quotient, SRO — slope ratio quotient. Other abbreviations as in Table 1.

*$p < .05$.

†$p < .01$.

§$p < .001$.

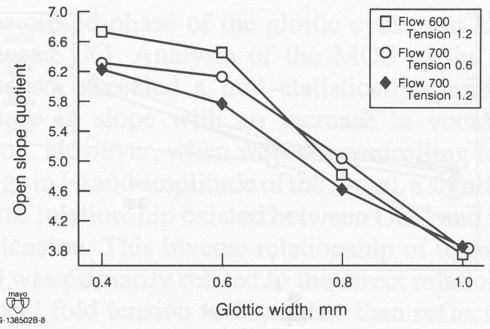

Fig 6. Open slope quotient in relation to glottic width for three configurations of vocal fold tension and airflow rate. There is significant inverse relationship between glottic width and open slope quotient (airflow in milliliters per second; vocal fold tension in units [1 unit equals 27,759 dynes]).

vocal fold tension had with SRQ had less statistical significance than the relationships of glottic width and tension to OSQ. Regression analysis demonstrated the SRQ to have a significant direct relationship with glottic resistance ($p < .001$), although the relationship of glottic resistance to OSQ was stronger (Tables 3 and 4).

Open Quotient. Multiple regression analysis of the data demonstrated a direct linear relationship between glottic width and OQ as well as between vocal fold tension and OQ ($F[2,449] = 6.10$, $p < .01$; Fig 9). The vocal fold tension had a more significant and stronger relationship with OQ than glottic width (Table 2). The OQ was also found to be inversely related to sound intensity ($p < .001$) and glottic efficiency ($p < .001$) but was not related to glottic resistance (Table 3).

Speed Quotient. Longitudinal vocal fold tension did not appear to be significantly related to SQ (Table 2). Glottic width was inversely related to SQ ($p <$ .05), while subglottic pressure was directly related to SQ ($p < .05$). Regression of the independent variables glottic resistance and vocal fold tension (Table 5) on SQ revealed a statistically significant direct relationship between SQ and glottic resistance, yet this was not as significant as the relationship of OSQ to glottic resistance (Table 4).

TABLE 3. REGRESSION COEFFICIENT (BETA) FOR PHYSIOLOGIC PARAMETERS VERSUS VIBRATORY PARAMETERS

Vibratory Parameters	*Glottic Resistance*	*Glottic Efficiency*
OSQ	0.377*	0.128†
	F[1,450] = 74.66	F[1,450] = 7.47
CSQ	−0.097§	0.001
	F[1,450] = 4.30	F[1,450] < 0.01
SRQ	0.374*	0.69
	F[1,450] = 73.00	F[1,450] = 2.02
OQ	−0.027	−0.176*
	F[1,450] = 0.34	F[1,450] = 14.34
SQ	0.114§	−0.113§
	F[1,450] = 5.86	F[1,450] = 5.86

Abbreviations as in Tables 1 and 2.
*p < .001.
†p < .01.
§p < .05.

TABLE 4. MULTIPLE REGRESSION COEFFICIENT (BETA) FOR VIBRATORY PARAMETERS VERSUS GLOTTIC RESISTANCE AND VOCAL FOLD TENSION

	OQ	*SQ*	*OSQ*	*CSQ*	*SRQ*
Glottic resistance	−0.043	0.114*	0.410†	−0.087	0.392†
Vocal fold tension	0.140§	0.119	−0.299†	−0.094*	−0.168†
F[2,449]	4.58*	5.31*	67.30†	4.16*	45.12†

Abbreviations as in Tables 1 and 2.
*p < .05.
†p < .001.
§p < .01.

DISCUSSION

This work investigated the ability of new glottographic parameters to reflect the changes in the vibratory pattern of the vocal fold with alterations in glottic width and vocal fold tension. The OSQ is a reflection of the maximum slope of the opening phase of a glottic cycle as measured from the PGG waveform. The OSQ differs from the previously reported glottographic quotients OQ and SQ in that it is a measure of a maximum slope or maximum speed, as opposed to a ratio of time periods that reflects average slope or average speed. Important to the use of a maximum slope measurement of the vibratory waveform is the ability to control for parameters that may effect changes in the maximum slope while not reflecting alterations in the vibratory pattern. Specifically, one must control for the amplitude of the PGG waveform because the intensity of the light source, as well as the sensitivity of the photosensor, can affect the amplitude of the PGG signal and thus alter the value for the MOS unrelated to changes in the vibratory patterns of the vocal folds. Similarly, alterations in the frequency of the vibratory waveform that can affect the MOS of the PGG waveform can be controlled for with the OSQ.

The use of an excised larynx preparation for voice

TABLE 5. MULTIPLE REGRESSION COEFFICIENT (BETA) FOR GLOTTIC RESISTANCE VERSUS GLOTTIC WIDTH AND VOCAL FOLD TENSION

	Glottic Resistance
Glottic width	−0.604*
Vocal fold tension	−0.021
	F[2,449] = 126.28*

*p < .001.

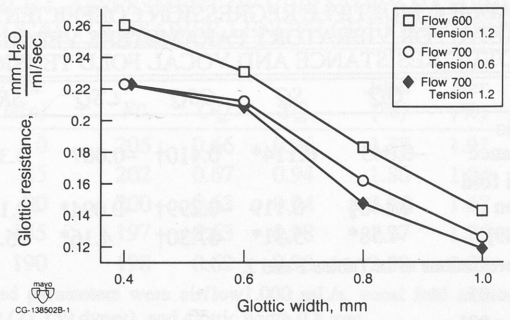

Fig 7. Glottic resistance as function of glottic width for three configurations of vocal fold tension and airflow rate. There is significant inverse relationship between glottic width and glottic resistance (airflow in milliliters per second; vocal fold tension in units [one unit equals 27,759 dynes]).

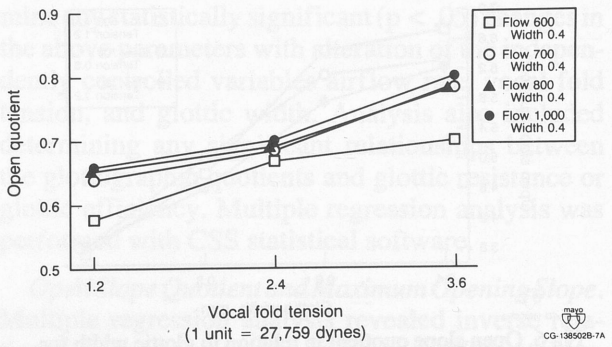

Fig 9. Open quotient in relation to vocal fold tension for four configurations of glottic width and airflow rate in excised canine larynx. Note direct relationship between vocal fold tension and open quotient (glottic width in millimeters; airflow in milliliters per second).

production leads to inherent limitations of the results. In this experiment, the excised canine larynx model served as a physiologic model for studying the effects of vocal fold tension and glottic width on the vibratory pattern of the vocal folds as measured by glottographic parameters. The excised canine larynx, in an experimentally produced phonatory model, vibrated in a two-margin system that appeared comparable to human voice production. Although there are differences between the canine and human larynges in terms of thickness of the vocal folds, histology of the vocal folds, size of the ventricles, absence of a vocal ligament, and position of the cricoid and thyroid cartilages,[14,16,17] the recorded glottographic waveforms from experimentally produced phonation in the excised canine model were similar to signals recorded in human studies. In the excised model, metabolism stopped when the blood supply ceased and the organized structure of the tissues deteriorated gradually, but there was no significant change in the vibratory nature of the vocal folds during the experiment. The consistency of the vibratory nature of the vocal folds in the excised canine model was confirmed by the reproducibility of the vibratory pattern

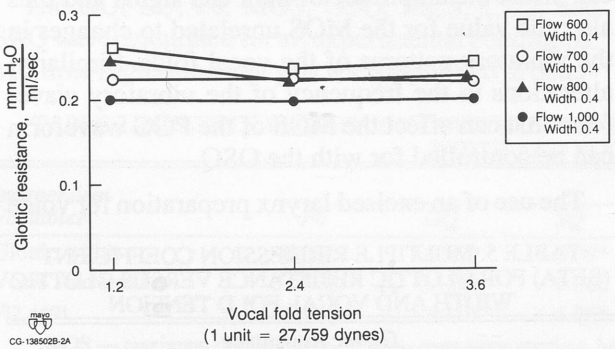

Fig 8. Glottic resistance as function of longitudinal vocal fold tension for four configurations of glottic width and airflow rate. Glottic resistance remains relatively constant as vocal fold tension is changed (glottic width in millimeters; airflow in milliliters per second).

as measured by F0, jitter, shimmer, and the glottographic quotients under specific test conditions repeated during the experiment (Table 1).

As the glottic width was narrowed, there was a significant increase in subglottic pressure and glottic resistance. The results of this study revealed that as the glottic resistance increased, the MOS and OSQ increased. With an increase in glottic resistance, a higher subglottic pressure was needed for phonation. As the critical pressure was reached, the upper margin of the vocal folds separated and there was an increase in the PGG waveform signal representing the increased transillumination of light through the opening glottis. The maximum slope of this inclination of the PGG signal appeared highly related to the glottic resistance. With an increase in the glottic resistance and a greater subglottic pressure needed for phonation, there was a higher maximum excursion rate of the vocal folds and a higher rate of change in glottic aperture during the opening phase.

Berke et al[18] previously made the analogy that the phonating larynx may be similar to a balloon filling with air. When the stiffness of the walls of the balloon is overcome, the balloon can be filled with air. The greater the stiffness or resistance of the walls of the balloon, the higher the pressure needed to overcome the resistance. With the stiffer and more resistant balloon there is a greater maximal excursion rate of the balloon once the critical pressure is overcome. In the current study, when glottic width was reduced and glottic resistance was increased, there was a greater maximal excursion rate once phonation began. Although increases in vocal fold tension affected the stiffness of the vocal fold, there was no significant change in resistance or maximum excursion rate.

An increase in longitudinal vocal fold tension caused a thinning and stiffening of the vocal folds with an increase in the frequency of vibrations (F0). The vocal folds spent a decreased proportion of time

in the closed phase of the glottic cycle and had an increased OQ. Analysis of the MOS of the PGG waveform revealed a non–statistically significant increase in slope with an increase in vocal fold tension. However, when we were controlling for the change in F0 and amplitude of the signal, a significant inverse relationship existed between OSQ and vocal fold tension. This inverse relationship of tension to OSQ was primarily related to the direct relationship of vocal fold tension to F0, rather than reflecting a relationship of tension to maximum slope of the PGG signal.

Although preliminary studies in humans show a similar relationship between OSQ and glottic resistance, further evaluation of the OSQ in human studies is ongoing, looking at both normal and pathologic conditions. Aerodynamic measures of vocal efficiency and glottic resistance[4] may be altered by the supraglottic resonant tract, while PGG can isolate laryngeal activity. The OSQ as an estimator of glottic resistance can provide useful clinical information. The OSQ may be a valuable tool in the assessment of the patient with hyperadduction dysphonia and increased glottic resistance. The assessment of medialization procedures as well as microlaryngeal surgery with the subsequent alterations of glottic resistance during phonation may be assessed by using the glottographic parameter OSQ. Systematic studies of human phonation will provide insight into the clinical applicability of OSQ. The development of glottographic parameters that reliably reflect vocal fold vibration is necessary for the further study of laryngeal physiology.

REFERENCES

1. Isshiki N, Morita H, Okamura H, Hiramoto M. Thyroplasty as a new phonosurgical technique. Acta Otolaryngol (Stockh) 1974;78:451-7.

2. Ford CN, Bless DM. Clinical experience with injectable collagen for vocal fold augmentation. Laryngoscope 1986;96: 863-9.

3. Bouchayer M, Cornut G. Microsurgery for benign lesions of the vocal folds. Ear Nose Throat J 1988;67:446-64.

4. Hirano M. Clinical examination of voice. New York, NY: Springer-Verlag, 1981.

5. Baken RJ. Clinical measurement of speech and voice. Boston, Mass: Little, Brown, 1987.

6. Childers DH, Krishnamurthy AK. A critical review of electroglottography. CRC Crit Rev Biomed Eng 1985;12:131-61.

7. Kitzing P. Glottography, the electrophysical investigation of phonatory biomechanics. Acta Otorhinolaryngol Belg 1986; 40:863-78.

8. Sonesson B. On the anatomy and vibratory pattern of the human vocal folds: with special reference to a photo-electrical method for studying the vibratory movements. Acta Otolaryngol [Suppl] (Stockh) 1960(suppl 156).

9. Baer T, Loefquist A, McGarr NS. Laryngeal vibrations: a comparison between high-speed filming and glottographic techniques. J Acoust Soc Am 1982;73:1304-80.

10. Hanson DG, Gerratt BR, Karin RR, Berke GS. Glottographic measures of vocal fold vibration: an examination of laryngeal paralysis. Laryngoscope 1988;98:541-9.

11. Slavit DH, Lipton RJ, McCaffrey TV. Glottographic analysis of phonation in the excised canine larynx. Ann Otol Rhinol Laryngol 1990;99:396-402.

12. Baer T. Vibration patterns of excised larynges. J Acoust Soc Am 1974;55:S79.

13. Childers DG, Hicks DM, Moore GP. A model for vocal fold vibratory motion, contact area, and the electroglottogram. J Acoust Soc Am 1986;80:1309-21.

14. Berke GS, Moore DM, Hantke DR, Hanson DG, Gerratt BR, Brustein F. Laryngeal modeling: theoretical, in vitro, in vivo. Laryngoscope 1987;97:871-81.

15. Titze IR. Regulation of vocal power and efficiency by subglottal pressure and glottal width. In: Fujimura O, ed. Vocal fold physiology. Vol 2. New York, NY: Raven Press, 1988:227-39.

16. Bradley OC, Grahame T. Topographical anatomy of the dog. New York, NY: Macmillan, 1959.

17. Hirano M. Morphological structure of the vocal cord as a vibrator and its variations. Folia Phoniatr (Basel) 1974;26:89-94.

18. Berke GS, Hanson DG, Gerratt BR, Trapp TK, Macagba C, Natividad M. The effect of air flow and medial adductory compression on vocal efficiency and glottal vibration. Otolaryngol Head Neck Surg 1990;102:212-8.

THYROARYTENOID INTRAMUSCULAR PRESSURES

DONALD S. COOPER, PHD
LOS ANGELES, CALIFORNIA

ERIC PINCZOWER, MD
SEATTLE, WASHINGTON

DALE H. RICE, MD
LOS ANGELES, CALIFORNIA

The aim of this research has been to investigate the measurement of laryngeal intramuscular fluid pressures as a technique for assessment of laryngeal muscle activity for diagnostic or experimental purposes. Simultaneous measurements of contractile force, intramuscular fluid pressure, and electromyographic signals were made under isometric conditions in the vocal fold muscles of anesthetized dogs during supramaximal stimulation of the recurrent laryngeal nerve. Covariation of force and pressure was studied in twitch and tetanic contractions, over a range of stimulation frequencies. Tetanic pressure rises were usually smaller than in human limb muscles, but were of sufficient magnitude that effects on blood flow and muscle metabolism are probable. Analysis of relations between pressure and force records demonstrated that intramuscular pressure variations correlated closely to isometric force in their time course. This finding suggests the potential significance of this measure as a relatively nonintrusive indicator of the level of force of muscles involved in laryngeal function, and as a physiological measure of importance.

KEY WORDS — intramuscular pressure, larynx, muscle, vocal cord.

INTRODUCTION

The function of laryngeal muscles has usually been assessed by either electromyography (EMG) or optical techniques. Electromyography is a complex technique,[1,2] and the relation between the force output of muscles and the EMG signal in anisometric contractions is not straightforward in practice.[3] Although optical techniques have been continually improved, they have rarely been applied in a manner that would realize their inherent promise of quantification, and at present it is unlikely that optical findings can be interpreted in a manner that will make possible specification or quantification of the active muscular forces, despite the step in this direction taken by Broad.[4] Measurements of mechanical activity of laryngeal muscles have been rare, and most often they have been conducted in acute experiments, carried out by procedures that do not allow experimental designs with measures repeated on successive occasions, and cannot be used on humans. In the conclusion of a previous study of the effects of reinnervation on the contractile properties of the thyroarytenoid muscle,[5] we noted how desirable would be alternative forms of mechanical measurement that would make possible successive measures of the mechanical response of laryngeal muscles so that, for instance, the time course of recovery after surgery could be evaluated more systematically. In this paper a different procedure will be demonstrated that to our knowledge has not yet been applied to muscles in the cranial nerve area, based on the relation between the variation of intramuscular fluid pressure and isometric muscle force. The present paper will emphasize methods and illustrative findings.

Most previous research on laryngeal muscle mechanics has depended on a one-dimensional conceptualization of muscle contraction as resulting only in longitudinal tension. Nevertheless, reminders of the three-dimensional character of muscle activity have cropped up occasionally for hundreds of years, as appears in the overviews by Partridge and Benton[6] and Reichel,[7] although formalization of three-dimensional analyses of muscle mechanics is relatively recent.

The first three-dimensional physiologic properties of laryngeal muscles to be studied were changes in the transverse viscoelastic properties of muscle during its contraction. These alterations have been long noted in the general literature on muscle mechanics. The effect has been noted since Leonardo da Vinci and has been used experimentally since the late 19th century.[6,7] The first quantitative study of laryngeal muscle mechanics known to the authors, by Réthi[8] in 1897, was based on inference of canine thyroaryte-

From the Department of Otolaryngology–Head and Neck Surgery, University of Southern California School of Medicine, Los Angeles, California (Cooper, Rice), and the Department of Otolaryngology–Head and Neck Surgery, University of Washington School of Medicine, Seattle, Washington (Pinczower). This research was supported by the Voice Foundation. This study was performed in accordance with the PHS Policy on Humane Care and Use of Laboratory Animals, the NIH *Guide for the Care and Use of Laboratory Animals*, and the Animal Welfare Act (7 U.S.C. et seq.); the animal use protocol was approved by the Institutional Animal Care and Use Committee (IACUC) of the University of Southern California.

Presented at the meeting of the American Laryngological Association, Waikoloa, Hawaii, May 4-5, 1991.

REPRINTS — Donald S. Cooper, PhD, Laboratory for Laryngeal Physiology, Hoffman 903, 2025 Zonal Ave, Los Angeles, CA 90033.

noid muscle force from changes in transverse elasticity in vivo. Mårtensson and Skoglund[9] based observations of speed of laryngeal muscle contraction on the muscles' lateral displacement during contraction; Haji et al[10] have studied the changes of transverse viscoelasticity of the vocal folds during thyroarytenoid contraction; and Berke et al (unpublished observations, 1990) have more recently studied the effect of contraction on the transverse elasticity of this muscle in vivo.

In 1948, Hill[11] demonstrated an increase of intramuscular fluid pressure on the order of 200 mm Hg in frog gastrocnemius muscle during tetanic contraction. Discussing the study later in his autobiographic survey of his own and related physiological research,[12] he saw its main implications as explaining both the small reversible volume changes found in this muscle during contraction, and the effect of high levels of contraction in the leg in ceasing blood flow. He was able to verify computationally that if the bulk elasticity of muscle is assumed to be equal to that of water, the measured fluid pressure changes do approximately account for the observed volume changes of contracting muscle. Nevertheless, other explanations have been proposed for rapid volume changes that are approximately synchronous with contraction.[13] Volume changes that persist after relaxation are attributed to metabolic processes. However, Hill[11] doubted that these pressure changes would be found in muscles with straight parallel fibers, such as the frog's sartorius, although he expected them to be general in other muscles of complex fiber course similar to the gastrocnemius. His prediction would thus also extend to the thyroarytenoid muscle, in which at least a large proportion of the fibers appear to be parallel, although there are significant findings indicating a more complex structure.[14]

Needham[13] has surveyed the various contributions to the analysis of volume changes, especially from Ernst, Meyerhof, and Abbott and their associates. An important question was raised by early studies of Meyerhof,[15] who found that volume changes were much smaller in lightly loaded isotonic contractions than in isometric contraction, while they increased with the level of load. Hill[11] attributed this to the hypothetic development of smaller fluid pressures in isotonic contraction. Fluid pressure measurements with change of muscle length are difficult to make reliably today, as they were in Hill's day; consequently, the available findings still come primarily from isometric studies. However, the eventual situations of interest also involve anisometric contraction, so that the effects of both stepwise and continuous changes of muscle length must be studied.

The volume and static pressure of interstitial fluid within muscles result from movement of fluid from the capillaries, its resorption by them, and lymph flow. The components of this balance are summed up in the well-known Starling equation. Hargens[16] provides details of the bases of the generation of this pressure. Interstitial fluid volume of skeletal muscle varies from about 8 to 20 mL per 100 g wet tissue[17]; thus, it amounts to a quarter or less of the total fluid in skeletal muscle, which in turn composes a mean of 79.2% of the weight of skeletal muscle.[18] However, this volume is variable: alterations of interstitial fluid pressure can considerably affect the rate of exchange of fluid between the circulating blood and the interstitial space.[19]

In recent research, the relationship of intramuscular fluid pressure to other physiological quantities has been studied primarily within the orthopedics and biomechanics literatures, and the in vivo application has been primarily in large limb muscles, except for occasional studies in small animals. An important series of studies has clarified the relationship between the interstitial fluid pressure of muscle and isometric force of skeletal muscle.[20] However, at a given level of contraction, fluid pressure varies from place to place within the muscle[21-23]; these relationships are not arbitrary, but at present they are incompletely investigated. There may be found a positive gradient of static fluid pressure as one passes from peripheral to deep tissues within the muscle, depending on whether the boundaries of the muscle are rigid or not.[20] Intramuscular pressure also increases with externally caused longitudinal tension of the muscle.[24] Detailed effects of these factors vary depending on the anatomy of the particular muscles in question.

Apart from these complicating factors, it has been found that interstitial fluid pressure at a given point is highly linearly related to isometric muscular force,[21,23,25] although the slope of this relation cannot at present be predicted. Although local fatigue probably develops where pressures exceed 20 to 30 mm Hg, intramuscular pressure in isometric contraction may reach levels as high as 600 mm Hg in maximal contraction.[20,26,27] Intramuscular pressure is more closely related to force than is the EMG signal, which is usually compared to force in rms or rectified and smoothed form.[25,28] The relation between intramuscular pressure and force, being purely mechanical, is not altered under conditions of fatigue or at high levels of contraction, as is the relation of the EMG signal to isometric force.[3,25]

METHODS

The dog was chosen for initial experiments be-

cause of the availability of a reasonable fund of information on the structure[29,30] and physiological properties of active canine vocal fold muscle both from earlier published in vivo results[9,31-35] and from our own in vivo research.[5,36] The available animals were small, of mean weight 6.7 ± 0.5 kg.

The experiments were approved by the USC IACUC. The methods were similar to those described earlier,[36] with the addition of the measurements of intramuscular pressure. Seven dogs were studied under general anesthesia. Each animal was premedicated with atropine 1/120 grain, ketamine 100 mg, and acepromazine 5 mg. General anesthesia was induced with pentobarbital. The animals were immobilized in the supine position on the operating table. After anesthesia was induced, the animals were intubated and assisted ventilation was begun.

The anterior neck and upper chest were shaved, prepared, and draped. A 6-cm midline vertical incision was made from just above the hyoid bone to the sternal notch. The median raphe was divided and the cartilaginous structure of the larynx and upper trachea was exposed. The hyoid bone was freed of the suprahyoid and infrahyoid musculature. The recurrent and (if present) pararecurrent laryngeal nerves were identified bilaterally. The trachea was transected at the fifth ring, and the animal was reintubated distally. The proximal portion was fixated to prevent laryngeal movement during respiration. Supramaximal stimulation of the recurrent nerve was used to activate the muscle.

The cricothyroid space was entered in the midline and a precise laryngofissure was created. Identification of the motor portion of the caudal laryngeal nerve was confirmed bilaterally by electrical stimulation. Each hemilarynx was now a separate experimental preparation.

For the study of a given muscle, a square of cartilage directly anterior to the thyroarytenoid muscle was created by incision through the outer perichondrium, the cartilage, and the inner perichondrium. The mucosa was freed inferiorly and superiorly. A suture of 2-0 polyester was placed between the cartilage and the inner perichondrium. The other end of the suture was attached to it. The EMG electrodes were placed directly in the thyroarytenoid muscle, and a 1-mm incision was made in the anterior aspect of the muscle for placement of the pressure transducer. The transducer was then gently threaded about 5 mm into the muscle and finally withdrawn 1 mm to allow a small fluid collection anterior to the transducer tip; thus, the transducer monitored fluid pressure. The arytenoid cartilage was fixated by pinning it to the posterior section of the cricoid cartilage, and this pin was fixed externally, so that muscle contraction was isometric and other muscles could not affect the measurement of thyroarytenoid muscle activity.

As experimentation proceeded, the animal was given maintenance doses of 5 mg/kg of pentobarbital as needed for adequate anesthesia. At the culmination of experimentation, the animals were given lethal doses of pentobarbital (100 mg/kg).

The EMG signal was recorded differentially from fine wire electrodes inserted separately into the vocal fold muscle with the interelectrode axis parallel to the muscle fibers; the ground electrode was attached to the edge of the neck incision. The capacitive force transducer had previously been calibrated with weights. Intramuscular fluid pressure was sensed by a transducer of 1.3 mm diameter (Camino Laboratories model 110-4D) at the end of a flexible fiberoptic cable inserted into the muscle. The principle of this transducer is discussed by Cobbold[37]: light is transmitted down one fiberoptic bundle to the tip, and the displacement of a diaphragm by external fluid pressure determines the amount of light reflected back through a second detector bundle. This transducer had been previously calibrated. Pressure measurements were made close to the center of the vocal fold, but there was some inevitable variation of transducer position across animals. Both mechanical transducers were linear over the range of interest. All these signals were recorded on a computer at not less than 5,000 points per second, together with a timing signal from the stimulator (Grass S88) that occurred simultaneously with the stimulation of the recurrent nerve by 0.1-millisecond supramaximal pulses presented through a stimulus isolation unit (Grass SIU7).

RESULTS

The intramuscular fluid pressure measured in resting thyroarytenoid muscle at resting length (fold adducted) had an average value of 14 mm Hg in a series of data sets across all animals studied. Since resting pressures were sometimes affected by preceding contractions, this value is a super-mean from the means for individual animals from the first set of pressure measurements on a given day for the vocal fold in question. Mean values for individual animals ranged from 1.7 to 30.9 mm Hg. Negative pressure values were rare, but small ones were observed.

Observations were made in three animals of the effect of change of muscle length on resting intramuscular pressure, over a range of 4 mm extension. Possibly, small changes of transducer position during extension of the muscle perturbed these measurements. If only data sets in which the relation was monotonic or nearly so ($r = .86$) are included, there

was a mean increase of intramuscular pressure of 4.4 ± 3.3 mm Hg per millimeter of extension.

At times a slow drift of fluid pressures was observed across successive activations of the muscles. For instance, a progressive decrease in resting fluid pressure from 21 to 13 mm Hg was observed over a series of five activations of the thyroarytenoid muscle of one animal. These values did not reflect a calibration drift in the pressure transducer, which was stable over the time intervals in question when tested in a water column and shows a maximum zero drift of about 3 mm Hg per 24 hours. Probably these changes reflected small shifts of fluid within the muscle occurring as a result of inequalities of local fluid pressure during contraction (Darcy's law effects).

The force range to be considered is from resting state to full tetanic contraction, which is usually, although not always, approximately equal in force to maximum voluntary contraction.[38] Thus, one focus of our initial studies has been on the onset of tetanic contraction, which permits a contrast of pressure and force extremes in resting and tetanic muscle. These data were available for five animals. When the recurrent laryngeal nerve was stimulated at 80 to 240 pulses per second, the mean tetanic pressure rise in this data set was 44.1 ± 36.5 mm Hg, varying widely from less than half this amount to more than twice it. The observed variability is accounted for partly by an increase of intramuscular pressure with activation rate over this range, and partly by cross-subject variability in the relation between contractile force and pressure as discussed below. Tetanic stimulation often, although not always, produced an increase in intramuscular pressure sufficient to affect the microcirculation.[20,23,26,27]

However, higher increases were observed in the tetanic burst paradigm illustrated below — rises sometimes ranging as high as those observed by Hill[11] in frog gastrocnemius (despite the difference in fiber course noted above), with a range of about 250 mm Hg. It should not be assumed that this is a functional maximum pressure for the muscle, since pressure increases resulting from other sources are also observed, as discussed below.

Previous studies noted above have indicated that the relation between variation of isometric force and intramuscular fluid pressure at a given point is linear.[21,23,25] However, as with isometric EMG, this slope of this relation cannot be predicted at present. In our data, the force-pressure relation was variable across animals. Slopes ($\Delta g/\Delta$mm Hg) determined just after the onset of tetanic contraction varied from subject to subject by a factor of six. (The overall mean for 23 tetanic onsets studied in five animals was 2.094 ± 1.221.) This cross-subject variation has also been observed in experiments on human limb muscles.[27] Some token-to-token variation of slope within a given animal was also observed, but some findings suggested that it may be possible to design procedures to obtain reliable data. For example, if the first data point is omitted in a series of tetanic rises (stimulus rates ranging from 80 to 240 pulses per second) for the seventh dog, the mean slope for six onset maneuvers is 0.739 ± 0.077. If it is included, the mean slope for the seven onsets is 0.986 ± 0.656. Future research must investigate the prediction of the force-pressure relation across subjects, the bases of its short-term variation within subjects, and the effects of alterations of muscle length on this relation.

The Figures illustrate the temporal relation of the pressure and isometric force records for sample data from the last animal studied, which was small (6.3 kg). The data shown come from a transducer placement at the approximate center of the muscle. The time course of pressure variation in recordings from other transducer locations, such as directly beneath the mucosa, differed from that of central pressures, with potentially important physiological implications. Apart from rescaling from electrical to mechanical units, the data have been left in the form in which they were recorded.

Figure 1A shows the timing of the stimulator pulse, in the illustration of an isometric twitch. Figure 1B shows intramuscular fluid pressure. The peak pressure rise here is just over 23 mm Hg. The pressure signal is updated every 900 microseconds; the resulting high-frequency component in its signal may be ignored for physiologic interpretations. Figure 1C shows isometric force with the DC offset corresponding to resting tension set to zero. The pressure signal reflects the limited system bandwidth of the available system (–3 dB at 33 Hz), and the pressure signal is delayed relative to the force by electronic processing; the lag duration will be specified approximately below. Figure 1D is the evoked EMG signal with an arbitrary scale.

Figure 2 shows the cross-correlation function (Fig 2A) between the pressure record (Fig 2B) and isometric force (Fig 2C), in the response to 50-millisecond repeated bursts of tetanic stimulation at 160 pulses per second. The cross-correlation function plots the degree of scale- and offset-free similarity between these signals as a function of the lag between them. It is used here in order to identify the lag between pressure and force as the point at which the value of the function peaks, since it is known that the physical variation of isometric force and intramuscular pressure is almost simultaneous. Here the cross-correlation function was calculated on the basis of 4,096-

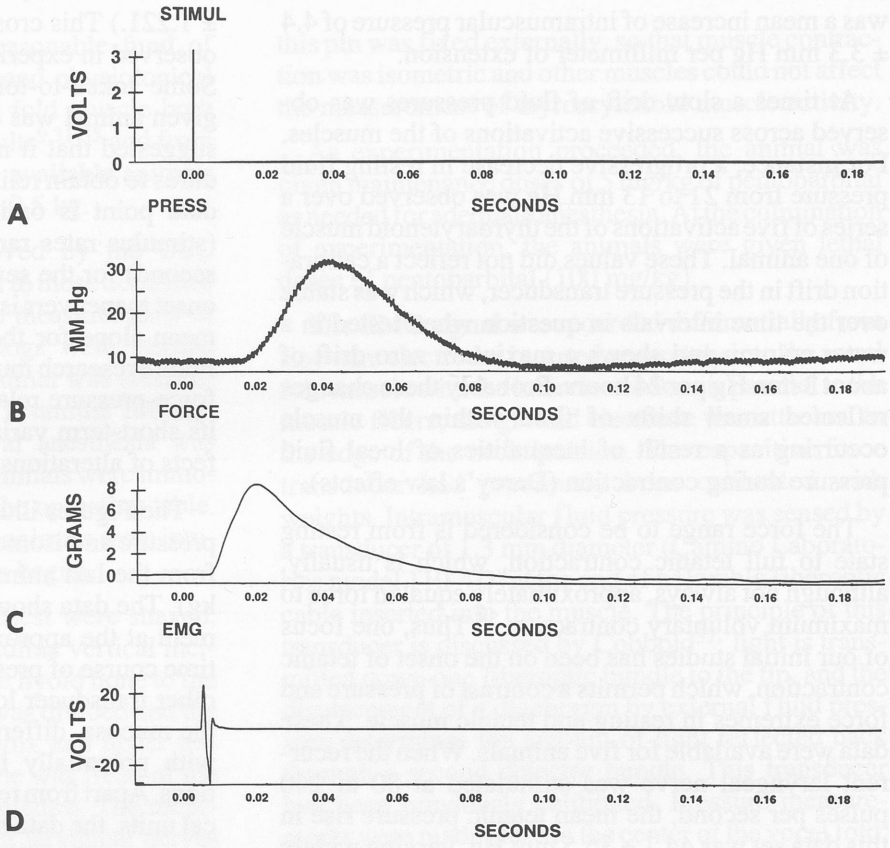

Fig 1. Twitch contraction of vocal fold of dog 7. Force and pressure changes are simultaneous, but electronic processing results in apparent temporal displacement indicated in Fig 2. A) Stimulator timing pulse simultaneous with stimulation. B) Intramuscular fluid pressure. C) Isometric muscle force, with resting tension set to zero. D) Electromyographic signal with arbitrary scale.

point records digitized at 10 kHz, including three cycles such as those illustrated. The cross-correlation function reaches a peak of r = .97 with a 14-millisecond lag between the two records. This delay includes both the processing lag noted above and the filter characteristics of the system; it is almost eliminated in a different version of the measurement system electronics, which was not available to us. The gradual fall of the cross-correlation function reflects a computational convention (addition of zeroes to the first data set) rather than an actual progressive decrease in the agreement between the two signals. In seven such data sets for this animal, the mean peak of the cross-correlation function was r = .939 ± .026. Since these data sets included 28,672 points, this correlation coefficient was significant at better than the .001 probability level.

Figure 3 superimposes the pressure and force records of Fig 2 with elimination of the indicated processing lag and visual rescaling to the same peak-to-peak amplitude. The close relation between the pressure and force signals is clear in both of these data sets.

DISCUSSION

Some remarks on the measurement system are necessary. The pressures are gauge pressures, ie, differences from atmospheric pressure. Above 250 mm Hg, the linearity of the measurement system used in the present study decreases. However, the high correlation (ie, highly linear relation) between force and pressure measures exemplified in Fig 2 indicates that any resulting perturbation in the present study was small. Most pressure values measured fell well below this level, in any case.

A major objective of the present study has been to determine the feasibility of such measurements in small laryngeal muscles. This question has been answered positively in the sense that the measurement of fluid pressures in a muscle that averaged about 1 cm in length in the small animals used made the present study almost a worst case. Since the muscles studied here had about two thirds the length of adult human ones, their volume was probably not more than one third that of the human thyroarytenoid muscle.[39]

Resting intramuscular pressure is expected to be slightly above atmospheric. The observed mean 14 mm Hg elevation of resting pressure is approximately accounted for by estimating the compliance of the interstitial fluid compartment on the basis of measurements from cat and rat muscles, which agree at 1.4 mL/100 g tissue x mm Hg,[19,40] and considering the effect of the introduction of the volume of the transducer (about 5 mm^3) in raising the intramuscular fluid pressure. Thus, the ratio of the volume of the

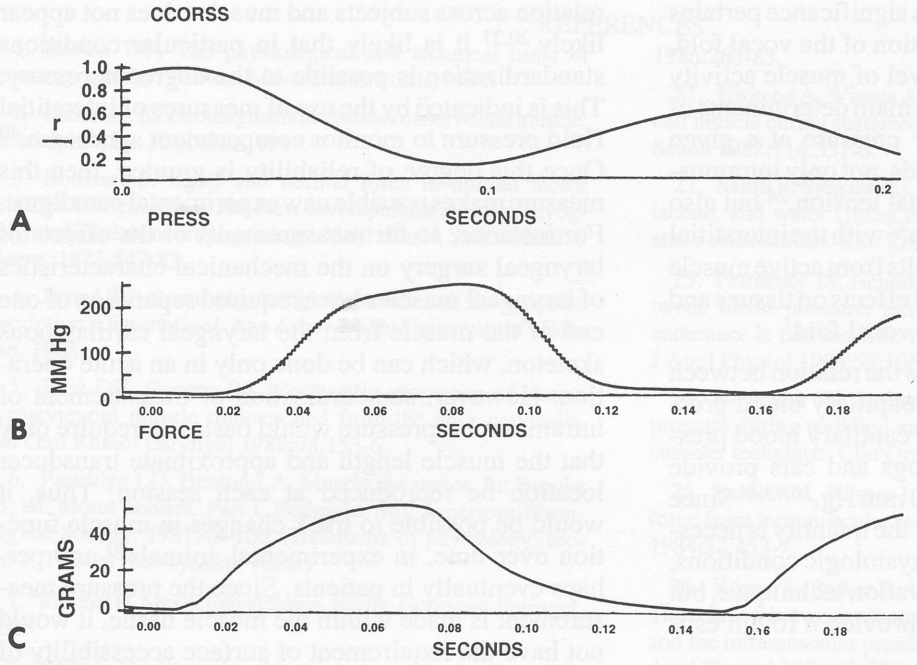

Fig 2. Relation between intramuscular pressure and isometric force in response to 50-millisecond bursts of tetanic stimulation at 160 pulses per second. A) Computed cross-correlation function between B) pressure and C) force records. Here, cross-correlation function reaches peak of r = .97 at 14-millisecond lag, indicating close relationship between pressure and force records when delay introduced by electronic processing in pressure system is taken into consideration.

muscle studied to that of the pressure transducer is a factor limiting measurement accuracy. In a future study, measurement accuracy could be improved by precise monitoring of intramuscular transducer location, by study of larger muscles as in the human larynx, and by decrease of the volume of the pressure transducer.

The fact that measurements of intramuscular fluid pressure could be made within the vocal folds of small animals using a size and type of transducer that still can be improved suggests that application in much larger human subjects need not be remote. The

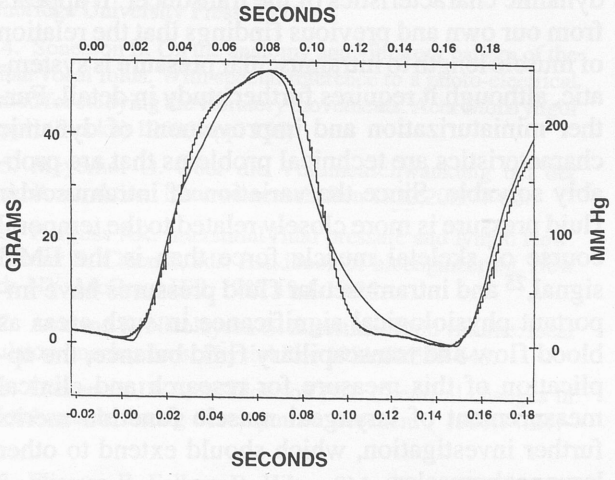

Fig 3. Superimposition of pressure and force records from Fig 2 indicates their similarity. Force record is smooth and pressure record stepped, as in Fig 2. Electronic lag defined by cross-correlation function is eliminated to show physical simultaneity of records, and vertical magnitude scales are equated. Top scale — time base for pressure, bottom scale — time base for force.

pressure transducer used in the present study was too large (1.3 mm diameter) for routine application in small muscles of human subjects. Foreseeable miniaturization could conceivably reduce such transducers to approximately the size of fine-wire electrodes (circa 50 μm diameter) for EMG; as in EMG, the available procedures for measurement of intramuscular fluid pressure would remain invasive to some degree. However, the pressure measurement is not suggested as a replacement for the EMG signal. The pressure signal, which represents the mechanical result of excitation-contraction coupling, is complementary to the EMG signal, which represents the spread of muscle excitation. Their combined use more adequately represents muscle activity than does either alone.

The range of intramuscular pressures during contraction observed in the present study is smaller than the higher pressure levels observed in human limb muscles during high levels of contraction (up to nearly 600 mm Hg).[27] One reason may be the fact that the animals and muscles studied were quite small. Inference to absolute pressure values that might be observed in the human vocal folds is thus limited by the fact that the structures studied would be much larger in adult human subjects. It is also the case that the course of muscle fibers in the canine vocal fold, which would affect the pressures developed, is not as well studied as it is in humans.[14] The fact that the mucosa of the canine vocal fold is thicker and somewhat differently constructed[30] from the human one would also affect comparison of the measurements.

The measurement of intramuscular fluid pressure has several distinct types of significance in the study

of voice physiology. Part of this significance pertains to the special mechanical situation of the vocal fold. In most muscles, of course, level of muscle activity and muscle length would be the main determinants of the variation of intramuscular pressure at a given point. However, in the vocal folds, not only intramuscular pressures from longitudinal tension,[24] but also collision pressures[41] would sum[42] with the interstitial fluid pressure variation that results from active muscle contraction, in their mechanical effects on tissues and movement of fluids within the vocal fold.

An important consideration is the relation between interstitial fluid pressures and capillary blood pressures. Direct determinations of capillary blood pressure in skeletal muscles of dogs and cats provide values in the range from 20 to 40 mm Hg.[16,43,44] Since blood flow may be intermittent, the quantity is necessarily variable depending on physiologic conditions, and it varies for different observation techniques, but these figures may be taken to provide a rough estimate.

It will be evident that these values are an order of magnitude smaller than those quoted as maximum pressures during voluntary contraction in human skeletal muscle, and even somewhat smaller than the tetanic pressures observed in the canine thyroarytenoid muscle. Consequently, it is not surprising that at high levels of contraction, muscle activity proceeds under ischemic conditions when interstitial pressures become so high that blood flow decreases or is entirely obstructed, resulting in more rapid fatigue than when normal blood flow is preserved.[20,44,45] It has been found that laryngeal muscles possess a strong oxidative metabolism with some specializations that are probably related to the degree of physiologic fatigue resistance found in laryngeal muscles of larger animals.[36,46-48] This is consistent with the respiratory function of these muscles, for which resistance to fatigue would be indispensable for survival. Consequently, the finding of this paper that thyroarytenoid intramuscular pressures resulting from high levels of contraction alone are probably sufficient to obstruct blood flow through the muscle suggests a metabolic significance for laryngeal intramuscular fluid pressures.

The covariation of intramuscular pressure and isometric force in a small laryngeal muscle has been exemplified in the Figures above. Although the variation across different specimens of the homologous muscles is such that complete standardization of this relation across subjects and muscles does not appear likely,[20,27] it is likely that in particular conditions standardization is possible to the degree necessary. This is indicated by the use of measures of interstitial fluid pressure to monitor compartment syndrome.[49] Once this degree of reliability is granted, then this measure makes possible new experimental paradigms. For instance, so far measurements of the effects of laryngeal surgery on the mechanical characteristics of laryngeal muscles have required separation of one end of the muscle from the laryngeal cartilaginous skeleton, which can be done only in an acute operation. However, standardization of measurement of intramuscular pressure would basically require only that the muscle length and approximate transducer location be reproduced at each session. Thus, it would be possible to track changes in muscle function over time, in experimental animals[50] and perhaps eventually in patients. Since the pressure measurement is made within the muscle tissue, it would not have the requirement of surface accessibility of the muscle that is a limitation of techniques based on measurement of the external mechanical properties of the muscle. Thus, despite the complexity of the mechanical determinants of the local intramuscular pressures, further research into the determinants of the scaling of the relationship between pressure and force is merited in order to make more precise the inference of muscle force from intramuscular pressure under specific conditions.

Other questions that must be addressed in further detail are the effects of change of muscle length on intramuscular pressures, further miniaturization of the pressure transducer, and improvement of the dynamic characteristics of the transducer. It appears from our own and previous findings that the relation of muscle length to intramuscular pressure is systematic, although it requires further study in detail. Further miniaturization and improvement of dynamic characteristics are technical problems that are probably solvable. Since the variation of intramuscular fluid pressure is more closely related to the temporal course of skeletal muscle force than is the EMG signal,[25] and intramuscular fluid pressures have important physiological significance in such areas as blood flow and transcapillary fluid balance, the application of this measure for research and clinical measurement of laryngeal muscle function merits further investigation, which should extend to other laryngeal muscles.

ACKNOWLEDGMENTS — We are grateful to Dr Alan Hargens of the National Aeronautics and Space Administration for technical advice. In formulating plans for this research, we were fortunate to have the advice of Dr Bernard Abbott of the Department of Biology of the University of Southern California, who observed the original experiments of A. V. Hill on intramuscular pressures. We are grateful to Dr Martin Weiss of the Department of Neurological Surgery of Los Angeles County–University of Southern California Medical Center for the use of the Camino 420 unit interfaced with the pressure transducer. The assistance of Jozsef Földi, research coordinator of the Department of Surgery, University of Southern California, and the use of the laboratory of the Department of Surgery are gratefully acknowledged.

REFERENCES

1. Brown WF. The physiological and technical basis of electromyography. Boston, Mass: Butterworth, 1984.

2. Kimura J. Electrodiagnosis in diseases of nerve and muscle. Philadelphia, Pa: FA Davis, 1989.

3. Bouisset S. EMG and normal force in normal motor activities. In: Desmedt JE, ed. New developments in electromyography and clinical neurophysiology. Vol 1. Basel, Switzerland: S Karger, 1973:547-83.

4. Broad DJ. Some physiological parameters for prosodic description [Dissertation]. Ann Arbor, Mich: University of Michigan, 1968.

5. Rice DH, Cooper DS. Contractile properties of canine thyroarytenoid muscle reinnervated from the ansa cervicalis. Ann Otol Rhinol Laryngol 1989;98:153-6.

6. Partridge LD, Benton LA. Muscle the motor. In: Brooks VB, ed. Motor control. Part I. Bethesda, Md: American Physiological Society, 1981:43-106. (Handbook of physiology; section 1. The nervous system; vol 2.)

7. Reichel H. Muskelphysiologie. Berlin, Germany: Springer, 1960.

8. Réthi L. Die Stimmbandspannung, experimentell geprüft. Sitzungsberichte der mathematisch-naturwissenschaftlichen Classe der kaiserlichen Akademie der Wissenschaften. CVI Band, Abtheilung III. Vienna: 1897:244-52.

9. Mårtensson A, Skoglund CR. Contraction properties of intrinsic laryngeal muscles. Acta Physiol Scand 1964;60:318-36.

10. Haji T, Nori K, Omori K, Taira T, Isshiki N. Mechanical property of vocal fold. In: Proceedings, XXIst Congress of the International Association of Logopedics and Phoniatrics. Vol 2. Prague, Czechoslovakia: IALP, 1989:312-4.

11. Hill AV. The pressure developed in muscle during contraction. J Physiol (Lond) 1948;107:518-26.

12. Hill AV. Trails and trials in physiology. Baltimore, Md: Williams & Wilkins, 1965.

13. Needham DM. Machina carnis. Cambridge, England: Cambridge University Press, 1971.

14. Sonesson B. On the anatomy and vibratory pattern of the human vocal folds. With special reference to a photo-electrical method for studying the vibratory movements. Acta Otolaryngol [Suppl] (Stockh) 1960(suppl 156).

15. Meyerhof O. Über die Volumenschwankung bei der Muskelkontraktion. Naturwissenschaften 1932;20:977-80.

16. Hargens AR. Interstitial fluid pressure and lymph flow. In: Skalak R, Chien S, eds. Handbook of bioengineering. New York, NY: McGraw-Hill, 1987:19.1-19.25.

17. Aukland K, Nicolaysen G. Interstitial fluid volume: local regulatory mechanisms. Physiol Rev 1981;61:556-643.

18. Dickerson JWT, Widdowson EM. Chemical changes in skeletal muscle during development. Biochem J 1960;74:247-57.

19. Eliassen E, Folkow B, Hilton SM, Öberg B, Rippe B. Pressure-volume characteristics of the interstitial fluid space in the skeletal muscle of the cat. Acta Physiol Scand 1974;90:583-93.

20. Sejersted OM, Hargens AR. Regional pressure and nutrition of skeletal muscle during isometric contraction. In: Hargens AR, ed. Tissue nutrition and viability. New York, NY: Springer, 1986:263-83.

21. Kirkebø A, Wisnes A. Regional tissue fluid pressure in rat calf muscle during sustained contraction or stretch. Acta Physiol Scand 1982;114:551-6.

22. Saltin B, Sjögaard G, Gaffney FA, Rowell LB. Potassium, lactate, and water fluxes in human quadriceps muscle during static contractions. Circ Res 1981;48(suppl 1):18-24.

23. Petrofsky JS, Hendershot DM. The interrelationship between blood pressure, intramuscular pressure, and isometric endurance in fast and slow twitch skeletal muscle in the cat. Eur J Appl Physiol 1984;53:106-11.

24. Baumann JU, Sutherland DH, Hänggi A. Intramuscular pressure during walking: an experimental study using the wick catheter technique. Clin Orthop 1979;145:292-9.

25. Parker PA, Körner L, Kadefors R. Estimation of muscle force from intramuscular total pressure. Med Biol Eng Comput 1984;22:453-7.

26. Körner L, Parker P, Almström C, Herberts P, Kadefors R. The relation between spectral changes of the myoelectric signal and the intramuscular pressure of human skeletal muscle. Eur J Appl Physiol 1984;42:202-6.

27. Sejersted OM, Hargens AR, Kardel KR, Blom P, Jensen O, Hermansen L. Intramuscular fluid pressure during isometric contraction of human skeletal muscle. J Appl Physiol Respir Environ Exercise Physiol 1984;56:287-95.

28. De Luca CJ, van Dyk EJ. Derivation of some parameters of myoelectric signals recorded during sustained constant force isometric contractions. Biophys J 1975;15:1167-80.

29. Kersing W. De Stembandmusculatuur. Een Histologische en Histochemische Studie. Utrecht, the Netherlands: Drukkerij Elinkwijk BV, 1983.

30. Kurita S, Nagata K, Hirano M. A comparative study of the layer structure of the vocal fold. In: Bless DM, Abbs JH, eds. Vocal fold physiology. San Diego, Calif: College-Hill Press, 1983:3-21.

31. Laporte Y, Bessou P. Etude de la contraction du muscle thyro-aryténoidien inférieur chez le chien. C R Soc Biol (Paris) 1956;150:2010-4.

32. Mårtensson A. Testing for doubly innervated fibers in the intrinsic laryngeal muscles of the dog. Acta Physiol Scand 1966;67:152-64.

33. Hast MH. Physiological mechanisms of phonation: tension of the vocal fold muscle. Acta Otolaryngol (Stockh) 1966; 62:309-18.

34. Hast MH. Mechanical properties of the vocal fold muscle. Pract Otorhinolaryngol 1967;29:53-6.

35. Sato F, Hisa Y. Mechanical properties of the intrinsic laryngeal muscles and biomechanics of the glottis in dogs. In: Hirano M, Kirchner JA, Bless DM, eds. Neurolaryngology. Recent advances. Boston, Mass: College Hill, 1987:97-106.

36. Cooper DS, Rice DH. Fatigue resistance of canine vocal fold muscle. Ann Otol Rhinol Laryngol 1990;99:228-33.

37. Cobbold RSC. Transducers for biomedical measurements. New York, NY: Wiley, 1974:226-9.

38. Bigland-Ritchie B. EMG and fatigue of human voluntary and stimulated contractions. In: Porter R, Whelan J, eds. Human muscle fatigue: physiological mechanisms. London, England:

Pitman Medical, 1981:130-56. (Ciba symposium 82.)

39. Faaborg-Andersen K. Electromyographic investigation of intrinsic laryngeal muscles in humans. Acta Physiol Scand [Suppl] 1957;41(suppl 140).

40. Reed RK, Wiig H. Compliance of the interstitial space in rats: I. Studies on hindlimb skeletal muscle. Acta Physiol Scand 1981;113:297-305.

41. Scherer RC, Titze IR. Vocal fold contact stress during phonation [Abstract]. J Acoust Soc Am 1982;71:S55.

42. Guyton AC, Barber BJ, Moffatt DS. Theory of interstitial pressures. In: Hargens A, ed. Tissue fluid pressure and composition. Baltimore, Md: Williams & Wilkins, 1981:11-9.

43. Fronek K, Zweifach BW. Microvascular pressure distribution in skeletal muscle and the effect of vasodilation. Am J Physiol 1975;228:791-6.

44. Hargens AR, Akeson WH, Mubarak SJ, et al. Fluid balance within the canine anterolateral compartment and its relationship to compartment syndromes. J Bone Joint Surg [Am] 1978;60:499-505.

45. Hudlická O. Muscle blood flow. Amsterdam, the Netherlands: Swets and Zeitlinger, 1973.

46. Edström L, Lindquist C, Mårtensson A. Correlation between functional and histochemical properties of the intrinsic laryngeal muscles in the cat. In: Wyke B, ed. Ventilatory and phonatory control systems. London, England: Oxford University Press, 1974:392-407.

47. Zealear DL. Specialization of laryngeal motor units for their functions [Dissertation]. San Francisco, Calif: University of California, 1979.

48. Mardini IA, McCarter RJM, Neal GD, Wiederhold ML, Compton CE. Contractile properties of laryngeal muscles in young and old baboons. Am J Otolaryngol 1987;8:85-90.

49. Mubarak SJ, Hargens AR. Compartment syndromes and Volkmann's contracture. Philadelphia, Pa: WB Saunders, 1981.

50. Hargens AR, Gomez MA, Evans KL, Tipton CM, Akeson WH. Correlation of interstitial fluid pressure and contraction force in canine skeletal muscle. Bibl Anat 1981;20:260-2.

MULTICHANNEL ELECTROMYOGRAPHIC OBSERVATIONS IN SPASMODIC DYSPHONIA PATIENTS AND NORMAL CONTROL SUBJECTS

STEVEN D. SCHAEFER, MD
DALLAS, TEXAS

RICK M. ROARK, PHD
DALLAS, TEXAS

BEN C. WATSON, PHD
DALLAS, TEXAS

GEORGE V. KONDRASKE, PHD
ARLINGTON, TEXAS

FRANCES J. FREEMAN, PHD
DALLAS, TEXAS

ROBERT W. BUTSCH, MS
DALLAS, TEXAS

JOHN POHL
ARLINGTON, TEXAS

Spasmodic dysphonia is primarily a disorder of vocalization. Increasing evidence, however, suggests that individuals with this disorder comprise a heterogeneous population characterized by abnormal motor control throughout the vocal tract. Multichannel simultaneous electromyography was performed on 11 spasmodic dysphonia patients and 10 normal awake subjects to investigate both the distribution of neuromotor abnormality within the vocal tract (eg, intrinsic and extrinsic laryngeal muscles, tongue, and palate) and the contribution of activation of higher central nervous system centers to observed abnormality. Experimental tasks ranged from vegetative (quiet breathing) to simple linguistic (short sentences). Digitized electromyographic signals were analyzed to compute the amplitude envelope and extract a set of parameters that represent amplitude characteristics. Electrode insertions were cross-validated by quantitative analysis of patterns of activation across selected reference tasks and by traditional qualitative methods. Between-group differences were found for measures of normalized median and peak token amplitudes. These differences are both task- and measure-dependent. Results highlight the complex and interactive effects of muscle, task, and quantitative measures on between-group differences.

KEY WORDS — multichannel electromyography, spasmodic dysphonia, voice.

INTRODUCTION

The initial description of spasmodic dysphonia (SD) as a form of nervous hoarseness by Traube[1] initiated the view, widely held over the subsequent century, that SD was solely a functional disorder. Elaborate statements endorsing this view were made based on the bizarre presentation of SD patients. Any consideration that such patients, or a subset of these patients, might have an organic disorder was dismissed.[2] In contrast, work beginning with Aronson et al[3,4] suggested the findings of voice tremor, facial or tongue twitches, and head or neck tremor were highly linked neurologic signs rather than incidental findings in a presumed psychiatric population. Additional evidence of an organic substrate to SD has come from various investigations showing auditory brain stem, gastric acid secretory (visceral vagal efferents), electromyography (EMG), blink reflex, and structural and functional brain abnormalities in part of the SD population.[5-11] Given this body of evidence, we believe that direct measures of human vocal tract neuromotor activity should further our understanding of SD, and perhaps our understanding of central nervous system (CNS) motor control of the vocal tract.

One approach to broadening our understanding of SD is to apply EMG measures to examine the nature and extent of vocal tract deficits in affected subjects. Such an approach must be recognized as having several inherent problems due to the population under study and the complexity of acquiring and analyzing multichannel vocal tract EMG. In regard to problems in studying a population of SD subjects, the first consideration is the heterogeneity of individuals who often share only their pattern of abnormal voicing. Some subjects may have several coexistent neurologic findings indicative of an organic basis for their disorder, while others remain a diagnostic challenge. Blitzer et al[12] have further characterized SD as a form of either focal (involving only the larynx) or generalized dystonia. Obviously, any one EMG measure of such a heterogeneous population could be expected to vary from subject to subject. However, a pattern of abnormalities may emerge from analysis of multiple EMG measures across muscles, tasks, and subjects.[12-15] A second consideration in studying SD by EMG is the observation that spasticity is exacerbated by increasing the communicative intent of the task.[13] For example, a pattern of essentially normal vocalization for static or sustained tasks, such as the vowel /i/, followed by impaired vocalization during simple sentences is one of the characteristics of SD thought to

From the Department of Otolaryngology (Schaefer, Roark, Butsch), University of Texas Southwestern Medical Center, Dallas, Callier Center for Communicative Disorders, University of Texas at Dallas (Watson, Freeman), and Human Performance Institute, University of Texas at Arlington (Kondraske, Pohl), Texas. Supported by National Institutes of Health grant R01-DC 00410-03.

Presented at the meeting of the American Laryngological Association, Waikoloa, Hawaii, May 4-5, 1991.

REPRINTS — Steven D. Schaefer, MD, Dept of Otolaryngology, University of Texas Southwestern Medical Center, 5323 Harry Hines Blvd, Dallas, TX 75235-9035.

be consistent with a psychiatric disorder.[16] Such a behavior within the same subject confounds testing confined to one or two speech tasks, since this approach fails to consider the well-recognized performance variability. This variability may reflect activation of hierarchically organized centers for vocal motor control within the CNS. A third consideration is the effect of the testing procedure on the patient's behavior; that is, results are influenced by the structure of vocal tasks, the testing environment, the interaction of the subject with investigators, subject instructions, and subject compensatory behaviors.[16]

In regard to vocal tract EMG, there are several additional considerations. First, the human vocal tract is best viewed as a highly integrated, dynamic, and adaptive system extending from the diaphragm to the lips. Experimental paradigms must provide for simultaneous measures of multiple elements of this system within the constraints inherent in human testing. With a few important exceptions,[17-20] vocal tract EMG has been limited primarily to concentric needle electrodes within a few endolaryngeal muscles during performance of static vocal tasks. A second consideration is the distinction between normal and pathologic performance on multiple simultaneous EMG measures of the human vocal tract. For example, a particular muscle might have a "normal" pattern of neuromotor activity as measured by the quality or quantity of electrical activity, but be inappropriately activated for a given vocal task. Third, descriptions of EMG abnormalities have often been qualitative. Given the unique function and anatomy of the vocal tract and the characteristics of laryngeal muscles, such analyses may be inadequate to describe the extent of abnormality in SD.[15,21] However, techniques for quantification and statistical comparisons can build upon EMG studies of the extremities.[22]

In an attempt to address many of the above problems, we evaluated SD patients and normal control subjects using a series of acoustic, kinematic, aerodynamic, and EMG measures. This report focuses on our initial quantitative evaluation of a subset of these data. Group comparisons are made for simultaneous EMG findings from vagally and nonvagally innervated muscles and clinical-perceptual findings of the study population performing tasks at points along a hierarchy of increasing linguistic and motoric complexity.

METHOD

Subjects. Eleven SD patients and 10 control subjects underwent simultaneous acoustic, kinematic, and EMG recordings in compliance with the informed consent policies of the Institutional Review Board of the University of Texas Southwestern Medical Center. The SD subjects included 4 men and 7 women (average age 48.6 years, range 25 to 69 years) who were drawn from a larger population of subjects who participated in extensive otolaryngologic and neurologic examinations, as well as static and dynamic brain imaging. Diagnosis of SD was made by a minimum of two otolaryngologists and two speech-language pathologists using both perceptual and fiberoptic laryngoscopic (ie, hyperadduction of vocal folds) criteria. No subject had structural or other laryngeal abnormalities that might confound measures employed in this study. Causes of SD were thought to be cerebral microvascular disease in 2 patients and familial in 1 patient, and were unknown in 8 patients. Duration of dysphonia varied from 1.5 to 20 years (average 8.6 years).

Ten control subjects, consisting of 4 men and 6 women (average age 42.1 years, range 25 to 51 years), were recruited from normal volunteers. Controls were matched as much as possible for gender and age of the study population. None of these subjects had a history of speech or neurologic disorders. History and physical findings were unremarkable and these control subjects were regarded as healthy examples of their respective age groups.

Muscle Selection, Electrode Insertion, and Verification. Recordings were made over two sessions (sessions 3 and 4) in awake, nonsedated subjects in the Vocal Tract Physiology Laboratory (an electrically shielded room) at the University of Texas Southwestern Medical Center. The same personnel participated in all sessions. These sessions were designed to measure multiple parameters of the human vocal tract, and for the purpose of this report, discussion is limited to acoustic and perceptual data and EMG findings in the left levator palatini (LP), genioglossus posterior (GGP), and right thyrohyoid (THD) muscles and both thyroarytenoid (TA) muscles. These muscles were selected to give a range of findings in vocal tract sites innervated by the vagus and hypoglossus nerves.

Bipolar hooked-wire electrodes were constructed using 0.05-mm coated platinum wire (Semiconductor Packaging Materials Inc; effective recording area 1 mm) and were inserted perorally (LP muscle) or transcutaneously.[23] Anesthesia was limited to 1% lidocaine hydrochloride intradermally or 4% lidocaine hydrochloride on mucosal surfaces at electrode insertion sites. Subjects were awake, unsedated, and withdrawn from any medication that might confound findings for a minimum of 2 weeks. Output from each electrode pair was routed to separate EMG amplifiers (Grass Instrument 7P511) through a shielded cable. Amplifiers were carefully calibrated and maintained to ensure accuracy of signals and to minimize extraneous noise. The impedance at each input terminal of the preamplifiers was ≥ 20 MΩ. Sensitivity varied from 5 to 75 μV/mm depending on the electrode configuration and muscle. Each channel was band-pass-filtered

TABLE 1. TASKS UNDER ANALYSIS

Type of Task	*Task*
Reference and verification	Tongue protrusion
	Swallow
	Valsalva maneuver
	High-pitched /i/
	Sustained "sh"
Vegetative	Quiet oral breathing
Paralinguistic	Sustained modal /i/
	Sustained modal /m/
Linguistic	*beep, beep, beep, beep, beep beep, beep went the heap*

Lists only those tasks being analyzed for this report and is drawn from protocol of 48 tasks performed over two sessions. Tasks might serve as both reference or verification and paralinguistic tasks (eg, sustained "sh").

with half amplitude points at 30 Hz and 3,000 Hz. A notch filter was used to minimize 60-Hz interference. All EMG signals were evaluated before and during recordings for extraneous artifacts by using a Tektronix model 11401 digital oscilloscope. Signals from the amplifiers were recorded on analog tape by using a 14-channel FM tape recorder (TEAC-XR-510). Nominal full scale signal amplitudes were ±2 V peak. Recording bandwidths were 2.5 kHz for frequency modulation (FM)–coded EMG channels and 18 kHz for the acoustic direct channel. Verification of insertions followed procedures developed at Haskins Laboratories and was based on appropriateness of electrical activity for a given muscle during specific maneuvers.[17-19] Such maneuvers included but were not limited to the following: 1) activation of the GGP muscle on tongue protrusion and swallowing, 2) activation of the THD muscle on swallowing and neck flexion, 3) activation of the LP muscle on voiceless fricative sounds and swallowing, and 4) activation of the TA muscle on the Valsalva maneuver, swallow, and phonation, but not on inspiration.

Experimental Paradigms and Data Acquisition. All subjects were familiar with the basic experimental tasks and conduct of the testing procedures, having undergone two prior 2- to 3-hour sessions dealing primarily with multiple kinematic, acoustic, and aerodynamic measures of vocal tract function. Subjects were seated in a standard otolaryngologic examination chair with the head fixed 20 cm from an Audio-technica ATM33R electric condenser microphone mounted to the chair. All experimental sessions were cued by a visual pacing light controlled by a desk top computer (Compaq 386/25) operating under the in-house–developed software program ACQUIRE.[24] Experimental tasks were randomly presented by the computer. Each task was guided by the computer-controlled pacing light in a highly reproducible and standardized fashion. Three to five repetitions or tokens of each vegetative, paralinguistic, and linguistic task were performed. For the purpose of this report, analysis is limited to tasks selected from a protocol of 48 (Table 1). Rank-ordered from lowest to highest complexity, these tasks are 1) quiet tidal oral breathing, 2) middle-pitch /i/ (mid /i/), 3) *beep, beep, beep, beep, beep* (beep..beep), and 4) *beep, beep went the heap* (beep..heap).

ACQUIRE software facilitated quality control by operating amplifiers, FM recorders, calibration procedures, and identification of tasks and tokens. At the completion of each session, a printed copy of the performed experimental tasks was provided by the system to verify each event against a handwritten task assessment form used by the investigators.

Acoustic and Perceptual Analysis. Clinical-perceptual analyses of each token were completed by four speech-language pathologists. All four were experienced in evaluating voice characteristics of SD. Mid /i/, beep..beep, and beep..heap were evaluated for presence and severity of strain-strangle quality. Randomized tokens were presented to the evaluators, who were blinded as to the identity of specific individuals and to the pattern of randomization. Strain-strangle was rated on a scale of 0 to 7 (7 = worst).

Data Conversion and Calibration. Analog data from FM tapes were converted to digital form after the data acquisition session. The computer program CONVERT automatically controlled playback of the multichannel tape recorder, a 12-bit digitizer board (Data Translation 2821-F-16SE), and storage of data to magnetic disk media.[24] The EMG signals were low-pass-filtered prior to digitization to reduce high-frequency noise and ensure antialiasing. Constant delay sixth-order analog filters (Frequency Devices 9002) were used at −3 dB cutoff frequencies of 2,500 Hz. Sampling of EMG data occurred at 5,000 samples per second. Acoustic data were similarly filtered at 5,000 Hz and digitized at 10,000 samples per second. Quantitation error due to digitization was 0.0122%. Data files were computer coded during the acquisition and digitization sessions according to subject, session, task, token, and signal channel.

Precision calibration signals recorded during the acquisition session were likewise digitized and analyzed to obtain baseline and multiplication parameters for each signal channel. These parameters were used to convert all EMG data to absolute microvolt units, within a 5% margin of precision. Once calibrated, data were stored to write once, read many (WORM) optical media, from which they could be routinely accessed by computer-aided analysis programs.

Data Analysis. Figure 1 shows EMG and acoustic signals beep..heap for an SD subject. Raw EMG files were first screened visually for quality. Signals that contained artifact or were saturated were eliminated from the data corpus. A file representing the envelope of the signal was computed for each of the

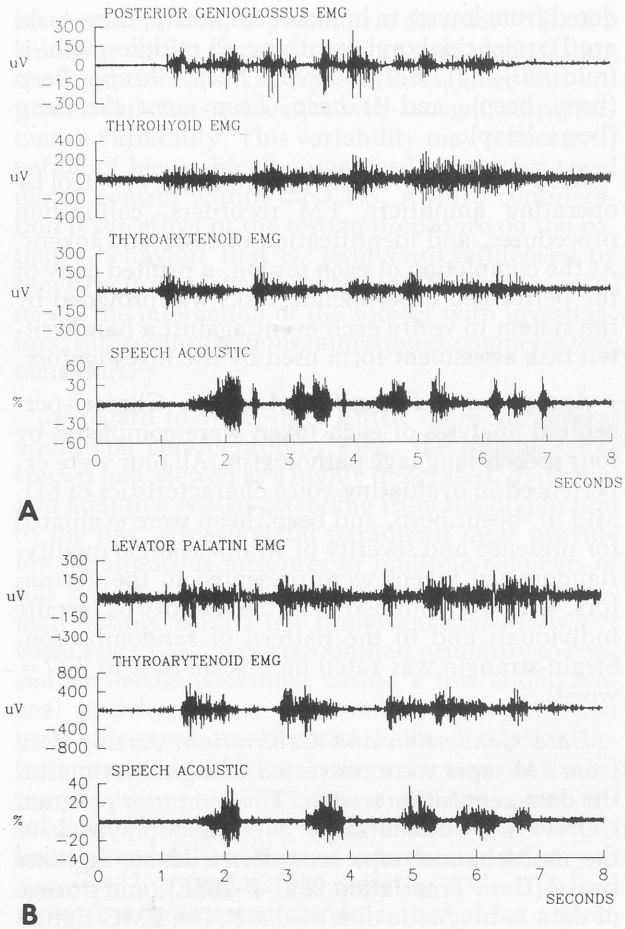

Fig 1. Multiple electromyographic (EMG) and speech acoustic signals recorded during *beep, beep went the heap* produced by the same spasmodic dysphonia subject during two of four data acquisition sessions. Electromyographic signals are calibrated to microvolts and acoustic signals are normalized to percent of maximum observed during single session. A) Session 3. B) Session 4.

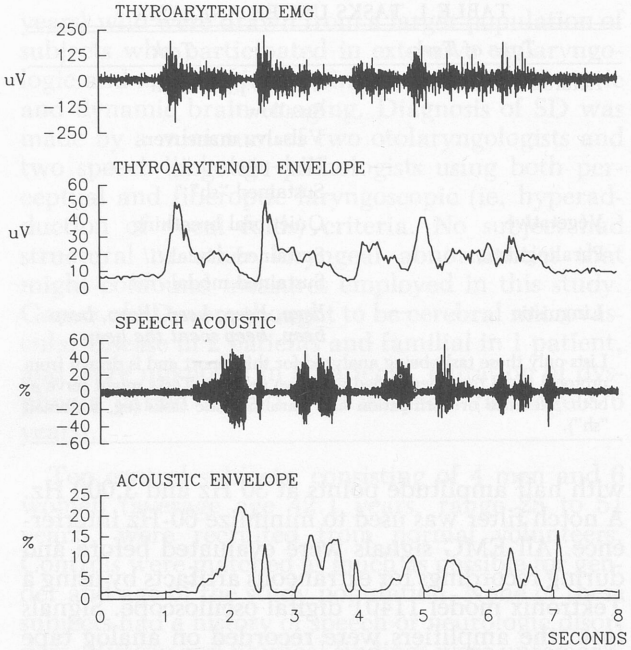

Fig 2. Thyroarytenoid electromyographic (EMG) and speech acoustic signals from Fig 1A for *beep, beep went the heap* along with their corresponding envelopes determined by computer processing. All EMG and acoustic signals are windowed to extract time interval of interest for each session task by using visual and acoustic playback methods.

remaining EMG files as well as for the acoustic signal. Generation of envelope files required several steps. First, any residual DC offset was removed by subtracting the average amplitude value from each data point. The signal was then rectified and digitally low-pass-filtered (cutoff frequency, 10 Hz). Data were then software down-sampled at an effective rate of 30 Hz for inclusion in the envelope files to reduce the size of these files (5,000:30 ratio) and therefore increase the speed of subsequent analyses. Figure 2 shows raw EMG and acoustic signals and corresponding envelope files for beep..heap for the same subject as Fig 1.

Custom software was developed to automatically process envelope files to extract selected measures. This software presented envelope files visually to allow an operator to select start and end times within a file, thereby identifying a segment for subsequent processing. Typically, the acoustic envelope was displayed first, then start and end times were selected, and these were applied to select segments from all signals recorded simultaneously and associated with that token. All signals for a given token were analyzed over the time segment selected to derive a common set of parameter measures. Parameters computed and saved were 1) start time (seconds into file), 2) end time (seconds into file), 3) peak amplitude (microvolts), 4) time into event when peak amplitude occurred (percentage of segment duration), 5) mean amplitude, 6) median amplitude, 7) percentage of event duration during which the signal was above the average amplitude, and 8) ratio of average to peak amplitude. The last two parameters were designed to capture information regarding the gross shape of envelope signals in a manner that is independent of absolute amplitude and are included as a prelude to more detailed temporal analyses. After parameter files were computed for each envelope file, intraindividual average values for each parameter were computed by averaging across values in parameter files representing different tokens of the same task. To conclude the first phase of analysis, the resulting averaged parameter files were concatenated (all parameter files for a given subject) into a single ASCII text file (one per subject) with proper delimiters included for subsequent importing to a spreadsheet. Each of the above steps was facilitated with custom analysis software.

Spreadsheet-compatible parameter files were imported to a MacIntosh computer (MAC II) using Microsoft EXCEL. This spreadsheet consisted of approximately 1,100 rows (21 subjects x 9 tasks x 6

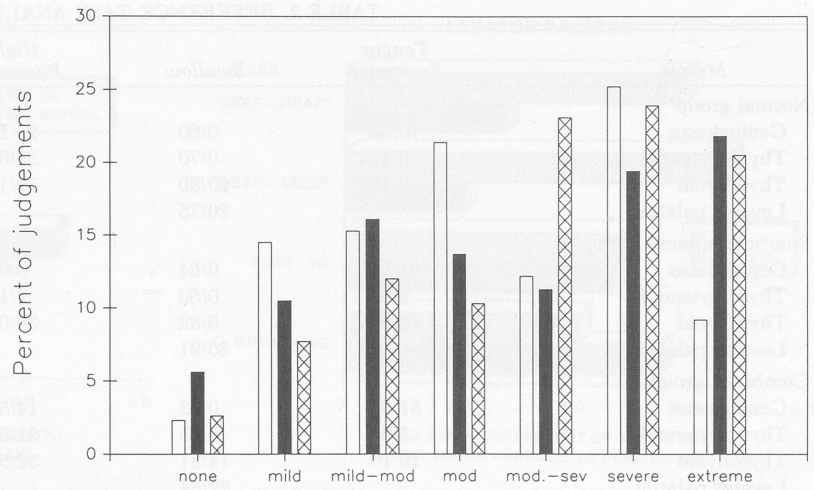

Fig 3. Perceptual judgments of severity of strain-strangle voice quality in spasmodic dysphonia subjects. Empty bars — sustained /i/; dark bars — five repetitions of *beep*; cross-hatched bars — *beep, beep went the heap*.

channels) and 22 columns (identifiers and computed parameters), or approximately 24,000 cells (a data reduction from approximately 110 megabytes of time series data). From this array, a variety of data groupings and restructuring was performed manually to support the last phase of analysis. These analyses included 1) basic descriptive statistics for raw parameters, 2) determination of which task maximally activated a given muscle, and 3) comparison of normal and SD groups as a function of task complexity.

Means and standard deviations were computed for each group separately for each task-muscle combination. Candidate reference tasks were either dynamic (eg, swallow) or sustained (eg, tongue protrusion or sustained "sh"). Peak and median amplitude measures were used to indicate level of activity for dynamic and sustained tasks, respectively. Initial analysis was performed intraindividually. Tasks were rank ordered on the basis of their relative ability to activate a given muscle for a given subject. After rankings were established for all muscles and all subjects, the percentage of observations for which task A was ranked first for a given muscle was computed. Task A was then designated the reference task for that muscle.

Establishment of reference tasks is not only a separately identified analysis, but one that is a necessary precursor to the analysis of differences between normal and SD groups as a function of task complexity. Normalized amplitude parameters were added to the parameter record for each token by dividing peak, mean, and median amplitude values for a given muscle by the activity level index (ie, median or peak amplitude value) associated with the corresponding reference task for that muscle. Thus, the respective normalized parameter represents a characteristic of muscle activity in terms of the percentage relative to reference task activation.

RESULTS

Acoustic and Perceptual Analysis. Distributions of ratings of strain-strangle quality for mid /i/, beep..beep, and beep..heap are shown in Fig 3. Chi-square analyses revealed significant differences between mid /i/ and beep..beep ($\chi^2 = 12.43$, $p = .05$) and between /i/ and beep..heap ($\chi^2 = 17.52$, $p = .008$). The difference between beep..beep and beep..heap was not significant.

Reference Tasks. Activity levels for verification reference tasks are shown in Table 2. Each table cell contains two entries representing the percentage of observations for which the given task produced a rank of 1 (ie, maximal activation) across all tasks analyzed. The left-side entry (denoted M) is based on computation using the median amplitude for each task, whereas the right-side entry (denoted M + P) is based on computation using the median amplitude for sustained tasks and the peak amplitude for dynamic tasks (eg, swallow). The Table has three sections representing analysis of normal, SD, and combined groups. Thus, the 70/30 entry in the first cell for normal subjects indicates that the genioglossus was maximally activated by tongue protrusion in 70% and 30% of the normal subjects using M and M + P, respectively. Peak activity during swallow was taken as the reference for normalizing EMG amplitude measures prior to within-group comparisons, since it is evident from M + P entries that swallow maximally activates all muscles on a frequent basis. To illustrate specificity of activation by task, M entries are shown graphically for the combined group in Fig 4. These values demonstrate specificity of activation of each muscle by the task selected a priori to verify electrode placement.

Group Comparisons. Several parameters were used to investigate differences between normal and SD subjects. One of these is the ratio of the envelope average amplitude to peak amplitude. This simple measure is expected to reflect gross dynamic differences. Figures 5 and 6 show coefficients of variation for normal and SD subjects associated with the average-to-peak ratio measure for the GGP and LP muscles across tasks. These findings show group dif-

TABLE 2. REFERENCE TASK ANALYSIS

Muscle	*Tongue Protrusion*	*Swallow*	*High-Pitched /i/*	*Valsalva Maneuver*	*Sustained "sh"*
Normal group					
Genioglossus	70/30	0/60	20/10	10/0	
Thyroarytenoid	0/10	0/70	38/0	63/20	
Thyrohyoid	0/10	20/80	70/10	10/0	
Levator palatini		20/75		43/13	29/13
Spastic dysphonia group					
Genioglossus	91/36	0/64	9/0	0/0	
Thyroarytenoid	9/0	0/60	9/10	82/30	
Thyrohyoid	18/9	9/82	36/0	36/9	
Levator palatini		30/91		50/9	20/0
Combined group					
Genioglossus	81/33	0/62	14/5	5/0	
Thyroarytenoid	5/5	0/65	21/5	74/25	
Thyrohyoid	10/10	14/81	52/5	24/5	
Levator palatini		29/84		47/11	24/5

Results of analysis to determine activation of muscles by candidate reference tasks. Each table cell represents percentage of observations for which given task produced rank of 1 (ie, maximal activation) across ranking sample set that included all tasks. Results are shown for rankings based on 1) median electromyographic envelope amplitude for all tasks (left-hand value), and 2) those based on median envelope amplitude for sustained tasks plus peak envelope amplitude for swallow (right-hand value).

ferences that depend on the task-muscle combination. The SD subjects showed greater variability in this measure than normals for the GGP muscle during mid /i/, but not during other tasks. In contrast, SD subjects showed greater variability than normals for the LP during the beep..beep and beep ..heap tasks, but not during other tasks.

Normalized activity parameters (peak, mean, and median amplitude) were computed by using the peak amplitude obtained during swallow for a given muscle and subject as the basis for normalization. Figure 7 contains results of this analysis for the TA muscle across tasks. Normalized peak values were used for dynamic tasks such as beep..beep, while normalized median amplitude values were used for mid /i/. A two-way ANOVA on this data set yielded a marginally significant group effect ($p \leq .06$) and a significant group-task interaction ($p \leq .020$). By using Scheffe's method to identify the source of this effect, significant group differences were found for both beep..beep and beep..heap, while differences for quiet breathing and mid /i/ were not significant. Similar analysis for the THD muscle found a significant task effect, but no group effect. The reader will recall that SD subjects showed significant increases in the perceived severity of strain-strangle voice quality for the beep..beep and beep..heap tasks. The decrement in voice quality is likely a reflection of abnormal increases in TA activity for these tasks.

DISCUSSION

The study reported herein applied quantitative measures of EMG signals to test two specific hypotheses regarding vocal tract neuromotor abnormalities in SD: 1) EMG abnormalities in SD are present in vocal tract musculature remote from the larynx, and 2) EMG abnormalities in SD increase as tasks increase in linguistic and motoric complexity. This study also examined the relation between clinical judgments of strain-strangle voice quality and TA activity in SD subjects. To achieve these ends, we reported selected quantitative measures of EMG signals recorded from an intrinsic laryngeal muscle (TA), an extrinsic laryngeal muscle (THD), and nonlaryngeal muscles (GGP, LP). Tasks selected for analysis represent points along a theoretic continuum of increasing complexity and ranged from nonspeech vegetative to simple linguistic.

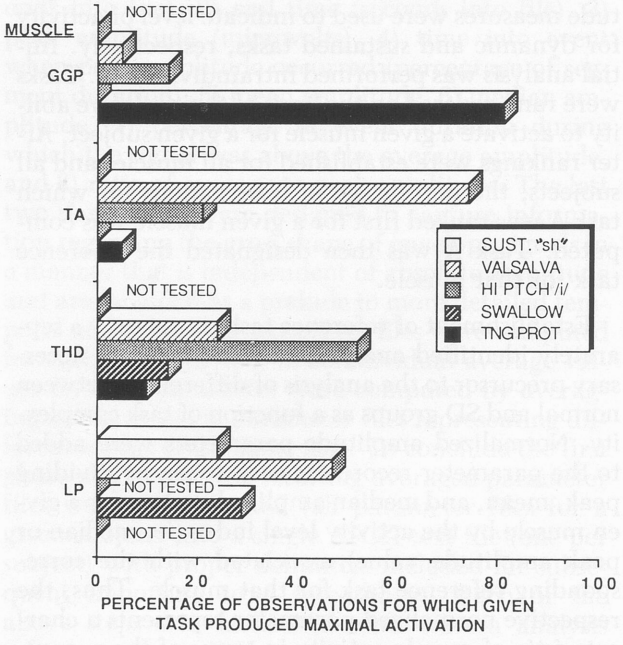

Fig 4. Muscle activation specificity during reference tasks for combined normal and spasmodic dysphonia subjects. TNG PROT — tongue protrusion, NOT TESTED — not analyzed for this graph, GGP — genioglossus posterior, TA — thyroarytenoid (both), THD — right thyrohyoid, LP — left levator palatini.

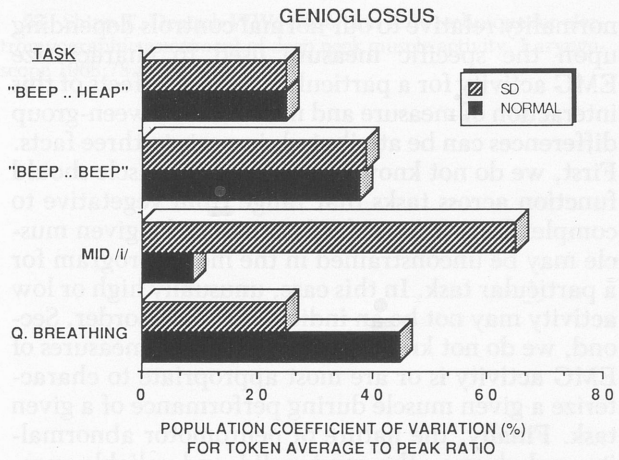

Fig 5. Comparison of normal and spasmodic dysphonia (SD) group coefficients of variation computed for average-to-peak ratio measure of genioglossus electromyographic envelopes for four tasks. Q. BREATHING — resting tidal oral breathing.

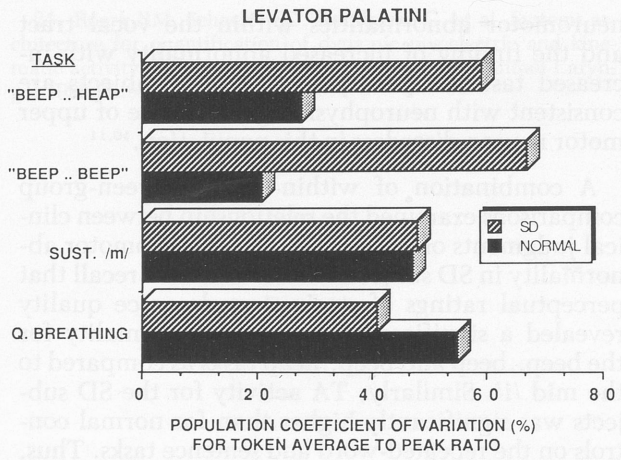

Fig 6. Comparison of normal and spasmodic dysphonia (SD) group coefficients of variation computed for average-to-peak ratio measure of levator palatini electromyographic envelopes for four tasks. Q. BREATHING — resting tidal oral breathing.

The first step in developing quantitative measures of the EMG signal was to examine the utility of these measures in verifying electrode placement and in identifying reference tasks for normalization of raw EMG signals prior to within- and between-group comparisons. Typically, EMG studies verify electrode placement by qualitative evaluation of patterns of muscle activation or inhibition during specific tasks.[18,19,23] Herein, we reported quantitative differences in median muscle activity across verification and reference tasks. This technique provides an objective approach to verification of electrode insertion.

Reference tasks for normalization of EMG signals may represent theoretic maximum or minimum activity for a given muscle. Since the experimental tasks we analyzed should elicit less than maximum activity, we sought to normalize EMG signals relative to maximum activity. With the exception of the swallow, all verification reference tasks were sustained. The inherently dynamic nature of a swallow suggests that maximum activation of a specific muscle cannot be maintained throughout the gesture. Therefore, we examined peak activity levels for each muscle during the swallow. When this measure was considered, all muscles showed maximum activity for the swallow. Thus, quantitative analyses permitted objective identification of the same reference task for all muscles. While we know of no other studies reporting vocal tract EMG that attempted to quantify electrode verification and selection of reference tasks, this strategy appears to be valid and may provide a mechanism for standardization of EMG data analysis. Such standardization will facilitate cross-study comparisons.

Between-group comparisons for the subset of tasks, muscles, and measures reported here revealed EMG abnormalities in multiple vocal tract muscles. Abnormalities were observed in muscles innervated by the vagus (TA, LP) and hypoglossus (GGP) nerves. However, these measures did not reveal abnormalities in another hypoglossus-innervated muscle (THD). In general, these findings are consistent with qualitative and quantitative abnormalities reported for a different set of SD patients by Schaefer et al.[15] Between-group comparisons also revealed differential neuromotor deficits as a function of task complexity. That is, SD subjects showed increased abnormality relative to normals as tasks increased in complexity. Post-test comparisons revealed significant between-group differences for normalized TA activity for beep..beep and beep..heap, but not for mid /i/ ($p < .05$). We have argued elsewhere that increased task complexity may represent increased participation of higher cortical and adjacent subcortical levels within the CNS.[15] The distribution of

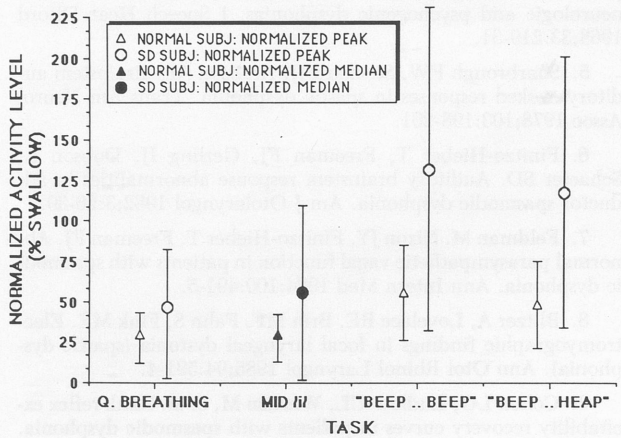

Fig 7. Comparison of normal and spasmodic dysphonia (SD) group thyroarytenoid levels across different tasks. Group means and standard deviations are shown for normalized activity level measures, obtained by dividing raw envelope amplitude characteristics (peak or median) by reference value (peak amplitude exhibited by given muscle during swallow by given subject). Normalized peak and median values are used for dynamic and sustained tasks, respectively.

neuromotor abnormalities within the vocal tract and the finding of increased abnormality with increased task complexity in these SD subjects are consistent with neurophysiologic evidence of upper motor neuron disorders in this population.[10,11]

A combination of within- and between-group comparisons examined the relationship between clinical judgments of voice quality and neuromotor abnormality in SD subjects. The reader will recall that perceptual ratings of strain-strangle voice quality revealed a significant increase in abnormality for the beep..beep and beep..heap tasks as compared to the mid /i/. Similarly, TA activity for the SD subjects was significantly higher than for normal controls on the repeated-word and sentence tasks. Thus, deterioration of voice quality during the more complex speech tasks co-occurs with abnormal increases in TA activity.

In conclusion, this preliminary quantitative analysis of EMG signals supports the hypotheses under test. The findings also yield insights into the complexity of applying quantitative analyses to investigate neuromotor abnormality in SD. For example, SD subjects showed a greater or lesser degree of abnormality relative to our normal controls depending upon the specific measure used to characterize EMG activity for a particular muscle. Effects of this interaction of measure and muscle on between-group differences can be attributed, in part, to three facts. First, we do not know how a specific muscle should function across tasks that range from vegetative to complex linguistic. Indeed, activity of a given muscle may be unconstrained in the motor program for a particular task. In this case, unusually high or low activity may not be an indication of a disorder. Second, we do not know which measure or measures of EMG activity is or are most appropriate to characterize a given muscle during performance of a given task. Finally, the nature of neuromotor abnormality and, hence, the most valid and reliable measure(s) of that abnormality may differ across muscles and/or across tasks within a muscle. Future reports will present analyses of additional tasks, muscles, and measures (eg, including temporal and spectral). Ultimately, our goal is to exploit the analytic power of multiple tasks, muscles, and measures to clarify normal vocal tract neuromotor function and the nature and extent of vocal tract neuromotor abnormality in SD.

ACKNOWLEDGMENTS — The authors wish to acknowledge the contributions of Michael Devous, PhD, Kenneth Pool, MD, and Terese Finitzo, PhD, in making this work possible.

REFERENCES

1. Traube L. Spastiche Form der nervoesen Heiserkeit. In: Traube L, ed. Gesammelte Beitraege zur Pathologie und Physiologie. Vol 2. Berlin: Hirschwald, 1871:674-8.

2. Bloch P. Neuro-psychiatric aspects of spastic dysphonia. Folia Phoniatr (Basel) 1965;17:301-64.

3. Aronson AE, Brown JR, Litin EM, Pearson JS. Spastic dysphonia. I. Voice, neurologic, and psychiatric aspects. J Speech Hear Disord 1968;33:203-18.

4. Aronson AE, Brown JR, Litin EM, Pearson JS. Spastic dysphonia. II. Comparison with essential (voice) tremor and other neurologic and psychogenic dysphonias. J Speech Hear Disord 1968;33:219-31.

5. Sharbrough FW, Stockard JJ, Aronson AE. Brainstem auditory-evoked responses in spastic dysphonia. Trans Am Neurol Assoc 1978;103:198-201.

6. Finitzo-Hieber T, Freeman FJ, Gerling IJ, Dobson L, Schaefer SD. Auditory brainstem response abnormalities in adductor spasmodic dysphonia. Am J Otolaryngol 1982;3:26-30.

7. Feldman M, Nixon JY, Finitzo-Hieber T, Freeman FJ. Abnormal parasympathetic vagal function in patients with spasmodic dysphonia. Ann Intern Med 1984;100:491-5.

8. Blitzer A, Lovelace RE, Brin MF, Fahn S, Fink ME. Electromyographic findings in focal laryngeal dystonia (spastic dysphonia). Ann Otol Rhinol Laryngol 1985;94:591-4.

9. Cohen LG, Ludlow CL, Warden M, et al. Blink reflex excitability recovery curves in patients with spasmodic dysphonia. Neurology 1989;39:572-7.

10. Finitzo T, Freeman F. Spasmodic dysphonia, whether and where: results of seven years of research. J Speech Hear Res 1989; 32:541-55.

11. Pool KD, Freeman FJ, Finitzo T, et al. Heterogeneity in spasmodic dysphonia: neurologic and voice findings. Arch Neurol 1991;48:305-9.

12. Blitzer A, Brin MF, Fahn S, Lovelace RE. Clinical and laboratory characteristics of focal laryngeal dystonia: study of 110 cases. Laryngoscope 1988;98:636-40.

13. Bloch CS, Hirano M, Gould WJ. Symptom response of spastic dysphonia in response to phonatory tasks. Ann Otol Rhinol Laryngol 1985;94:51-4.

14. Ludlow CL, Baker M, Naunton RF, Hallett M. Intrinsic laryngeal muscle activation in spasmodic dysphonia. In: Benecke R, Conrad B, Marden CD, eds. Motor disturbances. Vol 1. Orlando, Fla: Academic Press, 1987:119-30.

15. Schaefer S, Watson B, Freeman F, et al. Vocal tract electromyographic abnormalities in spasmodic dysphonia. Preliminary report. Trans Am Laryngol Assoc 1987;108:187-96.

16. Freeman FJ, Cannito MP, Finitzo-Hieber T. Classification of spasmodic dysphonia by perceptual-acoustic-visual means. In: Gates G, ed. Spastic dysphonia: state of the art. New York, NY: The Voice Foundation, 1985:5-18.

17. Hirose H. Electromyography of the larynx and other speech organs. In: Sawashima M, ed. Dynamic aspects of speech production. Tokyo, Japan: University of Tokyo Press, 1981.

18. Gay T, Hirose H, Strome M, Sawashima M. Electromyography of the intrinsic laryngeal muscles during phonation. Ann Otol Rhinol Laryngol 1972;81:401-9.

19. Hirano M, Ohala J. Use of hooked-wire electrodes for electromyography of the intrinsic laryngeal muscles. J Speech Hear Res 1969;12:362-73.

20. Freeman FJ, Ushijima T. Laryngeal activity during stuttering. J Speech Hear Res 1978;21:538-62.

21. Watson BC, Schaefer SD, Freeman FJ, Dembowski J, Kondraske G, Roark R. Laryngeal electromyographic activity in adductor and abductor spasmodic dysphonia. J Speech Hear Res 1991;34:473-82.

22. Shiavi R. Quantitative representation of electromyographic patterns generated during human locomotion. IEEE Trans Biomed Eng 1990;31:58-60.

23. Shipp T, Deatsch WW, Robertson K. A technique for electromyographic assessment of deep neck muscle activity. Laryngoscope 1968;78:418-32.

24. Roark RM, Schaefer SD, Kondraske G, et al. Systems architecture for quantification of dynamic myoelectric and kinematic activity of the human vocal tract. Ann Otol Rhinol Laryngol 1990;99:902-10.

VOLUNTARY CONTROL OF THE SOFT PALATE IN PHONATION

EIJI YANAGISAWA, MD
NEW HAVEN, CONNECTICUT
LAWRENCE MAMBRINO, MD
NEW HAVEN, CONNECTICUT
JO ESTILL
NEW YORK, NEW YORK
DAVID TALKIN
MURRAY HILL, NEW JERSEY

In our recent velolaryngeal videoendoscopic studies, an independent control of the soft palate during singing was observed. In the present study, the voluntary control of the soft palate is further explored. Velar activities of a series of subjects were studied by using the transnasal velar and simultaneous velolaryngeal videoendoscopic techniques. Our study suggested that the soft palate can be trained to make very discrete movements affecting the acoustic outcome of the voice. The audio recordings were analyzed acoustically. Differences in acoustic spectra were compared and related to the discrete movements of the soft palate videographed endoscopically. These findings may be of interest to otolaryngologists who must assess the need for remedial surgery of patients with insufficient velopharyngeal closure, to speech pathologists in the treatment of these patients, to speakers and singers whose purposes range from high soft singing to tones of maximal loudness, and to acousticians concerned with voice analysis and synthesis.

KEY WORDS — simultaneous velolaryngeal videoendoscopy, soft palate, telescopic velar videoendoscopy, velopharyngeal insufficiency.

Voluntary control of the soft palate is of considerable interest to physicians and speech-language pathologists whose patients may exhibit abnormal velopharyngeal closure. It is known that there are patients who are physiologically and anatomically capable of closing the velopharyngeal port but demonstrate velopharyngeal insufficiency on one or several sounds. This abnormal closure has been hypothesized in many cases to be an error of learning that can be corrected through training. However, the data from palate-training studies using numerous treatment programs have been conflicting, and there is controversy over whether there is independent control over discrete movements of the soft palate.[1-5]

The purpose of this study was to examine the movement and voluntary control of the soft palate during phonation in normal subjects (amateur and trained voice professionals) with transnasal velar and simultaneous velolaryngeal videoendoscopic techniques. Palatal movements were videoendoscopically observed and documented during a battery of selected tasks. Closure of the velopharyngeal port was visually determined and confirmed by acoustic analysis.

MATERIAL AND METHOD

SUBJECTS

Twelve subjects trained in "Compulsory Figures for Voice,"[6] the regimen for training the independent control of various structures in the vocal mechanism, participated in the study. Not all subjects were equally proficient at all maneuvers. The Table lists the subjects and their abilities to perform the tasks required to exhibit voluntary control of the soft palate. Nine of the subjects were professional singers, 3 were amateur singers (all singers were trained by one of the authors [J.E.]), and 1 subject (No. 11) was one of the authors (D.T.) — an engineer and speech scientist familiar with speech articulators and their movement. All 12 subjects could perform tasks 1 and 2. Ten could perform task 3 adequately; 11, task 4; and 9, task 5. The representative video images of the velopharyngeal port were chosen and acoustically analyzed from the audio recordings of these images.

EQUIPMENT

The following equipment was used for this study: 1) an Olympus ENF-P3 flexible fiberscope, 2) a Hopkins 70° rigid telescope (Karl Storz 7200C), 3)

SUBJECTS AND THEIR PERFORMANCE

Subject	*Task 1*	*Task 2*	*Task 3*	*Task 4*	*Task 5*
1	X	X	—	X	—
2	X	X	X	X	—
3	X	X	X	X	X
4	X	X	X	X	X
5	X	X	X	X	X
6	X	X	X	X	X
7	X	X	X	X	X
8*	X	X	X	X	X
9	X	X	X	X	X
10*	X	X	X	X	X
11*	X	X	—	—	—
12	X	X	X	X	X
Total	12	12	10	11	9

X — successful completion of task.
*Amateur singer.

From the Section of Otolaryngology, Department of Surgery, Yale University School of Medicine (Yanagisawa, Mambrino), and the Section of Otolaryngology, Department of Surgery, Hospital of St Raphael (Yanagisawa), New Haven, Connecticut, and AT&T Bell Laboratories, Murray Hill, New Jersey (Talkin). Ms Estill is an independent voice consultant in New York, New York.

Presented at the meeting of the American Laryngological Association, Waikoloa, Hawaii, May 4-5, 1991.

REPRINTS — Eiji Yanagisawa, MD, 98 York St, New Haven, CT 06511.

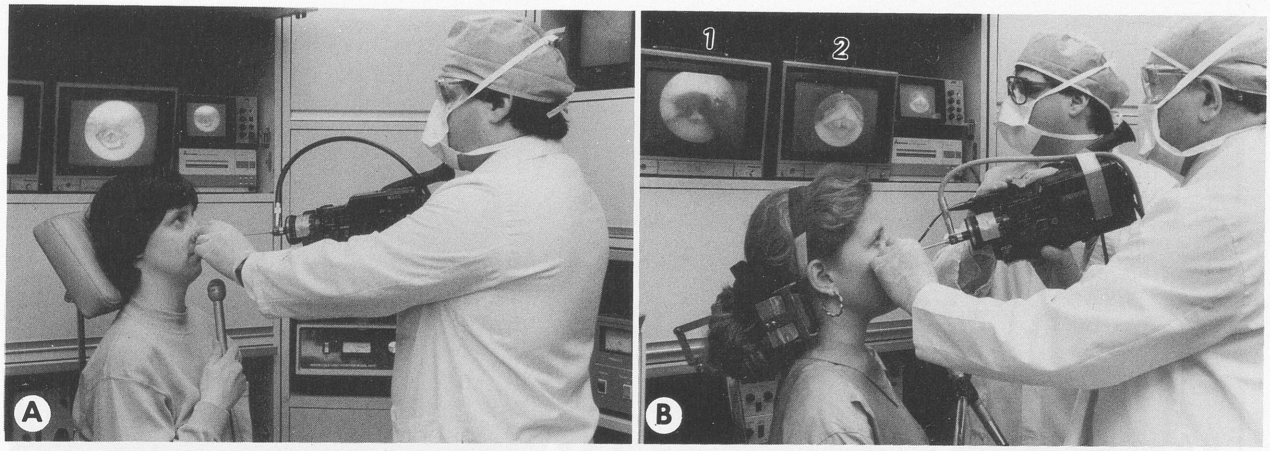

Fig 1. Techniques. A) Telescopic velar videoendoscopy. B) Simultaneous fiberscopic and telescopic velolaryngeal endoscopy. (Reprinted from Yanagisawa et al.[8]) 1 — monitor 1 (telescopic soft palate image), 2 — monitor 2 (fiberscopic laryngeal image).

xenon cold light illuminators (Karl Storz 487C and 615), 4) video cameras [1) an Elmo EM-202 micro CCD color video camera (15 lux) and a Karl Storz supercam 9050B (7 lux) attached to the flexible fiberscope, 2) a Ricoh CCD R-620 home color video camera (4 lux) attached to the Hopkins 70° rigid telescope, and 3) an Ikegami ITC 730AP camera, to videotape the overview picture of the procedure and two monitors placed side-by-side showing the simultaneous images of the soft palate and the larynx (used during review and editing)], 5) Sony $^3/_4$-in VO-5600, VO-9600, and VO-5850 video recorders, 6) an Electro-voice RE-10 unidirectional microphone, and 7) a Sony UP-5000 color video printer.

TECHNIQUE

For telescopic velar videoendoscopy the subject sat facing the examiner. Topical anesthesia and vasoconstriction of the nose were achieved with aerosolized 4% lidocaine hydrochloride (Xylocaine) and 3% ephedrine sulfate. In addition, a pledget soaked with 4% lidocaine solution and 3% ephedrine was placed for 3 minutes in the right side of the nasal cavity for easy passage of the rigid telescope. The Hopkins 70° rigid telescope, which is attached to the color video camera, was then passed into the right nostril. While viewing the telescopic image on the video monitor, the operator carefully and slowly passed the scope into the nasopharynx, and the optimal image of the upper surface of the soft palate and the velopharyngeal port was obtained (Fig 1A). All the recordings were made on the Sony $^3/_4$-in VO 5600 and VO 9600 recorders.

The technique of simultaneous telescopic/fiberscopic velolaryngeal videoendoscopy used for task 5 in this study was the same as that previously described by Yanagisawa et al[7,8] (Fig 1B).

Audio and Video Synchronization. During the procedure, the subject's voice was recorded simultaneously on each videotape recorder (Sony VO 5600 and 9600) on audio track channel 2 by using a single unidirectional microphone placed 7.5 cm diagonal to the subject's mouth. To aid in synchronization of the two diagnostic images, a time code from a single time code source was recorded simultaneously on audio track channel 1 of each videotape recorder, thus making it possible to match the telescopic and fiberscopic images quickly and accurately to the exact frame during editing.

In order to view the telescopic and fiberscopic images simultaneously on a single screen, it was necessary to reposition and reduce the size of both images. With a Microtime RP-1 three-dimensional digital effects generator, the telescopic image was first positioned on the left of the screen and then the fiberscopic image on the right side. The left and right images and both audio channels (channel 2 containing the subject's voice, and channel 1 containing the time code information) were rerecorded onto the new submaster on a Sony BVW-75 Betacam SP video cassette recorder to maintain the highest possible picture quality. A Sony BVE-900 automatic electronic editing controller and the Grass Valley 100 special effect generator were used to produce the final dual image tape in perfect synchronization for analytical review.

Acoustic Analysis. The speech was recorded on the audio track of the videotape machine by using a unidirectional microphone (Electro-voice RE-10). The microphone was hand-held approximately 7.5 cm diagonal to the lower lip. Satisfactory productions were chosen for which both audio and video recordings were available. The audio signal was low-pass-filtered at 5.8 kHz and digitized with 15 bits of resolution at a sampling frequency of 12 kHz. "Broadband" spectrograms of selected segments were then made on the computer by using 8-millisecond overlapping Hanning windows and + 6-dB-per-octave preemphasis. The resulting log-amplitude spectra were offset and scaled so that a 30-dB amplitude range is covered from the white background to saturated black of Figs 2 and 3D. It was desirable to limit the display dynamic range to 30

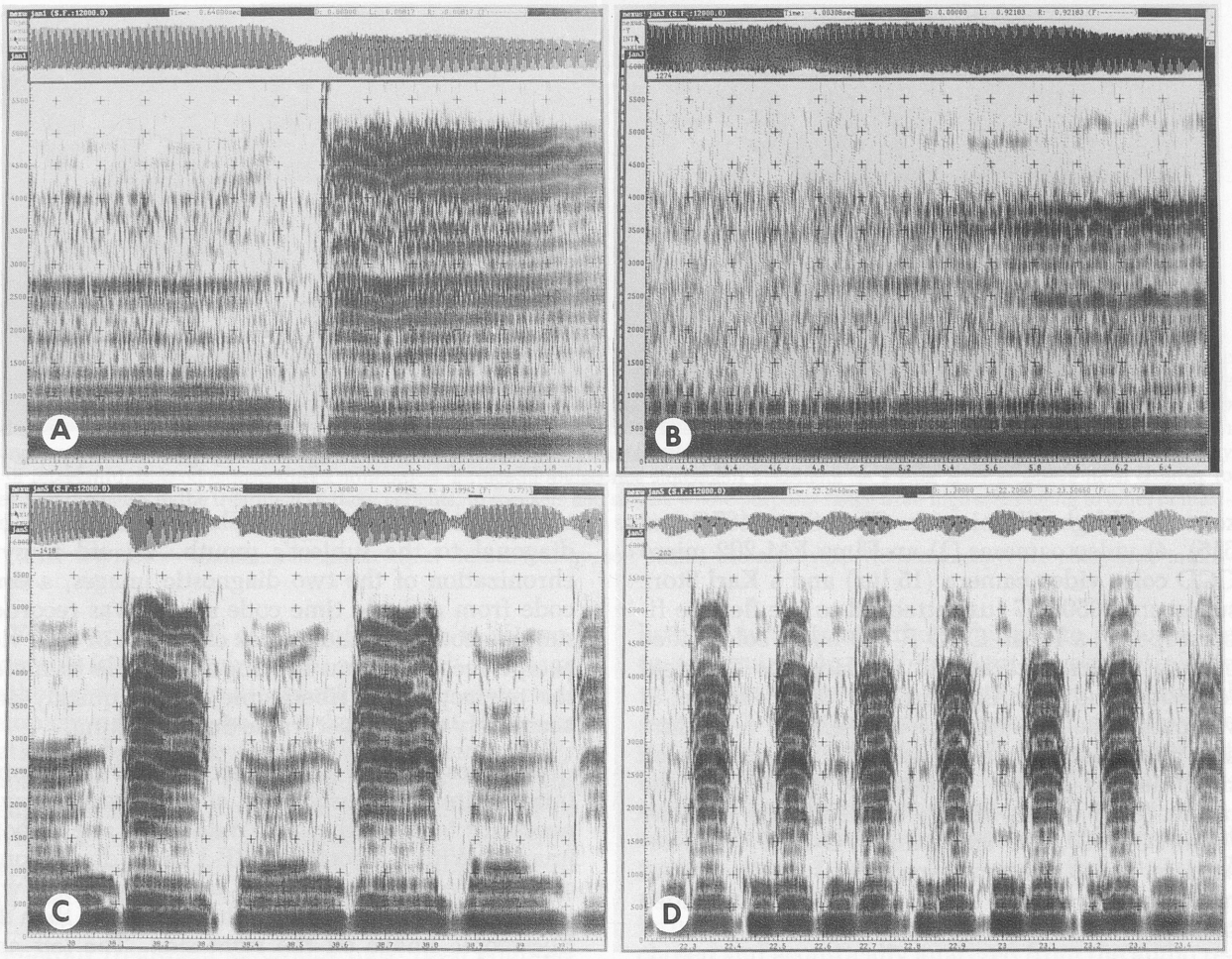

Fig 2. Acoustic analysis of tasks 1, 2, and 3. A) Spectrogram for task 1. Left side displays spectrogram for nasal "ng," and right side for non-nasal vowel /i/ as subject closed port sharply. Vertical dark midline at 1.3 seconds is moment of soft palate closure. B) Spectrogram for task 3. Subject controlled closure such that no aural perception of actual closure was evident, nor was there evidence of "voicebar" signifying production of /g/ or any burst of closure. Vertical axis on spectral prints represents acoustic energy up to 5,500 Hz, and horizontal axis represents time in seconds and milliseconds. Audio waveform is displayed horizontally at top of each spectral plate. C) Spectrogram for task 2. Subject alternately opened and closed VP port quickly. Closure or bursts occurred at 38.12, 38.63, and 39.12 seconds. D) Spectrogram for task 2. Subject alternately opened and closed VP port as quickly as possible. Subject made 5.4 complete cycles in 1 second, with closure occurring at 22.31, 22.5, 22.67, 22.86, 23.05, 23.22, and 23.42 seconds.

dB because the fan and other equipment noise in the laboratory resulted in roughly a 30-dB signal-to-noise ratio. Relative signal amplitudes across tasks are faithfully represented in the spectrographic figures. The scaling of the waveform plots at the top of the figures *do not* reflect relative amplitudes across tasks accurately.

PROTOCOL

The subjects were asked to perform the following tasks.

Task 1. Beginning with an "ng" sound, in which the velopharyngeal port is maximally open, the subject closes the velopharyngeal port sharply with a hard /gi/ so that the soft palate closes firmly against the posterior pharyngeal wall.

Task 2. The subject performs the opening and closing maneuver of task 1 as quickly as possible.

Task 3. The subject moves the soft palate as slowly as possible from an open nasal "ng" to a closed non-nasal /i/ position so that no sound of closure is heard.

Task 4. The subject performs a three-part maneuver beginning with a nasal "ng" and a totally open velopharyngeal port; he or she proceeds to a nasalized /i/ in which the velopharyngeal port is partially open, and ends with a totally closed port and a non-nasal vowel /i/. Then the figure is reversed.

Task 5. The subject constricts the larynx as in straining and then releases the constriction with the first pulse of a silent laugh (such that the vocal folds are maximally exposed as the false folds are retracted laterally). He or she holds the posture and the sensation of the silent laugh.

The Hopkins 70° rigid scope was used to examine the behavior of the soft palate in tasks 1 through 4 described above. Both the soft palate and the larynx

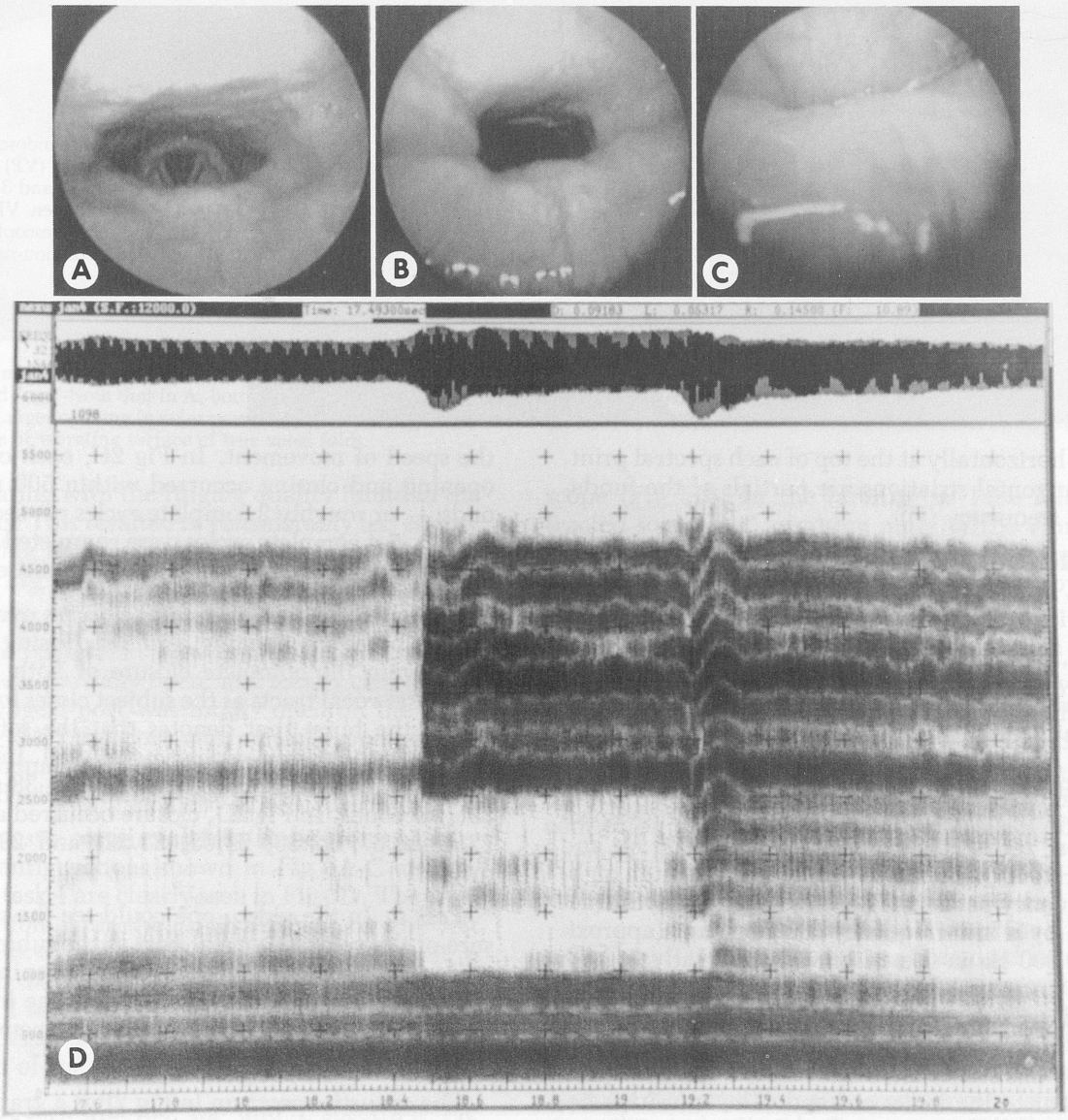

Fig 3. A-C) Velar videoendoscopic view of three VP port postures and D) their respective acoustic counterparts. Subject began with totally nasal "ng" (A) and proceeded to nasalized /i/ in which VP port is partially open and sound is being emitted orally as well as nasally (B). Task ends with non-nasal vowel /i/ in which VP port is totally closed (C). Three-part task is displayed acoustically, with spectrum divided into three separate segments by vertical markers ("bursts") signifying physiologic changes at 18.46 and 19.2 seconds.

were examined with the simultaneous velolaryngeal endoscopic procedure as the subjects performed task 5.

Because nasal measures are acoustically "nose-dependent" and because it is known that a sound can be perceived as non-nasal even with various degrees of velopharyngeal port opening, only samples with an endoscopically observable complete closure were accepted for acoustic analysis.

RESULTS

The video images of all patients who performed the tasks were studied. The results of those observations follow according to task.

Task 1. The velopharyngeal port was totally open as the subject made the nasal sound "ng" (Fig 4A), while the port was totally closed for the non-nasal vowel /i/ (Fig 4B).

In this task, the subject made a single abrupt transition from an "ng" (vocal tract was occluded by the base of tongue contacting the posterior palate; velopharyngeal port was open) to the vowel /i/ (oral tract was open, but partially constricted by the base of tongue; velopharyngeal port was closed). This maneuver resulted in a transitory complete closure of both oral and nasal passages resulting in an effective /g/ consonant production "voicebar" between 1.22 and 1.3 seconds on the acoustic spectrum (Fig 2A).

In all of the spectra presented, frequency is displayed on the vertical axis, and time (seconds) on the horizontal axis. The audio waveform is dis-

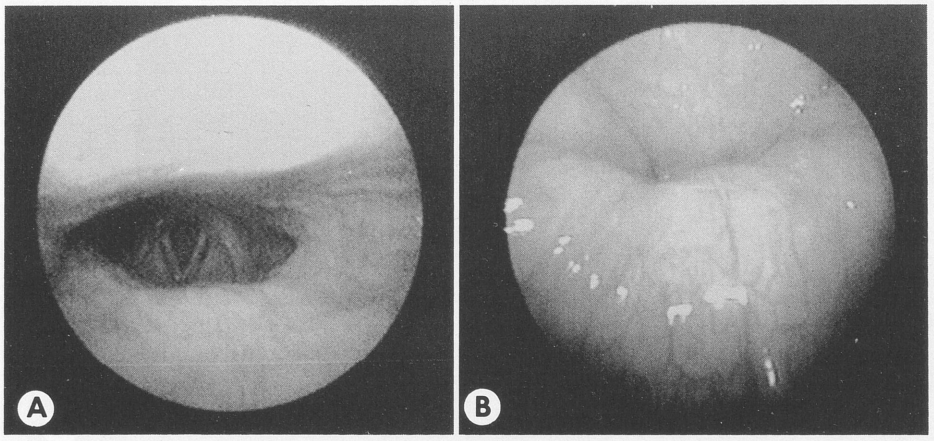

Fig 4. Velar videoendoscopic view of velopharyngeal (VP) port closure in tasks 1, 2, and 3. A) Telescopic view of open VP port on nasal "ng." B) Telescopic view of closed VP port on non-nasal vowel /i/ ("ee").

played horizontally at the top of each spectral print. The horizontal striations are partials of the fundamental frequency (F0).

The left side of the acoustic spectrum pictured in Fig 2A showed a sustained "ng" segment followed by a brief oral-nasal closure interval near the center and a sustained /i/ segment on the right of the figure. While nasal murmur spectra, such as the "ng" in these figures, are rather speaker- or nose-dependent generally, characteristic features were observed: 1) the presence of two resonances below 1,000 Hz (manifested as prominence of the first and third partials), 2) sharp dips in the amplitude spectrum or "zeros," clearly seen around 1,600 Hz and 3,000 Hz; and 3) relatively little energy in the higher-frequency partials. The /i/ was generally characterized by a low-frequency first formant (approximately 300 Hz in these figures) and relatively high second and third formants (at approximately 2,500 Hz and 3,400 Hz in these figures). Note that the relatively high energy in the region above 4,000 Hz seen for this subject was somewhat anomalous, but irrelevant to the issues at hand. The transition between "ng" and /i/ in tasks 1 and 2 (Fig 2A,C,D) resulted in the production of a /g/ with its attendant "voicebar" segment (seen in Fig 2A between 1.22 and 1.3 seconds) in which only the first partial was evident during the complete oral-nasal closure interval, followed by a broadband burst of noise (1.3 seconds) at the release of the interoral pressure by the tongue near the /i/ onset. (Note that the mottled background in the spectrum above 500 Hz during the "voicebar" was due to background noise in the laboratory.)

Task 2. In task 2, the subject alternated rapidly between the "ng" and /i/ oral-nasal configurations. Performing the same maneuver fast (Fig 2C,D) did not change the movements of the soft palate that were observed in the first task, as illustrated in Fig 4. The similarity of the spectra in the corresponding "ng" and /i/ segments of task 1 and task 2 in Fig 2C,D suggests that similar vocal-nasal configurations were attained independent of alternation rate. The difference between Fig 2C and Fig 2D was in the speed of movement. In Fig 2C, each complete opening and closing occurred within 500 milliseconds — or roughly 2 complete cycles per second. In Fig 2D, 5.4 complete cycles were completed in 1 second, or 1 complete cycle in about 185 milliseconds.

In Fig 2C the oral and nasal closures overlapped during both the opening and the closing phases. Note again the complete closure of both the oral and nasal vocal tracts as the subject closes for the /g/ before the burst that denotes that the soft palate contacted the posterior pharyngeal wall. In Fig 2C, bursts of closure occurred at 38.12, 38.63, and 39.12 seconds. In Fig 2D, closure occurred at 22.31, 22.5, 22.67, 22.86, 23.05, 23.22, and 23.42 seconds.

Task 3. In the video, one could see the slow closure of the velopharyngeal port as the subject gradually narrowed the velopharyngeal opening to the non-nasal /i/ at the end of the task. The images at the beginning and at the end of the maneuver were the same as those in Fig 4.

The acoustic spectrum in Fig 2B is a graphic representation of what was seen visually. As the subject made the slow, controlled transition from the "ng" to the /i/ position without producing any "clicks," the soft palate was raised from the lowered position for the "ng" to the closed position of the /i/ so slowly that a significant amount of time was spent with the port partly open, and there was no temporal overlap of the velar and oral closures for the /g/ (Fig 2A,C,D).

The acoustic spectra demonstrate that the subject in task 3 attained a graded transition from the "ng" to the /i/ (Fig 2B). The time scale of Fig 2B has been compressed by a factor of 2 compared to that of Fig 2A,C,D. The full "ng" configuration is represented at the left of the spectrogram, and the fully developed, non-nasalized /i/ is at the right. Note the absence of any "voicebar" related to complete oral-velar closure. The oral tract was open and in the /i/ configuration by about 5.2 seconds; the velar port reached full closure at about 6.1 seconds. During this relatively difficult maneuver, the subject was

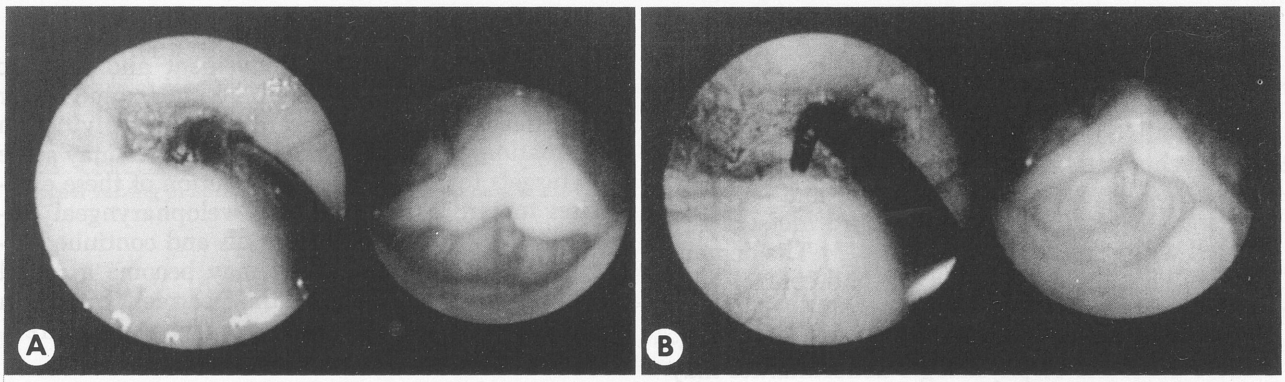

Fig 5. Simultaneous velolaryngeal endoscopic view of task 5. Shows laryngeal A) constriction and B) release as subject phonates on nasalized "ng." Note that in A, both VP port and larynx are constricted. In B, constriction in both VP port and larynx has been released. Larger opening in velar port in B exposes lower end of fiberscope. In larynx (B), false folds have retracted somewhat, exposing more of vibrating surface of true vocal folds.

not phonating with the ringing quality found in the other tasks. This resulted in considerably less energy in the higher partials throughout the interval represented in Fig 2B.

Task 4. In the fourth task, the subject moved the soft palate voluntarily into each of three positions: totally open, partially open, and totally closed. The velopharyngeal port was totally open on the nasal "ng" (Fig 3A), the port was partially open as the subject phonated a nasal /i/ (Fig 3B), and the port was closed with the non-nasal vowel /i/ (Fig 3C).

The acoustic correlates of the three discrete articulatory configurations shown in Fig 3A-C and required in task 4 are clearly seen in Fig 3D. The "ng" configuration with the "ng" segment on the left ended at 18.46 seconds; the nasalized /i/ segment in the center began at 18.46 seconds and ended at about 19.2 seconds. The full, non-nasalized /i/ on the right began at about 19.2 seconds and continued to the end of the phonation.

It can be seen that the "ng" and /i/ spectra in Fig 2A,C,D (tasks 1 and 2) compare favorably with the corresponding segments in Fig 3D (task 4). Note that the demands of an abrupt oral opening and an abrupt velopharyngeal closing both caused F0 perturbations (18.64 and 19.25 seconds) that took several tens of milliseconds for the subject to correct. That is, F0 only stabilized to its pretransitional value 100 milliseconds or more after the transition was initiated; this finding suggests central nervous system involvement in the F0 readjustment. The difference in the signal-to-noise ratio was attributed to the use of a different light source for which the noise level was significantly lower.

Task 5. Simultaneous endoscopic views of the soft palate and larynx demonstrated the constriction and release of the larynx (Fig 5). In the constricted condition (Fig 5A), both the soft palate and the larynx exhibited a narrowed aperture. When the constriction was released, the velopharyngeal port opened and exposed the lower end of the fiberscope (Fig 5B). In the larynx, the false folds retracted somewhat, exposing more of the vibrating true vocal folds. The aryepiglottic sphincter opened with the release of constriction, as observed by other investigators.[9]

No acoustic analyses were made of this task, since there were changes both in the velopharyngeal opening and in the laryngeal behavior, and though there may be differences in laryngeal behavior due to the condition of the velopharyngeal opening, the purpose of this study was to observe the voluntary control of the soft palate and the acoustic consequences thereof.

DISCUSSION

Many different methods have been used for documenting the soft palate in normal and in pathologic states. These methods include airflow studies, nasal listening devices and nasal flutter tests,[1,3,4,10] fiberscopic and telescopic endoscopy,[7,8,11-21] electromyography,[22,23] cephalometric radiography studies,[24] cineradiography,[25] videofluoroscopy,[19,26-28] tomography,[16] cine-computed tomography,[16,29] and magnetic resonance imaging.[30]

The advantage of telescopic velar videoendoscopy is that it delivers a high-quality view of the soft palate from above and often includes the behavior of the larynx below as seen through the wide-open velopharyngeal port. It allows a clear documentation of opening and closing of the soft palate, especially fine, delicate movements of the soft palate during its closure. The advantage of simultaneous velolaryngeal videoendoscopy is that it combines this view of the soft palate with a simultaneous view of the larynx and pharyngeal walls. This simultaneous view allows observation of complex maneuvers involving the interaction of the larynx and soft palate in producing sounds.

Among voice scientists and speech-language pathologists there have been a number of studies concerning evaluation of velopharyngeal closure and

the modification of velar incompetence through training procedures. Both direct and indirect methods of palatal training have been prescribed for patients with velopharyngeal insufficiency. However, because of the conflicting results of studies using these techniques, palate training methods are considered to be generally experimental and most patients with velopharyngeal closure defects are treated with prosthetics or surgery.[1,2,9] The demonstration of soft palate movement and control with palatal exercises may be of interest to medical and voice professionals. An individual with no demonstrable anatomic or physiologic abnormalities may sometimes speak with a hypernasal voice quality. For that individual, our results suggest that palatal training exercises may remedy his problem. In addition, actors, singers, and public speakers often need to change their voice quality for interpretive purposes. If they can learn to control the movements of the soft palate that make some of these changes, they might be able to perform with more confidence.

Correlation of palatal movement and acoustic spectra has proven to be useful to understand better the effect of voluntary control of velar activities on phonation. Patterns of acoustic analyses may serve as targets for the successful execution of these exercises toward a more efficient velopharyngeal closure. With further clinical trials and continued research, soft palate training may become a useful and effective alternative in the treatment of certain patients with insufficient velopharyngeal closure.

SUMMARY

Both telescopic velar and simultaneous telescopic-fiberscopic velolaryngeal videoendoscopy have proven to be useful in showing the degree of voluntary control of the soft palate. This study documents the ability of normal subjects, both amateurs and voice professionals, to make voluntary, discrete movements of the soft palate after a short period of training.

REFERENCES

1. Ruscello DM. Modifying velopharyngeal closure through training procedures. In: Bzoch KR, ed. Communicative disorders related to cleft lip and palate. 3rd ed. Boston, Mass: College-Hill Press, 1989:338-49.

2. Shelton RL. Oral sensory function in speech production and remediation. In: Bzoch KR, ed. Communicative disorders related to cleft lip and palate. 3rd ed. Boston, Mass: College-Hill Press, 1989:290-312.

3. Shprintzen RJ. Research revisited. Cleft Palate J 1989;26: 148-9.

4. Shprintzen RJ, McCall GN, Skolnick ML. A new therapeutic technique for the treatment of velopharyngeal incompetence. J Speech Hear Disord 1975;40:69-83.

5. McWilliams BJ, Morris HL, Shelton RL. Treatment of VPI. In: McWilliams BJ, Morris HL, Shelton RL. Cleft palate speech. Philadelphia, Pa: BC Decker, 1990:401-18.

6. Estill J. A model for subjects in voice research. Proceedings, International Conference on Voice. Satellite meeting of XXth Congress of IALP, Kurume, Japan, 1986;1:58-69.

7. Yanagisawa E, Kmucha ST, Estill J. Role of the soft palate in laryngeal functions and selected voice qualities. Simultaneous velolaryngeal videoendoscopy. Ann Otol Rhinol Laryngol 1990; 99:18-28.

8. Yanagisawa E, Estill J, Mambrino L, Talkin D. Supraglottic contribution to pitch raising. Videoendoscopic study with spectroanalysis. Ann Otol Rhinol Laryngol 1991;100:19-30.

9. Kmucha ST, Yanagisawa E, Estill J. Endolaryngeal changes during high-intensity phonation. Videolaryngoscopic observations. J Voice 1990;4:346-54.

10. Case JL. Clinical management of voice disorders. Rockville, Md: Aspen System Corp, 1984.

11. Skolnick ML, McCall GN, Barnes M. The sphincteric mechanism of velopharyngeal closure. Cleft Palate J 1973;10: 286-305.

12. Gilbert STJ, Pigott RW. The feasibility of nasal pharyngoscopy using the 70 degree Storz-Hopkins nasopharyngoscope. Br J Plast Surg 1982;35:14-8.

13. David DJ, White J, Sprod R, Bagnall A. Nasendoscopy: significant refinements of a direct-viewing technique of the velopharyngeal sphincter. Plast Reconstr Surg 1982;70:423-8.

14. Siegel-Sadewitz VL, Shprintzen RJ. Nasopharyngoscopy of the normal velopharyngeal sphincter: an experiment of biofeedback. Cleft Palate J 1982;19:194-200.

15. Karnell MP, Ibuki K, Morris HL, Van Demark DR. Reliability of the nasopharyngeal fiberscope (NPF) for assessing velopharyngeal function: analysis by judgment. Cleft Palate J 1983; 20:199-208.

16. Honjo I, Mitoma T, Ushiro K, Kawano M. Evaluation of velopharyngeal closure by CT scan and endoscopy. Plast Reconstr Surg 1984;74:620-7.

17. Karnell MP, Morris HL. Multiview videoendoscopic evaluation of velopharyngeal physiology in 15 normal speakers. Ann Otol Rhinol Laryngol 1985;94:361-5.

18. D'Antonio LL, Marsh JL, Province MA, Muntz HR, Phillips CJ. Reliability of flexible fiberoptic nasopharyngoscopy for evaluation of velopharyngeal function in a clinical population. Cleft Palate J 1989;26:217-25.

19. Shprintzen RJ. Nasopharyngoscopy. In: Bzoch KR, ed. Communicative disorders related to cleft lip and palate. 3rd ed. Boston, Mass: College-Hill Press, 1989:211-29.

20. Witzel MA, Posnick JC. Patterns and location of velopharyngeal valving problems: a typical finding on video nasopharyngoscopy. Cleft Palate J 1989;26:63-7.

21. Yanagisawa E, Isaacson G, Kmucha ST, Hirokawa R. Video nasopharyngoscopy: a comparison of fiberscopic, telescopic, and microscopic documentation. Ann Otol Rhinol Laryngol 1989;98:15-20.

22. Lubker J. An electromyographic-cinefluorographic investigation of velar function during normal speech production. Cleft Palate J 1968;5:1-18.

23. Kuehn DP, Folkins JW, Cutting CB. Relationships between muscle activity and velar position. Cleft Palate J 1982;19: 25-35.

24. Simpson RK, Colton J. A cephalometric study of velar stretch in adolescent subjects. Cleft Palate J 1980;17:40-7.

25. Astley R. The movements of the lateral walls of the nasopharynx: a cineradiographic study. J Laryngol Otol 1958;72: 325-8.

26. Shprintzen RJ, Lencione RM, McCall GN, Skolnick ML. A three dimensional cinefluoroscopic analysis of velopharyngeal clo-

sure during speech and nonspeech activities in normals. Cleft Palate J 1974;11:412-28.

27. Skolnick ML. Video velopharyngography in patients with nasal speech, with emphasis on lateral pharyngeal motion in velopharyngeal closure. Radiology 1969;93:747-55.

28. Croft CB, Shprintzen RJ, Rakoff SJ. Patterns of velopharyngeal valving in normal and cleft palate subjects: a multi-view videofluoroscopic and nasendoscopic study. Laryngoscope 1981; 91:265-71.

29. Moon JB, Smith WL. Application of cine computed tomography to the assessment of velopharyngeal form and function. Cleft Palate J 1987;24:226-32.

30. Lufkin RB, Wortham DG, Dietrich RB, et al. Tongue and oropharynx: findings on MR imaging. Radiology 1986;161:69-75.

NONINVASIVE TECHNIQUE FOR ESTIMATING SUBGLOTTIC PRESSURE AND LARYNGEAL EFFICIENCY

MICHAEL C. BARD, MD
ROCHESTER, MINNESOTA
THOMAS V. MCCAFFREY, MD, PHD
ROCHESTER, MINNESOTA
DAVID H. SLAVIT, MD
BROOKLYN, NEW YORK
RICHARD J. LIPTON, MD
DANBURY, CONNECTICUT

The clinical assessment of aerodynamic parameters is important in the physiology and pathophysiology of laryngeal function. Vocal efficiency is among these objective measurements and can be calculated from simultaneous recordings of subglottic pressure, airflow, and sound intensity. Modern techniques allow us to accurately determine sound intensity and airflow. However, methods to determine subglottic pressure are either invasive or laborious. We have evaluated a noninvasive, indirect method to determine subglottic pressure by using a technique based on the interruption of transglottic airflow during phonation. The correlation between the indirectly acquired subglottic pressure measured in the oral cavity by using this technique and the subglottic pressure obtained directly by translaryngeal puncture in human volunteers was highly significant in 35 trials ($r = .92$, $p < .01$). This study describes a reliable technique for the noninvasive measurement of subglottic pressure, sound intensity, and airflow.

KEY WORDS — subglottic pressure, vocal efficiency, vocal physiology, voice production measurement.

INTRODUCTION

Clinical assessment of aerodynamic parameters at the larynx is essential to obtaining an understanding of the physiology and pathophysiology of voice production. The larynx acts as a transducer, converting aerodynamic power from the lungs into acoustic power. The efficiency of this conversion is one of several objective measurements of laryngeal function. It can be expressed by the ratio of acoustic power (sound intensity) to aerodynamic power (subglottic pressure multiplied by airflow).[1]

Modern techniques allow us to determine airflow and sound intensity accurately. However, it is more cumbersome to assess subglottic pressure. The following methods are available.

1. Percutaneous catheter: a needle or catheter, to which a pressure transducer is connected, is placed through the cricothyroid membrane into the subglottis. This direct technique accurately measures subglottic pressure. However, it is invasive, is uncomfortable to the subject, and exposes him or her to certain risks involved with catheter placement.

2. Translaryngeal catheter: a small transducer or a catheter attached to a transducer is placed across the anesthetized larynx from the nasopharynx. The catheter itself and the anesthesia of the mucosa interfere with normal phonation, thereby potentially affecting the accuracy of this technique.

3. Intraesophageal catheter: the subject swallows an air balloon attached to a tube. The pressure inside the balloon is recorded through the tube. The subglottic pressure is calculated from esophageal pressure when lung volumes are held constant.[2,3] This is time-consuming because it is necessary to record lung volumes and perform elaborate calibrations when body plethysmography is used.

All of these methods are invasive and pose significant logistical problems in a clinical setting. An alternative noninvasive technique has been developed for routine clinical measurement of subglottic pressure.[4,5] This technique (the airway interruption method) was adapted from methods used to measure alveolar pressure in pulmonary laboratories.[6] Its conceptual development is based in general fluid dynamics theory, which states that estimation of upstream pressure-flow relationships can be made by downstream pressure-flow measurements under certain conditions. Application of this theory to the air-filled phonatory system implies that under certain conditions, measurements obtained at the mouth can be used to estimate laryngeal pressure-flow relationships.[5]

One of these conditions is met during the closure period of voiceless stops.[7] When the airstream of a vowel is interrupted by the closure of the lips, the glottis is open and translaryngeal pressure equilibrates with oral cavity pressure. Using this concept, Smitheran and Hixon[5] developed utterances that met this condition in a clinical setting. Subjects were asked to phonate the syllable /pi/ in one train of

From the Department of Otolaryngology, Mayo Clinic and Mayo Foundation, Rochester, Minnesota.
Presented at the meeting of the American Laryngological Association, Waikoloa, Hawaii, May 4-5, 1991.

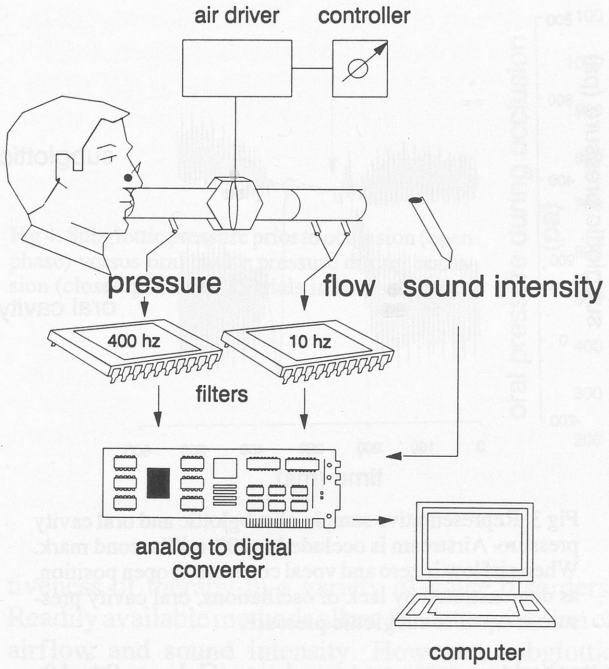

Fig 1. Schematic diagram of device used in this study.

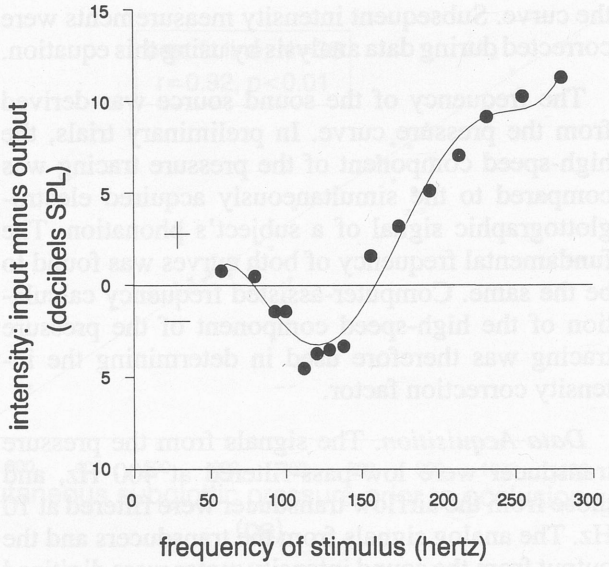

Fig 2. Sound intensity alteration of device as function of frequency. Value derived from y axis was added to measured sound intensity to correct for resonance characteristics of device at given fundamental frequency of sound source.

several repetitions. Pressure in the oral cavity was measured during the closure period (/p/). Airflow was measured during the open period (/i/). Interpolation of the oral pressure during the closed phase was taken to represent prevailing subglottic pressure during the open phase when airflow was measured. Löfquist et al[8] showed that this indirect technique closely estimates subglottic pressure (r = .92).

Using a similar concept, Sawashima et al[6] developed a tubular device that measures airflow, subglottic pressure, and sound intensity. With the mouthpiece held tightly at the lips, a mechanical shutter was used to interrupt the airflow during vowel production. The period when the shutter was closed is analogous to the closure period (/p/) in the preceding study.

The purpose of this study was to develop a similar device that could be used noninvasively to measure airflow, sound intensity, subglottic pressure, and frequency. Instead of a shutter, an air-driven balloon occluder was used. The resonance characteristics of the device were determined to correct the sound intensity calculations. This device can be constructed readily and provides a reliable way to calculate vocal efficiency and other aerodynamic parameters.

MATERIALS AND METHODS

Device. A schematic diagram of the device is shown in Fig 1. A disposable cardboard mouthpiece was attached to the balloon valve (Hans Rudolph inflatable balloon type 8250). A catheter attached to a pressure transducer (Celesco 0 to 10 cm H_2O, model LCVR) was connected between the mouthpiece and the balloon. A Fleisch-type pneumotachometer attached to a differential pressure transducer (Celesco 0 to 2 cm H_2O, model LCVR) was connected to the device distal to the balloon. The microphone of a Larson-Davis sound level meter was attached at the opening of the pneumotachometer. The balloon was connected to an automatic controller (Hans Rudolph controller 2430 series). The driver was regulated by a hand-held device that is able to vary the duration of balloon closure. The balloon valve, pneumotachometer, and microphone were attached to a hard plastic frame connected to a handpiece.

Sound Intensity Calculation. The sound from the end of the flowmeter was assumed to emanate in the fashion of a pulsating hemisphere. The microphone was attached 1 cm from the source and out of the airstream. Thus, intensity at the opening of the device (watts) was calculated to be

$$I = 10^{dB\ SPL/10} \times 10^{-12}(W/m^2) \times 2 \times \pi \times R^2$$

where R is the distance (meters) of the microphone to the sound source and dB SPL (decibels sound pressure level) is the sound intensity at the microphone. To calculate the intensity attenuation of the device, a sound source of known intensity was placed at the mouthpiece. The intensity of the sound output at the mouthpiece was measured. A correction factor (sound input minus output) for different frequencies was calculated and plotted as a function of frequency (Fig 2). A fifth-degree polynomial equation was fitted to

the curve. Subsequent intensity measurements were corrected during data analysis by using this equation.

The frequency of the sound source was derived from the pressure curve. In preliminary trials, the high-speed component of the pressure tracing was compared to the simultaneously acquired electroglottographic signal of a subject's phonation. The fundamental frequency of both curves was found to be the same. Computer-assisted frequency calculation of the high-speed component of the pressure tracing was therefore used in determining the intensity correction factor.

Data Acquisition. The signals from the pressure transducer were low-pass-filtered at 400 Hz, and those from the airflow transducer were filtered at 10 Hz. The analog signals from the transducers and the output from the sound intensity meter were digitized at 500 Hz by using an analog to digital converter. ASYSTANT II software was used to sample and analyze the data. Signals were acquired for 10-second periods and saved for later analysis.

Calibration. The pressure transducers were calibrated with a water manometer (300 Pa = 2 V). Airflow was calibrated with a Lab Crest airflow meter (100 mL/s = 1 V). Sound intensity was calibrated according to manufacturer instructions (Larson-Davis) by using a sound source specifically designed for this purpose.

Subjects. Six male and three female volunteers were used in this study. Ages ranged from 26 to 42 years (mean = 32). The subjects denied any history of smoking, laryngeal trauma or surgery, recent upper respiratory tract infection, or recent intubations. A total of 285 data points was obtained from the nine subjects.

Trials. Each subject was asked to place his or her mouth tightly around the mouthpiece. A nose clip was used to stop any air from escaping from the nares. The subjects were instructed to phonate /i/ into the device. They were instructed to maintain a constant pitch and intensity and not to push against the balloon when it was closed. Data were acquired at different pitches and intensities within the chest register. At random intervals during the phonation, the balloon was closed for 150 milliseconds. The optimal duration of the closure period was determined in preliminary trials.

Subglottic Pressure Measurement. In two male volunteers, percutaneous subglottic pressure was simultaneously recorded as well. Subglottic pressure was measured by using an 18-gauge needle placed through the cricothyroid membrane. The needle was attached to a pressure transducer (Celesco 0 to 10 cm H_2O, model LCVR). The signals were digitized and sampled at 500 Hz. During this part of the experiment, no filter was used for either the subglottic or oral cavity pressure signals. Thirty-five data points were obtained.

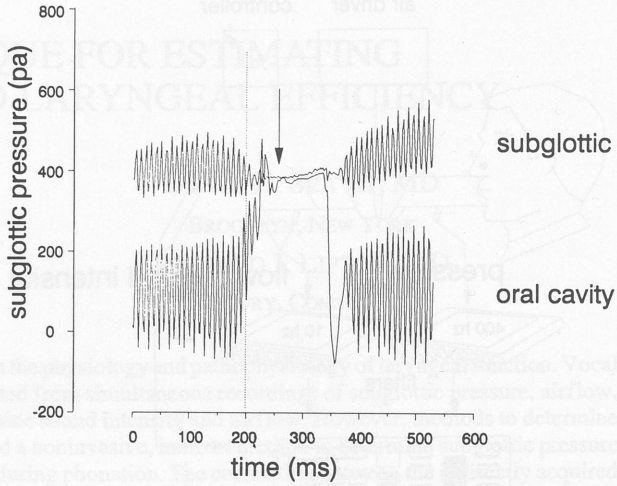

Fig 3. Representative sample of subglottic and oral cavity pressure. Airstream is occluded at 200-millisecond mark. When airflow is zero and vocal cords are in open position, as demonstrated by lack of oscillations, oral cavity pressure is equal to subglottic pressure.

RESULTS

Figure 3 shows the relationship between percutaneous subglottic pressure and oral cavity pressure. At the start of the plateau it is evident that these two pressures are almost the same. The correlation between subglottic pressure prior to occlusion and oral cavity pressure during occlusion was high (Fig 4). A representative example of airflow, intensity, and pressure is shown in Fig 5. Average airflow, sound intensity, and fundamental frequency and the intensity correction factor based on fundamental frequency were calculated during the segment prior to occlusion. Subglottic pressure was determined at the beginning of the plateau of the pressure curve during occlusion, which is shown by the arrow. The Table shows the averages and ranges of pressure, airflow, sound intensity, and laryngeal efficiency in 285 trials in nine subjects.

DISCUSSION

The measurement of aerodynamic parameters is important when studying the physiology and pathophysiology of the larynx. Vocal efficiency, one objective measure of laryngeal function, is determined from simultaneous measurements of airflow, sound intensity, and subglottic pressure. It has been used as part of a battery of clinical tests to assess the effec-

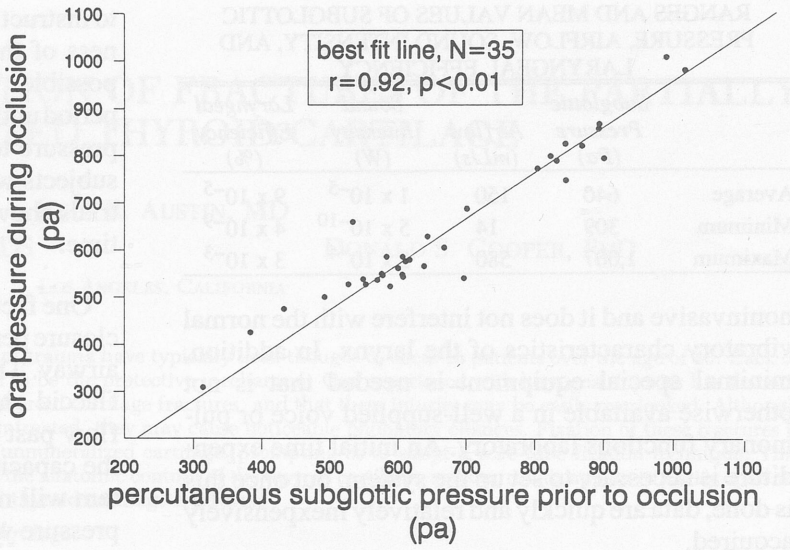

Fig 4. Subglottic pressure prior to occlusion (open phase) versus oral cavity pressure during occlusion (closed phase) in 35 trials in two subjects.

tiveness of therapy in a variety of voice disorders. Readily available methods allow for determination of airflow and sound intensity. However, subglottic pressure is more difficult to obtain because many of the techniques are invasive, require elaborate calibration, or interfere with the normal vibratory characteristics of the larynx. For this reason, we investigated a noninvasive technique to measure subglottic pressure, airflow, sound intensity, and frequency simultaneously.

The results of this study validate the premise of the airway interruption technique: the pressure obtained during the closed phase represents prevailing translaryngeal pressure during the open phase. It was shown that the oral cavity pressure during airway interruption highly correlated with percutaneous subglottic pressure during phonation. Thus, this method provides an accurate and reliable way to determine subglottic pressure indirectly.

Airflow and sound intensity are also measured by the device investigated in this study. The values correspond well with those in the literature. In his thesis about vocal efficiency, Schutte[2] reviewed more than 20 studies. Subglottic pressure ranged from 0.275 to 25 kPa and airflow from 4 to 480 mL/s. In his own experiment, efficiency ranged from 10^{-2} to 10^{-7}. In the present study, similar results were obtained (see Table).

The advantages of this method are that it is

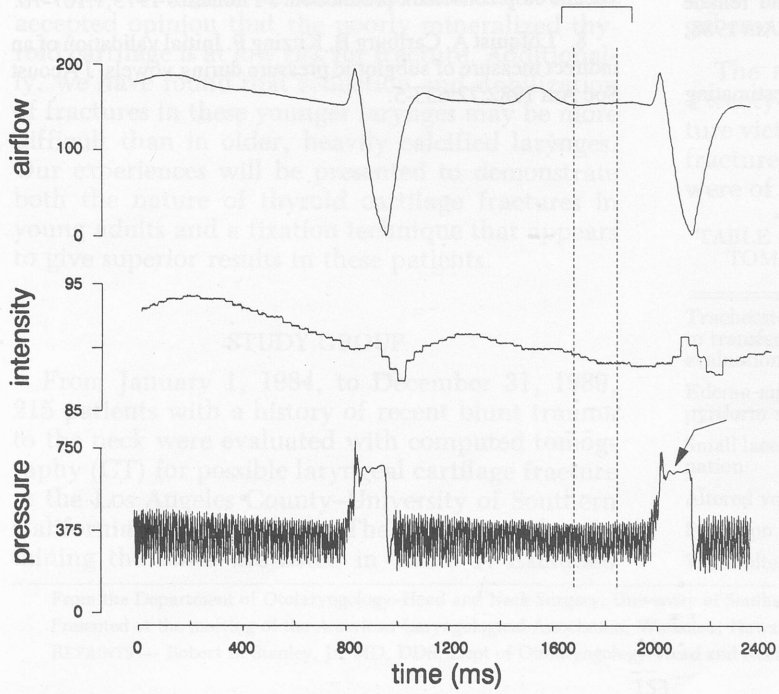

Fig 5. Representative sample of simultaneously acquired oral cavity pressure (pascals), airflow (milliliters per second), and sound intensity (decibels). Airflow, intensity, and frequency were measured during segment prior to occlusion of balloon (brackets). Subglottic pressure was measured at beginning of plateau (arrow).

RANGES AND MEAN VALUES OF SUBGLOTTIC PRESSURE, AIRFLOW, SOUND INTENSITY, AND LARYNGEAL EFFICIENCY

	Subglottic Pressure (Pa)	*Airflow (mL/s)*	*Sound Intensity (W)*	*Laryngeal Efficiency (%)*
Average	640	150	1×10^{-5}	9×10^{-5}
Minimum	309	14	5×10^{-10}	4×10^{-9}
Maximum	1,007	580	3×10^{-4}	3×10^{-3}

noninvasive and it does not interfere with the normal vibratory characteristics of the larynx. In addition, minimal special equipment is needed that is not otherwise available in a well-supplied voice or pulmonary functions laboratory. An initial time expenditure is necessary to set up the system, but once this is done, data are quickly and relatively inexpensively acquired.

The disadvantage of this technique is that it requires a significant amount of subject compliance and cooperation. In order for the premise of the airway interruption method to be supported, the subject must not alter phonation during the closure period. However, the natural tendency was for the subjects to push against the balloon. It was necessary to instruct them to avoid this. To minimize the awareness of the closure period, it was made as brief as possible. This was done by adjusting the closure period until it was long enough to allow translaryngeal pressure to equilibrate but short enough so that the subjects would not react to the closure. Preliminary trials showed that 150 milliseconds was the optimal time.

One factor that affected the optimal duration of the closure period was the capacitance of the supraglottic airway. Theoretically, if the capacitance is high (eg, flaccid cheeks or pharynx) the air will continue to flow past the larynx during the closure period until the capacitance is reached. This means that the system will not be in a steady state and the oral cavity pressure will not equal subglottic pressure. In some subjects, presumably because of higher capacitance, the closure period was increased to 200 milliseconds to allow enough time for the pressures to equilibrate. To help decrease the capacitance of their upper aerodigestive tracts, these subjects were instructed to maintain a pursed embouchure on the mouthpiece. With these directions, almost all of the pressures could then be measured within 150 milliseconds.

REFERENCES

1. Van den Berg J. Direct and indirect determination of the mean subglottic pressure. Folia Phoniatr (Basel) 1956;8:1-24.

2. Schutte HK. The efficiency of voice production. Groningen, the Netherlands: Kemper, 1981.

3. Kunze L. Evaluation of methods estimating subglottic air pressure. J Speech Hear Res 1964;7:151-64.

4. Holmberg E, Hillman R, Perkell J. Glottal air flow. Transglottal air pressure measurements for male and female speakers in soft, normal and loud voice. J Acoust Soc Am 1988; 84:511-29.

5. Smitheran J, Hixon T. A clinical method for estimating laryngeal airway resistance during vowel production. J Speech Hear Disord 1981;46:138-46.

6. Sawashima M, Kiritani S, Sekimoto S, Horiguchi S, Okafuji K, Shirai K. The airway interruption technique for measuring expiratory air pressure during phonation. Annu Bull RILP 1983;17:23-32.

7. Shipp T. Intraoral air pressure and lip occlusion and mid vocalic stop consonant production. J Phonetics 1973;1:167-70.

8. Löfquist A, Carlburg B, Kitzing P. Initial validation of an indirect measure of subglottic pressure during vowels. J Acoust Soc Am 1982;72:633-5.

STABLE INTERNAL FIXATION OF FRACTURES OF THE PARTIALLY MINERALIZED THYROID CARTILAGE

JOHN R. AUSTIN, MD
ROBERT B. STANLEY, MD, DDS
DONALD S. COOPER, PHD
LOS ANGELES, CALIFORNIA

Thyroid cartilage fractures due to external blunt trauma have typically been thought to occur in patients over the age of 40. Lack of mineralization of the cartilage has been considered to be the protective mechanism. Our experience with laryngeal injuries has demonstrated that younger persons are indeed at risk for thyroid cartilage fractures, and that these injuries may be easily overlooked. Although these fractures do not lead to laryngeal stenosis if untreated, they may cause noticeable phonatory changes. Fixation of these fractures is difficult because of the usual soft character of the unmineralized cartilage, prompting us to adopt a wire-tube fixation technique. This technique has been uniformly successful in restoring the anatomic contour of the thyroid cartilage, and our results appear to justify open reduction of these moderately displaced or angulated thyroid cartilage fractures.

KEY WORDS — fixation, fracture, thyroid cartilage.

Fractures of the thyroid cartilage have traditionally been described as occurring most often in individuals over the age of 40.[1,2] In childhood, the poorly mineralized thyroid cartilage appears to be protected from injury by its inherent flexibility and pliability.[3,4] These protective characteristics are thought to persist even into the third and fourth decades of life, and Yerman et al[5] have confirmed that calcification is not present in the thyroid cartilage until the age of 20. The mineralization process then begins at the posterior and inferior borders of each lamina and progresses superiorly in an unpredictable manner. The progression may be bilaterally asymmetric and the central lamina may be spared completely. Our recent experience with laryngeal injuries due to external blunt trauma has allowed us to make in vivo observations that paradoxically confirm the postmortem findings of Yerman et al and disprove the accepted opinion that the poorly mineralized thyroid cartilage is at low risk for fracture. Additionally, we have found that reduction and stabilization of fractures in these younger larynges may be more difficult than in older, heavily calcified larynges. Our experiences will be presented to demonstrate both the nature of thyroid cartilage fractures in young adults and a fixation technique that appears to give superior results in these patients.

STUDY GROUP

From January 1, 1984, to December 31, 1989, 215 patients with a history of recent blunt trauma to the neck were evaluated with computed tomography (CT) for possible laryngeal cartilage fracture at the Los Angeles County–University of Southern California Medical Center. The indications for obtaining the scans are listed in Table 1. Excluded from the study, therefore, were patients who suffered severe disruption of the laryngeal framework and internal soft tissues (thus requiring emergent tracheostomy and neck exploration) due to ultrahigh-speed deceleration impact forces that would crush even the most resilient of cartilaginous structures. Also excluded were patients with a suspected laryngeal injury who were taken emergently to the operating room for care of other life-threatening problems. Typically, these patients underwent direct endoscopic evaluation and neck exploration during the same session of general anesthesia. The study group therefore includes patients with a "suspected" laryngeal fracture, and admittedly includes some patients who fall well within the criteria established by some trauma surgeons[6,7] for mandatory exploration and some patients whose further evaluation was prompted only by the current medicolegal environment.

The results are summarized in Tables 2 and 3. Twenty-three (52%) of the total group of 44 fracture victims were 30 years of age or younger. Of the fractures that occurred in this younger subgroup, 18 were of the thyroid cartilage, 3 of the cricoid carti-

TABLE 1. INDICATIONS FOR OBTAINING COMPUTED TOMOGRAPHIC SCAN OF LARYNX FOLLOWING BLUNT NECK TRAUMA

Tracheostomy performed at another facility for stabilization prior to transfer, or by resident staff to protect airway prior to further evaluation
Edema and/or hematoma or ecchymosis visible in endolarynx or pyriform sinus on indirect examination
Small lacerations or blood visible in endolarynx on indirect examination
Altered vocal cord mobility
Palpation of external landmarks suspicious for fracture
Voice alterations noted by examiner or claimed by patient

From the Department of Otolaryngology–Head and Neck Surgery, University of Southern California School of Medicine, Los Angeles, California.
Presented at the meeting of the American Laryngological Association, Waikoloa, Hawaii, May 4-5, 1991.
REPRINTS — Robert B. Stanley, Jr, MD, DDS, Dept of Otolaryngology–Head and Neck Surgery, 1200 N State St, Box 795, Los Angeles, CA 90033.

TABLE 2. AGE DISTRIBUTION OF PATIENTS EVALUATED FOR SUSPECTED LARYNGEAL INJURY

	No.	Average Age (y)	Age Range (y)
Patients evaluated	215	30.4	4-65
Patients with fractures	44	29.5	16-53

lage, and 2 of both cartilages. Among the patients in this group with a fracture of the thyroid cartilage (with or without a cricoid cartilage fracture), none had derangement of the glottic and/or supraglottic soft tissues deemed severe enough to warrant thyrotomy and repair. None of the thyroid cartilage fractures in this group were comminuted, but rather most were moderately displaced or angulated single linear fractures that would not be expected to lead to acute airway obstruction or chronic laryngeal stenosis. However, we have developed an aggressive management philosophy for these types of injuries, based on previous clinical and laboratory observations.[8,9] These studies showed that even minimally displaced or angulated fractures of the thyroid laminae can produce alterations in the glottic configuration sufficient to disrupt the normal laryngeal valving mechanism. These changes produce increases or decreases in glottic resistance, dependent on the orientation of the displaced cartilage segments, and thus may produce noticeable if not debilitating phonatory disorders.

Once this aggressive policy was adopted, we were faced with the realization that standard reduction and fixation techniques using stainless steel wires or nonabsorbable sutures placed in a simple or figure-eight pattern were inadequate for holding a reduction. Although edge-to-edge contact could be maintained between the fragments, healed lateral fragments tended to be angulated and healed midline fractures tended to be flattened (as seen on postoperative CT scans). Overtightening of the wires in an attempt to hold the reduction invariably caused the wires to cut through the poorly mineralized cartilage. Similarly, the use of miniadaptation plates and screws from the maxillofacial trauma armamentarium failed to produce acceptable results when used on the soft cartilage.

TABLE 3. SITE OF LARYNGEAL CARTILAGE FRACTURE BY AGE (44 PATIENTS)

	Age (y)					
Cartilage	0-10	11-20	21-30	31-40	>40	Total
Thyroid	0	6	12	8	4	30
Cricoid	0	1	2	4	2	9
Thyroid and cricoid	0	0	2	2	1	5

We now use a technique that splints the fractures with fine wires passed through the lumina of blunted needles that are placed as battens to span the fractures. Occasionally, temporary translaryngeal wires will be used to reduce a severely flattened angle between the lateral laminae when a midline fracture is present. The technique is schematically demonstrated in Figs 1 and 2, and will also be demonstrated clinically in the following case reports. It has been successfully used in seven patients, and the success and ease with which it has been used have prompted us to apply it to all thyroid cartilage fractures, even comminuted injuries in older, more mineralized larynges.

CASE REPORTS

Case 1. A 28-year-old man suffered blunt neck trauma in a motor vehicle accident. He presented with acute dysphonia, mild endolaryngeal edema, and a hematoma in the right vocal cord. No lacerations of the mucosa were noted. He was started on a regimen of steroids and antibiotics, but 12 hours later the edema was felt to be sufficient to warrant securing of the airway with a tracheostomy. A CT scan revealed a displaced fracture of the right thyroid lamina (Fig 3A), and 2 days later the fracture was repaired by the technique shown in Fig 1. The patient was decannulated rapidly and he obtained an excellent voice that allowed him to return to singing in his church choir, although he did complain of occasional difficulty reaching high tones while singing. The reduced fracture is shown on a follow-up scan in Fig 3B.

Case 2. A 30-year-old male musician and singer was strangled with a forearm choke-hold. He presented with a complaint of a weak breathy voice

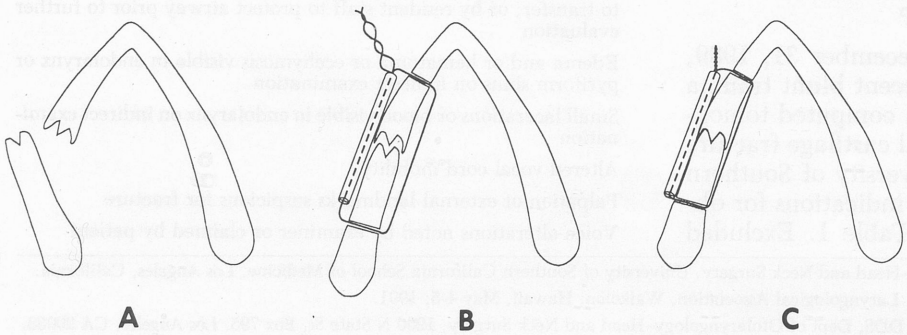

Fig 1. Schematic drawing of wire-tube technique. A) Displaced lateral lamina fracture. B) Wire passed through blunted 18-gauge needle and through cartilage in horizontal fashion. Wire and tube will remain in place permanently; therefore, endolaryngeal aspect of wire must be passed submucosally. C) Although wire may cut through cartilage immediately adjacent to needle hole, forces are distributed over broad enough area to prevent complete pull-through of wire. For lateral fracture, two wire-tube devices should be placed, one above and one below level of true vocal cord.

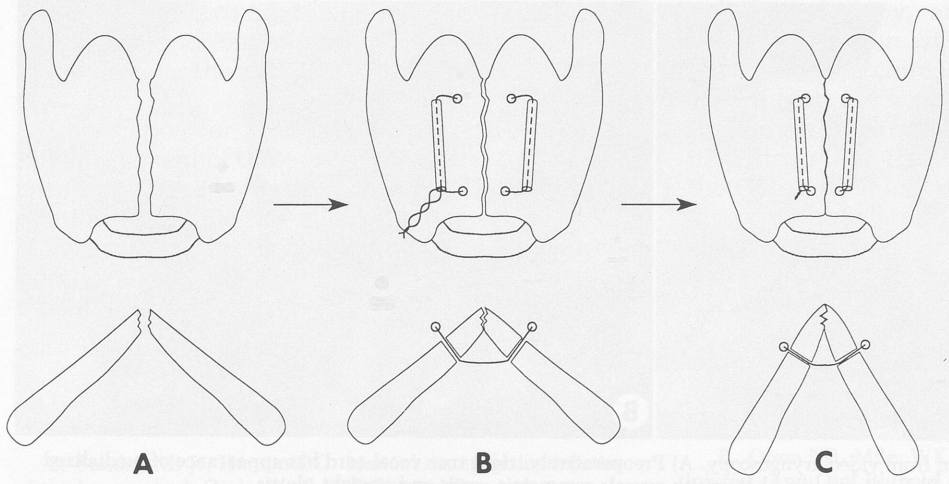

Fig 2. Schematic drawing of wire-tube technique for midline cartilage fracture. A) Midline fracture with flattened lamina. B) Wire passed in translaryngeal vertical mattress fashion. C) Wire secured with approximation and fixation of fracture with normal alignment of laminae. Although upper translaryngeal crossing of wire should be in preepiglottic space, lower crossing may be intraluminal at subglottic level. Removal in 2 to 3 months is therefore recommended.

and dysphagia but no airway distress. Indirect examination revealed a mobile right true vocal cord that appeared to be bulging medially and superiorly, but had no ecchymosis (Fig 4A). A CT scan demonstrated midline and right thyroid lamina fractures (Fig 5A). Although persistent edema could not be ruled out as being partially responsible for the bulging appearance of the cord, repair was undertaken to restore the contour of the thyroid cartilage. This decision was based on the observation that the position of the displaced fragment matched exactly a situation examined in the previously mentioned laboratory study,[9] and closely resembled the desired anatomic result of a thyroplasty intended to medialize the cord. Fixation was achieved with the wire-tube technique (Figs 1 and 2), restoring alignment of the cartilage as well as position and dimension of the vocal cord (Fig 4B). A tracheostomy was performed to facilitate reduction of the fragments, and the patient was easily decannulated several days later. A postoperative CT scan shows the stable reduction (Fig 5B). The patient claims a normal voice and has returned to professional singing.

Case 3. A 43-year-old woman was bitten on the neck by her horse during a grooming session. She noted immediate dysphagia and dysphonia but no respiratory distress. A tracheostomy was performed at another hospital 6 hours later when the patient was unable to breathe comfortably while supine. A CT scan demonstrated vertical fractures of the thyroid cartilage (Fig 6A). The fractures were reduced 3 days later by the wire-tube technique (Figs 1 and 2). Of note, the midline fracture was of the green-stick variety through an area that demonstrated little if any mineralization. Restoration of a more normal angle between the lateral laminae required translaryngeal wires (Fig 6B), and the tracheostomy was left in place in anticipation of subsequent removal of the wires under general anesthesia. A follow-up CT scan at 3 months revealed a stable reduction of the fractures, and the translaryngeal wires were removed. The patient now has a normal-appearing larynx with no evidence of endolaryngeal damage related to the translaryngeal wires. She has no complaints of voice change.

DISCUSSION

Liberal use of CT scanning in the evaluation of patients suffering blunt external trauma to the larynx has allowed us to show that the relatively low levels of mineralization in their thyroid cartilage do not protect young adults from fractures of this structure. Although members of this age group are occasionally seen with severe, comminuted crush in-

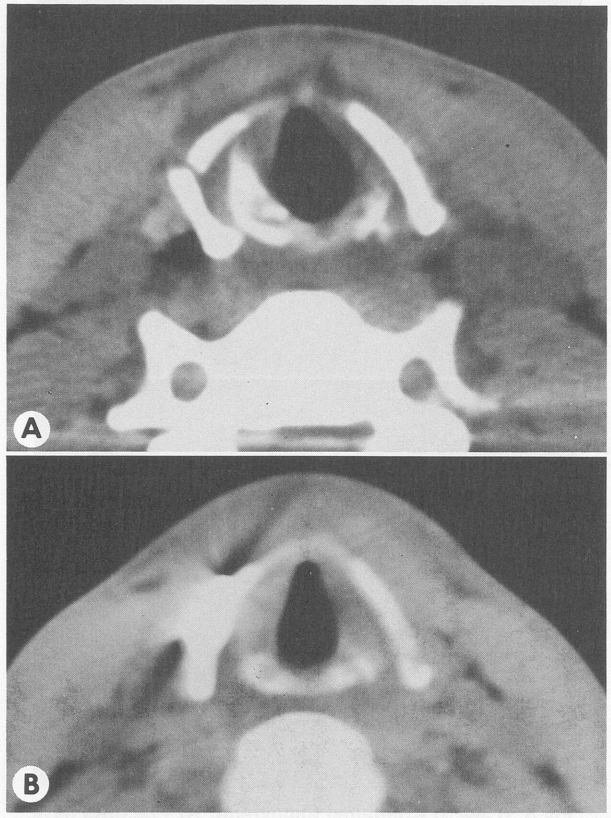

Fig 3. (Case 1) Computed tomograms. A) Preoperative scan showing displaced and angulated fracture of right thyroid lamina. B) Postoperative scan showing return of laryngeal symmetry. Artifact on film is scatter of x-ray beam by horizontally positioned wire-tube device.

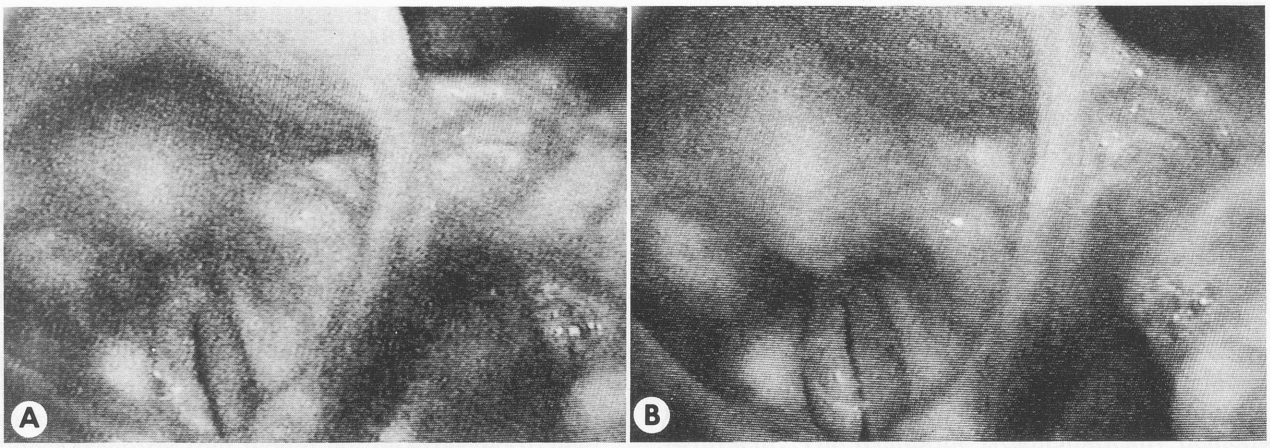

Fig 4. (Case 2) Photographs taken from videolaryngoscopy. A) Preoperatively, right true vocal cord has appearance of medialized cord and glottis is bowed to left. B) Postoperative photograph reveals symmetric cords and straight glottis.

juries due to high-speed deceleration events, many more appear to suffer linear, moderately displaced or angulated fractures due to lower-impact forces. More than one fracture line may be present, but endolaryngeal mucosa lacerations usually do not accompany these injuries, and the need for an emergent tracheostomy is unusual. Therefore, many of these injuries will go undetected initially if the otolaryngologist does not have a high index of suspicion and does not use CT scanning to evaluate the patient on the basis of criteria similar to those used at our institution. Patients in whom such an injury is overlooked most likely will not develop laryngeal stenosis or suffer marked changes in phonation. However, it is clear that these less severe injuries can modify the glottic configuration sufficiently to alter the more subtle aspects of phonation, includ-

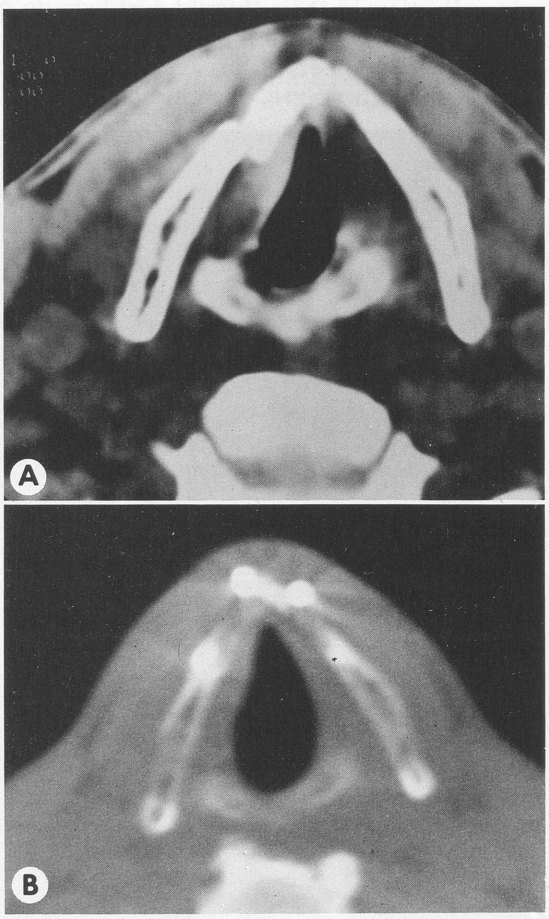

Fig 5. (Case 2) Computed tomograms. A) Fractures have resulted in medial displacement of anterior third of right thyroid lamina in manner that resembles thyroplasty for vocal cord medialization. B) Early postoperative scan shows realignment of laminae. Different window was used because of scatter from stainless steel needles.

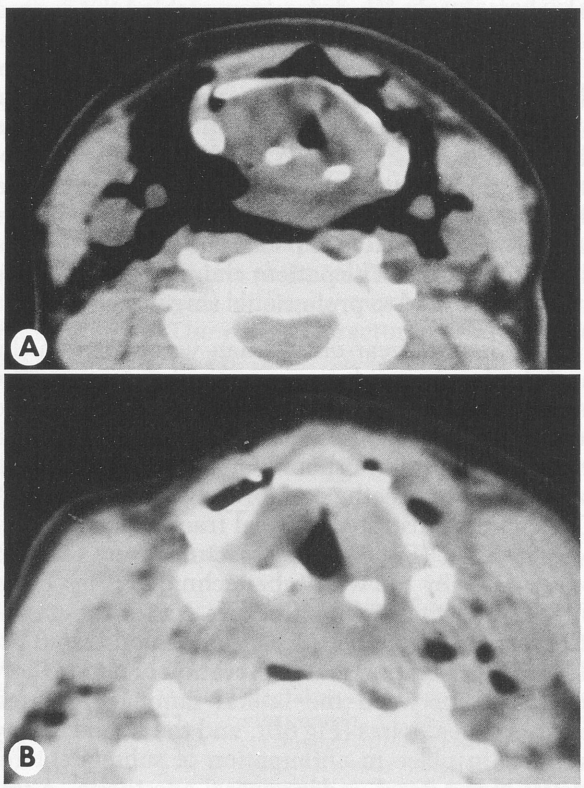

Fig 6. (Case 3) Computed tomograms. A) There is almost total flattening of angle between lateral laminae. B) Early postoperative scan with translaryngeal wires visible immediately above level of anterior commissure. More normal interlaminal angle has been restored.

ing mean frequency and frequency range. Although such perturbations might not be a problem in day-to-day conversational speech, noticeable difficulties might arise for the public speaker or singer.

Justification for an aggressive surgical approach in management of these injuries requires that an accurate, stable reduction be achieved. The wire-tube fixation technique has allowed us to achieve uniformly good results in stabilizing fractures of even poorly mineralized thyroid cartilages, as demonstrated by the anatomic reductions on postoperative CT scans, symmetric vocal cord appearance on videolaryngoscopy, and, most important, by patients' satisfaction with their speaking and singing voices. We therefore urge that the otolaryngologist have a high index of suspicion for fractures of the thyroid cartilage following blunt neck trauma, even in patients less than 40 years of age, previously thought to be at low risk. High-resolution CT scanning can demonstrate previously undetectable thyroid cartilage fractures, and treatment of those fractures can offer the patient an improved chance of regaining a near-normal if not normal voice.

REFERENCES

1. Polson CJ. The essentials of forensic medicine. 3rd ed. Springfield, Ill: Charles C Thomas, 1965:335-6.

2. Stanley RB Jr, Hanson DG. Manual strangulation injuries of the larynx. Arch Otolaryngol 1983;109:344-7.

3. Fearon B. Acute airway obstruction. In: Ferguson CF, Kendig EL, eds. Pediatric otolaryngology: disorders of the respiratory tract in children. Vol 2. Philadelphia, Pa: WB Saunders, 1972:1183-213.

4. Myer CM III, Orobello P, Cotton RT, Bratcher GO. Blunt laryngeal trauma in children. Laryngoscope 1987;97:1043-8.

5. Yerman HM, Werkhaven J, Schild JA. Evaluation of laryngeal calcium deposition: a new methodology. Ann Otol Rhinol Laryngol 1988;97:516-20.

6. Olson NR, Miles WK. Treatment of acute blunt laryngeal injuries. Ann Otol Rhinol Laryngol 1971;80:704-9.

7. Schaefer SD, Close LG. Acute management of laryngeal trauma. Update. Ann Otol Rhinol Laryngol 1989;98:98-104.

8. Hirano M, Kurita S, Terasawa R. Difficulty in high-pitched phonation by laryngeal trauma. Arch Otolaryngol 1985;111:59-61.

9. Stanley RB Jr, Cooper DS, Florman SH. Phonatory effects of thyroid cartilage fractures. Ann Otol Rhinol Laryngol 1987;96:493-6.

FREE JEJUNAL GRAFT: EFFECTS OF LONGITUDINAL MYOTOMY

BRUCE H. HAUGHEY, MBChB, FRACS JAMES W. FORSEN, MD

ST LOUIS, MISSOURI

Pharyngoesophageal reconstruction using the free vascularized jejunal graft results in dysphagia in approximately 20% to 40% of patients. This may be caused by graft contractility, and we therefore developed this canine model to assess the functional effects of myotomy on transplanted jejunum. Nine female dogs underwent microvascular transposition of jejunum to the neck, the bowel being placed subcutaneously with two end jejunostomies. Baseline functional manometry was performed. Five animals then underwent complete longitudinal myotomy and four animals underwent a sham procedure. Graft function was then reevaluated after complete wound healing. Contraction frequency, contraction amplitude, and total work done by the graft were recorded; all grafts demonstrated activity and were more active postrecovery than at the time of operation. Although myotomy animals showed a within-group trend to decreased contractility postintervention, this was not statistically significant. Furthermore, there was no significant postintervention difference between the sham and myotomy groups. We conclude that our model is effective for the study of activity in the free jejunal graft and that longitudinal myotomy does not significantly reduce, let alone ablate contraction.

KEY WORDS — free vascularized jejunal graft, graft contractility, myotomy, pharyngoesophageal reconstruction.

INTRODUCTION

Reconstruction of the upper aerodigestive tract after ablative procedures has always been of major concern to head and neck surgeons. Skin and musculocutaneous flaps have been used extensively,[1-3] because they are readily available, and patients can reestablish oral nutrition by using gravity through a passive conduit. These methods result in an adynamic segment in the swallowing tract with minimal adaptation to the functional qualities of either pharyngoesophageal musculature or the mucosal lining.

Improvement in reconstruction of pharyngoesophageal defects has accompanied the use of enteric tissue. Donor sites have included stomach, jejunum, ileum, and colon, and reliability of microvascular technique has made the use of free jejunal tissue transfer popular. The idea, however, of free tissue reconstruction in this region is not new. In 1907, Carrel[4] reported the experimental free transfer of bowel for restoration of an esophageal defect. Hiebert and Cumings[5] were the first to report this method in humans in 1961, using gastric antrum.

The free jejunal graft has been demonstrated to provide very satisfactory upper aerodigestive tract reconstruction. Advantages include relative ease of harvest, low donor site morbidity, a lumen diameter compatible with that of the esophagus, and lubrication of orogastric transport with constant secretion from the mucosal glands. Although the use of free jejunal grafts is widespread,[6] problems have been identified. Approximately 40% of patients have some degree of delay in bolus transit time through the grafted segment.[7] This is potentially an even greater problem if the larynx is preserved, as has been reported in conjunction with the use of free jejunal grafts,[8] because of the ever-attendant risk of aspiration. The motility problems in these grafts seem to be due to continued, unmodulated peristalsis and segmental contractions mediated by the myenteric plexus. Although the grafts are extrinsically denervated, these autonomous plexi continue to function. Disuse atrophy of muscle is thereby prevented and an associated decrease in activity may not ensue.

One of us (B.H.H.) developed a canine model that allowed for assessment of free jejunal graft motility characteristics.[9] By placing the segment subcutaneously in the neck and exteriorizing it to form end jejunostomies, easy access was provided to the lumen. Subsequently, various baseline studies were performed, including manometry, fluoroscopy, and electromyography.[10]

The present study was designed to eliminate the intrinsic contractions seen in the canine free jejunal graft. Specifically, a longitudinal myotomy was performed to convert the graft into a passive yet mucosally lined conduit. In addition, the original model[9] was modified so that it could be tested over a longer period of time.

From the Department of Otolaryngology–Head and Neck Surgery, Jewish Hospital Division, Washington University School of Medicine, St Louis, Missouri. Supported by a Jewish Hospital of St Louis Research Endowment Grant, 1990. This study was performed in accordance with the PHS Policy on Humane Care and Use of Laboratory Animals, the NIH *Guide for the Care and Use of Laboratory Animals*, and the Animal Welfare Act (7 U.S.C. et seq.); the animal use protocol was approved by the Committee on the Humane Care of Laboratory Animals (CHCLA) of Washington University.

Presented at the meeting of the American Laryngological Association, Waikoloa, Hawaii, May 4-5, 1991.

REPRINTS — Bruce H. Haughey, MBChB, FRACS, Dept of Otolaryngology–Head and Neck Surgery, Washington University School of Medicine, 4932 Forest Park Blvd, St Louis, MO 63108.

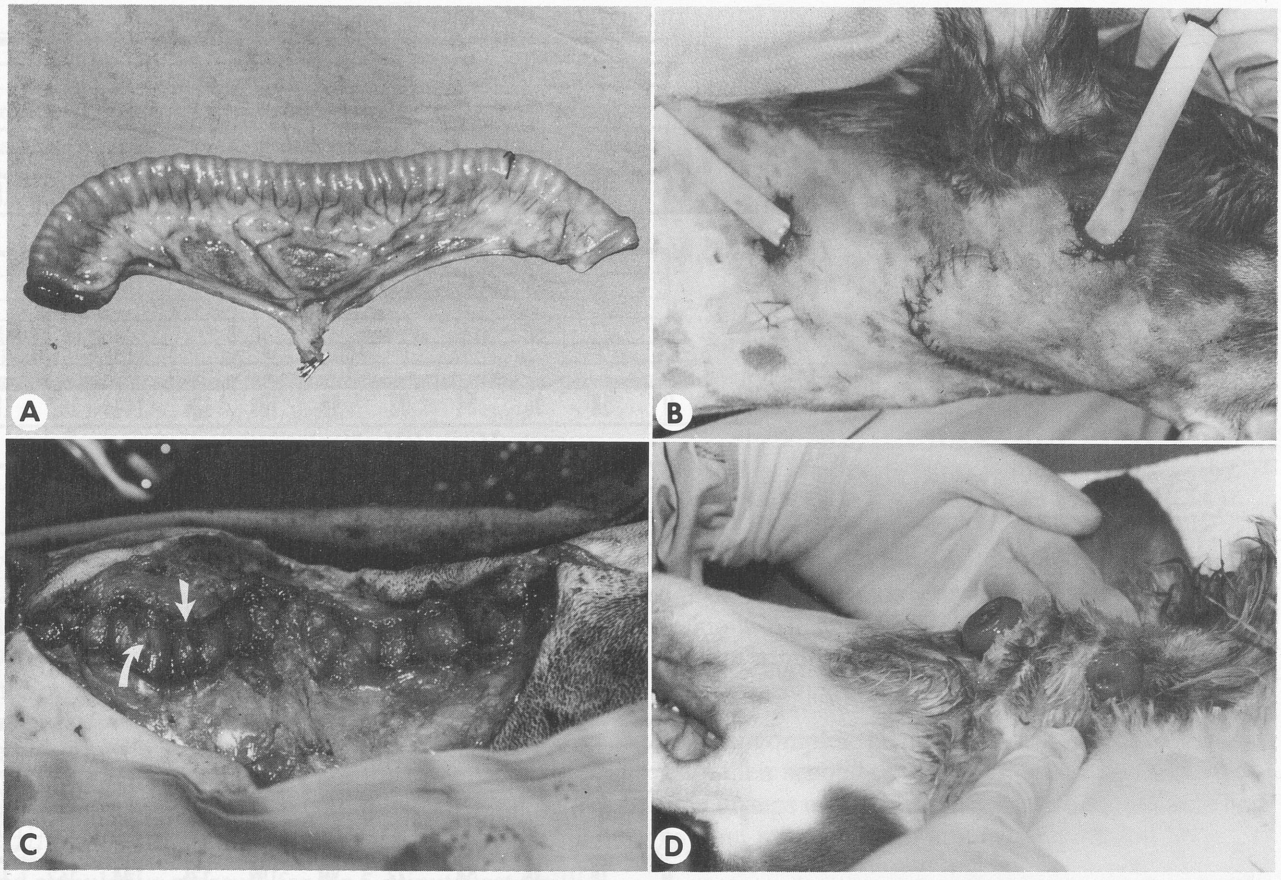

Fig 1. Photographs from myotomy procedure. A) Canine free jejunal graft (20 cm). B) Revascularized jejunal graft with Penrose drain exiting from jejunostomies. C) Myotomized free jejunal graft. Note exposed submucosa (curved arrow) and cut muscle margin (straight arrow). D) Free jejunal graft in ventral neck position. Note herniation of graft at jejunostomies and shortening of subcutaneous segment.

MATERIALS AND METHODS

The present study modified an earlier technique, in which we developed a canine model for study of revascularized free jejunal segments.[9] The modified incisions and graft placements detailed below allowed longer-term analysis of the canine free jejunal graft in both the control and experimental myotomy arms.

Nine female mongrel dogs were used, weighing between 15 and 20 kg. They received 1 g of neomycin sulfate orally twice a day for 2 days and were given nothing to eat for 24 hours preoperatively. On the day of operation, they were sedated with 10 mg of acepromazine maleate administered intramuscularly, and then shaved. Anesthetic induction was achieved with 25 mg/kg sodium pentobarbital administered intravenously and was followed by endotracheal intubation and maintenance on halothane 1%, nitrous oxide 1 L/min, and oxygen 1 L/min. After preparation, separate operative fields were established in the neck and abdomen.

A midline laparotomy was performed and jejunum just distal to the ligament of Treitz was evaluated. A bowel segment measuring from 15 to 25 cm, served by a single artery and vein, was harvested (Fig 1A), and the intestinal lumen was flushed with an iodine solution. The segmental artery and vein were prepared under the microscope, while the graft was bathed in cold saline. Bowel continuity in the abdomen was then reestablished by using a single layer of interrupted 3-0 Vicryl suture. The abdominal wall was closed in the standard layered fashion.

A single curved neck incision was then made, approximately 12 cm in length and transverse to the long axis of the neck and the jejunal graft. This approach was designed to minimize scar contracture along the axis of the graft. This in turn prevented gross shortening and herniation of the graft during the study period. This approach was a revision of our original model,[9] which employed a longitudinally directed neck incision. The external jugular vein, its major tributaries, and the lingual artery were carefully dissected free. End-to-end anastomoses were established between recipient and donor vessels by using interrupted or continuous 10-0 nylon suture and standard microvascular technique. Once the graft

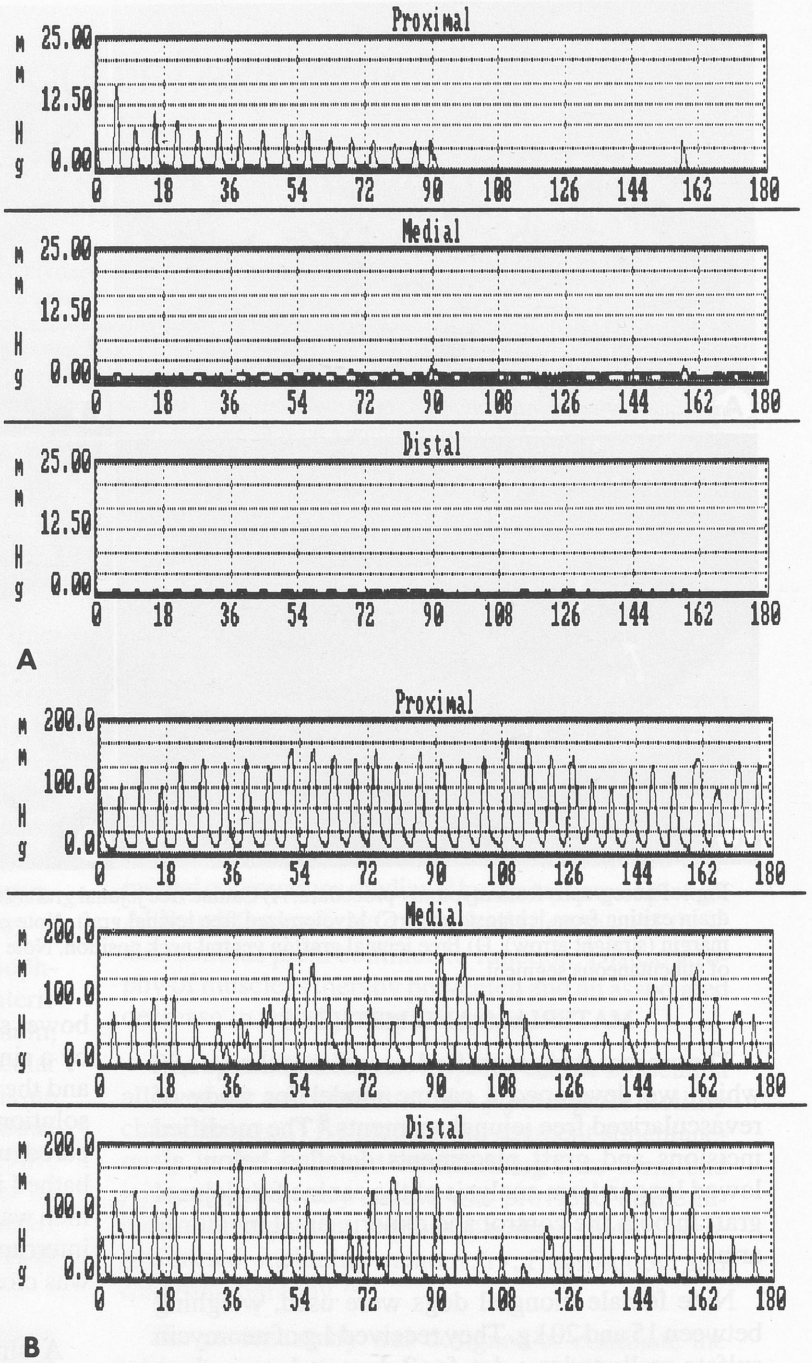

Fig 2. Representative manometry tracings from three transducer probes (time in seconds). A) At baseline. B) After metoclopramide hydrochloride stimulation.

was being perfused, it was placed parallel to the long axis of the neck in a lateral subcutaneous pocket. This dorsolateral placement kept the graft out of the loosest ventral skin on the flexor aspect of the neck, again to minimize any shortening. The ends of the graft were then tunneled beneath the skin flaps, and end jejunostomies were fashioned. One Penrose drain was placed in the wound while another was inserted through the lumen of the graft to allow adequate drainage of jejunal secretions (Fig 1B). The neck wound was closed in a layered fashion and a mild pressure dressing using an orthopedic stocking was applied.

The animals received morphine intramuscularly perioperatively and 300 mg ampicillin sodium intramuscularly twice a day for 1 week. They were initially given water ad libitum and then fed canned food on the fourth postoperative day. They were later advanced to dry chow.

Evaluation of jejunal graft activity was achieved with solid state manometry. The manometry catheter housed three circumferential pressure transducers spaced 3.5 cm apart (Konigsberg Instruments) and

FREE JEJUNAL GRAFT MOTILITY

Condition	*Parameter*	*Intervention*	*n*	*Testing Period (mean ± SD)*		
				Time of Operation	*Postrecovery and Preintervention*	*Postintervention*
Baseline	Contractions per minute	Sham	4	1.5 ± 1.1	0.5 ± 0.7	3.4 ± 1.8
		Myotomy	5	1.3 ± 1.2	4.3 ± 3.5	3.1 ± 3.4
	Contraction amplitude (mm Hg)	Sham	4	7.7 ± 1.7	2.3 ± 2.5	7.8 ± 5.0
		Myotomy	5	11.6 ± 10.3	15.4 ± 15.0	11.6 ± 15.1
	Cumulative pressure (mm Hg/s)	Sham	4	115.0 ± 68.4	58.2 ± 31.9	226.8 ±202.0
		Myotomy	5	131.9 ±118.7	249.7 ± 237.6	199.5 ±265.5
Metoclopramide stimulation	Contractions per minute	Sham	4	2.2 ± 1.3	7.4 ± 2.8	8.2 ± 3.2
		Myotomy	5	2.5 ± 2.5	6.6 ± 5.5	5.8 ± 4.2
	Contraction amplitude (mm Hg)	Sham	4	12.1 ± 3.3	65.1 ± 56.0	31.0 ± 22.5
		Myotomy	5	21.4 ± 16.2	51.9 ± 41.6	29.4 ± 25.5
	Cumulative pressure (mm Hg/s)	Sham	4	131.8 ± 48.9	124.1 ±1,109.8	668.6 ±549.6
		Myotomy	5	244.8 ±218.4	985.7 ± 863.3	635.8 ±580.1

was connected to a transducer coupler (type A; strain gauge bridge) that fed the electrical signals to an analog to digital converter (Coulbourn Instruments). Data were collected and analyzed on an XT 286 microcomputer with a custom-designed software program from National Instruments, Inc. The sinusoidal pressure waves from each transducer were displayed graphically and the program then obtained averages for contraction amplitude (millimeters of mercury), contraction frequency (waves per minute), and cumulative pressure for the 5-minute test (millimeters of mercury per second).

We performed baseline manometry immediately following graft revasculation at the time of operation and again 2 to 3 weeks postoperatively with the animal under light sedation (postrecovery and preintervention [PRPI]). All manometry tests were 5 minutes long and were performed on animals fasted for 24 hours. After each initial test, we repeated manometry at 5 minutes, 1 minute after a temporary motility stimulus (10 mg metoclopramide hydrochloride given intravenously). With baseline data collected and stored, the animals were randomly divided into a sham group (n = 4) and a myotomy group (n = 5). Under an anesthetic regimen similar to that in the tissue transfer operation, the myotomy-assigned animals underwent an S-shaped incision through the neck skin overlying the graft. Dissection continued down to the level of the jejunum, and a longitudinal incision was made through the serosa and both layers of muscle. To ensure complete circumferential discontinuity, the submucosal surface was carefully laid bare of muscle tissue for a width of 0.5 to 1.0 cm along the entire length of the graft (Fig 1C). Occasional rents in the mucosa were repaired with interrupted 4-0 chromic suture. In the sham operation, the approach and dissection went through the subcutaneous tissue to expose the graft, but did not penetrate the serosa or muscle. The wounds were then closed in a layered fashion. All animals received 300 mg ampicillin sodium administered intramuscularly twice a day for 4 days postoperatively.

After complete healing and recovery (2 to 3 weeks from their second operations), both sham and myotomy groups underwent manometric testing with and without metoclopramide (postintervention [PI]).

At the end of the study, all animals were painlessly killed and the grafts were immediately harvested and placed in 10% formalin. Gross and microscopic histology were performed by the Department of Pathology, Jewish Hospital of St Louis. All data collected were analyzed by a statistician using the Wilcoxon nonparametric test.

RESULTS

All nine animals survived the initial operation and had primarily viable free jejunal grafts. The average ischemia time was 2 hours. The graft length averaged 19 cm in the sham group and 20 cm in the myotomy group (range 15 to 25 cm). The wounds healed well after both primary free tissue transfer and surgical interventions. However, three of the five myotomy dogs developed temporary fistulae, probably due to occult microperforations caused by surgical trauma.

Figure 2A shows a representative tracing of waveforms from the three transducer probes in a graft during PRPI baseline testing. Figure 2B shows contractile activity in the same graft after injection of metoclopramide. Results from the motility studies are shown in the Table. Because the group sizes were small, statistical analysis of the data was nonparametric. All data had large standard deviations, and therefore statistical differences ($p < .05$, Wilcoxon test)

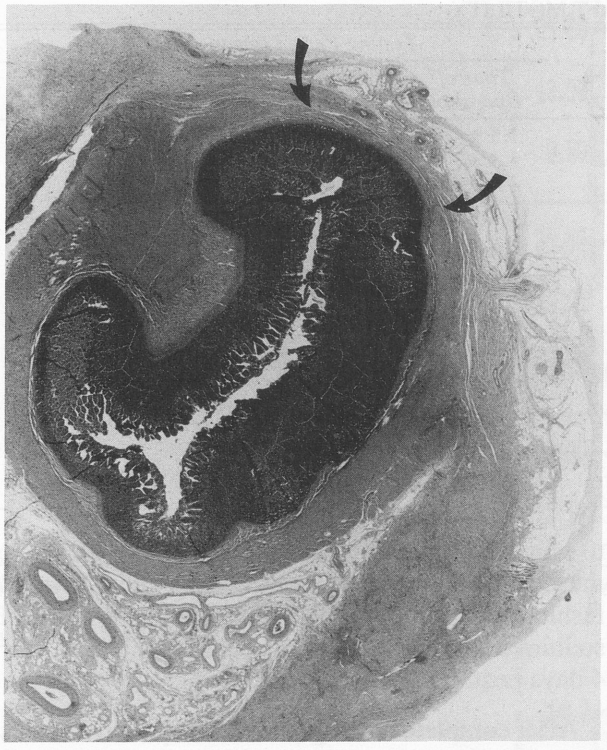

Fig 3. Postmyotomy histology showing cut end of circular and longitudinal muscle layers with ingrowth of fibrous scar tissue between arrows.

within and between groups were difficult to establish.

Each manometric test was first performed with the graft in the resting or baseline state. We anticipated that there would be low-grade contractile activity at this baseline. With this low activity possibly being reduced even further by myotomy, difficulty in detecting small differences in motility within and between grafts was predicted. Therefore, each graft was retested after injection of metoclopramide (Reglan, AH Robins), a potent stimulator of gut activity, to determine the potential maximum activity of the graft. The longitudinal jejunal myotomy was an effort to completely abolish not only baseline contractile activity, but also the potential for high-grade contractions seen at certain phases of the digestive cycle. The random assignment of dogs to the two intervention groups resulted in the following. The sham group, when tested at baseline before intervention, demonstrated a significantly decreased ($p < .02$) mean cumulative pressure (millimeters of mercury per second) for the 5-minute test versus the group randomized to myotomy. However, the group means were similar under a metoclopramide stimulus (see Table). We are unable to explain this peculiarity, but believe it may reflect our small group sizes. We did observe large individual differences in spontaneous graft contractility; thus, chance assignment of grafts with low activity to the sham group may have occurred.

There was a trend toward an increase in graft contractile activity from the time of operation to PRPI for the myotomy group, at baseline, and for both groups with metoclopramide. In no case, however, was this change statistically significant. The sham group activity was decreased, but not significantly (see Table).

Although there was a trend to decreased graft activity after myotomy, with a mean decrease in all parameters both with and without metoclopramide, there was not a statistically significant decrease within the group, ie, PRPI versus PI. Mean total graft work decreased 20% at baseline after myotomy and 36% in the metoclopramide-stimulated mode. The sham surgery dogs did 380% more baseline work after intervention, but 44% less metoclopramide-stimulated work. There was also no significant difference in activity between the sham surgery group and the myotomy group after intervention, either at baseline or with metoclopramide. In short, the longitudinal myotomy did not demonstrate the ability to significantly diminish contractile activity as measured by solid-state manometry.

DISCUSSION

Ever since the pioneering work[11] of Mikulicz, Gluck, Trotter, Wookey, and others, surgeons have searched for the ideal reconstruction following total laryngopharyngectomy and/or cervical esophagectomy. The primary goal is to establish orogastric transit sufficient for the patients' nutritional needs.

One-stage repair using the free jejunal autotransplant with microvascular anastomosis is successful and popular, but may leave the patient with functional dysphagia. This can be caused by attempting to swallow against a circumferentially contracted graft. Such contraction could also potentially inhibit tracheoesophageal or tracheojejunal phonation. We have noted starts and stops in speech continuity in these patients, possibly due to graft contraction.[12]

The present study reports the results of delayed surgical myotomy performed on microvascular free jejunal grafts in dogs. The original model[9] has been modified to facilitate long-term study of the jejunal segment.

We observed a wide range of spontaneous baseline activity from graft to graft after revascularization. This unpredictable behavior persisted after a sham operation, with baseline pressure parameters (frequency, amplitude, and cumulative pressure) appar-

ently increasing postoperatively. Under conditions of preoperative and postoperative metoclopramide stimulation, however, sham-operated dogs showed a trend to diminished activity. After the myotomy, despite the disrupted grafts' showing reduced activity on all parameters both with and without a metoclopramide stimulus, this trend was not statistically significant. Furthermore, pressure parameters between the myotomy group and the sham group were not significantly different. This suggests that even though the myenteric plexus is surgically interrupted, it relies on longitudinal rather than circumferential continuity for continued function. Furthermore, its residual motile function is capable of generating near-normal intraluminal pressure, despite discontinuity. One additional possibility to explain this would be restoration by scar tissue of a physical connection between the cut muscle margins. We were able to document this phenomenon histologically in sampled grafts (Fig 3). The manometry findings were contrary to our hypothesis that myotomy would cause total or near-total ablation of contractility. The rather small magnitude of reduction in average pressure parameters in myotomized grafts and the equivalence of sham surgery to myotomy surgery is strong experimental evidence that the myotomy we performed was ineffective. The next phase of this experimentation will study the effects of other forms of intervention, including drugs and radiotherapy.

CONCLUSIONS

1. A 3-month study of exteriorized jejunal free flaps is feasible in dogs, avoiding gross intussusception (Fig 1D).
2. Immediate postoperative motility is not predictive of activity in the healed, postoperative state.
3. Delayed myotomy of jejunal free flaps is feasible despite some temporary complications.
4. A trend to decreased motility in myotomized grafts is not clinically or statistically significant.
5. There is no significant difference in motility between myotomized grafts and sham-operated grafts.
6. Future research to modify jejunal graft motility should include other modalities, eg, pharmaceutical or radiotherapeutic.

REFERENCES

1. Wookey H. The surgical treatment of the carcinoma of the pharynx and upper esophagus. Surg Gynecol Obstet 1942;75:499-506.

2. Bakamjian VY. A two stage method for pharyngoesophageal reconstruction with a pectoral skin flap. Plast Reconstr Surg 1965;36:173-84.

3. Baek S, Lawson W, Biller HF. Reconstruction of hypopharynx and cervical esophagus with pectoralis major island myocutaneous flap. Ann Plast Surg 1981;7:18-24.

4. Carrel A. The surgery of blood vessels etc. Bull Johns Hopkins Hosp 1907;18:18-28.

5. Hiebert CA, Cumings GO. Successful replacement of the cervical esophagus by transplantation and revascularization of a free graft of gastric antrum. Ann Surg 1961;154:103-6.

6. Nahai F, Stahl RS, Hester TR, Clairmont AA. Advanced applications of revascularized free jejunal flaps for difficult wounds of the head and neck. Plast Reconstr Surg 1984;74:778-80.

7. Kerlin P, McCafferty GJ, Robinson DW, Theile D. Function of a free jejunal "conduit" graft in the cervical esophagus. Gastroenterology 1986;90:1956-63.

8. Schechter GL, Baker JW Jr, Gilbert DA. Functional evaluation of pharyngoesophageal reconstructive techniques. Arch Otolaryngol Head Neck Surg 1987;113:40-4.

9. Scher N, Garza JR, Haughey BH. New canine model for free jejunal graft studies. Microsurgery 1989;10:283-6.

10. Scher N, Wiederhold ML, Garza JR, Pingree TF, Haughey B. Baseline motility of the free jejunal graft in a new canine model. Am J Otolaryngol 1991;11:407-15.

11. DeSanto LW, Carpenter RJ. Reconstruction of the pharynx and upper esophagus after resection for cancer. Head Neck Surg 1980;2:369-79.

12. Purcell LL, Floyd LR, LaBlance GR, Paniello RC, Haughey BH. Speech after laryngectomy with jejunal flap and tracheojejunal puncture [Abstract]. Otolaryngol Head Neck Surg 1991; 105:291-2.

EFFECT OF BLOOD ON THE INCENDIARY PROPERTIES OF ENDOTRACHEAL TUBES IRRADIATED WITH THE CARBON DIOXIDE LASER

ROBERT H. OSSOFF, DMD, MD
NASHVILLE, TENNESSEE

DEBRA A. GONZALEZ, MD
BURLINGTON, VERMONT

The effect of blood on the incendiary properties of endotracheal tubes (ETTs) irradiated with the carbon dioxide laser has not been previously reported. Rusch red rubber and Mallinckrodt polyvinyl chloride ETTs wrapped with reflective metallic tape, a Mallinckrodt ETT wrapped with Americal Laser Guard, a Mallinckrodt Laser Flex ETT, and a Xomed-Treace Laser Shield II ETT were irradiated through three to five drops of heparinized canine blood with the carbon dioxide laser. One hundred percent oxygen at a flow rate of 3 L/min was delivered through the tube. The maximum continuous power that each tube could tolerate in the presence of blood without evidence of fire was determined for each ETT. The results of the study demonstrated that the presence of blood did not affect the incendiary properties of the Mallinckrodt ETT wrapped with Americal Laser Guard; all other tubes demonstrated a lower ignition threshold in the presence of blood.

KEY WORDS — blood, carbon dioxide laser, endotracheal tube, fire, incendiary properties, laser.

INTRODUCTION

The specialty of otolaryngology–head and neck surgery was first warned of the possibility of a laser-ignited endotracheal tube (ETT) fire as early as 1972, when Strong and Jako[1] presented their initial clinical report on the use of the carbon dioxide (CO_2) laser in otolaryngology at the annual meeting of the American Broncho-Esophagological Association. They recognized the vulnerability of the ETT cuff and suggested protecting it with a piece of "moist selvage gauze." The following year, these same two laser pioneers suggested protecting the ETT from accidental laser impact by wrapping the tube with a thin, reflective metal coating such as aluminum tape.[2] This represented the first reference to the necessity of ETT and cuff protection for CO_2 laser surgery of the upper aerodigestive tract.

In 1974, Andrews and Moss[3] presented the results of their in vitro bench experiments on the incendiary properties of ETTs at the annual meeting of the American Laryngological Association. They cautioned that plastic ETTs were more easily penetrated than red rubber tubes and that these same plastic tubes ignited far more easily in an oxygen-rich environment than did the red rubber tubes.

Stimulated by these early reports, anesthesiologists wrote prolifically about the anesthetic management of patients undergoing CO_2 laser surgery of the larynx and upper aerodigestive tract.[4,5] In 1975, Snow and Norton[6] reviewed and published their experiences with 700 laser cases. Four fire accidents were included in this report.

Norton and de Vos[7] introduced the first special endotracheal tube for microlaryngeal CO_2 laser surgery in 1978. This was a nonreflective, uncuffed metal tube that came in sizes for both adults and children. Several others introduced new tubes or catheters for laser surgery during the next 2 years.[8-10]

In 1979, Vourc'h et al[11] reviewed their experience in 257 patients undergoing microlaryngeal laser surgery. They cautioned their readers that both oxygen and nitrous oxide support combustion and that it may be better to mix oxygen with air to reduce the risk of endotracheal tube fire.

Reports of complications associated with performing microlaryngeal CO_2 laser surgery began to appear in the otolaryngology–head and neck surgery literature in 1981. These reports discussed individual experiences with ETT fires. Included were data from the testing of the ETTs available for use at the time of the reports. An attempt was made to determine which tube was the safest for microlaryngeal laser surgery.[12-16]

In 1982, LeJeune et al[17] suggested that the cuff be filled with saline instead of air. This action created a heat sink at the site of the cuff and prevented the cuff from acting as a potential kindling site for a laser-

From the Department of Otolaryngology, Vanderbilt University Medical Center, Nashville, Tennessee (Ossoff), and the Division of Otolaryngology, University of Vermont Medical School, Burlington, Vermont (Gonzalez).

Presented at the meeting of the American Laryngological Association, Waikoloa, Hawaii, May 4-5, 1991.

REPRINTS — Robert H. Ossoff, DMD, MD, Dept of Otolaryngology, Medical Center North, S-2100, Vanderbilt University Medical Center, Nashville, TN 37232-2559.

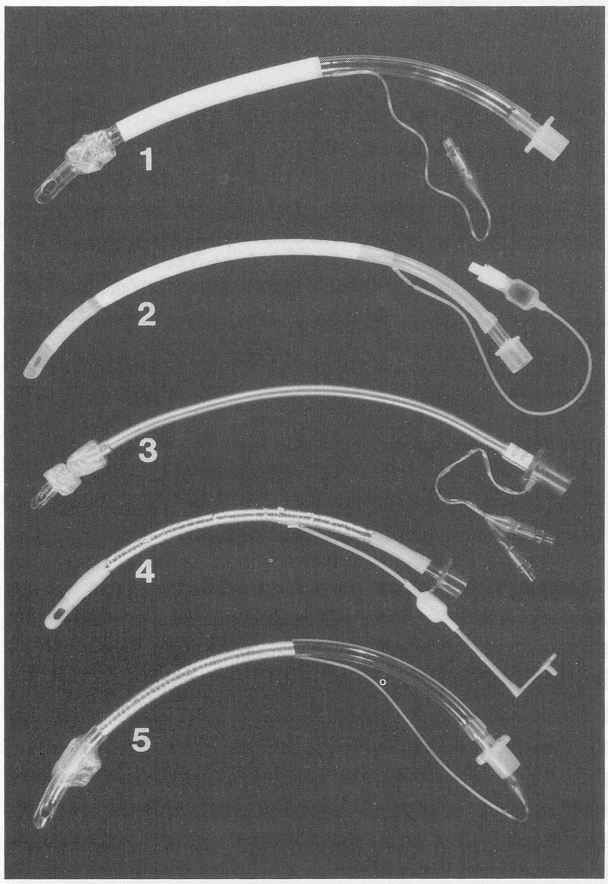

Fig 1. Endotracheal tubes used in study. 1 — Mallinckrodt polyvinyl chloride tube wrapped with Americal Laser Guard, 2 — Xomed-Treace Laser Shield II, 3 — Mallinckrodt Laser Flex, 4 — Rusch red rubber tube wrapped with reflective metallic tape, 5 — Mallinckrodt polyvinyl chloride tube wrapped with reflective metallic tape.

ignited ETT fire.

Healy et al[18] presented a retrospective review of their laser-related complications associated with 4,416 cases of upper aerodigestive tract surgery requiring the CO_2 laser. Nine complications were identified in this group of patients for an overall complication rate of 0.2%. Four of these complications were associated with ETT fires. All fires occurred early in their experience, prior to protecting the tube with reflective metallic tape.

In 1983, Ossoff et al[19] reviewed their experience with 204 cases. They found 12 laser-related complications over a 2-year period. No ETT fires were included in this series. All patients were operated on under the provisions of a comprehensive laser safety protocol.

Fried[20] presented the results of a laser safety survey of 229 otolaryngologists, 210 of whom responded. A total of 81 complications were cited in his paper. Significant findings were 28 ETT explosions and/or fires, 9 facial skin burns, and 3 ETT cuff ignitions.

Pashayan and Gravenstein[21] proposed the use of helium as a diluent for oxygen when performing microlaryngeal laser surgery. Their study, published in 1985, concluded that helium, in a concentration greater than 60%, significantly retarded ETT ignition of plastic tubes. However, these authors did not recommend wrapping the plastic ETT with any protective tape or using saline-saturated cottonoids to protect the cuff.

The next year, Lim and Kenney[22] reviewed 3,500 procedures that they had performed in the upper aerodigestive tract using the CO_2 laser. Among their six complications was one laser-ignited ETT fire.

In 1989, Ossoff[23] presented a comprehensive review of the literature related to anesthetic complications of upper aerodigestive tract laser surgery. He included a series of in vitro bench experiments performed on the incendiary properties of ETT irradiated by the CO_2 laser. Several conclusions were reached. First, both the Rusch red rubber and Xomed Laser Shield tubes should be protected by wrapping with reflective metallic tape. Second, saline-saturated cottonoids were suggested for cuff protection. Finally, oxygen-helium mixtures were proven to be more protective than oxygen-nitrogen mixtures in preventing ETT fires. In addition to the above experiments, a survey of complications similar to that of Fried[20] was sent to 337 past registrants of laser courses directed by Ossoff. Of the 253 registrants who returned their surveys, 218 had used the laser for more than 7,200 cases. Eleven physicians reported a total of 12 complications. No ETT fires were described in this publication.

In 1990, Sosis et al[24,25] reported their findings regarding the incendiary characteristics of ETTs. In addition to reporting on the ETT shaft and cuff characteristics of laser-irradiated tubes, they also studied the different foil tapes available for protecting the tubes.

To date, the effect of blood on the incendiary properties of ETTs irradiated with the CO_2 laser has not been reported. The deposition of blood or other pharyngeal secretions onto the ETT during intubation or microlaryngeal laser surgery is a distinct possibility. This paper presents the results of the effect of blood on the incendiary properties of ETTs. The potential implications of these findings as they relate to microlaryngeal laser surgery will be discussed.

MATERIALS AND METHODS

Rusch red rubber and Mallinckrodt polyvinyl chlo-

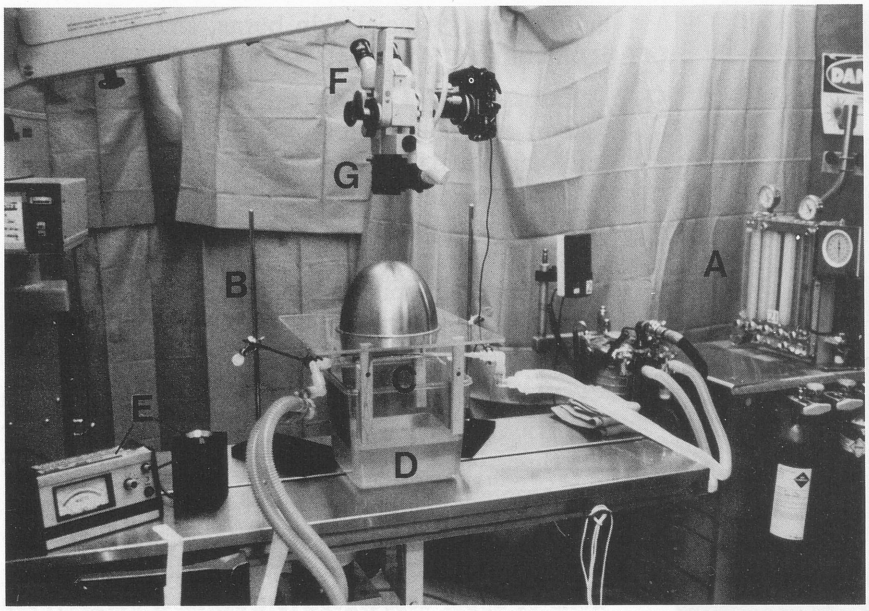

Fig 2. Laboratory setup for endotracheal tube testing. A — Vernatrol laboratory anesthesia unit, B — ring stands, C — endotracheal tube, D — plastic basin, E — Ophir power meter, F — operating microscope, G — 710 Acuspot micromanipulator.

ride (PVC) ETTs wrapped with reflective metallic tape, a Mallinckrodt ETT wrapped with Americal Laser Guard, a Mallinckrodt Laser Flex ETT, and a Xomed Laser Shield II ETT were irradiated through three to five drops of heparinized canine blood with the CO_2 laser at a focal distance of 400 mm. The five tubes used for these experiments are shown in Fig 1. One hundred percent oxygen was delivered through the circuit of a Vernatrol Vaporizing System laboratory anesthesia unit (Ohmeda Products, Division of the BOC Group, Inc) at a flow rate of 3 L/min. The ETT was suspended from two ring stands by two C clamps that held the tube in a horizontal position. A plastic basin filled with water was placed beneath the ETT to act as a heat sink and protect the laboratory counter top from ignition (Fig 2). A flat piece of Plexiglas with a large hole cut in the center was placed over the top of the basin, and a metal dome was used to cover the hole in the Plexiglas (Fig 3). A hole was located slightly off center on the top of the dome, through which the laser beam was aimed at the ETT; this off-center location of the hole permitted ETT irradiation without reflection of the beam back at the Acuspot microspot micromanipulator attached to the operating microscope. A Kelly clamp was positioned on the gas hose leading from the anesthesia unit to the tube to facilitate clamping the hose when a fire occurred, thus shutting off the supply of oxygen flowing to the tube, which in turn would help to extinguish the experimental laser-ignited tube fire.

A Sharplan model 1060 CO_2 laser with a maximum power output of 40 W was used. The laser was coupled to a Zeiss operating microscope using the first-generation prototype of the Sharplan 710 Acuspot microspot micromanipulator. The microscope objective lens and laser-focusing lens used for these studies had a focal length of 400 mm,which produced a surgical spot size of 0.38 mm. The spot size was verified by measuring power transmittance through a pinhole of known diameter.[26] An Ophir power meter was used to calibrate the power output of the laser for

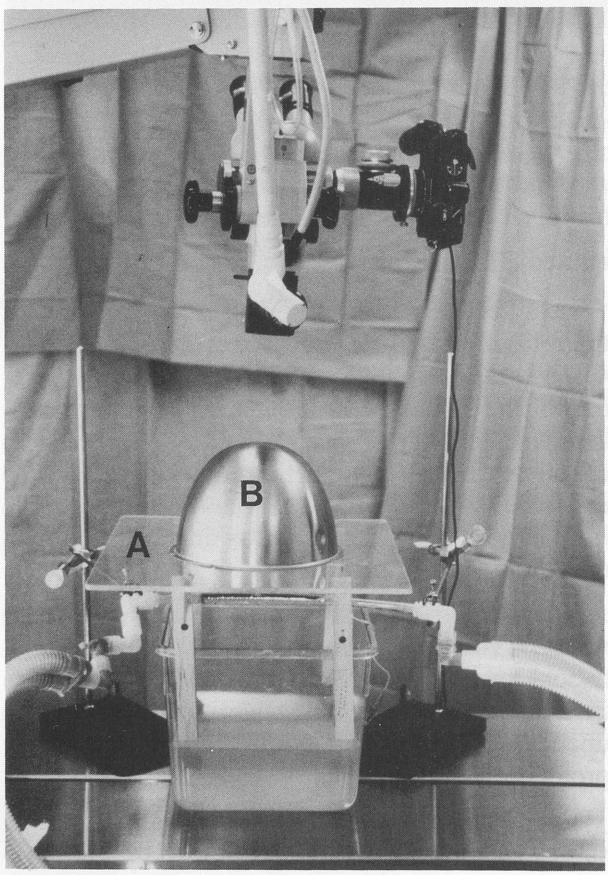

Fig 3. Close-up showing sheet of Plexiglas (A) and metal dome (B).

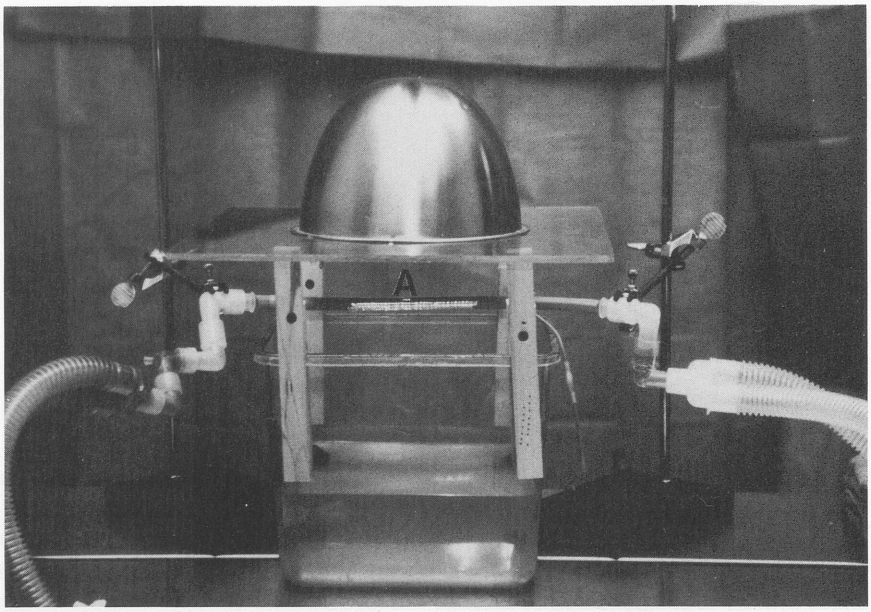

Fig 4. Red rubber endotracheal tube (A) wrapped with reflective metallic tape during irradiation.

each experiment; all power outputs were recorded in the laboratory workbook. The laser was used at powers of 40 W (35,273 W/cm^2), 35 W (30,864 W/cm^2), 30 W (26,455 W/cm^2), 25 W (22,046 W/cm^2), 20 W (17,637 W/cm^2), and 15 W (13,228 W/cm^2), respectively, in the continuous mode for up to 180 seconds or until a fire occurred. The time in seconds required by the laser to ignite the tube was recorded. The angle of incidence was 90°. A red rubber tube wrapped with the reflective metallic tape is shown in Fig 4. When the tubes were irradiated through blood, three to five drops of heparinized dog blood were applied to the surface of the tube to achieve a height of approximately 2 mm with a diameter of 5 mm. The maximum continuous power that each tube could tolerate in the presence of blood without evidence of fire was determined and compared with results previously obtained for these tubes in the absence of blood.

RESULTS

The Rusch red rubber and Mallinckrodt PVC ETTs wrapped with reflective metallic tape, the Mallinckrodt ETT wrapped with Americal Laser Guard, the Mallinckrodt Laser Flex ETT, and the Xomed-Treace Laser Shield II ETT irradiated in this study demonstrated a wide range of incendiary characteristics, especially when irradiated through blood. The Rusch red rubber tube wrapped with reflective metallic tape did not ignite when irradiated at 40 W (35,273 W/cm^2) for 180 seconds in the presence of 100% oxygen. However, when irradiated through blood, this same tube wrapped with the same tape withstood only 25 W (22,046 W/cm^2) for 180 seconds, also in the presence of 100% oxygen (Table 1).

The Mallinckrodt PVC tube wrapped with reflective metallic tape withstood 40 W (35,273 W/cm^2) of irradiation for 180 seconds in the presence of 100% oxygen. In the presence of blood, the metallic-taped PVC tube ignited at all power levels greater than 25 W (22,046 W/cm^2) when irradiated for 180 seconds with 100% oxygen flowing through the tube (Table 2). Figure 5 demonstrates a laser-ignited ETT with the Mallinckrodt PVC tube wrapped with reflective

TABLE 1. RED RUBBER TUBE WITH REFLECTIVE METALLIC TAPE

		Onset of Fire	
Power (W)	*Blood*	*Yes/No*	*Time (s)*
40	–	No	180
40	–	No	180
40	–	No	180
40	–	No	180
40	–	No	180
40	+	No	180
40	+	Yes	80
40	+	Yes	130
40	+	Yes	60
40	+	Yes	40
30	+	No	180
30	+	No	180
30	+	No	180
30	+	Yes	110
30	+	Yes	123
25	+	No	180
25	+	No	180
25	+	No	180
25	+	No	180
25	+	No	180

All fires were extraluminal.



Fig 5. Laser-ignited endotracheal tube fire (A) with Mallinckrodt polyvinyl chloride tube wrapped with reflective metallic tape.

metallic tape.

The Mallinckrodt PVC tube wrapped with Americal Laser Shield, dry and wet, withstood 35 W (30,864 W/cm^2) of continuous laser irradiation with 100% oxygen flowing through the tube both in the absence and in the presence of blood (Tables 3 and 4). On the days that this tube was tested the laser delivered 35 W as its maximum output.

The Mallinckrodt Laser Flex ETT tolerated only 20 W (17,637 W/cm^2) of continuous laser irradiation with 100% oxygen flowing at 3 L/min in the absence of blood. When three to five drops of blood were placed on this tube, the maximum power that the tube would tolerate dropped to 15 W (13,228 W/cm^2). The results for this tube are shown in Table 5.

The Xomed-Treace Laser Shield II ETT tolerated 40 W of continuous power with a 100% oxygen flow of 3 L/min in the absence of blood. When three to five drops of blood were placed on this tube, the maximum power that this new ETT would tolerate dropped to 25 W (22,046 W/cm^2); these data are listed in Table 6.

TABLE 2. MALLINCKRODT POLYVINYL CHLORIDE TUBE WITH REFLECTIVE METALLIC TAPE

		Onset of Fire	
Power (W)	*Blood*	*Yes/No*	*Time (s)*
40	–	No	180
40	–	No	180
40	–	No	180
40	–	No	180
40	–	No	180
30	+	No	180
30	+	Yes*	170
30	+	Yes†	30
30	+	No	180
30	+	No	180
25	+	No	180
25	+	No	180
25	+	No	180
25	+	No	180
25	+	No	180

* Intraluminal.
† Extraluminal.

DISCUSSION

This study was conducted to determine if the presence of blood affected the incendiary characteristics of ETTs irradiated with the CO_2 laser. Tubes tested included the Xomed Treace Laser Shield II, the Mallinckrodt Laser Flex, the Mallinckrodt PVC tube wrapped with reflective metallic tape or Americal Laser Guard, and a Rusch red rubber tube wrapped

TABLE 3. MALLINCKRODT POLYVINYL CHLORIDE TUBE WITH AMERICAL LASER SHIELD (WET)

		Onset of Fire	
Power (W)	*Blood*	*Yes/No*	*Time (s)*
35	–	No	180
35	–	No	180
35	–	No	180
35	–	No	180
35	–	No	180
35	+	No	180
35	+	No	180
35	+	No	180
35	+	No	180
35	+	No	180

Thirty-five watts was maximum laser output.

TABLE 4. MALLINCKRODT POLYVINYL CHLORIDE TUBE WITH AMERICAL LASER SHIELD (DRY)

		Onset of Fire	
Power (W)	*Blood*	*Yes/No*	*Time (s)*
35	–	No	180
35	–	No	180
35	–	No	180
35	–	No	180
35	–	No	180
35	+	No	180
35	+	No	180
35	+	No	180
35	+	No	180
35	+	No	180

Thirty-five watts was maximum laser output.

with reflective metallic tape. The experimental methods employed in this study measured the time to ignition (extraluminal or intraluminal fire) or the designated end point of 180 seconds. It was felt that the time to ignition would best characterize the incendiary properties of each tube or tube-wrapping combination.

The materials and methods used to perform this study are important because of the use of the Sharplan Acuspot 710.

To the best of our knowledge, this paper represents the first time that the incendiary properties of ETTs have been reported with use of a microspot micromanipulator. The fact that the new production model of the Acuspot 710 delivers a 250-μm spot size rather than the 380-μm spot characteristic of the prototype used in this experiment is significant because of the resultant higher power densities achieved at each power setting. The current generation of microspot micromanipulators represents the state of the art for laser microsurgery of the larynx for both benign and malignant lesions.[27,28] The power density of 35,273 W/cm^2 achieved with the prototype Acuspot 710 with a 380-μm spot size will be increased substantially to 81,633 W/cm^2 with the use of the production model, with its 250-μm spot size.

TABLE 5. MALLINCKRODT LASER FLEX

		Onset of Fire	
Power (W)	*Blood*	*Yes/No*	*Time (s)*
30	–	Yes	135
25	–	No	180
25	–	Yes	80
20	–	No	180
20	–	No	180
20	–	No	180
20	–	No	180
20	–	No	180
20	+	Yes	22
20	+	Yes	113
20	+	Yes	85
20	+	Yes	40
20	+	Yes	90
15	+	No	180
15	+	No	180
15	+	No	180
15	+	No	180
15	+	No	180

All fires were intraluminal.

TABLE 6. XOMED-TREACE LASER SHIELD II

		Onset of Fire	
Power (W)	*Blood*	*Yes/No*	*Time (s)*
40	–	No	180
40	–	No	180
40	–	No	180
40	–	No	180
40	–	No	180
30	+	No	180
30	+	No	180
30	+	Yes	19
30	+	Yes	15
30	+	No	180
25	+	No	180
25	+	No	180
25	+	No	180
25	+	No	180
25	+	No	180

Both fires were intraluminal.

All power densities used in this study greatly exceeded the power density range of 1,200 W/cm^2 to 1,800 W/cm^2 normally used in CO_2 laser microsurgery of the larynx. Regardless, the findings are significant because of the noted effects of blood on the incendiary characteristics of the ETTs and protective wrappings used in this experiment.

Analysis of the experimental results revealed that the presence of blood did not affect the incendiary properties of the Mallinckrodt ETT wrapped with Americal Laser Guard. All other tubes and wrappings demonstrated a lower ignition threshold in the presence of blood. The fact that the Americal product uses silver rather than the aluminum used in the reflective metallic tape may be the reason for the differences noted in this study. Further studies are warranted to determine if this is true. As noted in the literature review, the effect of blood on the incendiary properties of ETTs irradiated with the CO_2 laser has not been previously reported. The results of this study, then, suggest that blood and other pharyngeal secretions should be wiped off those areas of the ETT

exposed to the CO_2 laser beam during microlaryngeal laser surgery. This practice will decrease the risk of a laser-ignited ETT fire. Saline-saturated neurosurgical cottonoids can be used to gently wipe all blood and other pharyngeal contaminants from the tube and/or protective tape. Although the results of this study strongly demonstrate that the Americal Laser Guard was not affected by the presence of blood, these findings should not be considered an endorsement of one tube or wrapping tape over another.

All power densities used greatly exceeded the normal microlaryngeal operating conditions. Most otolaryngologist–head and neck surgeons use the CO_2 laser in the shuttered (pulsed) mode for laryngeal surgery. None of these tubes and wrapping tapes were tested in the shuttered mode. Most laryngeal microsurgeons use no greater than a 40% oxygen concentration diluted in helium, nitrogen, or air when performing CO_2 laser surgery. All trials in this study were performed in 100% oxygen. However, since present-generation CO_2 lasers cannot be programmed to eliminate the continuous mode option from their console, the possibility exists that the laser nurse could depress the continuous button. This would jeopardize all tubes except the Americal Laser Guard–protected tube, if blood happened to be present on the ETT.

The incendiary characteristics of the Americal Laser Guard tape wrapped on a PVC tube were not changed in the presence of blood. We do not, however, recommend using the PVC tube with the Americal Laser Guard. The PVC tube has been shown to be more incendiary than the red rubber tube,[29] and it is possible that the unprotected cuff or distal end of a PVC tube wrapped with Americal Laser Guard could ignite. It is also possible that an area of the tube could be left unprotected if some of the Americal Laser Guard or other protective tape were to be accidentally scraped from or disengaged from the ETT during exposure of the larynx with the laryngoscope or other surgical maneuver. The presence of blood in such a case would further increase the risk of a laser-ignited ETT fire.

The microspot, which is not yet being used by all otolaryngologist–head and neck surgeons currently performing CO_2 laser surgery of the larynx, was used in this study. The spot sizes achievable with the microspot represent the present and probable future of laryngeal laser surgery with the CO_2 laser. If lower, more surgically realistic power settings had been used, we might not have been able to demonstrate that the presence of blood had an effect on the incendiary properties of the ETT and protective tapes. Sosis et al[24,25] have recently been publishing their work using high power (70 W) with a standard micromanipulator. Our testing protocol parallels that of Sosis et al, in performing these tests under extreme conditions rather than under normal clinical conditions, to better assess the incendiary characteristics of these tubes and protective tapes.

CONCLUSIONS

On the basis of the results of this study, the presence of blood did affect the incendiary properties of Rusch red rubber and Mallinckrodt PVC ETTs wrapped with reflective metallic tape, Mallinckrodt Laser Flex endotracheal tubes, and Xomed-Treace Laser Shield II endotracheal tubes. Only Americal Laser Guard protective wrap was not affected by the presence of blood. Great care must be exercised by laryngeal microsurgeons to make certain that they wipe all blood off the exposed shaft and other areas of the ETT when performing microlaryngeal CO_2 laser surgery.

REFERENCES

1. Strong MS, Jako GJ. Laser surgery in the larynx. Early clinical experience with continuous CO_2 laser. Ann Otol Rhinol Laryngol 1972;81:791-8.

2. Strong MS, Jako GJ, Polanyi T,Wallace RA. Laser surgery in the aerodigestive tract. Am J Surg 1973;126:529-33.

3. Andrews AH Jr, Moss HW. Experiences with the carbon dioxide laser in the larynx. Ann Otol Rhinol Laryngol 1974; 83:462-70.

4. Snow JC, Kripke BJ, Strong MS, Jako GJ, Meyer MR, Vaughan CW. Anesthesia for carbon dioxide laser microsurgery on the larynx and trachea. Anesth Analg 1974;53:507-12.

5. Konchigeri HN, Shaker MH. Anesthesia for intralaryngeal laser surgery. Can Anaesth Soc J 1974;21:343-9.

6. Snow JC, Norton ML. Lasers and anesthesia. J Am Assoc Nurse Anesth 1975;43:464-9.

7. Norton ML, de Vos P. New endotracheal tube for laser surgery of the larynx. Ann Otol Rhinol Laryngol 1978;87:554-7.

8. Benjamin B, Gronow D. A new tube for microlaryngeal surgery. Anesth Intensive Care 1979;7:258-63.

9. Patil V, Stehling LC, Zauder HL. A modified endotracheal tube for laser microsurgery. Anesthesiology 1979;51:571.

10. Hirshman CA, Smith J. Indirect ignition of the endotracheal tube during carbon dioxide laser surgery. Arch Otolaryngol 1980;106:639-41.

11. Vourc'h G, Tannieres ML, Freche G. Anaesthesia for microsurgery of the larynx using a carbon dioxide laser. Anaesthesia 1979;34:53-7.

12. Meyers A. Complications of CO_2 laser surgery of the larynx. Ann Otol Rhinol Laryngol 1981;90:132-4.

13. Schramm VL Jr, Mattox DE, Stool SE. Acute management of laser-ignited intratracheal explosion. Laryngoscope 1981;91:1417-26.

14. Treyve E, Yarington CT Jr, Thompson GE. Incendiary characteristics of endotracheal tubes with the carbon dioxide

laser. An experimental study. Ann Otol Rhinol Laryngol 1981; 90:328-30.

15. Yarington CT Jr, Thompson GE. Incendiary characteristics of endotracheal tubes with the carbon dioxide laser. Supplemental report. Ann Otol Rhinol Laryngol 1982;91:605.

16. Patel KF, Hicks JN. Prevention of fire hazards associated with use of carbon dioxide lasers. Anesth Analg 1981;60:885-8.

17. LeJeune FE Jr, Guice C, LeTard F, Marice H. Heat sink protection against lasering endotracheal cuffs. Ann Otol Rhinol Laryngol 1982;91:606-7.

18. Healy GB, Strong MS, Shapshay S, Vaughan C, Jako G. Complications of CO2 laser surgery of the aerodigestive tract: experience of 4416 cases. Otolaryngol Head Neck Surg 1984; 92:13-8.

19. Ossoff RH, Hotaling AJ, Karlan MS, Sisson GA. CO2 laser in otolaryngology-head and neck surgery: a retrospective analysis of complications. Laryngoscope 1983;93:1287-9.

20. Fried MP. A survey of the complications of laser laryngoscopy. Arch Otolaryngol 1984;110:31-4.

21. Pashayan AG, Gravenstein JS. Helium retards endotracheal tube fires for carbon dioxide lasers. Anesthesiology 1985; 62:274-7.

22. Lim RY, Kenney CL. Precaution and safety in carbon dioxide laser surgery. Otolaryngol Head Neck Surg 1986;95:239-41.

23. Ossoff RH. Laser safety in otolaryngology–head and neck surgery: anesthetic and educational considerations for laryngeal surgery. Laryngoscope 1989;99(suppl 48).

24. Sosis M, Dillon F, Heller S. Rubber and PVC endotracheal tube cuffs are highly vulnerable to the CO2 laser. Anesth Analg 1990;70:S1-S450.

25. Sosis MB. Airway fire during CO2 laser surgery using a Xomed laser endotracheal tube. Anesthesiology 1990;72:747-9.

26. Laser Q-switching-giant pulses. In: Laser technology. Laser electro-optics technology series. Waco, Tex: Center for Occupational Research and Development, 1985:260-314.

27. Shapshay SM, Wallace RA, Kveton JF, Hybels RL, Setzer SE. New microspot micromanipulator for CO2 laser application in otolaryngology–head and neck surgery. Otolaryngol Head Neck Surg 1988;98:179-81.

28. Ossoff RH, Werkhaven JA, Raif J, Abraham M. Advanced microspot microslad for the CO2 laser. Otolaryngol Head Neck Surg 1991;105:411-4.

29. Ossoff RH, Duncavage JA, Eisenman TS, Karlan MS. Comparison of tracheal damage from laser-ignited endotracheal tube fires. Ann Otol Rhinol Laryngol 1983;92:333-6.

POINT-TOUCH TECHNIQUE OF BOTULINUM TOXIN INJECTION FOR THE TREATMENT OF SPASMODIC DYSPHONIA

DAVID C. GREEN, MD
SEATTLE, WASHINGTON
PAUL H. WARD, MD
LOS ANGELES, CALIFORNIA
GERALD S. BERKE, MD
LOS ANGELES, CALIFORNIA
BRUCE R. GERRATT, PHD
LOS ANGELES, CALIFORNIA

Intralaryngeal injections of botulinum toxin (Botox), under electromyographic guidance, have emerged as an effective treatment for adductor spasmodic dysphonia. To remain effective, these injections must be repeated every 3 to 9 months as the symptoms recur. One drawback to the current method is the need for electromyographic confirmation of needle placement into the thyroarytenoid muscle. This report describes an anatomic approach to Botox injection that requires only flexible nasopharyngeal endoscopy and careful evaluation of the anatomic landmarks. This technique has been used successfully on 13 patients, and objective pretreatment and posttreatment measures are reported.

KEY WORDS — botulinum injection, laryngeal dystonia, spastic dysphonia.

INTRODUCTION

Spasmodic dysphonia is a serious voice disorder characterized by a strained or strangled voice, and it often interrupts the fluency of continuous speech. Since the first description of the disorder by Traube[1] in 1871, its exact cause and treatment have been the subject of controversy.

In the past, this disorder was thought to reflect psychiatric problems. More recently, Blitzer et al[2] found through clinical and electromyography (EMG) evaluation that many patients with "spastic dysphonia" actually have a dystonia. Dystonia is a neurologic disorder of motor control processing characterized by abnormal, often action-induced, involuntary movements or uncontrolled spasms. The cause is usually idiopathic. The dystonia may be restricted to the larynx or present in other areas of the body as well, such as blepharospasm.[2]

There are a variety of treatments for adductor spastic dysphonia, which include speech therapy, psychotherapy, biofeedback, systemic medicine, nerve section, botulinum toxin (Botox) injection, and thyroplasty. Dedo[3] was the first to describe recurrent laryngeal nerve section as a treatment for spastic dysphonia. The aim was to achieve a voice that was slightly breathy but easier to produce. After a 3-year follow-up, his group[4] reported a 10% to 15% recurrence rate according to patient self-evaluations. Aronson and DeSanto[5] reported an initial success rate of 97% at 6 months for recurrent laryngeal nerve section. This success rate fell to 36% at 3 years' follow-up. The failures showed gradual hyperadduction of the intact vocal fold against the paralyzed fold. This was thought to be due to a worsening of the patient's underlying neurologic condition.

Biller et al[6] reported, in 1979, crushing the recurrent laryngeal nerve as a treatment for spastic dysphonia. Although all patients had initial improvement, only 13% were improved at 3 years' follow-up.[7]

Blitzer et al[8,9] reported the first series of patients with focal laryngeal dystonia to be treated with local vocal fold injection of Botox. This toxin acts presynaptically at nerve terminals to prevent calcium-dependent release of acetylcholine, which results in muscle paralysis. There were five patients in their series, and all, within 2 to 3 days, experienced benefit that lasted 3 to 6 months. Although the authors initially injected only one vocal fold, they now perform bilateral injections. There were no systemic side effects from the injections, but they state that the long-term systemic or local laryngeal effects are unknown.

Using EMG, Ludlow et al[10] studied patients with adductor spastic dysphonia who failed unilateral recurrent laryngeal nerve section. They found that some of the failures were due, at least in part, to reinnervation of the thyroarytenoid muscle by the previously sectioned recurrent laryngeal nerve, and that compensation by the nonoperated side may have

From the Division of Head and Neck Surgery, University of California at Los Angeles, and the West Los Angeles Veterans Administration Medical Center, Los Angeles, California.

Presented at the meeting of the American Laryngological Association, Waikoloa, Hawaii, May 4-5, 1991.

REPRINTS — Gerald S. Berke, MD, Division of Head and Neck Surgery, UCLA, 10833 Le Conte Ave, Los Angeles, CA 90024-1624.

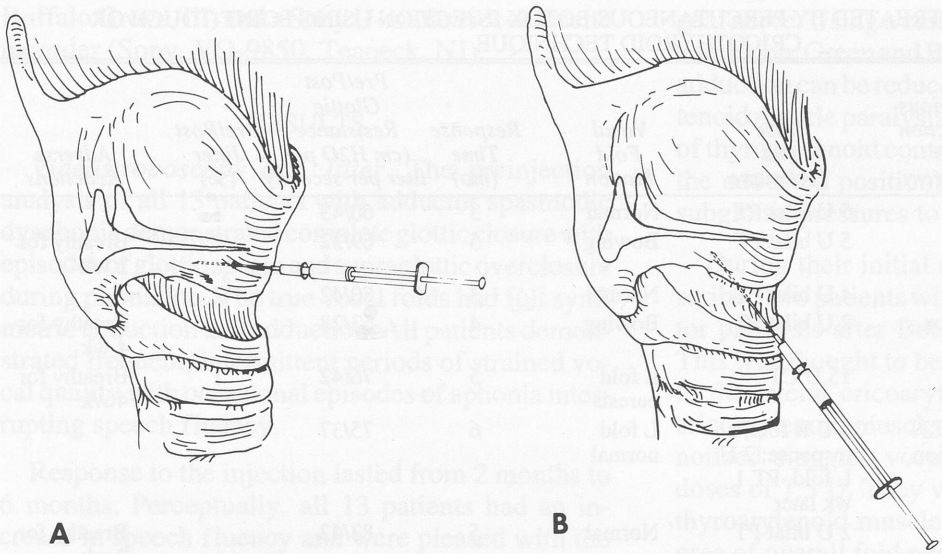

Location and direction of needle placement for transcutaneous injection of botulinum toxin into ipsilateral thyroarytenoid muscle. A) Through thyroid cartilage. B) Through cricothyroid membrane.

played a role in others.[10] They treated these patients successfully with Botox injections.

Initial reports of Botox injections of the true vocal fold have relied on EMG localization of the thyroarytenoid muscle for injection. Recently, Ford et al[11] described an indirect laryngoscopic approach to Botox injection in which all patients studied demonstrated objective improvement after injection.

The technique for transcutaneous injection of the vocal fold was first described in connection with Teflon injections as a treatment for unilateral vocal fold paralysis.[12] Ward et al[13] described insertion of a needle through the cricothyroid membrane into the subglottic space with monitoring of the actual fold injection through a fiberoptic nasopharyngoscope or a Hopkins rod laryngoscope. Hirano et al[14] described a transcutaneous vocal fold injection technique in which the needle is inserted through the cricothyroid membrane directly into the edge of the vocal fold.

This report describes a relatively safe and accurate transcutaneous method of Botox injection that requires only flexible nasopharyngeal endoscopy.

METHODS AND SUBJECTS

Injection Technique. The patient was seated in an examination chair. Palpation of the neck was used to mark the outline of the thyroid and cricoid cartilage on the anterior neck skin with a surgical marking pen.

The nose and pharynx were topically anesthetized with lidocaine 2% spray. A flexible nasopharyngoscope (Olympus, Los Angeles, Calif) was passed through the nose into the hypopharynx to visualize the true vocal folds. The fiberscopic laryngeal image was viewed on a television screen and recorded on videotape.

The cutaneous needle injection site was prepared with alcohol. The injection was given with a 2-mL syringe and a 1.5-in 27-gauge needle. The injected material was botulinum A toxin (Oculinum Inc, Berkeley, Calif) that was supplied as a freeze-dried residue of the toxin at a concentration of 50 ng per vial (140 U). The freeze-dried toxin was stored at –20°C and reconstituted with 0.9% saline at a concentration of 25 U/mL and used immediately.

The injection was given through the thyroid cartilage into the ipsilateral thyroarytenoid muscle unless the cartilage was ossified (see Figure, A). The needle was oriented at 90° to the skin of the neck and directed posteriorly in the sagittal plane. From the previously marked outline of the thyroid cartilage the approximate location of the anterior commissure of the vocal folds was estimated as midway between the thyroid notch and the bottom edge of the thyroid cartilage, in the midline.[15] The needle was placed 5 mm lateral and 5 mm inferior to this point. No previous or concurrent injections of local anesthetic were required. The accuracy of needle placement is assured by pointing the needle, on the basis of anatomic landmarks, into the ipsilateral thyroarytenoid muscle. The correct depth of needle penetration is judged by sensing the depth at which the needle passes through the thyroid cartilage to permit easy injection of toxin. While the needle is within the cartilage, injection pressures are high because of the density of the cartilage matrix. With further penetration, the injection pressure becomes low as the needle enters the thyroarytenoid muscle. We have termed this method the point-touch technique. Adequate needle positioning is confirmed through the flexible nasopharyngoscope before injection. Initially, 5 U of toxin was injected bilaterally by the point-touch technique. However, 2 U is routinely given now in order to

INITIAL 13 PATIENTS TREATED BY PERCUTANEOUS BOTOX INJECTION USING POINT-TOUCH OR CRICOTHYROID TECHNIQUE

Patient No.	Length of Symptoms (y)	Previous Injection or Surgery	Dose and Technique	Vocal Fold Motion	Response Time (mo)	Pre/Post Glottic Resistance (cm H2O per liter per second)	Pre/Post Jitter (%)	Adverse Reactions
1	2		5 U bilat PT	Normal	3	60/43		
2	7		5 U bilat PT	Bowing	5	69/32	3	Breathy for 2 wk
3	7		4 U bilat PT	Normal	3	80/42	2	
4	6	Botox	2 U bilat PT	Bowing	4	63/28		Breathy for 4 wk
5	7		15 U CT	L fold paresis	5	76/42	1	Breathy for 4 wk
6	10	R RLN section	4 U R fold, no response; 2 U L fold, PT 1 wk later	L fold normal	6	75/37		
7	5		2 U bilat PT	Normal	5	83/42		Breathy for 2 wk
8	6		2 U bilat PT	Normal	6	90/50		2 wk before improvement
9	5	Botox	2 U bilat PT	Normal	5			
10	6	Botox	1 U bilat PT	Normal	2			
11	5		2 U bilat PT	Normal	5	72/40	4	
12	10		15 U L fold CT	L fold paralysis	4	70/—		
13	10		2 U bilat PT	Bowing	4	84/40		Breathy for 3 wk

RLN — recurrent laryngeal nerve, PT — point-touch trans–thyroid cartilage technique, CT — cricothyroid membrane technique.

reduce the incidence of vocal fold bowing and breathiness.

If the thyroid cartilage could not be penetrated with the needle because of ossification, the injection was performed through the cricothyroid membrane (see Figure, B). In this case, the needle was placed just under the edge of the thyroid cartilage, approximately 1.5 cm from the midline, and directed superiorly, medially, and posteriorly. The proper depth of penetration and accuracy of needle placement into the ipsilateral thyroarytenoid muscle were monitored through the flexible nasopharyngoscope. Patients undergoing transcutaneous cricothyroid injection routinely receive 15 U into one vocal fold.

Subjects and Evaluation of Vocal Function. During the period April 1990 to October 1991, a total of 13 patients (5 men and 8 women) with a diagnosis of adductor spasmodic dysphonia underwent transcutaneous intrafold injection. The Table describes these 13 patients. The length of symptoms varied from 2 years to 10 years. Three of the 13 patients had undergone previous Botox injection with EMG control. One patient had previously undergone a right recurrent laryngeal nerve section. The usual dose for most patients was 2 U. Three patients developed vocal fold bowing after injection, and 2 patients after cricothyroid injection developed a fold paresis or paralysis.

Each patient was evaluated by an otolaryngologist and a speech pathologist. Ten of the 13 patients had previously seen a neurologist. Their ages ranged from 32 to 74 years with a mean of 50 years. Eleven of 13 patients underwent preinjection vocal function evaluation consisting of laryngostroboscopy, acoustic analysis of sustained phonation, and laryngeal resistance estimation. In addition, a 1-minute speech monologue was recorded. Of these 13 patients, 4 had acoustic measurements both before and after Botox injection, consisting of jitter of the vowel /a/. Ten of the 13 patients underwent both preinjection and postinjection evaluation of laryngeal resistance by the technique described by Smitheran and Hixon[16] with a modification: to reduce the chance that quick fluctuations in phonation influenced the results, we averaged the amplitude of the airflow signal over the steady-state, vocalic portion of the syllables, rather than measuring the amplitude of one point in the middle of the syllable.

For stroboscopic imaging of the larynx, a Bruel & Kjaer laryngostrobe unit (model 4914, Orange, Calif) was used. The stroboscope was connected to a Wolf 90° telescope via a fluid-filled light cable. The image was detected by a Toshiba CCD (charge-coupled device) video camera (Toshiba IK-C30A,

Buffalo Grove, Ill) and a Sony U-matic videocassette recorder (Sony, VO-9850, Teaneck, NJ).

RESULTS

Videostroboscopy and Jitter. The preinjection analysis of all 13 patients with adductor spasmodic dysphonia demonstrated complete glottic closure with episodes of glottic spasm and supraglottic overclosure during phonation. The true vocal folds had full symmetric abduction and adduction. All patients demonstrated frequent, intermittent periods of strained vocal quality with occasional episodes of aphonia interrupting speech fluency.

Response to the injection lasted from 2 months to 6 months. Perceptually, all 13 patients had an increase in speech fluency and were pleased with the result. Moreover, they have all returned for subsequent injections. The Table presents subject information and results after injection. Our findings indicate the 95% confidence interval of vocal tract resistance is 37 to 51 cm H_2O per liter per second for normally speaking men and 41 to 57 cm H_2O per liter per second for normally speaking women. (See similar normative results reported by Netsell et al.[17]) Although normative values for laryngeal resistance varied with sex and age, 10 of the 11 patients evaluated for laryngeal resistance demonstrated elevated laryngeal resistance before injection. Nine of these 10 subjects returned to the normal range 4 weeks after injection. The Table also compares the preinjection and postinjection percent jitter for 4 of the 13 injected patients. Three of the 4 patients had a decrease in jitter after injection. The one patient with an increase in jitter qualitatively demonstrated a breathy voice, although with increased fluency in continuous speech. The mean preinjection jitter for these 4 patients was 2.08%, compared to the postinjection value of 0.682%. There were no patients in this group with a posterior glottic chink leak during phonation after injection.

Complications. There were no airway complications or infectious complications from this method. All patients, immediately after injection, had a mild degree of true vocal fold edema that resolved. There were no cases of postinjection aspiration. The major adverse reaction included breathiness, lasting a maximum of 4 weeks in 5 of the 13 patients. One patient noted improvement 2 weeks after the injection, rather than the typical 36 hours.

DISCUSSION

The Botox injections paralyze the thyroarytenoid muscle by blocking the release of acetylcholine from the presynaptic nerve terminals of the recurrent laryngeal nerve. Using a canine model of laryngeal hyperadduction, Green and Berke[18] have shown that hyperadduction can be reduced through selective thyroarytenoid muscle paralysis alone. The unilateral absence of thyroarytenoid contraction (despite a vocal fold in the adducted position) allowed the intraglottic and subglottic pressures to fall during phonation.

During their initial experience, Miller et al[19] described two patients with unilateral vocal fold adductor paralysis after Botox injection of 20 and 30 U. This was thought to be due to migration of the toxin to the lateral cricoarytenoid muscle. The posterior cricoarytenoid muscle was not affected. Brin et al[20] noticed sluggish vocal fold motion with injection doses of 7.5 U. They were able to achieve selective thyroarytenoid muscle paralysis and reduce the degree of overall fold paralysis by injecting both folds with a reduced dose of 3.75 U. The point-touch technique presented in this report was also able to achieve selective thyroarytenoid muscle paralysis bilaterally with preservation of vocal fold adduction and abduction. It should be noticed that the three patients who had previously undergone Botox injection using EMG-guided injection underwent injection of the same number of units using the point-touch technique with the same effective response.

This study found subjective perceptual improvements in speech fluency in all patients after injection. Also, all patients evaluated before and after injection in this study showed improvement in laryngeal resistance with this technique. In one patient, the improvement in fluency was not accompanied by a decrease in jitter because of an increase in the breathiness of the patient's phonation after injection. This patient was pleased with the result despite the increase in jitter. This problem emphasizes the need to examine a wide variety of speech variables, including measures of continuous speech and pitch breaks, to more fully document patients' speech.

The optimal treatment for spasmodic dysphonia, like its fundamental cause, has yet to be found. Until more is known about the disorder, treatments will continue to be directed at the laryngeal symptoms it produces. Although Botox injections do improve the patient's ability to phonate, the improvement is not permanent. Reinjection is required every 3 to 6 months.

The advantages of the transcutaneous injection of Botox are as follows.

1. No EMG equipment or EMG technician is required.
2. The working distance is shorter than the transoral route.

3. Patients with a sensitive gag reflex or difficulty with full mouth opening can be injected.

The disadvantages are as follows:

1. The procedure requires a flexible nasopharyngoscope.
2. A second person is required to hold the nasopharyngoscope during injection.
3. In obese patients the external laryngeal landmarks may be difficult to locate.
4. Successful placement of the needle requires a working knowledge of the intralaryngeal position of the thyroarytenoid muscle as discerned from external laryngeal landmarks.

Efforts have been made to obtain permanent selective bilateral paralysis of the thyroarytenoid muscle surgically. Carpenter et al[21] divided the adductor branch of the recurrent laryngeal nerve in dogs and humans. This procedure was able to preserve the abductor movement of the vocal fold, but eliminated the adductor movement, as well as thyroarytenoid muscle contraction. This operation holds out the promise of a permanent selective denervation of the thyroarytenoid muscle. In the interim, the point-touch technique of Botox injection will allow patients with spasmodic dysphonia to be effectively treated by otolaryngologists within their own communities.

REFERENCES

1. Traube L. Spastishe Form der Nervousen Helserkeit. In: Gesammelte zur Pathologie und Physiologie. Vol 2. Berlin: Hirschwald, 1871.

2. Blitzer A, Lovelace RE, Brin MF, Fahn S, Fink ME. Electromyographic findings in focal laryngeal dystonia (spastic dysphonia). Ann Otol Rhinol Laryngol 1985;94:591-4.

3. Dedo HH. Recurrent laryngeal nerve section for spastic dysphonia. Ann Otol Rhinol Laryngol 1976;85:451-9.

4. Izdebski K, Dedo HH, Shipp T, Flower RM. Postoperative and follow-up studies of spastic dysphonia patients treated by recurrent laryngeal nerve section. Otolaryngol Head Neck Surg 1981;89:96-101.

5. Aronson AE, DeSanto LW. Adductor spastic dysphonia: three years after recurrent laryngeal nerve section. Laryngoscope 1983;93:1-8.

6. Biller HF, Som ML, Lawson W. Laryngeal nerve crush for spastic dysphonia. Ann Otol Rhinol Laryngol 1979;88:531-2.

7. Biller HF, Som ML, Lawson W. Laryngeal nerve crush for spastic dysphonia. Ann Otol Rhinol Laryngol 1983;92:469.

8. Blitzer A, Brin MF, Fahn S, Lange D, Lovelace RE. Letter to the editor. Laryngoscope 1986;96:1300-1.

9. Blitzer A, Brin MF, Fahn S, Lovelace RE. Localized injections of botulinum toxin for the treatment of focal laryngeal dystonia (spastic dysphonia). Laryngoscope 1988;98:193-7.

10. Ludlow CL, Naunton RF, Fujita M, Sedory SE. Spasmodic dysphonia: botulinum toxin injection after recurrent nerve surgery. Otolaryngol Head Neck Surg 1990;102:122-31.

11. Ford CN, Bless DM, Lowery JD. Indirect laryngoscopic approach for injection of botulinum toxin in spasmodic dysphonia. Otolaryngol Head Neck Surg 1990;103:752-8.

12. Seifert A. Perkutane Paraffininjektion zur Beseitigung der Folgen Einseitiger Stimmgandlaehmung. Z Laryngol Rhinol Otol Ihre Grenzgeb 1916;8:233-5.

13. Ward PH, Hanson DG, Abemayor E. Transcutaneous Teflon injection of the paralyzed vocal cord: a new technique. Laryngoscope 1985;95:644-9.

14. Hirano M, Tanaka S, Tanaka Y, Hibi S. Transcutaneous intrafold injection for unilateral vocal fold paralysis: functional results. Ann Otol Rhinol Laryngol 1990;99:598-604.

15. Koufman JA. Laryngoplasty for vocal cord medialization: an alternative to Teflon. Laryngoscope 1986;96:726-31.

16. Smitheran JR, Hixon TJ. A clinical method for estimating laryngeal airway resistance during vowel production. J Speech Hear Disord 1981;46:138-46.

17. Netsell R, Lotts W, Duchane AS, Barlow SM. Vocal tract aerodynamics during syllable production: normative data and theoretical implications. J Voice 1991;5:1-9.

18. Green DC, Berke GS. An in vivo canine model for testing treatment effects in laryngeal hyperadduction disorders. Laryngoscope 1990;100:1229-35.

19. Miller RH, Woodson GE, Jankovic J. Botulinum toxin injection of the vocal fold for spasmodic dysphonia. A preliminary report. Arch Otolaryngol Head Neck Surg 1987;113:603-5.

20. Brin MF, Blitzer A, Fahn S, Gould W, Lovelace RE. Adductor laryngeal dystonia (spastic dysphonia): treatment with local injections of botulinum toxin (Botox). Movement Disord 1989;4:287-96.

21. Carpenter RJ III, Snyder GG III, Henley-Cohn JL. Selective section of the recurrent laryngeal nerve for the treatment of spastic dysphonia: an experimental study and preliminary clinical report. Otolaryngol Head Neck Surg 1981;89:986-91.

PHYSIOLOGIC ASSESSMENT OF ARYTENOID ADDUCTION

DAVID H. SLAVIT, MD
BROOKLYN, NEW YORK

NICOLAS E. MARAGOS, MD
ROCHESTER, MINNESOTA

Arytenoid adduction as described by Isshiki is a surgical technique used to improve vocal quality by adducting the arytenoid cartilage of a paralyzed vocal fold, medializing the fold, and closing the posterior glottic aperture. Surgical results of this operation were evaluated by preoperative and postoperative voice recordings, laryngoscopy, and stroboscopy. Objective measurements of vocal jitter, shimmer, and signal to noise ratio were done to assess changes in the vibratory patterns, and analysis of data from 12 patients revealed improved glottic function postoperatively. Often an anterior medialization procedure, primarily a type I thyroplasty, was used to supplement the posterior medialization achieved by adduction of the arytenoid. Arytenoid adduction is recommended as an effective and reliable treatment for posterior glottic insufficiency.

KEY WORDS — arytenoid adduction, larynx, vocal fold paralysis, voice.

INTRODUCTION

Arytenoid adduction as described by Isshiki et al[1,2] is a surgical technique used to improve vocal quality and glottic competence. It has been used primarily in Japan since the 1970s, but recently has been used by various otolaryngologists in the United States. This procedure adducts and rotates the arytenoid cartilage of the paralyzed vocal fold, medializing the fold and closing the posterior glottic aperture. It is especially indicated for cases with a wide glottic chink. Because there is no direct surgical intervention through the vocal fold mucosa, postoperative scarring of the fold that would hinder vibration is avoided.

The use of Teflon injection or a type I thyroplasty[2,3] to medialize the vocal fold is usually unsuccessful in correcting a large posterior glottic defect. The reasons for this are various, but among the most important are 1) cricoarytenoid joint ankylosis in up to one third of patients with long-standing vocal fold paralysis, 2) inability to inject Teflon lateral to the arytenoid cartilage except toward the vocal process, and 3) inability to access the area lateral to the arytenoid in a type I thyroplasty unless the inner perichondrium of the thyroid cartilage is violated. On the other hand, the arytenoid adduction procedure allows for direct surgical correction of a posterior glottic deficiency. This procedure also pulls the arytenoid cartilage inferiorly, lowering the level of the paralyzed fold, and correcting the difference of levels of the vocal fold often seen with a large posterior glottic chink. The paralyzed fold is in a higher position than the nonparalyzed fold because of the characteristics of the cricoarytenoid joint.[4,5] Posterior glottic deficiencies are often seen with a combined paralysis of the ipsilateral superior and recurrent laryngeal nerves. These paralyses may be synchronous (eg, high vagal lesion) or time-delayed, but the underlying result is lateralization of the entire vocal fold through lateralization and lateral rotation of the arytenoid cartilage. In some of these patients an "anterior" medialization procedure (Teflon injection or type I thyroplasty) may need to be performed in conjunction with an arytenoid adduction to compensate for the atrophy and bowing of the anterior membranous vocal fold.

The physiologic assessment of patients undergoing arytenoid adduction procedures is presented. The physiologic parameters assessed included the measurements of vocal jitter and shimmer along with the aperiodicity signal to noise ratio (SNR) of the acoustic signal. Measures of sequential cycle-to-cycle variations of frequency (jitter) and amplitude (shimmer) during sustained vowel phonation have been implicated as physical correlates of rough or hoarse voice.[6-9] The SNR has also been useful in describing characteristics of normal and pathologic voice.[8] Of particular interest is the preoperative evaluation and determination of whether the procedure to correct a posterior glottic deficiency should include an arytenoid adduction with or without a simultaneous anterior medialization procedure.

MATERIALS AND METHODS

Patients. From November 1, 1988, to September 30, 1990, 12 patients underwent arytenoid adduction at the Mayo Clinic. Seven of the 12 patients were severely dysphonic or aphonic. Six cases were associated with a high vagal lesion. Surgery within the thorax was the cause of the vocal fold paralysis in 3 cases, and endotracheal intubation was associated with another case. A viral cause was suspected in the other 2 patients. All patients had lateralization of the vocal fold with a significant posterior glottic defect.

Instrumentation for Physiologic Assessment of

From the Department of Otolaryngology, Long Island College Hospital–State University of New York Health Science Center, Brooklyn, New York (Slavit), and the Department of Otorhinolaryngology, Mayo Clinic and Mayo Foundation, Rochester, Minnesota (Maragos).

Presented at the meeting of the American Laryngological Association, Waikoloa, Hawaii, May 4-5, 1991.

REPRINTS — Nicolas E. Maragos, MD, Dept of Otorhinolaryngology, Mayo Clinic, 200 First St SW, Rochester, MN 55905.

TABLE 1. COMPUTATIONAL FORMULAS FOR JITTER AND SHIMMER IN VOICE ANALYSIS

$$\% \text{ Jitter} = \frac{\sum_{i=1}^{N-1} | Pi - Pi+1 | /N-1}{\sum_{l=1}^{N} (Pi)/N} = \frac{\text{Average cycle-to-cycle difference in period}}{\text{Average period}}$$

$$\% \text{ Shimmer} = \frac{\sum_{i=1}^{N-1} | Ai - Ai+1 | /N-1}{\sum_{i=1}^{N} (Pi)/N} = \frac{\text{Average cycle-to-cycle difference in amplitude}}{\text{Average amplitude}}$$

Pi — period of ith cycle, Ai — amplitude of ith cycle, N — number of cycles.

TABLE 2. VIDEO LARYNGOSCOPY

Respiration
Regular
Rapid, forceful
Valsalva maneuver followed by slow release
Vowel prolongation "Aaaaaa" and "Eeeeee"
Continuous scale
Repeat "he" rapidly
Repeat "key" rapidly
Repeat "Cree" rapidly
Coup de glot (grunt)
Have patient read the following:

"You wish to know all about my grandfather. Well, he is nearly 93 years old, yet he still thinks as swiftly as ever. He dresses himself in an old black frock coat, usually several buttons missing. A long beard clings to his chin, giving those who observe him a pronounced feeling of the utmost respect."

Voice. Eleven patients completed preoperative and postoperative evaluation that included a combination of high-quality voice recording, video laryngoscopy, and laryngeal stroboscopy.[10] One patient died of unrelated causes prior to the completion of the postoperative voice analysis.

Voice recordings were obtained with an AKG D330T microphone and an Onkyo TA-W88 tape machine. An AST 20858 microcomputer with an 80287 math coprocessor and ASYSTANT software (ASYST Technologies) for high-speed data acquisition and analysis was used. Video laryngoscopy and stroboscopy were performed with a Bruel & Kjaer stroboscopic unit. An Olympus ENF P2 or ENF L3 nasopharyngoscope or a Nagashima 70° rigid telescope was used to visualize the larynx.

Speech Task, Data Aquisition, and Data Analysis. To determine jitter, shimmer, and SNR, subjects produced a steady-state vowel /a/ for as long as possible at a comfortable volume and pitch. During vowel prolongation the acoustic signal was recorded. The acoustic signal was then low-pass-filtered at 500 Hz and sampled at 20 kHz before being stored on the hard disk.

The computer software program was used to determine the vocal jitter, vocal shimmer, and SNR. Also determined was the fundamental frequency. One second of the waveform from the middle portion of each vowel prolongation was used to calculate these parameters. The computational formulas used for jitter and shimmer are shown in Table 1. Jitter was calculated as the ratio of the sum of the absolute cycle-to-cycle variability in the period to the mean period and was expressed as a percentage. Shimmer was determined as the ratio of the absolute cycle-to-cycle variability in amplitude to the mean amplitude multiplied by 100 and was expressed as a percentage. The SNR is the ratio of total energy in the speech signal to energy in the aperiodic component of the signal and was expressed in decibels.

Laryngoscopy was performed preoperatively and postoperatively by our standard laryngeal assessment recording techniques (Table 2). Laryngeal stroboscopy, preferably with the 70° rigid telescope to avoid any distortional effects due to displacement of the flexible nasopharyngoscope off midline, was also performed to assess the vibratory characteristics of the vocal folds.

Surgical Technique. A technique similar to that described by Isshiki et al[1,2] was used. These procedures were performed under local anesthesia so that the patients could phonate on request during the surgical procedure.

A horizontal incision was made in the anterior neck at the level of the vocal fold and was extended slightly further laterally on the side of the vocal fold paralysis. Subplatysmal skin flaps were raised superiorly and inferiorly. The strap muscles were then split in the midline and the thyroid cartilage was exposed. The posterior edge of the thyroid ala was exposed on the paralyzed side and the thyropharyngeal muscle was incised. With a small hook, the posterior edge of the thyroid cartilage was retracted and rotated anteriorly. The perichondrium at the posterior edge of the thyroid ala was incised and elevated subperichondrally along the posterior margin and inner surface of the thyroid cartilage. The cricothyroid joint was then dislocated and the thyroid cartilage further rotated anteriorly with exposure of the region of the pyriform sinus. In most cases, a 1.0-cm vertical strip of cartilage from this area was removed for better exposure. This strip included the inferior cornu and posterior edge of the thyroid ala to approximately 8 mm above the posterior projection of the vocal fold level. The superior cornu with muscular attachments remained intact. The mucosa of the pyriform sinus recess was then elevated upward and posteriorly to carefully expose and identify the posterior cricoarytenoid muscle. We identified the muscular process by tracing the fibers of the posterior cricoarytenoid muscle superiorly and anteriorly to their junction with the thyroarytenoid muscle. The muscular process of the arytenoid was also noted to be at the level of the vocal fold, approximately 1 cm above the cricothyroid

joint in an oblique direction, and could also be identified by following the posterolateral cricoid cartilage superiorly to the cricoarytenoid joint. Once the muscular process of the arytenoid was identified, the cricoarytenoid joint was opened laterally only. Two 4-0 nylon sutures on Keith needles were passed through the anterior aspect of the thyroid cartilage to the region of the muscular process. Two holes were drilled through the anterior cartilage to facilitate suture placement, the holes being approximately 5 mm and 10 mm from the midline and 3 mm inferior to the lower border of a possible type I thyroplasty window. These two sutures were passed through the thyroid cartilage along its caudal and inferior aspect so as not to interfere with the potential placement of a type I thyroplasty window. In fact, in recent cases we found it easier to completely outline the type I thyroplasty window, elevate the inner perichondrium, and depress the cartilage rectangle before placing sutures for the arytenoid adduction if both procedures were done concurrently. Suture placement in this manner will approximate the contraction vectors of the thyroarytenoid muscle (medial suture) and the lateral cricoarytenoid muscle.

After the sutures were passed posteriorly, the Keith needle was removed and the adduction sutures were individually placed through the muscular process of the arytenoid with a Lane threading needle. With acoustic auditory feedback as well as direct visual examination with an Olympus ENF P2 nasopharyngoscope and video monitor, the appropriate tension was applied to the nylon sutures to cause the desired rotation and adduction of the arytenoid cartilage. Once in the desired position, the two 4-0 nylon sutures were secured to each other along the anterior surface of the thyroid cartilage. The strap muscles were reapproximated and the skin wound was closed. The patients were given antibiotics for 1 week.

CASE REPORTS AND RESULTS

Each case of vocal cord paralysis involved a different combination of cause of the paralysis, final position of the paralyzed vocal fold, atrophy of the paralyzed vocal fold, bowing of the contralateral fold, compensation of the contralateral fold, and patient motivation and desires. Therefore, each case will be described individually. The results were evaluated through voice recording, video laryngoscopy, and stroboscopy.

Case 1. A 37-year-old man had aphonia due to left vocal fold paralysis resulting from removal of a left vagal neurilemmoma 3 months earlier. Via direct laryngoscopy, the left vocal fold was injected laterally with five clicks of Teflon, which brought the membranous vocal fold into good opposition in the midline. Postoperatively, the posterior glottis remained open and was responsible for persistent dysphonia. Three months later a left arytenoid adduction was performed. Afterward the voice was improved, and on physical examination the arytenoid was well medialized. With the combination of Teflon injection and arytenoid adduction, the aphonia was corrected, and objective assessment demonstrated normal values for jitter and shimmer[6-8] (Table 3).

Case 2. A 31-year-old woman had dysphonia secondary to left vocal fold paralysis after resection of a posterior mediastinal bronchogenic cyst and repair of the membranous portion of the trachea 5 months earlier. The left fold was widely abducted and higher than the right fold. There was no significant bowing or atrophy noted of the paralyzed vocal fold. Electromyography revealed no fibrillation potential. A left arytenoid adduction was performed. Postoperatively on examination there was better height similarity between the two vocal folds, with good closure of the glottis and no bowing of the vocal folds. Her voice was markedly improved, both subjectively and objectively, yet slightly raspy (Table 3).

Case 3. A 38-year-old man had aphonia related to right vocal fold paralysis after removal of a vagal neurilemmoma 9 months earlier. On examination, the right vocal fold was lateralized with a large interarytenoid gap. An arytenoid adduction was performed. The voice was noted to be improved but not perfect. Jitter was elevated and the SNR was low (Table 3). On examination the posterior glottis was now totally closed, yet there was marked bowing and atrophy of the membranous right vocal fold. Also noted was some slight overrotation of the arytenoid. To compensate for the bowing of the right vocal fold and weakness of the voice, the patient used a high-pitched voice with low amplitude. He was strongly motivated to improve his voice further, and 7 months after the arytenoid adduction a right Teflon injection via direct laryngoscopy was performed for slight bowing of the left vocal fold and marked bowing of the right vocal fold. The patient went into laryngospasm postoperatively and was emergently intubated. Findings on glottic examination were similar to preoperative ones, with apparent displacement of the Teflon during the reintubation. A right type I thyroplasty was then undertaken. During the operation, direct visualization of the larynx and voice assessment led to the conclusion that no further procedures were necessary. On postoperative follow-up evaluation there was noted to be good closure of the glottis, with only slight bowing of the left vocal fold. Objective evaluation of the voice revealed improvement of the severe dysphonia with the arytenoid adduction, and further benefit from the type I thyroplasty (Table 3).

Case 4. A 63-year-old woman had dysphonia secondary to left vocal fold paralysis. The cause of the vocal fold paralysis was never definitively iden-

TABLE 3. PREOPERATIVE AND POSTOPERATIVE OBJECTIVE VOICE ANALYSIS DATA

Case	*Status*	*F0 (Hz)*	*Jitter (%)*	*Shimmer (%)*	*SNR (dB)*
1	Preoperative	Aphon	Aphon	Aphon	Aphon
	After Teflon injection and arytenoid adduction	128.9	0.40	0.25	37.48
2	Preoperative	216.4	9.63	1.40	10.32
	After arytenoid adduction	218.3	1.50	0.77	22.25
3	Preoperative	Aphon	Aphon	Aphon	Aphon
	After arytenoid adduction	161.7	4.72	0.41	20.51
	After type I thyroplasty	127.2	0.45	0.35	28.41
4	Preoperative	235.5	3.77	0.88	17.65
	After arytenoid adduction	NC	NC	NC	NC
5	Preoperative	Aphon	Aphon	Aphon	Aphon
	After arytenoid adduction	135.3	6.34	1.78	15.50
6	Preoperative	163.1	4.94	5.72	11.93
	After arytenoid adduction	144.7	1.35	1.22	18.20
7	Preoperative	Aphon	Aphon	Aphon	Aphon
	After arytenoid adduction and type I thyroplasty	102.7	0.93	2.43	23.43
8	Preoperative	148.9	6.71	1.66	18.65
	After arytenoid adduction and type I thyroplasty	156.4	0.75	0.56	31.20
9	Preoperative	142.0	1.55	1.84	20.66
	After arytenoid adduction and type I thyroplasty	127.0	0.60	0.66	29.01
10	Preoperative	84.4	1.85	5.47	9.87
	After arytenoid adduction and type I thyroplasty	84.3	0.30	1.29	20.97
11	Preoperative	214.8	0.90	2.32	14.03
	After arytenoid adduction and type I thyroplasty	200.0	0.50	1.93	24.54
12	Preoperative	Aphon	Aphon	Aphon	Aphon
	After arytenoid adduction and type I thyroplasty	100.0	0.26	0.93	38.05

F0 — fundamental frequency, SNR — signal to noise ratio, Aphon — aphonic, NC — postoperative voice analysis not completed because of death of patient.

tified, yet it was felt to be secondary to viral infection. Examination revealed a large, incompetent posterior glottis. Six months after the diagnosis of the left vocal fold paralysis, the glottis was still noted to be widely patent posteriorly, and an arytenoid adduction was performed. Prior to the completion of postoperative voice analysis, the patient died of unrelated causes.

Case 5. A 71-year-old man had aphonia secondary to left vocal fold paralysis since repair of a ruptured thoracic aortic aneurysm 4 months before. There was a wide open posterior glottis. An arytenoid adduction was recommended along with the possibility of a type I thyroplasty, to be based on reevaluation during the surgical procedure. After only right arytenoid adduction, direct visualization of the glottis revealed good closure, and the voice had markedly improved, so a thyroplasty was not performed. Six months postoperatively the voice was slightly raspy, yet the patient was no longer aphonic. Objective assessment correlated with the subjective assessment of a raspy voice, with an elevated jitter and shimmer and a low SNR (Table 3).

Case 6. A 58-year-old man had dysphonia secondary to right vocal fold paralysis after resection of a glomus jugulare tumor 4 months earlier. The right vocal fold was positioned laterally, with a wide posterior gap and no significant atrophy of the membranous vocal fold. An arytenoid adduction alone was performed. Postoperatively, the voice was improved although not perfect, and objective assessment corresponded with the subjective observations (Table 3).

Case 7. A 62-year-old man had aphonia secondary to right vocal fold paralysis after resection of embryonal rhabdomyosarcoma in the right temporal, postauricular, retromandibular, infratemporal, and supraclavicular regions. There was also paralysis of the right pharyngeal muscles. Examination showed a large glottic chink. An arytenoid adduction and type I thyroplasty were performed along with a cricopharyngeal myotomy. Postoperative examination revealed normal jitter, shimmer, and SNR (Table 3).

Case 8. A 48-year-old woman had severe dysphonia secondary to left vocal cord paralysis since resection of vagal paraganglioma 12 months before. The left vocal cord was positioned laterally, with a wide glottic gap both anteriorly and posteriorly. An arytenoid adduction was performed and at the time of operation the vocal folds were still approximately 1.4 mm apart anteriorly after completion of the adduction procedure and closure of the posterior glottis. Therefore, in conjunction with the adduction procedure, a type I thyroplasty was performed on the left to close the anterior glottic defect. Postoperatively the voice was noted to be improved, with good closure of the entire glottis. Objective assessment revealed jitter and shimmer within the normal range and an increase in the SNR (Table 3).

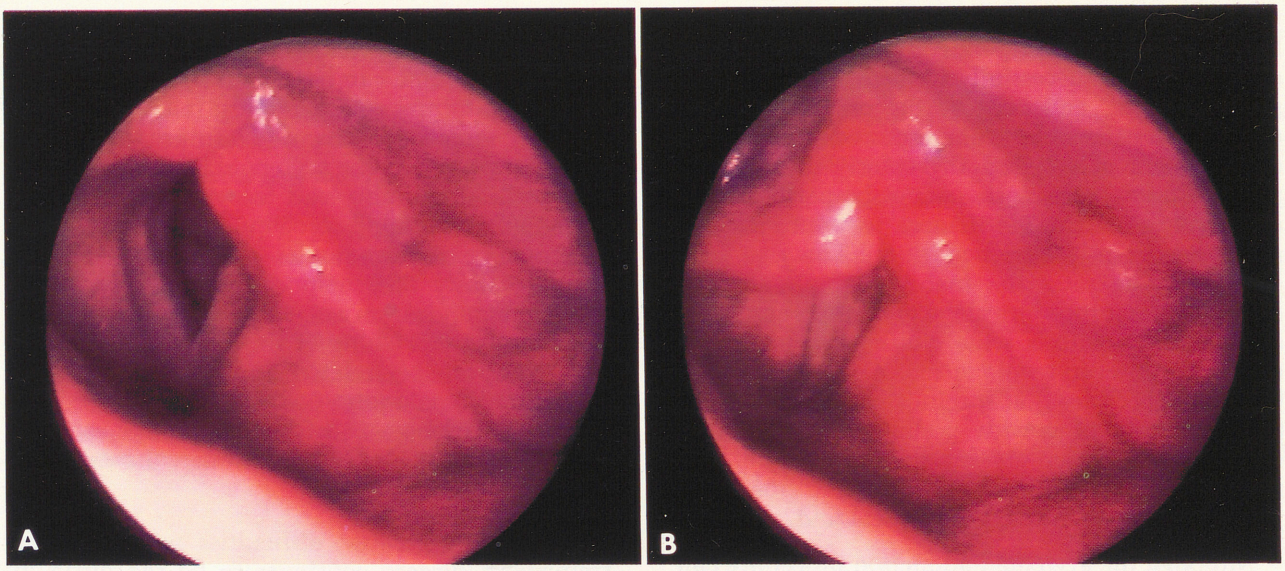

(Case 12) Laryngoscopic views after arytenoid adduction and type I thyroplasty. A) During quiet respiration, showing medialization and correction of bowing of left vocal fold. B) During phonation, showing complete glottic closure.

Case 9. A 74-year-old man had dysphonia secondary to right vocal fold paralysis related to removal of a meningioma in the right jugular bulb, posterior cranial fossa, and upper jugular vein. The patient also had right palatal weakness and pharyngeal weakness along with dysphagia and aspiration. Laryngeal examination after removal of the tumor showed vocal fold paralysis with an open posterior glottis and an elevated paralyzed fold related to the high vagal paralysis. Marked atrophy of the right vocal fold was also noted. An arytenoid adduction was therefore planned to close the posterior glottis, along with a type I thyroplasty to compensate for the vocal fold atrophy. Postoperatively there was improved closure of the entire glottis, and objective assessment correlated with the subjective improvement of voice (Table 3).

Case 10. A 57-year-old man had dysphonia secondary to left vocal fold paralysis felt to be probably viral in origin. The patient also had a history of adenocarcinoma of the esophagus. There was a wide glottis, with the paralyzed left vocal fold positioned laterally and slightly higher than the right vocal fold. There was also significant bowing of the left vocal fold and slight bowing of the right vocal fold. A left arytenoid adduction along with a left type I thyroplasty was performed. Intraoperatively, it was felt that there was good closure of the glottis and that further procedures for the slight bowing of the right vocal fold were not indicated. After resolution of the edema, follow-up examination 4 months postoperatively revealed slight overrotation of the left arytenoid cartilage, with the vocal process protruding into the airway, and related bowing along the left membranous vocal fold producing a slight glottic gap. Objective as well as subjective assessment of the voice revealed improvement, although the voice was not perfect (Table 3).

Case 11. A 34-year-old woman had dysphonia secondary to a left vocal fold paralysis, felt to probably be viral. She had progressive weakness, hoarseness, and lowering of vocal pitch beginning over 1 year prior to evaluation and becoming constant in nature in the last 10 months. Magnetic resonance imaging scans were negative for disease. Electromyography showed left thyroarytenoid muscle paralysis. The left arytenoid was localized far laterally with a glottic chink. Slight atrophy and bowing of the left vocal fold was noted as well. A left arytenoid adduction was performed, and intraoperatively the voice was improved but still slightly breathy, so a type I thyroplasty was included. Evaluation 4 months postoperatively, after resolution of edema, revealed good glottic closure (Table 3).

Case 12. A 61-year-old man had aphonia due to a left vocal cord paralysis believed to be related to endotracheal intubation. Examination revealed marked atrophy and bowing of the left vocal fold as well as slight bowing of the right vocal fold. On phonation the posterior glottis remained open, with an interarytenoid distance of 3 mm. The left vocal fold also appeared slightly higher in position than the right vocal fold. An arytenoid adduction was performed in conjunction with a type I thyroplasty. At the time of operation there was good closure of the glottis. Postoperatively, all vocal measurements were normal (Table 3), and on examination there was complete glottic closure on phonation (see Figure).

DISCUSSION

Vocal fold Teflon injection and type I thyroplasty are usually successful in treating unilateral vocal fold paralysis with a closed or narrow posterior glottic chink.[2,3,11,12] However, in the presence of a lateralized paralyzed vocal fold and a large posterior glottic defect, neither a Teflon injection nor

type I thyroplasty alone is able to achieve a relatively normal voice postoperatively. Teflon injection cannot be used successfully to medialize the arytenoid cartilage, and because the cricoid cartilage overlaps the thyroid cartilage posteriorly, inward displacement of a type I thyroplasty thyroid cartilage window posteriorly cannot be performed to effectively close this glottic area without violating the inner thyroid perichondrium. The first case described illustrates the inability of an anterior medialization procedure alone to correct for a vocal fold paralysis with a wide glottic defect that includes the interarytenoid space. Arytenoid adduction is a procedure that specifically is indicated for the correction of a wide posterior glottic chink. Arytenoid adduction also has the capability of correcting a difference in the levels of the true vocal folds by lowering the paralyzed vocal fold.

Although the arytenoid adduction procedure can close the posterior glottis and lower the paralyzed vocal fold to correct a height difference, this procedure alone is often unsuccessful in fully rehabilitating the voice, specifically because it does not directly affect the anterior vocal fold. In conjunction with an arytenoid adduction, a Teflon injection or type I thyroplasty is often indicated to medialize the membranous paralyzed vocal fold further. This is particularly of value in cases of marked atrophy and bowing of the membranous portion. In the case of the patient suffering from presbylaryngis and senile bowing of the vocal folds, a type I thyroplasty of the contralateral vocal fold may also be indicated to correct the bowing of the nonparalyzed side.

Case 3 demonstrates the inability of an arytenoid adduction alone to correct a lateralized paralyzed vocal fold with marked atrophy and bowing. Furthermore, in cases 5 and 6, a type I thyroplasty in conjunction with the arytenoid adduction would probably have been beneficial. In both cases 5 and 6 the vocal fold paralysis was only 4 months old, and further atrophy of the vocalis muscle likely occurred postoperatively. Currently our technique is to initially perform an arytenoid adduction in those patients with vocal fold paralysis and a lateralized fold. We assess the immediate results intraoperatively, with the option to proceed with a type I thyroplasty as indicated. The use of local anesthesia with intravenous sedation allows for intraoperative assessment of the voice and direct visualization of the larynx during phonation.

Although there were no major complications in our cases and the quality of the voice was always improved, a perfect voice was not always obtained. The arytenoid adduction procedure is technically a more difficult procedure to perform. In two of the cases (cases 3 and 8) there was slight overrotation of the arytenoid cartilage, the most common complication of this procedure. This caused the vocal process to protrude into the glottis with associated bowing of the membranous vocal cord. Overrotation and too much medial shift of the vocal fold across the midline can be caused by excessive traction on the sutures attached to the muscular process of the arytenoid. Placement of a suture through the muscular process of the arytenoid in an extreme lateral position can also lead to overrotation. If the arytenoid is rotated too much, a rough and "pressed" voice often results, and a type I and type IV thyroplasty may help correct this condition.[2] Another complication associated with arytenoid adduction was shortening of the vocal fold (case 3). This was probably related to excessive opening of the cricoarytenoid joint posteriorly and subsequent forward displacement of the arytenoid cartilage with traction on the suture through the muscular process.

One of the greatest difficulties with laryngeal framework surgery continues to be the difficulty with intraoperative assessment and the ability to predict the long-term postoperative results. The swelling and edema of the larynx that occurs during the surgical manipulation needs to be taken into consideration when establishing the new position of the vocal folds. One must therefore overcorrect intraoperatively and achieve a slightly tight or pressed voice, taking into account the edema that will resolve postoperatively. Other factors affecting the long-term postoperative result are related to the healing process. In the case of immediate treatment of a vocal fold paralysis, further atrophy will affect the long-term postoperative result. The longevity of the vocal fold tension created by the adduction of the arytenoid is also uncertain. Finally, modification of an artyenoid adduction without direct surgical intervention of the vocal fold may be difficult because of the ankylosis that occurs at the opened cricoarytenoid joint.

SUMMARY

The arytenoid adduction procedure is a surgical technique that provides the otolaryngologist with an effective means for correcting large posterior glottic defects. The arytenoid adduction procedure is a technically challenging procedure related to the identification of the muscular process of the arytenoid and appropriate positioning with rotation of the arytenoid cartilage. The use of an anterior medialization procedure such as a type I thyroplasty is a valuable adjunctive procedure in those cases of concurrent marked anterior vocal fold bowing. Every case of vocal fold paralysis is unique, and one must remember that patients with vocal fold paralysis can have different glottic configurations and vocal results. Likewise, there is not one universal treatment for vocal fold paralysis and each patient must be evaluated carefully to determine the appropriate procedure or combination of procedures. In the case of the open posterior glottis, the arytenoid

adduction procedure has proven to be an effective and reliable treatment for this troublesome defect.

REFERENCES

1. Isshiki N, Tanabe M, Sawada M. Arytenoid adduction for unilateral vocal cord paralysis. Arch Otolaryngol 1978;104:555-8.

2. Isshiki N. Phonosurgery: theory and practice. New York, NY: Springer-Verlag, 1989.

3. Isshiki N, Okamura H, Ishikawa T. Thyroplasty type I (lateral compression) for dysphonia due to vocal cord paralysis or atrophy. Acta Otolaryngol (Stockh) 1975;80:465-73.

4. Von Leden H, Moore P. The mechanics of the cricoarytenoid joint. Arch Otolaryngol 1961;73:541-50.

5. Isshiki N, Ishikawa T. Diagnostic value of tomography in unilateral vocal cord paralysis. Laryngoscope 1976;86:1573-8.

6. Kitzing P. Glottography, the electrophysical investigation of phonatory biomechanics. Acta Otorhinolaryngol Belg 1986; 40:863-78.

7. Baer T, Löfqvist A, McGarr NS. Laryngeal vibrations: a comparison between high-speed filming and glottographic techniques. J Acoust Soc Am 1983;73:1304-8.

8. Horii Y. Fundamental frequency perturbation observed in sustained phonation. J Speech Hear Res 1979;22:5-19.

9. Horii Y. Vocal shimmer in sustained phonation. J Speech Hear Res 1980;23:202-9.

10. Hirano M. Clinical examination of voice. New York, NY: Springer-Verlag, 1981.

11. Baken RJ. Clinical measurement of speech and voice. Boston, Mass: Little, Brown, 1987.

12. Lewy RB. Experience with vocal cord injection. Ann Otol Rhinol Laryngol 1976;85:440-50.

ROLE OF INJECTABLE COLLAGEN IN THE TREATMENT OF GLOTTIC INSUFFICIENCY: A STUDY OF 119 PATIENTS

CHARLES N. FORD, MD

DIANE M. BLESS, PHD JEAN M. LOFTUS, MD

MADISON, WISCONSIN

Injectable bovine collagen has been used for treatment of glottic insufficiency at the University of Wisconsin Clinical Science Center since 1983. This report reviews our experience in treating 119 patients with a variety of vocal fold disorders manifested by glottic insufficiency. Many of the patients were referred because of prior treatment failures or problems that were impossible to treat with other modalities. Results were assessed by comprehensive voice evaluations using subjective patient self-assessments, perceptual judgments made by a panel of experts who had no prior knowledge of the study, objective assessments, and videostroboscopy. Objective assessment included vocal function measures and acoustic analysis. Results indicate that collagen not only is comparable to other injection filler substances but also has unique advantages as a bioimplant. Collagen injection seems uniquely suited for treatment of several problems, including vocal fold atrophy, focal defects, minimal glottic insufficiency, and scarred vocal folds that are not managed optimally with Teflon injection. Overall there were no serious complications and treatment was effective for a broad spectrum of problems. In most instances the correction persisted, and in those instances in which injected collagen seemed improperly distributed, the vocal fold was recontoured or the implant removed without appreciable damage to the surrounding tissues. Injectable collagen has been extensively studied and deserves to be included in the armamentarium of the laryngeal surgeon.

KEY WORDS — collagen, larynx, vocal fold, voice.

INTRODUCTION

The search for an ideal substance for vocal fold augmentation led Arnold[1] to use Teflon (Polytef Paste), which has become the workhorse method for treating glottic insufficiency. Although Teflon injection has offered tremendous improvement, this alloplastic preparation induces a definite foreign body reaction and focal fibrosis.[2-5] Concerns about complications such as granuloma formation,[6,7] airway obstruction,[8,9] potentially irreversible damage to vocal fold vibratory structure by foreign body reaction and fibrosis,[10] and the possibility of implant extrusion or migration[11,12] have motivated clinicians to look for alternative forms of treatment. Such alternatives have been advocated to enhance voice results and provide greater flexibility without permanently altering vocal fold tissues.[13-15]

Collagen injection differs from other vocal fold medialization approaches in that it is a biological implant, providing more than medial displacement of the vocal fold. The collagen implant consists of bovine collagen modified by solubilization and cross-linking to reduce cellular and humoral host immune response, but it is histologically similar to the deep lamina propria tissues in the vocal fold. Host tolerance of injected collagen is characterized by gradual assimilation starting with ingrowth of vessels and progressive invasion of fibroblasts into the implanted collagen. The events following collagen injection that affect vocal fold function specifically include the gradual variable resorption of injected collagen, the replacement of some resorbed implant by deposition of new host collagen from metabolically active invading host fibroblasts, and the softening of existing scar tissue, probably due to fibroblastic production of collagenase.

The physiologic limitations of alloplastic augmentation and the theoretic advantages of bioimplantable materials have led to experimentation with collagen injection of the vocal fold. Injected soluble bovine collagen has been used successfully to augment dermal defects and to soften depressed scars. We reasoned that this collagen implant might be well tolerated in the collagen-containing layers of the vocal fold and might be useful in treating scarred larynges.

PREVIOUS WORK

These observations prompted us to compare collagen injection to Teflon injection in dog larynges[16] and to look at the long-term histologic fate of different forms of collagen injected into the canine vocal fold.[17] We found that collagen could be injected precisely through a 26-gauge needle into the deep lamina propria of the vocal fold — a site normally composed of dense collagen. The implant was remarkably well tolerated, with no evidence of foreign body or inflammatory reaction; over time there was some peripheral neovascularization and ingrowth of fibroblasts with deposition of scattered

From the Division of Otolaryngology, Department of Surgery (all authors), and the Department of Communicative Disorders (Bless), University of Wisconsin, Madison, Wisconsin. This work was supported in part by grants from the Food and Drug Administration, Orphaned Product Development Division (grant FD-R-000404-02), the Veterans Administration Rehabilitation Research and Development Service, and a General Research Support Grant to the University of Wisconsin Medical School from the National Institutes of Health Division of Research Facilities and Resources (project 133-H529).

Presented at the meeting of the American Laryngological Association, Waikoloa, Hawaii, May 4-5, 1991.

REPRINTS — Charles N. Ford, MD, University of Wisconsin CSC, H4/320, 600 Highland Ave, Madison, WI 53792.

foci of new host collagen within the implant matrix, replacing some of the assimilated implant. Persistence of the implant was noted at intervals up to 1 year. Similar results were obtained subsequently by Okamoto.[18]

We also looked at the effect of superficially injected collagen on vocal fold vibration in the excised larynx and noted that simulated deficiencies could be corrected, with correction resulting in normal passive activation of vibratory activity in response to a steady controlled subglottic air pressure.[19] Recent in vivo canine studies have demonstrated improvement in many vocal function parameters following injection for simulated vocal fold paralysis.[20]

In 1985 the authors[21] presented the first clinical trials of Zyderm Collagen Implant (Collagen Corp, Palo Alto, Calif) to correct glottic insufficiency in 27 patients. Objective voice analysis demonstrated efficacy, and none of these patients suffered complications. Questions were raised regarding long-term persistence of the implant and the possibility of hypersensitivity reactions.[22] A subsequent report with 2-year follow-up data indicated that in most patients, correction evident at 1 to 3 months persisted and results stabilized.[23] In this group of 44 patients, there was 1 with a delayed hypersensitivity reaction manifested by development of slight redness at the vocal fold and skin test site at 5 weeks. Since 1986 all patients have been injected with cross-linked collagen preparations (generic glutaraldehyde cross-linked [GAX] collagen, also marketed as Zyplast and Phonagel), which are less antigenic, diffuse easily, and undergo less initial shrinkage after injection.

Failure to gain Food and Drug Administration (FDA) approval limited clinical trials in this country, but others[24-29] have reported successful results with soluble collagen injections for glottic insufficiency. Most of these investigators made the injections in the superficial mucosal layers of the vocal fold, since it was demonstrated that collagen injected deep in vocalis muscle was rapidly resorbed.[17] The issue of resorption was addressed in two postmortem studies. Remacle and Marbaix[30] reported on the persistence of injected collagen in postmortem human larynges up to 5 months postinjection, and Ford et al[31] noted persistence in one patient after 1 year.

It was apparent from these initial studies that collagen injection was a successful treatment for a variety of pathologic disorders manifested by glottic insufficiency. The limitations of Teflon injection did not seem to apply to collagen, especially in the treatment of the scarred vocal fold, focal defects, atrophy, and limited glottic insufficiency problems. Efficacy was demonstrated in independent studies of patients with age-related changes in the vocal folds (presbylaryngis)[32] and in those with scarred larynges.[33]

PURPOSE OF STUDY

In an attempt to further explore the potentials of a biologic implant, we initiated a study (suppported by the Orphaned Products Division of the FDA) to treat glottic insufficiency in patients who were not optimal candidates for Teflon injection, and we reviewed the entire group of collagen-injected patients treated at the University of Wisconsin Clinical Science Center. Demonstration of efficacy in that select group of patients seemed a sufficiently important endeavor that no attempt was made to compare efficacy of collagen with other modes of treatment.

MATERIALS AND METHODS

Collagen injection of the vocal fold has been performed at the University of Wisconsin for management of glottic insufficiency since 1983. Goals included improving glottic closure, vocal quality, ease of phonation, and associated laryngeal functions in patients with a variety of vocal fold disorders. The experimental protocol was initiated in 166 patients, of whom 26 were lost to follow-up, 5 were treated too recently to include, and 2 had nonvoice problems. Fourteen patients were not treated: 4 had positive skin tests, 4 declined in favor of alternative forms of treatment, 3 had marginal airways, and 3 improved with voice therapy.

PATIENTS

The 119 patients reported in this study represent those individuals who were treated and who complied with our protocol for follow-up voice assessment data collection. The pretreatment age range was 17 to 87 years, with a mean of 56 years, and the male to female ratio was approximately 3:2. Nearly half of the patients treated had scarred larynges, often secondary to laryngeal cancer surgery — a fact reflected in the male preponderance, for laryngeal cancer remains a predominantly male disease. Patients had experienced voice problems for an average of 6.1 (0.08 to 33.9) years before treatment and 30% had undergone voice therapy prior to collagen injection. Some patients underwent more than one injection over a period of months or years. The average length of follow-up was 16.4 (1 to 67) months.

Potential patients were evaluated by a speech pathologist and the senior author (C.N.F.) to determine their suitability for treatment. In each case both the protocol and available alternatives to management were described. Those who seriously considered collagen injection were skin-tested with Zyderm, which is generically similar to GAX collagen but exhibits greater antigenicity. If the skin test remained negative for 6 weeks, injection was offered. Two patients were injected before 6 weeks

because of severe aspiration problems.

Each patient was assigned to one of three vocal fold disorder groups on the basis of those histopathologic findings that seem to affect function and outcome.

Scarred Vocal Fold. The scarred vocal fold group were patients who had evidence of vocal fold scarring manifested by stiffness or decreased mucosal wave on videostroboscopy. Such patients typically had the most impaired vocal fold vibration, often secondary to surgery such as cordectomy, vocal fold stripping, Teflon injection/or removal, and hemilaryngectomy. Other patients had undergone radiotherapy or prolonged endotracheal intubation.

Bilateral Disorder. The bilateral vocal fold disorder group comprised patients who had had some form of bilateral disorder without scar formation. These patients exhibited a variety of diagnoses, including neurologic disorders such as presbylaryngis, Parkinson's disease, and abductor spasmodic dysphonia with bowed vocal folds. Some of these patients showed atrophic changes associated with presbylaryngis as well as bilateral paresis. Bilateral paresis was also attributable to head injuries, respiratory infections, and idiopathic neuropathies.

Unilateral Disorder. The unilateral vocal fold disorder group was made up of patients who had essentially unilateral disorders without evidence of scar formation or contralateral vocal fold disorders. Some had iatrogenic injuries involving the recurrent and/or superior laryngeal nerves. Other patients were paretic or paralyzed as a result of cerebral vascular accident or prolonged intubation, and some cases were idiopathic.

Patients with mixed disorders were assigned to that group typically associated with their greatest impairment of vocal fold function according to the following hierarchy: scarred vocal fold > bilateral disorder > unilateral disorder. The FDA Orphaned Product study was limited to the most severely impaired larynges; these patients had mainly scarred vocal folds or bilateral disorders.

COLLAGEN

The material injected during the initial phase of this study consisted of Zyderm Collagen Implant, a soluble bovine collagen. Since 1986 we have used GAX collagen, an injectable glutaraldehyde cross-linked (0.0075%) fibrillar collagen (Zyplast, Phonagel). It is essentially type I collagen with a residue of 1% to 5% type III collagen, prepared by selective hydrolysis of the nonhelical amino-terminal and carboxy-terminal segments (telopeptides) of the collagen molecule. Antigenicity is reduced by telopeptide cleavage and further reduced during the cross-linking process. GAX collagen remains the preferred material for vocal fold injection because it persists with minimal shrinkage and has reduced antigenicity compared to other forms of injectable collagen.[34]

PROCEDURE

Most of the injections were made by using indirect laryngoscopy and topical anesthesia, but several patients, particularly in the scarred vocal fold group, required direct microlaryngoscopy for proper placement. The material was injected via a device designed by the senior author[35] through the superior surface of the vocal fold into the intermediate and deep lamina propria.[21,23] The 26-gauge needle allowed for precise visual and tactile placement at the plane of the vocal ligament; slight resistance is encountered as the needle is advanced from the superior surface further into the vocal fold tissue.[36] In heavily scarred larynges, an effort was made to get as much collagen injected into the scar as possible with the initial penetration; often this practice resulted in collagen's being dispersed in deeper or more superficial levels than would have been ideal. Subsequent injections were generally easier and more precisely placed. All injections were made on a distinctly more superficial plane than is typical with Teflon, silicone, Gelfoam, or fat. The superficial placement facilitates filling in focal defects without distorting the entire vocal fold, prevents rapid resorption, and allows the implant to be injected at a site in which collagen is normally found.

In some of the more complex cases, collagen injection was used to enhance or correct changes induced by other forms of therapy. For example, patients with fibrotic convex vocal folds secondary to Teflon granulomas were managed by endoscopic removal of Teflon; in those instances in which the medial edge remained irregular, the vocal fold was remodeled with precise injections of collagen. Four patients had sulcus vocalis deformities treated by cordotomy, lysis of the adhesions, and later collagen injection to contour and soften the vocal fold tissues. Several patients were referred because failed attempts at glottic reconstruction following various conservation laryngectomy procedures left them with stiff, scarred larynges incapable of useful phonation. One patient had bilateral vocal fold paralysis and a marginal airway unsafe for any vocal fold augmentation; after successful neuromuscular pedicle transfer to the posterior cricoarytenoid muscle, a small amount of collagen was injected unilaterally in the membranous vocal fold with perceptible improvement in voice and no change in exercise tolerance. Some patients with scarred larynges had large glottic gaps that were initially addressed with thyroplasty surgery, and the scarred vocal fold was treated with collagen injection to soften and restore the contour of the vocal fold.

Postoperatively, patients were observed for airway problems and kept on relative voice rest over-

night — talking only when necessary and avoiding extremes in pitch and loudness. Patients returned for full assessment at 1-, 3-, and 6-month and 1-year intervals. Subsequent data were collected on a yearly basis.

ASSESSMENT METHODS

Four general categories of voice assessment were used to measure treatment success: 1) subjective patient self-assessment of voice quality and effort of phonation, 2) perceptual judgments of voice recordings by an impartial panel of experts, 3) laboratory data based on acoustic signal analysis and aerodynamic measures during voice production, and 4) studies of the appearance of vocal fold vibration by videostroboscopy.

Subjective patient self-assessment ratings were included as part of this comprehensive voice evaluation. After treatment, patients were grouped on the basis of their own ratings of their vocal quality and the effort required to produce phonation: 1) voice not improved, 2) voice improved and sustained improvement, 3) transient improvement, and 4) voice worse. Some patients in group 2 (bilateral disorders) noted a very slight decrement in vocal function over time but were convinced that the voice was substantially improved over the pretreatment status. For patients who had multiple injections, the subjective category was based on comparing the most recent evaluation to that immediately before the last injection.

Audiotape recordings were made in a sound-controlled booth with a Nagra tape recorder, as previously described.[21] The test sample recorded included sustained vowels /a/ and /i/ produced at normal pitch and loudness and the sentence "The blue spot is on the key" produced at conversational level. These samples were used for both the acoustic and perceptual analyses.

Perceptual judgments were made from the audio recordings of sustained vowels and the standard sentence. Pretreatment and the most recent posttreatment recordings were randomized and paired on a master tape. Three experienced speech pathologists were asked to make paired comparison judgments to determine which sample, if either, sounded better; they also indicated when there was no appreciable difference. To determine reliability of judgments, 10% of the samples were repeated and 10% of the samples were foils consisting of two identical samples. Foils were used to determine validity of the perceptual ratings. The judges were 100% correct in judging these voices to be the same.

Acoustic analysis of voice production permits quantitative analysis of the multidimensional physical characteristics of the voice signal and inference about the underlying physiologic mechanism. Samples were digitized on an IBM-PC computer with a locally developed software program (C-Speech). Jitter, shimmer, and signal to noise ratio (SNR) were derived by using the least mean square fit of a waveform model to the speech waveform.

TABLE 1. SUBJECTIVE PATIENT SELF-ASSESSMENT REGARDING VOICE QUALITY AND EFFORT

Disorder	*N*	*Sustained Improvement*	*Transient Improvement*	*No Improvement*	*Worse*
Scarred vocal fold	55	39	4	12	0
Bilateral disorder	25	23	1	1	0
Unilateral disorder	39	39	0	0	0

Data are numbers of patients.

Vocal function measures were recorded by means of a face mask attached to the Nagashima PS-77 Phonatory Function Analyzer to obtain maximal intensity (decibels) and mean airflow (milliliters per second). Transglottic airflow was assessed during production of /a/ and /i/ during a variety of phonatory tasks. High airflows were considered an indicator of poor laryngeal closure, as might occur in glottic insufficiency. Low airflows generally signified a competent glottis, but were noted to occur also with hyperfunction of laryngeal structures (a common compensatory activity), obstruction, low patient effort, or poor respiratory support.

Vocal fold vibration was observed with a Bruel & Kjaer laryngeal videostroboscope coupled to a rigid 90°-angled Wolfe endoscope and videorecorder. Recordings were used to assess ongoing treatment and to study individual cases over time. Recordings were rated in 15 consecutive cases by trained observers who made qualitative judgments of vocal fold vibration and supraventricular hyperfunction. Parameters observed were symmetry, periodicity, glottic closure, vibration amplitude, mucosal wave, and supraventricular hyperfunction; preoperative and postoperative samples were compared for each patient.

In cases for which preinjection data were available from more than one date, the date closest to injection was selected. Postinjection data were selected from the latest date the patient had been evaluated. When collagen injection was done after thyroplasty, Teflon removal, or reinnervation surgery, baseline measures were taken after the previous operation and before collagen injection.

STATISTICAL ANALYSIS

Efficacy of collagen injections was addressed by asking two questions: 1) Was there a significant change in any of the variables postinjection? and 2) Was there any difference between disorder groups in response to the collagen treatment? To analyze for pretreatment and posttreatment changes in the parameters (acoustic, aerodynamic, perceptual), we used paired *t* tests to determine whether or not

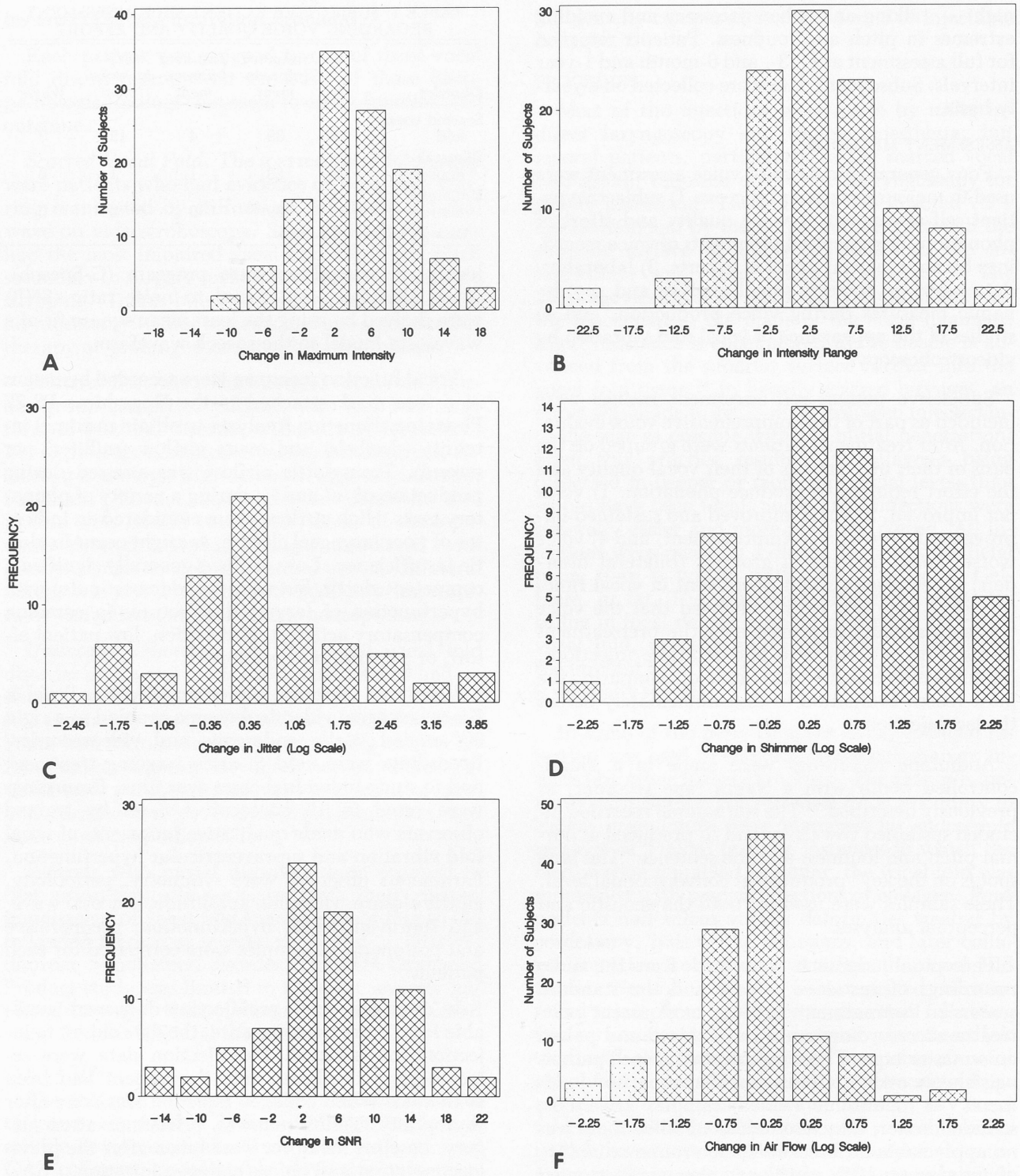

Fig 1. Bar graphs of changes from before to after collagen injection for six measures of vocal function. A) Maximum intensity. B) Intensity range. C) Jitter. D) Shimmer. E) Signal to noise ratio (SNR). F) Airflow.

the mean change was equal to zero. Differences between diagnosis groups were studied by using an analysis of variance. A χ^2 test was used for overall testing of perceptual change within and between groups. For measures with skewed distributions (airflow, jitter, shimmer), the log of the measure was used. These transformed measures had distributions close to normal, thus making the transformation changes nearly equivalent to analyzing percentage changes rather than absolute changes. Pearson's product-moment correlations were used to assess intrajudge and interjudge reliability. Wilcoxon's test was used to test for differences between stroboscopic recordings for select patients. The test

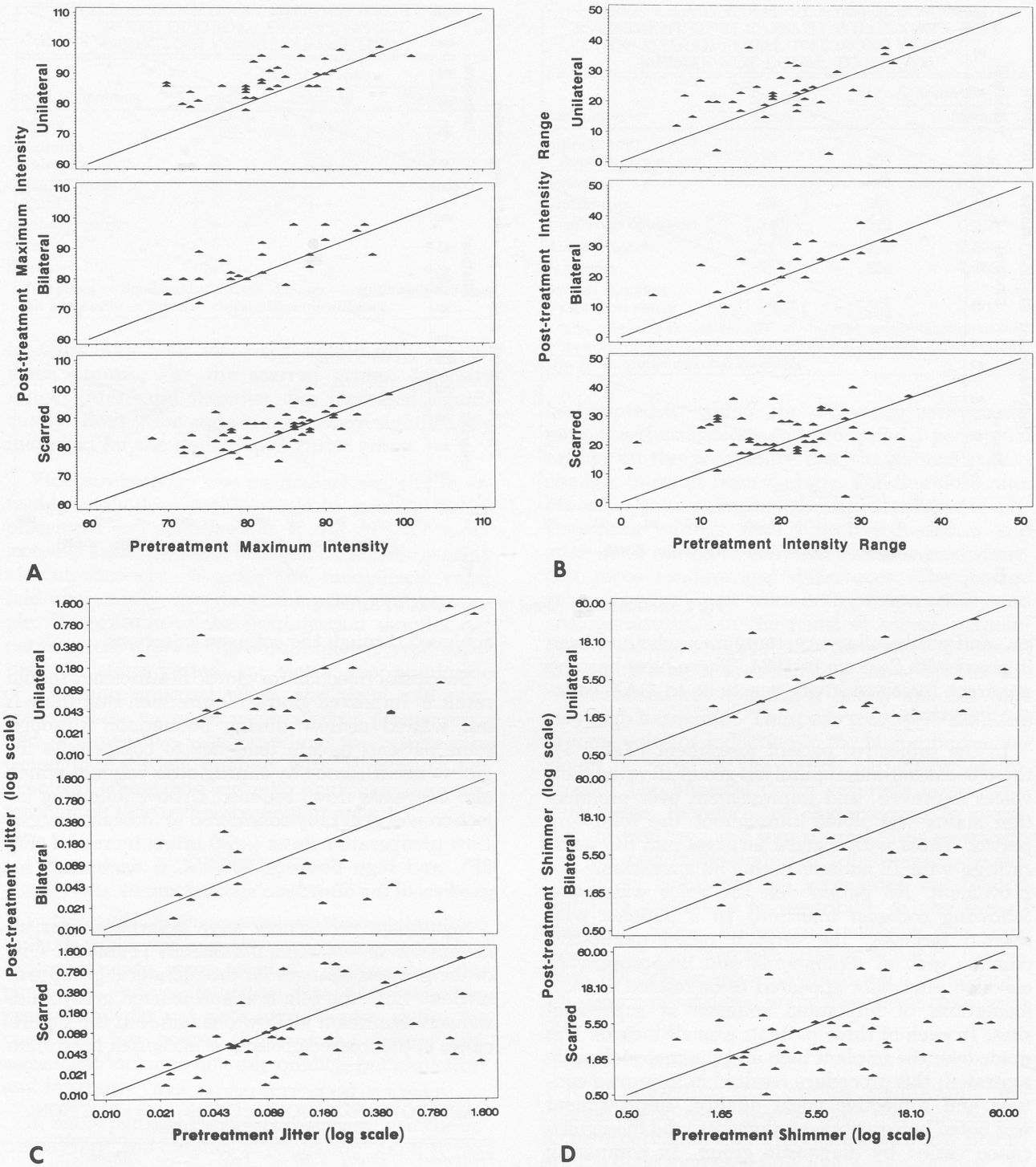

Fig 2. Scatterplots of three treatment groups' performance on measures of vocal function before and after collagen injections. A) Maximum intensity. B) Intensity range. C) Jitter. D) Shimmer. (Continued on next page.)

assumes that the distribution of the data is symmetric about the median.

RESULTS

There were no serious complications or side effects for any of the 119 patients. Two reactions to Zyderm injection in the vocal fold could be considered delayed hypersensitivity reactions. In 1 patient redness was noted at the injection site and developed at the skin test site 5 weeks after the initial skin test and 1 week after vocal fold injection. The second patient developed redness of the injected vocal fold at 1 year postinjection. Neither of these patients experienced any airway compromise and both noted improved voice that persisted. Interestingly, they were both alcoholics, heavy smok-

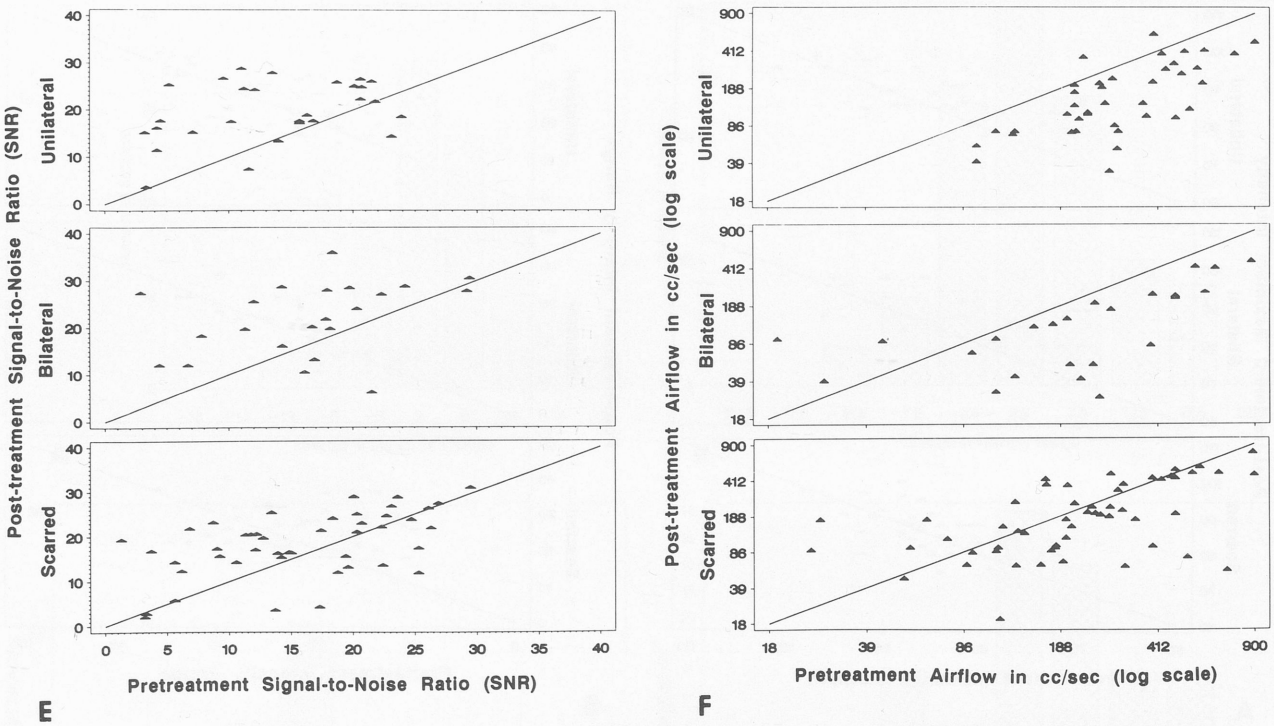

Fig 2, continued. E) Signal to noise ratio. F) Airflow.

ers, and posthemilaryngectomy men who had been injected with Zyderm in 1984. There have been no apparent hypersensitivity reactions to GAX collagen injections.

In the subjective patient assessment (Table 1), those in the unilateral paralysis group all rated their voices improved, and improvement over preinjection status was noted throughout the follow-up period. Those with scarred larynges had the worst ratings, with 12 patients noting no appreciable improvement. No patient felt the voice was worse following collagen injection. In 3 patients with scarred larynges, the surgeon noted qualitative changes such as diplophonia and inappropriately elevated pitch that appeared to be related to focal loculations of implanted collagen at superficial sites. In each of those patients a small incision was made over the implant bleb and the material easily aspirated; this procedure resulted in improved contour and subjective vocal quality. Improvement was noted by perceptual judgments, and the significance varied by diagnostic group. In comparing pretreatment to posttreatment assessments the overall improvement was significant at $p = .00023$ (unilateral $p = .021$, bilateral $p = .71$, and scarred $p = = .0009$).

Acoustic measures evaluated from pretreatment to posttreatment included maximum intensity, intensity range, jitter, shimmer, airflow, and SNR (Figs 1 and 2). In general, maximum intensity, intensity range, shimmer, and SNR increased and jitter and airflow decreased. Results were predicted (Table 2) as a function of the anatomic changes achieved through the collagen injections.

Successful injection for glottic insufficiency should result in improved glottic closure such that there is less wasted airflow during phonation. Although some patients have a tendency to compensate for glottic insufficiency by supraglottic valving, which also decreases flow, reduced airflow following injection was generally considered to indicate success. Low preoperative flows (<80 mL/s) increased (Fig 2F), and high flows (>200 mL/s) decreased, regardless of the disorder classification.

Significant differences were determined for all groups for six objective parameters (Table 3). One of the greatest changes for the unilateral group was airflow. Both the bilateral and scarred groups also showed significant airflow changes, but the significance in the scarred group was marginal. Maximum

TABLE 2. SELECTED VOCAL PARAMETERS AND HOW THEY SHOULD CHANGE AS FUNCTION OF TREATMENT GOALS

Treatment Goal	*Intensity*	*Airflow*	*Frequency*	*Jitter*	*Shimmer*	*SNR*
Improved closure	+	−	−	−	−	+
Decreased stiffness	+	−	−	+	0	+
Improved vocal fold contour	+	−	0	−	0	+
Reduced hyperfunction	0	+	0	+	0	0

SNR — signal to noise ratio, plus — should increase, minus — should decrease, zero — no predictable change.

TABLE 3. SIGNIFICANT DIFFERENCES FOR THREE DISORDER GROUPS ON SIX OBJECTIVE VOCAL PARAMETERS

Vocal Parameters	*Disorder Groups*		
	Scarred	*Bilateral*	*Unilateral*
Airflow	+	+ +	+ +
Maximum intensity	+ +	+ +	+ +
Signal to noise ratio	+ +	+ +	+ +
Intensity range	+ +	−	+
Jitter	+ +	−	+ +
Shimmer	+ +	+ +	+ +

Two pluses — significantly different, one plus — significantly different but marginally so, minus — not significantly different.

TABLE 4. LARYNGEAL VIDEOSTROBOSCOPIC ASSESSMENT OF 15 CASES BY WILCOXON'S TEST OF MEDIAN EQUAL TO 0.000000 VERSUS MEDIAN NOT EQUAL TO 0.000000

Parameters	*No. of Cases*	*Estimated*	
		p	*Median*
Supraglottic hyperfunction	15	.001	1.000
Periodicity	14*	.281	0.000
Glottic gap	15	.001	1.000
Amplitude vibration	14*	.022	0.500
Mucosal wave	14*	.022	0.500
Symmetry	15	.234	0.500
Overall function based on above	15	.001	3.000

*One subject could not be rated on vibratory activity because of malfunction of strobe light, so that subject was rated only on supraglottic activity, glottic gap, and symmetry.

intensity and SNR increased significantly for all three groups. For the scarred group, intensity range, jitter, and shimmer also increased significantly. Both jitter and shimmer were significantly increased for the unilateral disorder group.

Videostroboscopy was particularly helpful in assessing individual patients and in guiding initial placement and modification. It was difficult to objectively assess results of collagen injections by using videostroboscopy, because the medialized vocal fold was usually obvious in the postoperative sample. Recognition of the postinjection samples did not interfere with ratings of supraglottic hyperfunction, waveform periodicity, glottic gap, amplitude of vibration, mucosal wave, and vocal fold symmetry. These measures were rated on preoperative and postoperative videotapes and the results subjected to statistical analysis with Wilcoxon's test (Table 4). These data suggest a significant improvement in all videostroboscopic parameters.

DISCUSSION

SUBJECTIVE MEASURES

In this study, voice improvement was determined by both subjective and objective measures. Patient self-assessments were, overall, higher than the perceptual judgments of the panel of experts; the professional did not note improvement unless the voice was less hoarse, whereas the patient self-assessment included not only quality, but also effort and loudness.

In many patients the primary concern was the extreme effort and dyspnea of phonation; another frequent concern was inadequate vocal volume. After successful treatment, patients perceived a louder voice as improved because they could carry on a more normal life talking over noise in restaurants, cars, etc. Improved closure would often result in increased intensity levels even when quality was not changed. Although such changes may not have been apparent to the listener, for the speaker they were very important.

The patient self-assessments related well to the measures of airflow, SNR, and intensity. One might be tempted to explain the difference between the patient self-assessment and professional perceptual ratings on the probability that the patient expects changes to result from therapy, and therefore rates his or her voice as improved. The correlation of self-assessment ratings with objective measures and analysis of ratings in different disorder groups suggest more fundamental differences. The scarred group had the worst voice both preoperatively and postoperatively, but the panel of speech pathologists noted more individuals with improved voice in this group than in the other two. Some of these patients started out aphonic or nearly aphonic with very high harmonics. Thus, any treatment resulting in some voice or reduction in the higher harmonics would be rated by the speech pathologist as improved. The bilateral group generally began with some voice, though often characterized by weakness, breathiness, and poor control. This group also had the most individuals with other neurologic and respiratory problems that were often not treated and that continued to contribute to the overall quality of voice. Following treatment, the voice was louder and therefore rated as better by the patient, but not necessarily by the speech pathologist, who was more attuned to the absence of changes in quality.

OBJECTIVE MEASURES

It is interesting that airflow significantly decreased for all three groups. Even more interesting is the observation that individuals with low preoperative flows increased flow following treatment. In other words, the treatment tended to normalize values. It was anticipated that increased glottic closure would result in increased intensity and an improved SNR, as proved true for all three disorder groups. It was also assumed that increased closure would result in better vocal control, less aerodynamic turbulence, and decreased perturbation values. Contrary to expectations, jitter and shimmer increased significantly, not only in the unilateral group but in the scarred group as well. The bilateral groups showed a similar response, but only shimmer was signifi-

cantly changed.

Although laryngeal videostroboscopy is extremely useful in assessing disease and in observing the effect of treatment, it is difficult to objectively quantify these results to assess efficacy. It is possible to observe the effect of injection on vocal fold vibration and to determine the degree of correction of glottic closure; one can also grossly quantify the amplitude of vibration, mucosal wave, and periodicity. Unfortunately, it is difficult to mask the treated larynx because of the obvious displacement and whitish color often found in the injected fold. It is therefore not possible to objectively compare random preoperative and postoperative samples to eliminate judgment bias.

PHYSIOLOGIC ASPECTS OF COLLAGEN INJECTIONS

In addressing any particular type of disorder of the vocal fold, one must consider the components contributing to the dysphonia, including respiratory support and the vibratory structure. Often subtle changes in vocal fold composition affect vibratory properties, so that it is undesirable to lump all patients with paralysis or glottic insufficiency into the same group. For example, simply adding mass to a deficient vocal fold does not assure adequate vibration; in some instances it may increase stiffness and thereby impede vibration. The physical properties of GAX allowing superficial precise placement in focal defects and the biologic properties rendering it effective in the scarred larynx make collagen useful in addressing complex vocal fold problems associated with discrete tissue loss or scarring.

Resorption is reduced when collagen is injected into more superficial vocal fold levels (superficial lamina propria) and, in many patients, a superficially injected implant could be seen easily through the transparent mucosa years after injection. The recent use of GAX collagen has drastically reduced the amount of resorption,[25,26] but it may still occur in some patients. Usually it is very gradual and only minimal. In most of these patients, such resorption is not accompanied by a decrement in voice function. It is likely that some degree of resorption occurs in all patients, but this is quantitatively offset by deposition of host collagen. Functionally such change may be insignificant as long as the functional correction remains. Those patients who actually lose correction but maintain voice improvement deserve comment.

We hypothesize that the patient receives immediate relief after injection, and if the implant is properly placed in the lamina propria, gradual resorption and replacement allow the vocal mechanism to compensate incrementally for small changes. In other words, some neuromuscular retraining is occurring over time as the patient adjusts to these small changes, allowing the patient to hit the vocal target even with an inadequate vocal fold structure. This biologic successive approximation training is an example of alteration of the nervous system through biofeedback. Such nervous system plasticity may be an important mechanism in the success of collagen injection in some patients (H. Okamura, personal communication, 1989).

Reviewing selected patients' videostroboscopic studies reveals four patterns of change: 1) correction persists with negligible perceptible change, 2) correction decreases over the first few weeks and then stabilizes within 1 to 3 months, 3) correction persists months to years and then suddenly, usually after an upper respiratory tract infection, resorption occurs, and 4) rapid resorption occurs in a few patients within weeks. This last group consists mainly of patients with other medical problems such as Parkinson's disease. It is not totally clear why these patients are so resistant to correction. Problems with neuromotor control might explain their inability to adapt, but it is not at all clear why they should be susceptible to implant resorption.

In those patients for whom the implant persists but the contour or distribution is not ideal, it is possible to redistribute superficially placed collagen for several months after injection. In patients with less than ideal contour, voice, and stroboscopic findings following injection, visible collagen was nudged from an anterior to a more posterior location with the edge of the injection device; such procedures were done within 2 weeks of injection, by using topical anesthesia and indirect laryngoscopy in the outpatient clinic. In three patients we easily removed small focal blebs of injected collagen, within 1 year of injection, by placing a small incision over the collagen and aspirating with a small suction tip. No apparent scar tissue or inflammatory tissue developed, and in each case the voice improved with loss of diplophonia and decreased roughness.

No patients treated with GAX collagen injection experienced airway compromise, focal redness, swelling, or other signs of allergic reactions. Delayed onset of erythema at the injection site in two patients — one of whom also developed redness at the skin test site — occurred early in our series when Zyderm (not GAX collagen) was used. Overall, GAX preparations are less antigenic and persist longer.[37] Zyderm, Phonagel, and Zyplast are qualitatively different from other available forms of collagen (Koken Atelocollagen, Gelfoam, Collastat, and Avitene), and their biologic characteristics seem most favorable for vocal fold injection.[34] Other studies may not be comparable if different materials are used for injection.

ROLES OF COLLAGEN

Factors that determine the efficacy of collagen injection include the degree of glottic insufficiency

and the specific vocal fold disorder. In some instances conditions may be best treated by combining collagen injection with other modalities such as thyroplasty. Our experience suggests that collagen injection may be used to treat many different conditions, but it is particularly useful in four situations.

Atrophied Vocal Fold. Examples include patients with high vagal lesions showing loss of recurrent and superior laryngeal nerves, presbylaryngis with loss of vocal fold connective tissue bulk and a characteristic arrowhead-shaped residual glottic gap during phonation, congenital hypoplasia in which there is failure of development of the layers of vocal fold such as in sulcus vocalis, and isolated superior laryngeal nerve paralysis. In all of these examples there is loss of fullness of the vocal fold, often associated with a medial furrow. Since collagen can be injected effectively in a superficial plane, it is possible to fill out such folds and recontour the vocal fold to match the contralateral side.

Scarred Vocal Fold. Scarring of the membranous vocal fold is a difficult problem, because the functional integrity of the tissue is destroyed, and even with perfect displacement, restoration of vibratory activity will not occur unless the tissues undergo some biologic transformation. No procedure or material besides collagen has been shown to address this problem. Collagen injection has been demonstrated to soften scar tissue in the dermis[38] and also in vocal folds.[33] Such changes have allowed for additional augmentation and restoration of the body-cover relationship required for vocal fold vibration. This effect of collagen is based theoretically on the biologic activity of the implant affecting the scar tissue–amino acid equilibrium to allow remodeling over time. Unfortunately, it is difficult to inject anything into scar tissue, and optimal results may take many injections over several years. For now, there are no suitable alternatives.

Minimal Glottic Insufficiency. In patients with relatively minimal glottic insufficiency who are bothered by weak, breathy voice production, collagen injection has proven a relatively safe and successful method of treatment. Many patients with presbylaryngis, with bilateral paresis from neurologic disease or trauma, and with bowing due to cricothyroid muscle weakness fit in this group. We found that small amounts (0.05 to 0.20 cm^3) of GAX collagen injected in the plane of the vocal ligament and the intermediate layer of the lamina propria were successful at producing improved voices.[32] These cases may represent instances in which some gradual resorption occurs as the patient develops improved phonation strategies.

Focal Vocal Fold Defects and Adynamic Segments. Focal loss of tissue or scarring confined to a limited area of the membranous vocal fold requires precise placement of a filler substance. Often the scarring may be so subtle as to escape detection on routine examination but will appear as an adynamic segment, with absence of a mucosal wave, on laryngeal videostroboscopy. Collagen can be injected with extreme precision at the site of the defect in mucosal and immediate submucosal tissues. This is a unique advantage over Teflon, which must be injected deep into the thyroarytenoid muscle.

Each of the four conditions can coexist with additional vocal fold disease that might be more suitably handled with a different form of treatment such as thyroplasty, reinnervation, or arytenoid adduction. In some of these instances, collagen injection might be considered as an adjunctive measure.

In addition to patient selection, the most important factor in determining the success of collagen injection is proper technique. All those who have reported successful management of glottic insufficiency by collagen injection have described placement of the implant at a superficial level in the vocal fold. This is quite different from the placement of Teflon. Deep injection of collagen results in poor correction of the defect and rapid resorption of the implant. If the material fails to be distributed as intended, it is possible to modify the contour by rubbing the edge of the vocal fold with the injector device. Scarred vocal folds may require injection at different levels to facilitate maximal distribution of the implant.

SUMMARY AND CONCLUSIONS

This study and other clinical data indicate that collagen injection is relatively safe and useful in treating atrophic, scarred, or focally damaged vocal folds, and that it is helpful in relieving symptoms in patients with a small degree of glottic insufficiency. Some conditions treatable with collagen cannot be handled effectively with other treatment modalities, and other conditions might benefit from collagen injection as an alternative or adjunctive measure. While there is no reason to claim that collagen injection is the single best treatment for glottic insufficiency, these data support inclusion of GAX collagen injection in the armamentarium of the phonosurgeon engaged in treating glottic insufficiency problems. Collagen differs from other injectables in that it is a bioimplant with the capacity to be assimilated into the host tissues and soften scar tissue. A collagen implant can be redistributed or removed after injection without harmful effects. No patients have exhibited allergic reactions to the newer GAX collagens (Zyplast or Phonagel).

Acceptance, however, has been hampered by concerns over safety and efficacy that do not seem justified on the basis of worldwide experience and the data presented in this study. Ironically, Gelfoam has never been approved by the FDA for laryngeal injection, and yet it is commonly injected into vocal folds by laryngologists to determine if a patient is a suitable candidate for Teflon injection.

A GAX collagen generically identical to Zyplast is commercially available, but use in the larynx has not been approved.

The immediate challenge is to make collagen injection available to patients in need. Collagen injection has been studied more extensively than many other currently used substances. Our results on 119 patients showing it to be relatively safe, well tolerated, and effective are consistent with those of other researchers. Collagen can be used to treat a variety of conditions for which there are no good alternatives, and it can be considered a useful adjunctive measure in treating complex vocal fold problems.

ACKNOWLEDGMENTS — The authors thank Thomas D. Cook for his assistance in statistical analysis, Joseph F. Bollettierri for data processing, Celeste Kirk for editorial advice, Loree A. Ketner for typing the manuscript, and Danna Koschkee, Edie Swift, and Dawn Biever-Lowery for assisting in data collection.

REFERENCES

1. Arnold GE. Vocal rehabilitation of paralytic dysphonia. Arch Otolaryngol 1962;76:358-68.

2. Toomey JM, Brown BS. The histological response to intracordal injection of Teflon paste. Laryngoscope 1967;77:110-20.

3. Stone JW, Arnold GE. Human larynx injected with Teflon paste. Histologic study of innervation and tissue reaction. Arch Otolaryngol 1967;86:550-61.

4. Stone JW, Arnold GE, Stephens CB. Intracordal Polytef (Teflon) injection. Histologic study of three further cases. Arch Otolaryngol 1970;91:568-74.

5. Dedo HH, Carlsöö B. Histologic evaluation of Teflon granulomas of human vocal cords. A light and electron microscopic study. Acta Otolaryngol (Stockh) 1982;93:475-84.

6. Tucker HM. Complications after surgical management of the paralyzed larynx. Laryngoscope 1983;93:295-8.

7. Wenig BM, Heffner DK, Johnson FB. Teflonomas of the larynx and neck. Hum Pathol 1990;21:617-23.

8. Solomons NB, Livesey JR. Acute upper airway obstruction following Teflon injection of a vocal cord: the value of nebulized adrenaline and a helium/oxygen mixture in its management. J Laryngol Otol 1990;104:654-5.

9. Lewy RB. Teflon injection of the vocal cord: complications, errors, and precautions. Ann Otol Rhinol Laryngol 1983; 92:473-4.

10. Watterson T, McFarlane S, Menicucci A. Vibratory characteristics of Teflon-injected and noninjected paralyzed vocal folds. J Speech Hear Disord 1990;55:61-6.

11. Malizia AA, Reiman HM, Myers RP, et al. Migration and granulomatous reaction after periurethral injection of Polytef (Teflon). JAMA 1984;251:3277-81.

12. Ellis JC, McCaffrey TV, DeSanto LW, Reiman HV. Migration of Teflon after vocal cord injection. Otolaryngol Head Neck Surg 1987;96:63-6.

13. Isshiki N, Morita H, Okamura H, Hiramoto M. Thyroplasty as a new phonosurgical technique. Acta Otolaryngol (Stockh) 1974;78:451-7.

14. Kaufman JA. Laryngoplasty for vocal cord medialization: an alternative to Teflon®. Laryngoscope 1986;96:726-31.

15. Crumley RL, Izdebski K, McMicken B. Nerve transfer versus Teflon® injection for vocal cord paralysis: a comparison. Laryngoscope 1988;98:1200-4.

16. Ford CN, Martin DW, Warner TF. Injectable collagen in laryngeal rehabilitation. Laryngoscope 1984;94:513-8.

17. Ford CN. Histologic studies on the fate of soluble collagen injected into canine vocal folds. Laryngoscope 1986;96:1248-57.

18. Okamoto K. A fundamental study of injectable collagen in vocal rehabilitation. J Otolaryngol Jpn (Tokyo) 1987;90:394-403.

19. Ford CN, Bless DM, Campbell D. Studies of injectable soluble collagen for vocal fold augmentation. Rev Laryngol Otol Rhinol (Bord) 1987;108:33-6.

20. Trapp TK, Berke GS, Bell TS, Hanson DG, Ward PH. Effect of vocal fold augmentation on laryngeal vibration in simulated recurrent laryngeal nerve paralysis: a study of Teflon and Phonogel. Ann Otol Rhinol Laryngol 1989;98:220-7.

21. Ford CN, Bless DM. A preliminary study of injectable collagen in human vocal fold augmentation. Otolaryngol Head Neck Surg 1986;94:104-12.

22. Spiegel JR, Sataloff RT, Gould WJ. The treatment of vocal fold paralysis with injectable collagen: clinical concerns. J Voice 1987;1:119-21.

23. Ford CN, Bless DM. Clinical experience with injectable collagen for vocal fold augmentation. Laryngoscope 1986;96:863-9.

24. Remacle M, Clerin M, Dubois P, Ryckaert M, Bertrand B, Hamoir M. Exploration of glottic function before and after injection of collagen for rehabilitation of the vocal cord. Acta Otorhinolaryngol Belg 1986;40:405-20.

25. Remacle M, Marbaix E, Hamoir M, Declaye X, van den Eeckhaut J. Initial long-term results of collagen injection for vocal and laryngeal rehabilitation. Arch Otorhinolaryngol 1989;246: 403-6.

26. Remacle M, Marbaix E, Hamoir M, Bertrand B, van den Eeckhaut J. Correction of glottic insufficiency by collagen injection. Ann Otol Rhinol Laryngol 1990;99:438-44.

27. Okamoto K, Kawamura Y, Yumoto E, Okamura H. The application of injectable collagen in vocal rehabilitation. Proc Int Assoc Logopedics Phoniatrics 1986;1:484-5.

28. Joussen K. Soluble collagen as a bioimplant to remove glottic insufficiency. Proc Int Assoc Logopedics Phoniatrics 1986; 1:476-8.

29. Yumoto E, Okamoto K, Kawamura Y, Okamura H. Injection of atelocollagen to augment the paralyzed vocal cord. J Jpn Bronchoesophagol Soc 1988;39:271-4.

30. Remacle M, Marbaix E. Collagen implants in the human larynx, pathological examination of two cases. Arch Otorhinolaryngol 1988;245:203-9.

31. Ford CN, Gilchrist KW, Bartell TE. Persistence of injectable collagen in the human larynx: a histopathologic study. Laryngoscope 1987;97:724-7. [Erratum, Laryngoscope 1987;97: 1042.]

32. Ford CN, Bless DM, Pratt S, Peppard R, Collins MJ, Collins MT. Bovine collagen injections in the senile larynx [Abstract]. ASHA 1988;30:96.

33. Ford CN, Bless DM. Collagen injection in the scarred vocal fold. J Voice 1987;1:116-8.

34. DeLustro F, Contell RA, Nguyen MA, McPherson JM. A comparative study of the biologic and immunologic response to medical devices derived from dermal collagen. J Biomed Mater Res 1986;20:109-20.

35. Ford CN. A multipurpose laryngeal injector device. Otolaryngol Head Neck Surg 1990;103:135-7.

36. Ford CN. Laryngeal injection techniques. In: Ford CN, Bless DM, eds. Phonosurgery: assessment and surgical management of voice disorders. New York, NY: Raven Press, 1991:123-41.

37. Kligman AM, Armstrong RC. Histologic response to intradermal Zyderm and Zyplast (glutaraldehyde cross-linked) collagen in humans. J Dermatol Surg Oncol 1986;12:351-7.

38. Stegman SJ, Tromovich TA. Implantation of collagen for depressed scars. J Dermatol Surg Oncol 1980;6:450-3.

SURGICAL ANATOMY OF THE PHARYNGEAL PLEXUS

MARK I. SINGER, MD

SAN FRANCISCO, CALIFORNIA

Total laryngectomy remains central in the treatment of laryngeal carcinoma, and rehabilitation of voice is crucial to satisfactory recovery. Esophageal and tracheoesophageal speech are the preferred methods, but are dependent on the changing tonicity of the pharyngoesophageal segment. Effective relaxation of the pharyngeal constrictor muscles is achieved by pharyngeal plexus neurectomy. The surgical anatomy is presented and no significant disruption of deglutition is observed. Vocal results compare favorably to other methods.

KEY WORDS — laryngectomy, myotomy, neurectomy, speech rehabilitation.

Study of the surgical anatomy of the pharyngeal plexus is part of the evolution of clinical effort to reduce the problem of esophageal and tracheoesophageal speech failure because of involuntary air trapping. Initial experience with a large patient population of esophageal speech failures revealed that nearly 40% of laryngectomees were unable to release air for esophageal voice production in spite of adequate training, motivation, and injection techniques. When this group underwent voice restoration by tracheoesophageal puncture, the identical problem of air trapping was identified with eventual speech failure.[1]

The method of alaryngeal voice restoration by tracheoesophageal puncture introduces air into the esophagus inferior to the esophageal inlet and the cricopharyngeus muscle. Entry at this level takes advantage of favorable mechanics of the tracheostoma and its capacity to prevent uncontrolled fistula formation. Brisk distention of the esophagus results in "reflexive" elevation of tone in the upper esophageal sphincter, limiting air release through the pharynx with resultant air trapping and voice dysfluency. The characteristic phonatory effort is "spasmodic" and is accompanied by Valsalvalike behavior, limited speech production, and facial grimacing. Deglutition abnormalities have not been described in the absence of pharyngeal stricture, and strictures are rarely associated with speech failure in the laryngectomized population.

Clinically, the dynamics underlying the problem of air trapping were confirmed by an anesthetic block of the pharyngeal plexus. The radiographic appearance of the pharynx was altered after effective relaxation of the pharyngeal constrictor muscles, and free airflow produced fluent voice. The voice and altered pharyngeal constrictors were consistent with the duration of the injected anesthetic agent.

Initially, relaxation of the laryngectomized pharynx was accomplished by a 4- to 6-cm myotomy of the middle and inferior pharyngeal constrictor muscles and the cricopharyngeus muscle. Although this was generally effective, the trauma to the pharyngeal wall resulted in salivary leakage or wound breakdown in 8% of cases.[2] It is theorized that incision of the constrictor muscles may interfere with the vascularity of the pharyngeal wall, with subsequent ischemia and mucosal dehiscence. Therefore, a denervation procedure was introduced that was less destructive but capable of relaxation of the pharyngeal constrictor muscles.

MATERIALS AND METHODS

Three groups of 10 patients were studied over a 3-year period. The first had myotomy only, the second had cricopharyngeal myotomy accompanied by pharyngeal plexus neurectomy, and the third had pharyngeal plexus neurectomy alone. The second group was selected because of concern that the initial experiences with neurectomy produced subjective problems with deglutition. The third group represented the most recent experience with improved techniques for plexus identification and lysis.

The first description of laryngectomy with neurectomy suggested dissection and identification of the nerve branches after completion of the resection. This was replaced by the current approach to pharyngeal plexus identification with the in situ larynx in order to take advantage of the normal anatomic structures. The pharyngeal plexus is composed of nerve fibers originating from the 9th, 10th,

From the Department of Otolaryngology–Head and Neck Surgery, University of California, San Francisco, California.

Presented at the meeting of the American Laryngological Association, Waikoloa, Hawaii, May 4-5, 1991.

REPRINTS — Mark I. Singer, MD, Mt Zion Hospital of UCSF, 1600 Divisadero St, PO Box 7921, San Francisco, CA 94120.

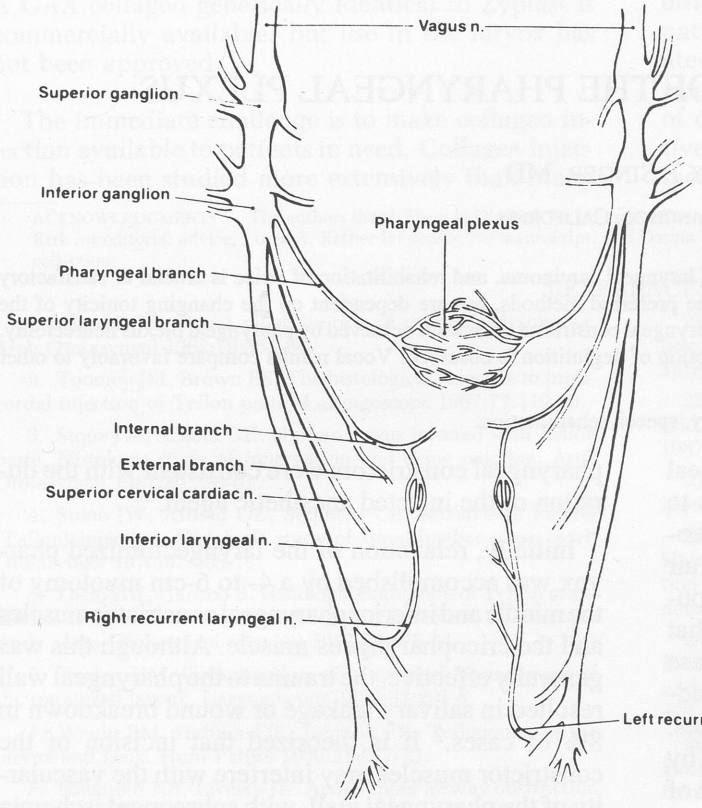

Fig 1. Anatomic depiction of pharyngeal plexus.

and 11th cranial nerves (Fig 1). There are few descriptions of this neural plexus. A plexus of nerve fibers is often illustrated residing in the retropharyngeal plane with crossover to the contralateral side. The fibers extend variably to the level of the cricopharyngeus muscle. Experimental studies of the innervation of the cricopharyngeus muscle by Dey and Kirchner[3] suggested a complex balance of motor fibers from the vagus nerve and the cervical sympathetics. Attributing autonomic innervation to striated muscle is controversial and represents a unique instance in biology.[4]

Identification of the motor innervation to the upper esophageal sphincter has not been previously described in the course of laryngectomy surgery. Following neck dissection in continuity with the laryngectomy, the larynx is mobilized by dissecting the suprahyoid musculature and separating the inferior sternohyoid and sternothyroid muscles with hemithyroidectomy. The inferior pharyngeal constrictor muscles are *not* sectioned at the oblique line of the thyroid cartilage, while traction on the larynx places tension on the constrictor muscles. Dissection to the level of the superior border of the inferior pharyngeal constrictor muscle will reveal an anatomic hiatus at the inferior border of the middle pharyngeal constrictor muscle. The middle pharyngeal constrictor muscle is a bulkier structure than the inferior constrictor and is 1.5 cm in vertical dimension, representing nearly 50% of the length of the inferior constrictor.

The greater cornu of the hyoid bone splits the middle pharyngeal constrictor into halves (Fig 2). The superior cornu of the thyroid cartilage indicates the inferior extent of the dissection of the pharyngeal plexus. The neural structures are located as they cross the inferior border of the middle pharyngeal constrictor muscle, coursing through the anatomic hiatus described above.

The retropharyngeal tissues and investing fascia are divided to expose the superior laryngeal nerve or artery. The caliber of nerve fibers composing the human pharyngeal plexus is less than 50% that of the superior laryngeal nerve. The main branches subdivide rapidly in their course inferiorly. At this point, electrostimulation of the nerve fibers is used to confirm the motor innervation of the pharyngeal constrictors. Stimulation at 0.5 mA produces a brisk contraction of the muscle fibers from superior to inferior, corresponding with the "stripping" activity of the pharyngeal wall during swallowing.

After identification of the neural plexus is complete, the fibers are tented above the underlying musculature and are electrocoagulated before division. The pharynx is entered through either the vallecula or the pyriform sinus. Scissors dissection is preferred, with one blade in the lumen while the other

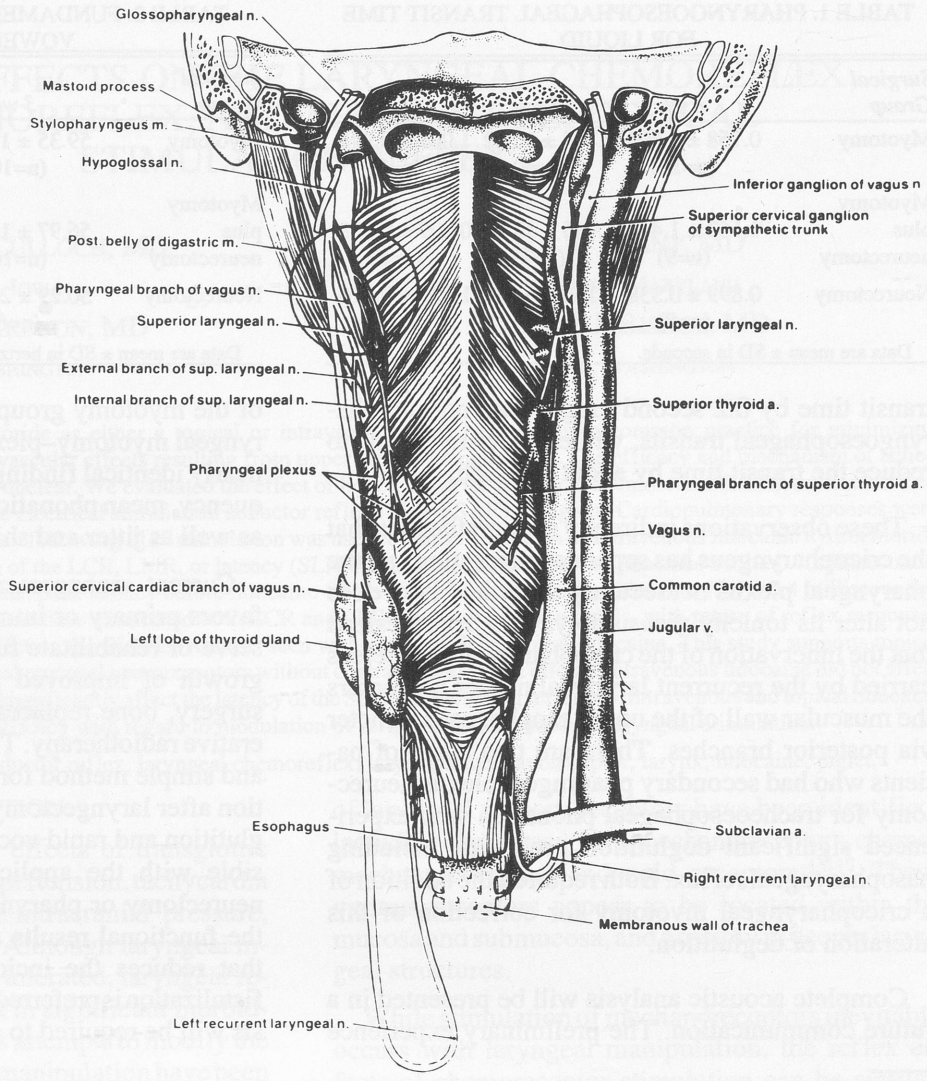

Fig 2. Relationship of pharyngeal plexus to underlying musculature of pharyngeal wall.

"straddles" the constrictor muscles. The mucosa and the constrictors are divided sharply, and the larynx is separated from the pharynx. This technique avoids separating the muscle from the mucosa and preserves its vascularity.

RESULTS

In the study groups, pharyngoesophageal mean transit times were 1.003 seconds for the myotomy alone, 0.899 second for myotomy of the cricopharyngeus and pharyngeal plexus neurectomy, and 1.220 seconds for neurectomy alone when liquids were evaluated 1 year later (Table 1). Normal deglutition for pharyngoesophageal transit is 1.0 second. A similar trend was noted for paste, with the myotomy group measured at 0.649 second, myotomy with neurectomy at 0.777 second, and neurectomy at 0.935 second.

Acoustic analysis of speech at 1 year for the myotomy group revealed a mean fundamental frequency of 58.58 Hz, and for the combined group, 58.72 Hz (Table 2). The maximum phonation time was 13.73 seconds for the myotomy group and 16.57 seconds for the combined group. Words per minute for the myotomized patients were 145.38, and for the combined group, 161.53. Analysis of the neurectomy-alone group is unavailable for this presentation because of problems with the computer program.

DISCUSSION

Although this study is limited by lack of available computerized acoustic data for the pure neurectomy group of patients, nevertheless, important trends are demonstrated. Initial concern that pharyngeal plexus neurectomy alters deglutition is supported by the observations. It is evident that limiting the myotomy to the cricopharyngeus muscle and neurectomizing the inferior and middle pharyngeal constrictors have similar results relative to deglutition analysis. The plexus neurectomy alone delays pharyngoesophageal

TABLE 1. PHARYNGOESOPHAGEAL TRANSIT TIME FOR LIQUID

Surgical Group	*3 wk*	*6 mo*	*12 mo*
Myotomy	0.758 ± 0.509 (n=10)	0.704 ± 0.302 (n=9)	1.003 ± 0.941 (n=8)
Myotomy plus neurectomy	1.162 ± 1.417 (n=9)	1.135 ± 1.096 (n=7)	0.899 ± 0.338 (n=8)
Neurectomy	0.899 ± 0.338 (n=8)	1.196 ± 0.586 (n=7)	1.220 ± 0.516 (n=6)

Data are mean ± SD in seconds.

TABLE 2. FUNDAMENTAL FREQUENCY DURING VOWEL PHONATION

Surgical Group	*3 wk*	*6 mo*	*12 mo*
Myotomy	59.35 ± 19.10 (n=10)	51.54 ± 15.57 (n=8)	58.58 ± 9.69 (n=7)
Myotomy plus neurectomy	56.97 ± 15.26 (n=10)	46.22 ± 14.00 (n=7)	58.72 ±12.50 (n=5)
Neurectomy	50.29 ± 20.01 (n=6)	—	—

Data are mean ± SD in hertz.

transit time by 0.2 second longer than normal pharyngoesophageal transits, while myotomy seems to reduce the transit time by about as much.

These observations indirectly support the idea that the cricopharyngeus has separate innervation and the pharyngeal plexus neurectomy described here does not alter its tonicity measurably. It is hypothesized that the innervation of the cricopharyngeus muscle is carried by the recurrent laryngeal nerves and enters the muscular wall of the upper esophageal sphincter via posterior branches. There are two cases of patients who had secondary pharyngeal plexus neurectomy for tracheoesophageal phonation who experienced significant deglutition problems, including nasopharyngeal reflux. Both required the addition of a cricopharyngeal myotomy for correction of this alteration of deglutition.

Complete acoustic analysis will be presented in a future communication. The preliminary experience of the myotomy group and the combined cricopharyngeal myotomy–plexus neurectomy group reveals nearly identical findings relative to fundamental frequency, mean phonation time, and words per minute, as well as jitter and shimmer.

Current management of head and neck cancer favors primary or immediate reconstruction to preserve or rehabilitate function. This is a natural outgrowth of improved pedicle flaps, microvascular surgery, bone replacement prostheses, and postoperative radiotherapy. The addition of a relatively safe and simple method for optimizing pharyngeal function after laryngectomy that permits satisfactory deglutition and rapid vocal rehabilitation appears possible with the application of pharyngeal plexus neurectomy or pharyngeal constrictor myotomy. If the functional results are equivalent, the technique that reduces the incidence of pharyngocutaneous fistulization is preferred. Further evaluation and analysis will be required to answer this question.

ACKNOWLEDGMENT — The author thanks Barbara Roa Pauloski, PhD, Program Project Coordinator of the Department of Communication Sciences and Disorders of Northwestern University, for her assistance in providing swallowing data on our patients.

REFERENCES

1. Singer MI, Blom ED, Hamaker RC. Further experience with voice restoration after total laryngectomy. Ann Otol Rhinol Laryngol 1981;90:498-502.

2. Singer MI, Blom ED, Hamaker RC. Pharyngeal plexus neurectomy for alaryngeal speech rehabilitation. Laryngoscope 1986;96:50-4.

3. Dey FL, Kirchner JA. The upper esophageal sphincter after laryngectomy. Laryngoscope 1961;71:99-115.

4. Asoh R, Goyal RK. Manometry and electromyography of the upper esophageal sphincter in the opossum. Gastroenterology 1978;74:514-20.

LIDOCAINE EFFECTS ON THE LARYNGEAL CHEMOREFLEX, MECHANOREFLEX, AND AFFERENT ELECTRICAL STIMULATION REFLEX

TIMOTHY M. MCCULLOCH, MD
IOWA CITY, IOWA
PAUL W. FLINT, MD
BALTIMORE, MARYLAND
MARK A. RICHARDSON, MD
SEATTLE, WASHINGTON
MICHAEL J. BISHOP, MD
SEATTLE, WASHINGTON

The use of lidocaine hydrochloride as either a topical or intravenous agent has become a common practice for minimizing laryngospasm and the reflex cardiovascular effects resulting from upper airway manipulation. The efficacy and mechanism of action of lidocaine for this purpose remain unclear. We evaluated the effect of lidocaine on the laryngeal chemoreflex (LCR), mechanoreflex (LMR), and superior laryngeal nerve electrical stimulation adductor reflex (SLN-ESAR) in piglets. Cardiopulmonary responses were used to assess LCR and LMR. Latency following SLN stimulation was used to assess SLN-ESAR. Intravenous lidocaine hydrochloride at 3 mg/kg produced no suppression of the LCR, LMR, or latency (SLN-ESAR onset latency before lidocaine 11.7 ± 0.7 milliseconds, after lidocaine 12.2 ± 0.5 milliseconds; peak latency before lidocaine 13.2 ± 0.2 milliseconds, after lidocaine 13.4 ± 0.4 milliseconds). Topically applied lidocaine at the same dose eliminated both LCR and LMR responses in all animals, with return of reflex responses 15 minutes after application. No effect on the SLN-ESAR was seen with application of topical lidocaine. This study supports topical lidocaine as a suppressant of laryngeal mucosal neuroreceptors without central neural reflex effects. Intravenous lidocaine did not affect peripheral neuroreceptors, nor did it significantly affect the latency of the SLN-ESAR neural reflex arc. Intravenous and topical lidocaine differ in mechanism of action and efficacy with regard to modulation of reflex effects induced by laryngeal stimulation.

KEY WORDS — laryngeal adductor reflex, laryngeal chemoreflex, laryngeal mechanoreceptor, larynx, lidocaine, piglet.

INTRODUCTION

The reflexive physiologic effects of transglottic tracheal intubation include hypertension, tachycardia or bradycardia, elevation of intracranial pressure, cough, and laryngospasm.[1-3] Although laryngeal instrumentation is usually well tolerated, laryngeal reflexes can occasionally result in significant morbidity or mortality. Over the years attempts to modify the reflex responses to laryngeal manipulation have been made, with the mainstay of interventional techniques being the combination of sedative-hypnotic drugs plus intravenous or laryngeal topical lidocaine hydrochloride. Gilbert et al[4] first reported the use of intravenous lidocaine hydrochloride as an adjunct to general inhalation agents in 1951. During the past four decades many articles have been published that either support or dispute the efficacy of lidocaine use during intubation, extubation, or laryngeal manipulation.[1,2,5-12]

The laryngeal and tracheal mucosa is innervated by the sensory branches of the vagus nerve, and the physiologic effects of intubation are mediated primarily through afferent vagal reflexes.[13,14] Several types of laryngeal sensory receptors have been identified, including chemoreceptors, mechanoreceptors, chemomechanoreceptors, and cold receptors.[15-17] These various receptors appear to be located within the mucosa and submucosa, and possibly in deeper laryngeal structures.

While stimulation of mechanoreceptors inevitably occurs with laryngeal manipulation, the reflex effects of chemoreceptor stimulation can be similar, and at time as severe.[13,18] Previous work has shown that topical lidocaine blocks stimulus-induced superior laryngeal nerve (SLN) afferent fiber firing and also eliminates the physiologic side effects of stimulation of laryngeal chemoreceptors and mechanoreceptors.[13,16,17] A large body of clinical work has shown that intravenous lidocaine can alter the physiologic reflex effects of glottic stimulation.[2,3,5-7,9-12] However, the efficacy of intravenous lidocaine's modulation of laryngospasm clinically remains in question.[8] Studies of intravenous lidocaine's effects on the more basic laryngeal reflex events in animal models in general are missing, and understanding of intravenous lidocaine's efficacy and site of action is lacking.

From the Departments of Otolaryngology–Head and Neck Surgery (McCulloch, Flint, Richardson), Anesthesiology (Bishop), and Medicine (Bishop), University of Washington, Seattle, Washington. Supported by the Department of Otolaryngology–Head and Neck Surgery Resident Research Fund. Dr McCulloch is currently in the Department of Otolaryngology–Head and Neck Surgery, The University of Iowa, Iowa City, Iowa. This study was performed in accordance with the PHS Policy on Humane Care and Use of Laboratory Animals, the NIH *Guide for the Care and Use of Laboratory Animals*, and the Animal Welfare Act (7 U.S.C. et seq.); the animal use protocol was approved by the Institutional Animal Care and Use Committee (IACUC) of the University of Washington.

Presented at the meeting of the American Laryngological Association, Waikoloa, Hawaii, May 4-5, 1991. Winner of the Resident Research Award.

Cocaine has been shown to produce central respiratory depression when delivered to regions of the pontine medullary centers of the brain stem.[19] Also, electroencephalographic changes consistent with cortical depression have been identified after intravenous lidocaine was used to supplement halothane inhalation anesthesia.[20] A similar central suppression of cough and laryngospasm has been proposed for intravenous lidocaine.[21,22] However, no study has delineated this "central suppressive" effect of intravenous lidocaine on laryngopulmonary reflex events. Evaluating the effects of lidocaine on well-described and controlled laryngeal reflex phenomena such as the laryngeal chemoreflex (LCR) and the laryngeal adductor reflex could provide insight into the efficacy of lidocaine use during laryngeal manipulation in humans.

In a piglet model we evaluated the effects of topical and intravenous lidocaine on three well-described laryngeal reflexes: the LCR, the laryngeal mechanoreceptor reflex (LMR), and the superior laryngeal nerve electrical stimulation adductor reflex (SLN-ESAR) or laryngeal adductor reflex.

MATERIALS AND METHODS

Nine piglets 2 to 4 weeks old were studied. In five of the animals we studied the effects of lidocaine on the LCR and LMR. Four piglets were used to evaluate lidocaine effects on the SLN-ESAR.

The LCR and LMR are reflex responses to stimulation of the supraglottic laryngeal mucosa with either water (LCR) or pressure (LMR) and manifest as central apnea, cardiovascular changes, and reflex laryngeal closure. The SLN-ESAR is a reflex event initiated by electrical stimulation of the SLN and ending with glottic closure.

The animals were anesthetized with intramuscular ketamine hydrochloride (35 mg/kg) and xylazine hydrochloride (5 mg/kg), which was followed by one third of a dose of ketamine intravenously every 30 to 45 minutes if the animal showed signs of awakening. Each animal was placed supine over a heating pad set at 37°C. Femoral intravenous and arterial catheters were placed surgically. The arterial line was used to monitor blood pressure via a pressure transducer and for blood sampling. The venous line was used to administer fluids and deliver ketamine. A tracheotomy was performed and an endotracheal tube placed to maintain an airway. An anterior midline thyrotomy was performed and stay sutures were placed in the anterior commissure bilaterally. An 18-gauge needle was passed into the endotracheal tube, and endotracheal pressure changes were recorded and the waveform peaks counted to obtain respiratory rate. Transcutaneous rhythm strip electrodes were placed and a cardiac rhythm was recorded. All data were recorded simultaneously on a Grass multichannel strip chart recorder.

Data from the strip chart recording included prestimulus and poststimulus pulsatile blood pressure, heart rate (HR) as counted from the cardiac rhythm strip recording, respiratory rates, and apnea length as counted from the respiratory pressure recording. The apnea length was considered to begin at the time of the final breath prior to water or mechanical stimulus and to end with the onset of regular respiration (more than one respiration within a 10-second period). Cardiovascular effects were assessed by evaluation of HR and mean arterial pressure (MAP). The MAP was calculated by the formula MAP = [systolic BP + (2 x diastolic BP)]/3. The prestimulus levels were taken from the 30-second period just prior to laryngeal stimulation. The poststimulus blood pressure was recorded at the point of greatest hypotension during the apneic period or within 30 seconds poststimulus when no apnea or brief apnea occurred. Poststimulus HR was counted from the point of greatest bradycardia during the apneic period or within 30 seconds poststimulus when no apnea or brief apnea occurred.

The LCR was induced by placing 2 to 3 mL of water on the exposed supraglottic laryngeal mucosa. The mechanoreceptors were stimulated by placing an oversized endotracheal tube transorally and applying pressure to the supraglottis. Apneic response of greater than 3 seconds or hypopnea (respiratory depression of greater than 20% for 30 seconds or longer) with associated cardiovascular changes (a decrease in HR and MAP of more than 5%) was considered a positive response.

The SLN-ESAR was obtained by monopolar needle electrode recording. An intramuscular monopolar electrode was placed under direct visualization into the thyroarytenoid muscle, and a reference electrode was placed subcutaneously. The animal, nerve stimulator, and oscilloscope were grounded. The SLN was isolated and then directly stimulated with a monopolar nerve stimulator set at 1 to 2 V. The stimulus artifact and reflex compound motor unit action potential were recorded with a storage oscilloscope (Tektronix 2232 100-MHz digital storage oscilloscope) and later plotted and measured with a MacIntosh computer. Onset and peak latencies were measured.

The experimental design is outlined in Figs 1 and 2. Lidocaine levels were assessed by Roche Biomedical Laboratories (Sacramento, Calif). Differences in apnea and latency duration were assessed by using Student's *t* test for paired observations.

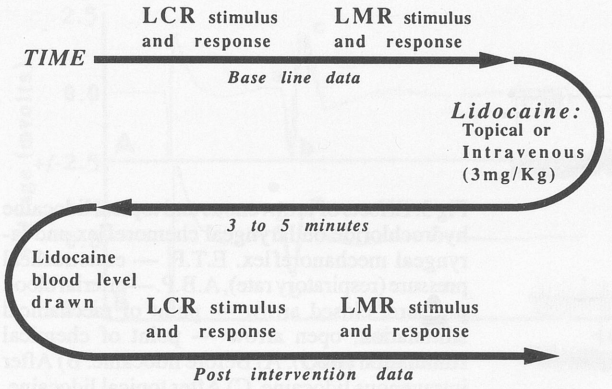

Fig 1. Experiment outline for laryngeal chemoreflex (LCR) and laryngeal mechanoreflex (LMR).

RESULTS

Laryngeal Chemoreflex and Mechanoreflex. Eight trials were run on five animals in the first study group. A reflex response with apnea occurred with stimulation of chemoreceptors and mechanoreceptors in all trials, both before and after administration of intravenous lidocaine. The mean duration of the apnea was shorter after lidocaine, but this difference was not statistically significant (Table 1). In both the prelidocaine and postlidocaine states, stimulation of the chemoreceptors induced a longer apnea duration compared to mechanoreceptor stimulation. An example of the LCR and LMR apnea data is shown in Fig 3. The group results of intravenous lidocaine effects on the LCR and LMR are shown in Table 1. The data are depicted as number and percent of positive reflex responses and mean apnea duration.

The cardiovascular effects of stimulation of the laryngeal chemoreflex and mechanoreflex were quite variable. A change in MAP and HR was identified in only 9 of 22 chemoreflex-induced apneas and during only 2 of 10 nonapneic trials (ie, after topical lidocaine). The cardiovascular effects of the mechanoreceptor stimulation were even less apparent. The cardiovascular changes associated with the chemoreflex apneas were not significantly different before versus after intravenous lidocaine: percentage of delta MAP before, -9.6 ± 15.0, after, -2.4 ± 3.4 ($p = .26$); percentage of delta HR before, -4.9 ± 4.5, after, -5.5 ± 3.7 ($p = .72$). The measured lidocaine levels 3 to 5 minutes after intravenous injection (3 mg/kg) had a value of 4.5 ± 1.4 μg/mL (mean ± SE).

Topical lidocaine effects, again depicted as number and percent of positive reflex responses and mean apnea duration, are shown in Table 2. Topical lidocaine eliminated the LCR and LMR. The single positive response recorded in each group consisted of only a brief period of apnea without cardiovascular changes. All reflex responses had returned by 15 minutes after lidocaine administration.

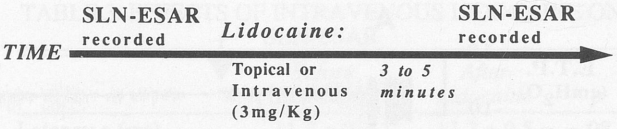

Fig 2. Experiment outline for superior laryngeal nerve electrical stimulation adductor reflex (SLN-ESAR).

Again, the small and variable cardiovascular responses of the chemoreflex were not significantly different before versus after topical lidocaine: percentage of delta MAP before, -2.9 ± 3.3, after -6.7 ± 5.0 ($p = .29$); percentage of delta HR before, -4.8 ± 2.3, after, 1.8 ± 4.5 ($p = .13$). Topical lidocaine did not produce a rise in blood lidocaine levels at 3 to 5 minutes postadministration.

Superior Laryngeal Nerve Electrical Stimulation Adductor Reflex. The waveforms presented in Fig 4 exemplify the SLN-ESAR recordings before and after intravenous lidocaine (3 mg/kg). Two waves were stored before and after lidocaine in each animal. The latencies were measured as onset latency and peak latencies.[23] The combined latencies from three animals are presented as mean and standard deviation in Table 3 (see also Fig 4). There is a trend toward a slight latency prolongation at all points of the SLN-ESAR after intravenous lidocaine in these animals, but latency differences did not reach significance. In one additional animal the 3-mg/kg dose of lidocaine was followed by a dose of 9 mg/kg, and again no change in SLN-ESAR was identified; onset latency at point "a" prelidocaine was 15.0 milliseconds, after 3 mg/kg was 15.1 milliseconds, and after 9 mg/kg was 15.0 milliseconds.

Topical lidocaine effects on the SLN-ESAR were recorded in only one animal. The onset latency at point "a" prelidocaine was 11.4 milliseconds, and postlidocaine was 11.8 milliseconds. The peak latency at point "b" prelidocaine was 13.2 milliseconds, and postlidocaine was 12.8 milliseconds.

DISCUSSION

Gilbert et al[4] were the first to report use of intravenous lidocaine as an adjunct to general anesthesia. In

TABLE 1. EFFECTS OF INTRAVENOUS LIDOCAINE ON LCR AND LMR

	Before Lidocaine	*After Lidocaine*	*p*
LCR			
Positive response	100% (8/8)	100% (8/8)	
Apnea duration (s)	26 ± 17	18 ± 7	.13
LMR			
Positive response	100% (6/6)	100% (6/6)	
Apnea duration (s)	11 ± 8	8 ± 7	.18

LCR — laryngeal chemoreflex, LMR — laryngeal mechanoreflex.

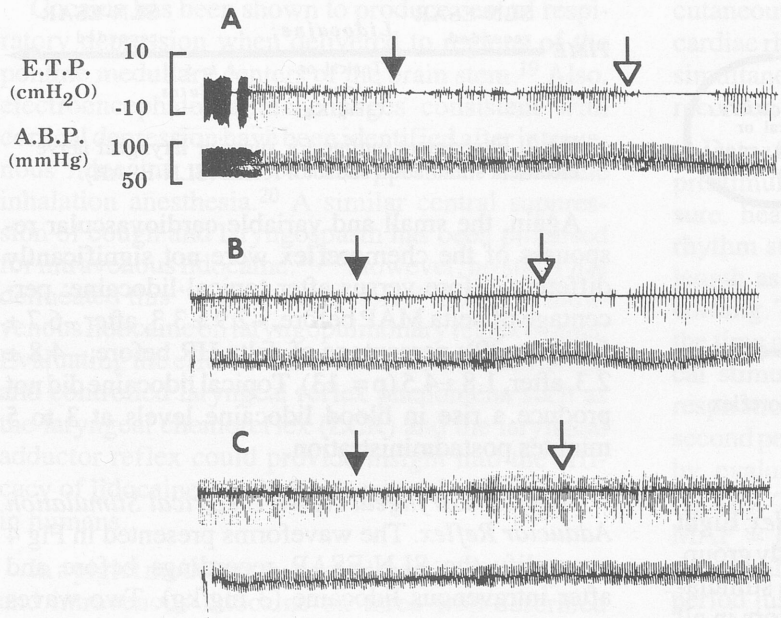

Fig 3. Effects of intravenous and topical lidocaine hydrochloride on laryngeal chemoreflex and laryngeal mechanoreflex. E.T.P. — endotracheal pressure (respiratory rate), A.B.P. — arterial blood pressure, closed arrow — point of mechanical stimulation, open arrow — point of chemical stimulation (H2O). A) Before lidocaine. B) After intravenous lidocaine. C) After topical lidocaine.

the 1940s and 1950s there were reports of using the local anesthetic agents procaine and lidocaine intravenously to control pain and as adjuncts to general anesthesia.[4,22,24,25] In 1951 Keats et al,[25] in a controlled study with procaine, concluded that these agents outside the operating room were only mildly effective for pain control and had major side effects.

In 1958, Steinhaus and Howland,[22] reported that the addition of intravenous lidocaine to nitrous oxide–thiobarbiturate anesthesia suppressed pharyngeal and laryngeal reflexes without significant respiratory depression. Phillips et al[26] in 1960 evaluated intravenous lidocaine as an adjunct to thiopental, nitrous oxide, and succinylcholine in a blinded study and found that with the addition of lidocaine the dose of succinylcholine required was reduced by 17%, and the dose of thiopental used was reduced by 13%. Using rats in 1976, DiFazio et al[27] found that the cyclopropane concentration required could be reduced by 40% when intravenous lidocaine was added. The decreasing cyclopropane concentration was linearly related to lidocaine blood levels up to 1 μg/mL. Above this level a ceiling effect was reached. A year later Himes et al[28] looked at the effects of lidocaine on the anesthetic requirements for nitrous oxide and halothane in humans. In that study anesthetic requirements could be reduced by 10% to 28% with lidocaine blood levels of 3 to 6 μg/mL, with a ceiling effect at approximately 5 μg/mL.

The interaction of lidocaine with the other agents may have synergistic effects on laryngeal reflex response. In our study animals were given ketamine. Ketamine is not a respiratory depressant and does not affect laryngeal reflexes alone.[29] Xylazine used as a single dose up front acts as a brief analgesic and muscle relaxant and is commonly used in animal studies.[18] The addition of intravenous lidocaine to a barbiturate-containing anesthetic regimen may potentiate the suppression of laryngeal reflexes even with relatively low barbiturate doses. Lidocaine has been shown to act as a synergistic agent in maintaining deeper levels of anesthesia, and recent studies have shown that deeper levels of anesthesia affect laryngeal reflex events.[30,31] It becomes difficult to sort out the anesthesia effects of lidocaine from its possible reflex suppressive effects. Although the cardiac and local anesthetic effects of lidocaine have been well described, the site and mechanism of action of lido-

TABLE 2. EFFECTS OF TOPICAL LIDOCAINE ON LCR AND LMR

		After Lidocaine		
	Before Lidocaine	*5 min*	*10 min*	*15 min*
LCR				
Positive response	100% (8/8)	12% (1/8)	88% (7/8)	100% (8/8)
Apnea duration (s)	19 ± 8	0 ± 1	9 ± 5	11 ± 2
LMR				
Positive response	100% (6/6)	16% (1/6)	33% (2/6)	100% (4/4)
Apnea duration (s)	11 ± 8	0 ± 1	1 ± 1	8 ± 4

LCR — laryngeal chemoreflex, LMR — laryngeal mechanoreflex.

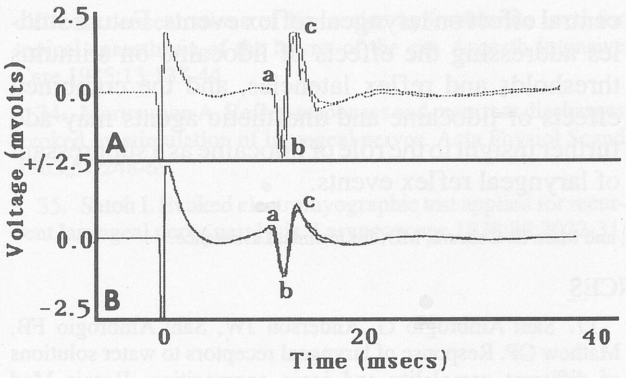

Fig 4. Effects of intravenous lidocaine hydrochloride on superior laryngeal nerve electrical stimulation adductor reflex. Values for points a, b, and c are given in Table 3. A) Before lidocaine. B) After intravenous lidocaine (3 mg/kg).

caine as a suppressant of laryngeal reflexes remain obscure. Topical lidocaine has been demonstrated to block or halt the chemolaryngeal reflex responses in animal studies. This effect is immediate and appears to be a primary mucosal neuroreceptor event.[8,13,16] Intravenous lidocaine, however, may act at peripheral neuroreceptors, at specific central laryngeal reflex pathways, or nonspecifically by potentiating the general anesthetic effects of other agents.[21,22,26-28]

As in previous studies, we found topical lidocaine to be a strong suppressant of tactile and chemolaryngeal reflexes, with a similar time frame of reflex return.[32,33] The effect was immediate in onset, was of short duration, and occurred without an elevation in the lidocaine blood level. This finding implies a peripheral mucosal rather than a systemic or central effect for topical lidocaine. With intravenous lidocaine doses of 3 mg/kg and blood levels well into the therapeutic range of 1.5 to 5 mg/kg, we found no significant effect on the LCR or LMR. A decreased mean apnea duration after intravenous lidocaine was noted, but this was not statistically significant.

The recorded SLN-ESAR waveforms exemplified in Fig 4 are consistent in both latency and configuration with those produced in humans and in other animals.[34-36] In this study the SLN-ESAR reflex arc remained intact and showed only a trend toward increasing latency after intravenous lidocaine at usual clinical doses. This latency increase was not significant in our group of animals. It is possible that with an increase in the number of animals studied the trends toward latency prolongation would reach statistical significance. Clearly, future study is warranted to address this issue. In addition, the effects of increasing the lidocaine dose have not been adequately studied; however, in order to obtain conduction delays in peripheral nerves by using intravenous lidocaine, toxic doses are required.[37] The clinical relevance of such studies would be limited by the lidocaine therapeutic window, since central nervous system side effects occur as plasma levels reach 5 μg/mL.[38]

TABLE 3. EFFECTS OF INTRAVENOUS LIDOCAINE ON SLN-ESAR

	Before Lidocaine	*After Lidocaine*	*p*
Latency a (ms)	11.7 ± 0.7	12.2 ± 0.5	.08
Latency b (ms)	13.2 ± 0.2	13.4 ± 0.4	.44
Latency c (ms)	14.8 ± 0.4	15.1 ± 0.3	.08

SLN-ESAR — superior laryngeal nerve electrical stimulation adductor reflex. Points a, b, and c are shown on Fig 4.

Intravenous lidocaine has been shown to be a strong suppressant of induced cough in awake patients, and cough suppression by intravenous lidocaine at the time of intubation has also been identified.[6,7,10,11] Complete cough suppression was accomplished by doses of 2 mg/kg and with plasma levels greater than 3 μg/mL.[7] Lidocaine may have a selective antitussive effect that we did not address.

Blancato et al[20] supplemented halothane inhalation anesthesia with intravenous lidocaine (4 to 5 mg/kg) during endoscopy and found a significant decrease in airway complications (laryngospasm, bronchospasm, and cyanosis) during the postoperative recovery period. These same patients were monitored with electroencephalography during the procedures, and postlidocaine waveform changes were identified that were consistent with cortical depression.[20] This and previous clinical studies support intravenous lidocaine as a central suppressant of some laryngopulmonary reflex events. However, our data do not support this conclusion.

Threshold changes were not evaluated in this study, and it is possible that changes in stimulus response thresholds occur with intravenous lidocaine. The reported ability of intravenous lidocaine to decrease the risk of laryngospasm and cough at times of laryngeal manipulation is possibly due to effects on response thresholds. The ability of intravenous lidocaine to deepen level of anesthesia most likely also plays a role in the clinically identified effects.

CONCLUSION

Intravenous and topical lidocaine appear to differ in mechanism of action and efficacy with regard to modulation of reflex effects induced by laryngeal stimulation in the piglet. Elimination of LCR and LMR produced by topical lidocaine and persistence of LCR and LMR following intravenous lidocaine imply that the principal site of action for topical lidocaine is at the peripheral receptors. The clinical literature supports a central lidocaine effect that could not be identified in this animal model. Only trends

toward latency prolongation in the SLN-ESAR and decreased LCR and LMR apnea durations after intravenous lidocaine hint at this presumed central effect of lidocaine. The clinically identified intravenous lidocaine effects may be secondary to lidocaine's effect on depth of anesthesia, as opposed to a specific central effect on laryngeal reflex events. Future studies addressing the effects of lidocaine on stimulus thresholds and reflex latencies, and the combined effects of lidocaine and anesthetic agents may add further insight to the role of lidocaine as a suppressant of laryngeal reflex events.

ACKNOWLEDGMENTS — We thank Greg Damiano, Sandra M. Guidotti, and Marc D. Coltrera, MD, for technical assistance.

REFERENCES

1. Abou-Madi MN, Keszler H, Yacoub JM. Cardiovascular reactions to laryngoscopy and tracheal intubation following small and large doses of lidocaine. Can Anaesth Soc J 1977;24:12-9.

2. Hamill JF, Bedford RF, Weaver DC, Colohan AR. Lidocaine before endotracheal intubation: intravenous or laryngotracheal. Anesthesiology 1981;55:578-81.

3. King BD, Harris LC Jr, Greifenstein FE, Elder JD, Dripps RD. Reflex circulatory responses to direct laryngoscopy and tracheal intubation performed during general anesthesia. Anesthesiology 1951;12:556-66.

4. Gilbert CRA, Hanson IR, Brown AB, Hingson RA. Intravenous use of Xylocaine. Anesth Analg 1951;30:301.

5. Gefke K, Anderson LW, Friesel E. Lidocaine given intravenously as a suppressant of cough and laryngospasm in connection with extubation after tonsillectomy. Acta Anaesthesiol Scand 1983;27:111-2.

6. Poulton TJ, James FM III. Cough suppression by lidocaine. Anesthesiology 1979;50:470-2.

7. Yukioka H, Yoshimoto N, Nishimura K, Fujimori M. Intravenous lidocaine as a suppressant of coughing during tracheal intubation. Anesth Analg 1985;64:1189-92.

8. Leicht P, Wisberg T, Chraemmer-Jorgensen B. Does intravenous lidocaine prevent laryngospasm after extubation in children? Anesth Analg 1985;64:1193-6.

9. Baraka A. Intravenous lidocaine controls extubation laryngospasm in children. Anesth Analg 1978;57:506-7.

10. Steinhaus JE, Gaskin L. A study of intravenous lidocaine as a suppressant of cough reflex. Anesthesiology 1963;24:285-90.

11. Christensen V, Ladegaard-Pedersen HJ, Skovsted P. Intravenous lidocaine as a suppressant of persistent cough caused by bronchoscopy. Acta Anaesthesiol Scand [Suppl] 1978(suppl 67):84-6.

12. Nishino T, Hiraga K, Sugimori K. Effects of IV lignocaine on airway reflexes elicited by irritation of the tracheal mucosa in humans anaesthetized with enflurane. Br J Anaesth 1990;64:682-7.

13. Lee JC, Stoll B, Dowing SE. Properties of the laryngeal chemoreflex in neonatal pigs. Am J Physiol 1977;233:30-7.

14. Suzuki M, Sasaki CT. Laryngeal spasm: a neurophysiologic redefinition. Ann Otol Rhinol Laryngol 1977;86:150-7.

15. Boushey HA, Richardson PS, Widdicombe JG, Wise JCM. The response of laryngeal afferent fibers to mechanical and chemical stimuli. J Physiol (Lond) 1974;240:153-75.

16. Harding R, Johnson P, McClelland ME. Liquid-sensitive laryngeal receptors in the developing sheep, cat and monkey. J Physiol (Lond) 1978;277:400-22.

17. Sant'Ambrogio G, Anderson JW, Sant'Ambrogio FB, Mathew OP. Response of laryngeal receptors to water solutions of different osmolality and ionic composition. Respir Med 1991;85(suppl A):57-60.

18. Lanier B, Richardson MA, Cummings C. Effect of hypoxia on laryngeal reflex apnea — implications for sudden infant death. Otolaryngol Head Neck Surg 1983;91:597-604.

19. Jolly ER, Steinhaus JE. The effects of drugs injected into limited portions of the cerebral circulation. J Pharmacol Exp Ther 1956;116:273-81.

20. Blancato LS, Peng ATC, Alonsabe D. Intravenous lidocaine as an adjunct to general anesthesia for endoscopy. Anesth Analg 1969;48:224-7.

21. Latto IP, Rosen M. Difficulties in tracheal intubation. London, England: Bailliere Tindall, 1987:16-7.

22. Steinhaus JE, Howland DE. Intravenously administered lidocaine as a supplement to nitrous oxide–thiobarbiturate anesthesia. Anesth Analg 1958;37:40-6.

23. Bradley WG, ed. AAEE glossary of terms in clinical electromyography. Muscle Nerve 1987;10(suppl).

24. Gordon RA. Intravenous Novocain for analgesia in burns. Can Med Assoc J 1943;49:478.

25. Keats AS, D'Alessandro GL, Beecher HK. A controlled study of pain relief by intravenous procaine. JAMA 1951;147:1761-3.

26. Phillips OC, Lyons WB, Harris LC, Nelson AT, Graff TD, Frazier TM. Intravenous lidocaine as an adjunct to general anesthesia: a clinical evaluation. Anesth Analg 1960;39:317-22.

27. DiFazio CA, Niederlehner JR, Burney RG. The anesthetic potency of lidocaine in the rat. Anesth Analg 1976;55:818-21.

28. Himes RS, DiFazio CA, Burney RG. Effects of lidocaine on the anesthetic requirements for nitrous oxide and halothane. Anesthesiology 1977;47:437-40.

29. Bovill JG, Clarke RSJ, Davis EA, Dundee JW. Some cardiovascular effects of ketamine in man. Br J Pharmacol 1971;41:411P-412P.

30. Donnelly DF, Haddad GG. Effect of graded anesthesia on laryngeal-induced central apnea. Respir Physiol 1986;66:235-45.

31. Nishino T, Hiraga K, Mizuguchi T, Honda Y. Respiratory reflex responses to stimulation of tracheal mucosa in enflurane-anesthetized humans. J Appl Physiol 1988;65:1069-74.

32. Cross BA, Guz A, Jain SK, Archer S, Stevens J, Reynolds F. The effect of anaesthesia of the airway in dog and man: a study of respiratory reflexes, sensations and lung mechanics. Clin Sci 1976;50:439-54.

33. Robinson EP, Rex MAE, Brown TCK. A comparison of

different concentrations of lignocaine hydrochloride used for topical anaesthesia of the larynx of the cat. Anaesth Intensive Care 1985;13:137-44.

34. Martensson A. Reflex responses and recurrent discharges evoked by stimulation of laryngeal nerves. Acta Physiol Scand 1963;57:248-69.

35. Satoh I. Evoked electromyographic test applied for recurrent laryngeal nerve paralysis. Laryngoscope 1978;88:2022-31.

36. Thumfart WF. Electrodiagnosis of laryngeal nerve disorders. Ear Nose Throat J 1988;67:380-93.

37. De Jong RH, Nace RA. Nerve impulse conduction during intravenous lidocaine injection. Anesthesiology 1968;29:22-8.

38. Bigger JT Jr, Hoffman BF. Antiarrhythmic drugs. In: Goodman LS, Gilman AS, Rall TW, Murad F, eds. The pharmacological basis of therapeutics. 7th ed. New York, NY: Macmillan, 1985:635.

LARYNGEAL SYNKINESIS FOLLOWING REINNERVATION IN THE RAT

NEUROANATOMIC AND PHYSIOLOGIC STUDY USING RETROGRADE FLUORESCENT TRACERS AND ELECTROMYOGRAPHY

PAUL W. FLINT, MD
BALTIMORE, MARYLAND

DANIEL H. DOWNS, MD
MINNEAPOLIS, MINNESOTA

MARC D. COLTRERA, MD
SEATTLE, WASHINGTON

The functional organization of laryngeal motoneurons in the nucleus ambiguus (NA) was evaluated in adult male rats before and after recurrent laryngeal nerve section and reinnervation. Using retrograde double labeling techniques with fluorescent probes, we obtained the number and position of labeled neurons by using the Bioquant 3-D imaging system. Reinnervation was documented by electromyography. In nine control animals vector analysis revealed significant ($p < .05$) separation of the posterior cricoarytenoid (PCA) muscle motoneurons and the thyroarytenoid and lateral cricoarytenoid (TA/LCA) muscle motoneurons. The PCA motoneurons were positioned ventromedially in the NA, and TA/LCA motoneurons were found dorsolaterally in the NA. Rostral-caudal separation was not significant. Electromyography revealed phasic electrical activity synchronous with respiration in the PCA, and activity synchronous with deglutition in the TA/LCA. In four animals surviving 15 weeks following recurrent laryngeal nerve section and primary neurorrhaphy, functional organization within the NA was lost and phasic motor unit activity synchronous with respiration was seen in the TA/LCA muscle as well as the PCA. Vector analysis revealed the reinnervating motoneurons for both the PCA and TA/LCA to be positioned dorsolaterally, similar to the control group TA/LCA motoneurons. These findings demonstrate a shift in the topographic organization of laryngeal motoneurons within the NA following reinnervation, with random organization occurring at the neurorrhaphy site.

KEY WORDS — electromyography, laryngeal paralysis, laryngeal synkinesis, motoneuron, neurorrhaphy, nucleus ambiguus, recurrent laryngeal nerve reinnervation.

INTRODUCTION

Recurrent laryngeal nerve (RLN) injury, traumatic or idiopathic, and subsequent reinnervation of the paralyzed larynx frequently results in synkinesis. Synkinesis may be defined as the synchronous contraction of muscles that normally do not contract together. Within the larynx this refers to the simultaneous contraction of antagonistic muscle groups, with the end result being an immobile vocal cord fixed by opposing forces (Fig 1A). Inappropriate innervation of the stronger adductor muscles (the thyroarytenoid [TA], interarytenoid [IA], and lateral cricoarytenoid [LCA] muscles) counteracts the weaker forces applied by the abductor (the posterior cricoarytenoid [PCA]) muscle and results in medialization of the vocal cord. This condition is, in part, responsible for the airway compromise occurring after bilateral vocal cord paralysis in humans, as well as the failure to achieve functional improvement following reinnervation procedures after transection of the RLN.[1] The overall incidence of synkinesis following experimental laryngeal reinnervation varies from 66% to 88%, which is believed to be comparable to the incidence in humans.[2-5]

Laryngeal synkinesis is hypothesized to occur as the result of misdirected axonal regeneration and subsequent inappropriate reinnervation of abductor laryngeal muscles by adductor fibers and vice versa.[6] Axons innervating both abductors and adductors are normally present in the RLN. Evidence of inappropriate reinnervation was reported by Siribodhi et al,[2] who first proposed the mechanism of aberrant regeneration of nerve fibers. By means of electromyography (EMG) following regeneration of repaired RLNs, inappropriate EMG activity with no meaningful laryngeal function was documented in three of four surviving dogs. Other reports confirm Siribodhi's original findings,[3,7-9] although a few studies report return of adductor function following reinnervation.[10-12] The return of adductor function may be the result of cricothyroid (CT) muscle activity, as suggested by Rice.[13]

Previous studies in rats,[14] rabbits,[15] cats,[16] and monkeys,[17] using horseradish peroxidase (HRP) retrograde labeling, have localized the somata of motoneurons innervating laryngeal muscles to the ipsilateral nucleus ambiguus (NA), the retrofacial nucleus, and the dorsal motor nucleus of cranial nerve X. The RLN axons arise from the motoneuron cell bodies in the NA. The NA maintains a narrow posi-

From the Department of Otolaryngology–Head and Neck Surgery, University of Washington School of Medicine, Seattle, Washington. Supported by Biomedical Research Support Grant 62-3108 from the University of Washington School of Medicine and by National Institutes of Health/National Institute on Deafness and Other Communication Disorders grants DC 00395 and K08DC 00035. This study was performed in accordance with the PHS Policy on Humane Care and Use of Laboratory Animals, the NIH *Guide for the Care and Use of Laboratory Animals*, and the Animal Welfare Act (7 U.S.C. et seq.); the animal use protocol was approved by the Institutional Animal Care and Use Committee (IACUC) of the University of Washington Medical Center.

Presented at the meeting of the American Laryngological Association, Waikoloa, Hawaii, May 4-5, 1991.

REPRINTS — Paul W. Flint, MD, Dept of Otolaryngology–Head and Neck Surgery, Johns Hopkins, POB 41402, Baltimore, MD 21203-6402.

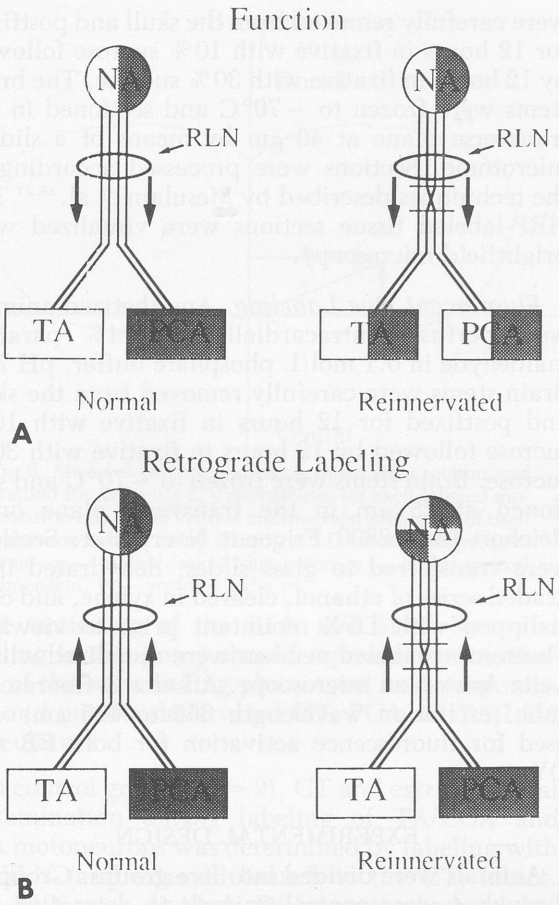

Fig 1. Functional organization of laryngeal motoneurons. RLN — recurrent laryngeal nerve. A) Diagram depicting somatotopic organization of motor units in normal animals and random reorganization at site of injury resulting in synkinesis. Shaded areas correspond to muscle with activity synchronous with respiration. Following reinnervation, activity synchronous with respiration is seen in both posterior cricoarytenoid (PCA) and thyroarytenoid (TA) muscles. B) Diagram depicting retrograde fluorescent labeling of nucleus ambiguus (NA) motoneurons in normal and reinnervated animals. Shaded areas correspond to biologic probe (fluorescent dye) used for retrograde labeling. On left, retrograde labeling of normal NA demonstrating two discrete populations of adductor (TA) and abductor (PCA) motoneurons. On right, retrograde labeling of antagonistic muscles following reinnervation would result in loss of separation of adductor and abductor motoneuron pools as result of random or nonselective reinnervation.

tion in the brain stem at the level of the upper medulla and lower pons, and lies adjacent to the ventral respiratory group motoneurons in the lateral tegmental region in the brain stem. The ventral respiratory group contains motoneurons innervating the diaphragm and accessory respiratory muscles, and appears to provide respiratory input to the laryngeal motoneurons.[18] Although slight variation occurs between different species, the cell bodies of motoneurons innervating the CT muscle in monkeys are found in the more rostral half of the NA dorsomedially, as well as in the adjacent retrofacial nucleus. The cell bodies of the motoneurons innervating the PCA, TA, LCA, and IA muscles are seen in the caudal half of the NA. The cell bodies of the PCA neurons are localized medially, the TA group are localized laterally, and the LCA and IA are sandwiched in between. These findings were confirmed in dogs[19] and cats[20] by using a double labeling method with retrograde fluorescent tracers. With this technique, Hisa and Sato[19] found little or no regional overlap in the motoneuron pools, although double-labeled cells innervating two synergistic muscles — the TA and the LCA — were identified.

Retrograde HRP has recently been applied to reinnervated laryngeal muscle groups. Using a freeze injury method to the RLN, Nahm et al[21] evaluated the effects of reinnervation on PCA motoneurons in the NA. The PCA cells in the normal animal were localized within the middle one third of the NA. Following reinnervation, PCA motoneurons were found in diminished numbers throughout the entire neuronal distribution of the RLN in the NA, suggesting random or nonselective reinnervation. Organization in the transverse plane was not evaluated.

Nonselective reinnervation has been documented in the hypoglossal nerve by using retrograde HRP labeling in cats,[22] and in the sciatic nerve in rats by using topographic nerve stimulation.[23] Other studies, however, have demonstrated evidence of selective reinnervation. Aldskogius and Thomander[24] reported selective reinnervation following facial nerve transection in neonatal rats and nonselective reinnervation in adult rats. Laskowski and Sanes[25] found selective reinnervation occurring with the serratus anterior and diaphragm muscles in neonatal rats and to a lesser degree in adult rats. The effects of age on selective reinnervation have not been investigated in the larynx.

The purpose of the present study is to assess the neuroanatomic changes and adaptive processes that result in laryngeal synkinesis following reinnervation after nerve section and repair. This is accomplished by placing two different fluorescent dyes, fast blue (FB) and diamidino yellow (DY), into the adductor (TA/LCA) and abductor (PCA) muscles and examining the three-dimensional (3-D) organization of labeled motoneurons in the NA of normal animals compared to reinnervated animals. If reinnervation occurs randomly at the anastomotic site, as is generally accepted, then retrograde labeling will result in loss of functional organization of laryngeal motoneurons in the NA (Fig 1B). However, if a selective process exists (ie, if one cell type has a selective advantage during reinnervation), a shift in position of motoneuron populations would be expected to occur regardless of the reinnervation process at the anastomotic site. The change in position and number of labeled nuclei will also be correlated with physiologic changes as assessed by EMG and fiberoptic laryngoscopy.

MATERIALS AND METHODS

Operative Technique. Adult male Sprague-Dawley rats (400 to 500 g) were anesthetized by intramuscular injection of ketamine hydrochloride (35 mg/kg) and xylazine hydrochloride (5 mg/kg). By means of a standard operating microscope, the larynx was approached through a midline incision. The TA and LCA muscles were treated together as the adductor group (TA/LCA) because of their small size and inability to be labeled separately (rats do not have an IA muscle). A window made in the anterior thyroid cartilage was used to expose the TA/LCA muscle. The PCA muscle was accessed by developing the tissue plane between the larynx and the esophagus, followed by the lateral rotation of the larynx.

To label the muscle fibers, HRP (type IV), FB, or DY (all Sigma, St Louis, Mo) crystals were inserted into the muscle with a 30-gauge needle. Excess dye was swabbed away following insertion of crystals to decrease contamination of other structures. For whole nerve labeling the RLN was sectioned approximately 0.5 cm caudal to its insertion into the laryngeal muscles and a 50% solution of HRP (distilled H_2O with 2% dimethyl sulfoxide) or FB crystals was placed into a 3-mm piece of Silastic tubing (diameter, 0.50 mm). The tubing was closed at one end and the proximal end of the sectioned nerve was placed into the other end of the tube and secured in position with 10-0 nylon suture.

The ipsilateral superior laryngeal nerve (SLN) was cut to minimize potential contamination from the CT muscle. When used, the cartilage window was closed with Gelfoam, and the neck was closed in layers. In preliminary studies, 3-day survival periods were found to be optimal for retrograde labeling in both the HRP and fluorescent dye methods.

Electromyography. Electromyograms were obtained prior to RLN section and 15 weeks following neurorrhaphy to document reinnervation of the muscle groups. Sectioning the ipsilateral SLN eliminates potential distant electrical activity from the CT muscle. Following anesthesia and exposure of the laryngeal muscles, a monopolar electrode was placed in the right PCA muscle and the right TA/LCA muscle. In addition, for each monopolar electrode, a reference electrode and a ground electrode were placed subcutaneously. The EMG signals were amplified by a Data Inc, 2124 model 2 instrumentation amplifier and stored in a Tektronix 2232 digital storage oscilloscope. Standardized amplification (gain, 100; high frequency filter, 10,000 Hz; low frequency filter, 30 Hz) and recording levels were used.

Horseradish Peroxidase Labeling. Anesthetized animals (intraperitoneal Equithesin 3 μL/g) were perfused intracardially with 4% glutaraldehyde in 0.1 mol/L phosphate buffer, pH 7.4. Brain stems were carefully removed from the skull and postfixed for 12 hours in fixative with 10% sucrose followed by 12 hours in fixative with 30% sucrose. The brain stems were frozen to $-70°C$ and sectioned in the transverse plane at 40 μm by means of a sliding microtome. Sections were processed according to the techniques described by Mesulam et al.[26,27] The HRP-labeled tissue sections were visualized with brightfield microscopy.

Fluorescent Dye Labeling. Anesthetized animals were perfused intracardially with 4% paraformaldehyde in 0.1 mol/L phosphate buffer, pH 7.4. Brain stems were carefully removed from the skull and postfixed for 12 hours in fixative with 10% sucrose followed by 12 hours in fixative with 30% sucrose. Brain stems were frozen to $-70°C$ and sectioned at 25 μm in the transverse plane on a Reichert-Jung 2800 Frigocut N cryostat. Sections were transferred to glass slides, dehydrated in a graded series of ethanol, cleared in xylene, and coverslipped with DPX mountant prior to viewing. Fluorescent-labeled neurons were visualized with a Leitz Aristoplan microscope. A Leitz D fluorescent cube (excitation wavelength 355 to 425 μm) was used for fluorescence activation for both FB and DY.

EXPERIMENTAL DESIGN

Animals were divided into five groups. Groups 1 through 4 were control animals to determine the normal distribution of PCA and TA motoneurons, and the degree of contamination from surrounding extralaryngeal muscles. Group 5 consisted of animals undergoing reinnervation for comparison to control animals.

In control group 1, the whole RLN was labeled either with HRP (n = 6) or FB (n = 3). These controls determined the location of RLN cell bodies in the NA. The rostral-caudal range of whole RLN labeling represented the limits of neuronal labeling for the PCA and TA/LCA motoneurons in the NA.

In control group 2, PCA and TA/LCA muscles were labeled with intramuscular crystal insertion following division of the SLN, thus eliminating possible CT motoneuron labeling. Retrograde labeling utilized either HRP (n = 6) inserted into the PCA and contralateral TA/LCA or dual fluorescent dye labeling (n = 9). Fast blue was used to label the PCA in seven animals and TA/LCA in two animals, while DY was used to label the ipsilateral antagonist PCA (n = 2) or TA/LCA (n = 7) muscle. The nine fluorescent-labeled animals in control group 2 were compared to the reinnervated animal group.

Control group 3 (n = 3) determined the extent of extralaryngeal muscle contamination following TA/LCA and PCA muscle labeling. Fast blue and DY were inserted intramuscularly into the PCA and TA/LCA muscles, respectively, followed by imme-

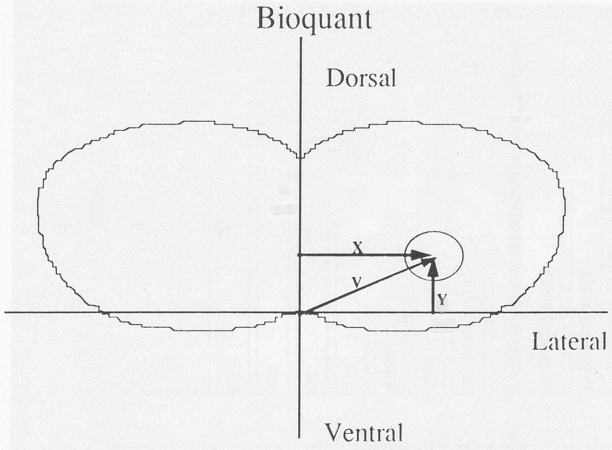

Fig 2. Model depicting transverse brain stem section and method for assigning x, y coordinates for each labeled motoneuron relative to ventral midline reference point of each transverse section using Bioquant 3-D reconstruction program. x — medial-lateral dimension, y — dorsal-ventral dimension, v — vector = $\sqrt{x^2 + y^2}$.

diate sectioning of the RLN and SLN. Neuronal labeling in this group should represent contamination of the surrounding pharyngeal and strap muscles and not the denervated CT, PCA, or TA/LCA musculature.

In control group 4 (n = 2), CT and extralaryngeal contamination during labeling of TA/LCA and PCA motoneurons was determined by labeling with the SLN (and external branch to the CT) intact. The RLN was divided. Differences observed between group 3 and group 4 represent the contribution of CT contamination.

In six animals, experimental group 5, the right RLN was sectioned approximately 0.5 cm proximal to the site of insertion into the larynx. The nerve was then immediately sutured together with 10-0 nylon suture. Laryngoscopy with a fiberoptic pediatric bronchoscope was used to document immobility of the right vocal cord. The surgical site was closed in layers and the animals were kept alive for 15 weeks to allow axonal regeneration. Fluorescent labeling was performed as described for control group 2. The PCA muscle was labeled with FB and the TA/LCA muscle was labeled with DY. Retrograde labeling was assessed after a 3-day survival period.

ANALYSIS OF DATA

The number and position of fluorescent-labeled neurons were obtained by using the Bioquant 3-D imaging system from R&M Biometrics Inc (Nashville, Tenn). Three-dimensional reconstructions of the brain stems were created by using the Bioquant system. The x and y coordinates and resultant vectors were determined for the FB- or DY-labeled neurons in each transverse section by using the ventral midline of each section as the origin or reference point (Fig 2). Rostral-caudal locations of la-

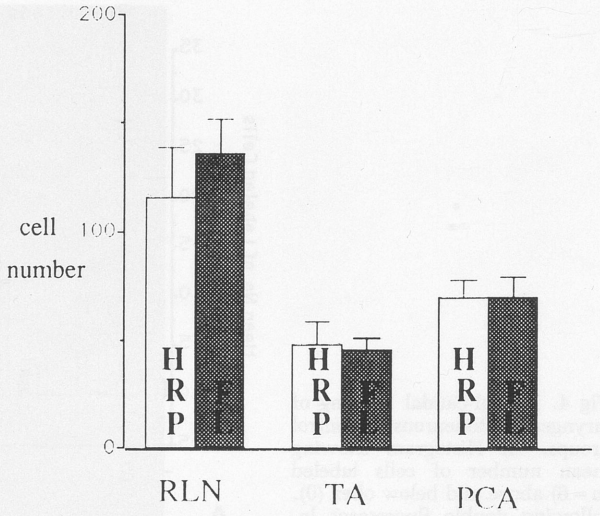

Fig 3. Comparison between horseradish peroxidase (HRP) and fluorescent dye (FL) neuronal labeling demonstrated no statistical advantage of either method when labeling whole recurrent laryngeal nerve (RLN; control group 1) or specific muscles (control group 2). Less uptake occurs with intramuscular injections when compared to whole-nerve labeling. Error bars — standard error of mean.

beled neurons were measured in the z axis relative to the obex. To eliminate double counting of neurons, absolute cell counts were adjusted by using the total count method defined by Abercrombie[28] for both HRP- and fluorescent dye–labeled brain stems.

Differential analyses of the PCA and TA/LCA neuronal population locations for each animal were performed by comparing the x, y, and vector values for the FB- and DY-labeled motoneurons. Two-tailed unpaired *t* tests on each normal animal and each reinnervated animal determined if statistically significant separation of neuronal populations existed.

To compare the position of PCA and TA/LCA neurons in the normal group to that in the reinnervated group, two-way mixed analysis of variance (ANOVA) was performed by using the mean x, y, and vector values for each animal. Separate ANOVAs were performed for each dimension. Post-hoc specific comparison between these mean positions were made by using the Newman-Keuls test.

RESULTS

Labeling. To determine quantitatively the ability of FB and DY to label laryngeal motoneurons, comparisons between the HRP and fluorescent dye retrograde labeling were performed. When comparing absolute numbers of labeled soma, no statistically significant advantage to either biologic probe was observed, regardless of whether whole-nerve or intramuscular labeling was performed (Fig 3). Therefore, all further studies used FB and DY.

Labeling of the whole RLN (control group 1) demonstrated laryngeal motoneurons ranging from 1.6 mm below the obex to approximately 0.6 mm above the obex, with a few scattered cells more

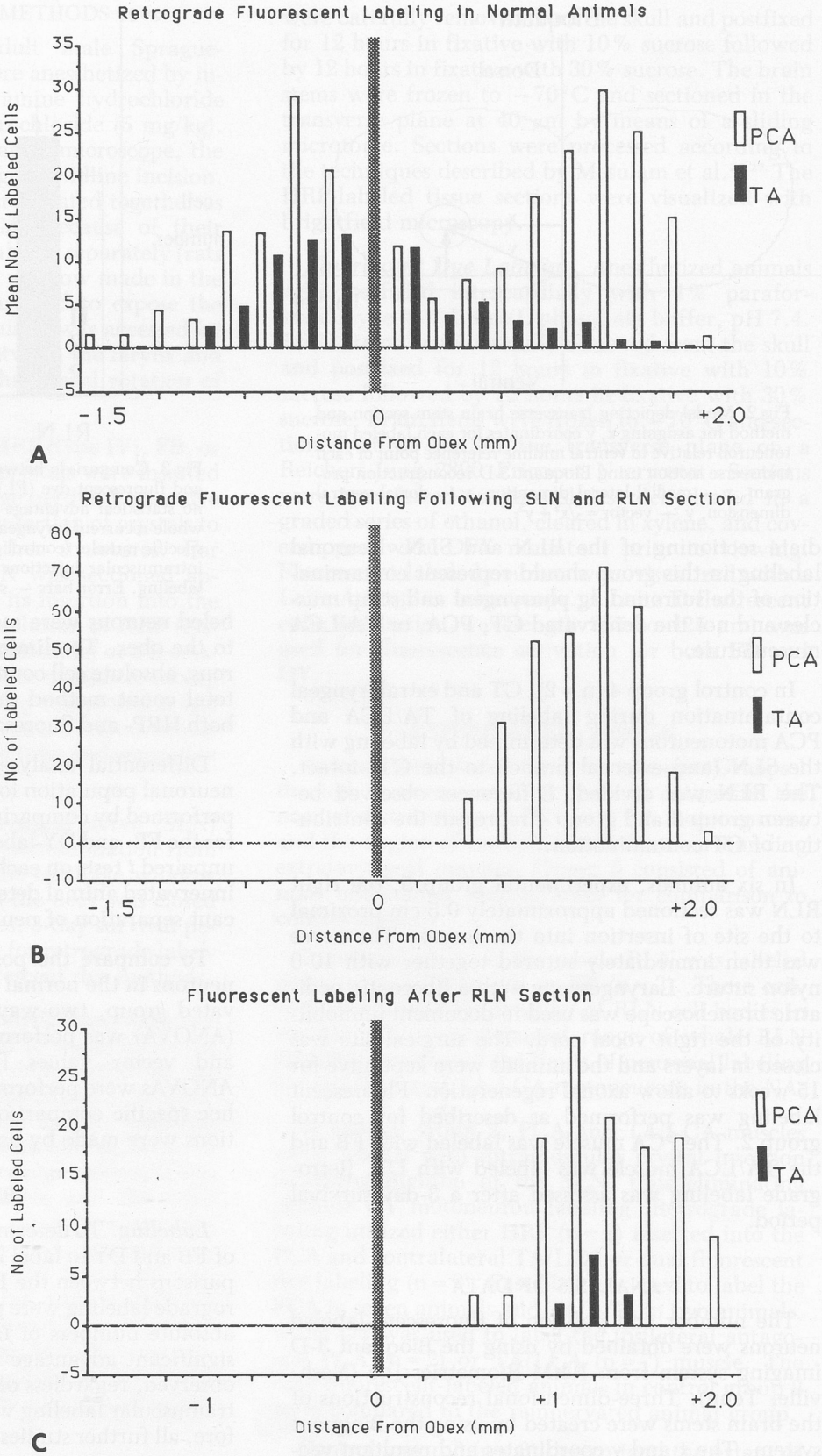

Fig 4. Rostral-caudal labeling of laryngeal motoneurons in control groups. A) Histogram showing mean number of cells labeled (n = 6) above and below obex (0), following double fluorescent labeling of PCA (fast blue) and TA (diamidino yellow) in normal rat. Separation of cells in rostral-caudal dimension does not occur. Large population of cells labeled with fast blue rostral to obex (0.6 to 2.0 mm) represents hypopharyngeal contamination (see B and C). B) Histogram showing number of cells labeled above and below obex (0), following double fluorescent labeling of PCA (fast blue) and TA (diamidino yellow) of single rat after transection of recurrent laryngeal nerve (RLN) and superior laryngeal nerve (SLN). Population of cells rostral to obex labeled with fast blue represents contamination of hypopharyngeal muscles. C) Histogram showing mean number of cells labeled (n = 3) above and below obex (0), following double fluorescent labeling of PCA (fast blue) and TA (diamidino yellow) after transection of RLN only. Labeling with diamidino yellow is seen in region above obex in addition to fast blue labeling (hypopharyngeal contamination), and results from contamination of cricothyroid muscle (innervated by SLN) during TA muscle labeling.

rostral (Fig 4A). Intramuscular injections into the PCA and TA/LCA with SLN sectioning (control group 2) resulted in labeling from 1.6 mm below the obex to 2.0 mm above the obex (Fig 4B). The more rostral labeling in control group 2 compared to whole RLN labeling (0.6 to 2.0 mm) resulted from extralaryngeal muscle contamination as demonstrated by control groups 3 (Fig 4B,C) and 4. Fol-

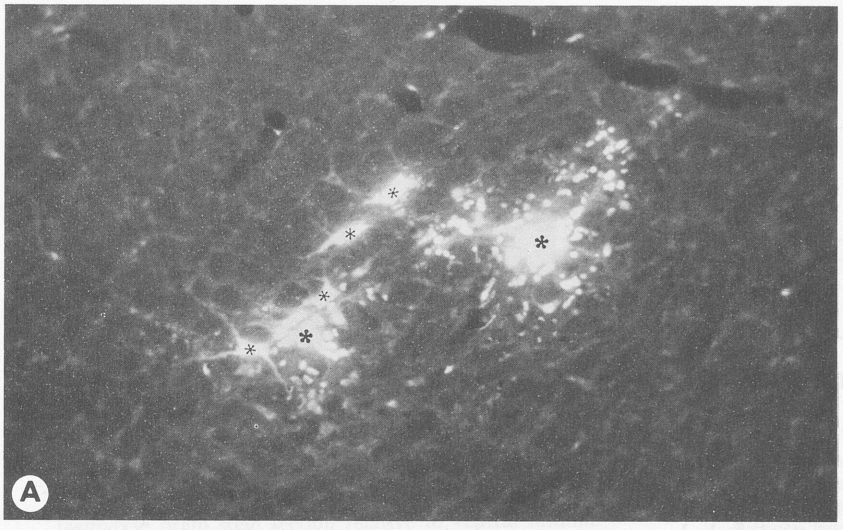

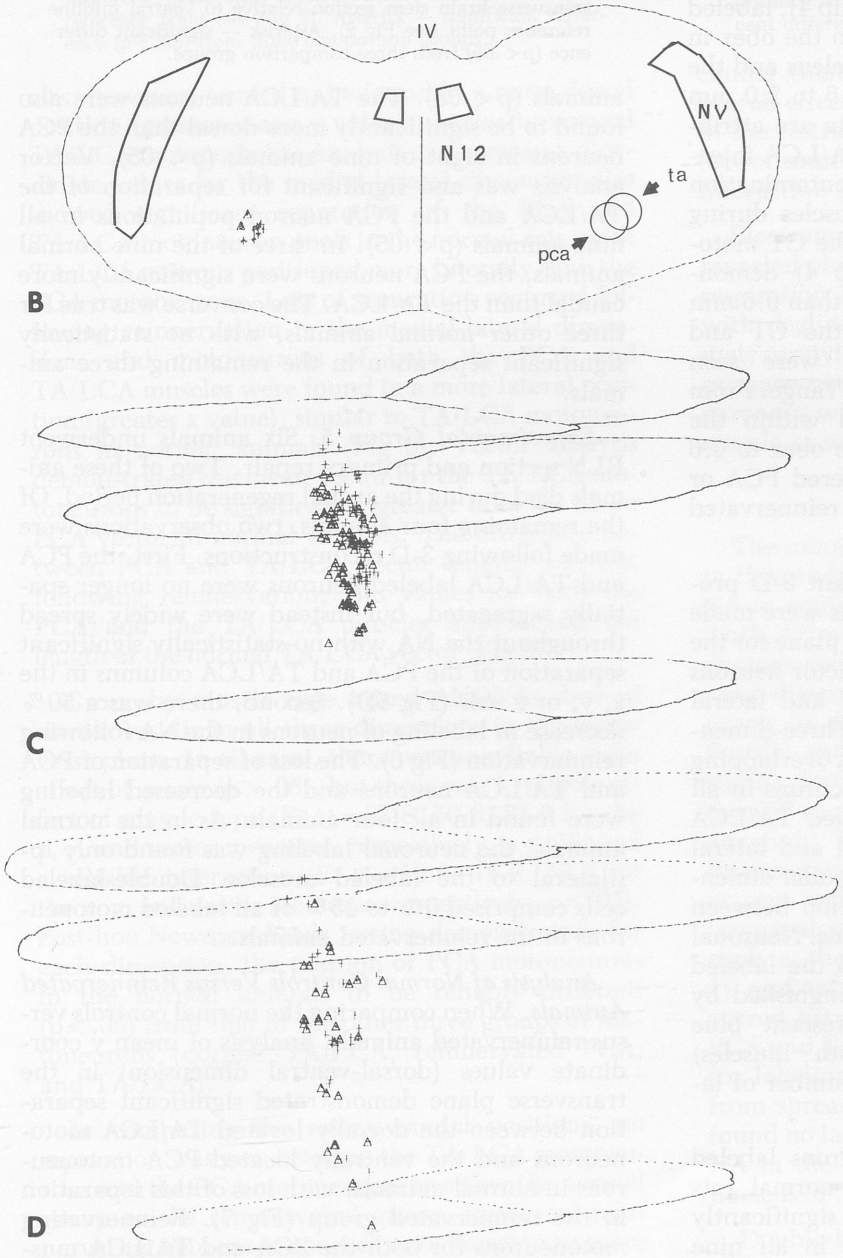

Fig 5. Nucleus ambiguus following retrograde labeling of motoneurons. A) Photomicrograph of transverse section through NA of normal rat following double labeling with fluorescent dyes. Diamidino yellow labels nucleus in TA/LCA (adductor) neurons (bold asterisks) bright yellow with some dye contamination found in cytoplasm and surrounding cells. Fast blue labels cytoplasm of PCA (abductor) motoneurons (light asterisks) with no spread into surrounding structures. Distinct separation of populations can be discriminated. B-D) △ — TA/LCA motoneurons, + — PCA motoneurons. B) Computer-generated reconstruction of transverse section of normal brain stem at level of obex showing location of TA/LCA and PCA motoneurons on left, and schematic illustration of two distinct motoneuron pools on right. IV — fourth ventricle, N12 — nucleus of cranial nerve XII, NV — nucleus of cranial nerve V. C) Three-dimensional reconstruction of control animal in which upper section is 600 μm rostral to obex, and lowest section is 1,600 μm caudal to obex. Intermediate section is at level of obex. Overlapping but distinct TA/LCA and PCA motoneuron pools are seen. D) Three-dimensional reconstruction of reinnervated animal. Uppermost section is 600 μm rostral to obex, and lowest section is 1,600 μm caudal to obex. Intermediate section is at level of obex.

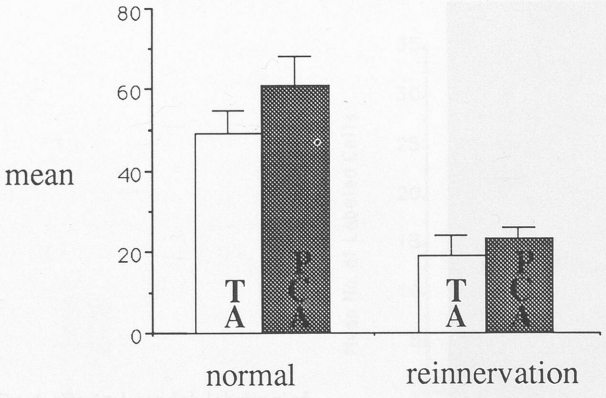

Fig 6. Absolute labeled cell count for normal (n = 9) and reinnervated (n = 4) animals.

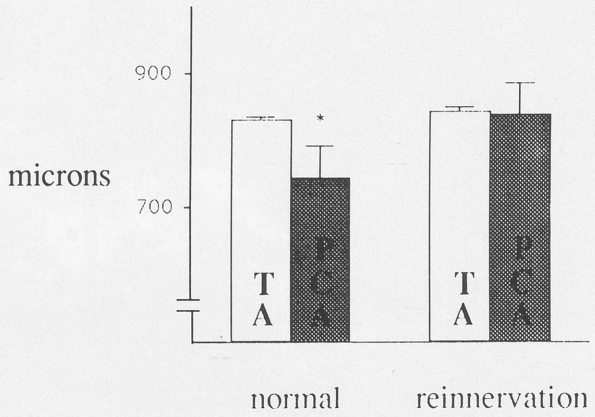

Fig 7. Mean y coordinate values are shown for TA and PCA muscles in normal animals (n = 9) compared to TA and PCA muscles in reinnervated animals (n = 4). Y coordinate value corresponds to dorsal-ventral position in transverse brain stem section relative to ventral midline reference point (see Fig 2). Asterisk — significant difference ($p < .05$) from three comparison groups.

lowing RLN plus SLN sectioning (control group 3) and RLN sectioning alone (control group 4), labeled neurons were found 0.6 mm rostral to the obex in the NA, and also in the retrofacial nucleus and the dorsal motor nucleus of the vagus (0.6 to 2.0 mm above the obex). These labeled somata are attributed to SLN contamination during TA/LCA injections by way of the CT, and vagal contamination via innervation of extralaryngeal muscles during PCA injection. Fast blue labeling of the CT motoneurons via the SLN (control group 4) demonstrated fluorescent motoneurons more than 0.6 mm above the obex. Less than 3% of the CT and extralaryngeal muscle motoneurons were seen caudal to the upper margin of the RLN range. From these parameters, only cells labeled within the range of the RLN (1.6 mm below the obex to 0.6 mm rostral to the obex) were considered PCA or TA/LCA motoneurons in control and reinnervated animals.

Normal Controls. Using the Bioquant 3-D program, two-dimensional reconstructions were made from each transverse section in the x-y plane for the normal controls (Fig 5A,B). The adductor neurons (TA/LCA) were located more dorsal and lateral than the abductor neurons (PCA). Three-dimensional reconstructions revealed distinct overlapping columns of TA/LCA and PCA motoneurons in all nine normal rats (Fig 5C). The labeled TA/LCA somata formed a column more dorsal and lateral than the PCA somata. In the rostral-caudal dimension, there was no pattern of separation between the abductor and adductor motoneurons. Neuronal labeling was found only ipsilateral to the labeled muscle. Double labeling of cells distinguished by fluorescent yellow nuclei and fluorescent blue cytoplasm (neurons innervating both muscles) ranged from 0% to 8% of the total number of labeled cells in nine normal animals.

Statistical analysis of the motoneurons labeled from PCA and TA/LCA muscles of normal rats revealed the TA/LCA neurons to be significantly more lateral than the PCA neurons in all nine animals ($p < .05$). The TA/LCA neurons were also found to be significantly more dorsal than the PCA neurons in eight of nine animals ($p < .05$). Vector analysis was also significant for separation of the TA/LCA and the PCA neuron populations in all nine animals ($p < .05$). In three of the nine normal animals, the PCA neurons were significantly more caudal than the TA/LCA. The converse was true for three other normal animals, with no statistically significant separation in the remaining three animals.

Experimental Group 5. Six animals underwent RLN section and primary repair. Two of these animals died during the axonal regeneration period. Of the remaining four animals, two observations were made following 3-D reconstructions. First, the PCA and TA/LCA labeled neurons were no longer spatially segregated, but instead were widely spread throughout the NA with no statistically significant separation of the PCA and TA/LCA columns in the x, y, or z axis (Fig 5D). Second, there was a 50% decrease in labeling of neurons in the NA following reinnervation (Fig 6). The loss of separation of PCA and TA/LCA neurons and the decreased labeling were found in all four animals. As in the normal animals, the neuronal labeling was found only ipsilateral to the labeled muscles. Double-labeled cells comprised 0% to 15% of all labeled motoneurons in the reinnervated animals.

Analysis of Normal Controls Versus Reinnervated Animals. When comparing the normal controls versus reinnervated animals, analysis of mean y coordinate values (dorsal-ventral dimension) in the transverse plane demonstrated significant separation between the dorsally located TA/LCA motoneurons and the ventrally located PCA motoneurons in normal animals, with loss of this separation in the reinnervated group (Fig 7). Reinnervating motoneurons for both the PCA and TA/LCA mus-

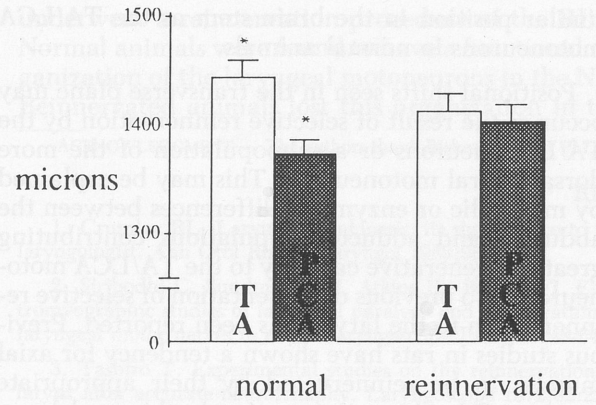

Fig 8. Mean x coordinate values are shown for TA and PCA muscles in normal animals (n = 9) compared to TA and PCA muscles in reinnervated animals (n = 4). X coordinate value corresponds to medial-lateral position in transverse brain stem section relative to ventral midline reference point (see Fig 2). Asterisk — significant difference ($p < .05$) from three comparison groups.

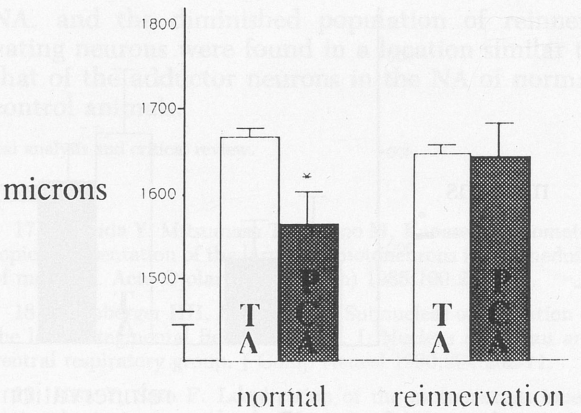

Fig 9. Mean vector values are shown for TA and PCA muscles in normal animals (n = 9) compared to TA and PCA muscles in reinnervated animals (n = 4). Resultant vector is obtained from x, y coordinates (see Fig 2) and represents distance from ventral reference point. Asterisk — significant difference ($p < .05$) from three comparison groups.

cles, however, tended to be found in a more dorsal position (greater mean y value), similar to normal TA/LCA motoneurons. Analysis of the mean x coordinate values for the medial-lateral dimension also showed significant separation of the PCA and TA/LCA motoneuron pools in the normal rats, with TA/LCA neurons positioned more laterally than the PCA motoneurons. Loss of separation occurred following reinnervation in the medial-lateral dimension, and motoneurons of both the PCA and TA/LCA muscles were found in a more lateral position (greater x value), similar to TA/LCA motoneurons in normal animals (Fig 8). Vector analysis demonstrated the mean vector for the TA/LCA motoneurons to be significantly greater than the mean PCA vector in normal controls. The difference between PCA and TA/LCA vector lengths was lost following reinnervation, and values for both the PCA and the TA/LCA muscles approached the length of the normal TA/LCA vector (Fig 9).

Group-by–muscle type mixed ANOVAs showed similar results in all three dimensions in the transverse plane. In all cases, there was no reliable main effect of group ($p > .05$), but there was a reliable effect of muscle type ($F_{1,11} = 27.8$, 50.6, 83.8 for the x, y, and vector measures, respectively, $p < .05$) and a reliable interaction ($F_{1,11} = 10.6$, 15.2, 33.0 for the x, y, and vector measures, respectively, $p < .05$). Post-hoc Newman-Keuls testing demonstrated, for each dimension, the position of PCA motoneurons in the normal animals to be reliably different ($p < .05$) from that of the other three groups of motoneurons (normal TA/LCA, reinnervated PCA, and TA/LCA).

In comparing the rostral-caudal positions, no separation was seen between the TA/LCA motoneurons and the PCA motoneurons in either the normal group or the reinnervated group. However, reinnervating neurons in general were found to be more caudal than the normal population (Fig 10). An overall effect of group ($F_{1,11} = 7.3$, $p < .05$) was seen in the rostral-caudal dimension, but no reliable effect of muscle type ($F_{1,11} = 0.3$, $p = .60$) or reliable interaction ($F_{1,11} = 1.1$, $p = .33$) was found.

Electromyography. In nine control animals EMG revealed phasic electrical activity synchronous with respiration in the PCA, and activity synchronous with deglutition in the TA/LCA. In the four animals surviving 15 weeks following RLN section and primary neurorrhaphy, phasic motor activity synchronous with respiration was seen in the TA/LCA muscle as well as the PCA (Fig 11).

DISCUSSION

The somatotopic arrangement of labeled neurons in this study, found in the lower two thirds of the NA in control animals, is consistent with previous work,[14,20] with a few exceptions. Separation of abductors and adductors was observed in the transverse dimension, although not in the rostral-caudal aspect as demonstrated by Portillo and Pasaro.[20] Portillo and Pasaro also found the PCA column to stretch further rostrally and mix extensively with the CT motoneurons — a finding not observed in our study. This difference may be due in part to our interpretation of what is a labeled laryngeal motoneuron and what is contamination. The range of laryngeal motoneuron labeling was defined in our study as the range of the whole RLN (control group 1), and only a very small rostral-caudal overlap occurred between the CT (control group 4) and the PCA and TA/LCA motoneuron populations. Except for labeling that was attributed to contamination from spread of dyes (control groups 3 and 4), we found no laryngeal motoneurons located outside the NA in the retrofacial nucleus or the dorsal motor nucleus of the vagus.

Double-labeled motoneurons (yellow nucleus sur-

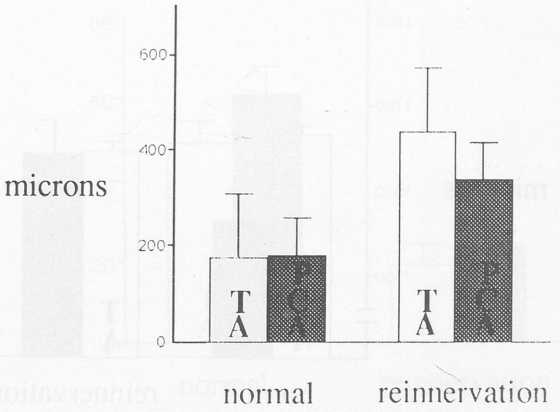

Fig 10. Mean z coordinate values are shown for TA and PCA muscles in normal animals (n = 9) compared to TA and PCA muscles in reinnervated animals (n = 4). Z coordinate value corresponds to rostral-caudal position in 3-D reconstruction relative to obex. By convention, positive values indicate distance caudal to obex. While there is more caudal shift following reinnervation, no significance was demonstrated.

rounded by blue cytoplasm) were found consistently in both normal and reinnervated populations. Previously, Hisa and Sato[19] found double-labeled motoneurons from both the TA and the LCA, muscles of similar function. Dual-functioning neurons were suggested to be involved in coordination of phonation and swallowing.[19] One might expect to see more of these neurons following a period of random axonal regeneration, but this was not observed in the present study. No new conclusions can be drawn at this time concerning the significance of these cells.

The loss of functional organization in the NA in the reinnervated animals supports the findings of Nahm et al.[21] Our study further defines the neuroanatomic changes that occur with reinnervation of the larynx. Reinnervating neurons for both the PCA and TA/LCA muscles tended to be located within a similar position in the brain stem as the TA/LCA motoneurons in normal animals.

Positional shifts seen in the transverse plane may occur as the result of selective reinnervation by the TA/LCA neurons or a subpopulation of the more dorsal-lateral motoneurons. This may be explained by metabolic or enzymatic differences between the abductor and adductor populations contributing greater regenerative capacity to the TA/LCA motoneurons. No previous documentation of selective reinnervation in the larynx has been reported. Previous studies in rats have shown a tendency for axial muscles to be reinnervated by their appropriate neurons. Selective reinnervation in this model was age-related, with younger animals showing greater selectivity.[25,29,30] Age-related selective reinnervation has also been demonstrated following facial nerve regeneration in the rat.[24]

A second possible explanation for the positional shift of reinnervating motoneurons is cell death of a specific motoneuron population. With relatively fewer PCA motoneurons surviving, the total population of reinnervating motoneurons would occupy a more dorsal-lateral position in the brain stem. Degeneration of motoneurons is supported by the decreased labeling of neurons documented in our study. Nahm et al[21] found a similar decrease in labeling of the PCA motoneurons in their freeze-regeneration study. They also reported chromatolytic changes in PCA neurons, but suggested the decrease in labeling was due not to neuronal death but to the inability of the new axons to transport HRP. Studies to determine the ability of the regenerated RLN to retrogradely transport dye, as well as investigate the question of cell death and selective reinnervation, are in progress.

SUMMARY

Fluorescent dyes were used for retrograde neuronal labeling studies in normal rats and rats that

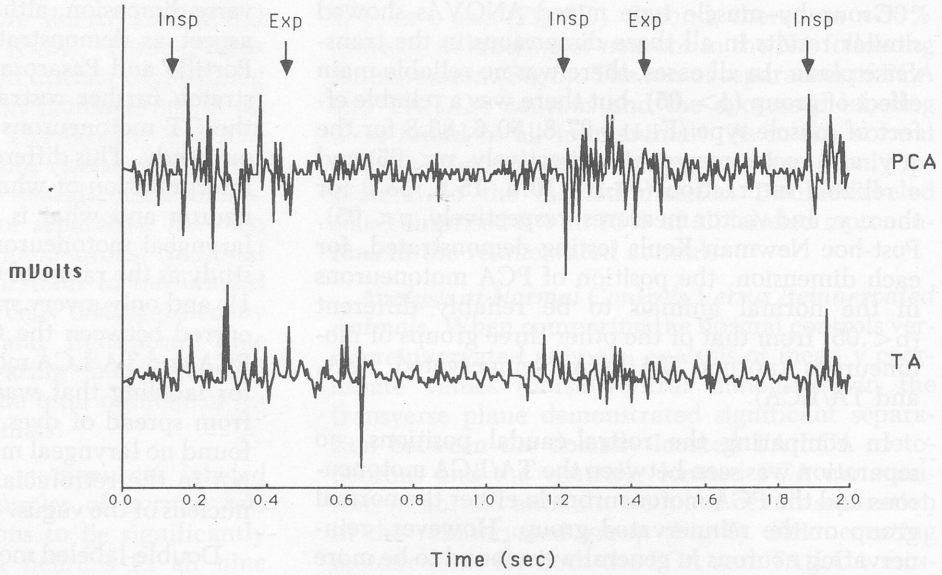

Fig 11. Simultaneous tracings of PCA and TA laryngeal electromyographic recordings are shown 3 months following reinnervation. Phasic electrical activity synchronous with respiration is seen in both TA and PCA tracings. Insp — inspiration, Exp — expiration.

underwent a reinnervation procedure of the RLN. Normal animals were found to have a functional organization of the laryngeal motoneurons in the NA. Reinnervated animals lost this organization in the NA, and the diminished population of reinnervating neurons were found in a location similar to that of the adductor neurons in the NA of normal control animals.

ACKNOWLEDGMENT — The authors thank Richard Hyson, PhD, for statistical analysis and critical review.

REFERENCES

1. Crumley RL. Laryngeal synkinesis: its significance to the laryngologist. Ann Otol Rhinol Laryngol 1989;98:87-92.

2. Siribodhi C, Sundmäker W, Atkins JP, Bonner FJ. Electromyographic studies of laryngeal paralysis and regeneration of laryngeal motor nerves in dogs. Laryngoscope 1963;73:148-64.

3. Tashiro T. Experimental studies on the reinnervation of larynx after accurate neurorrhaphy. Laryngoscope 1972;82:225-36.

4. Dedo HH. Electromyographic and visual evaluation of recurrent laryngeal nerve anastomosis in dogs. Ann Otol Rhinol Laryngol 1971;80:664-8.

5. Crumley RL, McCabe BF. Regeneration of the recurrent laryngeal nerve. Otolaryngol Head Neck Surg 1982;90:442-7.

6. Crumley RL. Mechanisms of synkinesis. Laryngoscope 1979;89:1847-54.

7. Tomita H. An electromyographic study of recurrent laryngeal nerve paralysis. Jpn J Otolaryngol 1967;70:963-85.

8. Murakami Y, Kirchner JA. Vocal cord abduction by regenerated recurrent laryngeal nerve. An experimental study in the dog. Arch Otolaryngol 1971;94:64-8.

9. Ohyama M, Ueda N, Harvey JE, Mogi G, Ogura JH. Electrophysiologic study of reinnervated laryngeal motor units. Laryngoscope 1972;82:237-51.

10. Doyle PJ, Brummet RE, Everts EC. Results of surgical section and repair of the recurrent laryngeal nerve. Laryngoscope 1967;77:1245-54.

11. Gordon T, Thomas CK, Stein RB, Erdebil S. Comparison of physiological and histochemical properties of motor units after cross-reinnervation of antagonistic muscles in the cat hindlimb. J Neurophysiol 1988;60:365-78.

12. Boles R, Fritzell B. Injury and repair of the recurrent laryngeal nerves in dogs. Laryngoscope 1969;79:1405-18.

13. Rice DH. Laryngeal reinnervation. Laryngoscope 1982; 92:1049-59.

14. Hinrichsen CFL, Ryan AT. Localization of laryngeal motoneurons in the rat: morphologic evidence for dual innervations? Exp Neurol 1981;74:341-55.

15. Davis PJ, Nail BS. On the location and size of laryngeal motoneurons in cat and rabbit. J Comp Neurol 1984;230:13-32.

16. Yoshida Y, Miyazaki T, Hirano M, Shin T, Kanaseki T. Arrangement of motoneurons innervating the intrinsic laryngeal muscles of cats as demonstrated by horseradish peroxidase. Acta Otolaryngol (Stockh) 1982;94:329-34.

17. Yoshida Y, Mitsumasu T, Hirano M, Kanaseki T. Somatotopic representation of the laryngeal motoneurons in the medulla of monkeys. Acta Otolaryngol (Stockh) 1985;100:299-303.

18. Ellenberger HH, Feldman JL. Subnuclear organization of the lateral tegmental field of the rat. I: Nucleus ambiguus and ventral respiratory group. J Comp Neurol 1990;294:202-11.

19. Hisa Y, Sato F. Localization of the motoneurons innervating the canine larynx by the fluorescent labeling technique. In: Hirano M, ed. Neurolaryngology: recent advances. Vol 2. Boston, Mass: Little, Brown, 1987:19-26.

20. Portillo F, Pasaro R. Location of motoneurons supplying the intrinsic laryngeal muscles of rats. Brain Rehav Evol 1988; 32:220-5.

21. Nahm I, Shin T, Chiba T. Regeneration of the recurrent laryngeal nerve in the guinea pig. Reorganization of motoneurons after freezing injury. Am J Otolaryngol 1990;11:90-8.

22. Mizuno N, Uemura-Sumi M, Matsuda K, Takeuchi Y, Kume M, Matsushima R. Non-selective distribution of hypoglossal nerve fibers after section and resuture: a horseradish peroxidase study in the cat. Neurosci Lett 1980;19:33-7.

23. Bernstein JJ, Guth L. Nonselectivity in establishment of neuromuscular connections following nerve regeneration in the rat. Exp Neurol 1961;4:262-75.

24. Aldskogius H, Thomander L. Selective reinnervation of somatotopically appropriate muscles after facial nerve transection and regeneration in the neonatal rat. Brain Res 1986;375:126-34.

25. Laskowski MB, Sanes JR. Topographically selective reinnervation of adult mammalian skeletal muscles. J Neurosci 1988; 8:3094-9.

26. Mesulam M-M. Tetramethyl benzidine for horseradish peroxidase neurohistochemistry: a non-carcinogenic blue reaction product with superior sensitivity for visualizing neural afferents and efferents. J Histochem Cytochem 1978;26:106-17.

27. Mesulam M-M, Hegarty E, Barbas H, et al. Additional factors influencing sensitivity in the tetramethyl benzidine method for horseradish peroxidase neurohistochemistry. J Histochem Cytochem 1980;28:1255-9.

28. Abercrombie M. Estimation of nuclear population from microtome sections. Anat Rec 1946;94:239-47.

29. Wigstad DJ, Sanes JR. Selective reinnervation of adult mammalian muscles by axons from different segmental levels. Nature 1982;299:464-7.

30. Laskowski MB, High JA. Expression of nerve-muscle topography during development. J Neurosci 1989;9:175-82.

CHARACTERISTICS OF LATE RESPONSES TO SUPERIOR LARYNGEAL NERVE STIMULATION IN HUMANS

CHRISTY L. LUDLOW, PHD
FREDERICK VAN PELT, MD JUNJI KODA, SCD
BETHESDA, MARYLAND

To characterize human thyroarytenoid and cricothyroid muscle responses to stimulation of the internal (sensory) and external (motor) branches of the superior laryngeal nerve (SLN), three awake subjects were studied at rest and during muscle activation with stimulation at different current levels. When only the external branch was stimulated, direct cricothyroid muscle responses were obtained without responses in either thyroarytenoid muscle. When only the internal branch was stimulated, no cricothyroid responses were obtained, but two late thyroarytenoid responses occurred (R1 and R2). The R1 response was usually ipsilateral and had a mean onset latency of 18 milliseconds, while the R2 response was bilateral and occurred between 66 and 70 milliseconds. Both responses tended to decrease in latency and increase in amplitude with increased stimulation level. The similarity of R1 to the adductor response and R2 to other late responses is discussed.

KEY WORDS — cricothyroid muscle, reflex, superior laryngeal nerve.

The larynx provides protective airway closure during swallowing and coughing. Both these functions produce strong vocal fold adduction, including shortening and adduction by the thyroarytenoid (TA) muscles.[1-3] Coughing is a response to afferent stimulation of supraglottal mucosal receptors resulting in rapid vocal fold adduction.[4] Studies of muscle responses to stimulation of afferent fibers in the superior laryngeal nerve (SLN) in animals have demonstrated a rapid short contraction in the TA muscle within 10 to 12 milliseconds in cats,[5,6] referred to as the glottal closure reflex. This response is rapid (completed within 20 milliseconds), occurs bilaterally with increased stimulation amplitude in cats, and can be elicited or enhanced by stimulation of other cranial nerves.[7,8]

Species differences have been noted in the occurrence of these responses, with a contralateral TA response being more easily elicited in cats than in dogs.[6,9] Only a few attempts have been made to elicit these responses from humans.[6,10] In three patients, the SLN was stimulated under anesthesia and an ipsilateral TA response was observed with an onset latency of 25 to 27 milliseconds.[6] However, contralateral SLN stimulation was unable to elicit a response; this finding suggested that the crossed glottic closure reflex did not appear in humans. These authors were also unable to elicit any responses in the posterior cricoarytenoid muscle following SLN stimulation.[6] In awake humans, surface stimulation in the region of the SLN was reported to produce an ipsilateral cricothyroid (CT) muscle response at about 5 milliseconds, followed by a second response at about 20 milliseconds with about an 8-millisecond duration.[10] This second response was also elicited from the posterior CT and TA muscles at 22 milliseconds on the ipsilateral side.[10] Because an early muscle response was elicited from the CT muscle, it is likely that both the external and internal branches of the SLN were stimulated.

The glottal closure reflex, a short regular response, has been differentiated neurophysiologically from "irregular excitatory after-discharges"[5(p151)] that occur when the SLN is repetitively stimulated at 8 Hz. These afterdischarges persist beyond the cessation of the repetitive stimulus and were thought to be similar to the strong clonic closure of laryngospasm,[5,11] an abnormal response to laryngeal stimulation occurring most often during extubation under light levels of anesthesia and in rare forms of neurologic disease. We have found no reports of late afterdischarges elicited in humans.

Our purpose was to study the characteristics of late responses to SLN stimulation in awake humans. Because the SLN has both external and internal branches, with the latter containing a greater number of mucosal afferents, we examined the characteristics of late responses during simultaneous stimulation of the external and internal branches and during separate stimulation of each branch.

METHODS AND MATERIALS

Three normal volunteers participated in these studies; one man of 52 years (subject 1) and two women of 18 and 49 years (subjects 2 and 3). All were free of neurologic or laryngologic disorders, had no medical history of such, and participated after informed consent. Hooked wire electrodes were

From the Voice and Speech Section, Division of Intramural Research, National Institutes of Health/National Institute on Deafness and Other Communication Disorders, Bethesda, Maryland.

Presented at the meeting of the American Laryngological Association, Waikoloa, Hawaii, May 4-5, 1991.

REPRINTS — Christy L. Ludlow, PhD, Voice and Speech Section, NIDCD, Bldg 10, Room 5D38, 9000 Rockville Pike, Bethesda, MD 20892.

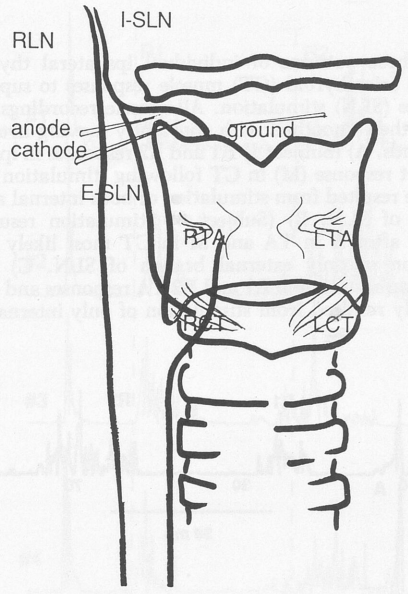

Fig 1. Schematic diagram of percutaneous insertion positions of stimulating and ground electrodes for stimulation of internal branch of superior laryngeal nerve (I-SLN), separate from external branch of superior laryngeal nerve (E-SLN) and not involving recurrent laryngeal nerve (RLN). Hooked wire electrodes were inserted percutaneously into four muscles labeled here: right thyroarytenoid (RTA), left thyroarytenoid (LTA), right cricothyroid (RCT), and left cricothyroid (LCT).

used for electromyographic (EMG) recordings from the right and left TA and the right and left CT muscles. Two stainless steel wires (0.0508 mm in diameter), stripped of insulation for 1 mm at one end, were contained in a 27-gauge needle. After a subcutaneous injection of 0.5 mL of 2% lidocaine with epinephrine, hooked wire electrodes were inserted into the CT and TA muscles by means of the insertion techniques described by Hirano and Ohala.[12] Verifying gestures included sustained activation during extended phonation and effort closure for the TA muscle.[12] Recordings with a burst of activation prior to and following phonation, but not during phonation and with phasic activation during exhalation, were identified as coming from the lateral cricoarytenoid muscle and were not used. For the CT muscle, activation increased during high-pitched phonation but not during low-pitched phonation.[12] Those with large increases during head raising were identified as coming from the sternohyoid or sternothyroid muscle and were not used. Respiratory inductive plethysmography (Respitrace) was used to record the sum of chest and abdominal movements during respiration in subjects 1 and 3.

After electrode verification, subjects were instructed to relax for 5 minutes before beginning nerve stimulation. Several minutes of muscle activity were recorded along with respiratory movement while the subject was in a supine position, relaxed, and not swallowing, before beginning stimulation. Two monopolar Teflon-coated 27-gauge, 37-mm needle electrodes (TECA MF-37) served as the stimulation electrodes and were inserted in the region between the hyoid bone and the thyroid cartilage, as illustrated in Fig 1. A third TECA electrode was inserted close to the midline of the superior border of the thyroid cartilage and served as a ground. Insertion was between 1 and 3 cm in depth for all three electrodes, with the cathode and anode inserted 1 cm apart. Stimulation was on the left side in subject 3 and on the right side in subjects 1 and 2. The ground electrode was necessary to reduce stimulus artifact in the muscle recordings. The stimulus was a rectangular current pulse of 1 millisecond in duration delivered through a DISA 15E07 stimulator output unit.

The stimulator was set at zero and incremented in 0.2-mA steps until a consistent threshold response was seen in at least one muscle on a Disagraph storage oscilloscope displaying the four muscle EMG signals over 30 milliseconds. Once this threshold response was obtained, usually around 1 mA, six stimulations were presented randomly at a rate of one every 5 seconds at that current level. Six stimuli were then presented at each of three or four current levels higher than the threshold level but less than 5.4 mA. Throughout the stimulation studies, the four muscle signals and the stimulation trigger were recorded simultaneously on a multichannel instrumentation tape recorder in all subjects. The Respitrace signal was also recorded in subjects 1 and 3. The passband on the EMG filters was between 100 and 5,000 Hz for the hooked wire electrodes.

Three different EMG response patterns were sought (Fig 2). One, with only an early response in the ipsilateral CT muscle at 6 to 8 milliseconds and no response in the TA muscle, was interpreted as stimulation of only the external branch of the SLN containing efferent fibers to the CT muscle (Fig 2B). A second, without any early response in the CT muscle but a late response between 16 and 24 milliseconds in the ipsilateral TA muscle, was interpreted as stimulation of only the afferent fibers contained in the internal branch of the SLN (Fig 2C). The third, with both an early response in the CT muscle at 6 to 8 milliseconds and a late response between 16 and 24 milliseconds in the TA muscle, was interpreted as stimulation of both the external and internal branches of the SLN (Fig 2A). Because these studies were being conducted in awake humans without dissection, we cannot be certain that our interpretations were correct regarding which SLN branches were being stimulated.

Besides six responses being recorded at each of three or four different stimulation current levels during quiet respiration, two subjects were also tested when the laryngeal muscle activity was significantly increased over quiet breathing levels: during effort closure in subject 2, and during fiberoptic viewing of vocal fold motion in subject 3. After eliciting responses exhibiting one of the three

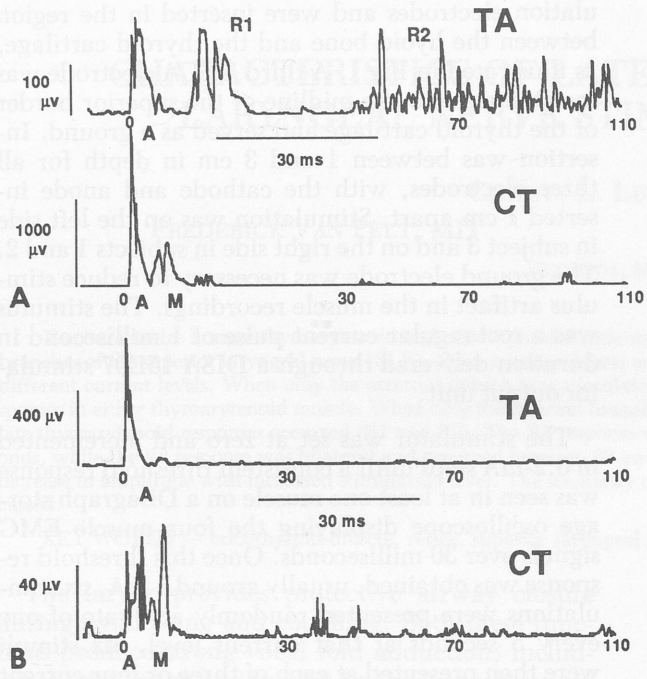

Fig 2. Three patterns of individual ipsilateral thyroarytenoid (TA) and cricothyroid (CT) muscle responses to superior laryngeal nerve (SLN) stimulation. All muscle recordings were rectified and then smoothed with constantly moving average over 5 milliseconds. A) (Subject 1) R1 and R2 responses in ipsilateral TA and direct response (M) in CT following stimulation artifact (A) may have resulted from stimulation of both internal and external branches of SLN. B) (Subject 3) Stimulation resulting in no responses after A in TA and M in CT most likely was due to stimulation of only external branch of SLN. C) (Subject 3) Stimulation resulting in R1 and R2 TA responses and no M in CT most likely resulted from stimulation of only internal branch of SLN.

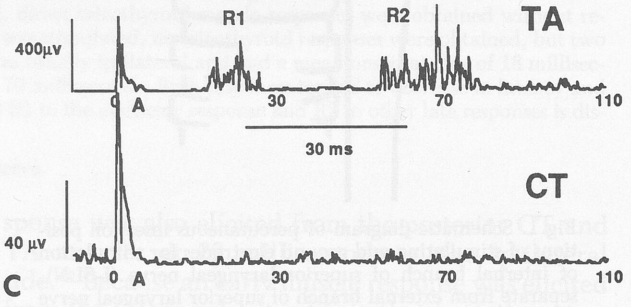

expected response patterns at three different amplitude levels, the stimulating electrodes were moved until another of the three different response patterns was obtained. At least three different current levels were readministered.

The tape recordings were digitized off-line into a PDP 11/73 LSI minicomputer. The trigger signal and the four muscle signals were digitized at 5,000 samples per second with anti-aliasing low-pass filtering at 2,000 Hz to prevent errors in the digitally sampled data due to rapid changes in the waveforms.[13] The respiratory signal was simultaneously sampled at 500 Hz with anti-aliasing at 100 Hz.

The trigger pulse was identified for synchronized display of each muscle response. A set of six responses at one stimulation level are displayed in Fig 3. Because of the variability in latency and amplitude of the responses from token to token, each individual response was measured. The 10 milliseconds prior to presentation of each stimulus was identified as a period of baseline muscle activity. This was measured by averaging the signal within the 10-millisecond static window. The mean and standard deviation of the baseline activity measures were computed from the six tokens recorded at each stimulation level in each muscle in each subject. Before attempting to identify muscle responses to the current stimulus, the muscle signals were first full-wave rectified and then smoothed by computing the moving average with a window width of 5 milliseconds. An algorithm containing a digital threshold detector was then used to determine response onset in the smoothed EMG signal. The detection threshold was set to an amplitude 3 SD above the mean of the baseline activity. Similarly, a response offset threshold detector was set to identify the end of a response by detecting when the EMG signal descended to below 1 SD above the baseline mean. The response onsets and offsets identified were used to define a static averaging window for computing the mean amount of muscle activation during each response, the response duration, and the onset latency after the onset of the pulse trigger. These measures were made for each of the responses occurring within 200 milliseconds after each pulse trigger and often included two responses, designated as R1 and R2. The first, R1, usually occurred between 16 and 25 milliseconds and had a duration of between 3 and 30 milliseconds. This was the expected time of occurrence previously reported for the glottal closure reflex.[6,10] Then R2, an unexpected response, was identified between 50 and 80 milliseconds and had a duration of between 15 and 100 milliseconds. The right and left TA recordings during each stimulation token were processed to determine if responses were identified and to determine the latency, duration, and mean amplitude of each response.

In subjects 1 and 3, movement of the Respitrace signal was examined simultaneous with the time of occurrence of the trigger pulse, and each token was identified as occurring during either inhalation or exhalation. All of the responses occurring during quiet respiration were classified as falling into either cycle.

The data were compiled according to whether an R1 and/or an R2 response occurred in a token and according to the mean and standard deviation of the baseline activity for the set of six tokens and the latency, duration, and amplitude of each R1 and R2 response. The token sets were compiled according to whether they were recorded during increased muscle activity or at rest, according to whether they

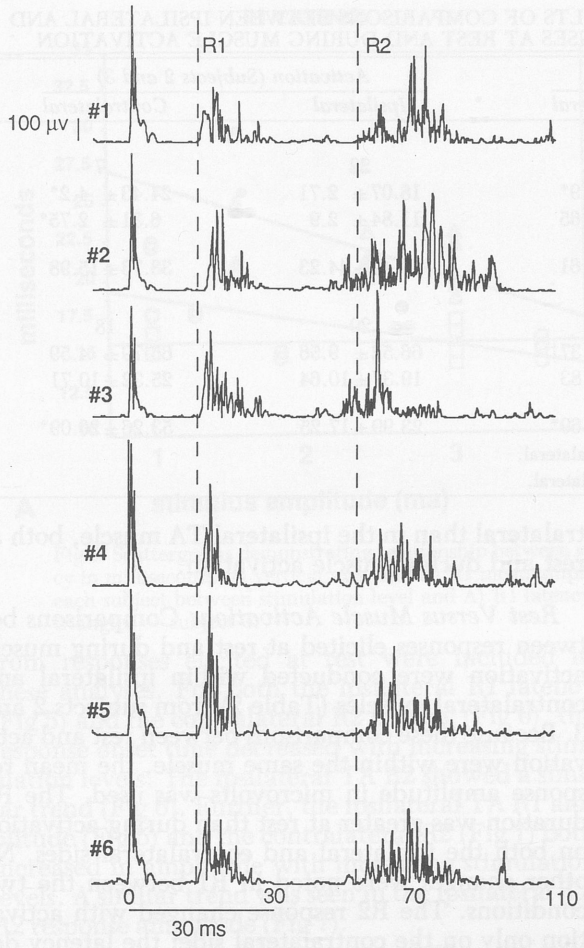

Fig 3. Set of six ipsilateral individual thyroarytenoid responses during internal superior laryngeal nerve stimulation at 2.2 mA. Onset latency and amplitude of R1 and R2 responses vary, although same stimulation level was used for each response. Signals have been full-wave rectified and smoothed with moving average over 5 milliseconds.

were from the TA muscle ipsilateral or contralateral to the SLN stimulation side, and according to stimulation current levels.

During data analysis, the frequencies of ipsilateral and contralateral TA responses during quiet breathing and with increased muscle activation were compared by using contingency analyses. Second, the latencies, durations, and amplitudes of the R1 and R2 responses, in the ipsilateral and contralateral TA muscles, were compared by using one-way analyses of variance. Third, the effects of increasing background muscle activity on the latencies, durations, and amplitudes of the R1 and R2 responses, in both the ipsilateral and contralateral TAs, were examined by using one-way analyses of variance. Fourth, the effects of increasing the stimulation level on the latency and amplitude of R1 and R2 responses were examined by computing the line of best fit between stimulation level and R1 and R2 response characteristics within each subject. Finally, the effects of the respiratory cycle on the frequency of R1 and R2 responses were examined by

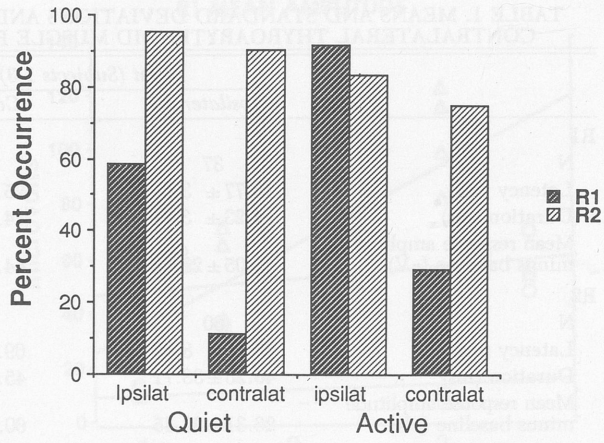

Fig 4. (Subjects 2 and 3) Histogram showing percentage of stimulations resulting in R1 and R2 responses in ipsilateral and contralateral thyroarytenoid muscles from two subjects at rest (quiet) and during muscle activity (active).

using contingency analyses, and differences in R1 and R2 latency and amplitude were compared between inhalation and exhalation by using analyses of variance.

RESULTS

Different response patterns were obtained in the three subjects. Subject 1 exhibited both early CT responses beginning between 3 and 4 milliseconds after stimulation and R1 and R2 in the TA muscle, suggesting that both the internal and external branches of the SLN were stimulated (Fig 2A). Both subject 2 and subject 3 exhibited two different response patterns during different electrode placements. At one placement, no CT response occurred, while R1 and R2 responses occurred in at least one TA muscle (Fig 2C); this finding suggests that only the internal branch was being stimulated. At the other, an early CT response occurred, but no responses in the TA; this finding suggests that only the external branch was being stimulated (Fig 2B). The data analysis in subjects 2 and 3 included the responses in which only internal SLN stimulation was suggested, while subject 1's responses were those obtained when stimulation of both branches was suggested.

Frequency of R1 and R2 Responses. A total of 174 tokens were measured (87 in each TA muscle), with 21 during quiet in subject 1; 24 during quiet and 12 during muscle activation in subject 2; and 18 during quiet and 12 during muscle activation in subject 3. The percentages of stimulations with R1 and R2 responses in the ipsilateral and contralateral TA muscles are displayed in Fig 4. A significantly higher percentage of R1 responses occurred in the ipsilateral than the contralateral TA muscle ($\chi^2 = 46.4$, $p = .0001$). The R2 response occurred equally on the ipsilateral and contralateral sides. The R1 response was more frequent during muscle activation than during quiet respiration ($\chi^2 = 9.82$, $p = .002$), while R2 was less frequent during muscle activation than during quiet respiration ($\chi^2 = 6.23$, $p = .01$).

TABLE 1. MEANS AND STANDARD DEVIATIONS AND RESULTS OF COMPARISONS BETWEEN IPSILATERAL AND CONTRALATERAL THYROARYTENOID MUSCLE RESPONSES AT REST AND DURING MUSCLE ACTIVATION

	Rest (Subjects 1-3)		*Activation (Subjects 2 and 3)*	
	Ipsilateral	*Contralateral*	*Ipsilateral*	*Contralateral*
R1				
N	37	7	22	7
Latency (ms)	18.77± 3.6	25.56± 6.9*	18.07± 2.71	24.43± 4.2*
Duration (ms)	14.23± 3.71	14.46± 9.65	11.84± 2.9	6.31± 2.75*
Mean response amplitude minus baseline (μV)	47.05±29.52	44.34±15.61	53.49±44.23	38.73±15.98
R2				
N	60	57	20	18
Latency (ms)	65.41± 8.42	69.93± 8.37†	66.52± 9.56	65.79± 4.59
Duration (ms)	40.26±33.71	45.26±30.83	19.37±10.64	25.32±10.71
Mean response amplitude minus baseline (μV)	26.31±23.45	60.87±29.69*	23.99±17.25	53.26±26.09*

*p≤.001, on one-way analysis of variance comparing ipsilateral with contralateral.
†p≤.01, on one-way analysis of variance comparing ipsilateral with contralateral.

Ipsilateral Versus Contralateral Thyroarytenoid Responses. Comparisons were made between the TA responses ipsilateral and contralateral to the stimulation side (Table 1). The data during muscle activation were from subjects 2 and 3 only. The R1 response latency was later in the contralateral TA muscle by a mean difference of 6.5 milliseconds both at rest and during muscle activation. The R1 duration was the same on the two sides at rest, but was reduced on the contralateral side with muscle activation. To compare the response amplitude between the ipsilateral and contralateral muscles, the muscle activation increase was normalized by subtracting the mean baseline activity from the mean response amplitude. This amplitude did not differ significantly between the ipsilateral and the contralateral TA muscles either at rest or during muscle activation.

The R2 comparisons indicated significant differences between the ipsilateral and contralateral responses both at rest and during activation. The R2 latency was later on the contralateral side with a mean difference of 4 milliseconds, at rest. The R2 response amplitude, when corrected by subtracting the mean baseline activity, was greater in the contralateral than in the ipsilateral TA muscle, both at rest and during muscle activation.

Rest Versus Muscle Activation. Comparisons between responses elicited at rest and during muscle activation were conducted within ipsilateral and contralateral muscles (Table 2) from subjects 2 and 3. Because these comparisons between rest and activation were within the same muscle, the mean response amplitude in microvolts was used. The R1 duration was greater at rest than during activation on both the ipsilateral and contralateral sides. No other changes were noted in R1 between the two conditions. The R2 response changed with activation only on the contralateral side: the latency decreased and the amplitude increased.

Changes in R1 and R2 With Increasing Stimulation Level. The R1 and R2 response characteristics were examined across increasing stimulation levels. The lines of best fit were derived for each subject between current levels and each of the following: R1 ipsilateral response latency and amplitude (Fig 5); ipsilateral and contralateral TA R2 response latencies (Fig 6); and ipsilateral and contralateral R2 mean response amplitudes (Fig 7). Only the data

TABLE 2. MEANS AND STANDARD DEVIATIONS AND RESULTS OF COMPARISONS BETWEEN RESPONSES AT REST AND DURING MUSCLE ACTIVATION IN IPSILATERAL AND CONTRALATERAL THYROARYTENOID MUSCLES

	Ipsilateral (Subjects 2 and 3)		*Contralateral (Subjects 2 and 3)*	
	Rest	*Activation*	*Rest*	*Activation*
R1				
N	23	22	4	7
Latency (ms)	19.8 ± 3.78	18.07± 2.71	20.52± 2.08	24.43± 4.2
Duration (ms)	14.4 ± 3.86	11.84± 2.9*	15.2 ± 6.06	6.31± 2.75*
Mean response amplitude (μV)	53.11±37.5	69.29±50.6	64.24±17.1	69.18±25.05
R2				
N	42	20	38	18
Latency (ms)	65.47± 4.53	66.52± 9.56	70.84± 5.31	65.79± 4.59†
Duration (ms)	23.8 ± 7.94	19.37±10.64	30.09±11.29	25.32±10.71
Mean response amplitude (μV)	32.33±30.87	37.82±24.94	52.44±14.74	83.56±33.36†

*p≤.01, on one-way analysis of variance comparing rest with activation.
†p≤.001, on one-way analysis of variance comparing rest with activation.

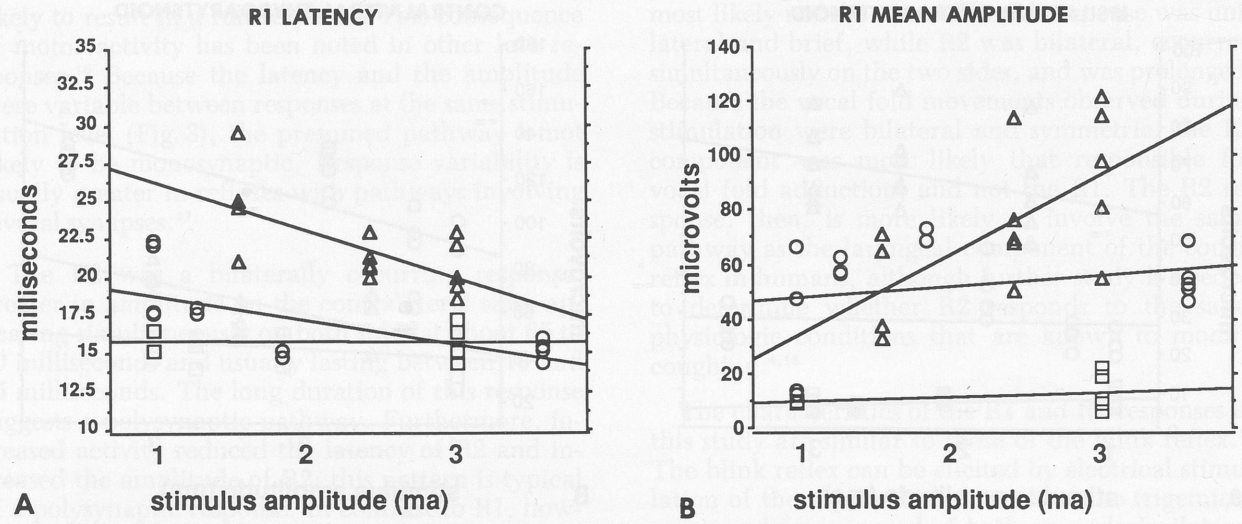

Fig 5. Scattergrams demonstrating relationship between stimulation level in milliamperes on horizontal axis and A) R1 latency in milliseconds on vertical axis, and B) R1 mean amplitude in microvolts on vertical axis. Lines of best fit are drawn for each subject between stimulation level and A) R1 latency and B) R1 amplitude. Circles — subject 1, squares — subject 2, triangles — subject 3.

from responses elicited at rest were included in these analyses. For both the ipsilateral R1 latency (Fig 5) and the contralateral R2 latency (Fig 6), the response onset time decreased with increasing stimulation levels. The ipsilateral TA R2 showed a similar trend (Fig 6). Further, the ipsilateral TA R1 amplitude (Fig 5) and the contralateral R2 (Fig 7) both increased in amplitude with increasing stimulation levels. A similar trend was seen in the ipsilateral TA R2 response amplitude (Fig 7).

Response Modulation During Respiratory Cycle. To examine the effects of the respiratory cycle on the frequency of occurrence of R1 and R2, contingency analyses were conducted. No difference in the frequency of occurrence in R1 was found between inhalation and exhalation ($\chi^2 = .11$, $p = .7387$). The R2 responses showed a tendency to occur more frequently during inhalation ($\chi^2 = 3.48$, $p = .06$). The R2 response was present 92% of the time during inhalation and 77.8% of the time during exhalation.

The effects of the respiratory cycle on the latency and amplitude of R1 and R2 responses occurring in quiet in ipsilateral and contralateral muscles were examined by using two-way analyses of variance, with respiratory cycle as one factor and muscle side as the other. None of the analyses had significant main effects for respiration cycle. The only significant interaction between muscle side (ipsilateral and contralateral) and respiration cycle (inhalation and exhalation) occurred with R1 latency ($p = .02$). The contralateral muscle had a shorter R1 latency during inhalation (mean = 19.95) than during exha-

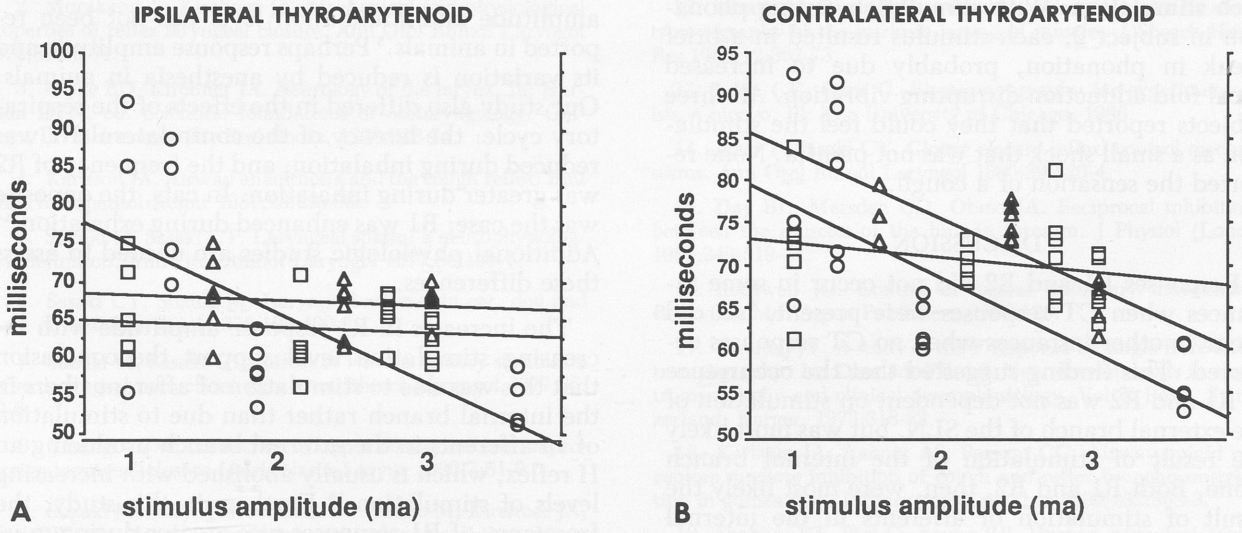

Fig 6. Scattergrams demonstrating relationship between stimulation level in milliamperes on horizontal axis and R2 latency in milliseconds on vertical axis in A) ipsilateral thyroarytenoid muscle and B) contralateral thyroarytenoid muscle. Lines of best fit between stimulation level and R2 latency are drawn for each subject in each graph. Circles — subject 1, squares — subject 2, triangles — subject 3.

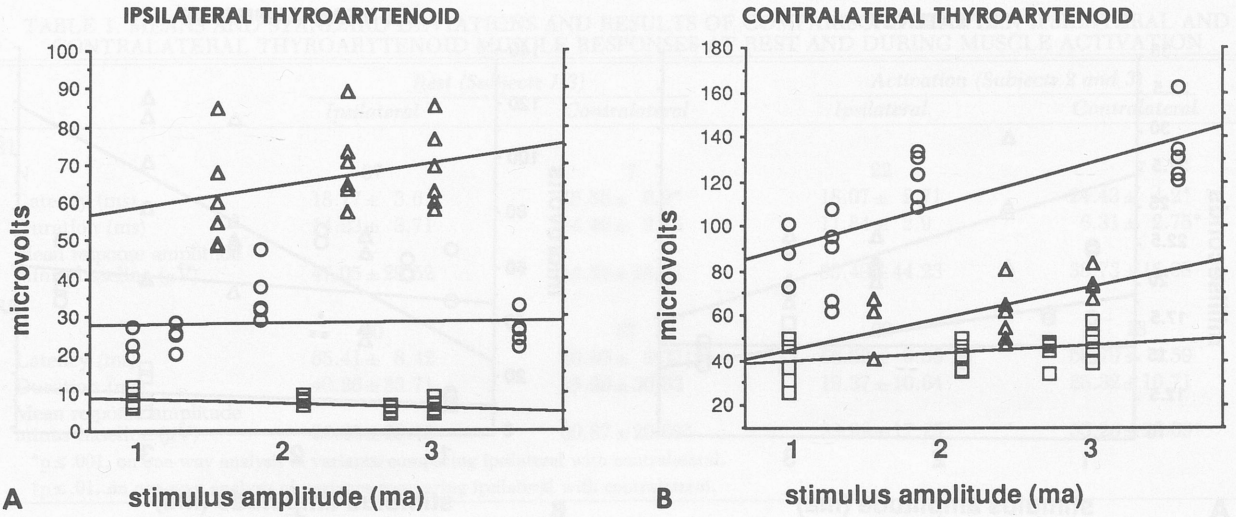

Fig 7. Scattergrams demonstrating relationship between stimulation level in milliamperes on horizontal axis and mean R2 amplitude in microvolts on vertical axis in A) ipsilateral thyroarytenoid muscle and B) contralateral thyroarytenoid muscle. Lines of best fit between stimulation level and R2 amplitude are drawn for each subject in each graft. Circles — subject 1, squares — subject 2, triangles — subject 3.

lation (mean = 27.8).

Relationship Between R1 and R2. To determine whether R1 and R2 had common underlying physiologic mechanisms, Spearman's rank correlation coefficients were computed between the mean values of the R1 and R2 responses within each of the three subjects. Significant relationships ($p \leq .05$) were found only in subject 1. The latencies of ipsilateral R1 and R2 responses were related ($r = .77$, $p = .01$), as were the durations of R1 and R2 ($r = .71$, $p = .02$).

Fiberoptic Viewing of Vocal Movement Responses and Subject Reports. In subject 3, a nasopharyngoscope was inserted and a videotape recording was made of vocal fold movement during stimulation of the internal branch of the SLN. Bilateral symmetric vocal fold adductions occurred synchronous with each stimulation. With stimulation during phonation in subject 2, each stimulus resulted in a brief break in phonation, probably due to increased vocal fold adduction disrupting vibration. All three subjects reported that they could feel the stimulation as a small shock that was not painful. None reported the sensation of a cough.

DISCUSSION

Responses R1 and R2 did not occur in some instances when CT responses were present, but did occur in other instances when no CT responses occurred. This finding suggested that the occurrence of R1 and R2 was not dependent on stimulation of the external branch of the SLN, but was most likely the result of stimulation of the internal branch alone. Both R1 and R2, then, were most likely the result of stimulation of afferents in the internal branch of the SLN.

The characteristics of R1 were somewhat similar to previous reports of the glottal closure reflex.[6,10] Responses were predominantly in the ipsilateral TA muscle, at 18 milliseconds. This is a longer latency than the 10 to 12 milliseconds reported in cats,[6] but shorter than the 25 to 27 milliseconds for ipsilateral responses reported in humans under anesthesia[6] or the 22 milliseconds previously reported in awake humans.[10] These differences may be due to a longer recurrent laryngeal nerve in humans than in cats and the effects of anesthesia on this reflex response. The only previous report of this early response in awake humans[10] used a shorter stimulation pulse, only 0.1 millisecond, and surface stimulation, which may have contributed to the later response latency than was reported here when a 1-millisecond stimulation pulse was used with indwelling electrodes.

The R1 relationship found here between response amplitude and stimulation level has not been reported in animals.[5] Perhaps response amplitude and its variation is reduced by anesthesia in animals. Our study also differed in the effects of the respiratory cycle: the latency of the contralateral R1 was reduced during inhalation, and the frequency of R2 was greater during inhalation. In cats, the opposite was the case; R1 was enhanced during exhalation.[14] Additional physiologic studies are needed to assess these differences.

The increases in R1 response amplitude with increasing stimulation level support the conclusion that this was due to stimulation of afferent fibers in the internal branch rather than due to stimulation of 1a afferents in the external branch producing an H reflex, which is usually abolished with increasing levels of stimulation.[15] Further, in this study, the frequency of R1 responses was greater during muscle activity than at rest. When neurons in the motor neuron pool are activated, a priming effect results, and afferent input to the motor neuron pool is more

likely to result in a full response. This consequence of motor activity has been noted in other late responses.[16] Because the latency and the amplitude were variable between responses at the same stimulation level (Fig 3), the presumed pathway is not likely to be monosynaptic. Response variability is usually greater in reflexes with pathways involving several synapses.[17]

The R2 was a bilaterally occurring response, greater in amplitude on the contralateral side, appearing simultaneously on both sides at about 65 to 70 milliseconds and usually lasting between 19 and 45 milliseconds. The long duration of this response suggests a polysynaptic pathway. Furthermore, increased activity reduced the latency of R2 and increased the amplitude of R2; this pattern is typical of a polysynaptic response. In contrast to R1, however, R2 was reduced in frequency of occurrence and tended to decrease in duration with muscle activation. The fact that increased activation of the motor neuron pool decreased this response suggests that some inhibitory interneurons may have been triggered by the muscle activity that modified R2 responses but did not interfere with R1. Little is known about inhibitory interneurons in the cranial nuclei and the nucleus ambiguus in particular, although their role has been well studied in spinal circuits.[16]

Given the differences in the R1 and R2 characteristics, the neurophysiologic bases of R1 and R2 are most likely not the same. The R1 response was unilateral and brief, while R2 was bilateral, occurred simultaneously on the two sides, and was prolonged. Because the vocal fold movements observed during stimulation were bilateral and symmetric, the R2 component was most likely that responsible for vocal fold adduction, and not the R1. The R2 response, then, is more likely to involve the same pathway as the laryngeal component of the cough reflex in humans, although further study is needed to determine whether R2 responds to the same physiologic conditions that are known to modify coughing.[4,18]

The characteristics of the R1 and R2 responses in this study are similar to those of the blink reflex.[19] The blink reflex can be elicited by electrical stimulation of the supraorbital branch of the trigeminal nerve and is composed of both an early ipsilateral response at 10 milliseconds and a late bilateral response at 40 milliseconds in the orbicularis oculi. Although these responses are more rapid than the adductor R1 and R2 responses, this difference can be explained by the greater length of the laryngeal nerves. The blink reflex has been found clinically useful in electrodiagnosis for assessing the integrity of the afferent and efferent nerves and brain stem functions in various forms of neurologic disease.[20] The R1 and R2 laryngeal responses studied here have potential for a similar role in neurolaryngology for assisting with the differential diagnosis of patients' neurologic disorders.

ACKNOWLEDGMENTS — The authors thank Mark Hallett, MD, and Erich Luschei, PhD, for valuable suggestions regarding the interpretation of the data.

REFERENCES

1. Kirchner JA. Pressman and Kelemen's Physiology of the larynx. Rochester, Minn: American Academy of Ophthalmology and Otolaryngology, 1970.

2. Murakami Y, Kirchner JA. Mechanical and physiological properties of reflex laryngeal closure. Ann Otol Rhinol Laryngol 1972;81:59-71.

3. Wyke BD, Kirchner JA. Neurology of the larynx. In: Harrison DFN, ed. Scientific foundations of otolaryngology. Chicago, Ill: Heinemann Medical Books, 1976:546-74.

4. Karlsson JA. Airway anaesthesia and the cough reflex. Bull Eur Physiopathol Respir 1987;23:29s-36s.

5. Suzuki M, Sasaki CT. Laryngeal spasm: a neurophysiologic redefinition. Ann Otol Rhinol Laryngol 1977;86:150-7.

6. Sasaki CT, Suzuki M. Laryngeal reflexes in cat, dog and man. Arch Otolaryngol 1976;102:400-2.

7. Suzuki M, Sasaki CT. Effect of various sensory stimuli on reflex laryngeal adduction. Ann Otol Rhinol Laryngol 1977;86:30-6.

8. Yamagiwa M. Interaction of upper airway reflexes on protective laryngeal closure. Auris Nasus Larynx 1980;7:51-9.

9. Suzuki M. Laryngeal reflexes. In: Hirano M, Kirchner JA, Bless DM, eds. Neurolaryngology: recent advances. Boston, Mass: College-Hill, 1987:142-55.

10. Thumfart WF. Electromyography of the larynx and related technics. Acta Otorhinolaryngol Belg 1986;40:358-76.

11. Martensson A. Reflex responses and recurrent discharges evoked by stimulation of laryngeal nerves. Acta Physiol Scand 1963;57:248-69.

12. Hirano M, Ohala J. Use of hooked-wire electrodes for electromyography of the intrinsic laryngeal muscles. J Speech Hear Res 1969;12:362-73.

13. Loeb GE, Gans C. Electromyography for experimentalists. Chicago, Ill: The University of Chicago, 1986.

14. Ikari T, Sasaki CT. Glottic closure reflex: control mechanisms. Ann Otol Rhinol Laryngol 1980;89:220-4.

15. Day BL, Marsden CD, Obeso JA. Reciprocal inhibition between the muscles of the human forearm. J Physiol (Lond) 1984;349:519-34.

16. Rothwell JC. Control of human voluntary movement. Rockville, Md: Aspen Publishers, 1987:126.

17. Trontelj JV. A study of the F response by single fibre electromyography. In: Desmedt FE, ed. New developments in electromyography and clinical neurophysiology. Vol 3. Basel, Switzerland: Karger, 1973:318-22.

18. Karlsson JA, Lanner AS, Persson CG. Airway opioid receptors mediate inhibition of cough and reflex bronchoconstriction in guinea pigs. J Pharmacol Exp Ther 1990;252:863-8.

19. Shahani BT, Phil D, Young RR. Human orbicularis oculi reflexes. Neurology 1972;22:149-54.

20. Kimura J. Electrodiagnosis in diseases of nerve and muscle: principles and practice. Philadelphia, Pa: FA Davis, 1983:323.

ELECTROPHYSIOLOGIC INVESTIGATION OF LOWER CRANIAL NERVE DISEASES BY MEANS OF MAGNETICALLY STIMULATED NEUROMYOGRAPHY OF THE LARYNX

WALTER F. THUMFART, MD
COLOGNE, GERMANY
PATRICK ZOROWKA, MD
MAINZ, GERMANY
CLAUS POTOTSCHNIG, MD
COLOGNE, GERMANY
HANS E. ECKEL, MD
COLOGNE, GERMANY

Zoom endoscopic electromyography of the larynx, as introduced in 1979, has contributed greatly to the diagnosis of lower cranial nerve palsies, but in the early stage of a vagus nerve disorder one cannot investigate the nerve conduction from the brain stem to the laryngeal muscles with electrical stimulation. As with the early diagnosis of facial nerve palsies, up to now the intracranial part of the motoric brain nerves could not be stimulated directly. With a new magnetic coil device (Novametrix, Magstim 200) this intracranial stimulation is easily possible in the awake patient with painless magnetic stimuli that induce a muscle action potential into the laryngeal muscles. Hence, an immediate diagnosis is possible. Two coils with mean diameters of 8.5 or 3 cm were used. The stimulator delivered current pulses of peak amplitude up to 5,000 A with rise times of 140 microseconds and 65 microseconds, respectively, that generated peak fields of up to 2 T. In a healthy population, cisternal stimulation of the vagus nerve leads to a muscular response in the vocal muscle after 4 to 6.6 milliseconds (mean 5 milliseconds). Cortical stimulation leads to such a response after 9.5 to 12 milliseconds. Potentials in healthy individuals have been shown to be very uniform. Stimulation in recurrent nerve palsies may show prolongation of these latencies up to 30 milliseconds. The method is limited by the fact that complete neural blocks cannot be overcome by proximal stimulation. We have applied magnetic stimulation to 190 patients with different disorders of the vagus nerve. It allows a differential diagnosis of palsies immediately after their onset, and is thus the first method to make such an early investigation possible.

KEY WORDS — laryngeal electromyography, lower cranial nerves, magnetic stimulation, neuromyography, palsy, recurrent laryngeal nerve, vagus nerve.

INTRODUCTION

Vital dysfunctions of breathing and swallowing, dysphonia, and speech disorders show up as symptoms of neuromuscular diseases of the larynx. In order to function properly, the larynx must achieve near-perfect synchronization of its intricate sensory and motor capabilities. In addition, the pharyngeal muscles and even the neck and thoracic muscles are often involved. A variety of neurologic diseases appear with central or peripheral impairment of coordination of these muscles or complete loss of function, causing pathologic movements or a direct mechanical failure of the caudal cranial nerves and their coordinated muscles.

Alterations in voice, globus hystericus, and dysphagia are early or even the only symptoms of neurologic or neuromuscular diseases of the oropharyngeal and laryngeal structures. Saccadic movements of the vocal cords causing a poor or unstable voice may be the first sign of multiple sclerosis. Bulbar paralysis, Parkinson's disease, brain tumors, and multiple sclerosis often show up as diminished amplitude and disturbance of vocal cord vibration during stroboscopy or as paradoxical movements of the vocal cords.

Another early symptom of these diseases may be a deglutition disturbance that later results in increased muscle tension, loss of coordination, or incongruity of function leading to disturbances of swallowing or aspiration.

We need diagnostic tools to determine the site and degree of the neuromuscular lesion, and classification of the type of nerve damage according to Seddon.[1] Diagnostic tools such as electromyography (EMG) and neuromyography (NMG) are necessary to solve this problem, but are difficult to use in the hidden muscles of the larynx and pharynx.

The zoom endoscopic application of tiny copper wire electrodes into the laryngeal and pharyngeal muscles of the awake patient as introduced by Thumfart et al[2-4] permits EMG and NMG of the laryngeal and pharyngeal structures with voluntary movements by the patient as well as electrical stimulation of the vagus nerve in the neck. This should result in an early differentiation of a vagus nerve palsy into degenerative causes such as axonotmesis or neurotmesis and

From the Department of Otorhinolaryngology, University of Cologne, Cologne, Germany. Supported by the German Research Society (DFG TH 266).

Presented at the meeting of the American Laryngological Association, Waikoloa, Hawaii, May 4-5, 1991.

REPRINTS — Walter F. Thumfart, MD, University HNO-Klinik, Joseph-Stelzmann-Strasse 9, D-5000 Cologne 41, Germany.

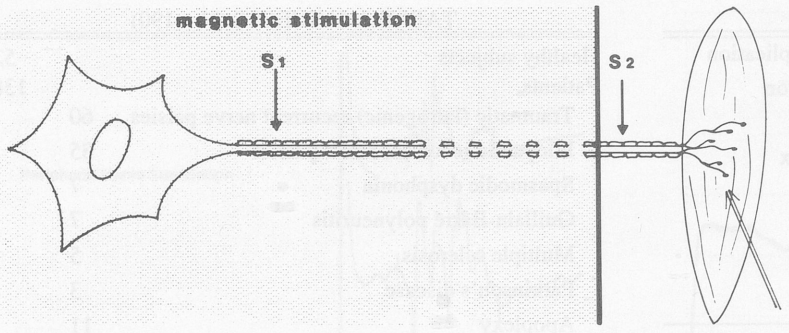

Fig 1. Schematic drawing of magnetic stimulation of lower cranial nerves in comparison to conventional electrodiagnostic methods. S1 — stimulation site 1 (intracranial), S2 — stimulation site 2 (extracranial).

causes with a better prognosis, such as neurapraxia with demyelinization without axon degeneration. In neurologic diagnosis with NMG, direct supramaximal stimulation of the nerve proximal and distal to the site of its lesion shows changes in the latency configuration of the muscle response. The proximal stimulation of motoric brain nerves has been a specific problem of cranial nerve diagnosis, since the area of damage of the cranial nerves mainly lies intracranially or at the skull base and is not accessible for electrical stimulation. This problem now seems to have been solved for routine diagnosis by magnetic stimulation, first described by Barker et al[5-7] in 1985. It allows an examination of the lower cranial nerves in the awake patient by stimulation of the proximal nerve endings across the lesion.

MATERIALS AND METHODS

Magnetic stimulation (Novametrix, Magstim 200) permits an examination of the facial nerve[8,9] and other lower cranial nerves in the conscious patient in routine diagnosis by stimulation of the proximal nerve ending across the lesion (Fig 1).

We used two coils with mean diameters of 8.5 or 3 cm consisting of 20 windings that delivered current pulses of peak amplitude up to 5,000 A with rise times of 140 microseconds (μs) and 65 μs, which generated peak fields of up to 2 T (Fig 2).

The magnetic impulse, because of its rapidly changing intensity, induces an electrical current in the surrounding tissue and liquids that reaches approximately 25 mA/cm^2 with its current density in an annulus underneath the coil, and a flow of direction contrary to the coil current flow.

Depending on the position of the coil, the flow of current stimulates a nerve activity potential underneath the coil and leads to nerve stimulation and a muscular response.

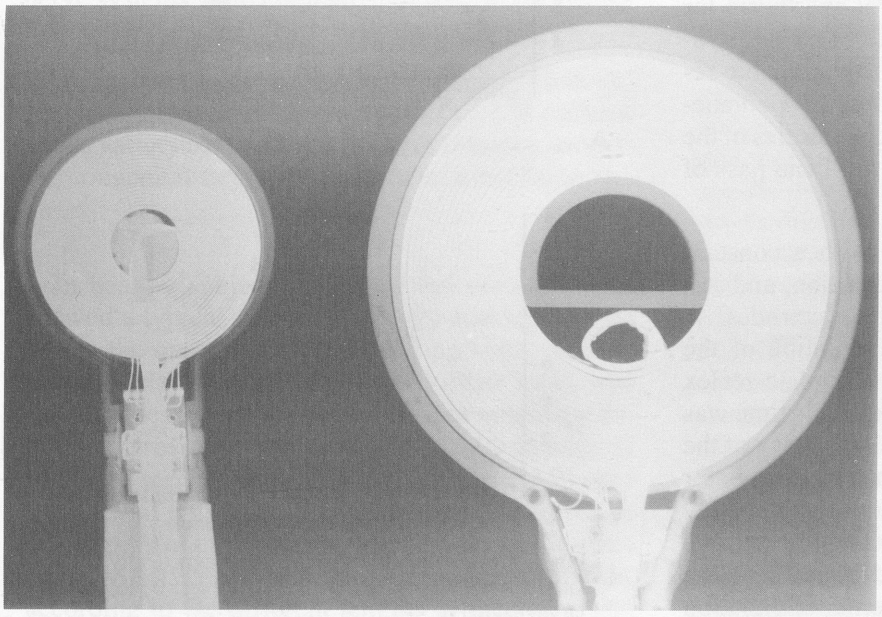

Fig 2. Coil geometries of different types in radiography technique.

TABLE 1. METHODS

Endolaryngeal and/or transcutaneous electrode application
Bipolar hooked-wire or needle electrodes in position
Spontaneous and voluntary electromyography
Electrically stimulated neuromyography and reflex myography
Magnetically stimulated neuromyography
Cortical
Cisternal
Peripheral

TABLE 2. SUBJECTS (N = 190)

Healthy subjects		52
Patients		138
Traumatic (iatrogenic) recurrent nerve palsies	60	
Idiopathic recurrent nerve palsies	35	
Spasmodic dysphonia	7	
Guillain-Barré polyneuritis	7	
Multiple sclerosis	5	
Parkinson's disease	3	
Apoplexy	11	
Congenital laryngeal palsies	10	

Time-varying magnetic fields pass through high-resistance structures such as the skin and skull without attenuation and induce electrical current flow proportional to the tissue conductibility. Thus, magnetic stimulation leads to a depolarization of the deep-seated neural structures that is completely painless, in contrast to the supramaximal stimulation in NMG or reflex myography. Nerve stimulation of the intracranial portion of the lower cranial nerves can be performed from the contralateral cortex, the ipsilateral vertex, and the ipsilateral skull base area for cisternal stimulation, as well as along the neck for vagus nerve stimulation.

The bipolar hooked wire electrodes for EMG recording are placed transorally after surface spray anesthesia in the awake patient under zoom endoscopic control.

The special electrode-holding forceps is immediately withdrawn after application of the electrodes to the vocal muscle or the posterior cricoarytenoid muscle. These electrodes are also suitable for recording of the palatal muscles, lingual muscles, and cricopharyngeal muscle. In less cooperative patients, bipolar needle electrodes are applied transcutaneously or inserted transorally under general anesthesia for successive measurements. A Tönnies TESY II two-channel electromyograph with a programmable recording system was used for recording of spontaneous and voluntary activity in the target muscles of the lower cranial nerves with an amplifier band pass of 20 Hz to 10 kHz.

Standard NMG was performed with a constant current of up to 20 mA at 200-μs duration, and at a rate of 2 Hz, with bipolar surface electrodes. A similar technique was used for stimulation of the upper laryngeal nerve in order to stimulate reflex myographic potentials. The NMG analysis time was 5 milliseconds (ms) per unit with a 1-ms delay of the stimulus. A Novametrix Magstim 200 stimulator generated a brief magnetic field with approximately 2 T and maximal output after 140 μs underneath the coil (center diameter 8.5 or 3 cm, depending on the coil type). Cortical as well as cisternal stimulation was employed with a stimulus intensity of 70% of the maximal output. The amplitude units are 1 mV per unit for EMG and 500 μV per unit for magnetically stimulated NMG.

With the electrodes held in position, magnetically stimulated NMG was performed after EMG recording (Table 1). For cortical stimulation at the vertex, the coil center (center diameter 8.5 cm) is positioned 4 cm below the vertex in relation to the jugular foramen. The coil is then moved down to approximately 2 cm behind and 6 cm above the external auditory canal for stimulation of the nerves at their cisternal part. Direct peripheral stimulation of the vagus nerve was done with the smaller coil (center diameter 3 cm). Latency, peak-to-peak amplitude, response duration, and peak integral were determined with the use of cursors. All responses were

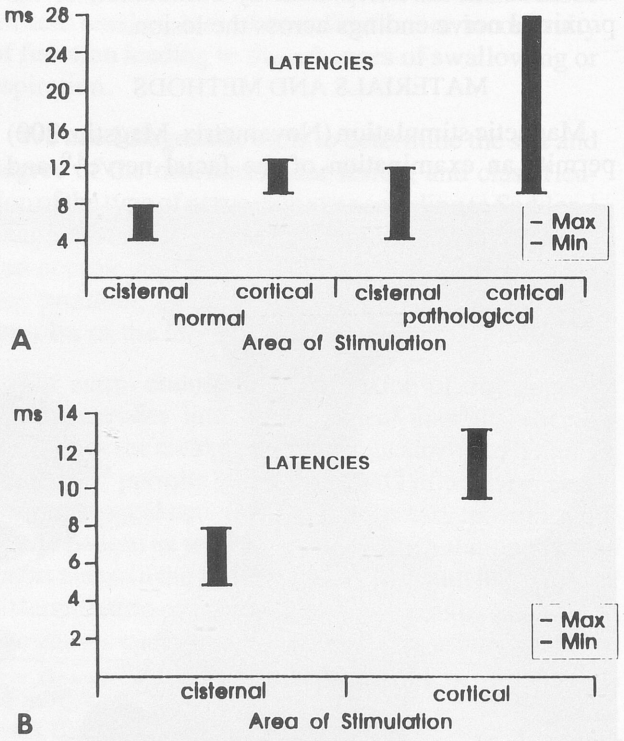

Fig 3. Mean values of latencies for magnetically stimulated neuromyography. A) Cranial nerves. B) Recurrent laryngeal nerve.

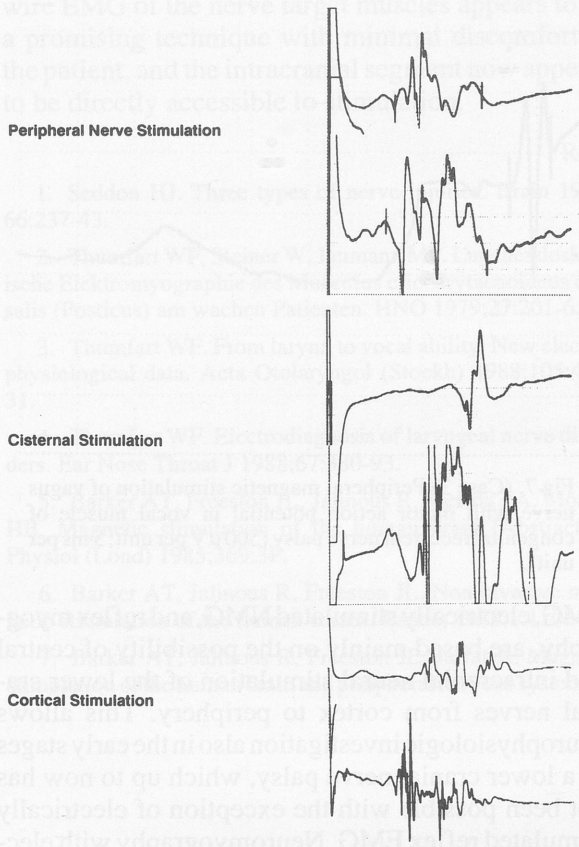

Fig 4. Magnetically stimulated neuromyograms following peripheral, cisternal, and cortical stimulation of motor action potential in vocal muscle (500 μV per unit; 1 to 2 ms per unit; 2 to 5 ms per unit, respectively).

recorded at least twice in order to observe reproducibility or were analyzed by an averager. (No averaging was necessary if there was a clear response after two samples.) The values for healthy and disturbed nerve systems were compared, as well as the results of electrical and magnetic stimulation.

The subjects were 52 healthy subjects with larynges with intact innervation, as well as 138 patients with a variety of lower cranial nerve diseases, including congenital laryngeal palsy in infants (Table 2).

RESULTS

In healthy subjects, EMG of the vocal muscles showed a typical voluntary activity starting 300 ms before the onset of voice and during voice production. Spontaneous activity, on the other hand, was found in degenerative palsies without voluntary activity, as previously reported. Electrically stimulated NMG induced a muscle action potential (MAP) after a latency of 6 to 8 ms. Electrically stimulated reflex myography of the superior laryngeal nerve elicited a reflex MAP after 22 to 26 ms, depending on the side, according to the different lengths of the vagus and recurrent laryngeal nerves.

Fig 5. Cortical magnetically stimulated neuromyogram in case of neurapraxia (500 μV per unit; 5 ms per unit).

Cortical magnetic stimulation in a healthy population led to a muscle response after 9.5 to 12 ms (SD 1.4; mean 10.8 ms). Cisternal stimulation of the vagus nerve caused a response in the vocal muscle after 4 to 6.6 ms (SD 0.7; mean 5 ms; Fig 3). Magnetic stimulation in the neck produced a MAP that was not statistically different from that obtained electrically (Fig 4). Otherwise, we found a small difference in amplitude and integral of the MAPs induced by opposite surfaces of the coil during cisternal and peripheral stimulation (depending on the flux direction). The main difference in amplitude and integral of the MAPs induced by opposite surfaces of the coil was in cortical stimulation, especially stimulation of the contralateral cortex.

The latency was prolonged up to two or three times as compared to the healthy sides in cases of neurapraxia (Fig 5). In cases of degenerative palsies, either a complete interruption or a difference between distal and proximal stimulation of 25 to 30 ms in latency was found. The values for latency, amplitude, response duration, and peak integral were also compared after cortical, cisternal, and peripheral stimulation, and a good correlation was found between the reduced response, the prolonged latency, and splitting of the MAP with the type of lesion. The difference in amplitude of proximal and distal stimulation varied from 2 to 1 in healthy subjects to 10 to 1 in cases of neurapraxia and 30 to 1 in cases of axonotmesis, if stimulation could be performed. During follow-up of neurapraxic lesions, even 3 to 4 months after complete regeneration a prolonged latency was found as compared to the healthy side, as well as diminished potentials or even the impossibility of stimulation at the cisternal portion, correlating with a

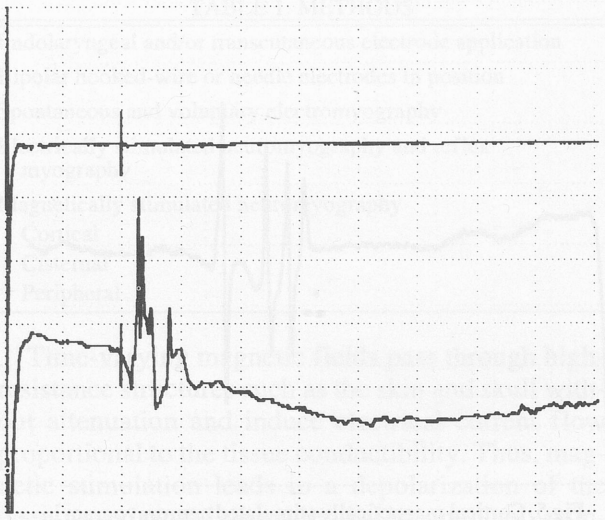

Fig 6. (Case 1) Cisternal magnetic stimulation in central vagus nerve palsy (500 μV per unit; 5 ms per unit).

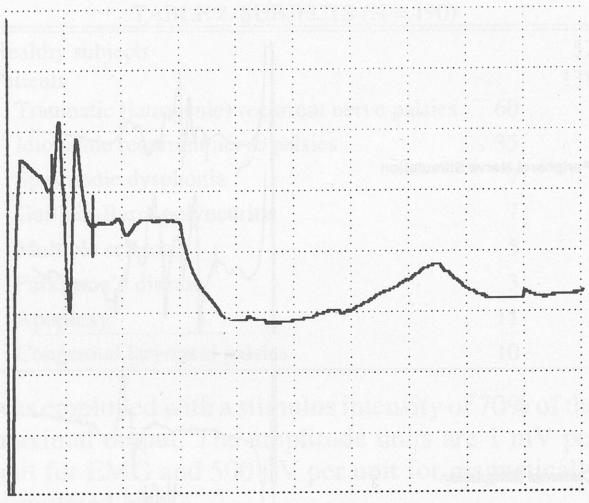

Fig 7. (Case 3) Peripheral magnetic stimulation of vagus nerve with motor action potential in vocal muscle of congenital recurrent nerve palsy (500 μV per unit; 5 ms per unit).

less excitable or nonexcitable cortical portion.

CASE REPORTS

Case 1. After long-term assisted respiration for polyneuritis, a 46-year-old woman developed recurrent laryngeal nerve palsy on the right side. Electromyography revealed a diminished voluntary activity. Cisternal magnetic stimulation resulted in a prolongation of latency up to 8 ms and a diminished amplitude of MAP (Fig 6). Contralateral cortical stimulation induced a MAP of 26 ms latency. Therefore, a combined central and peripheral vagus nerve lesion was diagnosed.

Case 2. Six weeks after thyroidectomy in a 32-year-old woman, EMG revealed single action potential voluntary activity in a unilateral recurrent nerve palsy. Cisternal magnetic stimulation resulted in a polyphasic MAP after 8 ms latency. A neurapraxic nerve lesion with a good prognosis was diagnosed, and normal function of the vocal cord was regained 4 weeks later.

Case 3. In a 10-day-old infant, inspiratory and expiratory stridor had led to intubation and microlaryngoscopic examination. This revealed a unilateral vocal cord palsy. Cortical magnetic stimulation led to no response. Cisternal and peripheral stimulation induced a MAP after 6.2 and 4 ms, respectively (Fig 7). After reduction of the general anesthesia, some voluntary activity potentials were recorded. Therefore, a premature nuclear area was diagnosed, with an intact peripheral vagus nerve system.

DISCUSSION

The advantages of magnetic stimulation, as compared to well-known electrophysiologic tools such as EMG, electrically stimulated NMG, and reflex myography, are based mainly on the possibility of central and intracranial neural stimulation of the lower cranial nerves from cortex to periphery. This allows neurophysiologic investigation also in the early stages of a lower cranial nerve palsy, which up to now has not been possible with the exception of electrically stimulated reflex EMG. Neuromyography with electrical stimuli only shows reliable results at least 6 to 8 days after the onset of a proximal palsy because of a time decay for wallerian degeneration. In contrast, cortical and especially cisternal stimulation of the lower cranial nerves leads to reliable results immediately after the onset of palsy, with the exception of a complete neurapraxic block over a larger distance. The lack of attenuation of an electrical field induced by pulsed magnetic fields results in painless stimulation,[10] which allows stimulation of deep-seated intracranial structures that were not accessible in the awake unanesthetized patient up to the present.

On the other hand, magnetic stimulation is not only feasible in the awake patient, but also in the unconscious or anesthetized patient, and hence is suitable for noncooperative patients and children. Because contact is not required, skin preparation is unnecessary. In addition, intracranial and extracranial neural systems are accessible with the same magnetic stimulation technique and a variety of coil geometries only.[11]

A present disadvantage of magnetic stimulation is that the site of stimulation of the lower cranial nerves is not readily defined, but as magnetic stimulus increases, there is less dependence on the exact electrode position relative to underlying neural structures. Magnetic stimulation of these lower cranial

nerves with a combination of transoral bipolar hooked wire EMG of the nerve target muscles appears to be a promising technique with minimal discomfort to the patient, and the intracranial segment now appears to be directly accessible to stimulation.

Magnetic stimulation should not be used in patients with epilepsy or after cranial surgery with magnetic material remaining (ie, clips), but it shows no apparent problems or dangers with other subjects.[7,8]

REFERENCES

1. Seddon HJ. Three types of nerve injuries. Brain 1943; 66:237-43.

2. Thumfart WF, Steiner W, Jaumann MP. Lupenendoskopische Elektromyographie des Musculus cricoarytaenoideus dorsalis (Posticus) am wachen Patienten. HNO 1979;27:201-6.

3. Thumfart WF. From larynx to vocal ability. New electrophysiological data. Acta Otolaryngol (Stockh) 1988;105:425-31.

4. Thumfart WF. Electrodiagnosis of laryngeal nerve disorders. Ear Nose Throat J 1988;67:380-93.

5. Barker AT, Freeston JL, Jalinous R, Merton PA, Morton HB. Magnetic stimulation of the human brain [Abstract]. J Physiol (Lond) 1985;369:3P.

6. Barker AT, Jalinous R, Freeston JL. Non invasive magnetic stimulation of the human cortex. Lancet 1985;1:1106-7.

7. Barker AT, Jalinous R, Freeston JL, Jarrat A. Magnetic stimulation of the human brain and peripheral nervous system: an introduction and the results of an initial clinical evaluation. Neurosurgery 1987;20:100-9.

8. Pototschnig C, Stennert E. Magnetic stimulation: new possibilities in the assessment of facial nerve dysfunction. In: Castro D, ed. The facial nerve. Amsterdam, the Netherlands: Kugler & Ghedini, 1990:183-9.

9. Thumfart WF, Stennert E, Pototschnig C. Magnetic stimulation: new possibilities in the assessment of facial nerve dysfunction. In: Haid CT, ed. Vestibular diagnosis and neuro-otosurgical management of the skull base. Graefelfing, Germany: Demeter, 1991.

10. Kartush JM, Bouchard KR, Graham MD, Linstrom C. Magnetic stimulation of the facial nerve. Am J Otol 1990;10:14-9.

11. Seki Y, Krain L, Yamada T, Kimura J. Transcranial magnetic stimulation of the facial nerve: recording technique and estimation of the stimulated site. Neurosurgery 1990;26:286-90.

THE THREE BELLIES OF THE CANINE CRICOTHYROID MUSC

LAUREN S. ZARETSKY, MD
LOS ANGELES, CALIFORNIA

IRA SANDERS, MD
NEW YORK, NEW YORK

The cricothyroid muscle is capable of multiple functions, including vocal cord elongation and adduction. In addition, the crico can lengthen the glottis as well as provide posture to the cricothyroid joint. The purpose of the present study is to demonstrate t many functional capabilities of the cricothyroid are a reflection of the existence of separate bellies within the muscle. Microdissec vealed three distinct muscle bellies within the cricothyroid: rectus, oblique, and horizontal. These differ in fiber orientation (rect oblique 48°, horizontal 7°) and are separated by fascial planes. Histochemistry showed that these three bellies are composed of d percentages of slow twitch fibers (rectus 31.3%, oblique 43.3%, horizontal 39.6%). Finally, electromyography demonstrated diff in the electrical activity patterns of the three bellies. It is concluded that the cricothyroid muscle is composed of three distinct muscl that probably play separate roles in the complex function of this muscle.

KEY WORDS — anatomy, cricothyroid muscle, muscle belly, muscle fiber typing, neuromuscular compartments, phonati

INTRODUCTION

In the research plan of the National Institute on Deafness and Other Communication Disorders, the first recommendation for major research opportunities in voice reads as follows: "Evaluate the compartmentalization of the laryngeal muscles with regard to histochemistry and motor unit organization during different gestures such as inhalation, exhalation, effort closure, phonation and swallowing."[1] Using the dog as an experimental model, recent work has demonstrated that the posterior cricoarytenoid muscle is compartmentalized into three bellies, each of which appears capable of some independent function.[2,3] Similarly, the thyroarytenoid muscle can be separated into two distinct compartments.[4]

In this study the cricothyroid muscle (CT) will be examined for evidence of functionally distinct compartments. The CT is a complex muscle that spans a joint with two planes of motion and is capable of multiple functions.[5-9] Studies have suggested that subareas within the muscle may have discrete functions.[10-13] This and other assumptions regarding CT activity are controversial owing to conflicting experimental evidence. Initially, all relevant literature will be reviewed regarding CT anatomy and physiology. Then anatomic, histochemical, and electromyography (EMG) evidence for the existence of multiple functional subunits within the CT will be presented.

Functional Anatomy. In the 16th century Andreas Vesalius[14] described the CT as two separate muscles. The terms cricothyreoideus rectus and cricothyreoideus obliquus were introduced by Jacob Henle in 1873.[15,16] Luschka added the term anticus to distinguish them from the cricothyreoideus posticus, known today as the posterior cricoarytenoid muscle.[16,17] The notion of two muscles was so placed with the current concept of a single CT posed of the rectus and oblique bellies.[6-10,18- rectus extends from the anterior ring, close midline, to the inferior border of the thyroid lage, with the inferior thyroid tubercle as a l margin. The oblique originates more latera the cricoid edge and inserts into the inferior th border, extending to the inferior horn.[16,21] In bellies of the CT the muscle fibers course c uously from origin to insertion.[26,27] Anomalies CT as well as an internal division of the muscl been described.[16,20,25,28]

In 1841, Longet described the innervation CT by the superior laryngeal nerve, later conf by Onodi, Lemere, and many others.[21,29-36] In Hooper demonstrated that electrical stimulat the superior laryngeal nerve caused the cricoi tilage to move.[16,37-39] In 1944, Tschiassny[16] dif tiated the functions of the rectus and obliq electrically stimulating them individually. He that the rectus caused upward movement of th coid arch whereas the oblique resulted in bot ward and backward displacement. Arnold[2] Mayet and Mundnich[20] also referred to specif tions of the rectus and oblique with similar co sions. The current consensus is that contract the CT causes elevation of the anterior cricoi by rotation at the cricothyroid joint. A secon tion of the CT is thought to be ventrodorsal s of the thyroid cartilage over the cricoid,[5,7,9 though a minority dispute this.[20,40]

The actions of the CT have significant effe the vocal cords. These effects vary depending action of the remaining intrinsic laryngeal mu Both rotation and posterior displacement of th

From the Doctor Eugene Grabschied Center for Voice, Department of Otolaryngology, Mount Sinai School of Medicine, New York, New Y Zaretsky is currently at the Department of Otolaryngology, University of Southern California Medical Center, Los Angeles, California. This st performed in accordance with the PHS Policy on Humane Care and Use of Laboratory Animals, the NIH *Guide for the Care and Use of La Animals*, and the Animal Welfare Act (7 U.S.C. et seq.); the animal use protocol was approved by the Institutional Animal Care and Use Co (IACUC) of Mount Sinai Medical Center.

Presented at the meeting of the American Laryngological Association, Waikoloa, Hawaii, May 4-5, 1991.

coid elongate the vocal cords by increasing the distance between the arytenoids and the thyroid cartilage.[9,18,19,41] Since the arytenoids are fixed to the cricoid cartilage by the posterior cricoarytenoid muscle and articular ligaments, this action both adducts and tenses the vocal cords in addition to increasing the anteroposterior diameter of the glottis.[19]

Phonation. During phonation the lengthening action of the CT tenses and thins the vocal folds. The decrease in effective vibrating mass causes the frequency of phonation to rise.[42] Ferrein first discovered this in 1741 by placing a finger in the cricothyroid space and noting that the gap narrowed with increased pitch.[6,43] Fink, in his book *The Human Larynx*,[6] credits Möller and Fischer[44] with providing the first radiographic proof in 1904 that closure of the cricothyroid gap is associated with an increase in phonatory tone. Sonninen[45] documented this in 1954 by using lateral radiographs. Laryngoscopic proof was provided by Farnsworth[46] in 1940. In the 1960s, increased electrical activity in the CT with increasing pitch was documented by EMG.[47-49] Negus[18] in 1949 and Arnold[21] in 1961 claimed that the thyroarytenoid and CT are in an agonist-antagonist relationship during phonation, one being an internal tensor, and the other an external tensor. This concept has been adopted by numerous other authors.[6,9,19,42]

The possibility of distinct functional roles in the two bellies during phonation was first postulated by Fink and Demarest.[10] The rectus would cause rotation at the cricothyroid joint, while the oblique would cause ventrodorsal sliding. Indeed, the ventrodorsal sliding action of the CT has been documented by lateral neck radiographs in trained singers, while being absent in nonsingers.[10] More recently it has been proposed that the oblique and rectus may have different actions concerning word accenting and sentence intonation.[50,51] Unfortunately, there is no controlled EMG experiment in the human that might clarify the roles of the two bellies during phonation.

Respiration. The CT also varies the anteroposterior dimension of the larynx during respiration. Simultaneous contractions of the posterior cricoarytenoid muscle and the CT make the glottic airway slightly larger than during posterior cricoarytenoid contraction alone.[12,19,52,53] However, in a recent study Woodson et al[54] did not observe this effect under normal conditions. Numerous EMG studies of the CT have been performed.[6,10-13,21,47,48,54-66] It has been shown that CT activity increases with voice frequency, hypercapnia, negative airway pressure, and lung deflation.[47,49,57,63] Some studies have presented evidence for CT activity primarily during inspiration, others for activity mainly in expiration, and still others for activity throughout the respiratory cycle. As a result the respiratory function of the CT is not well understood.

Previous EMG studies did not seek to record from specific locations within the CT, except for that of Rudomin.[11] In his study on respiratory activity of the CT in cats, he found no differences between the rectus and oblique, although this was not a primary goal of his study. On the other hand, he did find evidence for the respiratory specialization of motor units. Suzuki et al[12] provided data supporting the presence of specialized inspiratory and expiratory motor units, although they did not specify the exact location of the EMG electrodes. Mathew et al[13] investigated this point further, by using EMG in conjunction with the study of individual axon action potentials. This study revealed that while motor unit recordings generally reflected the behavior of the whole CT, there was some suggestion of specialization by differences found in thresholds of recruitment. Therefore, to date, the evidence for distinct function of the cricothyroid bellies during respiration is inconclusive.

Adduction. The CT is also an adductor of the vocal cords. As a result of its action as an external tensor of the vocal cords, the vocal processes of the arytenoids are rotated inward, resulting in adduction.[18,19,21,67] This action has been supported by experiments in which the CT is electrically stimulated and vocal cord motion is recorded.[30,68-71] Vocal cord adduction caused by the CT may not be important during normal laryngeal activity, but may become so during recurrent laryngeal nerve paralysis. For example, in unilateral vocal cord paralysis, a lesion of the superior laryngeal nerve causes the vocal cord to move from a paramedian to an intermediate position.[72] The ameliorating effect of sectioning the superior laryngeal nerve or removal of the CT on bilateral vocal cord paralysis was noted in the 1890s by Wagner and by Grossman.[73-75] Currently, it is considered that the CT is responsible for the paramedian position of the vocal cords after bilateral recurrent nerve paralysis,[30,67,68,72,76] and there is renewed interest in inducing CT paralysis to widen the glottic airway.[21,38,39,69,75,77] However, other data question the physiologic effect of CT contraction, and suggest that under normal conditions as well as following acute recurrent laryngeal nerve paralysis CT activity is insufficient to have an effect on vocal cord adduction.[54,55]

Posture. Finally, the CT is active in maintaining the orientation and patency of the upper airway by providing posture to the cricothyroid joint.[6,10] It has been shown that CT activity is affected by a variety of movements of the head, neck, and mouth; therefore, it is likely that the CT must continually adjust its level of function to maintain a consistent relationship between the thyroid and cricoid cartilages.[21] Further, there is controversy regarding which of the two cartilages forming this joint actually moves, and which, if either, is fixed.[5-7,16,40] As a result the activity of the CT in posture and stabilization of the respiratory axis is unknown.

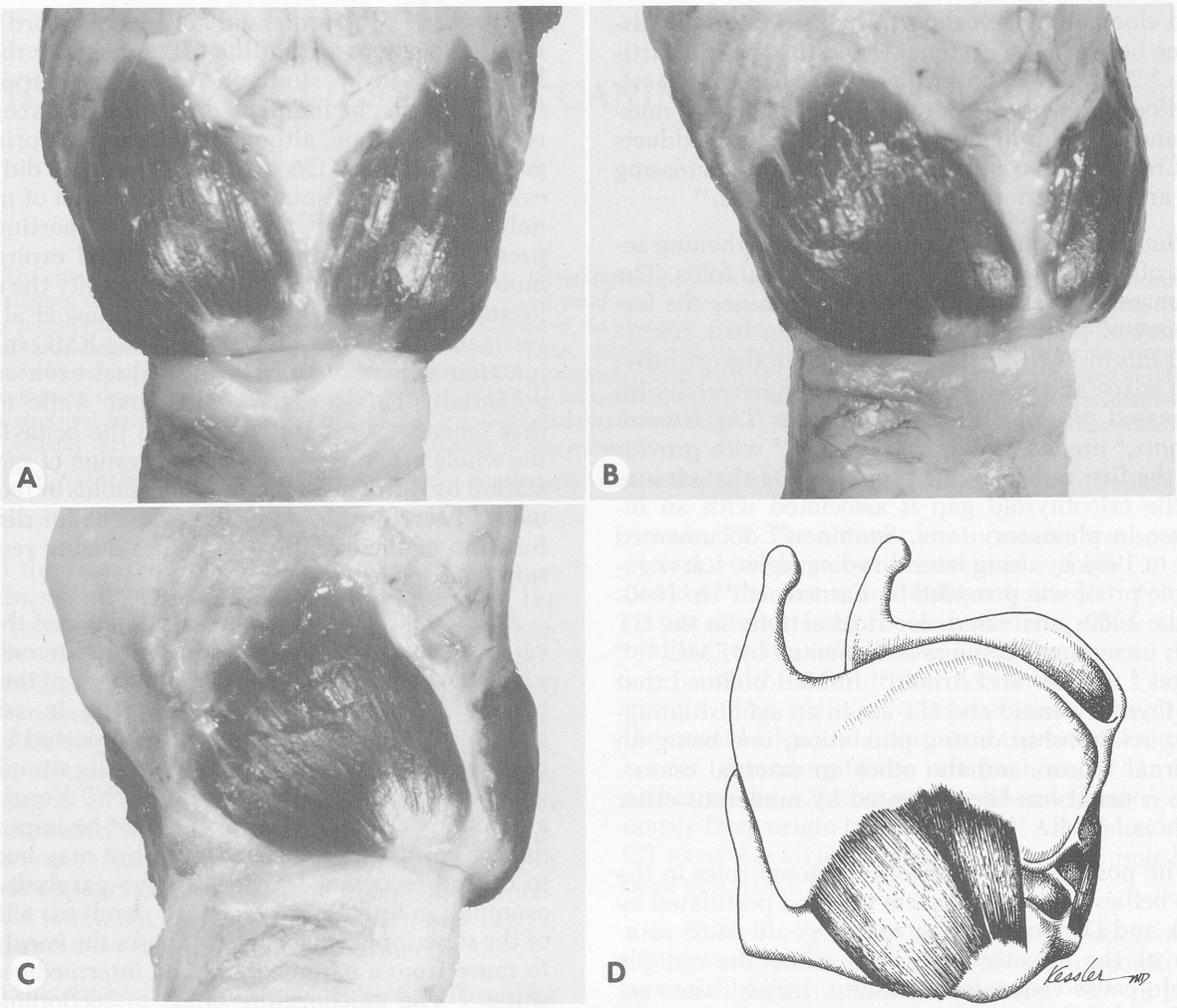

Fig 1. Views of cricothyroid muscle. Note origins and insertions of rectus and oblique, as well as 30° difference in their fiber orientation. A) Anterior. B) Oblique. C) Lateral. D) Schematic illustration.

It is apparent that the role of the CT during phonation, respiration, adduction, and posture is controversial. It is difficult to attribute these variations in function to a simple mechanism of control or to current concepts of anatomy. It is possible that instead the CT is composed of functional subunits. It was the purpose of this study to examine the evidence for distinct muscle bellies within the CT. Three approaches were used: gross anatomy, muscle fiber type histochemistry, and EMG.

METHODS

The dog was used as an experimental model because of its anatomic and functional similarity to humans and its previous extensive use in studies of laryngeal physiology.[30,32,40,60,70,78-80]

Gross Dissection. Laryngectomies were performed on eight male mongrel dogs weighing approximately 20 kg. In each dog, the CT was dissected by means of a binocular operating microscope. In three of the specimens dissected, detailed measurements were taken and drawings were made of the CT and its surrounding structures. Specifically, origins, insertions, fiber orientation and angles, and measurements of landmarks were carefully documented.

Histochemistry. The larynges of three male mongrel dogs were excised and immediately frozen in liquid nitrogen. The CT and cartilaginous attachments were removed en bloc from the larynx. The muscle was divided horizontally and placed on a mounting block, with care being taken to maintain orientation. By means of a cryostat, the specimens were cut into 10-μm horizontal sections 1 mm apart. The specimens were placed on chrome alum slides and stored at $-30°$C. The slides were stained for adenosine triphosphatase with pH 4.2 preincubation, as described by Guth and Samaha.[81] Acid preincubation results in dark-staining slow fibers and light-staining fast fibers. The slides were projected on an enlarger to 40 times normal size, and a map of the muscle was made. For analysis the CT was divided into six regions. Within each region, five sample populations, measuring 2 in^2 on the map, were manually counted for slow and fast fibers. Counting was done by the same individual for all specimens. Random checks were made by a sec-

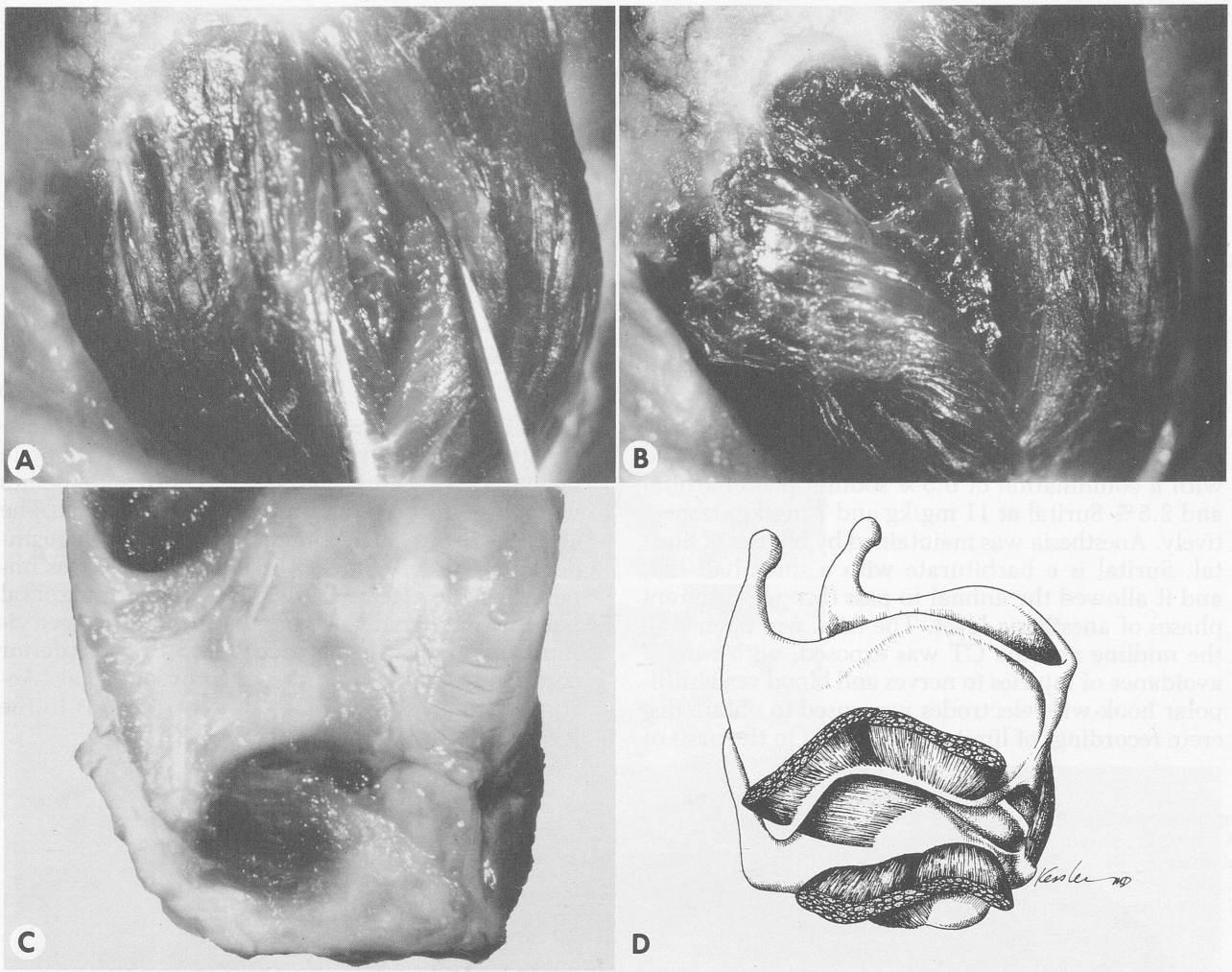

Fig 2. Dissection of cricothyroid muscle. A) Entering fascial plane between rectus and oblique, two bellies can be divided easily. Note nerve tissue seen between them. B) Oblique is retracted laterally. Again, nerve tissue is present. Evidently there is fascial plane that extends between superficial and deep portions of muscle. C) Horizontal belly. Note insertion and origin. Entire rectus and oblique have been removed to expose this belly. Horizontal belly is separated from oblique and rectus by well-defined fascial layer. Note transverse orientation of fibers. D) Schematic illustration of horizontal belly. Rectus and oblique have been divided and reflected away.

ond individual.

Additional specimens were processed for histologic analysis. The thyroarytenoid, a known fast muscle composed of 95% fast twitch fibers, was used as a control during each staining process.[82]

Electromyography. Five male mongrel dogs weigh-

TABLE 1. PERCENTAGE OF SLOW FIBERS BY REGION

Region	*Specimen Number* 1	2	3
Rectus			
Superficial (region 1)	36.3% (n = 399)	32.2% (n = 513)	38.8% (n = 276)
Middle (region 2)	38% (n = 532)	32.2% (n = 480)	32% (n = 311)
Deep (region 3)	31% (n = 1,224)	21% (n = 1,004)	22.8% (n = 517)
Overall	33.7%	30.1%	29%
Oblique			
Superficial (region 4)	46.2% (n = 342)	38.5% (n = 449)	34.5% (n = 304)
Deep (region 5)	51.1% (n = 548)	43% (n = 515)	44% (n = 452)
Overall	49%	41%	40%
Horizontal belly			
Tranverse (region 6)	44.3% (n = 174)	41.1% (n = 141)	33.6% (n = 143)

n is total number of fibers counted within each region. Note that within each of six regions (see Fig 4 for orientation), five sample populations were counted manually on enlarged map of each section. Average percentage of slow fibers in three specimens was 31%, 43.3%, and 39.6% in rectus, oblique, and horizontal bellies, respectively. Difference in fiber type composition between rectus and oblique, and rectus and horizontal belly is statistically significant ($p < .05$). Difference in composition of oblique and horizontal bellies was not statistically significant ($p = .2$).

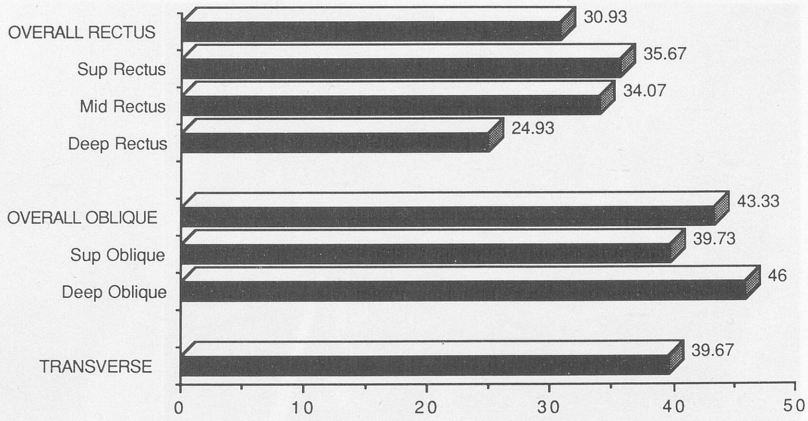

Fig 3. Bar graph showing percentage of slow fibers in each region.

ing approximately 20 kg were used during this portion of the experiment. The dogs were anesthetized with a combination of 6.5% sodium pentobarbital and 2.5% Surital at 11 mg/kg and 7 mg/kg, respectively. Anesthesia was maintained by boluses of Surital. Surital is a barbiturate with a short half-life, and it allowed the animal to pass through different phases of anesthesia level. The neck was opened in the midline and the CT was exposed, with careful avoidance of injuries to nerves and blood vessels. Bipolar hook-wire electrodes were used to obtain discrete recordings of limited areas.[63,72] On the basis of the results of the gross dissection and histochemistry, there seemed to be three well-defined muscle bellies. These rectus, oblique, and horizontal bellies were to be the target of this EMG investigation. The electrodes were placed in the rectus and oblique under direct vision. Since muscular integrity was imperative, the electrode meant to detect horizontal belly activity could not be placed under direct vision, but was instead placed deep to the inferior cornu, just superior to the cricothyroid joint. According to gross dissection, this corresponds to the location of the horizontal belly.

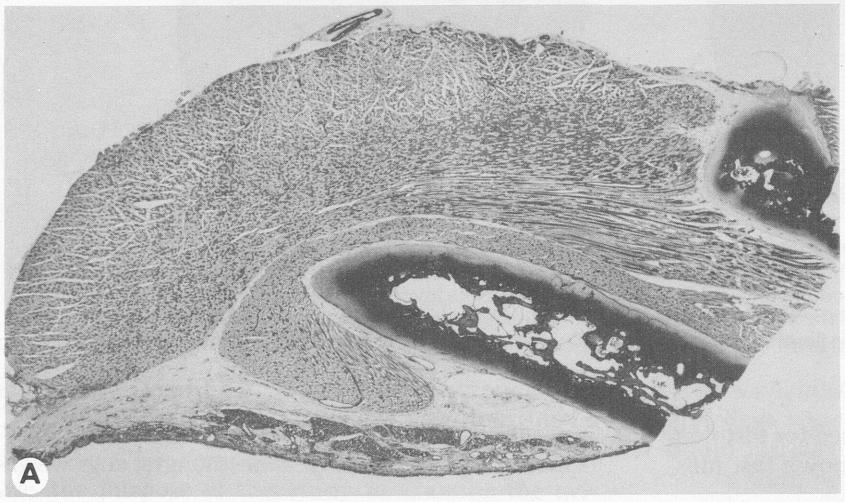

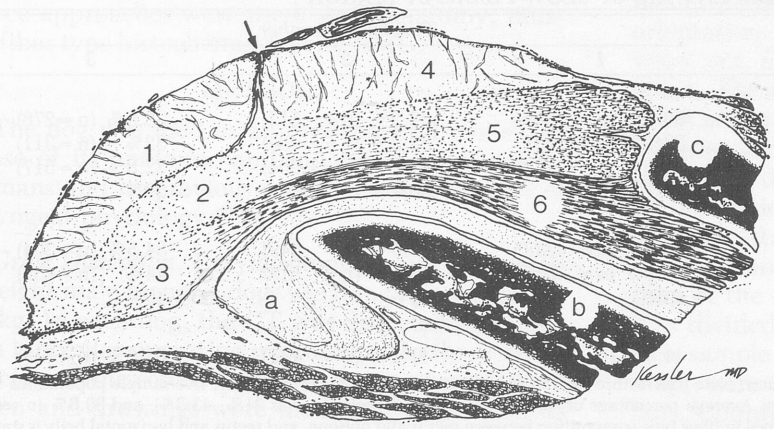

Fig 4. Cross section of cricothyroid muscle. A) Histochemical stain of horizontal cross section of cricothyroid muscle. Section is taken from middle of muscle. B) Map of A. Numbers 1 through 6 — muscle regions as defined for analysis (see Table 1), a — lateral cricoarytenoid muscle (LCA), b — cricoid cartilage, c — thyroid cartilage. Note fascial boundary between area 6 (horizontal belly) and LCA. Note that rectus has homogeneous appearance. Region 4 appears to have same composition as rectus; however, region 5 is notably darker. LCA is built-in control. It is very light-staining, as is consistent with its fast nature.

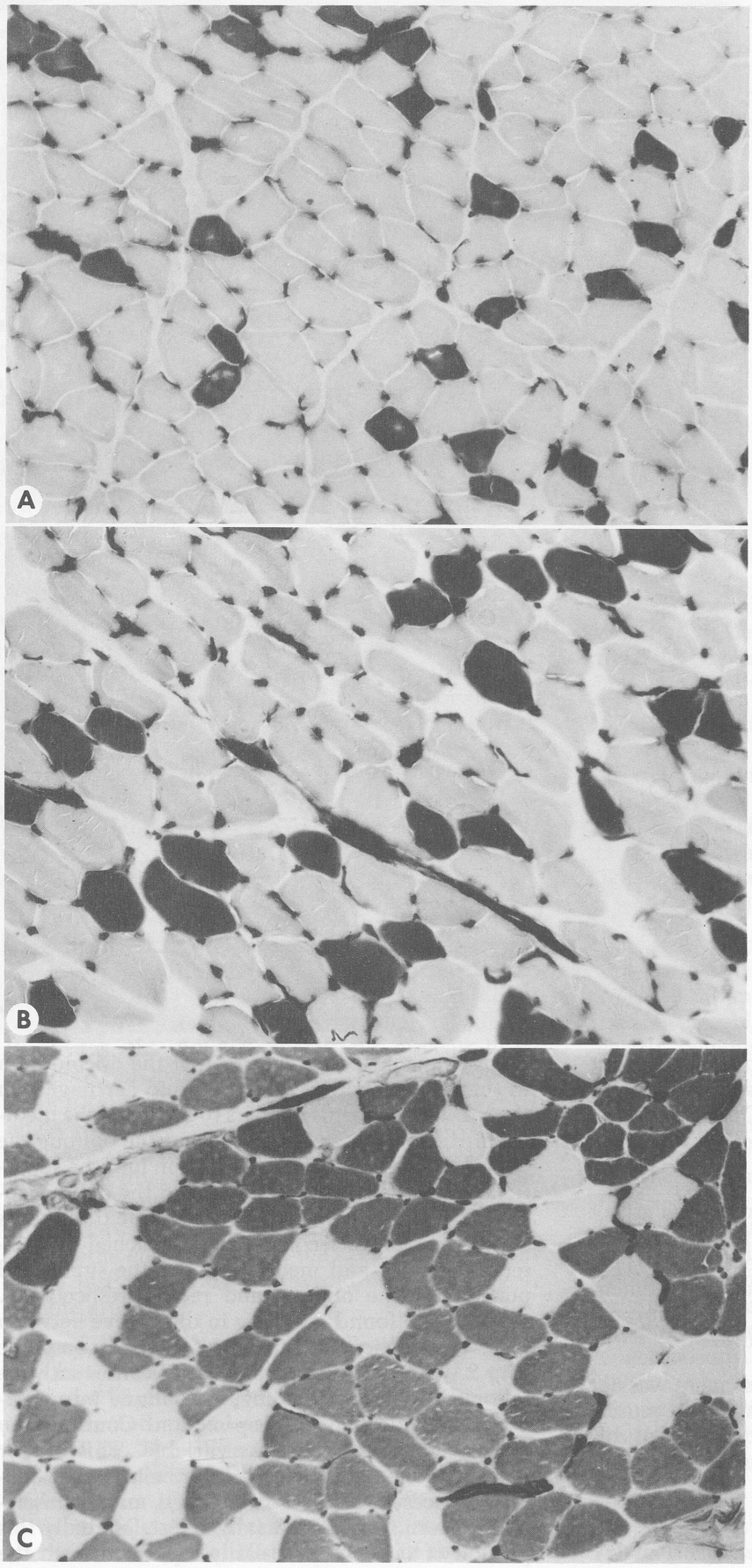

Fig 5. Histologic slides of adenosine triphosphatase–stained muscle regions. A) Rectus (original x20). B) Superficial oblique (original x20). C) Deep oblique (original x20). (Continued on next page.)

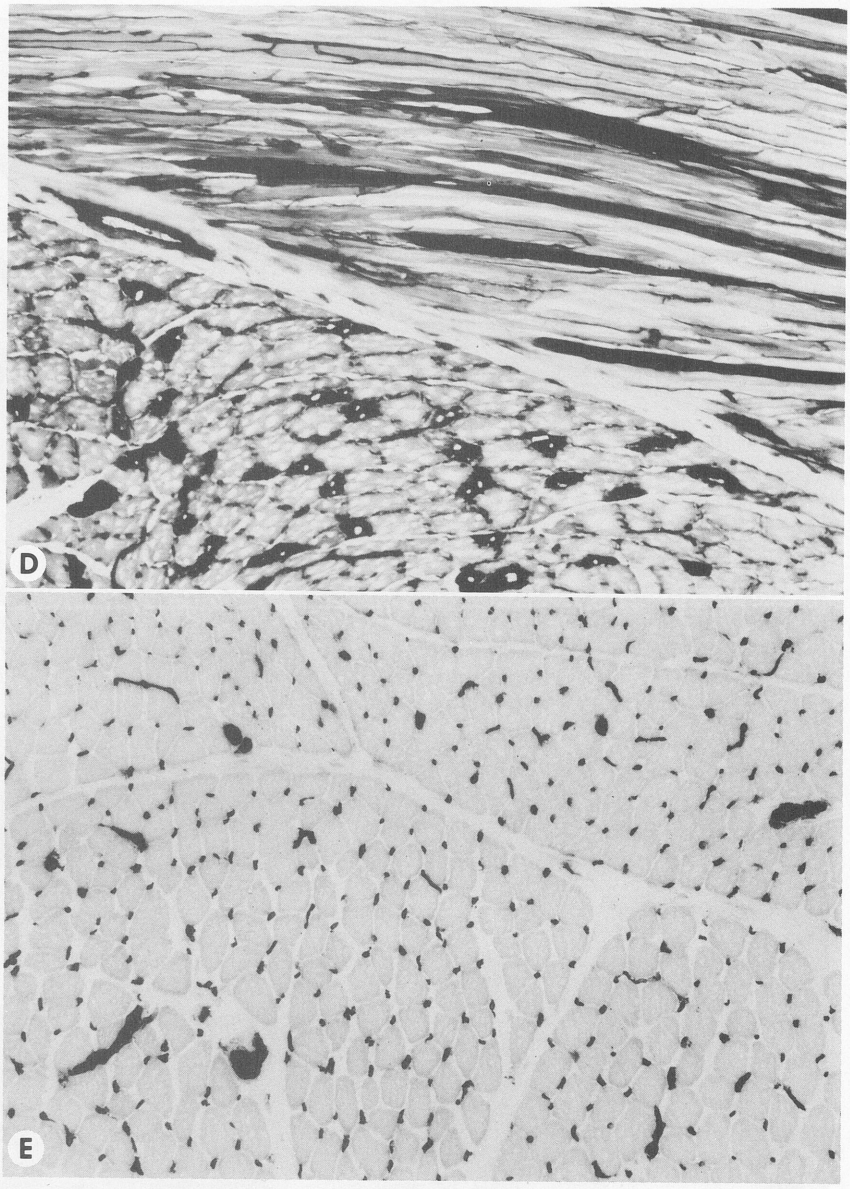

Fig 5, continued. D) Horizontal belly (original x10). Note fascial plane between it and lateral cricoarytenoid muscle. E) Thyroarytenoid muscle (original x10). Light-staining fibers are fast, while dark-staining fibers are slow. Note dramatic increase in darker-staining fibers in deep oblique, as well as change in fiber orientation between horizontal belly and other two bellies. Thyroarytenoid muscle is light-staining. This finding agrees with prior investigations and it is used here as control.[82]

Recordings were taken under both deep and light anesthesia. During deep anesthesia recordings of quiet breathing were still possible. During light anesthesia, respiration became more active, including occasional phonation.

Simultaneous recordings of the superficial aspect of the rectus in both the left and right CTs were used as controls. In addition, channels were switched periodically in the experiment in order to document their reliability. The EMG recorder was calibrated to 0.2 mV/cm prior to each procedure.

The goal of this portion of the experiment was not to define the exact activity pattern of the muscle bellies, but rather to document that significant differences existed during simultaneous recordings.

RESULTS

Gross Dissection and Histochemistry. The CT spans from the external surface of the cricoid arch to the inferior border of the thyroid cartilage. On the surface the rectus appears to comprise the medial third of the muscular mass, and the oblique the lateral two thirds (Fig 1). Dissection into the superficial fascia between the rectus and the oblique revealed that this plane does not continue through its depth. Instead, a second plane is reached that extends laterally and medially under the superficial portions of the oblique and rectus, respectively. Nerves were found traveling in the groove between these two bellies and on top of this deeper plane (Fig 2A,B). This second plane can consistently be followed laterally, dividing the oblique into a superficial section and a deep section. Continuation of this plane medially was variable. This deeper portion of the muscle inserts into the inner and medial surfaces of the thyroid cartilage, and the fascicular pattern seen superficially is lost. Medially this portion of the muscle is easily separated from the

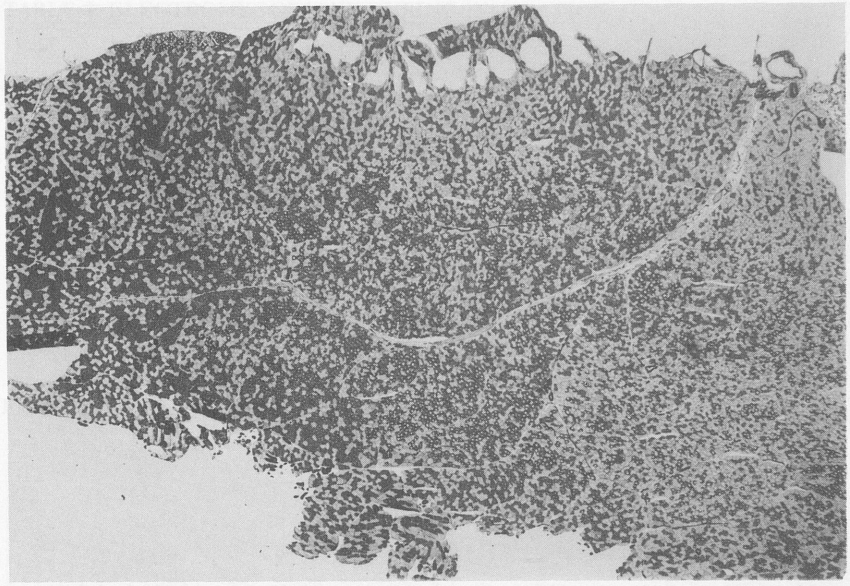

Fig 6. Fascial plane between rectus and oblique, separating oblique into superficial and deep portions. This finding was seen in gross dissection (Fig 2B) as well. Note that fascial barrier passes right through slower area of oblique. (Top is superficial, right is medial.)

lateral cricoarytenoid muscle, which has an overlying fascia.

The origin of the rectus is the anterior border of the cricoid arch, 1 mm above the inferior border of the cartilage. It inserts into the anterior and inner surfaces of the thyroid lamina, approximately 10 mm lateral to the midline at the region of the inferior thyroid tubercle. The rectus seems to be one muscular fascicle. Its fibers form a 79° angle (average of 80°, 79°, and 79°) with respect to the horizontal plane traversing its origin on the cricoid. In each specimen the rectus had the lowest proportion of slow twitch fibers, with its average being 31% (Table 1 and Fig 3).

The oblique originates from the inferior border of the cricoid. This belly fans out to insert on the anterior and inner surfaces of the thyroid cartilage, with the oblique line being its lateral margin and the inferior thyroid tubercle its medial margin. Unlike the rectus, the oblique superficially appears to be composed of multiple fascicles. The fibers of this belly form a 48.3° (average of 50°, 50°, and 45°) angle with the horizontal plane. A transition zone exists between the rectus and oblique that has a progression of fiber angles from 70° to 60°. The oblique is a slower belly than the rectus, with an average of 43.3% slow twitch fibers. Accordingly, the slowest area of the entire muscle is the deep portion of this belly, just medial to the thyroid cartilage (Fig 4, sample area 5).

Deep dissection reveals a bundle of muscle fibers that have a horizontal orientation. The fibers come from the ventral surface of the cricoid to insert on the inner and medial aspects of the inferior cornu (Fig 2C,D). These fibers were found during each of the eight microscopic dissections as well as on histologic sections (Fig 4, sample area 6). These fibers form an angle of 7° (average of 3°, 8°, and 9°) with the horizontal plane. Histochemistry of these areas discloses an intermediate composition of fast and slow fiber types in comparison to the rectus and oblique. The average percentage of slow twitch fibers found in this region was 39.6%. Since the orientation of these fibers is so different from that of the others described, this region has been named the horizontal belly for the purposes of this study.

Histologic slides demonstrating each of the muscle areas were made (Fig 5A-D[82]). The control sections of the thyroarytenoid consistently stained light, demonstrating 95% fast twitch fibers (Fig 5E). In addition, the lateral cricoarytenoid, another known fast muscle, was included in many of the specimens. This muscle was an added built-in control and showed 85% light-staining fast fibers (Fig 4).

The histologic sections also provided information about the fascial planes of the muscle as well as fiber orientation. The fascial boundaries between the rectus, the oblique, and the horizontal bellies are clearly demonstrated (Figs 6 and 7). While gross dissection suggested that the rectus and the oblique are separated into superficial and deep portions, fascial boundaries supporting this division were not seen on histologic sectioning. Fiber angulation can also be evaluated on these sections. A change in fiber orientation is seen when comparing cross sections of the rectus and oblique, as well as a dramatic difference in direction between these and the horizontal belly. In addition, histochemical stains of the origin and insertion of the CT reveal the posterior predilection of the darker-staining slow fibers, which occupy a position close to the cartilage (Fig 7). It is possible that these are the fibers from the slower deep area of the oblique seen on sections taken from the middle of the muscle (Fig 4, sample area 5).

Last, fibers were found coursing directly from the superior aspect of the cricoid cartilage to the inner surface of the thyroid cartilage. These fibers

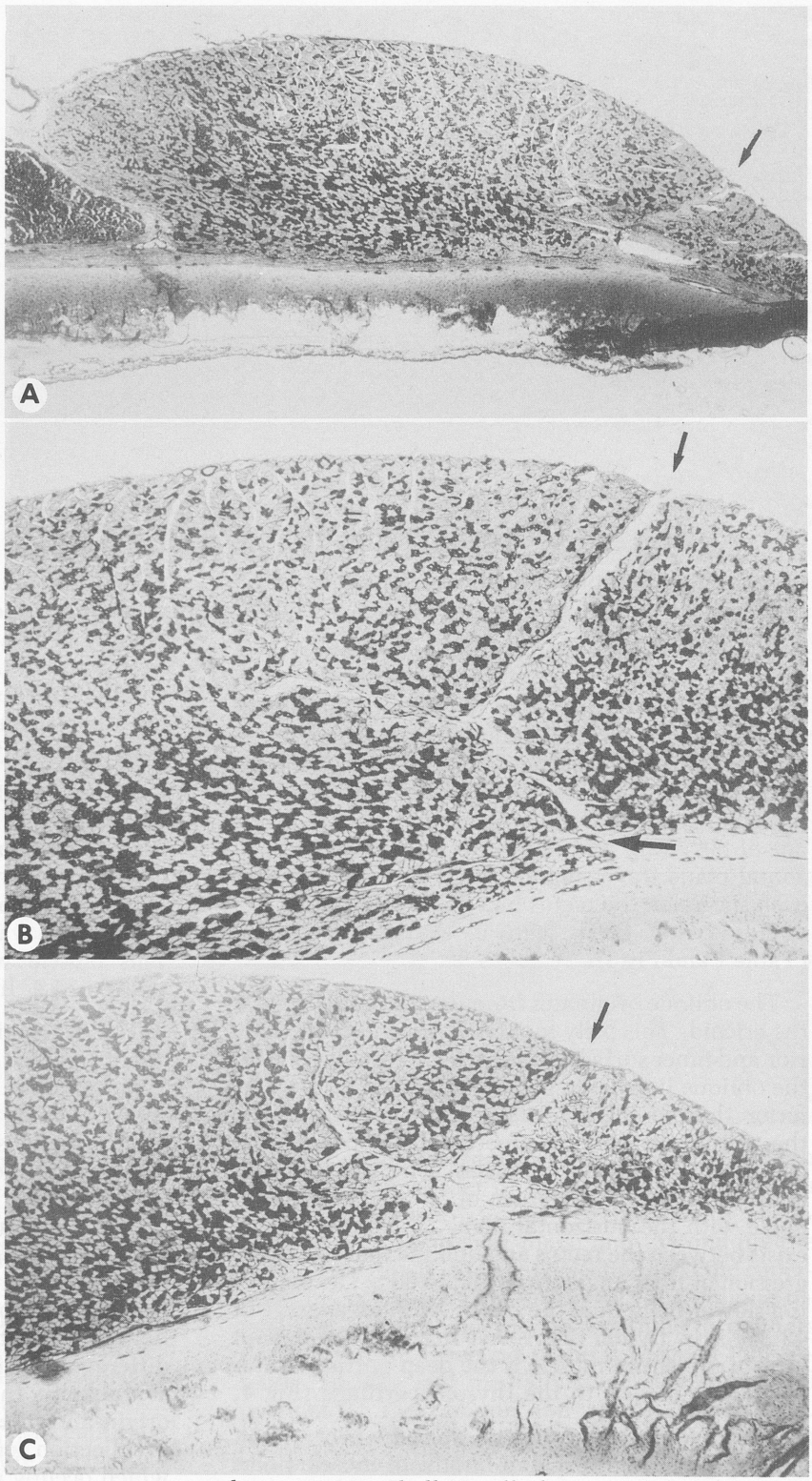

Fig 7. Horizontal sections through right cricothyroid muscle at three different levels. (Top is superficial, right is medial.) A) Insertion on thyroid cartilage. Note fascia between rectus and oblique (arrow). Deeper area is slow and superficial area is fast. B) Middle muscle section. Note fascia between rectus and oblique (small arrow) as well as between oblique and beginning of horizontal belly (large arrow). C) Origin on cricoid cartilage. Note darker-staining fibers arranged closer to cartilage, similar to what was seen in A. Again, fascia between rectus and oblique is marked with arrow.

were approximately 2 mm in length.

Electromyography. In all recordings inspiratory activity was dominant and synchronous. Differences were seen among the three bellies with regard to amplitude and variations in expiratory activity (Table 2).

During quiet breathing the rectus seemed to be the most active belly in all phases of the respiratory cycle (Fig 8A). As anesthesia level diminished and respiration became more active, including occasional phonation, the electrical activity of the oblique increased significantly (Fig 8B). This activity either approached or surpassed that of the rectus. This was true for both the inspiratory and expiratory phases of respiration.

TABLE 2. ELECTROMYOGRAPHY DURING INSPIRATION

Dog	*Anesthesia*	*Rectus*	*Oblique*	*Horizontal*
Inspiration				
1	Deep	21	19	8
	Light	14	20	—
2	Deep	27	17	11
	Light	28	27	—
3	Deep	20	21	7
	Light	21	32	—
4	Deep	17	10	12
	Light	37	33	—
5	Deep	20	16	3
	Light	21	32	—
Expiration				
1	Deep	4	4	0
	Light	3	8	—
2	Deep	8	4	3
	Light	4	5	—
3	Deep	5	5	3
	Light	6	15	—
4	Deep	6	2	0
	Light	7	10	—
5	Deep	4	0	0
	Light	3	6	—

Numbers are maximal recorded amplitude in millimeters. Note considerably less activity in horizontal belly. In addition there is reversal of activity when comparing rectus and oblique during deep and light anesthesia.

With particular regard to expiration, the oblique was often much less active than the rectus during quiet respiration. Again, changes occurred with lighter anesthesia. The electrical activity of the oblique increased such that the amplitude doubled in three of the samples in Table 2. In one case there was no oblique activity during quiet breathing, and with active breathing the electrical activity surpassed that of the rectus.

The horizontal belly had a totally different EMG pattern (Fig 8C). This belly was more active during inspiration than expiration, with no activity in expiration documented in three of five samples (Table 2). While this belly was functional during respiration, the recorded amplitudes imply significantly less activity than in the other bellies, especially during expiration.

Many of the EMG recordings demonstrated continuous tonic activity of the CT. In addition, heavy doses of barbiturates severely diminished CT activity. This is in accordance with the results of other investigators.[12,60]

Regional differences in activity were disclosed to the extent that one belly was active while another was silent (Fig 9).

DISCUSSION

The anatomic results of this experiment show that the CT of the dog is composed of three bellies. Two bellies, the rectus and the oblique, are well described

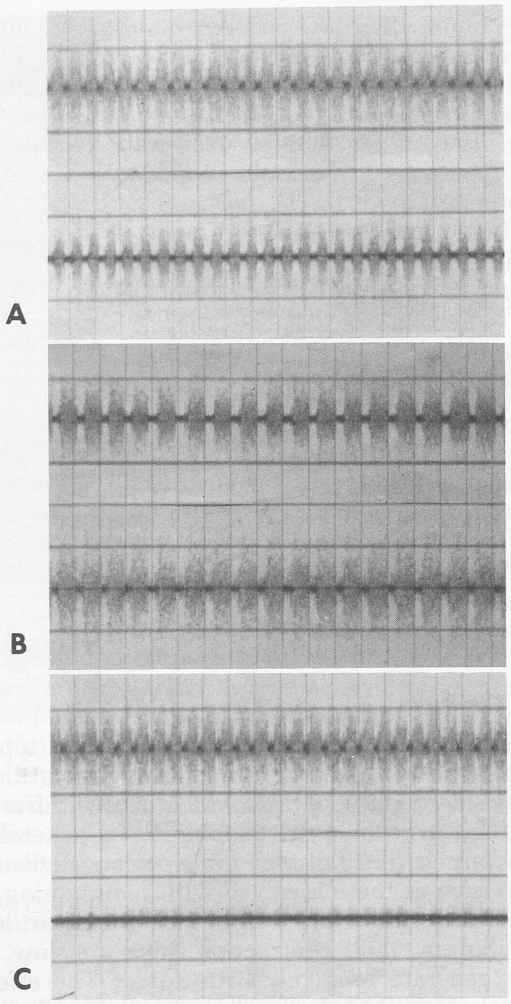

Fig 8. Electromyography. A) Rectus (top) and oblique (bottom) during quiet respiration. B) Rectus (top) and oblique (bottom) during active respiration. C) Rectus (top) and horizontal belly (bottom). Note increase in activity seen in oblique during inspiration and expiration as animal passes to lighter level of anesthesia. Note difference in activity between rectus and horizontal belly.

as the classic components of the CT. An unexpected finding was a clearly demarcated third belly, the horizontal. This belly is small and located deep in the muscle and is thus easy to overlook during dissections. The three bellies were anatomically defined by distinct fascial barriers as well as being oriented at 30° to each other. Inherent in their different orientations are different mechanical advantages in traction on the cricoid and thyroid cartilages. The logical action of the rectus is to narrow the cricothyroid gap by approximating the two cartilages in the vertical axis. The horizontal appears limited to ventrodorsal sliding of the two cartilages, while the oblique likely plays a role in both of these actions. Although these bellies are clearly separate in regard to their gross anatomy, this does not prove that their functions differ in any way. For this reason histochemical and EMG evidence was also obtained.

Histochemistry is an indirect method of studying

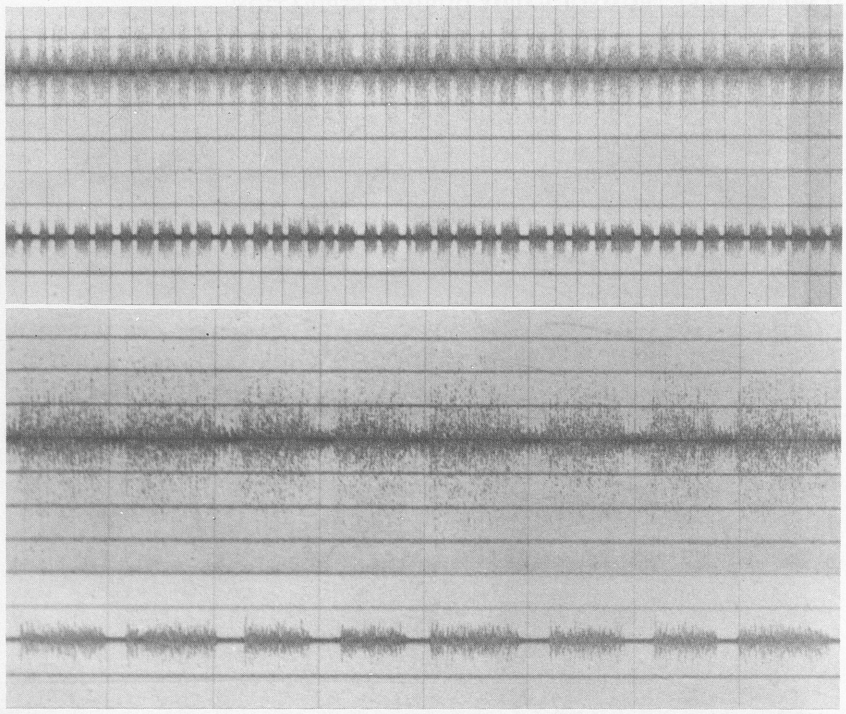

Fig 9. Electromyography. A) Rectus (top) and oblique (bottom). B) Same as A but at slower speed. Note that in this example oblique is silent during expiration, while rectus is active in both phases of respiratory cycle.

a muscle's activity. Slow (type I) and fast (type II) muscle fibers have slightly different myofibrillar adenosine triphosphatase, which can be differentiated by histochemical staining.[83] In general the slow muscle fibers display tonic prolonged contractions such as those involved with maintaining posture. These fibers are rich in enzymes of oxidative metabolism, their contraction times are slow, and they generate relatively little force. The efferent neural activity to slow muscle fibers is of low frequency. Fast muscle (type II) fibers show the opposite features in that they are poor in oxidative enzymes, are recruited at fast rates, have short contraction times, and are capable of high force levels.[84,85] Therefore, the fiber type as revealed by staining reflects a muscle fiber's normal activity.[84-86]

Most muscles are mixtures of both types of fibers. Some, however, have become so specialized that they are composed of a majority of one fiber type. The prototype of a slow muscle is the soleus.[87] It is capable of tonic contraction and is involved in the maintenance of upright body posture. The thyroarytenoid is an example of a fast muscle. This speed is needed to protect the airway during reflex vocal cord closure.[19,84,88] The thyroarytenoid is composed of 95% type II (fast) muscle fibers and has a contraction time of 14 to 24 milliseconds.[82,89,90] The CT is a slower muscle with diverse functions. It is composed of approximately 60% fast muscle fibers (Table 3[82,84,91-94]) and has a contraction time of 34 to 39 milliseconds.[22,89,90]

While investigators have provided histochemical data on the whole CT, none have looked at the regional distribution of fiber types. Just as individual muscles have different percentages of fast and slow fibers, so may regions within a muscle. Accordingly, the differences seen in whole muscle activities may also be seen when comparing regions of muscles.[95] One muscle in which this issue has been studied is the cat gastrocnemius. On the basis of fascial boundaries and muscle fiber orientation, this muscle contains three lateral bellies and one medial belly. Just as with the CT, differences exist between the bellies with regard to the proportion of fast and slow twitch fibers. In addition, the four bellies contain different amounts of muscle spindles and have no overlap of motor innervation.[96] This finding suggests that the afferent and efferent neural supplies are segregated for discrete control. Most important, EMG in the awake animal has demonstrated activity differences between the bellies.[96,97] The anatomic and histochemical results — and EMG, as described below — of the present study in the CT are comparable to those on the cat gastrocnemius. The difference between the rectus at 69% fast twitch and the oblique at 57% fast twitch is not as dramatic as between a prototypical fast muscle such as the

TABLE 3. FIBER TYPING OF CRICOTHYROID MUSCLE

Authors	*Year*	*Animal*	*% Slow*	*% Fast*
Syrovy and Gutmann[84]	1971	Rabbit	41	59
Asmussen and Wohlrab[91]	1972	Rabbit	35	65
Sahgal and Hast[92]	1974	Primates	30	70
Teig et al[93]	1978	Human	47	53
Braund et al[82]	1988	Dog	40	60
Happak et al[94]	1989	Sheep	57	43
		Human male	42	58
		Human female	43	57

thyroarytenoid and a slow muscle such as the gastrocnemius. Rather, what it suggests is that the activity of the two bellies differs significantly at least some of the time.

While histochemistry is merely an indicator of muscle activity, EMG is a true representation. The intent of EMG in this study was not to uncover the exact activity pattern of the CT. Instead, the aim was to demonstrate differences in activity patterns among the three bellies. The unnatural supine position of the animal, the extension of its head and neck, and the effect of barbiturates would be expected to obscure the EMG findings.[12,21,60] Moreover, under anesthesia the activity is limited to quiet respiration, which is perhaps the condition least likely to evoke EMG differences among the bellies. At first glance the EMG patterns appear similar, as all three bellies followed the inspiratory and expiratory cycle to greater or lesser degrees. However, on closer examination there were numerous subtle but significant discrepancies in the EMG patterns. The most common was a variation in the relative amplitude of inspiration at different levels of anesthesia. For example, the oblique belly often had less activity than the rectus during deep anesthesia. However, when the anesthesia lightened, the activity in the oblique often increased to double and triple that of the rectus. In addition, the bellies differed in the presence and amplitude of expiratory and tonic background activity. One belly might exhibit this activity while another would have none. At a later time this would change or even switch. These results cannot be explained as mere variations in recruitment thresholds among the bellies. Instead, they reflect that to some extent each belly is capable of distinct function. What these functions are and how and when they are used can only be answered by regional EMG recording in the awake animal while it performs the full range of normal activity.

The question then arises concerning the functional significance of multiple bellies within the CT. That the CT plays a major role during phonation and respiration is clear. However, to postulate a distinct role for each belly requires that they cause distinct motions of the thyroid and cricoid cartilages. There are two main motions at the cricothyroid joint, rotation and ventrodorsal sliding, and both appear to affect the vocal cord in a similar manner. There is only a small amount of evidence that suggests that these motions ever occur separately. However, this lack of evidence may be due to the fact that few experiments have been designed to examine the issue. Although the CT is the largest intrinsic laryngeal muscle, its actions are surprisingly subtle and difficult to quantify. We hope that studies such as this will inspire further investigation that will clarify its action.

ACKNOWLEDGMENTS — The authors thank Patrick Gannon, Michael Rothschild, MD, David Silva, MD, Lee Shangold, MD, Daniel Perl, MD, and Hugh Biller, MD, for their assistance during this project.

REFERENCES

1. A report of the Task Force on the National Strategic Research Plan. Voice and Voice Disorders. Bethesda, Md: National Institute on Deafness and Other Communication Disorders, National Institutes of Health, 1989:93-126.

2. Sanders I, Jacobs I, Wu B-L, Biller HF. Regional histochemical differences in the canine posterior cricoarytenoid muscle [Abstract]. Otolaryngol Head Neck Surg 1988;99:148-9.

3. Sanders I, Goldhaber N, Diamond A, Biller HF. Gross anatomic evidence for three bellies within the canine posterior cricoarytenoid muscle [Abstract]. Otolaryngol Head Neck Surg 1990: 103:240.

4. Wu B-L, Biller HF, Sanders I. Histochemical evidence for separate thyroarytenoid and vocalis muscles within the canine larynx [Abstract]. Otolaryngol Head Neck Surg 1990;103:191.

5. Ardran GM, Kemp FH. The mechanism of the larynx: part I. The movements of the arytenoid and cricoid cartilages. Br J Radiol 1966;39:641-54.

6. Fink BR. The human larynx: a functional study. New York, NY: Raven Press, 1975.

7. Vilkman EA, Pitkänen R, Suominen H. Observations on the structure and the biomechanics of the cricothyroid articulation. Acta Otolaryngol (Stockh) 1987;103:117-26.

8. Meller S. Functional anatomy of the larynx. Otolaryngol Clin North Am 1984;17:3-12.

9. Zemlin WR. Speech and hearing science: anatomy and physiology. Englewood Cliffs, NJ: Prentice Hall, 1981.

10. Fink BR, Demarest RJ. Laryngeal biomechanics. Boston, Mass: Harvard University Press, 1978.

11. Rudomin P. The electrical activity of the cricothyroid muscles of the cat. Arch Int Physiol Biochim 1966;74:135-53.

12. Suzuki M, Kirchner JA, Murakami Y. The cricothyroid as a respiratory muscle. Its characteristics in bilateral recurrent laryngeal nerve paralysis. Ann Otol Rhinol Laryngol 1970;79: 976-83.

13. Mathew OP, Sant'Ambrogio FB, Woodson GE, Sant'Ambrogio G. Respiratory activity of the cricothyroid muscle. Ann Otol Rhinol Laryngol 1988;97:680-7.

14. Vesalius A. De corporis humani fabrica, 1545.

15. Henle J. Handb Eingeweldelehre, 1873.

16. Tschiassny K. Studies concerning the action of the musculus cricothyroeoideus. Laryngoscope 1944;54:589-604.

17. Luschka H. Der Kehlkopf des Menschen. Tubingen: H Laupp, 1871.

18. Negus VE. The comparative anatomy and physiology of the larynx. New York, NY: Grune & Stratton, 1949.

19. Sasaki CT. Laryngeal physiology. In: Bailey BJ, Biller HF, eds. Surgery of the larynx. Philadelphia, Pa: WB Saunders, 1985: 27-44.

20. Mayet VA, Mundnich K. Beitrag zur Anatomie und zur Funktion des M. Cricothyreoideus und der Cricothyreoidgelenke. Acta Anat (Basel) 1958;33:273-88.

21. Arnold GE. Physiology and pathology of the cricothyroid muscle. Laryngoscope 1961;71:687-753.

22. Hast MH. Mechanical properties of the cricothyroid muscle. Laryngoscope 1966;76:537-48.

23. Pressman JJ. Physiology of the vocal cords in phonation and respiration. Arch Otolaryngol 1942;35:355-98.

24. Lore JM. Symposium on the larynx: I. Practical anatomical considerations of the larynx. Laryngoscope 1933;43:693-717.

25. Boshoff PH. The anatomy of the South African Negro larynx. S Afr J Med Sci 1945;10:35-50.

26. Rossi G, Cortesina G. Morphological study of the laryngeal muscles in man. Insertions and courses of the muscle fibers, motor end-plates and proprioceptors. Acta Otolaryngol (Stockh) 1965; 59:575-92.

27. Coers C. Structural organization of the motor nerve endings in mammalian muscle spindles and other striated muscle fibers. Am J Phys Med 1959;38:166-75.

28. Kanthack AA. The myology of the larynx. J Anat Physiol 1892;26:279-94.

29. Longet A. Recherches experimentales sur les nerfs des muscles du larynx. Gaz Med Paris 1841;9:465-73.

30. Lemere F. Innervation of the larynx. III. Experimental paralysis of the laryngeal nerve. Arch Otolaryngol 1933;18:413-24.

31. Onodi A. Die Anatomie und Physiologie der Kehlkopfnerven. Berlin, 1902.

32. Lemere F. Innervation of the larynx: I. Innervation of laryngeal muscles. Am J Anat 1932;51:417-37.

33. Dilworth TFM. The nerves of the human larynx. J Anat 1921-1922;56:48-52.

34. Clerf LH, Suehs OW. Paralysis of the larynx. Ann Otol Rhinol Laryngol 1941;50:762-8.

35. Berlin DD, Lahey FH. Dissections of the recurrent and superior laryngeal nerves. Surg Gynecol Obstet 1929;49:102-4.

36. Gregg RL. Experimental laryngeal paralysis. Ann Otol Rhinol Laryngol 1956;65:639-42.

37. Hooper FH. Experimental researches on the tension of the vocal bands. Arch Laryngol 1883;4(suppl 3).

38. Freedman LM. The role of the cricothyroid muscle in tension of the vocal cords. An experimental study in dogs designed to release tension of the vocal cords in bilateral recurrent laryngeal nerve paralysis. AMA Arch Otolaryngol 1955;62:347-53.

39. Freedman LM. The role of the cricothyroid muscle in tension of the vocal cords. An experimental study in dogs designed to release tension of the vocal cords in bilateral recurrent laryngeal nerve paralysis. Laryngoscope 1956;66:574-81.

40. Stone RE, Nuttall AL. Relative movements of the thyroid and cricoid cartilages assessed by neural stimulation in dogs. Acta Otolaryngol (Stockh) 1974;78:135-40.

41. Clerf LH, Baltzell WH. Re-evaluation of Semon's hypothesis. Laryngoscope 1953;63:693-9.

42. Moore DM, Berke GS. The effect of laryngeal nerve stimulation on phonation: a glottographic study using an in vivo canine model. J Acoust Soc Am 1988;83:705-15.

43. Ferrein A. De la formation de la voix de l'homme. Mem Acad R Sci (Paris) 1741;51:409-30.

44. Möller J, Fischer JF. Veber die Wirkung ders mm. Cricothyreoideus und Thyreo-arytaenoideus internus. Arch Laryngol Rhinol 1904;15:72-6.

45. Sonninen A. Is the length of the vocal cords the same at all different levels of singing? Acta Otolaryngol (Stockh) 1954;118: 219-31.

46. Farnsworth DW. High speed motion pictures of the human vocal cords. Bell Lab Rec 1940;18:203-8.

47. Yanagihara N, von Leden H. The cricothyroid muscle during phonation. Electromyographic, aerodynamic, and acoustic studies. Ann Otol Rhinol Laryngol 1966;75:987-1006.

48. Faaborg-Andersen K. Electromyographic investigation of intrinsic laryngeal muscles in humans. Acta Physiol Scand [Suppl] 1957;41(suppl 140).

49. Faaborg-Andersen K, Yanagihara N, von Leden H. Vocal pitch and intensity regulation. A comparative study of electrical activity in the cricothyroid muscle and the airflow rate. Arch Otolaryngol 1967;85:448-54.

50. Fujisaki H. A note on the physiological and physical basis for the phrase and accent components in the voice fundamental frequency contour. In: Fujimura O, ed. Vocal physiology: voice production, mechanisms and functions. New York, NY: Raven Press, 1988:347-55.

51. Vilkman E, Aaltonen O, Raimo I, Arajarvi P, Oksanen H. Articulatory hyoid-laryngeal changes vs. cricothyroid muscle activity in the control of intrinsic F0 of vowels. J Phonetics 1989;17: 193-203.

52. Barlett D. Respiratory functions of the larynx. Physiol Rev 1989;69:33-57.

53. Konrad HR, Rattenborg CC. Combined action of laryngeal muscles. Acta Otolaryngol (Stockh) 1969;67:646-9.

54. Woodson GE, Sant'Ambrogio F, Mathew O, Sant'Ambrogio G. Effects of cricothyroid muscle contraction on laryngeal resistance and glottic area. Ann Otol Rhinol Laryngol 1989;98: 119-24.

55. Woodson GE. Effects of recurrent laryngeal nerve transection and vagotomy on respiratory contraction of the cricothyroid muscle. Ann Otol Rhinol Laryngol 1989;98:373-8.

56. Weddel G, Feinstein B, Pattle RE. The electrical activity of voluntary muscle in man under normal and pathological conditions. Brain 1944;67:178-256.

57. Woodson GE. Respiratory activity of the cricothyroid muscle in conscious humans. Laryngoscope 1990;100:49-53.

58. Wyke B. Respiratory activity of intrinsic laryngeal muscles. An experimental study. In: Wyke B, ed. Ventilatory and phonatory control systems. London, England: Oxford University Press, 1974:408-29.

59. Fink BR, Basek M, Epanchin V. The mechanism of opening of the human larynx. Laryngoscope 1956;66:410-25.

60. Brewer DW, Dana ST. Investigations in laryngeal physiology: the canine larynx. Part II. Ann Otol Rhinol Laryngol 1963; 72:1060-75.

61. Horiuchi M, Sasaki CT. Cricothyroid muscle in respiration. Ann Otol Rhinol Laryngol 1978;87:386-91.

62. Haglund S. The normal electromyogram in human cricothyroid muscle. Acta Otolaryngol (Stockh) 1973;75:448-53.

63. Gay T, Hirose H, Strome M, Sawashima M. Electromyography of the intrinsic laryngeal muscles during phonation. Ann Otol Rhinol Laryngol 1972;81:401-9.

64. Nakamura F, Uyeda Y, Sonoda Y. Electromyographic study on respiratory movements of the intrinsic laryngeal muscles. Laryngoscope 1958;68:109-19.

65. Sherrey JH, Megirian D. Respiratory EMG activity of the posterior cricoarytenoid, cricothyroid and diaphragm muscles during sleep. Respir Physiol 1980;39:355-65.

66. Hiroto I, Hirano M, Toyozumi Y, Shin T. Electromyographic investigation of the intrinsic laryngeal muscles related to speech sounds. Ann Otol Rhinol Laryngol 1967;76:861-72.

67. Negus VE. Certain anatomical and physiological considerations in paralysis of the larynx. Proc R Soc Med 1947;40:849-53.

68. Murtagh JA. The respiratory function of the larynx. Some observations on laryngeal innervation. Preliminary report. Ann Otol Rhinol Laryngol 1945;54:307-21.

69. Fischer ND. Preliminary report on an application of the motor function of the superior laryngeal nerve. Ann Otol Rhinol Laryngol 1952;61:352-3.

70. Sasaki CT, Suzuki M. Laryngeal reflexes in cat, dog, and man. Arch Otolaryngol 1976;102:400-2.

71. Kotby MN, Haugen LK. Attempts at evaluation of the function of various laryngeal muscles in the light of muscle and nerve stimulation experiments in man. Acta Otolaryngol (Stockh) 1970;70:419-27.

72. Dedo HH. The paralyzed larynx: an electromyographic study in dogs and humans. Laryngoscope 1970;80:1455-517.

73. Wagner R. Die Medianstellung des Stimmbandes bei Recurrenslahmung. Arch Pathol Anat 1890;120:437-59.

74. Grossman M. Experimentelle Beitrage zur Lehre von der Posticuslahmung. Arch Laryngol Rhinol 1897;6:282.

75. Tschiassny K. Therapeutically induced paralysis of the cricothyroid muscle or its removal in paralytic laryngeal stenosis. AMA Arch Otolaryngol 1957;65:133-42.

76. Murtagh JA, Campbell CJ. Physiology of recurrent nerve. Report on progress. J Clin Endocrinol Metab 1952;12:1398-401.

77. Lemere F. Innervation of the larynx: IV. An analysis of Semon's law. Ann Otol Rhinol Laryngol 1934;43:525-40.

78. Vogel PH. The innervation of the larynx of man and the dog. Am J Anat 1952;90:427-47.

79. Brewer DW, Faaborg-Andersen K, Dana ST. Investigations in laryngeal physiology: the canine larynx, part I. Trans Am Laryngol Assoc 1962;83:174-5.

80. Hast MH. The primate larynx: a comparative physiological study of intrinsic muscles. Acta Otolaryngol (Stockh) 1969;67: 84-92.

81. Guth L, Samaha FJ. Procedure for the histochemical demonstration of actomyosin ATPase. Exp Neurol 1970;28:365-7.

82. Braund KG, Steiss JE, Marshall AE, Mehta JR, Amling KA. Morphologic and morphometric studies of the intrinsic laryngeal muscles in clinically normal adult dogs. Am J Vet Res 1988; 49:2105-10.

83. Guth L, Samaha FJ. Qualitative differences between actomyosin ATPase of slow and fast mammalian muscle. Exp Neurol 1969;25:138-52.

84. Syrovy I, Gutmann E. ATPase activity of two rabbit laryngeal muscles. Experientia 1971;27:248.

85. Armstrong RB, Phelps RO. Muscle fiber type composition of the rat hindlimb. Am J Anat 1984;171:259-72.

86. Kilarski W, Sjostrom M. Systematic distribution of muscle fibre types in the rat and rabbit diaphragm. A morphometric and ultrastructural analysis. J Anat 1990;168:13-30.

87. Johnson MA, Polgar J, Weightman D, Appleton D. Data on the distribution of fibre types in thirty-six human muscles: an autopsy study. J Neurol Sci 1973;18:111-29.

88. Pressman JJ, Kelemen G. Physiology of the larynx. Physiol Rev 1955;35:506-54.

89. Perlman AL, Alipour-Haghighi F. Comparative study of the physiological properties of the vocalis and cricothyroid muscles. Acta Otolaryngol (Stockh) 1988;105:372-8.

90. Martensson A, Skoglund CR. Contraction properties of intrinsic laryngeal muscles. Acta Physiol Scand 1964;60:318-36.

91. Asmussen G, Wohlrab F. Enzymhistochemische Untersuchungen au der Kehlkopfmuskulatur erwachsener Kaninchen. Z Mikrosk Anat Forsch 1972;86:383.

92. Sahgal V, Hast MH. Histochemistry of primate laryngeal muscles. Acta Otolaryngol (Stockh) 1974;78:277-81.

93. Teig E, Dahl HA, Thorkelsen H. Actomyosin ATPase activity of human laryngeal muscles. Acta Otolaryngol (Stockh) 1978;85:272-81.

94. Happak W, Zrunek M, Pechmann U, Streinzer W. Comparative histochemistry of human and sheep laryngeal muscles. Acta Otolaryngol (Stockh) 1989;107:283-8.

95. Binder MD. Changing perspectives on the functional organization of the segmental motor system. Can J Physiol Pharmacol 1986;64:495-8.

96. Windhorst U, Hamm TM, Stuart DG. On the function of muscle and reflex partitioning. Behav Brain Sci 1989;12:629-81.

97. English A. An electromyographic analysis of compartments in cat lateral gastrocnemius muscle during unrestrained locomotion. J Neurophysiol 1984;52:114-25.

MANAGEMENT OF AIRWAY OBSTRUCTION IN PATIENTS WITH CONGENITAL HEART DEFECTS

DEBORAH A. DAVIS, MD

JOHN A. TUCKER, MD PIERANTONIO RUSSO, MD

PHILADELPHIA, PENNSYLVANIA

Airway obstruction may complicate the course of infants undergoing repair of congenital heart disease. Airway obstruction was encountered in seven patients following surgery for complex congenital heart defects (two with interrupted aortic arch, one with pulmonary atresia and a ventricular septal defect, one with tetralogy of Fallot and an abnormal left anterior descending coronary artery, one with truncus arteriosus, and two with complex univentricular heart). In four patients, a conduit was implanted at the time of surgery. In all cases, bronchoscopy accurately demonstrated the cause of the airway obstruction. Two infants had hypoplasia of the left bronchus, and five had tracheobronchomalacia associated with extrinsic compression of the airway by a great vessel or conduit. All were treated conservatively with therapeutic bronchoscopy, tracheotomy, and/or stenting with prolonged mechanical ventilation. Follow-up ranged from 2 to 40 months. Four infants have been weaned from mechanical ventilation and decannulated; two are awaiting decannulation; and one was decannulated and died awaiting surgical repair. To reduce morbidity in infants undergoing surgery for congenital heart disease, the presence of preoperative airway anomalies should be sought and surgery planned to avoid airway compression. Conservative management using diagnostic and therapeutic bronchoscopy, tracheotomy, and stenting together with prolonged ventilator care is rewarding.

KEY WORDS — airway obstruction, congenital heart defects.

INTRODUCTION

Tracheobronchial obstruction is associated with significant morbidity and mortality in patients undergoing repair of congenital heart defects. Although vascular rings are a well-known cause of airway obstruction,[1] only recently has the association between more complex congenital heart malformations and airway compromise been recognized. We have recently reviewed our experience with seven consecutive patients in whom severe tracheobronchomalacia or bronchial obstruction was encountered following repair or palliation of complex congenital heart malformations. Our findings and management of these patients are reported in the present study.

PATIENTS AND METHODS

From August 1988 to January 1991, seven infants (age range 2 days to 7 months) presented with major airway obstruction following palliation or repair of complex congenital heart malformations (see Table). All patients failed extubation following successful palliative or reparative cardiac surgical procedures. Diagnosis was made with bronchoscopy in all.

Anesthesia for bronchoscopy was induced with an inhalational agent or intravenous narcotic depending on the severity of the underlying cardiac disease. All patients were intubated with appropriate-size uncuffed endotracheal tubes and had an audible leak around their endotracheal tube of less than 30 cm H_2O. Through the indwelling endotracheal tube, either mechanical or hand ventilation was maintained. Pulse oximetry and end tidal carbon dioxide measurements were continuously monitored. Spontaneous ventilation was used if vocal cord function was to be evaluated. Immediately before bronchoscopy, a muscle relaxant was given and hyperventilation with 100% oxygen was performed. The airway was evaluated endoscopically by direct laryngoscopy and bronchoscopy using an apneic technique with the aid of Hopkins rod telescopes. A Storz bronchoscope was used to dilate bronchi that were hypoplastic or compressed. After bronchoscopy, the endotracheal tube was replaced, anesthesia was discontinued, and the patient was transported back to the intensive care unit.

Once thoracotomy or sternotomy incisions were healed, the patient was returned to the operating room and a tracheotomy was performed. The average length of time between the cardiac procedures and the tracheotomy was 2 weeks. Conservative management

From the Pediatric Heart Institute, Temple University School of Medicine (Davis, Russo), the Departments of Anesthesia and Critical Care (Davis) and Surgery (Tucker, Russo), St Christopher's Hospital for Children, and the Division of Otolaryngology, Albert Einstein Medical Center (Tucker), Philadelphia, Pennsylvania.

Presented at the meeting of the American Laryngological Association, Waikoloa, Hawaii, May 4-5, 1991.

REPRINTS — Deborah A. Davis, MD, Dept of Anesthesia and Critical Care, St Christopher's Hospital for Children, Erie Ave and Front St, Philadelphia, PA 19134.

CARDIAC PROCEDURES AND AIRWAY OBSTRUCTION IN SEVEN INFANTS

Patient	*Age*	*Diagnosis*	*Cardiac Procedure*	*Airway Obstruction*	*Follow-up*
1	Newborn	IAA, VSD	Arch repair by end-end anastomosis, VSD repair	Tracheobronchomalacia, small left bronchus	Alive, good condition (16 mo)
2	Newborn	IAA, VSD	Arch repair by end-end anastomosis, PAB	Tracheomalacia (lower), compression left bronchus	Alive, good condition (36 mo)
3	Newborn	AVC, PA, TGV, HLV	Central shunt, RMBT shunt, hemi-Fontan	Stenosis left bronchus	Alive, good condition (32 mo)
4	Newborn	DORV, HLV, PA, TGV	LMBT shunt, aortopexy	Anterotracheal compression, compression left bronchus	Alive, good condition, awaiting Fontan (18 mo)
5	Premature newborn	Truncus arteriosus type II	Bilateral PAB	Compression trachea	Died awaiting cardiac repair (2 mo)
6	Newborn	TOF, PA, VSD	Complete repair RV-PA homograft	Compression left bronchus	Alive, good condition (40 mo)
7	Newborn	TOF, anomalous LAD	Complete repair RV-PA homograft	Compression trachea	Alive, good condition (6 mo)

IAA — interrupted aortic arch, VSD — ventricular septal defect, PAB — pulmonary artery banding, AVC — atrial-ventricular canal, PA — pulmonary atresia, TGV — transposition of great vessels, HLV — hypoplastic left ventricle, RMBT — right modified Blalock-Taussig, DORV — double-outlet right ventricle, LMBT — left modified Blalock-Taussig, TOF — tetralogy of Fallot, RV-PA — right ventricle to pulmonary artery, LAD — left anterior descending coronary artery.

involving prolonged mechanical ventilation with positive end-distending pressure was applied. Pulmonary function tests were performed in all patients in order to establish the degree of ventilatory support, particularly the optimal positive end-expiratory pressure, necessary to maintain patency of the central and peripheral airways.

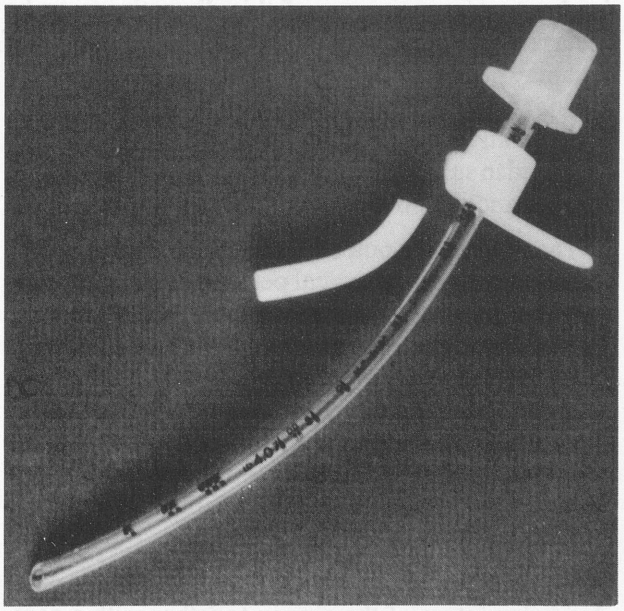

No. 3 pediatric Shiley tracheotomy tube modified to function as collar coupled with No. 3 pediatric endotracheal tube. Latter may be cut to any predetermined length.

In patients with bronchial compression (patients 1, 3, 4, and 6), frequent (initially weekly) bronchoscopy with dilation was necessary to avoid lung collapse. Subsequently, bronchoscopic dilation and lavage were performed at monthly intervals for a period of 6 months to avoid lung collapse.

Bronchoscopy was used to evaluate patients with generalized and diffuse airway obstruction (patients 2, 5, and 7) that revealed an extrinsic compression by a vascular structure. Based on the functional dimensions of the airway and degree of mucosal healing, plans for weaning from mechanical ventilation and eventual decannulation were made. Patient 4 had undergone a left modified Blalock-Taussig shunt (a 5-mm Goretex interposition graft between the left subclavian artery and left pulmonary artery) to increase pulmonary flow. Angiography revealed a dilated ascending aorta, and the patient required an aortopexy to relieve the anterior tracheal compression. He continued to require bronchoscopic dilation of his left bronchus for at least 6 months following the aortopexy. His airway was stented to the level of the left bronchus with a specifically calibrated tracheotomy tube fashioned for his particular airway dimensions (see Figure).

Follow-up has ranged between 2 and 40 months in all patients. Six patients were alive and in good condition at last follow-up. One patient died awaiting his cardiac repair.

Four patients have been successfully weaned from mechanical ventilation and decannulated. Patient 1 was decannulated and was free of symptoms after 16 months. Patient 6 was decannulated after 40 months. Patient 3 was successfully decannulated after his second cardiac operation, but required a new tracheotomy and continuous positive airway pressure following his third intracardiac procedure. He is progressing well, although his pulmonary compliance was reduced at his 32-month follow-up visit as compared to the preoperative period. Patient 5 was decannulated 2 months following bilateral pulmonary artery bands and tracheotomy. We believe that a reduction in pulmonary blood flow following the banding procedure reduced the degree of tracheobronchial compression, permitting a successful decannulation. This patient experienced sudden death while awaiting his intracardiac repair. Permission for a postmortem examination was not granted.

Patient 4 is awaiting decannulation at his 18-month follow-up. Patient 7 is awaiting decannulation at his 6-month follow-up.

Patients 1, 3, 4, 6, and 7 were enrolled in our home ventilator care program and were initially discharged home on mechanical ventilation and weaned from that mechanical ventilation at home. In the remaining patients, social and environmental reasons prevented their enrollment in our home ventilator care program. Patients awaiting decannulation were followed up with bronchoscopy and pulmonary function tests at regular intervals. Echocardiography and cardiac catheterizations were performed in all patients between 2 and 24 months following cardiac surgical procedures in order to evaluate the results of the cardiac palliation or repair.

DISCUSSION

The failure to wean a child from mechanical ventilation following a cardiac surgical procedure can be a relatively common occurrence, requiring a thorough evaluation of multiple and possibly interrelated causes. In those patients with elevated pulmonary blood flow, one needs to discern if the problem is related to direct vascular compression of the tracheobronchial tree or is caused by volume overload, interstitial edema, or decreased pulmonary compliance. If there is direct compression of the airway, the compromise is far more life-threatening in the pediatric population than in the adult. In addition to proportionally reduced dimensions,[2] structural features make the infant airway more vulnerable to extrinsic compression. The glottis in infancy has an anterior-posterior dimension of 7 mm and a posterior transverse dimension of 4 mm. Mucosal edema of 1 mm will create a glottic space 35% of normal.[3] The subglottic anterior-posterior diameter, the limiting dimension of the infant larynx, is approximately 5.7 mm at birth.[4] In infants, the cartilaginous, muscular, and elastic supporting structures of the airway are more pliable and susceptible to extrinsic compression. Air trapping and atelectasis are far more common in infancy as a consequence of these anatomic characteristics.

The infant or young child has high peripheral airway resistance, lending a greater tendency to airway closure. Resistance to airflow through the bronchial lumina is proportional to the radius of the lumina; consequently, a small amount of edema, mucus, or compression will markedly narrow the infant bronchus.[5]

It is not surprising, then, that complex cardiac malformations can compromise the infant airway by direct compression (heart or great vessel) or by increased pulmonary artery pressure and pulmonary interstitial edema.[6,7] Cardiac surgical procedures involving prosthetic devices or conduits may result in direct compression of the airway. In addition, pulmonary artery homografts or large systemic to pulmonary artery shunts, by increasing pulmonary blood flow, can distend the pulmonary arteries, which can compress the tracheobronchial tree. Surgical repair of an interrupted aortic arch or severe coarctation of the aorta may affect the tracheobronchial tree if an end-to-end anastomosis is done at the level of the left bronchus. Surgical dissection of vascular structures can result in edema that distorts the anatomic relationships around the tracheobronchial tree. Another inadvertent consequence of this dissection may be recurrent laryngeal nerve or phrenic nerve damage that may not cause airway obstruction, but should be considered in the difficult-to-extubate patient. In the postoperative course, recurrent tracheal infections may lead to subglottic inflammation and stenosis that may be another source of airway compromise.

The workup for potential airway problems should ideally precede the surgical period, as there are well-known associations between cardiac malformations and tracheobronchial abnormalities. There are those centers that use tracheography as a means of evaluating the airway. At our institution, we hesitate to use this method, as it results in inspissated tracheal secretions and bronchospasm despite aspiration of most of the dye after the study has been performed.

We believe that bronchoscopy has several diagnostic and therapeutic advantages. It provides a more dynamic picture of the airway together with a complete anatomic view of the central and peripheral bronchi; it allows ready removal of secretions, lavage,

and dilation of obstructed airways; it can be repeated at short intervals; and it facilitates the insertion of internal stenting, as in patient 4.

Surgical methods used to treat intrathoracic airway obstruction with or without malacia include tracheal bronchotomy with patch reconstruction and tracheal bronchial resection by end-to-end or end-to-side direct anastomosis. However, these methods very often require cardiopulmonary bypass and/or circulatory arrest with full heparinization. Bleeding, infection, and dehiscence of suture lines are problems associated with surgical resection and reconstruction of airways with cardiopulmonary bypass. In addition to high morbidity, mortality is as high as 40% in patients with complex congenital heart defects undergoing surgical repair of airway obstruction.[8]

In the present series there was only one death, not directly related to airway obstruction. This occurred in a premature baby who died suddenly with an arrhythmia while awaiting intracardiac repair.

In summary, we believe that tracheotomy, repeated bronchoscopy with or without stenting, and prolonged positive pressure ventilation is a valid alternative to surgical correction of an obstructed airway. The results of this series are rewarding and indicate that a more conservative approach as in this group of patients is warranted.

REFERENCES

1. Backer C, Ilbawi MN, Idriss FS, DeLeon SY. Vascular anomalies causing tracheoesophageal compression: review of experience in children. J Thorac Cardiovasc Surg 1989;97:725-31.

2. Tucker J, Tucker G. A clinical perspective on the development and anatomical aspects of the infant larynx and trachea. In: Healy G, McGill T, eds. Laryngo-tracheal problems in the pediatric patient. Springfield, Ill: Charles C Thomas, 1979:3-8.

3. Holinger P. Clinical aspects of congenital anomalies of the larynx, trachea, bronchi and esophagus. J Laryngol Otol 1961; 75:1-44.

4. Fearon B, Whalen JS. Tracheal dimensions in the living infant. (Preliminary report). Ann Otol Rhinol Laryngol 1967; 76:964-74.

5. Stranger P, Lucas R, Edwards J. Anatomic factors causing respiratory distress in acyanotic congenital cardiac disease. Pediatrics 1969;43:760-9.

6. Berlinger NT, Long C, Foker J, Lucas RV Jr. Tracheobronchial compression in acyanotic congenital heart disease. Ann Otol Rhinol Laryngol 1983;92:387-90.

7. Moss A, McDonald L. Cardiac disease in the wheezing child. Chest 1977;71:187-92.

8. Corno A, Giamberti A, Giannico S, et al. Airway obstructions associated with congenital heart disease in infancy. J Thorac Cardiovasc Surg 1990;99:1091-9.

ACQUIRED LARYNGOMALACIA: EPIGLOTTIS PROLAPSE AS A CAUSE OF AIRWAY OBSTRUCTION

PEAK WOO, MD

SYRACUSE, NEW YORK

Epiglottis prolapse during inspiration is an unusual cause of upper airway obstruction. It occurs primarily in patients who have lost pharyngeal airway support because of previous surgery or after head injury and coma. Eight cases of epiglottis prolapse are presented. One patient had epiglottis prolapse after resection of floor of mouth cancer and another after laryngeal fracture. The rest of the cases were seen in patients recovering from head injury and coma. Videolaryngoscopy shows the larynx to assume an ovoid shape within the pharynx. There is loss of the usual anterior to posterior pharyngeal and laryngeal dimension. The epiglottis is in a more horizontal position at rest. During inspiration, the epiglottis prolapses into the endolarynx, causing subtotal airway obstruction. Laryngeal obstruction due to epiglottis prolapse can prevent decannulation in the head-injured and can be the cause of obstructive sleep apnea. Endoscopic carbon dioxide laser epiglottectomy was successful in management of these cases.

KEY WORDS —acquired laryngomalacia, airway obstruction, epiglottis prolapse.

INTRODUCTION

Supraglottic airway collapse is a well-recognized cause of laryngeal stridor in children. Laryngomalacia is the most common cause of stridor in newborns.[1] However, collapse of normal supraglottic structures in adults has rarely been described as a cause of airway obstruction. Templer et al[2] described a case of congenital laryngeal anomaly persisting into adulthood. Peron et al[3] reported on their experience with treatment of redundant aryepiglottic folds as a cause of stridor. Their series of seven older patients had flaccid and redundant aryepiglottic folds as a cause of stridor occurring after central nervous system (CNS) injury. This was attributed to CNS disease in their patients. Kletzker and Bastian[4] also reported three cases of acquired airway obstruction due to histologically normal supraglottic soft tissue. These patients also had redundant aryepiglottic folds as the cause of airway obstruction. They were treated successfully by endoscopic removal of the redundant aryepiglottic folds. Our report presents eight additional cases of acquired supraglottic airway collapse as a cause of stridor. Unlike the other reports, the cause of airway obstruction in this series was prolapse of the epiglottis during inspiration. This airflow induced collapse of the epiglottis, which may also be termed acquired laryngomalacia, was the cause of severe upper airway obstruction in adults.

MATERIALS AND METHODS

Eight cases of epiglottis prolapse causing severe airway obstruction have been identified. Six patients were evaluated because they could not be decannulated after tracheostomy. All had severe CNS insults; all had severe stridor and airway obstruction upon being capped during the decannulation process. All six were in the process of recovering from coma. Two other patients were evaluated for progressive obstructive sleep apnea after previous surgery involving the larynx and pharynx.

CASE REPORTS

Case 1. A 19-year-old, previously healthy man was involved in a motor vehicle accident on July 3, 1988. He sustained extensive closed head injury requiring ventriculostomy, posterior fossa craniotomy for evacuation of hematoma, and a ventriculoperitoneal shunt. An uncomplicated tracheostomy was performed 10 days after admission. On September 14, the otolaryngology service was consulted to evaluate severe stridor occurring when his tracheostomy tube was capped. His neurologic condition was, at this time, improved enough to consider decannulation. He was aware, awake, and able to cough on command. Flexible laryngoscopy and tracheobronchoscopy was done. It showed a sizeable amount of peristomal granulation tissue and a flaccid, horizontally positioned epiglottis (Fig 1A). The peristomal granulation tissue was believed to be the source of stridor. On October 18, he underwent complete excision of suprastomal granulation tissue by use of the carbon dioxide (CO_2) laser bronchoscope. He was decannulated the next day. Immediately after decannulation, severe inspiratory stridor with oxygen desaturation occurred. The patient was reexamined. On fiberoptic laryngoscopy, the epiglottis was seen to be sucked into the larynx

From the Department of Otolaryngology, State University of New York Health Science Center at Syracuse, Syracuse, New York.

Presented at the meeting of the American Laryngological Association, Waikoloa, Hawaii, May 4-5, 1991.

REPRINTS — Peak Woo, MD, Dept of Otolaryngology, SUNY Health Science Center at Syracuse, 750 E Adams St, Syracuse, NY 13210.

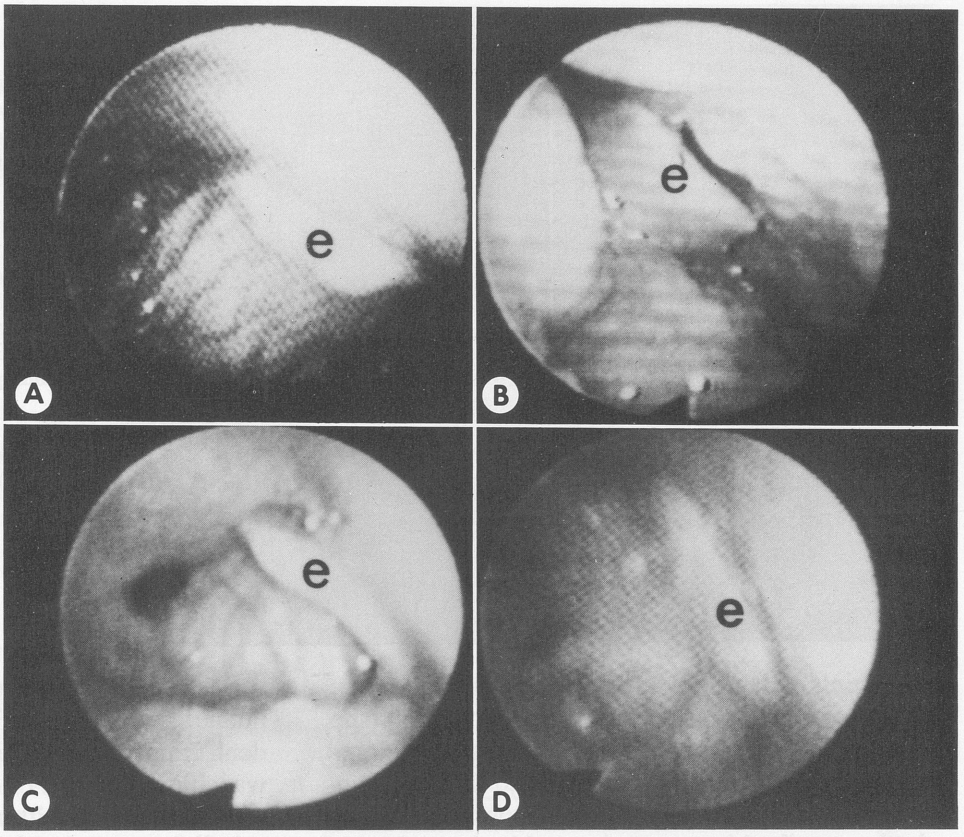

Fig 1. Photographs of epiglottis prolapse during inspiration in four patients. e — tip of epiglottis. A) (Case 1) Notice posterior and horizontal tilt of epiglottis. B) (Case 3) Notice impaction of epiglottis against posterior pharyngeal wall. C) (Case 4) Notice subtotal airway occlusion. D) Case 5.

during inspiration, thus causing subtotal upper airway obstruction. Examination of the rest of the larynx and trachea revealed normal findings. He was returned to the operating room. A partial epiglottis resection with the CO_2 laser was performed through the operating laryngoscope. Surgical excision consisted of resection of the superior half of the suprahyoid epiglottis. After this endoscopic procedure, there was complete relief of inspiratory stridor and the patient was discharged home decannulated and without stridor. Follow-up examination at 2 years showed excellent swallow function and respiration without airway obstruction. Laryngoscopy showed a shortened epiglottis in an upright posture without prolapse.

Case 2. A 68-year-old woman presented with a T4N0M0 squamous cell carcinoma of the oral vestibule due to smokeless tobacco. She was treated in February 1986 by a composite resection. Resection margins included all suprahyoid structures, the mandible, and the entire floor of the mouth. She was reconstructed with a large myocutaneous flap and a mandible reconstruction plate (AO-ASIF). She did well until June 8, 1988, when she was reevaluated for

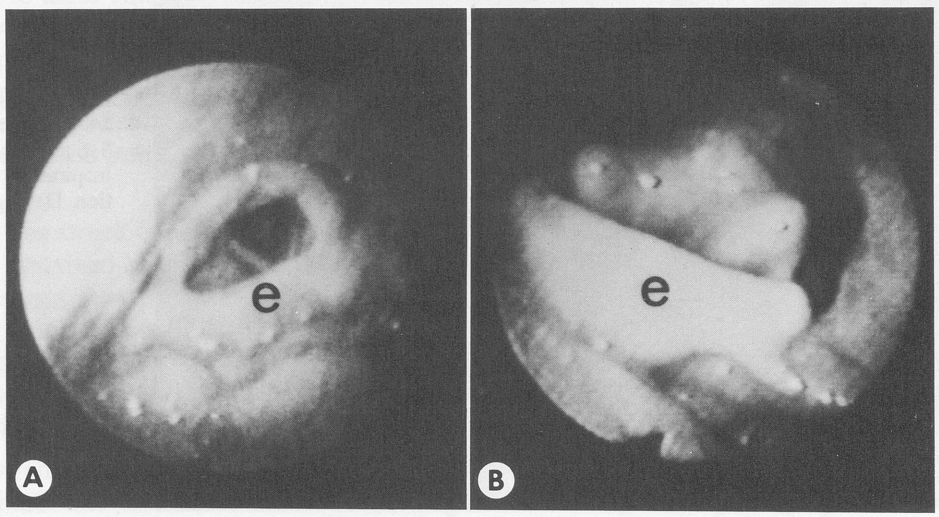

Fig 2. (Case 2) Photographs of larynx during inspiration. e — epiglottis. A) Partial epiglottectomy relieves flow-induced epiglottis prolapse without major resection of normal structures. B) Preoperative view. Larynx is obscured by epiglottis with symptoms of nocturnal airway obstruction.

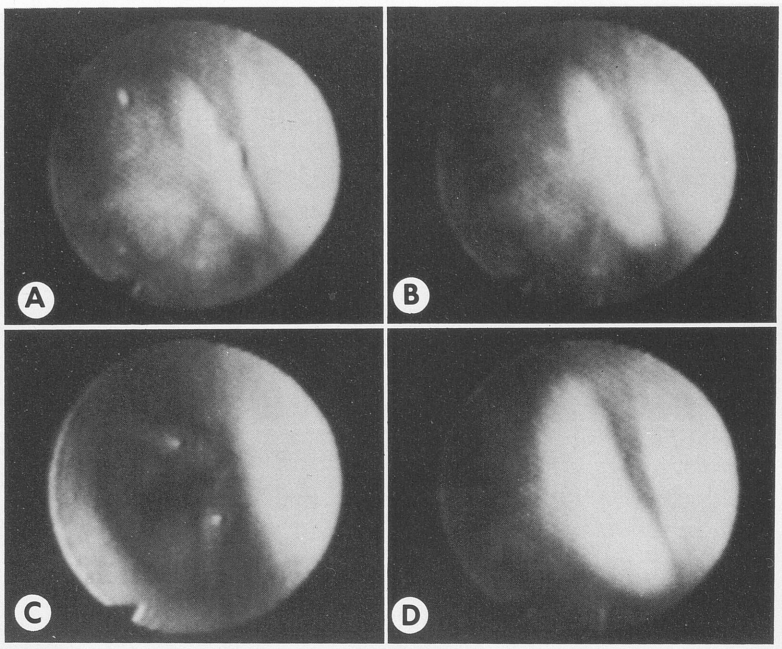

Fig 3. (Case 4) Severe obstruction during inspiration. Sequential frames of epiglottis and larynx during respiration. A) Epiglottis prolapse during inspiration. B) End of inspiration. C) Expiration. D) Beginning of inspiration.

complaints of daytime somnolence, nocturnal apnea, and stridor. When placed in a supine position, she became quite dyspneic. Flexible laryngoscopic examination and radiographic tests failed to show a recurrence. However, on fiberoptic laryngoscopy, the epiglottis was tilted in a posterior and horizontal position. With each inspiration, the epiglottis fluttered inferiorly and obstructed the laryngeal inlet. The patient was treated by tracheostomy followed by CO_2 laser endoscopic epiglottectomy to remove the superior half of the suprahyoid epiglottis.

She tolerated the procedure well and was decannulated immediately after the operation without incident. Immediately, she was able to sleep better and was able to lie flat. Follow-up at 2 years has shown an excellent airway with complete relief of obstructive sleep apnea. Figure 2 shows the preoperative view and the postoperative result. A better airway is observed after surgery.

Case 3. A 32-year-old man had blunt trauma to the neck with laryngeal fracture in 1984. He was treated

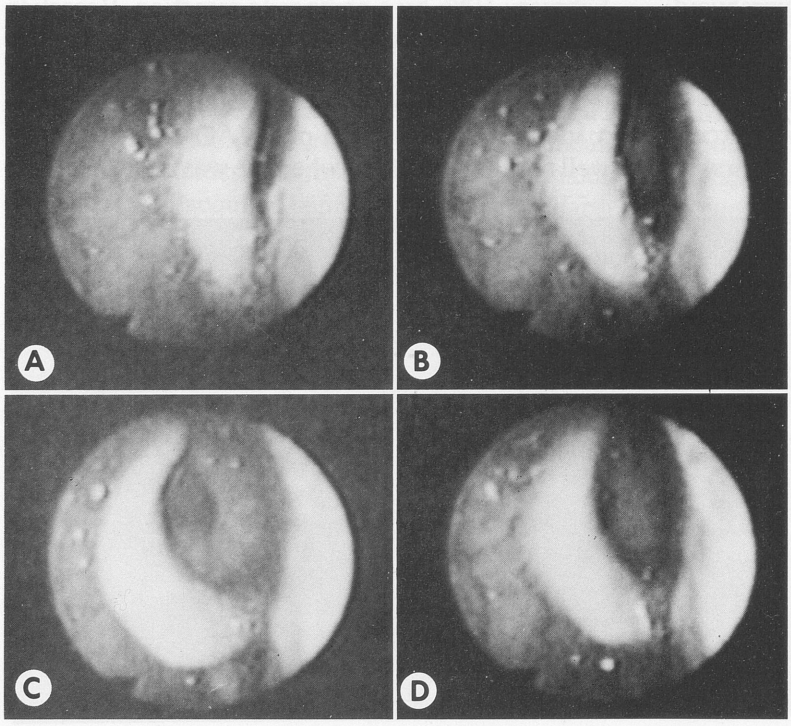

Fig 4. (Case 4) Mild obstruction. Sequential frames during respiration. Same patient as in Fig 3, 6 months later. A) Epiglottis prolapse during inspiration. B) End of inspiration. C) Expiration. D) Beginning of inspiration.

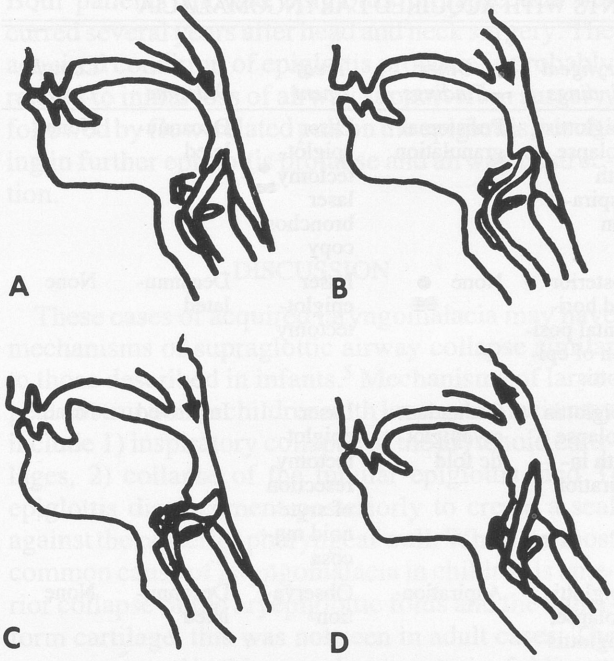

Fig 5. Schematic of flow-related collapse of epiglottis. A) Beginning of inspiration. B) Midcycle inspiration. C) Complete collapse at end of inspiration. D) Relief of airway obstruction during expiration.

elsewhere with thyrotomy, laryngeal stenting, and tracheostomy. He was decannulated successfully in 1985 after several operations. In June 1988, he came to the otolaryngology clinic because of progressive dyspnea with exertion, nocturnal airway obstruction, and inability to lie flat without dyspnea. Flexible fiberoptic laryngoscopy showed the following: the lingual tonsils were large, the hypopharynx was crowded, and the posterior tip of the epiglottis was touching the posterior pharyngeal wall (Fig 1B). With each inspiration, the epiglottis was drawn posteriorly into a horizontal position and collapsed against the posterior hypopharyngeal wall, thereby obstructing the airway. The vocal folds were mobile and the trachea was open. In addition to these findings, the aryepiglottic folds and the arytenoids also appeared swollen and redundant. The patient was treated by partial CO_2 laser epiglottectomy, and resection of redundant aryepiglottic folds. He had immediate relief of his airway symptoms. He remained free of symptoms 6 months later.

Case 4. A 49-year-old man was struck by a motor vehicle on May 23, 1988. He sustained closed head injury with coma. A tracheostomy was performed shortly after his injury. He was transferred to a neurologic rehabilitation center. On July 6, fiberoptic laryngoscopy was done to assess laryngeal function prior to attempted decannulation.

Fiberoptic examination showed a narrowed hypopharynx in that the tongue base was close to the posterior pharyngeal wall. The epiglottis was tilted in a horizontal position, occluding the larynx with each inspiratory effort. The patient was also aspirating his oral and pharyngeal secretions. Because of his aspiration, decannulation was delayed. Reexamination 6 months later showed a man with dramatically improved mental status, less aspiration, and markedly less epiglottis prolapse on inspiration. The hypopharyngeal dimension was also much wider and the epiglottis was less horizontally placed. Although the epiglottis still fluttered with inspiration, it was no longer touching the posterior pharyngeal wall. The patient was decannulated at that time without difficulty.

Reexamination 6 months later showed further improvement in mental status. Laryngoscopy revealed a normal-appearing larynx without posterior epiglottis prolapse or epiglottis flutter.

RESULTS

As part of this study, a retrospective review of videolaryngoscopy from 118 patients with severe closed head injuries was done. Of these, supraglottic airway obstruction due to epiglottis prolapse or epiglottis flutter was identified in 13 cases. The degree of obstruction varied from mild to severe. While only 6 patients were identified as having severe epiglottis prolapse as the cause for failure of decannulation, the rest had milder forms of obstruction by an abnormal epiglottis that contributed to stridor. All these patients were healthy prior to their neurologic insult. The types of central neurologic injury included diffuse anoxic injury, intracerebral hemorrhage, hydrocephalus, brain stem infarction, and closed head injury. All the patients with acquired epiglottis prolapse were in various degrees of coma on initial examination. Most still had a low score on the Glasgow Coma Scale. Common fiberoptic laryngoscopy findings in these patients included poor voluntary laryngeal and tongue control, poor neuromotor control to achieve pharyngeal dilation, and poor neuromotor control of deglutition. In these patients, despite their being examined in an upright posture, the epiglottis is tipped posteriorly and assumes a slightly horizontal posture. The tip of the epiglottis is in close proximity to the posterior pharyngeal wall. With inspiration, the epiglottis flutters and is displaced posteriorly and inferiorly. Upper airway obstruction occurs by impaction of the epiglottis against the posterior pharyngeal wall or by prolapse of the epiglottis onto the arytenoid and aryepiglottic folds.

The severity of airway obstruction is flow rate–dependent and is made worse by vigorous inspiratory efforts. Figure 3 is a sequential photograph of the

CLINICAL CHARACTERISTICS OF EIGHT PATIENTS WITH ACQUIRED LARYNGOMALACIA

Case	Age	Sex	Date of Injury	Date of Exam	Cause	Laryngeal Findings	Other Findings	Treatment	Outcome	Complications
1	19	M	7/3/88	9/14/88	Motor vehicle accident, coma	Epiglottis prolapse with inspiration	Peristomal granulation	Laser epiglottectomy, laser bronchoscopy	Decannulated	None
2	68	F	1/3/86	6/8/88	Suprahyoid cancer resection	Posterior and horizontal position of epiglottis	None	Laser epiglottectomy	Decannulated	None
3	27	M	1/5/86	7/2/88	Laryngeal fracture	Epiglottis prolapse with inspiration	Redundant aryepiglottic fold	Laser epiglottectomy, resection of arytenoid mucosa	Improved	None
4	49	M	5/23/88	2/6/88	Traumatic head injury	Epiglottis prolapse, epiglottis flutter	Aspiration	Observation	Decannulated	None
5	37	F	10/28/89	2/14/90	Bleeding aneurysm	Epiglottis prolapse with inspiration	Tracheal granulation	Laser epiglottectomy	Decannulated	Aspiration at 1 wk
6	26	F	1/29/89	6/28/89	Closed head injury	Epiglottis prolapse, posterior laryngeal web	Tracheal granulation	Epiglottectomy, web lysis	Decannulated	None
7	52	M	10/1/89	1/10/90	Brain stem stroke	Epiglottis prolapse, severe aspiration	Pharyngeal myoclonus	Total laryngectomy for aspiration	Laryngectomy	None
8	21	F	12/5/88	1/4/89	Closed head injury	Epiglottis prolapse, mild aspiration	Large tracheostomy tube	Observation, tube change	Decannulated	None

larynx (case 4) during respiration, showing the severe degree of airway obstruction occurring during inspiration. Figure 4 (case 4) shows the same patient after ventriculoperitoneal shunting followed by improved mental status. The improved mental status correlated well with improvements in the degree of supraglottic airway collapse.

Figure 5 is a schematic representation of the airflow-related collapse of the epiglottis. In the mild cases, only epiglottis fluttering was seen. In patients with severe obstruction, the epiglottis actually prolapsed into the supraglottic larynx and caused total airway obstruction during inspiration.

The Table summarizes the clinical data on the patients and their treatment. In four of the six head injury patients, other laryngotracheal abnormalities were identified. These included a posterior laryngeal web, suprastomal stenosis, and incomplete laryngeal abduction. However, in each case, the major cause of stridor was epiglottis prolapse (see Table). Corrective surgery by partial epiglottectomy relieved the symptoms in three of the six patients. In those not treated by surgery, improved mental status resulted in better neuromotor control, better pharyngeal dilation, and less epiglottis prolapse. This improvement in pharyngeal and laryngeal function correlated clinically with a decrease in degree of stridor. The cause of acquired upper airway collapse after head injury is believed to be loss of pharyngeal motor control. Although histologically normal, normal respiratory function is nevertheless compromised by epiglottis prolapse due to loss of central neuromotor control.

The other two patients had delayed onset of upper airway obstruction after head and neck surgery. One had surgical resection of the suprahyoid musculature for cancer, and the other had laryngeal fracture, thyrotomy, and injury to the hyoepiglottic ligament.

Both patients showed epiglottis prolapse that occurred several years after head and neck surgery. The acquired condition of epiglottis prolapse is probably related to initial loss of airway support from surgery, followed by flow-related pull on the epiglottis, resulting in further epiglottis prolapse and airway obstruction.

DISCUSSION

These cases of acquired laryngomalacia may have mechanisms of supraglottic airway collapse similar to those described in infants.[5] Mechanisms of laryngeal obstruction in children with laryngomalacia may include 1) inspiratory collapse of the arytenoid cartilages, 2) collapse of the tubular epiglottis, and 3) epiglottis displacement posteriorly to create a seal against the posterior pharyngeal wall. While the most common cause of laryngomalacia in children is anterior collapse of the aryepiglottic folds and the cuneiform cartilage, this was not seen in adult cases. The cases presented in this paper have posterior folding or "prolapse" of the epiglottis as the cause of airway obstruction.

Central nervous system disorders as a comorbidity in laryngomalacia has been recognized by previous authors. Belmont and Grundfast[6] noted a high association of neurologic disorders such as hypotonia and central apnea with congenital laryngeal stridor. Apley,[7] in his follow-up survey of 80 cases of infants with stridor, also noted a high incidence of disorders of the CNS, as compared with normal infants. He noted the abnormality as primarily one of movement, whereby the epiglottis and arytenoids are drawn into the larynx on inspiration. Laryngeal findings in our study are similar to the description noted in their paper. They include pharyngeal hypotonia, inspiratory movement of the epiglottis, and airway obstruction. The difference here is the acquired nature of laryngeal findings. All the patients presented here were previously healthy; they sustained a CNS insult or other injuries, developed epiglottis prolapse, and in some cases spontaneously resolved this condition with improvements in neural function.

These patients with acquired airway collapse hint at the importance of both extralaryngeal neuromotor control and intrinsic laryngeal structure to maintain airway support and patency. Kelemen, in his study on congenital laryngeal stridor, stated, "The suspension of the epiglottis is extremely loose. This fact is demonstrated (1) histologically by the areolar-adipose preepiglottic cushion, which continues...until it reaches the top of the ventricular appendix..."[8(p268)] Events leading to acquired laryngomalacia in our patients may follow these hypothetical steps: 1) loss of neuromotor control of the pharynx by CNS injury or loss of anatomic and muscular support by surgical resection of suprahyoid musculature and/or injury to the hyoepiglottic ligament; 2) loss of neuromotor control that narrows the anterior to posterior pharyngeal dimension, tipping the epiglottis horizontally against the posterior pharyngeal wall; 3) with inspiration, fast flow across a constricted pharyngeal orifice and the laryngeal surface of the epiglottis, resulting in a high negative pressure gradient (because of the Bernoulli phenomenon, this gradient results in sucking of the epiglottis into the larynx and causes inspiratory fluttering of the epiglottis); and 4) prolonged pull on the epiglottis, resulting in further weakening of the epiglottis suspensory ligaments and worsening airway obstruction.

Recognition of epiglottis prolapse as a cause of airway obstruction may prevent unnecessary long-term tracheostomy dependency and repeated surgery. In case 1, the failure to recognize this entity resulted in a second surgical procedure.

Treatment for this condition is directed toward reversal of the flow constriction. In those with spontaneous resolution of head injury, improved pharyngeal control and improved pharyngeal tone results in a widened anterior to posterior pharyngeal diameter and spontaneous improvement in respiratory difficulties. In those with no spontaneous improvement, the principle of surgical treatment is similar to those of treatments proposed for congenital laryngomalacia.[9,10] Carbon dioxide laser epiglottectomy or laser epiglottoplasty is performed to reverse the flow-induced obstruction. By trimming the top half of the suprahyoid epiglottis, flow-induced epiglottis prolapse is alleviated. Partial epiglottectomy has been tolerated well with little effect on swallow function. Although one patient had worsened aspiration for 1 to 2 weeks after laser epiglottectomy, no lasting sequelae have been observed after epiglottectomy.

In summary, acquired epiglottis prolapse may be a cause of obstructive apnea and failure to be decannulated after tracheostomy. Eight cases are reported. Most patients have central neurologic injury resulting in poor pharyngeal control and support; some patients may develop this condition after surgical resection of suprahyoid muscles and injury of epiglottis support. Clinical history and symptoms include inspiratory stridor, obstructive sleep apnea, and positional dyspnea. Fiberoptic laryngoscopy and video documentation is most useful in establishing the diagnosis. Awareness of this entity helps in planning appropriate surgical and nonsurgical treatment.

REFERENCES

1. Cotton RT, Reilly JS. Congenital malformations of the larynx. In: Bluestone CD, Stool SE, eds. Pediatric otolaryngology. Philadelphia, Pa: WB Saunders, 1990:1121-8.

2. Templer J, Hast M, Thomas JR, Davis WE. Congenital laryngeal stridor secondary to flaccid epiglottis, anomalous accessory cartilages and redundant aryepiglottic folds. Laryngoscope 1981;91:394-7.

3. Peron DL, Graffino DB, Zenker DO. The redundant aryepiglottic fold: report of a new cause of stridor. Laryngoscope 1988;98:659-63.

4. Kletzker GR, Bastian RW. Acquired airway obstruction from histologically normal, abnormally mobile supraglottic soft tissues. Laryngoscope 1990;100:375-9.

5. Holinger LD, Konior RJ. Surgical management of severe laryngomalacia. Laryngoscope 1989;99:136-42.

6. Belmont JR, Grundfast K. Congenital laryngeal stridor (laryngomalacia): etiologic factors and associated disorders. Ann Otol Rhinol Laryngol 1984;93:430-7.

7. Apley J. The infant with stridor: a follow-up survey of 80 cases. Arch Dis Child 1953;28:423-35.

8. Kelemen G. Congenital laryngeal stridor. Arch Otolaryngol 1953;58:245-68.

9. Zalzal GH, Anon JB, Cotton RT. Epiglottoplasty for the treatment of laryngomalacia. Ann Otol Rhinol Laryngol 1987; 96:72-6.

10. Kavanagh KT, Babin RW. Endoscopic surgical management for laryngomalacia. Case report and review of the literature. Ann Otol Rhinol Laryngol 1987;96:650-3.

SPECIAL INSTRUMENTS FOR LARYNGEAL FRAMEWORK SURGERY

NOBUHIKO ISSHIKI, MD
HISAYOSHI KOJIMA, MD MASAKI SAWADA, MD
KYOTO, JAPAN

Thyroplasties involve a variety of delicate surgical techniques that affect the outcome decisively. In particular, opening a window in the thyroid cartilage, undermining around the window frame and fixation of a window plug in thyroplasty, and passing a suture through the muscular process and thyroid ala are some examples of difficult procedures. Several instruments were devised to facilitate such procedures. They include a special raspatory, an ultrasonic osteotome for cartilage cutting, a narrow polyvinyl tube for suture passing, a suture holder for passing through the muscular process, and a wound retractor for arytenoid adduction. These were found useful in minimizing soft tissue damage and in precise performance of the procedures.

KEY WORDS — instruments, laryngeal framework surgery, thyroplasty, ultrasonic osteotome.

The voice result after laryngeal framework surgery largely depends on how it was performed, especially in terms of design and expertise of each surgical step. In thyroplasty type I, for instance, a rectangular window must be made at the right place on the thyroid ala with minimal damage inside the inner perichondrium so that intraoperative adjustment to the voice will be accurate. Several instruments have been found useful for this purpose.

INSTRUMENTS FOR THYROPLASTY TYPE I

Ultrasonic Osteotome. Fenestration in the thyroid ala is usually done with a B-P No. 11 blade in women and with a fine bur in older men whose thyroid cartilage is calcified. In order to avoid inadvertent cutting of the inner perichondrium, the last deep, thin layer of the cartilage is often cracked gently with a hemostatic chisel rather than cut with a knife.

A new instrument has recently been developed to cut hard material only, avoiding any damage to soft tissue underneath such as blood vessels. It is the ultrasonic osteotome (Sumisonic ME-2400, Sumitomo Bakelite Co, Ltd).

Figure 1 schematically shows a horn tip of the instrument that vibrates to and fro at an ultrasonic frequency with an amplitude of 200 μm. A water shower from the back of the blade automatically cools the heat resulting from friction. The soft tissue underneath is not cut, because it is easily distorted in accordance with the vibration, as illustrated. Be-

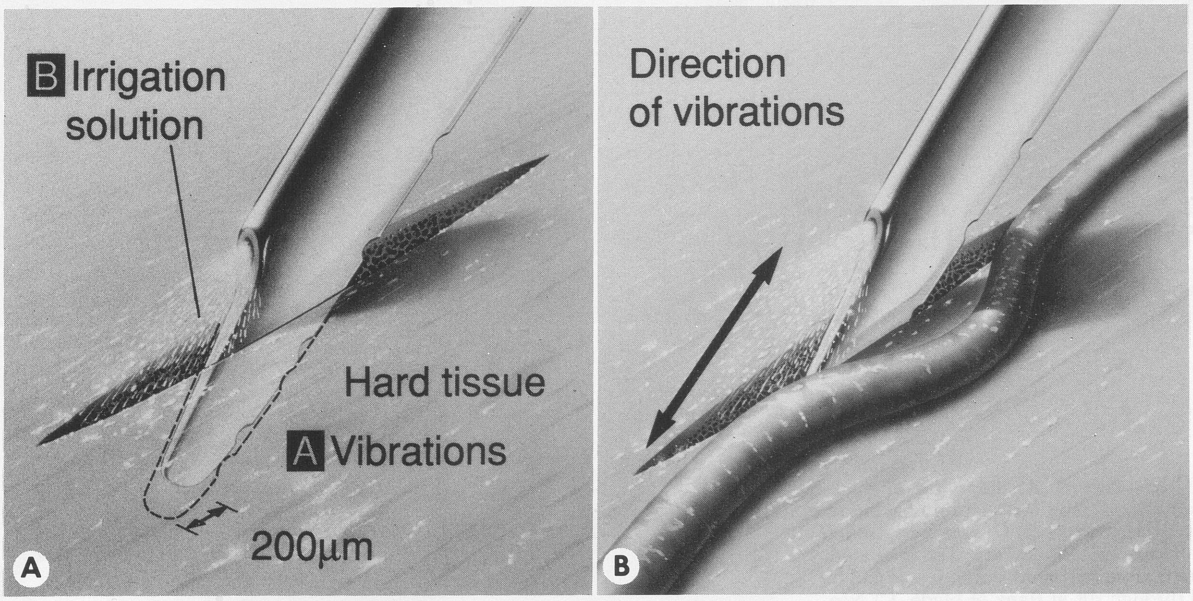

Fig 1. Schematic illustration of ultrasonic osteotome. A) Tip of instrument vibrates at ultrasonic frequency, cutting hard material only. Shower is provided from horn to cool friction heat. B) Soft tissue underneath will not be cut.

From the Departments of Plastic Surgery (Isshiki, Sawada) and Otorhinolaryngology (Kojima), Kyoto University, Kyoto, Japan.
Presented at the meeting of the American Laryngological Association, Waikoloa, Hawaii, May 4-5, 1991.
REPRINTS — Nobuhiko Isshiki, MD, Dept of Plastic Surgery, Medical School, Kyoto University, Sakyo-ku, Kyoto 606, Japan.

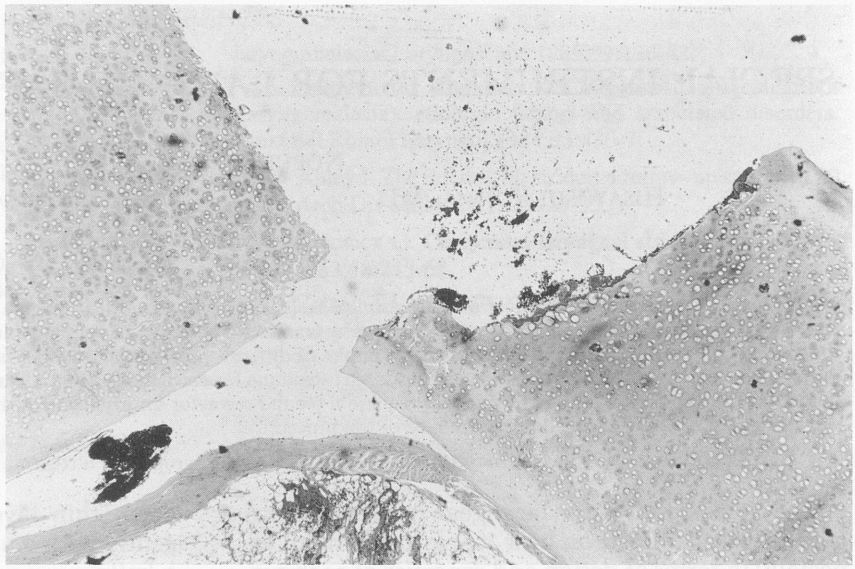

Fig 2. Histologic findings in incised rabbit rib cartilage and intact underlying soft tissue.

fore clinical application, a series of experiments were conducted in the rabbit to assess the extent of damage to the soft tissue under the rib cartilage. Histologic examinations of the composite hard and soft tissue to which the ultrasonic osteotome was applied all revealed intact soft tissue (Fig 2). This finding has led us to use it in laryngofissure and thyroplasty. During the procedure of cutting through the cartilage, not a drop of bleeding was noted. There is no doubt of the intended effect. The disadvantages would be its price and the water shower required to cool the heat accumulation.

Because it is expensive, we only borrowed it for a while for a pilot study. The high-pressure shower may accelerate the development of local edema.

Fixation of Window. Medialization of the vocal cord is adjusted during thyroplasty type I by trying plugs of various thicknesses. A thickness-adjustable silicone plug was produced (Fig 3A). It can be

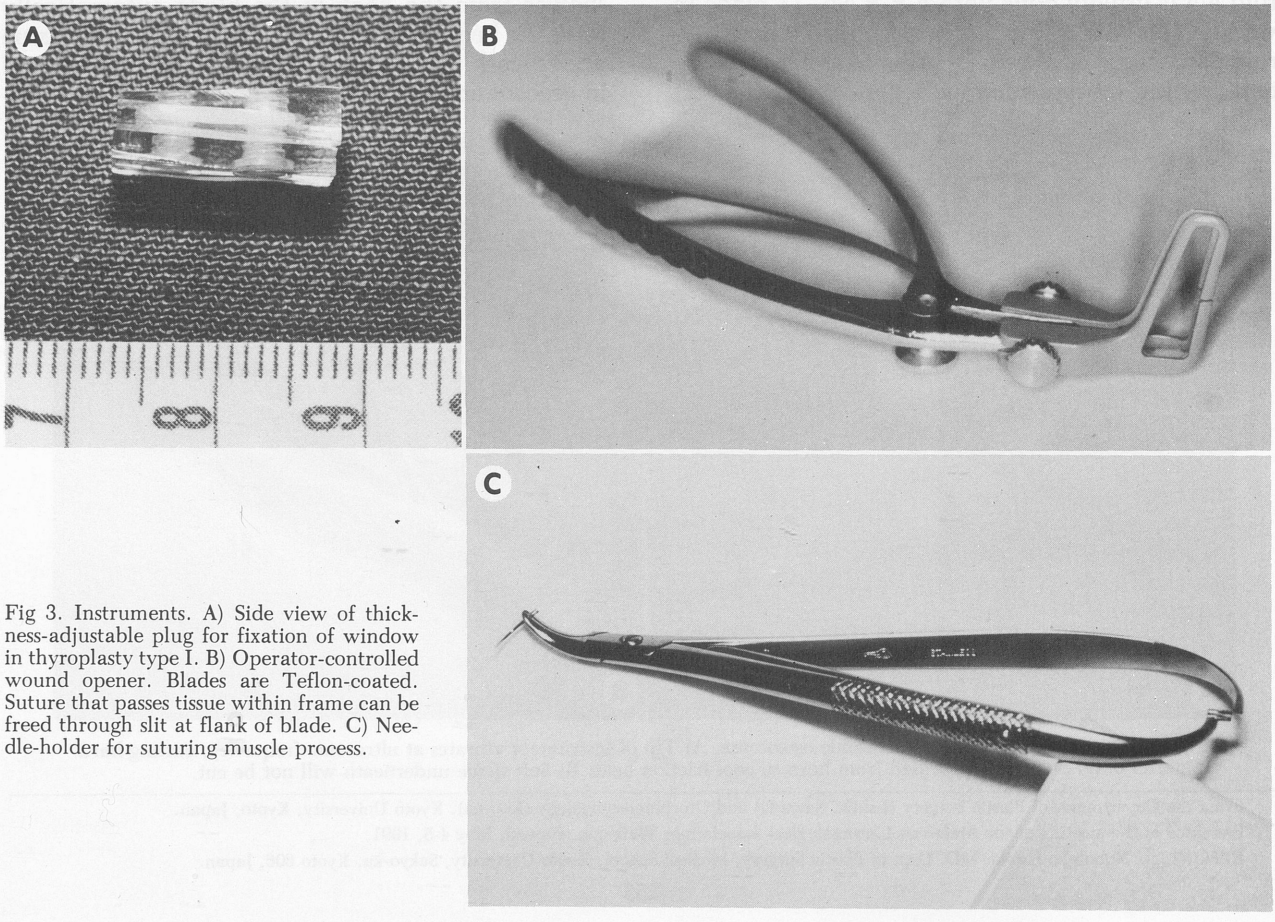

Fig 3. Instruments. A) Side view of thickness-adjustable plug for fixation of window in thyroplasty type I. B) Operator-controlled wound opener. Blades are Teflon-coated. Suture that passes tissue within frame can be freed through slit at flank of blade. C) Needle-holder for suturing muscle process.

screwed down to produce fine adjustments in thickness during surgery. It may be useful also for adjustment of medialization in a second operation, which may become necessary because of later atrophy or subsidence of edema of the vocal cord after the initial operation.

ARYTENOID ADDUCTION

Arytenoid adduction is generally more effective in medializing the vocal cord than thyroplasty type I. Difficulty in arytenoid adduction technique may be in 1) access to the muscular process, 2) suturing the process, or 3) adjustment of adduction to the voice.

The former two problems can be eased considerably by using a special wound opener and a needle holder. The wound opener is basically a type of nasal speculum that is controlled by one hand of the surgeon (Fig 3B).

It is modified, however, in two ways: the blades take the shape of a frame with a narrow opening so that one can obtain better vision and can pass the needle for suturing through the tissue that is squeezed from within the frame. A narrow opening at the flank of the frame is necessary when the passed suture is freed from the opener. The frame blades are silicone-coated to enable relatively safe electrocoagulation by means of a metal suction tube inserted between the opener blades.

Passing a needle through the muscular process within a deep and narrow surgical field is another procedure that is difficult to perform. A needle holder with a curved tip was found to be helpful (Fig 3C).

Several instruments are reported that facilitate surgical procedures in laryngeal framework surgery. Some are practical and others still need further modification.

INJECTION AND REMOVAL OF TEFLON FOR UNILATERAL VOCAL CORD PARALYSIS

HERBERT H. DEDO, MD

SAN FRANCISCO, CALIFORNIA

For over 70 years, reinnervation attempts have been unsuccessful in restoring motion to paralyzed vocal cords, in spite of occasional claims to the contrary. Fortunately, the major defect of unilateral vocal cord paralysis, a soft and breathy voice, can be eliminated if the edge of the paralyzed vocal cord is moved to the midline. This permits the mobile vocal cord to adduct and therefore to vibrate firmly against the edge of the paralyzed vocal cord during phonation, eliminating the air leak between the vocal cords. Teflon injection of the paralyzed vocal cord does this effectively. It is accomplished most easily and reliably via indirect laryngoscopy under local anesthesia, so the effect on the voice can be monitored during the injection. Teflon can be easily removed from the vocal cord via direct laryngoscopy. The disadvantages of trying to medialize the edge of a paralyzed vocal cord via a window in the thyroid cartilage (laryngeal framework surgery) will be discussed.

KEY WORDS — laryngeal framework surgery, medialization, neuromuscular grafts, recurrent laryngeal nerve paralysis, superior laryngeal nerve paralysis, Teflon injection, vocal cord.

PROBLEM

Two distinct categories of unilateral vocal cord paralysis exist: pure recurrent laryngeal nerve (RLN) paralysis and RLN plus superior laryngeal nerve (SLN) paralysis. These differences, plus variation in paralyzed vocal cord muscle atrophy and contracture and compensation by the mobile vocal cord, explain the variations seen in paralyzed vocal cord shape and position, and therefore voice breathiness and weakness both before and after medialization of the edge of the paralyzed vocal fold. Unilateral RLN paralysis leaves the ipsilateral vocal cord in the paramedian position (Fig 1A-D) and RLN + SLN paralysis places the edge more laterally in the intermediate position (Fig 1E,F).[1] With RLN paralysis during phonation, however, the arytenoid of the paralyzed vocal cord still adducts 1 to 2 mm and closes the posterior third of the glottis because of cricothyroid muscle plus interarytenoid muscle contraction (Fig 1D). With RLN + SLN paralysis, the ipsilateral cricothyroid muscle is also paralyzed, so only the partial interarytenoid muscle contraction remains, because half its motor nerve supply is still available from the intact RLN, to partially adduct the posterior edge of the arytenoid. As a result, in RLN + SLN paralysis the arytenoid drifts slightly laterally from the midline (Fig 1E,F). This leaves a 2-mm gap or chink between the arytenoids during phonation. Also, there is a wider chink between the membranous vocal cords, because the closing and tensing action of the cricoarytenoid muscle is lost and there is more vocal cord atrophy (and thus thinning) when both the SLN and RLN are paralyzed. Therefore, more air leakage, weakness, breathiness, and diplophonia — or, in some patients, paralytic falsetto (from overcompensation by the mobile cord) — occur during phonation in patients with RLN + SLN paralysis than in those with RLN paralysis alone.

Since medialization of the membranous vocal cord with Teflon injection, laryngeal framework surgery, or neural grafts cannot close this posterior gap or chink, voice results in RLN + SLN paralysis patients usually are not quite as good as in patients with pure RLN paralysis. This has not been emphasized enough, so surgeons and patients have not been prepared to accept a slightly breathy phonatory voice as being a good result in these combined RLN + SLN paralysis cases. If the patient wishes, the posterior third chink can still be treated with arytenoid medialization.[2] The improvement in RLN + SLN patients is usually more dramatic than in RLN patients, since their voice starts from a much worse level — often only a very breathy stage whisper. They are usually delighted with the result and do not wish an open operation. The typical result after medialization in pure RLN paralysis is a voice improvement from a mildly or moderately breathy phonatory voice to a clear, nonbreathy, phonatory one. Diplophonia and paralytic falsetto, if present, can also be eliminated if Teflon injection is performed correctly. Since surgeons generally have not been trying to identify whether an apparently paralyzed vocal cord is due to paralysis of the RLN or RLN + SLN (or cricoarytenoid joint fixation), they have not prepared themselves or their patients for the possibility that the patient's breathy, weak voice may be improved, often dramatically, but not made fully normal by medialization of the paralyzed membranous vocal cord.

Some doctors — whose patients have subsequent-

From the Department of Otolaryngology–Head and Neck Surgery, University of California, San Francisco, California.

Presented at the meeting of the American Laryngological Association, Waikoloa, Hawaii, May 4-5, 1991.

REPRINTS — Herbert H. Dedo, MD, Dept of Otolaryngology–Head and Neck Surgery, University of California, San Francisco, 400 Parnassus Ave, A735, Box 0342, San Francisco, CA 94143-0342.

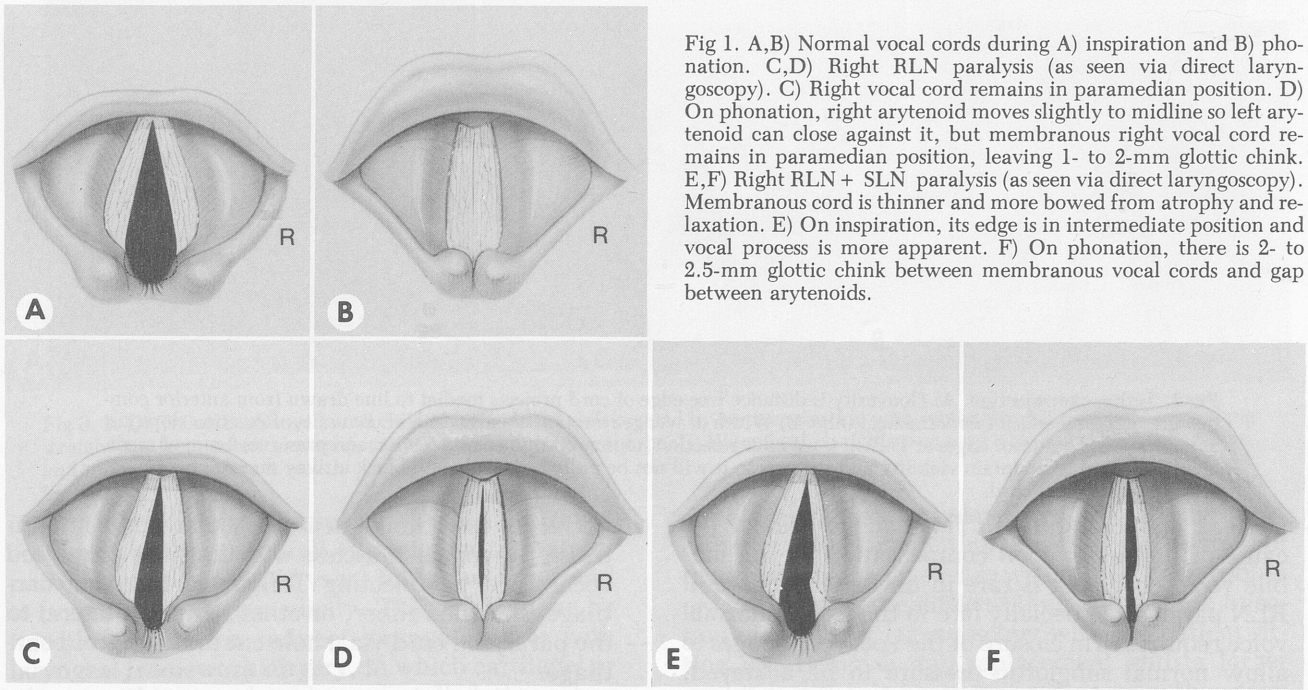

Fig 1. A,B) Normal vocal cords during A) inspiration and B) phonation. C,D) Right RLN paralysis (as seen via direct laryngoscopy). C) Right vocal cord remains in paramedian position. D) On phonation, right arytenoid moves slightly to midline so left arytenoid can close against it, but membranous right vocal cord remains in paramedian position, leaving 1- to 2-mm glottic chink. E,F) Right RLN + SLN paralysis (as seen via direct laryngoscopy). Membranous cord is thinner and more bowed from atrophy and relaxation. E) On inspiration, its edge is in intermediate position and vocal process is more apparent. F) On phonation, there is 2- to 2.5-mm glottic chink between membranous vocal cords and gap between arytenoids.

ly required partial Teflon removal — have injected too much Teflon either initially or later in their mistaken attempt to close the posterior-third gap between the arytenoids and to stop the breathiness (Fig 2). Posterior glottic closure is impossible with Teflon overinjection of the membranous cord. Instead, a bigger posterior gap is created, because the mobile cord is held back by the bulging paralyzed vocal cord and the vibration of the mobile cord is interfered with so that the voice is made husky and coarse, or gravelly. Failure to recognize and accept the limitations of medialization of the membranous portion of a paralyzed vocal cord has not only caused surgeons to overinject cords, it has also caused them to change from Teflon injection to insertion of cartilage or silicone rubber into the paralyzed vocal cord via an open neck incision (laryngeal framework surgery),[2,3] or to attempt laryngeal reinnervation.[4,5] Laryngeal framework surgery and reinnervation have been criticized as being less reliable, being harder on the patient, requiring Gelfoam injection,[6] and costing more than Teflon injection, while they do not provide a better voice. Initially, it was hoped that reinnervation would achieve remobilization of a paralyzed vocal cord. Now it is acknowledged that reinnervation does not achieve normal mobility,[6] and at best it may only medialize the edge of the cord so slightly after many months[5-12] that it has still been necessary to inject Gelfoam into the vocal cord.[6] In my experience, neural or neuromuscular grafting has not medialized the paralyzed vocal cord edge as reliably, inexpensively, and rapidly or as easily for the patient as Teflon injection via indirect laryngoscopy[12,13] — even when performed by its proponents in patients I have seen later.

CLASSIFICATION OF VOICE ABNORMALITY CAUSED BY UNILATERAL VOCAL CORD PARALYSIS

I use the following informal system to classify the degree or type of hoarseness caused by vocal cord paralysis. Incomplete or weak closure of the mobile vocal cord edge with the edge of the paralyzed vocal cord during phonation causes a voice weakness (poor projection or softness) and breathiness because of the air leakage between the vocal cords during phonation. If a large enough glottic chink or incompetence (2 to 3 mm at the widest point between vocal processes of arytenoids, usually from RLN + SLN paralysis) is present so one or both vocal cords fail to be thrown into vibration or oscillation, a pure whisper or white noise type 4 voice will result. If there is a slightly narrower chink, with some vibration of at least one vocal cord releasing puffs of air plus white noise from the continuous air leak, there will be a stage whisper (ie, whisper and some actual phonation) or a type 3 voice. This may be seen in an early pure RLN paralysis, but in a late paralysis (after 4 to 6 months of compensation) it is usually a result of RLN + SLN paralysis.

If there is a narrower gap during phonation (1 to 2 mm), a moderately breathy phonatory type 2 voice will result. If the mobile cord appears to close against the paralyzed vocal cord so no glottic chink is visible, but the closure is weak, the voice will be a slightly breathy phonatory type 1 voice, especially when the patient is fatigued or has been talking very much.

A soft normal or solid (ie, nonbreathy) phonatory voice occurs when the vocal cords close firmly enough between each vibration to prevent constant

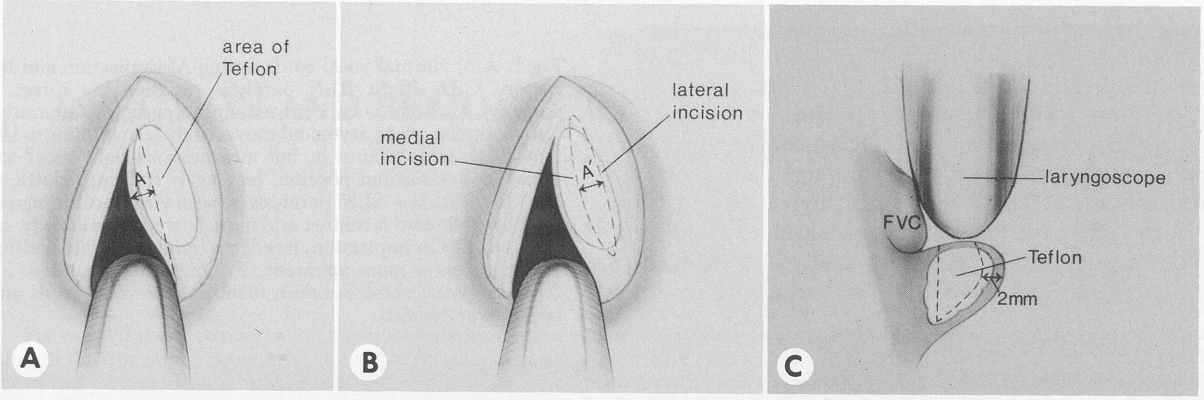

Fig 2. Teflon overinjection. A) Convexity is distance free edge of cord projects medial to line drawn from anterior commissure to lateral edge of endotracheal tube. B) Width of wedge resection equals width of convexity. Resection stops just at anterior and posterior edges of Teflon. C) Wedge resection stops at bottom edge of Teflon and preserves 2 mm of medial edge of cord to maintain viability and stiffness so it will not be pulled medially and block airway during inspiration. FVC — false vocal cord.

air leak and breathiness. This can be present because of unusually good compensation by the mobile vocal cord, but is rare in untreated unilateral RLN paralysis, especially late in the day. A normal voice requires firm closure of the vocal cord edges to allow normal subglottic pressure to be achieved, and therefore normal volume to be reached, during phonation.

A paralytic falsetto (abnormally high fundamental speaking frequency) voice occurs when the mobile vocal cord overcompensates while closing the chink, so while it eliminates the air leak and breathiness, it is stretched so tightly that its frequency of vibration is elevated above normal.

Diplophonia is the production of a harsh, husky, or gravelly voice that sounds as if there is mucus on the vocal cords when none is seen on indirect laryngoscopy. It is the result of the lesser mass and tension in the paralyzed vocal cord, causing it to vibrate at a lower frequency than the normal vocal cord.

SOLUTION

Since normal motion cannot be surgically restored to a paralyzed vocal cord,[6] effective treatment requires its edge to be repositioned medially. If the edge of a paralyzed vocal cord is moved to the straight midline position, the air leak and therefore the breathiness and weakness (or paralytic falsetto, if present) will be eliminated. A near-normal or normal phonatory voice will be achieved because one or both vibrating vocal cords will be letting out strong puffs of air. If paralytic falsetto is present, it will be lowered or eliminated because the mobile, intact vocal cord will not have to be pulled so tight longitudinally in compensation. If diplophonia persists, injection of a little more Teflon to stop the abnormal vibration of the paralyzed vocal cord can eliminate it.

Three basic approaches have been used to medialize the edge of the paralyzed vocal cord: distal RLN anastomosis to proximal RLN or other motor nerves, or insertion of neuromuscular grafts into intrinsic laryngeal muscles; widening the paralyzed vocal cord by injecting Teflon; or inserting cartilage, silicone rubber, or other materials lateral to the paralyzed cord via a hole cut in the thyroid cartilage.

Anastomosis of the ends of the severed RLN or of the distal RLN to another motor nerve in the area has been performed in humans by many surgeons for more than 70 years (when the severed ends could be found and joined) without restoring effective adduction during phonation, although resting tone may be improved after many months.[5-11] Visible adduction during phonation could not be achieved after prolonged follow-up, even when 16-0 monofilament nylon sutures and microsurgical techniques were used under ideal conditions on freshly cut RLNs in dogs.[12]

Neuromuscular grafts from local motor nerves and insertion of their motor end plates into laryngeal muscles have not recovered effective motion or reliable repositioning. The ansa hypoglossi–omohyoid[4] has been anastomosed into the posterior cricoarytenoid muscle for bilateral RLN paralysis in the hope of opening a paralyzed vocal cord during inspiration. Vagus, ansa hypoglossus, and phrenic nerve fibers or motor end plates have been inserted into the thyroarytenoid muscle to try to achieve adduction during phonation. These procedures have failed to reliably restore effective or useful motion that is visible on indirect laryngoscopy or on film — even when performed by the proponents of reinnervation.[4,5,11,13] Lately, some authors have admitted that normal motion was not regained from nerve transfer, but they claimed increased tone moved the vocal cord edge medially.[6] If it was so effective, however, why was it necessary in addition to inject Gelfoam into the vocal cord? Based on the results I have seen, reinnervation is neither consistent nor reliable.[13]

The most reliable, effective technique for achiev-

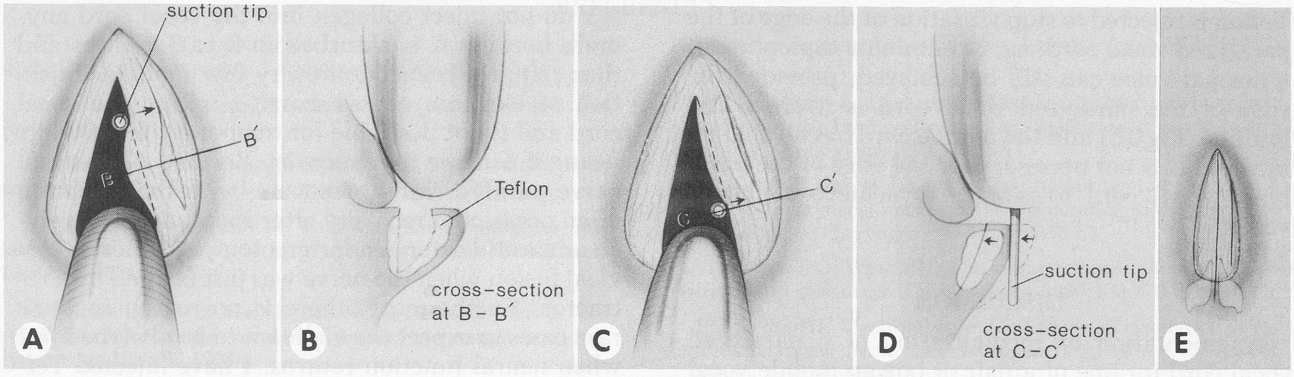

Fig 3. A-D) Teflon is removed until collapse of width of cleft created by wedge resection with suction tip puts free cord edge along straight line from anterior commissure to edge of endotracheal tube. E) When healed, right vocal cord edge is straight and midline, and mobile cord meets it well.

ing the best voice for a patient with unilateral vocal cord paralysis is to install material in the lateral portion of the paralyzed vocal fold to widen it and to push its free edge medially. This can be done by injecting Teflon via indirect laryngoscopy or with laryngeal framework surgery, in which cartilage[2] or silicone rubber wedges[2,3] are installed through a window made in the thyroid cartilage.

Teflon injection and insertion of cartilage or silicone rubber wedges in the lateral portion of the membranous vocal cord are similar in that they do not medialize the arytenoid because it is posterior to the area that can be augmented.[2,13] Also, if a large amount of foreign material is installed, the free edge of the paralyzed vocal cord will not vibrate, although this will not hurt the voice if the edge of the cord ends up straight and midline and if the mobile cord is normal. Since cartilage or silicone is placed lateral to the vocal cord, however, the cord can vibrate if a small amount is placed. Teflon also is injected lateral to the vibrating edge, and if the correct amount is used, the edge can vibrate just as well in synchrony with the mobile vocal cord. Both procedures require considerable experience with the technique and attention to detail to get the best results.

The laryngeal framework approach has several disadvantages. Installing silicone or cartilage wedges through a hole made in the thyroid cartilage requires a neck incision. The procedure usually takes more than an hour, allowing edema to accumulate in the vocal cord and causing difficulty in judging how large a block of foreign material to install, as well as prolonging patient discomfort. Increasing or decreasing the medialization of the cord edge subtly and rapidly is difficult. The relatively large block of foreign material can be displaced or become infected, necessitating removal through another open neck operation. The vocal cord must be observed through a fiberoptic laryngoscope, which gives a grainy, less precise view of the vocal cord edge than a mirror examination does on indirect laryngoscopy. The patient must be lying down under a drape, possibly sedated or under a general anesthetic; hence, evaluating the effect on the voice of the insertion of a given size wedge of silicone rubber or cartilage is more difficult than with Teflon injection via indirect laryngoscopy with the patient sitting up. Removal and replacement with a larger wedge is difficult because it requires another open operation. In addition, the procedure is two to three times as expensive as Teflon injection.

Advantages of Teflon Injection. I prefer Teflon injection via indirect laryngoscopy because it only takes about 10 minutes — 9½ minutes to topically anesthetize and a few seconds to inject — using the technique shown in detail in my surgical atlas.[13] Thus, it is easier on the patient and can be completed before edema distorts the vocal cord. This is important because subtle edema starts to accumulate in the paralyzed vocal cord within 2 to 5 minutes after the first needle insertion. If there is delay in completion of the medialization, this causes difficulty in seeing and hearing whether the correct amount of medialization has been achieved. Using Teflon paste, the vocal cord can be gradually widened by very small (0.1 mL) increments until the cord edge is midline while it is seen clearly and well in the mirror. Then the needle is withdrawn to a point just above the cord so it will not cause distortion, the patient is asked to say "he" or "ho," and the effect on the vocal cord and voice quality is confirmed by auditory perception. If a little more Teflon is required, it is injected and then the undersurface bulge is massaged back with the needle shank.[13]

The injected Teflon is in microscopic particles, so it is well tolerated by the tissues.[14] (I have only seen late convexity develop in the cord edge in 2% to 3% of patients.) The patient is sitting up and is not under a drape, so he or she can phonate and talk normally and easily. Teflon injection is cost-effective. If necessary (eg, if too much is injected, cord motion returns, or a rare, small intracordal granuloma develops), the Teflon is easily removed partially or completely via direct laryngoscopy[13,15] without a neck incision (Figs 2 and 3). If enough

Teflon is injected to stop vibration of the edge of the paralyzed vocal cord, eg, to eliminate diplophonia, a normal voice can still be achieved, provided the edge of the paralyzed vocal cord is straight and midline (Fig 3E) and the mobile cord has normal vibration. It is not necessary for the edge of the paralyzed vocal cord to vibrate to achieve a normal voice!

DISCUSSION

Augmentation or medialization of a paralyzed vocal cord (or one of a pair of bowed mobile vocal cords, as can occur in the elderly) is a form of vocal plastic surgery or phonosurgery. The unwanted vocal characteristics such as breathiness, weakness, paralytic falsetto, or diplophonia can be decreased or eliminated in a graded fashion that must be matched to the severity of the voice abnormality. Vocal cord medialization is similar to facial plastic surgery, liposuction, or breast augmentation in that the amount of material added or subtracted is important. In fact, in the vocal cord a one-drop difference in injected volume and a 1- to 2-mm difference in location of the paralyzed cord edge can have a large effect on the voice. As with surgery in general and plastic surgery in particular, the correct selection of patients and a precise surgical technique are very important in phonosurgery. Straightening and moving the medial edge of the vocal cord 1 to 2 mm to the midline can dramatically improve the voice, but bulging it 1 to 2 mm past the midline can eliminate the improvement and cause a rough and husky or gravelly voice that may be a disappointment.

The difficult part of Teflon injection via indirect laryngoscopy is developing eye-hand facility in inserting the curved needle into the vocal cord lateral to the vocal process of the arytenoid while looking at it in a laryngeal mirror. This is because the mirror image makes the needle appear to move to the right when the eye and hand try to move it to the left. This skill can be learned in vitro, however, by practicing with a headlight and laryngeal mirror while moving and positioning a curved Teflon injection needle on a Bruening syringe (Storz Instrument Co, St Louis, Mo) into a vocal cord drawn on a rubber glove or a piece of chicken breast placed in a small can.

The amount to be injected (usually only two to four clicks) is relatively easy to determine by watching the vocal cord edge and listening to the decreasing breathiness and increasing voice strength and clarity during trial phonations as this edge is moved to the straight midline position, allowing the mobile cord to close against it firmly. The skills required in installing the correct size, shape, and location of a cartilage or silicone rubber insert via a hole in the thyroid cartilage are not practiced so easily in vivo or in vitro.

I do not inject collagen into the vocal cord anymore because it is absorbed in 2 to 3 months and thus requires reinjection every few months. Injection of Gelfoam causes scarring within the vocal cord and is not desirable for temporary relief while seeing if a nerve may recover. Recurrent laryngeal nerve paralysis rarely recovers, with the exception of an occasional recovery after spontaneous paralysis or carotid artery endarterectomy or anterior cervical fusion when the nerve was just bruised by a retractor. Furthermore, there is no reason in these rare cases to expect the Gelfoam to be absorbed just when neural function returns. I have injected Teflon when there is a small chance of spontaneous recovery of motion and the patient cannot wait 6 to 12 months (eg, because of aspiration or loss of a job due to a weak voice). In two of my cases in which the paralysis cleared, the Teflon was removed without losing cord motion.[13,15]

SUMMARY

Neural or neuromuscular anastomosis and framework surgery do not restore normal vocal cord motion and at best may increase thyroarytenoid muscle tone and volume slightly. If these techniques do improve a voice, open surgery is required, which is more extensive, prolonged, expensive, and less reliable than Teflon injection done correctly. Also, with neural anastomosis or neuromuscular grafts, months — not minutes — will pass before voice improvement occurs, if it does. These patients may still need injection of material into the paralyzed cord to achieve proper medialization.

Teflon injection can be technically challenging at first for the surgeon. In my opinion, which is based on performing more than 400 Teflon vocal cord injections via indirect laryngoscopy and 8 via direct laryngoscopy under general anesthesia (required because of severe gagging, vertigo, paraplegia, etc), this is the easiest (for the patient), safest, most reliable, and most effective available means of restoring the best possible voice after unilateral vocal cord paralysis. Very small increments of Teflon can be injected while the surgeon observes the vocal cord and listens to the patient's voice to determine the correct end point. Then the inferior surface of the vocal cord can be molded slightly with the side of the needle as necessary, because the vocal cord is plastic until fibrosis fixes the Teflon particles in place 2 to 3 weeks postoperatively. If the minimum required amount of Teflon is placed laterally and posteriorly in the membranous paralyzed vocal cord, the free edge of the cord will vibrate in synchrony with the normal cord, although vibration of the edge of the paralyzed cord is not necessary to create a clear, solid phonatory voice. Teflon can easily be partially or completely removed later via direct laryngoscopy, if necessary.

REFERENCES

1. Dedo HH. The paralyzed larynx: an electromyographic study in dogs and humans. Laryngoscope 1970;80:1455-517.

2. Isshiki N. Phonosurgery: theory and practice. Tokyo, Japan: Springer-Verlag, 1989.

3. Koufman JA. Laryngoplasty for vocal cord medialization: an alternative to Teflon. Laryngoscope 1986;96:726-31.

4. Tucker HM, Rusnov M. Laryngeal reinnervation for unilateral vocal cord paralysis: long-term results. Ann Otol Rhinol Laryngol 1981;90:457-9.

5. Crumley RL, Izdebski K, McMicken B. Nerve transfer versus Teflon injection for vocal cord paralysis: a comparison. Laryngoscope 1988;98:1200-4.

6. Crumley RL. Update: ansa cervicalis to recurrent laryngeal nerve anastomosis for unilateral laryngeal paralysis. Laryngoscope 1991;101:384-8.

7. Siribodhi C, Sundmäker W, Atkins JP, Bonner FJ. Electromyographic studies of laryngeal paralysis and regeneration of laryngeal motor nerves in dogs. Laryngoscope 1963;73:148-64.

8. Tashiro T. Experimental studies on the reinnervation of larynx after accurate neurorrhaphy. Laryngoscope 1972;82:225-36.

9. Murakami Y, Kirchner JA. Vocal cord abduction by regenerated recurrent laryngeal nerve. An experimental study in the dog. Arch Otolaryngol 1971;94:64-8.

10. Satoh I, Harvey JE, Ogura JH. Impairment of function of the intrinsic laryngeal muscles after regeneration of the recurrent laryngeal nerve. Laryngoscope 1974;84:53-66.

11. Green DC, Ward PH. The management of the divided recurrent laryngeal nerve. Laryngoscope 1990;100:779-82.

12. Dedo HH. Electromyographic and visual evaluation of recurrent laryngeal nerve anastomosis in dogs. Ann Otol Rhinol Laryngol 1971;80:664-8.

13. Dedo HH. Surgery of the larynx and trachea. Philadelphia, Pa: BC Decker, 1990.

14. Dedo HH, Carlsöö B. Histologic evaluation of Teflon granulomas of human vocal cords. A light and electron microscopic study. Acta Otolaryngol (Stockh) 1982;93:475-84.

15. Horn KL, Dedo HH. Surgical correction of the convex vocal cord after Teflon injection. Laryngoscope 1980;90:281-6.

ETHMOID SURGERY COMPLICATIONS AND THEIR AVOIDANCE

ALAN SOGG, MD
CLEVELAND, OHIO

BERKLEY EICHEL, MD
TORRANCE, CALIFORNIA

The purpose of this report is to review the complications that two experienced operators have encountered during the past 20 years. The techniques employed by the authors are similar. Three thousand intranasal nonendoscopic procedures accumulated between the coauthors were further evaluated to explain why complications could occur. There were five dural injuries in this series that were managed conservatively. Periorbital ecchymoses were seen in 9% of the cases with no permanent adverse sequelae. Approximately 0.5% of the patients had postoperative bleeding. Conclusions that the authors reached were as follows. 1) A complication as a result of ethmoid sinus surgery can occur with any technique and in the hands of any surgeon. 2) Training and experience plus knowledge of the ethmoid anatomy may help reduce the absolute number of complications. 3) Early recognition of a complication and its appropriate management can help decrease the relative severity of the complication. 4) The surgeon should terminate a procedure when visualization and localization are compromised.

KEY WORDS — complications, ethmoid surgery.

INTRODUCTION

The development of the endoscopically performed ethmoid operation[1] has stimulated renewed interest in this type of surgery. It has also again brought to our attention that ethmoid surgery, regardless of the technique employed, has its potential dangers as currently[2-4] and previously reported,[5,6] in spite of a report to the contrary.[7]

The authors, who trained in different programs at approximately the same time, perform a nonendoscopic modified Yankauer procedure that both have described.[8,9] Their total ethmoid operative experience of 3,000 ethmoidectomies has been combined to examine the types of complications encountered and their severity. The complications are listed and methods for avoiding them discussed.

METHODS

The surgical indications for the patients in this study, from the total clinical experience of the authors, have been covered in previous publications.[8,9]

The authors both employ a modified Yankauer technique in that a portion of the middle turbinate is usually preserved and the dissection is started at the ethmoid bulla, when technically possible, because of its constancy.[10]

The total number of cases and any resulting complications have been combined, since the only major difference in technique between the authors was that one (B.E.) operated with general anesthesia and the other (A.S.) used local standby anesthesia.

The techniques employed for avoiding complication, or minimizing one should it occur, are described in the Discussion.

RESULTS

Minor Complications. Excessive bleeding, ie, that requiring termination of the procedure with resultant subsequent surgery to complete the originally planned operation, occurred in 15 patients or 0.3% of the series. Periorbital ecchymoses occurred in 270 patients or 9%. (These 270 complications occurred during the total operative experience of the authors — more than 20 years each. Our current rate of periorbital ecchymoses is less than 5%.) Two of these 270 patients had temporary (2 to 6 weeks) diplopia. Synechiae occurred in less than 1.0%, as did septal hematoma. Numbness of the upper incisors (temporary) occurred in 50%. This was a result of the injection for and/or creation of a megaantrostomy in the inferior meatus. Noncompliance of patients in prolonged follow-up created the increased likelihood of recurrent problems. Up to 50% of the patients do not return as frequently or for as many years for follow-up examinations as is suggested.

Major Complications. Cerebrospinal fluid leaks occurred in 5 patients (0.17%), 3 of whom required mucosal or fascial closure. Two of these had pneumoencephaloceles and 1 of these developed meningitis. All recovered without further sequelae. Two of these patients developed their leaks at least 1 year following the operation. Postoperative bleeding requiring hospitalization and packing occurred in 14 patients or 0.47%. Two of these patients required transfusion. Several of these patients had bleeding from the antrostomy opening. While other complications such as permanent diplopia, blindness, and death have been described in the literature or anecdotally, they did not occur in this series and are therefore omitted. The total major complication rate in this series was 0.64%.

DISCUSSION

The number and severity of the complications

Presented at the meeting of the American Laryngological Association, Waikoloa, Hawaii, May 4-5, 1991.

REPRINTS — Alan Sogg, MD, 21100 Southgate Park Blvd, Cleveland, OH 44137.

that were encountered we feel are not unacceptable and compare favorably with those in other reports. While other operative methods have previously been described and specific techniques advocated, the avoidance of complications has not been stressed. We both realize that a description of "avoidance techniques" is anecdotal and are disquieted by the fact that avoidance of complications defies statistical analysis. However, we will proceed, keeping in mind that the art of medicine must survive in the interest of well-rounded teaching and patient safety.

Since the seriousness of a complication varies, we have separated ours, as have others, into minor and major. We therefore have listed periorbital ecchymoses with the possible removal of a small amount of periorbital fat (without further intraorbital damage) as being minor. A dural tear, because of its different implications, is considered a major complication with or without further morbidity. We believe the inclusion of patient noncompliance as a minor complication merits explanation. Patients may not return for appropriate follow-up for several reasons, including their own perception that they are doing well and see no need for further visits to the operating surgeon. Possibly, the need for periodic examinations to help recognize and prevent recurrent problems was not stressed by the surgeon. A patient who requires reoperation will most likely have either distorted anatomy or absent landmarks and as a result be more at risk for a possible surgical complication.

There are, of course, many factors that contribute to the occurrence of complications and, ultimately, why they occur or, more important, do not occur. The depth of one's training and operative experience can be significant, even though it is acknowledged that any surgeon may have a problem. Early recognition of, for example, periorbital fat will likely prevent a serious orbital complication even though the patient will have periorbital ecchymoses. Gentle pressure on suspected periorbital fat intranasally can cause an obvious movement of the eye as seen externally. Conversely, gentle external pressure on the globe may cause movement of the suspected periorbital fat as viewed intranasally. If need be, a frozen section of the suspected fat can remove all doubt. The use of saline to see if the polyp sinks or the fat floats can be helpful. Further prevention of orbital complications is promoted by doing this operation with the patient awake. The sedated patient will generally respond to pain when periorbital fat is pulled with an instrument. This type of response can help alert the surgeon that he or she may be in a potentially dangerous area.

The recognition of one or more of the critical ethmoid landmarks is mandatory in the performance of this surgery. These include the ethmoid bulla, the medial wall of the middle turbinate, the anterior wall of the sphenoid (which can also be found transseptally), the fovea ethmoidalis, the anterior attachment of the middle turbinate to the lateral nasal wall, and a spatial appreciation of one's location in the ethmoid or sphenoid. If the operating surgeon is unsure of their location, one or more of the above-mentioned structures should be defined by either direct visualization or with the aid of a radiograph with appropriate markers. If the surgeon is unsure of their location in spite of all measures (and measurements[11,12]) at his or her disposal, it is the feeling of the authors that the safest course of action would be termination of the operation. This latter statement would apply whenever visualization and exposure are compromised from any cause, such as excessive bleeding or when the amount of blood loss is reaching the level that could possibly require transfusion. Dissection should only be performed under direct vision, regardless of the surgical technique. The operator should constantly keep in mind the relationships of the ethmoid labyrinth, such as the proximity of the posterior lateral ethmoid to the optic nerve. Also, instrumentation performed intranasally above the external inner canthal landmark can be dangerous.

A clear stream of fluid as opposed to blood should be recognized for what it is and managed appropriately. A cerebrospinal fluid leak may occur from dissecting when exposure is insufficient (see above) or from fovea rupture, particularly in areas of relative thinness of the bone.[13]

The prevention of excessive bleeding is aided by use of local anesthesia and injection of vasoconstrictors,[3] which should also be employed with general anesthesia.

CONCLUSIONS

1. A complication as a result of ethmoid sinus surgery can occur with any technique employed and in the hands of any surgeon.
2. Training and experience plus knowledge of the ethmoid anatomy may help reduce the absolute number of complications.
3. Early recognition of a complication and its appropriate management can help decrease the relative severity of the complication.
4. The surgeon should terminate a procedure when visualization and localization are compromised.

REFERENCES

1. Stammberger H. Endoscopic endonasal surgery — concepts in treatment of recurring rhinosinusitis. Part I. Anatomic and pathophysiologic considerations. Otolaryngol Head Neck Surg 1986;94:143-56.

2. Freedman HM, Kern EB. Complications of intranasal eth-

moidectomy: a review of 1,000 consecutive operations. Laryngoscope 1979;89:421-34.

3. Friedman WH, Katsantonis GP, Rosenblum BN, Cooper MH, Slavin R. Sphenoethmoidectomy: the case for ethmoid marsupialization. Laryngoscope 1986;96:473-9.

4. Stankiewicz JA. Complications of endoscopic intranasal ethmoidectomy. Laryngoscope 1987;97:1270-3.

5. Mosher HP. The applied anatomy and the intranasal surgery of the ethmoid labyrinth. Trans Am Laryngol Assoc 1912; 34:25-45.

6. Davison FW. Hyperplastic sinusitis — a five year study. Ann Otol Rhinol Laryngol 1963;72:462-74.

7. Dixon FW. A study of the clinical results of the intranasal ethmoidectomy. Trans Am Laryngol Rhinol Otol Soc 1945:35-42.

8. Eichel BS. The intranasal ethmoidectomy procedure: historical, technical and clinical considerations. Laryngoscope 1972; 82:1806-21.

9. Sogg A. Long-term results of ethmoid surgery. Ann Otol Rhinol Laryngol 1989;98:699-701.

10. Van Alyea OE. Nasal sinuses: an anatomic and clinical consideration. 2nd ed. Baltimore, Md: Williams & Wilkins, 1951.

11. Dixon FW. A comparative study of the sphenoid sinus. (A study of 1600 skulls.) Ann Otol Rhinol Laryngol 1937;46:687-98.

12. Mosher HP. Measurement of operating distances in the nose. Ann Surg 1902;36:554-9.

13. Kainz J, Stammberger H. The roof of the anterior ethmoid: a place of least resistance in the skull base. Am J Rhinol 1989;3:191-9.

IRRADIATION-INDUCED ATHEROSCLEROSIS: A FACTOR IN THERAPEUTIC PLANNING

W. FREDERICK MCGUIRT, MD
ROBERT S. FEEHS, MD
GENE BOND, PHD
HARRIET L. STRICKLAND, DVM
WILLIAM M. MCKINNEY, MD
WINSTON-SALEM, NORTH CAROLINA

Early primary head and neck cancers (stages I and II) and occult metastatic neck disease have caused debate regarding the choice between surgery and irradiation. The arguments for each are reviewed with a new consideration: the acceleration and/or induction of carotid atherosclerosis in irradiated patients. We present clinical case reports (n = 9), a retrospective clinical evaluation for the occurrence of carotid atherosclerosis in irradiated head and neck cancer patients (n = 57), and a comparison study of the extent and distribution of atherosclerosis in irradiated (n = 29) and nonirradiated head and neck cancer patients controlled for age, blood pressure, and tobacco use. The results show that carotid atherosclerosis is found in a wider anatomic distribution and to a greater extent in irradiated than in nonirradiated patients. We conclude that carotid atherosclerosis is induced and/or accelerated by neck irradiation. The implications as they relate to choice of treatment, to pretreatment evaluations, and to long-term follow-up are discussed.

KEY WORDS — carotid atherosclerosis, carotid ultrasound, head and neck neoplasms, irradiation.

INTRODUCTION

The proper treatment of the N0 neck remains an unresolved issue. Whether initial treatment of the neck concomitant with treatment of the primary tumor is beneficial and, if it is, which are the preferred method and proper timing remain debatable. Prevailing opinions are 1) that neck disease should be addressed when the expected occult rate exceeds 20%, and 2) that the neck may be treated equally well by irradiation or surgical dissection.[1,2] Similarly, because many T1- and T2-staged primary head and neck tumors have cure rates from either surgery or irradiation that are essentially equal, the same quandary as to the preferred treatment modality remains.

When different therapeutic modalities yield comparable results, the choice must be based on other variables. Important questions that must be addressed before treating occult metastatic nodal neck disease are

1. Is the primary tumor to be treated by surgery alone, or will irradiation, alone or as part of combined therapy, be used?
2. If surgery is to be used, will the approach be through the neck and allow simultaneous management of occult nodal disease?

Secondary considerations include

1. Is the primary tumor at the midline, requiring treatment to both sides of the neck?
2. Would a modified neck dissection limit the size of the irradiation field and thus the morbidity of irradiation?

With the myriad of opinions and data sources available, there is still no agreement between those preferring surgery and those preferring irradiation for occult metastatic or small primary tumors of the upper aerodigestive tract.[3-16]

Barring relevant social and economic considerations, the crucial medical question is that if both modalities of treatment are equally efficacious in the same disease setting, then which of the two causes the least harm or risk to the patient? Historically, negative surgical considerations have included loss of function,[17] cosmesis, and anesthetic and metabolic risks. Cosmesis and function are lesser factors now, since conservation and selective regional neck dissections have become the standard of care for occult disease.[3,18] Negative considerations for radiotherapy have included hypothyroidism,[19] xerostomia,[20-24] dental sequelae,[25] and loss of future treatment options for subsequent second primaries in patients at high risk for metachronous lesions.[26] What we believe now to be an additional major negative consideration relevant to the use of irradiation has been identified and prompts this report. This negative factor is the effect of irradiation on the carotid artery.

STUDY DESIGN AND RESULTS

We became concerned about this problem when we realized that nine of our head and neck cancer

From the Department of Otolaryngology (McGuirt, Feehs), the Department of Neurobiology and Anatomy, Division of Vascular Ultrasound Research (Bond, Strickland), and the Department of Neurology (McKinney), The Bowman Gray School of Medicine of Wake Forest University, Winston-Salem, North Carolina.

Presented at the meeting of the American Laryngological Association, Waikoloa, Hawaii, May 4-5, 1991.

REPRINTS — W. Frederick McGuirt, MD, Dept of Otolaryngology, Bowman Gray School of Medicine, Medical Center Blvd, Winston-Salem, NC 27157.

TABLE 1. RESULTS OF DIAGNOSTIC MEDICAL ULTRASOUND IN PATIENTS WITH HEAD AND NECK TUMORS HAVING UNDERGONE RADIOTHERAPY

Pt No.	Sex	Left/Right CCA	BIF	ICA	Stenosis
1	M	0/0	1/0	0/0	
2	M	1/0	1/0	1/0	
3	F	1/1	1/1	2/1	
4	F	1/0	1/2	1/0	
5	M	1/0	3/2	3/2	Decreased flow
6	M	NE	2/1	1/2	
7	M	1/1	1/2	2/2	
8	F	0/0	0/2	0/0	
9	M	1/0	2/2	3/3	Occlusion R; 50%-75% L
10	M	1/2	3/3	3/2	Occlusion ICA L; stenosis R
11	F	0/0	0/0	0/0	
12	F	1/2	1/0	1/1	
13	M	1/1	0/1	2/0	
14	F	0/1	1/2	1/2	
15	M	2/1	2/1	1/2	
16	M	1/1	1/3	2/2	Yes; 50%-75% L
17	F	0/0	1/1	0/0	
18	M	1/1	2/1	2/2	Yes; 50%-75% L
19	M	0/0	1/2	0/0	Yes
20	M	1/1	2/2	0/0	Yes
21	M	1/0	0/2	1/1	
22	F	0/0	2/2	2/2	Yes; ICA 1.4 mm R
23	M	2/1	2/1	2/2	Yes; 75%-95% L
24	M	2/1	2/0	2/1	Yes; 75%-95% bilaterally
25	M	0/0	1/2	0/0	
26	M	0/1	0/2	1/0	
27	F	0/1	1/2	1/2	
28	M	2/1	1/1	1/1	
29	F	1/0	2/1	2/0	
30	F	1/0	2/2	1/1	
31	M	1/0	1/0	2/1	
32	M	1/0	0/0	0/0	
33	M	1/2	2/2	0/1	
34	M	0/0	0/1	0/0	
35	M	1/2	2/2	1/2	
36	F	1/0	1/1	1/0	
37	F	2/0	2/2	1/2	
38	M	0/0	2/1	2/0	
39	M	1/2	1/3	2/2	
40	M	0/0	2/2	1/2	
41	F	0/0	2/1	0/1	
42	M	1/1	2/2	2/2	
43	F	1/2	0/0	0/2	
44	M	1/1	2/2	2/3	Yes; 50%-75%
45	M	0/0	1/0	3/0	
46	F	0/2	1/1	0/1	
47	M	1/2	2/2	2/2	
48	M	2/1	1/1	1/0	
49	M	?/3	3/3	ND	Occluded system R
50	M	1/1	1/2	2/1	
51	M	2/2	?/2	?/2	
52	M	1/0	0/2	0/0	
53	M	2/2	2/2	2/0	Minimal flow R
54	M	2/1	1/2	0/1	
55	M	0/0	0/0	1/0	
56	M	2/?	2/?	2/?	
57	M	0/0	0/1	0/0	

0 — none, 1 — minimal plaque, 2 — moderate plaque, 3 — large plaque, CCA — common carotid artery, BIF — bifurcation, ICA — internal carotid artery, NE — not examined, ND — no flow detected.

TABLE 2. SUMMARY OF STUDY GROUP 1

	No. Pts	%
Plaque severity		
Grade 0	1	1.75
Grade 1	8	14.0
Grade 2	40	70.1
Grade 3	8	14.0
Stenosis	13	22.8
Plaque distribution		
Bifurcation	53/57	93.0
Internal carotid artery	46/57	80.7
Common carotid artery	45/57	78.9

0 — none, 1 — minimal plaque, 2 — moderate plaque, 3 — large plaque.

patients had reported symptoms compatible with, and on workup ascribed to, carotid vascular disease. Summaries are presented in Case Reports. All patients had been treated with neck irradiation alone or in combination with surgery. Once alerted to the possibility of accelerated atherosclerosis following irradiation in head and neck cancer patients, we evaluated this hypothesis further.

Initially, 57 patients (study group 1) who had received neck irradiation as part or all of their treatment were randomly selected from those seen in our head and neck tumor clinic. These patients were referred to the Bowman Gray School of Medicine clinical ultrasound neurosonology laboratory for carotid artery evaluations. Real-time analysis was done on a Biosound Phase 2 machine. Three views (anterior, lateral, posterior) of each carotid artery were imaged. The posterior view was used to measure plaque thickness, because it best correlates with the arteriographic lateral view. Plaque thickness was measured to within 0.1-mm confidence and recorded for the common, internal, and external carotid arteries, as well as the bifurcations. The degree of plaque deposition or formation was reported as none, minimal (1 to 2 mm), moderate (2.1 to 4 mm), or large (>4 mm).

The results are given in Tables 1 and 2. A marked preponderance of patients (48 of 57 or 84.2%) had moderate to severe carotid atherosclerosis. Plaque deposition was greatest at the bifurcation (53 of 57 or 93.0%). The internal carotid (46 of 57 or 80.7%) and common carotid vessels (45 of 57 or 78.9%) of most patients had atherosclerotic changes as well. This unexpected finding was contrary to historical institutional data, which indicated that while the preponderance of atherosclerosis occurred at the carotid bifurcation, only rarely was it seen in the common and internal carotid systems.[27] In addition, 13 of 57 (22.8%) patients had stenosis of at least 50% and/or flow reductions noted by Doppler measurements. These ultrasound findings supported our original clinical observations and our concern that irradiation of the neck might accelerate or induce carotid artery atherosclerosis.

Because the initial study group had not been

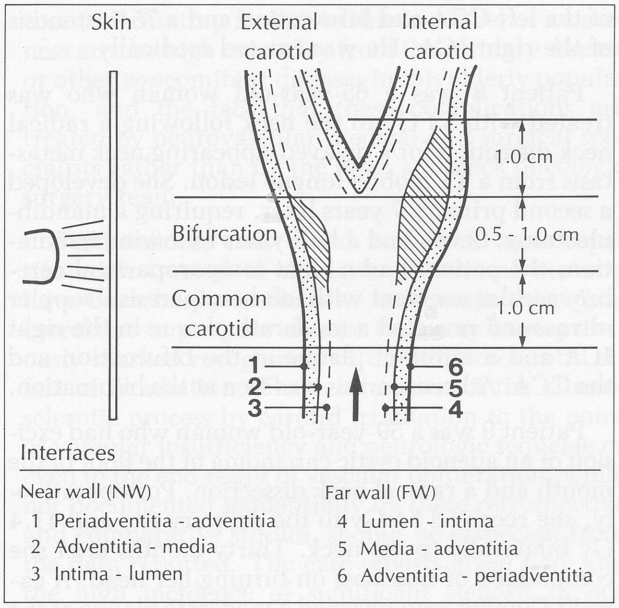

Schematic of high-resolution B-mode ultrasonograph of right carotid artery with lesion in bifurcation. Near wall interfaces (1, 2, and 3), and far wall interfaces (4, 5, and 6) are identified. (Reproduced with permission from Feehs RS, McGuirt WF, Bond MG, Strickland HL, Craven TE, Hiltbrand JB. Irradiation. A significant risk factor for carotid atherosclerosis. Arch Otolaryngol Head Neck Surg 1991;117:1135-7.)

compared with nonirradiated patients, and because no risk factors other than irradiation had been considered, 29 additional head and neck cancer patients (study group 2) who received therapeutic irradiation as all or part of their therapy were randomly selected for study in the laboratory of the Division of Vascular Ultrasound Research. These patients were compared with nonirradiated head and neck cancer patients also randomly selected from the same tumor registry. These control patients were comparable to an institutional stroke center data bank control population.

All test patients had received radiotherapy at least 3 years before the study. Each patient underwent B-mode ultrasound carotid examinations using the Biosound 2000 IIs.a. (8-MHz transducer) unit, which measures plaque thickness to within 0.1-mm confidence. Maximal intimal-medial arterial wall thicknesses were measured in the distal common carotid artery (CCA), the proximal internal carotid artery (ICA), and the carotid bifurcation (see Figure). An atherosclerotic plaque was defined as being present when the intimal-medial thickness was greater than 1.3 mm and was accompanied by nonparallel displacement of the interfaces used to define the intima and media. To obtain a value indicative of a patient's overall carotid intimal-medial thickening, the means for the near and far walls were averaged to yield a single mean maximal score. Age, blood pressure, tobacco consumption, and plasma cholesterol were recorded and compared for the two groups, as were the mean intimal-medial wall thickness and the distribution of plaques.

TABLE 3. SUMMARY OF STUDY GROUP 2

	Test	*Control*	*p*
Plaque severity as measured by mean maximal intimal-medial thickness (mm)			
Mean	1.28	0.90	.003*
SE	0.06	0.05	
Range	0.55-1.97	0.70-1.13	
Plaque incidence (% patients)	93	67	
Location of plaques (% patients)			.0007†
Bifurcation	89	100	
Internal carotid artery	63	0	
Common carotid artery	63	0	
Risk factors other than irradiation (mean ± SE)			
Age (y)	62.6 ± 11.6	58.7 ± 13.8	.40§
Systolic blood pressure (mm Hg)	138.6 ± 18.5	128.3 ± 20.7	.21§
Tobacco (pack years)	42.9 ± 28.7	50.5 ± 32.0	.32§

*Student's *t* test.
†Fisher's exact test.
§Analysis of covariance.

Statistical comparison between the two groups showed significantly more severe and more extensive atherosclerosis in the irradiated group (range, 0.55 to 1.97 mm; mean ± SE, 1.28 ± 0.06 mm) than in the control group (range, 0.70 to 1.13 mm; mean ± SE, 0.90 ± 0.05 mm). By Student's *t* test, these differences were statistically significant at the p = .003 level (Table 3), and they remained statistically significant (analysis of covariance) after possible confounding effects such as age, blood pressure, and tobacco consumption had been examined (Table 3). No patient in either group was hypercholesterolemic.

Intimal-medial thickening greater than 1.3 mm (plaque) was present in 93% of the irradiated patients and 67% of controls. Plaques were located at multiple sites in 81% of irradiated patients, with 33% of the patients having plaques in all three arterial segments. Control patients, however, had plaque involving only the carotid bifurcation. These differences in plaque distribution among arterial segments were significant (p = .0007, Fisher's exact test; Table 3).

Our conclusion was, as we had suspected clinically, that irradiation contributes to the development of more severe and more extensive carotid artery atherosclerosis in head and neck tumor patients.

CASE REPORTS

Patient 1 was a 70-year-old man with a T2N3M0 nasopharyngeal carcinoma. He had full-course radiotherapy to the primary lesion and both sides of the neck (60 Gy). Ten years later he developed episodes of right-sided numbness or weakness and syncopal attacks, and had three episodes of amaurosis fugax in the left ear. Carotid artery duplex ultrasound revealed a left internal carotid occlusion of 90% and a plaque with 40% occlusion of the right

bifurcation and ICA. He was treated medically.

Patient 2 was a 76-year-old woman with a T2N0M0 tongue base carcinoma. In 1978, she received full-course radiotherapy to her primary lesion (65 Gy) and both sides of the neck (50 Gy). A second head and neck primary lesion was diagnosed in May 1984. Carotid ultrasound was performed because of carotid bruits heard bilaterally on physical examination. A right-sided CCA stenosis of 50% to 70% and a left-sided ICA stenosis of 50% to 75% were reported. The patient died of her second cancer before the carotid problem could be addressed.

Patient 3 was a 73-year-old man with a tongue base T1N0M0 carcinoma. He was treated with radiotherapy (60 Gy to the primary lesion and 50 Gy to both sides of the neck). Nine years later he developed syncopal episodes and transient ischemic attacks. An arteriogram showed bilateral plaques with 50% stenosis of the left CCA. Carotid endarterectomy was performed.

Patient 4 was a 74-year-old man who presented with a T2N0M0 supraglottic carcinoma of the larynx that was treated with preoperative radiotherapy (45 Gy to the left side of the neck and 20 Gy to the right side of the neck). Eighteen years later he presented with a second primary lesion and a 2-year history of transient ischemic attacks. Carotid arteriograms indicated right carotid obstruction, and ultrasound confirmed no flow in the right ICA and a 50% to 75% stenosis in the left ICA. The patient was treated medically.

Patient 5 was a 68-year-old man with T3N0M0 carcinoma of the right tonsil. He was treated with 68 Gy to his primary lesion. Two years later he was admitted with second and third primary lesions. Seizures developed after laser resection of a postpharyngeal lesion. A 95% stenosis of the right CCA and ICA and 75% occlusion of the left CCA and ICA were found on carotid ultrasound during the workup of his seizure.

Patient 6 was an 87-year-old man with T2N0M0 laryngeal cancer who was treated with 68 Gy to the primary lesion and 50 Gy to both sides of the neck. Later, a metastatic node appeared within the irradiation portal and a radical neck dissection was performed. Two years after the initial irradiation treatment, the patient began having syncopal episodes and was noted to have bilateral carotid bruits. Carotid Doppler studies revealed 40% ICA stenosis bilaterally with a calcified plaque being noted in the bifurcation. He was treated medically.

Patient 7 was a 60-year-old man with a T2N1M0 carcinoma of the oropharynx who received radiotherapy with 60 Gy to the primary lesion and 50 Gy to both sides of the neck. Three years posttherapy the patient began having episodes of dizziness and blurred vision. A workup revealed a 95% occlusion of the left CCA and bifurcation and a 75% stenosis of the right ICA. He was treated medically.

Patient 8 was a 65-year-old woman who was treated with 53 Gy to the neck following a radical neck dissection for a delayed-appearing neck metastasis from a T1 mobile tongue lesion. She developed a second primary 7 years later, requiring a mandibulectomy. Seven and a half years following irradiation, the patient had a right temporoparietal cerebrovascular accident with left hemiparesis. Doppler ultrasound revealed a moderate plaque in the right ICA and a minimal plaque at the bifurcation and the CCA. Atherosclerosis was seen at the bifurcation.

Patient 9 was a 59-year-old woman who had excision of an adenoid cystic carcinoma of the floor of the mouth and a radical neck dissection. Postoperatively, she received 54 Gy to the primary site and 41.4 Gy bilaterally to the neck. Thirty months later she complained of dizziness on turning her head. A carotid Doppler scan revealed a moderate plaque at the carotid bifurcation and a severe plaque at the internal carotid origins. Medical therapy was instituted.

DISCUSSION

Radiotherapy plays a prominent role in the treatment of head and neck cancer. Its use is well established in the curative treatment of subclinical cervical node metastases, in the management of small primary mucosal tumors, and in combination with surgery for the eradication of manifest cervical node metastases and many larger primary tumors.[28-30]

Similarly well established by animal studies and anecdotal human observations are changes within the vascular system — intimal thickening, lipoid deposition, and adventitial fibrosis — that follow external irradiation to other parts of the body. All these changes, seen in arteriosclerosis and with the normal aging process, are produced or accelerated by irradiation.[31-35] Over long periods of survival, low doses of radiation (25 Gy) cause these same vascular changes and cause them to the same degree as doses higher than 45 Gy.[36] Irradiation-induced coronary artery disease in nonatherosclerotic young women and young men following chest and mediastinal irradiation has been reported[37-41]; ie, these changes may occur in the vessels of patients without preexisting atherosclerotic changes and in whom atherosclerosis is not normally seen.

Although the carotid vascular system is included in the treatment portals for irradiation of head and neck cancers, previous reports of irradiation damage to these large arteries are few[42-45] and are found predominantly in neurosurgical and vascular surgical journals.[46-49] The paucity of information on this subject directed toward head and neck oncologists has masked the magnitude of the problem and delayed awareness that accelerated atherosclerosis from irradiation to the neck is not uncommon. Fur-

ther contributing factors to this low level of awareness are the high mortality from the primary disease or other concomitant diseases in this elderly population, and the fact that these complications are treated by neurovascular medical and surgical specialists rather than by the head and neck oncologic surgery team.

Furthermore, most head and neck cancer patients are treated in the later decades of life and have been heavy smokers — both major historical correlates to vascular disease that may have previously masked recognition of the atherosclerotic effect of irradiation. The acceleration of the atherosclerotic process by carotid irradiation to the point of vascular insufficiency and neurologic sequelae or even to the end result of vascular obliteration, while not documented sequentially by these retrospective and comparative studies, should be suspected from the data reported. The case reports given here and the high incidence of significant stenosis in our retrospective uncontrolled clinical ultrasound study group 1 lend support to this concept. Our 22.8% incidence of hemodynamically significant lesions is in keeping with that of two other retrospective studies: one by Scholz et al,[50] comprising 37 patients having a 19% incidence, and one by Elerding et al,[51] comprising 118 patients having a 25% incidence. Compared with a 2.7% incidence in 556 controls in the study by Scholz et al, our findings and others represent a tenfold increase of hemodynamically significant lesions in the irradiated patient groups. Elerding et al noted a twofold increase in stroke incidence in comparison to their controls.

The studies of Scholz et al and Elerding et al and our case studies and study group 1 correlated the presence of carotid stenosis and prior irradiation. Our study group 1 in addition indicated a distribution and severity of carotid atherosclerosis not previously recognized. These studies did not, though, evaluate the significance of irradiation as a risk factor in relation to other known risk factors for atherosclerosis. Therefore, we undertook the comparative study of irradiated and nonirradiated patients comparing other risk factors. Data from this second study confirmed a statistically significant difference in the degree and distribution of carotid artery atherosclerosis within the test and control groups. The only causative differentiating factor was that the test group patients had received irradiation to the neck. The other factors known to be associated with atherosclerosis, such as hypertension, age, and tobacco use, were not statistically different between the two groups (Table 2).

This acceleration and worsening of atherosclerosis by irradiation should be a real concern, especially when treating patients with any history or physical findings of pretreatment diffuse arteriosclerosis. Awareness of this problem should dictate caution in incorporating neck irradiation into the treatment protocols of head and neck cancer patients. Both older patients with preexisting vascular disease and younger patients with longer life expectancy are at risk for progressive obliterative effects of radiotherapy. Such patients may be better served by alternative protocols excluding irradiation if the cure rates are comparable.

The above conclusion is particularly true for the patient with an N0 neck, in whom a conservative neck dissection or even observation and subsequent neck dissection[4,7] for later-manifested disease might be equally effective. In patients with manifest nodal disease confined within the nodal capsule, a neck dissection alone has proved to be sufficient therapy.[52] Similarly, for hypopharyngeal carcinoma, combined therapy has been questioned as to increasing survival beyond that of surgery alone.[53,54] A true increased benefit must be shown before the irradiation arm of therapy is routinely added to or replaces surgery.

All head and neck patients for whom irradiation is an option for treatment should be considered for a carotid ultrasound study as part of their pretreatment workup. Identification of carotid vascular disease and the risk of exacerbating this disease by irradiation must be weighed against a documented enhancement of cure by the inclusion of irradiation. For those patients who require neck irradiation, sequential carotid evaluations and a search for early clinical symptoms that would evoke interventional therapy should be performed. In non–high-risk patients, a clinically heightened suspicion should dictate when carotid vascular studies are appropriate.

The purpose of this communication is to alert the head and neck oncologist to the potentially serious side effect of accelerated atherosclerosis following irradiation in patients with head and neck cancer.

CONCLUSION

As suspected by clinical observations, ultrasonographic evaluation confirms that irradiation contributes to the development of severe and extensive carotid artery atherosclerosis in head and neck tumor patients.

REFERENCES

1. Collins SL. Controversies in management of cancer of the neck. In: Thawley SE, Panje WR, eds. Comprehensive management of head and neck tumors. Vol 2. Philadelphia, Pa: WB Saunders, 1987:1386-443.

2. Cummings BJ. Radiation therapy and the treatment of the cervical lymph nodes. In: Cummings CW, Fredrickson JM, Harker LA, Krause CJ, Schuller DE, eds. Otolaryngology–head and neck surgery. Vol 2. St Louis, Mo: CV Mosby, 1986:1671-91.

3. Lingeman RE, Helmus C, Stephens R, Ulm J. Neck dissection: radical or conservative. Ann Otol Rhinol Laryngol 1977;86:737-44.

4. Patterson HC, Dobie RA, Cummings CW. Treatment of

the clinically negative neck in floor of the mouth carcinoma. Laryngoscope 1984;94:820-4.

5. Mendenhall WM, Million RR, Cassisi NJ. Elective neck irradiation in squamous-cell carcinoma of the head and neck. Head Neck Surg 1980;3:15-20.

6. DeSanto LW, Holt JJ, Beahrs OH, O'Fallon WM. Neck dissection: is it worthwhile? Laryngoscope 1982;92:502-9.

7. Vandenbrouck C, Sancho-Garnier H, Chassagne D, Saravane D, Cachin Y, Micheau C. Elective versus therapeutic radical neck dissection in epidermoid carcinoma of the oral cavity. Results of a randomized clinical trial. Cancer 1980;46:386-90.

8. Jesse RH, Barkley HT Jr, Lindberg RD, Fletcher GH. Cancer of the oral cavity. Is elective neck dissection beneficial? Am J Surg 1970;120:505-8.

9. Jesse RH, Ballantyne AJ, Larson D. Radical or modified neck dissection: a therapeutic dilemma. Am J Surg 1978;136: 516-9.

10. Ogura JH, Biller HF, Wette R. Elective neck dissection for pharyngeal and laryngeal cancers. An evaluation. Ann Otol Rhinol Laryngol 1971;80:646-53.

11. Teichgraeber JF, Clairmont AA. The incidence of occult metastases for cancer of the oral tongue and floor of the mouth: treatment rationale. Head Neck Surg 1984;7:15-21.

12. Million RR. Elective neck irradiation for TxN0 squamous carcinoma of the oral tongue and floor of mouth. Cancer 1974; 34:149-55.

13. Bagshaw MA, Thompson RW. Elective irradiation of the neck in patients with primary carcinoma of the head and neck. JAMA 1971;217:456-8.

14. Fletcher GH. Elective irradiation of subclinical disease in cancers of the head and neck. Cancer 1972;29:1450-4.

15. Mendelson BC, Woods JE, Beahrs OH. Neck dissection in the treatment of carcinoma of the anterior two-thirds of the tongue. Surg Gynecol Obstet 1976;143:75-80.

16. Spiro RH, Strong EW. Epidermoid carcinoma of the oral cavity and oropharynx. Elective vs therapeutic radical neck dissection as treatment. Arch Surg 1973;107:382-4.

17. Ewing MR, Martin H. Disability following "radical neck dissection." An assessment based on the postoperative evaluation of 100 patients. Cancer 1952;5:873-83.

18. Medina JE, Byers RM. Supraomohyoid neck dissection: rationale, indications, and surgical technique. Head Neck Surg 1989;11:111-22.

19. Leining DA, Duncan NO, Blakeslee DB, Smith DB. Hypothyroidism following radiotherapy for head and neck cancer. Otolaryngol Head Neck Surg 1990;103:10-3.

20. Shannon IL, Starcke EN, Wescott WB. Effect of radiotherapy on whole saliva flow [Abstract]. J Dent Res 1977;56:693.

21. Shannon IL, Trodahl JN, Starcke EN. Radiosensitivity of the human parotid gland. Proc Soc Exp Biol Med 1978;157:50-3.

22. Dreizen S, Brown LR, Handler S, Levy BM. Radiation induced xerostomia in cancer patients. Cancer 1976;38:273-8.

23. Wescott WB, Mira JG, Starcke EN, Shannon IL, Thornby JI. Alterations in whole saliva flow rate induced by fractionated radiotherapy. AJR 1978;130:145-9.

24. Brown LR, Dreizen S, Handler S, Johnston DA. Effect of radiation induced xerostomia on human oral microflora. J Dent Res 1975;54:740-50.

25. Bulletin. J Oral Med 1978;33:23-7.

26. Larson JT, Adams GL, Fattah HA. Survival statistics for multiple primaries in head and neck cancer. Otolaryngol Head Neck Surg 1990;103:14-24.

27. Tell GS, Howard G, McKinney WM. Risk factors for site specific extracranial carotid artery plaque distribution as measured by B-mode ultrasound. J Clin Epidemiol 1989;42:551-9.

28. Hanks GE, Bagshaw MA, Kaplan HS. The management of cervical lymph node metastasis by megavoltage radiotherapy. AJR 1969;105:74-82.

29. Million RR, Fletcher GH, Jesse RH Jr. Evaluation of elective irradiation of the neck for squamous-cell carcinoma of the nasopharynx, tonsillar fossa, and base of tongue. Radiology 1963; 80:973-88.

30. Wizenberg MJ, Bloedorn FG, Weiner S, Gracia J. Treatment of lymph node metastases in head and neck cancer: a radiotherapeutic approach. Cancer 1972;29:1455-62.

31. Lamberts HB, de Boer WGRM. Contributions to the study of immediate and early x-ray reactions with regard to chemoprotection. VII. X-ray-induced atheromatous lesions in the arterial wall of hypercholesterolaemic rabbits. Int J Radiat Biol 1963;6: 343-50.

32. Lindsay S, Entenman C, Ellis EE, Geraci CL. Aortic arteriosclerosis in the dog after localized aortic irradiation with electrons. Circ Res 1962;10:61-7.

33. Sams A. Histological changes in the larger blood vessels of the hind limb of the mouse after x-irradiation. Int J Radiat Biol 1965;9:165-74.

34. Upadhaya BR, Chakravarti RN, Wahi PL. Post-irradiation vascular injury and accelerated development of experimental atherosclerosis. Indian J Med Res 1972;60:403-8.

35. Vesselinovitch D, Wissler RW. Experimental production of atherosclerosis in mice. Part 2. Effects of atherogenic and high-fat diets on vascular changes in chronically and acutely irradiated mice. J Atheroscler Res 1968;8:497-523.

36. Lindsay S, Kohn HI, Dakin RL, Jew J. Aortic arteriosclerosis in the dog after localized aortic x-irradiation. Circ Res 1962; 10:51-60.

37. Dollinger MR, Lavine DM, Foye LV Jr. Myocardial infarction following radiation [Letter]. Lancet 1965;2:246.

38. Huff H, Sanders EM. Coronary-artery occlusion after radiation [Letter]. N Engl J Med 1972;286:780.

39. McReynolds RA, Gold GL, Roberts WC. Coronary heart disease after mediastinal irradiation for Hodgkin's disease. Am J Med 1976;60:39-45.

40. Prentice RTW. Myocardial infarction following radiation [Letter]. Lancet 1965;2:388.

41. Tracy GP, Brown DE, Johnson LW, Gottlieb AJ. Radiation-induced coronary artery disease. JAMA 1974;228:1660-2.

42. Conomy JP, Kellermeyer RW. Delayed cerebrovascular consequences of therapeutic radiation. A clinicopathologic study of a stroke associated with radiation-related carotid arteriopathy. Cancer 1975;36:1702-8.

43. Glick B. Bilateral carotid occlusive disease following irradiation for carcinoma of the vocal cords. Arch Pathol 1972;93: 352-5.

44. St Louis EL, McLoughlin MJ, Wortzman G. Chronic damage to medium and large arteries following irradiation. J Can Assoc Radiol 1974;25:94-104.

45. Hayward RH. Arteriosclerosis induced by radiation. Surg Clin North Am 1972;52:359-66.

46. Levinson SA, Close MB, Ehrenfeld WK, Stoney RJ. Carotid artery occlusive disease following external cervical irradiation. Arch Surg 1973;107:395-7.

47. Silverberg GD, Britt RH, Goffinet DR. Radiation-induced carotid artery disease. Cancer 1978;41:130-7.

48. Atkinson JLD, Sundt TM Jr, Dale AJD, Cascino TL, Nichols DA. Radiation-associated atheromatous disease of the cervical carotid artery: report of seven cases and review of the literature. Neurosurgery 1989;24:171-8.

49. Nardelli E, Fiaschi A, Ferrari G. Delayed cerebrovascular consequences of radiation to the neck. A clinicopathologic study of a case. Arch Neurol 1978;35:538-40.

50. Scholz E, Diener HC, Voss AC. Gefässveränderungen der extrakraniellen Arterien nach Strahlentherapie von Kopf-Hals-Tumoren [abstract in English]. Strahlentherapie 1982;158:290-7.

51. Elerding SC, Fernandez RN, Grotta JC, Lindberg RD, Causay LC, McMurtrey MJ. Carotid artery disease following external cervical irradiation. Ann Surg 1981;194:609-15.

52. Johnson JT, Barnes EL, Myers EN, Schramm VL Jr, Borochovitz D, Sigler BA. The extracapsular spread of tumors in cervical node metastasis. Arch Otolaryngol 1981;107:725-9.

53. Yates A, Crumley RL. Surgical treatment of pyriform sinus cancer: a retrospective study. Laryngoscope 1984;94:1586-90.

54. Eisbach KJ, Krause CJ. Carcinoma of the pyriform sinus: a comparison of treatment modalities. Laryngoscope 1977;87: 1904-10.

ABSTRACTS

MICROVASCULARIZATION OF THE LARYNGEAL CARTILAGES AND ITS ONCOLOGIC IMPORTANCE

PROF MARIO ANDREA

LISBON, PORTUGAL

The invasion of the laryngeal cartilages by carcinoma is of great clinical importance. Based on several morphologic techniques, mainly microangiography, the ossification process and its vascular changes have been studied. With the ossification process, vessels that originated in the perichondrial vascular network penetrate the cartilage. This phenomenon contributes to a change in the behavior of the cartilage with invasion of carcinoma. The results obtained are correlated with the clinical evaluation of cartilaginous invasion.

Presented at the meeting of the American Laryngological Association, Waikoloa, Hawaii, May 4-5, 1991.

MEDIALIZATION LARYNGOPLASTY AND THE ARYTENOID ADDUCTION PROCEDURE: WHICH AND WHEN?

JAMES A. KOUFMAN, MD

WINSTON-SALEM, NORTH CAROLINA

Medialization laryngoplasty (ML) is emerging as an excellent alternative to injection techniques for paralytic dysphonia because ML is reversible, produces excellent vocal results, and can be performed in patients with deficient soft tissue. The success of ML, however, is limited by the preoperative configuration of the glottic defect; when the posterior glottic chink is wide open, ML is relatively ineffective since the technique does not close the posterior commissure. In such cases, the arytenoid adduction procedure may be indicated; however, the procedure is irreversible. This paper reviews the indications for each of the procedures alone and for a combined procedure (ML and arytenoid adduction). The role and interpretation of laryngeal electromyography is discussed in reference to procedure selection and the timing of intervention. The techniques, results, and complications of each procedure are also presented.

Presented at the meeting of the American Laryngological Association, Waikoloa, Hawaii, May 4-5, 1991.

DISCUSSIONS

CLINICAL STAGING FOR PRIMARY MALIGNANCIES OF THE SUPRAGLOTTIC LARYNX (p 32)

R. L. ZAMORA, MD; E. L. SPITZNAGEL, JR, PHD; D. G. SESSIONS, MD; J. E. HARVEY, PHD

PREEPIGLOTTIC SPACE INVASION IN "EARLY" EPIGLOTTIC CANCER (p 41)

S. M. ZEITELS, MD; C. W. VAUGHAN, MD

PROGNOSTIC SIGNIFICANCE OF TUMOR SITE, EXTENSION, AND MOBILITY IN GLOTTIC CANCER (p 45)

M. D. MORRISON, MD; A. D. FLORES, MD; A. SIKAND, MD; J. S. DURHAM, MD

META-ANALYSIS OF SECOND MALIGNANT TUMORS IN HEAD AND NECK CANCER: THE CASE FOR AN ENDOSCOPIC SCREENING PROTOCOL (p 51)

B. H. HAUGHEY, MBCHB, FRACS; G. A. GATES, MD; C. L. ARFKEN, PHD; J. HARVEY, PHD

PAUL H. WARD, MD (Los Angeles, Calif): Dr Zeitels, I am sure that Dr John Kirchner was as impressed as I am with your observations that T1 and T2 cancers of the infrahyoid epiglottis invade the preepiglottic space in nearly every case. Dr Kirchner, a member of this society, had many times cautioned us against surgically exploring this area. This is stated in your abstract. I wonder if you might comment on this because I know he is very opposed to exploring the preepiglottic space for cancer because it may contaminate the surgical field.

DOUGLAS P. BRYCE, MD (Toronto, Canada): There is historical interest in the paper with regard to invasion of the preepiglottic space. You were aware of what I called a rumor — that radiotherapy was not effective in the treatment of anterior commissure tumors. That was years ago. The reason for that was just nicely demonstrated in that, first of all, anterior commissure tumors are very rare. Secondly, the majority of them were tumors that had already invaded the preepiglottic space. This invasion was not understood at the time, particularly by the radiotherapists who were planning their treatment fields. When that was corrected, the myth of this condition was also exploded.

WILLARD E. FEE, JR, MD (Stanford, Calif): I enjoyed Dr Haughey's presentation very much. I wonder, did you include the cervical esophagus or did you include cervical esophagus in the head and neck group? I was rather surprised to see what I perceived as a low incidence of second primaries in the esophagus.

ERNEST A. WEYMULLER, JR, MD (Seattle, Wash): Dr Morrison, you have an enviable response rate for T1 and T2 carcinomas. Later this week we will be presenting the difference between a fractioned size of 180 versus 200 per day. I am wondering what the fractionation is of your radiation scheme that gets a nearly 100% result. The second comment is that you concluded that the staging system should stand, but you showed no difference between T1 and T2. Therefore, perhaps we should combine T1 and T2. I am wondering whether that is treatment-specific.

STEVEN M. ZEITELS, MD (Boston, Mass): With regard to the terminology of exploration, one of the goals of this study was that we, in Boston, had done that [explore the preepiglottic space], and we were trying to look for a method by which we did not need to do that because we thought we were understaging the cancer. In fact, this gave us more of an indication for which lesions were actually resectable by transoral, those being the suprahyoid lesion, something that Jackson noted 50 years ago. Now, since we had such firm data that those lesions were not in the preepiglottic space, we did not do a transoral excision. Dr Kirchner and I have had discussions about this. When we used the term exploration, we meant it in the sense that you could do an open laryngectomy as well, then section it, and you would have an exploration as well. You would be taking out the space to determine what was there. We did not mean to say all of these patients should undergo transoral excision. Be it an open or transoral excision, you are still exploring the space by removing it.

MURRAY D. MORRISON, MD (Vancouver, Canada): The treatment protocol used during that 5 years pretty well still stands at 6,000 cGy given in 25 fractions over 1 fraction per day, 5 days a week for 5 weeks. We are looking at changes of that protocol, but that is what we were using at that time and it worked quite well. The other question on T1 and T2 is very intriguing and niggled us while we were looking at it because of the fact that they were so close together and it is tempting to try to push that even a little farther. One of the questions that came up with us is that some of the patients were T2 by reduced mobility only, and there was often a difference between the referring otolaryngologists and the radiation oncologists or the consultant in the cancer agency regarding mobility or extension to some degree. I think we are staging some of the T2s too high because of that. The otolaryngologist goes in and debulks some of the tumor and what was mobile then begins to look like it has reduced mobility, perhaps because of inflammation or something else. I think that some of the tumors are staged too high.

BRUCE H. HAUGHEY, MBChB, FRACS (St Louis, Mo): Thank you for your question regarding the cervical esophagus, Dr Fee. Yes, the cervical esophagus was included in esophagus, not head and neck. There may be some reasons for the incidence being low. First of all, as I mentioned, there was a small study by us in the sense that we included more larynx cancer patients relative to the whole head and neck population group, and remember, we found that the larynx was statistically the lowest site of incidence of esophageal primaries. Second, there was a marked predominance in studies conducted by the radiotherapy departments or our registries, where the pickup rate is lower across the board. We only had five prospective panendoscopy studies, so there are significant possibilities of esophageal cancer being missed, and it is difficult to detect. In fact, the Japanese are now using a special staining technique at the time of endoscopy to pick up very early esophageal lesions. No, that was the figure we came up with for esophagus across the board, from the esophageal inlet down to the gastric inlet.

HEAD AND NECK SURVEILLANCE PROGRAM FOR FACTORY PERSONNEL EXPOSED TO ASBESTOS (p 59)

S. M. PARNES, MD; M. SHERMAN, PHD

CARCINOMA IN SITU AND MICROINVASIVE SQUAMOUS CELL CARCINOMA OF THE VOCAL CORDS (p 65)

R. E. ROTHFIELD, MD; E. N. MYERS, MD; J. T. JOHNSON, MD

CONGENITAL LACK OF OLFACTORY ABILITY (p 69)

D. A. LEOPOLD, MD; D. E. HORNUNG, PHD; J. E. SCHWOB, MD, PHD

MICROVASCULARIZATION OF THE LARYNGEAL CARTILAGES AND ITS ONCOLOGIC IMPORTANCE (p 274)

PROF M. ANDREA

WALTER F. THUMFART, MD (Cologne, Germany): I had a question for Dr Andrea because what he found is somewhat discouraging for an endoscopic laryngectomy, as we do it with a laser. We feel that in a T1 or T2 carcinoma, there is also a paravascular invasion of the cartilage.

IN SITU HYBRIDIZATION AND LARYNGEAL PAPILLOMAS (p 77)

F. RIMELL, MD; R. MAISEL, MD; V. DAYTON, MD

COLLAGEN IN THE DEVELOPING LARYNX. PRELIMINARY STUDY (p 85)

S. R. COHEN, MS, MD; D. T. CHEUNG, PHD; M. E. NIMNI, PHD; V. MAHNOVSKI, MD; G. LIAN, MD; N. PERELMAN; A. P. CARRANZA, MD

GARY SCHECHTER, MD (Norfolk, Va): I want to congratulate the authors of the paper from Minneapolis on human papillomavirus studies. I would like to point out to the audience the extreme difficulty that students of this particular subject have had over the past years, and introduction of this approach is extremely important. It has been a technology problem. For example, when we first studied human papillomavirus in relation to head and neck tumors, we were obtaining positive results in 1 or 2 out of groups of 30 or 40 patients at each anatomic site. Then switching to newer technology, polymerase chain reaction, we have now jumped to 40% positive results. So, the results we saw today, presented relative to the larynx, are extremely important and I encourage their work and encourage those of you who are reading about it to go back and look at the literature and see that some of the negative studies can be reinterpreted in terms of the newer technology that is being applied. The human papillomata virus is clearly one of the offending agents; how it relates to the cytogenetics of our tumor patients has yet to be defined.

CHARLES N. FORD, MD (Madison, Wis): I would like to congratulate Dr Cheung on an excellent presentation. The work was very elegantly done. I would be very interested in your results from analyzing vocal fold tissue, particularly the collagen in the conus elasticus and the vocal ligament. The results we have had in injecting collagen into the vocal folds, which I will be talking about tomorrow, indicate the cross-link preparation seems to be a lot better tolerated in the tissues at that site. I noticed you indicated that the cross-linked collagen was present in increasing amounts with aging in the cartilages. It would be interesting to see whether that phenomenon occurs also in the vocal fold. It might

explain the types of things we are seeing in patients adapting to the collagen injection.

HASKINS K. KASHIMA, MD (Baltimore, Md): I have a comment and a question for Dr Rimell, whose presentation I very much enjoyed. Some time ago we had spoken of what we called, and what Dr Mounts had described to be subtypes of type 6. In that report we identified type 6C as the one with the highest risk for widespread occurrence of papilloma with the tendency toward what seemed to be more rapid recurrence. It turns out that with careful genetic studies type 6C and type 11 are the same type, so the results that Dr Rimell reported this morning would accord well with what we had reported in that earlier study. We do believe that certain subtypes, therefore, of human papillomavirus may in fact be predictive and perhaps even set the tone for the type of clinical expression that would ultimately come about. It is, however, not totally determinant. I believe that important clinical interventions, and specifically tracheotomy, may in fact be some of the most important triggers in disseminating disease in the trachea and lungs. The question I therefore have is, "Was it the case that in the patients in whom the tracheal and bronchial spreads were seen, that all of these patients might not have had tracheotomy?"

DAVID T. CHEUNG, PHD (Los Angeles, Calif): I would just like to answer a comment on the vocal cord. Due to the complicated matter of the whole study, it is very difficult to present the work of all the tissues we looked at in a 10-minute fashion. We are looking at the other tissues and this examination is being completed at this point. It should be ready in the very near future.

FRANK RIMELL, MD (Minneapolis, Minn): I appreciate both comments by Dr Schechter and Dr Kashima. For Dr Kashima, one adult patient who had bronchial spread did not have a tracheotomy. We are having the same problems that both Drs Schechter and Kashima are having in finding what is the most accurate technique in identifying the virus. There are many techniques available and many institutions are getting different results.

SURGICAL ANATOMY OF THE PHARYNGEAL PLEXUS (p 195)

M. I. SINGER, MD

FREE JEJUNAL GRAFT: EFFECTS OF LONGITUDINAL MYOTOMY (p 158)

B. H. HAUGHEY, MBCHB, FRACS; J. W. FORSEN, MD

EFFECT OF BLOOD ON THE INCENDIARY PROPERTIES OF ENDOTRACHEAL TUBES IRRADIATED WITH THE CARBON DIOXIDE LASER (p 164)

R. H. OSSOFF, MD; D. A. GONZALEZ, MD

POINT-TOUCH TECHNIQUE OF BOTULINUM TOXIN INJECTION FOR THE TREATMENT OF SPASMODIC DYSPHONIA (p 172)

D. C. GREEN, MD; G. S. BERKE, MD; P. H. WARD, MD; B. R. GERRATT, PHD

GEORGE SIMPSON, MD (Buffalo, NY): I wanted to compliment all presenters on their papers. I have one question for Bob Ossoff. Have you formulated a theory of why the presence of blood either accelerates or encourages ignition or melting? We had always thought that blood functioned somewhat like water as a heat sink and was vaporized when it reached steam pressure. It appears to be enhancing the absorption of heat on the tube, and I am curious if he has speculated, having done the work, as to why this occurs. I am quite fascinated with what he has found.

ROBERT H. OSSOFF, MD (Nashville, Tenn): When working through high power in the operating microscope, doing these experiments, one could readily visualize that when the blood was irradiated with the CO_2 laser, it would immediately come to a boil, with carbon black particles being deposited very quickly in the site. It is our impression that these carbon black particles then further absorbed heat, unlike water, which would vaporize away, and that this continued absorption of heat appeared to affect, at least on the 3M wrap tapes, the adhesive underneath the tape. The adhesive appeared to catch fire almost prior to the reflective surface itself; this fire was extraluminal to start and became transmural and intraluminal. Similar events occurred on the laser guard tube, which is, of course, a metal tube, manufactured as such. Here, however, we do not have an adhesive on the tube, and it just appeared that the porosity of the metal or some other aspect of heat transmission to the oxygen, flowing at 3 L a minute within the tube, allowed for the fire to occur.

MURRAY D. MORRISON, MD (Vancouver, Canada): It is called Ficon, a black laser shielded tube; it is quite a firm tube. Have you had any experience and tried that in your lab?

DR OSSOFF: We have just received that new tube. In fact, there is a newer version of the tube that has an improved cuff, and we have not had an opportunity to test it in the laboratory before departing for the meeting. We have three and we plan to put them through the same test, both with and without blood.

DR MORRISON: We haven't performed any tests except infor-

mal ones in the operating room. It seems to be terrific and we are very pleased with it.

DR CHRISTY L. LUDLOW, PHD (Bethesda, Md): I had a question for Dr Green on the use of botulinum toxin. I think I heard him mention that his usual dosage was 5 U, which is double what is usually the case that is EMG-guided. I wondered if it was possible that they often were not inserting the toxin into the muscle and that is why a larger dose was required.

DAVID C. GREEN, MD (Los Angeles, Calif): We are in the process of evaluating, through a protocol, our dosage and actually have used several doses. It was just that those patients happened to have the larger dose. There is a possibility that even smaller doses given with this technique may be equally effective. Until we formally announce these results, I really cannot comment as to whether a smaller or larger dose would be equally effective.

MEDIALIZATION LARYNGOPLASTY AND THE ARYTENOID ADDUCTION PROCEDURE: WHICH AND WHEN? (p 274)

J. A. KOUFMAN, MD

PHYSIOLOGIC ASSESSMENT OF ARYTENOID ADDUCTION (p 177)

D. H. SLAVIT, MD; N. E. MARAGOS, MD

ROLE OF INJECTABLE COLLAGEN IN THE TREATMENT OF GLOTTIC INSUFFICIENCY: A STUDY OF 119 PATIENTS (p 178)

C. N. FORD, MD; D. M. BLESS, PHD; J. M. LOFTUS, MD

STABLE INTERNAL FIXATION OF FRACTURES OF THE PARTIALLY MINERALIZED THYROID CARTILAGE (p 153)

J. R. AUSTIN, MD; R. B. STANLEY, MD, DDS; D. S. COOPER, PHD

ROGER L. CRUMLEY, MD (Orange, Calif): I would like to compliment Dr Koufman on a special paper with, I think, a lot of deserving value for the Casselberry Award. Many of the papers that we see about thyroplasty or medialization laryngoplasty use the term reversibility. I am wondering, because Dr Koufman seems to know probably more at this hour about that procedure than most of us, is there anything in the literature now or in your own series that really proves the trend or concept of reversibility? To me reversibility would mean that the vocal cord, the paraglottic space, and vocal ligament would be unimpaired by the existence of the implant until its removal. I don't know if we have proof of that. I would like to ask if you have any further evidence of that.

JAMES A. KOUFMAN, MD (Winston-Salem, NC): One of the advantages of medialization is that there is the opportunity for earlier voice restoration. If a 70-year-old preacher comes to you and you tell him to wait 6 to 12 months before you are going to do something, he is going to be very upset. Even with EMG there are situations in which you can't be certain about return of function. I have two cases, one is of a patient who had an encephalitis and multiple cranial nerves out. She was aspirating like crazy, was aphonic, had a feeding tube, and had a medialization and did just great. Three months later she came in, her voice was getting worse, and she sounded more gravelly. She was having return of movement of her vocal fold. In a case like that, when you take out the implant, a patient gets breathy for a while, because the thin fibrous capsule collapses. That is not true in the case I showed of the patient who extruded that very long, in terms of its anteroposterior dimension, implant. When an extrusion occurs, the inflammatory process, the granulation process, is such that all of that stuff is filled in with granulation tissue, so all bets are off in the case of an infected implant. I think with the newer shapes that are somewhat more conservative, particularly in their anteroposterior direction, they extrude out the front. When we try not to overcorrect, when we really need an arytenoid adduction with a huge medialization implant, the incidence of extrusion is going to be very small. In answer to your question, I think, there is a small fibrous capsule that has been demonstrated both experimentally and in these couple of patients. It collapses except in cases of extrusion.

LIDOCAINE EFFECTS ON THE LARYNGEAL CHEMOREFLEX, MECHANOREFLEX, AND AFFERENT ELECTRICAL STIMULATION REFLEX (p 199)

T. M. McCULLOCH, MD; P. W. FLINT, MD; M. A. RICHARDSON, MD; M. J. BISHOP, MD

LARYNGEAL SYNKINESIS FOLLOWING REINNERVATION IN THE RAT. NEUROANATOMIC AND PHYSIOLOGIC STUDY USING RETROGRADE FLUORESCENT TRACERS AND ELECTROMYOGRAPHY (p 206)

P. W. FLINT, MD; D. H. DOWNS, MD; M. D. COLTRERA, MD

CHARACTERISTICS OF LATE RESPONSES TO SUPERIOR LARYNGEAL NERVE STIMULATION IN HUMANS (p 216)

C. L. LUDLOW, PHD; F. VAN PELT, MD; J. KODA, SCD

ELECTROPHYSIOLOGIC INVESTIGATION OF LOWER CRANIAL NERVE DISEASES BY MEANS OF MAGNETICALLY STIMULATED NEUROMYOGRAPHY OF THE LARYNX (p 224)

W. F. THUMFART, MD; C. POTOTSCHNIG, MD; P. ZOROWKA, MD; H. E. ECKEL, MD

MARK RUBENSTEIN, MD (Fairfax, Va): I have a question for Dr Flint regarding the relative number of thyroarytenoid and posterior cricoarytenoid neurons within the nucleus ambiguus. Are there equal numbers or a preponderance of thyroarytenoid cell bodies, if that is known, and would that have some influence on the chance for reinnervation to appear to occur more in the thyroarytenoid area?

GAYLE WOODSON, MD (San Diego, Calif): I really enjoyed this last group of papers. I thought it was a really excellent group. I would like to address my comment to Dr Flint and would like to commend him on doing a very careful study. It appears that people who have worked with HRP have experienced a lot of difficulty with the HRP bleeding from one muscle to the other, so they could not be sure that it was going to the motor neuron at that muscle unless they cut other nerves. I wondered if you considered this and if you think the dyes are better. My second comment is that I would be cautious about talking about central reorganization, unless you are directly recording from those cell bodies. I mean, just because they are connected to different muscles does not necessarily imply that they have reorganized.

STEVEN D. SCHAEFER, MD (Dallas, Tex): Dr Flint, I also compliment you on the study. My problem is that the rat is a very different animal than a higher-level primate. I was wondering, given the work of, say, Jurgens or Pratt in Munich, how applicable you believe it would be to really try and understand what is happening at a higher-primate level, and if so, looking at other models such as monkeys, to make assumptions that might be more applicable.

PAUL W. FLINT, MD (Seattle, Wash): This is just to address the first question with regard to the number of cells. I think you can see in the normal animal we had a slightly larger number of cells that were posterior cricoarytenoid (PCA) or adductor cells that were being labeled. We thought this might be related to the dye itself, that maybe fast blue, which we use for the PCA cells, traveled in retrograde fashion at a greater rate or more efficiently than diamidino yellow. We alternated these dyes in control animals and we had the same result. I think you can see that following reinnervation there is a greater than 50% or about 50% decrease in the number of labeled cells, and the ratio has not changed significantly.

With regard to the animal model question and whether the rat is applicable to higher-level primates, I would say that it is. In a sense what I have proposed to look at in the future are these developmental cues or atrophic factors that are responsible for the motor neurons during regeneration, ie, finding the appropriate target muscle. It has been demonstrated in these animals that there is a difference between adults and neonates, and in different settings it was, but within the facial nerve and within the sciatic and diaphragmatic muscle. So, I think that it is a place to start.

I will next answer the question about the type of dye we used and whether there is contamination when using effective fluorescent dyes. We had very little contamination and actually, if you could go to No. 21, we used a series of controls and we did compare normal animals. We did a whole series of animals with HRP initially and we had some data on normal animals using HRP to begin with. We then compared those data with normal control animals using fluorescent tracers. This just shows a rostral-caudal distribution following labeling of the PCA and the TA, the PCA with fast blue and the TA with the diamidino yellow described before. And this is with the ipsilateral superior laryngeal nerve and the ipsilateral recurrent laryngeal nerve intact. We then cut the recurrent laryngeal nerve and labeled the muscle bodies again in the same fashion. This is the contamination that we saw in this group of animals. So, we are seeing a large number of cells above the obex. The zero mark is at the level of the obex. So, at about 0.6 mm above the obex, we start seeing a large group of cells that are being labeled. That's for PCA and TA cells. We then cut the superior laryngeal nerve and the recurrent laryngeal nerve on the same side and we get the same sort of pattern, except we do not have the TA cells. When we label the thyroarytenoid

muscles, we go through the cricothyroid muscle. So, I think that accounts for the contamination you saw through the superior laryngeal nerve and through the cricothyroid muscle. Again, it is 0.6 mm above the obex, and now what I think you are seeing at this point, with both the superior laryngeal nerve and the recurrent laryngeal nerve cut, you are seeing contamination through the pharyngeal constrictor muscles. All of this, if you will note, is 0.6 mm above the obex. Therefore, in our experimental design, we limited the confines of the nucleus ambiguus or those cells that we counted from 2 mm below the obex to 0.6 mm above the obex. In this way we avoided this area of contamination.

JOHN M. FREDRICKSON, MD (St Louis, Mo): I have one quick question for Dr Thumfart. I would like to know the accuracy of the magnetic stimulation and the cost of that procedure, and whether or not there is myogenic noise generated by the stimulation of other cranial nerves that interferes with his recordings.

WALTER F. THUMFART, MD (Cologne, Germany): The magnetic stimulation technique costs about 30,000 marks —$16,000 — and it induces model action potential in several of the lower cranial nerves. You can watch the reaction very precisely by looking at the face of the patient and also at their arm movements. But what is important is what you are detecting from the target muscles you are aiming for, ie, the laryngeal muscles, the cricopharyngeal muscles, or the pharyngeal muscles. It is bipolar recording that is necessary. The advantage of the method is that you do not have so many artifacts as with electrostimulation. We do not know why up to now, but it is very precisely latency time you can record with this method.

THE THREE BELLIES OF THE CANINE CRICOTHYROID MUSCLE (p 230)

L. S. ZARETSKY, MD; I. SANDERS, MD

MANAGEMENT OF AIRWAY OBSTRUCTION IN PATIENTS WITH CONGENITAL HEART DEFECTS (p 244)

D. A. DAVIS, MD; J. A. TUCKER, MD; P. RUSSO, MD

ACQUIRED LARYNGOMALACIA: EPIGLOTTIS PROLAPSE AS A CAUSE OF AIRWAY OBSTRUCTION (p 248)

P. WOO, MD

SPECIAL INSTRUMENTS FOR LARYNGEAL FRAMEWORK SURGERY (p 255)

N. ISSHIKI, MD; H. KOJIMA, MD; M. SAWADA, MD

INJECTION AND REMOVAL OF TEFLON FOR UNILATERAL VOCAL CORD PARALYSIS (p 258)

H. H. DEDO, MD

ETHMOID SURGERY COMPLICATIONS AND THEIR AVOIDANCE (p 264)

A. SOGG, MD; B. EICHEL, MD

IRRADIATION-INDUCED ATHEROSCLEROSIS: A FACTOR IN THERAPEUTIC PLANNING (p 267)

W. F. MCGUIRT, MD; R. S. FEEHS, MD; G. BOND, PHD;
H. L. STRICKLAND, DVM; W. M. MCKINNEY, MD

DEBORAH A. DAVIS, MD (Philadelphia, Pa): We are just going to show one video to illustrate one patient with obstruction in the right main bronchus now. The telescope is coming back, you'll see the pulsating large obstructive aorta as it compresses the lower trachea. This is the patient that was referred to in which the prosthesis was created by attaching an endotracheal tube within a Shiley collar to obtain the depth that was needed to relieve the obstruction. It is clear that this is the tube sliding down and into the lower airway to maintain patency of the left main bronchus. This child has done very well at home with this circumstance. You can see that in the long term there is granulation tissue that will respond to the tracheotomy tube itself. This we can

endoscopically remove at the times of our periodic examinations.

CHARLES N. FORD, MD (Madison, Wis): I would like to address my comments to Dr Dedo. First of all, I would like to congratulate Dr Dedo on an outstanding series and excellent illustrations. Having observed him operate, I can assure you that his technique is excellent and, I think, far superior to that of the average person doing this work. I bring this to your attention because of my experience over the past 10 years in reoperating on a number of patients who have had unsuccessful Teflon injections. We reported a series of 22 of these in Japan about 5 years ago and I'm sure that series has doubled now. I think the experience of others may not exactly replicate Dr Dedo's. There are three points I would like to make. One is that I question what you mean when you refer to normal phonation with a stiff vocal fold. I see this and we inject Teflon, and we see patients who have improved phonation and sound a lot better than they did when they had the breathy dysphonia. But, when you say normal phonation, does that mean that the patient felt that he or she spoke better or that the surgeon felt that he or she spoke better? I have not personally seen anyone who has been injected who had "normal phonation." The second question or comment is that there is an implication from what you illustrate and present that once the Teflon is removed that the process is reversible. In my experience, it is possible to recontour a vocal fold so that the contour looks the same but in fact the process, which includes fibrotic reaction to the Teflon, is a permanent change, and I don't believe that is a reversible event. The last thing I would like to comment on is that I feel there is a tone in some presentations such as this that suggests that one procedure is clearly better than another procedure in a very global sense. It seems that this tone is evident when we are dealing with an issue of glottic insufficiency associated with a number of problems such as multiple nerve injuries, scarring or posttraumatic injuries or congenital anomalies such as sulcus vocalis. All of these are manifested by glottic insufficiency. I don't think, at this stage, it does the specialty a great deal of good to say there is one technique that is clearly better than all other techniques. I think as a society and as a group we should be looking at the indications for specific techniques. Certainly there is a role for Teflon. There is a role for framework surgery and arytenoid adduction and all of these. I would urge us to adopt that approach in assessing these types of studies.

VIJAY ANAND, MD (Jackson, Miss): My questions, again, are directed to Dr Dedo's excellent paper. The first concerns those patients who have a combined superior laryngeal and recurrent laryngeal nerve palsy and present primarily not only with hoarseness but also with aspiration problems. Dr Dedo commented that he ignored the posterior glottic chink problem after Teflon injection. What happens to the small percentage of patients who continue to have aspiration? What is his recommendation about controlling aspiration in that group? The second question pertains to the long-term histologic aspects of Teflon injection. Is there any study that documents well the long-term changes of Teflon injection in view of some concerns in neurologic circles about the potential for malignancy from Teflon injection?

HERBERT H. DEDO, MD (San Francisco, Calif): With my high-frequency hearing loss, I am not sure I heard a word that was asked. I understand that Dr Ford asked what I mean by normal voice. I mean a voice that is clear as opposed to hoarse as opposed to husky, solid or nonwhispery as opposed to the whispery voice of a paralyzed vocal cord, and that is phonatory as opposed to a whisper. So, my definition of a normal voice is a clear, solid, phonatory voice. The characteristics you typically find with a paralyzed vocal cord are that the voice is soft, breathy, and poorly phonatory. Or, you have a paralytic falsetto if the patient has overcompensated with the other vocal cord. Of course, this can be cured if you bring the paralyzed vocal cord to the midline so the other one is not overly tight during closure. The fibrosis that develops after Teflon injection and even more so after Gelfoam injection is, I agree, not reversible, but it does not matter because if the edge of the cord is straight midline and the other cord can vibrate normally against it, you can get a clear voice. As far as the question about aspiration, I think that Teflon injection or framework surgery to medialize the membranous cord has difficulty eliminating it. I have been able to reduce it some and in some of these patients it is necessary, as I discuss in the dysphagia chapter of my surgical atlas, to do a cricopharyngeal myotomy. If neither of these techniques works with severe aspiration, it can be necessary to do a laryngectomy. I no longer do laryngotracheal separation because I would just as soon get the larynx out of the way and not do a laryngectomy in situ. By getting the larynx out of the way, you are able to then put a valve in and get Blom-Singer valve speech.

CHARLES J. KRAUSE, MD (Ann Arbor, Mich): I would like to commend Dr McGuirt on the excellent paper on a really important topic and ask a couple of questions. Do the changes continue over time like the progressive fibrosis of small vessels that you see, and if so, then presumably would 23% become significantly worse 5 or 10 years later? Secondly, what about the time to onset? How quickly do you see these changes?

W. FREDERICK MCGUIRT, MD (Winston-Salem, NC): These are questions that I have too and I cannot give you an answer — only an impression. I think that onset is of short duration, and I think you do see an early reaction due to the vasa vasoram being affected. I think it is an ongoing effect. Most of the people that we saw with the real severe complications were out several years. But I think you do see measurable differences at 6 months. We are in the process of putting together a multi-institutional study of the duration of the onset of disease and its continuity, and hopefully to better get a real feel for what is a real incidence of these complications in a prospective fashion.

DOUGLAS P. BRYCE, MD (Toronto, Canada): I was interested in Dr Woo's paper because we have published a large series of head injuries with airway problems and aspiration problems, and I have not seen prolapse of the epiglottis as described. I wanted to ask Dr Woo how these patients were being fed: by a nasogastric tube or by gastrostomy? Of course, the nasogastric tube can produce the picture that he showed us and I assume this was not the case.

PEAK WOO, MD (Syracuse, NY): All these patients were fed by gastrostomy tube. The patients that we had were in severe degrees of coma. They were not the very mild patients. That is, they may be neurologically intact, but they had severe neurological abnormalities of the pharynx and the larynx.

MEMORIALS

Lup Q. Pang, MD, died July 28, 1990, at the age of 83. A boxer at McKinley High School in Honolulu, Hawaii, he completed his premed studies at the University of Hawaii. He was one of the first Asians to journey to New Orleans, La, where he received his medical training and specialty training in eye, ear, nose, and throat. He was named by Tulane University School of Medicine as "alumnus extraordinaire" because of his establishment of the Hawaiian connection, with many students following him to Tulane in ensuing years.

He was known to most of us on the mainland as "the otolaryngologist of the islands." He became a member of the American Laryngological Association in 1961 and was elevated to emeritus status in 1984. A regular attendee and participant in the Association spring meetings, his warmth and presence will be missed.

He was a founder of the Chock-Pang Clinic and was a regent of the University of Hawaii. Former US Senator Hiram L. Fong described L. Q. as "a great individual, great humanitarian, great doctor, great father, and a great friend." Most of us can add that we concur and were also fortunate to have experienced his warm personal friendship.

He was a founder and one-sixth owner of the Finance Factors Family of Companies, of which he held various positions and was a director for many years. He contributed his time and resources to help the poor and the sick and was a member of the Finance Factors Endowments, a group dedicated to charity work. He rose to membership in many of our medical organizations. He served as president of the American Society of Ophthalmologic and Otolaryngologic Allergy, and was a member of the Hawaii Eye, Ear, Nose and Throat Society and the Hawaii chapter of the American College of Surgeons. He was

LUP Q. PANG
1907-1990

a member of the St Francis Medical Center, and was head of its Department of Eye, Ear, Nose and Throat, and he was a member of the East-West Center National Review Board.

Dr Pang is survived by his wife, Tita C.; a daughter, Didi P. Leong; sons, Dr Meredith K. L., Dr Derek K. H., and Wendell K. K., president of Finance Factors; brothers, C. Q. and Dr H. Q. Pang; sisters, Beatrice Lum and Myrtle Tom; and four grandchildren.

P.H.W.

Peter N. Pastore was born in Bluefield, West Virginia, November 8, 1907, and died in Richmond, Virginia, September 16, 1989.

He graduated from Bluefield's Beaver High School in 1926 and continued his education at Bluefield College, where he received a Certificate of Proficiency in 1928. He received an AB degree from the University of Richmond in 1930, where he was a member of the Phi Beta Kappa Epsilon Honor Society. His medical degree was earned at the Medical College of Virginia in 1934, where he became a member of Alpha Omega Alpha Honor Medical Society. Dr Pastore completed his internship and residency at the Medical College of Virginia in 1936. He trained as a fellow at the Mayo Clinic and received an MS in otolaryngology from the University of Minnesota in 1939. He remained on the staff of the Mayo Clinic until 1942, after which he became the first professor and chairman of the Department of Otology, Rhinology, Laryngology, Audiology, and Speech Pathology at the Medical College of Virginia in Richmond. He served as professor and chairman until the time of his retirement in 1976. As emeritus professor, he maintained an active role in student and resident education.

Dr Pastore has always been a dedicated academician with a precise mind, a gentle touch, and a sincere interest in students, patients, and colleagues. He was a tenacious researcher with a driving desire for documentation of all events, whether they were medical, historical, or simple relaxation with family or friends. His camera was always within reach and ready for action. He had an interest in the McGuire Veterans Administration Medical Center and was Chief of Otolaryngology until 1976, after which he served as Director of Continuing Medical Education for Otolaryngology until his death. He also served on the faculty of the American Academy of Ophthalmology and Otolaryngology from 1951 until 1975. Dr Pastore published more than 45 scholarly works that covered all aspects of otolaryngology and medicine in general.

Dr Pastore was president of the Richmond Eye, Ear Nose and Throat Society (1945-1946); president of the Virginia Society of Ophthalmology and Otolaryngology (1952-1953); president of The International Association to Secretaries of Ophthalmological and Otolaryngological Societies (1959-1962); president of the Medical College of Virginia Alumni Society (1961-1962); president of the American Cancer Society, Richmond Unit (1960-1961); and president of the International College of Surgeons, Virginia Division (1962-1964). He was on numerous



PETER N. PASTORE
1907-1989

boards and was a life member of most of the major medical, surgical, and otolaryngological societies.

Dr Pastore had a strong commitment to community and religious organizations. He was president of the Catholic Physicians Guild (1962-1964). He was president of the board of Benedictine High School (1964-1966) and was on their advisory board since 1974. He was on the advisory board for the National Council for Christians and Jews since 1964. He was president of The Easter Seal Society of Richmond (1967-1970) and served as treasurer of that organization (1980-1985). He was on the board of The Richmond Children's Aid Society (1944-1947) and on the board of The Virginia Society for Crippled Children and Adults (1954-1974). He has received numerous honors and awards, including Medical-Scroll, Algernon Sydney Sullivan Award in Recognition of Spiritual and Humanitarian Service (1982); Outstanding Contributions to the Communicatively Handicapped in Virginia (1980); Virginia Cultural Laureate Society, Laureate of Virginia (1986); Award for Long Years of Commitment and Service to the Lives of People with Disabilities, The Easter Seal Society of Virginia, Inc, and The Presidential Medallion, Virginia Commonwealth University (1987).

Dr Pastore was founder of several funds and services. He was the first Director and Lecturer on Medicine and Medical Advances (1983) for Elderhostel

(the first and only in the world as of 1984). He established the Peter N. and Julia Pastore Professorship in Otolaryngology Fund through the Medical College of Virginia Foundation. He was founder of the Pastore Otolaryngology and Medical Artifacts Historical Collection, Medical College of Virginia, Virginia Commonwealth University, and Tompkins-McCaw Library Special Collections Archives in 1977, and devoted much of his time and resources to the artifacts collection during his retirement years. It is a tribute to his desire to document and preserve history.

Dr Pastore was a true Southern gentleman and a very kind and very gracious person. He has endeared the hearts of those who had the privilege to meet him, and it is unlikely he ever met a person he did not like. He was a devoted husband and father with strong religious convictions. He was a friend and a humanitarian par excellence.

G.H.W.

Dr Sam Houston Sanders was born in Holly Springs, Mississippi, on May 1, 1900, and died in Memphis, Tennessee, on March 14, 1991. He was 90 years of age. He was a prominent physician, sportsman, and philanthropist in his local community.

Dr Sanders graduated from Texas A & M in 1922. He lettered in four major sports and was captain of each team. He was a member of the famous 12th Man Team at A & M. Although he never weighed more than 122 pounds, he played football for the Aggies from 1919 to 1922, appearing in the first Cotton Bowl. In 1921, Dr Sanders was named All-Southwest Conference halfback and was a member of the All-Conference track team. A versatile athlete, he held records in the 440-yard dash and in the high jump.

He decided to study medicine at The University of Tennessee. On a campus visit in 1922, Dr Sam learned of the football team that was composed of medical, dental, and pharmacy students. It was called the "UT Docs," and it played from 1921 to 1926. As star quarterback, Dr Sanders led the team to a record of only one loss during his playing years.

For many years he served as a Southeastern Conference football game official and officiated at games in the Rose, Cotton, and Orange Bowls. He was credited with several innovative techniques and procedures that provided safety and care for injured football players.

He was installed as a member of the Tennessee Sports Hall of Fame.

Dr Sanders earned his medical degree from Tennessee in 1927, practiced otolaryngology and allergy, and joined the UT faculty in 1928. He served as chairman of the Department of Otolaryngology from 1954 to 1971, and was emeritus professor until his death.

SAM H. SANDERS
1900-1991

He received Texas A & M's Distinguished Alumni Award a few years ago and was named to that university's Hall of Fame. Allergy and sinus disease were the focus of his interest. He was a founding member of the American College of Allergy and a member of 38 professional, international, and honorary societies.

He established the Sam Houston Sanders Medical Foundation at Tennessee to assist residents and to honor his father. He was the widower of Marianne Sanders.

E.W.C.

OFFICERS 1879-1990

Presidents

1879 Louis Elsberg
1880 J. Solis-Cohen
1881 F. I. Knight
1882 G. M. Lefferts
1883 F. H. Bosworth
1884 E. L. Shurly
1885 Harrison Allen
1886 E. Fletcher Ingals
1887 R. P. Lincoln
1888 E. C. Morgan
1889 J. N. Mackenzie
1890 W. C. Glasgow
1891 S. W. Langmaid
1892 M. J. Asch
1893 D. Bryson Delavan
1894 J. O. Roe
1895 W. H. Daly
1896 C. H. Knight
1897 T. R. French
1898 W. E. Casselberry
1899 Samuel Johnston
1900 H. L. Swain
1901 J. W. Farlow
1902 J. H. Bryan
1903 J. H. Hartman
1904 C. C. Rice
1905 J. W. Gleitsmann
1906 A. W. de Roaldes
1907 H. S. Birkett
1908 A. Coolidge, Jr
1909 J. E. Logan
1910 D. Braden Kyle
1911 James E. Newcomb
1912 George A. Leland
1913 Thomas Hubbard
1914 Alexander W. MacCoy
1915 G. Hudson Makuen
1916 Joseph L. Goodale
1917 Thomas H. Halsted
1918 Cornelius G. Coakley
1919 Norval H. Pierce
1920 Harris P. Mosher
1921 Harmon Smith
1922 Emil Mayer
1923 J. Payson Clark
1924 Lee Wallace Dean
1925 Greenfield Sluder
1926 Chevalier Jackson
1927 D. Bryson Delavan
1928 Charles W. Richardson
1929 Lewis A. Coffin
1930 Francis R. Packard
1931 George E. Shambaugh
1932 George Fetterolf
1933 George M. Coates
1934 Dunbar Roy
1935 Burt R. Shurly
1936 William B. Chamberlain
1937 John F. Barnhill
1938 George B. Wood
1939 James A. Babbitt
1940 Gordon Berry
1941 Thomas E. Carmody
1942-3 Charles J. Imperatori
1944-5 Harold I. Lillie
1946 Frank R. Spencer
1947 Arthur W. Proetz
1948 Frederick T. Hill
1949 Ralph A. Fenton
1950 Gordon B. New
1951 H. Marshall Taylor
1952 Louis H. Clerf
1953 Gordon F. Harkness
1954 Henry B. Orton
1955 Bernard J. McMahon
1956 LeRoy A. Schall
1957 Harry P. Schenck
1958 Fred W. Dixon
1959 William J. McNally
1960 Edwin N. Broyles
1961 Dean M. Lierle
1962 Francis E. LeJeune
1963 Anderson C. Hilding
1964 Albert C. Furstenberg
1965 Paul H. Holinger
1966 Joel J. Pressman
1967 Lawrence R. Boies
1968 Francis W. Davison
1969 Alden H. Miller
1970 DeGraaf Woodman
1971 F. Johnson Putney
1972 Frank D. Lathrop
1973 G. Slaughter Fitz-Hugh
1974 Daniel C. Baker
1974 Joseph H. Ogura
1975 Stanton A. Friedberg
1976 Charles M. Norris
1977 Charles F. Ferguson
1978 John F. Daly
1979 John A. Kirchner
1980 Daniel Miller
1981 Harold C. Tabb
1982 M. Stuart Strong
1983 John S. Lewis
1984 Gabriel F. Tucker, Jr
1985 Douglas P. Bryce
1986 Loring W. Pratt
1987 Blair Fearon
1988 Seymour R. Cohen
1989 Eugene N. Myers
1990 James B. Snow, Jr

Vice-Presidents (First and Second)

1879 F. H. Davis
1880 W. C. Glasgow, J. O. Roe
1881 E. L. Shurly, W. Porter
1882 C. Seiler, E. F. Ingals
1883 S. W. Langmaid, S. Johnston
1884 J. H. Hartman, W. H. Daly
1885 H. A. Johnson, G. W. Major
1886 E. C. Morgan, J. N. Mackenzie
1887 J. N. Mackenzie, S. W. Langmaid
1888 W. C. Glasgow, C. E. DeM. Sajous
1889 F. Holden, C. E. Bean
1890 J. O. Roe, J. H. Hartman
1891 M. J. Asch, S. Johnston
1892 S. Johnston, J. C. Mulhall
1893 J. C. Mulhall, W. E. Casselberry
1894 C. C. Rice, S. H. Chapman
1895 J. Wright, A. W. de Roaldes
1896 T. M. Murray, D. N. Rankin
1897 A. W. MacCoy, H. S. Birkett
1898 J. W. Farlow, F. W. Hinkel
1899 T. A. DeBlois, M. R. Brown
1900 H. L. Wahner, A. A. Bliss
1901 J. W. Gleitsmann, D. Braden Kyle
1902 G. A. Leland, T. Melville Hardie
1903 J. H. Lowman, W. Peyre Porcher
1904 Thomas Hubbard, W. J. Freeman
1905 J. L. Goodale, C. W. Richardson
1906 G. H. Makuen, A. R. Thrasher
1907 J. P. Clark, J. E. Rhodes
1908 E. Mayer, F. R. Packard
1909 C. G. Coakley, H. P. Mosher
1910 Robert C. Myles, J. M. Ingersoll
1911 F. C. Cobb, B. R. Shurly
1912 A. W. Watson, W. Scott Renner
1913 F. E. Hopkins, George E. Shambaugh
1914 Clement T. Theisen, Lewis A. Coffin
1915 J. Gordon Wilson, Christian R. Holmes
1916 Thomas H. Halsted, Greenfield Sluder
1917 John Edwin Rhodes, D. Crosby Greene
1918 George E. Shambaugh, John R. Winslow

1919 Francis R. Packard, Harmon Smith
1920 Harmon Smith, W. B. Chamberlin
1921 Dunbar Roy, Robert C. Lynch
1922 George Fetterolf, Lorenzo B. Lockard
1923 Hubert Arrowsmith, Joseph B. Greene
1924 Ross H. Skillern, Gordon Berry
1925 John E. Mackenty, Robert Levy
1926 Lewis A. Coffin, William V. Mullin
1927 Charles W. Richardson, Hill Hastings
1928 Robert Clyde Lynch, Francis P. Emerson
1929 William B. Chamberlin, Ralph Albert Fenton
1930 Harris P. Mosher, James A. Babbitt
1931 Joseph B. Greene, E. Ross Faulkner
1932 Gordon Berry, Frank R. Spencer
1933 E. Ross Faulkner, Thomas S. Carmody
1934 Gordon B. New, Samuel McCullagh
1935 Edward C. Sewall, H. Marshall Taylor
1936 William P. Wherry, Harold I. Lillie
1937 Frank R. Spencer, Bernard J. McMahon
1938 Ralph A. Fenton, Frederick T. Hill
1939 John H. Foster, Thomas R. Gittins
1940 Charles H. Porter, Gordon F. Harkness
1941 Arthur W. Proetz, Henry B. Orton
1942-3 Harold I. Lillie, Dean M. Lierle
1944-5 John J. Shea, Thomas C. Galloway
1946 H. Marshall Taylor, C. Stewart Nash
1947 John J. Shea, Frederick A. Figi
1948 Henry B. Orton, Anderson C. Hilding
1949 LeRoy A. Schall, Fletcher D. Woodward
1950 W. Likely Simpson, Lyman G. Richards
1951 William J. McNally, Thomas C. Galloway
1952 J. Mackenzie Brown, Edwin N. Broyles
1953 Claude C. Cody, Daniel S. Cunning
1954 James H. Maxwell, Clyde A. Heatly
1955 Robert L. Goodale, Paul H. Holinger
1956 Henry M. Goodyear, Robert E. Priest
1957 Francis E. LeJeune, Pierre P. Viole
1958 Charles Blassingame, Chevalier L. Jackson
1959 James H. Maxwell, Oliver Van Alyea
1960 Walter Theobald, Anderson C. Hilding
1961 Julius W. McCall, P. E. Ireland
1962 Paul M. Moore, Jerome A. Hilger
1963 Paul M. Holinger, Lester A. Brown
1964 B. Slaughter Fitz-Hugh, Daniel C. Baker
1965 C. E. Munoz-MacCormick, Arthur J. Cracovaner
1966 Lawrence R. Boies, G. Edward Tremble
1967 John F. Daly, Stanton A. Friedberg
1968 DeGraaf Woodman, John Murtagh
1969 Joseph P. Atkins, Stanton A. Friedberg
1970 Robert B. Lewy, Oliver W. Suehs
1971 James A. Harrill, James D. Baxter
1972 Francis L. Weille, Sam H. Sanders
1973 William H. Saunders, Blair Fearon
1974 Joseph H. Ogura, Douglas P. Bryce, John A. Kirchner
1975 John S. Lewis, Edwin W. Cocke, Jr
1976 Emanuel M. Skolnik, John T. Dickinson
1977 J. Ryan Chandler, Herbert H. Dedo
1978 John E. Bordley, Lester A. Brown
1979 Albert H. Andrews, Seymour R. Cohen
1980 John Frazer, George A. Sisson

Vice-Presidents (Presidents-Elect)

1981 M. Stuart Strong
1982 John S. Lewis
1983 Gabriel F. Tucker, Jr
1984 Douglas P. Bryce
1985 Loring W. Pratt
1986 Blair Fearon
1987 Seymour R. Cohen
1988 Eugene N. Myers
1989 James B. Snow, Jr
1990 John M. Fredrickson

Secretaries and Treasurers

1879 G. M. Lefferts
1882 D. Bryson Delavan
1889 C. H. Knight
1895 H. L. Swain
1900 P. E. Newcomb
1911 Harmon Smith

Secretaries

1912 Harmon Smith
1918 D. Bryson Delavan
1919 J. M. Ingersoll
1920 George W. Coates
1933 William V. Mullin
1935 James A. Babbitt
1939 Charles J. Imperatori
1942 Arthur W. Proetz
1947 Louis H. Clerf
1952 Harry P. Schenck
1957 James H. Maxwell
1959 Lyman G. Richards
1968 Frank D. Lathrop
1972 John F. Daly
1977 William MacL. Trible
1982 Eugene N. Myers
1988 H. Bryan Neel III

Treasurers

1912 J. Payson Clark
1923 George Fetterolf
1932 William V. Mullin
1933 James A. Babbitt
1935 Charles J. Imperatori
1939 Frederick T. Hill
1948 Gordon F. Harkness
1953 Fred W. Dixon
1958 Francis E. LeJeune
1962 Alden H. Miller
1969 Charles M. Norris
1976 Harold G. Tabb
1981 Loring W. Pratt
1985 John M. Fredrickson
1990 Robert W. Cantrell

Librarians

1879 F. H. Bosworth
1883 T. R. French
1903 J. H. Bryan

1930 John F. Barnhill
1934 Burt R. Shurly
1935 George M. Coates

Librarian and Historian

1936 George M. Coates
1944 Louis H. Clerf

Librarian, Historian and Editor

1947 Harry P. Schenck
1952 Bernard J. McMahon
1955 Edwin N. Broyles
1960 Francis W. Davison
1964 F. Johnson Putney
1971 Charles F. Ferguson
1977 Gabriel F. Tucker, Jr
1983 James B. Snow, Jr
1989 Paul H. Ward

DECEASED FELLOWS

Dates indicate original election to the Association.

Honorary Fellows

1946 Alonso, Justo M., Montevideo, Uruguay
1908 Barnhill, John F., Miami Beach, Fla
1893 Birkett, Herbert S., Montreal
1878 Bosworth, Francke H., New York
1940 Broyles, Edwin N., Baltimore
1917 Coates, George M., Philadelphia
1925 Clerf, Louis H., St Petersburg, Fla
1918 Dean, Lee Wallace, St Louis
1881 Delavan, D. Bryson, New York
1890 De La Sota y Lastra, Ramon, Seville, Spain
1893 de Roaldes, Arthur W., New Orleans
1923 Fenton, Ralph A., Portland, Ore
1879 French, Thomas R., Brooklyn, NY
1936 Galloway, Thomas C., Evanston, Ill
1880 Garcia, Manuel, London
1903 Harris, Thomas J., New York
1943 Hilding, Anderson C., Duluth, Minn
1928 Hill, Frederick T., Waterville, Me
1945 Holinger, Paul H., Chicago
1957 Huizinga, Eelco, Groningen, the Netherlands
1907 Jackson, Chevalier, Schwenksville, Pa
1878 Johnston, Samuel, Baltimore
1878 Lefferts, George Morewood, Katonah, NY
1914 Levy, Robert, Denver
1918 Lewis, Fielding O., Media, Pa
1933 Lierle, Dean M., Iowa City
1883 Mackenzie, John N., Baltimore
1881 Mackenzie, Sir Morell, London
1910 Masser, Ferdinand, Naples, Italy
1904 Mosher, Harris P., Marblehead, Mass
1910 Moure, J. J. E., Bordeaux, France
1937 Nager, F. R., Zurich
1930 Negus, Sir Victor E., London
1918 Oliver, H. K., Boston
1957 Ono, Jo, Tokyo
1906 Pierce, Norval Harvey, San Diego
1937 Portmann, Georges, Bordeaux, France
1924 Proetz, Arthur C., St Louis
1932 Schall, LeRoy A., Boston
1909 Semon, Sir Felix, Great Missenden, England
1878 Solis-Cohen, J., Philadelphia
1973 Som, Max L., New York
1889 Swain, Henry L., New Haven, Conn
1914 Thomson, Sir St Clair, London
1903 Tilley, Herbert, London
1914 Wagner, Clinton, New York
1948 Williams, Henry L., Rochester, Minn
1951 Woodman, DeGraaf, New York
1890 Wright, Jonathan, Pleasantville, NY

Corresponding Fellows

1972 Arslan, Michele, Padua, Italy
1942 Batson, Oscar V., Philadelphia
1938 Blair, Vilray P., St Louis
1892 Browne, Lennox, London
1968 Cawthorne, Sir Terence, London
1940 Colledge, Lionel, London
1901 Collier, Mayo, Kearsney Abbey, Kent, England
1893 Desvernine, Carlos M., Havana
1966 Dohlman, Gösta, East Bradenton, Fla
1943 Eggston, Andrew A., New York
1930 Emerson, Francis P., Franklin, Mass
1961 Faaborg-Anderson, Kund, Nykobing, Denmark
1936 Fraser, John S., Edinburgh
1887 Gougenheim, A., Paris
1901 Grant, Sir James Dundas, London
1894 Holden, Edgar, Newark, NJ
1919 Kelly, Adam Brown, Helensburgh, Scotland
1881 Labus, Carlo, Milan, Italy
1950 Larsell, Olof, Portland, Ore
1931 LaSagna, Francesco, Parma, Italy
1926 Law, Frederick M., New York
1921 LeMaitre, Ferdinand, Paris
1902 Lermoyez, Marcel, Paris
1897 Luc, H., Paris
1896 MacDonald, Greville, Haslemere, England
1894 MacIntyre, John, Glasgow, Scotland
1903 McBride, P., York, England
1920 McKenzie, Dan, London
1919 McKernon, James F., New Canaan, Conn
1880 Meyer, Wilhelm, Copenhagen
1896 Mygind, Holger, Copenhagen
1950 Neil, James Hardie, Auckland, New Zealand
1919 Paterson, Donald Rose, Cardiff, Wales
1941 Patterson, Norman, Herts, England
1971 Rethi, Aurelius, Budapest
1919 Rogers, John, Jr, New York
1894 Sajous, C. E. DeM., Philadelphia
1924 Schaefer, J. Parson, Philadelphia
1896 Schmiegelow, Ernst, Copenhagen
1946 Segura, Eliseo, Buenos Aires
1940 Soto, E. Fernandez, Havana
1881 Thornton, Pugin, London
1913 Turner, A. Logan, Edinburgh
1880 Whistler, W. McNeil, London
1901 Wingrave, Wyatt, Lyme Regis, England
1894 Wolfenden, R. Norric, Kent, England

Emeritus Fellows

1962 Arnold, Godfrey E., Clinton, Miss
1936 Ballenger, Howard C., Winnetka, Ill
1923 Barlow, Roy A., Nova Scotia, Canada
1915 Barnes, Harry Aldrich, Kingston, Mass
1944 Beatty, Hugh G., Columbus, Ohio
1928 Beck, Joseph C., Chicago
1921 Berry, Gordon, Worcester, Mass
1944 Boies, Lawrence R., Minneapolis
1941 Bowers, Wesley C., New York
1901 Brown, J. Price, Toronto
1955 Brown, Lester A., Atlanta
1891 Bryan, Joseph H., Washington, DC

1913 Butler, Ralph, Philadelphia
1930 Campbell, Edward H., Philadelphia
1945 Campbell, Paul A., San Antonio, Tex
1959 Cardwell, Edgar P., Newark, NJ
1897 Clark, J. Payson, Boston
1899 Cobb, Frederick C., Bradenton, Fla
1939 Cody, Claude C., Jr, Houston
1905 Coffin, Lewis A., New York
1957 Converse, John Marquis, New York
1893 Coolidge, Algernon, Boston
1959 Cracovaner, Arthur J., New York
1937 Crowe, Samuel H., Baltimore
1941 Cunning, Daniel S., New York
1913 Dabney, Virginia, Washington, DC
1951 Davison, Francis W., Danville, Pa
1882 De Blois, Thomas Amory, Boston
1968 DeWeese, David D., Portland, Ore
1941 Dixon, Fred W., Shaker Heights, Ohio
1947 Eagle, Watt W., New Bern, NC
1892 Farlow, John W., Boston
1930 Figi, Frederick A., Rochester, Minn
1955 Fitz-Hugh, G. Slaughter, Charlottesville, Va
1922 Forbes, Henry H., New York
1933 Foster, John H., Houston
1905 Freer, Otto T., Chicago
1932 Furstenberg, Albert C., Ann Arbor, Mich
1940 Gatewood, E. Trible, Richmond, Va
1928 Gittins, Thomas R., Sioux City, Iowa
1880 Gleitsmann, Joseph W., New York
1922 Goldsmith, Perry G., Toronto
1898 Goodale, Joseph L., Ipswich, Mass
1940 Goodale, Robert L., Ipswich, Mass
1965 Goodyear, Henry M., Cincinnati
1932 Graham, Harrington B., San Francisco
1906 Greene, D. Crosby, Jr, Boston
1917 Greene, Joseph B., Asheville, NC
1950 Hall, Colby, Encino, Calif
1970 Halliday, Sir George C., Sydney, Australia
1905 Halsted, Thomas H., Los Angeles
1940 Hansel, French K., St Louis
1896 Hardie, Thomas Melville, Chicago
1959 Hart, Verling K., Charlotte, NC
1915 Hastings, Hill, Los Angeles
1944 Havens, Fred Z., Rochester, Minn
1888 Hinkel, Frank Whitehill, Buffalo
1944 Hoople, Gordon D., Syracuse, NY
1895 Hopkins, Frederick E., Springfield, Mass
1930 Houser, Karl M., Ardmore, Pa
1927 Hubbard, Thomas, Toledo
1919 Hurd, Lee Maidment, Rowayton, Conn
1920 Imperatori, Charles J., Essex, NY
1904 Ingersoll, John Marvin, Miami
1952 Ireland, Percy E., Toronto
1928 Jarvis, DeForest C., Barre, Vt
1939 Johnston, William H., Santa Barbara, Calif
1942 Kelly, Joseph D., New York
1918 Kenyon, Elmer L., Chicago
1921 Kernan, John D., New York
1965 King, James T., Atlanta
1929 Kistner, Frank B., Portland, Ore
1950 Kline, Oram R., Woodbury Heights, NJ
1885 Knight, Charles H., New York
1939 Large, Secord H., Cleveland
1963 Lathrop, Frank D., Pittsford, Vt
1939 LeJeune, Francis E., New Orleans
1894 Leland, George A., Boston
1922 Lillie, Harold I., Rochester, Minn
1943 Lincoln, William R., Cleveland
1949 Lindsay, John R., Evanston, Ill
1927 Lukens, Robert M., Wildwood Crest, NJ
1928 Lyman, Harry Webster, St Louis
1886 MacCoy, Alexander W., Philadelphia
1928 MacPherson, Duncan, New York
1941 Martin, Robert C., San Francisco
1896 Mayer, Emil, New York
1952 McCall, Julius W., Shaker Heights, Ohio
1951 McCart, Howard W. D., Toronto
1939 McCaskey, Carl H., Indianapolis
1943 McCullagh, Samuel, New York
1963 McGovern, Francis H., Danville, Va
1951 McHenry, Lawrence C., Oklahoma City
1923 McKinney, Richmond, Memphis
1933 McMahon, Bernard J., St Louis
1931 McNally, William J., Montreal
1954 Moore, Paul McN., Delray Beach, Fla
1953 Murtagh, John A., Hanover, NH
1939 Myers, John L., Kansas City, Mo
1927 Myerson, Mervin C., New York
1901 Myles, Robert C., New York
1937 Nash, C. Stewart, Rochester, NY
1922 New, Gordon B., Rochester, Minn
1923 Newhart, Horace, Minneapolis
1958 O'Keefe, John J., Philadelphia
1903 Packard, Francis R., Philadelphia
1961 Pang, Lup Q., Honolulu, HI
1961 Pastore, Peter N., Richmond, Va
1948 Phelps, Kenneth A., Burlington, NC
1878 Porter, William, Ocean Springs, Mass
1942 Potts, John B., Omaha
1951 Rawlins, Aubrey G., San Francisco
1903 Renner, W. Scott, Buffalo
1897 Rhodes, John Edwin, Chicago
1884 Rice, Clarence C., New York
1905 Richards, George L., South Yarmouth, Mass
1878 Robinson, Beverly, New York
1938 Salinger, Samuel, Palm Springs, Calif
1959 Sanders, Sam H., Memphis
1921 Sauer, William E., St Louis
1934 Schenck, Harry P., Philadelphia
1923 Sewall, Edward C., Palo Alto, Calif
1930 Seydell, Ernest M., Wichita, Kan
1907 Shambaugh, George E., Chicago
1939 Simpson, W. Likely, Memphis
1950 Smith, Austin T., Philadelphia
1908 Smith, Harmon, New York
1954 Sooy, Francis A., San Francisco
1923 Spencer, Frank R., Boulder, Colo
1947 Theobald, Walter H., Chicago
1927 Tobey, Harold G., Boston
1950 Tremble, G. Edward, Montreal
1925 Tucker, Gabriel, Haverford, Pa
1943 Van Alyea, Oliver E., Chicago
1941 Violé, Pierre, Los Angeles
1892 Wagner, Henry L., San Francisco
1892 Watson, Arthur W., Philadelphia
1948 Whalen, Edward J., Hartford, Conn
1922 White, Francis W., New York
1939 Wilson, J. Gordon, Old Bennington, Vt
1905 Wood, George B., Wynnewood, Pa
1935 Woodward, Fletcher D., Charlottesville, Va

Active Fellows

1958 Alfaro, Victor R., Washington, DC
1880 Allen, Harrison, Philadelphia
1969 Andrews, Albert H., Jr, Chicago
1917 Arrowsmith, Hubert, Brooklyn, NY
1879 Asch, Morris J., New York
1942 Ashley, Rae E., San Francisco
1958 Atkins, Joseph P., Philadelphia
1923 Babbitt, James A., Philadelphia
1906 Ballenger, William L., Chicago
1880 Bean, C. E., St Paul
1949 Beck, August L., New Rochelle, NY
1904 Berens, T. Passmore, New York
1924 Bigelow, Nolton, Providence, RI
1938 Blassingame, Charles D., Memphis
1893 Bliss, Arthur Ames, Philadelphia
1951 Boyden, Guy L., Portland, Ore
1895 Boylan, J. E., Cincinnati
1932 Brown, John Mackenzie, Los Angeles
1892 Brown, Moreau R., Chicago
1933 Buckley, Robert E., New York
1915 Canfield, R. Bishop, Ann Arbor, Mich
1934 Carmack, John Walter, Indianapolis
1924 Carmody, Thomas E., Denver
1889 Casselberry, William E., Chicago
1883 Chamberlain, C. W., Hartford, Conn
1917 Chamberlin, William B., Cleveland
1882 Chapman, S. Hartwell, New Haven, Conn
1896 Chappell, W. F., New York
1902 Coakley, Cornelius G., New York
1913 Coffin, Rockwell C., Boston
1918 Cox, Gerald H., New York
1880 Cushing, E. W., Boston
1878 Cutter, Ephraim, West Falmouth, Mass
1880 Daly, W. H., Pittsburgh
1878 Davis, F. H., Chicago
1941 Davis, Warren B., Philadelphia
1926 Dennis, Frank Lownes, Colorado Springs, Colo
1901 Dickerman, E. T., Chicago
1969 Dickinson, John T., Pittsburgh
1878 Donaldson, Frank, Baltimore
1954 Equen, Murdock S., Atlanta
1935 Eves, Curtis C., Philadelphia
1919 Faulkner, E. Ross, New York
1914 Fetterolf, George, Philadelphia
1901 Freeman, Walter J., Philadelphia
1917 Friedberg, Stanton A., Chicago
1897 Frothingham, Richard, New York
1940 Fuchs, Valentine H., New Orleans
1909 Getchell, Albert C., Worcester, Mass
1907 Gibb, Joseph S., Philadelphia
1940 Gill, William D., San Antonio, Tex
1878 Glasgow, William Carr, St Louis
1913 Goldstein, Max A., St Louis
1905 Grayson, Charles P., Philadelphia
1934 Grove, William E., Milwaukee
1933 Harkness, Gordon F., Davenport, Iowa
1957 Harrill, James A., Winston-Salem, NC
1878 Hartman, J. H., Baltimore
1945 Hickey, Harold L., Denver
1879 Holden, Edgar, Newark, NJ
1907 Holmes, Christian R., Cincinnati
1882 Hooper, Franklin H., Boston
1893 Hope, George B., New York
1938 Hourn, George E., St Louis
1939 Hunt, Westley Marshall, New York
1901 Hyatt, Frank, Washington, DC
1925 Iglauer, Samuel, Cincinnati
1878 Ingals, E. Fletcher, Chicago
1882 Ives, Frank L., New York
1938 Jackson, Chevalier L., Philadelphia
1880 Jarvis, William C., New York
1878 Johnson, Hosmer A., Chicago
1879 Johnson, Woolsey, New York
1960 Johnston, Kenneth C., Chicago
1961 Jones, Edley H., Vicksburg, Miss
1944 Jones, Marvin F., New York
1879 Kealhofer, R. H., St Louis
1964 Keim, W. Franklin, Montclair, NJ
1942 King, Edward D., North Hollywood, Calif
1901 King, Gordon, New Orleans
1878 Knight, Frederick Irving, Boston
1965 Knight, John S., Kansas City, Mo
1898 Kyle, D. Braden, Philadelphia
1880 Langmaid, Samuel W., Boston
1953 Lederer, Francis L., Chicago
1878 Lincoln, Rufus P., New York
1911 Lockard, Lorenzo B., Denver
1913 Loeb, Hanau W., St Louis
1897 Logan, James E., Kansas City, Mo
1935 Looper, Edward A., Baltimore
1888 Lowman, John H., Cleveland
1919 Lynah, Henry L., New York
1952 Lynch, Mercer G., New Orleans
1915 Lynch, Robert Clyde, New Orleans
1914 Mackenty, John E., New York
1881 Major, G. W., Montreal
1898 Makuen, G. Hudson, Philadelphia
1948 Maxwell, James H., Ann Arbor, Mich
1879 McBurney, Charles, New York
1927 McGinnis, Edwin, Chicago
1936 McGregor, Gregor, Toronto
1913 McKimmie, O. A., Washington, DC
1945 McLaurin, John G., Dallas
1885 McSherry II, Clinton, Baltimore
1954 Meltzer, Philip E., Boston
1958 Montreuil, Fernand, Montreal
1881 Morgan, E. C., Washington, DC
1950 Morrison, Lewis F., San Francisco
1940 Morrison, William W., New York
1886 Mulhall, J. C., St Louis
1925 Mullin, William V., Cleveland
1914 Munger, Carl E., Waterbury, Conn
1892 Murray, T. Morris, Washington, DC
1881 Mynter, H., Buffalo
1893 Newcomb, James E., New York
1895 Nichols, J. E. H., New York
1961 Ogura, Joseph H., St Louis
1927 Orton, Henry B., Newark, NJ
1894 Park, William H., New York
1892 Porcher, W. Peyre, Charleston, SC
1927 Porter, Charles T., Boston
1954 Pressman, Joel J., Los Angeles
1908 Randall, B. Alexander, Philadelphia
1882 Rankin, D. N., Allegheny, Pa
1934 Richards, Lyman G., Wellesley Hills, Mass
1902 Richardson, Charles W., Washington, DC
1930 Ridpath, Robert E., Philadelphia
1945 Robb, James M., Detroit

1953 Roberts, Sam E., Kansas City, Mo
1881 Robertson, J. M., Detroit
1879 Roe, John O., Rochester, NY
1913 Roy, Dunbar, Atlanta
1878 Rumbold, T. F., St Louis
1879 Seiler, Carl, Philadelphia
1928 Shea, John Joseph, Memphis
1893 Shields, Charles M., Richmond, Pa
1909 Shurly, Burt R., Detroit
1878 Shurly, E. L., Detroit
1959 Silcox, Louis E., Punta Gorda, Fla
1892 Simpson, William Kelly, New York
1919 Skillern, Ross H., Philadelphia
1909 Sluder, Greenfield, St Louis
1879 Smith, Andrew H., Geneva, NY
1932 Smyth, Duncan Campbell, Boston
1928 Sonnenschein, Robert, Chicago
1911 Staut, George C., Philadelphia
1924 Stein, Otto J., Chicago
1934 Stevenson, Walter, Quincy, Ill
1879 Tauber, Bernhard, Cincinnati
1924 Taylor, Hermon Marshall, Jacksonville, Fla
1903 Theisen, Clement F., Albany, NY
1899 Thorner, Max, Cincinnati
1892 Thrasher, Allen B., Cincinnati
1937 Tobey, George L., Jr, Boston
1967 Trible, William M., Washington, DC
1970 Tucker, Gabriel F., Jr, Chicago
1938 Vail, Harris H., Cincinnati
1888 Van der Poel, S. O., New York
1936 Voislawsky, Antonie P., New York
1954 Walsh, Theodore E., St Louis
1933 Wanamaker, Allison T., Seattle
1896 Ward, Marshall R., Pittsburgh
1879 Ward, Whitfield, New York
1886 Westbrook, Benjamin R., Brooklyn, NY
1924 Wherry, William P., Omaha
1924 White, Leon E., Boston
1953 Wilderson, William W., Nashville, Tenn
1939 Williams, Horace J., Philadelphia
1942 Wishart, D. E. Staunton, Toronto
1922 Wishart, David J. G., Toronto
1896 Wollen, Green V., Indianapolis
1940 Wood, V. Visscher, St Louis

ROSTER OF FELLOWS
1991

Date indicates year admitted to active fellowship. Attendance at meetings is shown by dates following each name. Asterisk indicates year paper was read. Year and asterisk in parentheses indicates coauthor of paper but not present at meeting.

Active Fellows — 99

1987 Adkins, Warren Y., Jr, Med Univ of SC, 171 Ashley Ave, Charleston, SC 29425, 1987, '89, '91.

1974 Alford, Bobby R., One Baylor Plaza, Houston, TX 77030, 1974, '78, '80-'83, '85-'87, '89, '91.

1984 Applebaum, Edward L., 1855 W Taylor St, Chicago, IL 60612, 1984-'87*, '88*-'91.

1975 Bailey, Byron J., Dept of Otolaryngol, UTMB, Galveston, TX 77550, 1975, '76*-'78, '81, '82, '84-'90.

1987 Baker, Shan R., Taubman Health Care Ctr, 1500 E Med Ctr Dr, Ann Arbor MI 48109, 1987.

1975 Biller, Hugh F., Mt Sinai Hosp, 100th St & Fifth Ave, New York, NY 10029, 1975-'77*, '79*, '80*, '81*, '82*, '83*, '84*, '85, '86*, '87*, '88*, '89*, '90.

1988 Birt, B. Derek, 2075 Bayview Ave, Toronto, Ont, M4N 3M5, Canada, 1988, '90.

1977 Blaugrund, Stanley M., 115 E 61st St, New York, NY 10021, 1977-'84*-'89*-'91.

1987 Blitzer, Andrew, Columbia Univ, 630 W 168th St, New York, NY 10032, 1987, '88*, '89*, '90*, '91.

1975 Boles, Roger, Dept of Otolaryngol, Univ of California, San Francisco, CA 94143, 1975-'82, '84-'89.

1984 Bone, Robert C., 10666 N Torrey Pine Rd, La Jolla, CA 92037, 1984, '86*, '88, '90.

1976 Briant, T. David R., St Michael's Hosp, 30 Bond St, Toronto, Ont, M5B 1W8, Canada, 1976, '77, '78, '80-'82, '85-'90.

1979 Calcaterra, Thomas C., UCLA Med Ctr, Los Angeles, CA 90024, 1979, '85, '87, '88*, '89*-'91.

1985 Canalis, Rinaldo F., Head and Neck Surg, UCLA 62-158, Los Angeles, CA 90024, 1985, '89, '91.

1976 Cantrell, Robert W., Univ of Virginia Med Ctr, Charlottesville, VA 22901, 1976, '77*-'80*-'84*-'88*-'91.

1985 Chodosh, Paul L., 99 North Ave, Hillside, NJ 07208, 1985, '86, '88*, '89.

1971 Cohen, Seymour R., 1300 N Vermont Ave, Los Angeles, CA 90027, 1971, '72*, '73*-'75*, '76*-'78*, '80*, '81*, '82*, '83*-'86*, '87*, '88*-'90*, '91*.

1988 Coulthard, Stanley W., Dept of Surgery, Arizona Health Sci Ctr, Tucson, AZ 85724, 1988.

1984 Crumley, Roger L., Univ of California, Irvine, 101 City St S, Orange, CA 92668, 1984*, '86-'88*-'90*, '91.

1980 Cummings, Charles W., Dept of Otolaryngol, Univ of Washington, Seattle, WA 98195, 1980-'82*, '83*-'91*.

1973 Dedo, Herbert H., Univ of California S.F., School of Med, 3rd and Parnassus, San Francisco, CA 94143, 1973*-'75*, '76*-'79*-'82*-'84*, '86*-'90*, '91*.

1984 DeSanto, Lawrence W., Mayo Clinic, Scottsdale, 13400 E Shea Blvd, Scottsdale, AZ 85259, 1984, '88*, '90*.

1976 Doyle, Patrick J., 1081 Burrard, Vancouver, BC, V6Z 1Y6, Canada, 1976, '77*, '80*, '81*, '84, '86-'89, '91.

1973 Duvall, Arndt J. III, Univ of Minnesota Hosp, 8-264 Phillips Wagensteen Bldg, Minneapolis, MN 55455, 1973*, '75-'78, '80, '81, '84, '86, '88, '89.

1968 Farrior, Richard T., 505 DeLeon, Tampa, FL 33606, 1968-'70*, '72, '74, '76-'81, '84-'90.

1964 Fearon, Blair, 308 Med Arts Bldg, 170 St George St, Toronto, Ont, M5R 2M8, Canada, 1964, '66-'71*, '72*, '73*, '74*-'78*-'81*, '82-'85*-'91.

1982 Fee, Willard E., Jr, Stanford Medical Ctr, Stanford, CA 94305, 1982-'87*-'91.

1990 Ford, Charles N., Univ WI CHS, 600 Highland Ave, Madison, WI 53792, 1990, '91*.

1977 Fredrickson, John M., Dept of Otolaryngol, Washington Univ, St Louis, MO 63110, 1977-'79*, '83-'87*-'91.

1989 Fried, Marvin P., 300 Brookline Ave, Boston, MA 02215, 1989, '90*.

1977 Gacek, Richard R., State Univ Hosp of the Upstate Med Ctr, 750 E Adams St, Syracuse, NY 13210, 1977*-'83*, '84*-'87*-'91.

1981 Gates, George A., Washington Univ, 517 S Euclid Ave, St Louis, MO 63110, 1981, '82*-'85*-'89*-('91*).

1991 Gluckman, Jack L., 103 Univ of Cincinnati Med Ctr, 231 Bethesda Ave, Cincinnati, OH 45267-0528.

1983 Goldstein, Jerome C., AAO-HNS, 1101 Vermont Ave NW, Washington, DC 20005, 1983-'91.

1985 Goode, Richard L., Div of Otolaryngol, R-135, Stanford Univ, Stanford, CA 94304, 1989.

1985 Gross, Charles W., 266 S Cleveland #202, Memphis, TN 38104, 1985-'89, '91.

1991 Gullane, Patrick J., 7-242 Eaton Wing N, 200 Elizabeth St, Toronto, Ont, M5G-1L7, Canada.

1988 Hanson, David G., Northwestern Univ Med Sch, 303 E Chicago Ave, Chicago, IL 60611, 1988, '90.

1987 Hawkins, Donald B., 1200 N State St, Los Angeles, CA 90033, 1987, '90, '91.

1983 Healy, Gerald B., 300 Longwood Ave, Boston, MA 02115, 1983, '84*, '85*-'91.

1983 Hicks, Julius N., 1501 5th Ave S, Birmingham, AL 35233, 1983, '84*-'91.

1986 Holinger, Lauren D., Children's Mem Hosp, 2300 Children's Plaza, Chicago, IL 60614, 1986, '87*-'89*-'91.

1974 Hudson, William R., Duke Univ Med Ctr, ENT, POB 3805, Durham, NC 27710, 1974-'78*, '81-'91.

1983 Jako, Geza J., 8 Porter St, Melrose, MA 02176, 1983, '85, '87*, '88.

1983 Johns, Michael E., Dept of Otolaryngol–Head and Neck Surg, Johns Hopkins Hosp, 600 N Wolfe St, Baltimore, MD 21205, 1983, '84*-'87*-'91.

1990 Johnson, Jonas T., Eye and Ear Hosp, 203 Lothrop St, Suite 500, Pittsburgh, Pa 15213, 1990*, '91*.

1985 Kashima, Haskins K., Johns Hopkins Hosp, Osler 425, Baltimore, MD 21205, 1985, '86*-'89*, '91*.

1991 Koufman, James A., Dept of Otolaryngology, Bowman Gray School of Med, Med Ctr Blvd, Winston-Salem, NC 27157, '91*.

1979 Krause, Charles J., Univ Hosp, Ann Arbor, MI 48109, 1979-'82*, '84-'87*, '88, '90, '91.

1981 Lawson, William, 19 E 98th St, New York, NY 10029, 1981*-'84*, '86*, '88*, '89*.

1988 Levine, Howard L., 9500 Euclid Ave, Cleveland, OH 44195, 1988*, '89*, '90.

1987 Lucente, Frank E., 310 E 14th St, New York, NY 10003, 1987, '88*, '89*-'91.

1978 Lyons, George D., 1542 Tulane Ave, New Orleans, LA 70112, 1978-'80, '82-'84, '88, '89.

1987 Maisel, Robert H., 701 Park Ave S, Minneapolis, MN 55415, 1988-'91*.

1989 Maniglia, Anthony J., 2074 Abington Rd, Cleveland, OH 44106, 1989*-'91.

1990 Marsh, Bernard R., 600 N Wolfe St, Baltimore, MD 21205, 1990, '91.

1988 Mathog, Robert H., Dept of Otolaryngol, Wayne State Univ, 540 E Canfield Ave, Detroit, MI 48201, 1988, '89*, '90.

1966 McCabe, Brian F., Dept of Otolaryngol, Univ Hosp, Iowa City, IA 52242, 1966, '69, '72*, '73, '75*, '76, '79*, '81*, '85, '86*, '87*, '88*, '89.

1989 McCaffrey, Thomas V., Dept of Otolaryngol, Mayo Clinic, Rochester, MN 55905, 1989*, '90*, ('91*).

1990 McGuirt, William F., 300 S Hawthorne Rd., Winston-Salem, NC 27103, 1990, '91*.

1987 Miller, Robert H., Dept of Otolaryngol, Tulane Med Sch, New Orleans, LA 70112, 1987-'91.

1986 Morrison, Murray D., 4th Floor, Willow Pavilion, Vancouver General Hosp, 805 W 12th Ave, Vancouver, BC V52 1M9, Canada, 1986, '87*-'91*.

1979 Myers, Eugene N., Dept of Otolaryngol, 230 Lothrop St, Pittsburgh, PA 15213, 1979, '80, '82*-'89*, '90*, '91*.

1981 Neel, H. Bryan III, 200 First St SW, Rochester, MN 55905, 1981, '82*-'85*-'88*, '89*-'91.

1980 Nichols, Richard D., Henry Ford Hosp, 2799 W Grand, Detroit, MI 48202, 1980, '81, '84, '87-'89*, '90.

1986 Noyek, Arnold M., 600 Univ Ave, Toronto, Ont, M5E 1X5, Canada, 1986, '87, '89*.

1982 Olson, Nels R., Suite R4016, 5333 McAuley Dr, Ypsilanti, MI 48197, 1982, '83*, '85, '87, '88, '90*.

1990 Osguthorpe, John D., MUSC Dept of Otolaryngol, 171 Ashley Ave, Charleston, SC 29403, 1990.

1990 Ossoff, Robert H., Vanderbilt Univ Med Ctr, MCN S-2100, Nashville, TN 37232, 1990*, '91*.

1988 Panje, William R., Univ of Chicago Med Ctr, 5841 S Maryland Ave, Box 412, Chicago, IL 60637, 1988.

1988 Pearson, Bruce W., Mayo Clinic, 4500 San Pablo Rd, Jacksonville, FL 32225, 1988*, '90.

1972 Pennington, Claude L., Jr, 800 First St, Macon, GA 31201, 1972, '73, '75, '76*, '78, '82-'89.

1989 Pillsbury, Harold C., 610 Burnett-Womack Bldg, Univ of North Carolina, Chapel Hill, NC 27514, 1989, '90.

1985 Rice, Dale H., 1300 N Vermont Ave, #508, Los Angeles, CA 90027, 1985-'88*-'91*.

1974 Ritter, Frank N., 2675 Englave Dr, Ann Arbor, MI 48103, 1974, '75, '77-'79, '81-'91.

1982 Rontal, Eugene, 21700 Northwestern Hwy, Southfield, MI 48075, 1982, ('83*), '84*, '86*, '90*.

1981 Sasaki, Clarence T., 333 Cedar St, New Haven, CT 06510, 1981, '83, '85-'88, '90*.

1984 Schild, Joyce A., Illinois Eye and Ear Inf, 1855 W Taylor St, Chicago, IL 60612, 1985*-'88*-'90*, '91.

1987 Schuller, David E., 456 Clinic Dr, Columbus, OH 43210, 1987, '88*, '89*-'91.

1978 Sessions, Donald G., 1960 Grassy Ridge Rd, Kirkwood, MO 63122, 1979*, '80*, '81, '83, '84, '86, '87*-('91*).

1983 Sessions, Roy B., Memorial Sloan-Kettering Cancer Ctr, 425 E 67th St, New York, NY 10021, 1983*, '86, '87, '89*, '90.

1990 Shapshay, Stanley M., Lahey Clinic Med Ctr, 41 Mall Rd, Burlington, MA 01805, 1990*, '91.

1988 Singer, Mark I., 1633 N Capitol, #780, Indianapolis, IN 46202, 1988, '89*-'91*.

1974 Snow, James B., Jr, Univ of Pennsylvania, 3400 Spruce St, Philadelphia, PA 19104, 1974, '75*-'78*, '79, '81-'91.

1979 Spector, Gershon J., Dept of Otolaryngol, Washington Univ, 517 S Euclid Ave, St Louis, MO 63110, 1979-'85, '88-'90.

1991 Strome, Marshall, 333 Longwood Ave, Boston, MA 02115.

1979 Tardy, M. Eugene, 2913 N Commonwealth, #430, Chicago, IL 60657, 1979, '82*, '84, '86.

1982 Thawley, Stanley E., Dept of Otolaryngol, Washington Univ, 517 S Euclid Ave, St Louis, MO 63110, 1982, '83*.

1989 Toohill, Robert J., 8700 W Wisconsin Ave, Box 199, Milwaukee, WI 53226, 1989, '90.

1978 Toomey, James M., Dept of Otolaryngol, Boston Univ, 88 E Newton St, Boston, MA 02118, 1979*-'81, '90.

1979 Tucker, Harvey M., Dept of Otolaryngol, Cleveland Clinic, Cleveland, OH 44195, 1979, '80*-'82*, '84*, '85*, '86*, '87*, '88*, '89*, '90*.

1973 Tucker, John A., St Christopher's Hosp, 2600 N Lawrence St, Philadelphia, PA 19133, 1973*, '74*, '75*-'77*, '78*, '80-'85*-'88*, '89*, '90*, '91*.

1984 Vaughan, Charles W., Veterans Adm Med Center, 150 S Huntington Ave, Boston, MA 02130, 1984-'86, '88*, '90*, ('91*).

1980 Vrabec, Donald P., Dept of Otolaryngol, Geisinger Med Ctr, Danville, PA 17821, 1980, '81*, '83, '86-'90.

1974 Ward, Paul H., UCLA School of Med, Los Angeles, CA 90024, 1974*-'77*, '78*, '79*, '81*, '82*, '83*, '84*-'86*-'88*-'90*, '91*.

1991 Weisberger, Edward C., Dept of Otolaryngol–Head and Neck Surg, Riley Hospital for Children, Suite A-56, Indianapolis, IN 46202-5230.

1989 Weymuller, Ernest A., Jr, Dept of Otolaryngol, RL-30, Univ of Washington, Seattle, WA 98195, 1989*, '91.

1981 Yanagisawa, Eiji, 98 York St, New Haven, CT 06511, 1981, '82*, '83*-'85*, '87*, '88*, '89*, '90*, '91*.

1983 Yarington, C. Thomas, Jr, 1100 9th Ave, POB 900, Seattle, WA 98111, 1983, '84*-'89*.

Honorary Fellows — 8

1978 (1959) Barretto, Plinio de Mattos, Rua Cons Torres, Homen 371, Sao Paulo, Brazil, 1960, '69, '73, '80.

1984 (1957) Conley, John J., 211 Central Park West, New York, NY 10024, 1958*, '60*-'62*, '64, '65, '70, '72, '74*, '75*-'78, '80, '82, ('83*)-'86, '89.

1984 (1960) Daly, John F., 16 N Brae Ct, Tenafly, NJ 07670, 1960, '61*, '79*, '81.

1986 Gould, Wilbur J., 47 E 77th St, New York, NY 10021, 1988, ('89*).

1978 (1971) Harrison, D. F. N., 330/332 Gray's Inn Rd, London, WCIX 8EE, United Kingdom, 1971, '77, '81*, '84*-'86*, '90*.

1985 (1963) Kirchner, John A., 333 Cedar St, New Haven, CT 06510, 1963, '65*, '67*-'69*-'71*-'75*, '77, '78, '80*, '82-'84*-'89*, '90*.

1984 (1956) Norris, Charles M., 3401 N Broad St, Philadelphia, PA 19140, 1956-'58*-'61*-'64, '66-'68*-'70*-'78*-'86, '88, '90.

1968 (1957) Ruedi, Luzius, Zollikerstrasse 185, 8008 Zurich, Switzerland, 1957.

Corresponding Fellows — 26

1991 Andrea, Mario, Av da Republica, 30-7° DTO, 1000 Lisbon, Portugal, 1991*.

1985 Aprigliano, Flavio, Rua Terezina 19, ZC-45 20,000 Rio de Janeiro, Brazil, 1985, '88, '90*.

1978 Arauz, Juan Carlos, J. E. Uriburu 1252-3°D, Buenos Aires, 1114 Argentina, 1980, '85*, '89.

1959 Bateman, Sir Geoffrey H., Thorney-Graff ham, Petworth, West Sussex, GU28 0EA United Kingdom.

1980 Benjamin, Bruce, 229 Macquarie St, Sydney, NSW 2000 Australia, 1980, '81, '83*, '84*, '85*, '87*.

1991 Bradley, Patrick J., Queens Medical Center, Nottingham, NG7 2UH, England.

1964 Cleves, Carlos, Carrea 12, No 20-69, Bogota, Colombia.

1984 Evans, John N. G., 55 Harley St, London W1N 1DD, United Kingdom, 1985*, '90.

1986 Ferlito, Alfio, Dept of Otolaryngol, Univ of Padua, Nuovo Policlinico, Via Giustiniani 2, 35128 Padua, Italy, 1986*, '87*-'89*, '90*.

1986 Fonseca, Rolando, Hosp de Clinicas, Jose de San Martin, Cordoba 2351, Buenos Aires, Argentina.

1984 Hirano, Minoru, Dept of Otolaryngol–Head and Neck Surg, Kurume Univ, 67 Asahi-machi, Kurume-shi 830, Japan, 1985*, '86*, '87*, '88*, '89*, '90*, '91*.

1970 Hutcheon, Jack, 336 Days Rd, Grange, Brisbane, 4051 Australia, 1971, '78, '80, '90.

1985 Inouye, Tetsuzo, Dept of Otolaryngol, National Defense Med College, Tokorozawa, Saitama, 359, Japan, 1985, '87, '88*, '89*.

1988 Isshiki, Nobuhiko, Dept of Plastic Surgery, Kyoto Univ, Kyoto 606, Japan, 1988*, '89*, '90*, '91*.

1988 Kim, Kwang-Moon, Dept of Otolaryngol, Yonsei Univ, Yongdong Severence Hosp, Yongdong, PO Box 1217, Seoul, 135 Korea, 1990.

1978 Kleinsasser, Oskar, Deutschhausstrasse 3, 3550 Marburg (Lahn), Cologne, Germany, 1982*, '88, '89*.

1971 Macbeth, Ronald G., Meadow Close, Church Hanborough, Oxford, United Kingdom.

1985 Murakami, Yasushi, Dept of Otolaryngol, Kyoto Univ, Kawaramachi, Kamikyo-ku, Kyoto 602, Japan, 1985*, '86*, '87, '90*.

1968 Nakamura, Fumio, Kyoto Prefectural Univ Medicine, Kawara-Machi, Kamikyo-ku, Kyoto, Japan.

1964 Perez, Alfredo C., Instituto Celis Perez, Avenida Montes Deoca, Valencia, Venezuela, 1965.

1989 Price, Brandon J., 31 Stone Mountain Ln, Marlton, NJ 08053.

1985 Shaw, Henry J., Royal Marsden Hosp, Fulham Rd, London SW3 6JJ, United Kingdom, 1986, '90*.

1984 Snow, Gordon B., Dept of Otolaryngol, Free Univ, DeBodelaan 1117, 1007 MB, Amsterdam, the Netherlands, 1983*, '85, '86*, '90.

1952 Tapia-Acuna, Ricardo, Av Insurgentes, Sur No. 300, Delegacion Cuauhtemoc 06700, Mexico 7 DF, 1953, '57, '60*, '67, '73, '75, '81*.

1987 Tu, Gui-yi, Dept of Head and Neck Surg, Cancer Hosp, Chinese Acad of Med Sciences, Pan Jia Yao, Chaoyang Qu, Beijing, People's Republic of China, 1987*.

1936 Vialle, Jacques, 27 Rue de France, Nice (Alpes Maritimes), France.

Emeritus Fellows — 54

1984 (1969) Ausband, John R., Emory Univ, 1365 Clifton Rd NE, Atlanta, GA 30322, 1970-'73, '75, '78, '81.

1988 (1970) Ballenger, John J., 723 Elm St, Winnetka, IL 60093, 1971-'91.

1989 (1963) Baxter, James D., 1509 Sherbrooke St W, Apt 12, Montreal, PQ H3B 1M1, Canada, 1963, '65*-'74, '76-'80, '82, '85-'87.

1986 (1955) Bordley, John E., Johns Hopkins Hosp, Baltimore, MD 21205, 1955-'57, '59, '60, '62-'67, '69-'73*-'80, '82, '83, '85*, '86, '90.

1988 (1959) Brewer, David W., 1100 E Genesee St, Syracuse, NY 13210, 1959, '60*-'62*, '63, '66, '70, '73, '74*, '77, '80, '81, '83, '85.

1990 (1963) Bryce, Douglas P., OPD, Toronto General Hosp, Toronto, Ont, M5G IL7 Canada, 1963*, '64, '66*, '67*, '68*-'79*, '81, '83-'87*-'91.

1965 (1942) Canfield, Norton, PO Box 1383, Miami, FL 33133, 1982, '84.

1989 (1968) Chandler, J. Ryan, 1700 NW 10th Ave, Miami, FL 33136, 1968, '69*-'79*-'84*-'91.

1989 (1967) Cocke, Edwin W., Jr, 920 Madison, Memphis, TN 38103, 1967-'70, '72, '74-'78, '80, '82, '84, '86, '87, '89-'91.

1988 (1964) Cody, Claude C. III, 529 E Friar Tuck, Houston, TX 77024, 1964, '65, '67, '69, '71, '73, '77-'79,

'81, '83-'85, '87, '91.

1985 (1966) Devine, Kenneth D., Mayo Clinic, Rochester, MN 55905, 1966-'68, '72*, '74*, '76*.

1972 (1962) Erich, John B., Mayo Clinic, 200 Second Ave SW, Rochester, MN 55905.

1982 (1963) Ferguson, Charles F., 5281 Cape Leyte Way, Siesta Key, Sarasota, FL 33581, 1963, '64*, '66, '67*-'69*-'74*-'78*-'82, '88.

1988 (1970) Frazer, John P., 329 Orchard Park Blvd, Rochester, NY 14609, 1971-'82, '86, '88.

1983 (1956) Friedberg, Stanton A., 5825 S Dorchester Ave, Chicago, IL 60637, 1956, '57, '65*, '71*, '76*, '78*, '79*, '80, '82, '83*-'85.

1985 (1959) Goldman, Joseph L., 55 E 87th St, New York, NY 10028, 1959, '60*-'72*-'78*-'80, '82-'84, '90.

1980 (1965) Hanckel, Richard W., Jr, 1167 S Sherwood Dr, Florence, SC 29501, 1965-'67, '69-'74, '77-'80.

1978 (1960) Harris, Herbert H., 3457 Meadow Lake Ln, Houston, TX 77027, 1960, '61*-'65*-'75, '77-'79, '81-'84, '86, '87.

1968 (1942) Heatley, Clyde A., 1570 East Ave, #412, Rochester, NY 14610, 1942, '46*, '49, '50, '52, '53*-'55, '57, '58, '60, '61, '65.

1978 (1959) Henry, G. Arnold, Suite 3, Group Box 23, Lagoon City, RR 1, Brechin, Ont, L0K 1B0, Canada, 1959, '61, '63, '66, '67, '69, '70, '73.

1980 (1955) Hilger, Jerome A., 1700 S Lexington, St Paul, MN 55118, 1955-'56*-'60, '62-'66, '68-'71, '75-'78, '80, '82.

1977 (1957) Holmes, Edgar M., 15 Graydale Cir, Auburndale, MA 02166, 1957, '59, '61, '63, '68, '70-'72, '74-'76, '80.

1991 (1975) Kirchner, Fernando R., 155 S 18th St, Kansas City, KS 66102, 1975*-'77, '79, '82*, '84, '86, '90.

1990 (1979) LeJeune, Francis E., Jr, 1514 Jefferson Hwy, New Orleans, LA 70121, 1979-'82*, '83*-'87*, '88, '90.

1991 (1966) Lewis, John S., 3 E 71st St, New York, NY 10021, 1966-'69*, '72, '74-'76*, '78-'83*-'87*-'89, '91.

1983 (1961) Lewy, Robert B., 25 E Washington, Chicago, IL 60602, 1961, '62*, '63, '65*, '67-'71, '73-'76*, '82, '83*-'90.

1989 (1976) Lingeman, Raleigh E., Riley Hosp, 702 Barnhill Rd, Indianapolis, IN 46223, 1976, '77*-'82*, '84, '86, '88, '89.

1989 (1973) Loré, John M., Jr, 2121 Main St, Buffalo, NY 14214, 1974*, '76, '77*, '78*, '81, '85-'87*, '88, '90, '91.

1991 (1976) Miglets, Andrew W., Jr, 410 W 10th Ave, Columbus, OH 43210, 1976-'78*, '80, '82, '85, '90.

1987 (1952) Miller, Alden H., 1705 Rancho Ave, Glendale, CA 91201, 1952, '53*, '55, '57, '58*, '61, '62, '64, '66-'73*, '74*, '76-'78*, '79, '81, '85, '89.

1984 (1965) Miller, Daniel, 110 Francis St, Boston, MA 02215, 1965-'69*-'73*-'77*-'81*, '82*-'87*, '88, '91.

1990 (1964) Montgomery, William W., 100 Charles River Plaza, Boston, MA 02114, 1964, '65*, '66*, '68*, '70-'72, '74*-'76*-'78, '80*-'82, '84-'88*, '90, '91.

1985 (1972) Morse, Harry R., 117 Nelson's Grove Rd, Lakeville, MA 02347, 1972, '75, '79-'81, '87.

1978 (1957) Munoz-MacCormick, Carlos Eduardo, 71 de Diego, Santurce, PR 00911, 1957-'80, '82-'84.

1991 (1967) Pratt, Loring W., 37 Lawrence Ave, Fairfield, ME 04937, 1967-'82, '84*-'87*, '88, '91.

1976 (1951) Priest, Robert E., 48 Groveland Terr #414, Minneapolis, MN 55403, 1977-'81.

1980 (1951) Putney, F. Johnson, 705 Knotty Pine Rd, Charleston, SC 29412, 1951-'53*-'58*-'63*, '64*-'68*, '69*, '70*-'72, '74-'78*, '79*, '82, '86.

1989 (1963) Reed, George F., 750 E Adams St, Syracuse, NY 13210, 1963, '65*, '66, '68, '69*-'73, '75-'82*-'89.

1972 (1956) Richardson, John R., PO Box 52, Searsport, ME 04974.

1989 (1964) Saunders, William H., Ohio State Univ, Room 3110, 456 Clinic Dr, Columbus, OH 43210, 1964-'66, '68*-'70*-'75*-'80, '82*-'84, '86-'89.

1990 (1979) Shapiro, Myron J., 101 Old Short Hills Rd, West Orange, NJ 07052, 1979-'81, '84, '86, '88, '89.

1977 (1958) Simonton, Kinsey M., 1000 Vicar's Landing Way, #F203, Ponte Vedra Beach, FL 32082, 1958, '59*, '62, '64, '66, '67, '69, '72, '74, '75, '78, '82, '84.

1989 (1962) Sisson, George A., Sr, Northwestern Univ Med Sch, 303 E Chicago Ave, Chicago, IL 60611, 1962, '63*, '65, '66, '68-'73, '76-'82, '84*, '85*-'88*-'90*, '91.

1988 (1964) Skolnik, Emanuel M., 1855 W Taylor St, Chicago, IL 60612, 1964*-'66*-'70*-'73, '75*-'80*-'82*, '85, '86*, '88.

1988 (1972) Soboroff, Burton J., 307 N Michigan Ave, Chicago, IL 60601, 1972-'77, '79, '80, '82, '86, '88, '89, '91.

1990 (1975) Sprinkle, Philip M., 125 N 6th St, Clarksburg, WV 26301, 1975-'78*-'82, '84-'89.

1990 (1975) Strong, M. Stuart, 35 Laurel Rd, Weston, MA 02193, 1975, '76*-'78*, '79*, '81, '82*-'84*-'86*-'91.

1982 (1961) Suehs, Oliver W., 2805 Robbs Run, Austin, TX 78703, 1961, '62*-'64, '66, '68-'72, '74-'78, '80.

1988 (1963) Tabb, Harold G., Dept of Otolaryngol, Tulane Med Sch, New Orleans, LA 70112, 1963, '65-'69, '71, '72, '74, '77-'84, '86-'90.

1983 (1954) Thornell, William C., 3516 Traskwood Cir, Cincinnati, OH 45208, 1957, '59, '63, '68, '70, '72, '74, '77, '78, '80.

1973 (1963) Tolan, John F., 3419 47th Ave NE, Seattle, WA

98105, 1963-'67, '69, '71, '73.

1977 (1962) Weaver, Delmar F., Medical Professional Bldg, PO Box 862, Culpepper, VA 22701, 1962-'64*, '65, '67*, '69, '70, '72, '74, '76.

1983 (1971) Williams, Russell I., 414 E 23rd St, Cheyenne, WY 82001, 1971, '72*-'74, '76-'78*, '80.

1975 (1953) Work, Walter P., 172 E Paseo de Golf, Green Valley, AZ 85614, 1953, '54, '56, '58, '59*, '62, '63*, '65, '67-'69, '72, '73, '75, '76, '78*, '79*, '82, '87.

OFFICERS 1991-1992

≈

PRESIDENT
JOHN M. FREDRICKSON, MD

VICE-PRESIDENT (PRESIDENT-ELECT)
WILLIAM R. HUDSON, MD

SECRETARY
H. BRYAN NEEL III, MD, PHD

TREASURER
ROBERT W. CANTRELL, MD

HISTORIAN-EDITOR
PAUL H. WARD, MD

FIRST COUNCILOR
SEYMOUR R. COHEN, MD

SECOND COUNCILOR
EUGENE N. MYERS, MD

THIRD COUNCILOR
JAMES B. SNOW, JR, MD

COUNCILORS-AT-LARGE
BYRON J. BAILEY, MD
CHARLES J. KRAUSE, MD

INDEX

AUTHORS

A

Andrea M 274
Arfken CL 51
Aronson AE 23
Austin JR 153

B

Bard MC 148
Berke GS 93, 172
Bishop MJ 199
Bless DM 184
Bond G 267
Bryce DP 20
Butsch RW 131

C

Cantrell RW 10
Carranza AP 85
Cheung DT 85
Cohen SR 85
Coltrera MD 206
Cooper DS 122, 153
Cummings CW 28

D

Davis DA 244
Dayton V 77
Dedo HH 258
Downs DH 206
Durham JS 45

E

Eckel HE 224
Eichel B 264
Estill J 140

F

Feehs RS 267
Flint PW 199, 206
Flores AD 45
Ford CN 184
Forsen JW 158
Freeman FJ 131

G

Gates GA 51
Gerratt BR 93, 172
Gonzalez DA 164
Green DC 172

H

Harvey JE 32, 51
Haughey BH 51, 158
Hawkshaw MJ 90
Hirano M 109
Hornung DE 69
Hudson WR 8, 24

I

Isshiki N 225

J

Johns ME 9
Johnson JT 65

K

Kashima HK 104
Koda J 216
Kojima H 255
Kondraske GV 131
Koufman JA 274

L

Leopold DA 69
Lian G 85
Lipton RJ 148
Loftus JM 184
Ludlow CL 216

M

Mahnovski V 85
Maisel R 77
Mambrino L 140
Maragos NE 177
McCaffrey TV 114, 148
McCulloch TM 199
McGuirt WF 267
McKinney WM 267
Ming Y 93
Morrison MD 45
Myers EN 9, 65

N

Natividad M 93
Neel HB III 8
Nimni ME 85

O

Ossoff RH 164

P

Parnes SM 59
Perelman N 85
Pinczower E 122
Pohl J 131
Pototschnig C 224

R

Rice DH 122
Richardson MA 199
Rimell F 77
Roark RM 131
Rothfield RE 65
Russo P 244

S

Sanders I 230
Sataloff RT 90
Sato K 109
Sawada M 255
Schaefer SD 131
Schwob JE 69
Sercarz JA 93
Sessions DG 32
Sherman M 59
Sikand A 45
Singer MI 195
Slavit DH 114, 148, 177
Snow JB Jr 15, 19, 22, 26, 27
Sogg A 264
Spiegel JR 90
Spitznagel EL Jr 32
Stanley RB 153
Strickland HL 267

T

Talkin D 140
Tanaka S 109
Thumfart WF 224
Tucker JA 25, 244

V

Van Pelt F 216
Vaughan CW 41

W

Ward PH 8, 172
Watson BC 131
Woo P 248

Y

Yanagisawa E 140

Z

Zamora RL 32
Zaretsky LS 230
Zeitels SM 41
Zhao R 109
Zorowka P 224

SUBJECTS

A

American Laryngological Association Award
Presentation 22
Recipients 13
Response of recipient 23

Anatomy
Surgical anatomy of pharyngeal plexus 195

Annual photograph 5

Anosmia
Congenital lack of olfactory ability 69

Arytenoid
Medialization laryngoplasty and arytenoid adduction procedure: which and when? (abstract) 274
Physiologic assessment of arytenoid adduction 177

Asbestos
Head and neck surveillance program for factory personnel exposed to asbestos 59

Atherosclerosis
Irradiation-induced atherosclerosis: factor in therapeutic planning 267

Awards
American Laryngological Association, Casselberry, De Roaldes, Newcomb, Resident Research, Gabriel F. Tucker, Young Faculty Research Award 13

B

Botulinum toxin
Point-touch technique of botulinum toxin injection for treatment of spasmodic dysphonia 172

C

Carcinoma
Carcinoma in situ and microinvasive squamous cell carcinoma of vocal cords 65
Clinical staging for primary malignancies of supraglottic larynx 32
Meta-analysis of second malignant tumors in head and neck cancer: case for endoscopic screening protocol 51
Preepiglottic space invasion in "early" epiglottic cancer 41
Prognostic significance of tumor site, extension, and mobility in glottic cancer 45
Stroboscopy for glottic T1a carcinomas: its role in diagnosis 109

Cartilage
Microvascularization of laryngeal cartilages and its oncologic importance (abstract) 274

Collagen
Collagen in developing larynx. Preliminary study 85
Role of injectable collagen in treatment of glottic insufficiency: study of 119 patients 184

Complications
Ethmoid surgery complications and their avoidance 264

Cordotomy
Bilateral vocal fold motion impairment: pathophysiology and management by transverse cordotomy 104

Cranial nerve
Electrophysiologic investigation of lower cranial nerve diseases by means of magnetically stimulated neuromyography of larynx 224

Cricothyroid
Three bellies of canine cricothyroid muscle 230

D

Daniel C. Baker, Jr, Memorial Lecture
Introduction 27
Lecture 28

De Roaldes Award
Presentation 26

Development
Collagen in developing larynx. Preliminary study 85

Discussions 275

E

Electromyography
Multichannel electromyographic observations in spasmodic dysphonia patients and normal control subjects 131

Epiglottis
Acquired laryngomalacia: epiglottis prolapse as cause of airway obstruction 248
Preepiglottic space invasion in "early" epiglottic cancer 41

Ethmoid
Ethmoid surgery complications and their avoidance 264

Executive Sessions
Minutes 7
Reports 8

F

Fellows
Deceased 289
Registration 6
Roster 293

Fracture
Stable internal fixation of fractures of partially mineralized thyroid cartilage 153

Framework
Special instruments for laryngeal framework surgery 255

Future
Otolaryngology–head and neck surgery: model specialty for future 28

G

Gabriel F. Tucker Award
Presentation 24
Recipients 13
Response of recipient 25

Glottic resistance
Open slope quotient: estimator of glottic resistance 114

Graft
Free jejunal graft: effects of longitudinal myotomy 158

Guest of Honor
Address 20
Introduction 19

H

Heart
Management of airway obstruction in patients with congenital heart defects 244

Hybridization
In situ hybridization and laryngeal papillomas 77

I

Incendiary properties
Effect of blood on incendiary properties of endotracheal tubes irradiated with carbon dioxide laser 164

Instruments
Special instruments for laryngeal framework surgery 255

Intramuscular pressure
Thyroarytenoid intramuscular pressures 122

Irradiation
Irradiation-induced atherosclerosis: factor in therapeutic planning 267

L

Laryngeal efficiency
Noninvasive technique for estimating subglottic pressure and laryngeal efficiency 148

Laryngomalacia
Acquired laryngomalacia: epiglottis prolapse as cause of airway obstruction 248

Laser
Effect of blood on incendiary properties of endotracheal tubes irradiated with carbon dioxide laser 164

Lidocaine
Lidocaine effects on laryngeal chemoreflex, mechanoreflex, and afferent electrical stimulation reflex 199

M

Medialization
Medialization laryngoplasty and arytenoid adduction procedure: which and when? (abstract) 274

Memorial Fund, Laryngological Research Fund 14

Memorials
Lup Q. Pang, MD 282
Peter N. Pastore, MD 283
Sam H. Sanders, MD 285

Microvascularization
Microvascularization of laryngeal cartilages and its oncologic importance (abstract) 274

Muscle
Three bellies of canine cricothyroid muscle 230

Myotomy
Free jejunal graft: effects of longitudinal myotomy 158

N

Neuromyography
Electrophysiologic investigation of lower cranial nerve diseases by means of magnetically stimulated neuromyography of larynx 224

O

Obstruction
Management of airway obstruction in patients with congenital heart defects 244

Officers
1879-1990 286
1990-1991 6
1991-1992 298

Olfaction
Congenital lack of olfactory ability 69

Open slope quotient
Open slope quotient: estimator of glottic resistance 114

P

Papilloma
In situ hybridization and laryngeal papillomas 77

Paralysis
Bilateral vocal fold motion impairment: pathophysiology and management by transverse cordotomy 104
Injection and removal of Teflon for unilateral vocal cord paralysis 258
Physiologic assessment of arytenoid adduction 177
Role of injectable collagen in treatment of glottic insufficiency: study of 119 patients 184
Videostroboscopy of human vocal fold paralysis 93

Pharyngeal plexus
Surgical anatomy of pharyngeal plexus 195

Phonation
Voluntary control of soft palate in phonation 140

Presidential Remarks 15

Prognosis
Prognostic significance of tumor site, extension, and mobility in glottic cancer 45

R

Reflex
Lidocaine effects on laryngeal chemoreflex, mechanoreflex, and afferent electrical stimulation reflex 199

Reinnervation
Laryngeal synkinesis following reinnervation in rat. Neuroanatomic and physiologic study using retrograde fluorescent tracers and electromyography 206

Reports
Governor, American College of Surgeons 9
Historian-Editor 8
Liaison Director, American Board of Otolaryngology 9
Representative, Board of Governors of American Academy of Otolaryngology–Head and Neck Surgery 8
Secretary 8
Treasurer 10

S

Screening
Meta-analysis of second malignant tumors in head and neck cancer: case for endoscopic screening protocol 51

Soft palate
Voluntary control of soft palate in phonation 140

Spasmodic dysphonia
Multichannel electromyographic observations in spasmodic dysphonia patients and normal control subjects 131
Point-touch technique of botulinum toxin injection for treatment of spasmodic dysphonia 172

Specialty
Otolaryngology–head and neck surgery: model specialty for future 28

Squamous cell carcinoma
Carcinoma in situ and microinvasive squamous cell carcinoma of vocal cords 65

Staging
Clinical staging for primary malignancies of supraglottic larynx 32

Stimulation
Characteristics of late responses to superior laryngeal nerve stimulation in humans 216

Stroboscopy
Stroboscopy for glottic T1a carcinomas: its role in diagnosis 109
Strobovideolaryngoscopy: results and clinical value 90
Videostroboscopy of human vocal fold paralysis 93

Subglottic pressure
Noninvasive technique for estimating subglottic pressure and laryngeal efficiency 148

Superior laryngeal nerve
Characteristics of late responses to superior laryngeal nerve stimulation in humans 216

Surveillance
Head and neck surveillance program for factory personnel exposed to asbestos 59

Synkinesis
Laryngeal synkinesis following reinnervation in rat. Neuroanatomic and physiologic study using retrograde fluorescent tracers and electromyography 206

T

Teflon
Injection and removal of Teflon for unilateral vocal cord paralysis 258

Thyroarytenoid muscle
Thyroarytenoid intramuscular pressures 122

Thyroid
Stable internal fixation of fractures of partially mineralized thyroid cartilage 153

V

Videolaryngoscopy
Strobovideolaryngoscopy: results and clinical value 90