TRANSACTIONS

AMERICAN LARYNGOLOGICAL ASSOCIATION

1994

VOLUME ONE HUNDRED FIFTEEN

"DOCENDO DISCIMUS"

≈

ONE HUNDRED FIFTEENTH ANNUAL MEETING

THE BREAKERS HOTEL

PALM BEACH, FLORIDA

MAY 7-8, 1994

≈

PUBLISHED BY THE ASSOCIATION
ST LOUIS, MISSOURI
PAUL H. WARD, MD, EDITOR

CONTENTS

Annual Photograph 4

Officers 1993-1994 5

Registration of Fellows 6

Minutes of Executive Sessions 7

Reports
- Secretary, Gerald B. Healy, MD 8
- Historian-Editor, Paul H. Ward, MD 8
- Representative to the Board of Governors of the American College of Surgeons, Warren Y. Adkins, Jr, MD 8
- Liaison of the American Board of Otolaryngology, Eugene N. Myers, MD 9
- Treasurer, Robert W. Cantrell, MD 9

Recipients of De Roaldes, Casselberry, Newcomb, Gabriel F. Tucker, American Laryngological Association, Resident Research, and Young Faculty Research Awards 13

The Memorial and Laryngological Research Funds 14

Presidential Remarks. The Future of the American Laryngological Association. Byron J. Bailey, MD 15

Introduction of Guest of Honor Paul H. Ward, MD. Byron J. Bailey, MD 19

Guest of Honor Address. Socioeconomic, Political, and Scientific Predictions for Otolaryngology and Laryngology by the Year 2000. Paul H. Ward, MD 20

Presentation of the American Laryngological Association Award to Professor John C. Polanyi
T. David Briant, MD 23

Response of the Recipient of the American Laryngological Association Award. Confessions of a Scientist.
Professor John C. Polanyi 24

Presentation of the Gabriel F. Tucker Award to Joyce A. Schild, MD.
Byron J. Bailey, MD 26

Response of the Recipient of the Gabriel F. Tucker Award.
Joyce A. Schild, MD 26

Introduction of the 20th Daniel C. Baker, Jr, Lecturer, Leroy E. Hood, MD.
Ernest A. Weymuller, Jr, MD 27

Twentieth Daniel C. Baker, Jr, Memorial Lecture.
Deciphering Human Heredity: A Revolution in Medicine of the 21st Century.
Leroy E. Hood, MD 28

SCIENTIFIC SESSIONS

Dynamic Properties of the Posterior Cricoarytenoid Muscle
Donald S. Cooper, PhD; Maisie Shindo, MD; Uttam Sinha, MD;
Malcolm H. Hast, PhD; Dale H. Rice, MD 34

Malignant Laryngeal Tumors in Children: A 15-Year Experience With Four Patients
Laurie A. Ohlms, MD; Trevor McGill, MD; Gerald B. Healy, MD 42

Three-Dimensional Imaging of the Hypopharynx and Larynx By Means of Helical (Spiral) Computed Tomography. Comparison of Radiological and Otolaryngological Evaluation
Paul M. Silverman, MD; Andrew S. Zeiberg, MD; Roy B. Sessions, MD;
Thomas R. Troost, MD; Robert K. Zeman, MD 49

Neuropeptide Participation in Canine Laryngeal Sensory Innervation. Immunohistochemistry and Retrograde Labeling
Yasuo Hisa, MD; Nobuhisa Tadaki, MD; Toshiyuki Uno, MD; Hitoshi Okamura, MD;
Jun-ichi Taguchi, PhD; Yasuhiko Ibata, MD 56

Positron Emission Tomography in the Evaluation of Laryngeal Carcinoma
W. Frederick McGuirt, MD; Kathryn M. Greven, MD; John W. Keyes, Jr, MD;
Daniel W. Williams III, MD; Nat E. Watson, Jr, MD; Kim R. Geisinger, MD; James O. Cappellari, MD 60

Endoscopic Vocal Fold Microflap: A Three-Year Experience
Mark S. Courey, MD; Glendon M. Gardner, MD; R. Edward Stone, PhD; Robert H. Ossoff, DMD, MD 65

Combined Thyroplasty Type I and Inferior Constrictor Myotomy
William W. Montgomery, MD; Robert E. Hillman, PhD; Mark A. Varvares, MD 72

Tracheoesophageal Voice Following Tubed Free Radial Forearm Flap Reconstruction of the Neopharynx
Daniel G. Deschler, MD; E. Thomas Doherty, PhD; Charles G. Reed, PhD;
James P. Anthony, MD; Mark I. Singer, MD 77

Autologous Fat Injection for Vocal Fold Paralysis: Long-Term Histologic Evaluation
Lauren S. Zaretsky, MD; Maisie L. Shindo, MD; Michael deTar, MD; Dale H. Rice, MD 85

"Window" Laryngoplasty: A New Combined Laser Endoscopic and Open Technique for Conservation Surgery
Stanley M. Shapshay, MD; Zhi Wang, MD; Elie E. Rebeiz, MD;
Donald F. Perrault, Jr; Michail M. Pankratov, MS 89

Teflon Granuloma of the Larynx: Etiology, Pathophysiology, and Management
Mark A. Varvares, MD; William W. Montgomery, MD; Robert E. Hillman, PhD 96

Noninvasive Measurement of Traveling Wave Velocity in the Canine Larynx
Sina Nasri, MD; Joel A. Sercarz, MD; Gerald S. Berke, MD 101

Electronic Speckle Pattern Interferometry of the Vibrating Larynx
Glendon M. Gardner, MD; James Castracane, PhD; Michelle Conerty, MS; Steven M. Parnes, MD 110

Diagnosis and Management of External Penetrating Cervical Esophageal Injuries
William B. Armstrong, MD; Maj Thomas R. Detar, MC, USAF; Robert B. Stanley, MD, DDS 118

Predicting Recurrence and Survival in Patients With Laryngeal Cancer By Means of DNA Cytometry,
Tumor Front Grading, and Proliferation Markers
Hans-J. Welkoborsky, MD, DDS; Michael Hinni, MD; Hans-P. Dienes, MD; Wolf J. Mann, MD, FACS 127

Cordectomy Versus Arytenoidectomy in the Management of Bilateral Vocal Cord Paralysis
Hans E. Eckel, MD; Monika Thumfart; Klaus Wassermann, MD;
Martin Vössing, MD; Walter F. Thumfart, MD 135

Jejunal Graft Reconstruction of Pharyngoesophageal Defects Without Microvascular Anastomoses
William R. Panje, MD; Hugh E. Hetherington, MD 141

Gender Differences in Cancer of the Larynx
Mimi S. Kokoska, MD; Jay F. Piccirillo, MD; Bruce H. Haughey, MB, ChB 147

Laryngoplastic Medialization and Arytenoid Adduction:
A Quantitative and Qualitative Analysis of Voice Improvement [Abstract]
James L. Netterville, MD; Liz Luken, CCC, SLP; Ed Stone, PhD;
William B. Armstrong, MD; David Hall; Robert H. Ossoff, DMD, MD 153

Phonatory Specialization of Human Laryngeal Muscles [Abstract]
Ira Sanders, MD; Bei-Lian Wu, MD; Hugh F. Biller, MD 153

Comparison of Soft Tissue Response in Rabbits Following Laryngeal Implantation
With Hydroxylapatite, Silastic, and Teflon [Abstract]
Paul W. Flint, MD; Sanjay Marwaha, MD; Ritu Goel, MD; Charles W. Cummings, MD 153

Discussions 154

Memorials
John E. Bordley, MD 164
John B. Erich, MD 165
Wilbur J. Gould, MD 166
Luzius Ruedi, MD 167
Emanuel M. Skolnick, MD 169

Officers 1879-1993 170

Deceased Fellows 173

Roster of Fellows 1994 177

Officers 1994-1995 182

Index 183

FELLOWS IN ATTENDANCE AT THE ONE HUNDRED FIFTEENTH ANNUAL MEETING

First Row: Yanagisawa, Noyek, Sasaki, Jako, Schild, Snow, Bailey, Healy, Hudson, Crumley, Fredrickson, Neel, Ward, Cantrell, Blitzer.

Second Row: Dedo, Vaughan, Myers, Hawkins, Thumfart, Ritter, Kashima, Hisa, Gacek, J. Tucker, Farrior, Woodson, Gregor, Abemayor, Ballenger.

Third Row: Berke, Lucente, Montgomery, Komisar, McCaffrey, Cummings, Weymuller, Gates, Doyle, Briant, Broniatowski, Vrabec, Lowry, Hanson.

Fourth Row: Cassisi, Gross, Schechter, Maisel, Canalis, Fee, McGuirt, Holinger, Richtsmeier, Lewis, Pratt, Caldarelli, J. Kirchner, Osguthorpe.

OFFICERS 1993-1994

≈

PRESIDENT

BYRON J. BAILEY, MD

VICE-PRESIDENT (PRESIDENT-ELECT)

H. BRYAN NEEL III, MD, PHD

SECRETARY

GERALD B. HEALY, MD

TREASURER

ROBERT W. CANTRELL, MD

HISTORIAN-EDITOR

PAUL H. WARD, MD

FIRST COUNCILOR

JAMES B. SNOW, JR, MD

SECOND COUNCILOR

JOHN M. FREDRICKSON, MD

THIRD COUNCILOR

WILLIAM R. HUDSON, MD

COUNCILORS-AT-LARGE

ROGER L. CRUMLEY, MD
JOYCE A. SCHILD, MD

REGISTRATION OF FELLOWS

ACTIVE

ABEMAYOR, ELLIOT
BAILEY, BYRON J.
BERKE, GERALD S.
BLITZER, ANDREW
BRIANT, T. DAVID
BRONIATOWSKI, MICHAEL
CALDARELLI, DAVID
CANALIS, RINALDO F.
CANTRELL, ROBERT W.
CASSISI, NICHOLAS J.
CRUMLEY, ROGER L.
CUMMINGS, CHARLES W.
DEDO, HERBERT H.
FEE, WILLARD E., JR
FREDRICKSON, JOHN M.
GACEK, RICHARD R.
GATES, GEORGE A.
GROSS, CHARLES W.
HANSON, DAVID G.
HAWKINS, DONALD B.
HEALY, GERALD B.
HOLINGER, LAUREN D.
HUDSON, WILLIAM R.
JAKO, GEZA J.
KASHIMA, HASKINS K.
KOMISAR, ARNOLD
LOWRY, LOUIS D.
LUCENTE, FRANK E.
MAISEL, ROBERT H.
MCCAFFREY, THOMAS V.
MCGUIRT, W. FREDERICK
MYERS, EUGENE N.
NEEL, H. BRYAN III
NOYEK, ARNOLD M.
OSGUTHORPE, J. DAVID
RICHTSMEIER, WILLIAM J.
SASAKI, CLARENCE T.
SCHECHTER, GARY L.
SCHILD, JOYCE A.
SNOW, JAMES B., JR
TUCKER, JOHN A.
VAUGHAN, CHARLES W.
VRABEC, DONALD P.
WARD, PAUL H.
WEYMULLER, ERNEST A., JR
WOODSON, GAYLE
YANAGISAWA, EIJI

HONORARY

KIRCHNER, JOHN A.

EMERITUS

BALLENGER, JOHN J.
DOYLE, PATRICK J.
FARRIOR, RICHARD T.
LEWIS, JOHN S.
MONTGOMERY, WILLIAM W.
PRATT, LORING
RITTER, FRANK N.

CORRESPONDING

GREGOR, REINHOLD
HISA, YASUO
THUMFART, WALTER F.

MINUTES OF THE EXECUTIVE SESSIONS

FIRST SESSION — MAY 7, 1994

The First Executive Session of the 115th Annual Meeting was convened at 7:00 AM at the Breakers Hotel, Palm Beach, Florida, Byron J. Bailey, MD, presiding.

The following candidates, having been recommended for Fellowship by the Council, were elected to *Active Fellowship*: Elliot Abemayor, MD, Los Angeles, California; Michael Broniatowski, MD, Cleveland, Ohio; David Caldarelli, MD, Chicago, Illinois; Nicholas J. Cassisi, MD, Gainesville, Florida; G. Richard Holt, MD, San Antonio, Texas; James L. Netterville, MD, Nashville, Tennessee; Barry Wenig, MD, Chicago, Illinois; Gayle Woodson, MD, Memphis, Tennessee; and to *Corresponding Fellowship*: Reinhold Gregor, MB, BCh, Amsterdam, the Netherlands.

Following their election, the Active Fellows were introduced by their sponsors and welcomed by President Bailey.

The following Fellows were elected to the Nominating Committee: Eugene N. Myers, MD, Chairman; Patrick J. Doyle, MD; Lauren D. Holinger, MD; Haskins Kashima, MD; and John A. Tucker, MD.

SECOND SESSION — MAY 8, 1994

The Second Executive Session was opened by President Bailey at 12:30 PM, and the report of the Nominating Committee was received from Dr Eugene N. Myers, Chairman of the Nominating Committee. The following Fellows were nominated and unanimously elected to the Council: Byron J. Bailey, MD; H. Bryan Neel III, MD, PhD; Robert W. Cantrell, MD; Paul H. Ward, MD; John M. Fredrickson, MD; Joyce A. Schild, MD; Gerald B. Healy, MD; Ernest A. Weymuller, Jr, MD; William R. Hudson, MD; and Robert H. Mathog, MD.

The reports of the Secretary, the Treasurer, and the Historian-Editor were submitted and accepted.

At the President's direction, the newly elected members of the Council, acting as Directors of the Association, organized themselves for the year 1994-1995 as follows: President, H. Bryan Neel III, MD, PhD; Vice-President (President-Elect), Paul H. Ward, MD; Secretary, Gerald B. Healy, MD; Treasurer, Robert W. Cantrell, MD; Historian-Editor, Ernest A. Weymuller, Jr, MD; First Councilor, John M. Fredrickson, MD; Second Councilor, William R. Hudson, MD; Third Councilor, Byron J. Bailey, MD; and Councilors-at-Large, Joyce A. Schild, MD, and Robert H. Mathog, MD.

The membership voted a dues increase to $250.00 with a $50.00 penalty for late payment.

At the close of the Scientific Session, the Executive Session was reconvened by President Bailey, who introduced Dr H. Bryan Neel III as the new President of the Association. Dr Neel thanked Dr Bailey for his outstanding leadership and work as President of the Association. The meeting was adjourned.

REPORTS

REPORT OF THE SECRETARY

The membership prior to this Annual Meeting consisted of 97 Active members, 55 Emeritus members, 28 Corresponding members, and 10 Honorary members, for a total of 190 members. After this year's elections, the membership will consist of 105 Active members, 55 Emeritus members, 29 Corresponding members, and 10 Honorary members, for a total of 199 members.

There were 41 requests for applications and 14 formal submissions for the American Laryngological Association Grant for 1993. This is the fourth year that an award has been made. The Laryngeal Research Fund Committee evaluated the grants and selected the best one for the $15,000 award. Already there have been 36 requests for applications for the 1994 grant.

The program evaluations of the 1993 Annual Meeting have been reviewed carefully by the Council. There were 134 evaluations returned. The Council also reviewed the written responses to the evaluation questions. It was concluded that the 1993 program was very well received by the membership.

The next meeting of the American Laryngological Association will be held at the Marriott Desert Springs Hotel in Palm Desert, California, April 29-30, 1995, in conjunction with the 1995 Combined Otolaryngological Spring Meetings.

The next meeting of the American Laryngological Association Council — the First (Winter) Council Meeting — will be held in conjunction with the Southern Section of the Triological Society at the Camelback Hotel.

Respectfully submitted,
Gerald B. Healy, MD
Secretary

REPORT OF THE HISTORIAN-EDITOR

I have the sad duty to report the deaths of two Honorary Fellows and three Emeritus Fellows. Dr Luzius Ruedi was elected to Corresponding membership in 1957 and was elevated to Honorary Fellowship in 1968. He died on July 19, 1993. Dr Wilbur J. Gould was elected to Honorary Fellowship in 1986. He died on February 5, 1994. Dr John E. Bordley was elected to membership in 1955 and was elevated to Emeritus status in 1986. He died on July 12, 1993. Dr John B. Erich was elected to membership in 1952 and was elevated to Emeritus status in 1972. He died on May 11, 1994. Dr Emanuel M. Skolnick was elected to membership in 1987. He died on April 28, 1994.

A complete set of the *Transactions* is now maintained in the library of the American Academy of Otolaryngology–Head and Neck Surgery.

At the direction of the Executive Committee, any *Transactions* that are more than 3 years old have been destroyed or placed in departmental libraries except for 2 copies. Up to 15 copies of the most recent 3 years are available to Fellows of the Association for $2.00 per copy.

Manuscripts of the 1995 meeting should be in the hands of the Editor of the *Annals of Otology, Rhinology & Laryngology* by March 1, 1995.

Respectfully submitted,
Paul H. Ward, MD
Historian-Editor

REPORT OF THE REPRESENTATIVE TO THE BOARD OF GOVERNORS OF THE AMERICAN COLLEGE OF SURGEONS

As the representative of the American Laryngological Association to the Board of Governors of the American College of Surgeons, I attended the winter meeting of the American Laryngological Association Council, which was held in conjunction with the Eastern Section of the American Laryngological, Rhinological and Otological Society in New York City in January 1993. I attended the interim meeting of the Advisory Council to Otolaryngology in Los Angeles, California, in April 1993, and the Advisory Council meeting held in San Francisco during the Clinical Congress in October 1993. In addition, I attended the Annual Meeting of the Board of Governors, which was held on October 11, 1993, at the San Francisco Hilton and Towers. Primary concerns of the Governors presented at the Annual Meeting in order of importance were health care reform, physician reimbursement, professional liability, third-party intervention and utilization review, new technology education and credentialing, graduate medical education, and acquired immune deficiency syndrome. A response report to the major concerns was given by Frank R. Lewis, Jr, MD, FACS, Chairman of the Board of Governors.

The feeling of many general surgeons that the American College of Surgeons does not adequately represent them remains a concern for the College. A number of steps have been taken by the College to try to accommodate this concern. The size of the Advisory Council for General Surgery has been increased, and the spring meeting is devoted to general surgery. At the same time, concern was expressed in the Advisory Council for Otolaryngology that the educational programs presented during the fall meeting of the College may not be adequate in content for our specialty to justify the expense of otolaryngologists belonging to the College. Apparently, some otolaryngology councils are considering eliminating the requirement for their members to belong to the American College of Surgeons. However, the consensus feeling of the Advisory Council was that the American College of Surgeons is the only group that can speak for the entire field of surgery, and they are more effective in protecting our interest than the American Medical Association. The American College of Surgeons continues to be increasingly active in the socioeconomic sphere, and this activity alone, without the educational programs of the College, most likely justifies the expense for otolaryngologists to belong.

Respectfully submitted,
Warren Y. Adkins, Jr, MD
Governor, American College of Surgeons

REPORT OF THE LIAISON OF THE AMERICAN BOARD OF OTOLARYNGOLOGY

The American Board of Otolaryngology (ABO) is pleased to report the following.

Examination Statistics. Three successful examination cycles have now been completed with use of the new examination format. For certification, candidates must first pass a written (qualifying) examination and then pass an oral examination. The written and oral examination scores are not combined. Candidates who pass the written examination have up to three consecutive opportunities to take the oral examination. If a passing score in the oral examination is not achieved after three examination cycles, the candidate must reapply to take the written examination, and must again achieve a qualifying score in order to be permitted to retake the oral examination.

Three hundred forty-five candidates took the written examination in September 1993. Of those candidates, 14% failed, while the remaining 86% became candidates for the oral examination. The oral examination was conducted for 337 candidates in April 1994 at the Palmer House Hotel in Chicago. Two hundred ninety-seven individuals were certified as a result of this examination, for an overall pass rate of 77%.

Elections. At the April 1994 business meeting, Dr M. Eugene Tardy, Jr, was elected President, and Dr Eugene N. Myers was elected Vice-President (President-Elect). Dr Robert W. Cantrell was reelected to a third term as Executive Vice President, and Dr D. Thane Cody continues to serve as Treasurer. Dr Herbert C. Jones and Dr Gayle E. Woodson were elected to the Board of Directors, replacing Dr Frank N. Ritter and Dr Paul H. Ward, who were elevated to Senior Councilor status after many years of dedicated service to the ABO. Dr Jones is in the private practice of otolaryngology–head and neck surgery in Atlanta, Georgia, and Dr Woodson is Professor of Otolaryngology at the University of Tennessee in Memphis.

Associate Examiners. The position of Associate Examiner was initiated last year. To be elected as an Associate Examiner, an individual must have served as an ABO examiner at least twice. He or she must be prominent in the specialty, especially in the areas of patient care and medical education, and must demonstrate an interest and ability in the creation of educational and test materials. The ABO is committed to electing and training new examiners while maintaining consistency in administering the examination. The Associate Examiners are a core group of experienced examiners to fulfill this need, along with the Directors. Associate Examiners are elected to a 3-year term, and are eligible for reelection to one additional term. The Associate Examiners are (elected in 1992) Edward L. Applebaum, MD; Hugh F. Biller, MD; Nicholas J. Cassisi, MD; A. Julianna Gulya, MD; Lauren D. Holinger, MD; Jonas T. Johnson, MD; Herbert C. Jones, MD; Frank E. Lucente, MD; Dale H. Rice, MD; James Y. Suen, MD; Gayle E. Woodson, MD; and (elected in 1993) Robert A. Dobie, MD; Paul J. Donald, MD; Ellen M. Friedman, MD; Jack L. Gluckman, MD; G. Richard Holt, MD; Herman A. Jenkins, MD; Douglas E. Mattox, MD; Richard T. Miyamoto, MD; Robert H. Ossoff, MD; William J. Richtsmeier, MD; Clarence T. Sasaki, MD; Nancy L. Snyderman, MD; and Ernest A. Weymuller, Jr, MD.

Respectfully submitted,
Eugene N. Myers, MD
ABO Liaison to the
American Laryngological Association

REPORT OF THE TREASURER

I present the audited financial statement for the Council's review.

The Finance Committee, consisting of Drs Byron J. Bailey, Gerald B. Healy, William R. Hudson, H. Bryan Neel III, and Robert W. Cantrell, Chairman, met and reviewed the audited financial statements for 1993 and made the following recommendations for the Council's consideration.

1. Proceeds from the Arthur W. Proetz Trust Fund shall be used as a part of the research grant in 1994.
2. Since operating expenses exceeded revenues, a dues increase from $200 to $250 will be recommended to the membership at the annual meeting with a $50 penalty if not paid in 6 months.
3. Reimbursement for the Council members for the January 1994 Council Meeting is as follows.
   a. Round trip coach airfare.
   b. Rental car expenses or ground transportation from airport to hotel.
   c. Room (4 nights) in hotel, meals, and tips.
4. Reimbursement for the COSM May 1994 meeting will be as follows.
   a. President — 3 nights in hotel, plus cost of spouses luncheon.
   b. Secretary — 3 nights in hotel.
   c. Council Members — 1 night in hotel.
5. Investment policy.
   a. Funds to be invested.
      1. 50% in equity.
      2. 50% in fixed instruments.
   b. Equities to be invested.
      1. One half (25% of total) in a fund similar to Vanguard's indexed to Standard and Poor's 500.
      2. One half (25% of total) invested in stock as now. Consideration should be given to investing in international equities.

Respectfully submitted,
Robert W. Cantrell, MD
Treasurer

To the Board of Directors of the
American Laryngological Association

We have compiled the accompanying balance sheet of the

American Laryngological Association as of December 31, 1993, and the related statements of revenues, expenses, and changes in fund balances and cash flows for the year then ended, and the accompanying supplementary information contained in Schedules I and II, which are presented only for supplementary analysis purposes, in accordance with standards established by the American Institute of Certified Public Accountants.

A compilation is limited to presenting, in the form of financial statements and supplementary schedules, information that is the representation of the Association's management. We have not audited or reviewed the accompanying financial statements and supplementary schedules and, accordingly, do not express an opinion or any other form of assurance on them.

Respectfully submitted,
Deane and Fulton, Ltd

Charlottesville, Virginia
January 11, 1994

STATEMENT OF ASSETS, LIABILITIES, AND FUND BALANCES FOR THE YEAR ENDED DECEMBER 31, 1993

ASSETS

Current Assets:	
Cash — checking	$104,902
Money Market Funds	36,612
Accounts receivable — dues	400
Accrued interest receivable	1,966
Prepaid expenses	650
Total Current Assets	$144,530
Long-term Investments:	
Marketable securities — stocks	$ 96,684
US Treasury obligations	199,752
Total Long-term Investments	$296,436
Total Assets	$440,966

LIABILITIES AND FUND BALANCES

Fund Balances (Deficit):	
General Fund	($ 37,068)
Trust Fund	478,034
Total Liabilities and Fund Balances	$440,966

See Accountants' Compilation Report and Notes to Financial Statements.

STATEMENT OF CASH FLOWS FOR THE YEAR ENDED DECEMBER 31, 1993

Cash Flows From Operating Activities:	
Deficit of revenues and investment income over expenditures	($ 7,846)
Adjustment to reconcile with net cash provided:	
Increase in accounts receivable — dues	(400)
Decrease in accounts receivable — banquet	190
Decrease in accrued interest receivable	290
Increase in prepaid expenses	(650)
Loss on sale of investments	738
Net Cash Applied to Operating Activities	($ 7,678)
Cash Flows From Investing Activities:	
Proceeds from sale of investments	$258,251
Payments to acquire investments	(206,139)
Net Cash Provided by Investing Activities	$ 52,112
Net Increase in Cash and Cash Equivalents	$ 44,434
Cash and Cash Equivalents, beginning of period	$ 97,080
Cash and Cash Equivalents, end of period	$141,514

See Accountants' Compilation Report and Notes to Financial Statements.

SCHEDULE OF LONG-TERM INVESTMENTS DECEMBER 31, 1993

Stocks	*Shares*	*Cost*	*Market Value*
American Telephone & Telegraph	300	$ 8,974	$ 15,750
Ameritech	60	1,122	4,605
Bell Atlantic	80	1,138	4,740
General Public Utilities	400	10,218	12,350
IBM	40	1,321	2,260
Long Island Lighting	200	4,661	4,875
MCI Communications	600	10,410	16,950
Niagara Mohawk Power	600	11,122	12,150
Nynex	80	1,068	3,210
Pacific Gas and Electric	300	9,423	10,538
Pacific Telesis	80	897	4,340
Procter & Gamble	200	10,136	11,400
Southern	200	6,389	8,825
Southwestern Bell	120	1,030	4,980
Texas Utilities	250	10,045	10,813
US West	300	8,730	13,762
		$ 96,684	$141,548
US Treasury Obligations:			
$100,000 3 7/8% Treasury Note due February 28, 1995		$ 99,876	$ 99,876
$100,000 3 7/8% Treasury Note due October 31, 1995		$ 99,876	$ 99,876
		$199,752	$199,752

See Accountants' Compilation Report and Notes to Financial Statements.

STATEMENT OF REVENUES, EXPENSES, AND CHANGES IN FUND BALANCES FOR THE YEAR ENDED DECEMBER 31, 1993

Revenues:	
Dues	$ 18,800
COSM registration	13,670
Sale of publications	2,040
Donations	8,100
Annual meeting	12,700
Speaker sponsorship	500
Proetz Trust	6,417
Total revenues	$ 62,227
Expenses:	
Annual meeting and banquet	$ 27,351
Council travel and expenses	12,269
Printing, postage, and supplies	4,944
Professional fees	2,099
Research awards/donations	21,149
Clerical and administrative	2,500
Publications	12,801
Insurance	1,795
Other travel	437
Accreditation fee	500
Miscellaneous	247
Total expenditures	$ 86,092
Deficit of Revenues over Expenditures	($23,865)
Investment Income	16,757
Loss on Sale of Investments	(738)
Deficit of Revenues and Investment Income over Expenses	($ 7,846)
Fund Balances, beginning of year	448,812
Fund Balances, end of year	$440,966

See Accountants' Compilation Report and Notes to Financial Statements.

SCHEDULE OF INDIVIDUAL TRUST FUNDS FOR THE YEAR ENDED DECEMBER 31, 1993

	Fund Balance 01/01/93	*Revenues*	*Income*	*Disbursements*	*Transfers*	*Fund Balance 12/31/93*
Daniel C. Baker, Jr, Memorial Fund	$ 51,398	$	$ 1,733	$ 3,092	$	$ 50,039
Casselberry Fund	30,881		1,041	(1,000)		30,922
Johnston Fund	31,797		1,072			32,869
De Roaldes Fund	17,938		605	(235)		18,308
Newcomb Trust Fund	12,650		427			13,077
Newcomb Prize Fund	3,041		103	(128)		3,016
Research Fund	132,410	7,450	4,465	(16,500)	1,137	128,962
Seymour Cohen Fund	130,033		4,385			134,418
Memorial Fund	33,726	650	1,137		(1,137)	34,376
Gabriel F. Tucker Fund	24,299		819	(194)		24,924
Dr Louis H. Clerf Memorial Fund	6,891		232			7,123
	$475,064	$ 8,100	$16,019	($21,149)	$ 0	$478,034

See Accountants' Compilation Report and Notes to Financial Statements.

NOTES TO FINANCIAL STATEMENTS — DECEMBER 31, 1993

1. Summary of significant accounting policies

This summary of significant accounting policies of the American Laryngological Association (the Association) is presented to assist in understanding the Association's financial statements. The financial statements and notes are representations of the Association's managing council, which is responsible for their integrity and objectivity.

General. The Association is a nonprofit corporation organized for the advancement and promotion of the study of the science of medicine and surgery, devoting special attention to the upper aerodigestive tract, and to engage in and to encourage research with respect thereto. This includes the elevation of standards of the fundamental study and teaching of rhinology and laryngology in the undergraduate and postgraduate medical schools of America, the publishing annually of the proceedings of this Association, and the honoring of those who, by their contributions in the field of rhinology and laryngology, have aided in its advancement.

Method of Accounting. The financial statements have been prepared in accordance with generally accepted accounting principles on the accrual basis.

Accounts Receivable. The Association follows the practice of writing off uncollectible accounts as they are incurred. There is no allowance for uncollectible accounts reflected in the balance sheet. Management is of the opinion any allowance would be immaterial.

Investments. The Association's investment in marketable securities (common stocks) is carried at the lower of aggregate cost or quoted market value.

2. Federal income tax

No provision for federal income tax is included in the financial statements as the Association is exempt from federal income tax under the provisions of Section 501(c)(3) of the Internal Revenue Code.

3. Allocation of investment income

Interest on US Treasury notes, certificates of deposit, and money market accounts, as well as dividends on common stock, are credited as income to the Trust Fund. Trust Fund income is further allocated to each individual fund in the ratio each fund balance bears to the total value of the trust funds at the beginning of the year. Additionally, by action of the Council on January 3, 1976, current income from the Memorial Fund is to be transferred to the fund balance of the Research Fund.

4. Arthur W. Proetz Trust Fund

On November 9, 1987, the American Laryngological Association was named the conditional beneficiary of a Trust under the will of Arthur W. Proetz. The entire net income derived from the Trust is paid quarterly to the Association to be used for research, education, or scientific activities related to the science of rhinology or laryngology. The following five persons comprise the committee that administers the disbursements of net income from the fund: Robert W. Cantrell, MD; John M. Fredrickson, MD; William R. Hudson, MD; H. Bryan Neel III, MD, PhD; and Byron J. Bailey, MD.

5. Cash flows

For purposes of the statement of cash flows, the Association considers all deposit accounts and money market funds to be cash and cash equivalents.

Respectfully submitted,
Robert W. Cantrell, MD
Treasurer

RECIPIENTS OF THE DE ROALDES AWARD

1928	Chevalier Jackson
1931	D. Bryson Delavan
1934	Harris P. Mosher
1937	Lee Wallace Dean
1943	Ralph A. Fenton
1949	George M. Coates
1951	Arthur W. Proetz
1954	Louis H. Clerf
1959	Albert C. Furstenberg
1960	Dean M. Lierle
1961	Frederick T. Hill
1966	Paul H. Holinger
1970	Francis E. LeJeune
1973	Lawrence R. Boies
1976	Anderson E. Hilding
1979	Joseph H. Ogura
1982	John J. Conley
1985	John A. Kirchner
1985	Charles M. Norris
1987	Walter P. Work
1988	DeGraaf Woodman
1989	John F. Daly
1990	Joseph L. Goldman
1991	William W. Montgomery
1992	M. Stuart Strong
1993	Douglas P. Bryce
1994	Paul H. Ward

RECIPIENTS OF THE CASSELBERRY AWARD

1923	George Fetterolf and Herbert Fox
1928	Ralph A. Fenton and O. Larsell
1929	Richard A. Kern and Harry P. Schenck
1929	Edward H. Campbell
1931	Arthur W. Proetz
1934	Anderson C. Hilding
1936	Francis E. LeJeune and Joel J. Pressman
1939	H. Marshall Taylor and Brien T. King
1940	French K. Hansel
1941	Noah D. Fabricant
1946	Paul H. Holinger
1949	Henry B. Orton
1962	Hans von Leden
1966	John A. Kirchner and Barry D. Wyke
1968	Joseph H. Ogura
1985	H. Bryan Neel III
1987	Joseph J. Fata
1991	James L. Koufman
1993	Frank E. Lucente
1994	Ira Sanders

RECIPIENTS OF THE NEWCOMB AWARD

1941	Burt R. Shurly
1942	Francis R. Packard
1943	George M. Coates
1944	Charles J. Imperatori
1947	Harris P. Mosher
1948	Gordon Berry
1949	Gordon B. New
1950	H. Marshall Taylor
1951	John D. Kernan
1952	William J. McNally
1953	Frederick T. Hill
1954	Henry B. Orton
1955	Thomas C. Galloway
1956	Dean M. Lierle
1957	Gordon F. Harkness
1958	Albert C. Furstenberg
1959	Harry P. Schenck
1960	Joel J. Pressman
1961	Chevalier L. Jackson
1962	Paul H. Holinger
1963	Francis E. LeJeune
1964	Fred W. Dixon
1965	Edwin N. Broyles
1966	Lyman G. Richards
1967	Joseph H. Ogura
1968	Walter P. Work
1969	John A. Kirchner
1970	Louis H. Clerf
1971	Daniel C. Baker, Jr
1972	Alden H. Miller
1973	DeGraaf Woodman
1974	John J. Conley
1975	Francis W. Davison
1976	Joseph L. Goldman
1977	F. Johnson Putney
1978	John F. Daly
1979	Charles F. Ferguson
1980	Charles M. Norris
1981	Stanton A. Friedberg
1982	William M. Trible
1983	Harold G. Tabb
1984	Daniel Miller
1985	M. Stuart Strong
1986	George A. Sisson
1987	John S. Lewis
1988	Douglas P. Bryce
1989	Loring W. Pratt
1990	William W. Montgomery
1991	Seymour R. Cohen
1992	Paul H. Ward
1993	Eugene N. Myers
1994	Richard R. Gacek

RECIPIENTS OF THE GABRIEL F. TUCKER AWARD

1987	Seymour R. Cohen
1988	Charles F. Ferguson
1989	Blair Fearon
1990	Gerald B. Healy
1991	John A. Tucker
1992	Bruce Benjamin
1993	John N. G. Evans
1994	Joyce A. Schild

RECIPIENTS OF THE AMERICAN LARYNGOLOGICAL ASSOCIATION AWARD

1988	Frank Netter
1989	Shigeto Ikeda
1990	Hans Littmann
1991	Arnold E. Aronson
1992	Michael Ter-Pogossian
1993	C. Everett Koop
1994	John C. Polanyi

RECIPIENTS OF THE AMERICAN LARYNGOLOGICAL ASSOCIATION RESIDENT RESEARCH AWARD

1990	David C. Green
1991	Timothy M. McCulloch
1991	Ramon M. Esclamado
1992	David H. Henick
1993	Gregory K. Hartig
1994	Sina Nasri

RECIPIENTS OF THE AMERICAN LARYNGOLOGICAL ASSOCIATION YOUNG FACULTY RESEARCH AWARD

1991	Paul W. Flint
1992	Yasuo Hisa
1993	Jay F. Piccirillo
1994	Hans J. Welkoborsky

THE MEMORIAL AND LARYNGOLOGICAL RESEARCH FUNDS

The Council earnestly requests that Fellows of the Association give consideration to making a special bequest to these important funds, or to becoming a Benefactor.

MEMORIAL FUND DONORS

Mrs Daniel C. Baker, Jr
Daniel C. Baker, Jr
John F. Barnhill
August L. Beck
Gordon Berry
William E. Casselberry
Cornelius G. Coakley
Robin T. Cotton
Lee Wallace Dean
Arthur W. De Roaldes
Fred W. Dixon
George Fetterolf
Joseph L. Goodale
William E. Grove
Gordon F. Harkness
Frederick T. Hill
George E. Hourn
Samuel Johnston
James E. Newcomb
Henry B. Orton
Lup Q. Pang
Pediatric Anaesthesia Associates, Ltd, of the Childrens Memorial Hospital of Chicago
Loring W. and Mrs Pratt
Lyman G. Richards
Burt R. Shurly
Lester T. Sunderland
H. Marshall Taylor
Walter H. Theobald
Gabriel F. Tucker, Jr
Francis L. Weille
Eiji Yanagisawa

BENEFACTORS

Mrs Sally Sample-Aall
Mrs Daniel C. Baker, Jr
Edwin N. Broyles
Louis H. Clerf
Seymour R. and Mrs Cohen
John J. Conley
John F. Daly
Francis W. and Mrs Davison
Stanton A. Friedberg
Thomas C. Galloway
Joseph L. Goldman
Robert L. Goodale
Edley H. Jones
Zelda Radow Weintraub Cancer Fund, Inc
A. P. Marchessini
Francis H. McGovern
Charles M. Norris
Samuel Salinger
Sam H. Sanders
Harry P. Schenck
Karl Storz Endoscopy–America, Inc
Oliver W. Suehs
William M. Trible
DeGraaf Woodman

PRESIDENTIAL REMARKS

THE FUTURE OF THE AMERICAN LARYNGOLOGICAL ASSOCIATION

BYRON J. BAILEY, MD

We are privileged to live in a time of unprecedented changes in biomedical research, medical education, and clinical practice. The rate of change, the scope of the issues involved, and the depth of the intent to restructure the very core of medicine has no parallel in history. While it is likely that some of the concepts and the principles that we have valued will be lost, I believe that it is equally certain that investigators, teachers, and physicians will have an exciting menu of new opportunities placed before them. Those who have prepared themselves for the future, those with open eyes and ears, and those with open minds will be positioned to benefit in the years ahead. This is a time for wise prophecy.

Recognizing the value of long-range and strategic planning, the American Laryngological Association (ALA) launched the first in a series of strategic planning meetings on January 14, 1994, in Marco Island, Florida. Those in attendance were Drs Robert W. Cantrell, Roger L. Crumley, John M. Fredrickson, Gerald B. Healy, William R. Hudson, Joyce A. Schild, James B. Snow, Jr, and Paul H. Ward. The ideas were creative, the discussions were lively, and the outcome of that meeting represents a first step in the evolution of a critical process of strategic planning for the American Laryngological Association.

It has often been said that "only fools try to predict the future." I believe that in these times, only fools *don't* try to predict the future. Of course, it is never an easy task, and as one great philosopher from our national pastime (Yogi Berra) observed, "The hard thing about trying to predict the future is that it hasn't happened yet."

As you review the elements of our proposed plan, we ask each member to provide feedback concerning items with which you agree or disagree, and suggestions for improving it. This will help us to determine the ALA's readiness to engage in reorganization for the future. We need validation of our general impression that this Association is well positioned for future events, but must be flexible, willing to change, and unified in its focus on meeting the needs of our patients.

The broad purpose of our long-range and strategic planning is to see the best role for the ALA in tomorrow's world and to restructure and move our resources in that direction. This may not be easy, and it may require a redefinition of the ALA in order to



increase its importance to investigators, educators, clinicians, and patients. In essence, it will require the setting of some new priorities, and the implementation of some new programs. The end result will be based on a careful reassessment of our mission, strengths, weaknesses, threats, and opportunities.

The bottom line of *the mission* of the ALA focuses on a vision of improved care of patients with laryngeal dysfunction by advancing diagnostic and treatment methods, by emphasizing neurolaryngology, and by expanding the research effort in this field.

Strengths. The ALA is a venerable professional society whose members have made thousands of important contributions to the field of laryngology. The society has a tradition of excellence and has been focused on important new information. We have enjoyed a membership of outstanding quality, perhaps to the point of maintaining an excessive element of exclusivity. We have changed slowly, we have had a long commitment to stability, but in the end we have had a willingness to adapt to the changing world around us.

Weaknesses. In the perception of the strategic planning group, the overarching weakness of the

ALA is that it has a very low profile. Some view this as the downside to our tradition of excellence and have observed that our elitist attitude and our limited membership may not work to our advantage in the future. We have not been as successful in involving key nonphysicians in our organization, nor have we provided the level of support for research activities that we must provide in the future. Beyond the conduct of an excellent annual scientific meeting, we have developed almost nothing in the way of an organized educational program for the dynamic field of laryngology.

Threats. The planning group observed with a sense of sadness that we are losing the rich heritage of laryngology, and notes that the names and contributions of the giants of the past century are generally unknown by the younger specialists in our field. The ALA has a minimal connection to the residents in our specialty and lacks a communication link to primary care physicians. At the present, there is a tenuous bond between laryngologists and neurolaryngologists. We lack standardization of many of our diagnostic tests and treatments, and we are deficient in outcome analysis for the therapies that we employ. Several of these concerns are related to the minimal leadership that this organization has provided in terms of seeking major research support and identifying important research priorities. The comment that we have all heard on many occasions is that this is an important professional society, but almost no one outside our small membership understands the present or future role of the ALA on the broad playing field of medicine.

Opportunities. Now is the time for the ALA to exert leadership in the area of biomedical research, and I will expand on that theme with some specific recommendations in a moment. We must design an initiative that will allow us an organization, and in conjunction with other organizations, to develop high-quality educational materials for practicing otolaryngologists, for residents, and for primary care physicians. We must recruit actively and welcome warmly into the ALA those individuals who are working in the emerging field of neurolaryngology. As we set future policy, we must be certain that our efforts are directed to unifying our small subspecialty, and we must avoid any steps that would fragment this field. We must provide leadership in the development of standardized measurements in our diagnostic and therapeutic efforts. Even the most casual observer can see the disparity between the progress that has been made in the field of audiology and hearing testing and the lack of uniformity in the assessment of vocal function and voice disorders. There is also a tremendous opportunity for the ALA in providing leadership in outcome research in the field of laryngology, particularly through the cooperative networking of existing resources and the encouragement we can provide to new investigators. Success in these areas will most certainly raise the profile of the ALA and will validate the opinions that we hold concerning its importance.

As we begin our march into the future, we must as always begin with a single step. I see that first step to be the reaching of a consensus that the ALA is in the business of *medical information*. Our central purpose is the discovery, the analysis, and the dissemination of important new scientific information that is useful in the daily decisions we make as we care for our patients. Improvements in our medical information base will lead to improving patient care.

If we can reach that consensus of the centrality of medical information, how do we move forward with a specific plan of work? This question brings us to the first of two important new concepts, and we will refer to this as the *ALA voice research network*. This organization currently funds one research grant per year. We can and we must do more, and I believe that it is realistic to set an initial goal of increasing our grant support tenfold over the next 10 years. This will require a new strategy and a new structure for the purpose of raising funds from sources beyond our own personal pocketbooks, namely, our patients, the larger public, and corporations. Perhaps the final model will bear some similarity to the Deafness Research Foundation, or perhaps it will look rather different. In any event, it will require the cooperative spirit of many of our members, a mechanism for dealing with both designated and unrestricted gifts, a willingness to trade some autonomy for a greatly expanded research treasury, and the ability to deal rationally with many other important issues. Securing an effective professional staff will be the major key to success. Working with celebrities, perhaps from many different fields of music and entertainment, will greatly enhance the visibility of this program and the ALA. I have appointed a task force to pursue this initiative, and I am extremely pleased that Dr Robert H. Ossoff has agreed to devote a good bit of his energy to the launching of this effort.

The organizations likely to retain their viability in the coming decades, and particularly those organizations that prosper, will find themselves extremely dependent on strategic alliances. The concept of an ALA-sponsored national voice research network is a perfect example of a strategic alliance that holds the key to the future of the ALA. Internal alliances, networks of our members interacting toward a com-

mon goal, have the potential to become the primary force in setting national research priorities, securing major research funding, and finding the answers to our clinical questions through solid investigative activities.

External networks, scientific partnerships, provide another major avenue for the future success of the ALA. The second key initiative discussed by the planning group is the creation of an *ALA laryngeal research study group*. This group will focus on liaison with the National Institute on Deafness and Other Communication Disorders (NIDCD) and will stay abreast of NIDCD activities and provide input with regard to important research priorities in laryngology and neurolaryngology. There would be great value in holding periodic meetings with the Director of NIDCD and with other funding agencies. Ideally, the ALA will provide the foundation for a research study group engaged in cooperative, multi-institutional, clinical investigation and outcome studies. It is feasible and highly desirable to proceed with the preparation of a grant application for funds to support such a study group in the near future. I have appointed a task force to pursue this initiative, and I am extremely pleased that Dr Roger L. Crumley has agreed to lead this effort.

If successful, these two initiatives will place the ALA at the forefront of research in our field worldwide. If successful, these two initiatives will bring forth more important new scientific information in the field of laryngology in a decade than has come forward in the past century. *Information is our future.* Information is the core of the ALA, and it has a value greatly in excess of what we have given it in the past.

In medicine, research activities are almost always interwoven with educational activities. This interdependent relationship is quite striking in some medical disciplines with regard to fellowship training in subspecialties. If we look at fellowships in the field of laryngology, we note that there are currently four such programs, and it is likely that the number will increase. I believe that it is time for the ALA to define its role with regard to fellowships in laryngology, lest they begin to spring up almost at the whim of individuals, and occasionally with less than ideal educational motivation or commitment. Understand that none of my remarks pertain to the four existing laryngology fellowships. My concern, and I have expressed it publicly on numerous occasions, is that the unrestrained proliferation of fellowship programs invites a variety of abuses. Perhaps the ALA should take a leadership position in developing a mechanism for sponsoring fellowships in laryngology. If so, this could lead to the creation of a few fellowship programs of high quality. These should probably be a minimum of 2 years in duration, and they should contain a strong research element. While I have been vocal in my objection to the proliferation of fellowships, especially those with a tenuous preceptorship quality, I want to be equally forceful in my support for a few high-quality fellowships, as I sincerely believe that the future of laryngeal research is closely linked to the success of a few excellent fellowships. These will be the source of the next generation of qualified clinical investigators in laryngology and neurolaryngology.

In the final segment of my address, I want to share with you some of the important elements of the transformation that the ALA must make to move successfully into the next millennium. First of all, I believe that we must change the way in which we view this organization. In the future, we will do well to think of the ALA less as a club, and more as an "18-wheeler" on the information superhighway. To survive, and certainly to prosper, the ALA must come to regard important new scientific information as its core business. Information will be the keystone that supports all of the other elements.

In addition, we must regard the ALA, a corporation serving a small subspecialty, as being a *business* in a certain sense. This perspective is important because of our competitive and rapidly changing world. In such an environment, the ALA, as a corporate entity, must focus on three items:

1. Defining our essential business.
2. Identifying our business needs.
3. Developing a strategic plan.

What are our business needs? While there are many needs, I believe that four items deserve particular emphasis:

1. We must train a new generation of investigators in the field of laryngology and neurolaryngology. These investigators, in addition to their basic research training, will need seed money, ongoing research support, and an investigative environment that will nurture their careers and produce important new information. Two key elements to sustain their activity will be the ALA voice research network and the ALA national laryngeal research study group.
2. We should expand our membership, so that all qualified clinicians and non-MD investigators are included in this Association.
3. We need to develop an expanded publication effort. Through the resources of the ALA and in

collaboration with other organizations, we must increase the amount of information provided to residents and practicing physicians in otolaryngology–head and neck surgery and to physicians in primary care fields.

4. We need to develop a higher profile.

In tomorrow's world, the ALA will have a focused information strategy. We will utilize important products of our expanded research activities to increase the scope and the reach of this organization through the leverage obtained from internal and external alliances, and thereby we will increase the flow of new information to those in need of our product.

This ALA strategic plan builds on our strengths, masks our weaknesses, and exploits the opportunities that will open up to us in the near future. The talented leaders of the future will avoid the threats and pitfalls lurking along the way and will wisely leverage our limited resources by means of strategic alliances among our membership and outside of the ALA.

And finally, let me ask you to join me in seeking the answers to the important questions about our future. What will the ALA look like in 20 years or 50 years or 100 years if we have recruited every deserving laryngologist, established the voice research network and the laryngeal research study group, embraced the field of neurolaryngology, recognized information as our essential business, and increased research funding through the ALA tenfold?

I believe that if we succeed in the area of these initiatives that we will be astonished at the outcome. I can see the ALA standing preeminent in laryngology and neurolaryngology on the world stage. I see an ALA future built upon the optimism of youth and the wisdom that comes from experience. It is a vision of the future that can only be achieved through cooperation, persistence, and hard work. Time will reveal whether I have shared with you the vision of a prophet or the dream of just another fool trying to predict the future.

In closing, I want to thank each of you for the high honor and the privilege of serving this past year as your President. It is a humbling experience for me to read the names of those who served as President of this organization during its long and illustrious history.

I am sincerely and deeply appreciative of the efforts of so many members of this organization who have enriched my life over the years. So much that we accomplish flows directly from the knowledge, the encouragement, and the wisdom of our teachers and our colleagues. I feel truly blessed to have the opportunity to learn from individuals like Joel J. Pressman, Paul H. Holinger, Joseph H. Ogura, George F. Reed, George A. Sisson, Bobby R. Alford, James B. Snow, Jr, Paul H. Ward, and so many others.

And yet, we have barely scratched the surface. The great majority of what we need to know remains unknown. The task is far from finished, and it is clearly up to each of you to take your particular measure of responsibility and to make a commitment to the continuing success of the ALA.

INTRODUCTION OF GUEST OF HONOR PAUL H. WARD, MD

BYRON J. BAILEY, MD

It is a great pleasure to introduce our Guest of Honor. Paul Ward has been a leader in our field for many years. He distinguished himself in his early years in Chicago, at Vanderbilt, and during many years at UCLA. I have enjoyed greatly the opportunity of working in many arenas with Paul and am continually impressed by his energy, his enthusiasm, and his ability to analyze critically the important issues confronting whatever group it might be. So, it is a great pleasure to introduce Paul Ward to you and to ask him to present a few of his thoughts as our Guest of Honor.

GUEST OF HONOR ADDRESS

SOCIOECONOMIC, POLITICAL, AND SCIENTIFIC PREDICTIONS FOR OTOLARYNGOLOGY AND LARYNGOLOGY BY THE YEAR 2000

PAUL H. WARD, MD

Let me express my deep appreciation to our President, Dr Byron Bailey, and the American Laryngological Association for this happy occasion of being selected Guest of Honor. My address is merely an appendage to President Bailey's. He has asked me to gaze into my crystal ball and come up with some socioeconomic, political, and scientific predictions for the next decade.

I'm reminded of the drunk who came home as the sun was rising. His wife was irate and wanted to know where he had been. He informed her he came home late in the evening, stopped to rest in the hammock, and fell asleep. She said she had taken down the old hammock 3 weeks ago. His reply was, "Well, that's my story and I'm sticking with it." What I am going to guess may or may not occur, but it is my story and I'm going to stick with it! It has about the same potential and may be as accurate or inaccurate as the expensive think tank studies commissioned by the government and other private organizations.

We now have almost $1^1/2$ years of Clinton presidency under his and her belts and a Congressional majority of Democrats in both the House and Senate. The milieu is preset for the most dramatic changes in society since the passage of the Social Security Act 60 years ago and that of Medicare in 1965. The President and Congress were elected upon their campaign promises to fix the broken health care delivery system. A system that is excessively expensive. A system where many of the poor have no access, where even the employed middle class with medical problems are only a pink slip away from the loss of their medical insurance because of a preexisting condition, and where corporate employers who are responsible for their employees' medical bills change their insurance carriers, leaving the employee without access to his or her physicians.

No one, of course, knows what will happen to the Clintons' plan for universal medical care, how it will be modified, *or* whether an alternate plan will be submitted by Congress.

Health care consumed over 14% of our gross national product in 1993, a figure predicted in 1989 to be reached in 1996. The current expenditure is increasing by 1% of our GNP every 35 months.



Currently, the major automotive companies expend $750 to $1,000 on health insurance for every automobile produced. The President feels health care reform is essential if we are going to get our economy on the move again.

Passage of the Clinton plan or a modified version of a competitive managed care plan appears probable *unless* a single-payer nationalized plan is passed by Congress. I have a strong feeling that we will go through the experience of a competitive managed care health process first. When the insurance companies, health maintenance organizations, and other private health care corporations have wrung the system dry, then we will witness buyouts, takeovers, and failures of many corporations such as we saw with Maxi Care a few years ago. At this point, with the difficult cost-cutting accomplished, the administration and Congress will introduce and pass a single-payer universal program. These experiences have already happened in California and will soon happen in your state. A single-payer initiative is already on the California ballot for November.

Let me return to the main topic of how these socioeconomic changes impact the future of otolaryngology–head and neck surgery.

Since the government's stated objective is to increase the number of primary care providers, which include general physicians, internists, nurse practitioners, and physician's assistants, the impact will be a programmed decrease in the numbers of all practicing specialists, in our case otolaryngologist–head and neck surgeons.

Your American Board of Otolaryngology is intensifying its manpower study to provide reasonable estimates of the numbers of specialists in our field who will be needed during the next decade based on prevalence of various diseases and the number of physicians who will be practicing in the specialty in the coming years. This also includes predicting how many residency positions are needed to meet these expectations. These figures are expected to be available this summer.

Well, here are my calculations based upon existing knowledge. There are currently approximately 8,000 otolaryngologists, of which 6,000 are Board-certified. Fourteen hundred otolaryngologist–head and neck surgeons are currently 55 years old or older. Most of this group have established their retirement nest eggs, likely will not adapt to the loss of autonomy, and abhor governmental or corporate bureaucracy. I predict many of them will retire — something we have already witnessed.

The 92 residency (some 5-year and others 6-year) programs produce around 262 residents yearly. This means there are approximately 1,200 to 1,300 residents in the training pool. In some programs, particularly in the big Eastern cities, residents serve primarily to provide service to indigent populations, learning by experience with minimal supervision. As a matter of fact, without this care, many of the patients in the county, city, and veterans hospitals would have even more difficulty than they currently experience in receiving their basic care. This must be considered in our calculations. Will patients with a Clinton Care Card still frequent their current service providers, or will they enter the system through local primary care gatekeepers who will refer them to their group's specialist? The latter appears more likely and has the potential for tremendous changes in our training of students, residents, and paramedical personnel and a shift in the characteristics of our practice. The current 8,000 physicians (including residents) functioning as otolaryngologists are excessive for the 257 million population that is increasing at a projected 3 million per year. In order to meet the cost cap, general physicians, nurse practitioners, technicians, and other less experienced paramedical personnel will be trained to take care of sore throats, colds, otitis media, and laryngitis. The primary care physicians and others will remove cerumen, perform flexible and rigid telescopic examinations, and perform biopsies on appropriate lesions of the head and neck.

We can assume that residents currently in training and most otolaryngologists under 55 will work until age 65 or older because of lower-salaried incomes, delayed acquisition of adequate retirement benefits, and anticipated *greater* longevity.

According to my calculations, we will require only 5,000 to 5,500 otolaryngologists to care for the expected 285 to 295 million population in the year 2004.

Residency positions must be reduced 30% to 35%, from 262 annually to 156 to 189. This is not cheerful news to residency directors and academicians who rely heavily upon residents to help them care for patients in return for teaching and research time. Since residency positions are primarily paid for by governmental funds, limiting the positions funded easily controls the numbers. Determining how and which residency positions and programs are to be deleted is a more difficult problem. Problems with geographic distribution of both primary care and specialist physicians will be solved by differential incentive remuneration.

Some of these predictions sound dire to the older generation of practicing otolaryngologists, but the specialty has blossomed into one of the most dynamic in medicine. Almost three times the number of highly qualified applicants seek residencies in otolaryngology as there are residency positions. We can predict that the dynamic breadth of the field, from the microsurgery of the ear, sinuses, and larynx to radical head and neck and reconstructive surgery, will continue to expand. There will appear new innovative diagnostic and therapeutic modalities almost beyond our imagination. Laryngology, neurolaryngology, and voice diagnosis and therapy will emerge as a recognized specialty.

The next decade is perhaps the most promising ever for all of medicine. The current generation of young people entering medicine and otolaryngology do so because of the new challenges. Their attitude is one of diminished expectations for monetary rewards but with enhanced expectations and excitement about current and developing technological, medical, and surgical advances.

The maturation and introduction of molecular biology offers the prevention and correction of many genetic and acquired diseases through genetic engi-

neering. This past year the French reported completion of the genome bank, beating out our national competitive efforts to be first. They have shared these data with the world, and the next few years will provide the laborious sequencing of the 100,000 genetic pieces. Gene therapy, genetic engineering, and splicing already offer promise of prevention and correction of several diseases (for example, cystic fibrosis). I predict we will finally see prevention and cure of some head and neck cancers by this technology (viral-induced papillomata and carcinoma of the larynx, congenital defects of the larynx such as subglottic and tracheal stenosis).

Other positive aspects of the restructuring of the health care delivery system as it applies to otolaryngology will be the elimination of most ineffectual treatments, be they medical or surgical. Unnecessary surgery and ineffectual medicines simply will not be paid for with our tax dollars. Wasteful, inadequate, and inferior hospitals, medical schools, and residency training programs will become extinct. The 6-year residency will be reduced to 5 years. Residencies will be shortened to minimize lengthy, marginally effective service requirements, and stress will be placed upon intensified training. In the medical centers the teaching and education of medical students, paramedical personnel, and residents will be elevated to a level of recognition equal to research. The abundance of recently proliferating preceptor fellowships will vanish.

Those who desire to go into otolaryngology–head and neck surgery will find it even more competitive and will do so because of a specific desire and love for the specialty. Those who continue on to more restricted fellowships will do so in search of personal knowledge and satisfaction, since they will receive little if any extra financial remuneration.

It seems safe to predict that like it or not, the private practice of medicine as we have known it will cease. Patients will be cared for by a pyramid of medical personnel providing basic medical care to all citizens of our great nation. A few staunch physicians may hold out, as they have with Medicare, and provide their services only to the wealthy. The wealthy can always care for themselves, but our poor can no longer go without. I continue to reassure the students and residents that physicians will always be at the top of the heap. They deserve a good living for their intellect and lengthy training. If they care for society, then society will continue to care for and reward them. What is most important is to contribute to the health and happiness of our fellow citizens. To seek intellectual challenge and restore the confidence that has led to the high esteem, respect, and prestige of physicians. We have a bright future. Let's focus and work on making it better. I predict higher self-satisfaction and greater freedom of time allotments with more time for family and other personal activities.

In summary, what will be the overall effects of these changes? I believe in the importance, dignity, and the art and science of otolaryngology–head and neck surgery. Our place in American medicine is secure. William Faulkner, in his 1950 Nobel laureate's address, addressing the fear and doom of a nuclear holocaust that permeated society, stated, "I refuse to accept this. I believe that man will not merely endure, he will prevail." Paraphrased, I refuse to accept the decline of our devotion to the highest principles of otolaryngology. I believe that they will not only endure but will prevail and will continue to make us one of the most intellectually challenging and dynamic fields of medicine.

PRESENTATION OF THE AMERICAN LARYNGOLOGICAL ASSOCIATION AWARD TO PROFESSOR JOHN C. POLANYI

T. DAVID BRIANT, MD

It gives me great pleasure to introduce Professor John Charles Polanyi, PC, FC, FRS, the recipient of the American Laryngological Association Award. This award is given for achievement, whether for medical or nonmedical work, which contributes to the field of laryngology.

Professor Polanyi was educated at the University of Manchester, England, and Princeton University in the United States and joined the University of Toronto, Canada, in 1956. He is not a medical doctor, but is a physical chemist. His early interests were in chemiluminscence of various substances. Of note is the Pergamon Press publication from London, 1956: "A Theoretical Discussion of the Conditions Necessary for Chemiluminescence Such as the 'Airglow and Aurora.'" He published a number of articles on both infrared and visible chemiluminescence. In 1961 he published an article: "Proposal for an Infrared Maser [as the term laser wasn't invented at that time] Dependent on Vibrational Excitation," and later produced another article on what he termed the iraser and the vaser, infrared and visible analogues of the maser. This is of interest because the chemistry, physics, and mathematics involved led to the development of the carbon dioxide laser. He has continued his work on chemiluminescence, particularly in the infrared field.

In all, Professor Polanyi has 207 publications in this field. In 1986 he was awarded a Nobel prize for his early work in chemiluminescence. His Nobel laureate address was titled "Some Concepts in Reaction Dynamics" and involved the physics and chemistry of chemiluminescence. His early work led to an understanding of present lasers. He was not the first to build a laser; however, his work led directly to the development of what we understand as lasers. Lasers, of course, in our field have become a tremendously important tool. They allow surgeons to work with extreme accuracy with absolute control of bleeding in very inaccessible parts of the body such as the larynx or the ear. The laser in other fields has had a huge effect on the world of technology today. We are indeed honored to have Professor Polanyi with us today, and be able to in some small way honor a basic scientist whose work has led to developments in a field far from his own.

Professor Polanyi has a long series of awards. As mentioned above, in 1986 he received the Nobel Prize in Chemistry. He has received the Royal Medal of the Royal Society of London, and 26 honorary degrees from 26 countries. He served on the Prime Minister of Canada's Advisory Board on Science and Technology and as a foreign honorary advisor to the Institute of Molecular Sciences in Japan. He is honorary advisor to the Max Planck Institute for Quantum Optics in Germany. He is a board member of the Steacie Institute for Molecular Sciences of Canada. He was a founding member of both the Committee on Scholarly Freedom of the Royal Society and also the Canadian Committee for Scientists and Scholars, of which he is the current President.

He has written extensively on science policy and on the control of armaments and is co-editor of the book *The Dangers of Nuclear War*. Professor Polanyi is married to a very charming and active woman, Sue, who composes, plays the piano, and teaches piano. The Polanyis have two children: a daughter who is a freelance journalist and a son who started out as a physicist and is now a social worker.

It is my great pleasure to introduce Professor John Polanyi. The title of his talk will be "Confessions of a Scientist."

RESPONSE OF THE RECIPIENT OF THE AMERICAN LARYNGOLOGICAL ASSOCIATION AWARD

CONFESSIONS OF A SCIENTIST

PROFESSOR JOHN C. POLANYI

The many occasions that I and my wife have shared with the medical community are a testimonial to your generosity. I am not thinking here of generosity in kind, but of mind. More than any profession that I know, you reach out to other disciplines. You feel a kinship, I think, with others, such as myself, who attempt to understand the world and then, having failed to understand it, are foolhardy enough to try to improve it.

I chose to make my career in the inanimate sciences. We all strike a variety of Faustian bargains. In mine it was simply that in order to find an area of study that was more tractable than yours, I was obliged to choose one that was less significant. Living things, as you rightly judged in your own career choice, are much the most interesting. They are also the most resistant to dependable generalizations — which are the very stuff of science.

It may, however, come as some comfort to you to realize that the pursuit of understanding, even at the boundary between chemistry and physics where I have spent my scientific life, is a pretty desperate undertaking. This is the case despite the fact that molecules generally keep their appointments and lead fairly regular lives. Notwithstanding these advantages, it commonly takes decades in my own field of chemical physics to recognize a recurrent pattern of behavior in the midst of the confusion of unknown, and hence uncontrolled, variables.

When my graduate students knock at my office door it is seldom in order to announce a discovery, but rather to explain to me in agonizing detail why it is that they are nowhere near making one. The only source of satisfaction that these callers have is in noting that once again the physician-in-chief, myself, has proved his incompetence by prescribing a treatment to which the molecules failed to respond.

This failure on my part leads to an interesting question. How in fact does a research director differ from those whose research he or she is directing? For I believe a disinterested viewer would indeed notice a difference. It consists in this. In the midst of the



scene of confusion that I have been describing, the director is the one who believes — in the face of all the evidence to the contrary — that the laws of physics continue to apply. The truth, he believes, *can* be found, and if one remains steadfast it will reveal itself. It is a remarkable affirmation of faith. Sometimes the facts even bear it out.

If this picture of the anguish of the researcher is a little overdrawn, it still comes closer to the realities of doing science than did earlier caricatures, in which a bloodless automaton was seen as having gained access to the scientific method.

Moreover, an important change in perception has occurred. Science has become such a prominent part of our lives that some glimmer of understanding of its subtle nature, as well as its inevitable waste and error, has reached the public.

We continue to do our best, of course, to keep the

John Polanyi is a Professor of Chemistry at the University of Toronto, where he studies molecular motions in simple chemical reactions, and made the first proposals for vibrational lasers before lasers existed. He is a Nobel laureate (1986) and author of over 100 articles on science policy and issues bearing on world peace.

truth about science a secret by writing our papers as works of fiction in which we claim to have known what we were doing from the outset. Some of us go further and deliver our papers in a monotone so as to disguise our feelings toward our work, which, far from being dispassionate, resemble those of a parent for a child.

It would not matter at all if the actual truth about science — at which I have been hinting — were out. It is good that people realize that in science, as in any other type of knowing, one must fumble in a dim light in order to determine the outlines of things, and must be prepared to revise one's goals as they come into view. No, what is so damaging is not that the truth is out, but that it is half out. The public senses the confusion that characterizes the voyage of scientific discovery, but fails to appreciate the necessity for it.

There is, as a result, an opening for facile demagoguery, and in my country at least, the air is thick with it. The cry is for a new order in science, an order in which fundamental discoveries will at last be made purposefully, with a view to wealth creation and social betterment. Scientific voyages of discovery are in future to be assessed in advance, on the basis of the geography of the lands they will ultimately discover.

When challenged in the past to say why I studied the motions in newly formed chemical reaction products, I had, I thought, a ready answer. In the first place, I was exploiting a new opportunity offered by nature, and secondly, I was doing it because in my estimation it could teach us something of importance. For the way in which molecules move at the instant of their birth should have things to tell us about the intimate details of the event of chemical reaction. And without chemical reaction we would not exist.

Increasingly, this appeal to the importance of new understanding is falling on deaf ears in Canada. Since understanding is for the long term, it seems to me that we must be in the process of losing faith in our future. Instead — rich as we are — we behave like communities under siege. "The time is too late for thought," we appear to be saying, "There is only time for action."

It is relatively easy to get support for an assault on some recognizable enemy (lack of industrial competitiveness, a cure for cancer or for AIDS), but it is ever harder to get it for the vital purpose of reconnoitering to see how that enemy has disposed his forces.

There is (if a layman may diagnose) an element of schizophrenia in the public mood. The same individuals who express concern over the inefficiency and ineffectiveness of discovery-oriented science lament the speed of change forced upon us by the current rapid pace of discovery.

Both things cannot be equally true, and of the two it is the latter that is the truer. Our stumbling individual pursuit of basic science, because it responds so sensitively to nature's contours, is in fact enormously effective. The problems that we face do not stem from the ineffectiveness of the scientific sorcerer, but from the flood of discovery that has engulfed the sorcerer's apprentice.

In my own field the apprentice has brought the delights of an easier life to some, together with the hazards of overpopulation and unfulfilled expectations of prosperity to many. In yours a profession with a tradition for caring has been offered, at a price, the prospect of curing.

As always in the world of practice, calculations of benefit are problematic. It is all too easy, for example, for the reality of care to be abandoned in favor of the illusion of cure. Similarly, in my own world of science-based megaprojects and quick fixes, care for nature has all too often been neglected in favor of an illusory cure for nature's ills.

Our problems, those of the physical sciences in my case and the medical sciences in yours, are not so different. They have two sources: ignorance, and arrogance (which stems from ignorance). The message of these remarks, beyond my thanks for your kindness, is to say that the process by which we battle ignorance — the process of discovery — is as subtle and as precious as life itself. That is not just hyperbole; from infancy on, discovery is central to our lives. Let us treasure it accordingly.

PRESENTATION OF THE GABRIEL F. TUCKER AWARD TO JOYCE A. SCHILD, MD

BYRON J. BAILEY, MD

It is a pleasure to present the Gabriel F. Tucker Award for outstanding contributions in pediatric laryngology. I would like to ask John Tucker to escort this year's Gabriel Tucker award winner to the podium. This award was established in 1987 for individuals who have made outstanding contributions to pediatric laryngology and/or to the ALA. In this instance, Dr Joyce Schild from Chicago qualifies on both counts, and it is a pleasure to present to Joyce this beautiful medal in recognition of her outstanding contributions.

RESPONSE OF THE RECIPIENT OF THE GABRIEL F. TUCKER AWARD

JOYCE A. SCHILD, MD

Thank you very much. I was really overwhelmed when I first heard about this, and I still am. I worked with Gabe for a number of years at Children's, directly and then indirectly as I went full-time with the University of Illinois in Chicago. Gabe was a wonderful teacher, a wonderful mentor, and a very true friend, and I am really honored.

INTRODUCTION OF THE 20TH DANIEL C. BAKER, JR, LECTURER, LEROY E. HOOD, MD

ERNEST A. WEYMULLER, JR, MD

Excitement at the University of Washington was palpable in 1992, when it was announced that Dr Leroy Hood would leave his position as Director of the National Science Foundation Science and Technology Center at Cal Tech to accept the William Gates Chair in Molecular Biotechnology.

Time does not permit a full summary of Dr Hood's vitae, but you should know that he has produced 434 papers and that he has been honored with the Albert Lasker Basic Medical Research Award and the Louis Pasteur Award for Medical Innovation. In 1993 he was named Scientist of the Year by *R & D Magazine* for his instrumental role in launching and promoting the Human Genome Project and for his pioneering role in developing revolutionary instruments to study genes, hormones, and antibodies.

In his youth Lee was an outstanding quarterback. Now he climbs mountains for recreation. He and his wife, Valerie, have two grown children.

This lectureship has featured leaders in our field, but on appropriate occasions has brought us Lewis Thomas, James Watson, and Howard Hiatt. It is my great privilege to introduce Dr Leroy Hood, the next of that distinguished company. Thank you, Lee, for accepting our invitation.

TWENTIETH DANIEL C. BAKER, JR, MEMORIAL LECTURE

DECIPHERING HUMAN HEREDITY: A REVOLUTION IN MEDICINE OF THE 21ST CENTURY

LEROY E. HOOD, MD

It is a pleasure to be here and share with you the excitement of the change that is occurring in biology. Although I won't address specific issues that are of particular interest to you, what I will try to do is give you some idea of the enormous changes that are coming and how we deal with genetic diseases, infectious diseases, autoimmune diseases, and even cancer. What has happened in the last 15 years in biology has been an enormous revolution in the techniques by which we can examine biological information. What has happened in the past 2 or 3 years to our capacity to actually analyze biological information has clearly given us a vision of what the future, the 21st century, is going to hold for medicine, and there will be, I think, two major revolutions.

One is the whole field of preventive medicine. There will be a fundamental change. I'll return to this again. It would be interesting to have each of you write a job description of what you might be doing in 25 years, and you might think about that after I finish the lecture. The second is, of course, an even more challenging issue in many ways. How do we integrate our more detailed and fundamental understanding of humans into society? Are there limits to what we should explore? What are going to be the implications for these fundamental understandings? These are all issues that I will return to. From the point of view of medicine, the real revolution that is coming is in our capacity both to manipulate and to decipher biological information. This is going to be the basis for a new medicine in the 21st century.

So, what would be useful is for you to have some understanding of what I mean by biological information. It turns out that this falls into three very interesting categories. The first of the types of biological information relates to the information that is present in our chromosomes. As you know, chromosomes have a four-letter language. They are long strings of information that actually encode how one constructs the human organism. There are approximately 100,000 of these units of information called genes; the information is linear and digital. It is digital in the same sense that the information you have in your computers is digital. Computers have a two-letter language, one and zero. The chromosomes have the capacity to



translate units of information, the genes, into a second kind of nucleic acid called messenger RNA. It, again, has a four-letter language. Ultimately, that is translated through complex machinery into the final output, which are linear strings called proteins, which have 20 letters in their language. It is proteins that constitute the second type of biological language, because these strings can actually fold in three dimensions to construct molecular machines. It is these molecular machines that catalyze the chemistry of life and give the body shape and form. In fact, when you look at another individual, virtually everything you see is a protein. One of the unsolved problems in contemporary biology is the question, How does the order of letters of the protein alphabet dictate how this string folds in three dimensions to make a molecular machine? This is called the protein folding problem, and solving it will unlock the secrets to our being able to design at will proteins that have any particular molecular shape. These will be fundamental therapeutic agents for the future. I will talk a bit about where we will use them.

So, the second type of biological information is the

three-dimensional information that is encoded in our proteins. So, we have one-dimensional information in our chromosomes. We have three-dimensional information in our proteins. Of course, the third type is what happens when proteins and other macromolecules assemble to make subcellular components, and cells can interact in very complex ways to make tissue. So, the third type of biological information is the information that arises from complex systems and networks of cells that constitute probably the most interesting features that we will be dealing with in biology in the future. What is striking about these complex systems and networks are emergent properties. That is, properties that arise from complexity as a consequence of the interaction of many different fundamental units. The emergent properties can't a priori be predicted from the properties of the individual units themselves, and let me use the nervous system as an example. In humans we have 10^{11} neurons that constitute 10^{18} connections. If, indeed, we were to take out a single neuron and study it in enormous detail for 20 years so we understood everything it could do, it wouldn't give us one iota more information about consciousness or memory or emotional stability, as these are fundamental human qualities that are a consequence of the network of interacting neurons. They are the so-called emergent properties.

The challenge in contemporary biology, then, is to devise tools that will permit us to analyze biological complexity. And, indeed, if this new department that we formed at the University of Washington has any major objective, it is to define the tools for attacking biological complexity and point them toward interesting biological problems, and I will show you one or two in the future. You have the one-dimensional information of the DNA, the three-dimensional information of proteins, and biological complexity.

Now, I am going to talk in just a moment about the human genome, and let me say that there are two sources of information for genomic analysis. DNA can be taken directly from chromosomes, or one can make copies of DNA messengers, and they have a particular advantage, because that lets us focus just on the genes themselves. It turns out just being able to analyze the genes themselves through copies of these messenger RNAs is really a critical new approach to cancer biology, and we will talk in a few moments about that. Now, what is going to revolutionize our understanding of all three types of biological complexity is deciphering the human genome, that is, being able to understand in detail the nature of the 24 different human chromosomes depicted diagrammatically here and, in fact, how they encode their 100,000 units or so of information. The amount of information encoded in each and every one of your 10^{14} cells is enormous, 3 billion letters of the DNA alphabet packaged into 24 chromosomes: 23 pairs of chromosomes, and the sex chromosomes X and Y, which, obviously, add the 24th chromosome. They encode, as I have said before, 100,000 genes. The fundamental function of this one-dimensional information of our chromosomes is, of course, this fascinating process of human development, how we take a single cell, and each and every one of us goes through exactly the same highly programmed process to generate spheres and cylinders that flatten and invaginate and ultimately form three major germ layers and the 10^{14} cells in the human organism. The fundamental biological question that remains here is, What is the nature of this fascinating chromosomal choreography that permits different subsets of information, these 100,000 genes, to be expressed in each of the different types of cells, so that muscle, brain, and connective tissue cells are quite distant from one another? This is the fundamental question of a second major problem in biology, namely, developmental biology, and it will be enormously enriched by detailed understanding of the human genome.

The next question is, What do we mean by deciphering the human genome? We really mean for each of our 24 chromosomes, the construction of two major types of maps. A genetic map is constructed by taking traits in humans that are encoded by genes, hair color, eye color, perhaps the tendency to schizophrenia, and the traits that actually have alternative forms whose segregation can be followed through families. This is classical genetics, and in following that segregation, you can assign the trait or its gene of a particular chromosome, and indeed, once you have assigned a series of traits to a chromosome, you can determine a relative order of these traits with respect to one another. So, in a sense, what a genetic map can do for us now is give us the general location of a particular gene that encodes a fascinating trait such as schizophrenia. Now, the final type of map is called a sequence map, and that's done by determining the exact order of each of the letters of the DNA alphabet all the way across each chromosome. Now, the average human chromosome has 120 million letters in its string. It obviously is an enormously complex object, but it is the final map that will allow us to uniquely and quickly identify the gene. So, the genetic map might be likened to a general map of the United States, where you could say the gene for schizophrenia is located in a particular city like Miami, whereas the sequence map gives us the exact address of the house within which that gene is located. Hence, we know the chemical nature of that gene and we can

begin to understand what it is about.

Thus, the Genome Project really has two major objectives. In a sense, it really is not science. It is the creation of this powerful infrastructure of maps that will allow us to change both biology and medicine, and it is the creation of tools that will allow us to carry out these mapping techniques and to decipher the information that we obtain. What I would say has happened is the mapping techniques for genetic analysis have come very quickly. The mapping techniques for the sequencing analysis represent an enormous technical challenge, and I will talk just a little about that to give you a feel for some of the technologies that are being developed. About 8 years ago we developed a technology whereby you could color-code each of the four letters of the DNA language with a different fluorescent dye, and we developed an approach whereby those labeled nucleotides could then be successively identified by separation of DNA fragments on gels, and the fragments could then be interrogated by an argon laser beam and the color of the band read into a computer so one could ultimately translate the string of letters of the DNA alphabet that were present in that particular DNA fragment. We have developed machines now that have the capacity to do 50 of these analyses simultaneously, so each of these vertical columns represents the analysis of a stretch of about 500 letters of the DNA alphabet from 50 different fragments of human DNA, and all of this can be analyzed in the context of transferring the information to computers and then beginning to carry out the analysis. Now, the striking fact is that even with these advances for the future, we need to develop machines for sequencing DNA that are at least 100 if not 1,000 times more effective, and to do that we are going to bring to biology an entirely new technology called nanofabrication or microfabrication. One of the approaches is to take a silicon chip that is the size of your fingernail — it is in many ways akin to a computer chip — and to construct on that silicon chip, for example, the 65,000 different possibilities that exist for 8 consecutive letters of the DNA alphabet and to construct them so we know the address of each of the 65,000 sequences, so these sequences can be used to interrogate unknown DNA using the properties of one-dimensional molecular complementarity. What we can read out from such a chip is the simultaneous analysis of all the 8 mers that might exist in a much longer string of 100,000 nucleotides, and then computationally we can take those 8 mers and assemble them into the unknown DNA sequence. Sequence analysis in the future might be done by very small DNA chips that can, in fact, read out a sequence in a fraction of the time — one ten thousandth of the time — it takes us now to carry out DNA sequence analysis. Miniaturization and enormous parallelization compressed together with powerful computational techniques is what the future will hold.

The next challenge is to think about all this information we are getting. DNA sequencing gives us little strings of information that are 500 letters of the alphabet long, and we have to compare that against the data base that now has more than 200 million letters of the DNA alphabet. The key question is, Does this new sequence look like anything else we have seen before, so as to give us a clue as to its particular function? The matching of small strings to big strings is computationally an enormously difficult problem that increases exponentially as the size of the strings compared increases. To get around that, rather than using supercomputers, we have done again the same thing. We have recently constructed a computer chip that is again the size of a fingernail which has 400,000 transistors. These are fundamental units of operation for a specialized coprocessor, and this little chip has the capacity to carry out this string matching analysis with unbelievable speed, such that the chip, which we call a BIS chip, can carry out a particular calculation in 3.5 seconds that takes a parallel supercomputer a minute to do and a linear supercomputer 12 minutes to do. This machine costs $5 million. The other machine costs close to $15 million, and a board of these chips will probably cost on the order of $10,000. Moreover, they can be placed in simple PC workstations so that biologists and physicians can then have access to this enormously powerful approach. We are doing other things like this to analyze biological information.

But let's turn from the techniques to the consideration of how the genome initiative will revolutionize medicine as we move into the 21st century. The big change, as I have already indicated, will be our capacity to fingerprint to diagnose genes, and this will lead us to preventive medicine, which I will discuss in just a few moments. Let me say also, as we identify the 100,000 genes, they will be the basic components by which hearts operate and immune systems operate and nervous systems operate, so we will have the building block component for understanding both normal physiology and abnormal pathology in these various types of systems. Let me give you an example of how the things we have talked about today are, I think, going to fundamentally change how we look at major problems. In the case of infectious disease, AIDS has been a problem that has been challenging and for which there has been modest success in spite of enormous investment of fundamental research and clinical dollars. The approach that we are planning to

take at the University of Washington is to set up a special facility that can decipher in a single day the entire genome of a typical AIDS virus, which is 10,000 letters of the DNA alphabet. We will do an entire genome in a day, and in a year we could complete 200 to 300 genomes. With this complete genome analysis, we can begin to ask fundamentally different questions that relate to the unique epidemiology and medical responses of the AIDS virus. How does the whole AIDS virus change with drug resistance? The structural genes — some studies have been made there — but the regulatory genes will be incredibly important to analyze. How does it change with regard to vaccine resistance? What is the nature of the AIDS virus and how it changes throughout the course of an infection, which goes from latent to more blatant and finally to extremely progressive forms? The AIDS virus is a quasi species. The AIDS virus in every individual represents many different genomes. It can represent differences of 4% to 6%. So, how do you analyze that kind of complexity? We can do it with the kind of sequence techniques we have developed here. And there are other fascinating questions. There is a group of homosexuals in Australia that has been infected for 13 years now with the AIDS virus and never moved to frank disease. What is different about that AIDS virus? Or why is it that some mothers can transmit AIDS to their offspring and do so inevitably, whereas others never do so? I think this kind of one-dimensional analysis of the AIDS virus genomes will fundamentally revolutionize how you can approach AIDS analysis.

We also have the capacity to take an entirely new approach to solid tumor analysis. The difficulty with most solid tumors, be they prostate, breast, lung, ovarian, or many of the tumors that you have to deal with, is that in each case the tissues in which the tumors arise represent biologically complex tissues, and to date, we have no good ways of dissecting the nature of that biological complexity. By analyzing these little bits of information that are translated into messenger RNA, we can take a particular tissue such as the prostate, analyze 2,000 of these units of information, and then map them against a series of 20 to 30 different tumors that arise spontaneously in that tissue to see which are expressed in which tumors. From that information we can construct a lineage analysis that tells us about the nature of complexity that arises in that particular tissue, and at the same time it will give us markers for each of the different cell types. With these markers we can make correlations from benign to malignant. With these markers we have fundamental therapeutic tools using these techniques of protein engineering that I discussed earlier to design effective new types of therapeutic reagents. By being able to carry out this analysis of the bits of information present in a tissue, to map it against tumors, to construct a lineage analysis and then to map that against a clinical course of tumors, we will be in the capacity to generate a whole new array of diagnostic markers for solid tumors and therapeutic tools for their attack.

Now, genetic diseases, of course, represent a particularly interesting area, and as one knows, genes may be normal, or they may have the ability to cause frank disease, or they may have the ability to predispose to disease. The interesting thing is you can have one defect on the chromosomes, one from the mother and one from the father, that causes a disease, or you can need two defects in order to get the disease. These are dominant and recessive diseases, effectively. So, a change can either cause a disease or it can predispose to a disease. Here you need something in the environment to trigger the disease. The Human Genome Project has given us some beautiful examples of these genes. They fall into two interesting categories. The gene for cystic fibrosis has been mapped. We can do diagnostic analyses and say whether you are likely to get cystic fibrosis. But what we do not have the capacity to do yet is anything from the therapeutic point of view. Whereas for the second category of genes that have been isolated — the colon cancer gene is a representative example — we do have preventive measures. There is a colon cancer gene, isolated about 6 months ago, that causes about 10% of colon cancers. If you have one copy of that gene, you have a 90% chance of getting colon cancer at 50 but, if you start annual colonoscopy at age 25 or so, you have a better than 95% chance of catching these tumors at a premalignant state. Here we can make the diagnosis, and we can suggest a therapeutic or preventive alternative. More and more genes are going to be falling into this particular category.

The other thing that one can say about the analysis of genes and disease is that in most cases there are a multiplicity of genes that cause disease. Our own particular interest is in the case of autoimmunity where, as you know, the immune system recognizes some self component like the myelin sheath and it makes T-helper cells that can mediate an immune attack against that myelin sheath. The T-helper cells represent a unique bottleneck in this whole process, and they are the specific target that we are going to approach for dealing in the future with autoimmune diseases, because each type of T cell has a unique molecular address called its T-cell receptor. When you initiate the autoimmune disease, the T-helper cells that start the process are very simple and have relatively few of these molecular addresses. For ex-

ample, in mouse autoimmune disease we have been able to model autoimmune diseases that resemble multiple sclerosis, in that there are two addresses. If we make antibodies against each of the T-cell receptor addresses and remove these cells prior to the initiation of disease, we prevent the disease at the 100% level. Or we can let mice get active multiple sclerosis–like disease, and we can reverse it with these antibodies. Of course, that is the kind of strategy that we would like to apply to humans. To do it we have carried out genetic mapping studies on one of the gene families that encodes the addresses that make these T-cell receptors. We, indeed, have localized for a small subset of patients a particular region within which must reside a gene that causes or predisposes to multiple sclerosis. And, indeed, it is not one gene, but we have been able to show now that three distinct immune receptor genes cause the disease. What is more important to understand is that any particular kind of autoimmune disease is not one disease but it will really be 10 or 15 or 20 diseases. So, multiple sclerosis will be 15 different diseases whose subcategorization, whose stratification, can be carried out by genome-wide genetic analyses. So what we will do in the future is determine what type of multiple sclerosis you have, and each therapeutic address or target will be directed then toward its specific subtype of disease. We know now that this almost certainly will be true for all autoimmune diseases. The basic idea is to design therapeutic reagents that can attack these specific addresses uniquely so we can have in a bottle reagents for 100 specific addresses that can delete any fraction of the immune system that we wish. This will give us the tools to deal with autoimmunity, transplantation rejection, allergy and hypersensitivity — those diseases that deal with immune abnormalities. In the future we will be able to clonally expand specific T cells using exactly the same strategy to deal with cancer, infectious disease, or an entirely new approach to making vaccines.

The point that emerges from this type of analysis is really quite an intriguing one. That is the idea that most diseases we are interested in are going to be encoded by a multiplicity of diseases, and of course what that leads us to, then, is the really exciting possibility. In the future we will have identified genes that predispose to most common medical diseases, and we will be able to carry out a DNA fingerprint analysis for each individual at the age of consent and be able to computationally identify the diseases to which the individual is predisposed — more particularly, the nature of the genetic defect that carries out that predisposition. We will be able to prescribe preventive measures.

This is where we move to the idea of manipulation of biological information for the good of medicine. All of these types of manipulation — and they are of the one-dimensional, the three-dimensional, the complex systems, and the network types — are the basic strategies that are now being applied by a generation of genetic engineering companies that will specialize in the ability to use applied molecular evolution of a whole series of different techniques. These are going to be the substrate from which we will model the preventive therapies of the future. This capacity raises interesting questions that society must worry about. Scientists put human genes in mice, and here are a couple of mice sticking up some humans. The really interesting question that raises is the question of individual responsibility, for, in fact, if your genes can control your behavior and, more specifically, can control a social behavior, a fascinating question is to what extent are you responsible for that behavior. This runs square into the judicial system and Hume's idea of individual responsibility. This is going to be an issue of enormous debate in the future. Humans will be able to engineer themselves, will be able to modify themselves in fantastic ways. This is not going to be in 5 years or 10 years. This is in 25 or 50 years. But there is no doubt that we will be able to engineer ourselves. To what end should that engineering be focused? What are the limits? Many citizens are worried about the new genetics and the forbidden knowledge it is revealing. Should there be limits to what we can do? And how should we prescribe these limits? These are all questions I would argue are of fundamental importance.

What I would like to do is close just by giving you an idea of some of the changes that we are really pushing at the University of Washington and point out how they are going apply in a very fundamental way to the whole field of medicine as we move into the next century. We moved to the University of Washington with really two ideas in mind. One, we would like to do research in a different way using powerful new interdisciplinary approaches. Two, we have the feeling that the nature of the responsibility of scientists and physicians to society has changed in fundamental ways just in the last 5 years. Let me talk about each of these in turn. With regard to interdisciplinary opportunities, if we are to solve the problem of biological complexity, we need to use math, physics, chemistry, computer science, and engineering. Since the practitioners of those arts speak a language very different from that of medicine or biology, how do we communicate and effectively collaborate? I think we do it through students. We are setting up a dual-mentored program — a mentor from our department and from computer science — where a student

can take a leading-edge biological problem and apply computational tools to it. In doing so, the student will be a medium of communication between the mentor in biology and the mentor in computer science, and at the same time, the student will be the mechanism by which the powerful technologies of these disciplines come to focus on biology. I would argue that in medicine the same kinds of things are going to be required. Think again about what your jobs will be if this kind of preventive medicine and the ability to manipulate biological information comes to the fore.

Finally, I would just like to point out that although the Genome Project gives us the ability to handle enormous complications — and this is a lineage diagram of a worm that has 1,000 cells or so — we still have major obligations to society. It is our contention that scientists and physicians should be spending 5% to 10% of their time bringing science to society and dealing with the many complex issues that society has to deal with. In that regard, the most effective way we found to do this is through outreach programs, and our department has set up a series of 12 outreach programs of hands-on science focused at teachers. To give you a sense of that, we are bringing to high school biology students the capacity to sequence the human genome. We figured out how to let them do this in biology classrooms in the high schools. The excitement of being able to do that is that so little of the human genome has been analyzed, they are creating real information that can be used by scientists. At the same time, they discuss biological issues. The final issue I would point out is how do we go from a worm, the wiry diagram here, to a human with 10^{14} cells and an incredibly complex array of events that lead to a final human organism? I hope I have given you in this lecture the idea that the powerful techniques that are arising from genomics are going to be the tools by which we can attack biological complexity. They are the tools that will revolutionize medicine, and I think the question we can all ask ourselves is, What will our role be in 25 years?

Dr Bailey: Dr Hood, on behalf of the American Laryngological Association, I would like to present you with this diploma in recognition of your outstanding contributions to the art and science of laryngology and rhinology, and I know that somewhere Daniel Baker is smiling to see this glimpse of the future. Thank you for being our guest.

DYNAMIC PROPERTIES OF THE POSTERIOR CRICOARYTENOID MUSCLE

DONALD S. COOPER, PHD
LOS ANGELES, CALIFORNIA

MAISIE SHINDO, MD
LOS ANGELES, CALIFORNIA

UTTAM SINHA, MD
LOS ANGELES, CALIFORNIA

MALCOLM H. HAST, PHD
CHICAGO, ILLINOIS

DALE H. RICE, MD
LOS ANGELES, CALIFORNIA

The aim of this research was to investigate the contractile properties of the posterior cricoarytenoid (PCA) muscle. Simultaneous measurements were made of the isometric force, temperature, and electromyographic activity of the dorsal cricoarytenoid muscle of anesthetized dogs during supramaximal stimulation of the recurrent laryngeal nerve for twitch and tetanic contraction. The conduction delay between stimulation of the recurrent nerve at the level of the larynx and the onset of the muscle action potential averaged 2.0 ± 0.2 milliseconds (ms), and the latent period between the onset of electrical activity of the muscle and the onset of contraction had a mean duration of 3.3 ± 0.8 ms. The mean of isometric contraction times found was 33.3 ± 2.0 ms, shorter than most previous studies of canine PCA muscle. Tetanic frequency defined as smooth contraction was higher than previous estimates. Considerations of scaling of physiological time based on animal mass were applied to analysis of the experimental findings to make possible systematic comparison of previous findings across species and animal size.

KEY WORDS — larynx, physiological scaling, posterior cricoarytenoid muscle.

The posterior cricoarytenoid (PCA) muscle, described by Hast[1] as the respiratory muscle of the larynx, is unique both in its importance for life and in the difficulty of its physiological study for muscle mechanics, because of its position in the neck. One of the few advantages in the physiological study of this muscle is that as Némai[2] indicated, it is one of the most constant laryngeal muscles across mammalian species in terms of both anatomy and function, so that animal models can be used. We have focused on findings from the dorsal cricoarytenoid muscle of the dog as a physiological model; by custom, this muscle in the animal model will be referred to here as the PCA muscle.

Réthi[3,4] provided the first estimates of the strength of the canine PCA muscle in tetanic contraction in 1897: 115 and 70 g. Although the mechanical situations of measurement were rather different, these values compare reasonably with the value found by Hast[1] of 79 g for tetanic contraction at resting length. For reasons that will be clarified later, it is important to compare the dynamic properties of the PCA muscle with those of the other slower laryngeal muscle, the cricothyroid (CT). Important findings were reported by Mårtensson and Skoglund[5] as part of an extensive study including a number of animal species and all laryngeal muscles: the canine PCA muscle was found to have a mean contraction time of 30 milliseconds (ms) (range, 25 to 35), compared to 35 ms (range, 30 to 40) for the CT muscle. In Hast's own studies, the canine PCA muscle was found to have a mean contraction time of 44.4 ms,[1] compared to 39 ms for the CT muscle.[6] Also in dogs, Sato and Hisa[7] found contraction times of 38 ms for the CT muscle and 42 ms for the PCA muscle. These findings should be compared to those for the cat: Hirose et al[8] found a contraction time of 22 ms for the cat PCA muscle and 44 ms for the cat CT muscle. In an in vitro study of rat laryngeal muscles, Hinrichsen and Dulhunty[9] found mean contraction times of 3.35 ms for the PCA muscle and 7.2 ms for the CT muscle. A puzzle emerges from these findings: Mårtensson and Skoglund's[5] findings for the dog and cat agree across

From the Department of Otolaryngology–Head and Neck Surgery, University of Southern California School of Medicine, Los Angeles, California (Cooper, Shindo, Sinha, Rice), and the Department of Otolaryngology–Head and Neck Surgery, Northwestern University, Chicago, Illinois (Hast).
This research was supported by grant DC01158-03 from the National Institutes of Health/National Institute on Deafness and Other Communication Disorders. Pilot research on laryngeal intramuscular fluid pressures was supported by the Voice Foundation. This study was performed in accordance with the PHS Policy on Humane Care and Use of Laboratory Animals, the NIH *Guide for the Care and Use of Laboratory Animals*, and the Animal Welfare Act (7 U.S.C. et seq.); the animal use protocol was approved by the Institutional Animal Care and Use Committee (IACUC) of the University of Southern California.

Presented at the meeting of the American Laryngological Association, Palm Beach, Florida, May 7-8, 1994.

REPRINTS — Donald S. Cooper, PhD, Laboratory for Laryngeal Physiology, Hoffman 903, 2025 Zonal Ave, Los Angeles, CA 90033.

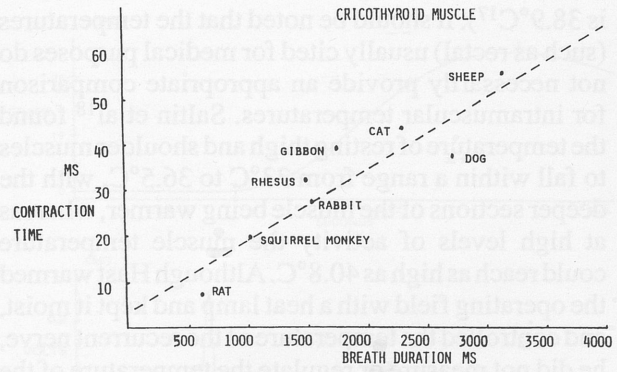

Fig 1. Mean twitch contraction time in milliseconds (ms) for cricothyroid muscle of indicated species (based on references 1, 5-9, 14, 15) is plotted as function of duration of respiratory cycle for that species in seconds. Interrupted line is based on linear regression for which each species is taken as single value.

species with those of Hirose et al[8] for the cat and of Hinrichsen and Dulhunty[9] for the rat in that the CT muscle was found to be slower than the PCA, while Hast[1,6] and Sato and Hisa[7] found the reverse.

It may be asked how systematic comparison of muscle speeds can be made across mammalian species. Although cats and rats are no more dogs than apples are oranges, they resemble them and each other more in terms of their common mammalian heritage than they differ. On the basis of the published findings for the dynamic properties of laryngeal muscles in species studied so far, it appears that the contraction time of a given laryngeal muscle constitutes a fraction of the duration of the respiratory cycle; this fraction is constant across species. The duration of the respiratory cycle, in turn, is a simple exponential function of animal mass. This finding builds on earlier research of Hill,[10] Stahl,[11] McMahon,[12] and Peters[13] on physiological scaling. Thus, if the scale of the animal is normalized, it appears that both contraction times for given laryngeal muscles and the breath duration are approximately constant across the mammalian species studied so far. The use of breath duration rather than other alternatives such as heart rate as a representative of the scale of physiological time has the advantage of a close link with the respiratory function of the larynx and its muscles.

The laryngeal muscle for which the most physiological data are available is the CT. Some variability in findings will inevitably result from differences in anesthesia, methods of force transduction, variation of animal size within species, etc. Nevertheless, Fig 1[1,5-9,14,15] illustrates a clear relationship between contraction time and breath duration. Since the descriptive statistics from many of the studies are incomplete, the regression line was constructed by taking the result of each study as a single point[1,5-9,14,15]; where several estimates for a given species were available, they were averaged with equal weight. Far fewer, and divergent, physiological data are available for the PCA muscle. Given the cross-species constancy of PCA anatomy and function noted above, the preceding paragraphs suggest that the reasons for the divergence of physiological findings within one species should be examined carefully.

Our laboratory has undertaken a general study of the relation between intramuscular fluid pressures in laryngeal muscles and the force that they produce, the first results of which were exemplified on the canine thyroarytenoid muscle.[16] In applying these techniques to the PCA muscle because of its special significance as the respiratory muscle of the larynx, it has been necessary to address the issue of the normal contractile properties of the PCA muscle as part of the development of experimental procedures.

METHODS

As indicated above, the position of the PCA muscle in the neck makes its study difficult. The starting point for our experimental work was the procedure developed by Hast[1] for the study of the dynamic contractile properties of the dorsal cricoarytenoid muscle of the dog as a model for physiological study of the PCA muscle. Hast's description of procedures was initially followed and is drawn on below. The methods used were approved by the University of Southern California Institutional Animal Care and Use Committee.

After premedication with atropine sulfate, ketamine hydrochloride, and acepromazine maleate, general anesthesia was induced with pentobarbital sodium, with the animal in a supine position on the operating table. After the anterior neck and upper chest were shaved, prepared, and draped, a midline vertical incision was made from the hyoid bone to a point near the sternum. A tracheostomy was performed, the animal was intubated, and assisted ventilation was begun and continued throughout the experiment. Heart activity was monitored continuously by an electrocardiograph or a pulse oximeter. Anesthesia was increased as necessary. After excision of the thyrohyoid muscle, the thyroid attachment of the inferior pharyngeal constrictor, and the middle and lateral thyrohyoid ligaments, the larynx was dissected free from the pharynx. The larynx was lifted out of the neck and retracted caudally so that the dorsal aspect of the larynx was accessible.

All attachments except the PCA muscle were dissected away from the arytenoid cartilage on the side to be studied; then a Teflon-coated polyester 2-0 suture was attached between the arytenoid cartilage

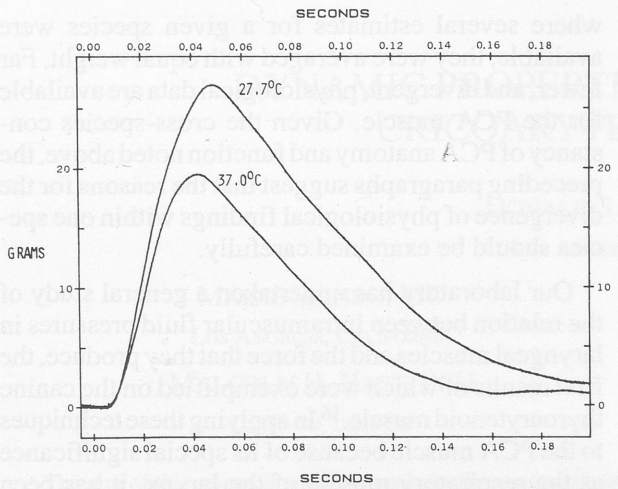

Fig 2. Posterior cricoarytenoid muscle isometric twitches from same dog at indicated temperatures as measured by intramuscular fine wire thermocouple. At lower temperature, twitch has longer contraction time and higher peak force.[20]

and the ergometer (Cambridge Technology 305B). The direction of movement of the ergometer arm and connecting suture was parallel to the direction of most PCA fibers. A heavy pin through the cricoid cartilage was used to immobilize the origin of the PCA muscle; in later experiments, two pins at 90° to one another were used for the same purpose, connected through a rigid framework to a heavy fixed base on each side of the dog in order to provide external stabilization for the preparation. Fine wire (51 μm diameter) electromyography (EMG) electrodes were inserted into the PCA muscle, and led to a differential amplifier (Data Inc, model 2124 model 2). A microwelded type T fine wire thermocouple (127 μm diameter) was slipped into the muscle so that the central intramuscular temperature of the muscle could be continuously monitored. The PCA muscle was activated by supramaximal twitch or tetanic stimulation of the recurrent nerve from a constant-current unit (Grass SIU7) controlled by a stimulator (Grass S-88) on the side studied. Force, (at times) intramuscular fluid pressure and muscle length, and EMG analog signals were digitized by a computer with 14-bit resolution in each channel, and recorded at 10,000 data points per second, and intramuscular temperature was displayed by a Fluke Hydra 2620A system.

Initial Results and Temperature Considerations. An important question arose in terms of the temperature conditions with Hast's technique: even with blood flow preserved and a nearby lamp used as a source of heat, the resting intramuscular temperatures of the PCA muscle measured with intramuscular fine wire thermocouples were well below those expected for the dog (canine mean rectal temperature is 38.9°C[17]). It should be noted that the temperatures (such as rectal) usually cited for medical purposes do not necessarily provide an appropriate comparison for intramuscular temperatures. Saltin et al[18] found the temperature of resting thigh and shoulder muscles to fall within a range from 33°C to 36.5°C, with the deeper sections of the muscle being warmer, whereas at high levels of activity the muscle temperature could reach as high as 40.8°C. Although Hast warmed the operating field with a heat lamp and kept it moist, and controlled the temperature of the recurrent nerve, he did not measure or regulate the temperature of the muscle studied. Since the dynamic characteristics of muscle are partly determined by temperature, exposure of the larynx in Hast's procedure probably produced cooling that would bias values of the dynamic constants in several respects (longer twitch contraction times, lower tetanic frequencies).[19,20]

An alteration of Hast's earlier procedure was made on the recommendation of its author, by only separating the larynx sufficiently from its rostral attachments to make it possible for it to be elevated within the neck sufficiently to provide access to the PCA muscle for the measurements described above. Initial use of a small heating lamp, a procedure used by Mårtensson and Skoglund,[5] was abandoned because of its drying effects; during the experiments described here the muscle was bathed continually with heated physiological saline solution in order to heat it. Measurements were made with muscle tissue at temperatures over a range from about 37°C to 39°C as measured by an intramuscular fine wire thermocouple. The exposed recurrent laryngeal nerve was covered with mineral oil to avoid drying. Figure 2[20] illustrates PCA twitches observed at the indicated temperatures in the same muscle. In this and subsequent Figures, time zero marks the time of stimulation of the recurrent nerve, and initial passive tension is treated as zero. All data illustrated were collected at physiological temperatures by the procedure discussed above.

RESULTS

With some variation of usage, the interval between the initiation of nerve-muscle excitation and the onset of contraction is known as the latent period.[20] In this study, the first part of this period, the time after nerve stimulation for conduction of the action potential along the nerve, time for synaptic transmission at the motor end plate, and time for propagation of the muscle action potential to the electrodes, shall be termed a conduction delay (Fig 3). The time between the onset of the muscle action potential and the onset of contraction is used here as the definition of latent period, as in Hirose et al.[8] In practice, a stimulus

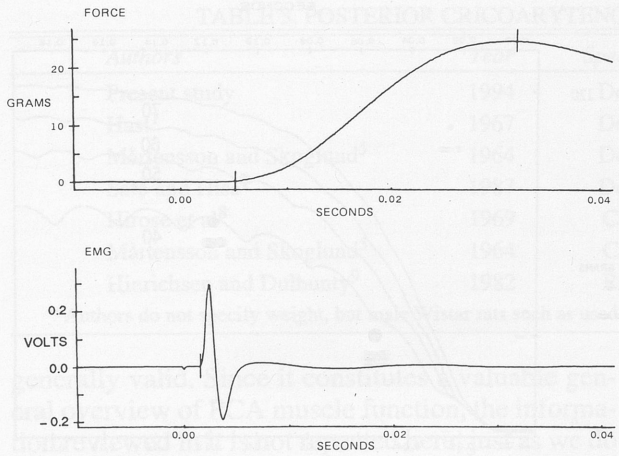

Fig 3. Electromyography (EMG) and force records from canine posterior cricoarytenoid muscle in isometric twitch. In force record, mean resting force level and its variability are determined on basis of ordinate values from record beginning up to trigger point time zero (5 milliseconds), at which recurrent laryngeal nerve is stimulated. In EMG record, small stimulus artifact follows time zero, and conduction delay is measured from time zero to onset of muscle action potential (vertical line). Latent period extends between onset of muscle action potential to earlier vertical line in force record, which indicates onset of contraction. Contraction time extends from earlier vertical line in force record to later line indicating peak twitch force.

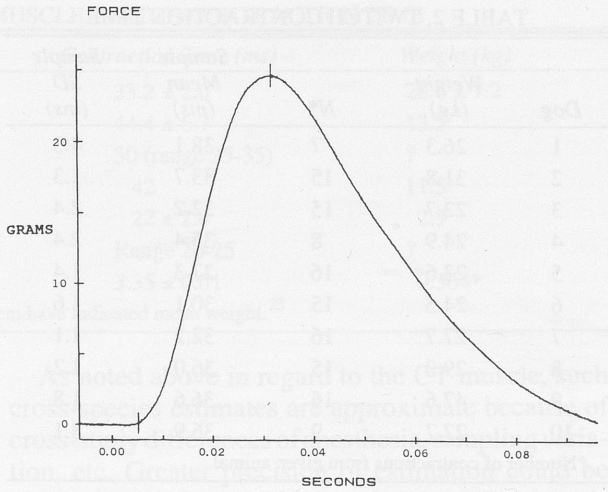

Fig 4. Plot of whole of isometric twitch illustrated in Fig 3, with vertical lines indicating onset and peak of contraction.

artifact is often observable in the EMG record; however, this usually is clearly distinguishable from the action potential, the onset of which was used as the reference marker in this study. In a number of animals, EMG recordings were made during the onsets of a series of muscle contractions without any pressure transducer inserted into the muscle. A weighted mean based on 203 contractions from 8 animals provides an approximate conduction delay of 2.0 ms between stimulation of the recurrent nerve at the level of the larynx, and the onset of the muscle action potential. Although this quantity is not rigorously defined, because the distance through which the action potential is propagated is slightly variable across animals, it is fairly consistent: the estimated SD for the pooled data is 0.2 ms. Similarly weighted, the latent period for the canine PCA muscle has a mean value across animals of 3.3 ms, with an estimated SD for the pooled data of 0.8 ms (Table 1). The only comparable earlier value is that of Hirose et al[8] for the cat PCA muscle, of a mean 7 ms. This divergence is likely to be attributable partly to differences in system frequency response and partly to slight differences in the definition of the onset of contraction. In the present study, all determinations of intervals were made from the numeric data rather than from plots.

TABLE 1. POSTERIOR CRICOARYTENOID MUSCLE LATENCY AND CONDUCTION DELAY

		Latency		*Conduction Delay*	
Dog	*N**	*Sample Mean (ms)*	*Sample SD (ms)*	*Sample Mean (ms)*	*Sample SD (ms)*
1	24	3.4	1.16	2.2	0.25
2	18	4.7	0.97	2.2	0.33
3	23	2.9	0.92	2.2	0.14
4	23	3.4	0.50	1.8	0.08
5	31	3.0	0.74	2.0	0.34
6	30	2.6	0.47	2.1	0.16
7	29	3.8	1.07	1.8	0.18
8	25	3.2	0.75	2.0	0.19

*Number of contractions from given animal.

Twitch contraction time was measured in three steps in the present study (Figs 3 and 4). First, the mean and SD of the resting force level of the muscle, usually during the 5 ms prior to stimulation, were calculated. Second, by proceeding down the ascending side of the twitch from later to earlier points, the onset of contraction was defined as the lowest force value in this series just exceeding the previous mean. In most cases, this was close to the first data point that fell within 1 SD of the values of resting force. Third, twitch contraction time was defined as the interval between the onset of contraction thus defined and the peak of isometric contraction force. With rare exceptions,[21] it has been usual in studies of laryngeal muscle to measure the interval between the onset of contraction and its peak as the contraction time. An alternative definition is to measure from the time of stimulation to the peak of twitch contraction force, which includes both the conduction delay and the latent period. This definition is also accepted[22]; there is a problem only when findings specified in terms of one definition are compared directly with findings in

TABLE 2. TWITCH CONTRACTION TIME

Dog	Weight (kg)	N*	Sample Mean (ms)	Sample SD (ms)
1	26.3	7	38.1	4.3
2	31.8	15	33.7	1.3
3	22.7	15	32.2	2.4
4	24.9	8	35.4	2.4
5	23.6	16	27.3	1.4
6	24.5	15	30.1	1.6
7	27.7	16	32.2	1.1
8	29.0	15	36.0	1.2
9	47.6	16	36.6	1.8
10	27.7	9	36.9	3.1

*Number of contractions from given animal.

terms of another without consideration of the duration of the early stages of nerve and muscle excitation, as we have noted elsewhere.[23]

In a series of 132 isometric twitches studied from 10 dogs, we found a mean contraction time of 33.2 ms under conditions in which the pressure transducer was not present in the muscle (Table 2). This number is a grand mean weighted according to the number of twitches studied from each animal. The estimated SD for the pooled data was 2.0 ms. Since different numbers of twitches were recorded in different animals, if the grand mean were to be determined by weighting the mean from each animal equally, the overall mean would be 33.8 ms. Figure 4 illustrates a characteristic twitch from our data.

Tetanic or fusion frequencies are not as clearly defined as are twitch characteristics. Since tetanic frequency is defined in terms of smoothness of response to rapid repeated supramaximal stimulation, findings from some earlier studies may be affected by the limited frequency response of pen-writers used for recording purposes. Hast[1] found a fusion frequency of 31 pulses per second, while Sato and Hisa[7] found a fusion frequency of 45 pulses per second. Figure 5 illustrates the variation of response for the canine PCA muscle in a series of onsets of responses to rapid stimulation, at 40, 50, 60, and 70 stimulations per second, without any intervening adjustment of muscle length or passive tension. The initial levels of passive tension were similar. In these data, the record for 40 pulses per second clearly is not yet tetanic. At what rate of activation the response becomes sufficiently smooth must be a matter for precise definition, but in these data it could not be before 60 pulses per second. A more precise definition of tetanic frequency could be given, for instance in terms of a coefficient of variation, as the frequency at which the RMS (time-varying root mean square) value of response is no more than a specified fraction of the DC

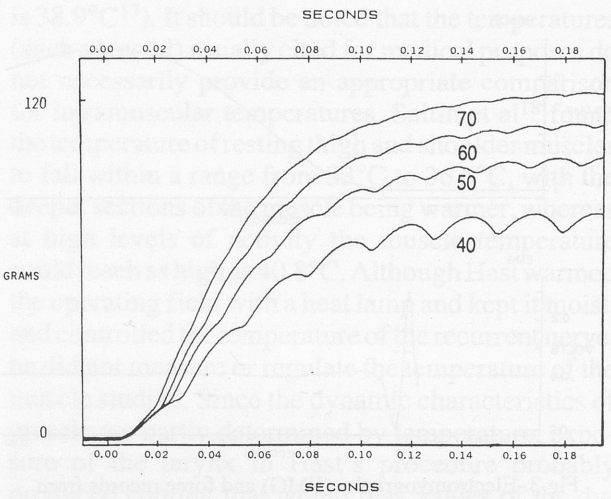

Fig 5. Superimposed onsets of tetanic contractions at 40, 50, 60, and 70 stimulations per second. Resting forces, approximately equal, are set to zero so that only force rise is shown.

(mean) value of that response; a series of such RMS/DC quotients as a function of stimulation rate could characterize the response of the muscle to rapid stimulation. Since no such definition is accepted, we do not give any extended analysis in terms of it.

DISCUSSION

First, it will be useful to discuss the relation of the present findings to those of the most detailed study of canine PCA contraction by Hast.[1] In part of our experiments, we have observed the effect of temperature on the twitch properties of the PCA muscle by varying muscle temperature systematically, and found on the average the observed lowering of temperature would result in a lengthening of contraction times by 2 to 3 ms, but not enough to account for the whole difference. A procedural specific may account for a larger effect: Hast maintained the muscle at its in situ length, and our findings indicate that PCA contraction time at low levels of length and tension may be 3 to 8 ms longer than at higher levels of resting tension, although this was not general. Our own figure is an average of contraction times over a range of passive muscle tensions from about 8 to 125 g; the details of length-tension effects will be considered elsewhere. Part of the difference may also be attributed to the effects of various aspects of the measurement system response. Although the effects of controlled temperature variation on the contractile properties of muscle are well known and can be treated as a simple scaling problem, it is more difficult to assess the effect of these technical factors retrospectively. Nevertheless, if the detailed findings are scaled upward slightly in terms of the estimate of the speed of PCA contraction, the content of Hast's article is still

TABLE 3. POSTERIOR CRICOARYTENOID MUSCLE TWITCH CONTRACTION TIME

Authors	*Year*	*Species*	*Contraction Time (ms)*	*Weight (kg)*
Present study	1994	Dog	33.2 ± 2.0	28.6 ± 7.2
Hast[1]	1967	Dog	44.4 ± 6.7	13.5
Mårtensson and Skoglund[5]	1964	Dog	30 (range 25-35)	?
Sato and Hisa[7]	1987	Dog	42	11.5
Hirose et al[8]	1969	Cat	22 ± 2.4	2.9
Mårtensson and Skoglund[5]	1964	Cat	Range 20-25	?
Hinrichsen and Dulhunty[9]	1982	Rat	3.35 ± 0.01	0.364*

*Authors do not specify weight, but male Wistar rats such as used by them have indicated mean weight.[25]

generally valid. Since it constitutes a valuable general overview of PCA muscle function, the information reviewed in it is not repeated here, just as we do not repeat the more detailed consideration of PCA metabolism in the context of general laryngeal muscle metabolism given elsewhere by Cooper et al.[24]

In regard to a different type of scaling problem, the values of physiological measures found in the present study should not be compared directly with previous findings, because of the different sizes (weights) of the animals used. Unfortunately, Mårtensson and Skoglund[5] do not specify the size of the animals they used. For other studies, Table 3[1,5,7-9,25] summarizes the relation between mean PCA contraction times and weights of experimental animals of all species studied so far.

The range of animal size studied for the CT muscle permits some confidence in the general character of the relation between contraction times and duration of the respiratory cycle displayed in Fig 1. More reserve must be retained in making similar estimates of the relation for the PCA muscle. Published information on the duration of the respiratory cycle in animals of varied species and size[25,26] can be combined with the values from rat and cat to estimate contraction times for the dog PCA muscle on the basis of the duration of the canine respiratory cycle. Both quantities are scaled in terms of physiological time, so the ratio of the duration of the respiratory cycle of an experimental animal to that of a reference animal is expected to be equal to the ratio of the respective contraction times of the laryngeal muscle in question. If the values for cat and rat are taken as the basis, this procedure suggests a contraction time for the dog close to that found by Mårtensson and Skoglund,[5] shorter than observed by Hast[1] and by Sato and Hisa.[7] Whether the agreement of this value with that found by Mårtensson and Skoglund is fortuitous cannot be determined because of lack of information on the weights of their animals. It must remain uncertain whether the disagreement with the findings of Sato and Hisa rests on technical or physiological factors.

As noted above in regard to the CT muscle, such cross-species estimates are approximate because of cross-study differences of anesthesia, sampling variation, etc. Greater precision of estimation could be obtained if the available data for the PCA muscle were expanded to include data from the range of animal sizes available for the CT muscle. On the other hand, if the canine PCA contraction times obtained in the present study are compared with published values for the contraction time of the CT muscle, they remove the cross-species incongruity noted in the beginning of this paper; that is, the present results agree with those of Mårtensson and Skoglund[5] in predicting that the CT muscle would be slower than the PCA for dogs, as for cats and rats. We plan to measure the dynamic properties of both muscles in the same dog to clarify this point.

Besides providing fresh estimates of the contractile properties of the respiratory muscle of the larynx, the present study has introduced a procedure that makes it possible to compare the dynamic properties of laryngeal muscles across species, on the basis of the mass of the animals concerned. Figure 1 above, from the CT muscle, suggests a general consistency across species such that in comparing data on contractile properties across species one can reason in terms of the general design parameters for the mammalian larynx. Such reasoning will not always suffice; for instance, in humans the glottis is actively widened for each cycle of rest breathing, while in cows it continually stands much more open for rest breathing, and the PCA muscle is activated only occasionally for exceptional degrees of opening, at times of increased oxygen requirement.[27] However, the respiratory activity of the PCA muscle in humans matches the general mammalian pattern, while that for cows stands apart from this pattern.

If we follow the same logic, Fig 1 suggests that it would be possible to estimate values for human CT muscle contraction time simply by entering a value for the duration of the human respiratory cycle and following the regression line; an analogous procedure might be followed for any laryngeal muscle for

which a regression equation could be established. Even overlooking possible effects of the addition of the requirements of human speech to laryngeal involvement in respiration and deglutition, a complication for this reasoning arises from evolutionary changes in proportions reflected in the dimensions of the structures of the erect primate. The larynx of a gibbon or large dog is in fact nearly as large as that of a human, although the whole animal weights are not proportionate. Functional differences resulting from such factors as the descent of the larynx in humans also may enter into play.

Available estimates of the contraction speed of laryngeal muscles in humans are based either on a direct transposition of values for dogs into application to humans, as suggested by some investigators (discussion following Cooper et al[24]), or on a variety of indirect measurements, the results of which have often been inconsistent. The present investigation of the contractile properties of the canine PCA muscle was carried out as part of a more extensive study of the properties of intramuscular fluid pressure as a direct measurement of the mechanical activity of laryngeal muscles. This measurement has the potential to provide more direct measurements of the mechanical activity of laryngeal muscles so that with improved miniaturization of the transducers, an empirical test of such estimates of the dynamic properties of human laryngeal muscles is foreseeable.

In its most general interpretation, Fig 1 suggests that an attainable objective of studies in laryngeal physiology is to generalize to the design parameters of the mammalian larynx based on comparative data, in such a way that evolutionary specializations stand out, for instance as deviations from the rectilinear graph. The results of the present study add to this perspective the consideration that comparison of the dynamic characteristics of laryngeal muscles, and probably many other physiological quantities, whether across species or even across studies of the same species, is complicated by the systematic variation of their behavior as a function of their physiological conditions, so that what is compared often cannot be simple numbers, but has to be a function of several variables, which often can be represented as multidimensional solids.[24]

ACKNOWLEDGMENT — The assistance of Jozsef Földi, research coordinator of the Department of Surgery, University of Southern California, and the use of the laboratory of the Department of Surgery are gratefully acknowledged.

REFERENCES

1. Hast MH. The respiratory muscle of the larynx. Ann Otol Rhinol Laryngol 1967;76:489-97.

2. Némai J. Vergleichend-anatomische Studien am Kehlkopf der Säugetiere. Arch Laryngol Rhinol (Berl) 1912;26:451-508.

3. Réthi L. Vocal cord tension tested experimentally. J Voice 1991;5:360-3. (Translation of Die Stimmbandspannung, experimentell geprüft, by Donald S. Cooper from the Sitzungsberiche der kaiserlichen Akademie der Wissenschaften. Mathematisch-naturwissenschaftliche Classe. Vienna 1897, CVI Band, VI Heft, Abtheilung III: 244-252.)

4. Cooper DS. Leopold Réthi and laryngeal muscle mechanics. J Voice 1991;5:354-9.

5. Mårtensson A, Skoglund CR. Contraction properties of intrinsic laryngeal muscles. Acta Physiol Scand 1964;60:318-36.

6. Hast MH. Mechanical properties of the cricothyroid muscle. Laryngoscope 1966;76:537-48.

7. Sato F, Hisa Y. Mechanical properties of the intrinsic laryngeal muscles and biomechanics of the glottis in dogs. In: Hirano M, Kirchner JA, Bless DM, eds. Neurolaryngology: recent advances. Boston, Mass: College Hill, 1987:97-106.

8. Hirose H, Ushijima T, Kobayashi T, Sawashima M. An experimental study of the contraction properties of the laryngeal muscles in the cat. Ann Otol Rhinol Laryngol 1969;78:297-306.

9. Hinrichsen C, Dulhunty A. The contractile properties, histochemistry, ultrastructure and electrophysiology of the cricothyroid and posterior cricoarytenoid muscles in the rat. J Muscle Res Cell Motil 1982;3:169-90.

10. Hill AV. The dimensions of animals and their muscle mechanics. In: Proceedings of the Royal Institution of Great Britain. Vol 34. London, England, 1950:450-71.

11. Stahl WR. Scaling respiratory variables in mammals. J Appl Physiol 1967;22:453-60.

12. McMahon TA. Scaling physiological time. In: Oster GF, ed. Some mathematical questions in biology. Providence, RI: American Mathematical Society, 1980:131-63. (Lectures on mathematics in the life sciences; vol 13.)

13. Peters RH. The ecological implications of body size. Cambridge, England: Cambridge University Press, 1983.

14. Hall-Craggs EC. The contraction times and enzyme activity of two rabbit laryngeal muscles. J Anat 1968;102:241-55.

15. Hast MH. The primate larynx. Acta Otolaryngol (Stockh) 1969;67:84-92.

16. Cooper DS, Pinczower E, Rice DH. Thyroarytenoid intramuscular pressures. Ann Otol Rhinol Laryngol 1993;102:167-75.

17. Dukes HH. Dukes' physiology of domestic animals. Swenson MJ, ed. Ithaca, NY: Comstock Publishing Associates, 1977.

18. Saltin B, Gagge AP, Stolwijk JAJ. Muscle temperature during submaximal exercise in man. J Appl Physiol 1968;25:679-88.

19. Partridge LD, Benton LA. Muscle the motor. In: Brooks VB, ed. Motor control. Part 1. Bethesda, Md: American Physiological Society, 1981:43-106. (Handbook of physiology; section 1. The nervous system; vol 2.)

20. Reichel H. Muskelphysiologie. Berlin, Germany: Springer, 1960.

21. Alipour-Haghighi F, Titze IR, Durham P. Twitch response in the canine vocalis muscle. J Speech Hear Res 1987;30:290-4.

22. Burke RE. Motor units: anatomy, physiology, and functional organization. In: Brooks VB, ed. Motor control. Part 1. Bethesda, Md: American Physiological Society, 1981:345-422. (Handbook of physiology; section 1. The nervous system; vol 2.)

23. Rice DH, Cooper DS. Contractile properties of canine thyroarytenoid muscle reinnervated from the ansa cervicalis. Ann Otol Rhinol Laryngol 1989;98:153-6.

24. Cooper DS, Partridge LD, Alipour-Haghighi F. Muscle energetics, vocal efficiency, and laryngeal biomechanics. In: Titze IR, ed. Vocal fold physiology. San Diego, Calif: Singular Publishing Group, 1993:37-92.

25. Spector WS. Handbook of biological data. Philadelphia, Pa: WB Saunders, 1956.

26. Altman PL, Dittmer DS, eds. Biology data book. 2nd ed. Vol 3. Bethesda, Md: Federation of American Societies of Experimental Biology, 1974.

27. Ganz H. Vergleichende enzymatische Untersuchungen an Kehlkopfmuskeln von Mensch und Rind zur Sonderstellung des M. posticus. Arch Ohren Nasen Kehlkopfheilkd 1964;183:406-12.

MALIGNANT LARYNGEAL TUMORS IN CHILDREN: A 15-YEAR EXPERIENCE WITH FOUR PATIENTS

LAURIE A. OHLMS, MD

TREVOR MCGILL, MD GERALD B. HEALY, MD

BOSTON, MASSACHUSETTS

Malignant laryngeal neoplasms in children are uncommon and present diagnostic and therapeutic challenges. A 15-year retrospective review of laryngeal tumors at our institution identified four patients with malignant neoplasms. These children, 7 months to 16 years of age, were treated for squamous cell carcinoma, choriocarcinoma, rhabdomyosarcoma, and primitive neuroectodermal tumor. This report details these cases, emphasizing diagnostic approaches, treatment decisions (medical oncologic management, surgical resection), and rehabilitation measures for postlaryngectomy communication. A multi-institutional pediatric head and neck tumor registry would be a useful reference to assist with individual treatment decisions.

KEY WORDS — choriocarcinoma, malignancy, pediatric laryngeal tumor, primitive neuroectodermal tumor, rhabdomyosarcoma, squamous cell carcinoma.

INTRODUCTION

Malignant neoplasms of the pediatric larynx are rare. Although isolated case reports have appeared in the literature, an extensive experience with pediatric laryngeal malignancies does not exist. Because these tumors are uncommon, treatment decisions may be difficult. We report our experience with malignant laryngeal tumors in children, including diagnostic approaches, treatment decisions, and rehabilitation measures.

METHODS

A 15-year retrospective review of laryngeal tumors at Children's Hospital, Boston, identified four patients with malignant neoplasms. These children, 7 months to 16 years of age, were treated for rhabdomyosarcoma, primitive neuroectodermal tumor, squamous cell carcinoma, and metastatic choriocarcinoma. One patient (case 1) has been previously reported.[1]

CASE REPORTS

CASE 1 (RHABDOMYOSARCOMA)

This 3-year-old boy presented with a 2-week history of inspiratory stridor and difficulty swallowing. Lateral neck radiography revealed a large supraglottic mass. Direct laryngoscopy and bronchoscopy confirmed the presence of a mass lesion involving the right paraglottic region. Biopsy revealed embryonal rhabdomyosarcoma. A metastatic evaluation was negative.

Treatment options were discussed. A curative dose of irradiation would most likely produce an infantile, useless larynx and might predispose the patient to a radiation-induced second tumor. Therefore, surgery and chemotherapy were chosen. The patient underwent a total laryngectomy (partial was felt not possible), with clear margins (Fig 1). He received one course of chemotherapy (vincristine sulfate, dactino-

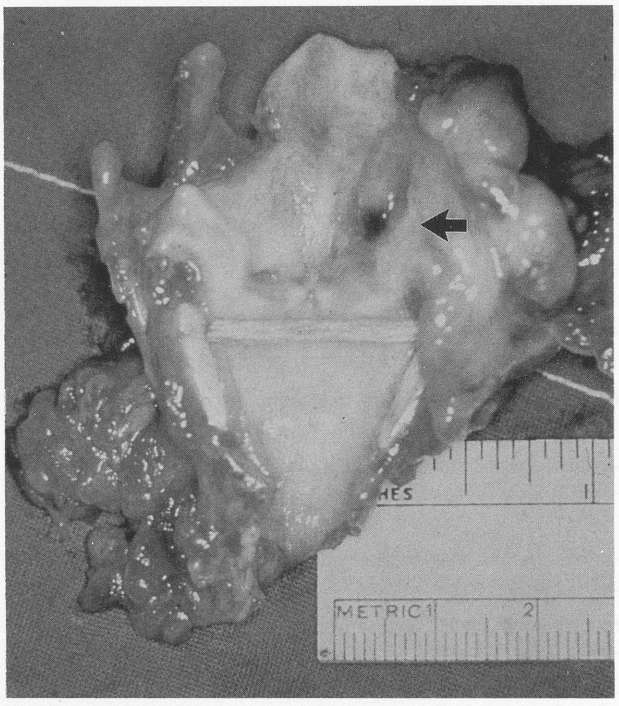

Fig 1. (Case 1) Total laryngectomy specimen showing rhabdomyosarcoma involving right paraglottic region (arrow).

From the Department of Otolaryngology, Children's Hospital, and the Department of Otology and Laryngology, Harvard Medical School, Boston, Massachusetts.

Presented at the meeting of the American Laryngological Association, Palm Beach, Florida, May 7-8, 1994.

REPRINTS — Laurie A. Ohlms, MD, Dept of Otolaryngology, Children's Hospital, 300 Longwood Ave, Boston, MA 02115.

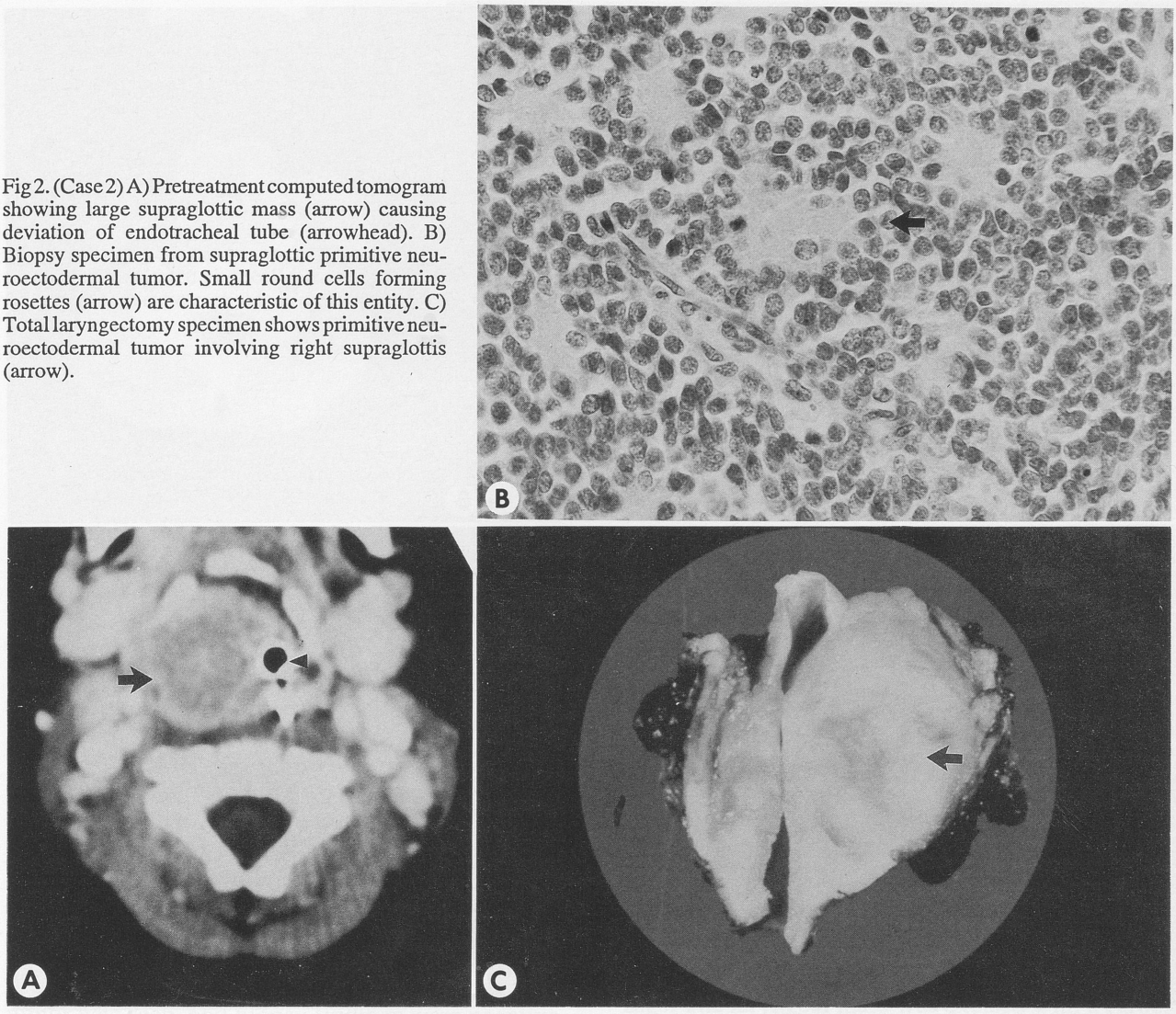

Fig 2. (Case 2) A) Pretreatment computed tomogram showing large supraglottic mass (arrow) causing deviation of endotracheal tube (arrowhead). B) Biopsy specimen from supraglottic primitive neuroectodermal tumor. Small round cells forming rosettes (arrow) are characteristic of this entity. C) Total laryngectomy specimen shows primitive neuroectodermal tumor involving right supraglottis (arrow).

mycin, and cyclophosphamide) prior to surgery and continued this protocol for 1 year postoperatively. He achieved esophageal speech, and 18 years after surgery has no evidence of recurrence.

CASE 2 (PRIMITIVE NEUROECTODERMAL TUMOR)

This 7-month-old boy had developed mild inspiratory stridor at age 3 months. Over the next 4 months, symptoms progressed to biphasic stridor, tachypnea, and marked respiratory distress. Evaluation began with a barium swallow study and direct laryngoscopy that revealed a large supraglottic mass. The patient was intubated and transferred to Children's Hospital, Boston.

Repeat direct laryngoscopy documented a large supraglottic mass involving the right aryepiglottic fold, right false vocal cord, arytenoid, and pyriform sinus. Biopsy specimens were taken. A computed tomography (CT) scan confirmed the above findings and revealed subglottic extension, establishing the lesion as transglottic (Fig 2A).

Pathologic examination revealed a primitive neuroectodermal tumor (Fig 2B). A metastatic evaluation, including bone marrow biopsy and aspirate, CT of the chest, and bone scan, was negative.

Treatment options were discussed with the family. Chemotherapy was unlikely to provide control of the large primary lesion; therapeutic irradiation (at least 5,000 cGy) would produce an infantile, useless larynx. Therefore, surgery with postoperative chemotherapy was chosen. The patient underwent total laryngectomy at the age of 7 months; surgical margins were negative (Fig 2C). He then received a 1-year course of chemotherapy (vincristine, doxorubicin hydrochloride, cyclophosphamide, and actinomycin D). A posttreatment CT scan showed no evidence of tumor.

Postlaryngectomy, the child initially used sign language for communication. At age 3 years, he

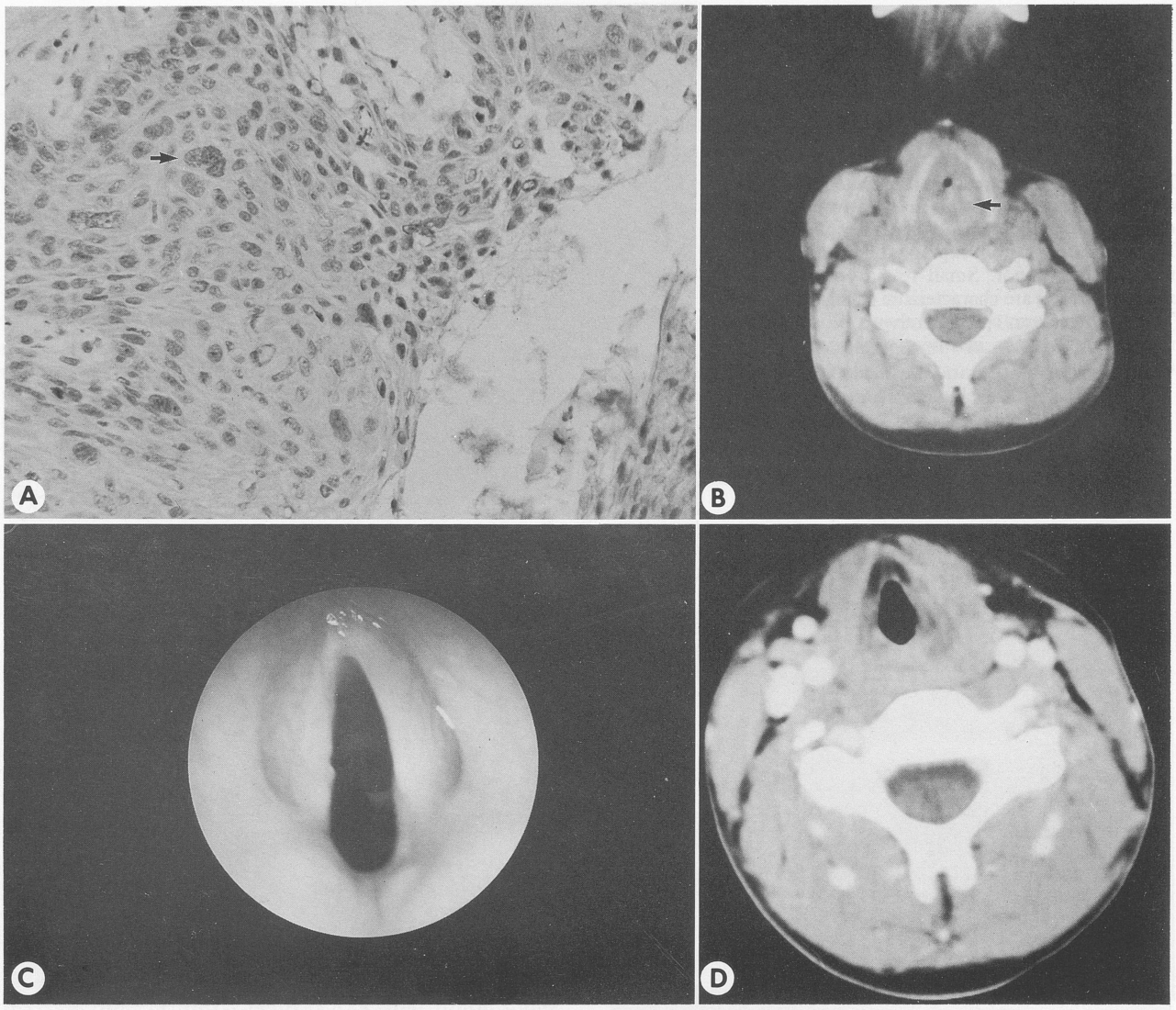

Fig 3. (Case 3) A) Biopsy specimen from left glottic mass, revealing well-differentiated squamous cell carcinoma. Full-thickness involvement is noted, with atypical cells and large hyperchromatic nuclei (arrow). B) Pretreatment computed tomogram shows obstructing glottic mass (arrow) without cartilage invasion. C) Posttreatment view of glottis shows mild erythema of left true vocal cord with no residual tumor. D) Posttreatment computed tomogram shows no residual tumor.

began to learn esophageal speech. He is now 6 years old (5 1/2 years postdiagnosis) and communicates with understandable esophageal speech. At last follow-up, he was free of disease.

CASE 3 (SQUAMOUS CELL CARCINOMA)

This 13-year-old, previously healthy boy noted a several-month history of hoarseness and a 1-month history of shortness of breath and inspiratory stridor.

His medical history and family history were noncontributory; there was no history of laryngeal papillomas. He denied any tobacco or alcohol use; there was no history of irradiation or chemical exposure.

Direct laryngoscopy and bronchoscopy revealed an obstructing exophytic mass arising from the left true vocal cord. A tracheotomy was performed and biopsy specimens were taken. Pathologic examination revealed a well-differentiated, superficially invasive squamous cell carcinoma (Fig 3A). A CT scan demonstrated an obstructing glottic mass with minimal subglottic extension (<5 mm; Fig 3B). A chest radiograph was clear.

The patient was then transferred to our institution for further evaluation and treatment. Laryngoscopy revealed a mass involving the left glottis, with limited mobility of the left true vocal cord. The right true vocal cord moved normally, and the anterior commissure was clear. There were no palpable neck masses. A metastatic workup was negative. Review of the pathologic specimen and CT scan confirmed the diagnosis of stage III (T3N0M0) squamous cell carcinoma of the larynx.

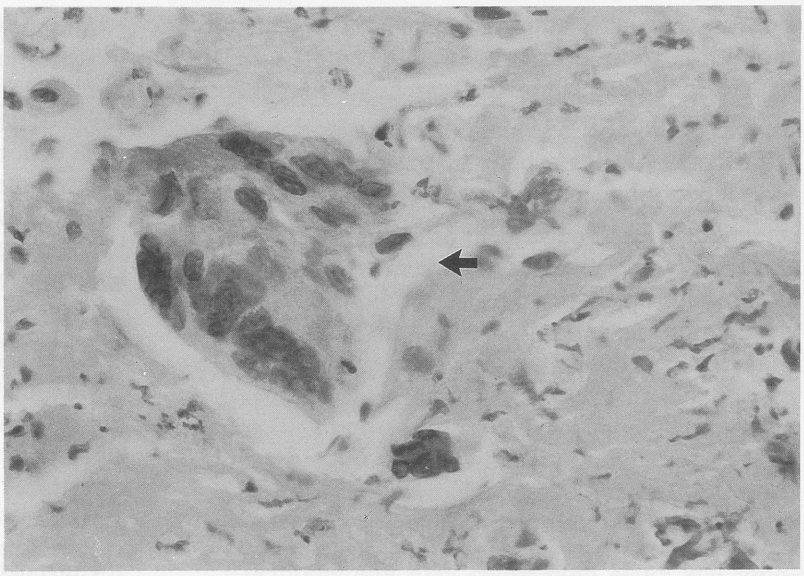

Fig 4. (Case 4) Biopsy specimen from glottic mass. Multinucleated giant cell (arrow) is characteristic of syncytiotrophoblasts seen in choriocarcinoma.

Lengthy discussions were held with the patient, his family, and the multidisciplinary tumor board. A laryngeal preservation treatment protocol was chosen. The patient would receive two courses of chemotherapy (5-fluorouracil, cisplatin, leucovorin calcium rescue). Repeat endoscopy and CT scan would then assess tumor response. If he had less than a partial response, total laryngectomy with postoperative radiotherapy would be performed. If he demonstrated at least a partial response, the third cycle would be administered and he would proceed to full-course radiotherapy.

After the second course of chemotherapy, direct laryngoscopy demonstrated erythema and decreased motion of the left true vocal cord (Fig 3C); no gross tumor was seen, and biopsy findings were negative. A repeat CT scan showed a marked decrease in the glottic soft tissue mass (Fig 3D). The patient completed the third course of chemotherapy and then received full-course radiotherapy (6,000 cGy). Irradiation fields included the primary site, the neck, and the upper mediastinum (including the tracheotomy stoma). At the completion of irradiation, endoscopy showed no evidence of residual tumor; the left true vocal cord remained fixed in the paramedian position. The patient was decannulated without difficulty.

At last follow-up (18 months after initial diagnosis, 9 months after completing treatment), he was doing well. He has a strong, clear voice and is able to participate in physical activities with no exercise intolerance. Laryngeal examination shows no evidence of recurrent tumor.

CASE 4 (METASTATIC CHORIOCARCINOMA)

This 16-year-old boy presented to an outside hospital with complaints of left pleuritic pain, hemoptysis, epistaxis, malaise, and decreased appetite. A careful history-taking revealed that he had noticed a painless left testicular mass 2 years previously, but did not seek medical attention.

Chest radiography revealed multiple nodular densities. Direct laryngoscopy and bronchoscopy demonstrated a friable mass involving the left false vocal cord and ventricle. Biopsy specimens were taken; a tracheotomy and a left orchiectomy were performed.

Pathologic examination revealed testicular choriocarcinoma with a laryngeal metastasis (Fig 4). The patient was transferred to our institution, where repeat direct laryngoscopy confirmed the above findings. The laryngeal mass was excised with a carbon dioxide laser. Systemic evaluation revealed metastases to the kidneys, spleen, vertebral column, and brain. The patient began treatment with chemotherapy (vinblastine sulfate, bleomycin, cisplatin, doxorubicin, and etoposide) and whole brain radiotherapy.

He was decannulated 3 weeks after laser excision of the laryngeal lesion. Despite intensive chemotherapy and radiotherapy, the patient died 19 months after diagnosis.

DISCUSSION

Malignant neoplastic involvement of the larynx is uncommon in the pediatric population. During a 15-year period at our tertiary referral center, only four cases were identified; three patients had a primary malignancy of the larynx, while one patient presented with a laryngeal metastasis. Benign tumors are much more common in the pediatric airway; these include recurrent respiratory papillomas, hemangiomas, and neurogenic tumors. Malignant pediatric laryngeal

tumors are usually in the sarcoma group, most commonly rhabdomyosarcoma.[2] Other reported malignancies include squamous cell carcinoma, lymphoma, and mucoepidermoid carcinoma.[3-6]

DIAGNOSIS

Tumors of the larynx present with similar signs and symptoms, independent of histology. The child develops voice changes (hoarseness), stridor, and progressive upper airway obstruction. Delay in diagnosis is not unusual. In the young child, these findings may represent inflammatory or benign laryngeal disease (such as croup or respiratory papillomas); if symptoms do not resolve with appropriate therapy, further investigation is indicated. In the older child, especially an adolescent male, hoarseness may be attributed to pubertal voice change. Persistent hoarseness in the pediatric patient should always be investigated.

The patients in our series developed symptoms often seen in common inflammatory or benign airway diseases: stridor, respiratory distress, hoarseness, and difficulty swallowing. The clinician must investigate these findings carefully if the patient does not respond to conventional treatment. A high level of suspicion may be necessary to rule out a malignant process.

The initial evaluation begins with laryngoscopy to assess the supraglottis and glottis, including true vocal cord mobility. Laryngoscopy (indirect or flexible) in the office may be difficult in the young, uncooperative child. One should not hesitate to proceed to formal direct laryngoscopy if the clinical situation warrants. Radiographic studies, anterior-posterior and lateral neck films, airway fluoroscopy, and barium swallow study can assess the tumor and rule out concomitant airway lesions. A CT or magnetic resonance imaging scan will demonstrate tumor volume and cartilage invasion, and may be helpful in follow-up to assess response to treatment.

The definitive diagnosis is based on endoscopic findings. Direct laryngoscopy and bronchoscopy are performed to demonstrate the tumor and its extent. A high index of suspicion is critical; a biopsy specimen should be taken prior to laser excision of presumed papillomas to rule out coexisting malignancy. The biopsy will establish the histology, and treatment decisions can then be made.

TREATMENT

Treatment depends on the tumor histology; decisions are based on current protocols for similar lesions at other sites. However, modifications may be necessary because of the unique characteristics of the pediatric larynx.

Rhabdomyosarcoma. Rhabdomyosarcoma is the most common soft tissue sarcoma in patients under the age of 15 years and represents 5% to 8% of all cases of childhood cancer.[7] In the head and neck, 25% of tumors arise in the orbit, and 50% involve other parameningeal sites (nasopharynx, paranasal sinuses, temporal bone, infratemporal fossa). Isolated laryngeal rhabdomyosarcoma is unusual.[8] These lesions usually present as a painless, progressively enlarging mass and tend to remain localized.

Once the diagnosis is established, a metastatic evaluation is performed. Rhabdomyosarcoma staging is currently based on surgical-pathologic findings, including the amount of residual disease after resection.[9] Prognosis is determined by extent of tumor, histologic subtype, and response to treatment.

Current treatment protocols include chemotherapy and high-dose radiotherapy, with surgery usually reserved for diagnostic biopsy only.[8] Rhabdomyosarcoma of the larynx in a child presents a difficult treatment decision. Conventional radiotherapy might provide local tumor control, but in the prepubescent child may result in a fibrotic, infantile larynx; irradiation also carries with it the potential risk of a second, irradiation-induced tumor. Therefore, as in case 1, chemotherapy can be combined with surgical resection of the tumor. Total laryngectomy in a child is not a popular treatment decision, but can result in a complete cure.

Primitive Neuroectodermal Tumor. Primitive neuroectodermal tumor is one of the small, round blue cell tumors of childhood; this soft tissue tumor is of presumed neural crest origin.[10] It is rarely found in the head and neck; most cases involve the central axis (the cerebrum) or the chest. Metastatic disease is common at the time of diagnosis.[11]

Primitive neuroectodermal tumor often has a rapid clinical progression with a high tendency for local recurrence. Therefore, aggressive attempts at local control are essential. Complete initial resection of the tumor may result in increased survival.[12] Our patient with laryngeal primitive neuroectodermal tumor (case 2) underwent total laryngectomy to achieve local control, followed by systemic chemotherapy. Radiotherapy would have arrested laryngeal growth, leading to a useless, infantile larynx. Chemotherapy alone would most likely not have resulted in a complete local response. Therefore, combination therapy was chosen.

Squamous Cell Carcinoma. Squamous cell carcinoma of the larynx is seen frequently in the adult population, but is rare in children. Since 1868, 56 cases of laryngeal carcinoma have been reported in

children under 15 years of age.[3,4,13-16] Squamous cell carcinoma has been reported in patients with laryngeal papillomatosis, with or without a history of irradiation. As with adults, tobacco and alcohol may be predisposing factors.

The goal of treatment is, of course, patient survival, with preservation of laryngeal function when possible. In the past, many pediatric patients were treated with a combination of surgery and irradiation, with dismal survival rates. In more recent reports, two patients were treated with radiotherapy and/or chemotherapy in an attempt to preserve laryngeal function.[4,13]

The adult experience with laryngeal preservation is more extensive. There have been several trials utilizing induction chemotherapy and radiotherapy for adults with advanced squamous cell carcinoma of the larynx.[17-19] Surgery is reserved for patients with less than a partial response to chemotherapy, or for recurrent or residual disease after chemotherapy and radiotherapy. Results suggest that induction chemotherapy followed by radiotherapy can achieve laryngeal preservation in 40% to 50% of patients, without compromising survival.[17,18]

A laryngeal preservation protocol was applied to our pediatric patient (case 3), with good results thus far (follow-up, 18 months). With only a few cases available for comparison, there is no established pediatric tumor experience on which to base treatment decisions. Perhaps one should carefully analyze the adult data and then apply them to the pediatric patient. The child with laryngeal cancer creates a unique dilemma; the desire to preserve laryngeal function will heavily influence multidisciplinary treatment discussions. Our decision to proceed with a laryngeal preservation protocol in a 13-year-old boy was made after careful consideration based on the adult literature.

Some might disagree with the treatment chosen for our patient. He had minimal subglottic tumor extension at diagnosis and had a tracheotomy, both of which are possible risk factors for recurrence after therapy. Care was taken to include the tracheotomy stoma and upper mediastinum in the irradiation field. Our patient was postpubertal; therefore, radiotherapy was unlikely to arrest laryngeal growth. Thus far, there has been no sign of recurrence.

Choriocarcinoma With Metastasis. Metastasis to the larynx is rarely seen in patients of any age.[20] An early manifestation of testicular choriocarcinoma in our patient (case 4) was hemoptysis from a laryngeal metastasis. Choriocarcinoma is an uncommon, highly malignant germ cell neoplasm. The testicular primary may present as a painless swelling of the testis or as a painful torsion. Metastases are common, involving the chest, abdomen, and bones.[21]

Treatment includes complete resection of the primary tumor when possible, followed by chemotherapy. Excision of isolated metastases (as in our patient) may help to control other symptoms. Radiotherapy is added for nonresponders or for relapse. Bone marrow transplantation for choriocarcinoma is experimental at this time.

COMPLICATIONS OF TREATMENT

All therapeutic modalities have benefits and side effects. Surgical resection of a laryngeal tumor will often require total laryngectomy; the child must learn a new means of communication. Loss of a normal voice may create serious psychosocial problems for both the child and the family.

Chemotherapy may cause both acute and long-term morbidity, including nausea and vomiting, alopecia, myelosuppression, mucositis, hearing loss, and renal toxicity. Some chemotherapeutic agents are radiosensitizers, and may increase the reaction to radiotherapy.

Radiotherapy is associated with erythema, swelling, and desquamation in the acute phase. The patient with a laryngeal tumor may require tracheotomy for airway control during treatment. The long-term sequelae are critical in a child. Irradiation of a developing structure may arrest its growth; the larynx is not fully developed until puberty.[22] Therapeutic laryngeal irradiation in a prepubescent child may result in an infantile larynx with no useful voice, airway, or swallowing function. In the adolescent, irradiation may produce fibrosis and a low-pitched, husky voice. There is a report of bilateral carotid stenosis after irradiation of a laryngeal rhabdomyosarcoma, as well as thyroid insufficiency.[8] Secondary tumors in the irradiated field (thyroid, salivary glands, laryngopharynx) are a major concern. Finally, there is a theoretic risk of possible germ cell injury with resultant infertility or abnormalities in offspring. Modern megavoltage techniques should result in a lower incidence of postirradiation sequelae.[4]

These complications emphasize that there is no perfect treatment for the child with a laryngeal malignancy. In each case, the risks and benefits are carefully weighed, and a therapeutic plan is designed. The plan must be flexible, and allow for salvage intervention (surgery) if the response to chemotherapy or radiotherapy is inadequate.

VOICE REHABILITATION

When laryngectomy is necessary for tumor control, the child will require alternate means of communication. Both of the laryngectomy patients in our

series were able to use esophageal speech effectively. One patient was prelingual at the time of laryngectomy, and initially used sign language; after 3 years of age, he was able to learn esophageal speech. For other patients, a voice prosthesis (tracheoesophageal puncture) might facilitate useful speech. It is important to remind parents and other members of the oncology team that communication is possible after laryngectomy.

FUTURE GOALS

Most otolaryngologists will never treat a child with a malignant laryngeal neoplasm; even large institutions rarely see a child with this problem. Multi-institutional trials are not feasible because of the low incidence of these lesions. A pediatric head and neck tumor registry would establish a listing of histologic findings, treatment protocols, and outcomes. Then, the otolaryngologist who diagnoses a new pediatric laryngeal malignancy could refer to the experience of others who have seen similar lesions. It would be impossible to generate a large series, but a sampling of the pediatric experience might lead to new ideas and improved treatment modalities.

ACKNOWLEDGMENT — We thank Harry Kozakewich, MD, for his assistance in preparing the histologic illustrations.

REFERENCES

1. Healy GB, Upton J, Black P McL, Ferraro N. The role of surgery in rhabdomyosarcoma of the head and neck in children. Arch Otolaryngol Head Neck Surg 1991;117:1185-8.

2. Ward RF, Healy GB. Neoplasia of the pediatric larynx. In: Fried M, ed. The larynx: a multidisciplinary approach. Boston, Mass: Little, Brown, 1988:163-9.

3. Gindhart TD, Johnston WH, Chism SE, Dedo HH. Carcinoma of the larynx in childhood. Cancer 1980;46:1683-7.

4. Zalzal GH, Cotton RT, Bove K. Carcinoma of the larynx in a child. Int J Pediatr Otorhinolaryngol 1987;13:219-25.

5. Cohen SR, Thompson JW, Siegel SE. Non-Hodgkin's lymphoma of the larynx in children. Ann Otol Rhinol Laryngol 1987;96:357-61.

6. Mitchell DB, Humphreys S, Kearns DB. Mucoepidermoid carcinoma of the larynx in a child. Int J Pediatr Otorhinolaryngol 1988;15:211-5.

7. Raney RB, Hays DM, Tefft M, Triche TJ. Rhabdomyosarcoma and the undifferentiated sarcomas. In: Pizzo PA, Poplack DG, eds. Principles and practice of pediatric oncology. Philadelphia, Pa: JB Lippincott, 1993:769-94.

8. Kato MADP, Flamant F, Terrier-Lacombe MJ, et al. Rhabdomyosarcoma of the larynx in children. Med Pediatr Oncol 1991;19:110-4.

9. Maurer HM. The Intergroup Rhabdomyosarcoma Study (NIH): objectives and clinical staging classification. J Pediatr Surg 1975;10:977-8.

10. Marina NM, Etcubanas E, Parham DM. Peripheral primitive neuroectodermal tumor (peripheral neuro-epithelioma) in children. Cancer 1989;64:1952-60.

11. Horowitz ME, DeLaney TF, Malawer MM, Tsokos MG. Ewing's sarcoma family of tumors: Ewing's sarcoma of bone and soft tissue and the peripheral primitive neuroectodermal tumors. In: Pizzo PA, Poplack DG, eds. Principles and practice of pediatric oncology. Philadelphia, Pa: JB Lippincott, 1993:795-821.

12. Jurgens H, Bier V, Harms D. Malignant peripheral neuroectodermal tumors: a retrospective analysis of 42 patients. Cancer 1988;61:349-57.

13. Laurian N, Sadov R, Strauss M, Kessler E. Laryngeal carcinoma in childhood. Report of a case and review of the literature. Laryngoscope 1984;94:684-7.

14. Pandey R, Choudhury C. Case report of cancer of the larynx in an adolescent. J Laryngol Otol 1968;82:469-71.

15. Seth RRS, Yadav YC, Kala DM. Epidermoid carcinoma of the laryngopharynx in a young girl. J Laryngol Otol 1978;92:925-6.

16. Ossoff RH, Tucker GF, Norris CM. Carcinoma of the larynx in an 11-year-old boy with late cervical metastasis: report of a case with a ten-year follow-up. Otolaryngol Head Neck Surg 1980;88:142-5.

17. The Department of Veterans Affairs Laryngeal Study Group. Induction chemotherapy plus radiation compared with surgery plus radiation in patients with advanced laryngeal cancer. N Engl J Med 1991;324:1685-90.

18. Merlano M, Vitale V, Rosso R, et al. Treatment of advanced squamous-cell carcinoma of the head and neck with alternating chemotherapy and radiotherapy. N Engl J Med 1992;327:1115-21.

19. Shirinian MH, Weber RS, Lippman SM, et al. Laryngeal preservation by induction chemotherapy plus radiotherapy in locally advanced head and neck cancer: the M. D. Anderson Cancer Center experience. Head Neck 1994;16:39-44.

20. Shimizu KT, Selch MT, Fu Y-S, Anzai Y, Lufkin RB. Osteosarcoma metastatic to the larynx. Ann Otol Rhinol Laryngol 1994;103:160-3.

21. Ablin A, Isaacs H. Germ cell tumors. In: Pizzo PA, Poplack DG, eds. Principles and practice of pediatric oncology. Philadelphia, Pa: JB Lippincott, 1993:867-87.

22. Benjamin B. Congenital disorders of the larynx. In: Cummings CW, Fredrickson JM, Harker LA, Krause CJ, Schuller DE, eds. Otolaryngology–head and neck surgery. St Louis, Mo: Mosby–Year Book, 1993:1831-53.

THREE-DIMENSIONAL IMAGING OF THE HYPOPHARYNX AND LARYNX BY MEANS OF HELICAL (SPIRAL) COMPUTED TOMOGRAPHY

COMPARISON OF RADIOLOGICAL AND OTOLARYNGOLOGICAL EVALUATION

PAUL M. SILVERMAN, MD

ANDREW S. ZEIBERG, MD

ROY B. SESSIONS, MD

THOMAS R. TROOST, MD

ROBERT K. ZEMAN, MD

WASHINGTON, DC

A new computed tomography (CT) technology, helical (spiral) CT, allows the entire neck to be imaged in only 30 seconds. Although multiplanar and three-dimensional (3-D) imaging could be performed with conventional CT, the volumetric acquisition provided by helical (spiral) CT allows significantly improved quality and easier reconstruction for more applications. These 3-D models show an airway appearance similar to that obtained with laryngography. Independent review of the 3-D images in 12 patients with lesions by two radiologists and one otolaryngologist was performed to assess 1) image quality, 2) ability to judge lesion extent, and 3) assistance in understanding the lesion compared to that provided by routine axial scans. Rating scores of 1 to 5 were assigned, with 5 representing the best quality or greatest value. The results showed that both groups scored image quality equally: 4.7. Lesion extent for the radiologists was 2.6, while the otolaryngologist's ranking was 3.7 ($p < .01$). In assisting understanding of lesions versus axial scans, radiologists ranked 3-D images 2.1, while the otolaryngologist ranked them 3.1 ($p < .01$). In summary, 3-D models provide a complementary imaging technique in understanding upper airway disease.

KEY WORDS — airway, helical computed tomography, hypopharynx, larynx, spiral computed tomography.

Prior to the advent of cross-sectional imaging techniques, radiologic imaging of the hypopharynx and larynx was limited to plain film radiography, tomography, fluoroscopy, and laryngography.[1-3] Although clinical examination is excellent in evaluating the supraglottic and glottic regions and assessing the mobility of structures, there are certain areas that are not optimally evaluated by endoscopy. These include the apices of the pyriform sinuses, the laryngeal ventricle, and the subglottic region, which on occasion could be evaluated with laryngography despite its invasive nature.[4,5]

The introduction of conventional computed tomography (CT) scanning has had a major impact on evaluating inflammatory and neoplastic masses of the hypopharynx and larynx. The basic cross-sectional display of axial images is able to distinguish soft tissue density from fat and evaluate for tumor invasion deep to the mucosal surfaces, especially in the preepiglottic and paralaryngeal spaces. Gross involvement of cartilaginous structures can be detected by CT, although subtle cartilage invasion may be missed because of incomplete ossification.[6-8] Additional three-dimensional (3-D) imaging is not necessary for this particular assessment. Limitations for conventional CT remain, since standard scanners require a 2- to 4-second scan time and a 6-second delay between images. Patient motion with breathing or swallowing often causes blurring of images.

Most recently, the introduction of helical (spiral) CT has dramatically changed our ability to image the hypopharynx, larynx, and upper airway. This differs from conventional CT in that the patient is moved continuously through the CT scanner during a continuous x-ray exposure. With most patients, the entire neck can be scanned within a single breath-hold (30 seconds). Prior to helical CT, hardware and software constraints made 3-D imaging by CT extremely difficult, except in the case of bony structures. Helical CT, by virtue of its volumetric acquisition, provides the first opportunity to produce high-quality 3-D images. Although this technique is primarily used to evaluate vascular structures, we have, for the first time, adapted it to produce 3-D "airway casts" that

From the Departments of Radiology (Silverman, Zeiberg, Zeman) and Otolaryngology (Sessions, Troost), Georgetown University Hospital, Washington, DC. Grant support and a Senior Research and Development Award (P.M.S.) were provided by General Electric Medical Systems, Milwaukee, Wisconsin.

Presented at the meeting of the American Laryngological Association, Palm Beach, Florida, May 7-8, 1994.

REPRINTS — Paul M. Silverman, MD, Dept of Radiology, Georgetown University Hospital, 3800 Reservoir Rd NW, Washington, DC 20007.

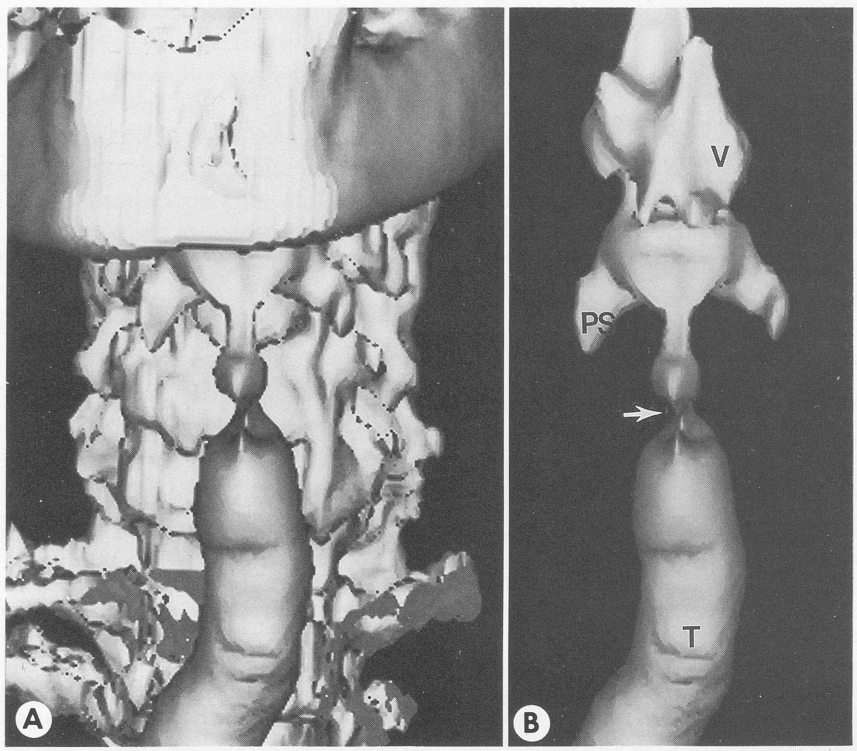

Fig 1. Three-dimensional (3-D) image of upper airway, demonstrating bony structure and air-containing structures, both in white. A) 3-D airway model viewed from anterior. Bony structures of spine overlap airway model, making it extremely difficult to appreciate these structures. B) After subtraction of bony structures, 3-D "airway cast" model now takes on appearance of laryngogram and can be rotated in 360° fashion around long or short axis of airway. V — vallecula, PS — pyriform sinus, arrow — true vocal cords, T — trachea.

mimic laryngograms (Fig 1). These images can be rotated continuously along any axis of the airway to optimally assess disease. The goal of the present study was threefold. First, we evaluated the quality of the 3-D images. Second, we evaluated to what degree these images assisted the radiologists and otolaryngologist in judging the lesion extent relative to axial images. Third, we assessed whether there was any difference between the radiologists' and otolaryngologist's perceptions of the 3-D images in assisting in understanding the lesion, especially its extent, compared to axial images.

MATERIALS AND METHODS

Twelve patients with suspected neoplasms or inflammatory lesions of the hypopharynx or larynx underwent helical (spiral) CT scanning of the neck. Disease was documented in all cases by biopsy or surgery. All patients were scanned with the GE Hi-Speed scanner (GE Medical Systems, Milwaukee, Wis). Scans were performed with 300 to 330 mA, 120 kV (peak), 5-mm collimation, 1-second scan time (table increment 5 mm/s), and a 30-second breathhold. A 1:1 pitch was used for all scans (yielding contiguous 5-mm increments). Patients were routinely hyperventilated prior to scanning in order to allow them to hold their breath a full 30 seconds. Because of the volumetric acquisition, motion artifact and misregistration is minimized with helical CT. There were no technical failures. All patients received 150 mL of iohexol (Omnipaque 300, Sanofi Winthrop Pharmaceuticals, New York, NY) given intravenously by a machine injector (Medrad, Pittsburgh, Pa) at a rate of 2 mL/s. Contrast administration began 40 seconds prior to scan initiation.

The data from the helical scans were used to generate a standard set of 5-mm contiguous images. Computer raw data were saved and reconstructed to produce 5-mm axial images that overlapped each adjacent image by 3 mm (5-mm slice taken every 3 mm). This resulted in another complete set of overlapping images without exposing the patient to any additional radiation. The space between slices was reduced from 5 mm to only 2 mm. Data sets containing the retrospectively reconstructed images were sent via local area network to a GE Windows Advantage workstation used to generate 3-D models. Axial images were reviewed on the workstation in order to determine the upper and lower extents of the object of interest to be modeled. Three-dimensional surface models were generated of this region of interest that included all structures that had a CT attenuation of between −1,000 and −500 Hounsfield units. The result was a surface model in which all air-containing structures appeared white. The soft tissues were eliminated. Next, the disarticulation tools in the 3-D software were used to separate the 3-D surface model of the air–soft tissue interfaces of the patient's airway (hypopharynx through proximal trachea) from the air-skin interface outside the patient. For most models, the disarticulation step involved no more than four individual steps and required less than 10 min-

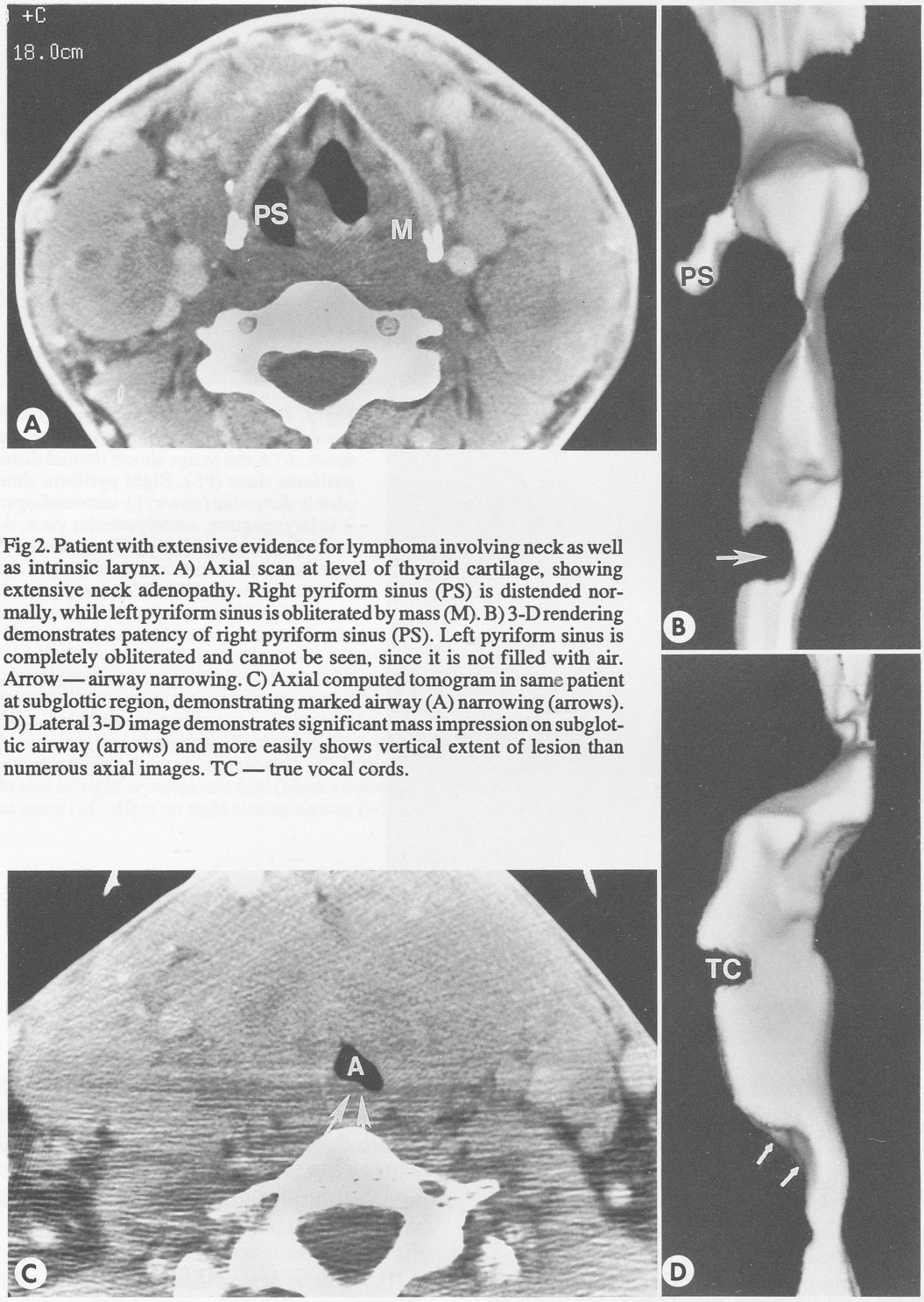

Fig 2. Patient with extensive evidence for lymphoma involving neck as well as intrinsic larynx. A) Axial scan at level of thyroid cartilage, showing extensive neck adenopathy. Right pyriform sinus (PS) is distended normally, while left pyriform sinus is obliterated by mass (M). B) 3-D rendering demonstrates patency of right pyriform sinus (PS). Left pyriform sinus is completely obliterated and cannot be seen, since it is not filled with air. Arrow — airway narrowing. C) Axial computed tomogram in same patient at subglottic region, demonstrating marked airway (A) narrowing (arrows). D) Lateral 3-D image demonstrates significant mass impression on subglottic airway (arrows) and more easily shows vertical extent of lesion than numerous axial images. TC — true vocal cords.

utes to perform. The 3-D models were then viewed by means of appropriate window and level settings and rotated into anteroposterior, lateral, and selected oblique projections to best define the disease. Models were able to be continuously rotated along any axis for a full 360°.

The 3-D images were reviewed by two radiologists together yielding one consensus score, and independently by one otolaryngologist. Images were reviewed to assess 1) quality, 2) ability to judge lesion extent, and 3) assistance in understanding the lesion (especially in extent) versus that provided by routine axial scans. The rating scores ranged from 1 to 5. Scoring in terms of image quality was 1 = poor, 2 = less than optimal, 3 = adequate, 4 = good, and 5 =

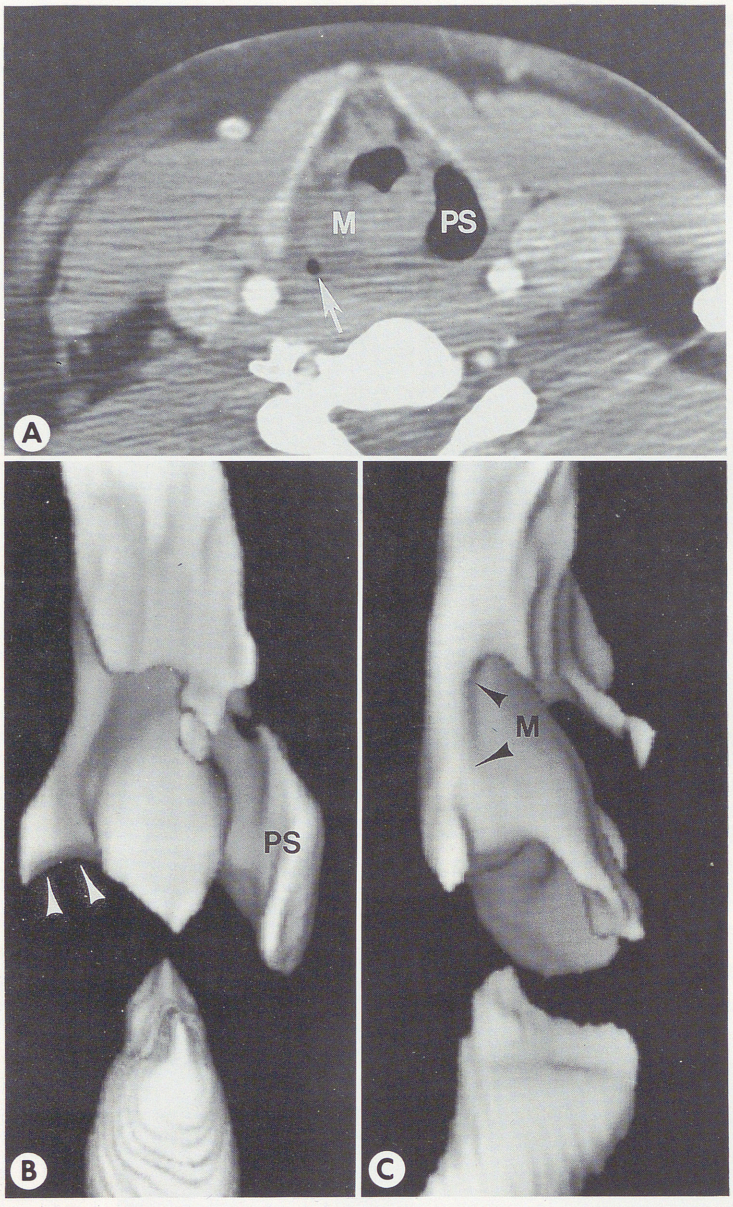

Fig 3. Patient with primary supraglottic carcinoma involving right pyriform sinus and right paralaryngeal space. A) Axial image shows normal distention of left pyriform sinus (PS). Right pyriform sinus is incompletely distended (arrow) by surrounding mass (M). B) 3-D laryngogram, anteroposterior view, demonstrates normal aeration of left pyriform sinus (PS). There is significant truncation and narrowing of right pyriform sinus (arrowheads). C) 3-D laryngogram, lateral view, shows significant mass (M) impression on adjacent airway structures (arrowheads).

excellent. Quality criteria included assessment for edge or "stair-step" artifact, motion artifacts, and overall image display. In evaluating the ability to judge the anatomic extent of the lesion, 1 = poor, 2 = minimal value, 3 = good, 4 = moderately helpful, and 5 = highly valuable. This included not only the vertical extent of the lesion, but the overall perception of the lesion compared to mentally stacking multiple axial images. In terms of the value of 3-D scanning in better understanding the lesion (especially in extent) compared to routine axial scans, the following rating scale was utilized: 1 = no value, 2 = minimal value, 3 = mild value, 4 = moderate value, and 5 = great value. Included in this last assessment was the ability of the radiologists and otolaryngologist to better appreciate the lesion itself and its relationship to adjacent normal structures. This included the mass effect on adjacent structures. Results were analyzed for statistical signficance by a standard paired Student's *t* test. A more rigorous statistical analysis using the Mann-Whitney test was also applied in order to control for the possibility of a nongaussian distribution of the data.

RESULTS

In the evaluation of the quality of the 3-D images, image quality was rated equally by both radiologists and the otolaryngologist with a score of 4.7, just slightly less than excellent. In terms of the ability to judge the anatomic extent of the lesion on the 3-D reconstructions relative to the standard axial image, the two radiologists rated as an average the 3-D images to be 2.6. The otolaryngologist ranking the same images assigned a value of 3.7. This difference

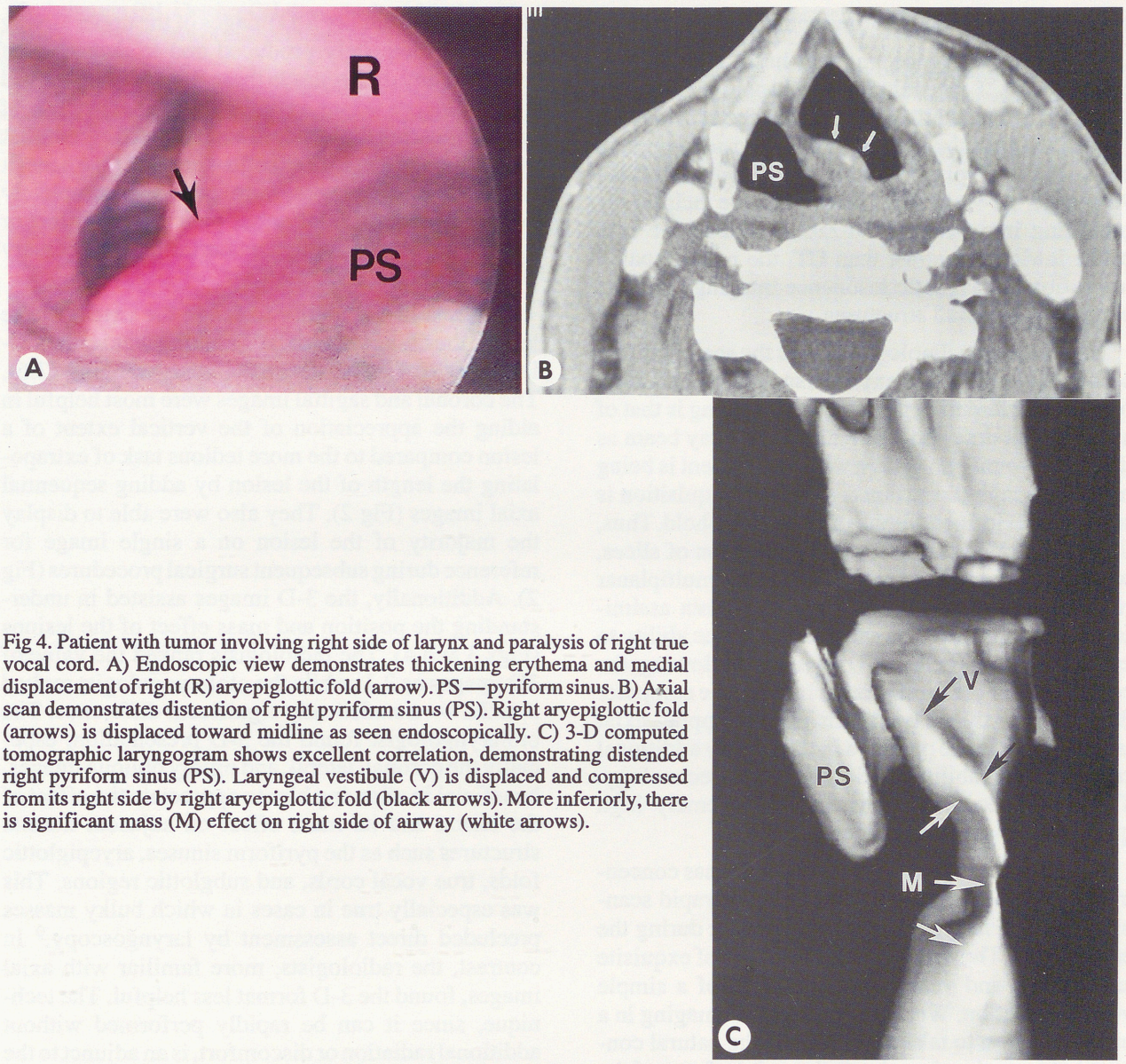

Fig 4. Patient with tumor involving right side of larynx and paralysis of right true vocal cord. A) Endoscopic view demonstrates thickening erythema and medial displacement of right (R) aryepiglottic fold (arrow). PS — pyriform sinus. B) Axial scan demonstrates distention of right pyriform sinus (PS). Right aryepiglottic fold (arrows) is displaced toward midline as seen endoscopically. C) 3-D computed tomographic laryngogram shows excellent correlation, demonstrating distended right pyriform sinus (PS). Laryngeal vestibule (V) is displaced and compressed from its right side by right aryepiglottic fold (black arrows). More inferiorly, there is significant mass (M) effect on right side of airway (white arrows).

was statistically significant by a paired Student's *t* test, with $p < .01$ ($p = .002$). The Mann-Whitney test also showed significance, with $p < .05$ ($p = .02$). In terms of assistance to the understanding of lesions as seen on axial scans, the two radiologists ranked the 3-D images to be 2.1, while the otolaryngologist ranked the images at 3.1. This difference was statistically significant by a paired Student's *t* test, with $p < .01$ ($p = .004$). The Mann-Whitney test also showed significance, with $p < .05$ ($p = .04$).

Image quality was assessed the same by the radiologists and the otolaryngologist. However, in terms of defining the lesion extent and assisting in understanding the axial CT scans, the otolaryngologist consistently ranked the 3-D images as being of additional value, compared to the standard axial CT examination.

DISCUSSION

The new technology of helical CT is rapidly becoming the preferred technology for scanning of the body. Conventional "step and shoot" CT requires a 2- to 4-second scan time and an obligatory 6-second delay between slices. Although the scan time is short enough to provide good-quality images of the upper airway, the duration of the scan may create motion artifact, especially from breathing or swallowing during the scan. The relatively long delay between scans translates into a scan time of approximately 4.5 minutes to scan the entire neck. Since each slice is performed independently, reconstructed images are crude unless very thin (1 to 1.5 mm) scans are performed, which require an unacceptable amount of time. Additionally, misregistration artifact is not uncommon if scans are not performed at exactly the

specified level because of movement.

Magnetic resonance imaging has a complementary role to CT in evaluating the upper airway. Although it is frequently subject to artifacts because of longer imaging times, it does have the advantage of being able to display lesions in a multiplanar fashion. Although T2-weighted images can be helpful by providing improved visualization of a tumor with better intrinsic contrast than CT, the poorer spatial resolution of magnetic resonance imaging limits its evaluation of small structures.

New helical technology reduces the scan time to 1 second and eliminates any interscan delay. An analogy put forward to explain helical scanning is that of a spring that describes the path of the x-ray beam as it rotates around the patient while the patient is being moved through the scanner. An entire acquisition is routinely performed within a single breath-hold. Thus, there is no opportunity for misregistration of slices, which would severely compromise any multiplanar reconstructions. The large number of data assimilated with helical CT provides one with the ability to construct high-quality 3-D images. Following the completion of the routine axial images, the computer data are reanalyzed by means of overlapping axial images without the patient's incurring any additional radiation. This ability is unique to helical technology. Thus, 3-D reconstructions are of extremely high quality, with smooth contours.

Until the present time, 3-D helical CT has concentrated on imaging of the vasculature, as rapid scanning has provided high levels of contrast during the entire study. The result is the production of exquisite angiograms and venograms by means of a simple venous injection. We have applied 3-D imaging in a unique fashion to take advantage of the natural contrast between the air and soft tissue interfaces of the upper airway — a technique not previously performed. The models have the resultant appearance of an airway "cast" or a laryngogram, with the air-containing structures being white, while all soft tissues are eliminated. Laryngograms, because of their invasive nature, have been used to a limited extent since the availability of CT. Prior to CT they allowed visualization of mucosal abnormalities, as well as the vertical extent of lesions.

In the present study, our goal was to evaluate whether high-quality 3-D images of the upper airway could be adequately produced and to determine if there was any difference in these images as perceived by radiologists versus an otolaryngologist in terms of complementing the standard axial CT. All agreed that the 3-D images were of excellent quality. One benefit was that these images were obtained completely noninvasively, without either patient discomfort or the instillation of foreign material as is necessary with laryngography.

In terms of the ability to judge the extent of the lesion, the otolaryngologist's ranking was statistically higher (3.7) than the radiologists' ranking (2.6). The coronal and sagittal images were most helpful in aiding the appreciation of the vertical extent of a lesion compared to the more tedious task of extrapolating the length of the lesion by adding sequential axial images (Fig 2). They also were able to display the majority of the lesion on a single image for reference during subsequent surgical procedures (Fig 2). Additionally, the 3-D images assisted in understanding the position and mass effect of the lesions (Figs 3 and 4). The radiologists ranked the value of 3D images as 2.1, while the otolaryngologist ranked it as 3.1 — a statistically significant difference. The otolaryngologist found the 3-D presentation, especially the coronal, lateral, and mildly oblique images, beneficial in allowing him to appreciate the effect of the lesion and its mass effect on adjacent normal structures such as the pyriform sinuses, aryepiglottic folds, true vocal cords, and subglottic regions. This was especially true in cases in which bulky masses precluded direct assessment by laryngoscopy.[9] In contrast, the radiologists, more familiar with axial images, found the 3-D format less helpful. The technique, since it can be rapidly performed without additional radiation or discomfort, is an adjunct to the standard axial scans. The standard axial images remain the mainstay of assessing deep tissue invasion and cartilage destruction. However, the overall impact of the study has been an improved understanding and appreciation of the correlation between the radiologic information and information obtained clinically. In the future, technical advances in 3-D imaging may offer the potential for an interactive, virtual reality–type image manipulation that might assist the otolaryngologist in planning the most appropriate surgical procedure.

REFERENCES

1. Ali YE, Saleh EM, Mancuso AA. Does conventional tomography still have a place in glottic cancer evaluation? Clin Radiol 1992;45:114-9.

2. Mancuso AA, Calcaterra TC, Hanafee WN. Computed tomography of the larynx. Radiol Clin North Am 1978;16:195-208.

3. Dawes PJDK, Patrick D, Hall K. The role of computed tomography and coronal plane tomography in radiotherapy for laryngeal cancers. Br J Radiol 1989;62:729-33.

4. Mancuso AA, Hanafee WN. Computed tomography and magnetic resonance imaging of the head and neck. 2nd ed. Baltimore, Md: Williams & Wilkins, 1985:241-76.

5. Lehmann QH, Fletcher GH. Contribution of the laryngogram to the management of malignant laryngeal tumors. Radiology 1964;83:486-500.

6. Reid MH. Laryngeal carcinoma: high-resolution computed tomography and thick anatomic sections. Radiology 1984; 151:689-96.

7. Silverman PM. Medullary space involvement in laryngeal carcinoma. Computed tomographic demonstration. Arch Otolaryngol 1985;111:541-2.

8. Silverman PM. CT staging of laryngeal hypopharyngeal carcinoma. In: Glazer GM, ed. Staging of neoplasms. New York, NY: Churchill Livingstone, 1986:55-77.

9. Curtin HD. Imaging of the larynx: current concepts. Radiology 1989;173:1-11.

NEUROPEPTIDE PARTICIPATION IN CANINE LARYNGEAL SENSORY INNERVATION

IMMUNOHISTOCHEMISTRY AND RETROGRADE LABELING

YASUO HISA, MD
NOBUHISA TADAKI, MD
TOSHIYUKI UNO, MD
HITOSHI OKAMURA, MD
JUN-ICHI TAGUCHI, PHD
YASUHIKO IBATA, MD

KYOTO, JAPAN

We investigated the quantitative participation of calcitonin gene-related peptide (CGRP), substance P (SP), and leu-enkephalin (ENK) in canine laryngeal sensory innervation by immunohistochemistry in combination with retrograde labeling using the recently introduced retrograde tracer cholera toxin subunit B–conjugated gold (CTBG). In the nodose ganglion, neurons labeled from the internal branch of the superior laryngeal nerve with CTBG were investigated immunohistochemically by means of antisera against CGRP, SP, and ENK. The percentages of neurons immunoreactive to each neuropeptide were as follows: CGRP 81.5%, SP 24.5%, and ENK 7.0%. These results suggest that CGRP is the main sensory neurotransmitter in canine laryngeal sensory innervation.

KEY WORDS — afferent system, calcitonin gene-related peptide, canine, cholera toxin, enkephalin, laryngeal nerve, nodose ganglion, substance P.

INTRODUCTION

In the peripheral afferent system of laryngeal innervation, several kinds of neuropeptides have been reported as putative sensory neurotransmitters and/or neuromodulators.[1-5]

In the present study, we investigated the quantitative participation of calcitonin gene-related peptide (CGRP), substance P (SP), and leu-enkephalin (ENK), putative sensory neurotransmitters, in laryngeal sensory innervation by immunohistochemistry in combination with retrograde labeling using the recently introduced retrograde tracer cholera toxin subunit B–conjugated gold (CTBG).[6]

MATERIALS AND METHODS

The procedure for preparing CTBG has been reported elsewhere.[7] Five puppies of both sexes, weighing 1.5 to 2 kg, were used, and all operative procedures were performed under deep anesthesia with pentobarbital (intraperitoneal administration, 30 mg/kg). The skin was incised on the ventral midline of the neck, and the right internal branch of the superior laryngeal nerve (SLNI) was exposed. Under a surgical microscope, 5 μL of CTBG solution was injected into the SLNI at the level of the thyrohyoid membrane. After the injection, the injected nerve and surrounding tissues were washed thoroughly with saline, after which the skin was sutured. After 48 hours, 300 μg of colchicine was injected into the ipsilateral nodose ganglion (NG). Twenty-four hours later, the canines were perfused through the left cardiac ventricle with 0.1 mol/L phosphate buffered saline (PBS) followed by an ice-cold fixative containing 4% paraformaldehyde, 0.2% picric acid, and 0.35% glutaraldehyde in 0.1 mol/L phosphate buffer (PB). After perfusion fixation, the right NG was removed and postfixed with 4% paraformaldehyde and 0.2% picric acid in 0.1 mol/L PB for 1 day. Thereafter, the extirpated NG was immersed in 0.1 mol/L PBS containing 20% sucrose for 1 day and then serially sectioned at 20 μm on a freezing microtome. Sections were successively collected in three different containers containing 0.1 mol/L PB solution, and were washed in this solution for 30 minutes on a mixing plate at room temperature. Gold labeling was converted to silver grain by means of a BioCell Silver Enhancing Kit (BioCell, Cardiff, Wales). After silver intensification, these sections were processed for immunohistochemistry. Free-floating sections were treated with 1% bovine serum for 1 hour. The sections collected in the different containers were respectively incubated with anti-CGRP serum (Amersham, ×5,000), anti-SP serum (Immunonuclear Co, ×5,000), and anti-ENK serum (Immunonuclear Co, ×5,000) for 4 days at 4°C. Sections were then incubated with biotinylated anti-rabbit IgG (Vector Lab, ×1,000) for 1 day and with avidin-biotin-peroxidase complex (Vector Lab,

From the Departments of Otolaryngology (Hisa, Tadaki, Uno) and Anatomy (Okamura, Taguchi, Ibata), Kyoto Prefectural University of Medicine, Kyoto, Japan. This work was supported by a Grant-in-Aid for Scientific Research (No. 03670816) from the Ministry of Education, Science and Culture, Japan.

Presented at the meeting of the American Laryngological Association, Palm Beach, Florida, May 7-8, 1994.

REPRINTS — Yasuo Hisa, MD, Dept of Otolaryngology, Kyoto Prefectural University of Medicine, Kawaramachi-Hirokoji, Kyoto 602, Japan.

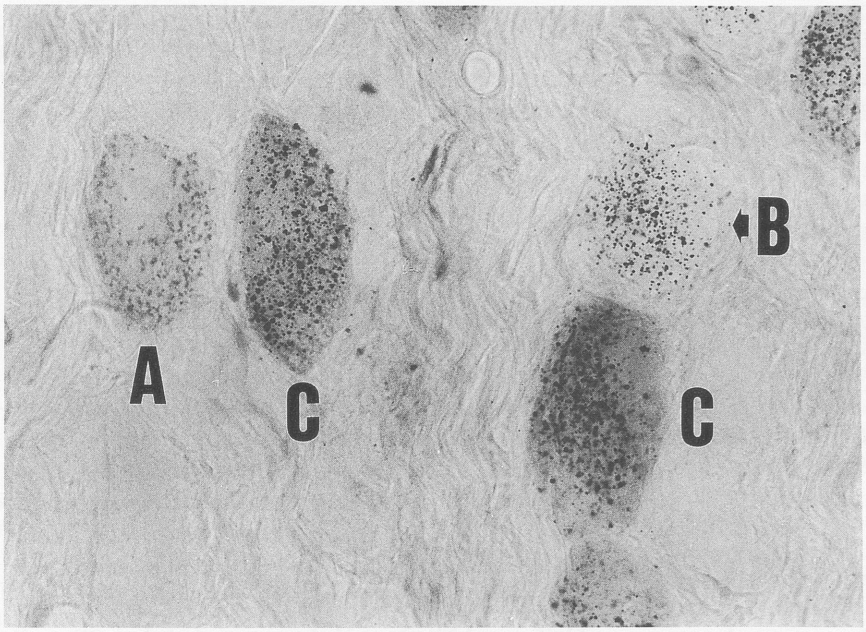

Fig 1. High magnification of neurons in ipsilateral nodose ganglion stained immunohistochemically with antiserum against calcitonin gene-related peptide (CGRP) after application of cholera toxin subunit B–conjugated gold (CTBG) to internal branch of superior laryngeal nerve (original ×1,000). Neurons with CGRP immunoreactivity only (A) were identified by presence of brown diamidinobenzidine product in their cytoplasm. B — CTBG-labeled neurons without CGRP-like immunoreactivity. C — CTBG-labeled neurons with CGRP-like immunoreactivity.

×1,000) for 1 day. All sera were diluted with 0.1 mol/L PBS containing 0.1% Triton X-100. Before each step of the reaction, sections were washed with 0.1 mol/L PBS. Bound peroxidase was visualized in 50 mmol/L Tris hydrochloride buffer (pH 7.5) containing 0.01% 3,3′diamidinobenzidine (DAB) and 0.01% hydrogen peroxide. The sections were then mounted on chrome-coated glass slides, air-dried, and washed with tap water. Finally, tissues were dehydrated in a graded series of ethanol, cleaned in xylene, and covered with Entellan (Merck, Darmstadt, Germany).

RESULTS

Neurons labeled with CTBG were clearly identified by the presence of scattered black dots in their cytoplasm. Neurons with each type of neuropeptide-like immunoreactivity were identified by the presence of brown DAB product in their cytoplasm. The black dots resulting from silver intensification of CTBG were clearly distinguishable from the DAB product obtained by immunohistochemistry. The CTBG-labeled neurons with and without neuropeptide-like immunoreactivity could be clearly identified (Fig 1).

The CTBG-labeled neurons were located in the rostrolateral division of the NG (Fig 2). The percentages of CTBG-labeled neurons with each neuropeptide-like immunoreactivity are shown in the Table.

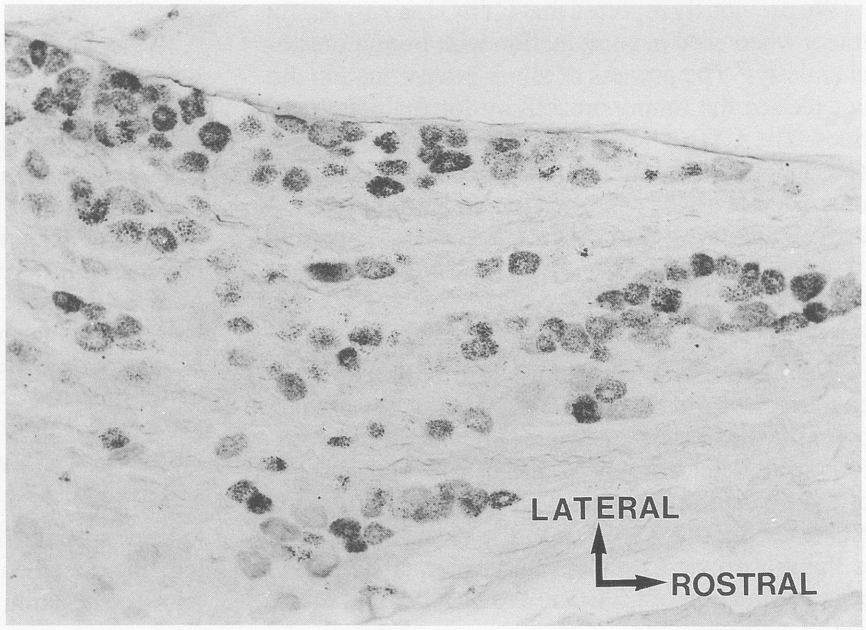

Fig 2. Ipsilateral nodose ganglion stained immunohistochemically with antiserum against CGRP after application of CTBG to internal branch of superior laryngeal nerve (original ×200). CTBG-labeled neurons were localized in rostrolateral division of ganglion. Most labeled neurons had CGRP-like immunoreactivity.

PERCENTAGE OF CTBG-LABELED NEURONS WITH CGRP-, SP-, AND ENK-LIKE IMMUNOREACTIVITY IN NODOSE GANGLION

Animal No.	*CGRP*	*SP*	*ENK*
1	73.2	17.7	5.7
2	81.2	23.1	6.3
3	85.8	26.5	8.5
4	88.7	33.4	NA
5	78.4	21.8	7.5
Average	81.5	24.5	7.0

CTBG — cholera toxin subunit B–conjugated gold, CGRP — calcitonin gene-related peptide, SP — substance P, ENK — leu-enkephalin, NA — not available.

Although immunohistochemistry for ENK failed in 1 animal, there were no problems with the specimens from the other animals.

DISCUSSION

Although a variety of tracers can be used in combination with immunohistochemistry, many have disadvantages that make them inappropriate for certain kinds of studies.[6] We previously found, using cholera toxin as a tracer, that the NG contains CGRP-immunoreactive neurons that send their nerve fibers into the SLNI.[8] However, a quantitative study could not be performed with this tracer. Tanaka et al[9] also investigated the CGRP-immunoreactive neurons in the cat NG supplying laryngeal sensory nerve fibers by using wheat germ agglutinin as a retrograde tracer in combination with immunohistochemistry of CGRP. However, they could not clarify the percentages of labeled neurons with CGRP-like immunoreactivity, since this technique did not simultaneously visualize retrograde wheat germ agglutinin and CGRP-like immunoreactivity on a single section.

We previously reported that CTBG is a very useful tracer when used in combination with immunohistochemistry.[7] The process of silver intensification did not reduce the immunoreactivity for the neuropeptides. The CTBG-labeled neurons with and without neuropeptide-like immunoreactivity were clearly distinguishable on the same section under light microscopy. Unlike with fluorescent tracers, it was possible to observe the retrograde tracer and immunoreactivity repeatedly. This is also a clear advantage of this tracer.

We previously examined the distribution of afferent neurons from the canine SLNI using horseradish peroxidase as a retrograde tracer.[10] The afferent neurons were detected only in the rostrolateral division of the ipsilateral NG, and never in the contralateral NG or the jugular ganglion of the vagus nerve. This is the reason we examined only the ipsilateral NG after application of CTBG to the SLNI in this study. The distribution pattern of CTBG-labeled neurons in the NG in this study corresponded well with the results obtained in our previous study using horseradish peroxidase,[10] indicating that CTBG is a reliable tracer.

Calcitonin gene-related peptide and SP have been considered to be the main putative neurotransmitters in the laryngeal afferent system.[1-5] Although the distribution patterns of these peptides in the canine laryngeal mucosa are similar, suggesting an overlapping distribution, we previously found that SP-immunoreactive fibers were fewer than CGRP-immunoreactive fibers.[3] In contrast to this finding, there have been reports that CGRP-immunoreactive fibers were similar in density and distribution to SP-immunoreactive fibers in the laryngeal epithelium of dogs[2] and cats.[5] This discrepancy seems to be due to the methods used for qualitative judgment in these studies.

Helke and Niederer[11] demonstrated that SP- and CGRP-like immunoreactivities were similarly distributed in scattered cells, concentrated mostly in the rostral pole of the rat NG, and that SP-like immunoreactivity coexisted with CGRP-like immunoreactivity, although there was at least twice the number of CGRP-immunoreactive neurons as SP-immunoreactive neurons, indicating the presence of CGRP-immunoreactive neurons that did not contain SP-like immunoreactivity. This finding and our previous report[3] suggest that there may be a difference in the numbers of CGRP- and SP-immunoreactive neurons in the NG of the laryngeal afferent system. The present study showed that there are almost three times as many CGRP-immunoreactive neurons as SP-immunoreactive neurons for the laryngeal afferent system.

Although the functional roles of SP- and CGRP-immunoreactive fibers in the laryngeal epithelium have not yet been clarified, these fibers might represent unmyelinated C fibers, because both SP and CGRP have been demonstrated to be released from the epithelium in the lower respiratory tract by capsaicin.[12-14] Thus, nerve fibers containing SP or CGRP either alone or in combination may subserve different local epithelial or mucosal responses (plasma extravasation and vasodilatation), and may be selectively activated by different airway stimuli (ie, chemical irritation versus immune responses).[14,15] The present study indicates that CGRP plays a major role in this system of the larynx.

Although CGRP and SP have been demonstrated to be neurotransmitters in the laryngeal afferent system, the existence of other putative neurotransmitters (cholecystokinin, neurokinin A, vasoactive intestinal

peptide, somatostatin, and dopamine) in the NG has also been reported.[11,16] The present study suggests that ENK is a candidate neurotransmitter in the laryngeal afferent system, although its involvement seems low, considering the fact that only 7% of afferent neurons from the SLNI had ENK-like immunoreactivity. The functional role of ENK in the laryngeal afferent system remains to be elucidated.

REFERENCES

1. Hisa Y, Sato F, Fukui K, Ibata Y, Mizukoshi O. Substance P nerve fibers in the canine larynx by PAP immunohistochemistry. Acta Otolaryngol (Stockh) 1985;100:128-33.

2. Kawasoe M, Shin T, Sadahiko M. Distribution of neuropeptide-like immunoreactive nerve fibers in the canine larynx. Otolaryngol Head Neck Surg 1990;103:957-62.

3. Hisa Y, Uno T, Tadaki N, Murakami Y, Okamura H, Ibata Y. Distribution of calcitonin gene-related peptide nerve fibers in the canine larynx. Eur Arch Otorhinolaryngol 1992;249:52-5.

4. Hause-Kronberger C, Albegger K, Saria A, Hacker GW. Regulatory peptides in the human larynx and recurrent nerves. Acta Otolaryngol (Stockh) 1993;113:409-13.

5. Tanaka Y, Yoshida Y, Hirano M, Morimoto M, Kanaseki T. Distribution of SP- and CGRP-immunoreactivity in the cat's larynx. J Laryngol Otol 1993;107:522-6.

6. Llewellyn-Smith IJ, Minson JB, Wright AP, Hodgson AJ. Cholera toxin B–gold, a retrograde tracer that can be used in light and electron microscopic immunohistochemical studies. J Comp Neurol 1990;294:179-91.

7. Hisa Y, Tadaki N, Uno T, Taguchi J, Okamura H, Ibata Y. Calcitonin gene-related peptide-like immunoreactive motoneurons innervating the canine inferior constrictor muscle. Acta Otolaryngol (Stockh) (in press).

8. Hisa Y, Uno T. Neurotransmitters in laryngeal protective function. In: Inoue T, Fukuda H, Sato T, Hinohara T, eds. Recent advances in bronchoesophagology. Amsterdam, the Netherlands: Excerpta Medica, 1990:105-10.

9. Tanaka Y, Yoshida Y, Hirano M. CGRP-immunoreactive cells supplying laryngeal sensory nerve fibers in the cat's nodose ganglion. J Laryngol Otol 1993;107:916-9.

10. Hisa Y, Toyoda K, Uno T, Murakami Y, Ibata Y. Localization of the sensory neurons in the canine nodose ganglion sending fibers into the internal branch of the superior laryngeal nerve. Eur Arch Otorhinolaryngol 1991;248:265-7.

11. Helke CJ, Niederer AJ. Studies on the coexistence of substance P with other putative transmitters in the nodose and petrosal ganglia. Synapse 1990;5:144-51.

12. Cadieux A, Springall DR, Mulderry PK, et al. Occurrence, distribution and ontogeny of CGRP immunoreactivity in the rat lower respiratory tract: effect of capsaicin treatment and surgical denervations. Neuroscience 1986;19:605-27.

13. Lundberg JM, Hökfelt T, Martling C-R, Saria A, Cuello C. Substance P–immunoreactive sensory nerves in the lower respiratory tract of various mammals including man. Cell Tissue Res 1984;235:251-61.

14. Dey RD, Altemus JB, Zervos I, Hoffpauir J. Origin and colocalization of CGRP- and SP-reactive nerves in cat airway epithelium. J Appl Physiol 1990;68:770-8.

15. Ishida-Yamamoto A, Tohyama M. Calcitonin gene-related peptide in the nervous tissue. Prog Neurobiol 1989;33:335-86.

16. Helke CJ, Hill KM. Immunohistochemical study of neuropeptides in vagal and glossopharyngeal afferent neurons in the rat. Neuroscience 1988;26:539-51.

POSITRON EMISSION TOMOGRAPHY IN THE EVALUATION OF LARYNGEAL CARCINOMA

W. FREDERICK MCGUIRT, MD
KATHRYN M. GREVEN, MD
JOHN W. KEYES, JR, MD
DANIEL W. WILLIAMS III, MD
NAT E. WATSON, JR, MD
KIM R. GEISINGER, MD
JAMES O. CAPPELLARI, MD
WINSTON-SALEM, NORTH CAROLINA

Positron emission tomography (PET) is a relatively new radiologic imaging technique based on glucose analog uptake and metabolism in tumor tissue. In this study, PET was used in evaluating 38 patients with laryngeal cancer. Twenty-five patients were examined with PET prior to treatment to study the reliability of PET in identifying the primary tumor and assessing regional nodal status; 13 patients who had previously received irradiation with curative intent and who represented differential diagnostic problems were imaged to differentiate between irradiation effects and recurrent or residual cancer. Findings for both groups were compared to results of clinical evaluation and those of computed tomography (CT) and magnetic resonance imaging (MRI). The PET results were essentially identical to those of CT, MRI, and clinical evaluation in identifying metastatic lesions (82% correct), and were as reliable as CT and MRI for correctly identifying primary tumors (88%). Positron emission tomography was most helpful in differentiating recurrent tumor from postirradiation tissue sequelae. However, its lack of anatomic detail made PET less valuable for primary staging and therapeutic planning. It may enhance the diagnostic accuracy of CT and MRI where anatomic distortions occur or where diagnostic criteria for CT and MRI are ambiguous.

KEY WORDS — cervical metastases, laryngeal carcinoma, laryngeal radionecrosis, positron emission tomography.

INTRODUCTION

In making treatment decisions for patients with laryngeal carcinoma, two areas of concern are 1) identification and management of occult and manifest nodal disease and 2) differentiation between tumor recurrence and postirradiation soft tissue sequelae.

Positron emission tomography (PET) is a functional imaging modality that can demonstrate differences in tissue metabolism. A radioisotope is affixed to a glucose analog, and areas of increased glucose uptake and increased metabolism can be seen on the PET images. Several investigators have reported the utility of 2-(fluorine-18)fluoro-2-deoxy-D-glucose (FDG-PET) in imaging head and neck carcinoma and regional metastases.[1-5]

Computed tomography (CT) or magnetic resonance imaging (MRI) frequently does not accurately predict disease recurrence after radiation treatment.[6] One clinically accepted indication for PET is distinguishing recurrent cerebral tumor from normal tissue changes after radiotherapy.[7-13] One study[10] showed FDG-PET to have an overall accuracy of 84%, and positive and negative predictive values of 79% and 89%, respectively.

Chaiken et al[5] studied postirradiation PET scans in 15 patients. Persistent or recurrent disease was found in 6 of 7 patients (86%) in whom FDG activity was elevated after irradiation.

In our study of two groups of patients with squamous cell carcinoma of the larynx, we compared PET findings to those of CT and MRI, as well as clinical evaluation for 1) pretreatment assessment of primary and metastatic disease and 2) posttreatment differentiation between radiation-related tissue sequelae and recurrent carcinoma.

MATERIALS AND METHODS

Thirty-eight patients with a clinical diagnosis of laryngeal carcinoma who were examined at the head and neck tumor clinic at our institution were enrolled in an institutionally approved research protocol. Twenty-five (group 1) were studied before definitive therapy; 13 with diagnostic problems (group 2) had previously undergone irradiation with curative intent at least 3 months earlier, but abnormal clinical soft tissue findings suggested recurrent cancer or radionecrosis.

From the Department of Otolaryngology (McGuirt), Radiology (Greven, Keyes, Williams, Watson), and Pathology (Geisinger, Cappellari), The Bowman Gray School of Medicine of Wake Forest University, Winston-Salem, North Carolina.

Presented at the meeting of the American Laryngological Association, Palm Beach, Florida, May 7-8, 1994.

REPRINTS — W. Frederick McGuirt, MD, Dept of Otolaryngology, The Bowman Gray School of Medicine, Medical Center Blvd, Winston-Salem, NC 27157-1034.

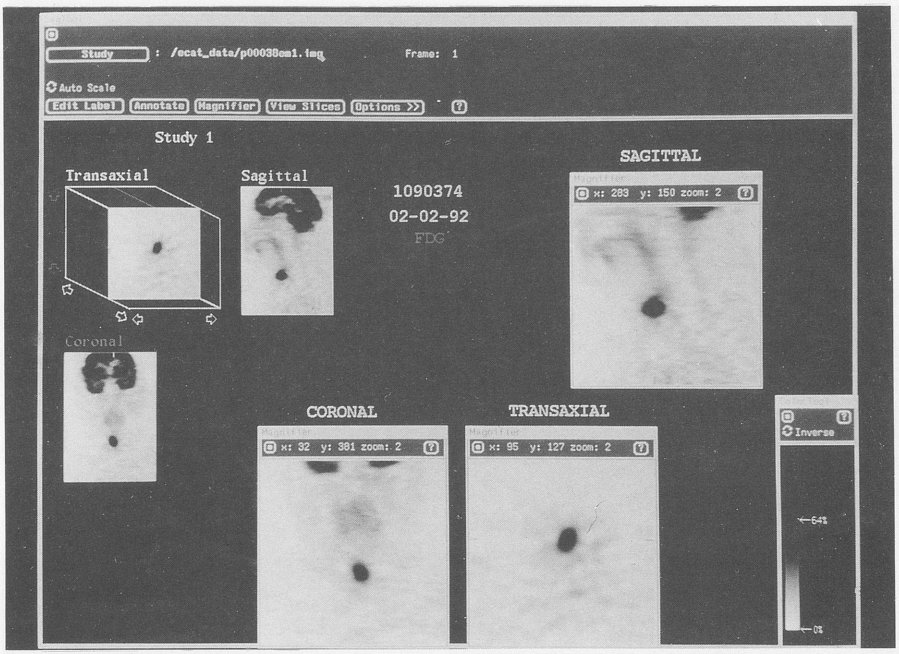

Fig 1. PET scan shows early laryngeal carcinoma (T1N0).

The CT or MRI images were obtained for all patients at the time of their PET examinations. The CT scans were performed with the GE 9800 Advantage Scanner with infusion of gadolinium and with 3-mm cuts at 3-mm intervals through the larynx and at 5-mm intervals below the larynx. The CT criteria for nodal positivity included central lucency (necrosis), size >1.5 cm, and irregular margins. The MRI scans were performed with the GE Signa 1.5-T scanner with infusion of gadolinium at 3-mm intervals.

All patients had clinical examinations and the 25 group 1 patients had tumor staging (4 T1, 7 T2, 10 T3, and 4 T4). Twenty-seven neck dissections were performed in 17 patients, after which the nodes were analyzed pathologically.

The PET studies were performed on a Siemens ECAT 951 unit (Siemens Medical Systems, Hoffman Estates, Ill) 45 minutes after the patient was injected with 10 mCi of FDG. The total scanning time was approximately 30 minutes. Images were corrected for attenuation by using a transmission scan of the patient obtained before the injection of FDG.

The PET images were displayed directly on a computer that showed the entire scan volume in three orthogonal planes (transaxial, coronal, and sagittal), as well as a ciné three-dimensional display. Lesions were identified and subjectively characterized in relationship to normal anatomy and surrounding tissue uptake. The standard uptake value (SUV) is the amount of radiotracer in a region normalized by the injected dose and the patient's body mass. The SUVs were calculated for any tissues that demonstrated increased radiotracer uptake. The PET images were displayed and regions were drawn snugly around areas of interest. The average and the maximal SUVs were recorded for each region.

Each pathology specimen was analyzed by one or the other of our two pathology colleagues (K.R.G. or J.O.C.).

RESULTS

Group 1. In 22 of the 25 patients (88%) in this pretreatment group, the primary tumor was correctly identified on the basis of PET findings (Fig 1). There was 1 false-negative (4%) result, and results were equivocal in 2 patients (8%). All 3 lesions not clearly identified were in the supraglottic region. One patient had synchronous primary tumors of the head and neck that were identified clinically, but only 1 of the 2 tumors was identified with PET.

The PET determination of neck nodal status was correlated with pathology findings in 27 neck specimens from 17 patients who later underwent surgery. The PET findings agreed with the pathology findings in 22 of 27 specimens (81%), were false-positive in 3 of 27 specimens, and were equivocal in 2 of 27 specimens.

In 22 of 27 neck specimens (81%), the results of CT and MRI also agreed with the pathology results as to the presence or absence of metastatic disease; 3 others were false-positive; 1 was false-negative; and 1 was equivocal by CT criteria. The CT and MRI demonstrated the primary lesion in 21 of 24 cases (87.5%), were equivocal in 1 case, and were false-negative in 2 cases. Only 1 of the 2 primary lesions

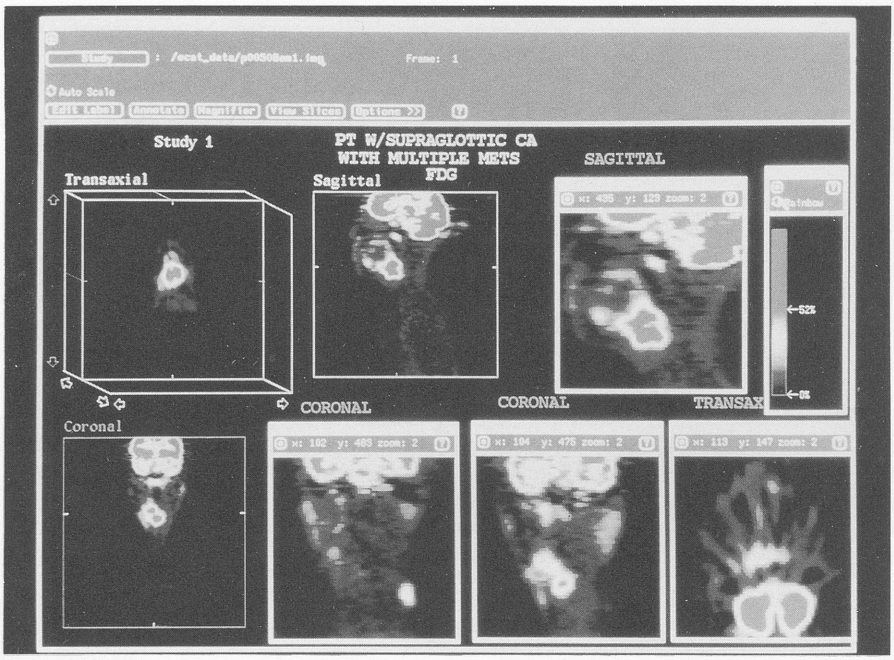

Fig 2. PET scan delineates advanced supraglottic laryngeal carcinoma with bilateral metastatic neck nodes (T3N2b).

was identified in the patient with synchronous primary lesions.

The correlation of PET with CT and MRI for neck nodal disease was 19 of 23 (4 neck specimens did not have CT or MRI studies; Fig 2). Where there were discrepancies in diagnosis, pathology specimens were available for 3 patients; 2 of these cases had been accurately predicted by PET, and 1 had been accurately predicted by CT.

All primary lesions and the simultaneous double primary tumors were identified clinically, and this was the method by which patients were entered into the study. One patient subsequently was found to have a granuloma rather than a carcinoma; therefore, the clinical false-positive ratio was 1 to 27 (3.7%). Clinical and pathologic assessment of nodal status agreed in 21 of 27 cases (78%); there were 4 false-positive (15%) and 2 false-negative (7%) diagnoses.

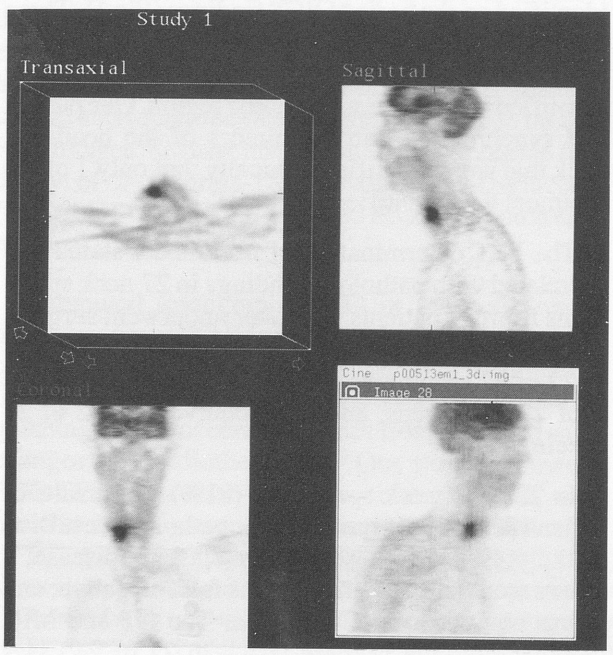

Fig 3. PET scanning for diagnostic dilemma: recurrent carcinoma versus radionecrosis. Scan is positive for recurrent carcinoma.

Group 2. Of the 13 posttreatment patients with the diagnostic dilemma of recurrent cancer versus postirradiation soft tissue changes, PET results correctly differentiated 11 (Figs 3 and 4). The PET study was equivocal in 1, and led to 1 false-negative diagnosis in a patient who was studied 2 months prior to resection. The last patient had a single microfocus of cancer found on whole-organ serial sectioning in an area distant from the area of radionecrosis when the nonfunctional larynx was removed because of aspiration and airway obstruction. Seven patients had recurrent or residual cancer confirmed by pathologic examination, 1 patient had no cancer by examination of the surgically removed dysfunctional larynx, and 5 patients, in whom the larynx had been salvaged, had no cancer on long-term clinical follow-up for more than 2 years.

The SUVs were determined for all patients. Patients with recurrent tumor had average SUVs ranging from 4.9 to 10.7 and maximal values ranging from 5.3 to 11.9. Patients in whom no recurrence has been detected had average values of 2.4 to 4.7 and maximal values ranging from 3.0 to 5.4.

Computed tomography or MRI studies were available for 12 of the 13 patients: 7 of the 12 studies were

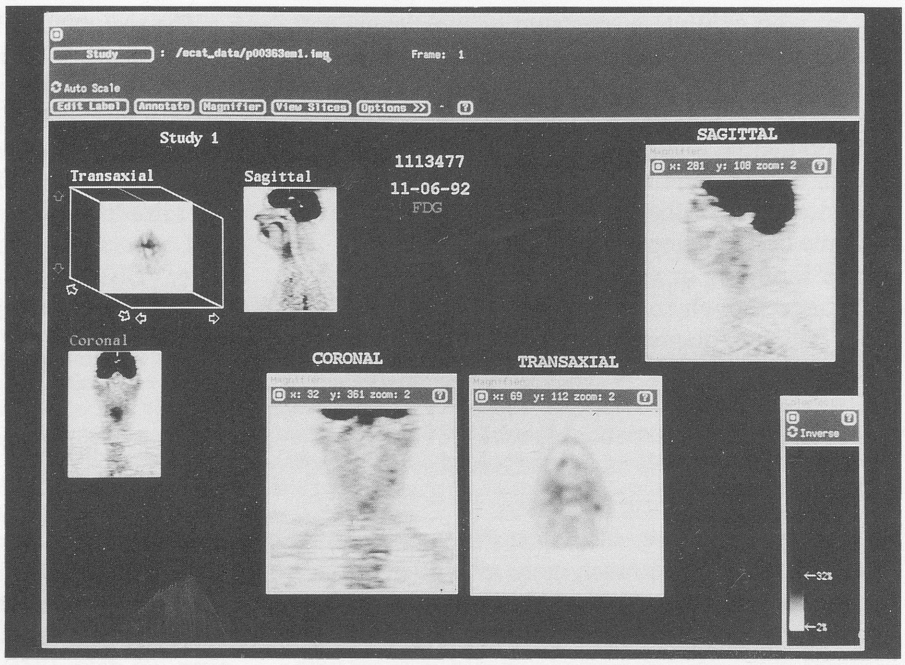

Fig 4. PET scanning for diagnostic dilemma: recurrent carcinoma versus radionecrosis (based on subjective and objective standard uptake values and ratios). Scan indicates laryngeal radionecrosis but positive nodal (left-sided) metastases, confirmed pathologically.

reported to be equivocal for tumor recurrence or persistence. In 5 (42%) of the 12 recurrent or residual cancers with available CT or MRI studies, a mass was detected that was believed to represent recurrent cancer in addition to the postirradiation changes (see Table).

DISCUSSION

In this study, the results of PET were comparable to those of CT or MRI with respect to positive identification of the primary tumor. However, as regards primary tumor identification, none of these modalities is yet as sensitive or as specific as clinical direct and indirect examinations.

One problem with PET is that resolution to 6 mm appears to be the limit of current equipment and techniques. The supraglottic region appears to present the greatest diagnostic difficulties. Low tumor volume in small, superficial lesions is one limiting factor, but difficulty in imaging tumors in this area is also related to the fact that FDG is secreted in saliva. This saliva pools in the valleculae and pyriform sinuses and may falsely elevate background uptake in those areas. Currently, quantification of this background uptake with SUVs is being studied.

ACCURACY IN EVALUATING LARYNGEAL CARCINOMA

Study	*Primary Lesions*	*Nodal Disease**	*Radionecrosis vs Carcinoma*
PET	22/25 (88%)	22/27 (81%)	11/13 (85%)
CT or MRI	21/24 (88%)	22/27 (81%)	5/12 (42%)
Clinical impression	24/25 (96%)	21/27 (78%)	

*Confirmed by pathology.

Another major deficiency of PET scanning is its lack of anatomic definition of lesion site and extent. These two determinants are key points in correct staging of tumors, in deciding if conservation surgical techniques are possible, and in selecting the appropriate treatment modality; ie, invasion of the preepiglottic space by supraglottic carcinoma may contraindicate radiotherapy, and glottic extension of supraglottic tumor militates against classic supraglottic conservation techniques.

The PET results and those of CT and MRI were comparable for establishing the presence or absence of nodal metastases and were slightly superior to the findings of clinical examination alone. Either form of imaging is potentially more beneficial in the postirradiated patient and the obese or muscular patient, in whom deep neck nodal metastases may be difficult to differentiate clinically. Information obtained with PET may prove to be additive to that obtained with CT in the equivocal case of marginal-size nodes (<1.5 cm) or a node with a small radiolucency that could represent either hilar fat or metastatic tumor.

Currently, PET studies cost 1 1/2 times as much as CT studies. Until either the cost is reduced or the results improve to show clear superiority, PET should remain an investigational modality for metastatic neck adenopathy. Currently, it is available when needed to help define the otherwise equivocal case.

Where PET is clearly superior to the clinical examination and to CT or MRI is in the postirradiation

patient who exhibits a spectrum of worrisome soft tissue changes ranging from persistent or excessive laryngeal edema, through ulcerated or granular endolaryngeal soft tissue changes, to perilaryngeal neck erythema, edema, and tenderness. Biopsy, although usually required for diagnosis, is frequently equivocal. Often, the surgeon is reluctant to obtain multiple or deep biopsy specimens in such cases for fear of initiating or aggravating radionecrosis. This reluctance, though, must be tempered by the possibility of failing to diagnose recurrent or residual cancer and thereby allowing it to progress while medical measures are utilized. If soft tissue or cartilage necrosis can be distinguished reliably with PET, the larynx may be salvageable through tracheostomy with antibiotics, hyperbaric oxygen, and cartilage debridement.

In this series of patients, while PET was not uniformly correct, it was much more reliable in providing the correct diagnosis than either clinical evaluation or CT and MRI. The single false-negative diagnosis involved a microfocus of tumor in a patient who had undergone PET 2 months earlier and who had progression of radionecrosis after negative biopsy results. The positive focus was found distant from the clinical area of suspicion and distant from the original tumor site.

The accuracy of PET in differentiating tumor from postirradiation tissue changes (85%) was essentially identical to that reported by Valk and Dillon[10] for brain tumors (84%). Therefore, PET is a valuable diagnostic tool in such cases. Analysis of postirradiation PET studies indicates that FDG uptake 1 month after irradiation is not reliable to differentiate persistent tumors[13] and has a high incidence of false negativity. Differentiation is more reliable 4 or more months postirradiation.

SUMMARY

Positron emission tomography is an effective tool for identifying primary laryngeal carcinoma and establishing the presence or absence of nodal metastatic disease in these patients. Currently, it is equal to CT or MRI and clinical examination for evaluating neck disease. It has not been useful in identifying early primary disease in the supraglottic region, however. To date, PET lacks sufficient anatomic detail relative to the primary tumor, and therefore has limited use in therapeutic planning. The major advantage of PET at this time in the management of laryngeal cancer is in the differentiation of recurrent cancers from postirradiation soft tissue sequelae.

REFERENCES

1. Jabour BA, Choi Y, Hoh CK, et al. Extracranial head and neck: PET imaging with 2-[F-18]fluoro-2-deoxy-D-glucose and MR imaging correlation. Radiology 1993;186:27-35.

2. Rabinov K, Kell T Jr, Gordon PH. CT of the salivary glands. Radiol Clin North Am 1984;22:145-59.

3. Minn H, Joensuu H, Ahonen A, Kelmi P. Fluorodeoxyglucose imaging: a method to assess the proliferative activity of human cancer in vivo. Comparison with DNA flow cytometry in head and neck tumors. Cancer 1988;61:1776-81.

4. Bailet JW, Abemayor E, Jabour BA, Hawkins RA, Ho C, Ward PH. Positron emission tomography: a new, precise imaging modality for detection of primary head and neck tumors and assessment of cervical adenopathy. Laryngoscope 1992;102:281-9.

5. Chaiken L, Rege S, Hoh C, et al. Positron emission tomography with fluorodeoxyglucose to evaluate tumor response and control after radiation therapy. Int J Radiat Oncol Biol Phys 1992;24(suppl 1).

6. Harnsberger H, Mancuso A, Muraki A, Parkin J. The upper aerodigestive tract and neck: CT evaluation of recurrent tumors. Radiology 1983;149:403-9.

7. Di Chiro G, Brooks RA. PET-FDG of untreated and treated cerebral gliomas [Letter]. J Nucl Med 1988;29:421-2.

8. Di Chiro G, Hathazaa J, Katz DA, Rizzoli HV, De Michele DJ. Glucose utilization by intracranial meningiomas as an index of tumor aggressivity and probability of recurrence: a PET study. Radiology 1987;164:521-6.

9. Di Chiro G, Oldfield E, Wright DC, et al. Cerebral necrosis after radiotherapy and/or intraarterial chemotherapy for brain tumors. PET and neuropathologic studies. AJR 1988;150:189-97.

10. Valk PE, Dillon WP. Radiation injury of the brain. AJNR 1991;12:45-62.

11. Ichiya Y, Kuwabara Y, Otsuka M, et al. Assessment of response to cancer therapy using fluorine-18-fluorodeoxyglucose and positron emission tomography. J Nucl Med 1991;32:1655-60.

12. Minn H, Paul R, Ahonen A. Evaluation of treatment response to radiotherapy in head and neck cancer with fluorine-18 fluorodeoxyglucose. J Nucl Med 1988;29:1521-5.

13. Greven KM, Williams DW III, Keyes JW Jr, et al. Positron emission tomography of patients with head and neck carcinoma before and after high-dose irradiation. Cancer 1994;74:1355-9.

ENDOSCOPIC VOCAL FOLD MICROFLAP: A THREE-YEAR EXPERIENCE

MARK S. COUREY, MD
R. EDWARD STONE, PHD
GLENDON M. GARDNER, MD
ROBERT H. OSSOFF, DMD, MD

NASHVILLE, TENNESSEE

Surgical techniques for the removal of vocal fold (VF) disorders that arise within the lamina propria must permit the preservation and/or restoration of VF vibratory characteristics. The endoscopic VF microflap is designed to do such. A retrospective study was undertaken to evaluate the efficacy of this procedure. Forty microflaps (7 bilateral, 1 revision) were performed on 32 patients. Charts and surgical pathology findings were reviewed. Preoperative and 3-month postoperative video recorded voice samples and stroboscopic examination results were compared. Findings on perceptual voice analysis did not significantly change. Stroboscopic examinations revealed improved postoperative VF closure in 27 of 29 patients with impaired preoperative closure and return of mucosal wave in 18 of 24 VFs operated on for the excision of cysts or polyps. When present preoperatively (6 patients), the mucosal wave was preserved. Most patients (28 of 30) rated themselves as clinically improved. The endoscopic VF microflap is efficacious in the treatment of selected VF disorders. The surgical technique is discussed.

KEY WORDS — glottis, laryngeal microflap, mucosal wave, polypoid corditis, Reinke's edema, vocal fold cyst.

INTRODUCTION

Since the initial popularization of the anatomy of the leading edge of the vocal fold by Minoru Hirano in the mid-1970s, and the development of an improved understanding of glottic vibratory cycles through the work of Titze and Talkin[1] and Titze[2] in the late 1970s, laryngologists have labored to find improved methods for the excision of benign vocal fold lesions. One unifying concept has emerged: excision of the lesion with as little disruption to the surrounding normal tissue as possible is desirable.

Most benign disorders of the true vocal folds arise within the superficial layer of the lamina propria.[3] Thus, with knowledge of the anatomy, the concept of microflap surgery arose. The microflap technique was designed to develop a surgical plane within the superficial layer of the lamina propria that would allow access to the root of the lesion while preserving the relatively uninvolved mucosal cover. The preserved mucosal cover would then protect the underlying vibratory structures. Theoretically, this should aid in the preservation or return of the mucosal wave after excision of the lesion. In addition, healing would be more rapid, as wounds could be closed primarily, without the need for remucosalization by secondary intention as required after vocal fold stripping.

The technique of vocal fold microflap surgery has been reported in the literature.[4-6] To date, however, no evaluation of outcome, in a systematic manner, has been reported to assess the utility of this procedure. Furthermore, the absence of an accessible animal model with a layered lamina propria precludes scientific, prospective animal studies. Therefore, this study was undertaken in a retrospective manner to assess the efficacy of vocal fold microflap surgery.

METHODS AND MATERIALS

A chart review of adult patients who had undergone vocal fold microflap surgery by the senior author (R.H.O.) between May 1990 and May 1993 was undertaken. Charts of all patients who had undergone direct microlaryngoscopy were examined and operative reports reviewed. If the operative report stated that an incision was made on the superior surface of the vocal fold, and a mucosal flap was elevated, the patient was considered to have undergone microflap surgery. Patients who had undergone excision of the microflap itself, for dysplasia or carcinoma, were excluded. Thirty-two patients were identified for the study period. Seven had undergone bilateral procedures, and 1 required a revision. Therefore, there were 40 microflap procedures completed.

The microflap operative technique used started with an incision on the superior surface of the vocal fold near the ventricle. The incision was made with a small sickle knife (see Figure, A). It was then further defined with up-cutting 2-mm microscissors (see

From the Department of Otolaryngology, Vanderbilt University Medical Center, Nashville, Tennessee.

Presented at the meeting of the American Laryngological Association, Palm Beach, Florida, May 7-8, 1994.

REPRINTS — Robert H. Ossoff, DMD, MD, Dept of Otolaryngology, Vanderbilt University Medical Center, MCN S-2100, Nashville, TN 37232-2559.

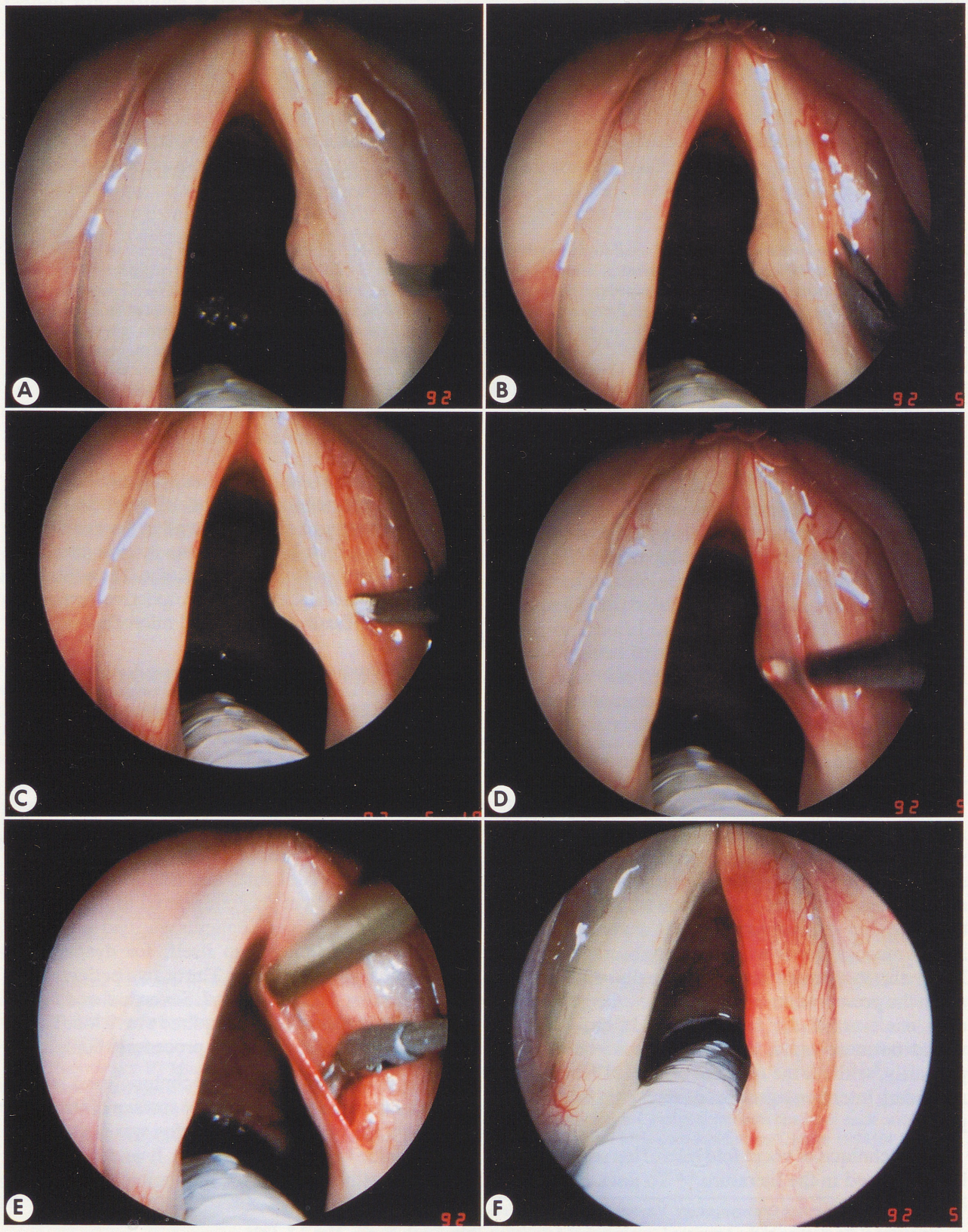

(Patient 7) Microflap procedure. A) Vocal fold with cyst. Microsickle knife for mucosal incision. B) Microscissors defining incision. C) Flap elevator defining plane within superficial layer of lamina propria. D) Dissection between lesion and vocal fold cover. E) Dissection of lesion from vocal ligament. F) Mucosal microflap redraped in position.

Figure, B). A blunt right-angled flap elevator was inserted through the incision and used to elevate the mucosal flap through the superficial layer of the lamina propria (see Figure, C). The lesion was dissected free from the mucosal cover (see Figure, D) and the underlying vocal ligament (see Figure, E). Once the lesion was excised, the field was inspected for complete removal. Corticosteroids were injected under the flap to theoretically reduce scar formation, and the flap was redraped to cover the undisturbed vocal ligament (see Figure, F).

All preoperative and postoperative chart notes were reviewed. When available (28 of 32), actual preoperative and 3-month postoperative videostroboscopic examinations were reviewed and reevaluated for the presence or absence of a mucosal wave on the involved vocal fold(s) and for changes in preoperative and postoperative glottic closure. If there was any question with regard to the actual presence of the mucosal wave, it was considered as absent. If there was a disagreement among the surgical authors, the tape was reviewed by a speech-language pathologist and the majority decision was taken. Secondary to the authors' familiarity with the subjects, it was not possible to review the video recordings in a blinded manner. When video film was not available (4 of 32), assessments were taken from chart notes made by the speech-language pathologists and operating surgeon.

Voices of 15 patients with available preoperative and postoperative audio recordings were evaluated on a perceptual scale. These recordings had been recorded on Super VHS tape with a microphone 20 cm from the patient's mouth. The recording room had been sound treated. Recordings were reviewed by a panel of three judges and a consensus rating was given. Again, secondary to the authors' familiarity with the subjects, it was not possible to perform perceptual analysis in a blinded manner. Voices were graded for pitch (fundamental frequency), intensity, timing, and quality by means of a four-point ordinal scale (0, normal; 1, abnormality noticeable to a professional looking for it; 2, abnormality noticeable to an unskilled observer when it is pointed out; 3, abnormality readily noticeable to nearly everyone). These results were then statistically analyzed by means of the Wilcoxon matched-pairs signed-ranks test for nonparametric data.

RESULTS

Forty microflaps were performed in 32 patients (see Table). Vocal fold disorders for which the microflap was employed included cyst (19), polypoid corditis (9), scar tissue, including cases that involved the entire membranous cord (5), and hemorrhagic polyp (7).

Review of preoperative stroboscopic data showed absence of a mucosal wave in 31 of 38 vocal folds. Stroboscopic data were not obtained in 1 patient with massive polypoid corditis (patient 23). Of these 31 vocal folds, return of the mucosal wave, after excision of the lesion by the microflap technique, was apparent in 18. None of the patients with massive polypoid corditis evidenced return of the mucosal wave postoperatively. Therefore, if this histologic diagnosis category is eliminated from the sample, then return of the wave was evident in 18 of 24 vocal folds.

Five patients (patients 15, 17, 23, 28, and 29) had polypoid degeneration involving 9 vocal folds. All of them underwent microflap excision. While subjective voice improvement was apparent in all these patients, none of them evidenced return of a mucosal wave. Glottic closure appeared to be improved. This was usually secondary to a diminution in the size of the posterior glottic gap.

Preoperatively, glottic closure was documented and evaluated stroboscopically in 31 of 32 patients. Two patients were lost to follow-up prior to 3 months postoperatively (patients 3 and 32). Therefore, changes in glottic closure could only be assessed in 29 patients. All 29 patients had impaired glottic closure preoperatively. Twenty-six of these 29 patients evidenced improvement in closure postoperatively. Two patients showed no change in their closure pattern (patients 6 and 18). One patient with bilateral vocal fold cysts showed bowing of the vocal folds with widening of the glottic gap on stroboscopy despite return of the mucosal wave bilaterally (patient 13).

Seven patients had an intact mucosal wave preoperatively. One of these patients was lost to follow-up (patient 3). Of the remaining 6, all had preservation or improvement of the mucosal wave, in comparison to the preoperative stroboscopic evaluation (microflaps 9, 10, 21, 25, 31, and 36; see Table).

Analysis of the perceptual ratings by the Wilcoxon matched-pairs signed-ranks test for nonparametric data did not reveal statistically significant changes for any of the parameters judged. Through candid interviews, patients were asked if they were satisfied with their voices postoperatively when compared to their preoperative vocal capabilities. Twenty-eight of 30 patients rated themselves as improved. Two patients were lost to follow-up, 1 patient (patient 13) rated herself as worse, and 1 patient (patient 27) felt there was no significant change. Patient 13 is presently working with our department of speech-language pathology and vocal pedagogy. She continues to make improvements. Now, 1 year postoperatively, she is singing at a level that is subjectively improved

PATIENT INFORMATION

Patient No.	*Microflap No.*	*Mucosal Wave*		*Pathology*	*Glottic Closure*		*Subjective Improvement*
		Preop	*Postop*		*Preop*	*Postop*	
1	1	Absent	Absent	Cyst	A-P gap	Intact	Yes
2	2	Absent	Present	Cyst	A-P gap	Intact	Yes
3	3	Present	†	Polyp	Intact	†	†
4	4	Absent	Present	Cyst	A-P gap	Intact	Yes
5	5	Absent	Absent	Cyst	A-P gap	Intact	Yes
6	6	Absent	Absent	Scar	A gap	A gap	Yes
7	7	Absent	Present	Cyst	A-P gap	Intact	Yes
8	8	Absent	Present	Polyp	A-P gap	Intact	Yes
9	9	Present	Present	Polyp	A-P gap	Intact	Yes
10	10	Present	Present	Polyp	A-P gap	Intact	Yes
11	11	Absent	Absent	Scar	A-P gap	Intact	Yes
12	12	Absent	Present	Scar	Intact	Intact	Yes
13	13	Absent	Present	Cyst	A-P gap	Worse	Worse
	14	Absent	Present	Cyst			
14	15	Absent	Present	Cyst	A gap	Intact	Yes
15	16	Absent	Absent	Corditis	Open	Improved	Yes
16	17	Absent	Present	Cyst	Intact	Intact	Yes
	18	Absent	Present	Cyst			
17	19	Absent	Absent	PC	Large P gap	Improved	Yes
	20	Absent	Absent	PC			
18	21	Present	Present	Cyst	Open slit	Open slit	Yes
19	22	Absent	Absent	Cyst	A-P gap	P gap	Yes
	23	Absent	Present	Cyst	A-P gap	Intact	
20	24	Absent	Present	Scar	P gap	Improved	Yes
21	25	Present	Present	Polyp	A-P gap	Intact	Yes
22	26	Absent	Present	Cyst	A-P gap	Intact	Yes
23	27	*	*	PC	*	*	Yes
	28	*	*	PC	*	*	
24	29	Absent	Present	Cyst	A-P gap	Intact	Yes
	30	Absent	Present	Cyst			
25	31	Present	Present	Polyp	A-P gap	Intact	Yes
26	32	Absent	Present	Scar	A gap	Improved	Yes
27	33	Absent	Present	Cyst	A-P gap	Intact	No
28	34	Absent	Absent	PC	Large P gap	Improved	Yes
	35	Absent	Absent	PC			
29	36	Present	Present	Polyp	P gap	Improved	Yes
30	37	Absent	Present	Cyst	Middle gap	Intact	Yes
31	38	Absent	Absent	PC	P gap	Improved	Yes
	39	Absent	Absent	PC			
32	40	Absent	†	Cyst	A-P gap	†	†

PC — polypoid corditis, A — anterior, P — posterior.
*Videostroboscopic examination not available.
†Lost to follow-up prior to 3 months postoperatively.

from her preoperative capabilities. Patient 27 has not followed up with us since his 4-month postoperative visit. At that examination, he was functioning at a level comparable to his preoperative capabilities.

DISCUSSION

Better understanding of vocal fold anatomy and physiology has spurred the development of surgical techniques for the removal of vocal fold lesions that arise within the lamina propria. The endoscopic microflap technique employs microsurgical principles to elevate and preserve the vocal fold cover while excising the submucosal lesion. Theoretically, this technique has advantages over other techniques in which the normal overlying mucosa is excised. The preserved mucosa provides a primary cover for the

remaining lamina propria and promotes primary wound closure as opposed to healing by secondary intention. Also, placing the mucosal incision laterally, over the superior surface of the vocal fold, as opposed to near the lesion, removes the incision site from the medial surface or vibratory edge of the vocal fold, theoretically reducing the risk of scar formation. One last advantage of the lateral microflap technique is that is allows for the identification of the vocal ligament away from the area of disease, thus reducing the risk of injury to the vocal ligament secondary to difficulty in identification. This is most significant in cases with severe scarring or with intimate attachment of a submucosal lesion to the vocal ligament.

The microflap technique is predicated on the histology of the lamina propria. The human lamina propria can be divided into three layers. These layers are not defined by fascial planes, but rather, are determined by the concentration of elastin and collagen fibers.[7,8] These elastin and collagen fibers, as well as blood vessels, run parallel to the free edge of the vocal fold. The basement membrane zone of the vocal fold mucosa is connected to the superficial layer of the lamina propria by an intricate series of proteins.[7,8] The microflap is therefore elevated through the superficial layer of the lamina propria. This results in preservation of the elastic fibers within the intermediate layer of the lamina propria, and does not disrupt the basement membrane zone or the blood supply of the mucosal membrane. Blood vessels running parallel to the free edge of the vocal fold can be readily seen within the semitransparent microflap.

Over the last 3 years, the microflap technique has been employed in the previously described patients. Disorders appropriate for the selection of this technique include vocal fold cysts, broad-based vocal fold polyps with normal-appearing overlying mucosa, severe submucosal scarring, and polypoid degeneration. The results have been encouraging. While not returning to 100% normal, the majority of vocal folds have regained a mucosal wave that is, at worst, only moderately reduced. In patients in whom a minimal mucosal wave returned postoperatively, voice results were still encouraging. We attributed vocal improvement to improved glottic closure obtained from creating a straighter vocal fold edge on the diseased fold(s).

This technique appeared to be particularly useful when applied to patients with submucosal scarring, broad-based polyps, and vocal fold cysts. Eighteen of these 24 vocal folds showed return of the mucosal wave when it was absent preoperatively. Of interest, no patients treated for polypoid corditis (Reinke's edema) experienced return of the mucosal wave. This finding is most likely secondary to the nature of polypoid corditis, which is unlike other vocal fold polyps. Polypoid corditis does not appear to be associated with vocal abuse, but is intimately associated with cigarette smoking. Grossly, the vocal folds are sausage-shaped, and the disease process involves the entire membranous vocal fold. Portions of the overlying epithelium may become hyperkeratotic. Treatment is aimed at excision of the polypoid changes that involve, or have replaced, the superficial layer of the lamina propria. Surgical treatment, with mucosal preservation, allows simultaneous treatment of both vocal folds with minimal risk of web formation. In addition, the microflap excision technique facilitates proper identification of the vocal ligament and minimizes the risk of inadvertent injury. Comparison of surgical techniques indicates that excision via the microflap technique results in the shortest duration of postoperative dysphonia.[9]

Regardless of mode of treatment, the superficial layer of the lamina propria has been replaced by a myxomatous stroma through the disease process, and must be removed. Loss of the loose areolar connective tissue is permanent. The mucosa attaches directly to the intermediate layer of the lamina propria, and the mucosal wave does not return. Perceptually and subjectively, these patients' voices returned toward normal, most likely because of a reduction in vocal fold mass with improved glottic closure. These results are consistent with other published reports on results of treatment for Reinke's edema,[9,10] although none of these studies has reported postoperative stroboscopic findings.

Microflap elevation and lesion excision on vocal folds with intact mucosal waves preoperatively resulted in preservation of the mucosal wave in all cases. This technique, therefore, is well applied to broad-based vocal fold lesions on which the overlying mucosa appears relatively normal, and in lesions that are difficult to distinguish from the vocal ligament. As previously stated, by making the incision laterally on the vocal fold, away from the site of disease, the ligament is more easily identified and is less likely to be injured. Injury to the vocal ligament can produce scarring with permanent dysphonia. For this reason, we advocate this technique for broad-based lesions over the technique described by Monday et al[11,12] and Bouchayer and Cornut,[13] in which the mucosal incision is placed next to the lesion.

Postoperative vocal rehabilitation and/or vocal reeducation is employed in all of our surgical cases. Rehabilitation is divided into four phases. Phase 1 consists of an initial 2-week period of complete voice rest after surgery. Opponents of prolonged voice rest

cite vocal fold atrophy and patient emotional trauma as reasons not to use it.[14] In 3 years and in multiple patients, we have not subjectively witnessed vocal fold atrophy. In addition, our patients are committed to their postoperative therapy and are emotionally prepared for the postoperative voice rest phase. Fourteen days of voice rest was chosen for two reasons. First, the microflap is not sutured in place; therefore, 14 days of voice rest allows minimal activity for wound disruption while collagen cross-linking is at its weakest point. By 14 days after surgery, collagen cross-linking is on a steady incline and the risk of displacement of the microflap is decreased. Second, surgical manipulation of the vocal fold leads to edema and induration. Overuse of an edematous or stiff vocal fold may lead to the development of functional vocal disorders.

At 2 weeks postoperatively, phase 2 begins. Stroboscopic examination usually reveals an edematous, stiff vocal fold. Traces of upper and lower lip formation as well as a superior surface wave are often identified. The patient is instructed off voice rest and is allowed to use the voice for 5 minutes the first day. This is doubled on a daily basis until the patient is back to full conversational use by the end of the fourth postoperative week. The patient is instructed to observe for hoarseness or neck pain with use. If these symptoms develop, then the patient is asked to reduce vocal activity.

Phase 3 incorporates postoperative weeks 5 through 12. At 1 month, examination usually reveals an improvement in upper and lower lip formation with return of the mucosal wave. Vocal rehabilitation continues and vocal coaching is instituted if appropriate. Breath management and body alignment are stressed to ensure hygienic vocal production.

Postoperative weeks 13 and beyond make up phase 4, which consists of return to full vocal activity with examination every other month for 2 years to assess the vocal fold appearance.

With the exception of patient 13, our patients have been able to adhere to the expected postoperative rehabilitation schedule. Patient 13 has had a prolonged recuperative phase. Her operation revealed bilateral vocal fold cysts with a unilateral sulcus vocalis and severe submucosal scarring. She continues to work with our vocal pedagogue and is still showing improvement in videostroboscopic findings and vocal capabilities. She is encouraged by her progress. Currently, she feels that her vocal abilities have improved since surgery, and we feel that she will continue to improve over the next year.

Over the past 3 years, using these surgical techniques with extensive postoperative rehabilitation, we have been able to obtain subjective improvement at 3 months postoperatively in 28 of 30 patients. When perceptual analysis is examined on a plus-minus scale and a sign test is employed, these results certainly reach statistical significance. The inability of our perceptual analysis system to reach statistical significance resulted from the fact that patients were placed in categories defined by physical characteristics, rather than graded by arbitrary degrees of improvement. Our classification system required the use of nonparametric analysis. Improvement was apparent to patients and ourselves, and when graded arbitrarily, it did reach statistical significance.

CONCLUSIONS

There is a great need for better understanding of vocal fold vibratory patterns and the anatomy, histology, and physiology of vocal fold vibration. This is a retrospective review of a surgical technique already in practice. It was undertaken to assess the utility of this technique for preserving or restoring mucosal vibratory patterns on the diseased vocal fold. No comparison of other techniques was undertaken. Therefore, this review cannot and is not meant to imply that this technique is better than other techniques. The review, however, does support the utility of the technique and that the microflap technique may allow certain advantages such as vocal ligament preservation, mucosal preservation, and mucosal wave restoration over other techniques. As this was a retrospective review, patients were not randomized to study groups, and blinded analysis was not possible secondary to patient, surgeon, and author familiarity.

After 3 years of continued use, it appears that the endoscopic vocal fold microflap technique is applicable to the excision of benign laryngeal lesions. Patients with vocal fold cysts, broad-based polyps, polypoid corditis, and submucosal scarring have benefited from microflap excision, and the mucosal wave returned in 18 of 24 vocal folds when it was absent preoperatively. With the exception of the condition of polypoid corditis, analysis of stroboscopic examinations shows a return of the mucosal wave in a high percentage of these patients. In addition to the restoration of the mucosal wave, improved glottic closure in 26 of 29 patients may also explain improvements in vocal capabilities, specifically when the mucosal wave was not restored. In the small number of patients with a mucosal wave present on the vocal fold preoperatively, application of the microflap technique did not disrupt the wave pattern postoperatively. Subjectively, 28 of these 30 patients have been improved after undergoing excision of their vocal fold lesions through the microflap technique.

REFERENCES

1. Titze IR, Talkin DT. A theoretical study of the various laryngeal configurations on the acoustics of phonation. J Acoust Soc Am 1979;66:60-74.

2. Titze IR. Comments on the myoelastic-aerodynamic theory of phonation. J Speech Hear Res 1980;23:495-510.

3. Hirano M. Surgical anatomy and physiology of the vocal folds. In: Gould WJ, Sataloff RT, Spiegel JR, eds. Voice surgery. Chicago, Ill: Mosby Year Book, 1993:125-58.

4. Sataloff RT. The professional voice. In: Cummings CW, Fredrickson JM, Harker LA, Krause CJ, Schuller DE, eds. Otolaryngology–head and neck surgery. Vol 3. St Louis, Mo: Mosby, 1986:2029-56.

5. Courey MS, Ossoff RH. Surgical management of benign voice disorders. In: Gould WJ, Rubin J, Korovin G, Sataloff RT, eds. Diagnosis and treatment of voice disorders. New York, NY: Igaku-Shoin (in press).

6. Hirano M, Yoshida T, Hirade Y, Sanada T. Improved surgical technique for epidermoid cysts of the vocal fold. Ann Otol Rhinol Laryngol 1989;98:791-5.

7. Gray SD. Basement membrane zone injury in vocal nodules. In: Gauffin J, Hammarberg B, eds. Vocal Fold Physiology Conference. San Diego, Calif: Singular Press, 1991:21-7.

8. Gray SD, Hirano M, Sato K. Molecular and cellular structure of vocal fold tissue. In: Gauffin J, Hammarberg B, eds. Vocal fold physiology. San Diego, Calif: Singular Press, 1992:1-35.

9. Lumpkin SM, Bennett S, Bishop SG. Postsurgical follow-up study of patients with severe polypoid degeneration. Laryngoscope 1990;100:399-402.

10. Lumpkin SMM, Bishop SG, Bennett S. Comparison of surgical techniques in the treatment of laryngeal polypoid degeneration. Ann Otol Rhinol Laryngol 1987;96:254-7.

11. Monday LA, Cornut G, Bouchayer M, Roch JB. Epidermoid cysts of the vocal cords. Ann Otol Rhinol Laryngol 1983; 92:124-7.

12. Monday LA, Cornut G, Bouchayer M, Roch JB, Loire R. Diagnosis and treatment of intracordal cysts. J Otolaryngol 1981; 10:363-70.

13. Bouchayer M, Cornut G. Microsurgery for benign vocal fold lesions. Ear Nose Throat J 1988;67:446-64.

14. Ford CN, Bless DM. Phonosurgery, assessment and surgical management of voice disorders. New York, NY: Raven Press, 1991.

COMBINED THYROPLASTY TYPE I AND INFERIOR CONSTRICTOR MYOTOMY

WILLIAM W. MONTGOMERY, MD

ROBERT E. HILLMAN, PHD MARK A. VARVARES, MD

BOSTON, MASSACHUSETTS

The preoperative evaluation and technique of combined thyroplasty and inferior constrictor myotomy are described and illustrated. The results in cases in which thyroplasty type I and inferior constrictor myotomy were done as separate procedures are compared to those in cases in which thyroplasty and inferior constrictor myotomy were combined in the same operation. The end results obtained with these two approaches did not differ significantly; however, with the exception of brain stem disease, patients undergoing the combined procedure at an early date are more likely to be spared gastrostomy and aspiration pneumonia. Diseases of the brain stem (ie, stroke and metastatic disease such as breast cancer) respond poorly to an inferior constrictor myotomy. In such cases the patient can best be rehabilitated with a thyroplasty type I along with a gastrostomy or laryngeal closure procedure.

KEY WORDS — cranial nerve paralysis, inferior constrictor, larynx, myotomy, phonosurgery, thyroplasty.

Numerous disorders of the head, neck, and chest can alter phonation and deglutition. Patients with brain stem strokes and metastasis such as from cancer of the breast exhibit abnormalities of the neuromuscular components of pharyngeal swallowing: unilateral pharyngeal paralysis, unilateral vocal cord paralysis, and inferior constrictor dysfunction.

With the increasing scope of our surgical procedures, so increase the number and severity of complications. Intracranial, base of skull, cervical, and thoracic surgery can seriously alter the function of the larynx and pharynx. With upper cervical, base of skull, and intracranial surgery, the injury is at the upper vagal level, and often, other nerves supplying motor and sensory function to the larynx, pharynx, and cervical esophagus are involved. The resulting symptoms of dysphagia, aphonia, lack of cough reflex, and aspiration are quite disabling. These complications are indeed devastating and often require not only a tracheotomy but a gastrostomy.

With thoracic and lower cervical surgery, only the recurrent laryngeal nerve is involved, and the disability is limited to altered vocal function. If the vocal cord is paralyzed in the median position, there is usually no dysphonia. If the paralyzed vocal cord is in the paramedian position, there is dysphonia. Aspiration as well as dysphonia occurs when the paralyzed cord is in the abducted position.

The purpose of this paper is to present a study of the rehabilitation of patients with deficits in voice and swallowing function due to disruption of the neural supply to the larynx and pharynx. Specifically, we ask whether a tracheotomy or gastrostomy is indicated. Is it necessary to medialize the paralyzed vocal cord or section the cricopharyngeal muscle? If indicated, when should these procedures be performed? Should the vocal cord medialization procedure be performed separately, or along with the inferior constrictor myotomy?

PATIENTS AND METHODS

Two groups of patients were studied. The first was those patients treated with thyroplasty type I and inferior constrictor myotomy as separate procedures. The senior author's technique has been previously described.[1-6] The second group included those patients treated with thyroplasty type I and inferior constrictor myotomy as a combined procedure.

RESULTS

There were 10 patients in the first group, presenting with dysphagia, dysphonia, and aspiration that were treated with thyroplasty type I and inferior constrictor myotomy as separate operations. In each case the thyroplasty was performed first. The interval between operations ranged from 3 to 11 months. There were 3 patients with a lesion at the posterior fossa level. Nerves IX and X were paralyzed. All 3 required a gastrostomy. Two developed pneumonia. All 3 demonstrated weight loss. Dysphonia improved following thyroplasty type I. There was no weight gain, and dysphagia persisted. Following inferior

From the Department of Otolaryngology, Massachusetts Eye and Ear Infirmary and Harvard Medical School, Boston, Massachusetts.

Presented at the meeting of the American Laryngological Association, Palm Beach, Florida, May 7-8, 1994.

REPRINTS — William W. Montgomery, MD, Massachusetts Eye and Ear Infirmary, 243 Charles St, Boston, MA 02114.

constrictor myotomy, these symptoms were relieved. One patient required a gastrostomy for an additional 6 months.

There were 4 base of skull lesions. Nerves IX and X were paralyzed. Two patients required gastrostomies. One developed pneumonia. Two patients had weight loss. The symptoms of all 4 were relieved by the medialization procedure followed by inferior constrictor myotomy. All 4 of the patients gained weight. There were 3 with good voices and 1 with a poor voice. The gastrostomies were eliminated.

There were 3 high vagal lesions. Nerves IX and X were paralyzed. One patient required a gastrostomy. No patient had a weight loss. Symptoms of aspiration and dysphagia persisted after a medialization procedure. Dysphonia improved. Following inferior constrictor myotomy, there was no dysphagia or aspiration. The gastrostomy was eliminated.

There were 15 patients in the second group, with dysphonia, dysphagia, and aspiration, treated with thyroplasty type I and inferior constrictor myotomy as a combined procedure. There were 2 cases of brain stem metastasis (cancer of the breast). Both patients had dysphagia, dysphonia, aspiration, weight loss, and pneumonia. Following the combined procedure, both had improvement in voice and dysphagia. Aspiration persisted and a gastrostomy was necessary in both cases. There were 2 cases of brain stem stroke; both patients developed dysphagia, dysphonia, aspiration, weight loss, and pneumonia. Following the combined procedure, there was improvement of all symptoms, but a permanent gastrostomy was necessary.

There were 3 posterior fossa lesions with the symptoms of dysphonia, dysphagia, aspiration, and weight loss. Following the combined procedure, there was return of function and weight gain in all 3 cases. Two patients had very good voices, and 1 a fair voice.

There were 4 patients with base of skull lesions. All 4 had dysphagia, dysphonia, and aspiration. Three had weight loss, and 2 required a gastrostomy. One patient developed pneumonia. Following the combined procedure, all 4 regained normal function and weight. The gastrostomies were eliminated.

One patient with quadriplegia (spinal cord tumor) had the symptoms of unilateral paralysis of nerves IX and X with resulting dysphagia, dysphonia, aspiration, and pneumonia. Following the combined procedure, there was marked improvement in the voice. Dysphagia and aspiration were eliminated.

There were 3 cases of high vagal lesions in the neck. All 3 patients had dysphagia, dysphonia, and aspiration. One patient had pneumonia. None had a weight loss. Following the combined procedure, all 4 regained normal function and weight.

COMMENT

As a general rule, patients with paralysis of the ninth and tenth cranial nerves have been treated with an injection of Teflon or a thyroplasty type I in order to medialize the paralyzed vocal cord in hopes of improving vocal function, control aspiration, and improve deglutition. In a large percentage of cases, phonatory function is improved but aspiration and dysphagia persist. An inferior constrictor myotomy has been performed as a second operation.

From the analysis of our cases, we conclude that when both nerves IX and X are paralyzed, it is best to perform a thyroplasty type I and an inferior constrictor myotomy simultaneously, and also that this procedure should be performed as soon as possible, even when there is hope that nerve function will return spontaneously. In those cases in which thyroplasty type I and inferior constrictor myotomy were performed separately as compared to those in which they were performed during the same operation, the end result is not significantly different, with the exception that during the interval between the thyroplasty type I and the inferior constrictor myotomy in the noncombined cases, there was persistent dysphonia because of retained saliva in the glottis, dysphagia with weight loss, and aspiration complicated by pneumonia. More cases in the noncombined group required a gastrostomy prior to the inferior constrictor myotomy.

The interval between the onset of symptoms and the performance of the combined thyroplasty type I and inferior constrictor myotomy was significant. Of these cases, 4 required gastrostomy that could have been prevented by performing the combined operation at an earlier date. If aspiration can be controlled at an early date, then pneumonia is quite often avoided.

In summary, with the thyroplasty type I and inferior constrictor myotomy performed simultaneously at an early date following onset of dysphagia, dysphonia, and aspiration, a tracheotomy and gastrostomy can often be avoided with the elimination of these disabling symptoms. The patient can resume normal activity and return to work at an earlier date. Pneumonia can be avoided. If vocal cord function returns, the thyroplasty can be reversed. The question of drawbacks to myotomy in cases of return of neural function has not been answered.

TECHNIQUE OF PROCEDURE

Appropriate doses of Versed, fentanyl citrate, and

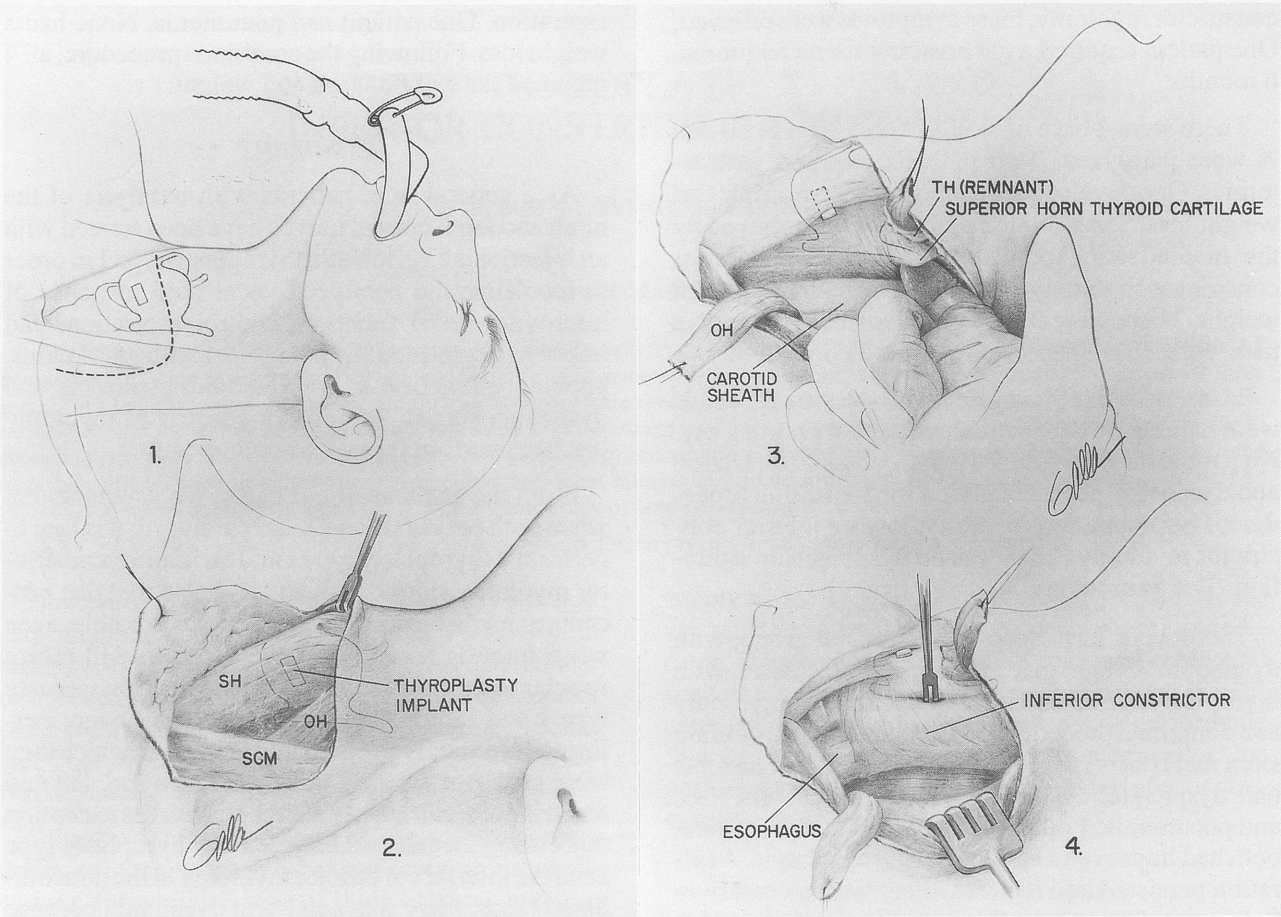

Combined thyroplasty type I and inferior constrictor myotomy. 1) Thyroplasty type I is completed by insertion of implant while observing paralyzed vocal cord with fiberoptic scope and listening to voice. General anesthesia is administered for rest of operation. Small (No. 4.5 to 5) endotracheal tube is inserted between cords and into trachea, preferably by laryngologist. Number 8 or 9 endotracheal tube with or without cuff is inserted by laryngologist into esophagus. This "darning egg" facilitates sectioning of inferior constrictor muscle. Incision for inferior constrictor myotomy is continued from lateral margin of thyroplasty incision and extends inferiorly along anterior border of sternocleidomastoid muscle to immediate supraclavicular region. 2) Flap is elevated by dissecting underneath platysma muscle. This exposes strap muscles. Position of thyroplasty prosthesis is shown. SH — sternohyoid muscle, OH — omohyoid muscle, SCM — sternocleidomastoid muscle. 3) Omohyoid muscle (OH) is transected. Lateral retraction demonstrates contents of carotid sheath. Prevertebral fascia is identified by blunt dissection of fascial planes. (Finger identifies superior horn of thyroid lamina on right side.) TH — thyrohyoid muscle. 4) Larynx is rotated to contralateral side with double hook, which is placed around posterior edge of right thyroid lamina. (Continued on next page.)

propofol are administered intravenously to keep the patient quiet and comfortable during the thyroplasty type I. The thyroplasty is performed under local anesthesia so that the position of the paralyzed vocal cord can be observed after insertion of the prosthesis by means of a fiberoptic laryngoscope.[1] The voice is tested by listening. Booster doses of propofol are needed when infiltrating the area of surgery with 1% Xylocaine with added epinephrine and also during the insertion of the prosthesis.

Following insertion of the prosthesis, the dosage of propofol is increased, and the remainder of the procedure is performed under general anesthesia with paralysis.

As soon as the patient is paralyzed, the larynx is carefully exposed by the surgeon and a No. 4.5 or 5 endotracheal tube is gently inserted through the vocal cords into the subglottic region. A No. 8 or 9 endotracheal tube with or without a cuff is inserted into the cervical esophagus. This acts as a "darning egg" to facilitate sectioning of the entire inferior constrictor muscle, including the cricopharyngeus, without entering the esophagus.

Starting with the lateral aspect of the thyroplasty incision, an incision is outlined extending inferiorly along the anterior border of the sternocleidomastoid muscle to the immediate supraclavicular area. Hatch marks are made in the skin prior to making the incision (see Figure, 1). The anterior border of the sternocleidomastoid muscle is dissected free to expose the omohyoid muscle (see Figure, 2).

After transection of the anterior belly of the

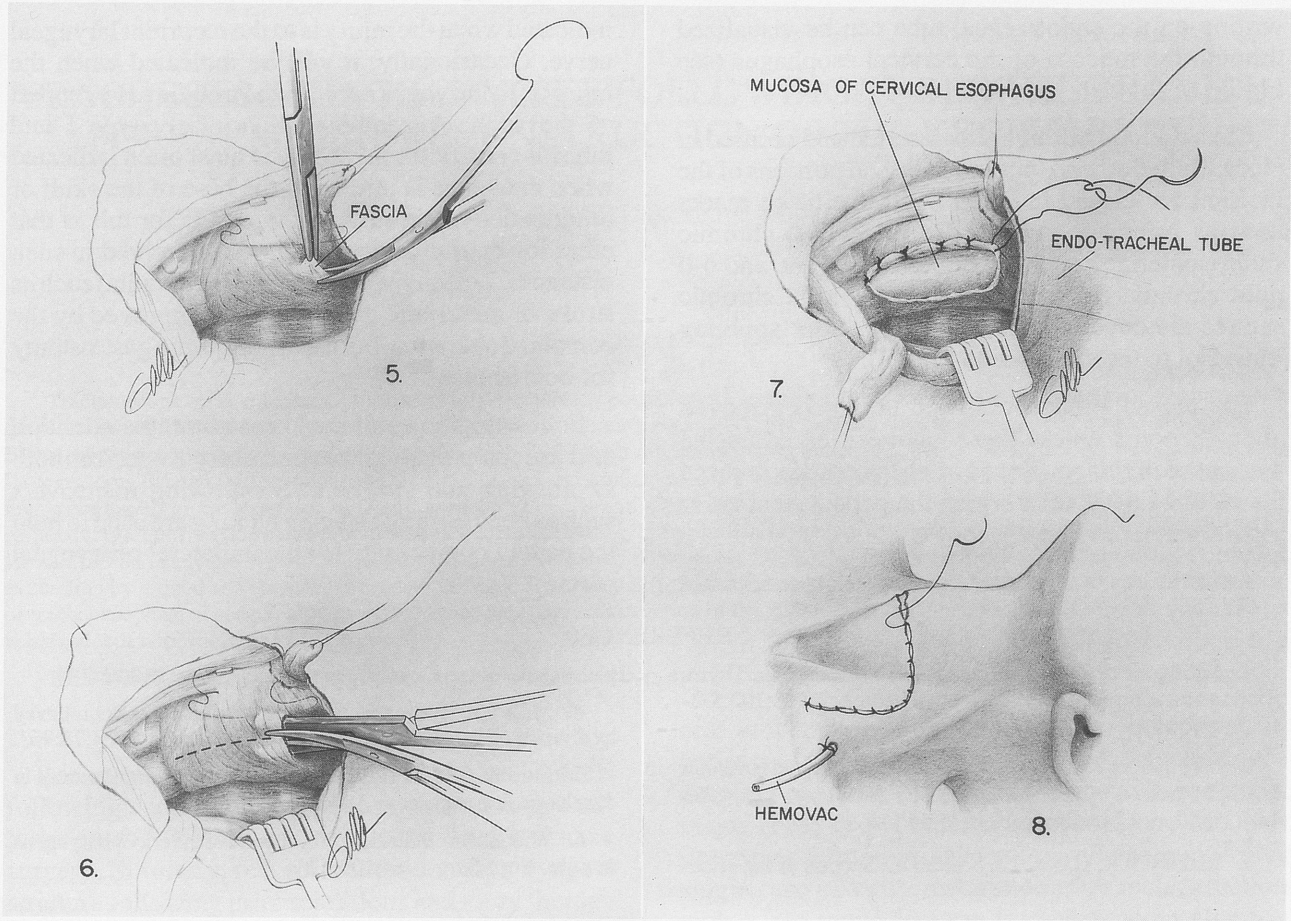

5) Fascia over upper margin of inferior constrictor muscle is grasped with forceps and incised with scissors. 6) Hemostat is used to identify plane between inferior constrictor muscle and submucosa of cervical esophagus. As hemostat is opened, inferior constrictor muscle is transected with Metzenbaum scissors. 7) Entire inferior constrictor muscle, including cricopharyngeus, has been sectioned. Anterior edge is sutured to soft tissues anteriorly. 8) Incision has been closed with cross-hatch marks used as guides. Closed suction drainage has been inserted.

omohyoid muscle, a plane is easily established between the larynx and the thyroid gland complex medially, and the carotid sheath laterally. The prevertebral fascia is dissected free along the entire length of the surgical field. The endotracheal tube in the cervical esophagus can be palpated to give positive identification of the location of the inferior constrictor muscle.

A double hook or a small rake retractor is inserted around the posterior margin of the thyroid lamina on the right side after the superior horn has been palpated with a finger (see Figure, 3). The larynx is rotated toward the contralateral side. This gives a good exposure of the inferior constrictor muscle so that it can be incised posterior to the tracheoesophageal groove, where lies the recurrent laryngeal nerve (see Figure, 4). The left superior cornu of the thyroid lamina roughly identifies the upper end of the inferior constrictor muscle, which can be seen through the overlying fascia. The fascia is grasped at this point with forceps and incised with scissors to expose the upper margin of the inferior constrictor muscle (see Figure, 5).

A hemostat is inserted underneath the inferior constrictor muscle in an inferior direction in the layer between the muscle and the submucosa of the cervical esophagus. As a general rule, this plane is easily established, but the maneuver must be performed with extreme care to prevent entering the lumen of the cervical esophagus. The upper end of the inferior constrictor muscle is sectioned between the two tines of the hemostat. This surgical maneuver is continued inferiorly until the inferior constrictor muscle, including the cricopharyngeal muscle, is sectioned. The submucosa of the cervical esophagus is inspected and palpated before each maneuver (see Figure, 6).

The anterior margin of the inferior constrictor muscle is sutured anteriorly to soft tissue in order to prevent its reuniting with the posterior margin. The inferior constrictor myotomy is complete when the

writing on the endotracheal tube can be visualized through the mucosa of the cervical esophagus (see Figure, 7).

Closed suction drainage is inserted and secured in place. Both the horizontal and vertical portions of the incision are closed in layers, with the hatch marks used as reference points. We prefer 3-0 chromic suture material for the subcutaneous layers, and 6-0 mild chromic for the skin. The 6-0 mild chromic sutures are covered with Steri-strips after applying Mastosol to the skin (see Figure, 8).

The closed suction drainage tubing is removed after 48 hours unless there has been an excessive amount of drainage. The Steri-strips remain in place for 10 to 14 days, after which the patient returns for a postoperative visit.

An inferior constrictor myotomy is, as a rule, not indicated when the injury is to the recurrent laryngeal nerve. Occasionally, it will be indicated when the injury is to the vagus nerve in the middle to lower part of the neck. A combined thyroplasty type I and inferior constrictor myotomy is most often indicated when the vagus is injured at the base of the skull or intracranially. We suspect the reason for this is that other lower cranial nerves are also involved in such instances. Lesions of the brain stem (medulla) such as stroke or metastatic disease can be improved by the combined operation, but usually require a gastrostomy for nourishment.

Following the combined procedure, the attention of a speech pathologist is necessary to perfect both swallowing and speaking. Swallowing maneuvers such as head turning and chin tucking are used to help the patient compensate for the unilateral pharyngeal paresis.

REFERENCES

1. Montgomery WW, Blaugrund SM, Varvares MA. Thyroplasty: a new approach. Ann Otol Rhinol Laryngol 1993;102:571-9.

2. Montgomery WW, Lynch JP. Oculopharyngeal muscular dystrophy treated by inferior constrictor myotomy. Trans Am Acad Ophthalmol Otolaryngol 1971;75:986-93.

3. Blakely WR, Garety EJ, Smith DE. Section of the cricopharyngeus muscle for dysphagia. Arch Surg 1968;96:745.

4. Mills CP. Dysphagia in progressive bulbar palsy relieved by division of the cricopharyngeus. J Laryngol Otol 1964;78:963.

5. Stevens KM, Newell RC. Cricopharyngeal myotomy in dysphagia. Laryngoscope 1971;81:1616-20.

6. Wilkins SA. Indications for section of the cricopharyngeus muscle. Am J Surg 1964;108:533.

TRACHEOESOPHAGEAL VOICE FOLLOWING TUBED FREE RADIAL FOREARM FLAP RECONSTRUCTION OF THE NEOPHARYNX

DANIEL G. DESCHLER, MD
E. THOMAS DOHERTY, PHD
CHARLES G. REED, PHD
JAMES P. ANTHONY, MD
MARK I. SINGER, MD
SAN FRANCISCO, CALIFORNIA

Tracheoesophageal voice restoration after laryngectomy is possible with a variety of neopharyngeal reconstructions. We have used the tubed radial forearm free flap for neopharyngeal reconstruction since 1991. Six patients have undergone voice restoration with the Blom-Singer prosthesis and were available for quantitative and qualitative speech analysis. These patients were compared to five laryngectomy patients with standard pharyngeal closures and similar voice restorations. The free flap patients produced similar loudness levels compared to the standards with soft speech (52.06 dB and 47.19 dB, respectively) and loud speech (62.66 dB and 60.91 dB, respectively). The free flap patients demonstrated adequate intelligibility, with fundamental frequencies comparable to standards (124.82 Hz and 135.66 Hz, respectively), although with increased jitter (5.00% versus 1.96%). No differences were statistically significant, but evaluation by trained and naive listeners demonstrated significant differences in voice quality. This quantitative and qualitative analysis of tracheoesophageal speech after radial forearm free flap reconstruction of the neopharynx demonstrates that acceptable voice can be achieved, but with limitations.

KEY WORDS — laryngectomy, neopharyngeal reconstruction, speech, tracheoesophageal voice, tubed radial forearm free flap.

INTRODUCTION

Reconstruction of circumferential mucosal defects following laryngopharyngectomy remains a challenge in ablative and reconstructive head and neck surgery. Similarly, reconstruction of neopharyngeal stricture following prior resections and x-ray therapy (XRT) is complicated by high failure rates. The successful outcome of pharyngeal reconstruction relies on unimpeded deglutition. Techniques have evolved from the use of local and regional skin flaps through pedicled myocutaneous flaps and enteric transposition to the use of free tissue transfer.[1-9] Reconstructive options are selected by the extent of resection, XRT, medical issues, and the techniques available at the time of resection. Published comparisons of various methods demonstrate the potential options, as well as the search for an improved alternative.[3-5,10] The development of enteric and fasciocutaneous free tissue transfer has provided dependable alternatives with high success rates.[6-9,11]

As reliable techniques evolve to restore deglutition, attention should focus on the function of voice. Tracheoesophageal fistula (TEF) is an uncomplicated, dependable, and accessible technique for voice restoration in the standard laryngectomy patient.[12-17] Success with this technique has also been reported in patients after laryngopharyngectomy who have undergone pharyngeal reconstruction with pectoralis major (PM) flaps, enteric transpositions, and free tissue reconstructions with colon and jejunum.[18-23] A single case of voice restoration after reconstruction with a free radial forearm fasciocutaneous flap has been reported.[24] The various methods available for neopharyngeal reconstruction use different tissues such as skin or bowel, and subsequent voice restoration success rates and quality vary among reconstructive options.

We prefer the tubed free radial forearm fasciocutaneous flap for restoring circumferential defects. Six patients were reconstructed secondarily because of neopharyngeal stricture after laryngectomy or extended laryngopharyngectomy. After successful voice restoration, they were available for voice testing. We undertook this study to characterize, in both a quantitative and a qualitative manner, the voice attainable with the TEF technique after secondary neopharyngeal reconstruction with the tubed free radial forearm fasciocutaneous flap.

MATERIALS AND METHODS

Two study groups were chosen for comparison: a

From the Department of Otolaryngology–Head and Neck Surgery (Deschler, Singer) and the Division of Plastic and Reconstructive Surgery (Anthony), University of California, San Francisco, and the Department of Speech and Audiology, San Francisco Veterans Hospital (Doherty, Reed), San Francisco, California. This research was supported in part by the Veterans Administration Research and Development Service, Department of Veterans Affairs Medical Center, San Francisco, California.

Presented at the meeting of the American Laryngological Association, Palm Beach, Florida, May 7-8, 1994.

REPRINTS — Daniel G. Deschler, MD, Dept of Otolaryngology–Head and Neck Surgery, University of California, San Francisco, 400 Parnassus Ave, A-717 Box 0342, San Francisco, CA 94143.

TABLE 1. PATIENT PROFILES

		Primary Procedure		Radiotherapy			Revision Surgery		TEP	
Patient	Age (y)	Type	Year	Type	Year	Complications	Type	Year	Type	Year
Group 1										
1	59	TL, PM	1986	Postop	1986	Stricture	RFF	1992	Sec	1993
2	69	TL, TEP	1992	Preop	1986	Stricture	RFF	1992	Pri	1992
3	74	TL, Bil ND	1987	Postop	1987	Stricture	RFF, PM	1992	Sec	1993
4	49	TL	1992	Postop	1992	Stricture	RFF, PM	1993	Sec	1993
5	47	TL	1969	Postop	1969	Stricture	Multiple revisions RFF	1993	Pri	1993
6	46	TL	1992	Postop	1992	Stricture, PC fistula	RFF	1993	Sec	1993
Group 2										
7	57	TL	1987	Postop	1987				Sec	1988
8	71	TL	1986	Postop	1986				Pri	1986
9	72	TL	1990	Postop	1990				Sec	1991
10	67	TL	1982	Preop	1974		CP myotomy	1982	Sec	1982
11	64	TL, RND	1989	Preop	1987		RND	1991	Sec	1990

All patients were male except for patient 1. All had squamous cell carcinoma. Group 1 consisted of patients with neopharyngeal reconstruction with free radial forearm fasciocutaneous flap. Group 2 had standard laryngectomy and tracheoesophageal fistula.

TL — total laryngectomy, PM — pectoralis major flap, TEP — tracheoesophageal puncture, Bil ND — bilateral neck dissection, RND — radical neck dissection, PC — pharyngocutaneous, RFF — radial forearm fasciocutaneous flap, CP — cricopharyngeal, Sec — secondary, Pri — primary.

group of patients who had undergone secondary neopharyngeal reconstruction with the tubed free radial forearm fasciocutaneous flap for debilitating stricture after laryngectomy and XRT, and a group of patients immediately reconstructed by primary pharyngeal closure. All patients underwent voice restoration with the Blom-Singer silicone prosthesis and use the standard tracheoesophageal (TE) speech techniques. Digital stomal occlusion was used in all cases. The charts of these patients were reviewed for age, sex, pathologic diagnosis, date and type of primary procedures, treatment with preoperative or postoperative XRT, complications including stricture requiring neopharyngeal reconstruction, reconstructive procedure undertaken, date of TEF, and voice restoration. These are listed in Table 1.

To compare the voice of these two patient groups, standardized vocal tasks of sustained phonation and speech were used. The tasks selected permit both quantitative and qualitative measures of acoustic characteristics such as loudness and pitch, as well as psychoacoustic judgments of pleasantness and intelligibility.

Patients were asked to produce a sustained /a/. This was done at both a soft and loud intensity. These utterances were used to establish each patient's dynamic range. It also provided estimates of the level of jitter in their vocalizations. A 1-second sample from the middle of the phonation was analyzed for these calculations. The patients were then asked to read two standard passages. The "Rainbow Passage" allows listeners to rate the pleasantness of the patient's voice. The "Grandfather Passage" provides a means to rate the patient's intelligibility and the listener's ability to evaluate the content of the speaker's message. Finally, the patients read 50 words from one of four standardized lists. These are sets of single-syllable words that are phonetically balanced. Each list contains a distribution of phonemes that is in proportion to their occurrence in the English language.

Signal recordings were done with patients seated in a quiet room while they produced speech samples. A Bruel & Kjaer 1-in condenser microphone, cartridge type 4132, was positioned approximately 30 cm from the speaker's mouth. The signal was fed to a Bruel & Kjaer microphone amplifier, type 2603. The acoustic signals were processed by a pulse code modulator, a Sony PCM-501ES digital audio processor, and stored on a Panasonic AG-1900 video cassette recorder. This technique records signals in a digital form that is virtually identical to that of compact disc recordings. Data acquisition was performed with the analog-to-digital converter of a Creative Technology, Ltd, Sound Blaster 16 ASP analog and digital input-output system in a Vanguard 486/33 personal computer. The analog-to-digital converter has a resolution of 16 bits, which is accurate to within ±0.0015% of the full scale reading. All signals were sampled at 44.1 kHz.

Voice samples were analyzed for amplitude, dynamic range, fundamental frequency (F0), and jitter. The range and mean of each parameter were calculated for the two groups.

TABLE 2. VOCAL SOUND PRESSURE LEVEL MEASUREMENTS FOR GROUPS 1 AND 2

Patient	*Soft (dB)*	*Loud (dB)*	*Difference (dB)*
Group 1			
1	49.40	60.56	11.16
2	54.99	64.04	9.05
3	59.41	65.42	6.01
4	46.53	57.67	11.14
5	50.99	68.86	17.87
6	51.04	59.42	8.38
Mean	52.06	62.66	10.60
SD	4.53	4.19	4.05
Group 2			
7	52.11	61.74	9.63
8	40.52	58.33	17.81
9	46.21	57.44	11.23
10	51.34	63.74	12.40
11	45.77	63.29	17.52
Mean	47.19	60.91	13.72
SD	4.71	2.87	3.74

Two groups of listeners were selected to evaluate voice quality. One group consisted of six trained listeners who were formally trained and licensed in speech pathology. Six naive listeners constituted the second group; they had no formal speech training or consistent contact with TE speakers. The listeners evaluated each patient's voice quality from a recording and were blinded to the patient's operative history. The "Rainbow" and "Grandfather" passages were used to evaluate nine qualitative voice parameters: intelligibility, communicative effectiveness, effective use of pitch, effective use of intensity, speaking rate, pleasantness, wetness, fluency, and extraneous speech noise. Listeners rated patients from 1 to 10 on a 10-cm line. Scores were achieved by measuring with a centimeter ruler. Results were calculated in millimeters. Listeners then evaluated the word list. Scores were rated as absolute number correct out of the total of 50 words.

Statistical analysis was completed with the Statistica, Release 4.0 (Statsoft, Inc, Tulsa, Okla) computer statistics package used to assess MANOVA.

RESULTS

The patient profiles of the two groups were roughly equivalent (Table 1). The average age of the secondarily reconstructed group 1 patients was 57 years (range, 46 to 74), whereas that of the primary standard closure group 2 patients was 66 years (range, 57 to 72). All patients were male except patient 1. All patients were treated for advanced squamous cell carcinoma of the larynx and hypopharynx and were clinically free of disease at the time of surgery and study. All patients received full-course XRT. One of the six patients in group 1 received preoperative XRT; the remainder were irradiated after the ablative procedure. Two of the group 2 patients received preoperative XRT; the remainder were irradiated postoperatively. All patients in group 1 underwent neopharyngeal reconstruction by the same surgical team for postlaryngectomy stricture that limited oral intake and was unimproved after multiple dilations. Patient 6 also presented with a pharyngocutaneous fistula prior to reconstruction. Two of the reconstructed patients had undergone previous neopharyngeal reconstructive procedures. A noncircumferential PM flap was used to reconstruct patient 1 at the primary ablative procedure. Patient 5 underwent multiple revisions with local and regional skin flaps, as well as a PM flap, prior to reconstruction with the free radial forearm fasciocutaneous flap. All group 2 patients had uncomplicated primary closures, and two patients required subsequent procedures after primary surgical therapy. Patient 10 required a cricopharyngeal myotomy 1 year after TEF. Patient 11 underwent contralateral radical neck dissection for recurrent disease. All patients in group 1 and group 2 had excellent deglutition and maintained regular diets at the time of study. Two patients in group 1 had TEFs at the time of reconstruction. One of these, patient 5, had a preexisting fistula that was maintained. One patient in group 2 underwent primary TEF. A marked difference was noted in the two groups when the length of time with TE speech was compared. Group 1 patients used TE speech for an average of 4 months (range, 1 to 12) prior to study, whereas the average duration of TE speech use for group 2 patients was 62 months (range, 18 to 126).

Intensity, as measured by sound pressure levels, was compared for soft and loud speech (Table 2). Both groups demonstrated dynamic range in their ability to create both soft and loud speech. The intensity levels in decibels were comparable between the study groups for both soft and loud speech (Fig 1A). The mean intensity for soft speech was 52.06 dB in the reconstructed group and 47.19 dB in the standard group, whereas for loud speech the mean intensity was 62.66 dB and 60.91 dB, respectively. The dynamic range, as measured by the difference between soft and loud sound pressure levels, was 10.61 dB in group 1 and 13.72 dB in group 2.

Fundamental frequency was similarly measured for soft and loud speech (Table 3). Three of the group 1 patients could not maintain sustained phonation sufficient to allow accurate measurement of F0 and jitter at soft voice levels. One patient in group 2 was

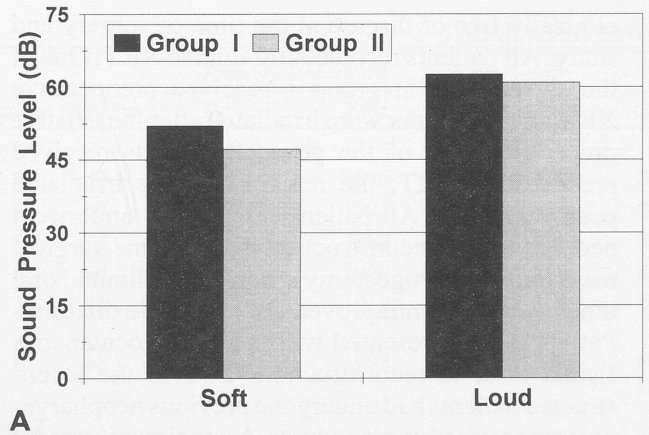

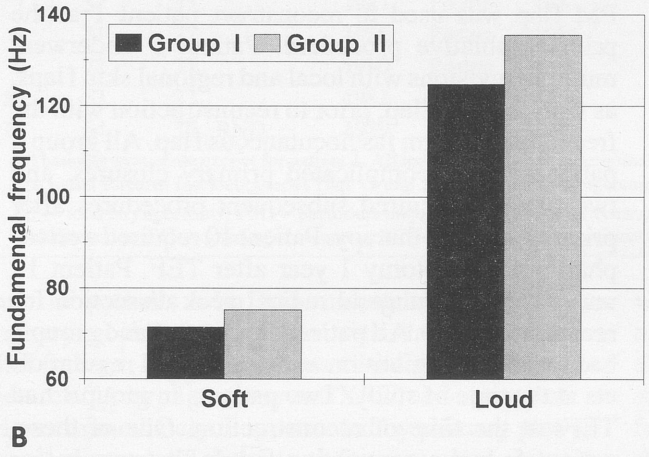

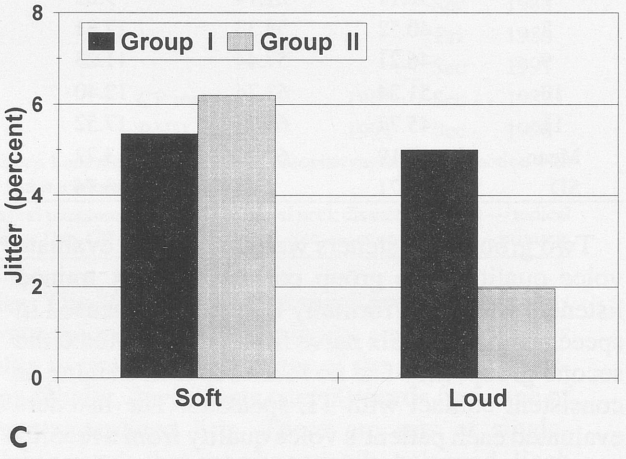

Fig 1. Bar graphs demonstrating values at soft and loud speech for groups 1 and 2. A) Vocal intensity (sound pressure level). B) Vocal pitch (fundamental frequency). C) Pitch perturbation (jitter).

similarly unmeasurable. The mean F0 for those patients measurable at soft speech was 71.43 Hz for group 1 and 75.24 Hz for group 2 (Fig 1B). All patients had measurable F0 for loud speech. Group 1 patients demonstrated a mean F0 of 124.82 Hz (range, 63.37 to 184.66 Hz). The mean F0 for group 2 was 135.56 Hz (range, 129.56 to 142.23 Hz).

Jitter, the cycle-to-cycle frequency variation, was measured in percent and was comparable for the measurable patients at soft speech for both group 1 and group 2: 5.35% and 6.20%, respectively. Jitter was different when the groups were compared for loud speech. The mean jitter for group 1 was 2.5 times that of group 2: 5.00% compared to 1.96% (Fig 1C). No differences were statistically significant.

Qualitative voice assessment was completed by evaluating the parameters of intelligibility, communicative effectiveness, effective use of pitch, effective use of intensity, speaking rate, pleasantness, wetness, fluency, extraneous speech noise, and word list scores. There was no statistically significant difference in the evaluation of the speakers between the two listener groups for the parameters of intelligibility, effective use of pitch, fluency, communicative effectiveness, pleasantness, or number of correct choices on the word list (Fig 2A). The patients with the standard reconstructions demonstrated better performance for these six parameters in a statistically

TABLE 3. FUNDAMENTAL FREQUENCY AND JITTER MEASUREMENTS FOR GROUPS 1 AND 2

	Soft		*Loud*	
Patient	*Frequency (Hz)*	*Jitter (%)*	*Frequency (Hz)*	*Jitter (%)*
Group 1				
1			184.66	5.84
2	59.46	6.55	159.44	5.05
3	73.01	3.32	63.37	5.43
4			106.57	1.57
5	81.81	6.18	123.74	5.71
6			111.16	6.39
Mean	71.43	5.35	124.82	5.00
SD	11.26	1.77	42.61	1.74
Group 2				
7	85.67	3.13	132.19	0.92
8	58.34	5.78	142.23	0.65
9	85.64	5.23	136.14	3.50
10			137.66	3.14
11	71.33	10.64	129.56	1.61
Mean	75.24	6.20	135.56	1.96
SD	13.14	3.18	4.91	1.29

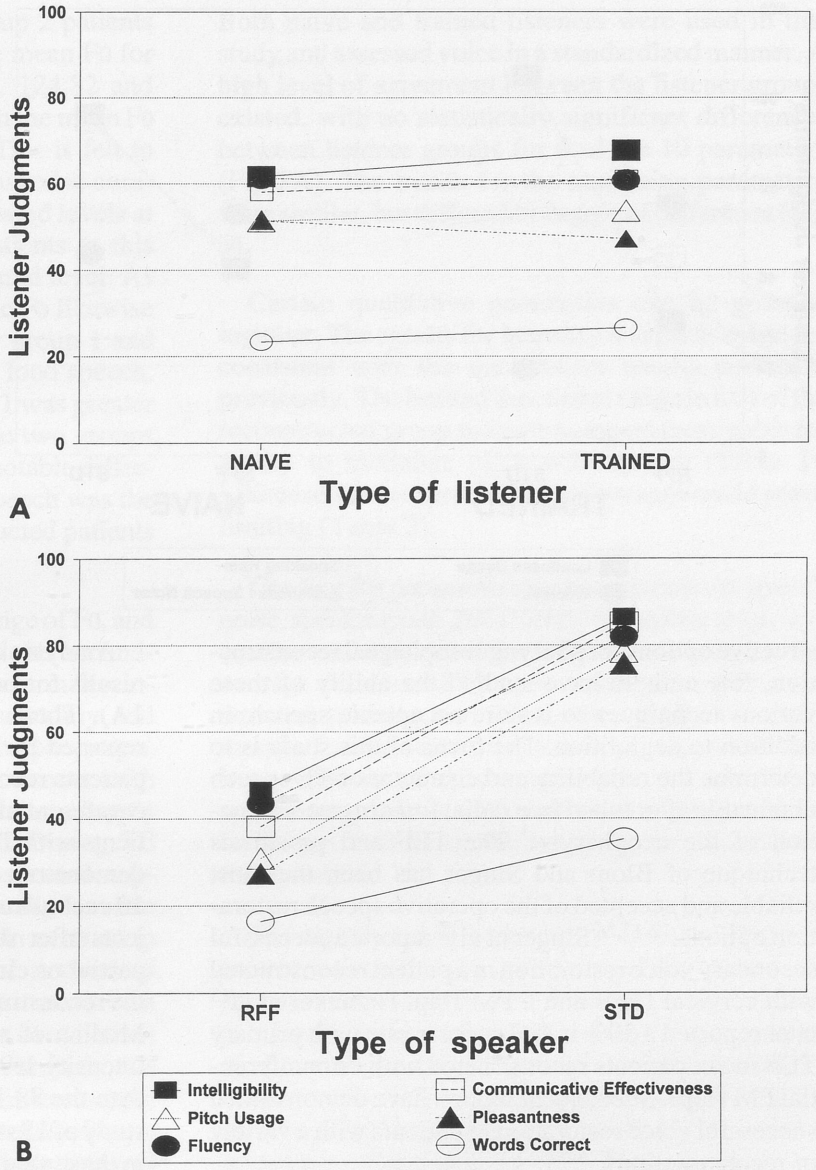

Fig 2. Qualitative assessment for six parameters not affected by listener type. A) Congruence of grading between naive and trained listeners for six parameters noted. B) Statistically significant differences in voice quality noted by both listener groups on arbitrary scale from 0 to 100. Word count is rated on scale from 1 to 50 based on number correct out of 50. RFF — radial forearm flap (group 1), STD — standard laryngectomy (group 2).

significant manner (Fig 2B). For the parameters of loudness usage, wetness, speaking rate, and extraneous speech noise, the two listener groups differed in assessment, but noted similar trends (Fig 3). The trained listeners graded the standard patients significantly better for the parameters of loudness usage, wetness, and extraneous noise, while only slightly better for speech rate. Likewise, the naive listeners graded the standard patients significantly better for loudness usage and speaking rate, but the differences in wetness and extraneous speaking noise were not statistically significant.

DISCUSSION

Neopharyngeal reconstruction after laryngopharyngectomy has evolved since Wookey[1] described the staged local skin flap closure in 1942. Current options include the PM myocutaneous flap, enteric transposition flap for defects extending beyond the cervical esophagus, and enteric or fasciocutaneous free tissue transfer. The free radial forearm fasciocutaneous flap was demonstrated to be reliable and versatile for intraoral reconstructions.[25] Harii et al[8] reported in 1985 that when tubed, this flap provided an excellent alternative for neopharyngeal reconstruction. Others have demonstrated similar success and prefer this method.[9,11] Advantages of the free radial forearm fasciocutaneous flap over other options include decreased operative time, as graft harvest is rapid and requires no laparotomy; the absence of postoperative morbidity secondary to laparotomy; minimal donor site morbidity; the presence of high-caliber, dependable vessels for microvascular transfer; and the possibility of reinnervation of the cutaneous segment.

In spite of this increase in the number of recon-

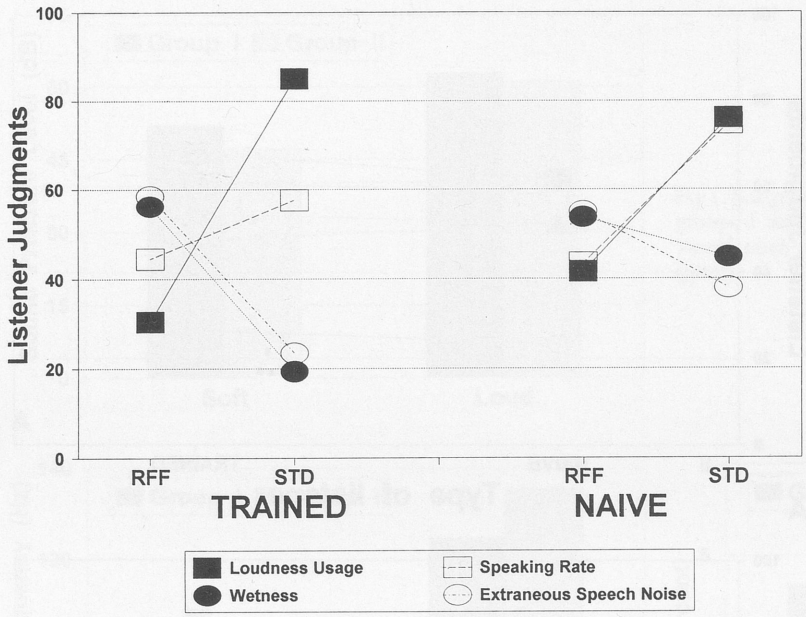

Fig 3. Qualitative assessment for four parameters affected by listener type. Similar scale as in Fig 2. All differences were statistically significant except loudness usage in trained group and wetness and extraneous speech noise in naive group. RFF — radial forearm flap (group 1), STD — standard laryngectomy (group 2).

structive options for pharyngoesophageal reconstruction, few authors have studied the ability of these various techniques to restore acceptable speech, in addition to deglutition. The focus of this study is to determine the reliability and character of TE speech obtainable after tubed free radial forearm reconstruction of the neopharynx. The TEF and prosthesis technique of Blom and Singer has been the most reliable and accepted of the operative speech restoration options.[12-17,26] Singer et al[12] reported successful secondary voice restoration in a patient reconstructed with cervical flaps and a PM flap. Hamaker et al[13] later reported a 50% initial success rate with primary TEF in six patients reconstructed with circumferential PM flaps. Subsequent reports have demonstrated successful voice restoration in patients with a variety of reconstructions.[18-24]

All patients in this study were reconstructed with the tubed free radial forearm fasciocutaneous flap. Similarly, these patients were reconstructed after XRT and secondarily for the difficult problem of neopharyngeal stricture, demonstrating the ability of this method in adverse settings. All flaps were successful and all patients had adequate deglutition, maintaining regular diets. The TEFs were successful and uncomplicated. These patients then underwent extensive and thorough voice analysis in an effort to characterize the TE voice attainable after tubed free radial forearm fasciocutaneous flap reconstruction when compared to the voice of patients who had uncomplicated laryngectomy and voice restoration. Previous reports of voice restoration after reconstruction with the radial forearm flap for a partial defect and a circumferential defect subjectively describe adequate voice, but contain no objective measures.[20,24]

Analysis of intensity levels demonstrated similar results for both groups at soft and loud speech (Fig 1A). These intensity levels were similar to those reported by Medina et al[18] in a study comparing 10 patients reconstructed with various methods for circumferential defects to standard laryngectomy patients with TEF voice restoration. Juarbe et al[19] also demonstrated similar intensity levels in an analysis of 10 reconstructed patients compared to control subjects after standard TEF. The extent of the defect, partial or circumferential, was not noted. Although the reconstructed patients in this study and in those of Medina et al and Juarbe et al demonstrated mean intensity levels for sustained vowel phonation less than the 88.1 dB mean noted by Robbins et al[27] in a study of 15 standard TEF speakers, the control groups in these studies, consisting of standard TEF patients, likewise had lowered mean intensities.

Group 1 and group 2 patients demonstrated the ability to create a dynamic range. Standard laryngectomy and TEF patients had a 30% greater range and a greater ability to create functional speech within that range, a finding similarly noted by Medina et al.[18] As noted in the analysis of F0 and jitter, half the group 1 patients could not maintain constant phonation at soft levels. Voice in these patients tended to lose periodicity and become very breathy. Even though these patients had intensity levels similar to those of standards at soft levels, the lack of periodicity at soft levels made voicing in this range nonfunctional, and patients adapted by increasing intensity until a constant pitch could be maintained. Those patients in group 1 who had functional voice at soft levels demonstrated similar F0 and jitter levels compared to group 2 patients (Fig 1B,C).

At loud levels, the group 1 and group 2 patients demonstrated similar F0 (Fig 1B). The mean F0 for group 1 and group 2 at loud speech, 124.82 and 135.86 dB, respectively, are greater than the mean F0 of 82.8 dB noted by Robbins et al.[27] This is felt to reflect the specific task speakers were asked to complete in each study. Robbins et al compared levels at a conversational tone, whereas the patients in this study were asked to phonate at a maximal level. As loudness increases in TEF speakers, the F0 likewise rises. For this reason, the F0 noted for group 1 and group 2 are appropriate for the task of loud speech. Although the range of F0 within group 1 was greater than that in group 2, the mean F0 of the two groups were not markedly different. The only notable difference between the two groups at loud speech was the greater jitter noted among the reconstructed patients (Fig 1C).

The differences in jitter, increased range of F0, and limited dynamic range found in the patients secondarily reconstructed with a free radial forearm fasciocutaneous flap can be traced to the anatomy and quality of the neopharynx available for phonation. Patients reconstructed in the standard manner with layered mucosal and muscular closure have a supple neopharynx with intrinsic musculature. During TE speech, phonatory vibrations may be created anywhere along the neopharynx. These usually localize to a limited but stable voicing source. In contrast to these patients with the neopharynx of a standard tissue type and quality, patients reconstructed with the skin-lined radial forearm flap have two distinct tissue types present in the neopharynx. Similarly, the radial forearm flap provides tissue that is less supple than mucosa and possesses no intrinsic musculature. For these reasons, the voicing source is less stable and well defined. This quantitative variability in functional voicing segment appears limited to the dynamic range and jitter. Overall, this does not impede the ability of the reconstructed patient to have reliable voice restoration, but may affect certain aspects of voice quality.

Previous reviews of TE speech following neopharyngeal reconstruction follow no set pattern of qualitative analysis of voice. Listeners such as speech pathologists, surgeons, naive listeners, or combinations assessed voice with limited and varying criteria. Although successful functional voice restoration was achieved in all patients reconstructed with the radial forearm free flap, thorough qualitative listener assessment of function was completed to define voice in the patients reconstructed with this method compared to standards. Ten parameters were chosen that adequately assess voice and TE speech specifically. Both naive and trained listeners were used in this study and assessed voice in a standardized manner. A high level of agreement between the listener groups existed, with no statistically significant differences between listener groups for 6 of the 10 parameters (Fig 2A). The trends for the remaining parameters were similar, but differed in degree of difference (Fig 3).

Certain qualitative parameters can be grouped together. The results for intensity and pitch usage are consistent with the quantitative results presented previously. The limited functional range in half of the reconstructed group patients hampers these patients' ability to modulate pitch with speech (Table 3). Likewise, the compressed intensity range could prove limiting (Table 2).

Grading for parameters such as extraneous speech noise, speaking rate, and fluency may relate to speaker comfort and mastery of the TE speech technique. The average duration of TE speech usage for the reconstructed patients was 4 months, compared to 62 months for the standard patients. It is possible that improvements of these parameters and of overall speech may follow with increased facility with the technique. Follow-up studies are planned to address this question.

The significant difference in wetness noted by the trained listeners is not surprising. This trend is reported by other authors.[18-22] Reconstructive methods using enteric flaps are prone to "wet" voice because of the intrinsic secretory nature of the mucosally lined tissue. With jejunal flaps, wetness may be increased by flap redundancy and inability to clear secretions. The radial forearm flap can also have decreased clearance of secretions secondary to redundancy, but lacks the added intrinsic secretions. Yet, secretions may pool because of the lack of intrinsic musculature discussed earlier. The remaining parameters assess overall speech quality and therefore are subject to limitations with factors discussed previously such as wetness and pitch or intensity usage.

Overall, speech was judged superior in the standard laryngectomy patients compared to the reconstructed patients in a statistically significant manner for all 10 qualitative parameters by one or both of the listener groups. This may partly reflect the nature of tissue transposed for the difficult problem of neopharyngeal reconstruction, as well as experience with TE speech techniques. Yet, all reconstructed patients were able to obtain a functional voice. Successful voice restoration, in addition to deglutition, after

secondary reconstruction with the free radial forearm fasciocutaneous flap makes this an encouraging reconstructive option.

SUMMARY

In conclusion, voice restoration with TEF and the Blom-Singer prosthesis is a relatively safe and dependable technique in patients who have undergone extensive neopharyngeal reconstruction with the free radial forearm fasciocutaneous flap. Quantitative voice analysis in six patients managed in this manner demonstrated no statistically significant differences in F0 and intensity levels in reconstructed patients as compared to standard patients. Jitter was increased for reconstructed patients, but not limiting. Similarly, the dynamic range was smaller. Qualitative review proved higher quality over 10 parameters for the standard patients, but dependable and understandable voice was achieved in the reconstructed patients. Further careful study of quantitative and qualitative aspects of alaryngeal voice after neopharyngeal reconstruction is required to assess speech in this patient group.

REFERENCES

1. Wookey H. The surgical treatment of carcinoma of the pharynx and upper oesophagus. Surg Gynecol Obstet 1942;75: 499-506.

2. Missotten FEM. Historical review of pharyngo-oesophageal reconstruction after resection for carcinoma of pharynx and cervical oesophagus. Clin Otolaryngol 1983;8:345-62.

3. Schuller DE. Reconstructive options for pharyngeal and/or cervical esophageal defects. Arch Otolaryngol 1985;111:193-7.

4. Shah JP, Shemen L, Spiro RH, Strong EW. Selecting variants in pharyngeal reconstruction. Ann Otol Rhinol Laryngol 1984;93:318-21.

5. De Vries EJ, Stein DW, Johnson JT, et al. Hypopharyngeal reconstruction: a comparison of two methods. Laryngoscope 1989;99:614-7.

6. Coleman JJ, Searles JM, Hester R, et al. Ten years experience with the free jejunal autograft. Am J Surg 1987;154:394-8.

7. Flynn MB, Banis J, Acland R. Reconstruction with free bowel autografts after pharyngoesophageal or laryngoesophageal resection. Am J Surg 1989;158:333-6.

8. Harii K, Ebihara S, Ono I, Saito H, Terui S, Takato T. Pharyngoesophageal reconstruction using a fabricated forearm free flap. Plast Reconstr Surg 1985;75:463-73.

9. Anthony JP, Singer MI, Mathes SJ. Pharyngoesophageal reconstruction using the tubed free radial forearm flap. Clin Plast Surg 1994;21:1-11.

10. Schechter GL, Baker JW, Gilbert DA. Functional evaluation of pharyngoesophageal reconstructive techniques. Arch Otolaryngol Head Neck Surg 1987;113:40-4.

11. Kelly KE, Anthony JP, Singer M. Pharyngoesophageal reconstruction using the radial forearm fasciocutaneous free flap: preliminary results. Otolaryngol Head Neck Surg 1994;111:16-24.

12. Singer MI, Blom ED, Hamaker RC. Voice restoration after total laryngectomy. J Otolaryngol 1983;12:329-34.

13. Hamaker RC, Singer MI, Blom ED, Daniels HA. Primary voice restoration at laryngectomy. Arch Otolaryngol 1985;111: 182-6.

14. Yoshida GY, Hamaker RC, Singer MI, Blom ED, Charles GA. Primary voice restoration at laryngectomy: 1989 update. Laryngoscope 1989;99:1093-5.

15. Recher G, Pesavento G, Cristoferi V, Ferlito A. Italian experience of voice restoration after laryngectomy with tracheoesophageal puncture. Ann Otol Rhinol Laryngol 1991;100:206-10.

16. Morris HL, Smith AE, Van Demark DR, Maves MD. Communication status following laryngectomy: the Iowa experience 1984-1987. Ann Otol Rhinol Laryngol 1992;101:503-10.

17. St Guily JL, Angelard B, El-Bez M, et al. Postlaryngectomy voice restoration: a prospective study in 83 patients. Arch Otolaryngol Head Neck Surg 1992;118:252-5.

18. Medina JE, Nance A, Burns L, Overton R. Voice restoration after total laryngopharyngectomy and cervical esophagectomy using the duckbill prosthesis. Am J Surg 1987;154:407-10.

19. Juarbe C, Shemen L, Wang R, et al. Tracheoesophageal puncture for voice restoration after extended laryngopharyngectomy. Arch Otolaryngol Head Neck Surg 1989;115:356-9.

20. Wenig BL, Keller AJ, Levy J, Mullooly V, Abramson AL. Voice restoration after laryngopharyngoesophagectomy. Otolaryngol Head Neck Surg 1989;101:11-3.

21. Maniglia AJ, Leder SB, Goodwin WJ, Sawyer R, Sasaki CT. Tracheogastric puncture for vocal rehabilitation following total pharyngolaryngoesophagectomy. Head Neck 1989;11:524-7.

22. Bleach N, Perry A, Cheesman A. Surgical voice restoration with the Blom-Singer prosthesis following laryngopharyngoesophagectomy and pharyngogastric anastomosis. Ann Otol Rhinol Laryngol 1991;100:142-7.

23. Bates GJ, McFeeter L, Coman W. Pharyngolaryngectomy and voice restoration. Laryngoscope 1990;100:1025-6.

24. Cumberworth VL, O'Flynn PO, Perry A, Bleach NR, Cheesman AD. Surgical voice restoration after laryngopharyngectomy with free radial forearm repair using a Blom-Singer prosthesis. J R Soc Med 1992;85:760-1.

25. Soutar DS, McGregor IA. The radial forearm flap in intraoral reconstruction: the experience of 60 consecutive cases. Plast Reconstr Surg 1986;78:1-8.

26. Lopez MJ, Kraybill W, McElroy TH, Guerra O. Voice rehabilitation practices among head and neck surgeons. Ann Otol Rhinol Laryngol 1987;96:261-3.

27. Robbins J, Fisher HB, Blom EC, Singer MI. A comparative acoustic study of normal, esophageal and tracheoesophageal speech production. J Speech Hear Disord 1984;49:202-10.

AUTOLOGOUS FAT INJECTION FOR VOCAL FOLD PARALYSIS: LONG-TERM HISTOLOGIC EVALUATION

LAUREN S. ZARETSKY, MD
STONY BROOK, NEW YORK
MAISIE L. SHINDO, MD
LOS ANGELES, CALIFORNIA
MICHAEL DETAR, MD
LOS ANGELES, CALIFORNIA
DALE H. RICE, MD
LOS ANGELES, CALIFORNIA

Many techniques have been developed for medialization of the paralyzed vocal fold. The purpose of this study is to evaluate autologous fat as an alternative to alloplastic substances for use in vocal fold medialization. Eight dogs underwent left recurrent laryngeal nerve sectioning. Autologous fat was harvested, and the paralyzed vocal fold was medialized by injecting the fat into the thyroarytenoid muscle. The animals were divided into three groups for evaluation at 1, 3, and 6 months. Videolaryngoscopy was performed prior to sacrificing the animals. The larynges were sectioned coronally, and histologic studies were performed. The studies confirmed the preservation of viable fat at the injected site in all animals. Only a minimal inflammatory response was observed in the 1-month group. It would appear that fat injection is a viable alternative to Teflon injection and thyroplasty; it eliminates the need for alloplastic materials, does not appear to migrate, and does not require an open procedure.

KEY WORDS — autologous fat injection, histology, vocal fold medialization, vocal fold paralysis.

INTRODUCTION

Glottic incompetence resulting from unilateral vocal fold paralysis can be improved by medialization of the paralyzed vocal fold. The techniques available for medialization are 1) injection of various substances (most commonly Teflon or Gelfoam) and 2) laryngeal framework surgery (medialization laryngoplasty [thyroplasty] and arytenoid adduction). Although effective, these methods have limitations and potential complications. Teflon injection may be associated with granuloma formation and scarring, which can result in a poor voice quality.[1] Gelfoam is used for temporary vocal fold paralysis and lasts only an average of 6 to 8 weeks.[2] Medialization laryngoplasty may be associated with extrusion of the implant. Arytenoid adduction is technically difficult to perform, and complications such as pharyngocutaneous fistula and airway obstruction have been reported.[3] Ideally, vocal fold medialization should be accomplished with a simple technique with a low risk of associated complications. Injection of an autologous substance with a low resorption rate would seem to fit these criteria. A few clinical cases of autologous fat injection for unilateral vocal fold paralysis have been reported in the literature with what appear to be favorable results.[4,5] The purpose of this study is to evaluate the fate of autologous fat injected into a paralyzed vocal fold in the canine model.

MATERIALS AND METHODS

Eight dogs weighing between 20 and 25 kg were used for the study. All procedures and handling of the animals complied with the regulations of the University of Southern California School of Medicine Vivarium. The animals were placed under general anesthesia with thiopental sodium and halothane. The left recurrent laryngeal nerve was identified through a paratracheal incision and subsequently sectioned to remove a 1-cm section of the nerve. Direct laryngoscopy was performed and the proximal stump of the nerve was electrically stimulated in order to confirm the vocal fold paralysis.

A separate supraclavicular incision was made and a portion of the supraclavicular fat pad was removed and placed in saline. With a No. 10 blade, the fat was minced into small pieces, and the surrounding fascia was meticulously removed. The fat was then placed on Marlex mesh and irrigated with sterile normal saline in order to rinse away remaining blood elements. The fat globules were then loaded into a Bruning syringe with a 19-gauge needle. The anesthesia was changed from inhalation anesthesia to intravenous sedation with thiopental until the animal

From the Department of Otolaryngology–Head and Neck Surgery, University of Southern California School of Medicine, Los Angeles, California. Dr Zaretsky is currently at the Department of Surgery, Division of Otolaryngology–Head and Neck Surgery, Stony Brook University Hospital, Stony Brook, New York. This study was performed in accordance with the PHS Policy on Humane Care and Use of Laboratory Animals, the NIH *Guide for the Care and Use of Laboratory Animals*, and the Animal Welfare Act (7 U.S.C. et seq.); the animal use protocol was approved by the Institutional Animal Care and Use Committee (IACUC) of the University of Southern California School of Medicine.

Presented at the meeting of the American Laryngological Association, Palm Beach, Florida, May 7-8, 1994.

REPRINTS — Maisie L. Shindo, MD, LAC-USC Medical Center, Dept of Otolaryngology–Head and Neck Surgery, 1200 N State St, Box 795, Los Angeles, CA 90033.

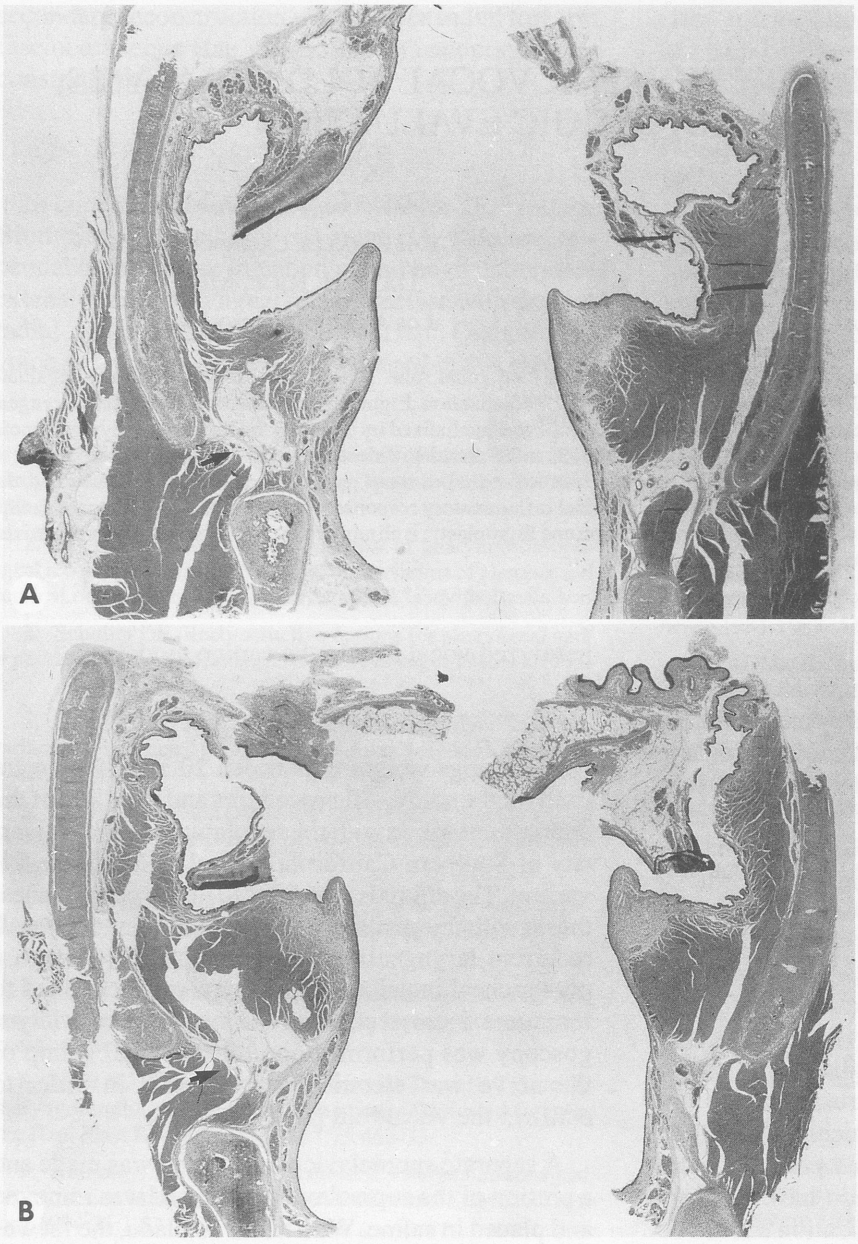

Fig 1. Coronal histologic sections. Arrow — injected fat. A) Three months after fat injection. Minimal inflammatory response is seen. Note atrophy of denervated muscle fibers. B) Six months after fat injection. Note lack of inflammation and continued atrophy of denervated muscle.

was breathing spontaneously. At this time the endotracheal tube was removed and the larynx was exposed with a tongue retractor and a 4-mm telescope. Under videolaryngoscopy, fat injections were made lateral to the true vocal fold at the middle third, as well as just lateral to the vocal process. Sufficient fat was injected to move the paralyzed fold to the midline. Variable amounts of fat were injected in the different dogs in order to obtain adequate medialization. The animals were divided into three groups that were painlessly sacrificed at 1 month (2 dogs), 3 months (3 dogs), and 6 months (3 dogs). Immediately prior to sacrifice, with intravenous sedation with thiopental, direct videolaryngoscopy was performed in order to evaluate and document the degree of medialization. After the animals were sacrificed, the larynges were removed and then sectioned and stained with hematoxylin and eosin. Microscopic specimens were analyzed for the amount of fat, the presence or absence of necrosis and/or lymphoid aggregates, and the degree of fibrosis. Selected specimens were further evaluated for fibrosis with Masson's stain. Fibrosis was graded as minimal, mild, or moderate.

RESULTS

Videolaryngoscopy. Videolaryngoscopy demonstrated good medialization of the vocal fold immediately after fat injection in each animal. Sequential laryngoscopy revealed continued medialization at 1 month, with a progressive decrease in bulk and volume noted in the 3- and 6-month animals.

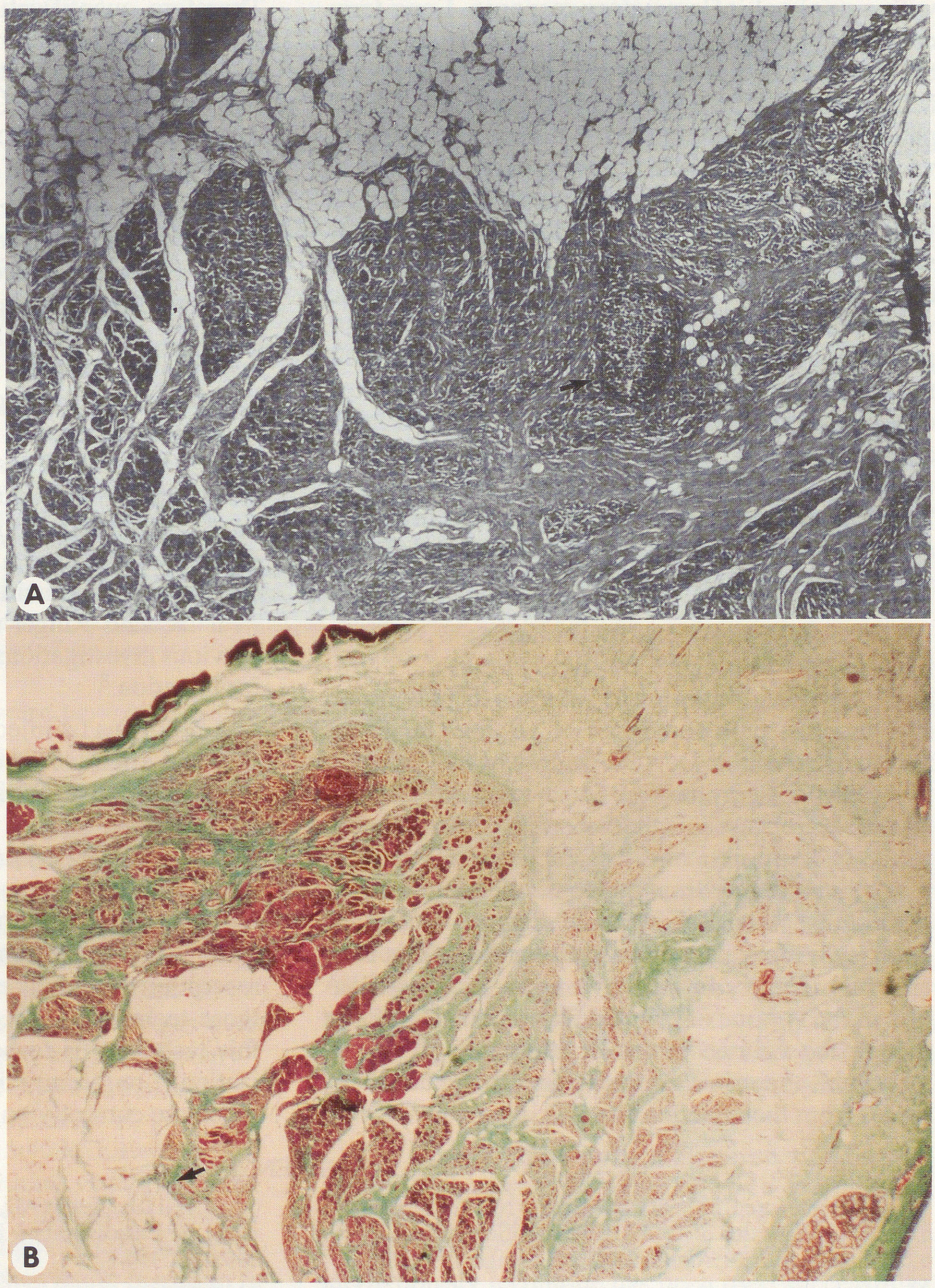

Fig 2. Six-month histologic sections. A) High-power section showing viable fat cells. Arrow — lymphoid aggregate. B) Masson's stain. Fibrosis (indicated by green color) occurs mostly between atrophic muscle fibers. Occasional areas of fibrosis are seen within fat. Arrow — injected fat.

Histology. Viable injected fat was identified in every dog. Its presence was easily identified by comparing the injected fold to the contralateral fold (Fig 1). The volume of fat appeared to be slightly less in the 6-month group when compared to the 1- and 3-month groups. A few scattered areas of lymphoid aggregates, some with germinal centers, were seen between the thyroarytenoid muscle fibers and the fat in 5 of the specimens (Fig 2A). One case demonstrated a lymphoid aggregate in the contralateral fold. Aggregates were only rarely identified in the injected fat itself. Another change was atrophy of various parts of the denervated thyroarytenoid muscle. At least some degree of atrophy was seen in almost all cases. Various degrees of fibrosis were seen between the atrophic muscle fibers (Fig 2B). None of the specimens showed any evidence of fat necrosis or acute inflammation.

DISCUSSION

The use of autologous fat for vocal fold augmentation in a canine model as well as in humans has previously been reported. Using a canine model, Hill et al[6] histologically evaluated the autologous fat injected into the thyroarytenoid muscle following recurrent laryngeal nerve sectioning. In their study the structure and volume of the fat was maintained,

with a minimal inflammatory response. Long-term conclusions cannot be made from their study, since the duration of the experiment was only 3 weeks. Mikaelian et al[4] in 1991 reported good results in 3 patients with autologous fat injection for unilateral vocal fold paralysis, with follow-up ranging from 3 to 12 months. Brandenburg et al[5] in 1992 reported on their experience with this technique in 11 patients with vocal fold paralysis. The follow-up period in this study was 5 to 42 months. They indicated that the vocal fold remained medialized in 10 patients, and 1 patient required reinjection. The results from their series are not consistent with previously reported observations on the long-term fate of injected fat in sites other than the larynx. Studies indicate that 20% to 90% of injected fat will ultimately be reabsorbed.[7] To the best of our knowledge, there are no previously reported studies on the long-term fate of fat injected into laryngeal muscles.

The videolaryngoscopic observations in our study indicate that autologous fat injected into the thyroarytenoid muscle appears to maintain its bulk for up to 3 months, with some loss of volume, however, noted by 6 months. Despite the loss of bulk seen on videolaryngoscopy, a significant number of viable fat cells were present in the 6-month histologic specimens. In addition, atrophy of the laryngeal muscles was observed over time on histologic sections. It is possible that the loss of volume seen on videolaryngoscopy is also related to muscle atrophy. This is an area that requires further investigation. Quantification of the volume of injected fat was difficult. Even though the volume in the Bruning syringe can be measured, there is a certain amount of fat that extrudes from the injection site and is suctioned away. Therefore, quantification could not be done by post-injection volume subtraction. On the average, 4 syringe clicks were used to attain the desired medialization. Microscopically, a minimal inflammatory response was seen, supporting the relative safety of this procedure.

Fat graft resorption rates are related to the ability of the graft to establish vascularity in the recipient bed. Many factors have been proposed to influence the survivability of the fat, including the handling of the graft, the technique of harvesting, and the method of insertion.[7-9] Previous investigators have attempted various ways to enhance the survival of transplanted fat by pretreatment of the fat with various solutions prior to injection. These treatments include washing the fat with saline or nutrient medium, immersing the fat in insulin, and adding hormonal factors.[7-9] In this experiment we used a simple method of harvesting combined with mincing the graft and then washing it with lactated Ringer's solution. As suggested by previous investigations, a large-bore needle was used for injection.[8]

Autologous fat injection appears to be a relatively safe and effective method of medializing the paralyzed vocal fold. While variability in resorption is expected, the bulk of the fat graft lasted at least 3 months in our experiment. It would appear, therefore, that this technique would be ideal for those patients whose paralysis has not yet been deemed permanent. Certainly, with the tremendous variability reported in resorption rates, future studies are needed to evaluate those techniques that will prolong graft survival if this technique is to be used for long-term medialization. Long-term clinical studies using this technique are currently ongoing at our institution.

REFERENCES

1. Kasperbauer JL, Slavit DH, Maragos NE. Teflon granulomas and overinjection of Teflon: a therapeutic challenge for the otorhinolaryngologist. Ann Otol Rhinol Laryngol 1993;102:748-51.

2. Schramm VL Jr, May M, Lavorato AS. Gelfoam paste injection for vocal cord paralysis: temporary rehabilitation of glottic incompetence. Laryngoscope 1978;88:1268-73.

3. Koufman JA, Isaacson G. Laryngoplastic phonosurgery. Otolaryngol Clin North Am 1991;24:1151-77.

4. Mikaelian DO, Lowry LD, Sataloff RT. Lipoinjection for unilateral vocal cord paralysis. Laryngoscope 1991;101:465-8.

5. Brandenburg JH, Kirkham W, Koschkee D. Vocal cord augmentation with autogenous fat. Laryngoscope 1992;102:495-500.

6. Hill DP, Meyers AD, Harris J. Autologous fat injection for vocal cord medialization in the canine larynx. Laryngoscope 1991;101:344-8.

7. Boyce RG, Nuss DW, Kluka EA. The use of autogenous fat, fascia, and nonvascularized muscle grafts in the head and neck. Otolaryngol Clin North Am 1994;27:39-68.

8. Mak K, Toriumi DM. Injectable filler materials for soft-tissue augmentation. Otolaryngol Clin North Am 1994;27:211-22.

9. Nguyen A, Pasyk KA, Bouvier TN, Hassett CA, Argenta LC. Comparative study of survival of autologous adipose tissue taken and transplanted by different techniques. Plast Reconstr Surg 1990;85:378-89.

"WINDOW" LARYNGOPLASTY: A NEW COMBINED LASER ENDOSCOPIC AND OPEN TECHNIQUE FOR CONSERVATION SURGERY

STANLEY M. SHAPSHAY, MD
ZHI WANG, MD
ELIE E. REBEIZ, MD
DONALD F. PERRAULT, JR
MICHAIL M. PANKRATOV, MS
BURLINGTON, MASSACHUSETTS

Endoscopic laser resection of early laryngeal carcinoma is an increasingly used treatment modality; however, the limited exposure achieved and the alteration of vocal function are still major problems. A new surgical procedure, "window" laryngoplasty, has been devised and tested in an in vivo study in 6 canines with 50 days' survival. The right vocal cord was incised endoscopically with the carbon dioxide laser, and the en bloc specimen with adjacent thyroid cartilage was removed through a window approach made in the thyroid cartilage. A sternohyoid muscle flap based superiorly was inserted into the cartilaginous window to reconstruct a pseudocord with coverage of either mucosa or fascia. A diode laser soldering technique was used to secure the mucosal graft in place. Epithelial transplantation can be accomplished externally with precise endoscopic guidance for reliable placement of the pseudocord. The results show that the new technique, a combination of endoscopic and open approaches, may be a better treatment choice than standard vertical partial laryngectomy in selected patients. Advantages of this technique include adequate en bloc resection, including adjacent cartilage for pathologic evaluation, preservation of the integrity of most of the laryngeal framework, avoidance of tracheotomy, and better functional results.

KEY WORDS — canine, endoscope, laryngeal carcinoma, laryngoplasty, laser.

INTRODUCTION

The concept of endoscopic resection of early laryngeal carcinoma has gained considerable popularity since the introduction of the carbon dioxide (CO_2) laser over 20 years ago. Successful use of the laser began experimentally with Jako,[1] and subsequently, Strong[2] presented his early clinical results in 1975. This endoscopic approach for the treatment of T1 vocal cord carcinoma offers some advantages over conventional partial laryngectomy and radiotherapy.[3] However, endoscopic laser excision has distinct limitations when used for the treatment of laryngeal carcinoma. These limitations include inadequate exposure in selected patients limiting visualization,[4,5] difficulty with reconstruction of the defects through the endoscopic approach, and impaired voice quality compared with radiotherapy when major resection is required.[6,7] When treating large, bulky T1 tumors, it is also difficult to determine depth of invasion and, in particular, to determine invasion of cartilage. Radiotherapy for early vocal cord carcinoma achieves excellent control of carcinoma; however, disadvantages include permanent side effects of dryness and voice impairment of variable degree and the requirement of 6 weeks of therapy, diminishing its cost-effectiveness. A surgical approach for early vocal cord carcinoma limiting resection to achieve adequate but not excessive margins and physiologic reconstruction under direct visualization would be a welcome addition to conservation laryngeal surgery. All too often, vertical partial laryngectomy techniques sacrifice large portions of thyroid cartilage to permit reconstruction of the glottis for adequate voice and to achieve glottic competence to prevent aspiration.

Can a major vocal cord en bloc resection be performed with surrounding cartilage by a combination of endoscopic and open techniques for conservation larynx surgery? The thyroid cartilage "window" laryngoplasty technique has been used successfully in treating unilateral vocal cord paralysis.[8-10] Its major advantage is preservation of the cartilaginous framework of the thyroid cartilage with minimal damage to the normal laryngeal structures through an external approach. In this in vivo canine study, the feasibility of using the concept of this technique as a

From the Department of Otolaryngology–Head and Neck Surgery and the Eleanor Naylor Dana Laser Research Laboratory, Lahey Clinic, Burlington, Massachusetts. This research was supported in part by a grant from the Eleanor Naylor Dana Charitable Trust, New York, New York. This study was performed in accordance with the PHS Policy on Humane Care and Use of Laboratory Animals, the NIH *Guide for the Care and Use of Laboratory Animals*, and the Animal Welfare Act (7 U.S.C. et seq.); the animal use protocol was approved by the Institutional Animal Care and Use Committee (IACUC) of Lahey Clinic.

Presented at the meeting of the American Laryngological Association, Palm Beach, Florida, May 7-8, 1994.

REPRINTS — Stanley M. Shapshay, MD, Dept of Otolaryngology–Head and Neck Surgery, New England Medical Center 850, 750 Washington St, Boston, MA 02111.

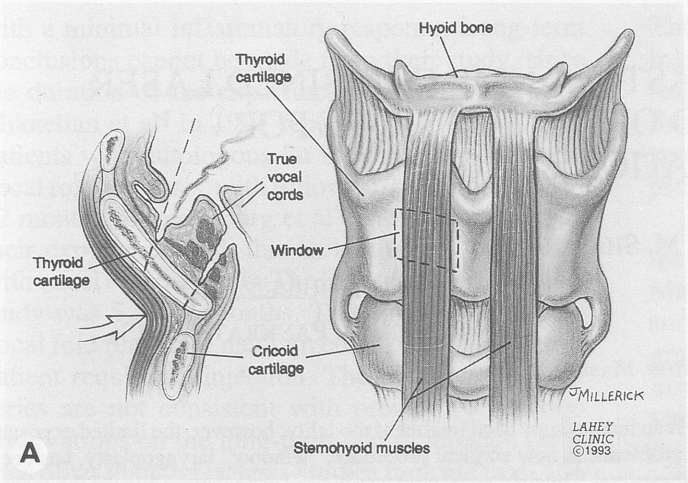

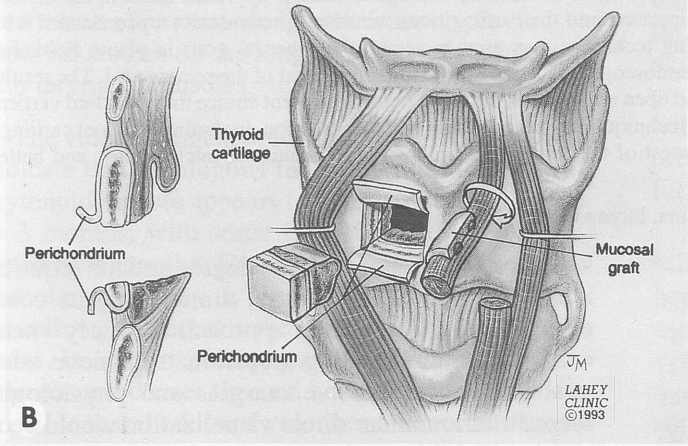

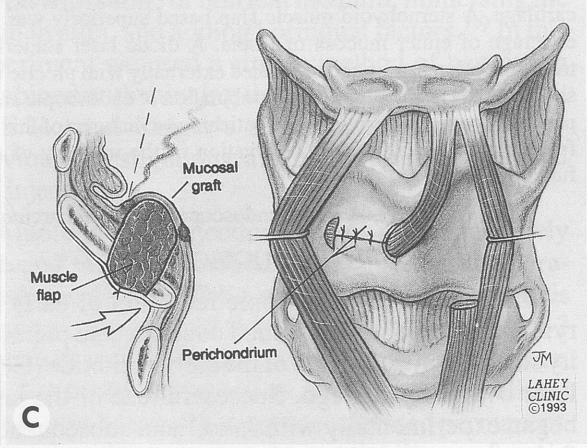

Fig 1. Schematic drawings of operation. A) Incision of right vocal cord is performed with carbon dioxide laser endoscopically (dashed line). B) Window on thyroid cartilage is created with removal of en bloc specimen, including vocal cord and thyroid cartilage. C) Pseudocord is reconstructed with sternohyoid muscle flap and welded mucosal graft after closure of window. (Reproduced with permission of Lahey Clinic.)

supplementary approach for endoscopic laser partial laryngectomy is explored. This new procedure, a combination of endoscopic and external approaches, is expected to overcome the limitations of the endoscopic approach alone and to minimize the morbidity associated with standard open partial laryngectomy.

MATERIALS AND METHODS

Six beagle dogs weighing 13 to 15 kg were used for the in vivo study in accordance with institutional guidelines for the care and use of animals. A suspension microlaryngoscopy (Dedo-Jako laryngoscope, Pilling Co, Philadelphia, Pa) was performed for glottic exposure after intravenous administration of general anesthesia with pentobarbital, 15 to 20 mg/kg of body weight. For preservation of the false vocal cord and better exposure of the subglottic larynx, a surgical assistant was asked to manually displace the thyroid cartilage alae medially during laser excision. Through an operating microscope (OPMI 1, Carl Zeiss, Thornwood, NY) with a 400-mm objective lens, a CO_2 laser with a microspot manipulator (Unilase, IL Med, Walpole, Mass), delivering a spot size of 300 μm at 1.5 to 2.5 W in continuous mode, was used to make an incision (8 × 15 mm) completely encompassing the right vocal cord (Fig 1A). The laryngeal framework was exposed through a neck incision, and a sternohyoid muscle flap was prepared. A needle was inserted through the thyroid cartilage into the laryngeal lumen and was viewed endoscopically to ensure correct position of the cartilaginous "window," which then was created to complete en bloc resection (Figs 1B and 2A).

The 6 dogs were divided into two groups of 3 based on mucosal or fascial coverage for the sternohyoid muscular flap. In the animals in group 1, free mucosa was used to cover a muscle flap. A piece of buccolabial mucosa of full thickness was obtained with a surgical blade, and the incision was closed with sutures of 3-0 Dexon. The mucosal graft was soldered onto the denuded inner surface of the muscular flap with a mixture of 1% indocyanine green dye and human fibrin adhesive with a 1-mm spot size at 400 mW of power from an 810-μm diode laser (Oculight, Iris Medical, Mountain View, Calif) in continuous mode. The pedicled muscle was inserted into the laryngeal window to serve as a new vocal cord, with the mucosa facing the endolarynx. The position of the recon-

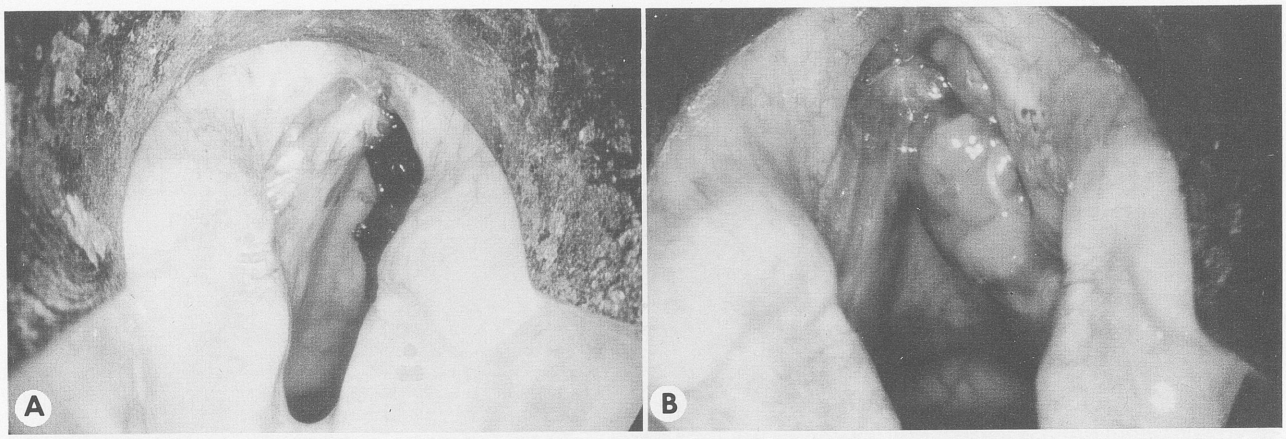

Fig 2. Endoscopic views. A) Appearance after removal of en bloc specimen through cartilaginous window. B) With guidance of endoscopic view, pseudocord was reconstructed externally through window.

structed vocal cord was adjusted externally under endoscopic monitoring until satisfactory glottic reconstruction was achieved (Fig 2B). Closure of the window was accomplished by reapproximation of thyroid perichondrium with interrupted sutures of 4-0 Dexon, and the skin was closed with sutures of 2-0 Dexon. Endoscopically, any remaining gap between the wound and the graft was soldered precisely as described and coated with fibrin adhesive glue solution as a seal (Fig 1C). Animals in group 2 received fascial coverage of the muscle flap. We used the overlying fascia on the sternohyoid muscle flap as coverage. The remainder of the procedure was the same as for group 1. Control animals without reconstruction were not entered in this study. The contralateral normal vocal cord served as both the control and the model for reconstruction.

The operating laryngoscope remained in place throughout the operation, and a long teaching arm on the microscope was angled toward the surgeon so the reconstructive procedure could be accomplished by the surgeon with minimal assistance as the surgeon monitored the endoscopic position of the reconstructed vocal cord. Alternatively, a video camera on the operating microscope could keep the endoscopic field in constant view.

Postoperatively, antibiotics were given for 3 days, and the animals were examined endoscopically at 10 days and immediately before sacrifice. The quality of the pseudocord reconstruction was evaluated and scored on a grading scale from 1 to 4 as compared with the contralateral normal control vocal cord. Grade 1 was 90% to 100% vocal cord reconstruction, grade 2 was 70% to 90%, grade 3 was 40% to 70%, and grade 4 was 0% to 40%. All animals were sacrificed painlessly 50 days after operation. The larynges were excised, fixed in 10% formalin solution, and decalcified for 24 hours before sectioning. Whole-organ sectioning was performed in an axial fashion with staining by hematoxylin and eosin for light microscopy.

The dogs' barks were tape-recorded before and after operation and then compared. The barks were

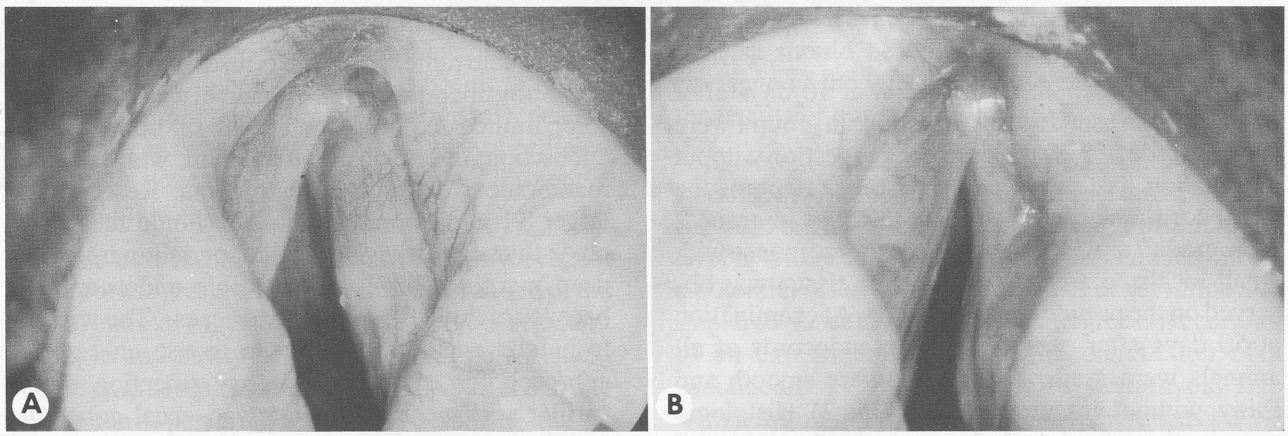

Fig 3. Endoscopic views of canine glottis at 50 days after operation. A) Group 1 (mucosal graft). Note excellent healing and appearance compared with normal (left) vocal cord. B) Group 2 (fascia). Note excellent healing; however, more scarring is seen here than in A.

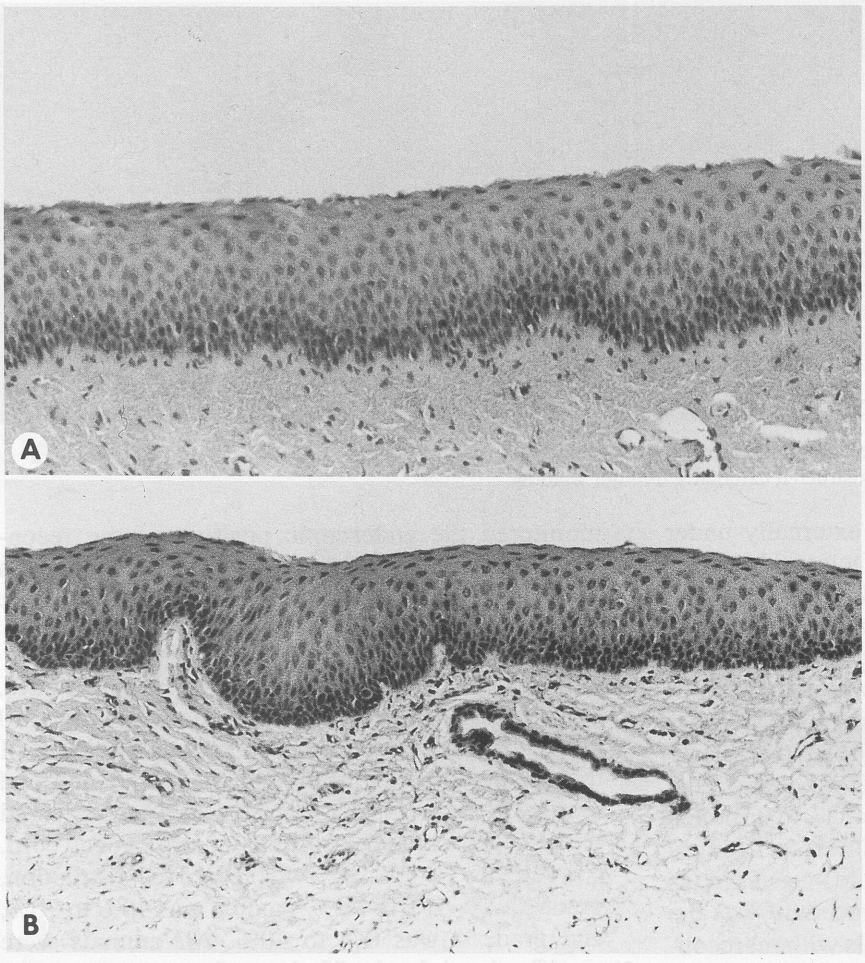

Fig 4. Photomicrographs showing pseudocord reconstruction in both groups at 50 days. Note normal squamous epithelium. A) Group 1. B) Group 2.

subjectively evaluated as normal, moderate, or weak (breathy).

RESULTS

All animals recovered with nearly normal intake of food and water on the first postoperative morning, and recovery proceeded normally without any complications before sacrifice. Specifically, no animal experienced aspiration, pneumonia, stridor, or subcutaneous emphysema, and tracheotomy was not required in any of the dogs.

At the endoscopic examination at 10 days after operation, the pseudocords in all dogs in group 1 were given a grade of 2. Some vascular congestion without granulation tissue was noted on the surface of the vocal cord. The pseudocords of the dogs in group 2 were grade 2 as well. An inflammatory response with small localized areas of granulation tissue was observed on the pseudocord of one dog. At examination at 50 days after operation, the pseudocords of all animals were grade 1. Surfaces were smooth and shiny, without granulation tissue (Fig 3). Histologic examination of axial whole-mount sections showed no difference in either group between experimental and contralateral control vocal cords. The overlying epithelium had normal squamous lining (Fig 4). Histologic findings confirmed that the pseudocords were reconstructed by an intact sternohyoid muscular flap placed through the cartilaginous window (Fig 5). Subjective analysis of the voice revealed that the dogs in group 1 had normal barks. However, in group 2, two dogs had moderate voice and the third had a weak voice.

DISCUSSION

Adequate tumor resection is an essential prerequisite to any operation for malignant disease, and therefore, limited exposure or access or both restricts endoscopic laser excision to a small, well-confined membranous vocal cord carcinoma. Resection of larger T1 vocal cord carcinomas should ideally include thyroid cartilage or at least perichondrium as a deep margin. This is not possible endoscopically because of limited exposure and access. The window technique enables the surgeon to use an external approach for adequate and easy resection of the cartilage adjacent to the involved vocal cord after endolaryngeal laser incision. It also makes it possible to enlarge any susceptible cartilaginous margin, if necessary. Additionally, the complete en bloc speci-

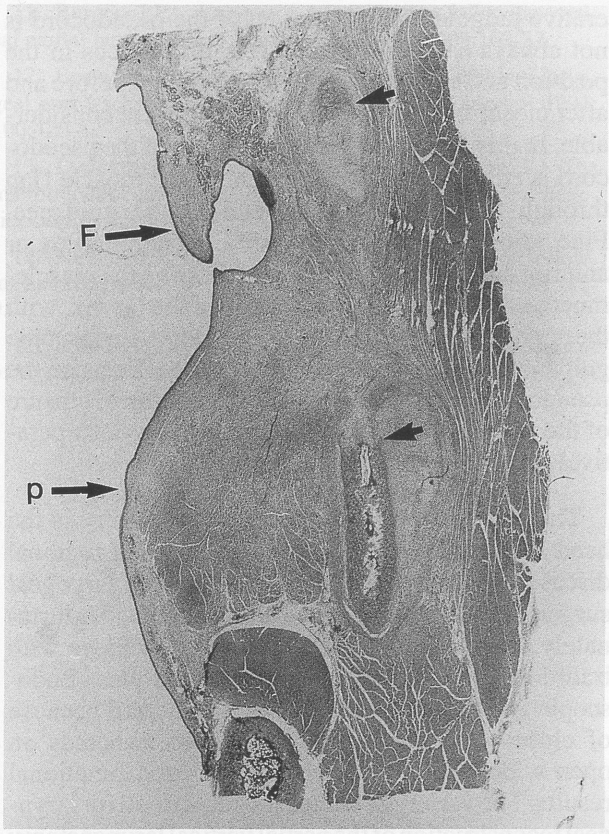

Fig 5. Whole-organ larynx coronal photomicrograph (50 days) showing pseudocord (p) reconstruction with sternohyoid muscle flap through thyroid cartilage window (arrowheads). F — false vocal cord.

men, including mucosa, muscle, and cartilage, will permit more accurate intraoperative frozen section examination and postoperative serial pathologic resection than that afforded by the endoscopic technique alone.

A traditional open approach[11] usually involves extensive resection of cartilage that impairs the integrity of the cartilaginous framework, which is a key element for normal laryngeal function and for the prevention of postoperative complications such as stenosis. On the other hand, it is difficult to reconstruct intraluminal structures endoscopically, despite the few successful cases reported with use of pedicled mucosa to cover the laryngeal wound through a transoral endoscope.[12,13]

In this new technique, most of the rigid laryngeal framework is preserved with minimal resection of the normal endolaryngeal structures. The reconstruction is simple and easily performed with one assistant. The laser mucosal soldering onto the surface of the muscle can be performed externally before the muscle flap is inserted into the window. If preferred, mucosal sutures can also be used; however, they may be a site of foreign body reaction leading to granulation tissue. Additionally, because the rigid framework is preserved, it is less likely that the flap will rotate or move and cause disruption of the mucosa after closure of the perichondrium.

One of the most common problems in reconstruction after partial laryngectomy is that of providing mucosal coverage to avoid granulation tissue and subsequent scarring. A variety of tissues, including mucosa, fascia, and skin, have been used for reconstruction. In this in vivo study, the muscle flaps were covered with either free mucosa or fascia. Morphologically, no differences existed between the groups after complete healing. However, the mucosal coverage is favored for functional results. Our results are consistent with those of other published reports[14,15] indicating that voice quality with mucosal grafting is superior to that obtained with other covering materials. Although the exact nature of these differences is unclear, they are thought to be related to tissue compliance and epithelial sensory receptors. It is well established that voice quality depends not only on competency of the glottic chink but also on a number of compliance factors, including tissue viscosity and vocal cord and epithelial thickness and stiffness, that could be determinants of vibration in mechanical and acoustic oscillating systems.[16] Additionally, several types of mechanoreceptors, sensitive to air pressures and airflows, have been described in laryngeal mucosa. They may provide information critical to phonatory control, such as rapid and fine adjustments of the larynx.[17]

Using fascia for the reconstructed vocal cord has certain advantages. It can be mobilized and tailored to cover or fill defects and has a strong ability to resist infections because of its low metabolic rate. The natural fascial covering of the sternohyoid muscle permits excellent approximation to the remaining laryngeal mucosa and subsequent rapid epithelialization.[18,19] However, if voice quality is important, mucosa should be considered the first choice for coverage of the intraluminal defect, on the basis of the results of our study.

In recent years, the bipedicled or unipedicled sternohyoid muscular flap has been a common material used for laryngeal reconstruction. Postoperative atrophy of the flap, especially the unipedicled one, is a potential disadvantage because of denervation and impaired vascularity of various degrees. According to an experimental study of reconstruction of a pseudocord with the unipedicled sternohyoid flap with a follow-up time of 6 months, there was a 23% reduction in the size of the flap. For this reason, attention should be given to the need for more bulk when planning to use this muscle flap. In addition,

epithelial coverage of the flap may minimize the chance of atrophy.[11] In our study, the muscle pedicle flap was designed to provide 30% more bulk than the normal vocal cord, with complete epithelial coverage (Fig 2B). We believe careful preparation of the pedicled muscle flap with microsurgical technique to preserve the blood supply and neural integrity is essential for reconstruction of the pseudocord. Sectioning of the sternohyoid muscle below the level of the cricoid cartilage will preserve the neural supply from the ansa cervicalis nerve.

Clinically, in an ideal situation, when tumor stage (large T1 and T2) permits this technique, it would be best to resect a vocal cord tumor completely with adequate margins, including adjacent cartilage. Precise reconstruction of the defect should take place with minimal disturbance of normal structures, avoiding tracheotomy if possible. To prevent secondary stenosis, complete mucosal resurfacing is necessary. This new technique, using combined endoscopic and open approaches for resection and reconstruction, appears to meet these criteria while probably shortening the hospital stay to 2 or 3 days.

With assistance of the external approach, this technique would not be limited to the treatment of confined early laryngeal carcinomas. It is reasonable to extend this approach to treatment of selected patients with larger T2 carcinomas involving the anterior commissure, provided an adequate cartilaginous framework is left after adequate resection of the tumor. However, this technique is contraindicated for any endoscopic resection of tumor located on the posterior aspect of the larynx, because of the difficulty in accessing the paraglottic space.

With use of the standard external partial laryngectomy approach in which normal intraluminal structures are resected along with the tumor, an intraoperative judgment on placement of the pseudocord is not always easy to make. Often, differences in the position and appearance of the vocal cord before and after closure of the thyroid ala incision are considerable. In this study, the precise position of the pseudocord is ensured by the placement of the muscle flap through the window under endoscopic guidance. Fine adjustment of the reconstructed hemilarynx or anterior commissure is made by adjusting the muscle-mucosa flap onto the desired area of the larynx, with the opposite cord used as a reference point. Endoscopic guidance is critical to these judgments. Because the pseudocord is fixed in position with sutures, closure of the wound will not change its position postoperatively.

The essential purpose of oncologic surgery in the head and neck is to obtain good control of regional disease, whereas the aim of conservative laryngeal surgery is to improve the quality of life. Unfortunately, these two goals are difficult to achieve with traditional partial laryngectomy techniques. Endoscopic limited resection has been criticized because of close, difficult-to-control margins, whereas an open wide resection compromises good functional results. The variety of techniques described for laryngeal reconstruction of the partial vertical laryngectomy defect over the past 20 years reflects the severity of the problem and the high rate of complications associated with the reconstruction. The simplicity of this new window approach, combining the advantages of endoscopic laser and external approaches, seems to indicate that the window technique could be a useful adjunct to existing reconstructive techniques, with adequate resection of the tumor and preservation of function. It appears to meet the criteria of the 1990s, that is, less invasiveness and more cost-effectiveness, and thus warrants careful clinical trials.

ACKNOWLEDGMENTS — We thank Christine Thomas, MD, and William Hamilton of the Department of Anatomic Pathology and Marygail Even and Sandra Brigham of our laboratory for their invaluable assistance. The diode laser was provided on loan by Iris Medical Instruments, Mountain View, California.

REFERENCES

1. Jako GJ. Laser surgery of the vocal cords. An experimental study with carbon dioxide lasers on dogs. Laryngoscope 1972; 82:2204-16.

2. Strong MS. Laser excision of carcinoma of the larynx. Laryngoscope 1975;85:1286-9.

3. McGuirt WF, Koufman JA. Endoscopic laser surgery. An alternative in laryngeal cancer treatment. Arch Otolaryngol Head Neck Surg 1987;113:501-5.

4. Krespi YP, Meltzer CJ. Laser surgery for vocal cord carcinoma involving the anterior commissure. Ann Otol Rhinol Laryngol 1989;98:105-9.

5. Davis RK, Jako GJ, Hyams VJ, Shapshay SM. The anatomic limitations of CO2 laser cordectomy. Laryngoscope 1982; 92:980-4.

6. Wolfensberger M, Dort JC. Endoscopic laser surgery for early glottic carcinoma: a clinical and experimental study. Laryngoscope 1990;100:1100-5.

7. Annyas AA, Van Overbeek JJM, Escajadillo JR, Hoeksema PE. CO2 laser in malignant lesions of the larynx. Laryngoscope 1984;94:836-8.

8. Isshiki N, Taira T, Kojima H, Shoji K. Recent modifications in thyroplasty type I. Ann Otol Rhinol Laryngol 1989;98:777-9.

9. Godley FA. A simple implant design for vocal cord medialization. Laryngoscope 1992;102:824-6.

10. Tucker HM. Combined laryngeal framework medialization and reinnervation for unilateral vocal fold paralysis. Ann Otol Rhinol Laryngol 1990;99:778-81.

11. Burgess LPA. Laryngeal reconstruction following vertical partial laryngectomy. Laryngoscope 1993;103:109-32.

12. Beste DJ, Toohill RJ. Microtrapdoor flap repair of laryngeal and tracheal stenosis. Ann Otol Rhinol Laryngol 1991; 100:420-3.

13. Duncavage JA, Piazza LS, Ossoff RH, Toohill RJ. The microtrapdoor technique for the management of laryngeal stenosis. Laryngoscope 1987;97:825-8.

14. Hirano M, Kurita S, Matsuoka H. Vocal function following hemilaryngectomy. Ann Otol Rhinol Laryngol 1987;96:586-9.

15. Isshiki N, Taira T, Nose K, Kojima H. Surgical treatment of laryngeal web with mucosa graft. Ann Otol Rhinol Laryngol 1991;100:95-100.

16. Wexler DB, Jiang J, Gray SD, Titze IR. Phonosurgical studies: fat-graft reconstruction of injured canine vocal cords. Ann Otol Rhinol Laryngol 1989;98:668-73.

17. Leonard RJ, Kiener D, Charpied G, Kelly A. Effects of repeated stripping on vocal fold mucosa in cats. Ann Otol Rhinol Laryngol 1985;94:258-62.

18. Krajina Z, Kosokovic F, Vecerina S. Laryngeal reconstruction with sternohyoid fascia in partial laryngectomy. J Laryngol Otol 1979;93:1181-9.

19. Calcaterra TC. Sternohyoid myofascial flap reconstruction of the larynx for vertical partial laryngectomy. Laryngoscope 1983;93:422-4.

TEFLON GRANULOMA OF THE LARYNX: ETIOLOGY, PATHOPHYSIOLOGY, AND MANAGEMENT

MARK A. VARVARES, MD
ST LOUIS, MISSOURI

WILLIAM W. MONTGOMERY, MD
BOSTON, MASSACHUSETTS

ROBERT E. HILLMAN, PHD
BOSTON, MASSACHUSETTS

Intralaryngeal Teflon injection for correction of unilateral vocal cord paralysis is known to produce a foreign body giant cell reaction. In our practice, we have seen increasing numbers of patients who had developed dysphonia related to Teflon injection. This patient series was reviewed, as were the surgical technique to correct this condition, voice results, and acoustic analysis of a subset of the patient series. We conclude that dysphonia, secondary to Teflon injection, can be either from overinjection of Teflon or inappropriate injection, or from the proliferative granulomatous response of the larynx to the Teflon. Our technique of laser incision into the superior aspect of the Teflon implant, followed by vaporization and preservation of a margin of mucosa of the cord medially, resulted in improved voice in 8 of 11 patients treated in this manner. Acoustic and aerodynamic analyses reveal significant deficits in vocal function that may persist after procedures used to correct this condition.

KEY WORDS — granuloma, larynx, laser, Teflon.

INTRODUCTION

Teflon injection for the correction of unilateral vocal cord paralysis in the abducted position was introduced by Arnold in 1962,[1] and was the mainstay for management of this problem for over 25 years. With the recent introduction of laryngeal framework surgery and medialization laryngoplasty,[2-4] fewer centers advocate Teflon injection, although proponents do remain.[5-8] In general, Teflon is well tolerated after injection into the larynx, but there are patients who will develop problems with either overinjection or improper injection of Teflon, and there are those who will develop Teflon granulomas. These patients may develop dysphonia that is difficult to correct with present surgical techniques, while others may develop a progressive granulomatous response that leads to airway obstruction.

Rubin[9] was the first to identify problems in the use of Teflon for the paralyzed vocal cord. He pointed out that technical errors in Teflon injection, such as overinjection, injecting too close to the vocal cord margin, or injecting too deeply, could all lead to dysphonia. He introduced the technique of removing the granuloma from the substance of the vocal cord, while preserving a medial margin of mucosa. He emphasized that the granuloma that forms is truly within the substance of the thyroarytenoid muscle, and that complete removal of the granuloma would result in destruction of a significant amount of cord tissue, making it unlikely for the voice to be restored to a preinjection state.

The problem of unsatisfactory results after Teflon injection received further attention in several subsequent clinical series. Dedo[8] and Horn and Dedo[10] reported the incidence of this problem to be 2% to 3% in their series of Teflon injections. They recommended removal of Teflon through a microlaryngoscopy approach and a superior cord incision. They removed just enough Teflon to allow the convex vocal cord to fall into the midline position. The vocal cord lateralized to this position after removal of the Teflon and still vibrated in synchrony with the normal cord.

Pohris and Kleinsasser[11] reported a patient who developed airway obstruction 18 months after an uneventful Teflon injection that had initially resulted in voice improvement. They removed the Teflon by a thyrotomy to avoid mucosal incisions. The histologic study on the resected tissue revealed Teflon particles, granulation tissue, and muscle fibers. Grossly and pathologically, there was no evidence of encapsulation of the Teflon. Pohris and Kleinsasser recommended that Teflon by used only in patients with a short life span because of the irreversible changes associated with its injection.

Recently, three separate series of patients who

From the Department of Otolaryngology, Massachusetts Eye and Ear Infirmary, Harvard School of Medicine, Boston, Massachusetts. Dr Varvares is currently at the Department of Otolaryngology–Head and Neck Surgery, St Louis University Health Sciences Center, St Louis, Missouri.

Presented at the meeting of the American Laryngological Association, Palm Beach, Florida, May 7-8, 1994.

REPRINTS — Mark A. Varvares, MD, Dept of Otolaryngology–Head and Neck Surgery, St Louis University Health Sciences Center, 3635 Vista Ave at Grand Blvd, St Louis, MO 63110.

underwent treatment for problems with injected Teflon have been reported.[12-14] These reports describe removing Teflon with a carbon dioxide laser incision into the superior surface of the vocal cord and then subsequent use of sharp instruments for removal of the Teflon. These series point out the difficulty in achieving good airway and voice, and the need for multiple endoscopic procedures and adjunctive procedures such as arytenoid adduction and type I thyroplasty following Teflon removal.

The series of Nakayama et al[14] included both subjective and objective voice analyses. They found that 68% of their patients believed their voices were moderately or greatly improved after the Teflon problem was corrected, while 7% felt that their voices had deteriorated. The patients improved following Teflon removal as measured by increased vocal intensity and signal to noise ratio, with decreased jitter and shimmer. Aerodynamically, a postoperative increase in mean airflow was found. Findings on videostroboscopy revealed that seldom was there a normal mucosal wave at the site of the granuloma, and there was "supraventricular hyperfunction."

The effects of Teflon injected into the soft tissues have been well documented in both experimental and postmortem studies. When injected into the canine larynx, Teflon has been noted to cause initially a marked response of histiocytes and giant cells in active phagocytosis. Moderate numbers of lymphocytes are noted, as are plasma cells. Within central portions of the foreign material, acute inflammation with dense infiltrates of neutrophilic polymorphonuclear cells can be seen. By 2 months following injection, the acute inflammation has subsided, and essentially what remains of the implant are Teflon particles surrounded by an exuberant formation of giant cells noted to be actively phagocytosing the Teflon.[15,16]

One experimental study found that when injected into the canine larynx, the 50- to 100-μm Teflon particles were disseminated in the cervical lymphatic system.[17] All animals injected and subsequently evaluated showed uptake of Teflon in the cervical lymph nodes, but this uptake did not increase with time. This finding suggests that lymphatic dissemination occurs at the time of injection and is not an ongoing process. There was no evidence of distant Teflon deposition beyond the confines of the cervical lymphatic system.

Postmortem evaluation of the human larynx after Teflon injection has been reported.[18-20] These studies revealed that the response to Teflon in all cases showed foreign body giant cells and mature collagen fibers as a matrix for the Teflon particles, contained within a dense fibrous envelope. In some cases the reaction products to Teflon and the Teflon itself were found to be extralaryngeal, having passed through the cricothyroid space and into the neck.

Dedo and Carlsöö[21] evaluated Teflon that was removed from 12 patients 4 weeks to 16 years post-injection. These patients showed no improvement in their voices immediately after Teflon injection, or had initial improvement in their voices only to have deterioration at a later date. In specimens evaluated at 4 weeks, Teflon particles were observed in the soft tissue of the larynx, and were found to have elicited numerous mononuclear histiocytes and a few lymphocytes. At 3 months, however, strands of fibrous tissue were observed to be intermingling between islands of Teflon particles, and a tendency toward encapsulation of the entire granuloma was present. This finding was seen throughout all of the more mature specimens and seemed not to change significantly. In addition, all patients evaluated at 3 or more months showed that in the setting of this dense collagenous tissue, there was a minimal inflammatory cell infiltrate. There were, however, in all cases numerous multinucleated giant cells. These results were further supported in a subsequent study.[22]

MATERIALS AND METHODS

The records of all patients in the senior author's series (W.W.M.) who presented with problems with Teflon implants after injection into the larynx since 1986 were reviewed. Charts were evaluated for the patient's age and sex, the site of disease, the cause of laryngeal paralysis that required Teflon injection, the interval between onset of symptoms and injection, the number of injections and voice results, the interval between injection and development of symptoms related to Teflon, the number of procedures required to treat the pathologic process, and the final voice results.

The analysis of voice results in this retrospective series was subjective and based on a patient's satisfaction with his or her voice and the surgeon's observation. Voices were judged to be good if the patient had a functional voice, with only mild amounts of dysphonia; moderate or marked dysphonia was considered a poor result. In the latter part of this series, patients underwent a complete voice analysis that included videostroboscopy, electroglottography, aerodynamic analysis of laryngeal airflow and subglottal pressure, and analysis of voice frequency, intensity, and perturbation.

All procedures were done under general anesthesia after intubation with a laser-safe endotracheal tube

RESULTS OF STUDY

Patient	Age (y)	Sex	Side	Cause of Paralysis	No. of Injections	Voice After Injections	Interval to Symptoms of Dysphonia (y)	No. of Procedures to Remove Teflon	Voice Results
1	41	M	R	Idiopathic	1	Good	11	1	Good
2	29	F	R	Vocal fold scarring	1	Poor	0	3	Good
3	42	M	R	Idiopathic	1	Good	1.5	3	Poor
4	68	F	R	Idiopathic	1	Poor	1	4	Good
5	26	F	L	Head injury	2	Poor	0	1*	Good
6	57	M	L	Idiopathic	1	Poor	0	1	?
7	37	F	L	Idiopathic	1	Poor	0	2	Good
8	55	F	L	Recurrent nerve section for spastic dysphonia	1	Poor	0	1	Good
9	56	M	L	Idiopathic	1	Good	7	1	Poor
10	32	M	L	Neck trauma	1	Poor	0	2	Good
11	35	M	L	Glomus tumor resection	2	Good	5	2	Good
12	42	F	L	Excision of neck tumor	1	Good	22	2	Poor
13	73	M	R	Excision of laryngeal chondroma	1	Good	25	1	Good

Only patient 7 had tracheotomy.
*Treated by steroid injection alone.

(Xomed-Treace). A Dedo laryngoscope was used. The patient was placed into suspension, and the operating microscope with the attached Coherent carbon dioxide laser was used to create an incision in the superior aspect of the vocal fold. Once the incision was made, the laser was used to vaporize the Teflon. This was done so as to preserve a margin of intact mucosa medially. In one case (patient 4) it was not possible to preserve the medial mucosal margin, and a partial cordectomy was performed. In one other case (patient 5) the laser was not used. Instead, the granuloma was injected with triamcinolone diacetate alone.

RESULTS

Results are summarized in the Table. There were 13 patients available for review: 6 women and 7 men. The ages ranged from 26 to 73 years of age. All lesions were unilateral, with eight on the left side and five on the right side. The causes leading to initial injection were idiopathic cord paralysis (6), closed head injury (1), neck trauma (1), glomus jugulare (1), bowed vocal cords (1), recurrent laryngeal nerve section for spastic dysphonia (1), laryngeal chondroma resection (1), and neck neurofibroma resection (1). The interval between onset of symptoms and injection ranged from 1 to 11 years.

After injection, 6 patients noted significant improvement in their voices, 1 patient noted only slight improvement, and 6 patients reported no improvement. The number of injections per patient varied, with 11 patients having one injection, while 2 patients had two injections. All patients presented to the senior author with dysphonia as their primary symptom.

The interval between injection and the development of dysphonia that prompted presentation also varied. As noted above, 6 patients had no improvement and a persistence of dysphonia immediately following injection, while in the remaining patients an interval of improved voice was followed by onset of dysphonia 1, 1.5, 5, 7, 11, 22, and 25 years following injection. The number of postinjection procedures required to correct the disorder also varied. Six patients required only one procedure, while 4 patients required two, and 2 patients required three procedures. Only 1 patient required four procedures. One patient required a tracheotomy perioperatively, but was decannulated in the perioperative period with an adequate airway.

Postoperatively, 9 patients were felt to have good voice after their last procedure, while 3 patients had a poor voice. One patient (patient 6) was not evaluated for voice quality postoperatively. The pathologic evaluation on all patients who had tissue removed revealed Teflon particles surrounded by a dense fibrous proliferation and foreign body giant cells. A representative specimen is seen in the Figure.

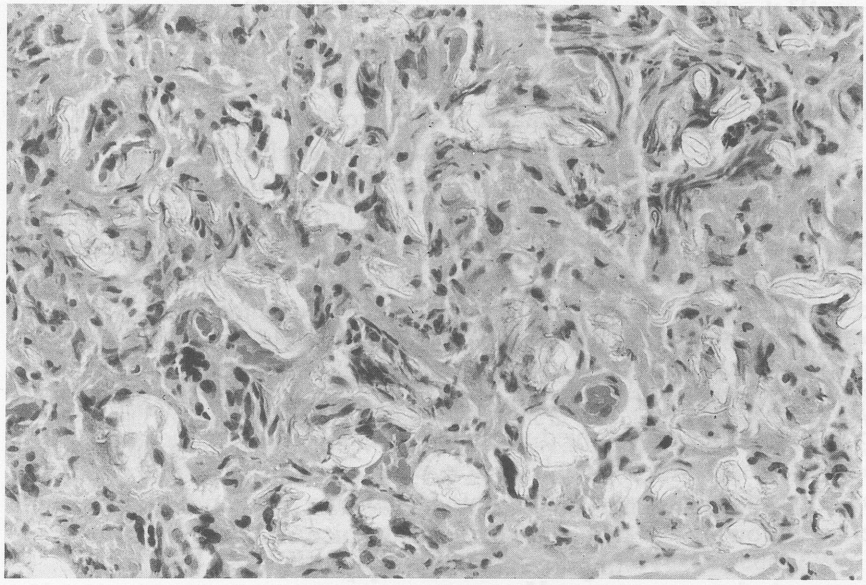

Representative pathologic specimen. Note Teflon particles, dense collagenous deposition, and multinucleated giant cells.

The results of the voice analysis on 6 patients who were seen in the latter part of the series revealed that vocal dysfunction was present both before and after attempts to remove the Teflon implant. All 6 patients evaluated showed abnormally high frequency perturbation (jitter) values. Four patients (1 preremoval and 3 postremoval) had increased amplitude perturbation (shimmer), and 2 postremoval patients had voices that were aperiodic (no measurable fundamental frequency). Three postremoval patients revealed decreased sound pressure levels. When evaluated aerodynamically, 4 patients (1 preremoval and 3 postremoval) displayed abnormally high subglottal air pressures, with 1 preremoval patient having decreased average airflow, and 3 patients (1 preremoval and 2 postremoval) having abnormally high airflows. Finally, 5 patients (2 preremoval and 3 postremoval) displayed decreased or abnormal (unmeasurable) electroglottographic duty cycles. Videostroboscopy revealed absence of, or a significantly reduced, mucosal wave on the affected vocal fold in both preremoval and postremoval patients.

DISCUSSION

The analysis of the presentation, treatment, and results of this series of patients contributes to a better understanding of the pathophysiology of the Teflon implant in the human larynx. This series suggests that there were two basic types of patient outcomes (groups) associated with Teflon injection: 1) patients whose voices do not improve with injection of Teflon; and 2) patients who initially display a good vocal result following injection of Teflon, but subsequently, be it months or years later, develop increasing dysphonia, requiring reevaluation.

We suggest that the first group represents patients who had either overinjection of or improperly injected Teflon. The second group, who developed delayed symptoms, represents patients who had Teflon injected in a proper quantity and location, but who developed an exuberant granulomatous response that eventually led to unfavorable vocal cord bulk and positioning and resultant dysphonia.

Analysis of the pathologic process in the present series and the literature review make it clear that all patients who have Teflon injected into the larynx develop a granulomatous response that results in a gradual degradation of the injected material by foreign body giant cells and a fibroblastic proliferation in the location of the implant.

Since it is the case that all Teflon injected into the human larynx does elicit a granulomatous response, we speculate that the incidence of granuloma or a convex vocal cord following Teflon injection is actually greater than the 2% to 3% reported.[8,10] Certainly the experience in our practice over the last 8 years appears to support this assumption as well.

The results of the present and previously reported clinical series demonstrate that it can be very difficult to attain improvement in voice following removal of Teflon from the larynx. Our technique, which preserves the medial margin of the vocal cord mucosa while removing just enough Teflon to place the paralyzed vocal cord into a favorable position, resulted in improvement in 8 of 11 patients who could be evaluated. (Patient 5 did not have the laser technique, and patient 6 was lost to follow-up before his voice was analyzed.) We have not as yet had to perform adjunctive procedures such as thyroplasty or arytenoid adduction following removal of Teflon,

although we agree with Kasperbauer et al[13] that this is a viable option in patients with residual dysphonia following removal of Teflon, particularly in cases that are characterized primarily by excessive "breathiness" (ie, insufficient adduction).

We have only recently been able to perform vocal analysis on our patients who present with problems related to Teflon injection. Unfortunately, our group was not uniformly evaluated both preoperatively and postoperatively. Because of this, we cannot report objective changes in voice following our surgical procedure. We do believe, however, that the value of the voice analysis data is that they support the clinical impression that patients who develop Teflon granulomas or who have Teflon injected in too great a quantity or in an improper location have significant deficits in vocal function that can persist following attempts at surgical intervention.

CONCLUSION

The management of patients who present with difficulties related to Teflon injection continues to be problematic. It is difficult to obtain voices that approach the predisease state when attempting to correct problems related to Teflon. Although the frequency with which Teflon is injected into the human larynx continues to decline, we believe that we will continue to see patients with problems related to injected Teflon for many years to come. In our own experience we have had patients present with problems related to Teflon as many as 25 years following injection. We believe that the best chance for improved voice is a conservative treatment, in which enough Teflon is removed to bring the paralyzed vocal cord into a favorable position. While this will not allow a normal voice, it can give significant improvement to many patients.

REFERENCES

1. Arnold GE. Vocal rehabilitation of paralytic dysphonia. VIII. Phoniatric methods of vocal compensation. Arch Otolaryngol 1962;76:76-83.

2. Koufman JA. Laryngoplasty for vocal cord medialization: an alternative to Teflon. Laryngoscope 1986;96:726-31.

3. Maves MD, McCabe BF, Gray S. Phonosurgery: indications and pitfalls. Ann Otol Rhinol Laryngol 1989;98:577-80.

4. Montgomery WW, Blaugrund SM, Varvares MA. Thyroplasty: a new approach. Ann Otol Rhinol Laryngol 1993;102:571-9.

5. Ward PH, Hanson DG, Abemayor E. Transcutaneous Teflon injection of the paralyzed vocal cord: a new technique. Laryngoscope 1985;95:644-9.

6. Alessi DM, Berke GS, Trapp TK, Gerratt BR, Hanson DG. An accurate method of Teflon injection using functional phonosurgery. Arch Otolaryngol Head Neck Surg 1988;114:1321-3.

7. Strasnick B, Berke GS, Ward PH. Transcutaneous Teflon injection for unilateral vocal cord paralysis: an update. Laryngoscope 1991;101:785-7.

8. Dedo HH. Injection and removal of Teflon for unilateral vocal cord paralysis. Ann Otol Rhinol Laryngol 1992;101:81-6.

9. Rubin HJ. Misadventures with injectable polytef (Teflon). Arch Otolaryngol 1975;101:114-6.

10. Horn KL, Dedo HH. Surgical correction of the convex vocal cord after Teflon injection. Laryngoscope 1980;90:281-6.

11. Pohris E, Kleinsasser O. Stenosis of the larynx following Teflon injection. Arch Otorhinolaryngol 1987;244:44-8.

12. Ossoff RH, Koriwchak MJ, Netterville JL, Duncavage JA. Difficulties in endoscopic removal of Teflon granulomas of the vocal fold. Ann Otol Rhinol Laryngol 1993;102:405-12.

13. Kasperbauer JL, Slavit DH, Maragos NE. Teflon granulomas and overinjection of Teflon: a therapeutic challenge for the otorhinolaryngologist. Ann Otol Rhinol Laryngol 1993;102:748-51.

14. Nakayama M, Ford CN, Bless DM. Teflon vocal fold augmentation: failures and management in 28 cases. Otolaryngol Head Neck Surg 1993;109:493-8.

15. Toomey JM, Brown BS. The histological response to intracordal injection of Teflon paste. Laryngoscope 1967;77:110-20.

16. Kirchner FR, Toledo PS, Svoboda DJ. Studies of the larynx after Teflon injection. Arch Otolaryngol 1966;83:350-4.

17. Ellis JC, McCaffrey TV, DeSanto LW, Reiman HV. Migration of Teflon after vocal fold injection. Otolaryngol Head Neck Surg 1987;96:63-6.

18. Harris HE Jr, Hawk WA. Laryngeal injection of Teflon paste. Report of a case with postmortem study of the larynx. Arch Otolaryngol 1969;90:194-7.

19. Stone JW, Arnold GE, Stephens CB. Intracordal polytef (Teflon) injection. Histologic study of three further cases. Arch Otolaryngol 1970;91:568-74.

20. Schmidt PJ, Wagenfeld D, Bridger MWM, van Nostrand AWP, Briant TDR. Teflon injection of the vocal cord: a clinical and histopathologic study. J Otolaryngol 1980;9:297-302.

21. Dedo HH, Carlsöö B. Histologic evaluation of Teflon granulomas of human vocal cords. A light and electron microscopic study. Acta Otolaryngol (Stockh) 1982;93:475-84.

22. Wenig BM, Heffner DK, Oertel YC, Johnson FB. Teflonomas of the larynx and neck. Hum Pathol 1990;21:617-23.

NONINVASIVE MEASUREMENT OF TRAVELING WAVE VELOCITY IN THE CANINE LARYNX

SINA NASRI, MD

JOEL A. SERCARZ, MD GERALD S. BERKE, MD

LOS ANGELES, CALIFORNIA

Laryngologists have long recognized that assessment of the mucosal wave is an important part of laryngeal evaluation. This is the first report of a noninvasive measurement of vocal fold displacement velocity in an in vivo canine model. A newly developed calibrating endoscopic instrument capable of measuring distances on the vocal fold surface is described. Displacement velocity was determined in three dogs and compared to physiologic measures in the in vivo phonation model. The results indicate that the calculated displacement velocity is linearly proportional to traveling wave velocity and fundamental frequency. Because traveling wave velocity has been shown to reflect vocal fold stiffness, this method may advance the usefulness of stroboscopy for the study of mucosal wave abnormalities.

KEY WORDS — canine, glottis, larynx, stroboscopy, traveling wave, velocity.

INTRODUCTION

Recent laryngeal research has indicated the importance of mucosal traveling wave properties. Most dysphonias are accompanied by an abnormality or asymmetry of the wave that is detectable on stroboscopy. The mucosal wave is a regular alteration in the laryngeal mucosa that begins in the subglottis and moves superiorly. Not unlike a time harmonic wave, this tissue wave has both vertical and horizontal components. As the vertical component of the wave travels superiorly, the lower margins of the vocal folds separate, then slowly begin to close as the upper margins open fully. The horizontal component of the traveling wave, meanwhile, travels mediolaterally. The lower margins return to the midline to close the glottis; this closure is followed shortly thereafter by the return of the upper margins.

The velocity of the traveling wave in the superior-inferior axis has been termed the traveling wave velocity (TWV). Some authors have described this velocity in terms of the phase delay between the opening of the lower margin of the fold and that of the upper margin.[1-3] The displacement velocity (DV) is the horizontal component of the wave velocity and will be measured in this study. Because the mucosal wave can be approximated by a sine wave, there is a mathematic relation between TWV and DV.

Theoretical Formulas. The following mathematic equations are presented to clarify the relationship between TWV and DV, which is essential to the conclusions expressed herein. Given the sinusoidal nature of a traveling wave, at any given point in time, the vocal fold configuration (u) can be approximated by (Fig 1)[4]:

$$(1) \qquad u(x,t) = A\cos[k(x - ct)]$$

in which A is the maximal amplitude of vibration, k is the wave number, and c is the TWV. The wave number can be calculated with the following equation:

$$(2) \qquad k = 2\pi/\lambda$$

where λ is the wavelength. The DV = v can be derived by differentiating equation 1[4]:

$$(3) \qquad \partial u/\partial t = v = Ak\cos[k(x - ct)]$$

It is apparent from this equation that the DV(v) of the vocal fold is proportional to its TWV (c). This is relevant because in contrast to TWV, the DV can be measured noninvasively. This is because the horizontal component of the displacement at the upper edge of the vocal folds used to calculate DV can be measured without touching the vocal fold. The calibrating endoscopic instrument, described in more detail below, was used for measurement of the displacement. This device obviates the need to mark the vocal folds, a method required for measurement of TWV.

From the Division of Head and Neck Surgery, UCLA School of Medicine (all authors), and the Division of Head and Neck Surgery, Harbor-UCLA School of Medicine (Sercarz), Los Angeles, California. This research was supported by National Institutes of Health/National Institute on Deafness and Other Communication Disorders grant R01 DC 00855-01. This study was performed in accordance with the PHS Policy on Humane Care and Use of Laboratory Animals, the NIH *Guide for the Care and Use of Laboratory Animals*, and the Animal Welfare Act (7 U.S.C. et seq.); the animal use protocol was approved by the Institutional Animal Care and Use Committee (IACUC) of the University of California, Los Angeles.

Presented at the meeting of the American Laryngological Association, Palm Beach, Florida, May 7-8, 1994. Recipient of the Resident Research Award.

REPRINTS — Gerald S. Berke, MD, Division of Head and Neck Surgery, UCLA School of Medicine, Los Angeles, CA 90024-1624.

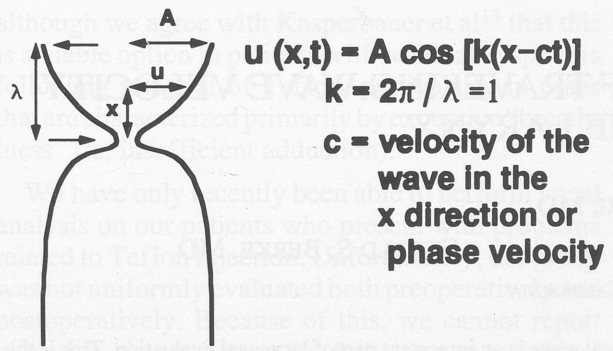

Fig 1. Coronal view of midportion of vocal folds demonstrating traveling wave and its equation.

The velocity of a wave in a viscoelastic medium is directly proportional to the stiffness of the medium and inversely proportional to the density of the medium[5]:

$$c = \sqrt{\frac{\Delta Y}{\rho}} \quad (4)$$

where c is the TWV, ΔY is the change in Young's elastic modulus, and ρ is the density of the elastic medium. Note that this equation is derived for a longitudinal elastic wave, in which the displacement from equilibrium is in the direction of propagation. A surface mucosal wave, on the other hand, is transverse; ie, its displacement from equilibrium is perpendicular to its direction of propagation. Empirically, however, there is a strong correlation between the TWV and Young's modulus, as has been described in previous studies.[5,6] ΔY can be calculated with the following equation[5,6]:

$$\Delta Y = \frac{\Delta F/A}{\frac{L - L0}{L0}} \quad (5)$$

where ΔF is the change in force required for lateral movement, A is the area over which force was applied, L is the final displacement, and L0 is the initial displacement.

Previous Studies. The relationship between the mucosal traveling wave and the underlying properties of the laryngeal muscles has been emphasized in many previous works. Hirano's[7,8] body-cover theory divides the folds into two layers with varying rheological properties. The cover, consisting of squamous epithelium and superficial and intermediate layers of lamina propria, is very pliable and can propagate a wave, but has no contractile properties. The body, consisting of the deep layer of the lamina propria and the vocalis muscle, contributes to vocal fold stiffness by active contraction. The combined stiffness of the folds is determined by extrinsic longitudinal tension on the cover and the internal stiffening of the body. Experimental evidence suggests close relationships among muscular tension, mechanical compliance, and TWV.[3,9-11]

The two-mass model of phonation of Ishizaka and Flanagan[12] correlates laryngeal vibration to mechanical compliance parameters. In this model, the vocal folds are simulated by two masses, representing the upper and lower margins of the folds, connected by springs. In order to define the motion of the masses, mechanical compliance parameters, including the elastic modulus, are determined. For this reason, a number of authors have measured the elastic modulus of the vocal folds in order to make predictions about laryngeal vibration.[5,6,13] However, the measurement of the elastic modulus in awake humans is extremely difficult, since the measurement device needs to come into contact with the vocal folds. Given this difficulty, several investigators have attempted to measure the TWV directly.

The TWV was determined by Sloan et al[10,11] in two experiments. The technique involved tattooing of the vocal folds by placing black india ink in the submucosal plane. By determining the time necessary for the wave to traverse these two tattoos and measuring the distance, the TWV was calculated. Young's elastic modulus was measured and found to be directly related to the TWV.

A significant disadvantage of this technique is the need to tattoo the vocal fold mucosa. Therefore, this method is not applicable to humans. This study describes a new technique for noninvasive measurement of the TWV. The distance traveled by the wave is measured with a custom-made rigid laryngoscope. The laryngoscope has an integrated reticle so that actual distances on the surface of the vocal folds can be measured. These distances are used to calculate the DV of the mucosal wave.

MATERIALS AND METHODS

Experimental Preparation. The experimental group consisted of three mongrel dogs (approximately 25 kg each) that underwent evaluation for measurement of the TWV. Each animal was premedicated with acepromazine maleate intramuscularly. Intravenous pentobarbital sodium (Nembutal) was then administered to the level of corneal anesthesia. Additional pentobarbital was given as needed to maintain this level of anesthesia.

The experimental setup has been described previously.[10,11] The animal was placed supine on the operating table and intubated. A midline neck incision was made from the sternal notch to the hyoid

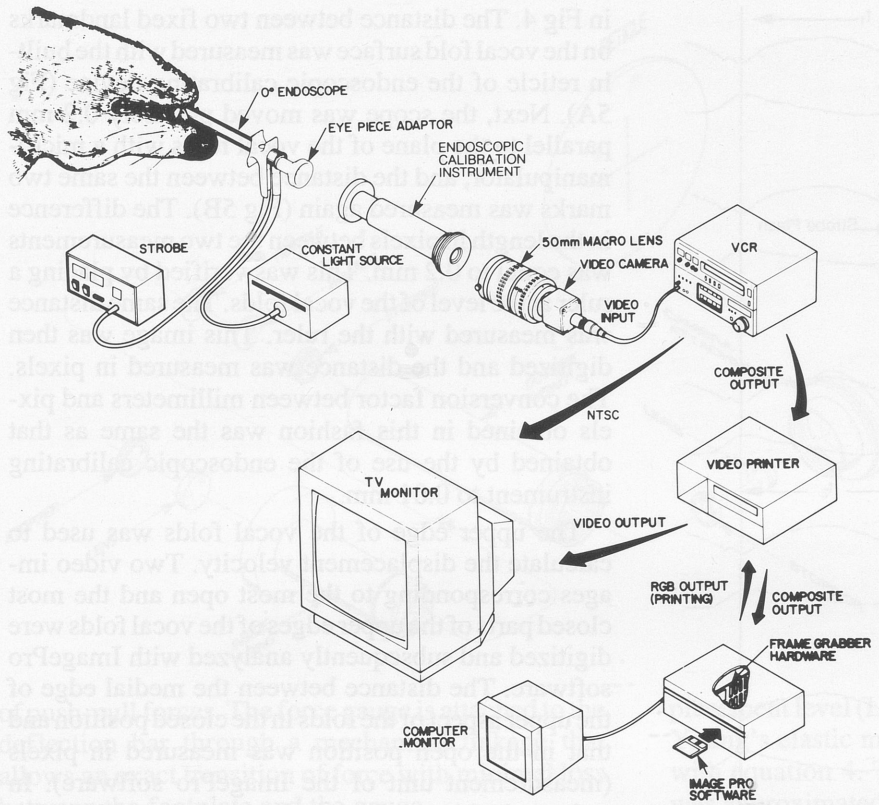

Fig 2. Videostroboscopic system used in experiment. Endoscopic calibrating instrument is placed between 0° Karl Storz laryngoscope and video camera. NTSC — National Television Standard Code, RGB — red, green, blue.

bone. Recurrent laryngeal nerves (RLNs) and superior laryngeal nerves (SLNs) were bilaterally identified and preserved. A low tracheotomy was performed at the level of the suprasternal notch, through which an endotracheal tube was passed to allow for ventilator-assisted respiration. A second tracheotomy was performed at a more superior position, through which a cuffed endotracheal tube was passed in a rostral direction and placed with the tip 10 cm below the level of the vocal folds. The cuff was inflated to just seal the trachea. Room air from a compressed air tank was passed through 37°C water for warming and humidification and flowed through this rostral tube at the rate of 318 cm^3/s. Flow was controlled with a needle valve (Whitney, Highland Heights, Ohio) and measured with a Gilmont flowmeter (model 1500, Great Neck, NY). A 1-cm button was used to suspend the epiglottis from a fixed point, providing direct visualization of the larynx through the oral cavity.

Electrical Stimulation. A 1-cm segment of each SLN (external branch) was isolated, and Harvard miniature electrodes (Harvard Apparatus Inc, Millis, Mass) were applied to each nerve. Both RLNs were isolated about 5 cm inferior to the larynx, and Harvard electrodes were applied. A constant current stimulator (model S2LH, WR Medical Electronics RLN stimulator, St Paul, Minn) was used to provide a variable amount of current (0.4 to 0.9 mA) to the RLNs at a frequency of 80 Hz. A Grass stimulator (model 54H, Quincy, Mass) provided voltage stimulation to the SLNs. The pulse duration of the stimulus was 1.5 milliseconds, with a frequency of 80 Hz. For the Grass stimulator, the voltage ranged from 0.44 to 0.80 V. No lengthening or thinning of the vocal folds was observed during maximal stimulation of the RLNs. No tensing or bulging of the vocalis muscle, or arytenoid adduction or phonation, was observed at maximal stimulation of the SLNs.

Videostroboscopy. Videostroboscopy was performed with Karl Storz laryngostrobe model 8000 (Culver City, Calif) connected with a fiberoptic cable to a 0° Karl Storz telescope. The video images were analyzed frame by frame with the use of a Sony videorecording unit (PVM 1341). The endoscopic calibrating instrument was placed between the 0° telescope and the video camera as shown in Fig 2. The function of the calibrating instrument will be described in more detail in the next section.

Synchronization and Wave Velocity Calculation. Videostroboscopic images were synchronized with subglottic pressure (SGP) and photoglottographic (PGG) tracings to measure the time interval between any two given video fields obtained with the videostroboscope. To measure the time, a 5-millisecond square wave pulse (SWP) was digitized and simultaneously recorded on the audio channel of the videotape recorder and on a C-Speech software channel. The SWP signal allowed correlation of the video

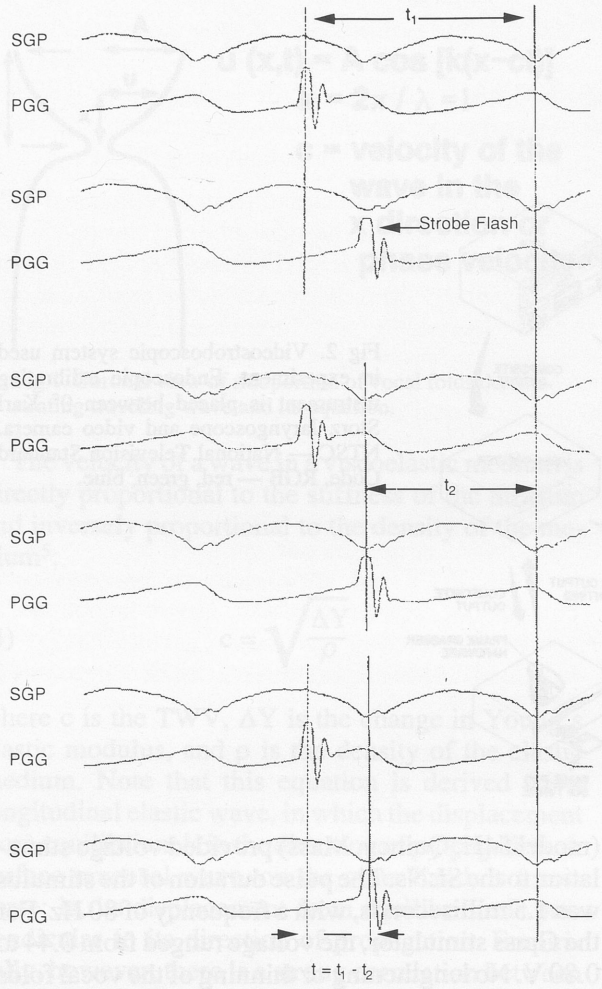

Fig 3. Time measurement was made by determining time elapsed between strobe flash (brisk upward deflection in photoglottographic [PGG] signal) and point at end of glottic cycle, indicated by vertical line to right of Figure. Time elapsed is indicated as t1 minus t2 (see text). SGP — subglottic pressure.

fields with the physiologic waveforms (PGG and SGP). The details of this method have been previously reported.[10,11,14] Briefly, the video images corresponding to the most open and the most closed parts of the upper edges of the vocal folds were determined. By correlating the strobe flash on the PGG waveform with the video image and correlating that with the SGP tracing, the time intervals between a reference video image and the most open and the most closed video images were determined. By subtracting the measured time of the most open part of the cycle (t1) from that of the most closed part of the cycle (t2), the time required for the upper edge of the folds to open completely was calculated (Fig 3).

A measuring 0° Karl Storz laryngoscope with an attached endoscopic calibrating device was used to convert the distance in pixels to millimeters. The components of the calibrating device are diagrammed in Fig 4. The distance between two fixed landmarks on the vocal fold surface was measured with the built-in reticle of the endoscopic calibrating device (Fig 5A). Next, the scope was moved precisely 0.2 mm parallel to the plane of the vocal folds with a micromanipulator, and the distance between the same two marks was measured again (Fig 5B). The difference in the length in pixels between the two measurements was equal to 0.2 mm. This was verified by placing a ruler at the level of the vocal folds. The same distance was measured with the ruler. This image was then digitized and the distance was measured in pixels. The conversion factor between millimeters and pixels obtained in this fashion was the same as that obtained by the use of the endoscopic calibrating instrument to 0.01 mm.

The upper edge of the vocal folds was used to calculate the displacement velocity. Two video images corresponding to the most open and the most closed parts of the upper edges of the vocal folds were digitized and subsequently analyzed with ImagePro software. The distance between the medial edge of the upper aspect of the folds in the closed position and that in the open position was measured in pixels (measurement unit of the ImagePro software). In order to do this, the distance between the medial edge of the upper aspect of the vocal fold in the most open position (at midfold level) and a line drawn from the point of attachment of the folds anteriorly to the point of contact of the folds posteriorly was measured. This assumes a displacement of zero for the medial edge of the fold in the most closed position. The distance in pixels was then converted to millimeters with the use of the conversion factor described in the previous paragraph. To calculate the opening displacement velocity, this distance was divided by the time required to travel the distance (t1 minus t2).

Measurement of Elastic Modulus. Young's elastic modulus is a measure of vocal fold stiffness and is defined as stress divided by strain. As described previously, change in Young's elastic modulus (ΔY) can be calculated from equation 5. The TWV can be calculated from Young's elastic modulus with equation 4.[5,6]

A "tensionometer," used for force measurement in this study, was devised to measure the transverse Young's modulus of the vocal folds during phonation.[5,6,13] The footplate of the tensionometer (located at the end of the deflection bar) was placed in contact with the medial margin of the vocal fold at approximately the midfold level. The footplate has a surface contact area of 0.04 cm^2 (A). Force (F) was measured with a Shimpo Digital Force Gauge (DF-0.5R, Shimpo American Corp), which combines a light beam detection design with a microcomputer for measurement

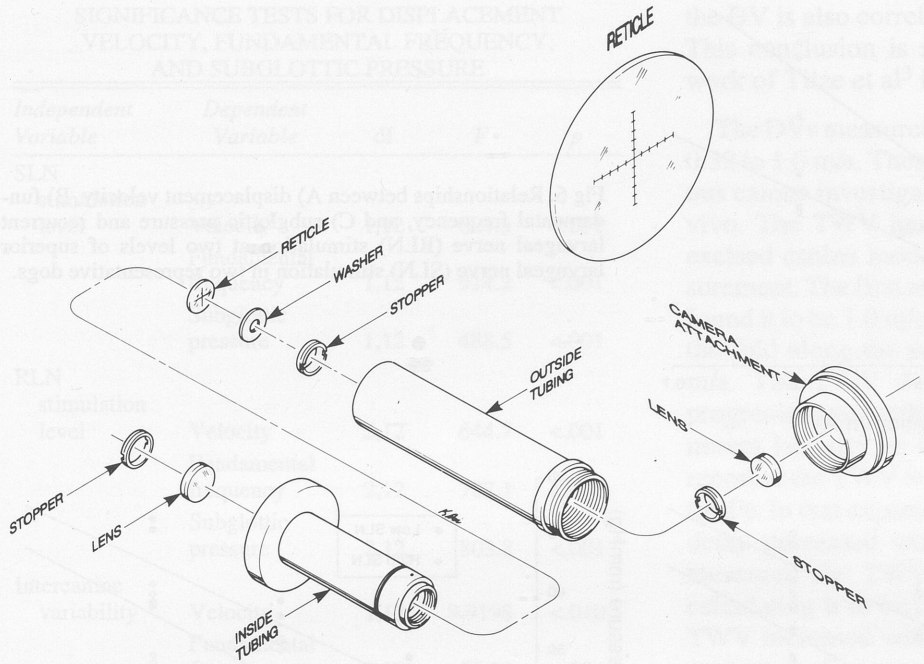

Fig 4. Components of endoscopic calibrating device.

of push-pull forces. The force gauge is attached to the deflection bar through a mechanical linkage that allows an exact transition of force with minimal loss between the footplate and the gauge.

At the beginning of each measurement, the device was initialized by using micrometer tuning to adjust the footplate so that the force exerted on the footplate was zero. This was defined as the initial displacement (L_0). Next, at any given stimulation level, the displacement was increased in 0.5-mm steps from 0 to 2.5 mm, and the force was measured for each displacement level (L). Equation 5 was used to calculate Young's elastic modulus. The TWV was calculated with equation 4. The density of the vocal folds (ρ) was approximated to be 1 g/cm^3.

Experimental Design. For each animal, three levels of RLN stimulation (low, medium, and high) were determined at which the animal could phonate at two discrete levels of SLN stimulation (low and high). Two trials at any given RLN and SLN stimulation were performed. All trials were performed in random order to avoid the effects of vocal fatigue. Four

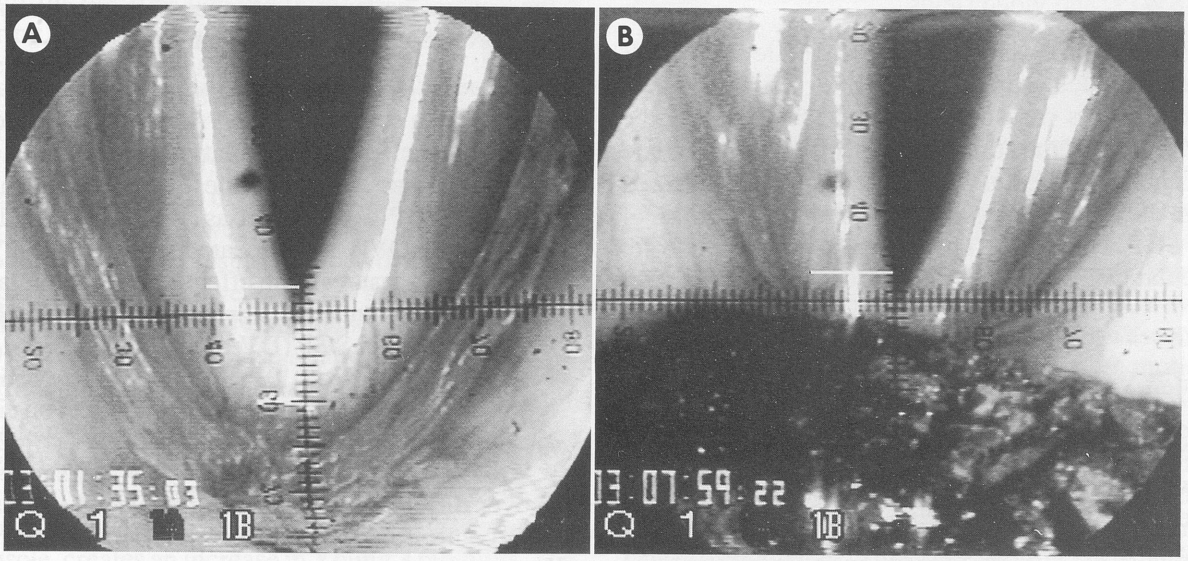

Fig 5. View of larynx through 0° Karl Storz laryngoscope with endoscopic calibrating device in place. A) ImagePro software was used to digitize and measure (white line) distance from vertical ruler to constant landmark (blood vessel, in this case) on superior aspect of vocal fold. B) Same view after laryngoscope was moved precisely 0.2 mm parallel to larynx. Landmark was measured as in A. Difference in length between two measurements is equal to 0.2 mm that laryngoscope was moved (see text).

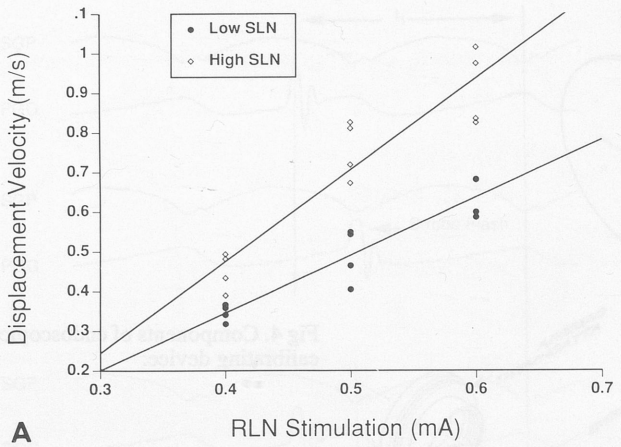

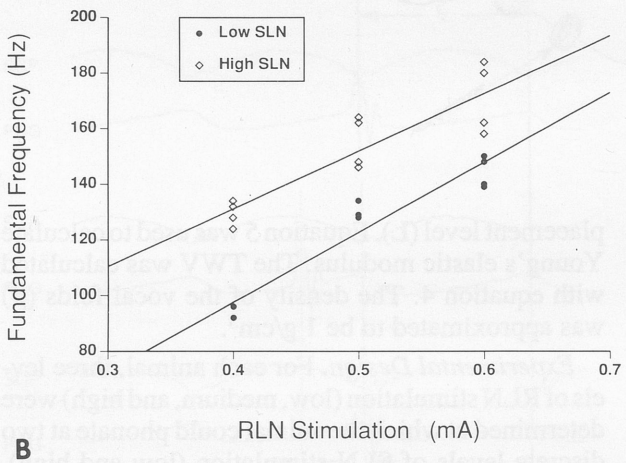

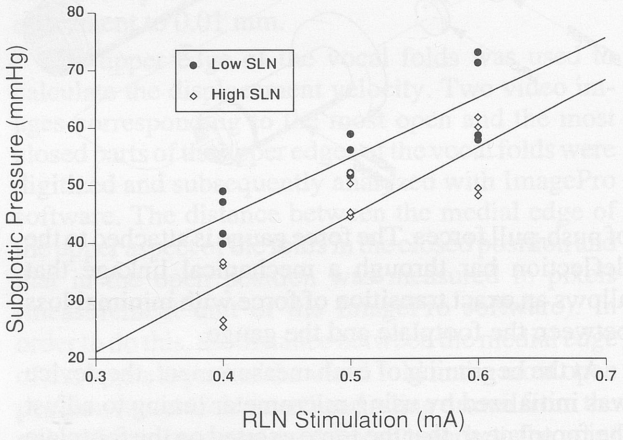

Fig 6. Relationships between A) displacement velocity, B) fundamental frequency, and C) subglottic pressure and recurrent laryngeal nerve (RLN) stimulation at two levels of superior laryngeal nerve (SLN) stimulation in two representative dogs.

channels were recorded on the speech analysis software for each trial. The waveforms recorded on the channels were SGP, PGG, an audio signal to record the SWPs, and video fields.

For each RLN and SLN stimulation level, the DV was calculated as described above. Young's elastic modulus was measured and used to calculate the TWV at the same stimulation level (equations 4 and 5). The fundamental frequency (F0) was measured from the PGG tracing and confirmed with the use of the SGP waveform. The relationships of DV with calculated TWV, SGP, and F0 were examined.

RESULTS

Figure 6 shows the relationships between DV, F0, and SGP in two representative dogs and increasing RLN stimulation at two levels of SLN stimulation (low and high). A three-way MANOVA examined the effects of RLN stimulation, and differences among dogs on DV, F0, and SGP. Significant main effects of each independent variable were observed (see Table), along with several significant interactions. Examination of means for the various cells suggested that these interaction effects represent differences in patterns of SGP variation for the two dogs. The SGP varied much more in response to changes in stimulation levels for one dog than for the other. However, the general patterns of responses were similar, so interactions were not further interpreted.

Because the dependent measures were moderately correlated, a step-down analysis was used to determine which effects of stimulation were independent and which were artifacts of these correlations. In this analysis, SGP was treated as a covariate, and the above MANOVA was repeated with F0 and DV as dependent measures. The effect of SLN stimulation on DV and F0 remained significant after controlling for differences in SGP (DV: $F_{(1,11)} = 25.07$, $p < .01$; F0: $F_{(1,11)} = 40.59$, $p < .01$). Changes in RLN stimulation had no significant independent effect on either variable after controlling for SGP (DV: $F_{(1,11)} = 2.14$, $p > .01$; F0: $F_{(1,11)} = 5.58$, $p > .01$). As suggested above, differences between dogs also disappeared after controlling for differences in SGP.

Figure 7 demonstrates the relationships between the DV and TWV, F0, and SGP. The DV ranged from 0.32 to 1.0 m/s. The TWV ranged from 0.76 to 2.2 m/s. Simple linear regression was used to examine

SIGNIFICANCE TESTS FOR DISPLACEMENT VELOCITY, FUNDAMENTAL FREQUENCY, AND SUBGLOTTIC PRESSURE

Independent Variable	*Dependent Variable*	df	*F*	*p*
SLN stimulation level	Velocity	1,12	624.5	<.001
	Fundamental frequency	1,12	914.2	<.001
	Subglottic pressure	1,12	488.5	<.001
RLN stimulation level	Velocity	2,12	644.7	<.001
	Fundamental frequency	2,12	782.1	<.001
	Subglottic pressure	2,12	803.8	<.001
Intercanine variability	Velocity	1,12	9.9198	<.010
	Fundamental frequency	1,12	55.19	<.001
	Subglottic pressure	1,12	412.1	<.001

SLN — superior laryngeal nerve, RLN — recurrent laryngeal nerve.

these relationships. The DV varied significantly with TWV ($F_{(1,34)} = 4{,}174.54$, $p < .01$; $r^2 = .99$) and with F0 ($F_{(1,34)} = 83.10$, $p < .01$; $r^2 = .71$). No significant relationship between DV and SGP was observed ($F_{(1,34)} = 5.02$, $p > .01$; $r^2 = .13$).

DISCUSSION

The opening DV refers to the velocity of a single point on the free mucosal edge of the vocal fold during laryngeal opening in a horizontal plane. The present experiment measured the opening DV of the vocal folds and correlated it to the TWV. Because a noninvasive method was sought, the TWV was calculated from Young's modulus rather than measured directly, on the basis of previous studies establishing the relationship between the TWV and the elastic modulus.[10,11] The results indicated that there is a linear correlation between the DV and the TWV. It is of interest that this correlation was very strong ($r^2 = .99$). This indicates a close relationship between the stiffness of the vocal folds and the measured DV.

At any given SLN stimulation level, with increasing RLN stimulation, the DV increases. With increasing RLN stimulation, the contraction of the intrinsic muscles, particularly the thyroarytenoid muscle, creates an increase in Young's modulus. The calculated TWV and the DV are increased — a finding that is consistent with studies that measured the TWV directly.[10,13] Because the F0 also rises with increasing RLN stimulation, the results indicate that the DV is also correlated directly with this measure. This conclusion is supported by the experimental work of Titze et al[3] in excised larynges.

The DVs measured in this experiment ranged from 0.32 to 1.0 m/s. These data are consistent with previous canine investigations in excised larynges and in vivo. The TWV has been measured most often in excised canine models because of the ease of measurement. The first measurement of TWV, by Baer,[15] found it to be 1.0 m/s. Hirano[8] measured the TWV of the fold along the superior surface to be 0.1 to 0.5 m/s. The TWV decreases as the mucosal wave progresses toward the superior surface of the fold and moves laterally on the upper surface.[15] Titze et al[3] reported the TWV to be 0.5 to 2.0 m/s, depending on the F0. In that experiment, TWV increased and phase delay decreased with increasing F0. Sloan et al[10] measured the TWV in an in vivo canine model, calculating it to be 0.9 to 1.6 m/s. In that study, the TWV increased with greater RLN stimulation. The present study suggests that the DV is also proportional to muscular stiffness of the larynx, represented by Young's elastic modulus.

Studies of the TWV in laryngeal models have determined that the velocity is related to qualities of the thyroarytenoid muscle, as well as other intrinsic laryngeal muscles — particularly the degree of contraction or tension.[10] Titze[16] described a relationship between wave properties and aerodynamics. He suggested that the mucosal wave velocity is related to the phonation threshold pressure, the minimal pressure required to establish phonation. In the future, adjusting the phonation threshold pressure may be a criterion for success in laryngeal framework surgery.

Characteristics of the mucosal wave have proven to be clinically valuable in the evaluation of voice disorders. For example, mucosal scarring or mass lesions may affect the amplitude and propagation of the mucosal wave.[17] In vocal fold paralysis, the observed and measured TWV is slower on the side of the paralysis.[9,10] The relationship between mucosal wave qualities and the associated voice, however, is multifaceted. For example, inflammation associated with edema of the vocal fold restricts the motion of the traveling wave, resulting in a decreased ability of the vocal folds to modulate airflow. Mass lesions or scars may affect the mucosal traveling wave in several ways. They may result in irregular vibrations of the folds secondary to differences between the masses of the two folds. They can cause a distribution of energy at inharmonic frequencies, manifested as noise in the sound spectrum. Masses may also prevent the folds from touching, resulting in escape of unmodulated airflow through the glottis. Some mass lesions,

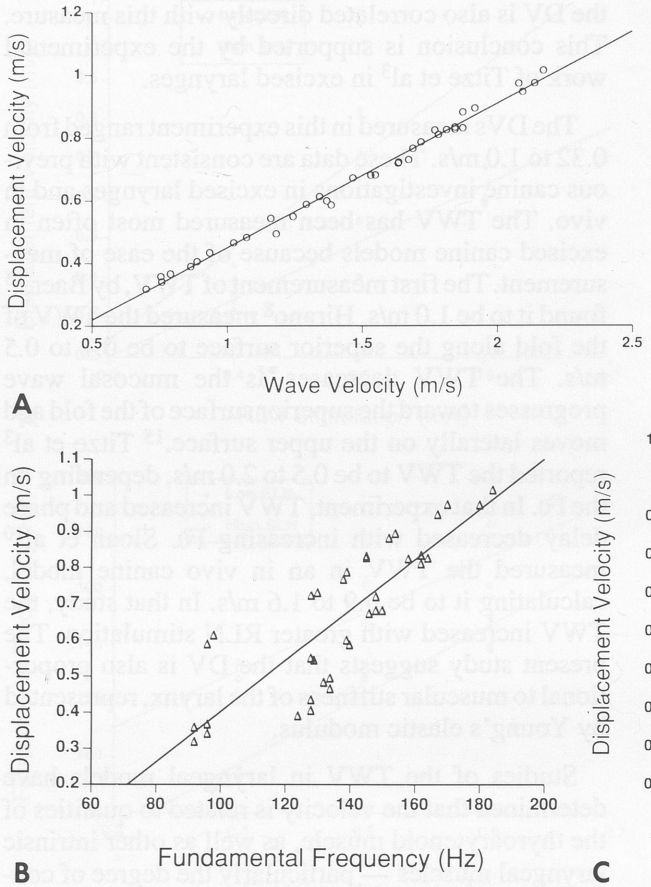

Fig 7. Relationships between displacement velocity and A) traveling wave velocity, B) fundamental frequency, and C) subglottic pressure in three dogs.

such as microinvasive carcinoma, may infiltrate the epithelium and the lamina propria, resulting in a loss of the traveling wave due to a restriction of mucosal motion.[18]

Data from dogs and humans indicate that asymmetric stiffness disorders such as SLN or RLN paralysis cause a decrease in the amplitude and velocity of the traveling wave on the side of the paralysis.[9,10,19] The vocal folds may close more slowly and less forcefully, causing less energy to be distributed to the higher harmonics. This results in a soft and breathy voice. A larger glottal gap may create an even greater air leak, resulting in a loss of the mucosal wave and a perception of breathiness associated with hoarseness, ie, the "white noise" associated with unmodulated airflow.

Medialization of a paralyzed vocal fold aims to increase contact area and improve entrainment (the simultaneous opening and closing of the vocal folds), thereby resulting in greater symmetry of vibration. In addition, the improved contact allows the larynx to produce greater SGP and speech intensity, avoiding the air escape and breathiness accompanying a glottal gap. In the future, one goal of phonosurgery may be to equalize the TWVs of the right and left hemilarynges by producing a surgical alteration in the stiffness properties of the larynx. One method of achieving this goal would be thyroplasty. This could alter Young's modulus of the vocal fold tissue and produce a more symmetric mucosal traveling wave.

Another possible application of this work is the intraoperative stroboscopic monitoring of phonosurgical procedures. A human laryngoscope could be fashioned by attachment of an endoscopic calibrating instrument to a rigid laryngoscope. The DVs can then be measured from the normal and paralyzed sides and compared. The phonosurgical operation will then be designed to bring the DV of the paralyzed fold as close to that of the normal fold as possible. We believe a device similar to the one used in this experiment could be employed in an awake patient in order to calculate the mucosal TWV for diagnostic and therapeutic purposes, since the measurement procedure is noninvasive. Currently, a modified 90° Berci-Ward laryngoscope is being tested in humans for this purpose.

In conclusion, this is the first report of a noninvasive measurement of vocal fold DV. The device designed in this experiment is capable of calculating DV. It was demonstrated that DV is proportional to

the stiffness of the vocal folds. The present study indicates that invasive techniques such as tattooing of the vocal fold are unnecessary for TWV calculations — a promising finding, because it makes TWV measurements applicable to human laryngeal research.

ACKNOWLEDGMENTS — The authors thank Jody Kreiman, PhD, for the statistical analysis and Katsuichi Doi for the illustrations.

REFERENCES

1. Ishizaka K, Matsudaira M. Fluid mechanical consideration of vocal fold vibration. Monograph 8. Santa Barbara, Calif: Speech Communication Research Laboratory, 1972.

2. Titze I. The physics of small-amplitude oscillation of the vocal folds. J Acoust Soc Am 1988;83:1536-52.

3. Titze IR, Jiang JJ, Hsiao T-Y. Measurement of mucosal wave propagation and vertical phase difference in vocal fold vibration. Ann Otol Rhinol Laryngol 1993;102:58-63.

4. Achenbach JD. Wave propagation in elastic solids. Evanston, Ill: Elsevier Scientific Publishers, 1984:30-3.

5. Berke GS. Intraoperative measurement of the elastic modulus of the vocal fold. Part 1. Device development. Laryngoscope 1992;102:760-9.

6. Berke GS, Smith ME. Intraoperative measurement of the elastic modulus of the vocal fold. Part 2. Preliminary results. Laryngoscope 1992;102:770-8.

7. Hirano M. Phonosurgery: basic and clinical investigations. Otologia (Fukuoka) 1975;21:239-440.

8. Hirano M. Morphological structure of the vocal cord as a vibrator and its variations. Folia Phoniatr (Basel) 1976;26:89-94.

9. Sercarz JA, Berke GS, Ming Y, Gerratt BR, Natividad M. Videostroboscopy of human vocal fold paralysis. Ann Otol Rhinol Laryngol 1992;101:567-77.

10. Sloan SH, Berke GS, Gerratt BR. Effect of asymmetric vocal fold stiffness on traveling wave velocity in the canine larynx. Otolaryngol Head Neck Surg 1992;107:516-26.

11. Sloan SH, Berke GS, Gerratt BR, Kreiman J, Ye M. Determination of vocal fold mucosal wave velocity in an in vivo canine model. Laryngoscope 1993;103:947-53.

12. Ishizaka K, Flanagan JL. Synthesis of voiced sounds from a two mass model of the vocal cords. Bell System Tech J 1972; 51:1233-68.

13. Tran QT, Berke GS, Gerratt BR, Kreiman J. Measurement of Young's modulus in the in vivo human vocal folds. Ann Otol Rhinol Laryngol 1993;102:584-91.

14. Sercarz JA, Berke GS, Gerratt BR, Kreiman J, Ming Y, Natividad M. Synchronizing videostroboscopic images of human laryngeal vibration with physiological signals. Am J Otolaryngol 1992;13:40-4.

15. Baer T. Investigation of phonation using excised larynges [Dissertation]. Cambridge, Mass: Massachusetts Institute of Technology, 1975.

16. Titze I. Phonation threshold pressure: a missing link in glottal aerodynamics. J Acoust Soc Am 1991;91:2926-35.

17. Bless DM, Hirano M, Feder RJ. Videostroboscopic evaluation of the larynx. Ear Nose Throat J 1987;66:48-58.

18. Sessions RB, Miller SD, Martin GF, Solomon BI, Harrison LB, Stackpole S. Videolaryngostroboscopic analysis of minimal glottic cancer. Trans Am Laryngol Assoc 1989;110:56-9.

19. Isshiki N, Tanabe M, Ishizaka K, Broad D. Clinical significance of asymmetrical vocal cord tension. Ann Otol Rhinol Laryngol 1977;86:58-66.

ELECTRONIC SPECKLE PATTERN INTERFEROMETRY OF THE VIBRATING LARYNX

GLENDON M. GARDNER, MD
DETROIT, MICHIGAN
MICHELLE CONERTY, MS
TROY, NEW YORK
JAMES CASTRACANE, PHD
TROY, NEW YORK
STEVEN M. PARNES, MD
ALBANY, NEW YORK

Laser holography is a technique that creates a three-dimensional image of a static object. This technique can be applied to the analysis of vibrating structures. Electronic speckle pattern interferometry uses a laser for illumination of the vibrating object and solid state detectors and digital hardware technology for capturing and processing the image in real time. This was performed on a human cadaver larynx and is the first time an interferogram of vibrating vocal cords has ever been obtained. Dark and bright interference fringes are seen that represent the vibratory motion of the vocal folds. These are presented in still photos as well as real-time on videotape. This method can provide advantages over current techniques of laryngeal study: it is sensitive to motion in the vertical dimension, and the digital data can be quantitatively analyzed. Application of this technique to study the larynx should eventually be a valuable clinical tool and provide quantitative research data.

KEY WORDS — interferometry, larynx, vocal folds.

INTRODUCTION

Several methods exist for studying vocal fold vibratory activity. Videostroboscopy (VS) is the most practical technique for use in a clinical setting. It provides an excellent image of the vibrating vocal folds and the mucosal wave, but this image is entirely qualitative. Additionally, the image obtained is essentially two-dimensional, and while it provides information about the movement of the vocal folds in a lateral direction, characteristics of the vertical movement of the folds and the mucosal wave can only be inferred from the video image.

Electroglottography and photoglottography, which are techniques used mostly in a research setting, provide somewhat more quantifiable data than does VS. These methods are indirect measures of vocal fold activity, however, and do not localize disease well.[1,2] High-speed cinematography, like VS, is not quantifiable and is not sensitive to motion in the vertical dimension.[3,4] X-ray stroboscopic study of animal larynges with lead pellets embedded in the vocal folds has yielded the best information regarding vertical movement of the vocal folds, but is, of course, a technique confined to animal models for in vivo studies.[5-7]

Laser holography is a technique that creates a three-dimensional image of a static object. Holography of a static canine larynx was reported by Raviv et al[8] in 1982, and of an excised human larynx by Gardner et al[9] in 1992. This technique can be applied to vibrating structures to measure displacement of the object. Time-averaged image interferometry creates a two-dimensional image that reveals the vibratory pattern of the object in dark and bright interference fringes superimposed on an image of the object. These fringe lines represent the third dimension of movement on this two-dimensional image, much as the elevation lines give a third dimension to a topographical map. Electronic speckle pattern interferometry (ESPI) involves capturing the image with a charge-coupled device (CCD) video camera so the interferometric pattern can be viewed real-time on a video monitor. This video signal can be digitally recorded for later computer analysis. The number of interference fringes seen, and the knowledge of the wavelength of the laser and viewing geometry, can be used to quantify the motion of the object.[10-12]

Application of ESPI to the vibrating larynx may yield quantification of the motion of the vocal folds in the vertical plane with good spatial and temporal resolution. The purpose of this study was to apply ESPI to a vibrating excised human larynx. We present some representative images obtained with this tech-

From the Vanderbilt Voice Center, Vanderbilt University, Nashville, Tennessee (Gardner), and InterScience, Inc, Troy (Castracane, Conerty), and the Division of Otolaryngology, Albany Medical College, Albany (Parnes), New York. Supported by National Institutes of Health Small Business Innovative Research Grant 1R43DC01165-01A1 and funds from InterScience, Inc, Troy, New York.

Presented at the meeting of the American Laryngological Association, Palm Beach, Florida, May 7-8, 1994.

REPRINTS — Glendon M. Gardner, MD, Dept of Otolaryngology–Head and Neck Surgery, Henry Ford Hospital, 2799 W Grand Blvd, Detroit, MI 48202-2689.

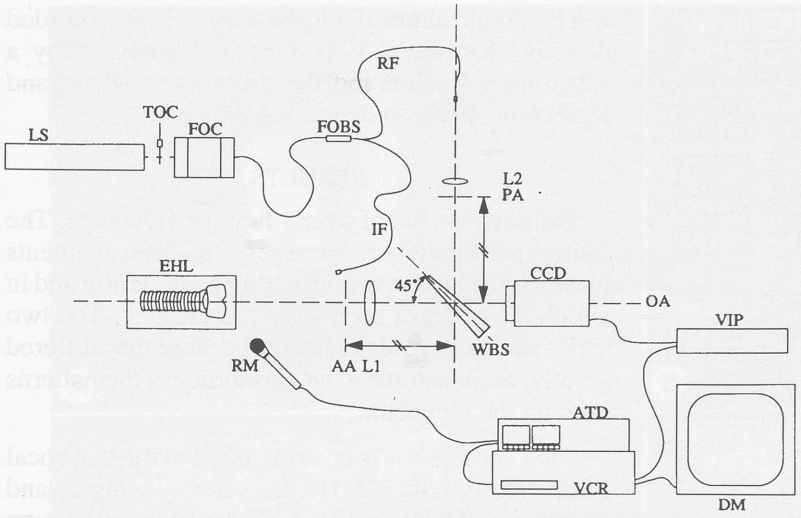

Fig 1. Schematic diagram of optical table layout. LS — laser source, TOC — tunable optical chopper, FOC — fiberoptic coupler, FOBS — fiberoptic beam splitter, RF — reference fiber, IF — illumination fiber, EHL — excised human larynx, AA — adjustable aperture, L1 — lens 1, L2 — lens 2, PA — pinhole aperture, WBS — wedged beam splitter, CCD — charge-coupled device camera, OA — optical axis, VIP — video image processor, ATD — audio tape deck, VCR — video cassette recorder, RM — recording microphone, DM — display monitor.

nique and discuss several possible interpretations of the data. The ultimate goal of this research is the clinical application of ESPI to the examination of vocal fold vibration.[9]

MATERIALS AND METHODS

Laryngeal Preparation. A grossly normal larynx was harvested from an adult male human at the time of autopsy prior to fixation and stored in normal saline. The trachea was transected immediately superior to the carina. The epiglottis was removed, with the petiole left intact. The false vocal folds and the petiole were sutured to the thyroid cartilage to improve exposure of the true vocal folds. A 3-0 nylon suture was passed through the thyrohyoid membrane and around the muscular process of the arytenoid cartilage, and tension was placed in the anterior direction to reproduce the action of the lateral cricoarytenoid muscle bilaterally. Interarytenoid muscle action was reproduced by suturing the arytenoid cartilages together. The vocal processes were also sutured together. Approximation of the membranous true vocal folds was achieved by performing bilateral medializations (Isshiki thyroplasty type I) with Silastic silicone rubber (Dow Corning) as described by Netterville et al.[13] The technique was modified by maintaining intact Silastic silicone rubber blocks that protruded out of the thyroid cartilage windows to allow adjustment of medialization by external pressure. A 2-0 silk suture was passed through a hole in the thyroid cartilage below the anterior commissure, around the anterior cricoid cartilage, to allow tensing of the vocal folds. Airflow was supplied via an endotracheal tube placed into the trachea from below. Dry air was used to prevent spraying the equipment with moisture, and the larynx was moistened intermittently with saline.

Electronic Speckle Pattern Interferometry. Laser holography and interferometry involve the interference of coherent plane wave fronts. A coherent light source (laser) is separated into two beams: the illumination, or object, beam and the reference beam. The object beam is incident upon the object of interest. The light reflected from this object is coaxially combined with the reference beam at the recording medium to create and record the interference pattern.[10]

A 10-mW helium-neon laser (λ = 633 nm) was launched through a tunable optical chopper (Scitec Instruments model 300CD, St Ives, England) into a single mode fiber (9-μm core) by a high-precision fiberoptic coupler with 60% coupling efficiency (Fig 1). The single mode fiber is then split into an object beam, which is incident on the larynx, and a reference beam, with 85% and 15% of the total power, respectively.

The reference beam and object beam (laryngeal image) are combined on the CCD detector face (Panasonic WV-CD24, 492 × 510 pixels, 6.6 × 8.8 mm) by a wedged beam splitter placed directly in front of the CCD camera at an angle of 45°. The beam splitter has a 1° wedge in order to minimize back reflections in the system. The ESPI system utilizes a real-time video image processor (VIP) developed in-house at InterScience, Inc. The VIP takes input directly from the CCD camera and subtracts successive frames (mode 1) or subtracts successive incoming frames from a stored reference frame (mode 2) and outputs the results in real time in the form of a video signal (Fig 2). The video output is recorded directly on a Super VHS (S-VHS) video cassette recorder and displayed live on the display monitor for immediate interpretation. The VIP incorporates state of the art microprocessor and field programmable gate array technology.

While the larynx was phonating, the optical chop-

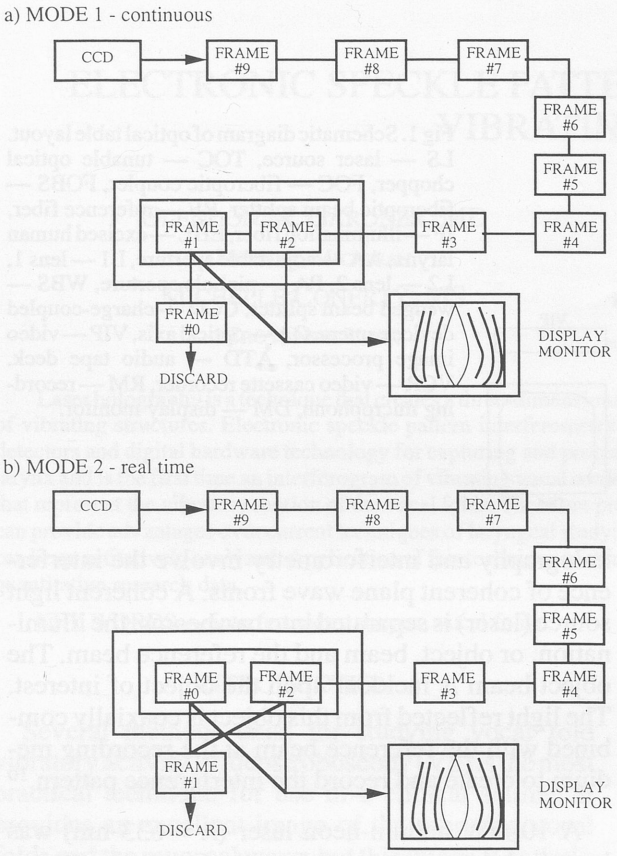

Fig 2. Schematic diagram of frame subtraction process that takes place in video image processor. See text for explanation.

per was tuned at the fundamental frequency (F0) to "freeze" the motion of the vibrating vocal folds. As the F0 changed slightly, the optical chopper was retuned to stay as close to frozen motion as possible. This was judged by directly observing the vocal folds, which appeared as they do in a typical stroboscopy image. Usable data were obtained only when the vocal folds were vibrating in a periodic manner.

Calibration of the video image was achieved by placing a ruler at the level of the vocal folds.

Computer Analysis. Images from the S-VHS tape were acquired with PrismView software (Dapple) on a Mac 68030 computer (Apple). The Adobe Photoshop software package was used to enhance the images by increasing contrast. Although this improves visualization of the fringes, this process makes the already grainy ESPI images even more grainy. The images were photographed with a Montage FR-1 unit (Presentation Technologies) to produce the photographs seen in Figs 3 and 4. Each image could then be analyzed for the number of fringes on each vocal fold. Each fringe represents movement of one half the wavelength of the laser, or 0.3 μm (λ = 0.633 μm), from the preceding frame.

The sound created by the larynx was recorded directly onto the S-VHS tape and analyzed by a substitution method and the stroboscope (Bruel and Kjaer type 4914) to determine the F0.

RESULTS

The data consist of over 1 hour of videotape. The frames presented here were selected from segments in which the larynx was vibrating consistently and in which the patterns seen were the clearest. The two series shown were also selected because they differed greatly, demonstrating the variability in the patterns seen on the videotape.

Four successive frames of ESPI with the vocal folds vibrating at 155 Hz are shown in Fig 3, and frames at 187 Hz in Fig 4. The continuous frame subtraction mode was used. The interference fringes are visible as bright and dark bands. The view is oriented anteriorly pointed upward, and the left vocal fold is seen on the left. A 19.4-mm section of the membranous vocal fold is seen in the anterior-posterior dimension in Fig 3. In this Figure, the most anterior aspect of the image is approximately 1 mm posterior to the anterior commissure, and the most posterior is approximately 1 mm anterior to the vocal processes of the arytenoid cartilages. In Fig 4, the magnification is almost 2× that in Fig 3. The location of the anterior aspect of the image is the same (1 mm posterior to the anterior commissure). Only the fringes on the membranous vocal folds are visible. The remainder of the larynx, being immobile, appears the same in each frame, and therefore is completely subtracted from the video image.

The right sides of Figs 3 and 4 are the same frames as on the left, with the bright interference fringes outlined in thin black lines and labeled "interference fringes." The dark interference fringes are between the bright fringes. The glottic aperture (which appeared closed during all of these frames) is indicated by a slightly thicker black line labeled "glottis."

In Fig 3A, the glottic opening is in the middle of the vertical white band, meaning that there is one fringe on either side of the glottic opening, parallel to the edge of the vocal fold, and one oval fringe on the left vocal fold. (Although the location of the glottic opening is not discernible in these photos, it is obvious when viewing the videotape. In the frames shown in Figs 3 and 4, the glottis was never actually open.) Figure 3C demonstrates one bright fringe lateral and parallel to the right vocal fold edge, and one large, oval bright fringe on the left fold. In both Figs 3C and Fig 3E, there are several smaller fringes, adjacent to the larger bright fringe on the left vocal fold, that are not oriented parallel to the edge of the fold. Figure 3G

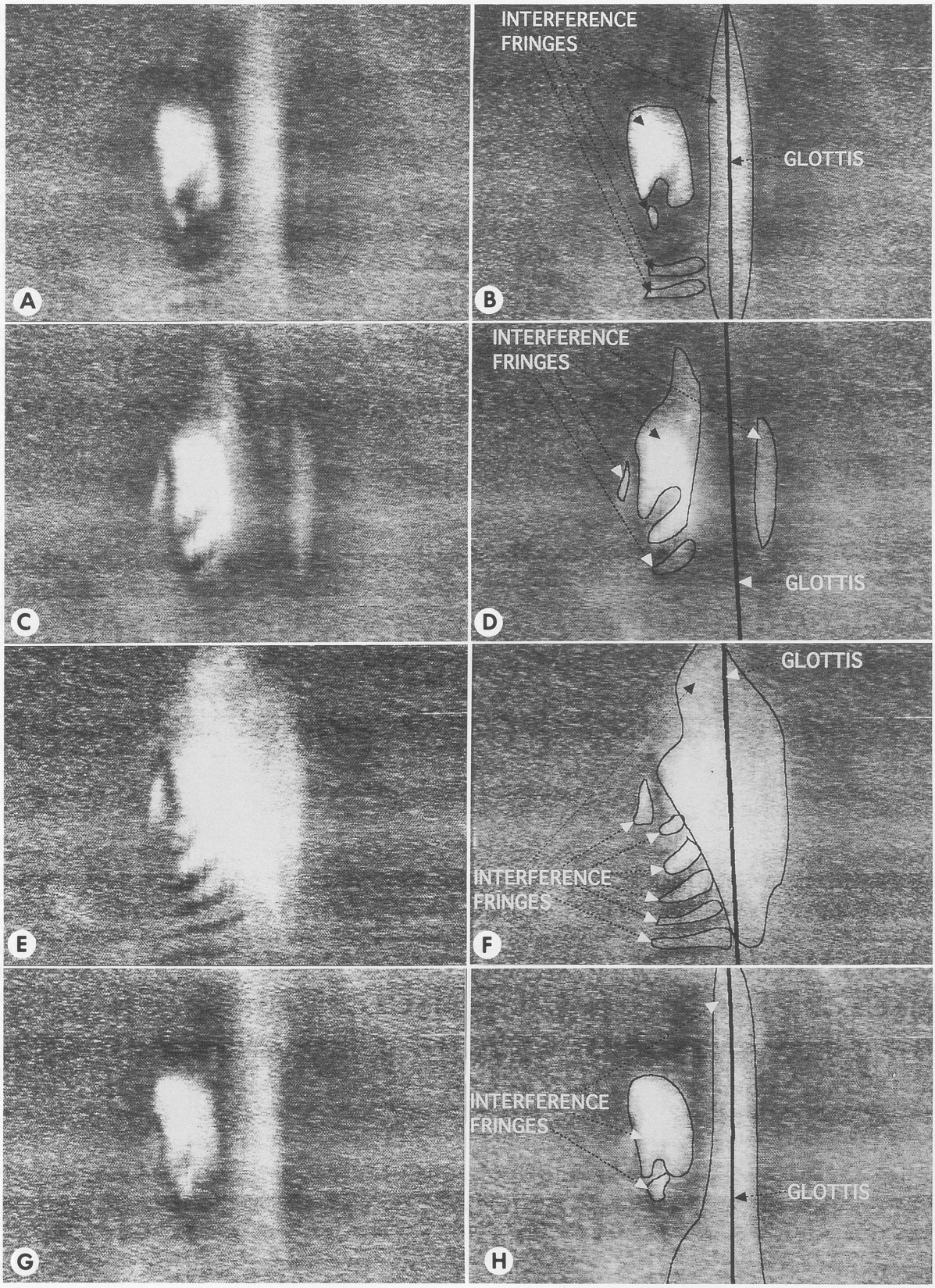

Fig 3. Four successive frames of videotape showing interferograms of vocal folds vibrating at 155 Hz. Anterior is upward and left vocal fold is on left. Top to bottom of each image is 19.4 mm. In images to right (B, D, F, H), bright interference fringes have been outlined in thin black lines and labeled "interference fringes," and location of glottic aperture is indicated by thick black line labeled "glottis." See text for explanation.

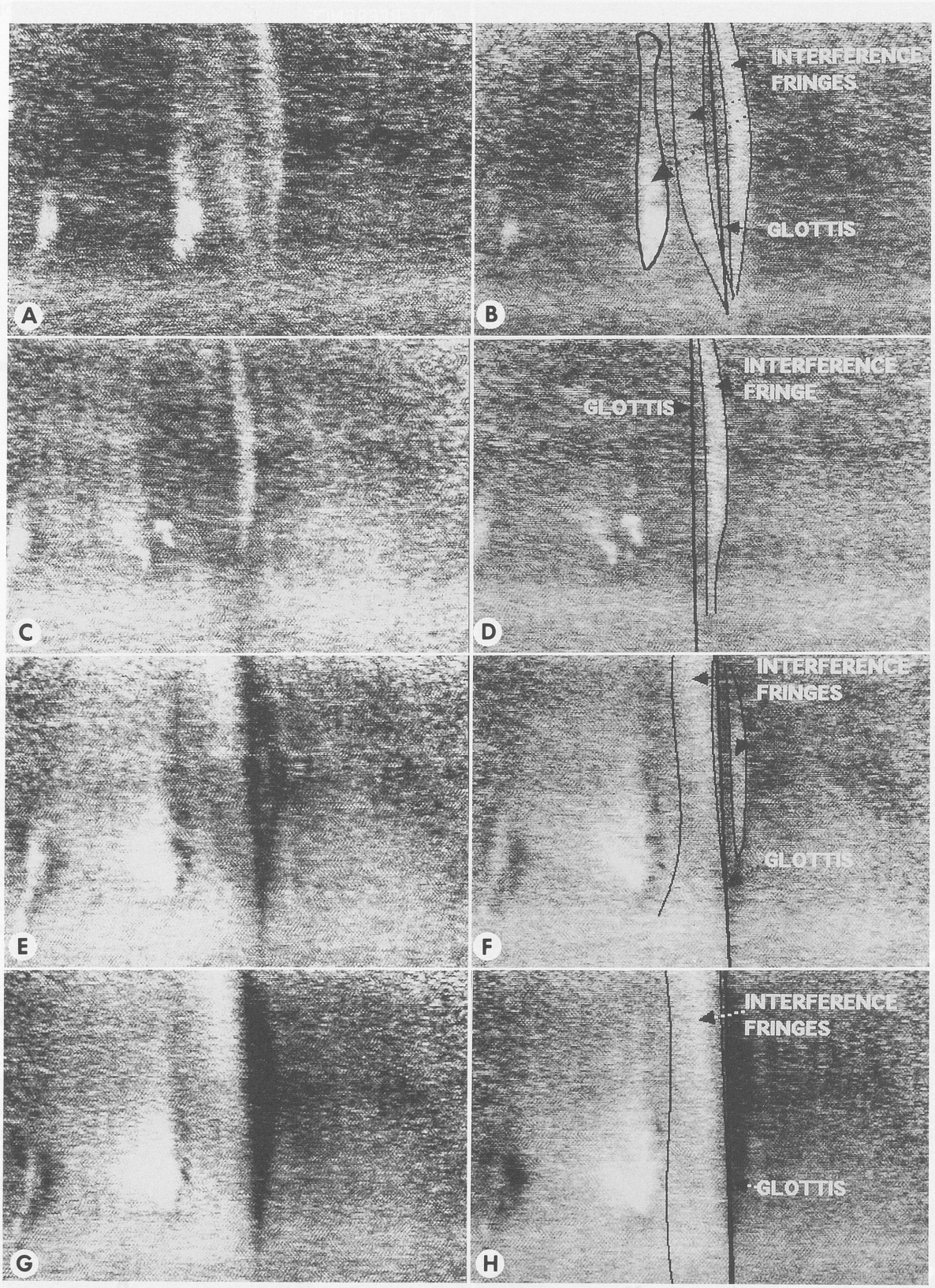

Fig 4. Four successive frames of videotape showing interferograms of vocal folds vibrating at 187 Hz. Anterior is upward and left vocal fold is on left. Top to bottom of each image is 10.1 mm. In images to right (B, D, F, H), bright interference fringes have been outlined in thin black lines and labeled "interference fringes," and location of glottic aperture is indicated by thick black line labeled "glottis." See text for explanation.

is similar to Fig 3A.

The fringes seen in Fig 4 are all parallel to the glottal opening. In Fig 4A, two bright fringes are seen to the left of the glottal aperture, and one to the right. Figure 4C demonstrates one bright fringe and one possible, faint bright fringe on the right vocal fold. In Fig 4E, a bright fringe is seen emerging between two dark fringes on the right vocal fold, and a broad bright fringe is seen on the left vocal fold. Figure 4G is similar to 4E, with absence of the subtle bright fringe on the right vocal fold.

The fringes parallel to the vocal fold edges are consistent with our concept of the mucosal wave, while the smaller fringes seen in Fig 3C,E may represent harmonic oscillations of the vocal fold mucosa.

If we take Fig 4A as an example, three fringes (two bright and one dark) are seen on the left vocal fold; this finding means that the mucosa of that fold has moved $3 \times {}^1/_2\lambda = 3 \times {}^1/_2\, 0.6\ \mu m = 0.9\ \mu m$ since the last frame was obtained. Where one bright fringe is seen on the right fold, the mucosa has moved 0.3 μm. The nonlinear geometry of the fringes in Fig 3 makes it difficult to clearly understand what motion is represented in those frames.

DISCUSSION

The movement of the vocal folds in the horizontal plane has been observed and/or recorded directly in various ways. These include high-speed cinematography,[4] high-speed digital image recording,[14,15] and VS.[16] Each of these techniques provides a high-quality image of the vocal folds in various stages of the glottal cycle. From these images, relative measurements can be made of the glottic area, vocal fold lesions, and the effect of lesions on glottic closure. When high-speed cinematography was first used for study of vocal fold vibration, these measurements were made essentially by hand — a very tedious and time-consuming task.[16] Later, these motion-picture images could be digitized and analyzed with the aid of a computer.[17,18] Videostroboscopic images can also be digitally analyzed by computer,[19] and now, video laryngeal images can be recorded directly into the computer.[14,15,20,21] Unfortunately, all of the above techniques can provide only relative measures of glottic structures in vivo, because they all lack the ability to calibrate the size of the video image at the level of the glottis, although Sercarz et al[16] placed a calibration ruler at the level of the glottis in canine experiments, enabling them to make quantitative measurements. The above techniques also all lack the ability to make any measurement whatsoever of vocal fold motion in the vertical plane.

The best information on the vertical motion of the vocal fold has been obtained by implanting radiopaque pellets in the vocal folds of live canine or excised human larynges and filming their motion with an x-ray stroboscope and an ultrahigh-speed camera in the frontal plane.[5-7] Fukuda et al[7] measured up to 6.1 mm of lateral movement of a pellet at the middle of the membranous vocal fold, and approximately 8 mm in the vertical axis. Cooper[22] stated that the vertical motion of the vocal fold is only 15% less than that in the horizontal plane.

The goal of our research is to develop a technique for studying vocal fold vibration that improves on the status quo by providing quantifiable data and the ability to measure movement in the vertical dimension (toward and away from the observer). Interferometry is attractive because it is sensitive to motion toward and away from the viewer, which in the live human almost always means from above the larynx. It also provides the possibility of quantification of this motion. This study represents the first interferogram obtained of the vibrating vocal fold — a significant step toward achieving our goal.

The images presented in Figs 3 and 4 are the result of a complex and not easily understood imaging and processing system. First, the vibrating larynx is illuminated with a laser that is being strobed at the F0 of the larynx. One fringe is produced for movement of only half the wavelength of the laser or 0.3 μm. Without slowing the apparent motion of the folds, the movement from frame to frame would be so great (several millimeters) that the many fringes created would blur together and none could be discerned. Even though the image is "frozen" to the eye, some change in the position of the vocal fold does occur, and this is enough for this technique to detect the motion.

Next, the two laser beams combine at the CCD camera to create the interferogram on the detector surface of the camera. The frame rate of the camera is 30 frames per second, which is considerably slower than the frequency of vibration of the vocal folds. This is another reason why it is necessary to slow the apparent motion of the vocal folds with the strobe effect of the chopped laser beam. Each frame, then, is a summation of approximately 6 cycles of the larynx (assuming F0 = 180 and the chopper at F0).

The video signal is sent to the VIP, where it can be processed in one of two ways. A frame can be saved as the reference image and each subsequent frame can be subtracted from that frame (mode 2, Fig 2). The resultant video image then represents the change in position of the object compared to the baseline frame. In other systems, such as metals or plastics in

industrial applications,[10] or the tympanic membrane,[23-27] this technique is used with the reference frame obtained at rest and subsequent frames obtained when the system is stressed or vibrating. In our experiment this was not practical, because when airflow was begun, the entire larynx moved and therefore the change in position between the original frame and subsequent frames represented this gross motion and not subtle movement of the vocal folds.

The second frame subtraction mode involves continually subtracting the next frame from the previous frame, repeatedly updating the image (mode 1, Fig 2). This was more practical in this case and yielded the clearer images.

The video image is the difference between two successive frames. The resultant fringes represent small changes in these frames that depend on small differences in position of the mucosa, which is, in turn, dependent on the wave motion of the vocal fold and the frequency and amplitude of vibration.

Figures 3 and 4 are two series of successive frames taken from the videotape. When the tape is running, the interference fringes are seen to flow away from the glottic opening. From our understanding of the mucosal wave, we would expect the displacement of the mucosa to propagate from inferior and medial to superior and lateral.

A possible interpretation of this image is that it is simply a mucosal wave on the surface of the vocal fold, as we typically see with standard stroboscopy. However, during the experiment, when the vocal fold motion was "frozen" to the naked eye examining the larynx directly, there was much activity on the video monitor. A more likely interpretation, then, is that the fringes seen on the video monitor represent the very subtle changes that occur from frame to frame while the vocal folds are very slowly moving through a glottal cycle. In other words, we may be seeing the mucosal wave with the greatest detail possible, at the micron level.

The fringes in Fig 3C,E that are oriented at almost 90° to the edge of the vocal fold do not fit into our current understanding of the wave motion of the vocal fold mucosa. The motion suggested here may represent harmonic oscillations of the vocal fold mucosa. Motion this subtle would not be detectable with any of our current techniques for studying vocal fold motion. In fact, we should not expect the mucosa of the vocal fold to move upward at exactly the same rate all along its length, especially when considering these movements in terms of microns. Hence, ESPI may provide us with the ability to examine a whole new realm of vocal fold vibratory characteristics that until now have been only theoretic postulations.

The next step in this series of investigations would be to manipulate the timing of the laser in a more precise manner. First, the laser could be strobed in the same manner as our current VS units, with the ability to truly synchronize the laser with the vocal signal and allow for varying of the phase relationship between the glottal cycle and the laser flashes. Second, a pulsed laser could be used to provide a very brief pulse (10 nanoseconds) that would illuminate a small portion of the glottal cycle. Another pulse would create another image, and these two frames could be subtracted to provide an interferogram representing the displacement of the vocal fold during a discrete portion of the glottal cycle. Too much displacement may cause blurring of the fringes, but as the time interval between pulses is decreased, usable data may be obtained. These investigations require a very bright pulsed laser, which we do not currently have.

A possible flaw of ESPI is that it may be too sensitive for application to the vibrating vocal folds, which typically move several millimeters during phonation. Currently, trying to quantitate the motion of the vocal fold during one full glottal cycle would require the analysis of thousands of video frames, each with very few fringes on them. We hope that the modifications described above will overcome this problem.

Another obvious criticism of this study and ESPI in general is the poor quality of the images. This is a problem inherent in ESPI, which sacrifices clarity of the image for much quicker processing time and a less cumbersome optical setup as compared to holographic interferometry with film plates. We hope that as we refine our system further, the quality will improve. Although it cannot be appreciated here, the running videotape provides a much better sense of the activity of the vocal folds than the still frames seen in this report.

Although application of this technique to the larynx is in its early stages and has not yet been refined for practical use, the results presented here demonstrate that ESPI of the vibrating vocal folds is possible. This procedure has the potential to provide us with a method for studying the vocal folds that is sensitive to motion in the vertical axis, provides quantifiable data, and may allow us to study fine motion of the vocal fold mucosa, which with current techniques is undetectable.

Clinical benefits that may be gained with ESPI include better sensitivity at detecting vocal fold le-

sions, including malignancies, and the ability to quantitate changes in vocal fold dynamics after phonosurgery.

SUMMARY

We have presented the first interferograms ever obtained of vibrating vocal folds. With ESPI, interference fringes were demonstrated on the vocal folds of an excised human larynx vibrating at physiologic levels.

By strobing the laser, the apparent motion of the vocal folds was "frozen," and ESPI was able to detect and measure the minimal displacement of the mucosa that occurred between frames captured by the video camera. This was between 0.3 and 0.9 μm.

Although this technique is not yet refined for practical use in the larynx, it holds much promise for providing a method of quantifying the motion of the vocal folds, including that motion that occurs in the vertical axis.

ACKNOWLEDGMENTS — The authors thank Lou Reinisch, PhD, for his insight into all matters associated with lasers and assistance with computer processing of the video image, and R. E. (Ed) Stone, PhD, for assistance with sound analysis.

REFERENCES

1. Hirano M. Clinical examination of the voice. Vienna, Austria: Springer-Verlag, 1981.

2. Kitzing P. Clinical applications of electroglottography. J Voice 1990;4:238-49.

3. Baer T, Lofqvist A, McGarr NS. Laryngeal vibrations: a comparison between high-speed filming and glottographic techniques. J Acoust Soc Am 1983;73:1304-8.

4. Von Leden H, Moore P. Vibratory pattern of the vocal cords in unilateral laryngeal paralysis. Acta Otolaryngol (Stockh) 1961;53:493-506.

5. Saito S, Fukuda H, Kitahara S, et al. Pellet tracking in the vocal fold while phonating — experimental study using canine larynges with muscle activity. In: Titze R, Scherer RC, eds. Vocal fold physiology. Denver, Colo: Denver Center for the Performing Arts, 1985:169-82.

6. Fukuda H, Saito S, Kitihara S, et al. Vocal fold vibration in excised larynges viewed with an x-ray stroboscope and an ultra-high-speed camera. In: Bless DM, Abbs JH, eds. Vocal fold physiology. San Diego, Calif: College-Hill Press, 1983:238-52.

7. Fukuda H, Kawasaki Y, Kawaida M, et al. Physiological properties and wave motion of the vocal fold membrane viewed from different directions. In: Gauffin J, Hammarberg B, eds. Vocal fold physiology. San Diego, Calif: Singular Publishing Group, 1991:7-14.

8. Raviv G, Marhic ME, Scanlon EF, Sener SF, Epstein M. In vivo holography of vocal cords. J Surg Oncol 1982;20:213-7.

9. Gardner GM, Castracane J, Conerty M, Parnes SM. Laser holography and interferometry of the larynx: preliminary studies with a cadaver model. Trans Am Laryngol Assoc 1992;113:104-9.

10. Sharp B. Electronic speckle pattern interferometry (ESPI). An engineering approach. Newport Corporation Technical Report, Fountain Valley, Calif, 1990.

11. Hogmoen K, Lokberg OJ. Detection and measurement of small vibrations using electronic speckle pattern interferometry. Appl Opt 1977;16:1869-75.

12. Hariharan P. Holographic and speckle interferometry. In: Basics of interferometry. San Diego, Calif: Academic Press, 1992:117-27.

13. Netterville JL, Stone RE, Luken ES, Civantos FJ, Ossoff RH. Silastic medialization and arytenoid adduction: the Vanderbilt experience. A review of 116 phonosurgical procedures. Ann Otol Rhinol Laryngol 1993;102:413-24.

14. Hess MM, Gross M. High-speed, light-intensified digital imaging of vocal fold vibrations in high optical resolution via indirect microlaryngoscopy. Ann Otol Rhinol Laryngol 1993; 102:502-7.

15. Kiritani S, Imagawa H, Hirose H. High-speed digital image recording for the observation of vocal cord vibration. In: Fujimura O, ed. Vocal physiology: voice production, mechanisms and functions. New York, NY: Raven Press, 1988:261-9.

16. Sercarz JA, Berke GS, Arnstein D, Gerratt B, Natividad M. A new technique for quantitative measurement of laryngeal videostroboscopic images. Arch Otolaryngol Head Neck Surg 1991;117:871-5.

17. Childers DG, Paige A, Moore GP. Laryngeal vibration patterns. Machine-aided measurements from high-speed film. Arch Otolaryngol 1976;102:407-10.

18. Koike Y, Imaizumi S. Objective evaluation of laryngostroboscopic findings. In: Fujimura O, ed. Vocal physiology: voice production, mechanisms and functions. New York, NY: Raven Press, 1988:433-42.

19. Colton RH, Casper JK, Brewer DW, Conture EG. Digital processing of laryngeal images: a preliminary report. J Voice 1989;3:132-42.

20. Hirose H, Kiritani S, Imagawa H. Clinical application of high-speed digital imaging of vocal fold vibration. In: Gauffin J, Hammarberg B, eds. Vocal fold physiology. San Diego, Calif: Singular Publishing Group, 1991:213-6.

21. Sloan S, Berke G, Gerratt B, Kreiman J, Ye M. Determination of vocal fold mucosal wave velocity in an in vivo canine model. Laryngoscope 1993;103:947-53.

22. Cooper DS. The laryngeal mucosa in voice production. Ear Nose Throat J 1988;67:332-52.

23. Khanna S, Tonndorf J. Tympanic membrane vibrations in cats studied by time-averaged holography. J Acoust Soc Am 1972;51:1904-20.

24. Løkberg OJ, Høgmoen K, Gundersen T. Vibration measurement of the human tympanic membrane — in vivo. Acta Otolaryngol (Stockh) 1980;89:37-42.

25. Decraemer WF, Khanna SM, Funnell WRJ. Interferometric measurement of the amplitude and phase of tympanic membrane vibrations in cat. Hear Res 1989;38:1-18.

26. Dirckx JJJ, Decraemer WF. Human tympanic membrane deformation under static pressure. Hear Res 1991;51:93-106.

27. Decraemer WF, Dirckx JJJ, Funnell WRJ. Shape and derived geometrical parameters of the adult, human tympanic membrane measured with a phase-shift moire interferometer. Hear Res 1991;51:107-22.

DIAGNOSIS AND MANAGEMENT OF EXTERNAL PENETRATING CERVICAL ESOPHAGEAL INJURIES

WILLIAM B. ARMSTRONG, MD
IRVINE, CALIFORNIA

MAJ THOMAS R. DETAR, MC, USAF
SHREVEPORT, LOUISIANA

ROBERT B. STANLEY, MD, DDS
SEATTLE, WASHINGTON

External penetrating injuries of the esophagus are more likely to cause serious morbidity and even mortality than those involving the pharynx. However, the cervical esophagus is extrathoracic in location, and controversy exists regarding the diagnosis and surgical management of penetrating injuries at this level. A retrospective review of 23 such injuries showed that contrast esophagography had only a 62% success rate in identification of cervical esophageal violations, compared to 100% for rigid esophagoscopy. Even large penetrations were successfully treated with limited debridement, primary repair when possible, muscle interposition flaps to separate common injuries of the tracheal wall, and, most important, external drainage of the adjacent neck spaces. Esophageal stricture occurred only when complex esophageal diversion procedures were performed, either as an unnecessary primary operation, or as a lifesaving secondary operation necessitated by infectious complications caused by delayed diagnosis and treatment of the esophageal violation. Penetrating injuries of the cervical esophagus can therefore be managed more as a pharyngeal injury if diagnosis and appropriate surgical treatment occur in a timely fashion.

KEY WORDS — diagnosis, esophagus, management, trauma.

INTRODUCTION

External penetrations of the cervical esophagus are relatively uncommon injuries, even in major urban areas. When suspected, this type of esophageal violation must be confirmed with contrast esophagography, rigid esophagoscopy, or open neck exploration. Each method has its proponents, but none of the three has been reported to be accurate in all cases when used alone.[1-8]

Once diagnosed, external penetrating injuries are most commonly treated by primary repair of the esophageal wall and/or drainage of the retroesophageal space. Observation is not advocated because of associated disruption of the surrounding deep neck fascial planes.[2,3,9-11] Delay in treatment from 12 to 24 hours has been thought to allow enough leakage of saliva and bacteria, as well as refluxed acid, pepsin, and bile, into the surrounding loose areolar tissues to produce suppurative infection and an intense necrotizing inflammatory response.[3,11] This inflammation may make primary closure futile, and may allow rapid spread of infection into the mediastinum under the forces of gravity and negative intrathoracic pressure if the leakage is not drained away from the deep neck spaces.[8,11] Actual diversion of the cervical esophagus to the skin by means of a side esophagostomy, or end esophagostomy with exclusion of the distal esophageal segment by suturing or stapling techniques, has been advocated as the primary treatment by several authors for injuries greater than 16 hours old, for injuries with extensive tissue loss, and as the treatment for primary closures that fail.[3,8,9]

Complications of esophageal diversion are not well documented.[11-14] The occurrence of three serious strictures related to cervical diversion procedures (two for cervical esophageal injuries, and one for a thoracic injury) prompted a retrospective review of the charts of patients whose external penetrating injuries of the cervical esophagus were treated at the Los Angeles County–University of Southern California Medical Center from June 1982 to November 1992. The review was directed toward evaluation of the influence of wound characteristics, diagnostic techniques, and surgical management on both immediate and long-term outcome.

MATERIALS AND METHODS

Charts for review were identified by searching the computerized ICD-9 (International Classification of Diseases) diagnosis and procedure codes for inpatients discharged during the 10½-year period. The cervical esophagus was defined as the segment of esophagus lying between the horizontal planes of the cricopharyngeal muscle and the sternal notch. A

From the Department of Otolaryngology–Head and Neck Surgery, University of Southern California, Los Angeles, California. Dr Armstrong is currently at the Department of Otolaryngology–Head and Neck Surgery, University of California, Irvine, California. The opinions and assertions contained herein are the private views of the authors, and are not to be construed as official or reflecting the views of the Department of Defense.

Presented at the meeting of the American Laryngological Association, Palm Beach, Florida, May 7-8, 1994.

REPRINTS — Robert B. Stanley, MD, DDS, Dept of Otolaryngology–Head and Neck Surgery, University of Washington, Seattle, WA 98195.

TABLE 1. PATIENT CHARACTERISTICS

Case	Age (y)	Sex	Type of Injury	Size of Injury	Tracheal Injury	Hours to Antibiotics	Hours to Surgery	Type of Repair	Layers of Repair	Drain Type	Muscle Flap	Leak	Neck Abscess
1	16	M	GSW	Large	No	6.5	13	R/D	2	Pas	No	No	No
2	33	M	GSW	Large	Yes	69	66	R/D	1	Suc	No	Yes	Yes
3	30	M	SW	Medium	No	13	14	R/D	1	Pas	No	No	No
4	20	M	GSW	Large	Yes	1.5	19	R/D	2	Pas	No	No	No
5	23	M	GSW	Medium	No	11	14.5	R/D	1	Suc	No	No	No
6	18	M	GSW	Medium	Yes	11	12.25	R/D	2	Pas	No	No	No
7	4	F	GSW	Small	Yes	11	3	R/D	1	Pas	No	Yes	No
8	12	M	GSW	Large	Yes	10.5	13	R/D	2	Pas	Yes	No	No
9	15	M	GSW	Small	No	22	14	Div	Div	Div	No	N/A	No
10	26	M	SW	Small	Yes	7	21.5	D	N/A	Pas	No	No	No
11	38	M	SW	Large	Yes	3.5	1.5	R/D	2	Suc	No	No	No
12	22	M	SW	Medium	Yes	11	14	R/D	2	Pas	No	Yes	No
13	29	M	GSW	Large	Yes	2	19.25	R/D	1	Pas	Yes	No	No
14	20	F	PW	Small	No	14	14	D	N/A	Pas	No	No	No
15	18	M	GSW	Small	No	16.5	19	R/D	2	Suc	Yes	Yes	Yes
16	21	M	GSW	Medium	No	4	11	R/D	2	Suc	No	No	No
17	36	M	SW	Medium	Yes	5.25	3	R/D	2	Pas	No	No	No
18	22	M	GSW	Small	No	17.5	21	D	N/A	Pas	No	Yes	No
19	23	M	GSW	Small	No	15	15	R/D	2	Pas	Yes	Yes	No
20	30	M	GSW	Large	Yes	1.5	19	R/D	2	Suc	Yes	Yes	No
21	30	M	GSW	Large	Yes	10	9.5	R/D	1	Pas	Yes	No	Yes
22	27	F	GSW	Large	Yes	13	20	R/D	2	Suc	Yes	No	No
23	35	F	GSW	Medium	Yes	1	26	R/D	1	Suc	Yes	Yes	No

GSW — gunshot wound, SW — stab wound, PW — pellet wound, R/D — repair and drainage, Div — diversion, D — drainage, N/A — not applicable, Pas — passive, Suc — suction.

patient was included if an external penetrating neck injury produced a confirmed violation of the esophageal mucosa between these levels. Therefore, external penetrations into the hypopharynx were excluded, as were perforations caused by endoscopic instrumentation. Twenty-five cases were identified, 2 of which were excluded because identification of the injury and surgical management were performed elsewhere prior to transfer to our facility. The 23 included charts were reviewed for patient age and sex, wounding mechanism, airway management, associated injuries, time until first antibiotic administration, time until surgery, injury characteristics, surgical management, postoperative complications, and follow-up airway and swallowing function.

Esophagrams were performed by having the patient swallow water-soluble and/or barium radiographic contrast material, or by instilling contrast material into the hypopharynx through a tube if the patient could not cooperate enough to initiate a swallow. Endoscopic techniques included flexible fiberoptic indirect laryngopharyngoscopy, rigid direct laryngoscopy, rigid cervical esophagoscopy, and in some cases rigid bronchoscopy. Flexible esophagoscopy and bronchoscopy were not performed in this series. The majority of patients were managed by the Otolaryngology–Head and Neck Surgery Service, although several were managed in conjunction with the General Surgery Service, or by that service alone.

RESULTS

General. A total of 23 patients who suffered external penetrating injuries of the cervical esophagus were managed (Table 1). The group included 19 male and 4 female patients, the age range being 4 to 38 years, with a mean age of 23.8 years. Five esophageal penetrations were due to stab wounds (SWs), 17 due to gunshot wounds (GSWs), and 1 due to a single pellet wound (PW) from a shotgun blast. Fourteen patients (61%) had associated tracheal injuries: 9 of these were in direct continuity with the esophageal injury, 4 were isolated from it, and 1 patient had a complete transection of both structures (the result of a self-inflicted slash wound). Cervical or upper thoracic spine fractures occurred in 6 patients, 2 of whom were paraplegic. Brachial plexus injuries were identified in 4 patients. Associated vascular injuries included 2 external jugular vein lacerations, 2 internal jugular vein lacerations, 1 thyrocervical trunk laceration, 1 vertebral artery pseudoaneurysm, 1 ver-

tebral artery occlusion, and 1 common carotid artery pseudoaneurysm. No sequelae of the vascular injuries occurred. All of these associated injuries except 1 external and 1 internal jugular vein laceration were the result of gunshot wounds. No deaths occurred in the study group.

Airway Management. Eight patients were deemed to have a stable airway and were intubated electively in the operating room for administration of general anesthesia prior to rigid endoscopy and/or neck exploration. Fifteen patients had an airway established prior to transfer to the operating room. Thirteen were considered to have emergent airways, and 1 an urgent airway, and 1 patient was prophylactically intubated for transfer to our facility. Eight patients were either orotracheally or nasotracheally intubated in the emergency room for airway obstruction (6 patients), for progressive airway compromise (1 patient), or prophylactically for transfer (1 patient) during their initial evaluation. Six patients underwent a tracheostomy and 1 patient a cricothyroidotomy for emergency airway establishment when the responsible physician decided that transoral or transnasal intubation could not be safely performed.

Laryngeal Examination. Flexible fiberoptic laryngoscopy was performed prior to transfer to the operating room in 14 patients. A unilateral vocal cord paralysis was noted in 6 patients, and a bilateral paralysis in 1 patient, and in 1 patient a determination could not be made because of bleeding. One patient (No. 11) had a self-inflicted slash wound transecting the esophagus and trachea with resultant clinically obvious bilateral recurrent nerve transection. No other instances of a transected recurrent nerve's being identified at the time of neck exploration were described, although several operative notes failed to mention the status of the nerve. Postoperatively, 11 patients were found to have vocal cord paralysis. These patients included the 8 known to have a paralysis preoperatively, 2 patients not examined preoperatively, and 1 patient who had documented bilateral vocal cord mobility prior to neck exploration. Further follow-up was accomplished in only 5 of these 11 patients, with 3 (including 1 bilateral paralysis patient) having partial or complete return of function.

Diagnosis of Esophageal Injury. At initial evaluation, subcutaneous air, or air escaping from the wound, was the most common clinical finding, present in 16 of the 23 patients. Other clinical findings commonly seen in these patients included airway compromise in 14 patients, blood from the mouth or throat in 11 patients, a neck hematoma in 9 patients, vocal cord paralysis in 8 patients, voice change in 6 patients, and odynophagia in 4 patients.

A contrast esophagram was performed in 13 patients, with positive studies (extravasation of material) seen in 8 (62%). Of the 5 studies that failed to reveal the injury, 3 were false-negative, 1 equivocal, and 1 "inadequate." Five of the 13 patients had an artificial airway in place at the time of the esophagram, and 4 of the studies that failed to show a leak were in these patients. Thus, only 1 missed injury occurred in a patient with no artificial airway in place. A preoperative contrast swallow study was not performed in 10 patients, because endoscopy and/or neck exploration was already planned on the basis of clinical or radiographic findings of a tracheal or esophageal injury.

Rigid esophagoscopy was performed before neck exploration in 16 patients, and the site of esophageal penetration was identified in all 16. One other patient (No. 18) initially thought to have an unstable cervical spine fracture underwent neck exploration without endoscopy. A bullet track between the trachea and esophagus was identified, but no mucosal violation of the trachea or esophagus was found. Exposure and drainage of the area was difficult, however, because the neck could not be extended. The patient was returned to the operating room for rigid endoscopy after the cervical spine was cleared, and disruption of the posterior tracheal wall and ecchymosis of the postcricoid mucosa were noted. The esophagus was very edematous, and no penetrations were seen. However, several days later, saliva appeared to be leaking from the drain site, and a contrast swallow study confirmed extravasation from an esophageal injury that appeared to be adequately drained. Seven other patients did not undergo rigid esophagoscopy prior to neck exploration. Five of these had positive esophagrams, 1 an obvious esophageal transection, and 1 did not have clearance of the cervical spine for extension.

Time Interval From Injury to Surgical Management. Five patients were taken to the operating room within 12 hours of the time of injury, 9 patients between 12 and 18 hours postinjury, 7 patients between 18 and 24 hours postinjury, and 2 patients over 24 hours postinjury.

Size of Esophageal Injury. Injuries were classified on the basis of the maximum described dimension as small (n = 7; less than or equal to 1 cm), medium (n = 7; greater than 1 cm but less than or equal to 2 cm), and large (n = 9; greater than 2 cm). The numbers of small, medium and large SWs, GSWs, and PWs are shown in Table 2.

Primary Treatment. Nineteen patients underwent primary repair of the esophageal penetration and drainage of the retroesophageal space. Closure of the

TABLE 2. CLASSIFICATION OF WOUNDS

	Stab	*Gunshot*	*Pellet*	*Total*
Small	1	5	1	7
Medium	3	4	0	7
Large	1	8	0	9
Total	5	17	1	23

esophagus was accomplished either in one layer with chromic gut (1 patient), polyglycolic acid (3 patients), or silk (3 patients), or in a two-layered manner with chromic gut used for both layers (1 patient), polyglycolic acid for both layers (4 patients), polyglycolic acid and silk (5 patients), or polyglycolic acid and polypropylene (2 patients). Sternocleidomastoid or strap muscle flaps were used to reinforce 8 of these closures: 6 flaps to separate a common tracheoesophageal injury, and 2 flaps to reinforce an isolated esophageal closure. Three patients underwent only drainage of the retroesophageal space after endoscopic identification of either an SW (patient 10) or a PW (patient 14) thought to be too small to warrant mobilization of the esophagus to allow for placement of sutures, or after failure to identify a small GSW (patient 15) at the time of neck exploration. One patient (No. 9) underwent side esophagostomy at the site of a small GSW. The decision to perform this primary diversion procedure was apparently based on a 14-hour time period between injury and surgical management.

Salivary Leaks. Patients were evaluated for healing of the esophageal repair by monitoring drain output, and in most patients with a methylene blue and/or radiographic contrast swallow study 7 to 10 days following surgery. If these studies did not demonstrate leakage, oral intake was initiated. A prolonged salivary leak was defined as lasting more than 7 days following the initial neck exploration, and was diagnosed by observation of obvious saliva or methylene blue drainage from the neck wound, radiographic evidence of contrast extravasation from the esophagus, or direct or endoscopic visualization of a hole at the site of primary closure, if the neck was reopened for drainage of an abscess. Patient 9, who underwent a primary diversion procedure that created an intentional esophagocutaneous fistula, was excluded, thus leaving 22 patients for evaluation of salivary leaks. Eight (36%) of the patients had a prolonged leak, including 7 of the 19 (37%) patients who underwent primary repair and drainage, and 1 of 3 (33%) patients who underwent drainage only. Three leaks closed spontaneously within 3 weeks, and 1 (patient 7) evolved into a blind retropharyngeal pouch that was endoscopically marsupialized 4 weeks after injury. Three additional leaks required between 3 and 8 weeks to spontaneously close. The remaining leak, in patient 2, eventually necessitated an end esophagostomy with distal esophageal exclusion to totally divert saliva from a chronically infected mediastinum.

Evaluation of the relationship of the size of the esophageal penetration alone to occurrence of salivary drainage revealed prolonged leaks in 4 of 6 small wounds (67%), 2 of 7 medium wounds (29%), and 2 of 9 large wounds (22%). Evaluation of the wounding mechanism alone showed that prolonged leaks occurred in 1 of 5 SWs (20%) and 7 of 16 GSWs (44%), and not in the 1 PW. Evaluation of treatment delay alone revealed that prolonged leaks occurred in 1 of 5 injuries (20%) treated in less than 12 hours, 2 of 8 (25%) treated between 12 and 18 hours, 3 of 7 (43%) treated between 18 and 24 hours, and 2 of 2 (100%) treated after 24 hours. The combined effect of wound size, wounding mechanism, and treatment delay is shown in Table 3.

TABLE 3. ESOPHAGEAL LEAKS VERSUS WOUND SIZE, WOUNDING MECHANISM, AND TIME DELAY BETWEEN INJURY AND SURGICAL TREATMENT

	Time to Operation (h)				
Wound Type	*<12*	*12-18*	*18-24*	*>24*	*Total*
Small SW			0/1		0/1 (0%)
Medium SW	0/1	1/2			1/3 (33%)
Large SW	0/1				0/1 (0%)
Small GSW	1/1	1/1	2/2		4/4 (100%)
Medium GSW	0/1	0/2		1/1	1/4 (25%)
Large GSW	0/1	0/2	1/4	1/1	2/8 (25%)
Small PW		0/1			0/1 (0%)
Medium PW					
Large PW					
Total	1/5 (20%)	2/8 (25%)	3/7 (43%)	2/2 (100%)	8/22 (36%)

Data are numbers of patients with leaks per number of patients in category. Patient 9, who underwent primary esophageal diversion, is excluded from this analysis.

SW — stab wound, GSW — gunshot wound, PW — pellet wound.

The only prolonged leak among SW victims occurred in patient 12, in whom a wound of medium size was repaired 14 hours following injury. He had an associated tracheal injury, and primary closure of both lumens was achieved in a layered fashion without a muscle interposition flap. Stab wound victims who healed without prolonged leaks include the following: patient 17, who also had a medium SW and an associated tracheal injury that were treated with the same type of repair 3 hours after the injury; patient 3, whose medium SW without an associated tracheal injury was repaired in a layered fashion 14 hours after injury; patient 10, who had a very small SW with an associated tracheal injury, the treatment of which consisted of drainage without closure 21.5 hours later; and patient 11, who suffered a self-inflicted slash wound that transected both the trachea and the esophagus, treated with a completion laryngectomy and layered closure of the esophageal transection 1.5 hours after the injury.

The cluster of prolonged leaks among the small GSW patients includes patient 18, whose injury was overlooked and therefore not repaired at the time of initial neck exploration; patient 7, whose penetration was closed with a single silk suture 3 hours after the injury; and 2 patients, 15 and 19, aggressively treated with two-layered esophageal closure reinforced with a local muscle flap, even though no tracheal injury was present, 19 hours and 15 hours after the injury, respectively. The only medium GSW (patient 23) that leaked was closed 26 hours after the injury in a single layer with a muscle flap interposed between adjacent tracheal and esophageal penetrations. Among the 3 medium GSWs that did not leak (patients 5, 6, and 16), all were repaired within 14.5 hours of injury, and only 1 (patient 6) was associated with a tracheal injury. A muscle flap was not used to separate the layered closures of the trachea and esophagus in this patient.

The only 2 large GSWs that led to prolonged leaks were in patient 2, whose injury was repaired with a single layer closure with no muscle flap interposed between adjacent tracheal and esophageal wounds 66 hours after the injury, and patient 20, whose injury was closed in a layered fashion with a muscle flap to separate an adjacent tracheal injury 19 hours following trauma. However, 3 other large GSWs also with adjacent tracheal injuries were successfully closed, in patients 4, 13, and 22, at 19 to 20 hours from injury. A two-layered closure was used, except in patient 13, and a muscle interposition flap was used, except in patient 4. Both large GSWs (patients 1 and 8) treated in the 12- to 18-hour period healed without problems. Patient 8 had an associated tracheal injury that was separated from the layered esophageal closure with a muscle flap. The single large GSW treated in under 12 hours (patient 21) healed without a prolonged leak following a one-layered closure of the esophagus with a muscle flap to separate an adjacent tracheal injury.

Further evaluation of repair and drainage techniques showed that 7 patients had esophageal wounds closed in one layer and 3 developed prolonged leaks (43%). This included patient 2, who had the extremely delayed surgery. Twelve patients were closed in a two-layered fashion, and 4 developed leaks (33%). Eight muscle flaps were used, and leaks developed in 4 (50%): 2 patients with small GSWs, 1 patient with a medium GSW, and 1 with a large GSW. The 4 patients with muscle flap supplementation that did not leak had large GSWs. Suction drains were used in 8 patients, and 4 of those (1 small, 1 medium, and 2 large GSWs) developed prolonged leaks (50%). Passive drains were used in 12 patients, and 4 of these (3 small GSWs and 1 medium SW) developed prolonged leaks (33%).

Further evaluation of the 14 associated tracheal injuries revealed that 9 were part of a common hole that exposed the lumina of both the trachea and the esophagus to the neck spaces. The 5 patients who did not have this finding included 3 with through-and-through tracheal wounds in which the exit wound from the trachea was through the common wall with the esophagus with no extraluminal exposure of either structure. The extraluminal violation of the esophagus then occurred as a second injury distant from the tracheal wound. One other patient had tangential injuries of the lateral walls of both structures with an intervening area of intact tissue in both walls, and the final patient had complete transection of both structures due to a self-inflicted slash wound.

The tracheal component of the 9 common hole injuries was repaired primarily, with 6 of these repairs being supplemented by a muscle flap interposed between the tracheal and esophageal closures. The 4 tracheal injuries that did not produce a common hole involving both lumina were not repaired and were allowed to heal by secondary intention, and the trachea in the patient who underwent the laryngectomy was, of course, brought to the skin as a tracheostoma. Prolonged esophageal leaks occurred in 5 of the total of 14 patients (36%) with associated tracheal injuries, 3 of these leaks being in the 9 patients with a common hole involving both lumina. Two of these leaks (patients 20 and 23) had muscle interposition flaps. Among the 4 patients whose tracheal and esophageal wounds were not in continuity, no interposition muscle flaps were used, and 2 prolonged leaks occurred. A persistent communication between the esophagus

and trachea beyond the time of initial surgery was noted in only 2 patients. One of these (patient 7) had no repair of a common wall injury that was observed to close spontaneously in 3 weeks. The second patient (No. 20) required revision of a failed sternocleidomastoid muscle flap with a larger, inferiorly based sternocleidomastoid flap.

Neck Infections. Purulence was already present in the wounds of 4 patients explored at 14 hours (patient 14), 19 hours (patient 15), 20 hours (patient 22), and 66 hours (patient 2) from the time of injury. Patients 14 and 22 healed without complications following their initial surgery. However, patients 2 and 15 developed deep neck abscesses. Patient 2 suffered a GSW that left him paraplegic because of a spinal cord injury at the T-1 level. He underwent an emergent cricothyroidotomy necessitated by a through-and-through injury of the trachea. An angiogram revealed no vascular injuries, and a technically adequate contrast swallow study failed to show evidence of an esophageal penetration. He was not started on antibiotics, and 2 days later he was noted to have increased subcutaneous air in the neck and spiking fevers. His neck was explored 66 hours from the time of injury, and he was found to have a large injury of the esophagus with an abscess. The esophageal injury was closed in one layer and the neck was drained. However, the purulence reaccumulated and spread to the mediastinum and pleural space, necessitating a thoracotomy, and eventual cervical esophageal diversion and exclusion of the distal segment for control of the mediastinal infection.

Patient 15 sustained a small GSW to the esophagus without an associated tracheal injury. The wound was repaired and drained 19 hours following injury, and there was purulent drainage in the wound bed at the time of repair. He subsequently developed a leak and abscess necessitating drainage procedures at 6 and 11 days following the initial repair. The leak sealed and the abscess resolved following adequate drainage. An abscess also developed in a third patient (No. 21) who suffered a GSW that disrupted greater than three fourths of the esophageal lumen, with extensive surrounding tissue damage that included an in-continuity tracheal defect. His neck was explored 9.5 hours from the time of injury, and a muscle flap was used to reinforce the repair of the esophagus. A lateral neck abscess developed, distant to the site of the esophageal injury, and no salivary leak was found when the abscess was drained. The patient healed without further complications.

Antibiotic Use. A variety of antibiotic agents, including penicillin, cefazolin, metronidazole, clindamycin, and gentamicin, were given to the patients in various combinations. Surprisingly, only 7 patients had their first dose of antibiotics within 6 hours of injury. Eight patients received the first antibiotic dose between 6 and 12 hours following injury, 6 patients between 12 and 18 hours postinjury, and 1 (No. 9) at 22 hours, and 1 patient (No. 2) did not receive his first antibiotic until 69 hours after injury. Six patients did not receive antibiotics until after their initial neck exploration. None of the 15 patients who received antibiotics within 12 hours of the injury had purulence in the neck wound at initial exploration, whereas 4 of 8 (50%) patients who received antibiotics 13 or more hours after the injury had purulence already in the wound. The 3 deep neck abscesses in the series developed in patients who received no antibiotics during the first 10 hours following injury.

Swallowing and Airway Function. Fifteen patients were taking what they considered to be their regular diet at last follow-up, which ranged from 1 week to 6 months. Four patients had persistent swallowing difficulties. These included patient 2, who eventually underwent a gastric pull-up following a secondary esophageal diversion, and patient 9, who underwent primary diversion. He developed a stricture at the diversion site, and required multiple dilations over the next 10 months. Patient 18 began experiencing vomiting after eating 4 months after the esophageal repair, and an esophagram demonstrated dysmotility distal to the injury. Patient 11, who underwent completion laryngopharyngectomy, experienced initial dysphagia thought to be due to poor oropharyngeal coordination, but did not develop a stricture and was eating well 6 months later. An exact description of the diet at time of discharge was not available for 4 patients, who did not return for follow-up. One of these patients died of a second GSW 3 months later.

Twenty of the 23 patients, including the 4 who did not return for follow-up after leaving the hospital, were breathing well without the need for an artificial airway when last seen. The only patients who had long-term tracheostomies were the 2 paraplegic patients, Nos. 2 and 20, who had their tracheostomy tubes in place when transferred for long-term spinal cord injury rehabilitation. Patient 11, who underwent laryngopharyngectomy, was breathing well through his tracheostoma.

DISCUSSION

The clinical findings of subcutaneous air, air escaping from a wound, vocal cord paralysis, and airway compromise following an external penetrating wound of the neck are all signs of injury to the upper aerodigestive tract. Unfortunately, they are nonspecific, and may develop secondary to laryn-

geal, pharyngeal, tracheal, or cervical esophageal injuries.[5,15] Infection within the deep neck spaces is more likely to result from penetration into the pharynx or cervical esophagus, because of the constant flow of bacteria-laden saliva through these structures. The chance of life-threatening spread into the mediastinum or pleural cavities increases as the level of the penetration approaches the thoracic inlet. Therefore, any external penetration into the cervical esophagus must be identified while the effects of the extraluminal contamination are minimal. Treatment must contain this contamination to the immediate vicinity of the penetration and restore the integrity of the wall of the esophagus.

Flexible fiberoptic laryngoscopy allowed for evaluation of the status of the endolarynx, as well as vocal cord mobility, in those patients who had not undergone emergency intubation. The finding of a paralyzed vocal cord in an otherwise intact larynx gave indirect evidence that the missile or pointed weapon had damaged the recurrent nerve, thus placing the path of penetration to at least the level of the tracheoesophageal sulcus. However, vocal cord mobility was found to be intact in 43% of patients whose laryngeal function was examined preoperatively, indicating that a serious esophageal injury can occur without injury to either recurrent laryngeal nerve. Perhaps more important, preoperative documentation of vocal cord movement may prevent blame from being placed on the subsequent surgical procedure as a cause of postoperative vocal cord paralysis.

Esophagography using water-soluble or barium contrast material successfully demonstrated the presence of an esophageal violation in only 62% of patients who underwent the study. One of the 5 esophagrams that failed to demonstrate the leak was performed in a cooperative, nonintubated patient, and 4 were performed in patients with artificial airways already in place. Two patients' cervical spines were not radiographically or clinically cleared for extension. This indicates that at best, contrast esophagography may be relied on to demonstrate most, but not all, cervical esophageal penetrations in patients who can cooperate fully during the swallow phase of the test. It is a totally inadequate test in the intubated and/or neurologically compromised patient. Reliance on a false-negative study early in the series led to a delay in diagnosis of the esophageal violation, which produced the most serious long-term morbidity among the whole group. Fortunately, no deaths occurred among our patients, although they have been reported related to false-negative esophagrams.[5]

Rigid cervical esophagoscopy was uniformly successful in identifying mucosal violations in patients examined prior to neck exploration. A single penetration was missed in a patient who had considerable edema and ecchymosis related to not only a GSW, but also a neck exploration performed 24 hours previously. The ability to recognize esophageal abnormalities does, however, depend on the skill and experience of the endoscopist, and the insertion of a rigid instrument into the esophagus carries a small but definite risk of iatrogenic perforation.[16] The major limitation of rigid endoscopy occurs in the patient with a known or a potential spinal injury that prevents manipulation of the neck during insertion of the instrument.[14] Flexible esophagoscopy, which was not used in this series, would seem to be an alternative in these patients, but its ability to allow for identification of abnormalities in the cervical esophagus has been reported to be poor, especially when mucosal edema due to trauma is present.[7,17]

The incidence of prolonged leakage in this series was higher than in other reports.[3,8,18] This is consistent with the previously described progressive increase in the likelihood of developing an esophageal leak as the time from injury to repair increases.[3,5] Only 5 of the 23 patients in our series were taken to the operating room within 12 hours of the time of injury, and the incidence of prolonged leakage increased from 20% to 43% when comparing this group of patients to the group treated between 18 and 24 hours from the time of injury. The delay in surgical management for each case could be attributed to either delays in performing preoperative angiography or contrast esophagography, or to low prioritization on the typically long list of patients waiting to be taken to the operating room at our institution for equally emergent problems.

Patients who suffered GSWs had twice the risk of developing a prolonged esophageal leak or neck abscess as those who suffered SWs or PWs. This can be attributed to the more extensive damage to the surrounding tissue that occurs as the missile penetrates the wall of the esophagus. Wound edges tend to be more irregular, and tissue viability may be in question. These factors partially explain why small GSWs had a very high incidence of prolonged leaks in this series. The injury was most likely underestimated at the time of repair, and sutures were placed through tissue of marginal viability, leading to wound breakdown and leakage, even when the closure was reinforced with a muscle flap. Inflammation related to delay of surgical management may also have been a contributing factor to the paradox of small wounds having a higher incidence of postrepair leaks than large wounds. In this group, as well as all the other patients, there appeared to be no relationship between the type of closure, type of drainage, or presence of an

associated tracheal injury and the development of a prolonged esophageal leak or deep neck abscess. Of note, 2 of the 3 patients who had a drainage procedure without repair of the esophagus did not develop an esophageal leak.

Long-term complications related to the esophageal injury were uncommon in this series. Swallowing function was preserved without additional treatment in all patients except for 2, who developed a symptomatic esophageal obstruction following formal esophageal diversion procedures. One of these was a primary procedure that on the basis of the findings for the other patients in this series appeared to be the causative factor for development of a stricture. This patient subsequently required multiple dilations. The other diversion was a secondary procedure performed in a patient whose initial diagnosis and treatment had been extremely delayed, leading to neck and mediastinal abscess formation. The esophageal obstruction in this patient was created intentionally so that saliva would be totally diverted from the thoracic inlet, thus allowing for sterilization of the mediastinum. A gastric pull-up was later required to restore limited swallowing function in this patient.

A watertight seal of an external penetrating injury into the cervical esophagus does not appear to always be a realistic or even desirable goal, particularly in patients with tissue loss due to GSWs, or in patients whose treatment has been delayed beyond 12 hours. To ensure that truly viable tissue is being approximated in every case would require resection of considerable mucosa around the periphery of the wound, and mobilization and advancement of adjacent tissue for closure. This dissection might actually further devascularize the injured segment of esophagus and increase the total amount of tissue loss, thus increasing the risk of stricture formation. Also, recurrent laryngeal nerves that survived the initial injury will be at high risk for damage if extensive dissection is performed in one or both tracheoesophageal sulci. Instead, an approach to these injuries that accepts a less than perfect approximation of the esophageal wall appears to be preferable as long as a salivary leak is anticipated and adequately drained externally, away from other deep neck spaces and the mediastinum.

Diversion of the saliva should not require a total esophageal diversion (end esophagostomy), or even partial esophageal diversion (side esophagostomy) if the initial neck exploration and drainage of the deep neck spaces are performed within 24 hours of the injury. Multiple drains may be required, and these can be either passive drains or suction drains, depending on the surgeon's preference. All patients must be followed up closely, and returned to the operating room immediately for repeat neck exploration if signs of infection develop. A formal primary diversion procedure should be considered if, at the initial procedure, purulence is found to have already advanced into the mediastinum because of a long delay in treatment, or if the esophageal violation extends below the level of the thoracic inlet, and the mediastinum has suffered prolonged direct contamination.

Muscle interposition flaps did not prevent prolonged salivary leaks in those patients with associated tracheal injuries, but they may have helped to channel the flow away from the trachea and prevent tracheoesophageal fistula formation. A conservative approach to management of the tracheal injuries themselves led to no known instance of symptomatic tracheal stenosis in this series. All patients, other than 2 spinal cord injury victims, were decannulated prior to discharge, or at their first postoperative clinic visit.

A totally unexpected finding was the long delay before antibiotic administration in almost every case. This delay appeared to be related to the movement of the patients to multiple areas in the hospital during their admission, workup, and transport to the operating room. In spite of this, purulence was found in the neck spaces at initial neck exploration in only 4 patients. All 4 had a delay in antibiotic administration of a least 12 hours, and a delay in surgical treatment of at least 14 hours. Of note, 2 of the 3 abscesses in the series developed in these 4 patients. The other abscess occurred in a patient (No. 21) who did not receive antibiotics until in the operating room 10 hours after the injury. His abscess was located in the lateral neck, distant from the primary repair, and appeared to be secondary to inadequate debridement of devitalized soft tissue, rather than delay of surgical management and antibiotic administration. Patients with suspected cervical esophageal penetrations would be better treated with early initiation of antibiotic therapy to cover oropharyngeal flora. Ideally, the first dose should be given before the patient leaves the emergency room, rather than depending on personnel in subsequent areas of the hospital to discover the order and initiate therapy. The antibiotics should be continued until the esophagus has been proven to be intact. There is no role for withholding antibiotics in these patients for fear of "masking" a developing infection.

CONCLUSION

Because of the extrathoracic location of the cervical esophagus, management of external penetrating wounds into this transition zone between the pharynx and the thoracic esophagus is controversial. Our experience indicates that contrast esophagography

has an unacceptably high rate of false-negative results, and should not be relied on to document the integrity of the esophageal wall, particularly in patients who have been intubated, who have had a tracheostomy or cricothyroidotomy placed, or who have cervical spine injuries. Rigid esophagoscopy, when performed by an experienced endoscopist, should have a nearly 100% success rate in identification of mucosal violations. For all patients with cervical spine instability that prevents the safe insertion of a rigid esophagoscope, prophylactic neck exploration is indicated to evaluate the esophagus if the clinical findings suggest an injury.

Unlike some pharyngeal injuries that can be relatively safely observed, all external penetrating injuries of the cervical esophagus must be explored, repaired if possible, and drained to the skin surface so that the nearby mediastinum is protected. A watertight closure of the wall of the esophagus may not be possible or desirable, and prolonged salivary leaks should be anticipated for large wounds, all gunshot wounds, and wounds treated over 12 hours from the time of injury. Therefore, adequate external drainage is critical in these patients. Actual diversion of the esophagus to the skin, as is often done to protect a thoracic esophageal injury from salivary flow, should not be necessary if the cervical esophageal injury is adequately treated within 24 hours of the injury. Patients treated without a diversion procedure should regain near-normal swallowing function, but those treated with a diversion are at high risk for developing esophageal obstruction.

Antibiotics should be started in the emergency room if an injury is suspected, and the workup should proceed at a pace that ideally allows for surgical management within 12 hours of the injury. Delays in antibiotic administration and neck exploration increase the likelihood not only that purulence will already be present in the wound at time of initial exploration, but also that the patient will develop a deep neck abscess. Patients must be returned to the operating room immediately if signs of abscess develop, so that repeat drainage can be performed before infection spreads to the mediastinum.

REFERENCES

1. Defore WW, Mattox KL, Hansen HA, Garcia-Rinaldi R, Beall AC, DeBakey ME. Surgical management of penetrating injuries of the esophagus. Am J Surg 1977;134:734-8.

2. Flynn AE, Verrier ED, Way LW, Thomas AN, Pellegrini CA. Esophageal perforation. Arch Surg 1989;124:1211-5.

3. Glatterer MS, Toon RS, Ellestad C, et al. Management of blunt and penetrating external esophageal trauma. J Trauma 1985;25:784-92.

4. Nesbitt JC, Sawyers JL. Surgical management of esophageal perforation. Am Surg 1987;53:183-90.

5. Sheely CH, Mattox KL, Beall AC, DeBakey ME. Penetrating wounds of the cervical esophagus. Am J Surg 1975;130: 707-11.

6. Spenler CW, Benfield JR. Esophageal disruption from blunt and penetrating external trauma. Arch Surg 1976;111:663-7.

7. Weigelt JA, Thal ER, Snyder WH, Fry RE, Meier DE, Kilman WJ. Diagnosis of penetrating cervical esophageal injuries. Am J Surg 1987;154:619-22.

8. Symbas PN, Hatcher CR, Vlasis SE. Esophageal gunshot injuries. Ann Surg 1980;191:703-7.

9. Feliciano DV, Bitondo CG, Mattox KL, et al. Combined tracheoesophageal injuries. Am J Surg 1985;150:710-5.

10. Shockley WW, Tate JL, Stucker FJ. Management of perforations of the hypopharynx and cervical esophagus. Laryngoscope 1985;95:939-41.

11. Urschel HC, Razzuk MA, Wood RE, Galbraith N, Pockey M, Paulson DL. Improved management of esophageal perforation: exclusion and diversion in continuity. Ann Surg 1974;179: 587-91.

12. Menguy R. Near-total esophageal exclusion by cervical esophagostomy and tube gastrostomy in the management of massive esophageal perforation: report of a case. Ann Surg 1971; 173:613-6.

13. Hantke DR, Hoover LA, Zuckerbraun L. Physiologic exclusion of the injured esophagus. Arch Otolaryngol Head Neck Surg 1988;114:457-9.

14. English GM, Hsu SF, Edgar R, Gibson-Eccles M. Oesophageal trauma in patients with spinal cord injury. Paraplegia 1992; 30:903-12.

15. Popovsky J. Perforations of the esophagus from gunshot wounds. J Trauma 1984;24:337-9.

16. Elleson DA, Rowley SD. Esophageal perforation: its early diagnosis and treatment. Laryngoscope 1982;92:678-80.

17. White RK, Morris DM. Diagnosis and management of esophageal perforations. Am Surg 1992;58:112-9.

18. Winter RP, Weigelt JA. Cervical esophageal trauma. Arch Surg 1990;125:849-52.

PREDICTING RECURRENCE AND SURVIVAL IN PATIENTS WITH LARYNGEAL CANCER BY MEANS OF DNA CYTOMETRY, TUMOR FRONT GRADING, AND PROLIFERATION MARKERS

HANS-J. WELKOBORSKY, MD, DDS
HANS-P. DIENES, MD
MICHAEL HINNI, MD
WOLF J. MANN, MD, FACS
MAINZ, GERMANY

The cure rates for squamous cell carcinoma of the larynx have improved little over the past few decades. Despite the large number of therapeutic and histopathologic studies that have been performed, there are currently no morphologic or cytologic markers available to predict outcome in patients with laryngeal cancer. In an attempt to create such a system, tissues from 40 patients who underwent surgery for carcinoma of the larynx were examined for this pilot study. The examinations included routine histology, morphologic grading at the tumor front, immunohistochemical identification of the proliferation markers proliferating cell nuclear antigen (PCNA) and Ki67, and quantitative DNA analysis. By means of the stepwise multivariate Cox regression analysis with forward selection, factors that were highly correlated to the development of recurrent disease and survival were determined. We found that the results of the DNA analysis (ie, 2c deviation index, DNA malignancy grade), along with the morphologic tumor front grading and Ki67 score, were closely related to prognosis ($p < .01$). All of these factors reflect tumor biology. No correlation was found for the Broders grading or for any other clinical parameter. With the test battery used in this preliminary study, patients at high risk for developing tumor recurrences could be recognized. The advantages of this technique are that it is an objective assessment of the tumor and that it can be performed on preoperative biopsy specimens. This might influence decisions regarding therapeutic management and could eventually lead to more appropriate and individualized therapy.

KEY WORDS — Ki67 (MIB I), laryngeal carcinoma, prognosis, proliferating cell nuclear antigen, quantitative DNA analysis, tumor biology, tumor front grading.

INTRODUCTION

The literature is full of references that promote one treatment over another in squamous cell carcinomas of the upper aerodigestive tract. However, cure rates of these cancers have improved little over the past few decades. Given that surgery, irradiation, and chemotherapy all have limitations regardless of the proposed combination in curing many advanced-stage carcinomas, it seems reasonable to direct our attention to studying the host and the biology of the particular tumor. Despite a large number of therapeutic and histopathologic studies in print, there is currently no morphologic or cytologic feature available that consistently predicts outcome in patients with laryngeal cancer. The traditional grading system of Broders[1] is still the most widely used method of staging disease. This method has enjoyed broad acceptance due in part to its simplicity and universal utility; however, it has consistently proven unsatisfactory in predicting survival and prognosis.[2,3] Unfortunately, it is easy to overstage or understage the disease, depending on the individual examiner. Additionally, many tumors are difficult to classify, especially the locally recurrent ones. Predicting prognosis and selecting the most appropriate therapy from surgery, irradiation, and/or chemotherapy is difficult to do by evaluating the size of the primary, the grade, the number and location of involved nodes, and the presence of extracapsular spread. Further, it is clear that tumors contain various degrees of differentiation depending on the site examined within a specific tumor. Clearly, squamous cell carcinoma of the larynx is too complex a disease process to be evaluated in this manner alone. Host-related factors and the specific biology of the tumor are probably of critical importance in predicting prognosis. Some quantitative measure of these parameters should be included before one can create a system that predicts prognosis in a manner affecting the selection of treatment options.

PURPOSE

The purpose of this pilot study was to analyze the tumor biologic and host-related factors in patients

From the Departments of Otorhinolaryngology (Welkoborsky, Hinni, Mann) and Pathology (Dienes), School of Medicine, University Hospital, Mainz, Germany. This study was supported by grants from the German Research Society (Deutsche Forschungsgemeinschaft, DFG, Az.: We 1349/4-1).

Presented at the meeting of the American Laryngological Association, Palm Beach, Florida, May 7-8, 1994. Dr Welkoborsky received the Young Faculty Research Award for 1994 from the Association.

REPRINTS — Hans-J. Welkoborsky, MD, DDS, Dept of Otorhinolaryngology, University Hospital, School of Medicine, Langenbeckstr 1, D-55101 Mainz, Germany.

TABLE 1. FEATURES USED FOR MORPHOLOGIC GRADING AND NUMERIC SCORE

	Score Points			
	1	*2*	*3*	*4*
Cytoplasmic differentiation (keratinization)	High (>50% keratinized)	Moderate (20% to 50% keratinized)	Poor (5% to 20% keratinized)	None (<5% keratinzed)
Nuclear differentiation (nuclear polymorphism)	High (>75% mature cells)	Moderate (50% to 75% mature)	Poor (25% to 50% mature)	None (<25% mature)
No. of mitoses per high-power field	Single (0-1)	Moderate number (2-3)	Large number (4-5)	Very numerous (>5)
Mode of invasion	Well-defined borderline	Cords; less marked borderline	Groups of cells; no distinct borderline	Diffuse growth
Stage of invasion (depth)	Possible invasion	Microinvasion (few cords)	Nodular into submucosa	Invasion deeper than submucosa
Plasmalymphocytic infiltration	Marked (continuous rim)	Moderate (many large patches)	Slight (few small patches)	None

Grading was performed only at most invasive zones of tumors (tumor front), as recommended in references 3-5.

with laryngeal carcinoma and evaluate the relationship of these factors to the recurrence-free survival time and to the overall survival.

In order to identify specific tumor factors that are highly predictive of prognosis, we have performed a pilot study of patients with laryngeal carcinomas. Factors suggested to reflect tumor biology that were evaluated include the following.

1. Morphologic tumor front grading, which was proven to be associated with prognosis in squamous cell carcinomas of the oral cavity.[4-6]
2. Quantitative DNA analysis, valuable in both malignancy grading and prognosis of various human malignancies.[7]
3. Analysis of the proliferative cell fraction by identification of the proliferating cell nuclear antigen (PCNA) and Ki67 (MIB I).[8-10]

MATERIALS AND METHODS

For this pilot study, tissue samples from 40 previously untreated patients who underwent surgery for glottic squamous cell carcinoma were examined. Only cases with a follow-up of at least 24 months were included. The examinations included routine histology, quantitative DNA measurements, and morphologic tumor front grading, along with immunohistochemical identification of the proliferation markers Ki67 (MIB I) and PCNA.

Routine Histology and Morphologic Tumor Front Grading. For routine histology, 4-μm paraffin sections were stained with hematoxylin and eosin (H&E) and examined by the pathologist. Tumors were graded according to morphologic differentiation as grade 1 (well differentiated), grade 2 (moderately well differentiated), grade 3 (poorly differentiated), and grade 4 (undifferentiated).[1] The margins of the tumor specimens were assessed on serial sections. Only cases with histologically clear margins were included in the study.

Morphologic tumor front grading was performed on H & E–stained 4-μm sections. This choice was based on several studies performed recently that compared the superficial and central parts of a tumor with the peripheral and most invasive parts. This "tumor front" is in direct contact with the host. We analyzed the following features at the most invasive zones of the tumor (tumor front)[2,3]: 1) cell differentiation, 2) nuclear polymorphism, 3) number of mitoses per high-power field, 4) stage of infiltration, 5) mode of infiltration, and 6) lymphocytic infiltration. These factors were assessed in at least five different regions of the tumor space. Each factor was graded on a scale ranging from 1 through 4, with 1 being mild and 4 being severe. The total morphologic tumor front grading score was computed as the sum of the six parameters, with a maximum score of 24 points. The tumor front grading is detailed in Table 1.[3-5] An example of a tumor front with a dissociated borderline is given in Fig 1A.

Immunohistochemical Detection of Proliferation Markers. Examinations that determine cell cycle can help to identify the proliferative cell fraction within a tumor. The PCNA is a nuclear protein with a molecular weight of 36 kD. It is identical to the DNA-polymerase-δ-auxiliary protein that is essential for DNA synthesis. Thus, PCNA can be used as a proliferation marker.[8,11]

The antibody Ki67 reacts with a nuclear nonhistone protein of 395 and 345 kD, which is present in all active parts of the cell cycle (ie, G1, S, G2, and mitosis) but not in the G0 phase.[10] As a result, this antibody identifies tumor cells that are proliferating.

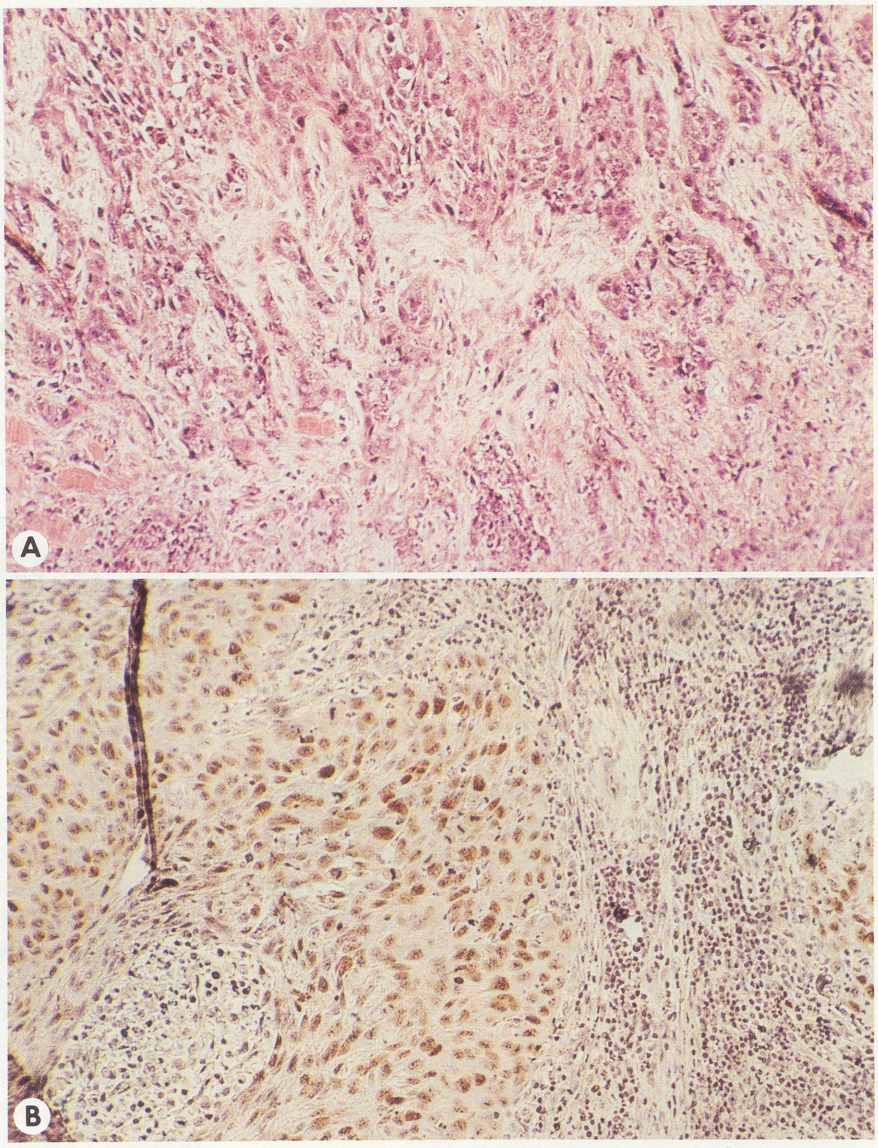

Fig 1. Photomicrographs. A) Tumor with dissociated tumor front with no distinct borderline (H & E, original ×40). B) Immunohistochemical identification of Ki67 (MIB I) at tumor front (original ×200). Immunostained nuclei that express Ki67 (MIB I) antigen show brownish color.

Since 1992, a monoclonal antibody Ki67 (MIB I) has been available that works in paraffin sections by means of a microwave oven process.[12]

For immunostaining with the PCNA antibody, 4-μm sections were cut from the paraffin block, placed onto a poly-L-lysine–coated glass slide, dewaxed in xylene, and then rehydrated in a graded alcohol row. The slides were then incubated with 1% hydrogen peroxide to block the endogeneous peroxidase activity. After washing in phosphate-buffered saline (PBS), the slides were incubated with the PCNA antibody (Ab PC 10, Clone Lane, Oncogene Science, Uniondale, NY) at room temperature for 60 minutes. The slides were then washed again with PBS and stained by the avidin-biotin-peroxidase complex (ABC) method.[13]

Immunohistochemical identification of the Ki67 was performed by means of the monoclonal antibody Ki67 (MIB I; Dianova, Hamburg, Germany). Four-micron slices were cut from the paraffin-embedded tissues and sliced onto a glass slide. After dewaxing in xylene and rehydrating in a graded alcohol row, the slides were placed into a citrate buffer–filled plastic jar and incubated in a microwave oven at 750 W for 5 minutes as described by Shi et al.[14] After microwave incubation the slides were cooled to room temperature and washed in PBS. Endogeneous peroxidase activity was blocked by incubation in 1% hydrogen peroxide. The slides were then incubated with the Ki67 antibody and stained by the ABC method.

Scores were determined microscopically by counting at least 1,000 cells at the tumor front in at least five different regions. The PCNA and Ki67 scores were defined as the percentage of positive nuclei per 1,000 cells (Fig 1B).

TABLE 2. RESULTS OF PCNA AND Ki67 SCORES IN RELATION TO T STAGE IN ALL TUMORS (N = 40)

	PCNA Score (% ± 1 SD)	*Ki67 Score (% ± 1 SD)*
T1	29.3 ± 17.3 (range, 12.6-77.0)	25.7 ± 14.2 (range, 14.4-69.4)
T2	26.8 ± 7.2 (range, 18.3-39.3)	27.1 ± 10.2 (range, 18.0-50.8)
T3	31.9 ± 7.3 (range, 20.1-44.2)	29.9 ± 7.7 (range, 14.2-41.1)
T4	37.1 ± 2.9 (range, 33.1-39.5)	39.1 ± 9.2 (range, 29.6-51.3)

PCNA — proliferating cell nuclear antigen.

Quantitative DNA Analysis. Fifty-micron sections were cut from the paraffin blocks, dewaxed with xylene, and rehydrated in a graded alcohol row. To achieve cell separation, the material was incubated with 0.05% pronase, washed in PBS, filtered through a mesh (pore size of 105 μm), and centrifuged onto glass slides (3,000 rpm, 10 minutes) as described elsewhere.[15,16] The nuclear DNA was stained with fuchsin–sulfuric acid according to the technique of Feulgen. Quantitative DNA analysis was then performed with a computerized image analysis system (Cytometer CM 1, Hund Cie, Wetzlar, Germany). At least 300 tumor cells were measured at random after identification on the video screen. Additionally, a minimum of 30 lymphocytes were measured in the same smear to determine the individual 2c peak. The following indices were determined from the single cell measurements.

1. The mean DNA content of the tumor cells.
2. The 2c deviation index (2c DI), defined as the mean square deviation from the diploid value.[17]
3. The 5c exceeding rate, defined as the percentage of tumor cells with an aneuploid DNA content exceeding 5c.
4. The entropy of the DNA distribution in the tumor.
5. The DNA malignancy grade (DNA MG).

Statistical Analysis. Statistical analysis was performed with a computer program (SAS 6.04, SAS Institute, Inc, Cary, NC). The univariate Cox regression analysis was performed to demonstrate the prognostic significance of specific parameters. The multivariate Cox regression analysis with forward selection was used to determine which factors had the strongest prognostic significance. Only p values of $<.05$ were regarded as significant. Living disease-free patients (and patients who died of unrelated causes) were included in the regression analysis as "censored" observations.

RESULTS

Specimens from 40 patients with laryngeal carcinomas (36 men, 4 women, with an average age of 54.3 years and a range of 40 to 73 years) were examined. All patients had glottic or transglottic tumors, with stages I through IV represented. Lymph node metastases in the neck were evident by clinical palpation and/or ultrasonography in 11 patients. All patients underwent surgery, with 5 cases receiving postoperative irradiation. The average follow-up time was 37.5 months (range, 24 to 60 months).

Invasive squamous cell carcinoma was confirmed histologically in all cases. All margins in each case were free of tumor as determined by frozen section pathology. Four patients had a well-differentiated carcinoma (grade 1), 28 patients had a moderately well-differentiated tumor (grade 2), and 8 patients had a poorly differentiated squamous cell carcinoma (grade 3). Undifferentiated carcinoma (grade 4) was not observed. Lymph node metastases were histologically confirmed in 10 patients: 8 had one or two positive nodes and 2 patients had three or more positive nodes. Extracapsular spread was described in 3 cases.

Morphologic tumor front grading revealed an average score of 11.3 points in T1 tumors (range, 7.8 to 18.4), 12.7 points in T2 tumors (range, 9.9 to 16.0), 14.3 points in T3 tumors (range, 12.6 to 18.2), and 15.4 points in T4 tumors (range, 13.3 to 17.2). The differences between the tumor front grading in T1 and T4 lesions were statistically significant ($p = .04$, Wilcoxon), probably because of a frequent lower score for the feature "stage and depth of invasion" in the T1 lesions. No significant differences were found between T2 and T3, T2 and T4, or T3 and T4 tumors, respectively.

The results of the Ki67 and PCNA scores relative to tumor stage are detailed in Table 2. The T4 tumors demonstrated higher values for the proliferative cell fraction. The differences between PCNA and Ki67 scores in T4 and T1 tumors were significant. No significance was found when PCNA and Ki67 scores of T1, T2, and T3 tumors were compared.

Ten patients developed tumor recurrences: 7 in the neck and 3 at the primary site. The time between initial treatment and recurrence averaged 13.8 months (range, 6 to 23 months). Prior to the treatment of these 10 patients, 2 patients had T1 tumors, 3 patients each had T2 and T3 tumors, and 2 patients had carcinoma staged as T4. Of the 10 recurrences, 8 patients died of disease, with an average survival time of 21.4 months (range, 12 to 30 months) from the first diagnosis of cancer. These patients included the 7 with neck

TABLE 3. RESULTS OF UNIVARIATE REGRESSION ANALYSIS OF CLINICAL AND BIOLOGIC FACTORS RELATED TO TUMOR RECURRENCE AND SURVIVAL (N = 40)

	Recurrence		*Survival*	
	χ^2	*p*	χ^2	*p*
T stage	1.9088	.1671	1.5587	.2118
N stage	4.0603	.0510	3.6932	.0546
Broders grading	0.0297	.9186	0.0561	.8127
Histologic node status	7.6067	.0058	7.8490	.0051
No. of infiltrative nodes	4.4730	.0344	3.4410	.0636
Tumor front grade	16.2446	.0001	14.4119	.0001
Ki67 score	20.6259	.0001	16.7743	.0001
PCNA score	13.7094	.0002	10.3729	.0013
Mean DNA content	12.8817	.0003	11.2747	.0008
2c Deviation index	17.3648	.0001	14.9982	.0001
5c Exceeding rate	18.3868	.0001	14.9408	.0001
Entropy	10.8875	.0010	6.6249	.0101
DNA malignancy grade	13.7732	.0002	11.5699	.0007

Follow-up time averaged 37.5 mo (range, 24 to 60 mo).

recurrences and 1 with recurrence at the primary site. This last patient had a partial laryngectomy at the initial operation, with no treatment to the neck. After recurrence the patient underwent a total laryngectomy and irradiation, but had developed distant metastases. Of the other 7 deaths (all those with neck recurrences), 6 had undergone neck dissection on the side of recurrence, and 4 had also received postoperative irradiation as part of the initial treatment. Lymph node metastases had been histologically confirmed in all 6 of these specimens, with extracapsular spread evident in 2. One patient had not received neck treatment, having had a negative neck to both palpation and ultrasound, but did receive both a neck dissection and postoperative irradiation after the recurrence. The 2 patients who survived their recurrences had received a partial cordectomy and partial vertical laryngectomy, respectively. These 2 patients had recurrences at the primary site and were treated with total laryngectomy and radiotherapy; they are well, 12 months and 33 months after treatment for the recurrent tumor.

In the analysis of tumor front grading, proliferation markers, and quantitative DNA measurements in tumors with and without recurrence, significant differences were found between both groups. Tumors that recurred showed significantly higher values for all markers examined, regardless of the tumor stage and the Broders grading. For example, the Ki67 and PCNA scores for all carcinomas considered together averaged 30.4 and 31.2, respectively. When the scores of the tumors that recurred are considered, these values were found to be 46.1 and 41.3, respectively. Similar differences are evident if T stages are individually compared. Additionally, the Ki67, PCNA, and tumor front grading scores, along with the 2c DI and DNA MG, in the recurrent T1 tumors were as high as in the recurrent T3 and T4 tumors.

Univariate regression analysis was performed for the biologic and clinical markers tested with respect to clinical outcome (Table 3). No correlation between recurrence and survival rates was found for the Broders grading and tumor stage. In contrast, close correlations were found for DNA MG, 2c DI, 5c exceeding rate, tumor front grading, Ki67, and PCNA scores. Significant differences were also found for the number of and the presence of pathologically confirmed metastatic lymph nodes.

The data were further subjected to multivariate

TABLE 4. RESULTS OF MULTIVARIATE COX REGRESSION ANALYSIS WITH FORWARD SELECTION TO DETERMINE FACTORS WITH SIGNIFICANT IMPACT ON SURVIVAL AND RECURRENCE

		χ^2	*p*
Survival	PCNA score	10.9186	.0010
	Tumor front grade	7.0288	.0080
	2c Deviation index	14.9983	.0003
	DNA malignancy grade	5.8352	.0100
Recurrence	Ki67 score	32.8008	.0001
	DNA malignancy grade	7.4986	.0062
	Tumor front grade	4.8181	.0282

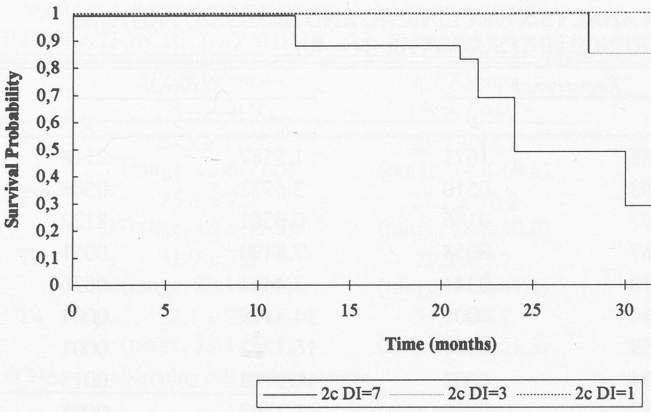

Fig 2. Example of probability plot based on results of stepwise multivariate Cox regression analysis with forward selection. Risk of tumor recurrence or survival probability can be extrapolated for particular factor such as 2c deviation index (DI). Probability for survival in patient with tumor with 2c DI of 1 after 30 months is 100%, but only 30% in patient with tumor with 2c DI of 7.

analysis using the stepwise Cox regression with forward selection. Only the most significant factors were included in the analysis. Factors that were highly associated with recurrent disease included Ki67, DNA MG, and tumor front grading. On the other hand, survival was best predicted by 2c DI, DNA MG, PCNA score, and tumor front grading (Table 4). Other clinical and histopathologic factors demonstrating prognostic significance in the univariate analysis did not reveal the significance level of .05 when entered into the multivariate model.

On the basis of this analysis, model probability plots for both survival rates and recurrence could be created. Figure 2 is an example of this "estimation probability plot" for different values of the 2c DI. Similar plots were generated for the other significant factors for both survival and the probability of recurrence.

DISCUSSION

Factors relevant to prognosis of laryngeal carcinomas are tumor stage, tumor site, nodal status, and therapeutic procedures employed. Of these, nodal status (ie, number of infiltrated nodes, extracapsular spread) has been shown to be the most important traditional prognostic factor in laryngeal cancer.[18-20] Tumor biologic factors or host-related factors, however, both of which probably play the most important role in determining the eventual disease outcome, have not usually been taken into consideration. Another problem of retrospective survival studies is that they often deal with a heterogeneous population of tumors, and a variety of therapeutic strategies influenced by clinical judgment.[21,22]

In the present pilot study we have examined factors that might reflect tumor biology and correlated the results to the survival and recurrence rate of patients with glottic carcinomas. All tumors were surgically removed and all had histologically clear margins. By analyzing tumor biology, we found great differences between tumors of equal stage. Factors that correlated significantly with prognosis were tumor front grading, 2c DI, DNA MG, and Ki67 score. All of these factors reflect tumor biology. No correlation with prognosis was found for the morphologic Broders grading.

The tumor front grading provides multifactorial morphologic information about tumor biology and host-related factors. Cell differentiation, nuclear polymorphism, and number of mitoses are directly related to the biology of the tumor cells. The stage and mode of invasion indicate tumor aggressiveness. Lymphocytic infiltration might be related to the immunologic defense of the host.[2-4,6] The high correlation between this grading system and survival in laryngeal cancer is in accordance with the results of tumor front grading in squamous cell carcinomas of other sites, including the oral cavity and tongue.[3,6] These results suggest that prognosis is determined by the biology of the cells at the most invasive zone of the tumor (tumor front), which often are less differentiated than the cells in the superficial parts of the tumor. One must grade the tumor front at multiple sites to assess tumor heterogeneity accurately.

Additional important prognostic factors were identified by the analysis of the proliferative cell fraction at the tumor front with proliferation markers Ki67 and PCNA. These scores are a measure of proliferation rate and tumor progression. No correlation was found in our study between the proliferation rate and tumor stage; however, all recurrent tumors showed high proliferation scores, suggesting that the proliferation rate is a better indicator of tumor aggressiveness than tumor stage.[23]

DNA analysis has been shown to be related to prognosis in squamous cell carcinomas of different head and neck sites such as the oral cavity and cervical esophagus.[24-26] Whether this analysis predicts the outcome in laryngeal carcinomas is a subject of controversy. Franzen et al[27] did not identify any

correlation between ploidy status and survival in irradiated small glottic carcinomas. Similarly, it was found that ploidy status did not reveal any additional information about prognosis when compared to morphologic malignancy score and nodal status in a multivariate analysis.[19] Others could not find any correlation between DNA analysis and survival rates or recurrence rates based on flow cytometry in supraglottic cancer.[20] On the other hand, Crissman and Fu[28] and Crissman and Zarbo[29] found that the progression of squamous intraepithelial neoplasia to invasive carcinoma correlated closely with DNA measurements based on image analysis. In other studies, similar relationships were identified between DNA distribution and survival rates,[30-34] response rates to chemotherapy, and potential for tumor metastasis.[35-37]

Discrepancies in the results of DNA analysis regarding prognosis in squamous cell carcinomas of the larynx might be due to differences in the techniques employed to determine DNA content. In some studies, flow cytometry was used for determining the ploidy status of the tumors.[19,20] Advantages of this technique include the ability to evaluate a large number of cells rapidly and to accurately define the stem line. The primary disadvantages are that one cannot control for the morphologic variation of the analyzed cells and that single aneuploid cells may be hidden in a wide G0-G1 peak. These cells are probably of prognostic significance and cannot be resolved by flow cytometry.[38]

In the present study, DNA measurements were made by image analysis. Cytologic smears are prepared by cell separation from paraffin-embedded tumor specimens. Cells remain undisturbed in this process, with whole nuclei present for evaluation. The system employs a computer and a color monitor in addition to the microscope. This permits the additional advantage of morphologic control, in that the examiner can visualize each nucleus to be evaluated prior to data acquisition.

The data with the greatest correlation to prognosis were the 2c DI and the DNA malignancy grade. Of interest, this correlation is independent of T stage. All recurrent tumors had a high 2c DI, as well as an increased DNA MG in the original primary. Given that these DNA data reflect tumor heterogeneity, support is offered for the theory that genetic heterogeneity and aneuploidy increase the chance that a particular tumor will recur. Analysis of this kind provides objective and reproducible results independent of individual morphologic interpretation.[7]

Because this is a pilot study with a low number of patients having variable tumor stages, these results are only preliminary. Nevertheless, we demonstrated that the tumor biologic factors Ki67, PCNA, tumor front grading, and quantitative DNA analysis have a strong correlation to prognosis in patients with laryngeal carcinomas. According to the multivariate Cox hazards proportional model, these factors had a stronger correlation to prognosis than any other clinical or histologic parameter, including nodal status. When the tumor biologic parameters were included in the multivariate model, neither nodal status nor the number of histologically infiltrated nodes demonstrated a significant correlation to prognosis.

By using multivariate analysis in this pilot study, it was possible to create a system in which the probability of tumor recurrence in a particular patient could be predicted. All tests in this study were performed on operative specimens, but it is possible to do these examinations on material from deep preoperative biopsies. The test battery is easy to perform in equipped laboratories, and the results can be available in 2 days. Should these parameters remain highly significant in studies of large numbers, then this system might influence the selection of treatment options and could eventually lead to more appropriate and individualized therapy.

ACKNOWLEDGMENTS — The authors thank Gertrud Wolf from the Tumor Research Laboratories at the Department of Otorhinolaryngology, University Hospital, Mainz, for processing the slides, and Stefan Wellek, PhD, and Doris Lautz from the Institute for Medical Documentation and Statistics, University of Mainz, for their excellent assistance in the statistical analysis.

REFERENCES

1. Broders AC. Carcinoma of the mouth: types and degrees of malignancy. Am J Roentgenol Radium Ther Nucl Med 1927;17: 90-103.

2. Anneroth G, Hansen LS, Silverman S. Malignancy grading in oral squamous cell carcinoma. I. Squamous cell carcinoma of the tongue and floor of mouth: histologic grading in the clinical evaluation. J Oral Pathol 1986;15:162-8.

3. Bryne M, Koppang HS, Lilleng R, Stene T, Bang G, Dabelsteen E. New malignancy grading is a better prognostic indicator than Broders' grading in oral squamous cell carcinomas. J Oral Pathol Med 1989;18:432-7.

4. Lund C, Sogaard O, Elbrond K, Joergensen K, Andersen AP. Epidermoid carcinoma of the tongue. Histologic grading in the clinical evaluation. Acta Radiol Ther Phys Biol 1975;14:513-21.

5. Jacobsson PA, Eneroth CM, Killander D, Moberger G, Martenson B. Histologic classification and grading of malignancy in squamous cell carcinoma of the larynx (a pilot study). Acta Radiol Ther Phys Biol 1973;12:1-8.

6. Bryne M. Prognostic value of various molecular and cellular features in oral squamous cell carcinomas: a review. J Oral Pathol Med 1991;20:413-20.

7. Boecking A. DNA-cytometry and automation in clinical diagnosis. Verh Dtsch Ges Pathol 1990;74:176-85.

8. Waseem NH, Lane DP. Monoclonal antibody analysis of the proliferating cell nuclear antigen (PCNA). Structural conservation and the detection of a nucleolar form. J Cell Sci 1990;96: 121-9.

9. Hall PA, Levison DA, Woods AL, et al. Proliferating cell nuclear antigen (PCNA) immunolocalization in paraffin sections: an index of cell proliferation with evidence of deregulated expression in some neoplasms. J Pathol 1990;162:285-94.

10. Gerdes J. Ki67 and other proliferation markers useful for immunohistological diagnostic and prognostic evaluations in human malignancies. In: Osborn M, ed. Cancer biology. Vol 1. London, England: Saunders Scientific Publications, 1990:99-206.

11. Bravo R, MacDonald-Bravo H. Existence of two populations of cyclin/proliferating cell nuclear antigen during the cell cycle: association with DNA replication sites. J Cell Biol 1987;105: 1549-54.

12. Cattoretti G, Becker MHG, Key G, et al. Monoclonal antibodies against recombinant parts of the Ki-67 antigen (MIB1 and MIB3) detect proliferating cells in microwave-processed formalin-fixed paraffin sections. J Pathol 1992;168:357-63.

13. Hsu SM, Raine L, Fanger H. Use of avidin-biotin-peroxidase complex (ABC) in immunoperoxidase techniques: a comparison between ABC and unlabeled antibody (PAP) procedures. J Histochem Cytochem 1981;29:577-80.

14. Shi SR, Key ME, Kalra K. Antigen retrieval in formalin-fixed, paraffin-embedded tissues: an enhancement method for immunohistochemical staining based on microwave oven heating of tissue sections. J Histochem Cytochem 1991;39:741-8.

15. Delgado R, Mikuz G, Hostaetter F. DNA-Feulgen cytophotometric analysis of single cells isolated from paraffin embedded tissue. Pathol Res Pract 1984;179:92-4.

16. Hedley DW, Friedlander ML, Taylor IW. Application of DNA flow cytometry to paraffin-embedded archival material for the study of aneuploidy and its clinical significance. Cytometry 1985;6:327-33.

17. Boecking A, Adler CP, Common HH, Hilgarth M, Granzen B, Auffermann W. Algorithm for a DNA-photocytometric diagnosis and grading of malignancy. Anal Quant Cytol Histol 1984; 6:1-8.

18. Snow GB, Patel P, Leemans CR, Tiwari R. Management of cervical lymph nodes in patients with head and neck cancer. Eur Arch Otorhinolaryngol 1992;249:187-94.

19. Zätterström UK, Wennerberg J, Ewers SB, Willen R, Attewell R. Prognostic factors in head and neck cancer: histologic grading, DNA ploidy and nodal status. Head Neck 1991;13: 477-87.

20. Barona de Guzman R, Martorell MA, Basterra J, Armengot M, Montoro A, Montoro J. Analysis of DNA content in supraglottic epidermoid carcinoma. Otolaryngol Head Neck Surg 1993;108: 706-10.

21. Eibrand JD, Elias EG, Suter CM, Gray WC, Didolkar MS. Prognostic factors in squamous cell carcinoma of the larynx. Am J Surg 1989;158:314-7.

22. Pera E, Morena A, Galindo L. Prognostic factors in laryngeal carcinoma. A multifactorial study of 416 cases. Cancer 1986;58:928-34.

23. Lampe HB. DNA analysis of head and neck squamous cell carcinoma by flow cytometry. Laryngoscope 1993;103:637-44.

24. Tytor M, Olofsson J, Ledin T, Brunk U, Klintenberg C. Squamous cell carcinoma of the oral cavity. A review of 176 cases with application of malignancy grading and DNA measurements. Clin Otolaryngol 1990;15:235-51.

25. Holm LE. Cellular DNA amounts of squamous cell carcinomas of the head and neck region in relation to prognosis. Laryngoscope 1982;92:1064-9.

26. Munck-Wikland E, Auer G, Kuylenstierna R, Lindholm J, Rubio C. Image cytometry DNA analysis of invasive squamous cell carcinoma of the esophagus. Anticancer Res 1989;9:545-50.

27. Franzen G, Olofsson J, Klintenberg C, Brunk U. Prognostic value of malignancy grading and DNA measurements in small glottic carcinomas. ORL J Otorhinolaryngol Relat Spec 1987;49: 73-80.

28. Crissman JD, Fu YS. Intraepithelial neoplasia of the larynx. A clinicopathologic study of six cases with DNA analysis. Arch Otolaryngol Head Neck Surg 1986;112:522-8.

29. Crissman JD, Zarbo RJ. Quantitation of DNA ploidy in squamous intraepithelial neoplasia of the laryngeal glottis. Arch Otolaryngol Head Neck Surg 1991;117:182-8.

30. Kaplan AS, Caldarelli DD, Chacho MS, et al. Retrospective DNA analysis of head and neck squamous cell carcinoma. Arch Otolaryngol Head Neck Surg 1986;112:1159-62.

31. Kokal WA, Gardine RL, Sheibani K, et al. Tumor DNA content as a prognostic indicator in squamous cell carcinoma of the head and neck region. Am J Surg 1988;156:276-80.

32. Boecking A, Auffermann W, Vogel H, Schloendorff G, Goebbels R. Diagnosis and grading of malignancy in squamous epithelial lesions of the larynx with DNA cytophotometry. Cancer 1985;56:1600-4.

33. Rua S, Comino A, Fruttero A, et al. Relationship between histologic features, DNA flow cytometry, and clinical behavior of squamous cell carcinomas of the larynx. Cancer 1991;67:141-8.

34. Truelson JM, Fisher SG, Beals TE, McClatchy KD, Wolf GT. DNA content and histologic growth pattern correlate with prognosis in patients with advanced squamous cell carcinoma of the larynx. Cancer 1992;70:56-62.

35. Gregg CM, Beals TE, McClatchy KM, Fisher SG, Wolf GT. DNA content and tumor response to induction chemotherapy in patients with advanced laryngeal squamous cell carcinoma. Otolaryngol Head Neck Surg 1993;108:731-7.

36. Welkoborsky H-J, Mann WJ, Gluckman JL, Freije JE. Comparison of quantitative DNA measurements and cytomorphology in squamous cell carcinomas of the upper aerodigestive tract with and without lymph node metastases. Ann Otol Rhinol Laryngol 1993;102:52-7.

37. Wolf GT, Fisher SG, Truelson JM, Beals TE. DNA content and regional metastases in patients with advanced laryngeal squamous carcinoma. Laryngoscope 1994;104:479-83.

38. McFadden PW, Clowry LJ, Daehnert K, Hause LL, Koethe SM. Image analysis confirmation of DNA aneuploidy in flow cytometric DNA distributions having a wide coefficient of variation of the G0/G1 peak. Am J Clin Pathol 1990;93:637-42.

CORDECTOMY VERSUS ARYTENOIDECTOMY IN THE MANAGEMENT OF BILATERAL VOCAL CORD PARALYSIS

HANS E. ECKEL, MD
COLOGNE, GERMANY

MONIKA THUMFART
COLOGNE, GERMANY

KLAUS WASSERMANN, MD
COLOGNE, GERMANY

MARTIN VÖSSING, MD
COLOGNE, GERMANY

WALTER F. THUMFART, MD
INNSBRUCK, AUSTRIA

Our objective was to assess the effectiveness of transoral laser cordectomy and laser arytenoidectomy and to compare the results with a view to respiratory and phonatory function and deglutition. Twenty-eight patients with bilateral vocal cord paralysis were included in a prospective study. Eighteen patients had cordectomy, and 10, arytenoidectomy. Lung function tests and voice analysis were performed preoperatively and postoperatively. Subclinical aspiration was determined by endoscopic evaluation of the larynx during deglutition. The results were compared to determine the relative effectiveness of both surgical methods. Flow volume spirograms documented equally improved flow rates in both groups. The final voice evaluation revealed that maximum phonation time, peak sound pressure levels, and frequency range were reduced in all 28 patients, but the phonatory results varied considerably in each group. Subclinical aspiration was noticed in 5 of 10 patients after arytenoidectomy, but in none of 18 patients after cordectomy. Four of 6 previously tracheostomized patients were decannulated within 2 weeks after surgery, while the other 22 patients had no perioperative tracheostomies. We conclude that transoral laser cordectomy and arytenoidectomy are equally effective and reliable in the management of the restricted airway. Phonatory outcome is not predictable with either surgical procedure. Cordectomy is easier and faster to perform, and subclinical aspiration is not encountered with this procedure.

KEY WORDS — arytenoidectomy, cordectomy, larynx, laser, paralysis, vocal cord.

INTRODUCTION

Bilateral vocal cord paralysis is a potentially life-threatening condition that frequently requires some kind of surgical intervention to prevent acute asphyxiation or chronic central airway obstruction.

Thornell,[1] in 1948, was the first to describe an endolaryngeal procedure, namely endolaryngeal arytenoidectomy, for the treatment of laryngeal airway stenosis caused by bilateral vocal cord abductor paralysis. Kleinsasser and Nolte[2] and Kleinsasser[3] combined microlaryngoscopic arytenoidectomy and submucous partial cordectomy. Although excellent results were reported for both methods,[2,4] these techniques have obviously not found wider acceptance, probably because they are technically difficult. Besides, both procedures require routine tracheostomy and therefore cannot be considered to be pure endoscopic interventions. Extralaryngeal vocal cord lateralization as described by Woodman,[5] therefore, remained the standard procedure for the surgical treatment of bilateral vocal cord paralysis, until the carbon dioxide surgical laser was introduced into endolaryngeal management of this condition by the experimental work of Eskew and Bailey[6] in 1983 and the first clinical application by Ossoff et al[7] in 1984. Both studies demonstrated that arytenoidectomy could be carried out with less bleeding and better visualization of the surgical field when the surgical laser was used to ablate the arytenoid cartilage. Further experience revealed that routine tracheostomy prior to laser arytenoidectomy is not an essential prerequisite for this procedure.[8] Laser arytenoidectomy, therefore, is now a truly endoscopic procedure, without the need to perform open surgery.[9]

A more recent approach to the endoscopic restoration of an adequate airway in patients suffering from bilateral vocal cord paralysis is endolaryngeal laser cordectomy without arytenoidectomy. Laser cordectomy is now frequently used for the treatment of early vocal cord carcinoma,[10] and has become a commonly used microlaryngoscopic intervention. Lately, it has repeatedly been recommended for the treatment of bilateral vocal cord paralysis,[11,12] but no information on the comparative value of this procedure for the restoration of an adequate airway in patients with bilateral recurrent nerve paralysis is so far available.

From the Department of Otorhinolaryngology (Eckel, M. Thumfart, Vössing) and Medical Department III (Wassermann), University of Cologne, Cologne, Germany, and the Department of Otorhinolaryngology, University of Innsbruck, Innsbruck, Austria (W. F. Thumfart).

Presented at the meeting of the American Laryngological Association, Palm Beach, Florida, May 7-8, 1994.

REPRINTS — Hans E. Eckel, MD, Univ-HNO-Klinik, Joseph Stelzmann Str 9, D-50924 Koeln, Germany.

TABLE 1. PATIENT CHARACTERISTICS

	Group A (Cordectomy)	*Group B (Arytenoidectomy)*
No. of patients	18	10
Age (y)	42-84 (mean, 56)	35-72 (mean, 59)
Sex	Female 13, male 5	Female 8, male 2
Duration of paralysis (mo)	1-54 (mean, 7)	6-42 (mean, 11)
No. of patients with indwelling tracheostomies	4	2
Cause of paralysis	Thyroid surgery in 17, esophagus surgery in 1	Thyroid surgery in all

The objective of this study was to assess the effectiveness of transoral laser cordectomy and laser arytenoidectomy and to compare the results with a view to respiratory and phonatory function and deglutition.

PATIENTS AND METHODS

Patients. Thirty-six patients with bilateral vocal cord paralysis were included in a prospective study and operated on to improve their laryngeal airways. The diagnosis of bilateral vocal cord paralysis was confirmed electromyographically for all patients prior to treatment.[13] Patients were selected randomly for two different surgical procedures, ie, cordectomy (group A) or arytenoidectomy (group B). One of these patients (in group A) died 2 months after surgery of progressive thyroid cancer. Seven patients did not present for follow-up examinations (4 from group A, 3 from group B), and their fate is unknown. Twenty-eight patients were fully eligible for preoperative and postoperative evaluation and constitute the subject of this investigation. Eighteen of them had cordectomy, and 10 had arytenoidectomy. Patient characteristics are given in Table 1.

Surgical Technique. All procedures were carried out with a Heracure surgical carbon dioxide laser (Heracure LS 500, Heraeus Company, Hanau, Germany) coupled to an operating microscope with a 400-mm–objective lens. The laser was set to an output power of 4 W in the superpulse mode at a spot size of approximately 0.8 mm^2. All patients were intubated transorally for surgery except for those who had preexisting tracheostomies.

Cordectomies included transection of the vocal process of the arytenoid cartilage, followed by the resection of the vocal ligament, the vocalis muscle, and much of the lateral thyroarytenoid muscle. The very anterior portion of the vocal cord, however, was not included in the resection, since its removal would have contributed little to the desired airway enlargement.

Arytenoidectomies were performed according to Kleinsasser's[3] technique except for the use of the laser instead of conventional microlaryngoscopic instrumentation. Simultaneous submucous cordectomy, as advocated by Kleinsasser, was not performed in patients undergoing arytenoidectomy. Care was taken to transect the conus elasticus completely from the vocalis process of the arytenoid down to the inner surface of the cricoid cartilage in both procedures, ie, cordectomy and arytenoidectomy.

All patients received 250 mg of methylprednisolone sodium succinate intravenously during the intervention, and 80 mg orally of the same drug during the first 3 to 4 days after surgery. Extubation was performed 30 to 60 minutes after the end of the intervention, and patients were observed for 4 to 24 hours in an intensive care unit after extubation. Patients were usually kept in the hospital for 7 days after surgery.

Preoperative and Postoperative Evaluation. Lung function tests and a voice analysis were performed preoperatively and 6 to 12 months postoperatively. To determine the improvement in respiration, peak expiratory flow (PEF) and total airway resistance (R_{tot}) were recorded at Medical Department III, University of Cologne. Voice analysis included registration of maximum phonation time (MPT), peak sound pressure levels (PSP), and phonational frequency range (PFR). The MPT was evaluated by asking patients to sustain the vowel /a/ as long and steadily as possible. The PSP was measured with an integrating impulse sound level meter (type 2226, Brüel & Kjaer, Naerum, Denmark) at a distance of 30 cm from the patients' lips. The PFR was measured by determining the highest and lowest frequencies the patient could sing. The range between the highest and lowest tones sung was determined by the number of halftones sung by the patient on the equal-tempered musical scale. A PFR value of zero was attributed to patients presenting with aphonia. Subclinical aspiration was determined by flexible transnasal endoscopic evaluation of the larynx during deglutition of diluted methylene blue.

Remaining tracheostomies and eventually performed revision surgery were also noted.

Statistical Methods. The results of lung function tests and voice analysis of both groups were summa-

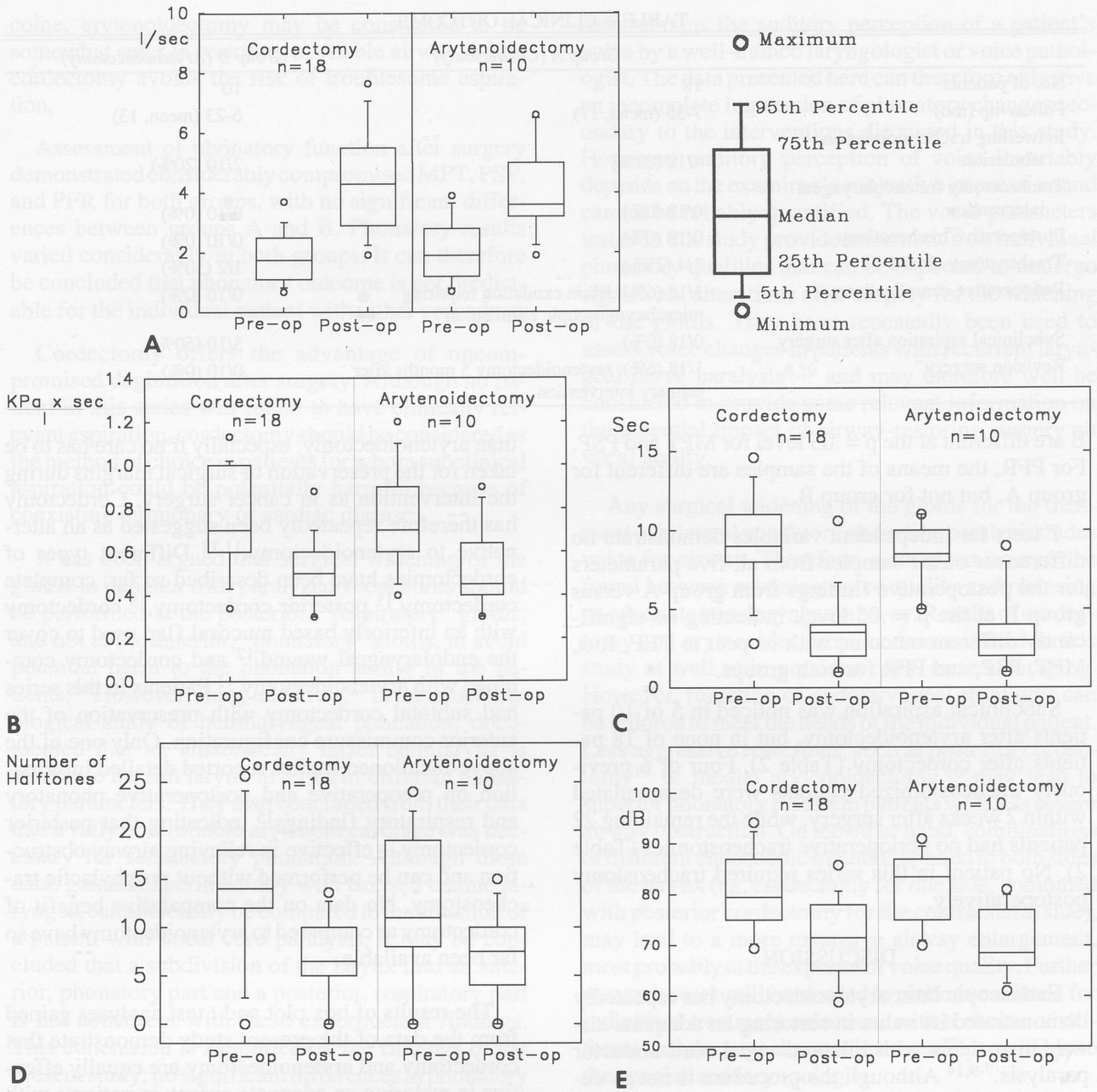

Box plots summarizing data for 28 patients with bilateral recurrent laryngeal nerve paralysis, before and after cordectomy or arytenoidectomy. A) Peak expiratory flow. B) Total airway resistance. C) Maximum phonation time. D) Phonational frequency range. E) Peak sound pressure level.

rized in box plots with Jandel's Sigma Plot software for IBM-compatible personal computers and compared to determine the relative effectiveness of both surgical methods. *T* tests for paired samples were conducted to determine whether differences in preoperative and postoperative results for PEF, Rtot, MPT, PSP, and PFR were significant at the p = .05 level. *T* tests for independent variables were conducted to determine whether the results of the above-mentioned respiratory and phonatory variables were significantly different at the p = .05 level for groups A and B, respectively.

RESULTS

Body plethysmography and flow volume spirograms documented equally improved PEF and Rtot rates in both groups (see Figure; A,B). The means of the preoperative and postoperative samples for PEF and Rtot from groups A and B are different at the p = .05 level, indicating significant airway enlargement in both groups. Final voice evaluation revealed MPT, PSP, and PFR were considerably reduced in all 28 patients, but phonatory results varied greatly in each group (see Figure; C-E). The means of the preoperative and postoperative samples from groups A and

TABLE 2. CLINICAL OUTCOME

	Group A (Cordectomy)	*Group B (Arytenoidectomy)*
No. of patients	18	10
Follow-up (mo)	7-35 (mean, 17)	6-23 (mean, 13)
Indwelling tracheostomies on admission	4/18 (22%)	2/10 (20%)
Tracheostomy for endolaryngeal intervention	0/18 (0%)	0/10 (0%)
Postoperative tracheostomy	0/18 (0%)	0/10 (0%)
Tracheostomy closed	3/4 (75%)	1/2 (50%)
Perioperative complications	1/18 (6%), fibrin exudation requiring microlaryngoscopic elimination	0/10 (0%)
Subclinical aspiration after surgery	0/18 (0%)	5/10 (50%)
Revision surgery	1/18 (6%), arytenoidectomy 5 months after primary intervention	0/10 (0%)

B are different at the p = .05 level for MPT and PSP. For PFR, the means of the samples are different for group A, but not for group B.

T tests for independent variables demonstrate no differences of the samples from all five parameters for the postoperative findings from group A versus group B at the p = .05 level, indicating no significantly different outcome with respect to PEF, Rtot, MPT, PSP, and PFR for both groups.

Subclinical aspiration was noticed in 5 of 10 patients after arytenoidectomy, but in none of 18 patients after cordectomy (Table 2). Four of 6 previously tracheostomized patients were decannulated within 2 weeks after surgery, while the remaining 22 patients had no perioperative tracheostomies (Table 2). No patient in this series required tracheostomy postoperatively.

DISCUSSION

Endoscopic laser arytenoidectomy has repeatedly demonstrated its value in restoring an adequate airway in patients with bilateral vocal cord abductor paralysis.[7-9,14] Although the procedure is not as demanding technically as conventional microlaryngoscopic arytenoidectomy, it remains a challenge to the laryngologist, especially if the intervention is to be performed in the absence of preoperative tracheostomy. Complete excision of the arytenoid cartilage is especially difficult because of the invariably poor visualization of the muscularis process, and troublesome bleeding from the inferior laryngeal artery. Vaporization of the arytenoid may be somewhat easier to perform, but is still far from being a minor endoscopic intervention.

Endoscopic laser cordectomy has recently been demonstrated to be a convenient method for the treatment of early vocal cord carcinoma.[9] In the authors' experience, it is faster and easier to perform than arytenoidectomy, especially if no care has to be taken for the preservation of surgical margins during the intervention as in cancer surgery. Cordectomy has therefore repeatedly been suggested as an alternative to arytenoidectomy.[11,12] Different types of cordectomies have been described so far: complete cordectomy,[11] posterior cordectomy,[15] cordectomy with an inferiorly based mucosal flap used to cover the endolaryngeal wound,[12] and cordectomy combined with arytenoidectomy.[11] Patients in this series had subtotal cordectomy with preservation of the anterior commissure configuration. Only one of the above-mentioned studies reported detailed information on preoperative and postoperative phonatory and respiratory findings[15] indicating that posterior cordectomy is effective in relieving airway obstruction and can be performed without prophylactic tracheostomy. No data on the comparative benefit of cordectomy as compared to arytenoidectomy have so far been available.

The results of box plot and *t* test analyses gained from the data of the present study demonstrate that cordectomy and arytenoidectomy are equally effective in restoring an adequate airway in patients with bilateral vocal cord abductor paralysis. However, 2 patients in the cordectomy group required surgical revision. One was a patient who had obstructing fibrinous exudations removed from the cordectomy wound microlaryngoscopically 4 days after initial surgery. The further healing process was uncomplicated, and final respiratory and phonatory results were satisfactory. Another patient needed additional arytenoidectomy 5 months after initial cordectomy because of an unsatisfactory respiratory result. No patient in group B needed further surgery during the follow-up period. Arytenoidectomy, as expected, led to a substantial (50%) rate of subclinical aspiration, while no patient with cordectomy was affected by this disorder. Therefore, as judged by clinical out-

come, arytenoidectomy may be considered to be somewhat safer in restoring a reliable airway, while cordectomy avoids the risk of troublesome aspiration.

Assessment of phonatory function after surgery demonstrated considerably compromised MPT, PSP, and PFR for both groups, with no significant differences between groups A and B. Phonatory results varied considerably in both groups. It can therefore be concluded that phonatory outcome is not predictable for the individual patient with either procedure.

Cordectomy offers the advantage of uncompromised deglutition after surgery. Although no patient in this series was found to have clinically relevant aspiration, cordectomy should be considered as the method of choice in patients for whom subclinical aspiration could be potentially harmful because of coexisting pulmonary or cardiac disease.

It has been argued that surgical widening of the glottis in patients with paralyzed vocal cords should be performed at the posterior, "respiratory" glottis, and not at the anterior, "phonatory" glottis, to avoid potential harm to the phonation ability of the patients.[16] However, Jiang and Titze,[17] in their methodological study of hemilaryngeal phonation, documented that an anatomically intact hemilarynx is similar to the full larynx in terms of different phonatory parameters. They also concluded from their data that a fully controllable arytenoid cartilage was necessary for satisfactory phonation. Although these data, gained experimentally with excised canine larynges, cannot readily be compared to the situation of a patient with vocal cord paralysis, it may be concluded that a subdivision of the larynx into an anterior, phonatory part and a posterior, respiratory part is not consistent with these experimental findings. This conclusion is supported by the findings of the present study: no significant differences in phonatory outcome as determined by MPT, PSP, and PFR could be found between groups A and B. Besides, morphometric measurements conducted to determine the dimensions of laryngeal cross-sectional areas demonstrate that cordectomy potentially offers more enlargement of the glottic airway (169 ± 20 mm^2 in males and 138 ± 22 mm^2 in females) than arytenoidectomy (42 ± 12 mm^2 in males and 34 ± 6 mm^2 in females).[18] Therefore, the concept of an anterior, phonatory glottis as opposed to a posterior, respiratory glottis should be reconsidered for patients with bilateral vocal cord abductor paralysis.

A comprehensive assessment of voice quality cannot be performed by measuring individual phonatory parameters. The gold standard of voice assessment to date remains the auditory perception of a patient's voice by a well-trained laryngologist or voice pathologist. The data presented here can therefore only give an incomplete impression of phonatory changes secondary to the interventions discussed in this study. However, auditory perception of voice invariably depends on the examiner's subjective impression and cannot be reliably quantified. The vocal parameters tested in this study provide information on individual phonatory qualities that can be expected to undergo significant alterations after surgery for the widening of the glottis. They have repeatedly been used to assess voice changes in patients with recurrent laryngeal nerve paralysis[8,19] and may therefore well be considered to provide some relevant information on the potential impact of airway-restoring surgery on vocal ability.

Any surgical widening of the glottis for the treatment of bilateral vocal cord abduction paralysis trades voice for airway. Therefore, a compromise must be found between retaining voice quality and restoring an adequate translaryngeal airway. Results of cordectomy and arytenoidectomy, as demonstrated in this study as well as in previous ones, are encouraging. However, resection of endolaryngeal structures can be tailored to meet the needs of the individual patient. Less aggressive resections, such as posterior cordectomy[15] or medial arytenoidectomy,[16] may lead to superior phonatory results in patients with less severe airway obstruction. On the other hand, combinations of different endoscopic methods applied to both sides of the larynx (eg, cordectomy for one side, combined with posterior cordectomy for the contralateral side), may lead to a more extensive airway enlargement, most probably at the expense of voice quality. Further research work will be needed to elaborate criteria for individual treatment selection, with a choice of different endolaryngeal procedures readily available to the specialized laryngologist.

CONCLUSION

Transoral laser cordectomy and arytenoidectomy are equally effective and reliable in the management of the restricted airway. No significant difference between these minimally invasive procedures was found in terms of respiratory and functional results. Preoperative tracheostomies are not required for either intervention.

Completely normal values for phonational and respiratory parameters are not achieved with either method, since airway widening in patients with bilateral vocal cord abductor paralysis to date must con-

tinue to establish a tolerable compromise between airway and voice. Phonatory outcome is not predictable with either surgical procedure.

Cordectomy is easier and faster to perform, and subclinical aspiration is not encountered with this procedure.

REFERENCES

1. Thornell WC. Intralaryngeal approach for arytenoidectomy in bilateral abductor paralysis of the vocal cords. A preliminary report. Arch Otolaryngol 1948;47:505-8.

2. Kleinsasser O, Nolte E. Report on the indication, technique and functional results of endolaryngeal arytenoidectomy and submucous partial cordectomy in bilateral paralysis of the vocal cord. Laryngol Rhinol Otol (Stuttg) 1981;60:397-401.

3. Kleinsasser O. Microlaryngoscopy and endolaryngeal microsurgery. 3rd ed. London, England: Mosby–Year Book Europe, 1992.

4. Whicker JH, Devine KD. Long-term results of Thornell arytenoidectomy in the surgical treatment of bilateral vocal cord paralysis. Laryngoscope 1972;82:1331-6.

5. Woodman D. A modification of the extralaryngeal approach to arytenoidectomy for bilateral abductor paralysis. Arch Otolaryngol 1946;43:63-5.

6. Eskew JR, Bailey BJ. Laser arytenoidectomy for bilateral vocal cord paralysis. Otolaryngol Head Neck Surg 1983;91:294-8.

7. Ossoff RH, Sisson GA, Duncavage JA, Moselle HI, Andrews PE, McMillan WG. Endoscopic laser arytenoidectomy for the treatment of bilateral vocal cord paralysis. Laryngoscope 1984;94:1293-7.

8. Ossoff RH, Duncavage JA, Shapshay SM, Krespi YP, Sisson GA Sr. Endoscopic laser arytenoidectomy revisited. Ann Otol Rhinol Laryngol 1990;99:764-71.

9. Steiner W, Aurbach G, Ambrosch P. Minimally invasive therapy in otorhinolaryngology and head and neck surgery. Minim Invas Ther 1991;1:57-70.

10. Bailey BJ. Early glottic carcinoma. In: Bailey BJ, ed. Head and neck surgery–otolaryngology. Vol 2. Philadelphia, Pa: JB Lippincott, 1993:1313-33.

11. Holm AF, Wouters B, Van Overbeek JJM. CO2 laser cordectomy for bilateral vocal cord paralysis. Lasers Med Sci 1989;4:93-6.

12. Eckel HE. Microlaryngoscopic laser vocal fold lateralization for the treatment of bilateral vocal fold paralysis — technique and results. Laryngol Rhinol Otol (Stuttg) 1991;70:17-20.

13. Thumfart WF. Electromyography of the larynx and related techniques. Acta Otorhinolaryngol Belg 1986;40:358-76.

14. Lim RY. Laser arytenoidectomy. Arch Otolaryngol 1985; 111:262-3.

15. Dennis DP, Kashima H. Carbon dioxide laser posterior cordectomy for treatment of bilateral vocal cord paralysis. Ann Otol Rhinol Laryngol 1989;98:930-4.

16. Crumley RL. Endoscopic laser medial arytenoidectomy for airway management in bilateral laryngeal paralysis. Ann Otol Rhinol Laryngol 1993;102:81-4.

17. Jiang JJ, Titze IR. A methodological study of hemilaryngeal phonation. Laryngoscope 1993;103:872-82.

18. Eckel HE, Sittel C. Morphometry of the glottis: an anatomical basis for airway restoring procedures in bilateral recurrent nerve paralysis. Laryngol Rhinol Otol (Stuttg) 1994;73:417-22.

19. Woo P, Colton R, Brewer D, Casper J. Functional staging for vocal cord paralysis. Otolaryngol Head Neck Surg 1991;105: 440-8.

JEJUNAL GRAFT RECONSTRUCTION OF PHARYNGOESOPHAGEAL DEFECTS WITHOUT MICROVASCULAR ANASTOMOSES

WILLIAM R. PANJE, MD HUGH E. HETHERINGTON, MD

CHICAGO, ILLINOIS

The purpose of this article is to describe transplantation of jejunal grafts without microvascular anastomoses for reconstruction of the pharynx and/or upper esophagus following oncologic resections. Even though use of free flaps including jejunum, a method that requires revascularization, continues to offer superior results in pharyngoesophageal reconstruction, the technique described in this article provides a readily available alternative. This timesaving technique is particularly useful if the surgeon encounters intraoperative complications related to either the microvascular anastomoses or to an unstable patient. The principal advantages of jejunal graft reconstruction include the absence of a need for microvascular anastomoses, a decreased operating time, a one-stage operation, and the replacement of pharyngoesophageal mucosa with like tissue. The disadvantages include the need for laparotomy, the requirement for a well-vascularized tissue bed, delayed wound healing, the need for stenting, and delayed initiation of oral intake.

KEY WORDS — esophageal reconstruction, jejunal graft, microvascular anastomosis, pharyngeal reconstruction.

INTRODUCTION

Pharyngoesophageal reconstruction remains a challenging and controversial surgical problem.[1] Reconstructive goals include preserving adequate deglutition and phonation while preventing aspiration. A single-stage procedure is ideal, since it minimizes hospitalization and rehabilitation. Surgical therapy for many is only palliative; thus, preserving the remaining quality of life is paramount.[2]

A number of different surgical alternatives exist for reconstruction of the pharyngoesophagus.[3] These procedures include the Wookey operation, skin grafts, deltopectoral and various myocutaneous flaps, gastric pull-up, colon interposition, and, more recently, microvascular free flaps, including free jejunal grafts (FJGs) with microvascular anastomoses. (An FJG is a jejunal segment including a mesenteric vascular pedicle that is frequently used in pharyngoesophageal reconstruction and requires microvascular anastomoses. A jejunal graft [JG] is a partial-thickness jejunal segment without any vascular pedicle or serosa that is transplanted without a vascular supply.) The microsurgical transplantation of small intestine has increasingly become more popular for one-stage pharyngeal and/or upper esophageal reconstruction. Low morbidity, reduced hospital stays, and excellent functional results are possible with this technique. Major impediments to the successful use of free jejunal reconstruction are microvascular anastomoses, infection, and prolonged operating time.[4]

Previous experimental results as well as personal experience reveal that in select cases of pharyngoesophageal reconstruction, jejunal transplantation without microvascular anastomoses is possible. This article describes 7 cases of successful immediate reconstruction of the pharynx and/or upper esophagus using a JG without microvascular anastomoses.

MATERIALS AND METHODS

Seven patients underwent reconstruction of pharyngoesophageal defects utilizing JGs. All had resection of malignancies involving the hypopharynx and/or cervical esophagus. Two patients had preoperative irradiation of the pharynx and neck areas.

The JG was harvested from the abdomen by standard bowel resection techniques. Mesentery, fat, and any vessels were removed from the bowel. The jejunal serosa was scraped off the intestinal segment with a knife blade. This process also removed some of the muscular coat. Attempts to separate the muscular coat from the mucosa were unrewarding. The JG was split longitudinally and cut to the approximate size of the defect in 5 cases. Two cases required a circumferential jejunal segment. The JG was then sutured into place by a two-layered (mucosa and muscle) closure technique. The graft was carefully secured to underlying healthy muscle or other well-vascularized tissue, with care taken to obliterate any dead space between the graft and the recipient bed (Figs 1 and 2). In some cases the pharynx and/or cervical esophagus JG was held in place with a silicone salivary bypass tube until the completion of wound healing. All wounds were passively drained with rubber tubes. Cervical pressure bandages were maintained until

From the Department of Otolaryngology and Bronchoesophagology, Rush–Presbyterian–St Luke's Medical Center, Chicago, Illinois.

Presented at the meeting of the American Laryngological Association, Palm Beach, Florida, May 7-8, 1994.

REPRINTS — William R. Panje, MD, 1725 W Harrison St, Suite 340, Chicago, IL 60612.

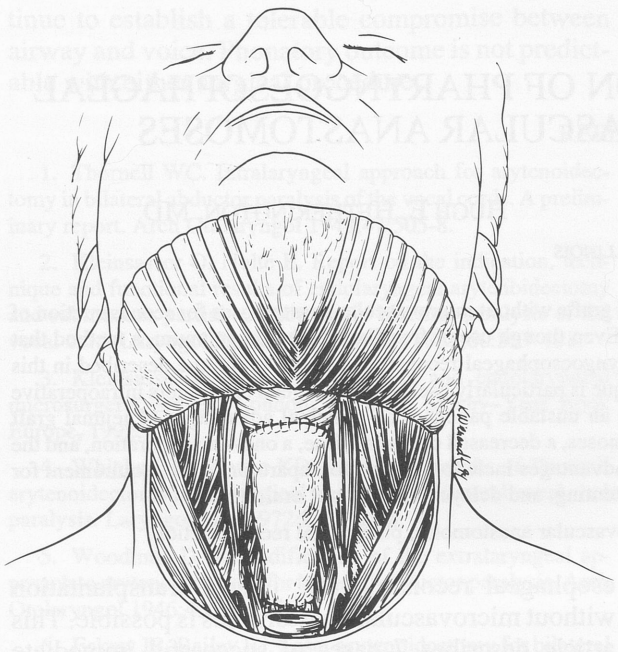

Fig 1. Pharyngoesophageal defect with jejunal graft in place.

neck drainage ceased: usually 5 to 12 days. All patients received broad-spectrum antibiotics until completion of wound healing. A feeding jejunostomy and a gastric feeding tube were also placed. Feedings were initially begun through the jejunostomy. The jejunostomy catheter was removed when gastrostomy feedings were deemed appropriate. The gastrostomy feedings were continued until the neck and pharynx wounds were completely healed: usually 3 to 4 weeks following the operation. Oropharyngeal motility studies and esophagrams were obtained in each patient prior to beginning oral deglutition.

RESULTS

All 7 patients had JG reconstruction of the pharynx and/or esophagus (see Table). Two patients had circumferential replacement of the pharyngoesophageal segment. There were no apparent graft failures. Three patients had delayed wound healing as evidenced by prolonged cervical drainage. Two patients developed fistuli at 9 and 10 days postoperatively. Two patients with large hemipharyngeal repairs that extended into the esophageal opening developed strictures. A single esophageal dilation in each patient corrected the problem, although persistent dysphagia continued in 1 senile patient with severe xerostomia. Cineesophagrams eventually revealed intact pharyngoesophageal segments in all patients. All of the JGs demonstrated a smooth surface on barium swallow study. This is in contrast to free jejunal transplantation, in which radiographic contrast studies reveal numerous circular folds and peristalsis. Aspiration has not been a problem in any of the patients.

DISCUSSION

There are experimental as well as anecdotal clinical accounts supporting the transplantation of gastrointestinal mucosa grafts without a blood supply. Doolin,[5] as early as 1915, successfully implanted free gastric mucous membrane autografts into dog spleens and noted persistence of the muscularis mucosa. Herbsman et al,[6] in 1957, building on Doolin's prior work, published their results on the experimental transplantation of free intestinal mucous membrane grafts. They found the grafts could survive transplantation to the mucosa-stripped oral cavity and urinary bladder of the dog. Unstented intestinal mucous membrane grafts contracted similarly to intraoral skin grafts. Of additional interest was the finding that normal bladder and oral cavity epithelium overgrows transplanted intestinal mucous membrane. They felt the absence of an intact blood supply for the first few days following transplantation might be an important factor in the susceptibility of the graft to overgrowth by surrounding epithelium. Subsequent biopsies (greater than 4 months following transplantation) of the JGs from 3 patients in this report revealed stratified squamous epithelium with some mucous glands similar to that of the oral cavity and laryngeal epithelium. Two of these patients had prior irradiation to the

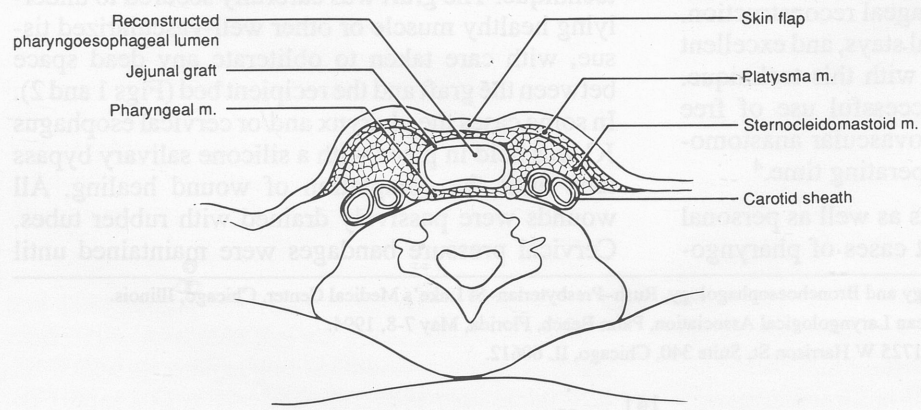

Fig 2. Cross section of pharyngoesophageal reconstruction with jejunal graft in place. Note close approximation of jejunal graft to underlying vascularized tissue bed.

SUMMARY OF PATIENTS UNDERGOING JEJUNAL GRAFT RECONSTRUCTION OF PHARYNGOESOPHAGUS

Age	*Diagnosis*	*Stage*	*Location*	*XRT*	*Status*	*Complications*	*Procedure*	*Follow-up (mo)*
59	Squamous cell carcinoma	T3N2b	Right pyriform sinus	None	NED	Fistula at 9 d (spontaneously closed)	Partial pharyngectomy and ipsilateral neck dissection	96
54	Squamous cell carcinoma	T4N2b	Larynx and pyriform sinus (circumferential)	Preop	DOD	Wound drainage (12 d)	Total laryngopharyngectomy, bilateral neck dissections, and pectoralis myocutaneous flap	14
61	Squamous cell carcinoma	T4N1	Larynx and pyriform sinus (circumferential)	Postop	NED	Wound drainage (6 d)	Total laryngopharyngectomy, mediastinectomy, and bilateral neck dissections	47
57	Squamous cell carcinoma	T2N2	Posterior pharyngeal wall	Postop	NED	Wound drainage (12 d)	Pharyngectomy, cervical esophagectomy, and modified neck dissection	30
73	Squamous cell carcinoma	T2N2	Lateral pharyngeal wall	Postop	AWD	Stricture (resolved with dilation), persistent dysphagia	Partial pharyngectomy and ipsilateral neck dissection	18
36	Hurthle cell carcinoma	T4N0M0	Partial cervical esophagus and hemipharynx	Postop	DOD	Fistula at 10 d (spontaneously closed), stricture at 1 mo (resolved with dilation)	Total thyroidectomy, cervical esophagectomy, and partial pharyngectomy	12
63	Squamous cell carcinoma	T4N0	Left pyriform sinus with pharyngocutaneous fistula	Preop	Lost to follow-up	None	Partial pharyngectomy and pectoral flap	14

XRT — radiotherapy, NED — no evidence of disease, DOD — dead of disease, AWD — alive with disease.

biopsy areas.

The environment of the intestinal graft transplant appears to have an effect on its regenerative capacity. Lippman and Longmire[7] transplanted jejunal mucosa-submucosa autografts to mucosa-stripped stomachs of dogs. They noted early necrosis of the superficial epithelium with subsequent regeneration from the basal layers of the graft. The study of Oesch et al[8] of esophageal reconstruction with JGs, completed in 1980, histologically demonstrated near-total replacement of intestinal mucosa by esophageal squamous epithelium.

On the basis of the prior conclusive work of Maguire et al[9] showing that small bowel mucosa would anatomically survive after grafting, Neumann et al[10] in 1959 examined the functional capacity of intestinal mucosa grafts. Examining the uptake of a glucose solution by the grafts, these investigators concluded that free grafts of ileal mucosa retain an appreciable degree of their original absorbing function. This report suggests that despite the inherent clinical and histologic changes associated with grafting of intestine into a different environment, the principal elements of a moist mucosal appearance, as well as maintenance of some of its original function, remain following transplantation without microvascular anastomoses.

Seidenberg et al[11] in 1959 reported the successful immediate reconstruction of the cervical esophagus by a revascularized isolated jejunal segment. This landmark report opened a new era in the reconstruction of pharyngoesophageal defects. Large quantities of tissue could be readily transplanted with the full expectation that the transplant would retain the structure and function of its origin. The usual problems with graft contracture and changes in graft characteristics seen when the intestinal graft was transplanted without a blood supply were now hardly a consider-

ation. Attention was directed toward perfecting the microvascular anastomosis and transplanting nearly anything the human body could spare for reconstructing tissue deficiencies.

Research concerning intestinal grafting without microvascular anastomoses became dormant until a report in 1980 by Oesch et al.[8] Their study was prompted by trying to find a method to replace a long segment of esophagus for esophageal atresia or severe stenosis in children. They used JGs without microvascular anastomoses to reconstruct the middle segments of the esophagi of cats. They demonstrated the survival of the full intestinal graft, regardless of length, as long as good contact was maintained between the muscularis coat of the graft and a recipient vascularized tissue bed. Meticulous surgical technique was necessary to ensure adequate contact between the graft and the recipient tissues, since any site at which the graft lacked contact ("dead space") subsequently necrosed. Clinically, in performing JG for pharyngoesophageal defects, the muscularis coat of the small intestine must be in intimate contact with well-vascularized tissues. The intestinal anastomosis to the pharynx and/or esophagus is a "watertight" closure done in an overlapping fashion with muscle or vascularized fascia. Stenting with an intraluminal silicone tube or an antibiotic-impregnated gauze bolster is critical to ensuring adequate donor-recipient site contact and preventing graft contracture. In essence, the mucosal graft should be handled similar to that of an upper aerodigestive tract skin graft reconstruction.[12,13]

Clinically, until this report, only several anecdotal cases of gastrointestinal mucosa graft reconstruction had been described. Maguire et al,[9] in their 1958 experimental paper, described the use of a gastric mucosa graft, similar to the use of a skin graft to repair an abdominal skin defect. Six months later, the 90% contracted graft was excised. Microscopic sections of the graft showed normal gastric mucosa. Stallings et al[14] in 1971 described the use of a full-thickness graft of vaginal mucosa to reconstruct the inside of the upper lip. Biopsy of the intraoral vaginal mucosa graft 10 months later revealed histologic features similar to those of the oral mucosa.

In 1984, while attempting an FJG reconstruction of the pharynx, the senior author (W.R.P.) was confronted with the inability to reestablish an adequate blood supply despite repeated microvascular anastomoses. The operation had stretched to 10 hours. The patient was hypothermic, with a labile blood pressure. Faced with performing another method of pharyngoesophageal reconstruction and prolonging the operation in a deteriorating patient, the author decided to convert the split jejunum into a graft and use it as a split-thickness skin graft. The mesenteric vascular pedicle, serosa, and part of the outer muscular coat of the jejunum were removed. Although the author was hopeful of the JG's taking, the tissue was used primarily as a temporary biologic dressing. Once the patient's condition had stabilized, the plan was either to complete another flap reconstruction of the pharynx or to accept the consequence of a fistula. In anticipation of a fistula, the pharyngeal defect was meticulously separated from the carotid-jugular vessels by an intervening sternocleidomastoid muscle flap. The patient's marginal physical capacity to undergo another general anesthetic did not allow for another operation. A small fistula did develop at 9 days postoperatively, but it spontaneously closed after another 9 days. The graft was observed to remain a pinkish gray color. Approximately 1 month following the JG of the pharynx, the patient began oral feeding. A subsequent radiographic barium contrast study of the pharyngoesophagus was unremarkable for fistula, stenosis, or aspiration. Not until 4 years later, when confronted with a similar set of circumstances, did the author perform another JG procedure, which also was successful. A review of the literature was supportive of continuing JG reconstruction of the pharynx and upper esophagus in select situations.

A JG without microvascular anastomoses is a possible alternative to other currently available methods of reconstruction in *select cases* of limited pharyngoesophageal defects. In this limited series, all patients were unsuitable candidates for FJG reconstruction either because of an inability to establish an adequate blood supply or because of hemodynamic instability requiring a shortened operation time. The advantages of JG include replacement of the pharynx and/or upper esophageal defects with moist mucosa without the need for microvascular anastomoses. A laparotomy and a well-vascularized tissue bed are the principal requirements for this technique. Even though 2 patients in this series had prior irradiation to the neck and pharynx, with extreme caution this technique can be used in such a patient. Irradiation produces capillary fibrosis, reducing recipient bed vascularity.

In every case in this series particular attention was directed toward separating the graft site from the carotid-jugular vessels with vascularized tissue (eg, sternocleidomastoid or pharyngeal musculature). A JG requires meticulous surgical technique to ensure complete contact of the muscularis with recipient vascularized tissues. Passive cervical drainage with a pressure bandage is important for maintaining good contact between the graft and the recipient bed.

Wound drainage commonly persists longer than when a flap is used to repair a pharyngoesophageal defect. Although infection was not a problem in this series, all patients did receive perioperative antibiotics that were continued postoperatively until wound drainage ceased and/or the graft appeared healed. Because of the tenuous nature of these grafts and the need to establish adequate in situ graft vascularity, oral feedings should not commence for at least 3 weeks following the operation. Two of the patients in this series developed delayed fistuli after commencing oral feeding at 10 days following the operation, despite normal-appearing pharyngoesophagrams. Since the JG technique requires a laparotomy and bowel resection, all patients receive a jejunostomy. Nasogastric tubes are unnecessary and are contraindicated. The patient can receive alimentation via the jejunostomy almost immediately after surgery, since this is below the level of the bowel resection and anastomosis. The jejunostomy catheter is removed and gastrostomy feedings are begun once satisfactory healing of the intestinal anastomosis occurs.

Despite the positive results of this series, the authors continue to favor vascularized flap reconstruction of the pharyngoesophagus. Maintenance of gastrointestinal vascularity following transplantation ensures anatomic and functional characteristics inherent to the tissue's original location. Peristalsis of the free intestinal graft remains intact following transplantation. Although the experimental study of Oesch et al[8] demonstrated peristalsis in JGs, our study did not demonstrate graft peristalsis. Unlike revascularized jejunum, the JG quickly loses the circumferential folds and flattens out. This is a relative advantage of the JG as compared to vascularized jejunum, since in the latter, the circumferential folds, at least during the first 6 to 12 months following transplantation, tend to trap and hold food particles that can lead to halitosis. This problem lessens with time as the revascularized jejunum also takes on the appearance of the surrounding tissues. Another distinct advantage of vascularized flap reconstruction of the pharyngoesophagus is the addition of new vascularity to the recipient bed. The advantages to healing and reduced wound complications of vascularized flaps take on added importance in reconstructing previously irradiated wound beds.

Flap reconstruction of the pharyngoesophageal segment tends to have less contracture and/or stricture than do grafts. Several of the experimental reports on gastrointestinal grafting without microvascular anastomoses emphasized graft contracture in the absence of stenting. Only 2 patients in our series had circumferential repair of the pharyngoesophageal segment. Both had a laryngectomy and a salivary bypass tube stent during healing. Neither of these patients had subsequent dysphagia. Two patients with larger pharyngeal defects and retention of the larynx developed pharyngoesophageal segment stricture following split JG repair. Neither of these patients had graft stenting. Both strictures responded to dilation. In 1 patient dysphagia to solids continued, aggravated by severe xerostomia and pharyngeal hypesthesia. Stenting is recommended for all JGs regardless of location or size of the defect.

CONCLUSIONS

1. Jejunal grafting without microvascular anastomoses for reconstruction of pharynx and/or upper esophagus defects is possible in select situations.

2. Jejunal grafting without microvascular anastomoses for reconstruction of the pharyngoesophagus can be helpful, either when microvascular anastomoses cannot be completed or when there is a need to shorten the patient's operating time because of hemodynamic instability.

3. Special technical precautions must be taken with either a graft or a revascularized segment of intestine when repairing the pharynx and/or esophagus.

4. Advantages of the JG without microvascular anastomoses for reconstruction of the pharyngoesophagus include the avoidance of microvascular anastomoses, a reduced operating time, a one-stage operation, a readily available alternative in the event of intraoperative FJG failure, and a resulting thin, flat, moist mucosal tissue similar to the pharyngoesophagus.

5. Disadvantages of the JG without microvascular anastomosis reconstruction of the pharyngoesophagus include the need for a laparotomy, the requirement of a well-vascularized recipient bed, delayed wound healing, the need for stenting, possible fistula formation, delayed initiation of oral intake, and abdominal tube feeding.

REFERENCES

1. McConnel FMS. Rehabilitation of patients with tumors of the pharynx. In: Thawley SE, Panje WR, eds. Comprehensive management of head and neck tumors. Philadelphia, Pa: WB Saunders, 1987:813-57.

2. Kirchner JA. Pyriform sinus cancer: a clinical and laboratory study. Ann Otol Rhinol Laryngol 1975;84:793-803.

3. Surkin MI, Lawson W, Biller HF. Analysis of the methods of pharyngoesophageal reconstruction. Head Neck Surg 1984;6: 953-70.

4. Reece GP, Bengtson BP, Schusterman MA. Reconstruc-

tion of the pharynx and cervical esophagus using free jejunal transfer. Clin Plast Surg 1994;21:125-36.

5. Doolin W. Experiments on the transplantation of gastric mucous membrane. Surg Gynecol Obstet 1915;20:53-9.

6. Herbsman H, Rabson AS, Schatten WE. Experimental transplantation of free grafts of intestinal mucous membrane. Plast Reconstr Surg 1957;20:366-78.

7. Lippman HN, Longmire WP. Studies on the transplantation of free jejunal mucosa-submucosa autografts to the mucosa stripped stomach of the dog. Ann Surg 1954;140:86-92.

8. Oesch I, Helikson MA, Shermeta DW, Hutchins GM, Haller JA. Esophageal reconstruction with free jejunal grafts: an experimental study. J Pediatr Surg 1980;15:433-6.

9. Maguire C, Georgiade N, McWhirt J, Pickrell K. The use gastrointestinal mucous membrane as a replacement for skin — an experimental study. Plast Reconstr Surg 1958;22:139-49.

10. Neumann CG, Richman H, Ardizone RA. A preliminary study of the retention of absorptive function by free grafts of intestinal mucosa. Plast Reconstr Surg 1959;24:596-9.

11. Seidenberg B, Rosenak S, Hurwitt ES, Som ML. Immediate reconstruction of the cervical esophagus by a revascularized isolated jejunal segment. Ann Surg 1959;149:162-71.

12. Schramm VL Jr, Myers EN. Skin graft reconstruction following composite resection. Laryngoscope 1980;90:1737-9.

13. LaFerriere KA, Sessions DG, Thawley SE, Wood BJ, Ogura JH. Composite resection and reconstruction for oral cavity and oropharynx cancer. A functional approach. Arch Otolaryngol 1980;106:103-10.

14. Stallings JO, Gills RE, Sessions DG. Free graft of vaginal mucosa to the mouth. Plast Reconstr Surg 1971;47:498-501.

GENDER DIFFERENCES IN CANCER OF THE LARYNX

MIMI S. KOKOSKA, MD

JAY F. PICCIRILLO, MD BRUCE H. HAUGHEY, MB, CHB

ST LOUIS, MISSOURI

Gender differences in the incidence and mortality rates for cancers of the lung, colon, and larynx have previously been noted. The goal of this project was to identify gender differences in prognostic variables for survival and recurrence for patients with cancer of the larynx. The medical records of 193 patients with cancer of the larynx treated initially between 1973 and 1985 were examined retrospectively. A total of 151 men and 42 women were included. A majority of men developed glottic cancers, whereas a majority of women developed supraglottic cancers. Age was prognostically important for both genders; however, comorbidity, symptom severity, anatomic subsite, and TNM stage all had different impacts on survival and recurrence in men and women. No gender difference in initial treatment was found. This study suggests that when designing and analyzing the results from clinical studies of cancer of the larynx, it is important to employ stratification based on gender.

KEY WORDS — comorbidity, gender, head and neck cancer, prognosis.

INTRODUCTION

Gender differences in the incidence and mortality for patients with cancer of the lung, colon, and larynx have been noted.[1] For example, 61% of lung cancer patients and 79% of larynx cancer patients are men. In colorectal cancer, woman have been found to have a significantly higher incidence of right-sided colon cancer with increasing age.[2] The estimated differential 5-year survival rates based on gender for these cancer sites are as follows: lung (men 9%, women 18%),[3] colorectal (men 21%, women 52%),[4] and larynx (men 57%, women 59%).[5] Hormonal effects,[6] differential use of known cancer-promoting agents such as alcohol and tobacco,[7,8] and sociocultural influences[4,9] have all been suggested as causes for the observed gender differences.

Since the 1950s, the use of tobacco-containing products by women has increased significantly.[1,9] In association with this increased use is the marked increase in incidence of laryngeal and lung cancer over the last three decades.[1,10,11] Finally, sociocultural effects, such as social isolation and a decreased social support network, have been shown to be associated with different survival rates for men and women with chronic diseases.[12]

The goal of this project was to identify gender differences in prognostic variables for survival and recurrence for patients with cancer of the larynx. The identification of gender-specific prognostically significant clinical variables may be used to guide treatment and improve data analysis.

METHODS

POPULATION UNDER STUDY

The patients included in this study were described more completely in a previous study.[13] In brief, the patients were first treated at Yale–New Haven Hospital (YNHH) between January 1, 1973, and December 31, 1985, for a primary carcinoma of the larynx and were identified through the Yale Tumor Registry and diagnostic lists maintained by the Medical Record Department of YNHH. A full 5-year follow-up was obtained for 193 patients.

COLLECTION OF DATA

The data included basic demographic information; a history of symptom type, duration, and severity; a complete anatomic description of the primary tumor; nodal and distant metastatic spread, if known; a summary of other medical conditions; and results of pertinent laboratory and radiographic studies at the start of cancer treatment. The recorded details of therapy, follow-up data, and survival for the post-treatment period were also included.

CLASSIFICATION OF DATA

Symptoms and Symptom Stages. The symptom staging system that was used has been presented previously.[13] Individual patients were classified according to symptom stages (local, perilocal, extralocal, and distant) based on the types of symptoms present.

Anatomic Extensiveness. The boundaries of the three anatomic subsites within the larynx — supraglottic, glottic, and subglottic — were defined by the

From the Department of Otolaryngology–Head and Neck Surgery, Washington University School of Medicine, St Louis, Missouri. Dr Piccirillo is a recipient of the American Cancer Society Junior Clinical Research Award (JCRA No. 1).

Presented at the meeting of the American Laryngological Association, Palm Beach, Florida, May 7-8, 1994.

REPRINTS — Mimi S. Kokoska, MD, Dept of Otolaryngology–Head and Neck Surgery, Washington University School of Medicine, 517 S Euclid Ave, Box 8115, St Louis, MO 63110.

TABLE 1. BASELINE DESCRIPTIONS FOR TOTAL POPULATION

			5-Year Survival		Recurrence	
Variable	*Category*	*Total No.*	*No.*	*%*	*No.*	*%*
Total population		193	127	66	52	27
Gender	Men	151	98	65	40	26
	Women	42	29	69	12	29
Age group	<53	52	42	81*	12	23
	53-67	96	66	69	32	33
	>67	45	19	42	8	18
Race	White	165	110	67	45	27
	African-American	24	14	58	6	25
	Hispanic	3	2	67	1	33
	Other	1	1	100	0	0
Marital status	Single	18	8	44†	4	22
	Married	124	90	73	33	27
	Divorced/separated	13	9	69	4	31
	Widowed	16	7	44	2	13
	Unknown	22	13	59	9	41
Occupational status	None/unemployed	9	7	78	0	0
	Laborer	8	3	38	3	38
	Operatives/semiskilled	47	31	66	15	32
	Clerical/skilled	58	37	64	19	33
	Professional/manager	33	24	73	5	15
	Homemaker	5	3	60	2	40
	Unknown	33	22	67	8	25
Prognostic comorbidity	Absent	166	123	74*	45	27
	Present	27	4	15	7	26
Symptom severity	Local	81	65	80*	18	22
	Perilocal	34	26	76	11	32
	Functional	62	30	48	16	26
	Distant	16	6	38	7	44
Site	Supraglottic	88	49	56§	29	33†
	Glottic	97	75	77	19	20
	Subglottic	7	3	43	4	57
TNM stage	I	77	60	78*	15	19
	II	48	32	67	17	35
	III	45	27	60	11	24
	IV	23	8	35	9	39
Histologic grade	CIS and CIS with microinvasion	13	10	77	2	15
	Well	79	55	70	20	25
	Moderate	35	22	63	11	31
	Poor	22	10	45	9	41
	Verrucous/anaplastic	5	3	60	2	40
	Unknown	39	27	69	8	21
Initial treatment	Irradiation alone	102	74	73†	30	29
	Surgery alone	43	29	67	11	26
	Combined	41	22	54	9	22
	Other	4	2	50	2	50
	None	3	0	0	0	0

CIS — carcinoma in situ.
*p < .001.
†p < .05.
§p < .01.

American Joint Committee on Cancer[14] 1988 TNM criteria.

Prognostic Comorbidity. Associated diseases, which are usually nonneoplastic and not related to the

TABLE 2. INCIDENCE OF LARYNGEAL SUBSITE INVOLVEMENT BY GENDER

	Subsite		
Gender	*Glottic*	*Supraglottic*	*Total*
Men	86	62	148
Women	14	26	40
Total	100	88	188

Four patients had subglottic involvement (3 men, 1 woman). One patient had unknown subsite.
$\chi^2 = 6.75$, $p < .01$.

index cancer, are called comorbidities. They have been found[15] to have important effects on prognosis and treatment. In this study we use the term prognostic comorbidity for concomitant ailments that could significantly reduce the patient's prognostic anticipations for life. Such ailments would be classified as grade 3 (severe organ decompensation) in the Kaplan-Feinstein classification system.[16]

FOLLOW-UP

Each patient's posttreatment course was extracted and coded to cite whatever clinical (death), anatomic (recurrence and new primary cancer), and therapeutic (subsequent therapy) changes had occurred.

OUTCOME

Information on tumor recurrence and tumor status at death (or last follow-up) was extracted. Five-year observed survival rate was selected as the primary outcome measure because it is a standard measure in prognostic studies of patients with cancer.

DATA ANALYSIS

After all medical record data were transferred to coding forms, the computerized data entry was done by a professional data management company and subjected to double entry and verification. Sorting, tabulation, and statistical analysis, including multivariable analyses, was done with the Statistical Analysis Software system, from the SAS Institute Inc, Cary, NC.

RESULTS

TOTAL POPULATION

In Table 1, the baseline description of the total population is shown along with the 5-year survival and recurrence rates. Survival was significantly related to age ($\chi^2 = 16.67$, $p = .0001$), marital status ($\chi^2 = 10.51$, $p = .038$), comorbidity ($\chi^2 = 36.27$, $p = .001$), symptom severity ($\chi^2 = 23.28$, $p = .0001$), anatomic subsite ($\chi^2 = 11.41$, $p = .003$), TNM stage ($\chi^2 = 15.55$, $p = .001$), and type of initial treatment ($\chi^2 = 13.24$, $p = .039$). Recurrence was only related to anatomic subsite ($\chi^2 = 7.5$, $p = .024$). In Table 2, the gender difference in the incidence of glottic and supraglottic cancers is shown. Men were significantly more likely to develop glottic cancer, while women were more likely to develop supraglottic cancer ($\chi^2 = 6.75$, $p = .0094$).

MEN ONLY

In Table 3, the 5-year survival and recurrence rates are shown for men only. The significant variables for survival include age ($\chi^2 = 8.90$, $p = .012$), comorbidity ($\chi^2 = 33.94$, $p = .0001$), symptom severity ($\chi^2 = 14.16$, $p = .003$), anatomic subsite ($\chi^2 = 12.86$, $p = .002$), TNM stage ($\chi^2 = 14.19$, $p = .003$), and type of initial treatment received ($\chi^2 = 14.14$, $p = .028$). No variable was identified that was significantly associated with the development of recurrence.

WOMEN ONLY

The survival and recurrence rates for the 42 women in this study are shown in Table 4. Survival was significantly related to age ($\chi^2 = 11.00$, $p = .004$), marital status ($\chi^2 = 10.43$, $p = .034$), comorbidity ($\chi^2 = 4.6$, $p = .032$), and symptom severity ($\chi^2 = 11.40$, $p = .01$). Recurrence was only related to TNM stage ($\chi^2 = 9.2$, $p = .027$).

MULTIVARIABLE ANALYSIS

In order to evaluate the relative prognostic impact of each of the significant variables, a multivariable analysis was performed.

Survival Rate. In Table 5, the multivariable analysis for the total population, men only, and women only is shown. For the total population, comorbidity, symptom severity, and age were all independently important. For men, age, comorbidity, anatomic subsite, and TNM stage were important, while only age and symptom severity were important for women.

Recurrence Rate. Since the only variable significantly associated with recurrence was TNM stage (in women) by bivariate analysis, a multivariable analysis was not performed.

DISCUSSION

The results of this study suggest that there may be important gender differences in subsite incidence and prognosis for patients with laryngeal cancer. As in previous studies,[5,17] glottic involvement was more common in men, whereas supraglottic involvement was more frequent in women. While age was equally important as a prognostic factor for both men and women, comorbidity, symptom severity, anatomic subsite, and TNM stage all had different impacts on survival and recurrence in men and women.

There has not been a plausible explanation for this differential gender subsite involvement and prognosis. Sex hormone receptors have been identified in

TABLE 3. BASELINE DESCRIPTIONS FOR MEN ONLY

			5-Year Survival		Recurrence	
Variable	*Category*	*Total No.*	*No.*	*%*	*No.*	*%*
Total population		151	98	65	40	26
Age group	<53	39	30	77*	8	21
	53-67	73	50	68	25	34
	≥67	39	18	46	7	18
Race	White	128	85	66	34	27
	African-American	21	12	57	5	24
	Hispanic	2	1	50	1	50
	Other	0	0	0	0	0
Marital status	Single	15	6	40	4	27
	Married	101	72	71	27	27
	Divorced/separated	9	5	56	3	33
	Widowed	10	6	60	1	10
	Unknown	16	9	56	5	31
Occupational status	None/unemployed	6	4	67	0	0
	Laborer	8	3	38	3	38
	Operatives/semiskilled	37	23	62	12	32
	Clerical/skilled	49	32	65	17	35
	Professional/manager	29	21	72	5	17
	Homemaker	0	0	0	0	0
	Unknown	22	15	68	3	14
Prognostic comorbidity	Absent	132	97	73†	36	27
	Present	19	1	5	4	21
Symptom severity	Local	66	51	77§	13	20
	Perilocal	27	20	74	11	41
	Functional	46	22	48	12	26
	Distant	12	5	42	4	33
Site	Supraglottic	62	32	52§	20	32
	Glottic	83	64	77	17	20
	Subglottic	6	2	33	3	50
TNM stage	I	65	51	78§	14	22
	II	36	23	64	13	36
	III	32	18	56	8	25
	IV	18	6	33	5	28
Histologic grade	CIS and CIS with microinvasion	9	7	78	2	22
	Well	63	43	68	17	27
	Moderate	30	19	63	9	30
	Poor	12	4	33	5	42
	Verrucous/anaplastic	5	3	60	2	40
	Unknown	32	22	69	5	16
Initial treatment	Irradiation alone	78	56	72*	23	29
	Surgery alone	36	25	69	10	28
	Combined	31	16	52	6	19
	Other	3	1	33	1	33
	None	3	0	0	0	0

*$p < .05$.
†$p < .001$.
§$p < .01$.

larynx tissue and other aerodigestive sites.[18,19] A number of in vitro studies have suggested that sex hormones may have a growth regulatory role in cancer of the larynx.[19,20] Whether quantitative hormone receptor subsite differences or menopausal status have prognostic value in cancer of the larynx can only be elucidated by studies that correlate outcome with these variables. The disparities in cancer

TABLE 4. BASELINE DESCRIPTIONS FOR WOMEN ONLY

			5-Year Survival		Recurrence	
Variable	*Category*	*Total No.*	*No.*	*%*	*No.*	*%*
Total population		42	29	69	12	29
Age group	<53	13	12	92*	4	31
	53-67	23	16	70	7	30
	≥67	6	1	17	1	17
Race	White	37	25	68	11	30
	African-American	3	2	67	1	33
	Hispanic	1	1	100	0	0
	Other	1	1	100	0	0
Marital status	Single	3	2	67†	0	0
	Married	23	18	78	6	26
	Divorced/separated	4	4	100	1	25
	Widowed	6	1	17	1	17
	Unknown	6	4	67	4	67
Occupational status	None/unemployed	3	3	100	0	0
	Laborer	0	0	0	0	0
	Operatives/semiskilled	10	8	80	3	30
	Clerical/skilled	9	5	56	2	22
	Professional/manager	4	3	75	0	0
	Homemaker	5	3	60	2	40
	Unknown	11	7	64	5	45
Prognostic comorbidity	Absent	34	26	76†	9	26
	Present	8	3	38	3	38
Symptom severity	Local	15	14	93*	5	33
	Perilocal	7	6	86	0	0
	Functional	16	8	50	4	25
	Distant	4	1	25	3	75
Site	Supraglottic	26	17	65	9	35
	Glottic	14	11	79	2	14
	Subglottic	1	1	100	1	100
	Unknown	1	0	0	0	0
TNM stage	I	12	9	75	1	8†
	II	12	9	75	4	33
	III	13	9	69	3	23
	IV	5	2	40	4	80
Histologic grade	CIS and CIS with microinvasion	4	3	75	0	0
	Well	16	12	75	3	19
	Moderate	5	3	60	2	40
	Poor	10	6	60	4	40
	Verrucous/anaplastic	0	0	0	0	0
	Unknown	7	5	71	3	43
Initial treatment	Irradiation alone	24	18	75	7	29
	Surgery alone	7	4	57	1	14
	Combined	10	6	60	3	30
	Other	1	1	100	1	100
	None	0	0	0	0	0

*$p < .01$.
†$p < .05$.

incidence and 5-year survival for different racial and socioeconomic groups have been shown to reflect sociocultural differences, as well as income and education level.[1,9] And finally, regardless of the reasons for the observed gender differences, gender may influence cancer screening and therapy.

We have examined 5-year survival and recurrence

TABLE 5. MULTIVARIABLE ANALYSIS

	5-Year Survival								
	Arrangement 1 (Total Population)			*Arrangement 2 (Men Only)*			*Arrangement 3 (Women Only)*		
Variable	χ^2	*p*	*Rank*	χ^2	*p*	*Rank*	χ^2	*p*	*Rank*
Gender	2.12	.14	5	Not included			Not included		
Age group	9.27	.002	3	3.98	.045	4	5.77	.016	2
Marital status	1.38	.24	7	Not included			Not entered		
Prognostic comorbidity	30.18	.000	1	22.41	.000	1	2.72	.099	4
Symptom severity	13.71	.000	2	.87	.352	5	10.14	.001	1
Site	1.80	.18	6	11.18	.001	2	1.96	.161	3
TNM stage	2.73	.10	4	4.48	.034	3	Not included		
Initial treatment	Not entered			Not entered			Not included		

Variables listed as "not included" were not included in analysis. Variables listed as "not entered" were included in analysis but were not entered into final mathematical model because variable did not achieve statistical significance.

rates within groups of men and women as a function of age, comorbidity, symptom severity, TNM stage, anatomic subsite, and several other variables. Prognostic factors appear to be different for men and women with cancer of the larynx. This study suggests that when designing and analyzing the results from clinical studies of cancer of the larynx, it may be important to employ stratification based on gender. In addition, because of the suspected regulatory role of hormones in cancer of the larynx, it would be useful to obtain actual menopausal status (not only age) and hormone therapy history in women in the design of clinical trials. Because these data are derived from a relatively small population and the study is retrospective, the conclusions must be regarded as preliminary.

REFERENCES

1. Boring CC, Squires TS, Tong T. Cancer statistics. CA 1993;43:7-26.

2. Butcher D, Hassanein K, Dudgeon M, Rhodes J, Holmes FF. Female gender is a major determinant of changing subsite distribution of colorectal cancer with age. Cancer 1985;56:714-6.

3. Ferguson MK, Skosey C, Hoffman PC, Golomb HM. Sex-associated differences in presentation and survival in patients with lung cancer. J Clin Oncol 1990;8:1402-7.

4. Petrek JA, Sandberg WA, Bean PK. The role of gender and other factors in the prognosis of young patients with colorectal cancer. Cancer 1985;56:952-5.

5. Stephenson WT, Barnes DE, Holmes FF, Norris CW. Gender influences subsite of origin of laryngeal carcinoma. Arch Otolaryngol Head Neck Surg 1991;117:774-8.

6. Haidoutova R, Melamed M, Dimitrova S, Kyossovska R. Investigations of serum testosterone levels in patients with laryngeal cancers. Arch Otorhinolaryngol 1985;241:213-7.

7. Browson RC, Chang JC, Davis JR. Gender and histologic type variations in smoking-related risk of lung cancer. Epidemiology 1992;3:61-4.

8. Cancer facts and figures — 1991. Atlanta, Ga: American Cancer Society, 1991:1-29.

9. Boring CC, Squires TS, Heath CW. Cancer statistics for African-Americans. CA 1992;42:7-17.

10. Silverberg E, Grant RN. Cancer statistics. CA 1970;20:11-23.

11. Silverberg E. Cancer statistics. CA 1980;30:23-44.

12. Berkman LF, Syme SL. Social networks, host resistance, and mortality: a nine-year follow-up study of Alameda County residents. Am J Epidemiol 1979;109:186-204.

13. Piccirillo JF, Wells CK, Sasaki CT, Feinstein AR. New clinical severity staging system for cancer of the larynx. Five-year survival rates. Ann Otol Rhinol Laryngol 1994;103:83-92.

14. American Joint Committee on Cancer. Manual for staging of cancer. 3rd ed. Philadelphia, Pa: JB Lippincott, 1988.

15. Feinstein AR. The pre-therapeutic classification of co-morbidity in chronic disease. J Chronic Dis 1970;23:455-69.

16. Kaplan M, Feinstein AR. The importance of classifying initial co-morbidity in evaluating the outcome of diabetes mellitus. J Chronic Dis 1974;27:387-404.

17. Robbin KT. Prognostic and therapeutic implications of gender and menopausal status in laryngeal cancer. J Otol 1988; 17:81-5.

18. Sesti G, Marini MA, Briata P, et al. Androgens increase insulin receptors mRNA levels, insulin binding, and insulin responsiveness in HEP-2 larynx carcinoma cells. Mol Cell Endocrinol 1992;86:111-8.

19. Matsuoka H, Sugimachi K, Ueo H, Kuwano H, Nakano S, Nakayama M. Sex hormone response of a newly established squamous cell line derived from clinical esophageal carcinoma. Cancer Res 1987;47:4134-40.

20. Grenman R, Virolainen E, Shapiro A, Carey T. In vitro effects of tamoxifen on um-scc head and neck cancer cell lines: correlation with the estrogen and progesterone receptor content. Int J Cancer 1987;39:77-81.

LARYNGOPLASTIC MEDIALIZATION AND ARYTENOID ADDUCTION: A QUANTITATIVE AND QUALITATIVE ANALYSIS OF VOICE IMPROVEMENT

JAMES L. NETTERVILLE, MD
LIZ LUKEN, CCC, SLP
ED STONE, PHD
WILLIAM B. ARMSTRONG, MD
DAVID HALL
ROBERT H. OSSOFF, DMD, MD
NASHVILLE, TENNESSEE

Although it is quite easy to tell perceptually if a voice is significantly better after therapy, it is difficult to quantify this improvement in a reliable way for result comparisons. In order to try to quantify the voice change seen after phonosurgery, patients were tested both preoperatively and postoperatively with laryngeal function tests, voice recordings, and videostroboscopy. The records of 175 patients who have undergone Silastic medialization (SM) with or without arytenoid adduction (AA) were reviewed. Of this group 102 underwent secondary (2°) SM with or without AA under local anesthesia, 48 underwent primary (1°) SM with or without AA under general anesthesia at the time of sacrifice of laryngeal innervation, and 25 underwent bilateral SM. Maximum phonation time (MPT), mean airflow (MAF), and voice quality scores were used to compare either preoperative voice to postoperative voice or postoperative voice to normal data. In the 2° SM group, the MPT changed from a preoperative median score of 7.8 s to 16.4 s postoperatively ($p = .0001$), while the median MAF changed from 310 mL/s to 123 mL/s ($p = .0001$). There was a significant improvement in voice scores for this group. In the 1° SM group the postoperative median MPT was 14.5 s with a MAF of 157 mL/s. In the bilateral SM group the median MPT improved from 10.96 to 16.5 s, while the MAF improved from 195 to 104 mL/s. The paper will further develop the usefulness of these values in defining the voice improvement seen with SM and AA.

Presented at the meeting of the American Laryngological Association, Palm Beach, Florida, May 7-8, 1994.

PHONATORY SPECIALIZATION OF HUMAN LARYNGEAL MUSCLES

IRA SANDERS, MD
BEI-LIAN WU, MD
HUGH F. BILLER, MD
NEW YORK, NEW YORK

This study examines the possibility of functionally different areas within the human thyroarytenoid (TA) muscle. Ten TA muscles were obtained from human autopsies. The muscles were frozen sectioned and stained for ATPase at pH 4.1. Stained sections were projected onto a grid and the proportions of fast and slow twitch muscle fibers were counted throughout each muscle. It was found that there is a large gradient within the TA muscle, with the medial part of the muscle containing almost twice as many slow twitch muscle fibers as the lateral part. The high proportion of slow twitch muscle fibers is believed to reflect a specialization for phonation in this area. It is proposed that the medial aspect of the TA muscle combines with similar slow twitch areas in other laryngeal muscles to form a functionally distinct phonatory subsystem.

Presented at the meeting of the American Laryngological Association, Palm Beach, Florida, May 7-8, 1994.

COMPARISON OF SOFT TISSUE RESPONSE IN RABBITS FOLLOWING LARYNGEAL IMPLANTATION WITH HYDROXYLAPATITE, SILASTIC, AND TEFLON

PAUL W. FLINT, MD
SANJAY MARWAHA, MD
RITU GOEL, MD
CHARLES W. CUMMINGS, MD
BALTIMORE, MARYLAND

This study evaluates the soft tissue response in rabbits following laryngeal implantation for medialization with hydroxylapatite prostheses, carved Silastic prostheses, and injectable Teflon. Sixteen rabbits underwent left recurrent laryngeal nerve section for denervation and laryngeal implantation with hydroxylapatite. At 1, 3, 6, and 12 months, 4 animals were sacrificed and processed for histology. In similar groups, animals were implanted with carved Silastic prostheses or with Teflon injected through a flap in the thyroid lamina. In animals implanted with hydroxylapatite, histologic findings include absence of acute or chronic inflammatory response, thin fibrous encapsulation, and osteogenesis in the region of the fenestra with lamellar bone bridging the space between the implant and the thyroid lamina. With Silastic prostheses, there is fibrous encapsulation of the implant without evidence of osteogenesis. Animals implanted with Teflon demonstrated classic foreign body reaction with multinucleated giant cells and granuloma formation. With respect to soft tissue response, both hydroxylapatite and Silastic are less reactive than Teflon. The osteogenesis observed in the presence of hydroxylapatite theoretically will result in a more stable implant and minimize the risk of migration. Conversely, the presence of bone growth may limit the reversibility of medialization procedures performed with hydroxylapatite.

Presented at the meeting of the American Laryngological Association, Palm Beach, Florida, May 7-8, 1994.

DISCUSSIONS

DYNAMIC PROPERTIES OF THE POSTERIOR CRICOARYTENOID MUSCLE (p 34)

DONALD S. COOPER, PHD; MAISIE SHINDO, MD; UTTAM SINHA, MD;
MALCOLM H. HAST, PHD; DALE H. RICE, MD

NEUROPEPTIDE PARTICIPATION IN CANINE LARYNGEAL SENSORY INNERVATION. IMMUNOHISTOCHEMISTRY AND RETROGRADE LABELING (p 56)

YASUO HISA, MD; NOBUHISA TADAKI, MD; TOSHIYUKI UNO, MD; HITOSHI OKAMURA, MD;
JUN-ICHI TAGUCHI, MD; YASUHIKO IBATA, MD

CLARENCE T. SASAKI, MD (New Haven, Conn): The authors of the first paper began their project with the hope of reconciling investigator-specific differences within a species. By exercising the scientific method in its most admirable form, they discovered an interesting number of facts that greatly improved the accuracy of their measurements. But more important, they foresee trends, and I stress the word trends, that provide a means of extrapolating across species. When possible, these types of discoveries represent cornerstones of our understanding, because they allow us to generalize results from many sources to establish biologic truth and, in this case, to better understand the human PCA. After all, it was Lewis Thomas who told us that's what biology is all about. As we discover trends that approach the truth, we must ask our investigative colleagues several questions. What plans do you have to derive a mathematical function of PCA contraction properties across species, and what statistical measures will you apply to validate that function? Ultimately, what clinical importance do you attach to the extrapolation of this information to human PCA contraction properties? I wonder if Dr Cooper and his colleagues might comment at this time.

DONALD S. COOPER, PHD (Los Angeles, Calif): The approach that I exemplified for the cricothyroid does lead quite specifically to a quantitate prediction of contraction times. Given the mass of the animal, we can predict the duration of the rest of the voice cycle. I used that to begin with, just because it is closely tied to our original measurement. Given that duration, all we need to know is the slope. The slope, being constant across species, will allow us to make a measurement of the contraction times for a rat. Now, how do we extend this to humans? Primarily through extension of our work by using the measurement of intramuscular fluid pressure. This is a measurement which, at this point, is not but could be used in a human being. We can perceive the miniaturization of these chip masses to a point where they are no larger than, say, an ENG electrode, and would be capable of insertion into the muscle together with the ENG electrode. That would give us the measurement which would allow us to judge the accuracy of the extrapolation.

DR SASAKI: I just wonder if you would tell the audience why this information might be important to them.

DR COOPER: It is of considerable clinical importance, because at this point, if we want to judge the activity of a muscle, we can do so primarily in two ways. One is looking at the movement it generates, using optical information. The movement from that to any decision looking at muscle function is difficult. We can use ENG, but again, ENG gives information about excitation of muscle, not about the mechanical effects. The pressure with relationship to the intramuscular fluid pressure in force is quite close. We can have a measurement which is mechanical, which can be applied in the muscles, that will give us something which is clinically applicable to say, "What did this muscle put out at this point?" and would allow us to look at the effect of the surgical procedure up and down the road. It will allow making repeated measures in research, rather than using a repeat experiment to see the change over time.

DR SASAKI: Thank you, Dr Cooper. It was a pleasure to discuss that particular paper, because I think it is an important contribution to clinicians. It is the kind of research that should bring us all great pride and gratification. The authors of the second paper provide a rather powerful means of localizing site-specific afferent fibers in SLN, but further promise to characterize their specific neurotransmitters. The work has far-reaching impact. For example, our ability to chemically modulate specific laryngeal functions in the treatment of certain disease states. With a basic understanding of laryngeal neurotransmitters, could we one day differentially, for example, up- or down-regulate specific laryngeal behavior by simply writing a drugstore prescription? I am hoping, Dr Hisa, that you would hypothesize how function-specific, rather than site-specific, neurotransmitter identification could provide us this ability. Would you care to comment? You've given us some information about the site-specific identification of these neurotransmitters, that is, from the entire chunk of the superior laryngeal nerve, but I wonder if you might just speculate for a moment and tell us how function-specific labeling of these fibers might be helpful to us in the future?

YASUO HISA, MD (Kyoto, Japan): In answer to your question, I think there are more transmitters.

THREE-DIMENSIONAL IMAGING OF THE HYPOPHARYNX AND LARYNX BY MEANS OF HELICAL (SPIRAL) COMPUTED TOMOGRAPHY. COMPARISON OF RADIOLOGICAL AND OTOLARYNGOLOGICAL EVALUATION (p 49)

PAUL M. SILVERMAN, MD; ANDREW S. ZEIBERG, MD; ROY B. SESSIONS, MD; THOMAS R. TROOST, MD; ROBERT K. ZEMAN, MD

POSITRON EMISSION TOMOGRAPHY IN THE EVALUATION OF LARYNGEAL CARCINOMA (p 60)

W. FREDERICK MCGUIRT, MD; KATHRYN M. GREVEN, MD; JOHN W. KEYES, JR, MD; DANIEL W. WILLIAMS III, MD; NAT E. WATSON, JR, MD; KIM R. GEISINGER, MD; JAMES O. CAPPELLARI, MD

WILLIAM R. HUDSON, MD (Durham, NC): As opposed to some other organ systems, the larynx is accessible to direct and indirect examination. No imaging technology is as specific or sensitive as one's hands and eyes in primary tumor evaluation. In the paper by McGuirt, two key observations are made. One, imaging with CT, MRI, or PET is not as sensitive or specific as clinical direct and indirect examination in primary laryngeal tumor evaluation. And number two, CT, MRI, and PET were slightly superior to the clinical examination in nodal disease. Imaging may help in divining tumor extent and cartilage invasion, but the great majority of our therapeutic decisions in primary laryngeal disease are based on clinical examination. Dr McGuirt and his colleagues have confirmed the inadequacy of PET in the pretreatment evaluation of primary tumors of the larynx and its questionable value in the evaluation of nodal disease. The paper documents the value of PET in posttreatment patients for recurrent or residual disease. His findings are similar to our experience at Duke. Of the 15 posttreatment patients at risk, 13 were correctly differentiated by PET. What is not clear to me from the paper is the number of those who were positive and the number of PET-negative. One false negative was noted, identified after laryngectomy as having a small focus of tumor. I would appreciate Dr McGuirt's commenting on the following questions. How many of the 13 patients correctly differentiated by PET had tumor? How many were negative? What would be your criteria in obtaining a posttreatment PET, and given a negative PET in a suspicious patient, would you feel comfortable in conservative management without a biopsy? On the contrary, given a positive PET, would you feel comfortable in performing a laryngectomy without a positive biopsy? Would you please comment?

W. FREDERICK MCGUIRT, MD (Winston-Salem, NC): Of the 13, 5 were radionecrosis patients without tumor. The others had residual cancer, and that's the way they worked out. As far as observations in this relationship, I still am hesitant to do that. I think the advantage of PET in at least 2 of these cases we have shown here is the end result of progressive biopsies, and oftentimes these people come in fairly early with lesions and radionecrosis that can be managed conservatively and probably save the larynx. The problem arises when you then go in and start biopsying and accentuate this radionecrotic process, and I'm still trying to work this out in my own mind in patients who have early small lesions. I still get the PET. I think that if it is negative I would probably go ahead and continue to follow those clinically and would probably send some of these folks over to your institution for hyperbaric oxygen and put them on long-term antibiotic treatment and try to follow them clinically to see if their disease progresses. Some of these came in really dysfunctional, in very severe pain, and they were aspirating. Their voice is really not functional, and certainly if the PET is positive, I would go ahead and take the larynx out. If it were negative, I wouldn't take it out.

DR HUDSON: The reason I posed that last question was that as I left Duke last week, the residents were biopsying a patient with postradiation laryngeal changes who had a positive PET, and it sure would have been nice to have made a decision to go ahead with the laryngectomy rather than do multiple biopsies. It might be added that PET may well be useful in identifying second primaries and, in a recent study, to be presented at the Triological Society, in identifying unknown primaries. The use of helical CTs for 3-D imaging of the larynx, as reported by Silverman et al, is innovative, and the resulting images are excellent. The images are compared by the authors to a laryngogram. Many of us recall the physician and patient trials in obtaining a good laryngogram. These "radiographic laryngograms" are obtained with no significant patient discomfort. There should be more substance to an image than merely a "pretty face." In truth, I have never felt laryngograms were particularly helpful to me in my decision-making. The data presented seem to confirm my opinion of the marginal benefits of these images. The methodology described in obtaining the data, that is, review of the images by two radiologists and one otolaryngologist, is, I feel, somewhat questionable. My radiology colleagues, however, are most enthusiastic about the potential of helical or spiral CTs. Software is being developed for both surface and volume rendering. High 3-D resolution is possible, and for specific sites and contrast may also be used. I would like for the presenter to briefly comment on the potential use of helical CT in head and neck, particularly in tumor extent and pediatric airway evaluation, and I would like him to comment briefly on the radiation dosage in helical CT.

ANDREW S. ZEIBERG, MD (Washington, DC): I alluded to the future of central helical CT in my conclusions. We expect in the near future in the upcoming months to display both the fleeting airway that I have shown in my talk, as well as the tumor mass, so this will provide more information than just a laryngogram. In terms of other advantages of the helical CT, its very graphic imaging is one of its major assets. The entire neck is scanned in 30 seconds, which is excellent, particularly in pediatric evaluations, where you have to sedate the child with possible airway intubation, which is troublesome for us and with all the monitoring that is necessary. The patient can be scanned in 30 seconds and we have all the information. The standard CT scan usually requires up to 10 minutes for the imaging acquisition, for often the patient would have to be moved and the scanner would have

to reposition itself, and all of this added up to a time interval of 5 to 10 minutes. So, we see there is going to be great potential for helical CT imaging in the head and neck.

DR HUDSON: There is one additional question.

ARNOLD M. NOYEK, MD (Toronto, Canada): Just a comment. This is a small point. In an area where our technical expertise is increasing and our professionalism, at the same time, has come under increasing attack, it is important to sense how this armamentarium may be useful. The impulse scanning is far superior. The extent of the tumor volume is going to be a very important consideration, and the helical CT can provide that, and if you just think from the cost-effective side, you can do these short studies with savings of contrast agents. When you work these up from the imager's perspective, the savings are substantial.

COMBINED THYROPLASTY TYPE I AND INFERIOR CONSTRICTOR MYOTOMY (p 72)

WILLIAM W. MONTGOMERY, MD; ROBERT E. HILLMAN, PHD; MARK A. VARVARES, MD

"WINDOW" LARYNGOPLASTY: A NEW COMBINED LASER ENDOSCOPIC AND OPEN TECHNIQUE FOR CONSERVATION SURGERY (p 89)

STANLEY M. SHAPSHAY, MD; ZHI WANG, MD; ELIE E. REBEIZ, MD; DONALD F. PERRAULT, JR; MICHAIL M. PANKRATOV, MS

LARYNGOPLASTIC MEDIALIZATION AND ARYTENOID ADDUCTION: A QUANTITATIVE AND QUALITATIVE ANALYSIS OF VOICE IMPROVEMENT (Abstract, p 153)

JAMES L. NETTERVILLE, MD; LIZ LUKEN, CCC, SLP; ED STONE, PHD; WILLIAM B. ARMSTRONG, MD; DAVID W. HALL; ROBERT H. OSSOFF, DMD, MD

ROBERT H. OSSOFF, MD (Nashville, Tenn): My congratulations to the three speakers for a job well done, and I would like to also thank them for sending the manuscripts to me so I would have an opportunity to prepare this discussion. Dr Shapshay and his colleagues have presented us with an innovative yet very logical approach towards extending the principles of endoscopic excisional biopsy to more advanced T1 and T2 lesions of the glottic larynx. The new surgical procedure, window laryngoplasty, combines existing endoscopic laser technology and laryngeal reconstructive principles with the newer approaches of laryngeal framework surgery and laser soldering techniques from mucosal grafting. The result is a combination of endoscopic and open approaches to facilitate adequate en bloc resection including adjacent cartilage and a tumor of the true vocal fold. The immediate reconstruction with the sternohyoid muscle flap base superiorly covered with a mucosal graft and inserted into the cartilaginous window to reconstruct a pseudocord demonstrated promising results in the in vivo study in six dogs. These authors raise a very pertinent question. Can a major vocal fold en bloc resection be performed with surrounding cartilage, using a combination of endoscopic and open techniques for conservation laryngeal surgery? The in vivo canine study tests the feasibility of this concept as a supplementary approach for endoscopic laser partial laryngectomy. It is suggested by these authors that this new approach is expected to overcome the limitations of the endoscopic approach alone, and to minimize the morbidity associated with standard partial laryngectomy. As they presented, six beagle dogs were used in this study: three who had full-thickness grafts from the buccal labial mucosa laser soldered, and three who had the overlying fascia used as coverage. The muscle flap itself, inserted through the window in the thyroid cartilage, served as a new vocal fold with the mucosa or fascia facing the endolarynx. They did a nice job presenting the technical aspects. Perceptual analysis of the dogs' voice, the bark, revealed that the dogs with mucosal grafts had a normal bark, while those with the fascia coverage had a moderate or weak bark. The authors did not state if their bark evaluation was performed in a blinded manner. A key point is that this graft with the muscle can be placed in the precise position of the pseudocord, and this is ensured via this combination of external and endoscopic approach. Dr Shapshay concludes that the new window approach could be a useful adjunct to existing reconstructive techniques, with adequate resection of the tumor and preservation of function, and I certainly look forward to hearing from him and his coauthors in the future as they apply this canine research to patients.

Dr Montgomery and his colleagues present us with a study of the rehabilitation of patients with deficits in voice and swallowing function due to disruption of the neural supply to the pharynx and larynx. Several questions were asked by these authors, including whether a tracheotomy or gastrostomy is indicated, whether medialization laryngoplasty or cricopharyngeal myotomy is indicated and, if so, should these procedures be performed separately or together. Twenty-five patients are presented by this group, 10 in the first group, where the thyroplasty and myotomy were performed in separate procedures, and 15 in the second group, where the thyroplasty and myotomy were performed as a combined procedure. Each of these groups were then further broken down by site of lesion and yielded 3 subgroups of 10 patients each where we could have a comparison between group 1 — delayed thyroplasty and myotomy — and group 2 — simultaneous thyroplasty and myotomy. These 3 subgroups were patients with lesions of the posterior fossa level, patients with base of skull lesions, and patients with high vagal lesions. There is controversy, to say the least, amongst those who perform

cranial base surgery, over the role of cricopharyngeal myotomy in the rehabilitation of these patients with dysphagia secondary to the cranial nerve injury IX and X. The well-designed, randomized prospective study does not exist. Supporting papers on both sides do exist with regard to this controversy, and Dr Montgomery's paper certainly supports the thesis that cricopharyngeal myotomy should be added to the medialization laryngoplasty for rehabilitation of patients with lesions localized to the posterior fossa, base of skull, or high vagal area. Further, Dr Montgomery and his colleagues make a compelling case for simultaneous medialization laryngoplasty and cricopharyngeal myotomy as opposed to initial laryngoplasty followed by myotomy several months later. Both tracheotomy and gastrostomy can be avoided when these procedures are performed simultaneously. Two points associated with their presentation are worthy of discussion. First, the total number of patients presented was very small and does not allow for any meaningful statistical analysis. Furthermore, improvement in voice and dysphagia aspiration was not documented in the manuscript I reviewed with any objective test such as acoustical analysis, laryngeal function tests, or radiographic analysis of swallowing and aspiration. One other point for discussion relates to the possibility of increase in silent reflux in patients with unilateral injury to cranial nerves IX and X who undergo subsequent cricopharyngeal myotomy or surgical relaxation of the superior esophageal sphincter.

Dr Netterville and his colleagues present us with their analysis of voice results in 211 patients treated with medialization laryngoplasty, medialization laryngoplasty and arytenoid adduction, or bilateral medialization laryngoplasty for glottic incompetence. Their surgical goals were to improve both voice quality and glottal competence. The data presented in their manuscript were exhaustive. Three tests of voice were utilized by these authors. Two are well known to us and demonstrate glottal competence: the MPT or median phonation time and the MR or mean flow rate. Both of these tests are parallel measures of glottal competence. The third test, the desirability voice rating, represents a new system to attempt to judge voice improvement. It is perceptual or subjective, but was performed in a blinded fashion, with its goal being to judge the patient's ability to communicate in society in an improved fashion following laryngeal framework surgery with or without arytenoid adduction. Following the desirability voice rating test by the five raters, the data were objectively analyzed by computer. Of interest and significance was the extremely close interrater variability demonstrated by this test. All groups of patients in this series demonstrated improvement in glottal competence, following medialization laryngoplasty with or without arytenoid adduction. Although the voice scores were improved in all groups, those patients with unilateral paralysis alone exhibited the most improvement, while those with bilateral bowing showed less improvement. This is expected, however, considering that the baseline scores were better in those with bilateral bowing than in those with unilateral paralysis. The voice desirability rating test proved to be a useful rating method, especially with the gradations presented in the written manuscript. If these data in their digitalized form can be combined with the more traditional measures of jitter, shimmer, signal to noise ratio, and voice spectroscopy, a more meaningful approach to voice analysis may result. The fact that this group of authors only looked at three measures of voice is an obvious area of weakness of this paper. The remainder of the data that they collected need to be studied, quantified, and presented, including the acoustical analysis of the voice samples and the laryngeal function studies, and I would hope we would hear from Dr Netterville and his colleagues in the future regarding these as yet unreported data from their large series of patients.

TRACHEOESOPHAGEAL VOICE FOLLOWING TUBED FREE RADIAL FOREARM FLAP RECONSTRUCTION OF THE NEOPHARYNX (p 77)

DANIEL G. DESCHLER, MD; E. THOMAS DOHERTY, PHD; CHARLES G. REED, PHD; JAMES P. ANTHONY, MD; MARK I. SINGER, MD

TEFLON GRANULOMA OF THE LARYNX: ETIOLOGY, PATHOPHYSIOLOGY, AND MANAGEMENT (p 96)

MARK A. VARVARES, MD; WILLIAM W. MONTGOMERY, MD; ROBERT E. HILLMAN, PHD

JOHN M. FREDRICKSON, MD (St Louis, Mo): I am going to try to keep my comments brief, because there may be some questions from the audience or comments. I congratulate the essayists for very interesting papers. In Dr Varvares' paper, unfortunately, as he pointed out, acoustic measures were not done in many of the patients. Only two preop and four postop patients had these measures carried out. I am sure that in the future they will try to do more prospective acoustic measures. I assume that in his series there were no naive and professional listeners to judge the voice quality, and if there were, I wonder if he could give us those results. In his paper, I noted that he mentioned that Dr Dedo's series of some 600 cases had 12 patients with Teflon injection that had some kind of granuloma problem requiring reoperation, which is certainly a fairly small percentage, and really the question is technique in many instances, I assume. In whose hands is this operation more frequently successful and more frequently less successful? His patients really seem to fall into two groups. There were approximately one half of the patients who had problems very early on, and there were the other half that had problems years later, up to 20 and 25 years later. I assume that technique has had something to do with the early failures in those patients in whom early failure occurred. I wonder if he has any comments regarding that. He also mentioned in his paper that Dr Dedo claimed that he noted that the injected Teflon vocal cord vibrated in synchrony with its mate, and I wonder whether he has any objective evidence of that, and I wonder whether Dr Varvares

could let us know about that. With regard to the paper in general, of course, one would have preferred a more prospective study with preoperative and postoperative results on all of these patients, but at least, I think it would be interesting for him to add some planned outcomes measures to judge not just the voice but the patient's quality of life.

For Dr Deschler's paper, I wonder whether all of the TE punctures on the radial forearm flap patients were done secondarily or primarily. I assume secondarily. His study was very well controlled. They had a very carefully planned prospective study with preoperative and postoperative results — very interesting indeed and very valuable. Once again, I would urge that the outcomes approached be added to this and using standardized methods to assess the quality of life. That is, how effectively are these patients judged by listeners in their environment, and how comfortable do these patients feel speaking in all environments? Is there social acceptability? So, I look forward to that information, and I look forward to the comparison of the radial forearm flap–reconstructed patients with those who had routine TE punctures following laryngectomy over time. That is to say, as he mentioned in his paper, those individuals with radial forearm flap reconstruction had only been using the TE puncture technique for a short period of time, and it would be interesting to know whether those individuals improved their efficiency over time.

HERBERT H. DEDO, MD (San Francisco, Calif): I just wanted to say, first of all, that there were about 450 Teflon injections, not 600. The incidence of granuloma formation in our series is 1% to 2%. When the Teflon has been injected laterally in the small appropriate amount, the edge of the cord vibrates. The measurement of that is stroboscopic observation, so you can decide for yourself its motion. Now, if the cord is filled with Teflon sufficiently so the edge of the cord won't vibrate, then obviously it can't vibrate.

DR FREDRICKSON: I wonder if either of the essayists want to comment on the questions posed?

DR DEDO: The statement that Teflon is not reversible is incorrect. I have made it very clear that it can be removed, and I have been doing that since 1970. I published a paper in the late 1970s showing how it can be removed by lasering a wedge out of the top of the cord. It is reversible.

DR FREDRICKSON: That's an interesting statement. Anybody want to take that one on?

MARK A. VARVARES, MD (Boston, Mass): I appreciate Dr Dedo's comments. His experience with Teflon injection is probably one of the best in the country, and I think his low incidence of granuloma represents that. In response to your comments, Dr Fredrickson, obviously we do not have objective data on our voice results. We will in the future, now that we have a voice therapist there who can do objective acoustic and aerodynamic measures. We also have a quality of life questionnaire that we have our medialization patients or laryngoplasty patients fill out and will also apply it to our Teflon granuloma patients to get the impact of our work and the impact of the pathology on their lives. I think that is very valuable, certainly in the future outcome studies that health care reformers are going to perform. The other question, about Dr Dedo's series, was just answered. The issue of mucosal wave in patients that we've seen with Teflon granulomas, we don't have any objective data or objective evidence of wave formation when we look at videostroboscopy, but these are patients who have granuloma formation. These aren't patients who have a well-injected cord. So, all I can say is that in the cases that we have seen with problems with Teflon, there is an absence of the mucosal wave, and we think that probably contributes to the dysphonia.

CHARLES W. CUMMINGS, MD (Baltimore, Md): I would just like to ask Dr Dedo how long his following is. My experience is that Teflon granulation occurs as a very delayed event years later, or 6 to 10 to 12 years later. I would like to hear how long you follow these patients.

DR DEDO: Six months to 28 years, and I agree with you. It is delayed. But the other problem is that some of the granulomas occur early.

GERALD S. BERKE, MD (Los Angeles, Calif): I agree with Dr Dedo. It is difficult to reverse thyroplasty. A curve in the thyroid cartilage makes it difficult to take out Silastic blocks once they are put in, but there is an essential difference that I think we must remember, both in thyroplasty and injected Teflon. Thyroplasty really does not affect the muscle at all. In fact, you can do thyroplasties, as Dr Netterville explained, on patients and end up with very mobile vocal cords. In contrast, with Teflon, of necessity, you inject it into the vocalis muscle. Almost all patients that had Teflon injections have paralyzed vocal cords. The Teflon was injected for many types of paresis, and paralysis may be responsible for the differences in the two materials.

DR FREDRICKSON: We better get the final comment from Dr Deschler if he has one.

DANIEL G. DESCHLER, MD (San Francisco, Calif): Very briefly, on the issue of whether the patients with free forearm flaps were punctured secondarily, they were. Your comments about quality of life are valuable. What we intend to do as follow-up studies with these patients is bring them back and record their voices after a period of 1 to 3 years and then hear them again to compare with their voice restoration studies.

NONINVASIVE MEASUREMENT OF TRAVELING WAVE VELOCITY IN THE CANINE LARYNX (p 101)

SINA NASRI, MD; JOEL A. SERCARZ, MD; GERALD S. BERKE, MD

ELECTRONIC SPECKLE PATTERN INTERFEROMETRY OF THE VIBRATING LARYNX (p 110)

GLENDON M. GARDNER, MD; JAMES CASTRACANE, PHD; MICHELLE CONERTY, MS; STEVEN M. PARNES, MD

PHONATORY SPECIALIZATION OF HUMAN LARYNGEAL MUSCLES (Abstract, p 153)

IRA SANDERS, MD; BEI-LIAN WU, MD; HUGH F. BILLER, MD

ROGER L. CRUMLEY, MD (Orange, Calif): These three papers are very sound research contributions, each with meaningful clinical implications. Dr Sanders has presented yet another in a series of important investigations in laryngeal muscle, this time in the thyroarytenoid muscle. He has shown us that the medial portion of the thyroarytenoid (vocalis) is predominantly slow twitch muscle, while the lateral portion of the TA muscle (or muscularis) is fast twitch. We know that slow twitch muscle is generally innervated by motor axons with small motor units (or numbers of muscle fibers innervated by a single axon), and fast twitch muscle (the gastrocnemius is a good example) with large motor units. Prior data confirm that one motor axon in gastrocnemius may innervate as many as 2,000 muscle fibers — a very large motor unit. The vocalis has been previously estimated to have some of the smallest motor unit sizes in the body, with estimates of one muscle fiber innervated by one motor axon. In addition, there is recent evidence from the literature that one muscle fiber may contain multiple isoforms of myosin, and hence may in fact be innervated by two axons, one fast and one slow.

The lateral cricoarytenoid is the primary vocal adductor, and is a relatively fast muscle. It follows that the fast TA muscularis, as described in Dr Sanders' paper, probably functions as an assistant to the lateral cricoarytenoid (LCA) in quick adduction, medializing the vocal process and preparing the vocal fold for phonation, coughing, or Valsalva maneuvers. The data would suggest that the slower vocalis muscle, working in concert with the horizontal portion of PCA, and also with the cricothyroid, then adjusts the tension, mass, and other physical properties of the vocal fold to tune it appropriately for the adductive maneuver. In phonation, for example, it is thought that there is more PCA activity in high-pitched sounds than in low-pitched.

The clinical implications of this study relate to accurate placement of Botox, and understanding of laryngeal reinnervation and medialization procedures, and how they work. This may lead someday to reconstructive techniques which might actually replace the functioning vocal unit of vocalis, vocal ligament, Reinke's space, and mucosa. In addition, when correlated with biomechanical studies, it will further enable us to understand the complex mechanism of phonation, something we clearly know too little about.

I've learned from our own muscle physiologist at UC Irvine that II-C muscle fibers have come to be of interest, and I learned yesterday from Dr Cooper that these muscle fibers may be more prevalent in the infant larynx. I would ask Dr Sanders if he has any information regarding the presence of II-C fibers in TA and, at the same time, any evidence of the more recently discovered II-X fibers. (These generally require monoclonal antibody gel techniques for demonstration.)

An additional question. Ira, do you have any information regarding the makeup of the fast fibers? What percentage of the muscularis is II-A, and what percentage II-B? The ratio between A and B may help us understand vocal fatigue, and the superiority of the singer's voice, as well as promoting understanding of how reinnervation procedures work.

Drs Nasri, Sercarz, and Berke have demonstrated a sophisticated research investigation from Dr Berke's very productive UCLA laryngeal laboratory, a descendant of Drs Joel Pressman and Paul Ward. (Talk about "shoulders of giants"!) It appears to be a quantum step forward in understanding how the vocal fold functions, and more importantly, a method of quantifying vocal fold stiffness, and even the traveling wave's characteristics. I particularly like a section in the written version of the paper which discusses medialization laryngoplasty and how it may produce alteration in Young's modulus of the vocal fold tissue, and hence equalize the wave velocities of the two hemilarynges, producing glottic symmetry. We need more of this kind of thinking as we analyze the biomechanical and phonatory effects of such things as thyroplasty, Teflon injection, reinnervation, or even the various types of arytenoidectomy.

Since this technique appears useful clinically, this paper may represent a major advance. I'd like to ask Dr Nasri and/or Dr Berke whether this technique could be used in an outpatient videostrobe laboratory without anesthesia. In other words, would it require measurement of Young's modulus by contacting the vocal fold with the tensionometer in each case? Or is it possible to infer these data from other patients? The second question is, What techniques do you suggest we pursue to confirm these data? Since the displacement velocity (DV) is a direct measurement, but traveling wave velocity (TWV) appears to be an indirect measurement?

The third paper, by Dr Gardner, required some intensive review on my part, just to understand the laser physics involved. I consulted with scientists at UC Irvine's Beckman Laser Institute regarding the technique of interferometry. I learned that similar studies are going on at my own institution, utilizing optical low coherence reflectometry to ascertain blood flow in the microcirculation under the skin of laboratory animals. This important new technique (OLCR) has also been used at MIT in tomographic measurement of the peripapillary area of the retina, and the coronary arteries of animals.

I would congratulate Dr Gardner for employing these new laser-based measurement techniques to the larynx. Since the technique proposes to measure TWV in the vertical axis, these two papers appear to have opened the era when both TWV and DV are quantifiable. Knowledge of these two parameters in the diseased and normal larynx would take us far beyond the current use of videostroboscopy, the data from which are almost random sampling, and poorly understood at best.

I would ask the authors to comment on the possible simultaneous determination of TWV and DV. In other words, could this device be built in such a way as to make both determinations? And could this be done via a fiberscope? What would such a device cost? What were the actual data for TWV in meters per second, which I couldn't find in the written paper, and would they like to correlate them with the data in Dr Nasri's paper?

SINA NASRI, MD (Los Angeles, Calif): Thank you for your comments and questions, Dr Crumley. As far as your question is concerned, yes, that is the goal of our laboratory, and as I briefly mentioned in my talk, it is applicable to human research. What we are doing is modifying a 90° laryngoscope and we are building in the calibrating instrument inside it. There is basically a trigger that moves the laryngoscope a very exact given amount while you are videoing the patient. The importance of this is that we have to

try to minimize the movement of the patient. Then we can actually measure distance, measure time, and calculate displacement velocity. As far as measure of the tension and Young's modulus is concerned, I think the importance of this work is that given the fact that we have shown the relationship between velocity and Young's modulus, it is not necessary. We can actually use displacement velocity in lieu of Young's modulus and use that as a measure of the stiffness, since we showed a linear correlation between displacement velocity and the traveling wave velocity, and predict characteristics of the fold, and hopefully, use that for both diagnostic measures as well as therapeutic measures.

GLENDON M. GARDNER, MD (Nashville, Tenn): Thank you for your comments, Dr Crumley. When we first embarked on this project 3 years ago, the goal was to create an instrument that would employ this technique in vivo in patients, much as a fiber nasopharyngolaryngoscope is used today. When we presented our first results of holography 2 years ago at this forum, we actually included the design of that scope, rather prematurely. The goal is to eventually get the components small enough and to be able to hook it up to either rigid telescopes or fiberoptic scopes so we can use it much as we use stroboscopy today. As far as cost, right now it is prohibitive, but hopefully by then it won't cost too much more than the fiberoptic scopes we use today.

ENDOSCOPIC VOCAL FOLD MICROFLAP: A THREE-YEAR EXPERIENCE (p 65)

MARK S. COUREY, MD; GLENDON M. GARDNER, MD;
R. EDWARD STONE, PHD; ROBERT H. OSSOFF, DMD, MD

AUTOLOGOUS FAT INJECTION FOR VOCAL FOLD PARALYSIS: LONG-TERM HISTOLOGIC EVALUATION (p 85)

LAUREN S. ZARETSKY, MD; MAISIE L. SHINDO, MD; MICHAEL DETAR, MD; DALE H. RICE, MD

CORDECTOMY VERSUS ARYTENOIDECTOMY IN THE MANAGEMENT OF BILATERAL VOCAL CORD PARALYSIS (p 135)

HANS E. ECKEL, MD; MONIKA THUMFART; KLAUS WASSERMANN, MD;
MARTIN VÖSSING, MD; WALTER F. THUMFART, MD

JONAS T. JOHNSON, MD (Pittsburgh, Pa): I'd like to thank the authors for providing me with their manuscripts prior to the meeting. I'll discuss the manuscripts in the order of presentation.

Dr Courey and his colleagues present their extensive experience employing the microflap technique. It's interesting to note that 93% of the patients are rated as improved based upon subjective assessment. Interestingly, however, it was not possible to show a statistically significant improvement based upon perceptual evaluation. This suggests to me that the current state of the art for evaluation of voice is imperfect. The techniques described earlier in the program by Drs Nasri and Gardner, both of which allow evaluation of the mucosal waveform, may, in fact, contribute to our ability to evaluate postoperative results. When, in fact, these improved techniques are available and have been validated, it will then be possible to proceed with a prospective randomized trial of various approaches to therapeutic intervention.

The authors describe an extremely rigorous program of voice and vocal rehabilitation that requires up to 3 months. Is this rigorous program necessary? What happens when patients fail to observe absolute voice rest for 2 weeks? I would suggest that more insight into the need for postoperative voice rest is important and should be the topic of future investigation.

Dr Zaretsky and colleagues should be congratulated for pursuing continued investigation into alternative techniques for vocal cord medialization. The goal is to maintain the normal vibratory characteristics of the vocal fold. Results of autologous fat injection must, of necessity, be compared to the excellent results currently being reported employing thyroplasty. Once again, improved techniques of objective assessment may be required before these data are readily available.

The authors acknowledge that the long-term fate of autologous fat may be reabsorption. This study only followed their experimental model for 6 months. This issue, too, must be the subject of further research.

Dr Eckel and colleagues remind us that "any widening of the glottis for vocal cord paralysis trades voice for airway." The voice results obtained following cordectomy or arytenoidectomy were unpredictable. Perhaps this again reflects our relative inability to assess voice. The authors also remind me that until just recently the results of procedures aimed at the relief of bilateral vocal cord paralysis were often based upon our ability to decannulate the patient. A shortcoming of this approach is highlighted by the data presented, because 24 of 28 patients did not require tracheotomy preoperatively. Accordingly, any technique which requires an intraoperative tracheotomy, and then uses removal of the tracheotomy as the standard for success, clearly introduces an artificial standard which cannot be relied upon.

MARK S. COUREY, MD (Nashville, Tenn): Thank you for your

review. Our choice of 2 weeks of postoperative voice rest is fairly arbitrary. Surgeons and laryngologists report 0 or 3 days as a minimum to 10, and we are very conservative, with 14 days. There is certainly swelling and edema after surgery, and the feeling is that the overuse of a stiff vocal mechanism can lead to the development of functional compensatory behaviors. Therefore, we discourage use. There are also wound healing studies which seem to indicate that wound strength is greater starting at 10 to 14 days with collagen deposition and wound healing. This is another reason we feel that the microflap which is not sutured in place will have a better chance of being in the proper position at 2 weeks. We realize the severe emotional impact to the patient. We hope our patients are cooperative, but we cannot always guarantee that. We discuss it with them before surgery. We have seen no instances of vocal fold atrophy or muscle atrophy as a contraindication to extended voice use.

MALIGNANT LARYNGEAL TUMORS IN CHILDREN: A 15-YEAR EXPERIENCE WITH FOUR PATIENTS (p 42)

LAURIE A. OHLMS, MD; TREVOR MCGILL, MD; GERALD B. HEALY, MD

DIAGNOSIS AND MANAGEMENT OF EXTERNAL PENETRATING CERVICAL ESOPHAGEAL INJURIES (p 118)

WILLIAM B. ARMSTRONG, MD; MAJ THOMAS R. DETAR, MC, USAF; ROBERT B. STANLEY, MD, DDS

JEJUNAL GRAFT RECONSTRUCTION OF PHARYNGOESOPHAGEAL DEFECTS WITHOUT MICROVASCULAR ANASTOMOSES (p 141)

WILLIAM R. PANJE, MD; HUGH E. HETHERINGTON, MD

GARY L. SCHECHTER, MD (Norfolk, Va): Thank you, Dr Cantrell, Dr Ward, Dr Bailey, members, and guests. I am privileged to discuss these three papers, and I thank the authors for providing me with copies well in advance of this meeting. The first paper was a very good review of a rare entity, namely, malignant laryngeal tumors in children. Only four cases have presented at one of our large premier pediatric hospitals in 15 years, and this attests to the rarity of the lesion. The literature contains isolated case reports and other very limited series. The paper points out two important things to this reader. First, the basic principles of treatment for a particular histologic type of tumor (ie, rhabdomyosarcoma) apply to a tumor in the pediatric larynx as they do elsewhere, and secondly, basic surgical principles of laryngeal surgery (ie, conservation of the larynx) could apply to the tumors in the pediatric larynx as well. I agree with the authors that a registry for this rare entity as well as other head and neck tumors is needed and urge the senior authors to gather all experiences available for such a registry. I have three questions. First, how can the ALA and other organized otolaryngology–head and neck surgery organizations help with this problem? I suggest the answer to this be directed to our leadership. Secondly, what is the role of tracheoesophageal puncture and valve placement in children? Third, not to be inflammatory, but was the patient who had epidermoid carcinoma evaluated by a surgeon who routinely evaluates this kind of lesion? And who operated on this kind of lesion?

LAURIE OHLMS, MD (Boston, Mass): I would like to thank Dr Schechter for his comments. We would like to set up a registry, and we would appreciate any help. The second question, about tracheoesophageal puncture: to my knowledge and after asking people at other institutions, we know of no other pediatric patients who have had punctures, so we would be interested to hear if anyone has experience. The third patient with squamous cell carcinoma was seen by several members of our department, as well as the adult surgeons in our department who work at the Dana Farber, and multiple surgical procedures were discussed, including conservation laryngectomy.

DR SCHECHTER: The second paper diagnoses the management of external penetrating cervical esophagal injuries. This paper reports, and I will borrow the term from Dr Ossoff, an exhaustive study of 23 patients with external penetrating cervical esophageal injuries. It is retrospective. The patients were not treated according to a particular protocol. Since the patients were treated during a $10^1/2$-year period, one can assume that a variety of attending physician influences were brought to bear on the residents managing the cases. In spite of these shortcomings, this study is useful, even important. What can we learn from this experience? The workup is very important. An esophagram in a swallowing patient tells you if there has been a perforation in greater than two thirds of the patients. However, it is not perfect. Rigid esophagoscopy is an excellent evaluation tool to determine esophageal integrity. When a combination of barium swallow and endoscopy is used, there is a very high level of accuracy in determining whether or not the esophagus is penetrated. Although the authors downplay the use of flexible esophagoscopy, mostly on the basis of what is suggested in the literature, their conclusions are not based on experience. My experience over the past 24 years indicates that if one uses the flexible esophagoscope on a regular basis and the patient is under general anesthesia with paralysis, it provides excellent visualization of the cervical esophagus. Most otolaryngologists are not experienced in using the flexible esophagoscope, and this represents a deficiency in our training programs and continued political pressures from those who feel this particular instrumentation is only in their domain. A pediatric esophagoscope is certainly the instrument of choice in evaluating patients with cervical spine injuries, or those who for whatever reason have not had their cervical spine cleared. The speaker feels that if you have to depend upon flexible esophagoscopy for these special circumstances, then you should be experienced with the instrument through continued use in routine cases. These cases

must be worked up and treated early in the postinjury period. Even the most severely injured patients in this study did surprisingly well if they were explored and treated within 12 to 24 hours of the injury. If there is any question of penetrating injury, antibiotics are essential in order to prevent deep neck space infection. Every effort should be made to repair even the most difficult injury. Diversion procedures should be avoided. Repair, good drainage, and antibiotics will give the best immediate and long-term result. Finally, these patients require careful follow-up and should be explored if sepsis occurs after drains are removed. Dr Armstrong, what rationale is behind feeding these patients at 7 to 10 days?

WILLIAM B. ARMSTRONG, MD (Nashville, Tenn): The 7- to 10-day number is fairly arbitrary, and we base it on the same 7- to 10-day waiting period used by others.

DR SCHECHTER: In the third paper, once again, Bill Panje's bold approach to head and neck reconstruction has given us useful information. However, I must say that Drs Bernie Seidenberg and Max Som may have unknowingly preceded you in using this jejunum without vascular anastomosis. Dr Bailey had no way of knowing this when he asked me to discuss this paper, but I was an intern with Dr Som in 1963. Prior to starting his rotation, he always gave you a collection of his papers. We happened to have a case that had a cervical esophageal cancer, a rare entity. All of the house staff gathered around Dr Som and asked whether he was going to use the revolutionary technique that had been described by him and Dr Seidenberg in 1959. He said no. Dr Som's impression was that those cases ended up with a vascular necrosis and fibrosis, and this was based on their need for repeated dilations. It also explained why Dr Som continued to use the laryngotracheal autograft for cervical esophageal reconstruction in spite of that 1959 paper. Regardless of this little bit of history, Dr Panje has provided us with a useful approach to the patient whose jejunal autograft has immediate vascular anastomosis failure and in whom further surgery is contraindicated. In my 16 years of experience with jejunal autografts, I have had several very poor jejunal grafts after the microvascular surgeon has finally thrown up his hands and either retrieved another piece of jejunum or I insisted on using the chest flap. My question to the presenter is, Do you feel that there is a point in time when the jejunum has been damaged irreversibly for use as a nonvascularized graft?

WILLIAM R. PANJE, MD (Chicago, Ill): I'll answer your question! I guess you'd have to base that on your clinical impression in terms of the graft, and certainly it appears to be a problem.

ROBERT W. CANTRELL, MD (Charlottesville, Va): I am going to exercise the prerogative of the Chair and make a couple of comments on these. First of all, for Dr Armstrong and his colleagues, the size of the entrance wound in the neck from a gunshot wound is no indication of the amount of damage. That is better assessed by the velocity of the bullet, from which the amount of energy expended is directly translated to the amount of tissue damage. A very small missile traveling at a high speed can result in a great deal of damage, and a large one going slower would be less damaging. The other comment or what came to mind when I heard this paper by Drs Panje and Hetherington, regarding reconstruction of the hypopharynx following a laryngopharyngectomy, was a study I saw some years ago from Israel where they took the skin of the penile shaft and turned it wrong side out and used that to reconstruct the hypopharynx. I haven't heard much about that lately, and I assume that the process fell into disuse because they couldn't find donors.

PREDICTING RECURRENCE AND SURVIVAL IN PATIENTS WTH LARYNGEAL CANCER BY MEANS OF DNA CYTOMETRY, TUMOR FRONT GRADING, AND PROLIFERATION MARKERS (p 127)

HANS-J. WELKOBORSKY, MD, DDS; MICHAEL HINNI, MD; HANS-P. DIENES, MD; WOLF J. MANN, MD, FACS

GENDER DIFFERENCES IN CANCER OF THE LARYNX (p 147)

MIMI S. KOKOSKA, MD; JAY F. PICCIRILLO, MD; BRUCE H. HAUGHEY, MD, CHB

COMPARISON OF SOFT TISSUE RESPONSE IN RABBITS FOLLOWING LARYNGEAL IMPLANTATION WITH HYDROXYLAPATITE, SILASTIC AND TEFLON (Abstract, p 153)

PAUL W. FLINT, MD; SANJAY MARWAHA, MD; RITU GOEL, MD; CHARLES W. CUMMINGS, MD

CHARLES W. CUMMINGS, MD (Baltimore, Md): The first paper, by Drs Kokoska, Piccirillo, and Haughey, I think, is truly a notable contribution towards potentially a more effective stratification of the treatment modalities by the exploration of specific gender differences as they relate to laryngeal cancer. That survival of the afflicted male is related not only to age and symptom severity, as it is in the female, but as well to the comorbidity, anatomical subsite, and TNM staging is really quite revealing. This study has added new information to an area that heretofore has received little attention. Further scrutiny of the gender differences should be brought to bear on treatment planning. If, for instance, TNM staging and anatomic subsites do not affect the survival statistics of females, should we become less exacting and thus less costly to the health system by dampening our efforts to definitively stage the tumor? Can we do less and still achieve the same level of survival? This, to me, is an exciting paper and exciting information. The question for Dr Kokoska is, Do you have plans for the future to analyze, relative to gender, therapeutic responses to the various available modalities employed in the treatment of laryngeal cancer? Is it possible with the information

at hand to down-stage the efforts of staging the laryngeal tumor?

MIMI S. KOKOSKA, MD (St Louis, Mo): In response to the first question, certainly we have other studies and we would like to stratify gender results. With this being a small study, we would like to see larger studies done using stratification as well.

DR CUMMINGS: Is there a way, with what we know now, to be less exacting in our staging procedures for the female?

DR KOKOSKA: I am not aware of any.

DR CUMMINGS: On the second paper, the biopsy of the laryngeal tumors was evaluated by DNA analysis of cytometry, by tumor infiltration, and by Ki67 scans at the tumor margin. Each of these contribute to the predictability of tumor recurrence as shown by the authors. This information is required prior to definitive treatment and therefore may shape the aggressiveness of the definitive treatment for each disease. My question of the authors is, how accessible is this technology to the average head and neck surgeon, not the one who is focused and sited at a major head and neck center, but those in the community who are doing very good work? Is this something that is accessible in Germany, and does anyone know if it is accessible in this country on a routine basis?

HANS-J. WELKOBORSKY, MD, DDS (Mainz, Germany): Apparently, this technique, the DNA analysis, is based on a computerized image analysis system. The DNA analysis we use in our department. This machine can be bought. This machine costs about 100,000 deutsche marks, which right now is $60,000. However, all the other studies you can do by an immune histochemical routine process, and so these are not very expensive. The whole procedure is presently very time-consuming. Currently, we say you need about 6 hours for one case.

DR CUMMINGS: On the third paper, I would like to say at the outset to Dr Flint that I am delighted to know that you actually were in the lab when you told me you were in the lab. I think what you have done is to identify incontrovertibly that Teflon in its paste/suspension form does invariably precipitate a pronounced inflammatory response. I think this has been accepted and believed for a long period of time, but this is very graphic histological evidence. My sense is that although hydroxylapatite is currently the best material available, we have not found the perfect material yet, and I would appreciate your opinion as to what the qualifications and character would be for a laryngeal prosthetic implant.

PAUL W. FLINT, MD (Baltimore, Md): The material would certainly be easily accessible. The ideal is that this is a minimally invasive procedure. It should certainly be nontoxic, noncarcinogenic. The cellular and chemoresponse should be limited or none at all. I think that by at least eliminating the cellular response you minimize the risk of impairing the normal function of these vibratory characteristics.

John E. Bordley was born in Baltimore, Maryland, at the Johns Hopkins Hospital in 1902. Born into an old Baltimore family with strong ties to the Johns Hopkins School of Medicine and Hospital, he also devoted his life to Johns Hopkins. His brothers trained in surgery at Hopkins and his father was a member of the Johns Hopkins Department of Ophthalmology.

Dr Bordley graduated from the Johns Hopkins School of Medicine in 1925 and served his internship at Union Memorial Hospital in Baltimore. He served in World War II with honor as a member of the Johns Hopkins 118th General Hospital Division in Australia, New Guinea, and the Philippines. He was awarded three battle stars for his service in the Pacific theater.

In 1952 he was appointed Director of the Department of Otolaryngology and Otolaryngologist in Charge at the Johns Hopkins Hospital. He was designated the Andelot Professor of Otolaryngology and served as Chair for 35 years. His contributions to the literature, to research, and to the development of otolaryngology and speech research at the National Institutes of Health led not only to the development and recognition of the strong Johns Hopkins residency program, but also to the support and development of other divisions and departments of otolaryngology across the country.

Dr Bordley worked with William G. Hardy, PhD, of the Johns Hopkins Hearing and Speech Clinic to develop an interdisciplinary approach to the treatment of hearing and speech problems. He was an innovative investigator and applied the scientific method to investigation and treatment of disorders of hearing and communication. His anatomical and epidemiological work correlated materials on rubella and hearing loss.

Dr Bordley received many honors nationally and internationally. He received the Award of Merit for his distinguished contributions to otology from the American Otological Society, and a Gold Medal Award from the International Federation of Otolaryngology. He was Executive Director of the American Council of Otolaryngology from 1968 to 1972. He helped guide and direct its amalgamation with the American Academy of Otolaryngology. He served as President of the American Otological Society, the



JOHN E. BORDLEY
1902-1993

Society for University Otolaryngologists, the American Otological, Rhinological and Laryngological Society, and numerous other organizations.

He was honorary President of the VII World Congress of Otolaryngology in 1985. He has served visiting professorships in Guy's Hospital in London, Egypt, Lebanon, Iran, South Africa, and India, as well as many others in the United States. Many of his students, residents, and fellows have become the teachers of our specialty. In 1990 his former students, along with his colleagues, honored him further by establishing the John E. Bordley Chair in Otolaryngology at the Johns Hopkins Hospital School of Medicine.

Dr Bordley is survived by his wife, helpmate, companion, and best friend, Ellen Fisher Bordley; his daughters, Ellen Bruce Gibbs and Anne Moss; three grandchildren; and three great grandchildren.

L.P.
P.H.W.



JOHN B. ERICH
1907-1994

John B. Erich was born in Chicago, Illinois, on January 14, 1907. He attended the University of Illinois in Chicago from 1926 to 1933, attaining the degrees of Bachelor of Science in 1929 and Doctor of Medicine in 1933. He received the degree of Master of Science in Plastic Surgery from the University of Illinois in 1935. In 1933 he was a fellow in Plastic Surgery in the Mayo Graduate School of Medicine, concentrating his studies on laryngology and oral and plastic surgery. In 1934 he was appointed First Assistant in Oral and Plastic Surgery, and in 1937 he joined the staff of the Mayo Clinic as a member of the Section of Laryngology, Oral and Plastic Surgery. He served as head of the Section of Plastic Surgery and Laryngology (otolaryngology) from October 1937 until July 1955, when he became a senior consultant. He advanced from Assistant Professor in 1940 through the ranks to Full Professor in 1942. He was one of the founders of the American Board of Plastic Surgery, Inc, in 1937 and was certified by that board in 1942. He was a member of that board from 1958 to 1964. He was also certified by the American Board of Otolaryngology, Inc, in 1949. He was the author of 153 papers, numerous chapters, 2 books, and other contributions to the surgical literature.

He was a fellow of the American College of Surgeons since 1945 and was also a fellow of the American Academy of Ophthalmology and Otolaryngology and a member of the American Medical Association, the American Association of Plastic Surgeons, the American Society of Plastic and Reconstructive Surgeons, Inc, the American Society of Maxillofacial Surgeons, the American Fracture Association, the Society of Head and Neck Surgeons, the American Laryngological, Rhinological and Otological Society, Inc, the American Laryngological Association, the Minnesota Academy of Ophthalmology and Otolaryngology, the Minnesota State Medical Association, the Southern Minnesota Medical Association, the Zumbro Valley Medical Society, the Alumni Association of the Mayo Graduate School of Medicine, the Society of Sigma Xi, and the dental honor society Omicron Kappa Upsilon. He has served as regional Vice President of the American Fracture Association and was President of the American Society of Maxillofacial Surgeons in 1951.

He is survived by his wife, Edith (the former Miss Edith Gebhardt), of Chicago, Illinois.

H.B.N.
P.H.W.

Wilbur J. Gould, MD, internationally renowned and respected otolaryngologist, pioneer advocate and educator in voice science, humanitarian and healer, died in New York City, February 5, 1994.

He and his many devoted colleagues made significant contributions to the world's literature in voice through research performed in the Vocal Dynamics Laboratory at Lenox Hill Hospital, New York City, which he founded in the early 1970s, and at the Voice Laboratory of the Denver Center for the Performing Arts, posthumously renamed in his honor.

Dr Gould was Director of the Department of Otolaryngology at Lenox Hill Hospital from 1966 to 1979 and Chief of Laryngology at the Center for Communication Disorders, Lenox Hill Hospital, from 1979 until his death. He was founder of the Voice Foundation and served with great distinction as its director and chairman for over 20 years. Under Dr Gould's leadership, the Foundation, together with Lenox Hill Hospital and The Julliard School of Music, sponsored annual seminars on the Care of the Professional Voice, given alternately for many years in New York, Philadelphia, and Denver, and contributed research funds to many investigators whose efforts furthered the fund of knowledge in voice science.

Dr Gould was born in Norwalk, Connecticut, September 1, 1919. He received his BS at Harvard in 1941 and his MD from the New York University Medical School in 1944. He served his internship and residency in otolaryngology at Lenox Hill Hospital from 1944 to 1951. Following the completion of his residency in otolaryngology, he entered the Army and served at the Fitzsimons General Hospital, Denver, Colorado, from 1946 to 1948. In 1953 he obtained his Board Certification in Otolaryngology and in the same year joined the staff of the Department of Otolaryngology at Lenox Hill Hospital, where he practiced until the time of his death. He also was a member of the staffs of the New York Eye and Ear Infirmary and the Manhattan Eye, Ear & Throat Hospital, was consultant to the voice laboratories of numerous institutions around the world, and served on the Advisory Council of the Kathryn & Gilbert Miller Health Care Institute for Performing Artists at the Roosevelt–St Luke's Medical Center, New York.

Dr Gould contributed his expertise to many notable scientific organizations. He served on the Advisory Board of the National Institute on Deafness and Other Communication Disorders, was on the editorial boards of the *Journal of Voice* and the *Dysphagia Journal*, was Honorary Director of the New York League for the Hard of Hearing, and was Director of the Recording and Research Center, Denver Center for the Performing Arts. He served the New York



WILBUR J. GOULD
1919-1994

County Medical Society in many ways: as Vice-President from 1978 to 1987, as Chairman of the Health Systems Agency Coordination Committee from 1978 to 1982, and on numerous other committees, including Peer Review, Public Relations, Medical Malpractice, Medical Economics, Credentials, Legislative Affairs, and Health Planning, of the Lenox Hill Hospital.

He received the Laryngeal Research Award of the American Laryngological Association in 1984. In 1986 he was elected to Honorary Fellowship in the American Laryngological Association and was awarded the Doctor of Music (Honorary) by Oberlin College. He was also Honorary President of the Fondation de la Voix, France.

Dr Gould's consuming passion and commitment to the voice was unsurpassed in his time. His selfless dedication to the voices of statesmen, professional voice users, entertainers and performers, and countless patients with vocal disorders was legendary. His pioneering efforts in research and education of voice professionals had profound influence over the specialties and practice of otolaryngology, speech pathology, and voice science. Jim will be sorely missed by those who worked closely with him, and by his many patients, friends, and colleagues throughout the world. He is survived by his devoted wife, Maureen, and daughter, Tamara.

S.M.B.

Luzius Ruedi died on July 19, 1993, at the age of 93 at his home in Zurich, Switzerland. He was one of Europe's foremost otolaryngologists, highly regarded by his colleagues in the United States, and a treasured friend of many members of the American Laryngological Association, of which he was an honorary member.

Born in Thusis, Switzerland, in 1900, he grew up in Davos, where his father was an esteemed otolaryngologist. It was during those formative years that he was first exposed to the powerful attraction, challenges, and glamour of the surgical specialty to which his future contributions would eventually earn him an international reputation.

After graduation from Zurich University School of Medicine in 1925, he began his postgraduate training in otolaryngology in Vienna with Professo Otto Meyer. He received his residency education in Zurich with Professor Felix Nager. After a few years of a very successful private practice, he joined the faculty and staff of Zurich University School of Medicine and Hospital in 1937, and in 1941 assumed the Chairmanship of Otolaryngology at the University of Bern. In 1948, he succeeded his former teacher Felix Nager as Chairman and Director of Otolaryngology at Zurich University and Hospital, a position he held for 22 years until his retirement in 1970.

Luzius Ruedi was an excellent clinician, a very skillful and innovative surgeon, a gifted clinical investigator, and a very talented and enthusiastic teacher. His clinical astuteness reflected a vast knowledge accumulated from careful observations and insight during his postgraduate education and private practice. As a brilliant surgeon with the foresight to pursue the new developments in surgical techniques, he had the aptitude of recognizing immediately their potential significance. His over 150 contributions to the literature covered many aspects of otolaryngology.

Luzius Ruedi had all the qualifications of a great teacher. The high quality, the art of presenting a particular subject, and the enthusiasm that characterized his formal lectures and less formal discussions on ward rounds fascinated the medical students and had a decisive influence on many in the selection of their future medical specialty.

As was to be expected, several of his trainees assumed important positions in academic and other medical institutions of Switzerland and Europe. One of his students was Professor Ugo Fisch, who succeeded him as Chairman and Clinical Director in 1970.

Promotion of team spirit, fairness, encouragement,



LUZIUS RUEDI
1900-1993

and support distinguished Luzius Ruedi's leadership as Departmental Chairman and was characteristic of his relation to his associates and professional and supporting staff. His cheerful, trustful, and reassuring personality was a great comfort to his patients. He had the gift and intuition to help and stand by them in an admirable way through very difficult situations.

Luzius Ruedi was the recipient of innumerable academic honors and awards while always remaining very modest — an attribute of true greatness. He was an honorary member of many American and international societies. He was elected Corresponding fellow of the American Laryngological Association in 1957 and elevated to Honorary fellow in 1968.

Shortly after his retirement, a tragic accident bereaved him unexpectedly of his physical strength and left him totally dependent. He tolerated and endured the progressive loss of muscular control with the most admirable self-discipline, sacrifice, and equanimity. The serenity with which he accepted the enormous burden of his fate without ever a hint of complaint left a profound impression on all who knew him during that period. All his life, his wife Lotti, in her legendary modest and indulgent way, had been his strongest and most loyal support. With the assistance of members of her family, she took care of him in a manner of magnificent devotion and unselfishness, never leaving his side for two decades,

that earned her the highest admiration of everyone.

The composure with which Luzius Ruedi mastered his physical handicap while maintaining his brilliant mental faculties will always be remembered, as will his valuable contributions as a great physician, investigator, and teacher.

G.T.N.
U.F.
P.H.W.



EMANUEL M. SKOLNIK
1916-1994

Emanuel (Manny) Skolnik was born in Chicago, raised his family there, and spent his entire professional life practicing and teaching in that city. He received his undergraduate and medical degrees from the University of Illinois, after which he interned at Cook County Hospital, where he was in training when Pearl Harbor was attacked. Following military service in the European theater as a major in the medical corps, he returned to the University for a postgraduate course in the basic science of otolaryngology and a residency in the specialty. He became a diplomate of the American Board of Otolaryngology in 1949.

Dr Skolnik was a dedicated teacher, researcher, and clinician. His clinical and academic productivity resulted in a steady progression of promotions at the University of Illinois until he was made Professor of Otolaryngology in 1963 and much later, Professor Emeritus. He worked regularly with residents in the operating room and served his patients continually for many years in several private Chicago and suburban hospitals. He continued actively in the Department of Otolaryngology–Head and Neck Surgery at the University of Illinois Eye and Ear Infirmary until the recent months of his last illness.

Although he was broadly trained in his specialty, Dr Skolnik's clinical and research efforts were chiefly in the discipline of head and neck surgery. He made numerous contributions to the advancement of the management of tumors of the head and neck and he was the author of more than 125 publications. Many of his papers in clinical research have as coauthors residents and students who were inspired to become involved in investigation and writing.

Manny was a member and officer of many major national and international medical societies. He was a Fellow of the American College of Surgeons, the American Academy of Otolaryngology–Head and Neck Surgery, and the American Laryngological, Rhinological and Otological Society. He was also a Fellow of the American Society for Head and Neck Surgery, which he served as President in 1975, and the American Laryngological Association, of which he was Guest of Honor at the 107th meeting in 1986. He was elected a Director of the American Board of Otolaryngology in 1967 and served in that capacity until 1982, when he was elevated to Senior Councillor.

At the University of Illinois, for many years, he directed the Annual Otolaryngologic Assembly, a review course for a week each year for otolaryngologists from the entire United States. He invited speakers of outstanding ability who presented current updating of basic and advanced material in our specialty.

Manny Skolnik was a dedicated physician and close friend through our many years together at the University of Illinois. During his long tenure with the University, his enthusiasm for teaching both in the operating room and clinics never diminished. He enjoyed his work with residents and medical students and shared his activities with colleagues over the entire world. His well-known sense of humor remained even through his serious final illness.

We extend our heartfelt condolences to his wife, Helen, his daughters, Robin and Carol, his five grandchildren, and the entire family.

B.J.S.

OFFICERS 1879-1993

Presidents

1879 Louis Elsberg
1880 J. Solis-Cohen
1881 F. I. Knight
1882 G. M. Lefferts
1883 F. H. Bosworth
1884 E. L. Shurly
1885 Harrison Allen
1886 E. Fletcher Ingals
1887 R. P. Lincoln
1888 E. C. Morgan
1889 J. N. Mackenzie
1890 W. C. Glasgow
1891 S. W. Langmaid
1892 M. J. Asch
1893 D. Bryson Delavan
1894 J. O. Roe
1895 W. H. Daly
1896 C. H. Knight
1897 T. R. French
1898 W. E. Casselberry
1899 Samuel Johnston
1900 H. L. Swain
1901 J. W. Farlow
1902 J. H. Bryan
1903 J. H. Hartman
1904 C. C. Rice
1905 J. W. Gleitsmann
1906 A. W. de Roaldes
1907 H. S. Birkett
1908 A. Coolidge, Jr
1909 J. E. Logan
1910 D. Braden Kyle
1911 James E. Newcomb
1912 George A. Leland
1913 Thomas Hubbard
1914 Alexander W. MacCoy
1915 G. Hudson Makuen
1916 Joseph L. Goodale
1917 Thomas H. Halsted
1918 Cornelius G. Coakley
1919 Norval H. Pierce
1920 Harris P. Mosher
1921 Harmon Smith
1922 Emil Mayer
1923 J. Payson Clark
1924 Lee Wallace Dean
1925 Greenfield Sluder
1926 Chevalier Jackson
1927 D. Bryson Delavan
1928 Charles W. Richardson
1929 Lewis A. Coffin
1930 Francis R. Packard
1931 George E. Shambaugh
1932 George Fetterolf
1933 George M. Coates
1934 Dunbar Roy
1935 Burt R. Shurly
1936 William B. Chamberlain
1937 John F. Barnhill
1938 George B. Wood
1939 James A. Babbitt
1940 Gordon Berry
1941 Thomas E. Carmody
1942-3 Charles J. Imperatori
1944-5 Harold I. Lillie
1946 Frank R. Spencer
1947 Arthur W. Proetz
1948 Frederick T. Hill
1949 Ralph A. Fenton
1950 Gordon B. New
1951 H. Marshall Taylor
1952 Louis H. Clerf
1953 Gordon F. Harkness
1954 Henry B. Orton
1955 Bernard J. McMahon
1956 LeRoy A. Schall
1957 Harry P. Schenck
1958 Fred W. Dixon
1959 William J. McNally
1960 Edwin N. Broyles
1961 Dean M. Lierle
1962 Francis E. LeJeune
1963 Anderson C. Hilding
1964 Albert C. Furstenberg
1965 Paul H. Holinger
1966 Joel J. Pressman
1967 Lawrence R. Boies
1968 Francis W. Davison
1969 Alden H. Miller
1970 DeGraaf Woodman
1971 F. Johnson Putney
1972 Frank D. Lathrop
1973 G. Slaughter Fitz-Hugh
1974 Daniel C. Baker
1974 Joseph H. Ogura
1975 Stanton A. Friedberg
1976 Charles M. Norris
1977 Charles F. Ferguson
1978 John F. Daly
1979 John A. Kirchner
1980 Daniel Miller
1981 Harold C. Tabb
1982 M. Stuart Strong
1983 John S. Lewis
1984 Gabriel F. Tucker, Jr
1985 Douglas P. Bryce
1986 Loring W. Pratt
1987 Blair Fearon
1988 Seymour R. Cohen
1989 Eugene N. Myers
1990 James B. Snow, Jr
1991 John M. Fredrickson
1992 William R. Hudson
1993 Byron J. Bailey

Vice-Presidents (First and Second)

1879 F. H. Davis
1880 W. C. Glasgow, J. O. Roe
1881 E. L. Shurly, W. Porter
1882 C. Seiler, E. F. Ingals
1883 S. W. Langmaid, S. Johnston
1884 J. H. Hartman, W. H. Daly
1885 H. A. Johnson, G. W. Major
1886 E. C. Morgan, J. N. Mackenzie
1887 J. N. Mackenzie, S. W. Langmaid
1888 W. C. Glasgow, C. E. DeM. Sajous
1889 F. Holden, C. E. Bean
1890 J. O. Roe, J. H. Hartman
1891 M. J. Asch, S. Johnston
1892 S. Johnston, J. C. Mulhall
1893 J. C. Mulhall, W. E. Casselberry
1894 C. C. Rice, S. H. Chapman
1895 J. Wright, A. W. de Roaldes
1896 T. M. Murray, D. N. Rankin
1897 A. W. MacCoy, H. S. Birkett
1898 J. W. Farlow, F. W. Hinkel
1899 T. A. DeBlois, M. R. Brown
1900 H. L. Wahner, A. A. Bliss
1901 J. W. Gleitsmann, D. Braden Kyle
1902 G. A. Leland, T. Melville Hardie
1903 J. H. Lowman, W. Peyre Porcher
1904 Thomas Hubbard, W. J. Freeman
1905 J. L. Goodale, C. W. Richardson
1906 G. H. Makuen, A. R. Thrasher
1907 J. P. Clark, J. E. Rhodes
1908 E. Mayer, F. R. Packard
1909 C. G. Coakley, H. P. Mosher
1910 Robert C. Myles, J. M. Ingersoll
1911 F. C. Cobb, B. R. Shurly
1912 A. W. Watson, W. Scott Renner
1913 F. E. Hopkins, George E. Shambaugh
1914 Clement T. Theisen, Lewis A. Coffin
1915 J. Gordon Wilson, Christian R. Holmes
1916 Thomas H. Halsted, Greenfield Sluder
1917 John Edwin Rhodes, D. Crosby Greene
1918 George E. Shambaugh, John R. Winslow

1919 Francis R. Packard, Harmon Smith
1920 Harmon Smith, W. B. Chamberlin
1921 Dunbar Roy, Robert C. Lynch
1922 George Fetterolf, Lorenzo B. Lockard
1923 Hubert Arrowsmith, Joseph B. Greene
1924 Ross H. Skillern, Gordon Berry
1925 John E. Mackenty, Robert Levy
1926 Lewis A. Coffin, William V. Mullin
1927 Charles W. Richardson, Hill Hastings
1928 Robert Clyde Lynch, Francis P. Emerson
1929 William B. Chamberlin, Ralph Albert Fenton
1930 Harris P. Mosher, James A. Babbitt
1931 Joseph B. Greene, E. Ross Faulkner
1932 Gordon Berry, Frank R. Spencer
1933 E. Ross Faulkner, Thomas S. Carmody
1934 Gordon B. New, Samuel McCullagh
1935 Edward C. Sewall, H. Marshall Taylor
1936 William P. Wherry, Harold I. Lillie
1937 Frank R. Spencer, Bernard J. McMahon
1938 Ralph A. Fenton, Frederick T. Hill
1939 John H. Foster, Thomas R. Gittins
1940 Charles H. Porter, Gordon F. Harkness
1941 Arthur W. Proetz, Henry B. Orton
1942-3 Harold I. Lillie, Dean M. Lierle
1944-5 John J. Shea, Thomas C. Galloway
1946 H. Marshall Taylor, C. Stewart Nash
1947 John J. Shea, Frederick A. Figi
1948 Henry B. Orton, Anderson C. Hilding
1949 LeRoy A. Schall, Fletcher D. Woodward
1950 W. Likely Simpson, Lyman G. Richards
1951 William J. McNally, Thomas C. Galloway
1952 J. Mackenzie Brown, Edwin N. Broyles
1953 Claude C. Cody, Daniel S. Cunning
1954 James H. Maxwell, Clyde A. Heatly
1955 Robert L. Goodale, Paul H. Holinger
1956 Henry M. Goodyear, Robert E. Priest
1957 Francis E. LeJeune, Pierre P. Viole
1958 Charles Blassingame, Chevalier L. Jackson
1959 James H. Maxwell, Oliver Van Alyea
1960 Walter Theobald, Anderson C. Hilding
1961 Julius W. McCall, P. E. Ireland
1962 Paul M. Moore, Jerome A. Hilger
1963 Paul M. Holinger, Lester A. Brown
1964 B. Slaughter Fitz-Hugh, Daniel C. Baker
1965 C. E. Munoz-MacCormick, Arthur J. Cracovaner
1966 Lawrence R. Boies, G. Edward Tremble
1967 John F. Daly, Stanton A. Friedberg
1968 DeGraaf Woodman, John Murtagh
1969 Joseph P. Atkins, Stanton A. Friedberg
1970 Robert B. Lewy, Oliver W. Suehs
1971 James A. Harrill, James D. Baxter
1972 Francis L. Weille, Sam H. Sanders
1973 William H. Saunders, Blair Fearon
1974 Joseph H. Ogura, Douglas P. Bryce, John A. Kirchner
1975 John S. Lewis, Edwin W. Cocke, Jr
1976 Emanuel M. Skolnik, John T. Dickinson
1977 J. Ryan Chandler, Herbert H. Dedo
1978 John E. Bordley, Lester A. Brown
1979 Albert H. Andrews, Seymour R. Cohen
1980 John Frazer, George A. Sisson

Vice-Presidents (Presidents-Elect)

1981 M. Stuart Strong
1982 John S. Lewis
1983 Gabriel F. Tucker, Jr
1984 Douglas P. Bryce
1985 Loring W. Pratt
1986 Blair Fearon
1987 Seymour R. Cohen
1988 Eugene N. Myers
1989 James B. Snow, Jr
1990 John M. Fredrickson
1991 William R. Hudson
1992 Byron J. Bailey
1993 H. Bryan Neel III

Secretaries and Treasurers

1879 G. M. Lefferts
1882 D. Bryson Delavan
1889 C. H. Knight
1895 H. L. Swain
1900 P. E. Newcomb
1911 Harmon Smith

Secretaries

1912 Harmon Smith
1918 D. Bryson Delavan
1919 J. M. Ingersoll
1920 George M. Coates
1933 William V. Mullin
1935 James A. Babbitt
1939 Charles J. Imperatori
1942 Arthur W. Proetz
1947 Louis H. Clerf
1952 Harry P. Schenck
1957 James H. Maxwell
1959 Lyman G. Richards
1968 Frank D. Lathrop
1972 John F. Daly
1977 William MacL. Trible
1982 Eugene N. Myers
1988 H. Bryan Neel III
1993 Gerald B. Healy

Treasurers

1912 J. Payson Clark
1923 George Fetterolf
1932 William V. Mullin
1933 James A. Babbitt
1935 Charles J. Imperatori
1939 Frederick T. Hill
1948 Gordon F. Harkness
1953 Fred W. Dixon
1958 Francis E. LeJeune
1962 Alden H. Miller
1969 Charles M. Norris
1976 Harold G. Tabb
1981 Loring W. Pratt
1985 John M. Fredrickson
1990 Robert W. Cantrell

Librarians

1879 F. H. Bosworth
1883 T. R. French
1903 J. H. Bryan

1930 John F. Barnhill

1934 Burt R. Shurly

1935 George M. Coates

Librarian and Historian

1936 George M. Coates

1944 Louis H. Clerf

Librarian, Historian and Editor

1947 Harry P. Schenck
1952 Bernard J. McMahon
1955 Edwin N. Broyles
1960 Francis W. Davison
1964 F. Johnson Putney
1971 Charles F. Ferguson
1977 Gabriel F. Tucker, Jr
1983 James B. Snow, Jr
1989 Paul H. Ward

DECEASED FELLOWS

Dates indicate original election to the Association.

Honorary Fellows

1946 Alonso, Justo M., Montevideo, Uruguay
1908 Barnhill, John F., Miami Beach, Fla
1893 Birkett, Herbert S., Montreal
1878 Bosworth, Francke H., New York
1940 Broyles, Edwin N., Baltimore
1917 Coates, George M., Philadelphia
1925 Clerf, Louis H., St Petersburg, Fla
1918 Dean, Lee Wallace, St Louis
1881 Delavan, D. Bryson, New York
1890 De La Sota y Lastra, Ramon, Seville, Spain
1893 de Roaldes, Arthur W., New Orleans
1923 Fenton, Ralph A., Portland, Ore
1879 French, Thomas R., Brooklyn, NY
1936 Galloway, Thomas C., Evanston, Ill
1880 Garcia, Manuel, London
1986 Gould, Wilbur J., New York
1903 Harris, Thomas J., New York
1943 Hilding, Anderson C., Duluth, Minn
1928 Hill, Frederick T., Waterville, Me
1945 Holinger, Paul H., Chicago
1957 Huizinga, Eelco, Groningen, the Netherlands
1907 Jackson, Chevalier, Schwenksville, Pa
1878 Johnston, Samuel, Baltimore
1878 Lefferts, George Morewood, Katonah, NY
1914 Levy, Robert, Denver
1918 Lewis, Fielding O., Media, Pa
1933 Lierle, Dean M., Iowa City
1883 Mackenzie, John N., Baltimore
1881 Mackenzie, Sir Morell, London
1910 Masser, Ferdinand, Naples, Italy
1904 Mosher, Harris P., Marblehead, Mass
1910 Moure, J. J. E., Bordeaux, France
1937 Nager, F. R., Zurich
1930 Negus, Sir Victor E., London
1918 Oliver, H. K., Boston
1957 Ono, Jo, Tokyo
1906 Pierce, Norval Harvey, San Diego
1937 Portmann, Georges, Bordeaux, France
1924 Proetz, Arthur C., St Louis
1957 Ruedi, Luzius, Zurich
1932 Schall, LeRoy A., Boston
1909 Semon, Sir Felix, Great Missenden, England
1878 Solis-Cohen, J., Philadelphia
1973 Som, Max L., New York
1889 Swain, Henry L., New Haven, Conn
1914 Thomson, Sir St Clair, London
1903 Tilley, Herbert, London
1914 Wagner, Clinton, New York
1948 Williams, Henry L., Rochester, Minn
1951 Woodman, DeGraaf, New York
1890 Wright, Jonathan, Pleasantville, NY

Corresponding Fellows

1972 Arslan, Michele, Padua, Italy
1942 Batson, Oscar V., Philadelphia
1938 Blair, Vilray P., St Louis
1892 Browne, Lennox, London
1968 Cawthorne, Sir Terence, London
1964 Cleves, Carlos, Bogota, Colombia
1940 Colledge, Lionel, London
1901 Collier, Mayo, Kearsney Abbey, Kent, England
1893 Desvernine, Carlos M., Havana
1966 Dohlman, Gösta, East Bradenton, Fla
1943 Eggston, Andrew A., New York
1930 Emerson, Francis P., Franklin, Mass
1961 Faaborg-Anderson, Kund, Nykobing, Denmark
1936 Fraser, John S., Edinburgh
1887 Gougenheim, A., Paris
1901 Grant, Sir James Dundas, London
1894 Holden, Edgar, Newark, NJ
1970 Hutcheon, Jack R., Brisbane, Australia
1919 Kelly, Adam Brown, Helensburgh, Scotland
1881 Labus, Carlo, Milan, Italy
1950 Larsell, Olof, Portland, Ore
1931 LaSagna, Francesco, Parma, Italy
1926 Law, Frederick M., New York
1921 LeMaitre, Ferdinand, Paris
1902 Lermoyez, Marcel, Paris
1897 Luc, H., Paris
1970 Macbeth, Ronald G., Oxford, England
1896 MacDonald, Greville, Haslemere, England
1894 MacIntyre, John, Glasgow, Scotland
1903 McBride, P., York, England
1920 McKenzie, Dan, London
1919 McKernon, James F., New Canaan, Conn
1880 Meyer, Wilhelm, Copenhagen
1896 Mygind, Holger, Copenhagen
1950 Neil, James Hardie, Auckland, New Zealand
1919 Paterson, Donald Rose, Cardiff, Wales
1941 Patterson, Norman, Herts, England
1971 Rethi, Aurelius, Budapest
1919 Rogers, John, Jr, New York
1894 Sajous, C. E. DeM., Philadelphia
1924 Schaefer, J. Parson, Philadelphia
1896 Schmiegelow, Ernst, Copenhagen
1946 Segura, Eliseo, Buenos Aires
1940 Soto, E. Fernandez, Havana
1881 Thornton, Pugin, London
1913 Turner, A. Logan, Edinburgh
1936 Vialle, Jacques, Nice, France
1880 Whistler, W. McNeil, London
1901 Wingrave, Wyatt, Lyme Regis, England
1894 Wolfenden, R. Norric, Kent, England

Emeritus Fellows

1962 Arnold, Godfrey E., Clinton, Miss
1936 Ballenger, Howard C., Winnetka, Ill
1923 Barlow, Roy A., Nova Scotia, Canada
1915 Barnes, Harry Aldrich, Kingston, Mass
1944 Beatty, Hugh G., Columbus, Ohio
1928 Beck, Joseph C., Chicago
1921 Berry, Gordon, Worcester, Mass
1944 Boies, Lawrence R., Minneapolis
1955 Bordley, John E., Baltimore
1941 Bowers, Wesley C., New York
1901 Brown, J. Price, Toronto
1955 Brown, Lester A., Atlanta

1891 Bryan, Joseph H., Washington, DC
1913 Butler, Ralph, Philadelphia
1930 Campbell, Edward H., Philadelphia
1945 Campbell, Paul A., San Antonio, Tex
1942 Canfield, Norton, Miami
1959 Cardwell, Edgar P., Newark, NJ
1897 Clark, J. Payson, Boston
1899 Cobb, Frederick C., Bradenton, Fla
1939 Cody, Claude C., Jr, Houston
1905 Coffin, Lewis A., New York
1957 Converse, John Marquis, New York
1893 Coolidge, Algernon, Boston
1959 Cracovaner, Arthur J., New York
1937 Crowe, Samuel H., Baltimore
1941 Cunning, Daniel S., New York
1913 Dabney, Virginia, Washington, DC
1951 Davison, Francis W., Danville, Pa
1882 De Blois, Thomas Amory, Boston
1968 DeWeese, David D., Portland, Ore
1941 Dixon, Fred W., Shaker Heights, Ohio
1947 Eagle, Watt W., New Bern, NC
1952 Erich, John B., Rochester, Minn
1892 Farlow, John W., Boston
1930 Figi, Frederick A., Rochester, Minn
1955 Fitz-Hugh, G. Slaughter, Charlottesville, Va
1922 Forbes, Henry H., New York
1933 Foster, John H., Houston
1905 Freer, Otto T., Chicago
1932 Furstenberg, Albert C., Ann Arbor, Mich
1940 Gatewood, E. Trible, Richmond, Va
1928 Gittins, Thomas R., Sioux City, Iowa
1880 Gleitsmann, Joseph W., New York
1959 Goldman, Joseph L., New York
1922 Goldsmith, Perry G., Toronto
1898 Goodale, Joseph L., Ipswich, Mass
1940 Goodale, Robert L., Ipswich, Mass
1965 Goodyear, Henry M., Cincinnati
1932 Graham, Harrington B., San Francisco
1906 Greene, D. Crosby, Jr, Boston
1917 Greene, Joseph B., Asheville, NC
1950 Hall, Colby, Encino, Calif
1970 Halliday, Sir George C., Sydney, Australia
1905 Halsted, Thomas H., Los Angeles
1940 Hansel, French K., St Louis
1896 Hardie, Thomas Melville, Chicago
1960 Harris, Herbert H., Houston
1959 Hart, Verling K., Charlotte, NC
1915 Hastings, Hill, Los Angeles
1944 Havens, Fred Z., Rochester, Minn
1959 Henry, G. Arnold, Lagoon City, Canada
1888 Hinkel, Frank Whitehill, Buffalo
1944 Hoople, Gordon D., Syracuse, NY
1895 Hopkins, Frederick E., Springfield, Mass
1930 Houser, Karl M., Ardmore, Pa
1927 Hubbard, Thomas, Toledo
1919 Hurd, Lee Maidment, Rowayton, Conn
1920 Imperatori, Charles J., Essex, NY
1904 Ingersoll, John Marvin, Miami
1952 Ireland, Percy E., Toronto
1928 Jarvis, DeForest C., Barre, Vt
1939 Johnston, William H., Santa Barbara, Calif
1942 Kelly, Joseph D., New York
1918 Kenyon, Elmer L., Chicago
1921 Kernan, John D., New York
1965 King, James T., Atlanta
1929 Kistner, Frank B., Portland, Ore
1950 Kline, Oram R., Woodbury Heights, NJ
1885 Knight, Charles H., New York
1939 Large, Secord H., Cleveland
1963 Lathrop, Frank D., Pittsford, Vt
1939 LeJeune, Francis E., New Orleans
1894 Leland, George A., Boston
1922 Lillie, Harold I., Rochester, Minn
1943 Lincoln, William R., Cleveland
1949 Lindsay, John R., Evanston, Ill
1927 Lukens, Robert M., Wildwood Crest, NJ
1928 Lyman, Harry Webster, St Louis
1886 MacCoy, Alexander W., Philadelphia
1928 MacPherson, Duncan, New York
1941 Martin, Robert C., San Francisco
1896 Mayer, Emil, New York
1952 McCall, Julius W., Shaker Heights, Ohio
1951 McCart, Howard W. D., Toronto
1939 McCaskey, Carl H., Indianapolis
1943 McCullagh, Samuel, New York
1963 McGovern, Francis H., Danville, Va
1951 McHenry, Lawrence C., Oklahoma City
1923 McKinney, Richmond, Memphis
1933 McMahon, Bernard J., St Louis
1931 McNally, William J., Montreal
1952 Miller, Alden H., Glendale, Calif
1965 Miller, Daniel, Boston
1954 Moore, Paul McN., Delray Beach, Fla
1957 Munoz-MacCormick, Carlos E., Santurce, PR
1953 Murtagh, John A., Hanover, NH
1939 Myers, John L., Kansas City, Mo
1927 Myerson, Mervin C., New York
1901 Myles, Robert C., New York
1937 Nash, C. Stewart, Rochester, NY
1922 New, Gordon B., Rochester, Minn
1923 Newhart, Horace, Minneapolis
1958 O'Keefe, John J., Philadelphia
1903 Packard, Francis R., Philadelphia
1961 Pang, Lup Q., Honolulu, HI
1961 Pastore, Peter N., Richmond, Va
1948 Phelps, Kenneth A., Burlington, NC
1878 Porter, William, Ocean Springs, Mass
1942 Potts, John B., Omaha
1951 Rawlins, Aubrey G., San Francisco
1903 Renner, W. Scott, Buffalo
1897 Rhodes, John Edwin, Chicago
1884 Rice, Clarence C., New York
1905 Richards, George L., South Yarmouth, Mass
1956 Richardson, John R., Searsport, Me
1878 Robinson, Beverly, New York
1938 Salinger, Samuel, Palm Springs, Calif
1959 Sanders, Sam H., Memphis
1921 Sauer, William E., St Louis
1934 Schenck, Harry P., Philadelphia
1923 Sewall, Edward C., Palo Alto, Calif
1930 Seydell, Ernest M., Wichita, Kan
1907 Shambaugh, George E., Chicago
1939 Simpson, W. Likely, Memphis
1987 Skolnik, Emanuel M., Chicago
1950 Smith, Austin T., Philadelphia
1908 Smith, Harmon, New York
1954 Sooy, Francis A., San Francisco
1923 Spencer, Frank R., Boulder, Colo
1947 Theobald, Walter H., Chicago
1927 Tobey, Harold G., Boston
1950 Tremble, G. Edward, Montreal
1925 Tucker, Gabriel, Haverford, Pa

1943 Van Alyea, Oliver E., Chicago
1941 Violé, Pierre, Los Angeles
1892 Wagner, Henry L., San Francisco
1892 Watson, Arthur W., Philadelphia
1948 Whalen, Edward J., Hartford, Conn
1922 White, Francis W., New York
1939 Wilson, J. Gordon, Old Bennington, Vt
1905 Wood, George B., Wynnewood, Pa
1935 Woodward, Fletcher D., Charlottesville, Va

Active Fellows

1958 Alfaro, Victor R., Washington, DC
1880 Allen, Harrison, Philadelphia
1969 Andrews, Albert H., Jr, Chicago
1917 Arrowsmith, Hubert, Brooklyn, NY
1879 Asch, Morris J., New York
1942 Ashley, Rae E., San Francisco
1958 Atkins, Joseph P., Philadelphia
1923 Babbitt, James A., Philadelphia
1906 Ballenger, William L., Chicago
1880 Bean, C. E., St Paul
1949 Beck, August L., New Rochelle, NY
1904 Berens, T. Passmore, New York
1924 Bigelow, Nolton, Providence, RI
1938 Blassingame, Charles D., Memphis
1893 Bliss, Arthur Ames, Philadelphia
1951 Boyden, Guy L., Portland, Ore
1895 Boylan, J. E., Cincinnati
1932 Brown, John Mackenzie, Los Angeles
1892 Brown, Moreau R., Chicago
1933 Buckley, Robert E., New York
1915 Canfield, R. Bishop, Ann Arbor, Mich
1934 Carmack, John Walter, Indianapolis
1924 Carmody, Thomas E., Denver
1889 Casselberry, William E., Chicago
1883 Chamberlain, C. W., Hartford, Conn
1917 Chamberlin, William B., Cleveland
1882 Chapman, S. Hartwell, New Haven, Conn
1896 Chappell, W. F., New York
1902 Coakley, Cornelius G., New York
1913 Coffin, Rockwell C., Boston
1918 Cox, Gerald H., New York
1880 Cushing, E. W., Boston
1878 Cutter, Ephraim, West Falmouth, Mass
1880 Daly, W. H., Pittsburgh
1878 Davis, F. H., Chicago
1941 Davis, Warren B., Philadelphia
1926 Dennis, Frank Lownes, Colorado Springs, Colo
1901 Dickerman, E. T., Chicago
1969 Dickinson, John T., Pittsburgh
1878 Donaldson, Frank, Baltimore
1954 Equen, Murdock S., Atlanta
1935 Eves, Curtis C., Philadelphia
1919 Faulkner, E. Ross, New York
1914 Fetterolf, George, Philadelphia
1901 Freeman, Walter J., Philadelphia
1917 Friedberg, Stanton A., Chicago
1897 Frothingham, Richard, New York
1940 Fuchs, Valentine H., New Orleans
1909 Getchell, Albert C., Worcester, Mass
1907 Gibb, Joseph S., Philadelphia
1940 Gill, William D., San Antonio, Tex
1878 Glasgow, William Carr, St Louis
1913 Goldstein, Max A., St Louis
1905 Grayson, Charles P., Philadelphia
1934 Grove, William E., Milwaukee
1933 Harkness, Gordon F., Davenport, Iowa
1957 Harrill, James A., Winston-Salem, NC
1878 Hartman, J. H., Baltimore
1945 Hickey, Harold L., Denver
1879 Holden, Edgar, Newark, NJ
1907 Holmes, Christian R., Cincinnati
1882 Hooper, Franklin H., Boston
1893 Hope, George B., New York
1938 Hourn, George E., St Louis
1939 Hunt, Westley Marshall, New York
1901 Hyatt, Frank, Washington, DC
1925 Iglauer, Samuel, Cincinnati
1878 Ingals, E. Fletcher, Chicago
1882 Ives, Frank L., New York
1938 Jackson, Chevalier L., Philadelphia
1880 Jarvis, William C., New York
1878 Johnson, Hosmer A., Chicago
1879 Johnson, Woolsey, New York
1960 Johnston, Kenneth C., Chicago
1961 Jones, Edley H., Vicksburg, Miss
1944 Jones, Marvin F., New York
1879 Kealhofer, R. H., St Louis
1964 Keim, W. Franklin, Montclair, NJ
1942 King, Edward D., North Hollywood, Calif
1901 King, Gordon, New Orleans
1878 Knight, Frederick Irving, Boston
1965 Knight, John S., Kansas City, Mo
1898 Kyle, D. Braden, Philadelphia
1880 Langmaid, Samuel W., Boston
1953 Lederer, Francis L., Chicago
1878 Lincoln, Rufus P., New York
1911 Lockard, Lorenzo B., Denver
1913 Loeb, Hanau W., St Louis
1897 Logan, James E., Kansas City, Mo
1935 Looper, Edward A., Baltimore
1888 Lowman, John H., Cleveland
1919 Lynah, Henry L., New York
1952 Lynch, Mercer G., New Orleans
1915 Lynch, Robert Clyde, New Orleans
1914 Mackenty, John E., New York
1881 Major, G. W., Montreal
1898 Makuen, G. Hudson, Philadelphia
1948 Maxwell, James H., Ann Arbor, Mich
1879 McBurney, Charles, New York
1927 McGinnis, Edwin, Chicago
1936 McGregor, Gregor, Toronto
1913 McKimmie, O. A., Washington, DC
1945 McLaurin, John G., Dallas
1885 McSherry II, Clinton, Baltimore
1954 Meltzer, Philip E., Boston
1958 Montreuil, Fernand, Montreal
1881 Morgan, E. C., Washington, DC
1950 Morrison, Lewis F., San Francisco
1940 Morrison, William W., New York
1886 Mulhall, J. C., St Louis
1925 Mullin, William V., Cleveland
1914 Munger, Carl E., Waterbury, Conn
1892 Murray, T. Morris, Washington, DC
1881 Mynter, H., Buffalo
1893 Newcomb, James E., New York
1895 Nichols, J. E. H., New York
1961 Ogura, Joseph H., St Louis
1927 Orton, Henry B., Newark, NJ

1894 Park, William H., New York
1892 Porcher, W. Peyre, Charleston, SC
1927 Porter, Charles T., Boston
1954 Pressman, Joel J., Los Angeles
1908 Randall, B. Alexander, Philadelphia
1882 Rankin, D. N., Allegheny, Pa
1934 Richards, Lyman G., Wellesley Hills, Mass
1902 Richardson, Charles W., Washington, DC
1930 Ridpath, Robert E., Philadelphia
1945 Robb, James M., Detroit
1953 Roberts, Sam E., Kansas City, Mo
1881 Robertson, J. M., Detroit
1879 Roe, John O., Rochester, NY
1913 Roy, Dunbar, Atlanta
1878 Rumbold, T. F., St Louis
1879 Seiler, Carl, Philadelphia
1928 Shea, John Joseph, Memphis
1893 Shields, Charles M., Richmond, Pa
1909 Shurly, Burt R., Detroit
1878 Shurly, E. L., Detroit
1959 Silcox, Louis E., Punta Gorda, Fla
1892 Simpson, William Kelly, New York
1919 Skillern, Ross H., Philadelphia
1909 Sluder, Greenfield, St Louis
1879 Smith, Andrew H., Geneva, NY
1932 Smyth, Duncan Campbell, Boston
1928 Sonnenschein, Robert, Chicago
1911 Staut, George C., Philadelphia
1924 Stein, Otto J., Chicago
1934 Stevenson, Walter, Quincy, Ill
1879 Tauber, Bernhard, Cincinnati
1924 Taylor, Hermon Marshall, Jacksonville, Fla
1903 Theisen, Clement F., Albany, NY
1899 Thorner, Max, Cincinnati
1892 Thrasher, Allen B., Cincinnati
1937 Tobey, George L., Jr, Boston
1967 Trible, William M., Washington, DC
1970 Tucker, Gabriel F., Jr, Chicago
1938 Vail, Harris H., Cincinnati
1888 Van der Poel, S. O., New York
1936 Voislawsky, Antonie P., New York
1954 Walsh, Theodore E., St Louis
1933 Wanamaker, Allison T., Seattle
1896 Ward, Marshall R., Pittsburgh
1879 Ward, Whitfield, New York
1886 Westbrook, Benjamin R., Brooklyn, NY
1924 Wherry, William P., Omaha
1924 White, Leon E., Boston
1953 Wilderson, William W., Nashville, Tenn
1939 Williams, Horace J., Philadelphia
1942 Wishart, D. E. Staunton, Toronto
1922 Wishart, David J. G., Toronto
1896 Wollen, Green V., Indianapolis
1940 Wood, V. Visscher, St Louis

ROSTER OF FELLOWS
1994

Date indicates year admitted to active fellowship. Attendance at meetings is shown by dates following each name. Asterisk indicates year paper was read. Year and asterisk in parentheses indicates coauthor of paper but not present at meeting.

Active Fellows — 105

1994 Abemayor, Elliot, 10833 Le Conte Ave, Rm 62-132 CHS, Los Angeles, CA 90095, '94.

1987 Adkins, Warren Y., 1-N Clin Sci Bldg, 171 Ashley Ave, Charleston, SC 29425-0001, 1987, '89, '91, '92, '93.

1974 Alford, Bobby R., One Baylor Plaza, Houston, TX 77030, 1974, '78, '80-'83, '85-'87, '89, '91.

1984 Applebaum, Edward L., 1855 W Taylor St, Chicago, IL 60612, 1984-'87*, '88*-'93.

1975 Bailey, Byron J., Dept of Otolaryngol, UTMB, Galveston, TX 77550, 1975, '76*-'78, '81, '82, '84-'91, '93, '94.

1987 Baker, Shan R., 1500 E Medical Center Dr, Ann Arbor MI 48109-0312, 1987.

1993 Berke, Gerald S., 10833 Le Conte, Los Angeles, CA 90024-1300, 1993*, '94*.

1975 Biller, Hugh F., Mt Sinai Hosp, 100th St & Fifth Ave, New York, NY 10029, 1975-'77*, '79*, '80*, '81*, '82*, '83*, '84*, '85, '86*, '87*, '88*, '89*, '90, '92, '93, ('94*).

1988 Birt, B. Derek, 2075 Bayview Ave, Toronto, Ont, M4N 3M5, Canada, 1988, '90.

1977 Blaugrund, Stanley M., 115 E 61st St, New York, NY 10021, 1977-'84*-'89*-'92*, '93.

1987 Blitzer, Andrew, 630 W 168th St, New York, NY 10032, 1987, '88*, '89*, '90*-'92*, '94.

1984 Bone, Robert C., 10666 N Torrey Pines Rd, La Jolla, CA 92037, 1984, '86*, '88, '90.

1976 Briant, Thomas D. R., 30 Bond St, Toronto, Ont, M5B 1W8, Canada, 1976, '77, '78, '80-'82, '85-'90, '92, '94*.

1994 Broniatowski, Michael, 2351 E 22nd, Cleveland, OH 44115-3111, '94.

1979 Calcaterra, Thomas C., UCLA Med Ctr, Los Angeles, CA 90024, 1979, '85, '87, '88*, '89*-'93.

1994 Caldarelli, David, 1725 W Harrison, 308, Chicago, IL 60612, '94.

1985 Canalis, Rinaldo F., Head and Neck Surg, UCLA Med Ctr, 62-158, Los Angeles, CA 90024, 1985, '89, '91, '94.

1976 Cantrell, Robert W., Univ of Virginia Med Ctr, Box 430, Charlottesville, VA 22901, 1976, '77*-'80*-'84*-'88*-'94.

1994 Cassisi, Nicholas J., Health Science Center, Box 100284, Gainesville, FL 32610-0264, '94.

1985 Chodosh, Paul L., 99 North Ave, Hillside, NJ 07208, 1985, '86, '88*, '89.

1993 Close, Lanny G., 5323 Harry Hines Blvd, Dallas, TX 75235-7200, 1993.

1992 Cotton, Robin T., Children's Hospital Med Ctr ASB-3, Cincinnati, OH 45229-2899, 1992.

1988 Coulthard, Stanley W., 1501 N Campbell Ave, Tucson, AZ 85724, 1988.

1984 Crumley, Roger L., 101 City Dr S, Bldg 25, Orange, CA 92668, 1984*, '86-'88*-'92*-'94.

1980 Cummings, Charles W., 600 N Wolfe St, Baltimore, MD 21205, 1980-'82*, '83*-'91*, '92*, '93*, '94*.

1973 Dedo, Herbert H., 711 Eucalyptus Ave, Hillsborough, CA 94010, 1973*-'75*, '76*-'79*-'82*-'84*, '86*-'90*, '91*, '93, '94.

1984 DeSanto, Lawrence W., 13400 E Shea Blvd, Scottsdale, AZ 85259, 1984, '88*, '90*, '93.

1982 Fee, Willard E., Jr, Stanford Medical Ctr, R135, Stanford, CA 94305, 1982-'87*-'94.

1990 Ford, Charles N., UW-CSC, H4/320, 600 Highland Ave, Madison, WI 53792, 1990, '91*-'93.

1977 Fredrickson, John M., 517 S Euclid Ave, St Louis, MO 63110, 1977-'79*, '83-'87*-'94.

1989 Fried, Marvin P., 333 Longwood Ave, Boston, MA 02115, 1989, '90*, '92.

1977 Gacek, Richard R., 750 E Adams St, Syracuse, NY 13210, 1977*-'83*, '84*-'87*-'94.

1981 Gates, George A., 1325 Fourth Ave, S 2000, Seattle, WA 98101, 1981, '82*-'85*-'89*-('91*), '92*-'94.

1991 Gluckman, Jack L., 231 Bethesda Ave, Cincinnati, OH 45267-0528, 1991, '93.

1983 Goldstein, Jerome C., One Prince St, Alexandria, VA 22314, 1983-'93.

1985 Goode, Richard L., 300 Pasteur Dr, R135, Palo Alto, CA 94304, 1989, '92, '93.

1985 Gross, Charles W., Univ VA Health Sci Ctr, Box 430, Charlottesville, VA 22908-0001, 1985-'89, '91-'94.

1991 Gullane, Patrick J., 200 Elizabeth St, EN 7-242, Toronto, Ont, M5G 2C4, Canada, 1991, '93.

1988 Hanson, David G., 12-580 Searle Bldg, 303 E Chicago Ave, Chicago, IL 60611-3008, 1988, '90, '93, '94.

1987 Hawkins, Donald B., 1200 N State St, Box 296, Los Angeles, CA 90033, 1987, '90, '91, '93, '94.

1983 Healy, Gerald B., 300 Longwood Ave, Boston, MA 02115, 1983, '84*, '85*-'93*, '94*.

1983 Hicks, Julius N., 1501 Fifth Ave S, Birmingham, AL 35233, 1983, '84*-'93.

1986 Holinger, Lauren D., 2300 Children's Plaza, Box 25, Chicago, IL 60614, 1986, '87*-'89*-'94.

1994 Holt, G. Richard, 540 Madison Oak, 450, San Antonio, TX 78258.

1974 Hudson, William R., Duke Univ Med Ctr, Box 3805, Durham, NC 27710, 1974-'78*, '81-'94.

1983 Jako, Geza J., Eight Porter St, Melrose, MA 02176, 1983, '85, '87*, '88, '94.

1983 Johns, Michael E., 600 N Wolfe St, Baltimore, MD 21205, 1983, '84*-'87*-'91, '93.

1990 Johnson, Jonas T., 203 Lothrop St, 500, Pittsburgh, Pa 15213, 1990*, '91*, ('92*), '93*.

1985 Kashima, Haskins K., 600 N Wolfe St, Baltimore, MD 21205, 1985, '86*-'89*, '91*, '92*, '93*, '94.

1993 Komisar, Arnold, 1317 Third Ave, 10th Fl, New York, NY 10021, 1993, '94.

1991 Koufman, James A., 300 S Hawthorne Rd, Winston-Salem, NC 27103, '91*, '92, '93*.

1979 Krause, Charles J., 1500 E Medical Center Dr, Ann Arbor, MI 48109-0312, 1979-'82*, '84-'87*, '88, '90, '91.

1981 Lawson, William, Mount Sinai Hosp, Fifth Ave and 100th St, Box 1189, New York, NY 10029, 1981*-'84*, '86*, '88*, '89*.

1988 Levine, Howard L., 29001 Cedar Rd, 307, Lyndhurst, OH 44124, 1988*, '89*, '90, '93.

1992 Lowry, Louis D., 909 Walnut St, Philadelphia, PA 19107-5211, 1992-'94.

1987 Lucente, Frank E., Long Island College Hosp, Brooklyn, NY 11201, 1987, '88*, '89*-'91, '93*, '94.

1987 Maisel, Robert H., 701 Park Ave S, Minneapolis, MN 55415, 1988-'91*-'94.

1989 Maniglia, Anthony J., 2074 Abington Rd, Cleveland, OH 44106, 1989*-'93.

1990 Marsh, Bernard R., Johns Hopkins Hosp, POB 41402, Baltimore, MD 21203, 1990-'93.

1988 Mathog, Robert H., 540 E Canfield Ave, Detroit, MI 48201, 1988, '89*, '90, '93.

1989 McCaffrey, Thomas V., 200 First St SW, Rochester, MN 55905, 1989*, '90*, ('91*), '93, '94.

1990 McGuirt, William F., 300 S Hawthorne Rd., Winston-Salem, NC 27103, 1990, '91*-'94.

1993 Medina, Jesus E., Univ of Oklahoma Health Science Ctr, 3SP-224, PO Box 26901, Oklahoma City, OK 73126, 1993.

1987 Miller, Robert H., 1430 Tulane Ave, New Orleans, LA 70112, 1987-'93.

1986 Morrison, Murray D., 805 W 12th St, Vancouver, BC V5Z 1M9, Canada, 1986, '87*-'91*, '93.

1979 Myers, Eugene N., 230 Lothrop St, 500, Pittsburgh, PA 15213, 1979, '80, '82*-'89*, '90*, '91*-'93*, '94.

1981 Neel, H. Bryan III, 200 First St SW, Rochester, MN 55905, 1981, '82*-'85*-'88*, '89*-'94.

1994 Netterville, James L., Vanderbilt Univ Med Ctr, Dept of Otolaryngology, S-2100 MCN, Nashville, TN 37232-2559, ('94*).

1980 Nichols, Richard D., 2799 W Grand Blvd, Detroit, MI 48202, 1980, '81, '84, '87-'89*, '90, '92.

1986 Noyek, Arnold M., 600 University Ave, 401, Toronto, Ont, M5G 1X5, Canada, 1986, '87, '89*, '93, '94.

1982 Olson, Nels R., 2950 Newport, Ann Arbor, MI 48103, 1982, '83*, '85, '87, '88, '90*, '93.

1990 Osguthorpe, John D., 171 Ashley Ave, Charleston, SC 29425-2422, 1990, '92-'94.

1990 Ossoff, Robert H., Vanderbilt Univ Med Ctr, MCN S-2100, Nashville, TN 37232, 1990*, '91*, '92*, '93*, ('94*).

1988 Panje, William R., 5841 S Maryland Ave, Chicago, IL 60637, 1988, '92, ('94*).

1988 Pearson, Bruce W., 4500 San Pablo Rd, Jacksonville, FL 32224, 1988*, '90.

1989 Pillsbury, Harold C., 610 Burnett-Womack Bldg, Univ of North Carolina, Chapel Hill, NC 27514, 1989, '90, '93.

1985 Rice, Dale H., 1510 San Pablo St, Los Angeles, CA 90033, 1985-'88*-'91*-'93, ('94*).

1992 Richtsmeier, William J., Duke Univ Medical Center, Dept of Otolaryngol, PO Box 3805, Durham, NC 27710, 1992-'94.

1982 Rontal, Eugene, 21700 Northwestern Hwy, 545, Tower 14, Southfield, MI 48705, 1982, ('83*), '84*, '86*, '90*, '93*.

1981 Sasaki, Clarence T., 333 Cedar St, New Haven, CT 06510, 1981, '83, '85-'88, '90*, '93*, '94.

1992 Schaefer, Steven D., Dept of Otorhinolaryngol, New York Medical College, Valhalla, NY 10595, 1992.

1992 Schechter, Gary L., 825 Fairfax Ave, Norfolk, VA 23507-1912, 1992-'94.

1984 Schild, Joyce A., 1855 W Taylor St, 2.42, Chicago, IL 60612, 1985*-'88*-'90*-'94.

1987 Schuller, David E., 456 Clinic Dr, Columbus, OH 43210, 1987, '88*, '89*-'92.

1978 Sessions, Donald G., 1960 Grassy Ridge Rd, Kirkwood, MO 63122, 1979*, '80*, '81, '83, '84, '86, '87*-('91*), '93.

1983 Sessions, Roy B., 3800 Reservoir Rd NW, Washington, DC 20007, 1983*, '86, '87, '89*, '90, '92, '93, ('94*).

1990 Shapshay, Stanley M., 41 Mall Rd, Burlington, MA 01805, 1990*-'92, ('94*).

1988 Singer, Mark I., 1600 Divisadero St, San Francisco, 94120, 1988, '89*-'91*, '92, ('94*).

1974 Snow, James B., Jr, NIDCD, NIH, Bethesda, MD 20892, 1974, '75*-'78*, '79, '81-'94.

1979 Spector, Gershon J., 517 S Euclid Ave, St Louis, MO 63110, 1979-'85, '88-'90, '92.

1991 Strome, Marshall, 333 Longwood Ave, Boston, MA 02115, 1992, '93*.

1979 Tardy, M. Eugene, 2913 N Commonwealth, 430, Chicago, IL 60657, 1979, '82*, '84, '86.

1982 Thawley, Stanley E., 517 S Euclid Ave, St Louis, MO 63110, 1982, '83*.

1989 Toohill, Robert J., 8700 W Wisconsin Ave, Box 199, Milwaukee, WI 53226, 1989, '90, '93*.

1979 Tucker, Harvey M., 9500 Euclid Ave, Cleveland, OH 44195, 1979, '80*-'82*, '84*, '85*, '86*, '87*, '88*, '89*, '90*-'93*.

1973 Tucker, John A., 2nd Fl Paley Bldg-ENT, 5501 Old York Rd, Philadelphia, PA 19141, 1973*, '74*, '75*-'77*, '78*, '80-'85*-'88*, '89*, '90*, '91*-'93*, '94.

1984 Vaughan, Charles W., 150 S Huntington Ave, Boston, MA 02130, 1984-'86, '88*, '90*, ('91*), '92, '94.

1980 Vrabec, Donald P., Geisinger Med Ctr, Danville, PA 17821, 1980, '81*, '83, '86-'90, '93, '94.

1974 Ward, Paul H., UCLA School of Med, 62-215 Ctr Health Sci, Los Angeles, CA 90024, 1974*-'77*, '78*, '79*, '81*, '82*, '83*, '84*-'86*-'88*-'90*, '91*, '92*-'94.

1991 Weisberger, Edward C., 702 Barnhill Dr, A-56, Indianapolis, IN 46202.

1994 Wenig, Barry, 1855 W Taylor M/C 648, Chicago, IL 60612.

1989 Weymuller, Ernest A., Jr, Dept of Otolaryngol, RL-30, Univ of Washington Med School, Seattle, WA 98195, 1989*, '91-'93*, '94.

1994 Woodson, Gayle E., 956 Court, Rm B210, Memphis, TN 38163, '94.

1981 Yanagisawa, Eiji, 98 York St, New Haven, CT 06511, 1981, '82*, '83*-'85*, '87*, '88*, '89*, '90*, '91*-'94.

1983 Yarington, C. Thomas, Jr, 1100 Ninth Ave, POB 900, Seattle, WA 98111, 1983, '84*-'89*, '92*, '93.

Honorary Fellows — 8

1992 Aschan, Gunnar K., Repslagaregatan 34, S582 22 Linköping, Sweden, 1992.

1978 (1959) Barretto, Plinio de Mattos, Rua Cons Torres Homen 371, 01432 Sao Paulo, Brazil, 1960, '69, '73, '80.

1990 Bocca, Ettore, Vle Regina Giovanna 15, Milano 20129, Italy.

1984 (1957) Conley, John J., 212 Central Park West, New York, NY 10024, 1958*, '60*-'62*, '64, '65, '70, '72, '74*, '75*-'78, '80, '82, ('83*)-'86, '89.

1984 (1960) Daly, John F., 1500 Palisade Ave, Fort Lee, NJ 07024, 1960, '61*, '79*, '81.

1978 (1971) Harrison, D. F. N., 330/332 Gray's Inn Rd, London, WCIX 8EE, England, 1971, '77, '81*, '84*-'86*, '90*.

1991 (1963) Kirchner, John A., 333 Cedar St, New Haven, CT 06510, 1963, '65*, '67*-'69*-'71*-'75*, '77, '78, '80*, '82-'84*-'89*, '90*, '93, '94.

1984 (1956) Norris, Charles M., 3401 N Broad St, Philadelphia, PA 19140, 1956-'58*-'61*-'64, '66-'68*-'70*-'78*-'86, '88, '90.

Corresponding Fellows — 29

1991 Andrea, Mario, Av da Republica, 30-2°-D, 1000 Lisbon, Portugal, 1991*.

1985 Aprigliano, Flavio, Rua Terezina 19, ZC-45 20,000 Rio de Janeiro, Brazil, 1985, '88, '90*.

1978 Arauz, Juan Carlos, J. E. Uriburu 1252-3°D, 1114 Buenos Aires, Argentina, 1980, '85*, '89.

1959 Bateman, Sir Geoffrey H., Thorney-Graffham, Petworth, West Sussex, GU28 0GA United Kingdom.

1980 Benjamin, Bruce, 229 Macquarie St, Sydney, NSW, 2000 Australia, 1980, '81, '83*, '84*, '85*, '87*, '92*, '93*.

1991 Bradley, Patrick J., Queen's Medical Center, Nottingham, NG7 2UH, England, 1992*, '93*.

1993 Brasnu, Daniel F., Hopital Laennec, 42 Rue de Sevres, 75007 Paris, France, 1993.

1984 Evans, John N. G., 55 Harley St, London W1N 1DD, United Kingdom, 1985*, '90, '93.

1986 Ferlito, Alfio, Dept of Otolaryngol, Univ of Padua, Nuovo Policlinico, Via Giustiniani 2, 35128 Padua, Italy, 1986*, '87*-'89*, '90*, '93*.

1986 Fonseca, Rolando, Hosp de Clinicas, Jose de San Martin, Cordoba 2351, Buenos Aires, Argentina.

1994 Gregor, Reinhold, Plesmanlaan 121, 1066 CX Amsterdam, the Netherlands, '94.

1984 Hirano, Minoru, Dept of Otolaryngol–Head and Neck Surg, Kurume Univ, 67 Asahi-machi, Kurume-shi 830, Japan, 1985*, '86*, '87*, '88*, '89*, '90*, '91*, '92*, '93*.

1991 Hisa, Yasuo, Dept of Otolaryngol, Kyoto Prefectural Univ Medicine, Kawaramachi-Hirokoji, Kyoto 602, Japan, 1992*, '94*.

1993 Howard, David J., Royal National ENT Hospital, 330 Gray's Inn Rd, London WC1XS DA, England, 1993.

1985 Inouye, Tetsuzo, Dept of Otolaryngol, National Defense Med College, 3-2 Namiki, Tokorozawa, Saitama, Japan, 1985, '87, '88*, '89*, '92*, '93*.

1988 Isshiki, Nobuhiko, 3F, 18-1 Unrin-in-cho, Murasakino, Kitaku, Kyoto 603, Japan, 1988*, '89*, '90*, '91*, '92.

1988 Kim, Kwang-Moon, Dept of Otolaryngol, Yonsei Univ, Yongdong Severeance Hosp, Yongdong, PO Box 1217, Seoul, Korea, 1990.

1978 Kleinsasser, Oskar, Deutschhausstrasse 3, D-3550 Marburg (Lahn), Germany, 1982*, '88, '89*.

1992 Ludlow, Christy L., NIH, 9000 Rockville Pike, Bethesda, MD 20892, 1992, '93*.

1993 Mann, Wolf J., Univ HNO-Klinik, Lagenbeck-Str 1, Mainz, Germany D6500, 1993, ('94*).

1985 Murakami, Yasushi, Dept of Otolaryngol, Kyoto Prefectural Univ Medicine, Kawaramachi, Hirokoji Kamikyo-ku, Kyoto 602, Japan, 1985*, '86*, '87, '90*, ('92*).

1968 Nakamura, Fumio, Kyoto Prefectural Univ Medicine, Kawara-Machi, Kamikyo-ku, Kyoto, Japan.

1964 Perez, Alfredo C., Instituto Celis Perez, Avenida Montes Deoca, Valencia, Venezuela, 1965.

1989 Price, Brandon J., Quality Biologics, Inc, Copewood St, Camden, NJ 08103.

1985 Shaw, Henry J., Lislee House, Tredenham Rd, St Mawes, Cornwall TR2 5AN, England, 1986, '90*.

1984 Snow, Gordon B., Dept of Otolaryngol, Free Univ Hosp, De Boelelaan 1117, 1081 HV, Amsterdam, the Netherlands, 1983*, '85, '86*, '90.

1952 Tapia-Acuna, Ricardo, Av Insurgentes Sur No. 300, Delegacion Cuauhtemoc, 06700, Mexico 7 DF, 1953, '57, '60*, '67, '73, '75, '81*.

1991 Thumfart, Walter F., Joseph-Stelzmann-Str 9, D-5000, Köln 41, Germany, 1991, '93*, '94*.

1987 Tu, Gui-yi, Dept of Head and Neck Surg, Cancer Hosp, PO Box 2258, Beijing, People's Republic of China, 1987*.

Emeritus Fellows — 57

1984 (1969) Ausband, John R., 1365 Clifton Rd NE, Atlanta, GA 30322-1013, 1970-'73, '75, '78, '81.

1988 (1970) Ballenger, John J., 660 Winnetka Mews, Winnetka, IL 60093-1968, 1971-'91, '93, '94.

1989 (1963) Baxter, James D., 1509 Sherbrooke St W, Apt 12, Montreal, Quebec H3G 1M1, Canada, 1963,

'65*-'74, '76-'80, '82, '85-'87.

1992 (1975) Boles, Roger, Dept of Otolaryngol, 739A, Univ of California, San Francisco, CA 94143, 1975-'82, '84-'89, '92, '93.

1988 (1959) Brewer, David W., 1100 E Genessee St, Syracuse, NY 13210, 1959, '60*-'62*, '63, '66, '70, '73, '74*, '77, '80, '81, '83, '85.

1990 (1963) Bryce, Douglas P., 82 Belmont St, Toronto, Ont, M5R 1P8 Canada, 1963*, '64, '66*, '67*, '68*-'79*, '81, '83-'87*-'91, '93.

1989 (1968) Chandler, J. Ryan, 1700 10th Ave NW, Miami, FL 33136, 1968, '69*-'79*-'84*-'91, '93.

1989 (1967) Cocke, Edwin W., Jr, 920 Madison, 1030, Memphis, TN 38103, 1967-'70, '72, '74-'78, '80, '82, '84, '86, '87, '89-'91.

1988 (1964) Cody, Claude C. III, 529 E Friar Tuck Lane, Houston, TX 77024, 1964, '65, '67, '69, '71, '73, '77-'79, '81, '83-'85, '87, '91.

1993 (1971) Cohen, Seymour R., 4301 Cromwell Ave, Los Angeles, CA 90027, 1971, '72*, '73*-'75*, '76*-'78*, '80*, '81*, '82*, '83*-'86*, '87*, '88*-'90*, '91*-'93*.

1985 (1966) Devine, Kenneth D., c/o Rick Colvin, Mayo Clinic, 200 First St SW, Rochester, MN 55905, 1966-'68, '72*, '74*, '76*.

1993 (1976) Doyle, Patrick J., 1081 Burrard, Vancouver, BC, V6Z 1Y6, Canada, 1976, '77*, '80*, '81*, '84, '86-'89, '91-'93*, '94.

1993 (1973) Duvall, Arndt J. III, Univ of Minnesota Hosp, Box 478, Minneapolis, MN 55455, 1973*, '75-'78, '80, '81, '84, '86, '88, '89.

1992 (1968) Farrior, Richard T., 4 Columbia Dr, 860, Davis Island, Tampa, FL 33606, 1968-'70*, '72, '74, '76-'81, '84-'90, '92, '94.

1992 (1964) Fearon, Blair, 170 St George St, 308, Toronto, Ont, M5R 2M8, Canada, 1964, '66-'71*, '72*, '73*, '74*-'78*-'81*, '82-'85*-'92.

1982 (1963) Ferguson, Charles F., 5281 Cape Leyte Way, Sarasota, FL 34242, 1963, '64*, '66, '67*-'69*-'74*-'78*-'82, '88.

1988 (1970) Frazer, John P., 329 Orchard Park Blvd, Rochester, NY 14609, 1971-'82, '86, '88.

1983 (1956) Friedberg, Stanton A., 5825 S Dorchester Ave, 15W, Chicago, IL 60637, 1956, '57, '65*, '71*, '76*, '78*, '79*, '80, '82, '83*-'85.

1980 (1965) Hanckel, Richard W., Jr, 1167 S Sherwood Dr, Florence, SC 29501, 1965-'67, '69-'74, '77-'80.

1968 (1942) Heatley, Clyde A., 1570 East Ave, 412, Rochester, NY 14610, 1942, '46*, '49, '50, '52, '53*-'55, '57, '58, '60, '61, '65.

1980 (1955) Hilger, Jerome A., 1700 S Lexington Ave, 409, St Paul, MN 55118, 1955-'56*-'60, '62-'66, '68-'71, '75-'78, '80, '82.

1977 (1957) Holmes, Edgar M., PO Box 121, S Orleans, MA 02662-0121, 1957, '59, '61, '63, '68, '70-'72, '74-'76, '80.

1991 (1975) Kirchner, Fernando R., 6860 N Terra Vista, Tucson, AZ 85715, 1975*-'77, '79, '82*, '84, '86, '90.

1990 (1979) LeJeune, Francis E., Jr, 1514 Jefferson Hwy, New Orleans, LA 70121, 1979-'82*, '83*-'87*, '88, '90, '92.

1991 (1966) Lewis, John S., 245 Nyac Ave, Pelham, NY, 10803, 1966-'69*, '72, '74-'76*, '78-'83*-'87*-'89, '91, '94.

1983 (1961) Lewy, Robert B., 5532 S Shore Dr, 9E, Chicago, IL 60637, 1961, '62*, '63, '65*, '67-'71, '73-'76*, '82, '83*-'90, '92*.

1989 (1976) Lingeman, Raleigh E., Riley Hosp, A56, 702 Barnhill Dr, Indianapolis, IN 46223, 1976, '77*-'82*, '84, '86, '88, '89, '93.

1989 (1973) Loré, John M., Jr, 2121 Main St, 208, Buffalo, NY 14214, 1974*, '76, '77*, '78*, '81, '85-'87*, '88, '90, '91, '93.

1993 (1978) Lyons, George D., Louisiana State Univ School of Med, New Orleans, LA 70112, 1978-'80, '82-'84, '88, '89, '92, '93*.

1992 (1966) McCabe, Brian F., Dept of Otolaryngol, Univ Hosp, Iowa City, IA 52242, 1966, '69, '72*, '73, '75*, '76, '79*, '81*, '85, '86*, '87*, '88*, '89.

1991 (1976) Miglets, Andrew W., Jr, 410 W 10th Ave, Columbus, OH 43210, 1976-'78*, '80, '82, '85, '90.

1990 (1964) Montgomery, William W., 243 Charles St, Boston, MA 02114-3004, 1964, '65*, '66*, '68*, '70-'72, '74*-'76*-'78, '80*-'82, '84-'88*, '90-'92*, '93, '94*.

1985 (1972) Morse, Harry R., 117 Nelson's Grove Rd, Lakeville, MA 02347, 1972, '75, '79-'81, '87.

1992 (1972) Pennington, Claude L., 800 First St, 100, Macon, GA 31210, 1972, '73, '75, '76*, '78, '82-'89.

1991 (1967) Pratt, Loring W., 37 Lawrence Ave, Fairfield, ME 04937, 1967-'82, '84*-'87*, '88, '91-'94.

1976 (1951) Priest, Robert E., 48 Groveland Terrace, 414, Minneapolis, MN 55403, 1977-'81.

1980 (1951) Putney, F. Johnson, 705 Knotty Pine Rd, Charleston, SC 29412, 1951-'53*-'58*-'63*, '64*-'68*, '69*, '70*-'72, '74-'78*, '79*, '82, '86.

1989 (1963) Reed, George F., 750 E Adams St, Syracuse, NY 13210, 1963, '65*, '66, '68, '69*-'73, '75-'82*-'89, '92.

1993 (1974) Ritter, Frank N., 2675 Englave Dr, Ann Arbor, MI 48103, 1974, '75, '77-'79, '81-'94.

1989 (1964) Saunders, William H., 4102 Univ Hosp Clinic, 456 Clinic Dr, Columbus, OH 43210-1240, 1964-'66, '68*-'70*-'75*-'80, '82*-'84, '86-'89, '92, '93.

1990 (1979) Shapiro, Myron J., 185 S Orange Ave, H586, Newark, NJ 07103, 1979-'81, '84, '86, '88, '89.

1977 (1958) Simonton, Kinsey M., 1000 Vicar's Landing Way, F203, Ponte Vedra Beach, FL 32082, 1958, '59*, '62, '64, '66, '67, '69, '72, '74, '75, '78, '82, '84.

1989 (1962) Sisson, George A., 303 Chicago Ave, Chicago, IL 60611, 1962, '63*, '65, '66, '68-'73, '76-'82, '84*, '85*-'88*-'90*, '91.

1988 (1972) Soboroff, Burton J., 307 N Michigan Ave, Chicago, IL 60601, 1972-'77, '79, '80, '82, '86, '88, '89, '91.

1990 (1975) Sprinkle, Philip M., 125 N Sixth St, Clarksburg, WV 26301, 1975-'78*-'82, '84-'89.

1990 (1975) Strong, M. Stuart, 35 Laurel Rd, Weston, MA 02193, 1975, '76*-'78*, '79*, '81, '82*-'84*-'86*-'93.

1981 (1961) Suehs, Oliver W., 2805 Robbs Run, Austin, TX 78703, 1961, '62*-'64, '66, '68-'72, '74-'78, '80.

1988 (1963) Tabb, Harold G., 1430 Tulane Ave, New Orleans, LA 70112-2699, 1963, '65-'69, '71, '72, '74, '77-'84, '86-'90, '92.

1983 (1954) Thornell, William C., 3516 Traskwood Circle, Cincinnati, OH 45208-1810, 1957, '59, '63, '68, '70, '72, '74, '77, '78, '80.

1973 (1963) Tolan, John F., 3419 47th Ave NE, Seattle, WA 98105, 1963-'67, '69, '71, '73.

1993 (1978) Toomey, James M., 150 S Huntington Ave, Boston, MA 02130-4820, 1979*-'81, '90.

1977 (1962) Weaver, Delmar F., Medical Professional Bldg, PO Box 862, Culpepper, VA 22701, 1962-'64*, '65, '67*, '69, '70, '72, '74, '76.

1983 (1971) Williams, Russell I., 414 E 23rd St, Cheyenne, WY 82001, 1971, '72*-'74, '76-'78*, '80.

1975 (1953) Work, Walter P., 172 E Paseo de Golf, Green Valley, AZ 85614, 1953, '54, '56, '58, '59*, '62, '63*, '65, '67-'69, '72, '73, '75, '76, '78*, '79*, '82, '87.

OFFICERS 1994-1995

≈

PRESIDENT
H. BRYAN NEEL III, MD, PHD

VICE-PRESIDENT (PRESIDENT-ELECT)
PAUL H. WARD, MD

SECRETARY
GERALD B. HEALY, MD

TREASURER
ROBERT W. CANTRELL, MD

HISTORIAN-EDITOR
ERNEST A. WEYMULLER, JR, MD

FIRST COUNCILOR
JOHN M. FREDRICKSON, MD

SECOND COUNCILOR
WILLIAM R. HUDSON, MD

THIRD COUNCILOR
H. BRYAN NEEL III, MD, PHD

COUNCILORS-AT-LARGE
JOYCE A. SCHILD, MD
ROBERT H. MATHOG, MD

INDEX

AUTHORS

A

Adkins WY Jr 8
Anthony JP 77
Armstrong WB 118, 153

B

Bailey BJ 15, 19, 26
Berke GS 101
Biller HF 153
Briant TD 23

C

Cantrell RW 9
Cappellari JO 60
Castracane J 110
Conerty M 110
Cooper DS 34
Courey MS 65
Cummings CW 153

D

Deschler DG 77
deTar M 85
Detar TR 118
Dienes H-P 127
Doherty ET 77

E

Eckel HE 135

F

Flint PW 153

G

Gardner GM 65, 110
Geisinger KR 60
Goel R 153
Greven KM 60

H

Hall D 153
Hast MH 34
Haughey BH 147
Healy GB 8, 42
Hetherington HE 141
Hillman RE 72, 96
Hinni M 127
Hisa Y 56
Hood LE 28

I

Ibata Y 56

K

Keyes JW Jr 60
Kokoska MS 147

L

Luken L 153

M

Mann WJ 127
Marwaha S 153
McGill T 42
McGuirt WF 60
Montgomery WW 72, 96
Myers EN 9

N

Nasri S 101
Netterville JL 153

O

Ohlms LA 42
Okamura H 56
Ossoff RH 65, 153

P

Panje WR 141
Pankratov MM 89
Parnes SM 110
Perrault DF Jr 89
Piccirillo JF 147
Polanyi JC 24

R

Rebeiz EE 89
Reed CG 77
Rice DH 34, 85

S

Sanders I 153
Schild JA 26
Sercarz JA 101
Sessions RB 49
Shapshay SM 89
Shindo M 34, 85
Silverman PM 49
Singer MI 77
Sinha U 34
Stanley RB 118
Stone RE 65, 153

T

Tadaki N 56
Taguchi J 56
Thumfart M 135
Thumfart WF 135
Troost TR 49

U

Uno T 56

V

Varvares MA 72, 96
Vössing M 135

W

Wang Z 89
Ward PH 8, 20
Wassermann K 135
Watson NE Jr 60
Welkoborsky H-J 127
Weymuller EA Jr 27
Williams DW III 60
Wu B-L 153

Z

Zaretsky LS 85
Zeiberg AS 49
Zeman RK 49

SUBJECTS

A

American Laryngological Association Award
- Presentation ... 23
- Recipients ... 14
- Response ... 24

Annual photograph ... 4

Arytenoidectomy
- Cordectomy versus arytenoidectomy in management of bilateral vocal cord paralysis ... 135

Awards
- American Laryngological Association, Casselberry, De Roaldes, Newcomb, Resident Research, Gabriel F. Tucker, Young Faculty Research Award ... 13

C

Cervical injury
- Diagnosis and management of external penetrating cervical esophageal injuries ... 118

Child
- Malignant laryngeal tumors in children: 15-year experience with four patients ... 42

Complication
- Teflon granuloma of larynx: etiology, pathophysiology, and management ... 96

Computed tomography
- Three-dimensional imaging of hypopharynx and larynx by means of helical (spiral) computed tomography. Comparison of radiological and otolaryngological evaluation ... 49

Conservation
- "Window" laryngoplasty: new combined laser endoscopic and open technique for conservation surgery ... 89

Cordectomy
- Cordectomy versus arytenoidectomy in management of bilateral vocal cord paralysis ... 135

D

Daniel C. Baker, Jr, Memorial Lecture
- Introduction ... 27
- Lecture ... 28

Discussions ... 154

DNA
- Predicting recurrence and survival in patients with laryngeal cancer by means of DNA cytometry, tumor front grading, and proliferation markers ... 127

Dynamic properties
- Dynamic properties of posterior cricoarytenoid muscle ... 34

E

Electronic speckle pattern interferometry
- Electronic speckle pattern interferometry of vibrating larynx ... 110

Endoscopy
- Endoscopic vocal fold microflap: three-year experience ... 65
- "Window" laryngoplasty: new combined laser endoscopic and open technique for conservation surgery ... 89

Esophagus
- Diagnosis and management of external penetrating cervical esophageal injuries ... 118

Executive Sessions
- Minutes ... 7
- Reports ... 8

F

Fat
- Autologous fat injection for vocal fold paralysis: long-term histologic evaluation ... 85

Fellows
- Deceased ... 173
- Registration ... 6
- Roster ... 177

Flap
- Endoscopic vocal fold microflap: three-year experience ... 65
- Tracheoesophageal voice following tubed free radial forearm flap reconstruction of neopharynx ... 77

Follow-up
- Malignant laryngeal tumors in children: 15-year experience with four patients ... 42

G

Gabriel F. Tucker Award
- Presentation ... 26
- Recipients ... 13
- Response ... 26

Gender
- Gender differences in cancer of larynx ... 147

Graft
- Jejunal graft reconstruction of pharyngoesophageal defects without microvascular anatomoses ... 141

Granuloma
- Teflon granuloma of larynx: etiology, pathophysiology, and management ... 96

Guest of Honor
- Address ... 20
- Introduction ... 19

H

Helical computed tomography
- Three-dimensional imaging of hypopharynx and larynx by means of helical (spiral) computed tomography. Comparison of radiological and otolaryngological evaluation ... 49

Hydroxylapatite
- Comparison of soft tissue response in rabbits following laryngeal implantation with hydroxylapatite, Silastic, and Teflon (abstract) ... 153

I

Imaging
- Positron emission tomography in evaluation of laryngeal carcinoma ... 60

Three-dimensional imaging of hypopharynx and larynx by means of helical (spiral) computed tomography. Comparison of radiological and otolaryngological evaluation 49

Inferior constrictor
Combined thyroplasty type I and inferior constrictor myotomy 72

Injection
Autologous fat injection for vocal fold paralysis: long-term histologic evaluation 85

Injury
Diagnosis and management of external penetrating cervical esophageal injuries 118

Innervation
Neuropeptide participation in canine laryngeal sensory innervation. Immunohistochemistry and retrograde labeling 56

Interferometry
Electronic speckle pattern interferometry of vibrating larynx 110

J

Jejunum
Jejunal graft reconstruction of pharyngoesophageal defects without microvascular anastomoses 141

L

Laryngoplasty
Laryngoplastic medialization and arytenoid adduction: quantitative and qualitative analysis of voice improvement (abstract) 153

M

Malignancy
Malignant laryngeal tumors in children: 15-year experience with four patients 42

Medialization
Laryngoplastic medialization and arytenoid adduction: quantitative and qualitative analysis of voice improvement (abstract) 153

Memorial Fund, Laryngological Research Fund 14

Memorials
John E. Bordley, MD 164
John B. Erich, MD 165
Wilbur J. Gould, MD 166
Luzius Ruedi, MD 167
Emanuel M. Skolnick, MD 169

Metastasis
Positron emission tomography in evaluation of laryngeal carcinoma 60

Microflap
Endoscopic vocal fold microflap: three-year experience 65

Muscle
Combined thyroplasty type I and inferior constrictor myotomy 72
Dynamic properties of posterior cricoarytenoid muscle 34
Phonatory specialization of human laryngeal muscles (abstract) 153

N

Neuropeptide
Neuropeptide participation in canine laryngeal sensory innervation. Immunohistochemistry and retrograde labeling 56

O

Officers
1879-1993 170
1993-1994 5
1994-1995 182

P

Paralysis
Autologous fat injection for vocal fold paralysis: long-term histologic evaluation 85
Cordectomy versus arytenoidectomy in management of bilateral vocal cord paralysis 135

Phonation
Phonatory specialization of human laryngeal muscles (abstract) 153

Positron emission tomography
Positron emission tomography in evaluation of laryngeal carcinoma 60

Posterior cricoarytenoid muscle
Dynamic properties of posterior cricoarytenoid muscle 34

Presidential Remarks 15

Prognosis
Gender differences in cancer of larynx 147

R

Reconstruction
Jejunal graft reconstruction of pharyngoesophageal defects without microvascular anastomoses 141
Tracheoesophageal voice following tubed free radial forearm flap reconstruction of neopharynx 77

Recurrence
Predicting recurrence and survival in patients with laryngeal cancer by means of DNA cytometry, tumor front grading, and proliferation markers 127

Reports
Historian-Editor 8
Liaison of the American Board of Otolaryngology 9
Representative to the Board of Governors of the American College of Surgeons 8
Secretary 8
Treasurer 9

S

Sensory innervation
Neuropeptide participation in canine laryngeal sensory innervation. Immunohistochemistry and retrograde labeling 56

Sex
Gender differences in cancer of larynx 147

Silicone
Comparison of soft tissue response in rabbits following laryngeal implantation with hydroxylapatite, Silastic, and Teflon (abstract) 153

Specialization
Phonatory specialization of human laryngeal muscles (abstract) 153

Survival
Predicting recurrence and survival in patients with laryngeal cancer by means of DNA cytometry, tumor front grading, and proliferation markers 127

T

Teflon
Comparison of soft tissue response in rabbits following laryngeal implantation with hydroxylapatite, Silastic, and Teflon (abstract) 153
Teflon granuloma of larynx: etiology, pathophysiology, and management 96

Thyroplasty
Combined thyroplasty type I and inferior constrictor myotomy 72

Traveling wave velocity
Noninvasive measurement of traveling wave velocity in canine larynx 101

V

Velocity
Noninvasive measurement of traveling wave velocity in canine larynx 101

Vibration
Electronic speckle pattern interferometry of vibrating larynx 110

Voice
Laryngoplastic medialization and arytenoid adduction: quantitative and qualitative analysis of voice improvement (abstract) 153
Tracheoesophageal voice following tubed free radial forearm flap reconstruction of neopharynx 77

W

Wave
Noninvasive measurement of traveling wave velocity in canine larynx 101

Window laryngoplasty
"Window" laryngoplasty: new combined laser endoscopic and open technique for conservation surgery 89